

Practical Manual of Tricuspid Valve Diseases

Osama I. Soliman
Folkert J. ten Cate
Editors

EXTRAS ONLINE



Springer

Practical Manual of Tricuspid Valve Diseases

Osama I. Soliman • Folkert J. ten Cate
Editors

Practical Manual of Tricuspid Valve Diseases

 Springer

Editors

Osama I. Soliman
The Thoraxcenter, Erasmus MC:
University Medical Center Rotterdam
Rotterdam
The Netherlands

Folkert J. ten Cate
The Thoraxcenter, Erasmus MC:
University Medical Center Rotterdam
Rotterdam
The Netherlands

ISBN 978-3-319-58228-3 ISBN 978-3-319-58229-0 (eBook)
DOI 10.1007/978-3-319-58229-0

Library of Congress Control Number: 2017955549

© Springer International Publishing AG 2018

This work is subject to copyright. All rights are reserved by the Publisher, whether the whole or part of the material is concerned, specifically the rights of translation, reprinting, reuse of illustrations, recitation, broadcasting, reproduction on microfilms or in any other physical way, and transmission or information storage and retrieval, electronic adaptation, computer software, or by similar or dissimilar methodology now known or hereafter developed.

The use of general descriptive names, registered names, trademarks, service marks, etc. in this publication does not imply, even in the absence of a specific statement, that such names are exempt from the relevant protective laws and regulations and therefore free for general use.

The publisher, the authors and the editors are safe to assume that the advice and information in this book are believed to be true and accurate at the date of publication. Neither the publisher nor the authors or the editors give a warranty, express or implied, with respect to the material contained herein or for any errors or omissions that may have been made. The publisher remains neutral with regard to jurisdictional claims in published maps and institutional affiliations.

Printed on acid-free paper

This Springer imprint is published by Springer Nature
The registered company is Springer International Publishing AG
The registered company address is: Gewerbestrasse 11, 6330 Cham, Switzerland

*To our families for their loving support
and inspiration.*

Preface

Why Do We Need This Book?

Since the conception of the first aortic valvular intervention in 1912, it took the medical and surgical cardiology community over four decades to perform the first tricuspid valvular intervention in 1954. Technological advancement now is relatively faster; while the first transcatheter aortic valve replacement took place in 2002, transcatheter tricuspid valve repair/replacement was attempted in men in 2010. The tricuspid valve has become subject of interest in order to replicate the success in the aortic and pulmonary interventions. It is for sure no more the “forgotten valve.”

We have learned and greatly benefited from the 15 years of experience in aortic valve interventions. There is a need for understanding anatomical and imaging requirements as well as anticipating and understanding complications. Recently, first-in-man experience of completely percutaneous tricuspid valve repair to treat severe tricuspid regurgitation has been performed in a few structural heart centers of excellence. There is a need as well as an opportunity to begin with tricuspid valve interventions from where aortic valve interventions reached so far.

This book is written by world-renowned experts in cardiology and cardiothoracic surgery. It provides a comprehensive but concise overview of tricuspid valve disease in adults, which is relevant in daily practice.

This book includes 19 chapters divided into 5 parts or perspectives. In Part I, the authors provide a perspective on the anatomy and pathology of the tricuspid valve. In Part II, the authors discuss clinical perspective of tricuspid valve disease with attention to special populations of patients with TVD due to pacemakers and post-heart transplant. Part III provides detailed imaging perspective that covers noninvasive imaging. Readers will learn about measurements of tricuspid annulus and quantification of right heart function. Part IV highlights hemodynamic approach to tricuspid valve disease as well as right heart catheterization. Therapeutic options of tricuspid valve disease are thoroughly discussed in Part V. Readers can learn about current technique, risk stratification, and outcome of current therapy for tricuspid

valve disease. Furthermore, heart team discussion, tips, and tricks for tricuspid valve interventions are discussed.

The book has an educational goal. Key messages are highlighted at the end of each chapter. Review Questions at the end of each chapter is dedicated to test knowledge and give feedback on each individual chapter.

We sincerely thank all contributors, who are world-renowned experts in their respective area of interest, for their hard work. This book will serve as the standard reference regarding all aspects of tricuspid valve disease in adults. We expect that this work will be helpful to the readers and ultimately have a positive impact on the care of our patients.

Rotterdam, The Netherlands
Rotterdam, The Netherlands

Osama I. Soliman, M.D., Ph.D.
Folkert J. ten Cate, M.D., Ph.D.

Contents

Part I Anatomical and Pathological Perspective

- 1 Anatomy and Pathology of the Tricuspid Valve** 3
Karen P. McCarthy, Jan Lukas Robertus, and S. Yen Ho

Part II Clinical Perspective

- 2 Clinical Recognition of Tricuspid Valve Disease** 25
Ashraf M. Anwar, Folkert J. ten Cate, and Osama I. Soliman
- 3 Tricuspid Regurgitation in Patients with Heart Transplant** 49
Kadir Caliskan, Mihai Strachinaru, and Osama I. Soliman
- 4 Tricuspid Regurgitation in Patients with Pacemakers and Implantable Cardiac Defibrillators** 59
Yash Jobanputra, Jasneet Deygun, Mandeep Bhargava, and Samir Kapadia

Part III Non-invasive Imaging Perspective

- 5 Tricuspid Valve Disease: Imaging Using Transthoracic Echocardiography** 79
Osama I. Soliman, Jackie McGhie, Ashraf M. Anwar, Mihai Strachinaru, Marcel L. Geleijnse, and Folkert J. ten Cate
- 6 Imaging of the Tricuspid Valve: Transoesophageal Echocardiography** 117
Rebecca T. Hahn
- 7 A Surgeon's View on Echocardiographic Imaging of the Tricuspid Valve** 127
Kevin M. Veen, Folkert J. ten Cate, and Frans B. Oei

8	Imaging of the Tricuspid Valve: Magnetic Resonance Imaging	143
	Soha Romeih and Sara El Fawal	
9	Tricuspid Valve Disease: A Computed Tomographic Assessment . . .	179
	Rahatullah Muslem, Mohammed Ouhlous, Sakir Akin, Abd Alla Fares, and Osama I. Soliman	
10	Tricuspid Annulus Measurements: Dynamic Changes in Health and Disease	205
	Denisa Muraru and Luigi P. Badano	
11	Imaging of the Right Ventricle: Overview of Imaging Modalities for Assessing RV Volume and Function	221
	Annemien van den Bosch and Roderick van Grootel	
Part IV Hemodynamic Perspective		
12	Echocardiographic Assessment of Pulmonary Artery Pressure, Tips and Tricks.	235
	Anthonie L. Duijnhouwer and Arie P.J. van Dijk	
13	Right Heart Catheterization for Hemodynamic Evaluation of Right Sided Heart Disease	253
	Tim ten Cate, Tamara Aipassa, and Roland van Kimmenade	
Part V Therapeutic Perspective		
14	Pharmacotherapy of Tricuspid Valve Disease	273
	Kadir Caliskan	
15	Tricuspid Valve Interventions: Heart Team Discussion, When, Who and What?	279
	Joachim Schofer	
16	Tricuspid Valve Disease: Surgical Outcome	305
	Kevin M. Veen, Jonathan R.G. Etnel, and Johanna J.M. Takkenberg	
17	Tricuspid Valve Disease: Surgical Techniques	329
	Michele De Bonis, Benedetto Del Forno, Teodora Nisi, Elisabetta Lapenna, and Ottavio Alfieri	
18	Transcatheter Interventions for Tricuspid Regurgitation: Rationale, Overview of Current Technologies, and Future Perspectives	353
	Mohammad Abdelghani, Joachim Schofer, and Osama I. Soliman	
19	Catheter-Based Therapy for Tricuspid Valve Disease: Practical Considerations for Interventionalists	379
	Shingo Kuwata, Alberto Pozzoli, Francesco Maisano, and Maurizio Taramasso	
	Index	393

Part I
Anatomical and Pathological Perspective

Chapter 1

Anatomy and Pathology of the Tricuspid Valve

Karen P. McCarthy, Jan Lukas Robertus, and S. Yen Ho

Abstract The tricuspid valve (TV), the morphologically right atrioventricular valve, guards the inflow junction between the right atrium and right ventricle. In functional anatomy, the valve does not consist only of leaflets. Instead, the valve complex is comprised of the annulus, leaflets, tendinous cords and papillary muscles occupying the inlet part of the right ventricle. Right sided structures have not had the extensive analysis when viewed in comparison to the systemic mitral valve. This is possibly due to the complexity of measuring the geometrically unusual shape of the right ventricular cavity, tricuspid valve, the curvature of the muscular ventricular septum and the right ventricular cavity wrapping around the systemic left ventricle. The route of inflow to outflow in the low pressure right ventricle (RV) is elongated compared to the left side of the heart. The right ventricle itself is an anterior structure forming the sterno-costal border of the heart beneath the sternum. The tricuspid valve is always associated with a morphological right ventricle. The chamber can be arbitrarily demarcated into three regions: inlet, apical and outlet, hence the concept of a tripartite ventricle. But, there are no anatomic borders for these regions within the right ventricle. The inflow region of the tricuspid valve is separated from the outflow pulmonary valve by several muscular structures; the ventricular infundibular fold (VIF), septomarginal trabeculation (SMT), septoparietal trabeculations (SPT) and the free standing subpulmonary infundibulum musculature (Fig. 1.1). Adjacent along the atrial side tricuspid valve complex are important structures like the triangle of Koch, tendon of Todaro, atrioventricular node continuing into the bundle of His and coronary sinus orifice (Fig. 1.2). Continuing improvements of imaging methods such as echocardiography, cardiac magnetic resonance imaging and computed tomography to examine in detail and analyse these structures and to measure the flow of deoxygenated blood to the lungs from the right heart allows critical analysis and on-going follow up of patients in normal and disease states.

K.P. McCarthy (✉) • S. Yen Ho
Brompton Cardiac Morphology Unit, Royal Brompton & Harefield NHS Trust,
Sydney Street, London SW3 6NP, UK
e-mail: k.mccarthy@rbht.nhs.uk

J.L. Robertus
Histopathology Department, Royal Brompton & Harefield NHS Trust,
Sydney Street, London SW3 6NP, UK

Keywords Tricuspid • Valve • Annulus • Leaflets • Fibrous skeleton • Commissures • Papillary muscles • Stenosis • Regurgitation • Right ventricle • Right atrium

Components of the Tricuspid Valve

The tricuspid valve is a composite of several structures that work in synchrony in order to open during diastole and close in systole. This capability to open and close efficiently is controlled by the leaflets, tendinous cords, papillary muscles (themselves attached to the ventricular wall), and the annular attachment at the atrioventricular junction all working in concert. In situ, on the cardiac shadow, its orifice occupies a plane that is more vertically orientated than horizontal. Unlike the left heart valves, the tricuspid valve is remote from the pulmonary valve (Figs. 1.1, 1.2, and 1.3). It guards the exit of the right atrium where its orifice is surrounded by the smooth-walled atrial vestibule.

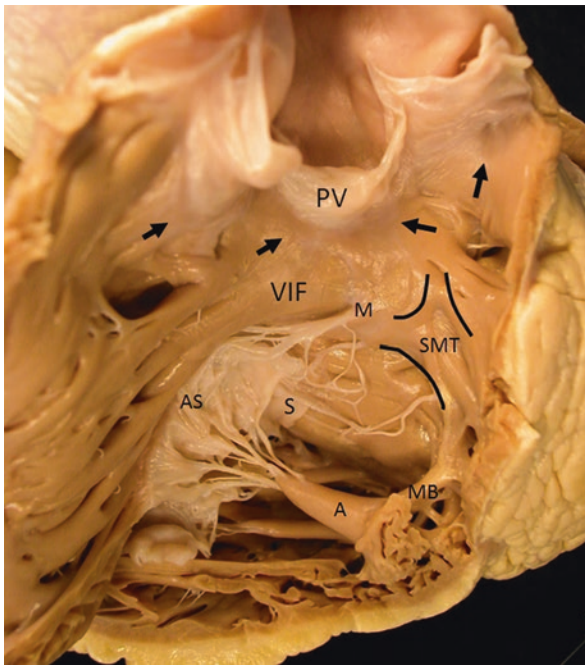


Fig. 1.1 This specimen demonstrates the medial and anterior papillary muscles as well as the moderator band extending from the apical trabeculations in the right ventricle. The right ventricular outflow tract has a 'Y' shaped muscle bundle called the septomarginal trabeculation (SMT). The muscle underneath the pulmonary valve is not part of the ventricular septum. This subpulmonary infundibulum can be dissected to liberate the pulmonary valve as in the Ross procedure. *AS* anterosuperior leaflet, *S* septal leaflet, *PV* pulmonary valve, *VIF* ventriculo-infundibular fold, *SMT* septomarginal trabeculation, *M* medial papillary muscle, *MB* papillary muscle, *Ant* anterior papillary muscle, *MB* moderator band, *Arrows* subpulmonary infundibulum

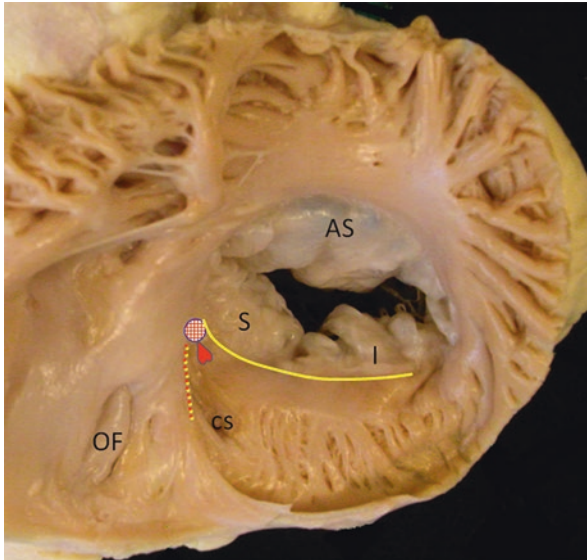


Fig. 1.2 Viewed from the right atrial aspect the position of the triangle of Koch can be located and the close association of the atrioventricular node (AVN) to the hingeline attachment point of the tricuspid valve at the right atrioventricular annulus. The triangle of Koch is demarcated by dotted lines marking the tendon of Todaro. The solid line marking the tricuspid valve attachment. The third border is the location of the coronary sinus. The hatched oval marks the position of the central fibrous body and the heart shape indicates the location of the atrioventricular node. AS anterosuperior leaflet, S septal leaflet, I inferior papillary muscle, CS coronary sinus, OF oval fossa

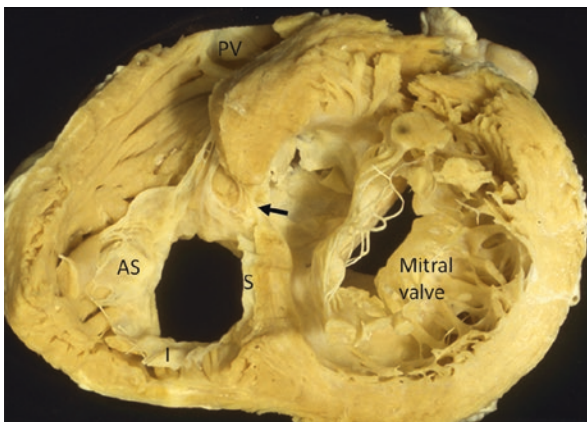


Fig. 1.3 In short axis section the position of tricuspid and pulmonary valves can be seen. The two valves are separated by musculature. From the ventricular aspect the orifice of the three tricuspid leaflets can be seen in relation to the mitral valve. The muscular ventricular separating the two atrioventricular valves has been removed in this specimen but a thin part of the septum, the membranous septum, is revealed. AS anterosuperior leaflet, S septal leaflet, I inferior leaflet, PV pulmonary valve, Arrow membranous septum

The tricuspid annulus (or hingeline) within the right ventricle demarcates the junction between the right atrial myocardium and right ventricular myocardium with the attachment of leaflets at this intersection. Although the term ‘annulus’ conveys the impression of a well formed fibrous ring-like structure separating atrial from ventricular myocardium, the leaflets of the tricuspid valve in reality are attached to a poorly formed fibrous annulus that is not as clear to delineate as with the mitral valve [1]. Even so, anatomically, the mitral annulus is also not as well defined as commonly thought [2]. Nevertheless, the term, ‘annulus’ continues to be used in the clinical arena in preference to ‘hingeline’. At the tricuspid annulus, musculature of the atrial wall overlaps minimally the atrial surface of the leaflets and the major portion is separated from ventricular wall by fibro-fatty tissues of the atrioventricular groove through which run the right coronary artery and branches of the coronary veins. While the initial course of the right coronary artery is relatively distant from the annulus, there is a gradual shortening of the distance to the endocardial surface toward the inferior segment of the annulus to <3 mm [3]. This has important implications for invasive intracardiac procedures whether it is to ablate accessory atrioventricular pathways for pre-excitation or to repair the tricuspid valve at the annular level.

The tricuspid orifice is larger than the mitral orifice [4] and in this low pressure environment the leaflets are thinner and more translucent [5]. The three dimensional shape of the tricuspid annulus changes not only during the dynamic low pressure cardiac cycle but during disease. This adds to the complexity of understanding the geometry of the valve and right ventricle. Anatomically, the right atrioventricular annulus is located in an almost vertical position and is oval in shape becoming round when dilated [6, 7]. The valve complex is saddle shaped forming a conduit to the right ventricle [8] although it is less saddle shaped than the mitral valve [9]. Owing to the near vertical location of the annulus, valve margins and the leaflets are described as anterosuperior, septal and inferior. There is variation in the annular conformation of the valve between systole and diastole [6] this change is significant and a reduction of 19% in annular circumference during systole has been found [10]. The tricuspid annulus has its highest point at the anteroseptal commissure and its lowest point at the posteroseptal commissure [11]. With enhanced imaging more precise anatomical description may need to be employed to describe the valve during the cardiac cycle.

The normal dimensions of the tricuspid annulus in men and women, have been determined in various clinical studies (3.15 ± 0.4 cm diastolic diameter in males and 3.01 ± 0.47 cm diastolic diameter in females) [12] as well as pathological studies of normal hearts where the annular circumference for males was 11.4 ± 1.1 cm and 10.8 ± 1.3 cm for females [13]. This analysis of the normal morphology is essential in diagnosing altered pathophysiology, to establish if dilatation of the annulus is progressing to regurgitation and to appreciate that the annulus dimensions change during the cardiac cycle. In experimental studies during sinus rhythm the annular size was reduced by 20–39%. Less narrowing of the annulus was also noted with increased heart rates [14].

The Tricuspid Leaflets and Commissures

In our study of 50 heart specimens only 62% had three readily identifiable leaflets whereas 30% could be described as having two leaflets and 8% had four leaflets. But, in the same study, a review of a series of cross sectional echocardiograms showed three definite lines of closure in all cases [15]. The trifoliate configuration of the leaflets can be seen from the right atrial aspect when the valve is closed in systole thus preventing back flow of blood back into the right atrium (Fig. 1.4). Complete closure and apposition of the leaflets is essential in preventing regurgitation and maintaining ventricular pressure. Proper valve function is controlled by a number of factors including the contraction of the papillary muscles and ventricular wall. But there is also a 'spectrum of normality' in the variation of tendinous cord attachment to the tricuspid valve. The leaflets are tethered down by an elegant arrangement of cords attached to papillary muscles and the septum; this prevents ballooning of the leaflets back into the right atrium.

The leaflets of the valve do not all lie in the same plane [16] and the attachment is described as non-planar [17]. Each leaflet is unique and all have variation in shape, scallop indentations along the elongated free edge and attachment in the normal valve [18, 19] as well as in disease conditions. Normal variations as well as remodelling due to disease need to be appreciated.

The three leaflets of the tricuspid valve should be designated according to their location as anterosuperior, inferior and septal. The anterosuperior leaflet has been labelled anterior while the inferior leaflet has been labelled posterior or mural in

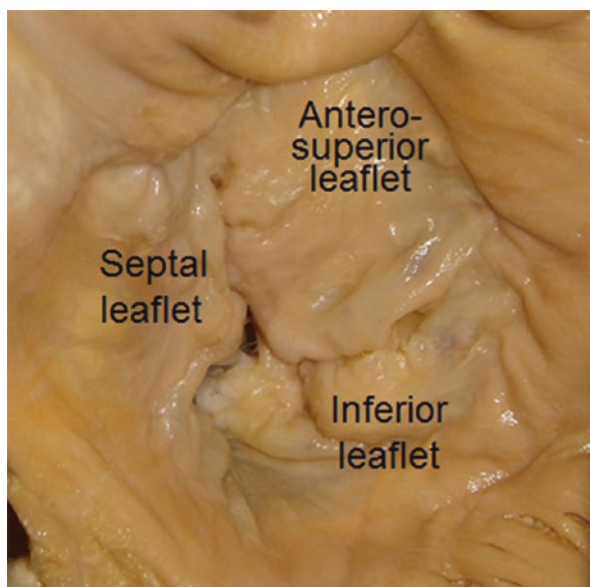


Fig. 1.4 Viewed from the right atrium the trifoliate arrangement of the three leaflets when in closed position can be seen

other reports. All leaflets are attached like a hinge at the annulus of the right atrio-ventricular junction, leading to the use of the term hinge-line. All three are noticeably dissimilar in shape and size to each other. The posteroseptal portion of the leaflets is near to the coronary sinus. Taking the plane of the annulus as a whole, the anterolateral portions of the leaflets are nearest to the apex and posterolateral nearer the right atrium. Each leaflet has variable number of scallops along the free edge and is attached within the ventricle via the cords and papillary muscles. Some papers have previously defined the tricuspid valve as having more than three leaflets or cusps [20, 21] and subdivision by scallops of the leaflets has also been described [13]. The general agreement is that there are three tricuspid leaflets which may or may not have scallops.

Viewed from the right atrial aspect the tricuspid valve orifice is roughly triangular in appearance with the three leaflets closing together resulting in a large area of coaptation. The anterosuperior leaflet is the largest and most extensive leaflet that extends curtain-like around approximately half the free wall of the right ventricle from the infundibular outflow region to the inferior part of the right ventricle. Anatomically, the inferior/mural leaflet occupies an inferior location and originates from the diaphragmatic parietal wall of the right ventricle and is also described as the inferior or in older literature as the posterior leaflet.

The septal leaflet is more complex than the anterosseptal and inferior leaflets. This leaflet has been described as occupying the smallest portion of the annulus [8, 22] while other studies describe the mural leaflet as the smallest [23]. From the septal leaflet tendinous cords attach directly to the muscular ventricular septum. This is one of the characteristic features of the tricuspid valve seen with diagnostic imaging that distinguishes it from the mitral valve which does not normally have cordal attachments to the septum. The restricted size of the septal leaflet and the multiple tendinous cord attachments along the septal leaflet directly to the septum results in a different range of movement compared to the other two tricuspid leaflets whose cord attachments have a different morphology [8, 17].

The septal leaflet attachment across the membranous septum divides it into two; a right atrial to right ventricular component which is superior (atrial) to the tricuspid valve and an interventricular component between both ventricles and inferior to the tricuspid valve leaflet. The septal leaflet has one other distinct feature seen with cross sectional imaging and that is its more apically located annular attachment in contrast to the mitral valve. This offset attachment is a key feature seen in diagnostic cross-sectional imaging in the four-chamber plane that aids identification of ventricular morphology in congenital heart disease.

Corresponding to the three leaflets configuration, there are three commissures or peaks of apposition between adjacent leaflets. It is important, however, to appreciate that although 'tricuspid' denotes three leaflets, there is no separation of one leaflet from another in that the three leaflets are arranged like a skirt and commissures between the leaflets do not extend all the way to the level of the annulus. Instead, continuity between adjacent leaflets is preserved by at least 5 mm of leaflet tissue along the annulus. This continuity is crucial for maintaining integrity of the valve when the leaflets come together in apposition. As mentioned above, the septal leaflet

crosses the membranous septum. It swings ‘around the corner’, away from the septum into the antero-superior leaflet. Thus, the antero-septal commissure attached to the medial papillary muscle is away from the septum. Interestingly, at the membranous septum, it is not uncommon to find a gap in the septal leaflet. Leaflet tissue around this area is usually adequate to provide apposition to close the orifice.

From the attachment of the leaflet at the annulus to the free edge, the tricuspid leaflet has specific zones [13]. The clear zone comprises the majority of the leaflet and is the thin translucent central portion and generally comprises two-thirds of the leaflet length from the annulus toward the free margin.

The basal zone is the portion of the leaflet attached to the annulus at the atrioventricular junction at this connection point there is vascularisation and innervation to the leaflet. This is the junction where atrial myocardium inserts at the annulus. The rough zone forms the free edge and the region of apposition, forming approximately a third of the leaflet length. This thicker portion of the leaflet contains more glycosaminoglycans allowing cushioning of the leaflet edges as they oppose during closure. These zones emphasise that the morphology is not uniform macroscopically or microscopically throughout the leaflet.

In cross section, each leaflet extends from the annulus hinge line proximally to the free edge distally. The normal tricuspid valve has a layered leaflet arrangement of the atrialis, spongiosa, fibrosa and ventricularis layers surrounded by a layer of endothelial cells which is continuous with the luminal surface of the atrium and the ventricle. In the tricuspid valve the leaflet comprises interstitial fibroblasts and connective tissue fibres within an extracellular matrix.

The atrialis is the uppermost layer. When the valve is in closed position, the atrialis faces directly the right atrium. This layer is composed of mainly aligned elastic and collagen fibres covered with overlying endothelium. Of the layers, the atrialis has the most elastic fibres [24]. Beneath the atrialis is the spongiosa layer. This layer is composed largely of an extracellular matrix of proteoglycans and glycosaminoglycans, along with elastic fibres. The glycosaminoglycans and proteoglycans are hydrophilic and attract water molecules. This causes the extracellular matrix to expand and swell at the free edge, providing a natural physical protective buffer to the leaflet. The spongiosa functions as a physiological ‘shock absorber’. It provides a structural cushion along the point of apposition to offset the effect of leaflet closure at the free edge.

Beneath the spongiosa is the fibrosa layer which is the major load-bearing layer, comprising the central structural collagenous core [5] of compact and aligned collagen fibres to the leaflet. The fibrosa layer extends from the annulus into two thirds of the leaflet and is absent at the free edge. The final layer of the tricuspid leaflet is the ventricularis, this layer is covered by a continuous sheet of endothelial cells that overlie elastic fibres and collagen fibres. The thickness of each layer varies from the attachment site at the annulus to the free edge. At the proximal region of the leaflet, near the annulus, the fibrosa is the thickest layer providing the structural core of the leaflet. The spongiosa and atrialis in contrast are relatively thin at the annulus attachment point of the leaflet, but increase in thickness distally, becoming the main component of the leaflet at the free edge.

Histologically, the extracellular matrix surrounds the connective tissue fibres in the leaflet and is a dynamic substrate of neutral pH [25]. The leaflet is composed of the glycosaminoglycan hyaluronic acid and proteoglycans such as aggrecan, decorin, versican [26–28] as well as fibroblast cells, some with variable phenotypes exhibiting actin filaments [29].

The maintenance of connective tissue integrity is fundamental in determining the overall strength and competence of the leaflet. This depends upon a continued balance between synthesis of the matrix components, their deposition and repair within the leaflet and the degradation of the tissue elements. Metalloproteinase enzymes, synthesised from fibroblasts, regulate the renewal and turnover of matrix components in connective tissues [30] within the human cardiac valves [31].

Under normal physiological conditions, the extracellular matrix comprising fibrillar proteins of the normal leaflet undergoes constant turnover of constituents to maintain both structure and function with the expression various proteins, including the contractile proteins troponin [32] and myosin [33]. These factors contribute in determining the overall structural integrity of the leaflets. External factors, such as mechanical stresses exerted on the valve leaflet, may also trigger secondary physiological responses affecting the structure and function of the leaflet.

Collagen fibres are the major component of atrioventricular leaflets and have an important role in defining shape, integrity and mechanical strength. Collagen fibres are produced from interstitial fibroblasts and endothelial cells [34, 35]. The alignment of collagen provides mechanical strength required for the repeated opening and closing of the valve. Elastic fibres interconnect with the collagen fibrils and bundles and promote recoil ensuring the leaflet and tendinous cord can return to the resting state.

The pH of the extracellular matrix environment affects the morphology of the fibres. Normal collagen fibres in the tissues are tightly packed and interspersed with smaller homogenous fibrils [36]. These are stable within a near neutral pH [37] but if the pH is altered, as seen in studies on collagen fibre development in chicks where the pH was more acidic, the collagen fibres synthesised can have variable diameters [38].

Matrix enzymes such as matrix metalloproteinases (MMP) and tissue inhibitor of matrix metalloproteinases (TIMP) can also act on collagen fibres [30] to remodel the leaflet tissue.

Tendinous Cords and Papillary Muscles

The slender and fibrous tendinous cords are the key interconnecting structure tethering the leaflets to the papillary muscles ensuring a functional and efficient valve. In the normal valve, leaflet cords and interleaflet cords have been identified. Fan-shaped tendinous cords insert at the junction between each leaflet, facilitating the bringing together and separation of adjacent leaflets as the valve closes and opens. These are the interleaflet cords and they have multiple connections between

adjacent leaflet connecting to the papillary muscles. Leaflets cords include rough zone tendinous cords which insert directly to the ventricular surface of the leaflet. The thicker ones are sometimes referred to as strut cords as they bear the mechanical load during valve opening and closing. On the ventricular aspect of the leaflet there are also attachments of tendinous cords to the rough and clear zones of the leaflet and these are termed deep cords. Basal cords can be found attaching the underside of the leaflets close to the annulus directly to the ventricular wall. Further leaflet cords also attach to the free edge of the leaflet and these are simply described as free-edge cords. The multiple attachments of the tendinous cords along the leaflets result in greater support and control of the valve.

Although the papillary muscles are not as uniformly distributed as in the mitral valve, the anterior papillary muscle sited in the right ventricle is usually well-defined, supporting the antero-superior leaflet in its midportion. Usually, there is a cluster of smaller papillary muscles located laterally or inferiorly in the right ventricle and these support the inferior as well as the antero-superior leaflets. Supporting the commissure between the septal and antero-superior leaflets is a small papillary muscle called the medial (or conal) papillary muscle, also known as the muscle of Lancisi. Variability in number of papillary muscles has been noted as well as the papillary muscle group having multiple heads [39, 40].

The papillary muscles are extensions of trabecular myocardium extending from the apical portion of the right ventricle and are highly innervated, highly vascularised with a central artery, and carry the distal ramifications of the Purkinje fibre network. The most common pattern of coronary supply to the right ventricle and papillary muscles is via the dominant right coronary artery running within the right atrioventricular groove. Histologically, the cords are formed of a collagen core with elastic fibres surrounded by endothelial cells. The mechanical load is supported by the collagen fibres during systole.

The anterior papillary muscle is the largest of the three papillary muscles and usually is composed of a distinct conical muscle with multiple heads with cords attached, hence it is described as bifid or trifid. Sometimes, there are several papillary muscles fused together or there is a dominant papillary muscle with adjoining smaller papillary muscles. They are located between the anteroseptal leaflet and the inferior leaflet. Additionally, further support from smaller anterior muscles is provided to the anterior segment of the leaflet (Fig. 1.5). The anterior papillary muscle extends from the apical portion of the right ventricle. It usually arises or continues from the moderator band as the latter muscle band crosses the right ventricular cavity. The origin of the anterior papillary muscle from the moderator band can be midway along the band or close to where the band itself fuses with the right ventricular free wall, on cross sectional imaging, recognising the moderator band is one way of distinguishing the morphologically right ventricle from a left ventricle. Apart from the distinctive moderator band, the right ventricular chamber is criss-crossed by further muscle bundles termed trabeculations and these mainly occupy the apical portion. They interconnect extending from the septal to the apical and parietal walls and these trabeculations are coarse in comparison to those in the left ventricle.

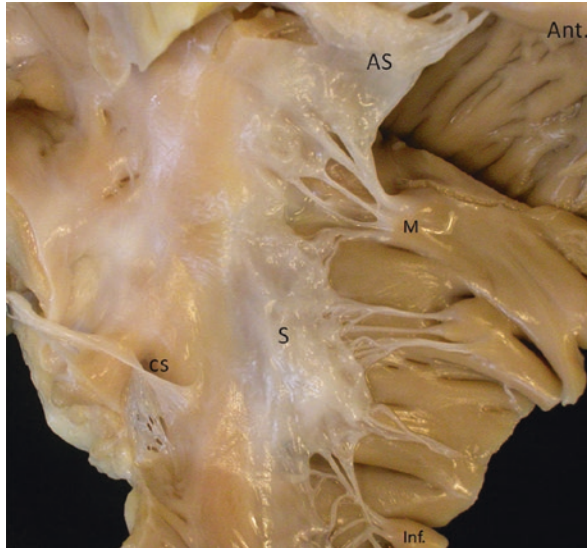


Fig. 1.5 This inflow view of the right atrium to right ventricle displays all three papillary muscles. The anterior papillary has noticeable multiple heads. *AS* anterosuperior leaflet, *S* septal leaflet, *M* medial papillary muscle, *Ant* anterior papillary muscle, *Inf* Inferior papillary muscle, *CS* coronary sinus

The inferior papillary muscle attaches between the inferior leaflet and the septal leaflets. Very often, however, it is not one individual muscle but is made up of a group of multiple heads of papillary muscles.

The medial papillary muscle is integral to the ventricular septum and it supports the antero-septal commissure. This is the smallest of the papillary muscles supporting the tricuspid valve. It usually comprises of only one muscle but it can be accompanied by several others that also have cordal insertions to the leaflets. But, the medial papillary muscle is distinguished by its fan-shaped interleaflet cord that inserts to both leaflets. However, the muscle is not present in every tricuspid complex, one study examining human tricuspid valves only identified the medial papillary in just over 80% of cases, in the other cases the tendinous cords directly attached to the septum [40]. When present the medial papillary muscle usually has a single head [18] in comparison to the anterior and inferior papillary muscles and is positioned in a sub infundibular position on the muscular septum. The medial papillary muscle arises from the superior part of the septum, adjacent to the bifurcation of the septomarginal trabeculation (SMT) from the posterior limb of the SMT. The base of the medial papillary muscle is an important landmark to the emergence of the right bundle branch within the right ventricle.

Pathological Changes in the Tricuspid Valve

The normal tricuspid valve alters during growth and ageing, there is a decrease in translucency of the leaflets and these become more opaque. Overall the leaflets of both atrioventricular valves become thicker during ageing [41]. With age,

elongation and doming of the tricuspid valve apparatus can occur along with floppy changes and this can lead to valve regurgitation [19]. Heart valve disease is an increasing clinical challenge encompassing valve replacement and reconstruction of the valve to maintain appropriate physiological parameters. Newer technologies, including tissue engineering, are being employed to repair valvar disease.

The Tricuspid Valve in Disease

Tricuspid Regurgitation

The purpose of an efficient tricuspid valve to the pumping of blood has been noted since ancient Greece [42]. When the valve fails tricuspid regurgitation occurs and this is a common condition in asymptomatic patients which can be associated with an adverse diagnosis. However the study of regurgitation has not been as extensive as systemic heart disease [43]. Functional regurgitation is a lesion produced by a disturbance of the efficient coordination of all the elements of the valve complex such as caused by annular dilatation, elongation of the valve cords, perforation of the leaflet, and so on. Dysfunction of the valve primarily leads to incompetence and regurgitation of blood back into the right atrium cardiac output decreases and this can potentially progress to atrial dilatation/fibrillation. There are several etiologies to cause alteration to one or more valve components resulting in regurgitation. Dilatation of the tricuspid annulus and the attachment of the leaflets are recognised as the primary mechanisms of functional TV regurgitation.

Structural anomalies of the valve apparatus include unguarded TV orifice, cord rupture, flail cords [44], parachute TV [45], double orifice TV, cleft TV, and Ebstein malformation. Acquired lesions affecting the valve such as prolapse, dysplasia, floppy TV, papillary fibroelastoma, rheumatic changes, endocarditis, carcinoid disease, endomyocardial fibrosis, RV dilatation following pulmonary hypertension or cardiomyopathy and RV dysfunction as a result of myocardial disease, RV ischemia or infarction can cause tricuspid regurgitation. There are also iatrogenic lesions following interventions in patients with permanent pacemakers or implantable defibrillators which may damage the tricuspid valve and cause tricuspid regurgitation. Over time when the leads and guide wires of such devices become adherent to the valvar elements that may disturb the cords, papillary muscles or leaflets and be the cause of valvar insufficiency. Adhesions also put the valve at risk of damage during lead extraction. Or, the tricuspid valve can be damaged during biopsy collection following heart transplantation and this leads to regurgitation of the valve [46]. Use of circular mapping catheters of the tricuspid valve in adult congenital heart disease may also increase risk of damage. Overall, regurgitation from the tricuspid valve can be divided into functional and degenerative in origin. Functional regurgitation can be caused by an enlarged/dilated ventricle. Degenerative incompetence affects the valve and the apparatus itself such as; rupture of the cords, or papillary muscles or damage to the leaflets.

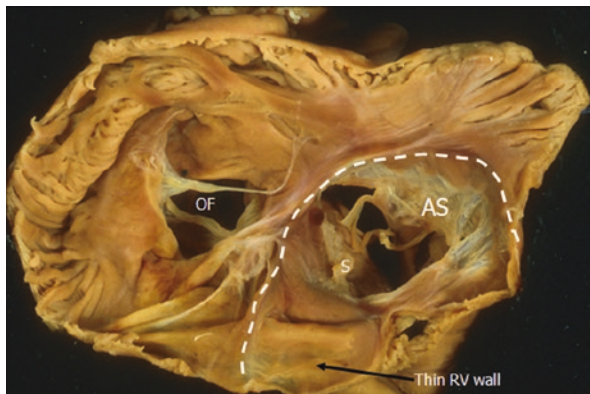

Fig. 1.6 This case of Ebstein malformation of the tricuspid valve particularly shows the failure of delamination of the septal leaflet and this is now a bubble-like formation on the ventricular septal surface. The attachment is not at the atrioventricular junction, indicated by the dotted line. This case of Ebstein also shows the atrialisation of a portion of the right ventricular wall. The anterosuperior leaflet is forming the curtain of valve tissue to separate inflow from outflow in this ventricle. *OF* oval fossa, *AS* anterosuperior leaflet, *S* septal leaflet, *Dotted line* atrioventricular junction

Among the congenital abnormalities of the TV causing regurgitation, Ebstein anomaly is probably the most distinctive although its milder forms may be missed. This malformation can be associated with other congenital heart defects but more commonly it co-exists with an atrial septal defect. Developmentally, there is incomplete delamination of the septal and inferior leaflets from the ventricular wall/septum causing the hingelines of these two leaflets to be located well within the ventricular chamber, away from the level of the atrioventricular junction (Fig. 1.6). The most affected site is usually the region between the inferior and septal leaflets [47]. In cross-sectional imaging, the four chamber plane shows increase in length of offset at the septum between the mitral and tricuspid insertions, with the tricuspid more apically displaced than normal. In mildly affected cases, the increased offset can be difficult to recognise. In severe more forms, the septal leaflet may appear like an bubble of tissue on the septum, or be missing altogether. The lack of delamination of the affected leaflets can result in the corresponding ventricular inferior wall becoming thinner, resembling the thickness of the atrial wall, and described as atrialisation of the ventricle. Indeed, in such cases the atrial chamber appears larger than it is, even taking into account the effect of tricuspid regurgitation. The antero-superior leaflet is well delaminated and hinged appropriately to the atrioventricular junction. However, it is never entirely normal. Often it is large, deeper than normal, and has abnormal attachments and abnormal papillary muscles supporting it. Sometimes, its leaflet may be muscularised, leading to suggestions that the muscle may be substrates for accessory atrioventricular pathways. In some severe forms, instead of attaching to papillary muscles, its free edge may be attached to a large muscle band that subdivides the right ventricle. This arrangement can result in the effective orifice of the valve that is the gap between the septum and the antero-superior leaflet being displaced toward the right ventricular outlet and becoming much reduced in size, leading to valvar incompetence and stenosis.

Other examples of congenital tricuspid malformations causing regurgitation include leaflet dysplasia, cordal elongations with hooding of leaflets, accessory orifices, breach or cleft in a leaflet, and agenesis of one or more leaflets.

Valvar Stenosis

Stenosis of the tricuspid valve involves one or more elements of the valvar apparatus that is abnormally formed or become changed resulting in reduction of flow from the atrium to the ventricle. For instance, reduction in annular size results in narrowing of the effective atrioventricular orifice as the tricuspid valve fails to open fully in diastole thus hindering filling of the ventricle. Tricuspid stenosis can take various pathologies from acquired to congenital origins.

Acquired tricuspid stenosis includes forms of degenerative disease, endocarditis, stiffening of the leaflets and calcification. Some cases of endocarditis develop perforations in the leaflets leading to regurgitation. The tricuspid valve is the most frequently affected valve in carcinoid heart disease resulting in tricuspid stenosis. Furthermore, the leaflets become thickened with increased fibrosis resulting in stiffening and reduced overall motility. Vegetations on the tricuspid leaflets can also affect leaflet motility and hazard of embolic event. Rheumatic disease is also a cause of stenosis where thick leaflets have restricted motion, there is fusion at the commissures, shortening of cords as well as reduced separation of the leaflets leading to a restricted orifice. Ultimately, the valve becomes stenotic as well as regurgitant. Globally the most common cause of tricuspid stenosis is rheumatic fever most often found in children.

Congenitally malformed tricuspid valves obstructing inflow into the right ventricle can occur in isolation or with other congenital heart lesions. The underlying malformation affect one or more elements of the valve e.g. underdeveloped leaflets, short and thickened or fused tendinous cords, a small annulus or abnormal papillary muscles. The extreme example of the malformation is in the rare setting of tricuspid atresia in infants where there is complete occlusion of the tricuspid valve orifice owing to fusion of the valvar leaflets forming an imperforate membrane across the atrioventricular junction. It is pertinent to highlight that the more common forms of 'tricuspid atresia' are hearts without any evidence of a tricuspid valve (Fig. 1.7). These are hearts with univentricular atrioventricular connection in which the right sided atrium has no egress to the ventricular mass other than through an interatrial communication to the left side of the heart, in other words these are hearts with absence of the right atrioventricular connection.

Congenital tricuspid valve stenosis is often seen in association with obstructions to right ventricular outflow e.g. severe pulmonary stenosis or atresia. Most commonly, the valvar leaflets in these settings are thickened, with rolled edges, and the cords are short and thick. Or, the commissures are fused or incompletely separated. Rarely, the tricuspid valve may be supported by a single group of papillary muscles resulting in ineffective separation of the leaflets and, consequently, inadequate opening of the valvar orifice similar to that of a parachute mitral valve. Tricuspid valve dysplasia presenting with mucoid degeneration (Fig. 1.8), cauliflower formation of the leaflets may occur in isolation. In such cases concomitant stenosis and regurgitation may occur.

Fig. 1.7 In this case there is no evidence of the formation of a tricuspid valve. This is termed absent right atrioventricular connection (sometimes referred to as tricuspid atresia). *OF* oval fossa, *CS* coronary sinus, *App.* Right atrial appendage, *RA* right atrium

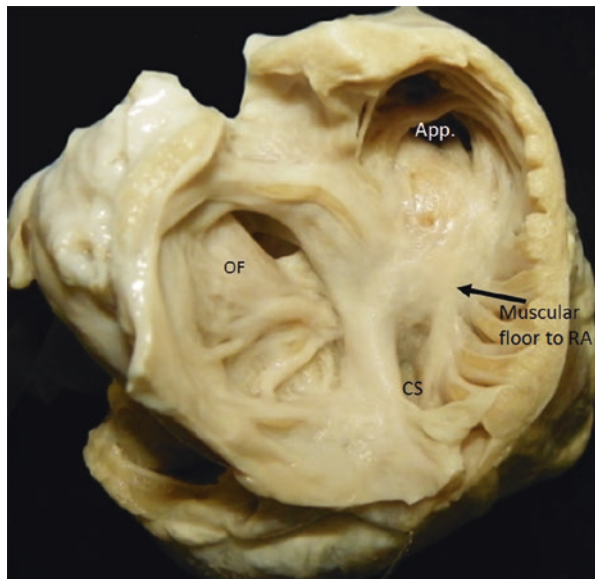
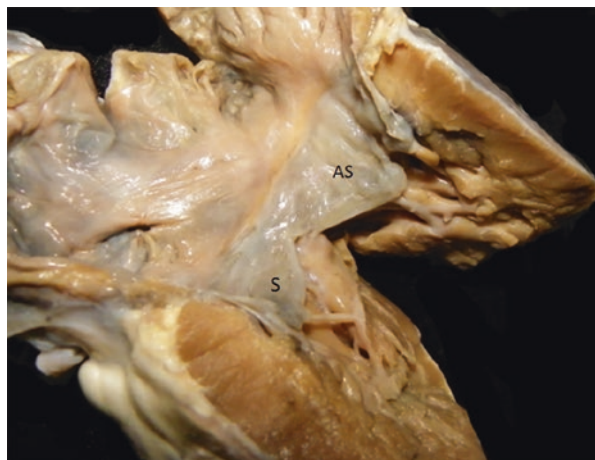


Fig. 1.8 In this example of tricuspid dysplasia the leaflets are highly thickened and not as mobile as the cords are also shortened leading to valve regurgitation. *AS* anterosuperior leaflet, *S* septal leaflet



Straddling Tricuspid Valve

In the presence of a ventricular septal defect the tricuspid valve can straddle the defect [48] with cords attaching within the left ventricle or the cords can be anchored to a papillary muscle within the left ventricle. If the ventricular septal defect is associated with malalignment of the septums then not only is the valve leaflet straddling across the defect but the valve orifice may also override the septum resulting in

tricuspid inflow going to both ventricles. The malignment of the atrial and ventricular septums at the atrioventricular junction in this setting is also associated with deviation of the atrioventricular node rightward and inferiorly.

Conclusion

The tricuspid valve, like the mitral valve, requires coordination and integrity of its various components for normal function. It is a common misconception to consider a valve solely in terms of its leaflets. For proper function, the tricuspid valve requires all its component parts i.e. the annulus with extension of atrial wall, the leaflets, tendinous cords, papillary muscles and the associated ventricular/septal walls to work in harmony. Not only that, the surrounding cardiac structures should be examined prior to considering any interventional procedures on the valve. Of particular note are the locations of the atrioventricular node and His bundle of the conduction system. The course of the right coronary artery should also be taken into account.

There is still much to learn about the complex tricuspid valve. Understanding the valve features in the normal valve, the normal spectrum of variation, the natural changes that occur during ageing and those changes during disease will help in understanding the changes that occur to this dynamic and highly mobile structure.

Take Home Points

- The tricuspid valve is not simply the leaflets but a valve complex involving the cords, papillary muscles, annulus and the surrounding musculature.
- The valve remodels during aging becoming thicker and prone to regurgitation.
- With numerous scallops, cord attachment and papillary muscle morphology, the tricuspid valve has greater variation than the anatomy of the mitral valve.

Review Questions

1. Which of the following sentences is correct?
 - (a) The tricuspid valve has greater variation than the anatomy of the mitral valve
 - (b) The tricuspid valve has always three clearly identifiable three leaflets as proven on post-mortem studies
 - (c) the tricuspid valve leaflets position is less apical than those of the mitral valve
 - (d) The tricuspid valve is not always associated with a morphological right ventricle.

2. Which of the following sentences is correct?
 - (a) The tricuspid valve leaflets are uniform throughout in structure?
 - (b) The tricuspid valve septal and anterior leaflets are uniform throughout in structure?
 - (c) The tricuspid valve septal and posterior leaflets are uniform throughout in structure?
 - (d) The tricuspid valve leaflets are not uniform throughout in structure?
3. Which of the following sentences is correct?
 - (a) Two of the tricuspid valve papillary muscles are attached to septum
 - (b) Unlike the left heart valves, the tricuspid valve is remote from the pulmonary valve
 - (c) The tricuspid orifice is smaller than the mitral orifice
 - (d) The tricuspid annulus has a near horizontal location
4. Which of the following sentences is correct?
 - (a) The attachment of the tricuspid valve leaflets crosses the atrioventricular node?
 - (b) The attachment of the inferior (posterior) tricuspid valve leaflet is the closest to the atrioventricular node?
 - (c) The attachment of the anterior (anterosuperior) tricuspid valve leaflet is the closest to the atrioventricular node?
 - (d) The attachment of the septal tricuspid valve leaflet is separated by the central fibrous body from the atrioventricular node?
5. Which of the following sentences is correct?
 - (a) The right coronary artery runs in closest proximity to the tricuspid annulus at its initial course.
 - (b) The right coronary artery runs always above to the tricuspid annulus.
 - (c) The right coronary artery runs always below to the tricuspid annulus.
 - (d) There is a gradual shortening of the distance between the right coronary artery and the endocardial surface toward the inferior segment of the annulus to <3 mm.

References

1. Taramasso M, Vanermen H, Maisano F, Guidotti A, La Canna G, Alfieri O. The growing clinical importance of secondary tricuspid regurgitation. *J Am Coll Cardiol.* 2012;59:703–10.
2. Angelini A, Ho SY, Anderson RH, Davies MJ, Becker AE. A histological study of the atrioventricular junction in hearts with normal and prolapsed leaflets of the mitral valve. *Br Heart J.* 1988;59(6):712–6.

3. Ueda A, McCarthy KP, Sánchez-Quintana D, Ho SY. Right atrial appendage and vestibule: further anatomical insights with implications for invasive electrophysiology. *Europace*. 2013;15(5):728–34.
4. Yacoub MH, Cohn LH. Novel approaches to cardiac valve repair from structure to function: part I. *Circulation*. 2004;109:942–50.
5. Misfeld M, Sievers HH. Heart valve macro- and microstructure. *Philos Trans R Soc Lond B Biol Sci*. 2007;362:1421–36.
6. Kwan J, Kim GC, Jeon MJ, Kim DH, Shiota T, Thomas JD, Park KS, Lee WH. 3D geometry of a normal tricuspid annulus during systole: a comparison study with the mitral annulus using real-time 3D echocardiography. *Eur J Echocardiogr*. 2007;8:375–83.
7. Shah PM, Raney AA. Tricuspid valve disease. *Curr Probl Cardiol*. 2008;33:47–84.
8. Rogers JH, Bolling SF. The tricuspid valve. current perspective and evolving management of tricuspid regurgitation. *Circulation*. 2009;119:2718–25.
9. Bateman MG, Quill JL, Hill AJ, Iaizzo PA. The clinical anatomy and pathology of the human atrioventricular valves: implications for repair or replacement. *J Cardiovasc Trans Res*. 2013;6:155–65.
10. Fukuda S, Saracino G, Matsumura Y, et al. Three-dimensional geometry of the tricuspid annulus in healthy subjects and in patients with functional tricuspid regurgitation: a real-time, 3-dimensional echocardiographic study. *Circulation*. 2006;114:1492–8.
11. Fawzy H, Fukamachi K, Mazer CD, Harrington A, Latter D, Bonneau D, Errett L. Complete mapping of the tricuspid valve apparatus using three-dimensional sonomicrometry. *J Thorac Cardiovasc Surg*. 2011;141:1037–43.
12. Dwivedi G, Mahadevan G, Jimenez D, Frenneaux M, Steeds RP. Reference values for mitral and tricuspid annular dimensions using two-dimensional echocardiography. *Echo Res Pract*. 2014;1(2):43–50.
13. Silver MD, Lam JHC, Ranganathan N, Wigle ED. Morphology of the human tricuspid valve. *Circulation*. 1971;43:333–48.
14. Tsakiris AG, Mai DD, Seki S, et al. Motion of the tricuspid valve annulus in anesthetized intact dogs. *Circ Res*. 1975;36(1):43–8.
15. Sutton JP, Ho SY, Vogel M, Anderson RH. Is the morphologically right atrioventricular valve tricuspid? *J Heart Valve Dis*. 1995;4(6):571–5.
16. Dreyfus GD, Martin RP, KMJ C, Dulguerov F, Alexandrescu C. Functional tricuspid regurgitation. a need to revise our understanding. *J Am Coll Cardiol*. 2015;65(21):2331–6.
17. Huttin O, Voilliot D, Mandry D, Vennera C, Juillièrre Y, Selton-Sutya C. All you need to know about the tricuspid valve: tricuspid valve imaging and tricuspid regurgitation analysis. *Arch Cardiovasc Dis*. 2016;109:67–80.
18. Tretter JT, Sarwark AE, Anderson RH, Spicer DE. Assessment of the anatomical variation to be found in the normal tricuspid valve. *Clin Anat*. 2016;29:399–407.
19. Davies MJ. The mitral valve. In: *Pathology of cardiac valves*. London: Butterworths; 1980.
20. Ikegaya T, Kurata C, Hayashi H, Muro H, Yamazaki N. A case of congenital tricuspid valve abnormality showing six leaflets. *Eur Heart J*. 1991;12:94–5.
21. Wafae N, Hayashi H, Gerola LR, Vieira MC. Anatomical study of the human tricuspid valve. *Surg Radiol Anat*. 1990;12:37–41.
22. Antoniali F, Braile DM, Poterio GMB, da Costa CE, Lopes MM, Ribeiro GCA, Tarelho LDS. Proportion among the segments of the normal tricuspid valve annulus: parameter for valve annuloplasty. *Braz J Cardiovasc Surg*. 2006;21(3):262–71.
23. Skwarek M, Hreczecha J, Dudziak M, Jerzemowski J, Szpinda M, Grzybiak M. Morphometric features of the right atrioventricular orifice in adult human hearts. *Folia Morphol (Warsz)*. 2008;67(1):53–7.
24. Otto S, Baum T, Keller F. Sex-dependence of the relative number of elastic fibres in human heart valves. *Ann Anat*. 2006;188:153–8.
25. Stetler-Stevenson WG. Dynamics of matrix turnover during pathologic remodeling of the extracellular matrix. *Am J Pathol*. 1996;148:1345–50.

26. Grande-Allen KJ, Calabro A, Gupta V, Wight TN, Hascall VC, Vesely I. Glycosaminoglycans and proteoglycans in normal mitral valve leaflets and chordae: association with regions of tensile and compressive loading. *Glycobiology*. 2004;14:621–33.
27. Iozzo RV. The biology of the small leucine-rich proteoglycans. *J Biol Chem*. 1999;274(27):18843–6.
28. McDonald PC, Wilson JE, McNeill S, Gao M, Spinelli JJ, Rosenberg F, Wiebe H, McManus BM. The challenge of defining normality for human mitral and aortic valves. Geometrical and compositional analysis. *Cardiovasc Pathol*. 2002;11:193–209.
29. Filip DA, Radu A, Simionescu M. Interstitial cells of the heart valves possess characteristics similar to smooth muscle cells. *Circ Res*. 1986;59:310–20.
30. Woessner FJ, Nagase H. Introduction, overview of the individual TIMPS; Protein substrates of the MMPs. In: *Matrix metalloproteinases and TIMPs*. 2nd ed. New York: Oxford University Press; 2002.
31. Dreger SA, Taylor PM, Allen SP, Yacoub MH. Profile and localization of matrix metalloproteinases (MMPs) and their tissue inhibitors (TIMPs) in human heart valves. *J Heart Valve Dis*. 2002;11:875–80.
32. Roy A, Brand NJ, Yacoub MH. Molecular characterization of interstitial cells isolated from human heart valves. *J Heart Valve Disease*. 2000;9:459–64.
33. Taylor PM, Batten P, Brand NJ, Thomas PS, Yacoub MH. The cardiac valve interstitial cell. *Int J Biochem Cell Biol*. 2003;35:113–8.
34. Hafizi S, Taylor PM, Chester AH, Allen SP, Yacoub MH. Mitogenic and secretory responses of human valve interstitial cells to vasoactive agents. *J Heart Valve Disease*. 2000;9:454–8.
35. Mulholland DL, Gotlieb AI. Cardiac valve interstitial cells: regulator of valve structure and function. *Cardiovasc Pathol*. 1997;6:167–74.
36. Ottani V, Raspanti M, Ruggeri A. Collagen structure and functional applications. *Micron*. 2001;32:251–60.
37. Zanaboni G, Rossi A, Tina Onana AM, Tenni R. Stability and networks of hydrogen bonds of the collagen triple helical structure: influence of pH and chaotrophic nature of three anions. *Matrix Biol*. 2000;19:511–20.
38. Bard JBL, Hulmes DJS, Purdom IF, Ross ASA. Chick corneal development in vitro: diverse effects of pH on collagen assembly. *J Cell Sci*. 1993;105:1045–55.
39. Aktas EO, Govsa F, Kocak A, Boydak B, Yavuz IC. Variations in the papillary muscles of normal tricuspid valve and their clinical relevance in medicolegal autopsies. *Saudi Med J*. 2004;25(9):1176–85.
40. Loukas M, Tubbs RS, Louis RG Jr, Apaydin N, Bartczak A, Huseng V, Alsaiegh N, Fudalej M. An endoscopic and anatomical approach to the septal papillary muscle of the conus. *Surg Radiol Anat*. 2009;31:701–6.
41. Gross L, Kugel MA. Topographic anatomy and histology of the valves in the human heart. *Am J Pathol*. 1931;7:445–73.
42. Paraskevas G, Koutsouflianiotis K, Iliou K. The first descriptions of various anatomical structures and embryological remnants of the heart: a systematic overview. *Int J Cardiol*. 2017;227:674–90.
43. Mascherbauer J, Maurer G. The forgotten valve: lessons to be learned in tricuspid regurgitation. *Eur Heart J*. 2010;31:2841–3.
44. D'Aloia A, Bonadei I, Vizzardi E, Sciatti E, Bugatti S, Curnis A, Metra M. Different types of tricuspid flail: case reports and review of the literature. *Hell J Cardiol*. 2016;57:134–7.
45. Godart F, Piot D, Rey C. Parachute tricuspid valve, supraavalvar tricuspid ring, and coarctation of aorta in congenitally corrected transposition. *Cardiol Young*. 1997;7:337–9.
46. Fiorelli AI, Coelho GHB, Aiello VD, Benvenuti LA, Palazzo JF, Santos Júnior VP, Canizares B, Dias RR, Stolf NAG. Tricuspid valve injury after heart transplantation due to endomyocardial biopsy: an analysis of 3550 biopsies. *Transplant Proc*. 2012;44:2479–82.

47. Schreiber C, Cook A, Ho SY, Augustin N, Anderson RH. Morphologic spectrum of Ebstein's malformation: revisitation relative to surgical repair. *J Thorac Cardiovasc Surg.* 1999;117(1):148–55.
48. Milo S, Ho SY, Macartney FJ, Wilkinson JL, Becker AE, Wenink AC, Gittenberger de Groot AC, Anderson RH. Straddling and overriding atrioventricular valves: morphology and classification. *Am J Cardiol.* 1979;44(6):1122–34.

Part II
Clinical Perspective

Chapter 2

Clinical Recognition of Tricuspid Valve Disease

Ashraf M. Anwar, Folkert J. ten Cate, and Osama I. Soliman

Abstract Tricuspid valve (TV) dysfunction can result from morphological alterations in the valve or from functional aberrations of the myocardium. It can be classified as primary and secondary. Primary TV disease with intrinsic structural abnormality is less common than diseases of the aortic and mitral valves. The slow progression of the disease leads to delayed appearance of symptoms. The physical signs are often less impressive. Hence, it may go undetected until advanced stage results in hepatomegaly, ascites, and leg edema. The secondary form of TV disease is far more common and is often the result of annular dilatation with incomplete valve closure. The functional abnormalities may be in the form of pure or predominant tricuspid stenosis (TS), pure or predominant tricuspid regurgitation (TR), or mixed.

Keywords Tricuspid • Valve • Stenosis • Regurgitation • Epidemiology • Aetiology • Imaging • Diagnosis • Natural history • Therapy • Outcome

Tricuspid Stenosis

Most cases of tricuspid stenosis (TS) are associated with a clinical evidence of tricuspid regurgitation (TR) that can be documented by performing a physical examination, echocardiography, or angiography. Stenotic tricuspid valves are always anatomically abnormal, and the cause of valve stenosis is limited to a few conditions. With the exceptions of congenital causes or active infective endocarditis, TS takes years to develop [1].

A.M. Anwar, M.D., Ph.D. (✉)
Department of Cardiology, Al-Azhar University, Cairo, Egypt
e-mail: ashrafanwar2000@hotmail.com

F.J. ten Cate, M.D., Ph.D. • O.I. Soliman, M.D., Ph.D.
Department of Cardiology, The Thoraxcenter, Erasmus MC: University Medical Center
Rotterdam, Rotterdam, The Netherlands

Frequency [2]

United States: TS is rare, occurring in less than 1% of the population. While found in approximately 15% of patients with rheumatic heart disease at autopsy, it is estimated to be clinically significant in only 5% of these patients. The incidence of the congenital form of the disease is less than 1%.

Worldwide: TS is found in approximately 3% worldwide. It is more prevalent in areas with a high incidence of rheumatic fever. The congenital form of the disease is rare and true incidence is not known.

Natural History

Few data are available on the natural history of isolated TS because it typically accompanies rheumatic mitral valve disease. As for mitral stenosis (MS), TS is the result of a chronic, slowly progressive disease process correlating with a gradual increase in stenosis severity and gradual onset of symptoms. The mortality associated with TS depends on the precipitating cause.

Prevalence: TS can present as a congenital lesion and accounts for approximately 0.3% of all congenital heart disease cases. The congenital form of the disease has a slightly higher male predominance. The frequency of TS in the older population, due to secondary causes, ranges from 0.3 to 3.2%. It is observed more commonly in women than in men, similar to mitral stenosis of rheumatic origin [3]. No racial predisposition is apparent.

Clinical Features

Many variables are affecting the presentation of TS. They include the degree of TS, duration of TS, associated underlying etiology and concomitant cardiac lesions. It is difficult to separate symptoms specific to TS from those of mitral stenosis and/or regurgitation [4]. In isolated TS, the following symptoms can be identified.

Common Symptoms

- Weakness and easy fatigability, due to low cardiac output.
- Edema and anorexia.

Less Common Symptoms

- Fluttering pulsations in the neck.
- Right upper quadrant abdominal pain due to stretch of liver capsule. The Systemic venous congestion onset is usually gradual, but it may be rapid if *atrial fibrillation* or *flutter* develops.

Rare Symptoms

- Orthopnea, paroxysmal nocturnal dyspnea, pulmonary edema and hemoptysis (high suspicion of concomitant mitral valve disease).
- Flushing and diarrhea in metastatic carcinoid tumor.

Important clues: In patient with significant MS, the following findings are high indices of concomitant TS:

- Unexpected amelioration of typical symptoms of MS e.g. dyspnea, hemoptysis, and orthopnea (due to limited cardiac output to the pulmonary bed).
- Elevated jugular venous pressure (JVP) out of proportion to signs of pulmonary congestion.

Physical examination: clinical manifestations are far overshadowed by those attributable to the associated left-sided (particularly mitral) valve disease. The specific physical findings of TS are [4, 5]:

- Wasting and peripheral cyanosis.
- Elevated central venous pressure.
- With sinus rhythm (more common with TS than with mitral stenosis), the “a” wave is prominent, rapid rising and may be confused with carotid pulse. It occurs at the time of first heart sound due to powerful right atrial (RA) contraction against stenotic TV (Fig. 2.1). If atrial fibrillation occurs, the “a” wave is lost.

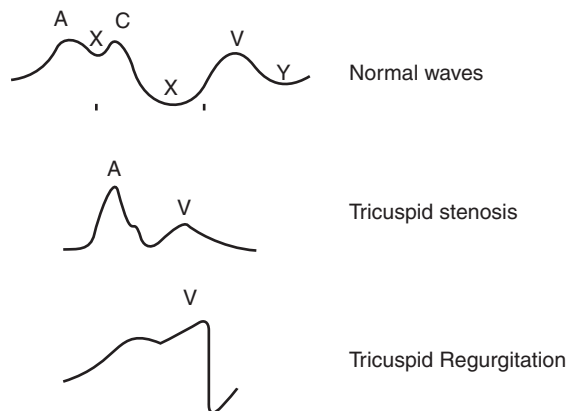


Fig. 2.1 JVP findings in tricuspid valve disease

Table 2.1 Stages of severe TS

Stage	Definition	Valve anatomy	Valve hemodynamics	Hemodynamic consequences	Symptoms
C, D	Severe TS	<ul style="list-style-type: none"> Thickened, distorted, calcified leaflets 	<ul style="list-style-type: none"> PHT \geq 190 ms Valve area = <1 cm² 	<ul style="list-style-type: none"> RA/IVC enlargement 	<ul style="list-style-type: none"> None or variable presentations Dependent on severity of valve associated disease and degree of obstruction

Reprinted with permission from Nishimura et al. [6]

The tricuspid diastolic gradient is highly variable and is affected by heart rate, forward flow, and phases of the respiratory cycle. However, severe TS usually has mean pressure gradients >5 – 10 mm Hg at heart rate 70 beats/min [7]

bpm beats per minute, *IVC* inferior vena cava, *RA* right atrium, *PHT* pressure half-time, *TS* tricuspid stenosis

- Peripheral oedema and ascites (with severe TS).
- Slow ‘y’ descent.
- A prominent RA may be palpable to the right of the sternum.
- The first heart sound may be split widely.
- The second heart sound may be single due to the inaudible closure of the pulmonary valve from the decrease in blood flow through the stenotic tricuspid valve.
- High pitched tricuspid opening snap if the TV is flexible and not obscured by MS sounds.
- Low pitched diastolic rumbling murmur is audible along the left lower sternal border in the third or fourth intercostals space or at the xiphoid process. In sinus rhythm, the murmur is maximal at end-diastole (pre-systole) while in AF, the prominence of murmur in early to mid-diastole. Murmur usually increases with inspiration and with any maneuver that increase the systemic venous return to RA and drop in right ventricular (RV) filling pressure e.g. exercise, intravenous fluid, Atropine administration ...etc.

Stages of TS: According to AHA/ACC (Table 2.1), only late two stages are identified (severe asymptomatic and severe symptomatic). The early two stages (at risk and progressive) were not defined [6].

Aetiology and Pathogenesis

At least four conditions can cause obstruction of the native TV. These include (1) rheumatic heart disease, (2) congenital abnormalities, (3) active infective endocarditis, and (4) metabolic or enzymatic abnormalities.

Rheumatic Heart Disease

In more than 90% of cases of TS, rheumatic heart disease is the cause. Rheumatic involvement of the TV is far less common than the mitral and the aortic valves. Isolated rheumatic TV disease is rare. Clinically significant TV disease almost always associated with rheumatic MS and up to 67% of patients with mitral valve disease showed involvement of TV with rheumatic process. Rheumatic process include diffuse thickening of the leaflets with contraction and fibrosis with or without fusion of the commissures. The chordae tendineae may be thickened and shortened. Calcification of the valve is rare [8, 9].

Congenital Tricuspid Stenosis

Congenital TS is characterized by a small but well-formed TV that joins an underdeveloped inlet portion of the RV. It represents a less severe form of tricuspid atresia. Abbott's series of 1000 cases of congenital heart disease identified only three cases of congenital TS (0.3% prevalence [3]). Hauck et al. reviewed the Mayo Clinic's registry of excised tricuspid valves over 25 years. Out of 363 valves, only one showed TS without tricuspid insufficiency, and 3 showed combined stenosis and insufficiency. There was only one case of congenital TS. They may manifest as incompletely developed leaflets, shortened or malformed chordae, small annuli, abnormal size and number of the papillary muscles, or any combination of these defects [3, 10].

Infective Endocarditis

Infective endocarditis of the TV is not uncommon among intravenous drug abusers. It may also be observed in patients with long-term intravenous lines. Large infected vegetations obstructing the orifice of the TV may produce stenosis. This condition is relatively uncommon, even in those who abuse intravenous drugs. The clinical presentation is one of general systematic symptoms such as fever, weight loss, anemia, and fatigue; or of pulmonary embolism; or of right heart failure with hepatic congestion, peripheral edema, and ascites.

Carcinoid Heart Disease

Carcinoid tumors arising in the intestinal tract with secondary liver metastases are commonly associated with valvular pathology. The most commonly affected valve is the TV followed by the pulmonary valve. Occasionally, the left-sided heart valves may be affected when the primary carcinoid tumor is in the lung. Carcinoid valve lesions characteristically manifest as fibrous white plaques located on the valvular and mural endocardium. The valve leaflets are thickened, rigid, and reduced in area. Fibrous tissue proliferation is present on the atrial and ventricular surfaces of the valve

structure. The valve leaflets are held partially open during systole and diastole leading to TS and TR. These lesions are observed more commonly in infants [11, 12].

Unusual Causes

- Metabolic abnormalities: Fabry disease, Whipple disease and giant blood cysts.
- Deposition abnormalities: Lofferler's syndrome, endomyocardial fibroelastosis.
- Drug-induced deposition (serotonin like substances): Methysegide, Ergotamine, Fenfuramine.

Differential Diagnosis

Diseases are mimicking TS due to delay of RA emptying in diastole [12–15] include:

- Atrial Myxoma
- Other intracardiac or extracardiac tumors,
- Thrombosis or emboli,
- Large endocarditis vegetations,
- Supravalvular obstruction from congenital diaphragms,
- Endomyocardial Fibrosis,
- Tricuspid Atresia.

Diseases that impair right-sided filling can produce similar symptoms and physical findings. These conditions include:

- Constrictive Pericarditis
- Effusive-Constrictive Pericarditis
- Restrictive Cardiomyopathy

Investigations

- Electrocardiogram: ECG may show evidence of right atrial hypertrophy with tall peaked P waves. Atrial fibrillation and atrial flutter occur frequently. Absence of ECG abnormalities cannot be used to exclude significant tricuspid disease.
- Chest Radiography: Chest X-ray examination may show an enlarged right atrium without an enlarged pulmonary-artery segment. Cardiac size may range from normal to cardiomegaly. Calcification of the TV is rarely observed.
- Echocardiography: Two-dimensional and three-dimensional echocardiography are used to detect and quantify TS and for quantification of cardiac chambers, determination of right ventricular and pulmonary pressures and detection of associated other heart valve abnormalities [7].

- **Cardiac catheterization:** Due to accuracy of echocardiographic assessment of TV, catheterization is rarely necessary. It may be required prior to surgery to assess for possible coronary artery disease. Right heart catheterization can help to determine the severity of the stenosis and associated congenital defects. Assessment of aortic and mitral valves via left heart catheterization is useful in patients with rheumatic disease.

Management

1. Life Style Modification

- Fluid and sodium restriction is prudent if signs of venous congestion are present.
- No specific dietary restrictions are necessary.
- Activity is usually self-limited by the patient because of easy fatigability secondary to oxygen deprivation. No activity restrictions are necessary after invasive treatment.

2. Pharmacotherapy: The goals of pharmacotherapy are to reduce morbidity and to prevent complications.

- Treatment of the underlying condition—e.g., antibiotics for infective endocarditis.
- Treatment of associated arrhythmias.
- Management of heart failure. Loop diuretics may be useful to relieve systemic and hepatic congestion in patients with severe, symptomatic TS, although their use may be limited by worsening low-flow syndrome.

3. Surgery: Surgery is usually carried out in severe TS at the time of intervention for the other left sided valves and in symptomatic isolated severe TS.

4. Balloon valvuloplasty: Tricuspid balloon valvotomy has been advocated for TS of various causes. However, severe TR is a common consequence of this procedure, and results are poor when severe TR develops [16, 17].

Prognosis: Prognosis is generally good but dependent on the prognosis of the underlying disease, associated other heart abnormalities and associated arrhythmias.

Consultations

- Consultation with infectious disease specialists may be appropriate if the stenosis is secondary to an infectious process.
- An endocrinologist may be of assistance if carcinoid syndrome or an inborn error of metabolism is the cause of the pathology.

Tricuspid Regurgitation

Tricuspid regurgitation (TR) is a common valve lesion. Prevalence of moderate-to-severe TR is estimated to be 1.6 million in the United States [17]. Using echocardiography, the Framingham Heart Study investigators found a prevalence of moderate or severe TR of 0.8% and an increased prevalence with ageing. Overall, the prevalence of significant TR was 4.3 times greater in women than in men [18]. The pathophysiology is divided into three major categories:

1. **Physiologic TR:** It is described as trivial to mild TR frequently detected by echocardiography in normal subjects with the absence of TV pathology and dilated chamber sizes. It is seen in over 70% of healthy adults [19].
2. **Primary (organic) TR:** About 14% of significant TR may occur in the absence of structural TV alterations, pulmonary hypertension, or left heart dysfunction but due to local destruction of TV [20]. It can occur with or without TS. A long list of aetiologies account for organic TR.
3. **Secondary (functional) TR:** is defined as TR without any identifiable structural damage of the TV leaflets or chordae. More than 80% of cases of significant TR are functional in nature with male predominance. It is related to one or more of the following mechanism [21, 22]:
 - Annular dilatation due to RV and/or RA dilatation results in lack of leaflet apposition.
 - Increased tricuspid leaflet tethering in relation to RV pressure and/or volume overload e.g., pulmonary hypertension.
 - Distortion of RV shape and papillary muscles e.g. RV infarction and intrinsic disease of the RV (Table 2.2).

Pathophysiology

The pathophysiology of secondary TR can be divided into three phases [13, 23, 24]. In the first phase, initial RV dilation results in tricuspid annulus dilation. Dilation of the tricuspid annulus occurs mainly in its posterior and anterior portions. Depending on the degree of annular dilation, TR may or may not be present. In the second phase, with progressive dilation of both RV and tricuspid annulus, malcoaptation of TV leaflets leads to significant TR. Finally, with progressive RV distortion and eccentricity, tethering of the leaflets occurs, in addition to tricuspid annulus dilation.

Presentation: AHA/ACC guidelines [6] categorized the with TR patients according to the stages of valve lesion (see Table 2.3).

In primary TR, patients can be asymptomatic. Even severe TR may be well tolerated for a long period of time. With the development of RV systolic dysfunction,

Table 2.2 List of underlying aetiologies of primary and secondary TR**Primary TR: diseases of the TV leaflets or chordal structures, or both***Congenital disease*

- Ebstein's anomaly
- Tricuspid valve dysplasia, hypoplasia, or cleft
- Double orifice TV
- Unguarded tricuspid valve orifice

Acquired disease

- Infective Endocarditis (e.g., intravenous drug abuse).
- Marantic endocarditis
- Rheumatic heart disease
- Carcinoid syndrome, serotonin-active drugs
- Tricuspid valve prolapse, flail
- Mediastinal radiation
- Cardiac device (PPM, ICD) leads
- Blunt chest wall trauma
- Right ventricular endomyocardial biopsy
- Degenerated bioprosthesis

Secondary TR: Diseases affecting the right ventricle and tricuspid annulus

- Right ventricular and tricuspid annular dilatation,
- Left-sided valvular and/or myocardial disease,
- Pulmonary hypertension independent of left-sided cardiac pathology,
- Right ventricular infarction with remodeling,
- Papillary muscle dysfunction,
- Chronic right ventricular pacing (dyssynchrony),
- Atrial fibrillation.

symptoms of systemic venous congestion appear. In secondary TR, the spectrum of presenting symptoms depends on underlying aetiology, chronicity of TR and presence or absence of pulmonary hypertension.

- It is often asymptomatic in the absence of pulmonary hypertension.
- Development of pulmonary hypertension leads to reduction of cardiac output and features of right heart failure with dyspnoea, fatigue, cyanosis, cold skin, oedema and discomfort in the right hypochondrium.
- Ascites and oedema.
- Neck pulsation or eyeball pulsation.

Physical Examination

Findings on cardiovascular examination in patients with significant TR include the following:

- Cachexia, peripheral oedema.
- Cyanosis and jaundice.

Table 2.3 Stages of TR

Stage	Definition	Valve anatomy	Hemodynamic	Symptoms
A	At risk	<p>Primary</p> <ul style="list-style-type: none"> Mild rheumatic change Mild prolapse Other (e.g., IE with vegetation, early carcinoid deposition, radiation) Intra-annular RV pacemaker or ICD lead Postcardiac transplant (biopsy related) <p>Functional</p> <ul style="list-style-type: none"> Normal Early annular dilation 	None	None or in relation to other left heart or pulmonary/pulmonary vascular disease
B	Progressive	<p>Primary</p> <ul style="list-style-type: none"> Progressive leaflet deterioration/destruction Moderate-to-severe prolapse, limited chordal rupture <p>Functional</p> <ul style="list-style-type: none"> Early annular dilation Moderate leaflet tethering 	<p>Mild TR</p> <ul style="list-style-type: none"> RV/RA/IVC size normal <p>Moderate TR</p> <ul style="list-style-type: none"> No RV enlargement No or mild RA enlargement No or mild IVC enlargement with normal respirophasic variation Normal RA pressure 	None or in relation to other left heart or pulmonary/pulmonary vascular disease
C	Asymptomatic severe	<p>Primary</p> <ul style="list-style-type: none"> Flail or grossly distorted leaflets <p>Functional</p> <ul style="list-style-type: none"> Severe annular dilation (>40 mm or 21 mm/m²) Marked leaflet tethering 	<p>RV/RA/IVC dilated with decreased IVC respirophasic variation</p> <ul style="list-style-type: none"> Elevated RA pressure with “c-V” wave Diastolic interventricular septal flattening may be present 	None, or in relation to other left heart or pulmonary/pulmonary vascular disease

D	Symptomatic severe	<p>Primary</p> <ul style="list-style-type: none"> • Flail or grossly distorted leaflets <p>Functional</p> <ul style="list-style-type: none"> • Severe annular dilation (>40 mm or >21 mm/m²) • Marked leaflet tethering 	<p>RV/RA/IVC dilated with decreased IVC respirophasic variation</p> <ul style="list-style-type: none"> • Elevated RA pressure with “c-V” wave • Diastolic interventricular septal flattening • Reduced RV systolic function in late phase 	Fatigue, palpitations, dyspnea, abdominal bloating, anorexia, edema
---	--------------------	---	--	---

Reprinted with permission from Nishimura et al. [6]
 Several valve hemodynamic criteria are provided for assessment of severity of TR, but not all criteria for each category will necessarily be present in every patient. Categorization of severity of TR as mild, moderate, or severe also depends on image quality and integration of these parameters with clinical findings. CW continuous wave, ICD implantable cardioverter-defibrillator, IE infective endocarditis, IVC inferior vena cava, RA right atrium, RV right ventricle, TR tricuspid regurgitation

- Diminished peripheral pulse volume secondary to low cardiac output.
- Atrial fibrillation.
- Venous systolic thrill in the neck may present in severe TR.
- Jugular venous pressure is elevated with a prominent systolic ‘v’ wave in 35% to 75% of patients (Fig. 2.1).
- Ascites.
- Hepatomegaly in 90% of patients. Palpable systolic pulsations of an enlarged and tender liver is less common.
- Pulmonary rales, if the tricuspid regurgitation is associated with left ventricular dysfunction or mitral stenosis.
- Right ventricular impulse is hyperdynamic and may be thrusting in quality.
- Heart sounds and murmurs:
 - In presence of pulmonary hypertension, the pulmonary component of the second heart sound becomes accentuated and a high-pitched pansystolic murmur is audible most prominent in the fourth intercostal space in the left parasternal area. The murmur is accentuated during inspiration, with exercise, with legs raised, and with direct liver compression.
 - In the absence of pulmonary hypertension, the pulmonary component of the second heart sound is normal and the murmur is usually low-pitched and short (limited to first half of systole).
 - In RV failure, RV S₃ and S₄ gallop that increases with inspiration can be detected.
 - In tricuspid valve prolapse, murmur is late systolic and mid-systolic click may present.
 - In advanced stage of severe TR, the murmur is barely audible or absent due to ventricularization of RA.
 - Diastolic TR: It can occur if atrial contraction is not followed by ventricular contraction at regular interval e.g. heart block, restrictive cardiomyopathy, severe pulmonary regurgitation.

Differential Diagnosis

- Atrial Fibrillation
- Biliary Disease
- Ebstein Anomaly
- Cardiac Cirrhosis and Congestive Hepatopathy
- Cor Pulmonale
- Dilated Cardiomyopathy
- Eisenmenger Syndrome
- Heart Failure
- Intestinal Carcinoid Tumor
- Mitral Regurgitation

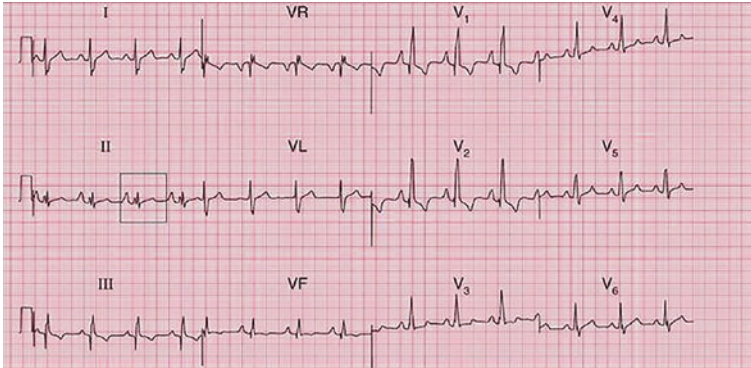


Fig. 2.2 ECG findings in Ebstein anomaly

Investigations

ECG (Fig. 2.2): Findings are usually nonspecific; they may show right atrial hypertrophy (tall peaked ‘p’ waves), incomplete right bundle-branch block, Q waves in lead V1, and atrial fibrillation.

Chest Radiography: Chest X ray has limited utility. It may show one or more of these findings:

- Marked cardiomegaly
- Evidence of elevated right atrial pressure may include distention of the azygous vein and pleural effusions
- Ascites with diaphragmatic elevation may be present
- Pulmonary arterial and venous hypertension is common

Echocardiography: is the main diagnostic modality to detect and quantify TR and for quantification of cardiac chambers, determination of right ventricular and pulmonary pressures and detection of other associated heart valve abnormalities (see Chaps. 5 and 6).

Cardiac magnetic resonance (CMR): CMR is the preferred method when available, for evaluating RV size and function (see Chap. 8).

Cardiac catheterisation: Catheterization may be required prior to surgery to rule out coronary artery disease and help determine the severity of the regurgitation and associated congenital defects (see Chap. 13).

Natural History and Prognosis

Moderate or greater degree of TR, regardless of aetiology, usually engenders worsening TR owing to overload, resulting in a slow and inexorable clinical and hemodynamic deterioration [25–27]. There are key facts that could summarize the natural history and prognosis of TR:

- Significant reduction in exercise functional capacity due to impaired cardiac output in severe TR.
- Severe TR has a poor prognosis, even if it may be well tolerated functionally for years.
- Prolonged volume overload may result in ventricular dysfunction and irreversible myocardial damage.
- Atrial arrhythmias are common secondary to RA enlargement and may be difficult to treat in the presence of chronic and severe TR.
- Flail TV (classically associated with severe TR) is associated with decreased survival and increased risk of heart failure.
- TR may persist even after successful correction of left-sided lesions.
- Pulmonary hypertension, increased right ventricular pressure and size, impaired RV function, atrial fibrillation, pacemaker leads and the severity of tricuspid valve deformation are important risk factors for persistence or late worsening TR.

Medical Therapy

In brief, medical therapy used in the treatment of TR is directed primarily toward control of left-sided heart failure that is causing or contributing to the problem. However, there are no data on the efficacy of various pharmacological approaches in severe TR. In addition to reduction of fluid and salt intake, the following medications can be used:

Diuretics: Diuretics are used to control the fluid overload associated with TR. The dose must be individualized to the patient according to his loading status and response to diuresis. Dose is titrated until a satisfactory effect is achieved.

Anti-arrhythmics: To control atrial fibrillation and to increase myocardial contractility.

Digoxin (Lanoxin): Its direct inotropic effects on cardiac muscle lead to increase of myocardial systolic contraction. Its indirect actions result in increased carotid sinus nerve activity and enhanced sympathetic withdrawal for any given increase in mean arterial pressure.

ACE Inhibitors: ACE inhibitors are used to provide afterload reduction, thereby decreasing the RV volume load.

Long-Term Monitoring

Patients with a history of TR should be carefully monitored for control of any heart failure. Repeat echocardiography is indicated at 6-month intervals for patients in whom the valve has been repaired. Annual echocardiography should be considered in patients in whom valve has been replaced.

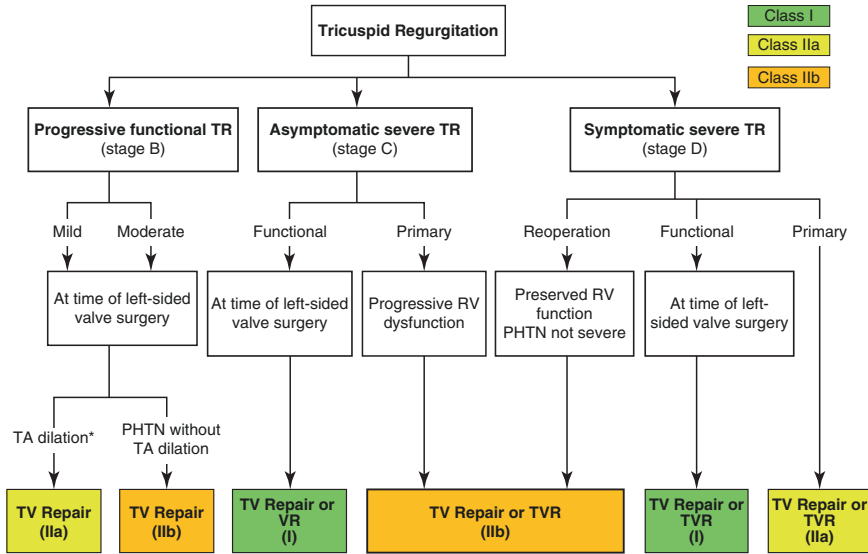


Fig. 2.3 Indications for Surgery are shown on the figure in respect with stages of presentation as well as grading of severity. See Table 2.2 for definition of stages. Tricuspid annulus dilatation is defined by >40 mm on TTE >21 mm/m² or >70 mm on direct intraoperative measurement. *LV* left ventricular, *PHTN* pulmonary hypertension, *RV* right ventricular, *TA* tricuspid annular, *TR* tricuspid regurgitation, *TTE* transthoracic echocardiogram, *TV* tricuspid valve, *TVR* tricuspid valve replacement. Reprinted with permission from Nishimura et al. [6]

Surgical Intervention: Surgical options include annuloplasty and valve replacement. Timing of surgery and selection of proper intervention will be discussed later Chap. 17. Figure 2.3 outlines ACC/AHA guidelines for treatment of patients with TR.

Percutaneous Interventions: Many techniques applied for mitral valve are tested for correction of TR e.g. TriAlign, MitraClip system, Millipede system and valve stent. More details are discussed in Chap. 18.

Approach Considerations

The choice of treatment for TR depends on the aetiology and severity of the condition. Dreyfus et al. [28] classified the functional TR into three stages:

- Stage 1: No or mild TR, normal annulus diameter <40 mm and good surface of coaptation between leaflets. In this stage, no surgical intervention is indicated.
- Stage 2: Mild or moderate TR, dilated annulus >40 mm and leaflet coaptation occurring only at the edges. In this stage, surgical tricuspid annuloplasty is recommended.
- Stage 3: Severe TR, Dilated annulus >40 mm and leaflet coaptation occurring only at the edges or not at all. Leaflet tethering may be added. In this stage, surgical tricuspid annuloplasty is recommended. Augmentation of the anterior leaflet is indicated if significant tethering is present.

Specific Conditions

Flail TV: Flail tricuspid leaflet has been defined as a prolapsed TV leaflet with excursion of the leaflet edge and/or free chords into the RA during systole. Flail TV leaflets causing severe TR is usually due to blunt chest trauma and can be identified years later [29, 30]. Its frequency is underestimated because initial attention is usually placed on other organ injuries. The right ventricle is being vulnerable to blunt trauma and acute elevation of its intraventricular pressure results in injury of the TV apparatus. Furthermore, flail TV can be caused by infective endocarditis or is a consequence of a myxomatously degenerated valve. Messika-Zeitoun et al. [25] reported a traumatic cause in 62% of patients, related to blunt chest trauma (mostly motor vehicle accident) in 50% and iatrogenic chordal severing (mostly right ventricular biopsy) in the other 50%. Non-traumatic causes were myxomatous (12%), infective endocarditis (8%), and congenital (3%). The most frequently reported mechanism of injury is chordal rupture, followed by rupture of the anterior papillary muscle and leaflet tear, primarily of the anterior leaflet. Early surgery should be considered because of high risk of long-term poor prognosis and the likelihood of repair is high.

Ebstein Anomaly: Ebstein anomaly is a congenital malformation that is characterized by apical displacement of the septal and posterior TV leaflets, leading to atrialization of the RV with a variable degree of malformation and displacement of the anterior leaflet. Ebstein anomaly probably accounts for 0.5% of cases of congenital heart diseases. Ebstein anomaly is more common in children of white females with no specific sex predominance exists. It can present at various stages of life [31].

- Fetal life: It is usually diagnosed incidentally by echocardiography.
- Neonatal life and infancy: It presents with cyanosis and/or severe heart failure; typically, symptoms present in infancy and later on improve as pulmonary vascular resistance decreases.
- Adult life: It presents with fatigue, exertional dyspnea, cyanosis, TR and/or right heart failure, palpitations; and arrhythmias are common.

Ebstein anomaly presents with a spectrum of congenital abnormalities of the TV and the right ventricle. Treatment of Ebstein anomaly is complex and dictated mainly by the severity of the disease itself and the effect of accompanying congenital structural and electrical abnormalities [32]. Treatment options include medical therapy, radiofrequency ablation, and surgical therapy.

Pacemakers and Defibrillators-Induced TR: The current literature regarding symptomatic, lead-related TR following ICD or PPM is based mainly on case reports and observational studies [33]. The prevalence of TR is between 25 and 29% of patients with PPM. TR may worsen, or new TR may develop after up to 7 years of device implantation [34]. The possible mechanism of new development or worsening of TR is one or more of the following [35–37]:

- Mechanical causes such as scar formation or thrombus on the leads impairing closure.

- Perforation or lacerations of valve leaflets are most commonly noted at the posterior leaflet.
- Asynchrony, resulting from abnormal RV activation from a pacemaker.
- Adherence of the pacemaker leads to the TV leaflets, and even more commonly to the papillary muscles.

When clinically significant, management typically involves percutaneous extraction of the offending leads. Larger, prospective, and well-controlled studies are needed to truly assess the incidence and timing of TR after lead implantation along with associated prognosis and mortality [35]. Pacemakers and defibrillators induced TR are discussed in more details in Chap. 4.

Secondary TR due to pulmonary hypertension: Pulmonary hypertension is a common cause of functional TR. Pulmonary artery systolic pressure is a strong determinant of TR severity, but many patients with pulmonary hypertension do not exhibit significant TR. In addition to PASP, demographic characteristics, mechanical factors, remodeling of the right heart cavities, and other factors (possibly reflecting the presence of atrial fibrillation or occult organic TV disease) are predictive of TR severity [38]. In patients with pulmonary hypertension secondary to pulmonary thromboembolic disease, pulmonary thromboendarterectomy alone has been shown to reduce not only pulmonary hypertension but also TR without the need for concomitant tricuspid annuloplasty even if the tricuspid valve annulus is dilated. TR secondary to severe primary pulmonary hypertension is usually treated with pulmonary vasodilator and diuretic therapy alone because of the risk of cardiac surgical intervention and the poor overall prognosis [39].

Carcinoid heart diseases (See TS)

Left ventricular assist devices (LVAD): Almost 50% of patients referred for implantable LVAD have significant TR. Severe RV dysfunction is a predictor of high postoperative mortality. Concomitant TV procedures (repair or bioprosthesis) for severe TR promotes RV reverse remodeling and improved clinical outcomes [40, 41].

Pregnancy: The patient with isolated severe TR without RV dysfunction generally tolerates pregnancy well and rarely causes any clinical sequelae during pregnancy, labor or delivery, and rarely requires correction prior to pregnancy. However, maternal risk can be increased in severe symptomatic TR or in women with RV dysfunction. The management of severe TR with heart failure is usually conservative during pregnancy. In severe symptomatic TR, repair should be considered pre-pregnancy. The preferred mode of delivery is vaginal in almost all cases [42].

Tricuspid Atresia

In patients with tricuspid atresia, venous blood returning to the RA can only exit via an intra-atrial communication. Other cardiovascular anomalies may co-exist with tricuspid atresia—e.g., transposition of the great vessels.

Presentation

- Tricuspid atresia is usually detected in infancy with cyanosis, heart failure and growth restriction.
- Raised jugular venous pressure.
- The left ventricular impulse is prominent because of volume overload. The apical impulse is displaced to the left of the mid-clavicular line.
- The liver may be large and pulsatile.
- There is usually a single first heart sound that may be increased in intensity. The second heart sound may be single or normally split.
- Cardiac murmurs are often present:
 - A pansystolic murmur, which may signify blood flow through the ventricular septal defect.
 - Systemic-to-pulmonary arterial collaterals or arterial-to-pulmonary arterial anastomoses surgically created to improve pulmonary blood flow, which may cause a continuous murmur.
 - A murmur indicating mitral regurgitation, which may be present.

Investigations

- Full blood picture may show polycythaemia.
- Blood gases may show hypoxaemia and acidosis.
- CXR: cardiomegaly is usually present, with a prominent right heart border (enlargement of the right atrium). Pulmonary vascular markings are usually diminished (but may be increased when pulmonary flow is not obstructed).
- Other investigations include ECG, echocardiography and cardiac catheterisation.

Management

- Infants with obstructed pulmonary blood flow and severe hypoxaemia require urgent prostaglandin E infusions in order to maintain patency of the ductus arteriosus.
- Other non-surgical management includes oxygen therapy, prevention of bacterial endocarditis and management of heart failure.
- Most patients with tricuspid atresia require some form of surgical treatment during the first year of life, usually involving a palliative shunt procedure.
- Fontan's operation involves the formation of a right atrial-to-pulmonary artery connection or an extracardiac vena cava-to-pulmonary artery anastomosis.

Complications

- Paradoxical emboli, stroke, brain abscess.
- Polycythaemia.
- Progressive cardiac dilatation.
- Ventricular dysfunction.
- Mitral valve insufficiency.
- Arrhythmias.

Prognosis

The prognosis will depend on associated cardiac abnormalities. The perioperative mortality of the Fontan procedure is about 5%.

Review Questions

Select the Single Best Answer

6. Maneuvers that increase the intensity of murmur in TS act through:
 - (a) Increase the heart rate
 - (b) Decrease the pulmonary blood flow
 - (c) Create the balance between right and left side of the heart
 - (d) increase the systemic venous return to RA
7. The following diseases are mimicking TS due to delay diastolic emptying of RA except:
 - (a) Tricuspid Atresia
 - (b) Atrial Myxoma
 - (c) Restrictive Cardiomyopathy
 - (d) Large endocarditis vegetations
8. In significant TS, examination of JVP may show:
 - (a) Prominent V wave with slow y descent
 - (b) Prominent V wave with rapid y descent
 - (c) Prominent a wave with slow y descent
 - (d) Prominent a wave with slow x descent

9. Secondary TR can be related to the following mechanisms except:
- (a) lack of leaflet apposition
 - (b) Increased tricuspid leaflet tethering
 - (c) Moderate subvalvular affection
 - (d) Dilated TV annulus
10. Edema and ascites in patients with TV disease indicate that:
- (a) Pulmonary hypertension is associated with significant TS
 - (b) Pulmonary hypertension is associated with significant TR
 - (c) TS is not associated with pulmonary hypertension
 - (d) TS is associated with significant MS
11. In patients with significant TR, murmur intensity and duration are changing according to the following except
- (a) Change in heart rate
 - (b) RV systolic function (good or poor)
 - (c) Presence of pulmonary hypertension
 - (d) Maneuvers that increase venous return
12. Which of the following sentences is correct?
- (a) In patient with TS, paroxysmal nocturnal dyspnea is common symptoms
 - (b) In patient with TS, paroxysmal nocturnal dyspnea is rare symptoms
 - (c) In patient with mild TR, paroxysmal nocturnal dyspnea is common symptoms
 - (d) In patient with severe TR, paroxysmal nocturnal dyspnea is common symptoms
13. Which of the following sentences is correct?
- (a) Examination of JVP in TS, prominent a wave is a common finding regardless of the heart rhythm
 - (b) Examination of JVP in TS, prominent a wave is a common finding in patients with atrial fibrillation
 - (c) Examination of JVP in TS, prominent a wave is a common finding in patients with sinus rhythm
 - (d) Examination of JVP in TS, prominent x wave is a common finding in patients with atrial fibrillation
14. Which of the following sentences is correct?
- (a) Low pitched opening snap can be detected with TS
 - (b) High pitched opening snap can be detected with TS
 - (c) Low pitched opening snap can be detected with TR
 - (d) High pitched opening snap cannot be detected with TS

15. Which of the following sentences is correct?
- (a) Murmur of TS is always mid systole in both sinus and AF patients.
 - (b) Murmur of TS is always mid diastole in both sinus and AF patients.
 - (c) Murmur of TS is always early systole in both sinus and AF patients.
 - (d) Murmur of TS is always early diastolic in sinus and early to mid in AF patients.
16. Which of the following sentences is correct?
- (a) Differentiation between physiologic TR and organic TR is based mainly on the degree of TR.
 - (b) Differentiation between physiologic TR and organic TR is based mainly on the degree of flow reversal in pulmonary veins.
 - (c) Differentiation between physiologic TR and organic TR is based mainly on the degree of flow reversal in hepatic veins.
 - (d) Differentiation between physiologic TR and organic TR is based mainly on the valve morphology.
17. Which of the following sentences is correct?
- (a) Development of pulmonary oedema in TS patients excludes the suspicion of concomitant mitral valve disease.
 - (b) Development of pulmonary oedema in TS patients raises the suspicion of concomitant mitral valve disease.
 - (c) Development of pulmonary oedema in TS patients indicated always pulmonary origin of the pulmonary oedema
 - (d) Development of pulmonary oedema in TS patients indicated combined severe TR.

Case Studies

Case (1): 43 years old female had long history of rheumatic heart disease since childhood. During last delivery 5 years ago, she was diagnosed as moderate MS. At that time, she was dyspnoeic and admitted at ICU after delivery for diuresis and heart rate control. Regular echo and follow up showed progression of MS severity and she was advised to do balloon valvuloplasty 2 years ago but she was reluctant. Last month in outpatient cardiology clinic she told her doctor that she stopped all medications because she felt better and no symptoms. Cardiac examination showed reduction of the intensity of MS murmur and elevated JVP.

18. Select one or more of possible explanation(s) of these new changes and explain why??
- (a) Development of significant mitral regurgitation
 - (b) Development of significant Aortic regurgitation
 - (c) Development of significant TR
 - (d) Development of significant TS
19. The expected main echocardiographic finding is:
- (a) Dilated left ventricle with severe mitral regurgitation
 - (b) Dilated RA with significant TS
 - (c) Dilated RV with severe TR
 - (d) Dilated both right and left ventricles
20. According to the latest ACC/AHA guidelines for the management of valvular heart disease, this patient can be classified at stage:
- (a) Stage A.
 - (b) Stage B
 - (c) Stage C/D
 - (d) Stage E

Case (2): 45 years old female came to cardiology clinic complaining of dyspnea on exertion (class II). No other complaint. She had no past history of cardiac problem and not on any medication. Clinical examination detected mild lower limb edema and slightly elevated JVP. Cardiac auscultation detected ejection systolic murmur at the left second intercostals space. Resting ECG showed right axis deviation and signs of RV dilatation.

21. What are the possible valve lesions?
- (a) Aortic stenosis and mitral regurgitation
 - (b) Tricuspid stenosis and mitral regurgitation
 - (c) Tricuspid regurgitation and pulmonary stenosis
 - (d) Aortic stenosis and pulmonary stenosis
22. What is the possible underlying aetiology?
- (a) Rheumatic heart disease
 - (b) Carcinoid disease
 - (c) Myxomatous degeneration
 - (d) Calcific
23. What are the expected echo findings in this case?
- (a) Thickened and restricted mobility of TV leaflets
 - (b) Flail septal leaflet of TV
 - (c) Doming and thickening of all TV leaflets

References

1. Shah PM, Raney AA. Tricuspid valve disease. *Curr Probl Cardiol.* 2008;33:47–84.
2. Chambers JB, Bridgewater B. Epidemiology of valvular heart disease. In: Otto CM, Bonow RO, editors. *Valvular heart disease: a companion to Braunwald's heart disease.* 4th ed. Philadelphia, PA: Elsevier/Saunders; 2014. 1 online resource (xix, 454 pages).
3. Hauck AJ, Freeman DP, Ackermann DM, Danielson GK, Edwards WD. Surgical pathology of the tricuspid valve: a study of 363 cases spanning 25 years. *Mayo Clin Proc.* 1988;63:851–63.
4. Bruce CJ, Connolly HM. Right-sided valve disease deserves a little more respect. *Circulation.* 2009;119:2726–34.
5. Wooley CF, Fontana ME, Kilman JW, Ryan JM. Tricuspid stenosis. Atrial systolic murmur, tricuspid opening snap, and right atrial pressure pulse. *Am J Med.* 1985;78:375–84.
6. Nishimura RA, Otto CM, Bonow RO, et al. AHA/ACC guideline for the management of patients with valvular heart disease: executive summary: a report of the American College of Cardiology/American Heart Association Task Force on Practice Guidelines. *J Am Coll Cardiol.* 2014;63:2438–88.
7. Baumgartner H, Hung J, Bermejo J, et al. Echocardiographic assessment of valve stenosis: EAE/ASE recommendations for clinical practice. *Eur J Echocardiogr.* 2009;10:1–25.
8. Waller BF, Howard J, Fess S. Pathology of tricuspid valve stenosis and pure tricuspid regurgitation--Part III. *Clin Cardiol.* 1995;18:225–30.
9. Yousof AM, Shafei MZ, Endrys G, Khan N, Simo M, Cherian G. Tricuspid stenosis and regurgitation in rheumatic heart disease: a prospective cardiac catheterization study in 525 patients. *Am Heart J.* 1985;110:60–4.
10. Perloff JK. *The clinical recognition of congenital heart disease.* 3rd ed. Philadelphia: Saunders; 1987.
11. Fox DJ, Khattar RS. Carcinoid heart disease: presentation, diagnosis, and management. *Heart.* 2004;90:1224–8.
12. Thatipelli MR, Uber PA, Mehra MR. Isolated tricuspid stenosis and heart failure: a focus on carcinoid heart disease. *Congest Heart Fail.* 2003;9:294–6.
13. Waller BF, Howard J, Fess S. Pathology of tricuspid valve stenosis and pure tricuspid regurgitation--Part II. *Clin Cardiol.* 1995;18:167–74.
14. Kuralay E, Cingoz F, Gunay C, Demirkilic U, Tatar H. Huge right atrial myxoma causing fixed tricuspid stenosis with constitutional symptoms. *J Card Surg.* 2003;18:550–3.
15. Uribe-Etxebarria N, Voces R, Rodriguez MA, Llorente A, Perez P, Aramendi JI. Reversible tricuspid valve stenosis due to a metastatic dissemination of a noncardiac sarcoma. *Ann Thorac Surg.* 2005;80:e1–2.
16. Onate A, Alcibar J, Inguanzo R, Pena N, Gochi R. Balloon dilation of tricuspid and pulmonary valves in carcinoid heart disease. *Tex Heart Inst J.* 1993;20:115–9.
17. Stuge O, Liddicoat J. Emerging opportunities for cardiac surgeons within structural heart disease. *J Thorac Cardiovasc Surg.* 2006;132:1258–61.
18. Singh JP, Evans JC, Levy D, et al. Prevalence and clinical determinants of mitral, tricuspid, and aortic regurgitation (the Framingham Heart Study). *Am J Cardiol.* 1999;83:897–902.
19. Badano LP, Muraru D, Enriquez-Sarano M. Assessment of functional tricuspid regurgitation. *Eur Heart J.* 2013;34:1875–85.
20. Izumi C, Iga K, Konishi T. Progression of isolated tricuspid regurgitation late after mitral valve surgery for rheumatic mitral valve disease. *J Heart Valve Dis.* 2002;11:353–6.
21. Chikwe J, Itagaki S, Anyanwu A, Adams DH. Impact of concomitant tricuspid annuloplasty on tricuspid regurgitation, right ventricular function, and pulmonary artery hypertension after repair of mitral valve prolapse. *J Am Coll Cardiol.* 2015;65:1931–8.
22. Dreyfus GD, Corbi PJ, Chan KM, Bahrami T. Secondary tricuspid regurgitation or dilatation: which should be the criteria for surgical repair? *Ann Thorac Surg.* 2005;79:127–32.

23. Frater R. Tricuspid insufficiency. *J Thorac Cardiovasc Surg.* 2001;122:427–9.
24. Raja SG, Dreyfus GD. Basis for intervention on functional tricuspid regurgitation. *Semin Thorac Cardiovasc Surg.* 2010;22:79–83.
25. Messika-Zeitoun D, Thomson H, Bellamy M, et al. Medical and surgical outcome of tricuspid regurgitation caused by flail leaflets. *J Thorac Cardiovasc Surg.* 2004;128:296–302.
26. Nath J, Foster E, Heidenreich PA. Impact of tricuspid regurgitation on long-term survival. *J Am Coll Cardiol.* 2004;43:405–9.
27. Topilsky Y, Nkomo VT, Vatury O, et al. Clinical outcome of isolated tricuspid regurgitation. *JACC Cardiovasc Imaging.* 2014;7:1185–94.
28. Dreyfus GD, Martin RP, Chan KM, Dulguerov F, Alexandrescu C. Functional tricuspid regurgitation: a need to revise our understanding. *J Am Coll Cardiol.* 2015;65:2331–6.
29. Gill DS, Lee RK, Yong QW, Ng KS. Isolated traumatic chordal rupture of the anterior tricuspid valve. *Echocardiography.* 2006;23:254–5.
30. Gulel O, Demir S, Gol MK. Detection of flail tricuspid valve many years after blunt chest trauma. *Eur J Echocardiogr.* 2008;9:119–20.
31. Munoz-Castellanos L, Espinola-Zavaleta N, Kuri-Nivon M, Keirns C. Ebstein's Anomaly: anatomic-echocardiographic correlation. *Cardiovasc Ultrasound.* 2007;5:43.
32. Attenhofer Jost CH, Connolly HM, Dearani JA, Edwards WD, Danielson GK. Ebstein's anomaly. *Circulation.* 2007;115:277–85.
33. Klutstein M, Balkin J, Butnaru A, Ilan M, Lahad A, Rosenmann D. Tricuspid incompetence following permanent pacemaker implantation. *Pacing Clin Electrophysiol.* 2009;32(Suppl 1):S135–7.
34. Chen TE, Wang CC, Chern MS, Chu JJ. Entrapment of permanent pacemaker lead as the cause of tricuspid regurgitation. *Circ J.* 2007;71:1169–71.
35. Al-Bawardy R, Krishnaswamy A, Bhargava M, et al. Tricuspid regurgitation in patients with pacemakers and implantable cardiac defibrillators: a comprehensive review. *Clin Cardiol.* 2013;36:249–54.
36. Iskandar SB, Ann Jackson S, Fahrig S, Mechleb BK, Garcia ID. Tricuspid valve malfunction and ventricular pacemaker lead: case report and review of the literature. *Echocardiography.* 2006;23:692–7.
37. Lin G, Nishimura RA, Connolly HM, Dearani JA, Sundt TM 3rd, Hayes DL. Severe symptomatic tricuspid valve regurgitation due to permanent pacemaker or implantable cardioverter-defibrillator leads. *J Am Coll Cardiol.* 2005;45:1672–5.
38. Mutlak D, Aronson D, Lessick J, Reisner SA, Dabbah S, Agmon Y. Functional tricuspid regurgitation in patients with pulmonary hypertension: is pulmonary artery pressure the only determinant of regurgitation severity? *Chest.* 2009;135:115–21.
39. Sadeghi HM, Kimura BJ, Raisinghani A, et al. Does lowering pulmonary arterial pressure eliminate severe functional tricuspid regurgitation? Insights from pulmonary thromboendarterectomy. *J Am Coll Cardiol.* 2004;44:126–32.
40. Piacentino V 3rd, Troupes CD, Ganapathi AM, et al. Clinical impact of concomitant tricuspid valve procedures during left ventricular assist device implantation. *Ann Thorac Surg.* 2011;92:1414–8. discussion 1418–9
41. Potapov EV, Schweiger M, Stepanenko A, et al. Tricuspid valve repair in patients supported with left ventricular assist devices. *ASAIO J.* 2011;57:363–7.
42. European Society of Gynecology (ESG), Association for European Paediatric Cardiology (AEPC), German Society for Gender Medicine (DGesGM), et al. ESC Guidelines on the management of cardiovascular diseases during pregnancy: the Task Force on the Management of Cardiovascular Diseases during Pregnancy of the European Society of Cardiology (ESC). *Eur Heart J.* 2011;32:3147–97.

Chapter 3

Tricuspid Regurgitation in Patients with Heart Transplant

Kadir Caliskan, Mihai Strachinaru, and Osama I. Soliman

Abstract In this chapter, an overview of the epidemiology, the pathophysiology, the clinical features, management and prognosis of tricuspid regurgitation in patients post heart transplant will be discussed. An overview of the natural history of severe tricuspid regurgitation and treatment options will be illustrated via a clinical case.

Keywords Tricuspid • Regurgitation • Heart transplant • Echocardiography • Therapy • Outcome

Introduction

Tricuspid regurgitation (TR) is one of the common cardiac complications post heart transplantation (HTx), potentially jeopardizing the long-term outcome and survival. However, despite existence of the clinical problem from the beginning of the HTx era in the early 80s, the appropriate approach for clinical management is yet not established. In this chapter, we present a clinical case with severe post-HTx TR, in which for a long time a surgical approach was postponed by the patient, illustrating the natural history of severe TR with all the potential cardiac and extra-cardiac complications. Thereafter, we provide an overview of the pathophysiology, the epidemiology, the clinical features, management and prognosis of TR according the current literature combined with our clinical experience as a medium sized HTx center since 1984.

Electronic Supplementary Material The online version of this chapter (doi: [10.1007/978-3-319-58229-0_3](https://doi.org/10.1007/978-3-319-58229-0_3)) contains supplementary material, which is available to authorized users.

K. Caliskan, M.D., Ph.D. (✉) • M. Strachinaru, M.D. • O.I. Soliman, M.D., Ph.D.
Department of Cardiology, Unit Heart Failure, Heart Transplantation & Mechanical Circulatory Support, The Thoraxcenter, Erasmus MC: University Medical Center Rotterdam, Rotterdam, The Netherlands
e-mail: k.caliskan@erasmusmc.nl

Case

Mrs. A underwent HTx in 1994, at the age of 32 years, because of severe chronic heart failure due to dilated cardiomyopathy, from which she was suffering since 1990. In 2012, pathogenic phospholamban mutation was found as the aetiology of her familial dilated cardiomyopathy. In the first year after transplantation, she was treated for three episodes of acute cellular rejection. From the first year on she was known with severe TR with partial prolapse due to chordae rupture, probably a complication of several surveillance endomyocardial biopsies (EMB's). The right atrium (RA) and right ventricle (RV) was severely dilated, but with preserved systolic function. The left ventricular function was normal, but the septum movement was paradoxal. The liver veins and vena cava inferior (VCI) were also dilated (30 mm), and TR peak velocity of 2.2 m/s. The hepatic veins Doppler showed systolic reversal. From 1994 to 2008 she remained reasonably well compensated with a good quality of life.

In 2008 she developed paroxysmal atrial tachycardia, along with progression of the right-sided congestion. Low doses of furosemide, metoprolol and later on flecainide was started. Because of syncope due the asystole's in 2009, a DDI-pacemaker was implanted. In the same year, electrophysiological ablation of the paroxysmal atrial tachycardia were performed. In the years following, she was relatively stable with low dose furosemide. Her echocardiography in 2010 showed persistent RV dilatation, severe RA dilatation and severe TR. The VCI was unvaried dilated (33 mm), barely collapsing. Her estimated systolic RV pressure was 39 mm Hg.

In 2014, she had more and more complaints of fatigue, right-sided congestion and slowly deterioration of her renal insufficiency and liver enzymes (see Fig. 3.1a and b). She had an evident progression of the TR severity with an estimated systolic RV pressure of 56 mm Hg. Her case was extensively discussed in the transplant team and a tricuspid valve surgery advised. The patient however was very reluctant about a major cardiac surgery and asked a second opinion in another heart centre. Their advice was however the same, but the patient remained dismissive of the operation.

In June 2016, she was admitted with severe heart failure and progression of her renal insufficiency. The electrocardiogram (see Fig. 3.2) of the severe TR patient at the latest follow-up, showing prominent right bundle branch block with right sided strain pattern, present from the very early in the course of the heart transplantation. She was treated with intravenous inotropic and diuretics and heart failure symptoms could be fairly compensated. However, this was at the expense of her renal function, with estimated e-GFR values of 20–30 mL/min, only with the support of continuous intravenous inotropics. On the other hand, without inotropic support, her renal functions deteriorated to e-GFR 15 mL/min and her symptoms escalated. After extensive discussion with the patient and family, we decided at last for tricuspid valve surgery. This was done in July 2016, with a valve replacement by a bioprosthesis. The postoperative period was complicated by transient delirium and acute

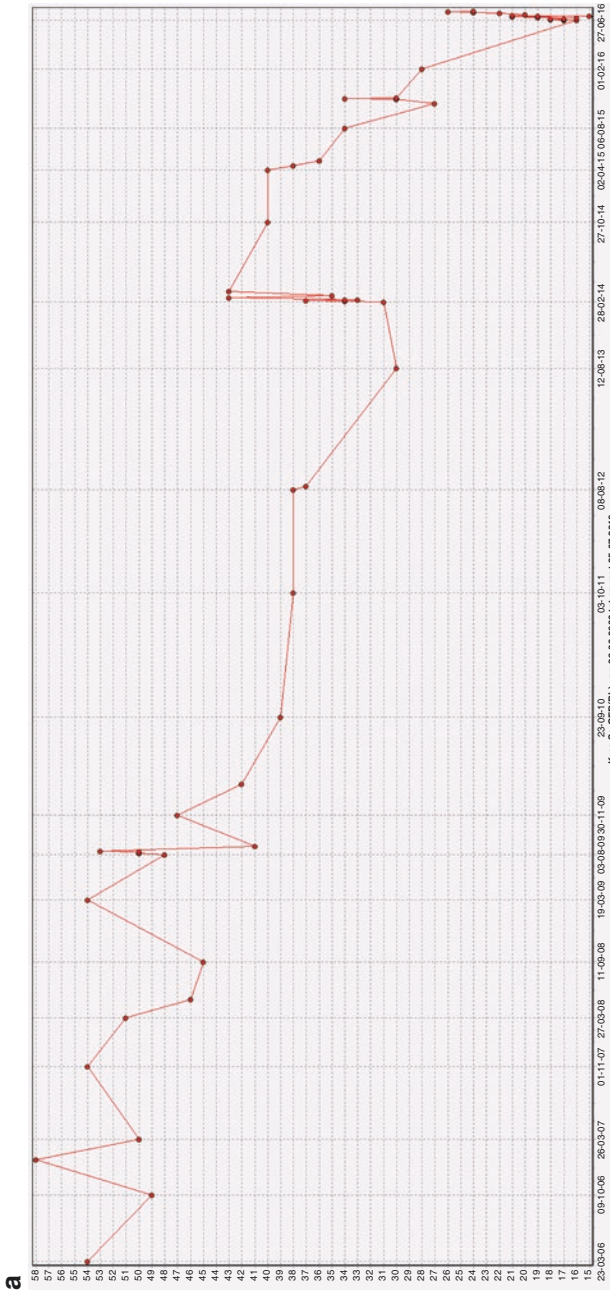


Fig. 3.1 (a) The e-GFR in the last 10 years. The renal function is progressively deteriorating albeit the clinical symptoms of right sided heart failure were present only during the last couple of years. (b) The cours of gamma-GT in the last 10 years. It's the most reliable parameter, like the e-GFR for the cardio-renal syndrome, for the cardio-hepatic syndrome as the right sided heart failure/chronic hepatic congestion over time progress. (c) The classical heart failure bio-marker is less reliable in the setting of chronic right sided heart failure as a marker of the progression. The NT-proBNP is chronically 20–25 times the normal value ($N < 14$) elevated, but escalated very late in the disease course

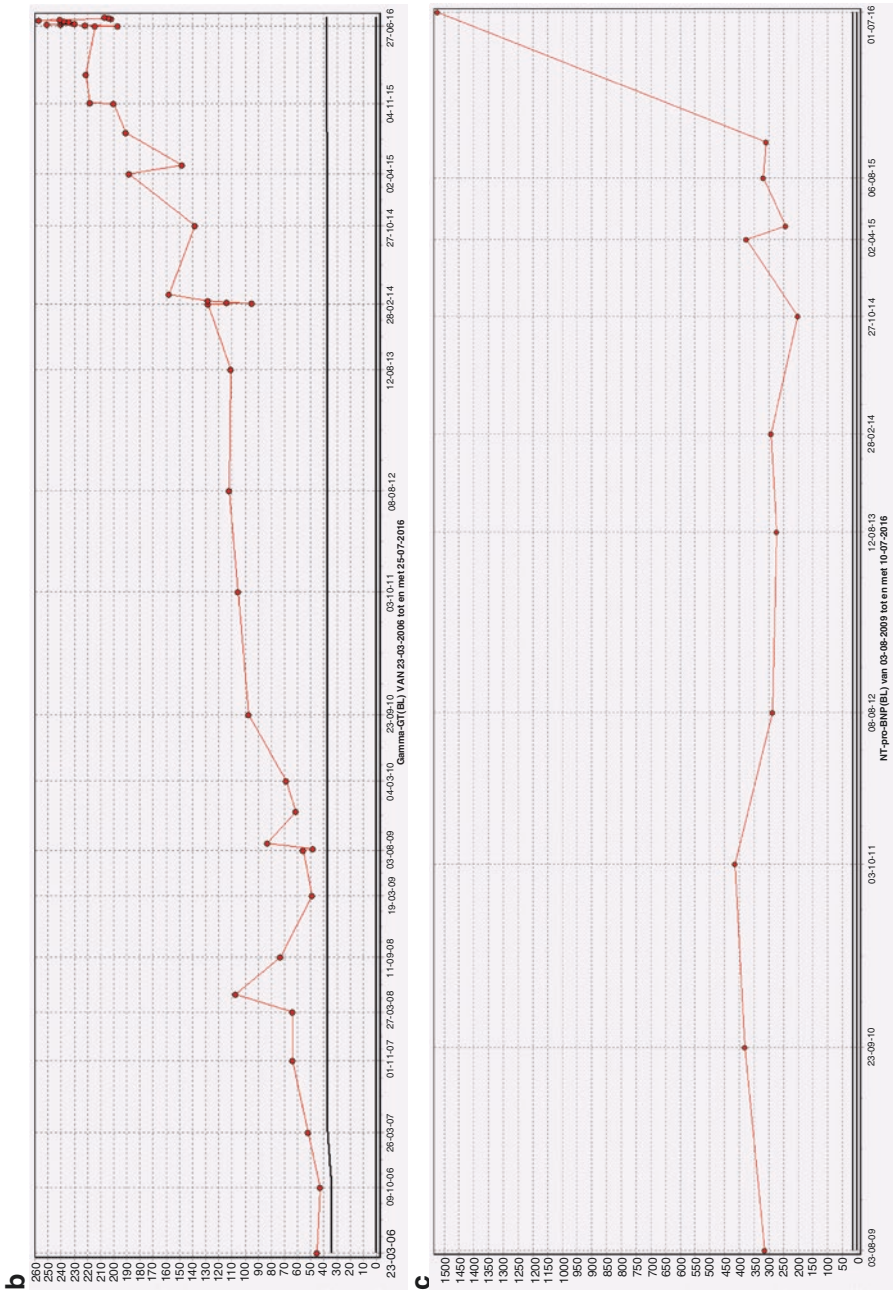


Fig. 3.1 (continued)

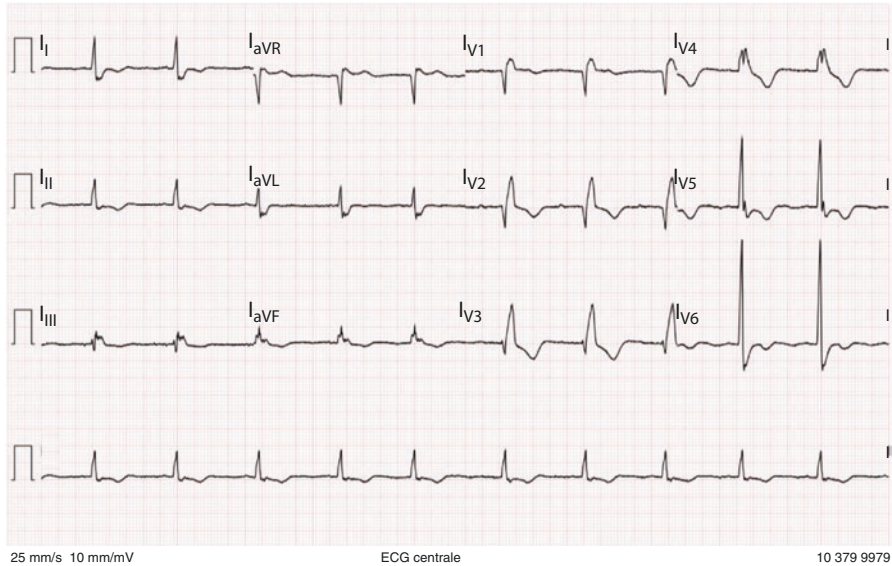


Fig. 3.2 The electrocardiogram of the severe tricuspid regurgitation patient at the last follow-up, showing prominent right bundle branch block with right sided strain pattern, which was present from the very early in the course after the heart transplantation

kidney failure, but she recovered very well. At 3-months follow-up, she was remained stable without signs of herat failure and her renal function was improved to serum creatinine of 125 mmol/L and a e-GFR of 39 mL/min.

Her preoperative (see Fig. 3.3a through c and Videos S1–S3) as well as postoperative (see Fig. 3.3d through f and Videos S4–S6) echocardiographic finding are shown.

Epidemiology

TR prevalence is reported very variable, from 19 to 84% of all HTx recipients [1]. However, in our clinical cohort of 688 patients, severe TR was present in only 32 patients (4.7%), a marked difference, reflecting probably the variable definition used in the literature. In the report by Chan et al. presenting 336 patients, whom were transplanted between 1990 and 1995, they reported moderate TR in 27% and severe in 7%, comparable with our findings [2]. Berger et al. found significant TR in 14.1% of 163 HTx patients between 1988 and 2009, during a mean 8.2 years. Significant TR was correlated with the biatrial surgical technique ($p < 0.01$) and the presence of graft vasculopathy ($p < 0.001$) [3].

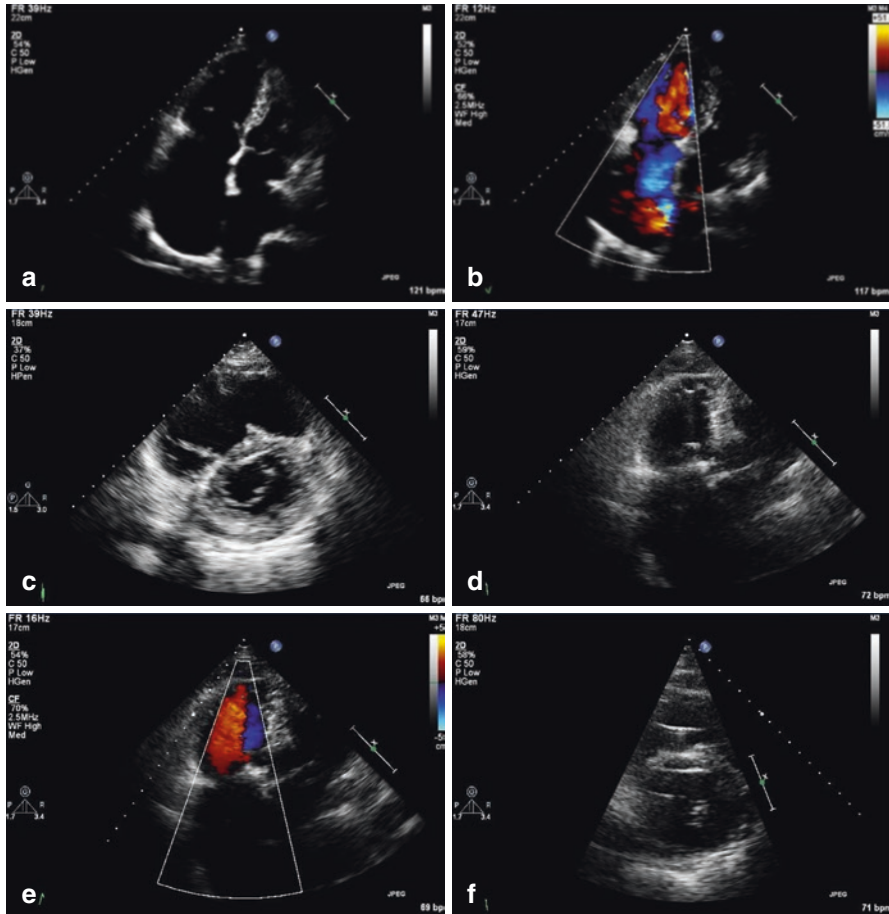


Fig. 3.3 (a, b, and c, Movies S1, S2, and S3) Apical four chamber view demonstrating the severe dilated right ventricle and atrium with severe tricuspid regurgitation. The parasternal short-axis view shows enlarged right ventricle with diastolic collaps (“D-sign”) of the interventricular septum. (d, e and f, Movies S4, S5, and S6) Postoperative images, showing relatively reduced right ventricular size, with trace resting tricuspid regurgitation and disappearance of the “D-sign”

Pathophysiology

There are several mechanisms of post HTx TR. Functional TR is usually caused by annular dilation due to postoperative RV failure due to pre-transplant pulmonary hypertension, RV dysfunction after several rejections, or donor-recipient size-mismatch [4]. On the other hand, structural valve abnormalities caused by torn leaflets, ruptured chordae are due to several surveillance EMB’s in the first year. The risk of EMB related tricuspid valve damage are related to operator experience, patients clinical state, access site, biotome type [5]. Fiorelli et al. followed 417 HTx patients between 1985 and 2010, who underwent in total 3550 EMB (average 8.5/pt)

after HTx. Traumatic tricuspid valve injury due to EMB rarely led to severe valvular regurgitation and only a minority of patients develop significant clinical symptoms [6]. On the other hand, Alharethi et al. found that flail leaflets were the most common operative finding, suggesting that biopsy-induced trauma is the likely cause of severe TR in these patients [7].

In the report by Tarek et al., orthotopic HTx was performed in 249 patients: 161 by the standard technique versus 88 by the bicaval technique. The incidence of both early and late TR was much lower with bicaval technique. Other variables influencing the prevalence of TR were: 2 or more rejections, total number of EMB's and severe preoperative pulmonary hypertension [8]. Furthermore, the native and recipient RA diameters were found to be a risk factor for the development of TR. Wartig et al. also found that bicaval orthotopic heart transplantation was the only predictor of lower risk of early significant TR (OR = 2.70; 95% CI = 1.68–4.32; $p < 0.001$).

Clinical Features

TR usually remains asymptomatic for years, despite progressive right atrial and ventricular dilatation and right-sided congestion. However, progressive atrial overload and dilatation results in the long-term atrial arrhythmias (atrial tachycardia's and atrial fibrillation). The third phase begins when the heart failure symptoms and signs develop. In this phase, physical examination reveals often markedly pulsating and distended jugular veins, progressive hepatomegaly, pulsating liver ("the liver pulse"), liver enzyme abnormalities, liver fibrosis and ultimately cardiac cirrhosis. The classical heart failure biomarker is less reliable in the setting of chronic right-sided heart failure as a marker of the progression. As shown in Fig. 3.1, the NT-proBNP is chronically 20–25 times the normal value ($N < 14$) elevated, but escalated very late in the disease course.

If left untreated, symptomatic severe TR results in progressive renal failure, the "cardio-renal syndrome", which is usually accelerated by the need of escalating doses of diuretics.

Management and Prognosis

TR was usually associated with increased mortality and morbidity. Patients with mild or no TR have better survival than those with moderate or severe TR [9]. The optimal treatment of post-transplant severe TR is however not well defined. Since severe TR remains asymptomatic for a long-time it is not unusual that conservative treatment is preferred to surgical treatment. Conservative treatment consists of appropriate management of volume overload and congestion by diuretics. Furthermore, any left-sided heart failure and/or pulmonary hypertension should be targeted aggressively. Digoxin should be prescribed for patients who develop signs of right ventricular dysfunction and/or supra-ventricular arrhythmias.

Surgical correction of severe TR is considered as the final solution for patients with refractory right-sided heart failure like in our case [1]. However, the right surgical approach and the timing of the surgery is yet not well defined. Alharethi et al. found that tricuspid valve repair or replacement is a safe and effective procedure to alleviate HF symptoms [7]. They reported data from 17 patients, in which 16 patients tricuspid replacement and in 2 repair was performed. In an another report, eight patients with symptomatic severe TR underwent tricuspid annuloplasty, four had valve repair and annuloplasty, and two had replacement [10]. In three of the six primary repairs failed and required replacement with a bio-prosthesis at 8 days, 14 days and 4 years, respectively. No failure occurred in any of the five bioprosthetic valves placed at a mean 55 months of follow-up.

Bellano et al. followed 96 adult patients who underwent HTx during 2010–2013. Seven patients (7.2%) with severe TVR after median of 47 days (range 27–60) underwent surgical valvular repair. They found that early surgical repair of post-transplant severe TR appears to be a safe treatment strategy in selected patients and is likely to contribute to enhanced cardiac performance and alleviation of associated organ dysfunction [11].

In conclusion, the existing data suggest that the tricuspid valve repair should be considered in patients with dilated tricuspid annulus. On the other hand, bio-prosthetic valve replacement is preferred in leaflet prolapse and/or chordal injury.

Key Points

- Tricuspid regurgitation is the most common valvular abnormality after heart transplant.
- The aetiology of post heart transplant is commonly due to tricuspid valvular apparatus damage because of frequent endomyocardial biopsies, annular dilatation due to right heart failure, with or without pre-transplant pulmonary hypertension, and/or distorted tricuspidal anatomy at bi-atrial orthotopic heart transplantation.
- Post heart transplant TR often remain asymptomatic, however in the long-term it is associated with increased mortality and morbidity.
- Surgical valve replacement with a bioprosthesis, is warranted in selected cases to prevent progressive renal failure, morbidity and mortality.

Review Questions

Select the Single Best Sentence

24. Which of the following statements about post heart transplantation TR is true?
- (a) TR is in the literature reported very variable, from 19 to 84% of all heart transplant recipients
 - (b) TR is reported in 25% in the first postoperative year and is always trace

- (c) TR is reported in 25% in the first postoperative year and is always mild
 - (d) TR is reported in 25% in the first postoperative year and is always severe
25. Which of the following statements about post heart transplantation TR is correct?
- (a) Only seen after bicaval but not after biatrial transplantation techniques
 - (b) Is exclusively seen in patients with patent foramen ovale
 - (c) Severe TR after heart transplantation is often due to frequent endomyocardial biopsies
 - (d) Severe TR after heart transplantation is seen in less than 1% of cases
26. Which of the following statements about surgical treatment of post heart transplantation TR is correct?
- (a) Flail leaflets are the most common operative finding after heart transplant
 - (b) Perforated leaflets are the most common operative finding after heart transplant
 - (c) Restricted leaflets are the most common operative finding after heart transplant
 - (d) Calcific posterior leaflet is the most common operative finding after heart transplant
27. Which of the following statements about optimal treatment of post heart transplantation TR is correct?
- (a) The optimal treatment of post-transplant severe TR is however not well defined
 - (b) Surgery is indicated for all patients with severe TR regardless symptoms
 - (c) Catheter based therapy is indicated for all patients with severe TR regardless symptoms
 - (d) Surgery is indicated for all patients with patients with mild TR when pulmonary hypertension exists

References

1. Wong RC, Abrahams Z, Hanna M, Pangrace J, Gonzalez-Stawinski G, Starling R, et al. Tricuspid regurgitation after cardiac transplantation: an old problem revisited. *J Heart Lung Transplant.* 2008;27(3):247–52.
2. Chan MC, Giannetti N, Kato T, Kornbluth M, Oyer P, Valentine HA, et al. Severe tricuspid regurgitation after heart transplantation. *J Heart Lung Transplant.* 2001;20(7):709–17.
3. Berger Y, Har Zahav Y, Kassif Y, Kogan A, Kuperstein R, Freimark D, et al. Tricuspid valve regurgitation after orthotopic heart transplantation: prevalence and etiology. *J Transp Secur.* 2012;120702:2012.
4. Birnbaum J, Ulrich SM, Schramm R, Hagl C, Lehner A, Fischer M, et al. Transient severe tricuspid regurgitation after transplantation of an extremely oversized donor heart in a child—does size matter? A case report. *Pediatr Transplant.* 2017;21(1)
5. Cooper LT, Baughman KL, Feldman AM, Frustaci A, Jessup M, Kuhl U, et al. The role of endomyocardial biopsy in the management of cardiovascular disease: a scientific statement

- from the American Heart Association, the American College of Cardiology, and the European Society of Cardiology. *Circulation*. 2007;116(19):2216–33.
6. Fiorelli AI, Coelho GH, Aiello VD, Benvenuti LA, Palazzo JF, Santos Junior VP, et al. Tricuspid valve injury after heart transplantation due to endomyocardial biopsy: an analysis of 3550 biopsies. *Transplant Proc*. 2012;44(8):2479–82.
 7. Alharethi R, Bader F, Kfoury AG, Hammond ME, Karwande SV, Gilbert EM, et al. Tricuspid valve replacement after cardiac transplantation. *J Heart Lung Transplant*. 2006;25(1):48–52.
 8. Aziz TM, Burgess MI, Rahman AN, Campbell CS, Deiraniya AK, Yonan NA. Risk factors for tricuspid valve regurgitation after orthotopic heart transplantation. *Ann Thorac Surg*. 1999;68(4):1247–51.
 9. Wartig M, Tesan S, Gabel J, Jeppsson A, Selimovic N, Holmberg E, et al. Tricuspid regurgitation influences outcome after heart transplantation. *J Heart Lung Transplant*. 2014;33(8):829–35.
 10. Filsoufi F, Salzberg SP, Anderson CA, Couper GS, Cohn LH, Adams DH. Optimal surgical management of severe tricuspid regurgitation in cardiac transplant patients. *J Heart Lung Transplant*. 2006;25(3):289–93.
 11. Bollano E, Karason K, Liden H, Dellgren G. How should we manage early tricuspid valve regurgitation after heart transplantation? *Int J Cardiol*. 2016;214:191–3.

Chapter 4

Tricuspid Regurgitation in Patients with Pacemakers and Implantable Cardiac Defibrillators

Yash Jobanputra, Jasneet Devgun, Mandeep Bhargava, and Samir Kapadia

Abstract Tricuspid regurgitation (TR) secondary to placement of implantable cardiac devices, including defibrillators and pacemakers, is now a definitive entity. TR usually occurs over time after lead implantation. Mechanisms include laceration of valve leaflets, entrapment of leads causing scar formation, interference with valve coaptation, and asynchronized activation of the right ventricle. Diagnosis by clinical exam and 2-dimensional echocardiography is further supported by 3-dimensional echocardiography and/or computed tomography. Management typically involves medical management as well as percutaneous extraction of the offending leads. Prospective methods to prevent or reduce the incidence of this complication include improved imaging modalities intraoperatively, procedural techniques, and particular lead placement. Newer technologies can help mitigate this problem but their effectiveness remains to be seen in larger prospective trials.

Keywords Tricuspid valve • Tricuspid regurgitation • Implantable cardiac defibrillator • Permanent pacemaker • Color Doppler flow • Ring annuloplasty • Bioprosthetic valves

Y. Jobanputra, M.D. • J. Devgun, D.O. • M. Bhargava, M.D.
Department of Cardiovascular Medicine, Heart and Vascular Institute, Cleveland Clinic,
Cleveland, OH, USA

S. Kapadia, M.D. (✉)
Department of Cardiovascular Medicine, Cardiac Catheterization Laboratory,
Heart and Vascular Institute, Cleveland Clinic,
9500 Euclid, J2-3, Cleveland, OH 44195, USA
e-mail: kapadis@ccf.org

Introduction

Tricuspid regurgitation (TR) in the setting of permanent pacemakers (PPM) and implantable cardioverter defibrillators (ICD) is not an uncommon complication, with a prevalence reported to be between 25 and 29% and an incidence of worsening preexisting TR from 10 to 25% [1–12]. Our understanding of the problem is now emerging in the wake of increased PPM and ICD implantations worldwide [13–15]. The association was first described in 1980 by Gibson and colleagues, in which a case of a young 23-year-old woman was described to have developed TR following the placement of a PPM [16]. Since then, in the last three decades the mechanisms, incidence, risk factors, as well as management and prognosis of this curious yet potentially formidable repercussion have been further elucidated.

Pathophysiology and Mechanisms (See Fig. 4.1)

Various potential mechanisms have been described to explain the development of TR following PPM and/or ICD implantation. These mechanisms can be categorized as related to the tricuspid valve (TV) itself, the PPM or ICD leads, as well as cardiac structure and function.

Tricuspid valve: Tricuspid valve trauma, laceration or perforation, and scar formation as a consequence of the PPM or ICD leads potentiate and contribute to mal-apposition and improper coaptation of the valve leaflets [1, 17–20]. Leaflet perforations or lacerations are most notably present in the posterior leaflet. In TR which develops over years after PPM implantation, it has been suggested that adhesion of the TV leaflet itself to the pacemaker lead results in restricted movement, and therefore, improper coaptation of the posterior leaflet with the septal and anterior leaflets [21]. Infective endocarditis is also a potential complication of lead placement which similarly affects the TV leaflets via adhesions and vegetation, and therefore contributes to another mechanism of subsequent TR [17].

PPM and ICD leads: Physical and mechanical complications resulting from the introduction of PPM or ICD leads may also contribute to TR. Mechanisms (see Fig. 4.2) include thrombus and fibrous tissue formation on the leads, adherence of the lead to the TV apparatus, and impingement and entanglement in the TV as well as within the chorda apparatus. One small study in particular found that the mechanism of TR after pacemaker implantation was related to lead impingement in 39%, lead adherence in 34%, lead perforation in 17%, and lead entanglement in 39% [19].

Within 12 h of implantation of PPM or ICD, the formation of neoendocardium results in development of fibrous sheaths surrounding the electrode [1]. The consequence is multiple endocardial attachments, fibrosis, and adhesion which potentially affects TV function. A thin fibrin layer begins to develop around the wire during this time. Approximately 4–5 days following implantation, thrombosis on

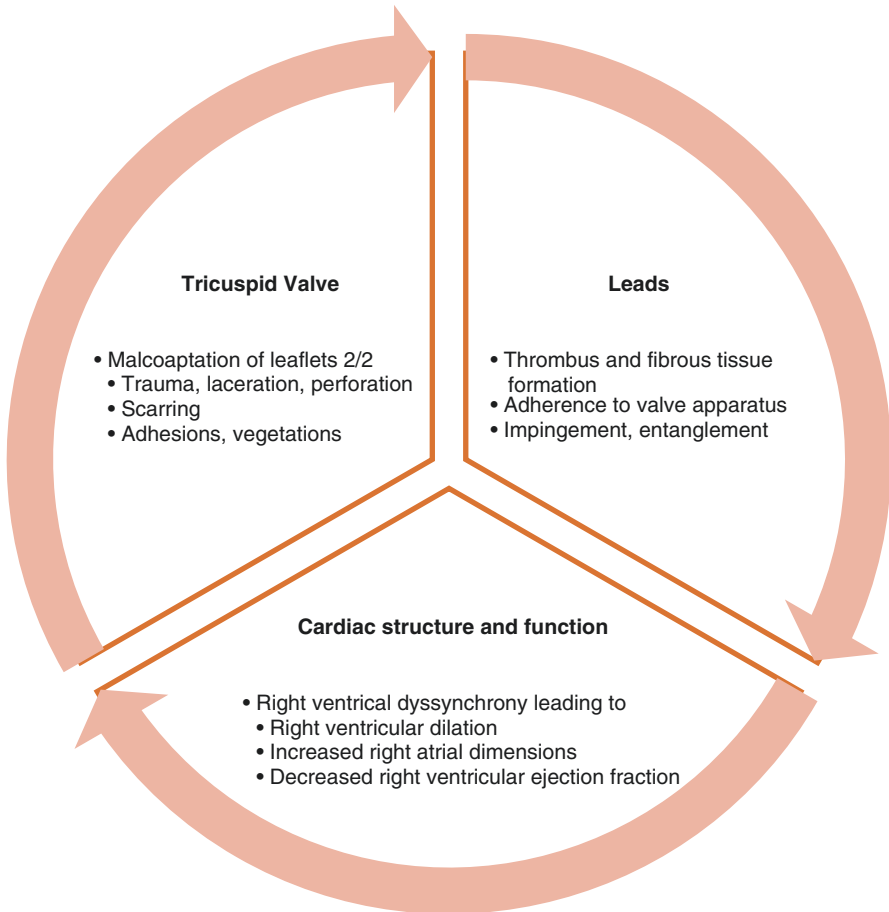


Fig. 4.1 Mechanisms and pathophysiology of lead-related tricuspid regurgitation

the lead and edema of the valve tissue itself often occurs [22]. Development of acute TR as a result of this remains to be controversial, as the frequency of acute TR varies in the literature [9–11, 23].

In addition to tissue homeostasis as a complicating and etiological factor, mechanical and physical complications of the leads coming in contact with the TV apparatus contribute to the development of TR. Leads positioned directly on the annulus or in the commissure between the leaflets may lead to obstruction and a subsequent progression of TR. In fact, it has been described that the majority of lead-related TR occurs when the leads are placed between the posterior and septal leaflets in particular [18]. One post-mortem study provided evidence of other mechanical complications, including leads fixed by fibrous tissue to the tricuspid orifice, as well as leads penetrated through the chordae tendinae [24]. Another less common mechanical etiology includes other valvular interventions leading to TR, such as one case of TR

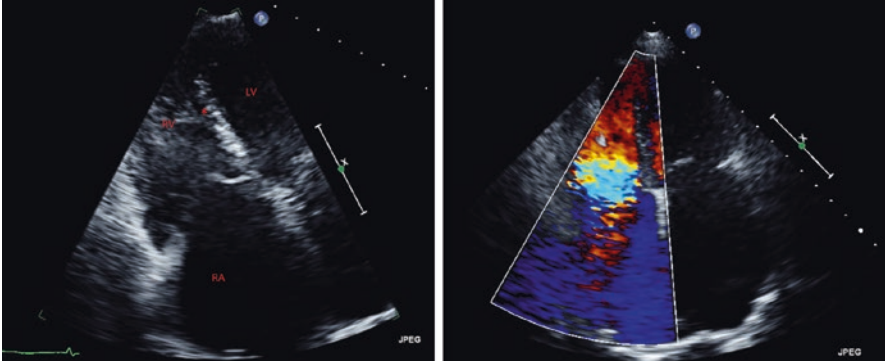


Fig. 4.2 (a) Section of the apical four-chamber view showing dilated right atrium (RA), dilated right ventricle (RV) and *pacemaker lead placed in the RV. (b) There is severe (4+) tricuspid valve regurgitation caused by annular dilatation. There is a centrally directed regurgitant jet. The left atrial cavity is severely dilated. RV systolic tissue Doppler velocity is 13.1 cm/s. Tricuspid annular displacement is 1.8 cm

years following PPM lead implantation and one month following aortic valve replacement [25]. It is postulated that the aortic valve replacement may have led to conformational changes between the tricuspid valve and the pacemaker leads.

Cardiac structure and function: Right ventricular (RV) dyssynchrony resulting from improper RV activation via the pacemaker has also been described as a potential mechanism. This may also be related to lead position, as one study showed a statistically significant increase in TR after PPM or ICD placement when the lead was apically placed versus in the right ventricular outflow tract (RVOT) [7]. Studies evaluating patients with 2-dimensional transthoracic echocardiography (2D TTE) prior to and following implantation of a PPM or ICD have also demonstrated significant RV dilation, increase in RA dimensions, as well as decrease in RV ejection fraction (RVEF) at up to one year following the procedure [4]. RV pacing frequency and dependence at follow up, however, has shown to have no effect on worsening of TR severity [6, 7].

Clinical Presentation

Clinical symptoms: The presentation of TR secondary to PPM/ICD placement may involve symptoms of decompensated right-sided congestive heart failure, such as abdominal distension and fullness, lower extremity edema, dyspnea on exertion, and palpitations related to atrial fibrillation [16, 21, 26]. An enlarged, pulsatile liver is a late finding [27]. In one study, patients with significant lead-induced TR following PPM or ICD implantation (increase of TR severity by ≥ 2 grades at follow up)

had more heart failure related events. This significant TR was even independently associated with increased all-cause mortality [5, 28]. Many patients may remain asymptomatic despite the presence of new or worsening TR. Larger studies have demonstrated that the majority of patients have new-onset or worsening of pre-existing TR several years following implantation, with some suggestion of acute worsening of TR in a small number of patients.

Physical examination: The physical examination may reveal the characteristic respirophasic, high-pitched, holosystolic murmur at the left lower sternal border that increases with inspiration (Carvallo's sign or maneuver). However, in many this murmur is unimpressive. In fact, the literature reports that only 28% of those with TR evidenced by echocardiography may have a regurgitant murmur on physical exam [29]. Nevertheless, when detected the Carvallo's maneuver has a sensitivity and specificity of 80% and 100%, respectively [30]. The TR murmurs that increase with inspiration are different from those which are associated with congestive heart failure, which often diminish with inspiration.

Other findings on exam may be consistent with isolated right-sided congestive heart failure, such as jugular venous distension, pulsatile liver, abdominal distension, and lower extremity pitting edema [19, 31]. Hepatojugular reflex may also be seen, with a sensitivity of 66% and specificity of 100% in detecting TR [30]. Likewise, the right atrial V wave is highly sensitive, yet it is not entirely specific for detecting the presence or severity of TR [32]. In addition to signs and symptoms of right-sided heart failure, some may have concurrent signs and symptoms of left-sided heart failure, especially those with some functional TR prior to the procedure and those who need ICD implantation for reduced left ventricular ejection fraction (LVEF).

Risk factors (see Table 4.1): The risk factors for developing TR following PPM/ICD implantation are not entirely understood. Some predictors have been shown to be significant in recent studies. Advanced age is found to be a risk factor, with an average age of 73 years [7, 8]. Other predictors include body mass index, pre-device atrial fibrillation, heart rate, moderate or severe mitral regurgitation, history of mitral valve surgery, pulmonary artery systolic pressure ≥ 37 mmHg, elevated right ventricular systolic pressure and RV dilation [5, 7]. There is conflicting data in the literature regarding whether the placement of more than one lead predisposes to worsening of TR. In the pediatric population, a risk factor for lead-related TR was congenital heart disease which is not right-sided [9].

Table 4.1 Predictors of tricuspid regurgitation following PPM/ICD lead implantation

Predictors of lead related tricuspid regurgitation
Advanced age
High BMI
Atrial fibrillation
Tachycardia
Mitral valve disease
Pulmonary artery pressure ≥ 37 mmHg
Elevated right ventricular systolic pressure
Right ventricular dilation

Imaging

Diagnosing TR requires both 2D echocardiography (see Fig. 4.3) and color Doppler flow mapping. The severity of TR is graded based on the direction and size of the regurgitant jet, the presence of proximal flow convergence, and vena contracta width [33]. Using the vena contracta width of ≥ 6.5 mm, the sensitivity and specificity of detecting severe TR is 88.5% and 93.3%, respectively [34]. Other findings in new or worsening TR following PPM or ICD placement include increased RV and RA dimensions, greater pulmonary artery systolic pressure, elevated right ventricular systolic pressure, and decreased right ventricular ejection fraction (RVEF) compared to the pre-procedural values [4].

The utility of 2D echocardiography may be limited as it may underestimate the presence and severity of TR. It proves to be difficult to appreciate the full anatomical relationships between the TV and the ICD or PPM lead(s), as only two out of the three leaflets are visible simultaneously when using any 2D imaging plane [18, 35]. The posterior leaflet, which is implicated in most cases, is only visualized in some views, and is less commonly imaged during the routine echocardiographic examination [35]. In fact, the PPM lead may become entrapped in the thickened, fibrotic, and fused posterior and septal leaflets. These leads are visualized in only 12–17% of patients using 2D echocardiography [18, 19].

Three-dimensional transthoracic echocardiography (3D TTE) affords the ability to visualize all three TV leaflets and the short axis of the TV, not obtainable with 2D echocardiography. This allows the assessment of the route and position of the PPM/ICD lead within the TV apparatus [18, 31, 35, 36]. Mediratta et al. demonstrated that 3D TTE clearly depicted lead position in 90% of patients, in which 46% of patients had impinging leads visualized in the posterior (20%), septal (23%), and

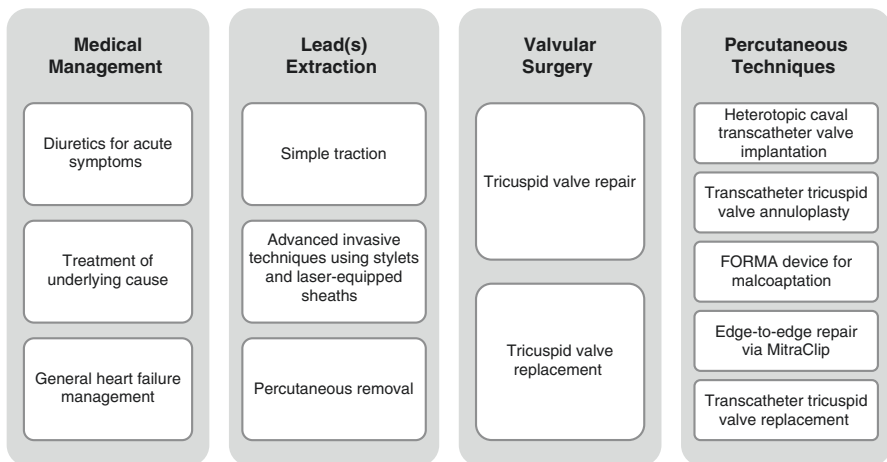


Fig. 4.3 Management of tricuspid regurgitation secondary to PPM/ICD lead implantation

anterior (4%) leaflets [36]. Those who did not have lead impingement, i.e. when the lead was visualized intercommisurally or in the middle of the tricuspid orifice, did not have evidence of significant TR compared to those with lead impingement. Due to this strong association between lead impingement and post-procedural TR, it has been suggested that 3D TTE targeted guidance of device- lead placement may be beneficial to avoid lead impingement, as lead placement is solely done under fluoroscopic guidance as of now [36]. It is undetermined, however, whether the lead would maintain its position from the time of placement to the time of development of TR, and therefore, the ultimate utility of intraprocedural 3D TTE is unclear. Additionally, due to the need of dedicated probes and image analysis software, as well as higher cost, 3D echocardiography is not widely used at the moment.

Other evolving imaging methods include contrast-enhanced multidetector computed tomography, which can indirectly be used to detect and grade TR. This is based on early opacification of hepatic veins or the inferior vena cava during first-pass intravenous contrast enhancement. In detecting echocardiographic TR, this particular method has a sensitivity of 90.4% and a specificity of 100% [37, 38].

An additional imaging modality is cardiac magnetic resonance (CMR), which can be used to detect and quantify TR based on the regurgitant jet area and volume. The sensitivity and specificity of this is 88% and 94%, respectively, compared to right ventricular angiography. Despite the favorable detection of this imaging modality, most pacemaker devices and leads are not compatible with CMR [39].

Management (See Fig. 4.4)

Medical management: Medical management has been largely studied in patients with functional TR, which involves treating the underlying cause as well as management of congestive heart failure [37]. Aggressive volume diuresis in acute decompensation and general balance of hemodynamics largely by the use of diuretics may be beneficial. There is, however, a paucity of data elucidating the outcomes of these patients with lead-related TR who are medically managed.

Lead(s) extraction: Lead placement is acutely associated with inflammatory changes, as well as chronically with fibrosis and scar tissue formation, which allows for lead adherence to the TV. The main indication for lead extraction is device and lead related infection [40]. The methods and techniques for lead extraction have become more sophisticated and specialized over time. Some leads can be removed by simple traction alone, while others require advanced techniques using locking stylets and laser-equipped sheaths. Percutaneous removal of PPM or ICD leads is often performed in large specialty centers with advanced technical skill and experience. However this carries significant and potentially fatal risk [31]. Major complications of lead extraction include cardiac or vascular avulsion requiring open chest interventions, pulmonary embolism, respiratory distress, stroke, and even death in up to 0.5% of patients.

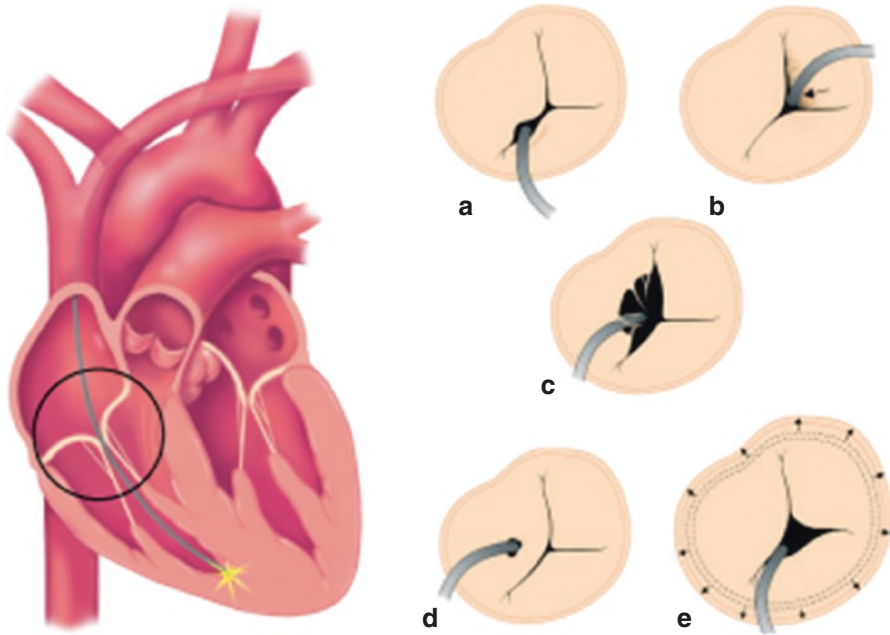


Fig. 4.4 Mechanisms of mechanical tricuspid regurgitation in the setting of permanent pacemaker or implantable cardioverter-defibrillator leads. (a) Valve obstruction caused by lead placed between leaflets. (b) Lead adherence due to fibrosis and scar formation to valve causing incomplete closure. (c) Lead entrapment in the tricuspid valve apparatus. (d) Valve perforation or laceration. (e) Annular dilatation

However, in the last decade, success rate of lead extraction has been between 95% and 97%, and the complication rate has remained low at 0.4–1% [40].

Lead extraction itself may paradoxically lead to worsening TR [31, 35, 41]. Major risk factors and predictors of developing TR after extraction are the use of laser sheath or any additional tools for extraction beyond simple traction, extraction of more than two leads, female sex, and patients with longer duration of implantation [42]. Fortunately, There is no significantly increased mortality in those who develop TR post-extraction compared to those who do not develop TR. Tricuspid regurgitation is more likely to occur after PPM extraction than ICD lead extraction. This may be due to a longer duration of implantation or more fibrous tissue deposition and adherence to the TV [41].

Valvular surgery: The decision to operate on a regurgitant TV depends on the severity and clinical situation [27]. Tricuspid valve surgery is clearly indicated in primary severe TR at the time of left-sided valve surgery. It can also be considered in those with symptomatic severe TR who are unresponsive to medical management. Additionally, it may be considered in those who are asymptomatic or have minimal symptoms but have increasing RV dilation and dysfunction prior to any clinical right-sided heart failure.

Tricuspid regurgitation is managed surgically either via surgical repair or replacement depending on the etiology and mechanisms of valve dysfunction. Tricuspid valve repair often involves suture or ring annuloplasty as well as additional adjunctive techniques. It is often used in the case of secondary TR, with the goal of restoring tricuspid annulus geometry as well as concurrently reducing RV afterload by correcting left-sided valvular dysfunction [27]. On the other hand, tricuspid valve replacement is generally done when valve repair is technically not feasible, as in the setting of complex lesions causing severe primary TR and severe tricuspid stenosis. Those with secondary TR with marked RV remodeling and leaflet tethering may also benefit from replacement rather than repair.

It is estimated that approximately 8000 surgical tricuspid repairs occur annually in the United States, the majority of these cases involving patients without ICD or PPM-related TV pathology. Tricuspid valve repair has a success rate of above 85%. Recurrence of TR is common and occurs in about 20–30% of patients [37, 43]. Tricuspid valve replacement is associated with a 6% 30-day post-operative mortality rate, as well as 8% in-hospital mortality [21, 23, 35]. The 10-year survival for patients after a tricuspid valve replacement combined with left-sided heart valve surgery is 78%, but is only 41% in those with triple valve surgery. This is lower than the 10-year survival of patients undergoing aortic valve replacement (65%), mitral valve replacement (55%), and combined aortic and mitral valve replacement (55%) [37, 38].

There is limited data in the literature about surgical treatment in patients with TR secondary to PPM/ICD leads. Some of the literature recommends the removal of the original pacemaker leads and placement of an epicardial or transcatheter sinus lead in those patients who require TV replacement [44]. The disadvantage of epicardial leads has been the relatively high capture thresholds as resulting in frequent battery changes. An alternative is to surgically position the original lead between the sewing ring and the native annulus, or to place it inside the posteroseptal annulus with Lemert-type sutures [26]. Although promising, this technique makes it difficult to remove the lead transvenously in the future.

In regards to TV repair, ring annuloplasty is preferred over suture repair as it lends a lower incidence of recurrent and residual TR, fewer reoperations, and an improved survival for functional TR [43]. Some studies supporting this have included patients who have needed TV repair due to lead-related TR, with favorable outcomes. There is ongoing discussion and controversy over whether flexible versus rigid annuloplasty rings are superior. Some of the literature has shown that a rigid annuloplasty ring does not result in worsening of any residual TR following TV repair, while worsening was appreciated with flexible ring annuloplasty [23]. However, residual TR is still a significant problem which exists following TV repair regardless of the type of annuloplasty ring used. Additionally, there is an associated risk of increased postoperative conduction disturbances with the prosthetic ring compared to the suture annuloplasty technique [27].

Average time to surgery has been described in the literature as 72 months following device implantation [19]. This allows for the argument that lead-related TR is likely to occur over a longer period of time, although a small number of patients

have demonstrated acute decompensation within a shorter time frame. These patients fare well and show significant improvement postoperatively [19].

There is some recent data in the literature which outlines and demonstrates significant mortality associated with $\geq 3+$ TR related to PPM's in particular [5]. Another study described that patients with device-related infection had an 18% all-cause mortality after 6 months of infection [45]. Overall, however, there is a paucity in data in the literature in order to come to a firm conclusion on these patients' potential benefits from surgery. Specifically, the long-term durability of surgical results remains unknown.

Percutaneous techniques: Percutaneous transcatheter techniques for TV repair or replacement are currently in their infancy, with feasibility studies in animal models and few in-human studies performed. Interest in this route remains high due to the significant risks of isolated TV surgery especially in the setting of reoperation following left-sided valve surgery [27]. The development of percutaneous techniques faces unique anatomic hurdles, such as the elliptical shape of the TV annulus, absence of calcium for good deployment and tethering, and proximity to important structures including the AV node/bundle of His, right coronary artery, and RVOT. Despite this, some important techniques and devices have been developed and have even shown procedural success and clinical improvement in small, early in-human studies.

Among these is the heterotopic caval transcatheter valve implantation. This procedure involves implantation of bioprosthetic valves at the level of the superior and inferior cavoatrial junctions. This aims to reduce the reflux of severe TR and improves heart failure symptoms but it does not affect the magnitude of the TR itself. Two prototypes have been developed: the self-expandable TricValve (P + F Products + Features Vertriebs GmbH, Vienna, Austria in cooperation with Braile Biomedica, São José do Rio Preto, Brazil) and the balloon-expandable Edwards valve (Edwards Lifesciences, Irvine, CA, USA). In addition, the self-expandable Edwards SAPIEN XT and SAPIEN 3 valves, which are primarily used for transcatheter aortic valve replacement (TAVR), have been used off-label for chronic severe TR, in which case a large self-expandable peripheral stent is implanted at the cavoatrial junction prior to implantation for proper "landing". Early studies have demonstrated successful valve implantation, improvement of heart failure symptoms, and no residual transvalvular or perivalvular leak with the above mentioned bioprostheses [27].

Transcatheter tricuspid valve annuloplasty is another method being explored, with early studies using the Mitralign (Mitralign Inc., Tewksbury, MA, USA) and TriCinch (4Tech Cardio Ltd., Galway, Ireland) devices. The Mitralign device functions in the plication of the anterior and posterior aspects of the TV annulus, creating a functionally bicuspid valve as seen in the Kay surgical technique. The TriCinch device, currently being studied in the PREVENT registry, consists of a corkscrew anchor as well as a self-expandable stent which are connected by a Dacron band. The anchor is implanted into the TV annulus in the anterior and

posterior aspects, and the self-expandable stent is placed in the inferior vena cava. The modification and decrease of TV annular size is achieved by applying tension to the Dacron band.

Other methods include the FORMA device (Edwards Lifesciences) which aims to improve leaflet coaptation, the use of the MitraClip for TR, as well as transcatheter TV replacement. The FORMA device consists of a foam-filled balloon which acts as a spacer and is anchored at the RV apex. This has shown to be implanted successfully with improved outcomes in early studies [27]. Similarly, improved outcomes without any major complications have been demonstrated with the use of MitraClip on the TV for severe TR. In regards to transcatheter TV replacement, successful implantation have been demonstrated in animal models, however no in-human studies have been performed.

As of now, the above mentioned modalities have demonstrated favorable outcomes but these studies involve very small study populations. Studies involving human subjects and larger patient populations are needed to further elucidate the feasibility of these techniques.

Prevention (See Table 4.2)

Some suggestions have been made on ways to potentially prevent post-procedural TR, although the data behind this is overall limited. These involve various methods involving the type of leads used, procedural technique and location of lead implantation. Alternatives to the traditional intracardiac pacing devices have also been suggested as a possibility in some patients.

Lead type: Some authors have postulated that the lead type may be related to lead-related TR. One animal-based study found that expanded polytetrafluoroethylene-coated coils are easily extracted compared to backfilled with medical adhesive coils and uncoated coils, as these are commonly associated

Table 4.2 Prevention of lead related tricuspid regurgitation

Lead type	<ul style="list-style-type: none"> • Expanded polytetrafluoroethylene-coated coils • Polyurethane leads
Procedural technique	<ul style="list-style-type: none"> • Prolapsing technique
Lead location	<ul style="list-style-type: none"> • Septal or RVOT • Transvenous epicardial lead in coronary sinus • Intercommisural placement across tricuspid valve orifice
Imaging	<ul style="list-style-type: none"> • Intraoperative 3D TTE along with fluoroscopy
Alternative devices	<ul style="list-style-type: none"> • Leadless pacing • Subcutaneous cardioverter defibrillators
Surveillance	<ul style="list-style-type: none"> • Echocardiographic monitoring in select patients

with less fibrosis and, therefore, potentially less TR [46]. Whereas, Lin G et al. has reported higher prevalence of silicone versus polyurethane leads in those with lead-related TR [19].

Procedural technique: There are three methods to lead implantation during the procedure [47]. The first is the prolapsing technique, in which the lead is prolapsed across the tricuspid valve by first creating a loop in the right atrium, then subsequently advancing the loop with the inner stylet until the lead falls into the valve. The second is to cross the valve directly, aiming towards the target location with a shaped stylet. The third and final technique is also to cross the valve directly, however towards the RVOT with a curved stylet in place, then bringing the lead back until it is aimed towards the target location. Some experts suggest that the prolapsing technique is sometimes the preferred method, as the leads are not directly placed, decreasing risk of damage and trauma to the tricuspid apparatus. One disadvantage of the prolapsing technique, however, is the possibility of causing trauma to the structures surrounding the TV prior to advancement into the RV. Nevertheless, data still remains to be minimal on which method truly in fact causes the least damage to the TV apparatus.

Lead location: location of the lead itself may play a factor in the development or worsening of TR. Expert opinion explains that apically placed leads have the potential of tethering to the posterior TV leaflet more than septally placed leads. Recent literature has shown a higher incidence of lead-related TR with leads placed apically versus those placed in the RVOT [7]. Apical pacing can contribute to RV dyssynchrony and alterations in RV geometry. This may explain some literature that has shown a higher incidence of lead-related TR following ICD placement versus PPM as ICD leads must be placed apically. However, whether there is a higher incidence of TR with ICDs versus PPMs remains controversial.

Case reports in the literature have demonstrated the possibility and feasibility of transvenous epicardial leads in the coronary sinus or middle cardiac vein rather than intracardiac lead placement for permanent pacing [17, 48]. These cases were primarily those patients with whom a lead could not be placed across the TV, such as those with a history of TV surgery. This method is already accepted as an indication for cardiac resynchronization therapy; extension of the indication to permanent pacing may provide an alternate option to avoid trauma to the TV with intracardiac leads, and therefore, prevent lead-related TR.

As mentioned previously, 3D TTE studies have demonstrated that much of lead-related TR is associated with leads interfering with the posterior and/or septal TV leaflets [36]. Those without lead-related TR were found to have the lead placed intercommisurally or in the center of the TV orifice. This information could be potentially used for prevention of TR following PPM or ICD placement. It is suggested that intra-operative 3D TTE along with traditional fluoroscopy may be beneficial to adequately place the leads in a more optimal location and, therefore, potentially prevent post-procedural TR. However, this has not been studied head-to-head with purely intra-operative fluoroscopy, and the possibility of lead displacement following the procedure has not been assessed. Given the large

number of device implants, intra-operative echocardiography for lead placement would pose a significant logistical and financial challenge.

Alternative devices: Newer technologies can help in reducing lead-related TR. Leadless pacing has been possible with a self-contained encapsulated unit which can be attached to the endocardium of the right ventricle. Feasibility trials, such as the LEADLESS, LEADLESS II, and Micra Transcatheter Pacing Study have achieved positive results [17, 49–51]. The Micra Transcatheter Pacing Study in particular reported a 96% Kaplan-Meier estimate of freedom from device-related adverse events at 6 months [49]. One of these device-related adverse events was cardiac failure, which occurred in 0.9% of the patients, however device-related TR was not specifically reported.

Subcutaneous cardioverter defibrillators are also another alternative which do not involve leads that would cross the TV [17]. The generator is implanted subcutaneously in the lateral chest wall, the lead running also subcutaneously across the left side of the chest and along the parasternal area, thus avoiding any intravascular intervention. The major limitation of subcutaneous defibrillators is the inability to pace. In addition, the patient population in which subcutaneous defibrillators may be used is limited to those with appropriate recoding of cardiac signals according to the orientation of the device in the chest.

Surveillance: Although there are no data regarding the specific benefits and clinical effect of surveillance, some patients may benefit from close echocardiographic monitoring. These include those who develop signs and symptoms of new-onset right-sided heart failure, have pre-existing TR, or those who have more than one apical lead [1].

Summary

Device-related TR is not an uncommon complication of PPM or ICD placement. Although a previously unrecognized entity, it is now better understood and recognized with emerging literature. TR following PPM or ICD placement is most often secondary to either mechanical or physiological mechanisms which involve damage or deformity to the TV apparatus, leads, and/or cardiac structure and function. Clinically significant lead-related TR involves the signs and symptoms of right-sided heart failure, which is further exemplified and evidenced by 2D TTE and color Doppler flow mapping. Management typically involves medical management as well as percutaneous extraction of the offending leads. Prospective methods to prevent or reduce the incidence of this complication include improved imaging modalities intraoperatively, procedural techniques, particular lead placement, and the use of the cardiac venous system. In the future, devices which do not involve leads may be another alternative. As of now, the literature is continuing to emerge, while case studies and retrospective studies predominate and prospective studies are just beginning to surface. Further studies are needed to solidify our understanding of lead-related TR incidence/risk, prognosis and mortality, proper management, and possible prevention.

Review Questions

28. Which of the following mechanisms of mechanical tricuspid regurgitation in the setting of permanent pacemaker or implantable cardioverter-defibrillator leads is **not** correct?
- (a) Valve obstruction caused by lead placed in between leaflets.
 - (b) Lead entrapment in the tricuspid valve apparatus.
 - (c) Annular dilatation.
 - (d) None of the above.
29. Which of the following statements about mechanical tricuspid regurgitation in the setting of permanent pacemaker or implantable cardioverter-defibrillator leads is **not** correct?
- (a) A prevalence reported to be between 25 and 29%.
 - (b) It causes worsening of pre-existing TR in 10 to 25%.
 - (c) TR is more often seen in apically implanted pacemaker leads.
 - (d) TR is caused by lead perforation in 17%.
30. Which of the following are potential risk factors for mechanical tricuspid regurgitation in the setting of permanent pacemaker or implantable cardioverter-defibrillator leads?
- (a) Advanced age
 - (b) Obesity
 - (c) Preexisting atrial fibrillation
 - (d) All of the above

References

1. Al-Bawardy R, Krishnaswamy A, Bhargava M, Dunn J, Wazni O, Tuzcu EM, Stewart W, Kapadia SR. Tricuspid regurgitation in patients with pacemakers and implantable cardiac defibrillators: a comprehensive review. *Clin Cardiol.* 2013;36(5):249–54.
2. Paniagua D, Aldrich HR, Lieberman EH, Lamas GA, Agatston AS. Increased prevalence of significant tricuspid regurgitation in patients with transvenous pacemakers leads. *Am J Cardiol.* 1998;82(9):1130–2.
3. de Cock CC, Vinkers M, Van Campe LC, Verhorst PM, Visser CA. Long-term outcome of patients with multiple (> or = 3) noninfected transvenous leads: a clinical and echocardiographic study. *Pacing Clin Electrophysiol.* 2000;23(4):423–6.
4. Arabi P, Özer N, Ateş AH, Yorgun H, Oto A, Aytemir K. Effects of pacemaker and implantable cardioverter defibrillator electrodes on tricuspid regurgitation and right sided heart functions. *Cardiol J.* 2015;22(6):637–44.
5. Dellling FN, Hassan ZK, Piatkowski G, Tsao CW, Rajabali A, Markson LJ, Zimetbaum PJ, Manning WJ, Chang JD, Mukamal KJ. Tricuspid regurgitation and mortality in patients with transvenous permanent pacemaker leads. *Am J Cardiol.* 2016;117(6):988–92.
6. Fanari Z, Hammami S, Hammami MB, Hammami S, Shuraih M. The effects of right ventricular apical pacing with transvenous pacemaker and implantable cardioverter defibrillator on mitral and tricuspid regurgitation. *J Electrocardiol.* 2015;48(5):791–7.

7. Lee RC, Friedman SE, Kono AT, Greenberg ML, Palac RT. Tricuspid regurgitation following implantation of endocardial leads: incidence and predictors. *Pacing Clin Electrophysiol.* 2015;38(11):1267–74.
8. Klutstein M, Balkin J, Butnaru A, Ilan M, Lahad A, Rosenmann D. Tricuspid incompetence following permanent pacemaker implantation. *Pacing Clin Electrophysiol.* 2009;32(suppl 1):S135–7.
9. Webster G, Margossian R, Alexander ME, Cecchin F, Triedman JK, Walsh EP, Berul CI. Impact of transvenous ventricular pacing leads on tricuspid regurgitation in pediatric and congenital heart disease patients. *J Interv Card Electrophysiol.* 2008;21(1):65–8.
10. Kucukarslan N, Kirilmaz A, Ulusoy E, Yokusoglu M, Gramatnikovski N, Ozal E, Tatar H. Tricuspid insufficiency does not increase early after permanent implantation of pacemaker leads. *J Card Surg.* 2006;21(4):391–4.
11. Leibowitz DW, Rosenheck S, Pollak A, Geist M, Gilon D. Transvenous pacemaker leads do not worsen tricuspid regurgitation: a prospective echocardiographic study. *Cardiology.* 2000;93(1–2):74–7.
12. Kim JB, Spevack DM, Tunick PA, Bullinga JR, Kronzon I, Chinitz LA, Reynolds HR. The effect of transvenous pacemaker and implantable cardioverter defibrillator lead placement on tricuspid valve function: an observational study. *J Am Soc Echocardiogr.* 2008;21(3):284–7.
13. Kremers M, Hammill S, Berul C, et al. The National ICD Registry Report: version 2.1 including leads and pediatrics for years 2010 and 2011. *Hear Rhythm.* 2013;10(4):e59–65.
14. Kurtz S, Ochoa J, Lau E, et al. Implantation trends and patient profiles for pacemakers and implantable cardioverter defibrillators in the United States: 1993–2006. *Pacing Clin Electrophysiol.* 2010;33(6):705–11.
15. Mond H, Proclemer A. The 11th world survey of cardiac pacing and implantable cardioverter-defibrillators: calendar year 2009--a World Society of Arrhythmia's project. *Pacing Clin Electrophysiol.* 2011;34(8):1013–27.
16. Gibson TC, Davidson RC, DeSilvey DL. Presumptive tricuspid valve malfunction induced by a pacemaker lead: a case report and review of the literature. *Pacing Clin Electrophysiol.* 1980;3(1):88–95.
17. Baquero GA, Luck J, Naccarelli GV, Gonzalez MD, Banchs JE. Tricuspid valve incompetence following implantation of ventricular leads. *Curr Heart Fail Rep.* 2015;12(2):150–7.
18. Seo Y, Ishizu T, Nakajima H, Sekiguchi Y, Watanabe S, Aonuma K. Clinical utility of 3-dimensional echocardiography in the evaluation of tricuspid regurgitation caused by pacemaker leads. *Circ J.* 2008;72(9):1465–70.
19. Lin G, Nishimura RA, Connolly HM, Dearani JA, Sundt TM 3rd, Hayes DL. Severe symptomatic tricuspid valve regurgitation due to permanent pacemaker or implantable cardioverter-defibrillator leads. *J Am Coll Cardiol.* 2005;45(10):1672–5.
20. Champagne J, Poirier P, Dumesnil JG, Desaulniers D, Boudreault JR, O'Hara G, Gilbert M, Philippon F. Permanent pacemaker lead entrapment: role of the transesophageal echocardiography. *Pacing Clin Electrophysiol.* 2002;25(7):1131–4.
21. Iskandar SB, Ann Jackson S, Fahrig S, Mechleb BK, Garcia ID. Tricuspid valve malfunction and ventricular pacemaker lead: case report and review of the literature. *Echocardiography.* 2006;23(8):692–7.
22. Huang TY, Baba N. Cardiac pathology of transvenous pacemakers. *Am Heart J.* 1972;83(4):469–74.
23. McCarthy PM, Bhudia SK, Rajeswaran J, Hoercher KJ, Lytle BW, Cosgrove DM, Blackstone EH. Tricuspid valve repair: durability and risk factors for failure. *J Thorac Cardiovasc Surg.* 2004;127(3):674–85.
24. Novak M, Dvorak P, Kamaryt P, Slana B, Lipoldova J. Autopsy and clinical context in deceased patients with implanted pacemakers and defibrillators: intracardiac findings near their leads and electrodes. *Europace.* 2009;11(11):1510–6.
25. Loupy A, Messika-Zeitoun D, Cachier A, Himbert D, Brochet E, Lung B, Vahanian A. An unusual cause of pacemaker-induced severe tricuspid regurgitation. *Eur J Echocardiogr.* 2008;9(1):201–3.

26. Lee JH, Kim TH, Wook SK. Permanent pacemaker lead induced severe tricuspid regurgitation in patient undergoing multiple valve surgery. *Korean J Thorac Cardiovasc Surg.* 2015;48(2):129–33.
27. Rodés-Cabau J, Taramasso M, O’Gara P. Diagnosis and treatment of tricuspid valve disease: current and future perspectives. *Lancet.* 2016;388(10058):2431–22.
28. Höke U, Auger DT, Thijssen J, et al. Significant lead-induced tricuspid regurgitation is associated with poor prognosis at long-term follow-up. *Heart.* 2014;100(12):960–8.
29. Rahko PS. Prevalence of regurgitant murmurs in patients with valvular regurgitation detected by Doppler echocardiography. *Ann Intern Med.* 1989;111(6):466–72.
30. Maisel AS, Atwood JE, Goldberger AL. Hepatojugular reflux: useful in the bedside diagnosis of tricuspid regurgitation. *Ann Intern Med.* 1984;101(6):781–2.
31. Nucifora G, Badano LP, Allocca G, Gianfagna P, Proclemer A, Cinello M, Fioretti PM. Severe tricuspid regurgitation due to entrapment of the anterior leaflet of the valve by a permanent pacemaker lead: role of real time three-dimensional echocardiography. *Echocardiography.* 2007;24(6):649–52.
32. Pitts WR, Lange RA, Cigarroa JE, Hillis LD. Predictive value of prominent right atrial V waves in assessing the presence and severity of tricuspid regurgitation. *Am J Cardiol.* 1999;83(4):617–8.
33. Rogers JH, Bolling SF. The tricuspid valve: current perspective and evolving management of tricuspid regurgitation. *Circulation.* 2009;119(20):2718–25.
34. Tribouilloy CM, Enriquez-Sarano M, Bailey KR, Tajik AJ, Seward JB. Quantification of tricuspid regurgitation by measuring the width of the vena contracta with Doppler color flow imaging: a clinical study. *J Am Coll Cardiol.* 2000;36(2):472–8.
35. Chen TE, Wang CC, Chern MS, Chu JJ. Entrapment of permanent pacemaker lead as the cause of tricuspid regurgitation. *Circ J.* 2007;71(7):1169–71.
36. Mediratta A, Addetia K, Yamat M, et al. No Tilt3D echocardiographic location of implantable device leads and mechanism of associated tricuspid regurgitation. *JACC Cardiovasc Imaging.* 2014;7(4):337–47.
37. Agarwal S, Tuzcu EM, Rodriguez ER, Rodriguez LL, Kapadia SR. Interventional cardiology perspective of functional tricuspid regurgitation. *Circ Cardiovasc Interv.* 2009;2(6):565–73. doi:10.1161/CIRCINTERVENTIONS.109.878983.
38. Groves AM, Win T, Charman SC, Wisbey C, Pepke-Zaba J, Coulden RA. Semi-quantitative assessment of tricuspid regurgitation on contrast-enhanced multidetector CT. *Clin Radiol.* 2004;59(8):715–9.
39. Nagel E, Jungehülsing M, Smolarz K, Klaer R, Sechtem U, Schicha H, Hilger HH. Diagnosis and classification of tricuspid valve insufficiency with dynamic magnetic resonance tomography: comparison with right ventricular angiography. *Z Kardiol.* 1991;80(9):561–8.
40. Rickard J, Wilkoff BL. Extraction of implantable cardiac electronic devices. *Curr Cardiol Rep.* 2011;13(5):407–14.
41. Glover BM, Watkins S, Mariani JA, Yap S, Asta J, Cusimano RJ, Ralph-Edwards AC, Cameron DA. Prevalence of tricuspid regurgitation and pericardial effusions following pacemaker and defibrillator lead extraction. *Int J Cardiol.* 2010;145(3):593–4.
42. Franceschi F, Thuny F, Giorgi R, Sanaa I, Peyrouse E, Assouan X, Prévôt S, Bastard E, Habib G, Deharo JC. Incidence, risk factors, and outcome of traumatic tricuspid regurgitation after percutaneous ventricular lead removal. *J Am Coll Cardiol.* 2009;53(23):2168–74.
43. Ratschiller T, Guenther T, Guenzinger R, Noebauer C, Kehl V, Gertler R, Lange R. Early experiences with a new three-dimensional annuloplasty ring for the treatment of functional tricuspid regurgitation. *Ann Thorac Surg.* 2014;98(6):2039–44.
44. Pfannmueller B, Hirmler G, Seeburger J, et al. Tricuspid valve repair in the presence of a permanent ventricular pacemaker lead. *Eur J Cardiothorac Surg.* 2011;39(5):657–61.
45. Baman TS, Gupta SK, Valle JA, Yamada E. Risk factors for mortality in patients with cardiac device-related infection. *Circ Arrhythm Electrophysiol.* 2009;2(2):129–34.

46. Wilkoff BL, Belott PH, Love CJ, Scheiner A, Westlund R, Rippey M, Krishnan M, Norlander BE, Steinhaus B, Emmanuel J, Zeller PJ. Improved extraction of ePTFE and medical adhesive modified defibrillation leads from the coronary sinus and great cardiac vein. *Pacing Clin Electrophysiol.* 2005;28(3):205–11.
47. Rajappan K. Permanent pacemaker implantation technique: part II. *Heart.* 2009;95(4):334–42.
48. Lopez J. Implantable cardioverter defibrillator lead placement in the middle cardiac vein after tricuspid valve surgery. *Europace.* 2012;14(6):853–8.
49. Reynolds D, Duray G, Omar R, et al. A leadless intracardiac transcatheter pacing system. *N Engl J Med.* 2016;374(6):533–41.
50. Reddy V, Exner D, Cantillon D, et al. Percutaneous implantation of an entirely intracardiac leadless pacemaker. *N Engl J Med.* 2015;373(12):1125–35.
51. Reddy V, Knops R, Sperzel J, et al. Permanent leadless cardiac pacing: results of the LEADLESS trial. *Circulation.* 2014;129(14):1466–71.

Part III
Non-invasive Imaging Perspective

Chapter 5

Tricuspid Valve Disease: Imaging Using Transthoracic Echocardiography

Osama I. Soliman, Jackie McGhie, Ashraf M. Anwar, Mihai Strachinaru, Marcel L. Geleijnse, and Folkert J. ten Cate

Abstract Tricuspid valve disease is common but often has less attention than in the left side of the heart. Functional tricuspid regurgitation if left untreated is associated with unfavorable outcome. Moreover, tricuspid valve surgery is often associated with higher complications than for any other surgical valve intervention. Transthoracic echocardiography (TTE) is the gold standard imaging of choice in the assessment of tricuspid valve disease. TTE has many sub modalities such as the M-mode, 2D and 3D modes, the bi-plane mode and the recently introduced iRotate mode. Furthermore, Doppler interrogation of the tricuspid valve as well as blood flow over other cardiac valves, pulmonary, aortic, hepatic venous flow is the mainstay in hemodynamic assessment of patients with tricuspid valve disease. TTE role begins with screening for the presence or absence and type of tricuspid valve disease. Moreover, determination of the etiology, severity of the tricuspid lesion, associated other valvular problems and chamber quantification are part of an imaging protocol/approach, which required for full diagnosis of tricuspid valve disease.

Electronic Supplementary Material The online version of this chapter (doi: [10.1007/978-3-319-58229-0_5](https://doi.org/10.1007/978-3-319-58229-0_5)) contains supplementary material, which is available to authorized users.

O.I. Soliman, M.D., Ph.D., F.A.C.C., F.E.S.C. (✉)
Department of Cardiology, Thoraxcenter, Erasmus MC: University Medical Center
Rotterdam, 's-Gravendijkwal 230, 3015CE Rotterdam, The Netherlands
e-mail: o.soliman@erasmusmc.nl

J. McGhie, M.Sc. • M. Strachinaru, M.D. • M.L. Geleijnse, M.D., Ph.D.
F.J. ten Cate, M.D., Ph.D.
Thoraxcenter, Erasmus University Medical Center,
s-Gravendijkwal 230, 3015CR Rotterdam, The Netherlands

A.M. Anwar, M.D., Ph.D.
Cardiology Department, Faculty of Medicine, Al-Azhar University, Cairo, Egypt

Pre-operative and pre-catheter interventional planning can be performed by TTE. Finally, post interventional outcome as well as follow-up is often determined via TTE. In this chapter, we will provide a comprehensive and state-of-the art overview of the use of TTE for the assessment of TV disease. Advantages as well as limitations of each TTE sub modality will be outlined. A perspective on the value of TTE in the era of percutaneous transcatheter TV interventions will also be highlighted.

Keywords Echocardiography • Transthoracic • M-mode • Doppler • iRotate • 2 Dimensional • 3 Dimensional • Tricuspid • Stenosis • Regurgitation • Severity • Surgery • Interventions • Outcome

Introduction

Transthoracic echocardiography (TTE) has been the mainstream imaging modality of choice for the assessment of tricuspid valve (TV) disease. TTE is versatile, low cost, is available at bedside and can be easily repeated without risks of ionizing radiation such as in computed tomography or device incompatibility such as in magnetic resonance imaging. Tricuspid regurgitation (TR) is the most common form of TV disease. TTE provides functional information, grading of TR severity as well as detailed morphologic assessment of TV leaflets that are not easily seen on other imaging modalities. These TTE modalities are M-mode, Doppler, multiplane imaging and three-dimensional (3D) imaging. 3D-TTE provides a full perspective of right- as well as left-sided valves and chambers. Moreover, 3D colour-Doppler can provide quantification of TR severity. The multiplane iRotate mode which has been recently introduced into clinical practice, provides not only high frame rate imaging that is comparable to 2D echocardiography, but also a multiplane perspective as in 3D echocardiography.

Tricuspid Valve Apparatus

Detailed cardiac anatomy and embryology are provided in Chap. 1 of this book. In brief, the TV is the atrioventricular valve that separates the right atrium (RA) from the right ventricle (RV). It is the largest and most apical of all cardiac valves. Its main function is to prevent blood returning to the RA. The TV apparatus is composed of a fibrous annulus, three leaflets (anterior, posterior and septal), chordae tendinae, three papillary muscles, and right ventricular myocardium. Papillary muscles are relatively smaller and more widely spaced as compared to the left side of the heart. The septal leaflet is more fixed than the other two leaflets and the posterior leaflet is the smallest. Anterior and posterior leaflets have several secondary chordae which are attached to the moderator band and the highly trabeculated free wall.

The TV has a complex saddle-shaped structure, which results in the attachment of the three leaflets not being aligned. Therefore, imaging of the TV annulus together with all three leaflets requires a 3D modality. Anwar et al. have shown that only two leaflets can be seen simultaneously in one 2D view. Moreover, identification of individual leaflets and hence localization of TV pathology can be challenging, particularly in disease conditions [1]. However, manipulation of the ultrasound transducer in the apical 4-chamber view using an anterior to posterior sweep or preferably a well performed subcostal view acquisition could, in some instances, allow for simultaneous display of all three TV leaflets. These views require an experienced echographer as well as a 3D interpretation of the individual leaflet orientation in space. Successful TV function depends on integrated and well-coordinated components of the whole TV apparatus.

TTE Examination of the Tricuspid Valve

TV morphology can be evaluated using 2D-TTE, which is considered the first modality for screening. Generally, TTE assessment of the TV is preferred to transesophageal echocardiography (TEE) as the right heart is situated in the near field. TTE scanning of the TV is rather challenging because of the complex non-planar position of the annulus and its highly variable anatomy [1]. It is very difficult to visualize all three leaflets simultaneously in one 2D-TTE view. Therefore, other echocardiographic modalities such as the multiplane iRotate, 3D-TTE or transesophageal echocardiography may be needed to complete TV evaluation.

TTE Modes

Table 5.1 lists the TTE modes that could be used for screening and assessment of tricuspid valve disease.

Table 5.1 Key uses of different transthoracic echocardiographic modalities

Modality	Utility
2D-TTE	Initial screening, often provides first clue for TV disease.
M-mode	Best used for tricuspid annular systolic excursion (TAPSE).
Doppler	The only modality, which provides hemodynamic and valvular regurgitation assessment.
Bi-Plane	Provides an orthogonal view of TV and right-sided chambers
iRotate	Provides a comprehensive evaluation of the TV annulus, leaflets as well as chamber quantification.
3D-TTE	Complete visualization of TV morphology; enface views as well as accurate valvular and chamber quantification.

Table 5.2 2D–TTE acoustic windows (views)

Acoustic window	Utility
Parasternal right ventricular inflow tract view (RVIT)	One of the most important views to assess TV morphology, regurgitation and to measure TV annulus.
Parasternal short-axis view (SAX) at the base of the heart	Provides valuable information regarding TV morphology, regurgitation
Apical 4-chamber views	
• Standard	Provides valuable information regarding TV morphology, regurgitation
• Focused	Provides valuable information regarding TV morphology, regurgitation
• Modified	Provides valuable information regarding TV morphology, regurgitation
• Subcostal 4-chamber view	Provides valuable information regarding TV morphology, regurgitation
Subcostal short-axis view	Provides comprehensive visualization of TV three leaflets as well as TV morphology and regurgitation

2D–TTE

Standard 2D-TTE for the assessment of TV morphology and function can be performed from multiple acoustic windows. Essential 2D–TTE acoustic windows include the standard parasternal long-axis (RV inflow), the parasternal short-axis view, the apical 4-chamber view, and the subcostal view (Table 5.2 and Figs. 5.1, 5.2, and 5.3). A comprehensive TTE exam of the TV requires the use of all feasible 2D views alongside Doppler Interrogation to obtain full assessment of the TV apparatus, right heart chambers as well as venous and pulmonary circulation. A localized pathology such as a flail leaflet could be missed if all the TTE views are not attempted. Detailed transesophageal assessment of TV is provided in Chap. 6.

3D-TTE

3D-TTE is often used in experienced centers to provide a comprehensive interrogation of the TV leaflets, annulus, subvalvular apparatus and RV size and function quantification.

Acquisition

3D-TTE acquisition can be performed from any of the standard 2D acoustic windows (parasternal, apical and subcostal). Using current technology cardiac structures in the axial dimension (y, azimuthal) have the best resolution (0.5 mm), in

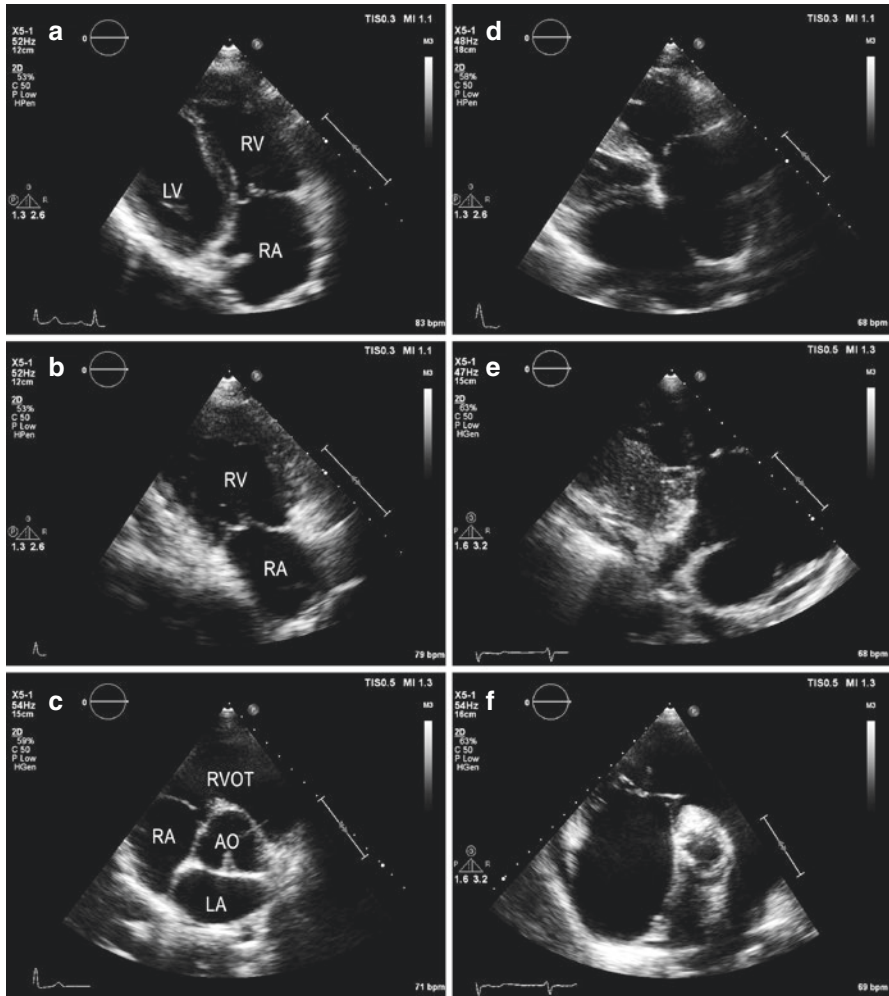


Fig. 5.1 The parasternal 2D-TTE views: standard right ventricular inflow tract view from a normal subject (a) and after further angulation (b) to exclude left ventricle from the scan sector and a standard parasternal short-axis view at base of the heart (aortic valve) level (c). Corresponding views from a patient with an abnormal TV (d, e and f). *LV* left ventricle, *RV* right ventricle, *RA* right atrium, *RVOT* right ventricular outflow tract, *LA* Left atrium, *AO* aorta

the lateral dimension (x) (2.5 mm), and in the elevation dimension (3.0 mm) the least resolution. Therefore, the parasternal short-axis window should provide the best quality for an “enface surgical” view. Consequently, TV display on 3D-TTE has an intermediate quality in the parasternal long-axis window and has the least quality in the apical window acquisition. The two most commonly used 3D-TTE modes are the real-time and the full-volume modes. The former has a relatively narrow angle (smaller scan sector) but it provides a higher resolution than the

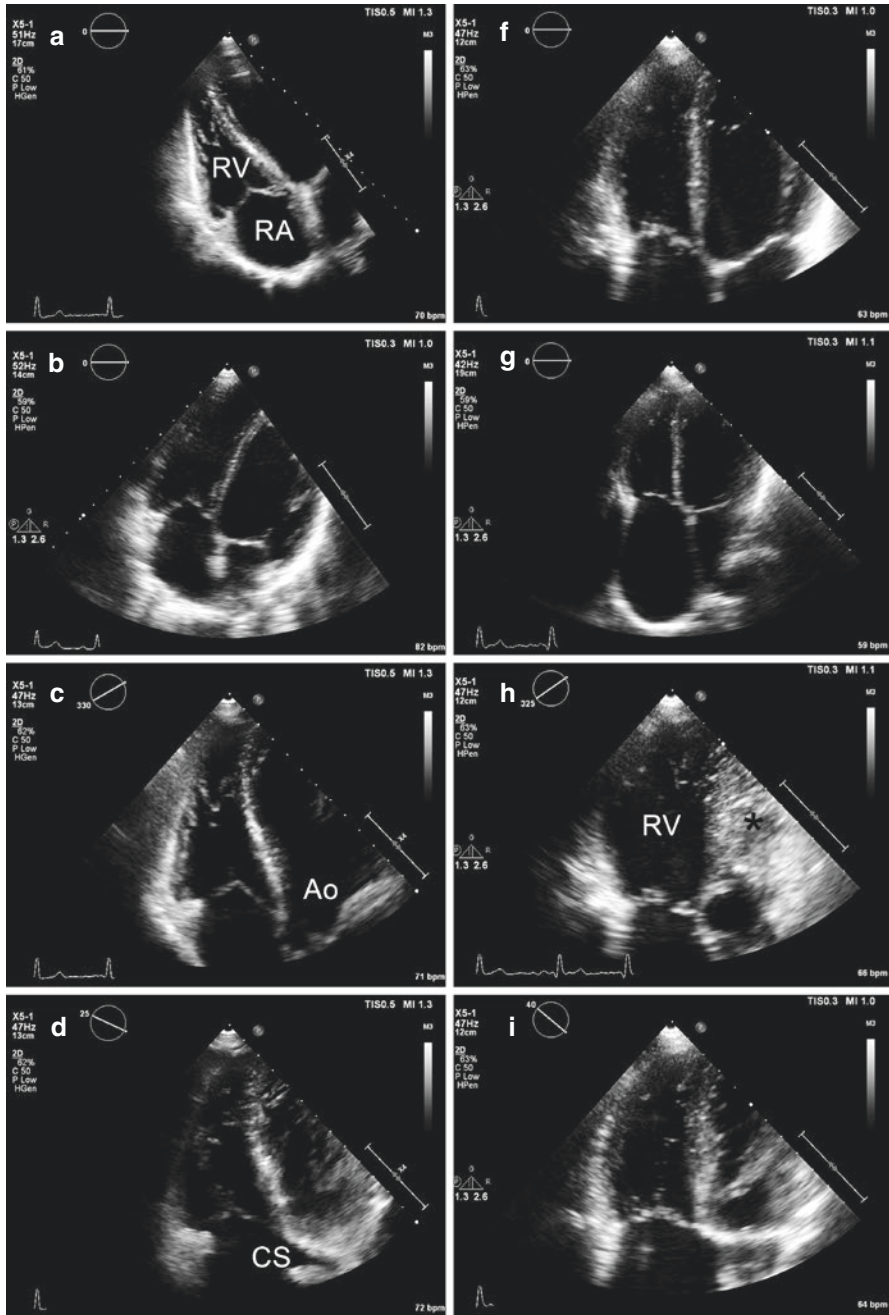


Fig. 5.2 The 2D-TTE apical views from a normal right heart (a–e): focused (a); modified (b); aortic (c); coronary sinus (d) and subcostal (e). Corresponding views from a subject with an abnormal TV (f–j). Note that in “h” LV cavity is minimally visualized due to the prominent RV (see*). Abbreviations are similar to Fig. 5.1, CS coronary sinus

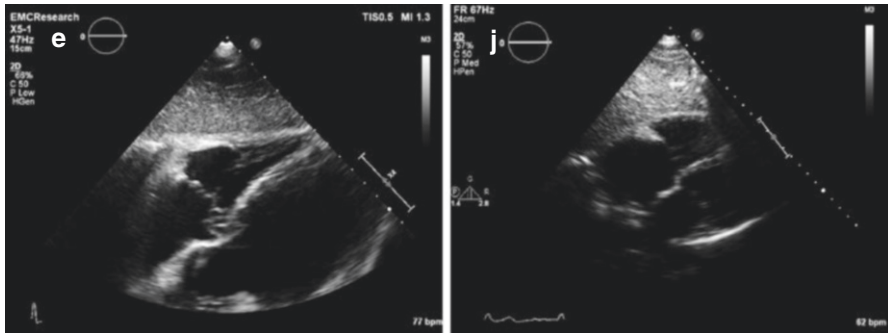


Fig. 5.2 (continued)

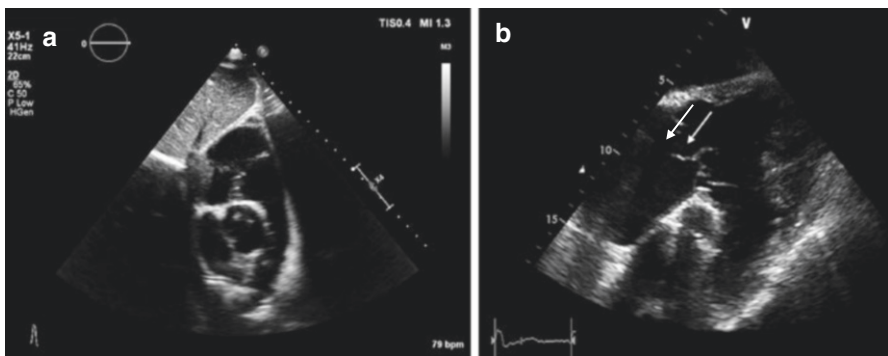


Fig. 5.3 The 2D-TTE subcostal short-axis views from a normal subject (a) and a subject (b) with a TV prolapse (arrow)

latter. Furthermore, a real-time scan is not limited to the number of heart cycles nor it is limited by respiration or arrhythmia. Moreover, it allows for focusing on a specific region of interest. On the other hand, the full volume mode allows for a wider angle (larger scan sector) that can include more structures in a single acquisition. However, structures on the full-volume mode have much lower resolution and could be limited by artifacts due to respiration or arrhythmia. The trade-offs between the two modes should be taken into consideration as per patient and according to the objectives of the 3D-TTE scan.

Analysis and Display

Similar to other 3D imaging modalities such as magnetic resonance imaging or computed tomography, real-time 3D-TTE datasets in the multiplanar reconstruction mode, display the full TV apparatus in 3D as well as right sided chambers in the 2D long-axis (coronal and sagittal) and short-axis (axial) planes. This allows for a

single image displaying the TV in an enface surgical view simultaneously with a full assessment of the TV leaflets (Fig. 5.4). For uniformity it has been proposed that display of the 3D-TTE enface view of the TV should preferably be performed with the septal leaflet in the 6 o'clock position [2].

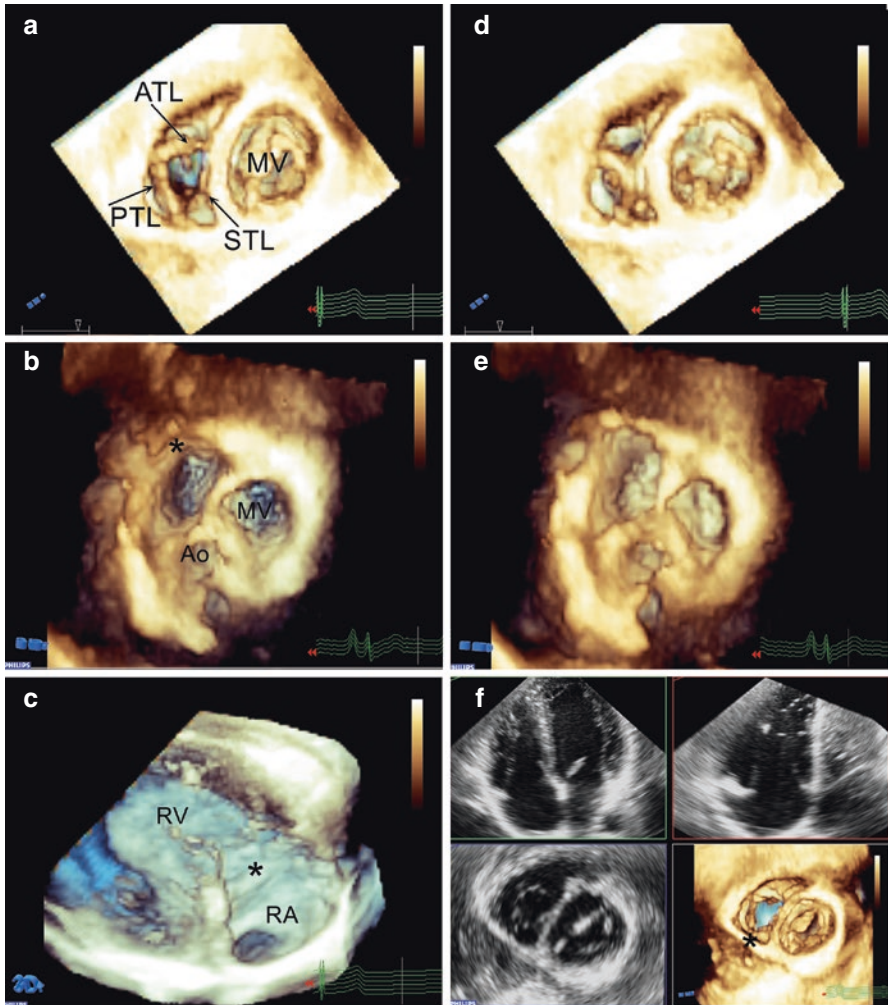


Fig. 5.4 Multiple 3D-TTE views of an open TV as seen from RV aspect (a) and from RA aspect (b) and the corresponding views with the valve closed (d and e); RV inflow view (c) and a 2D multiplane reconstruction from 3D dataset (f). Note that asterisk refers to the place of TV annulus. *ATL* anterior leaflet, *PTL* posterior leaflet, *STL* septal leaflet, *MV* mitral valve, *Ao* aorta, *RV* right ventricle, *RA* right atrium

Incremental Value of 3D-TTE over 2D-TTE of the TV

Compared with left sided structures, echocardiographic assessment of right-sided structures is more difficult due to the anterior location of the right heart and the variable position of the TV leaflets. Since 3DE is dependent on 2DE quality, 3DE acquisition of the right heart is still challenging. However, there is accumulating evidence that 3DE has incremental value in the assessment of TV disease compared with 2D-TTE.

Visualization of TV leaflets: Using 2D-TTE, it is extremely difficult to identify all leaflets in the parasternal short-axis view due to variability in their position. Anwar et al. have shown that by using a 3D mental reconstruction, both septal and anterior leaflets can be identified in all cases from the parasternal long-axis (RV inflow) and the apical 4-chamber views (Fig. 5.5). The use of an enface view from a right atrial or right ventricular aspect, “surgical view” provides a simultaneous display of the TV leaflets and their attachment to the TV annulus as well as it provides accurate assessment of leaflet morphology, thickness, leaflet defect, prolapse and fusion of commissures.

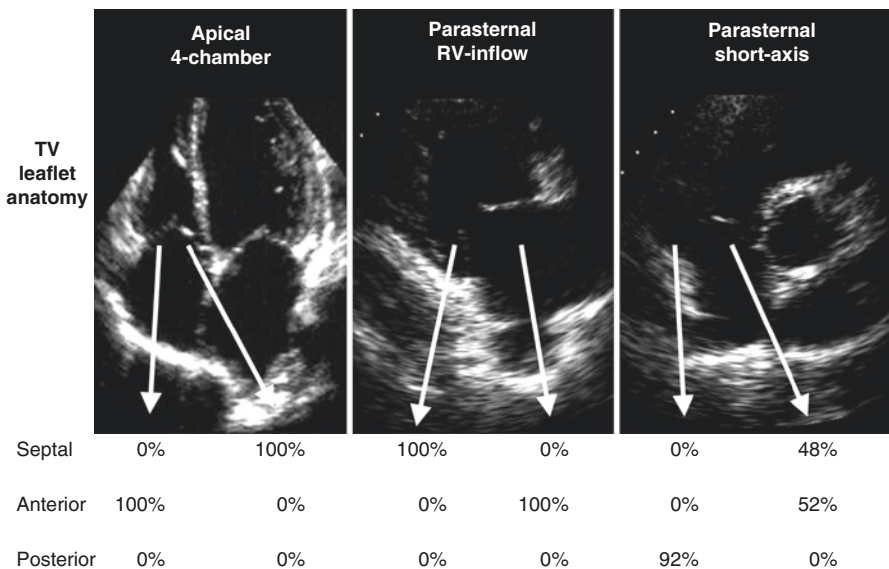


Fig. 5.5 Visualization of TV leaflets on three standard 2D-TTE views. Percentages of the leaflet identification have been reported below each 2D view. From Anwar et al. with permission [1]

Quantification of TV annulus: Another clear advantage of 3D-TTE over 2D-TTE is the ability of the former to accurately quantify the non-planner TV **annulus** [1, 3]. Detailed measurements of leaflets size, intercommisural distance, and cyclic variation can be made [1].

Assessment of TR: Moreover, real-time 3D-TTE has an increasing role in the assessment of TR (Fig. 5.6). Assessment of TV leaflets and commissures morphology, annulus size and non-coaptation distance provide important clues to **etiology and mechanism**

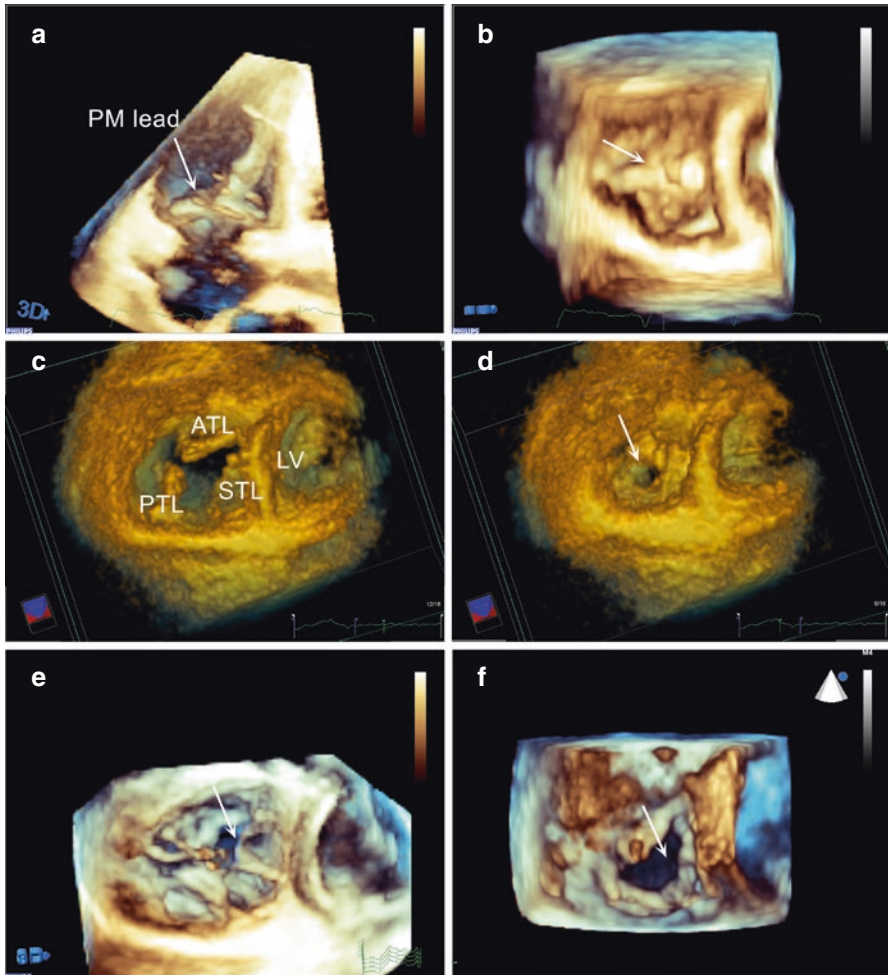


Fig. 5.6 Visualization of different etiologies and mechanisms of TR on real-time 3D-TTE: (a) a long-axis and (b) a short-axis enface TV view as seen from the RV aspect, a pacemaker lead (*arrow*) restricts TV leaflets from closing. (c) and (d) are from a patient with a prolapse of the posterior leaflet of the TV with elongated chordae as seen from RV aspect with TV open (c) and RA aspect TV closed (d). The arrow points to incomplete TV coaptation due to prolapsed posterior leaflet. Image (e) shows an enface view of TV, as seen from the RV aspect, with a tear in the TV leaflets (*arrow*) after repeated biopsies in a patient with a heart transplant. Image (f) shows lack of TV leaflets coaptation (*arrow*) due to carcinoid disease in enface RV view. ATL anterior leaflet, PTL posterior leaflet, STL septal leaflet, PM pacemaker lead, LV left ventricle

of TR. Furthermore, although practically difficult, quantification of **vena contracta area** of TR jet on real-time colour Doppler 3D-TTE has been accomplished. The authors proposed new cut-off values for TR severity: 0.5 cm^2 for mild, $0.5\text{--}0.75 \text{ cm}^2$ for moderate, and $>0.75 \text{ cm}^2$ for severe TR [4]. However, these values need to be prospectively validated in a larger external population. Respiratory variation of **TV jet regurgitant orifice area** has been shown on colour Doppler 3D-TTE, as well as other TR parameters on 2D-TTE [5, 6].

Tricuspid annular dilatation in patients with functional TR can be a more accurate indicator of TR severity than color Doppler of TR alone [7–9]. Therefore; the ability to accurately quantify TV annulus with 3D-TTE is important in the assessment of TR severity [10, 11].

Display and assessment of **TV enface area**, similar to mitral enface area; in patients with suspected TV stenosis is required for accurate diagnosis of TV pathology, and of course only feasible on 3D-TTE [12, 13].

Simultaneous Multiplane Imaging

With the introduction of the MATRIX transducer, simultaneous multiplane imaging has become available. This new modality permits the use of a full electronic rotation of 360° (adjustable by 5° steps) of the 2D image (iRotate) and a simultaneously adjustable bi-plane 2D image (xPlane).

Bi-plane TTE

In the bi-plane mode an orthogonal view can be obtained through the midline of the primary image, such as the tricuspid valve, and displayed as a secondary image. If necessary, from the midline additional secondary images can be visualized by a lateral tilt of up to maximal $+30^\circ$ to -30° (Fig. 5.7).

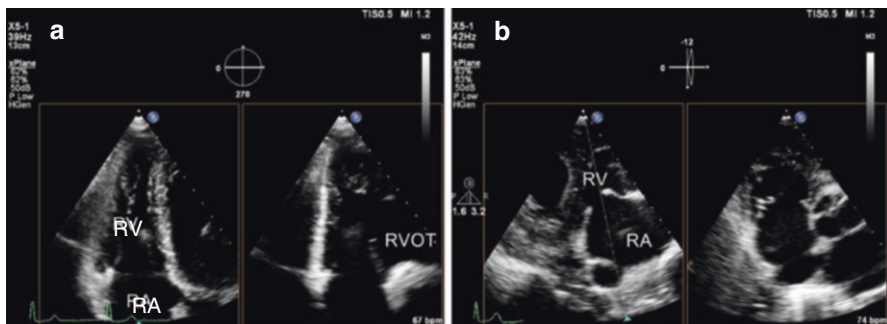


Fig. 5.7 2D-TTE bi-plane mode assessment of the TV in two different views: (a) from a normal subject where the reference line transects the tricuspid valve annulus in a focused RV apical view allowing measurements of two axes diameters; (b) from a patient with TV disease where the reference line, transects the tricuspid valve annulus in the RV inflow view allowing measurements of two axes diameters. All measurements can be performed in the same heartbeat. *RV* right ventricle, *RA* right atrium, *RVOT* right ventricular outflow tract

iRotate Mode

2D- iRotate echocardiography is a relatively new echo modality aiming at maximizing the benefits of using 2D- and 3D-TTE in routine clinical practice by combining the advantages of the two echo modalities. It allows for full assessment of a cardiac structure such as the right ventricle from a single transducer position. The iRotate images retain the advantages of a better quality and a higher frame rate than 3D-TTE. The feasibility of 2D-TTE iRotate has been examined by our group for the assessment of right ventricular function using fixed anatomic landmarks [14] as well as right ventricular strain assessment [15].

McGhie et al. proposed a novel 13-segment model to assess right ventricular function from a single apical acquisition using the iRotate mode. The proposed protocol uses four anatomic landmarks to identify the different right ventricular walls, namely: mitral valve for RV lateral free wall, coronary sinus for RV anterior wall, aortic valve for RV inferior wall and RVOT for RVOT anterior and inferior wall. From the apical window, a standard apical 4-Chamber view can be adjusted to acquire a focused non-foreshortened RV view with the tricuspid valve centered along, or as near as possible, to the midline of the sector. With the iRotate mode a full electronic rotation can be performed. Using the anatomic landmarks, as defined above, four standard TV annulus views can be acquired (Figs. 5.8 and 5.9).

The 2D-TTE iRotate mode provides a standard methodology for serial assessment of RV function [16]. High quality image acquisition using the 2D-TTE iRotate mode could be achieved after a relatively short learning curve of 20 cases. The feasibility of segmental RV wall analysis approached 95% in subjects with normal- and patients with dilated-RVs. Furthermore, quantification of RV function using tricuspid annular plane systolic excursion (TAPSE) and Doppler tissue velocities were feasible in more than 90% of subjects with normal RV size and in all patients

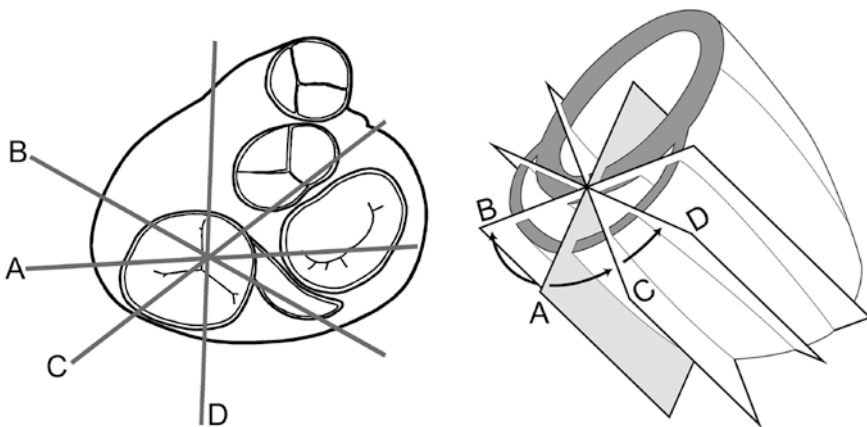


Fig. 5.8 A schematic drawing of the cut planes for the four iRotate RV views. *Left*: as visualized in the transvers plane viewed from the RV aspect. *Right*: as visualized in the RV sagittal plane

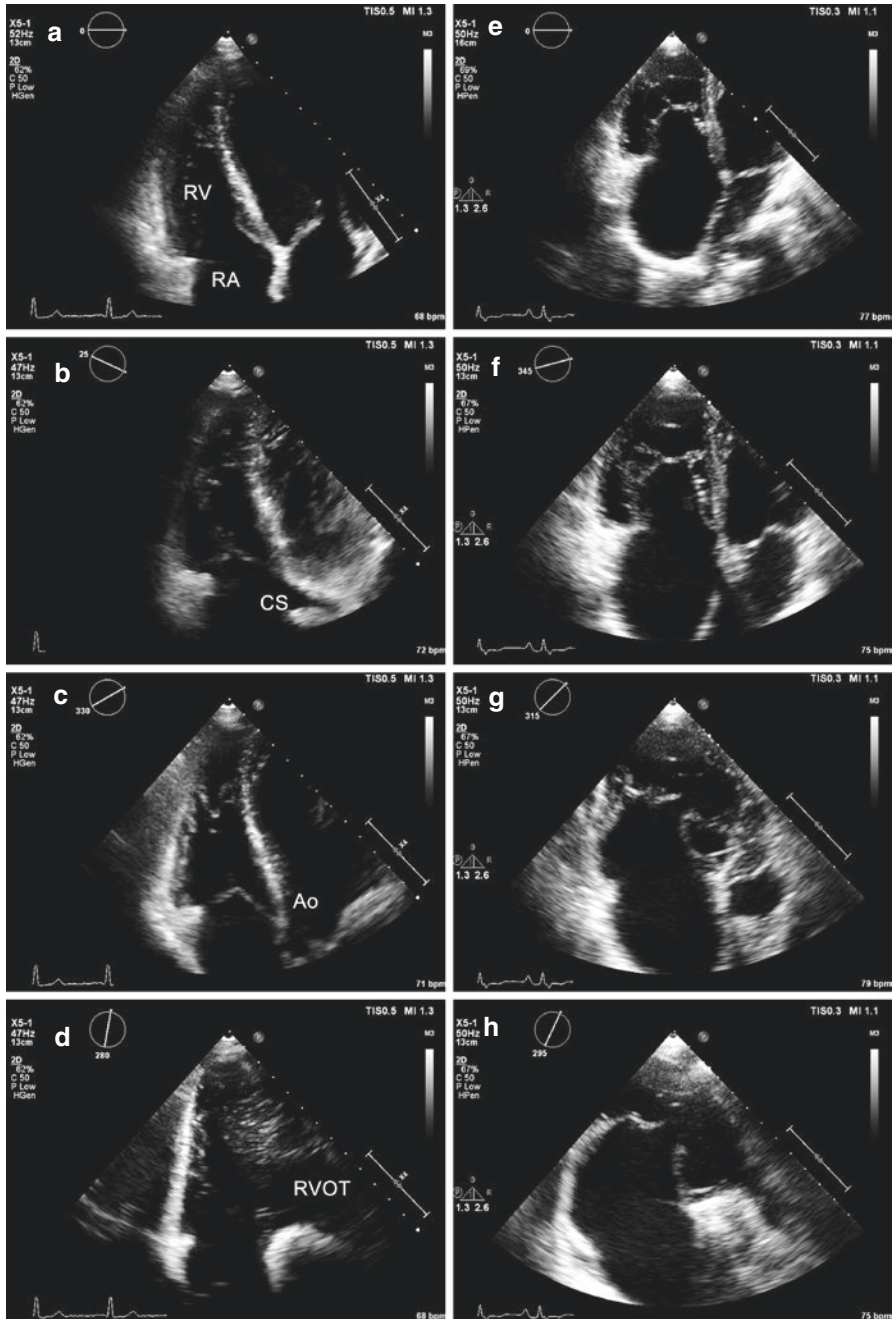


Fig. 5.9 The 2D-iRotate image acquisitions of the four RV views from a normal TV valve, *left*, and *right* the corresponding views from a patient with Ebstein's anomaly (**a, e**) the mitral view: visualizing the RV lateral wall; (**b, f**) the coronary sinus view: visualizing the RV anterior wall; (**c, g**) the aortic view: visualizing the RV inferior wall; (**d, g**) the coronal view: visualizing the RV inferior wall and RVOT anterior wall. Note the position of the chordal attachments, towards the RVOT, of the Ebstein TV in (**h**)

with dilated RVs. Likewise, assessment of RV strain in subjects with normal and dilated RV has been shown feasible and reproducible using the 2D-TTE iRotate mode [15].

Translating those initial feasibility studies of the 2D-TTE iRotate mode into direct TV assessment could be speculated in several aspects. It could be used for more robust serial follow up of disease progression before- and reverse remodeling after percutaneous interventions or surgery involving the TV. Likewise, recovery of RV function after TV repair or replacement could be more accurately quantified. The 2D-TTE iRotate mode could be used as well for comprehensive and robust serial assessment of TV annulus size and function.

TTE Approach to Tricuspid Valve Disease

Tricuspid pathology can be broadly described as stenotic, regurgitant or both. TV disease varies widely from asymptomatic lesions to advanced cases with generalized anasarca due to severe TR. Congenital TV disease is beyond the scope of this book chapter.

A diagnostic approach begins with morphologic assessment and localization of the underlying TV pathology. Once the etiology of TV lesion is established, assessment of disease severity is the next step. Impact of TV disease on right sided chambers size and function as well as pulmonary and hepatic circulation should follow. Finally, associated valvular lesions and assessment of left sided chambers should be performed. Table 5.3 lists the comprehensive assessment of the TV with 2D-TTE.

TTE Approach to Tricuspid Valve Stenosis

TV stenosis can be due to rheumatic, infiltration such as in carcinoid disease, or rarely, due to compression by external structure such as tumor, thrombus or the aorta. When suspected, morphologic assessment with 2D-TTE and colour-Doppler, spectral pulsed- and continuous-wave Doppler is required (Fig. 5.10). Tracing of

Table 5.3 Comprehensive tricuspid valve assessment on transthoracic echocardiography

Item	Utility
Leaflets	Thickening, doming, restriction Coaptation Flail
Annulus	Diameter, area, changes over cardiac cycle
Gradient	Mean gradient
Tricuspid regurgitation	Severity of regurgitation.
Septum	Septal flattening
Right atrium	Chamber quantification
Right ventricle	Chamber quantification
Pulmonary artery	Pulmonary artery pressure

Doppler flow envelopes should be performed and averaged from three to five cardiac cycles. Velocity timed integral (VTI) and mean gradient can then be calculated automatically. There are several methods for calculation of the TV cross sectional area (Tables 5.4 and 5.5).

Doppler estimation of TV cross-sectional area is based on the conservation of mass theory. Using the continuity equation, TV cross-sectional area can be calculated from the standard formula (TV cross sectional area in $\text{cm}^2 = [A_1 * V_1 / V_2]$) where A_1 is the cross-sectional area from left or right ventricular outflow, V_1 is the peak flow velocity from left or right ventricular outflow on pulsed-wave Doppler. V_2 is the peak flow velocity from forward TV flow on continuous-wave Doppler. Another method for estimation of TV cross-sectional area can be derived from the formula TV area in $\text{cm}^2 = \text{stroke volume} / \text{TV-VTI}$. Stroke volume, mentioned above, is derived from left or right ventricular outflow. Stroke volume can be estimated from the formula (stroke volume = cross sectional area * velocity time integral) based on Doppler interrogation of either left or right outflow tracts.

TV area can also be estimated from the formula $190/\text{PHT}$, where PHT is the pressure half time from forward TV flow on continuous-wave Doppler. In the presence of mild or more TR, the derived area will be underestimated. Furthermore, the stroke volume calculation becomes inaccurate in cases of aortic or pulmonary regurgitation. Tricuspid inflow velocities are largely dependent on respiration, heart

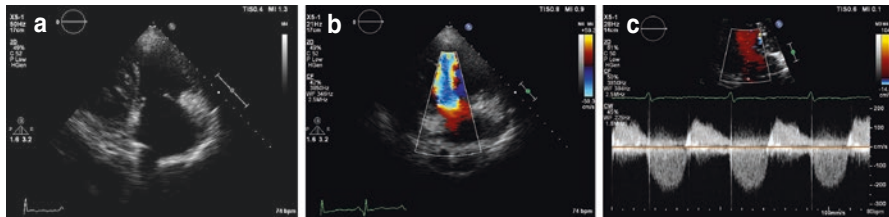


Fig. 5.10 Example of a stenotic tricuspid valve on 2D-TTE (a); flow acceleration on colour-Doppler (b) and typical pattern on spectral continuous-wave Doppler (c)

Table 5.4 Estimation of TV cross-sectional area on transthoracic echocardiography

	Formula
Continuity equation	TV cross sectional area in $\text{cm}^2 = [A_1 * V_1 / V_2]$
	TV cross sectional area in $\text{cm}^2 = [A_1 * \text{VTI}_1 / \text{VTI}_2]$
	TV cross sectional area in $\text{cm}^2 = [\text{Stroke volume} / \text{VTI}_2]$
PHT	TV cross sectional area in $\text{cm}^2 = 190/\text{PHT}$

A_1 is the cross-sectional area from left or right ventricular outflow; V_1 is the peak flow velocity from left or right ventricular outflow on pulsed-wave Doppler. V_2 is the peak flow velocity from forward TV flow on continuous-wave Doppler and VT_1 is the velocity time integral from the pulsed-wave Doppler of either right or left ventricular outflow tracts; VT_2 is the velocity time integral from the pulsed-wave Doppler of blood flow at the tricuspid valve annulus. TV cross sectional area in $\text{cm}^2 = \text{stroke volume} / \text{TV-VT}_1$. Stroke volume as above-mentioned is derived from left or right ventricular outflow PHT, Pressure half time; TV, Tricuspid valve; VTI, Velocity time integral. Although there are similarities between mitral and tricuspid stenosis, the P1/2t method has not been as extensively validated for the calculation of tricuspid valve area [34]

Table 5.5 Signs of hemodynamically significant TV stenosis on transthoracic echocardiography

Item	Cut-off value
<i>Specific findings</i>	
Mean pressure gradient	≥5 mmHg
RV inflow velocity-time integral	≥60 cm
RV inflow PHT	≥190 ms
TV area	≤1 cm ²
<i>Supporting findings</i>	
Dilated right atrium	≥Moderate
Dilated inferior vena cava	

TV tricuspid valve, RV right ventricle, PHT pressure half time

rate and rhythm. Therefore, all measurements must be averaged throughout the respiratory cycle or recorded at endexpiratory apnea. As a rule of thumb, Doppler measurements from a minimum of three (sinus rhythm) or five cardiac cycles (atrial fibrillation) should be averaged. Likewise, pressure half-time is not reliable in case of tachycardia.

TTE Approach to Tricuspid Valve Regurgitation

TR is the most frequently seen TV pathology. It can be organic due to leaflet pathology or functional secondary to annular dilatation and/or ventricular dysfunction. The latter is the predominant form mostly encountered in clinical practice. Trivial TR is considered physiologic and it is very often seen on routine echocardiography. Mild TR has been reported in 80–90% of echocardiograms. The prevalence of moderate or severe TR was 0.8% in the Framingham heart study with an increased prevalence with age and was fourfold more frequent in females than males [17]. One-third of patients with mitral valve stenosis have at least moderate TR [18]. Severe TR has been reported in 23–37% of patients who underwent mitral valve replacement for rheumatic mitral valve disease [19, 20]. This form of TR is defined as “functional” or “secondary” since no primary TV pathology could be seen in most of these patients. Likewise, functional TR is often seen in patients with advanced left heart disease [21].

Residual moderate or severe TR after correction of left sided lesions is not benign; it does not often regress and is associated with reduced cardiac output and right-sided heart failure. Redo surgery is associated with up to 10% mortality. More importantly, it has been associated with poor long-term outcome [22]. Therefore, surgical TV repair or replacement is indicated for patients with stages C and D functional severe TR undergoing left sided valve surgery [23]. Details on TR clinical spectrum are described in Chap. 2 of this book.

TTE Diagnostic Algorithm of TR

According to the current guidelines, TTE is the primary modality for TR assessment. Complete TR assessment requires; identification of etiology, severity and impact on right ventricle (and vice versa) size and function as well as right atrial size and assessment of inferior vena cava. Furthermore, pulmonary artery systolic pressure should be estimated and any associated left heart disease should be assessed [23, 24].

Etiology and Mechanisms of TR

TR can be due to a primary cause such as a structural abnormality of the TV or incomplete leaflet closure secondary to a dilated TV annulus or a dilated right ventricle or to mal-coaptation and/or tethering of the TV leaflets (Table 5.6).

Table 5.6 Etiology and mechanisms of tricuspid regurgitation

Aetiology	Feature	Mechanism(s)
Primary	Less common (10–25%) Structural abnormality of tricuspid valve leaflets Acquired disease or congenital	Cleft leaflet (congenital) Perforation (endocarditis) Mal-coaptation (pacemaker leads) Retraction (rheumatic, radiation, drug, carcinoid) Prolapse (degenerative) Ruptured chordae (traumatic or endocarditis) Congenital Ebstein's anomaly or prolapse <i>Other congenial etiologies:</i> TV dysplasia TV tethering (perimembranous ventricular septal defect and ventricular septal aneurysm) Repaired tetralogy of Fallot Congenitally corrected transposition of the great arteries Other (giant right atrium)
Secondary (Functional)	Most frequent (80–90%) Morphologic normal leaflets with impaired leaflets coaptation	Annular dilatation and or RV dilatation Leaflet tethering due to left sided heart disease or pulmonary hypertension RV dysfunction (RV ischemia; RV volume overload, RV cardiomyopathy) RA abnormalities (atrial fibrillation)

RV right ventricular

Grading of TR Severity

Similar to all other valves, TR is first assessed by visual inspection of the return of blood from the right ventricle into right atrium using colour Doppler. As recommended by the ASE guidelines, the use of a multi-parametric approach is mandatory [26, 40]. TR severity is determined according to 2D chamber measurements and function and Doppler recordings of jet characters. There are a few colour Doppler jet characteristics including jet area, vena contracta (VC) width and area, proximal isovelocity area (PISA) radius and flow convergence. Continuous-wave Doppler parameters include TR Doppler jet envelope shape and density. Furthermore, Doppler interrogation of hepatic venous flow is an integral part of 2D echocardiographic estimation of TR severity. However, Doppler cut-off values, which are used for grading TR severity, are largely not well validated, nor in respect all aspects of TR severity, particularly functional TR (Table 5.7).

When moderate or severe TR is suspected it is often associated with an abnormally dilated right atrium, right ventricle and inferior vena cava. Spectral Doppler profile of the hepatic veins assists in the diagnosis of TR severity: systolic flow blunting is often seen in patients with moderate TR and systolic flow reversal in severe TR.

Use of Colour Doppler in TR Severity Assessment

Colour flow Doppler is often used as the first modality to screen for regurgitant valvular lesions. It provides visualization of the jet origin, jet width and its spatial orientation in the receiving chamber. In case of severe regurgitation, flow convergence occurs into the regurgitant orifice. An optimally visualized TR jet is composed of three parts: jet head, seen inside the right ventricle, jet neck and jet body seen inside the right atrium (Figs. 5.11 and 5.12).

TR Jet Area

While a large jet area on colour Doppler is associated with more significant TR, there are several determinants of the TR jet area on colour Doppler regarding severity: hemodynamic or loading conditions, etiology and shape of the jet as well as technical factors (Table 5.8). Optimal machine settings include a Nyquist limit (aliasing velocity) of ± 50 –70 cm/s, and a colour gain that is just enough to eliminate random colour speckles from non-moving tissue. Optimized and standardized machine settings are essential in serial follow-up studies to avoid measurement errors (Fig. 5.13) while assessing progression or regression of TR after pharmacological, percutaneous or surgical interventions. There are several caveats in using

Table 5.7 Assessment of chronic tricuspid regurgitation severity on transthoracic echocardiography

Parameter	Mild	Moderate	Severe
<i>Structural</i>			
TV morphology	Normal or mildly abnormal leaflets	Moderately abnormal leaflets	Severe valve lesions (e.g., flail leaflets severe retraction, large perforation)
RV, RA	Usually normal	Normal or mild dilatation	Usually dilated ^a
RV eccentricity index	Usually normal	Normal or abnormal	>2
Inferior vena cava	Usually normal	Normal or abnormal	>21 mm with <50% collapse
<i>Qualitative Doppler</i>			
Color flow jet area ^b	Small, narrow, central	Moderate central	Large central jet or eccentric wall impinging jet of variable size
Flow convergence zone	Not visible, transient or small	Intermediate in size and duration	Large throughout systole
CWD jet	Faint/partial/parabolic	Dense, parabolic or triangular	Dense, often triangular
<i>Qualitative Doppler</i>			
Color flow jet area (cm ²) ^b	Not defined	Not defined	>10
VCW (cm) ^b	<0.3	0.3–0.69	≥0.7
PISA radius (cm) ^c	≤0.5	0.6–0.9	>0.9
Hepatic vein flow ^d	Systolic dominance	Systolic blunting	Systolic flow reversal
Tricuspid inflow ^d	A-wave dominant	Variable	<i>E</i> -wave >1.0 m/s
<i>Qualitative Doppler</i>			
EROA (cm ²)	<0.20	0.20–0.39 ^e	≥0.40
RVol (2D PISA) (mL)	<30	30–44 ^e	≥45

RA right atrium

Bolded signs are considered specific for their TR grade

Reprinted with permission from Ref. [40]

^aRV and RA size can be within the “normal” range in patients with acute severe TR

^bWith Nyquist limit >50–70 cm/s

^cWith baseline Nyquist limit shift of 28 cm/s

^dSigns are nonspecific and are influenced by many other factors (RV diastolic function, atrial fibrillation, RA pressure)

^eThere are little data to support further separation of these values

color jet area for assessing TR severity. TR jet area can show a considerable overlap in patients with mild versus moderate TR. Furthermore, eccentric and wall impinging jets appear smaller than central jets with similar regurgitation volume. Another extreme form of misleading color Doppler jet area could be seen in patients with severe TR and wide-open (no TV coaptation). In those patients the TR velocity could be quite low without aliasing or distinct jet pattern [40].

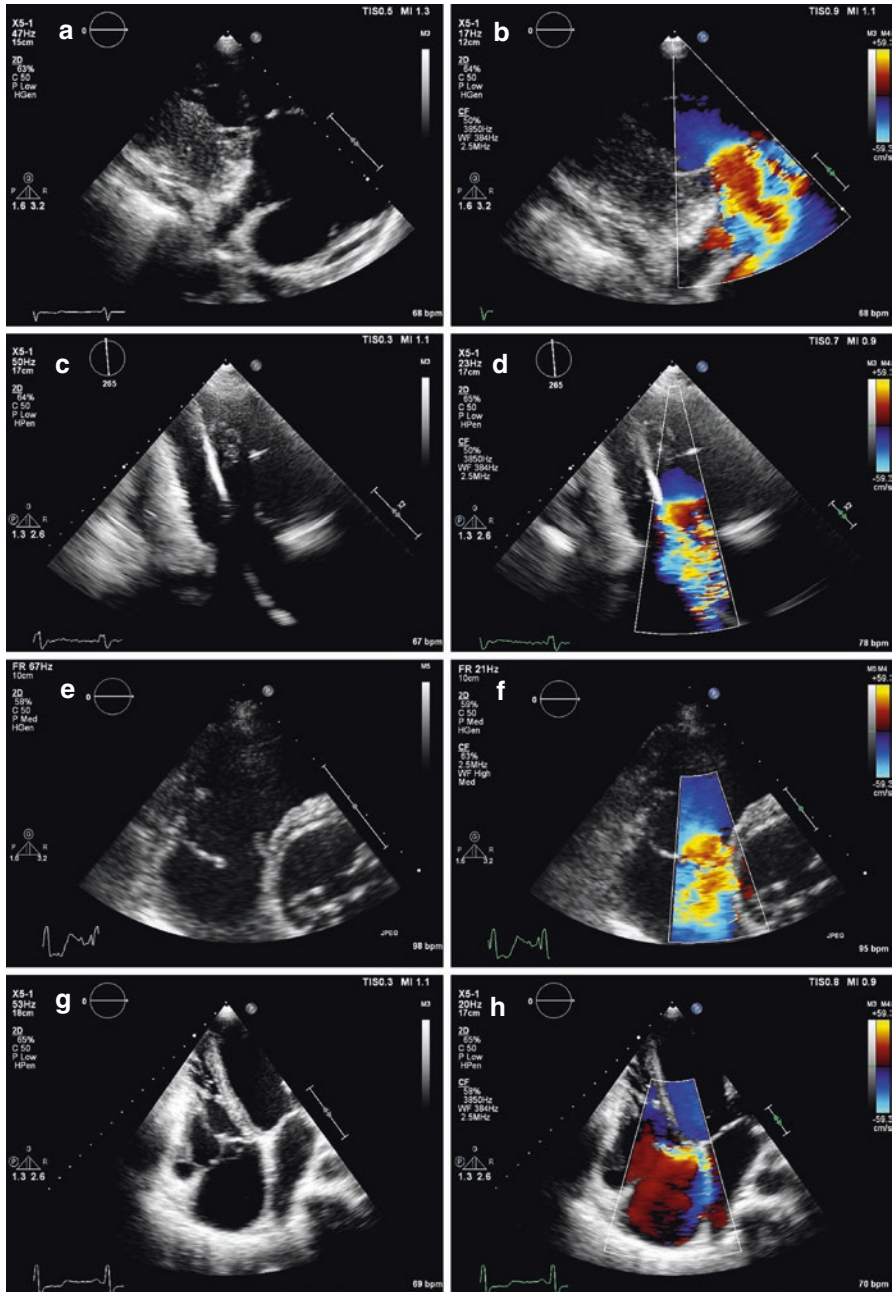


Fig. 5.11 Visualization of different TR aetiologies due to: no coaptation (a and b), pacemaker lead (c and d); frequent biopsies in a patient post heart transplant (e and f) and TV leaflets prolapse (g and h)

Fig. 5.12 Visualization of a central (a) and an eccentric (b) TR jets

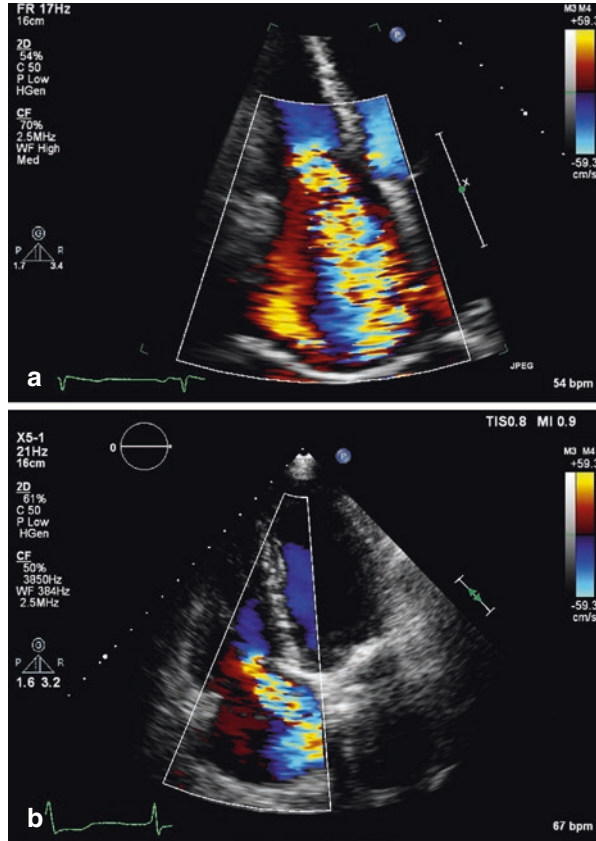


Table 5.8 Determinants of tricuspid regurgitation on colour Doppler

Feature	Description
Hemodynamic/loading conditions	Hyper/hypotension RA size and capacitance RA pressure RA-RV pressure gradient Phase of respiration
Aetiology and shape of TR jet	Central jet Versus eccentric jet (coanda effect) and wall impinging jets, use multiple views
Technical limitations	Nyquist limit Sector depth and size Gain settings Transducer frequency Suboptimal views

RV right ventricular, *TR* tricuspid regurgitation, *RA* right atrium

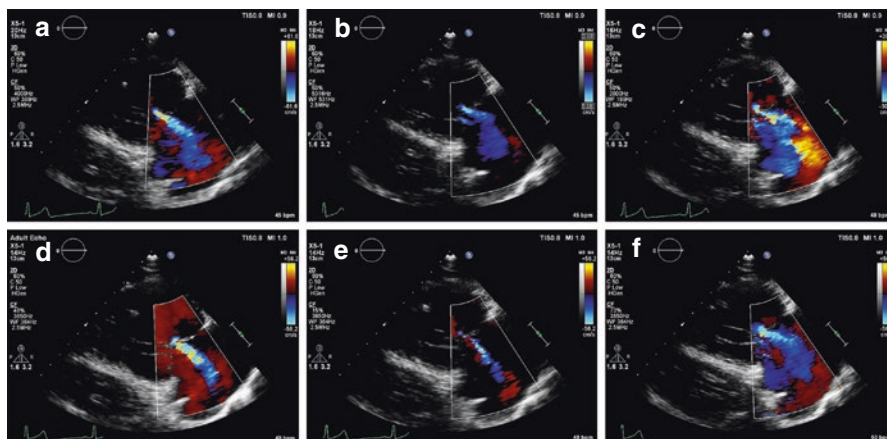


Fig. 5.13 Impact of altered machine settings on the assessment of TR severity. Upper panel: influence of the velocity scale: normal (a), high (b) and low (c). Lower panel: influence of gain: normal (d), too little (e) and too much (f)

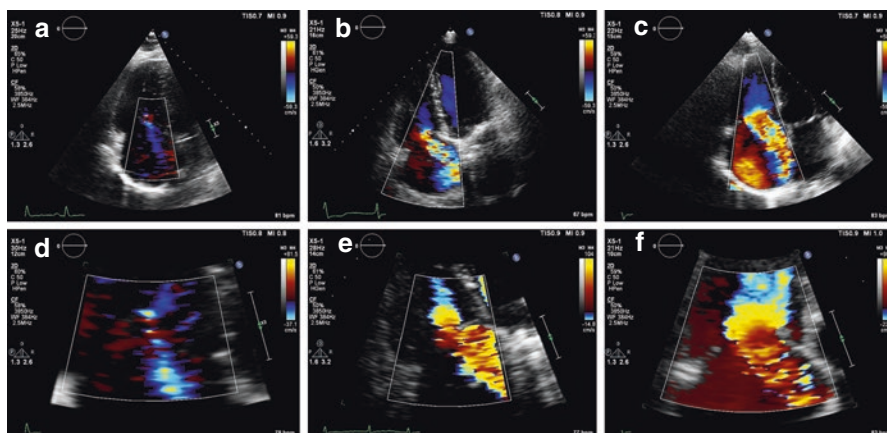


Fig. 5.14 Optimal visualization and measurement of TR jet vena contracta on colour Doppler in a patient with mild (a, d), moderate (b, e) and severe (c, f) TR

TR Jet Vena Contracta

The vena contracta (VC), (Fig. 5.14), is the narrowest portion of a jet that occurs at or just downstream from the orifice. Visualization of TR VC is technically less demanding than the PISA method. For optimization of the TR jet VC width one should: use colour Doppler interrogation of the TR signal in the apical 4-chamber view and RV inflow parasternal view; set the Nyquist limit to $\pm 50\text{--}70$ cm/s and use a narrow sector and zoom in to allow a frame rate of >20 frames per second. A jet VC of >7 mm has 89% sensitivity and 93% specificity for severe TR [25, 26].

Chen et al. [27] Have shown that VC area (A) measurement on 3D-TTE is feasible in the majority of patients with at least mild TR and in sinus rhythm but not in

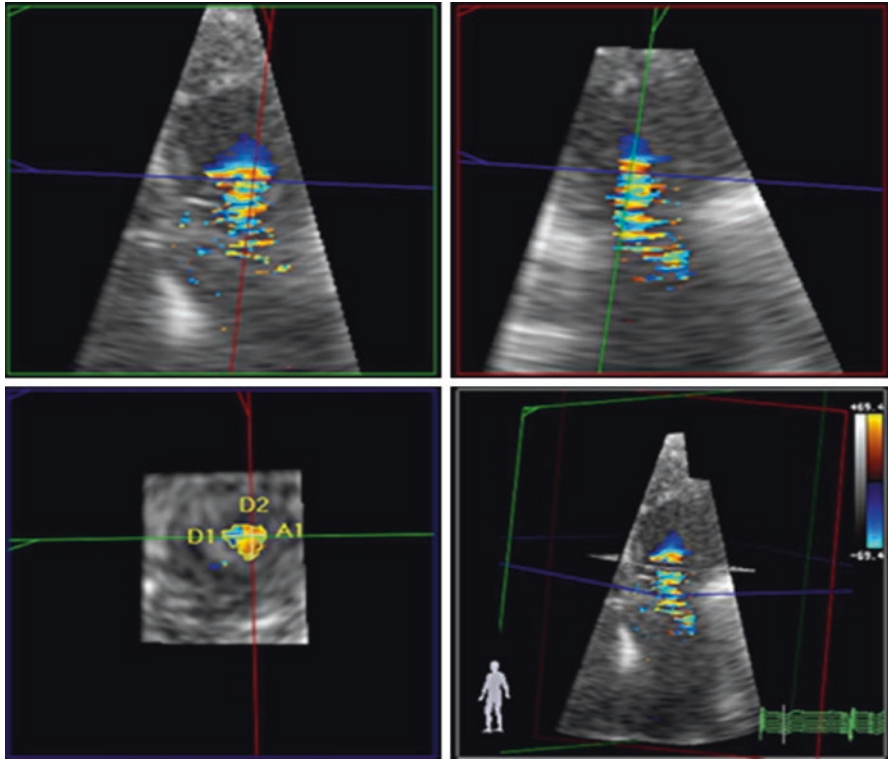


Fig. 5.15 Three-dimensionally guided 2D direct planimetry of vena contracta area (VCA) in multiplanar reconstruction (MPR) mode in a patient with severe TR. Three-dimensional colour pyramidal full-volume data sets were reviewed in MPR mode in the mid-systolic phase, the red quadrature/sagittal plane (*top right*) and green quadrature/coronal plane (*top left*) were carefully adjusted to be parallel to the colour jet and moved into the center of TR, and then the blue quadrature/transverse plane (*bottom left*) was moved to reach the level of the VC, where direct planimetry of VCA (A1), long axis (D1), and short axis (D2) was performed. The *white quadrature* (*bottom right*) shows the MPR slice view of three orthogonal planes of the 3D pyramidal volume

patients with atrial fibrillation, even with $<20\%$ cycle length variation (Fig. 5.15). Based on current evidence, a VC area $> 0.4 \text{ cm}^2$ is a reasonable cutoff value for severe TR [33, 40].

Flow convergence method (proximal isovelocity surface area [PISA] method). Flow Acceleration and TR Jet Effective Regurgitant Orifice Area (EROA)

PISA can be assessed in the apical 4-chamber view. For optimal optimization of the TR jet PISA radius, set the Nyquist limit to an aliasing velocity of 28 cm/s. A PISA radius of $>9 \text{ mm}$ correlates with severe TR, 6–9 mm correlates with moderate TR, while a PISA radius of 5 mm or less is often associated with mild TR.

Method 1. PISA Quantification of TR

Step 1. Measure the radius of the PISA hemisphere to calculate the hemispheric area where $area = 2\pi r^2$

Step 2. Measure the flow through the PISA using the formula: Q (flow in mL/min) = Area * Velocity or $2\pi r^2 * V_A$ (V_A = Aliasing velocity based on Doppler scale).

Step 3. Measure flow velocity of the TR jet (V_R) from the CW Doppler envelope.

Step 4. Based on the continuity equation, flow at PISA is equal to the flow at the regurgitant orifice area (ROA). Therefore, $ROA * V_R = 2\pi r^2 * V_A$ or $ROA = (2\pi r^2 * V_A)/V_R$.

Method 2. PISA Quantification of TR

There is another simplified one step approach for PISA quantification of TR severity based on the measurement of the PISA radius. The rationale behind this simplified approach is based on adjusting the colour Doppler aliasing velocity to 1/12 of the TR jet velocity on continuous-wave Doppler. This is shown in the following algorithm:

Begin with step 3 as above, and then adjust V_A to 1/12 of V_R on ultrasound machine.

- $ROA = (2\pi r^2 * V_A)/V_R = (6.28 r^2 * V_A)/V_R$
- Since $V_A/V_R = 1/12$, then $ROA = 6.28 r^2 * 1/12 = 0.5 r^2$
- From the table below, you can estimate ROA from the PISA radius

However, it is important to correct for underestimation of the flow rate due to flattening of the isovelocity shells close to the orifice [28]. Therefore, correct for velocity by using the ratio $(V/[V - V_A])$, where V is the peak TR velocity from continuous-wave Doppler and correct for the irregular funnel shaped TR orifice (Table 5.9).

Thus, the mid-systolic instantaneous is calculated as TR flow $Q = (2\pi * r^2 * V_A) * (V/[V - V_A]) * (\alpha/180)$. Where α is the angle of the systolic inverted tricuspid valve funnel [25]. Therefore, $ROA = Q/V$.

Table 5.9 Estimation of tricuspid regurgitation severity based on PISA radius

PISA radius ($V_A = 1/12$ of V_R)	ROA	
1–4 mm	5–8 mm ²	Mild
5–8 mm	13–32 mm ²	Moderate
>9 mm	>40 mm ²	Severe

Caveats in PISA Estimation of TR

Assessment of TR severity based on the PISA method can result in significant underestimation of the regurgitant orifice area (ROA) [29–31]. The shape of the tricuspid regurgitant orifice is often elliptical or very irregular, particularly in cases of severely tethered TV leaflets. Another important caveat in the PISA calculation is related to respiratory variations in the TR jet velocity and PISA radius. During inspiration, flow increases but TR velocity decreases and the opposite occurs during expiration [32]. Therefore, both measurements should be averaged when assessing the severity of TR. Topilsky et al. have shown that despite a reduction in the regurgitation gradient and consequently TR peak jet velocity during inspiration, there is a significant increase in tricuspid regurgitant volume due to a large increase in effective regurgitant orifice [32]. The latter is linked to an inspiratory widening of the RV cavity and thus TV annular enlargement, which means a decreased valvular coverage and increased valvular tenting [32] (Fig. 5.16).

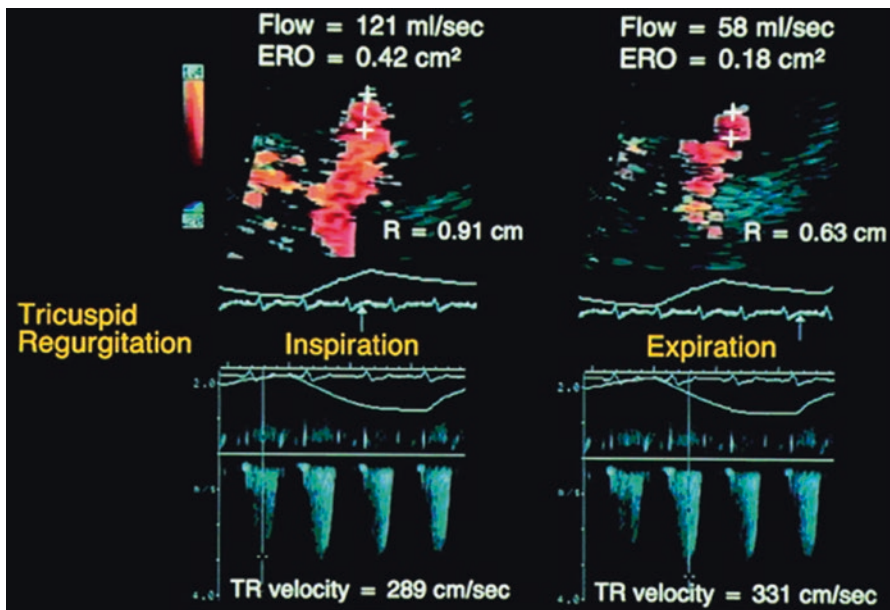


Fig. 5.16 Impact of inspiration and expiration on the measurements of TR flow using the flow convergence method (*top*) and peak velocity using continuous-wave Doppler (*V_{max}*; *bottom*) with calculation of ERO in inspiration (*left*) and expiration (*right*). Respirometer curves ascend with inspiration and descend with expiration. During inspiration, *V_{max}* decreases, regurgitant flow increases, and ERO increases considerably. Modified with permission from Topilsky et al. [32]

PISA Quantification on 3DE

It has been shown that the EROA as well as the regurgitation volume can be measured directly from 3DE [33]. The 3D method is quite simple, where a direct measurement of the flow convergence area is made possible on a 3D-TTE multiplanar reconstruction, thus no geometric assumption is made (Fig. 5.17). The method however, requires inclusion of the entire TR jet PISA in the 3D dataset and avoidance of rhythm or respiratory artifacts. Important caveats of the 3D PISA measurements are in general the low temporal and spatial resolution and the lack of wide availability.

TR Jet on Continuous-Wave Doppler

Assessment of the severity of the TR jet on continuous-wave Doppler should include shape of Doppler profile, density of the TR jet, peak TR jet velocity and peak TV inflow velocity. The rationale behind continuous-wave Doppler is that it records the velocities of all the blood cells moving along the path of the sound beam. Therefore,

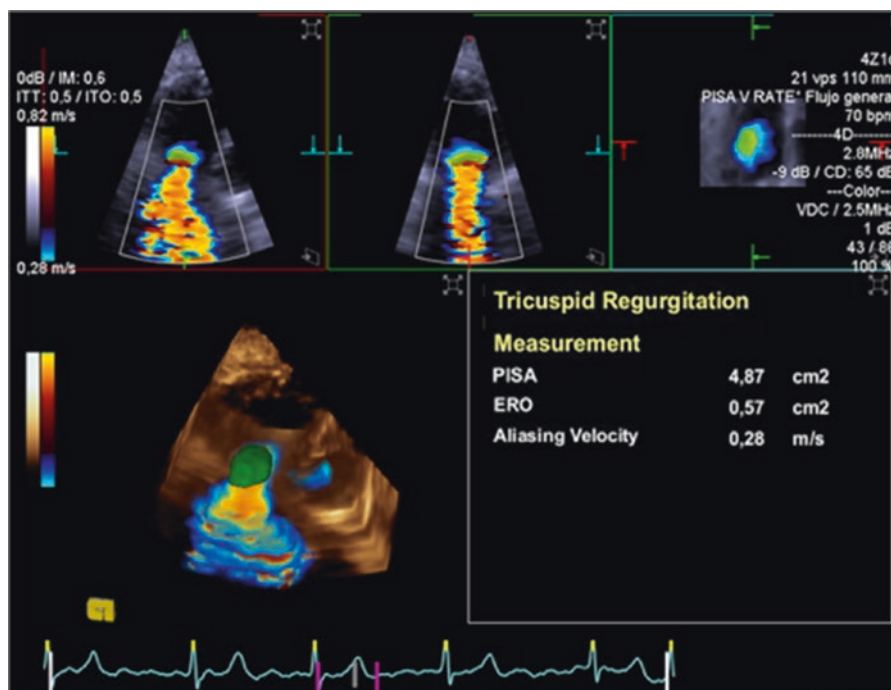


Fig. 5.17 A multiplanar reconstruction of 3D-TTE dataset obtained via a single beat acquisition. 3D PISA is automatically extracted and displayed as green overlay on a 3D colour Doppler image (top, the three reference planes: left, four-chamber view; center, two-chamber view; right, short-axis view). Bottom left: 3D rendered PISA in the volume-rendered image. ERO: Effective regurgitant orifice. Modified from de Agustin et al. with permission [33]

the Doppler envelope contains the full envelope spectrum; the outer boundary represents the fastest moving blood cells [34]. An important caveat is the ultrasound beam being parallel with the blood flow, this is often difficult to achieve, particularly for eccentric TR jets (Fig. 5.18).

Hepatic Vein Flow in Patients with TR

Assessment of the hepatic venous flow is an integral part of 2D-TTE assessment of TR severity. The normal flow pattern of the hepatic vein on a pulsed-wave Doppler recording consists of four phasic components. The forward systolic velocity (S) is larger than the diastolic (D) velocity. Two relatively small reversal waves are seen in late systole (V-wave) and late diastole (A-wave).

Patients with mild TR often have normal hepatic vein flow patterns. Patients with moderate TR often display a flow pattern that consists of a blunted S-wave, a large D-wave, and an S/D ratio < 1. Inspiration results in increased velocity of the S and D waveforms, however, the S/D ratio < 1 persists independently of the phase of respiration. Patients with severe TR often display a flow pattern that consists of a prominent systolic reversal (SR) wave that replaces the forward S-wave. The SR peaks in late systole and the only forward flow is seen in diastole (Fig. 5.19).

There are several caveats, which are important in the interpretation of hepatic vein flow patterns for grading TR severity. Hepatic flow is dependent on several

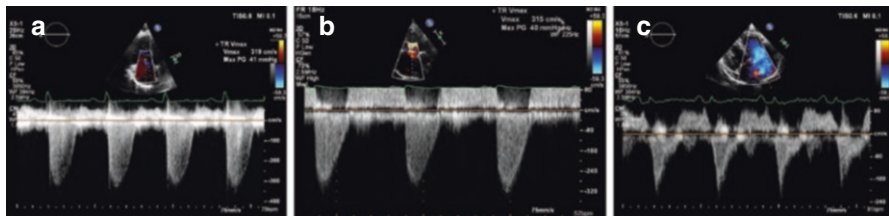


Fig. 5.18 Optimal visualization of TR jet on CW Doppler in a patient with mild (a), moderate (b) and severe (c) TR. Observe the shape of the TR jet envelope

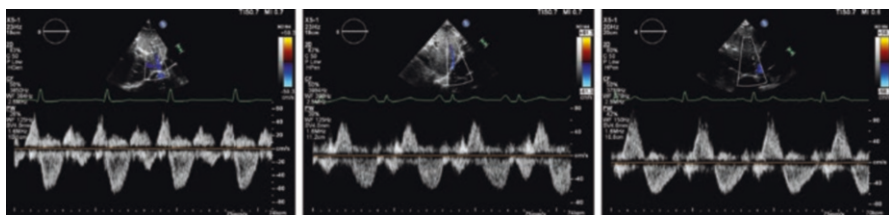


Fig. 5.19 Optimal visualization of typical hepatic venous flow in three patients with systolic predominance (left), systolic blunting (middle) and systolic flow reversal (right)

factors including hemodynamic loading, respiration, cardiac rhythm and RA and RV compliance [35]. Inspiration will increase both systolic and diastolic flow velocity, therefore the ratio will not be affected. Therefore, a blunted systolic flow would be present despite inspiratory increase in the flow velocities. A compliant right atrium would lessen the impact of severe TR leading to a blunted systolic flow instead of systolic reversal of flow (Table 5.10).

Other Surrogate Signs of TR Severity

There are several signs of severe TR on 2D-TTE such as a dilated inferior vena cava and hepatic veins (Fig. 5.20).

Hemodynamically significant TR is often associated with dilated right-sided chambers. The latter is either the cause or the result of significant TR. Therefore,

Table 5.10 Patterns and determinants of hepatic veins flow in patients with tricuspid regurgitation

	TR severity
S > D	None, mild or moderate
S < D	*Mild with confounders Moderate or severe
Systolic reversal	Severe *Mild or moderate with confounders
*Confounders of (S < D) or systolic reversal	Atrial fibrillation Impaired RV systolic function Acute RV infarction Acute RV dilatation Post cardiopulmonary bypass Restrictive cardiomyopathy Constrictive pericarditis

S systolic wave and D diastolic wave on hepatic veins flow on pulsed wave Doppler; RV right ventricular

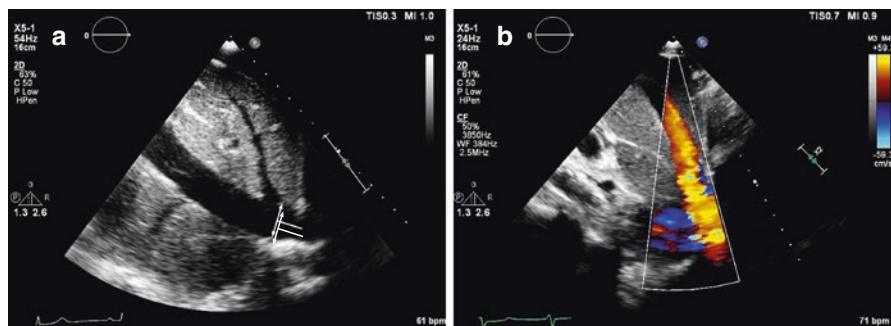


Fig. 5.20 Optimal visualization of inferior vena cava measurements in patients with suspected TR: a dilated IVC on 2D-TTE measurement according to guidelines [40] (a) and colour flow reversal in hepatic vein due to severe TR (b)

assessment of the RV and RA size and function and pulmonary artery pressure are essential components of the complete TR assessment. Visualization of interventricular septum is important to depict RV volume or pressure overload. When the position of the septum produces a D-shaped LV predominantly in diastole (RV volume overload pattern). On the other hand, when septal flattening is present throughout the cardiac cycle, it reflects the diastolic and systolic overload of the RV (RV pressure overload pattern) commonly seen in TR is due to pulmonary hypertension. Current guidelines recommend the use of TAPSE, FAC for RV systolic function. A TAPSE <1.6 cm and an RV FAC <35% are suggestive of RV dysfunction. TAPSE may yield both false-positive and -negative results. Impaired RV function in the presence of a morphologically normal TV is more likely the cause rather than the effect of TR [41]. Significant chronic TR also causes enlargement of the RA and inferior vena cava. Furthermore, a RA enlargement in patients with permanent atrial fibrillation and concomitant TV annular dilatation (>35 mm) may result in secondary TR. Advanced imaging using tissue Doppler and speckle tracking for RV deformation can also be attempted. However, volumetric assessment of the right heart chambers should preferably be based on a 3D modality such as 3D-TTE or magnetic resonance imaging due to the complex morphology of RV. On the other hand, estimated pulmonary artery pressure is commonly performed from the TR jet velocity profile based on the modified Bernoulli equation, *detailed assessment of RV and pulmonary artery hemodynamics are provided in Chap. 11 of this book.*

Assessment of TR Severity in Functional TR (Special Considerations)

Functional TR pathology can be categorized into one of three stages according to the severity of TR, in the presence or absence of annular dilatation and leaflet coaptation (Table 5.11).

Table 5.11 Dreyfus et al. classification of functional tricuspid regurgitation pathology [8]

	Stage 1	Stage 2	Stage 3
TR severity	None or mild	Mild or moderate	Severe
Annular diameter, mm	<40	>40	>40
Leaflet coaptation mode	Normal ^a	Edge-to-edge ^a	Absent ^b
Treatment	Pharmacological	Annuloplasty	Annuloplasty plus leaflet augmentation [‡]

TR tricuspid regurgitation. Modified with permission from Dreyfus et al. [8]. [‡]If leaflet tethering is present

^aNo leaflet tethering (<8 mm)

^bLeaflet tethering may be present (≥8 mm)

- The severity of TR is based on a multiparametric echocardiographic approach as explained above.

Annular dilatation

- Definition of significant annular dilatation is based on the 2D-TTE measurements of a TV annulus of >40 mm or >21 mm/m² in end-diastolic diameter on the apical 4-chamber view. Based on the current ACC/AHA guidelines, significant annular dilatation is the main imaging criterion to indicate severe TR [23].
- The assessment of TV leaflet coaptation is based on measurement of the surface of contact between the leaflets, which is defined as the coaptation height or coaptation length. Normal coaptation height is seen at the level of the annulus or just below it, and is considered normal if the coaptation length is of 5–10 mm. Therefore, leaflet tethering is considered present if the tenting distance is >8 mm and/or tenting area is >1.6 cm² [36] on 2D echocardiography.
- In stage 1, patients have no or mild TR without annular dilatation in the presence of a normal TV leaflets coaptation. Those patients do not often require surgical intervention. In stage 2, patients have mild or moderate TR in the setting of a dilated TV annulus and a limited so called edge-to-edge coaptation. TV annuloplasty could help to reduce TR. In the advanced stage 3, patients often have severe TR due to absent leaflets coaptation and dilated annulus. In the latter annuloplasty is not enough but leaflets augmentation is often required to treat TR.

TTE Assessment of the Tricuspid Valve Annulus

The TV annulus is nonplanar, saddle-shaped similar to mitral valve but more irregular, oval or elliptical. Tricuspid annular size varies during the cardiac cycle as it moves downwards during systole [1, 37, 38]. Because of the relatively fixed interventricular septum; atrial or ventricular dilatation causes annular dilatation, which occurs in the direction of the free wall of the right ventricle. The latter pulls on the leaflets and causes TR [39]. Furthermore; apical displacement causes leaflet tethering which causes more TR [31]. Tricuspid annular dilatation is an important indicator for surgery in the current American and European guidelines. Patients with even mild or moderate TR and a TV annulus ≥ 40 mm or 21 mm/m² who are undergoing left sided valve surgery should also undergo a TV repair [23, 24]. More notably, in the most recent ACC/AHA guidelines, the presence of pulmonary hypertension without TV annulus dilatation is an indication for TV repair in patients with functional mild or moderate TR undergoing left sided valve surgery [23] (Fig. 5.21).

Assessment of the TV annulus is an important step for complete understanding of the TV pathology as well as for preoperative planning. It provides as well prognostic information. Detailed assessment of the TV annulus is provided in Chap. 10 of this book.

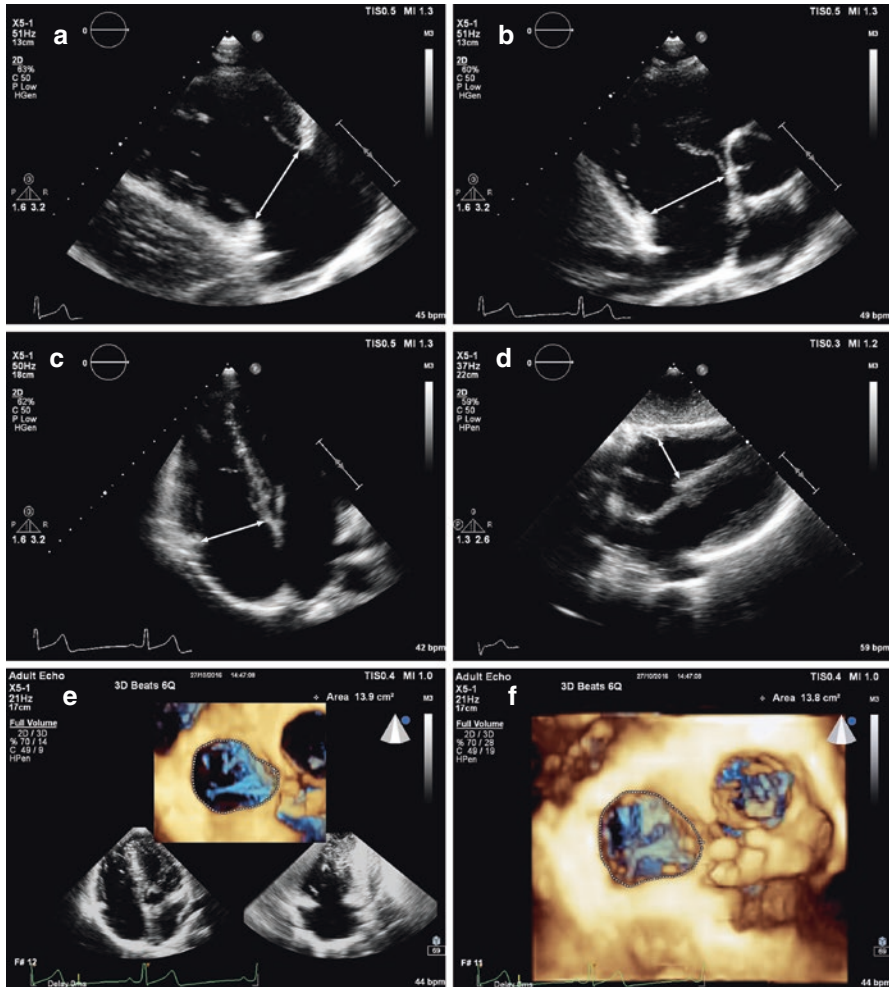


Fig. 5.21 Displays end-diastolic tricuspid annulus (TA) measurements on 2D-TTE in the RV inflow long-axis view (a), short-axis view at the aortic valve level (b), apical four-chamber (c) and subcostal long-axis view (d). Image (e) display a multiplane area and image (f) details direct area measurement on the 3D

Key Points

- TTE is more suitable than TEE in the assessment of the TV due to its position in the near field. However, the transgastric TEE view has an important role in guiding TV interventions.
- TR is a highly dynamic pathology in which TR severity is greatly affected by preload, afterload and RV contractility as well as respiration. Impact of loading

conditions, respiratory variation and right heart hemodynamics should be considered with serial evaluation of TR for targeted therapy such as percutaneous TV repair.

- Functional TR is the most common form of TR and its severity should not only be assessed via Doppler but rather via a comprehensive assessment of the entire TV apparatus.
- 3DE has several unique advantages over 2D-TTE in TV assessment including the enface view of the TV and accurate RV chamber quantification. Also 3DE colour Doppler measurements of the vena contracta.
- 3DE has several limitations related to the lower spatial and temporal resolution, which makes it difficult to assess thin structures such as valve leaflets. However, technological advances in transducer technologies could improve its capabilities in the near future.
- Multiplane iRotate echocardiography is a relatively new 2D echo modality that could be an essential tool in the assessment of TV in routine clinical practice.
- Quantification of the TV annulus should be based on a 3D technique or at least the iRotate mode; however the clinical utility of the latter is yet to be confirmed.
- Leaflets coaptation as well as annulus dimensions are important for therapeutic decision in patients with functional tricuspid regurgitation

Appendix (Fig. 5.22): Suggested algorithm for the integration of multiple parameters of TR severity

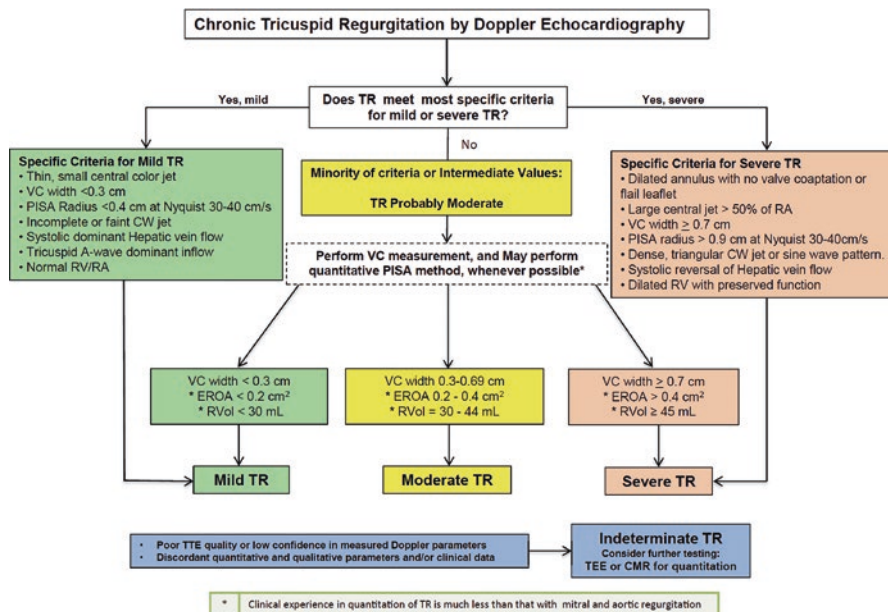


Fig. 5.22 Algorithm for the integration of multiple parameters of TR severity. Good-quality echocardiographic imaging and complete data acquisition are assumed. If imaging is technically difficult, consider TEE or CMR. TR severity may be indeterminate due to poor image quality, technical issues with data, internal inconsistency among echo findings, or discordance with clinical findings [40]

Review Questions

Select the Single Best Sentence

31. Which of the following statements about normal tricuspid anatomy is true?
- (a) papillary muscles are smaller and widely spaced than in the left ventricle
 - (b) tricuspid valve is less apical than mitral valve
 - (c) right ventricle has two papillary muscles, which are larger than in left ventricle
 - (d) posterior leaflet of the tricuspid valve is the largest of the three leaflets
 - (e) anterior and posterior leaflets are exactly the same size
32. Which of the following statements is correct about the TV leaflets in the apical 4-chamber view?
- (a) septal leaflet is often identified in 87% of cases
 - (b) septal leaflet is identified in all subjects except in patients with dilated right ventricle
 - (c) septal leaflet is identified in all subjects
 - (d) septal leaflet is identified in all subjects only in the focused apical 4-chamber view
 - (e) posterior leaflet is seen in all subjects in focused RV view
33. Which of the following statements is correct about TV leaflets on 2D-TTE in the parasternal right ventricular inflow view with LV cavity displayed?
- (a) anterior leaflet is always seen in the near field and the septal leaflet in the far field
 - (b) septal leaflet is identified in all subjects except in patients with dilated right ventricle
 - (c) septal leaflet is identified in all subjects in the near field
 - (d) posterior leaflet is identified in all subjects in the far field
 - (e) both anterior and posterior leaflets could be seen if transducer is posteriorly tilt to exclude the LV cavity
34. Which of the following statements about TV leaflets on 2D-TTE in the standard parasternal short-axis view are not correct (check all that apply)?
- (a) the leaflet to the next to aorta is the anterior leaflet in 50% of cases
 - (b) the leaflet next to aorta is the septal leaflet in 50% of cases
 - (c) the leaflet next to aorta is the septal leaflet in 100% of cases
 - (d) the leaflet next attached to RV free is the anterior leaflet in almost 100% of cases
 - (e) the leaflet next attached to RV free is the posterior leaflet in almost 100% of cases
35. Which of the following parameters/modalities is adequate for the assessment of tricuspid valve regurgitation severity grade?
- (a) Color Doppler of tricuspid regurgitation jet
 - (b) Continuous-wave Doppler of tricuspid regurgitation jet
 - (c) Pulsed-wave Doppler of tricuspid regurgitation jet

- (d) 2D-TEE of annulus enlargement and chamber dilatation
 - (e) All of the above must be combined together for a reliable assessment of TR severity
36. Which of the following statements are correct regarding frame rate?
- (a) 2D-TTE has a higher frame rate than M-mode
 - (b) The biplane simultaneous multiplane imaging has a similar frame rate to 2D-TTE
 - (c) The simultaneous multiplane imaging has a similar frame rate to the iRotate mode
 - (d) The biplane simultaneous multiplane imaging has a higher frame rate to 2D-TTE
 - (e) The iRotate mode has a similar frame rate to 2D-TTE
37. Doppler estimation of tricuspid valve cross-sectional area is based on the concept of:
- (a) conservation of energy theory
 - (b) conservation of mass theory
 - (c) flow augmentation theory
 - (d) Simpson's formula
 - (e) Cubic formula
38. Which of the following is not a sign of a hemodynamically significant tricuspid stenosis?
- (a) Mean pressure gradient of 5 or more mmHg
 - (b) Right ventricular inflow velocity time integral of 60 or more cm
 - (c) Right ventricular inflow pressure half time of 190 or more
 - (d) tricuspid valve area of less than 1 cm^2
 - (e) dilated right ventricular, and smaller right atrial volume
39. Which of the following is not a sign of a severe tricuspid regurgitation?
- (a) Right ventricular eccentricity index of 1.4
 - (b) TR jet color area more than 10 cm^2 or $>30\%$ of RA area
 - (c) TR jet vena contracta width more than 7 mm
 - (d) TR jet PISA radius of more than 9 mm
 - (e) TR effective regurgitant orifice area of 40 or more mm^2
40. Which of the following statements is false regarding tricuspid leaflets coaptation?
- (a) Normal coaptation height is seen at the level of the annulus or just below it.
 - (b) Is considered normal if the coaptation length of 5–10 mm.
 - (c) Leaflet tethering is considered present if the tenting distance $>8 \text{ mm}$.
 - (d) Leaflet tethering is considered present if the tenting area $> 1.6 \text{ cm}^2$.
 - (e) The coaptation height is often larger than coaptation length.
41. Regarding functional tricuspid regurgitation, which of the following statements is false?
- (a) Is the most common form of TR, which occur in almost 80% of all TR
 - (b) Annuloplasty is enough to treat patients with tricuspid annulus of more than 40 mm and absent leaflet coaptation

- (c) Some patients with mild TR could be surgically treated if tricuspid annulus is more than 40 mm
- (d) Patients with tricuspid annulus of more than 40 mm and edge-to-edge leaflet coaptation are treated with Annuloplasty
- (e) Patients with tricuspid annulus of more than 21 mm/m² and edge-to-edge leaflet coaptation are treated with Annuloplasty

References

1. Anwar AM, Geleijnse ML, Soliman OI, McGhie JS, Frowijn R, Nemes A, van den Bosch AE, Galema TW, Ten Cate FJ. Assessment of normal tricuspid valve anatomy in adults by real-time three-dimensional echocardiography. *Int J Cardiovasc Imaging*. 2007;23:717–24.
2. Lang RM, Badano LP, Tsang W, Adams DH, Agricola E, Buck T, Faletra FF, Franke A, Hung J, de Isla LP, Kamp O, Kasprzak JD, Lancellotti P, Marwick TH, McCulloch ML, Monaghan MJ, Nihoyannopoulos P, Pandian NG, Pellikka PA, Pepi M, Roberson DA, Shernan SK, Shirali GS, Sugeng L, Ten Cate FJ, Vannan MA, Zamorano JL, Zoghbi WA, American Society of Echocardiography, European Association of Echocardiography. EAE/ASE recommendations for image acquisition and display using three-dimensional echocardiography. *J Am Soc Echocardiogr*. 2012;25:3–46.
3. Anwar AM, Geleijnse ML, Ten Cate FJ, Meijboom FJ. Assessment of tricuspid valve annulus size, shape and function using real-time three-dimensional echocardiography. *Interact Cardiovasc Thorac Surg*. 2006;5:683–7.
4. Velayudhan DE, Brown TM, Nanda NC, Patel V, Miller AP, Mehmood F, Rajdev S, Fang L, Frans EE, Vengala S, Madadi P, Yelamanchili P, Baysan O. Quantification of tricuspid regurgitation by live three-dimensional transthoracic echocardiographic measurements of vena contracta area. *Echocardiography*. 2006;23:793–800.
5. Mutlak D, Carasso S, Lessick J, Aronson D, Reisner SA, Agmon Y. Excessive respiratory variation in tricuspid regurgitation systolic velocities in patients with severe tricuspid regurgitation. *Eur Heart J Cardiovasc Imaging*. 2013;14:957–62.
6. Agmon Y, Caspi O. Respiratory variation in tricuspid valve regurgitant orifice: a three-dimensional transthoracic echocardiographic perspective. *Eur Heart J Cardiovasc Imaging*. 2016;17(10):1188.
7. Dreyfus GD, Chan KM. Functional tricuspid regurgitation: a more complex entity than it appears. *Heart*. 2009;95:868–9.
8. Dreyfus GD, Martin RP, Chan KM, Dulguerov F, Alexandrescu C. Functional tricuspid regurgitation: a need to revise our understanding. *J Am Coll Cardiol*. 2015;65:2331–6.
9. Raja SG, Dreyfus GD. Basis for intervention on functional tricuspid regurgitation. *Semin Thorac Cardiovasc Surg*. 2010;22:79–83.
10. Dreyfus J, Durand-Viel G, Raffoul R, Alkhoder S, Hvass U, Radu C, Al-Attar N, Ghodbhane W, Attias D, Nataf P, Vahanian A, Messika-Zeitoun D. Comparison of 2-dimensional, 3-dimensional, and surgical measurements of the tricuspid annulus size: clinical implications. *Circ Cardiovasc Imaging*. 2015;8:e003241.
11. Anwar AM, Soliman OI, Nemes A, van Geuns RJ, Geleijnse ML, Ten Cate FJ. Value of assessment of tricuspid annulus: real-time three-dimensional echocardiography and magnetic resonance imaging. *Int J Cardiovasc Imaging*. 2007;23:701–5.
12. Anwar AM, Geleijnse ML, Soliman OI, McGhie JS, Nemes A, ten Cate FJ. Evaluation of rheumatic tricuspid valve stenosis by real-time three-dimensional echocardiography. *Heart*. 2007;93:363–4.
13. Faletra F, La Marchesina U, Bragato R, De Chiara F. Three dimensional transthoracic echocardiography images of tricuspid stenosis. *Heart*. 2005;91:499.
14. McGhie JS, Menting ME, Vletter WB, Frowijn R, Roos-Hesselink JW, Soliman OI, van der Zwaan HB, Geleijnse ML, van den Bosch AE. A novel 13-segment standardized model for

- assessment of right ventricular function using two-dimensional iRotate echocardiography. *Echocardiography*. 2016;33:353–61.
15. McGhie JS, Menting ME, Vletter WB, Frowijn R, Roos-Hesselink JW, van der Zwaan HB, Soliman OI, Geleijnse ML, van den Bosch AE. Quantitative assessment of the entire right ventricle from one acoustic window: an attractive approach. *Eur Heart J Cardiovasc Imaging*. 2016 Aug 7. pii: jew165. [Epub ahead of print].
 16. Addetia K, Yamat M, Mediratta A, Medvedofsky D, Patel M, Ferrara P, Mor-Avi V, Lang RM. Comprehensive two-dimensional interrogation of the tricuspid valve using knowledge derived from three-dimensional echocardiography. *J Am Soc Echocardiogr*. 2016;29:74–82.
 17. Singh JP, Evans JC, Levy D, Larson MG, Freed LA, Fuller DL, Lehman B, Benjamin EJ. Prevalence and clinical determinants of mitral, tricuspid, and aortic regurgitation (the Framingham Heart Study). *Am J Cardiol*. 1999;83:897–902.
 18. Boyaci A, Gokce V, Topaloglu S, Korkmaz S, Goksel S. Outcome of significant functional tricuspid regurgitation late after mitral valve replacement for predominant rheumatic mitral stenosis. *Angiology*. 2007;58:336–42.
 19. Porter A, Shapira Y, Wurzel M, Sulkes J, Vaturi M, Adler Y, Sahar G, Sagie A. Tricuspid regurgitation late after mitral valve replacement: clinical and echocardiographic evaluation. *J Heart Valve Dis*. 1999;8:57–62.
 20. Izumi C, Iga K, Konishi T. Progression of isolated tricuspid regurgitation late after mitral valve surgery for rheumatic mitral valve disease. *J Heart Valve Dis*. 2002;11:353–6.
 21. Bruce CJ, Connolly HM. Right-sided valve disease deserves a little more respect. *Circulation*. 2009;119:2726–34.
 22. Nath J, Foster E, Heidenreich PA. Impact of tricuspid regurgitation on long-term survival. *J Am Coll Cardiol*. 2004;43:405–9.
 23. Nishimura RA, Otto CM, Bonow RO, Carabello BA, Erwin JP 3rd, Guyton RA, O'Gara PT, Ruiz CE, Skubas NJ, Sorajja P, Sundt TM 3rd, Thomas JD, American College of Cardiology/American Heart Association Task Force on Practice G. 2014 AHA/ACC guideline for the management of patients with valvular heart disease: executive summary: a report of the American College of Cardiology/American Heart Association Task Force on Practice Guidelines. *J Am Coll Cardiol*. 2014;63:2438–88.
 24. Joint Task Force on the Management of Valvular Heart Disease of the European Society of C, European Association for Cardio-Thoracic S, Vahanian A, Alfieri O, Andreotti F, Antunes MJ, Baron-Esquivias G, Baumgartner H, Borger MA, Carrel TP, De Bonis M, Evangelista A, Falk V, Jung B, Lancellotti P, Pierard L, Price S, Schafers HJ, Schuler G, Stepinska J, Swedberg K, Takkenberg J, Von Oppell UO, Windecker S, Zamorano JL, Zembala M. Guidelines on the management of valvular heart disease (version 2012). *Eur Heart J*. 2012;33:2451–96.
 25. Tribouilloy CM, Enriquez-Sarano M, Bailey KR, Tajik AJ, Seward JB. Quantification of tricuspid regurgitation by measuring the width of the vena contracta with Doppler color flow imaging: a clinical study. *J Am Coll Cardiol*. 2000;36:472–8.
 26. Zoghbi WA, Enriquez-Sarano M, Foster E, Grayburn PA, Kraft CD, Levine RA, Nihoyannopoulos P, Otto CM, Quinones MA, Rakowski H, Stewart WJ, Waggoner A, Weissman NJ, American Society of E. Recommendations for evaluation of the severity of native valvular regurgitation with two-dimensional and Doppler echocardiography. *J Am Soc Echocardiogr*. 2003;16:777–802.
 27. Chen TE, Kwon SH, Enriquez-Sarano M, Wong BF, Mankad SV. Three-dimensional color Doppler echocardiographic quantification of tricuspid regurgitation orifice area: comparison with conventional two-dimensional measures. *J Am Soc Echocardiogr*. 2013;26:1143–52.
 28. Rodriguez L, Thomas JD, Monterroso V, Weyman AE, Harrigan P, Mueller LN, Levine RA. Validation of the proximal flow convergence method. Calculation of orifice area in patients with mitral stenosis. *Circulation*. 1993;88:1157–65.
 29. Rodriguez L, Anconina J, Flachskampf FA, Weyman AE, Levine RA, Thomas JD. Impact of finite orifice size on proximal flow convergence. Implications for Doppler quantification of valvular regurgitation. *Circ Res*. 1992;70:923–30.

30. Sugeng L, Weinert L, Lang RM. Real-time 3-dimensional color Doppler flow of mitral and tricuspid regurgitation: feasibility and initial quantitative comparison with 2-dimensional methods. *J Am Soc Echocardiogr.* 2007;20:1050–7.
31. Mascherbauer J, Maurer G. The forgotten valve: lessons to be learned in tricuspid regurgitation. *Eur Heart J.* 2010;31:2841–3.
32. Topilsky Y, Tribouilloy C, Michelena HI, Pislaru S, Mahoney DW, Enriquez-Sarano M. Pathophysiology of tricuspid regurgitation: quantitative Doppler echocardiographic assessment of respiratory dependence. *Circulation.* 2010;122:1505–13.
33. de Agustín JA, Viliani D, Vieira C, Islas F, Marcos-Alberca P, Gomez de Diego JJ, Nunez-Gil JJ, Almeria C, Rodrigo JL, Luaces M, Garcia-Fernandez MA, Macaya C, Perez de Isla L. Proximal isovelocity surface area by single-beat three-dimensional color Doppler echocardiography applied for tricuspid regurgitation quantification. *J Am Soc Echocardiogr.* 2013;26:1063–72.
34. Quinones MA, Otto CM, Stoddard M, Waggoner A, Zoghbi WA, Doppler Quantification Task Force of the N, Standards Committee of the American Society of E. Recommendations for quantification of Doppler echocardiography: a report from the Doppler Quantification Task Force of the Nomenclature and Standards Committee of the American Society of Echocardiography. *J Am Soc Echocardiogr.* 2002;15:167–84.
35. Fadel BM, Almulla K, Husain A, Dahdouh Z, Di Salvo G, Mohty D. Spectral Doppler of the hepatic veins in tricuspid valve disease. *Echocardiography.* 2015;32:856–9.
36. Kim HK, Kim YJ, Park JS, Kim KH, Kim KB, Ahn H, Sohn DW, Oh BH, Park YB, Choi YS. Determinants of the severity of functional tricuspid regurgitation. *Am J Cardiol.* 2006;98:236–42.
37. Fawzy H, Fukamachi K, Mazer CD, Harrington A, Latter D, Bonneau D, Errett L. Complete mapping of the tricuspid valve apparatus using three-dimensional sonomicrometry. *J Thorac Cardiovasc Surg.* 2011;141:1037–43.
38. Maffessanti F, Gripari P, Pontone G, Andreini D, Bertella E, Mushtaq S, Tamborini G, Fusini L, Pepi M, Caiani EG. Three-dimensional dynamic assessment of tricuspid and mitral annuli using cardiovascular magnetic resonance. *Eur Heart J Cardiovasc Imaging.* 2013;14:986–95.
39. Ton-Nu TT, Levine RA, Handschumacher MD, Dorer DJ, Yosefy C, Fan D, Hua L, Jiang L, Hung J. Geometric determinants of functional tricuspid regurgitation: insights from 3-dimensional echocardiography. *Circulation.* 2006;114:143–9.
40. Zoghbi WA, Adams D, Bonow RO, Enriquez-Sarano M, Foster E, Grayburn PA, Hahn RT, Han Y, Hung J, Lang RM, Little SH, Shah DJ, Shernan S, Thavendiranathan P, Thomas JD, Weissman NJ. Recommendations for Noninvasive Evaluation of Native Valvular Regurgitation. *J Am Soc Echocardiogr.* 2017;30(4):303–71.
41. Lawrence G, Rudski, Wyman W, Lai, Jonathan Afilalo, Lanqi Hua, Mark D. Handschumacher, Krishnaswamy Chandrasekaran, Scott D. Solomon, Eric K. Louie, Nelson B. Schiller, (2010) Guidelines for the Echocardiographic Assessment of the Right Heart in Adults: A Report from the American Society of Echocardiography. *J Am Soc Echocardiogr.* 23(7):685–713

Chapter 6

Imaging of the Tricuspid Valve: Transoesophageal Echocardiography

Rebecca T. Hahn

Abstract The presence of functional TR, either isolated or in combination with left heart disease is associated with unfavorable natural history. In addition, mortality for isolated tricuspid valve interventions remain higher than for any other single valve surgery. Finally, as more left sided valve disease is treated with transcatheter therapies the need for transcatheter solutions to functional tricuspid regurgitation. Transesophageal echocardiographic (TOE) imaging of the tricuspid valve has become an important intra-procedural tool for assessing the morphology of the valve apparatus and severity of disease, guiding transcatheter solutions and assessing the results of interventions. The following chapter reviews the tricuspid valve anatomy and essential TOE views to define this anatomy and valvular function.

Keywords Transoesophageal echocardiography • Tricuspid valve • Tricuspid regurgitation

Introduction

The most recent American Society of Echocardiography (ASE) guideline for performing a comprehensive TOE examination [1] includes addition imaging, many of which were intended to improve imaging of the tricuspid valve. A comprehensive TOE examination of the tricuspid valve should include imaging from several depths and multiplane angles. Additional views specific to imaging the tricuspid valve which are not included in the guidelines will be discussed below [2]. Multiple

R.T. Hahn, M.D.
Columbia University Medical Center, New York-Presbyterian Hospital,
177 Fort Washington Avenue, New York, NY 10032, USA
e-mail: rth2@cumc.columbia.edu

guidelines [1, 3] also describe the technique of 3D imaging of the tricuspid valve. Standardization of the image acquisition and display is particularly important when imaging is performed for transcatheter devices, improving communication with the interventionalist. This technology has significantly improved the accuracy of imaging and identification of the tricuspid leaflets and associated anatomic components of the tricuspid valve complex and has already been shown to be integral to tricuspid valve interventions [4].

TOE Imaging for Tricuspid Valve Imaging

Given the position of the heart in relation to the esophagus and stomach, there are four levels which may bring the probe closest to the tricuspid valve for both 2D and 3D imaging: mid-esophageal (ME), low esophageal or gastro-esophageal (LE) junction, shallow transgastric (TG) as well as deep transgastric (DTG) views (Fig. 6.1). A few important anatomic clues to the location of the leaflets can be used. First, the septal leaflet is the shortest in the radial direction and the least mobile due to direct chordal attachment to the septum. The tricuspid leaflet associated with the interventricular or interatrial septae is the septal leaflet. The commissure between the septal and anterior leaflet is typically adjacent to the most posterior border of the aortic noncoronary sinus of Valsalva. A portion of the anterior leaflet is also adjacent to the aorta (noncoronary and right coronary sinuses of Valsalva) but extends further anterior and lateral over the associated walls of the right ventricle, and under the right atrial appendage. The posterior leaflet which is often scalloped and may not be clearly distinguishable from the anterior leaflet, extends from the lateral to posterior walls of the right ventricle. The commissure between the septal and posterior leaflet is typically near the inflow of the coronary sinus. It is important at each

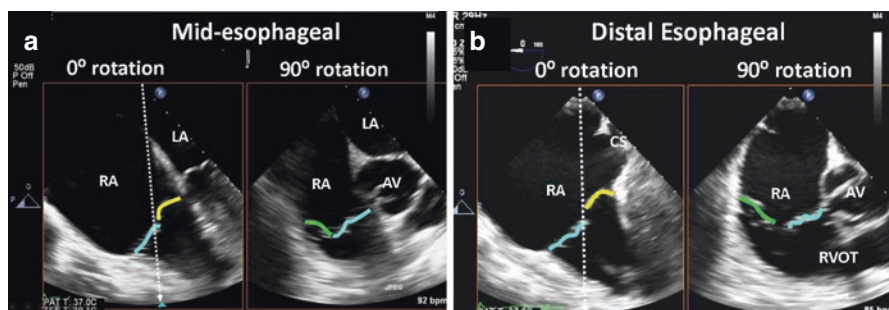


Fig. 6.1 Esophageal views of the tricuspid valve. Panel (a) is a simultaneous multiplane image from the mid-esophageal (ME) level. The 4-chamber view is seen in the 0 degree plane with septal (yellow line) and typically the anterior leaflet (blue line) is seen. The orthogonal plane with the aortic valve (AV) in view, the anterior leaflet and posterior leaflet (green line) are seen. Panel (b) is a simultaneous multiplane image from the lowesophageal level with no left atrium (LA) but the coronary sinus (CS) in view

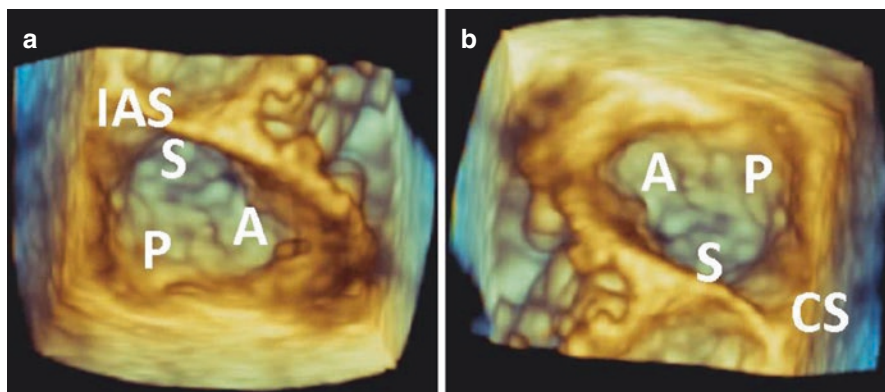


Fig. 6.2 Three-dimensional imaging of the tricuspid valve. From the distal esophageal views, a user-defined volume is obtained, and rotated to image the valve from the atrial side (panel **a**). The surgical view is then obtain by rotating this view with the interatrial septum (*IAS*) in the far field (panel **b**), which places the anterior leaflet (*A*) in the near field and to the left, with the posterior leaflet (*P*) in the near field and to the right. The coronary sinus (*CS*) is then at the 7-o'clock position

level to rotate through multiple planes to comprehensively evaluate the tricuspid valve and to use the simultaneous multiplane modality to help with identifying leaflets and appreciating adjacent anatomy.

Mid-esophageal level: From the ME four-chamber view, rotating the probe clockwise to center the tricuspid valve in the imaging plane, permits visualization of the septal leaflet (arising from the septum) and typically the anterior leaflet (adjacent to the right atrial appendage); simultaneous biplane imaging may help clarify which leaflet is imaged since the anterior leaflet is typically seen adjacent to the aorta (Fig. 6.1a). Because the lower right heart border is close to the diaphragm, slow insertion brings the TOE probe to the distal esophagus, brings the probe closer to the tricuspid annulus; frequently there is no left atrium seen, and only the right atrium and coronary sinus with the orthogonal view imaging the right ventricular outflow tract (Fig. 6.1b). This view may also align the Doppler beam with the regurgitant jet and allow a comprehensive evaluation of tricuspid valve function, including an assessment of tricuspid regurgitation severity. Acquiring 3D volumes of the tricuspid valve from this view, may allow live-3D imaging of the surgical view (Fig. 6.2).

Transgastric level: Advancing the TEE probe into the stomach results in the transgastric views. Using a right flexion and rotating the probe to center the tricuspid valve in the imaging plane, results in the inflow-outflow view of the right heart (Fig. 6.3a). The orthogonal view shows all three tricuspid valve leaflets which can also be imaged using a single plane view between 60 and 90 degrees (Fig. 6.3b). This view may be particularly useful intra-procedurally to identify the leaflets and commissures. And using this view as the primary image, a sweep of the entire tricuspid valve orifice could be imaged using simultaneous multiplane imaging. Advancing the TOE probe further into the stomach along with rightward anterior

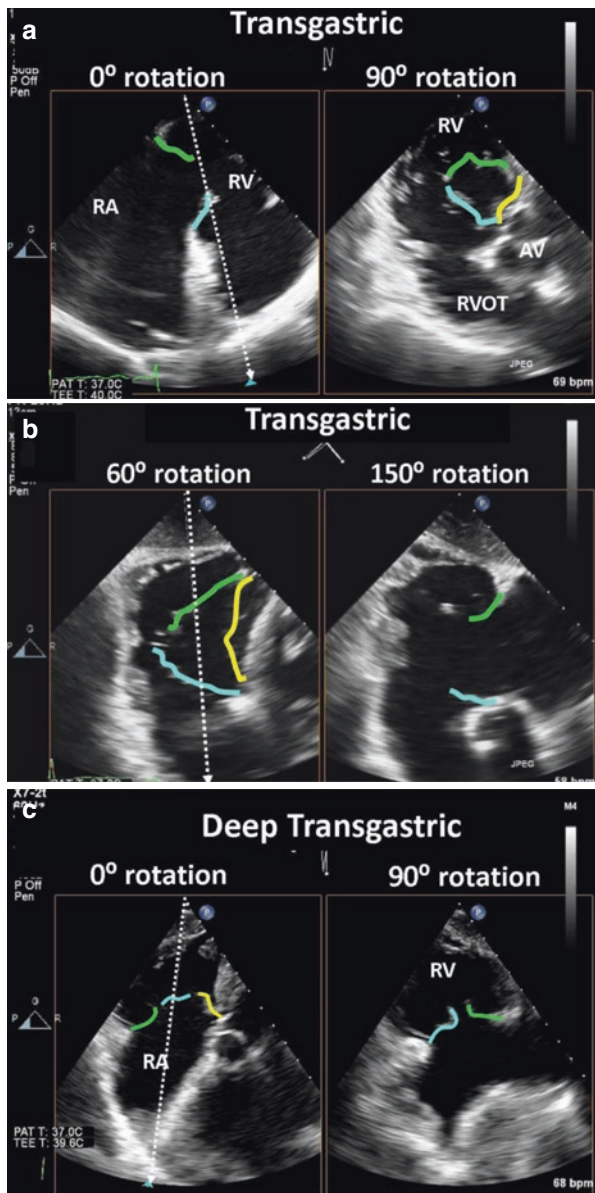


Fig. 6.3 Simultaneous biplane imaging from transgastric views with right and antelexion, the inflow-outflow view of the right heart (panel a) images the anterior (blue line) and posterior leaflet (green line) at 0 degrees. The orthogonal view shows all three tricuspid valve leaflets. This short-axis view of the tricuspid valve can also be imaged between 60 and 90 degrees (panel b) with the simultaneous multiplane imaging plane used to image all three leaflet tips. Deep transgastric views of the tricuspid valve (panel c), may align the insonation beam with the flow across the tricuspid valve for Doppler assessment

flexion produces a deep transgastric view of the tricuspid valve (Fig. 6.3c), which may also align the insonation beam with the flow across the tricuspid valve, and should be used to assess tricuspid valve function.

Three-dimensional (3D) Echocardiography: 3D echocardiography has significantly improved the accuracy of imaging and identification of the tricuspid leaflets and associated anatomic components of the tricuspid valve complex and obviates the need for mental reconstruction of multiple 2D planes [5]. Lang et al. [6] has suggested standardized imaging display (Fig. 6.2) for the en face view of the tricuspid valve with the interatrial septum placed inferiorly (at the 6 o'clock position) regardless of the atrial or ventricular orientation. The current 3D systems have different resolution for each of the 3 dimensions with axial resolution (~0.5 mm) better than lateral (~2.5 mm) and elevational resolution (~3 mm) [5]. Similar to 2D imaging however, images in the far field may be subject to beam widening and attenuation. When creating 3D images, keeping these current equipment limitations in mind will help determine the best imaging plane for imaging a specific abnormality. The best imaging plane for the tricuspid valve leaflets in systole (closed leaflets) may be the esophageal views since the closed leaflets are perpendicular to the insonation beam, however the diastolic (open) leaflets may be poorly imaged. Conversely, transgastric views may allow imaging of the diastolic leaflets since they will be perpendicular to the insonation beam, but leaflet definition may not be optimal in systole. Obtaining multiple 3D volumes from different views may still be necessary to fully characterize the valve and annulus. Finally, because of the complex nature of the valve, the volume acquired may need to have adjacent structures to help identify leaflet anatomy; the aortic valve/aorta to identify the anterior leaflet, and the interatrial septum/mitral valve to identify the septal leaflet.

Grading Severity of Tricuspid Regurgitation

Grading of the severity of the tricuspid regurgitation (TR) has been well-described by the ASE guidelines [7] as well as the European Association of Echocardiography guidelines and focuses on assessment by transthoracic imaging [8]. Nonetheless, TOE imaging can be used to assess many of the parameters, although validation of cut-offs is lacking. Table 6.1 summarizes the parameters most commonly used for this assessment. Importantly, many of the studies validating the use of these parameters have significant limitations with a lack of a “gold standard” for comparison or support from outcomes data. It is thus essential to use a multi-parametric method for determining severity since no single parameter has adequate specificity. Future studies are needed to determine the validity and prognostic utility of these parameters.

A recent study evaluated the utility of an algorithm for assessing the severity of TR [9]. Severe TR was present in the presence of a suggestive color Doppler jet and if any one or more of the following combinations of criteria were present: (1) IVC diameter > 2.5 cm AND RA area > 18 cm² (in the absence of ASD or pulmonic valvular disease); (2) jet area > 10 cm² AND vena contracta width > 7 mm; (3)

Table 6.1 Grading the severity of chronic TR by echocardiography

Parameters	Mild	Moderate	Severe
Structural	Bolded signs are considered specific for their TR grade.		
TV morphology	Normal or mildly abnormal leaflets	Moderately abnormal leaflets	Severe valve lesions (e.g., flail leaflet, severe retraction, large perforation)
RV and RA size	Usually normal	Normal or mild dilation	Usually dilated ^a
Inferior vena cava diameter	Normal <2 cm	Normal or mildly dilated 2.1–2.5 cm	Dilated >2.5 cm
Qualitative Doppler	Bolded signs are considered specific for their TR grade.		
Color flow jet area ^b	Small, narrow, central	Moderate central	Large central jet or eccentric wall-impinging jet of variable size
Flow convergence zone	Not visible, transient or small	Intermediate in size and duration	Large throughout systole
CWD jet	Faint/partial/parabolic	Dense, parabolic or triangular	Dense, often triangular
Semi quantitative	Bolded signs are considered specific for their TR grade.		
Color flow jet area (cm ²) ^b	Not defined	Not defined	>10
VCW (cm) ^b	<0.3	0.3–0.69	≥0.7
PISA radius (cm) ^c	≤0.5	0.6–0.9	>0.9
Hepatic vein flow ^d	Systolic dominance	Systolic blunting	Systolic flow reversal
Tricuspid inflow ^d	A-wave dominant	Variable	E-wave>1.0 m/s
<i>Quantitative</i>			
EROA (cm ²)	<0.20	0.20–0.39 ^e	≥0.40
RVol (mL/beat)	<30	30–44 ^e	≥45

^aRV and RA size can be within the “normal” range in patients with acute severe TR

^bWith Nyquist limit >50–70 cm/sec

^cWith baseline Nyquist limit shift of 28 cm/sec

^dSigns are nonspecific and are influenced by many other factors (RV diastolic function, atrial fibrillation, RA pressure)

^eThere are little data to support further separation of these values

systolic flow reversal in the hepatic veins in the absence of AV dissociation, ventricular pacing, or atrial arrhythmia; (4) triangular continuous wave Doppler signal with density equal to or greater than that of tricuspid inflow. These parameters correlated best with expert-reads and magnetic resonance imaging determined regurgitant volume and fraction (using $>48\%$ to define severe) and improved inter-observer agreement. The jet area:RA area ratio (in %) is not included in current guidelines, but was previously validated by both thermodilution techniques [10] and open surgical techniques [11].

Quantitation of the severity TR can be performed by a number of methods but also lack validation against imaging modalities such as cardiac magnetic resonance imaging. Although the proximal isovelocity surface area (PISA) method is simple and easy to perform [12], the shape of the tricuspid regurgitant orifice is often elliptical [13] or stellate which may result in significant underestimation of the ROA by this method. More recently, 3D PISA has been used to quantify TR [14]. This method uses a vendor-specific software package to analyze the largest convergence zone, and a specific software which measures the 3D PISA. Regurgitant orifice area is then calculated as $3D\ PISA \times V_{aliasing}/peak\ TR\ velocity$ where $V_{aliasing}$ is the aliasing velocity. In this study, 3D PISA-derived ROA correlated well with 3D planimetered vena contracta ($r = 0.97$).

Few studies have used quantitation of TR by relative stroke volumes [12, 15, 16]. In these studies, a single plane tricuspid annular diameter was measured from the 4-chamber view and the tricuspid annular area calculated using a circular formula to calculate the tricuspid annular area. The sample volume for measuring the velocity-time-integral was placed at the tips of the leaflets, unlike the recommended position of the sample volume for mitral quantitation, which is at the level of annulus. Despite these limitations, there was a high correlation with catheterization-derived data. This method has not been validated in patients with pathologic tricuspid regurgitation which may be associated with asymmetric dilatation of the annulus. The Early Feasibility of the Mitralign Percutaneous Tricuspid Valve Annuloplasty System (PTVAS) (SCOUT) trial (ClinicalTrials.gov Identifier: NCT02574650) using the Trialign system (Mitralign Inc., Tewksbury, Massachusetts) has recently been reported. (Hahn RT, Meduri CU, Davidson CJ, Lim S, Nazif TM, Ricciardi MJ, Rajagopal V, Ailawadi G, Vannan MA, Thomas JD, Fowler D, Rich S, Martin R, Ong G, Groothuis A, Kodali S. Early Feasibility Study of a Transcatheter Tricuspid Valve Annuloplasty: SCOUT Trial 30-Day Results. *J Am Coll Cardiol.* 2017 Apr 11;69(14):1795-1806). Tricuspid regurgitation was assessed using multiple quantitative methods including PISA and relative stroke volumes. For the later, forward stroke volume was measured using with the LVOT or RVOT forward flow. Diastolic stroke volume across the tricuspid valve was calculated using orthogonal plane annular diameters in early diastole (one frame after initial valve opening) in an ellipse formula to calculate annular area, and then multiplying this by the pulsed wave Doppler velocity time integral with sample volume at the tricuspid annular plane. PISA underestimated the EROA by relative stroke volume by $>50\%$. Importantly, a reduction in tricuspid EROA (by either method) following the transcatheter annuloplasty was associated with an increase in left ventricular outflow tract stroke volume, and significant improvement in functional status.

The quantitative EROA inclusion criteria for the patients in the SCOUT trial was $\leq 1.2\ cm^2$. This is 3 times the criteria for severe. To better characterize the severity

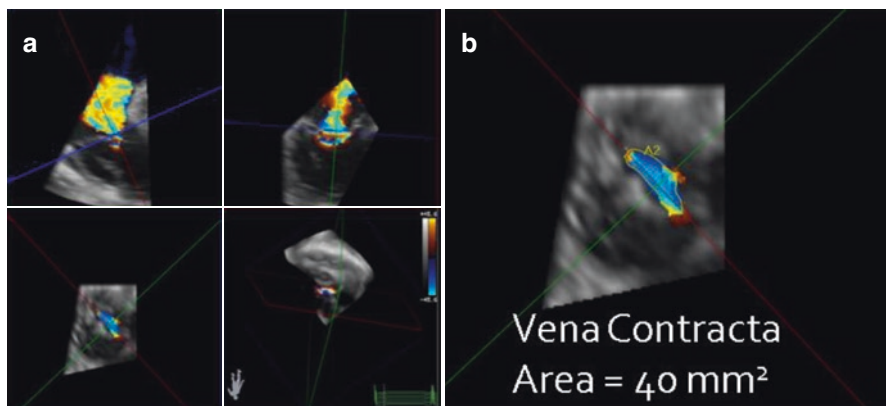


Fig. 6.4 Multi-planar reconstruction of a 3D color Doppler volume. Panel **a** shows the multiplanar reconstruction of a 3D color Doppler volume, where the *green* and *red* planes are used to align the *blue* plane in the vena contracta of the jet. The vena contracta area is then planimetered in the *blue* plane (panel **b**)

of regurgitation in this population of symptomatic patients, a new grading scheme has been proposed, including grades of massive and torrential. (Hahn RT and Zamorano, J, EurHtJ, in press).

Three-dimensional methods may help improve the accuracy of quantitative Doppler methods. Using either 3D planimetered diastolic annular area, or two orthogonal diastolic annular diameters and a pulsed sample volume at the annulus to measure the velocity time integral, a diastolic stroke volume can be measured. Subtracting the forward stroke volume (either from the left ventricular outflow tract or right ventricular outflow tract) results in the regurgitant volume. These methods require validation.

A number of studies have shown the utility of 3D color Doppler to quantify tricuspid regurgitation (Fig. 6.4) [13, 14, 17, 18]. Velayudhan et al. was one of the first to correlate standard Doppler methods of quantifying TR with planimetry of the 3D vena contracta area (VCA). Using the validated measure of regurgitant jet area/right atrial area > 34% [11] and regurgitant jet area > 10 cm² to define severe TR [19], a 3D TTE planimetered VCA of >0.75 cm² was the most sensitive cutoff (Sens. 85.2%, Spec. 82.1%). This higher cutoff has also been shown by Chen et al., with severe TR by 2D criteria associated with a 3D VCA of >0.6 ± 0.4 cm² and non-severe TR by 2D methods with a 3D VCA of ≤0.3 ± 0.1 cm². However, receiver-operator curve demonstrated that a 3D VCA of 0.36 cm² was the best cutoff value for severe TR, with sensitivity of 89% and specificity of 84% in predicting severe TR defined by 2D echocardiographic integrative criteria.

Key Points

- Comprehensive tricuspid valve imaging on TOE involves the use of multiple probe levels as well as multi-plane and multi-angle views.
- Use of three-dimensional imaging of the tricuspid valve can be optimized to assess leaflets and annulus.

- Assessment of tricuspid valve regurgitation should use a multi-parametric method which includes 2D and 3D measurements, as well as Doppler semi-quantitative and quantitative measurements, although the latter requires further study.

Review Questions

Select the Single Best Sentence

42. Which leaflet is seen adjacent to the aortic valve?
- (a) Septal leaflet
 - (b) Anterior leaflet
 - (c) Posterior leaflet
 - (d) Anterior or posterior leaflets
 - (e) Posterior or septal leaflets
43. Which of the following probe locations and angles allows imaging of all three tricuspid leaflets in a single view?
- (a) Mid-esophageal view, 0 degrees.
 - (b) Distal esophageal view, 90 degrees.
 - (c) Transgastric view, 0 degrees.
 - (d) Transgastric view, 60 degrees.
 - (e) Deep transgastric view, 60 degrees.
44. Which of the following statements is most accurate regarding the assessment of tricuspid regurgitation severity?
- (a) Well-validated criteria have been established to assess the severity of tricuspid regurgitation.
 - (b) Color Doppler parameters alone can be reliably used to assess severity.
 - (c) Quantitative Doppler methods have been validated against cardiac magnetic resonance imaging and are the recommended method of assessing severity.
 - (d) A multi-parametric method should be used to assess tricuspid regurgitation severity since no single measurement has adequate sensitivity and specificity.
 - (e) Three-dimensional planimetry of the vena contracta has been validated against outcomes data.

References

1. Hahn RT, Abraham T, Adams MS, et al. Guidelines for performing a comprehensive trans-esophageal echocardiographic examination: recommendations from the American society of echocardiography and the society of cardiovascular anesthesiologists. *J Am Soc Echocardiogr.* 2013;26:921–64.

2. Hahn RT. State-of-the-Art Review of Echocardiographic Imaging in the Evaluation and Treatment of Functional Tricuspid Regurgitation. *Circ Cardiovasc Imaging*. 2016;9(12). pii: e005332.
3. Lang RM, Badano LP, Tsang W, et al. EAE/ASE recommendations for image acquisition and display using three-dimensional echocardiography. *Eur Heart J Cardiovasc Imaging*. 2012;13:1–46.
4. Schofer J, Bijklic K, Tiburtius C, Hansen L, Groothuis A, Hahn RT. First-in-Human transcatheter tricuspid valve repair in a patient with severely regurgitant tricuspid valve. *J Am Coll Cardiol*. 2015;65(12):1190–5.
5. Badano LP, Agricola E, de Isla LP, Gianfagna P, Zamorano JL. Evaluation of the tricuspid valve morphology and function by transthoracic real-time three-dimensional echocardiography. *Eur J Echocardiogr*. 2009;10:477–84.
6. Lang RM, Badano LP, Tsang W, et al. EAE/ASE recommendations for image acquisition and display using three-dimensional echocardiography. *J Am Soc Echocardiogr*. 2012;25:3–46.
7. Zoghbi WA, Adams D, Bonow RO, Enriquez-Sarano M, Foster E, Grayburn PA, Hahn RT, Han Y, Hung J, Lang RM, Little SH, Shah DJ, Sherman S, Thavendiranathan P, Thomas JD, Weissman NJ. Recommendations for Noninvasive Evaluation of Native Valvular Regurgitation: A Report from the American Society of Echocardiography Developed in Collaboration with the Society for Cardiovascular Magnetic Resonance. *J Am Soc Echocardiogr*. 2017;30(4):303–71.
8. Lancellotti P, Moura L, Pierard LA, et al. European Association of Echocardiography recommendations for the assessment of valvular regurgitation. Part 2: mitral and tricuspid regurgitation (native valve disease). *Eur J Echocardiogr*. 2010;11:307–32.
9. Grant AD, Thavendiranathan P, Rodriguez LL, Kwon D, Marwick TH. Development of a consensus algorithm to improve interobserver agreement and accuracy in the determination of tricuspid regurgitation severity. *J Am Soc Echocardiogr*. 2014;27:277–84.
10. Mugge A, Daniel WG, Herrmann G, Simon R, Lichtlen PR. Quantification of tricuspid regurgitation by Doppler color flow mapping after cardiac transplantation. *Am J Cardiol*. 1990;66:884–7.
11. Chopra HK, Nanda NC, Fan P, et al. Can two-dimensional echocardiography and Doppler color flow mapping identify the need for tricuspid valve repair? *J Am Coll Cardiol*. 1989;14:1266–74.
12. Rivera JM, Mele D, Vandervoort PM, Morris E, Weyman AE, Thomas JD. Effective regurgitant orifice area in tricuspid regurgitation: clinical implementation and follow-up study. *Am Heart J*. 1994;128:927–33.
13. Sugeng L, Weinert L, Lang RM. Real-time 3-dimensional color Doppler flow of mitral and tricuspid regurgitation: feasibility and initial quantitative comparison with 2-dimensional methods. *J Am Soc Echocardiogr*. 2007;20:1050–7.
14. de Agustin JA, Viliani D, Vieira C, et al. Proximal isovelocity surface area by single-beat three-dimensional color Doppler echocardiography applied for tricuspid regurgitation quantification. *J Am Soc Echocardiogr*. 2013;26:1063–72.
15. Loeber CP, Goldberg SJ, Allen HD. Doppler echocardiographic comparison of flows distal to the four cardiac valves. *J Am Coll Cardiol*. 1984;4:268–72.
16. Meijboom EJ, Horowitz S, Valdes-Cruz LM, Sahn DJ, Larson DF, Oliveira Lima C. A Doppler echocardiographic method for calculating volume flow across the tricuspid valve: correlative laboratory and clinical studies. *Circulation*. 1985;71:551–6.
17. Velayudhan DE, Brown TM, Nanda NC, et al. Quantification of tricuspid regurgitation by live three-dimensional transthoracic echocardiographic measurements of vena contracta area. *Echocardiography*. 2006;23:793–800.
18. Chen TE, Kwon SH, Enriquez-Sarano M, Wong BF, Mankad SV. Three-dimensional color Doppler echocardiographic quantification of tricuspid regurgitation orifice area: comparison with conventional two-dimensional measures. *J Am Soc Echocardiogr*. 2013;26:1143–52.
19. Gonzalez-Vilchez F, Zarauza J, Vazquez de Prada JA, et al. Assessment of tricuspid regurgitation by Doppler color flow imaging: angiographic correlation. *Int J Cardiol*. 1994;44:275–83.

Chapter 7

A Surgeon's View on Echocardiographic Imaging of the Tricuspid Valve

Kevin M. Veen, Folkert J. ten Cate, and Frans B. Oei

Abstract Echocardiography has evolved into an important diagnostic tool in cardiac imaging and is frequently used in preparing for cardiac surgery. In this chapter we will discuss a surgeon's view on imaging of the tricuspid valve. Generally, cardiac surgeons focus on four different aspects of echocardiography when preparing for tricuspid valve surgery: the size of the tricuspid annulus; the severity of tricuspid regurgitation, the morphology of valve leaflets and the degree of tethering of the tricuspid valve. In this chapter we discuss each of these four aspect separately. The emphasis is based on two dimensional echocardiography used in three clinical cases outlining the advantages and disadvantages of this contemporary technique.

Keywords Echocardiography • Tricuspid valve • Tricuspid valve surgery

Introduction

Historically, tricuspid valve disease was believed to be benign and of lesser importance. However, recent studies have shown that tricuspid valve regurgitation leads to impaired survival [1]. These observations have led to renewed interest in the tricuspid valve and subsequently the imaging of the tricuspid valve.

During the last decades, cardiac imaging progressed from infant techniques to a tool which plays a crucial role in clinical practice. Especially echocardiography, being non invasive, easy to handle and relatively inexpensive, has evolved to an important diagnostic tool in cardiac imaging. Furthermore, echo images are used by

K.M. Veen, M.D. • F.B. Oei, M.D., Ph.D. (✉)

Department of Cardiothoracic Surgery, Thoraxcenter, Erasmus MC: University Medical Centre Rotterdam, Rotterdam, The Netherlands

e-mail: f.oei@erasmusmc.nl

F.J. ten Cate, M.D., Ph.D.

Department of Cardiology, Thoraxcenter, Erasmus MC: University Medical Centre Rotterdam, Rotterdam, The Netherlands

surgeons to determine indications for operations and more importantly to provide surgeons with an adequate anatomical overview in order to select the suitable technique for the operation ahead. This chapter will discuss the surgeon's view on this specific form of cardiac imaging. The emphasis is based upon two dimensional cardiac echocardiography which is used in three clinical cases which will be presented in this chapter in order to outline the advantages and disadvantages of this technique.

In general cardiac surgeons focus on four different aspects of echocardiography when preparing for tricuspid valve surgery: the size of the tricuspid annulus; the severity of tricuspid regurgitation, the morphology of valve leaflets and the degree of tethering of the tricuspid valve.

Tricuspid Annulus

The tricuspid valve annulus is only partially fibrous in nature. Three leaflets are attached on the annulus: the septal leaflet, the anterior leaflet and the posterior leaflet. The septal part of the annulus is believed to be analogous to the inter-trigonal part of the mitral annulus and the only fibrous part of the annulus. Therefore, it is relatively spared from displacement in annular dilation. The other parts of the tricuspid annulus are more flexible. Hence, dilatation of the annulus occurs in the anterior and posterior direction, which may lead to functional regurgitation due to leaflet malcoaptation. Fukuda and colleagues used real time 3D transthoracic echocardiography to map the tricuspid annulus. They noticed that the tricuspid annulus had a nonplanar elliptical shape, which differs from the more symmetrical saddle shape of the mitral annulus. Therefore, tricuspid annuloplasty rings are non-planar and attempt to resemble the physiological structure (Fig. 7.1). During a cardiac cycle the annulus diameter reduces approximately 19%. They also noticed that in case of dilatation the tricuspid annulus gradually becomes more planar [2].




Fig. 7.1 A Carpentier-Edwards Physio tricuspid annuloplasty ring. The rings are non-planar and resemble the physiological tricuspid valve annulus. The rings have a septal segment opening (indicated by the *arrow*), in order to avoid damage to the conduction system. Source: <http://www.edwards.com/eu/products/rings/pages/physiotricuspid.aspx>

2D transthoracic echocardiography (TTE) echocardiography underestimates tricuspid annulus measurements significantly, while 3D echocardiography gives a more correct estimate compared to the golden standard (magnetic resonance imaging) [3]. Current European guidelines (ESC) advise tricuspid valve surgery when patients undergo left sided valve surgery if tricuspid annulus dilation >40 mm (21 mm/m²) is present even in mild/non-severe tricuspid regurgitation (Class IIa evidence) [4].

Degree of Tricuspid Regurgitation

Both the European and American guidelines agree that tricuspid valve surgery is indicated in patients with severe tricuspid regurgitation undergoing left sided valve surgery, both class I evidence [4, 5]. Nevertheless, assessing the severity of tricuspid regurgitation is still controversial. A recent study identified a modest inter-observer agreement in assessing tricuspid regurgitation, however this variability improved with a new standardized assessing method [6].

Morphology

Tricuspid valve morphology is an important parameter to consider before surgery, since various structural abnormalities in the leaflets generally require different surgical approaches. Leaflets can be fibrotic, calcified, damaged by vaso-active peptides or extra-cardiac (pacemaker, ICD) leads and vegetation's due to endocarditis can be present. Nevertheless, tricuspid valve morphology is difficult to visualize by 2D echocardiography, since not all three leaflets can be visualized in one single view by using the standardized echographical angles [7].

Tethering

Tethering is a phenomena where the papillary muscles and tendinous chords have become functionally too short resulting in malcoaptation. Leaflet tethering is generally associated with functional tricuspid value regurgitation. Tethering is usually caused by dilatation of right ventricle, but in some cases it may be caused by a diversity of subvalvular abnormalities, like aberrant chordae [8]. Leaflet tethering is a preoperative predictor of residual tricuspid regurgitation [9].

In the following part of this chapter, we describe three cases in which the tricuspid valve repair has been performed. These cases describe the presenting clinical symptoms, a brief medical history and a summary of the heart team evaluation. The intraoperative findings and performance and the clinical course of the postoperative period will be discussed. Thereafter, all cases will be evaluated and a final take home message will be provided.

Case 1: Functional Tricuspid Regurgitation with a Structural Component

A 53 year old female presents with symptoms of dyspnea and angina pectoris. She is in NYHA class III. Her medical history is significant for hypercholesteremia, hypertension and terminal kidney failure based upon lithium use for a bipolar psychiatric disorder.

Heart Team Evaluation

First echocardiogram was made 8 months before the heart team evaluation. Transesophageal echocardiography (TEE) shows severe mitral regurgitation, which is likely caused by a restrictive posterior valve. Moderate left atrium dilatation was found. Left ventricular ejection fraction was measured 47%. Two months

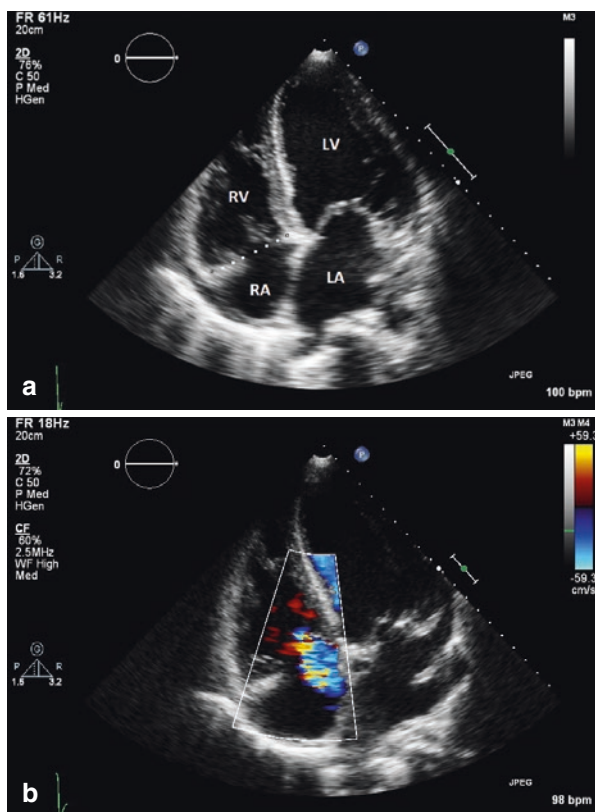


Fig. 7.2 (a) TTE 4-chamber view, note the left sided dilatation. The tricuspid annulus measured 48 mm. (b) TTE Doppler of the tricuspid valve demonstrated severe insufficiency. Note the direction of the jet points toward the atrial septum (eccentric jet). RA right atrium, RV right ventricle, LV left ventricle, LA left atrium

prior to operation severe tricuspid regurgitation was found on Trans thoracic echocardiography (TTE), as shown in Fig. 7.2. The annulus of the tricuspid valve measured 48 mm. The heart team concludes that left sided valve intervention is necessary and concomitant tricuspid valve surgery is indicated. This decision is supported by the current ESC-guidelines [4].

Operation

Patients was electively admitted for mitral and tricuspid valve surgery. Operation was done by median sternotomy. After central bi-caval cannulation the circulation is taken over by cardio pulmonary bypass and after aortic cross clamping, cardioplegia was admitted. The left atrium was opened via Waterston's groove and the mitral valve is exposed. A Mitral Physio-ring (Edwards Lifescience) size 26 is implanted in the dilated annulus. The left atrium is closed with 4 × 0 Prolene sutures. The right atrium is opened and the tricuspid valve is exposed. The annulus is dilated and septal leaflet tissue is limited. This wasn't noted on preoperative echocardiography images. A Tricuspid Physioring (Edward Lifescience) size 32 is implanted with Tricon 2 × 0 annular sutures. The right atrium is closed with Prolene 4 × 0 sutures. During removal of the aortic cross clamp and venting the aortic ascendens major ST deviations followed by ventricular fibrillation occurs, most likely due to coronary air embolisms. After defibrillating the rhythm converted to sinus rhythm. Temporary epicardial pacemaker leads were left on the right ventricle and the sternum was closed by steel wires. Subsequently, the skin was closed by staplers. Both the mitral and tricuspid ring are shown in Fig. 7.3a.

Postoperative Period

The patient is admitted to the intensive care unit and recovered successfully without any significant events. Postoperative TTE shows a trace of mitral regurgitation and still severe residual tricuspid regurgitation, as shown in Fig. 7.3b. In this particular case, the limited valve tissue could be the reason of persistent malcoaption. Annuloplasty, by implantation of a rigid ring alone, without valve leaflet augmentation has resulted in a failed repair.

Case 2: Cardiac Endovascular Pacemaker-Lead Interference of the Tricuspid Valve

A 79 year old male presents with dyspnea (NYHA class III) and intense fatigue. Physical examination reveals peripheral edema, vesicular breath sounds and bilateral jugular vein engorgment. Blood pressure is 113/61 with a ventricular paced rhythm of 50 beats per minute. His medical history includes complete heart block

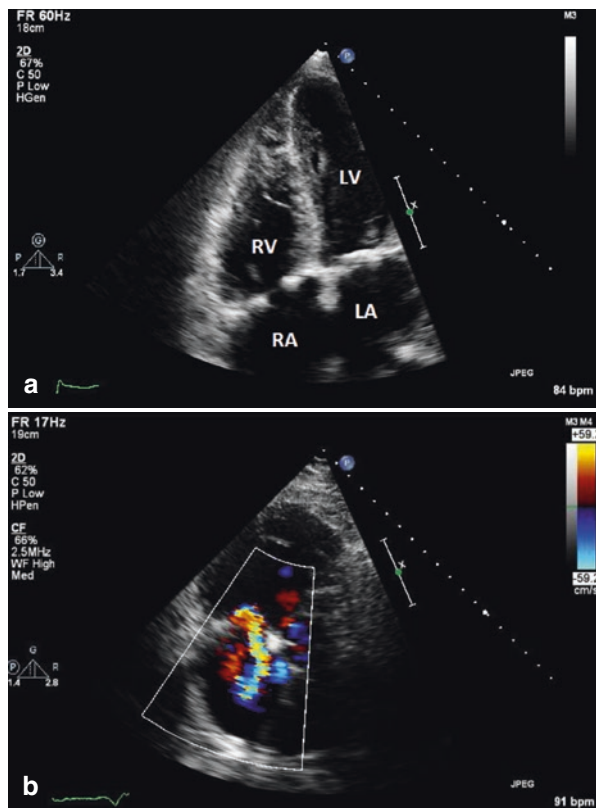


Fig. 7.3 (a) TTE 4-chamber view. Both the ring in the tricuspid position as the ring in mitral position are visible. When eyeballing the left chamber, a reduction in dilation already has taken place. (b) TTE 4-chamber view of the tricuspid valve. Severe residual tricuspid regurgitation is present. Note that the jet is smaller than the preoperative jet

5 years ago and subsequently an implantation of endovascular DDD pacemaker system. Shortly after the implantation an acute myocardial infarction occurred due to significant lesion of the ramus circumflexus sinister. The patient was treated by a percutaneous coronary intervention. In the following years liver dysfunction developed, probably caused by right heart failure.

Heart Team Evaluation

This patient is discussed twice in a heart team meeting. The first meeting took place after echocardiographic imaging which showed a severely dilated right ventricle, as shown in Fig. 7.4a. Right ventricle dimensions are 87 mm for apex to basis and the annulus measured 59 mm. Systolic function of the right ventricle is graded as

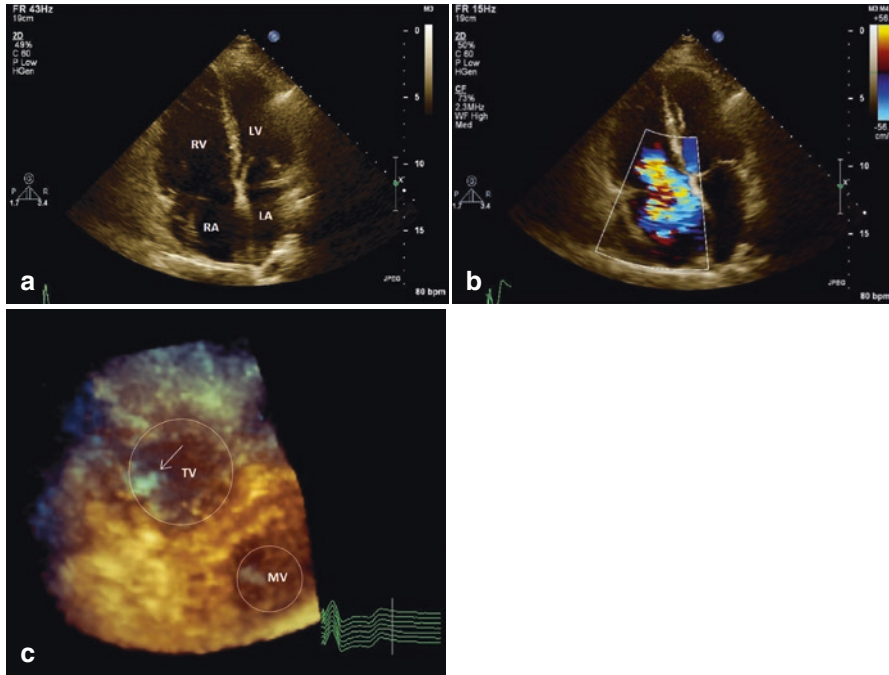


Fig. 7.4 Panel (a) shows dilatation of the right ventricle and right atrium. RA dimensions are 73×59 mm, TAPSE is 21 mm. (b) Massive tricuspid regurgitation is present. (c) With 3d echocardiography the cardiac pacemaker lead can be visualized (the arrow points to the lead). MV mitral valve, TV tricuspid valve

moderate. Mean pulmonary artery pressure (mPAP) is mildly increased (30 mmHg). Fig. 7.4b displays massive tricuspid regurgitation which is probably caused by both right ventricular dilatation and cardiac pacemaker lead interference of the tricuspid valve. 3D echocardiography confirms this suspicion (Fig. 7.4c). The left heart has fractional shortening of 40%, which is graded as a moderate systolic function. Only mild mitral regurgitation is noticed.

The heart team initially concludes that the congestive right heart failure is caused by tricuspid regurgitation with volume overload, primary right ventricular failure and the lack of AV synchrony. However, the consensus is reached to prescribe a medical therapy in the first place and not to operate this patient because of the unpredictable outcome of and uncertainty of tricuspid valve repair and the expected high operation risks (due to age and pre-existed kidney failure). The consensus is discussed with the patient and he agrees with the proposed medical treatment.

During the following months the right heart failure persisted and the patient needs to be admitted for intravenous diuretic treatment. In the second meeting the heart team decides to perform the high risk operation due to persistent right heart failure on medications. Additionally, the VVI-pacemaker system is to be replaced for an epicardial system, due to interference with tricuspid valve leaflets causing severe tricuspid regurgitation.

Operation

Patient is electively admitted at our center and underwent surgery of the tricuspid valve, a coronary artery bypass graft (CABG) and removal of the endovascular DDD pacemaker system, which is replaced with a epicardial DDD pacemaker system. Operation was done via median sternotomy. After central and bi-caval cannulation, circulation is taken over by cardio pulmonary bypass. Because of pre-existed kidney failure blood pressure is kept at 70 mmHg, resulting in good diuresis during surgery. The operation is performed on beating heart without aorta cross clamping. The distal right coronary artery is calcified and this vessel is grafted by a vena saphenous magna (VSM) graft. On beating heart the right atrium is opened and the tricuspid valve is exposed. The atrial lead is located in the auricle, but the lead had grown into the anterior part of the right atrium and also in the anterior part of the tricuspid annulus, resulting in deformation of the tricuspid annulus. The ventricular lead originates from the VCS following the posterior wall of the atrium to the inter-commissural area of the tricuspid annulus and pushed the septal leaflet laterally, in which the lead also have grown into. Carefully, both pacemaker leads are removed and a small defect on the septal leaflet is sutured by prolene 6×0 sutures, without leaflet extention. A Tricuspid Physio (Edwards Lifescience) ring size 34 is implanted and the tricuspid valve appears sufficient with watertest. New epicardial leads are introduced and are connected to a Biotronik pacemaker, which is placed at the dorsal left side of the rectus abdominis. Peri-operative TEE showed significant diminished tricuspid valve regurgitation.

Postoperative Period

Posteroperatively the patient is transferred to the intensive care. The intensive care stay was characterized by hemodynamic and respiratory stability. However, the pre-existing kidney failure worsened, which was medically treated. Thereafter, the patients recovered and left the hospital in reasonable good condition.

Post-operative echocardiography 2 weeks after operation showed moderate residual tricuspid regurgitation, as is shown in Fig. 7.5b. Right ventricle size reduced to moderate dilation and its function remained moderate. Despite annuloplasty and valvuloplasty of the septal leaflet, moderate residual tricuspid regurgitation recurred post-operatively. The reappearance of tricuspid regurgitation after 2 weeks after recovery of the right ventricular function suggests structural failure of the valve leaflets. Primary suturing of the destructed valve leaflet may lead to fibrosis and eventually retraction of the valve leaflet and increases residual regurgitation post-operatively.

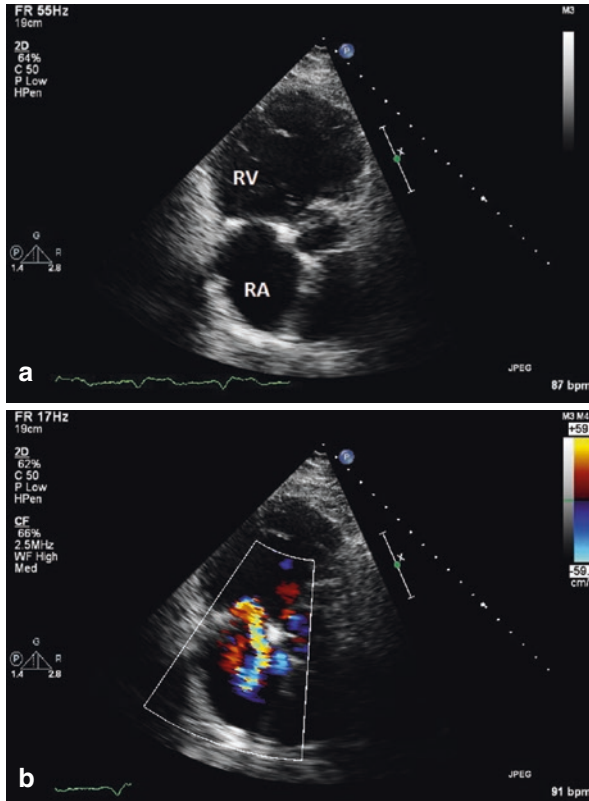


Fig. 7.5 (a) View of Carpentier Edwards ring in the tricuspid position. (b) Doppler echocardiography shows moderate residual tricuspid regurgitation

Case 3: Functional Regurgitation Due to Left Sided Heart Disease

A 78 old male presents with progressive dyspnea (NYHA class IV), orthopneu, lower limbs edema and nocturia. His stomach is slightly distended. He smokes ten cigarettes a day. Physical examination reveals blood pressure of 106/85 with 104 beats per minute and auscultation reveals bibasilar crackles of the lungs. His medical history is significant for atrium fibrillation and instable angina pectoris.

Heart Team Evaluation

Echocardiography shows severe central mitral valve regurgitation and dilated tricuspid valve annulus of >40 mm. Measurement of the tricuspid valve annulus was done by TEE and TTE. TTE measurement of the annulus of the 4-chamber view was found to be 50 mm, as shown in Fig. 7.5b. Measuring by TEE resulted in an annulus size of 48 mm Fig. 7.6a. Consensus was reached to operate on the mitral valve with concomitant tricuspid valve surgery.

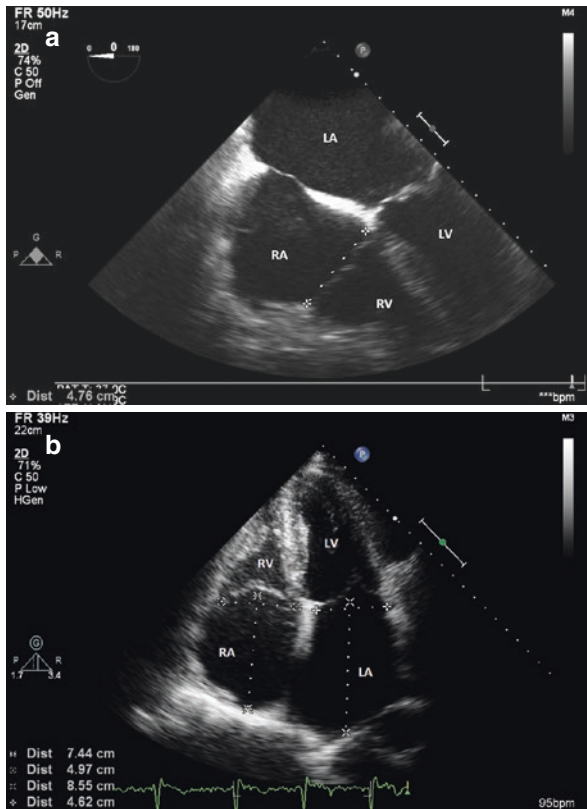


Fig. 7.6 (a) Preoperative TEE of the tricuspid valve and measurement of the annulus of the tricuspid valve. (b) Preoperative TTE 4 chamber view and measurement of annulus dilation of the tricuspid valve

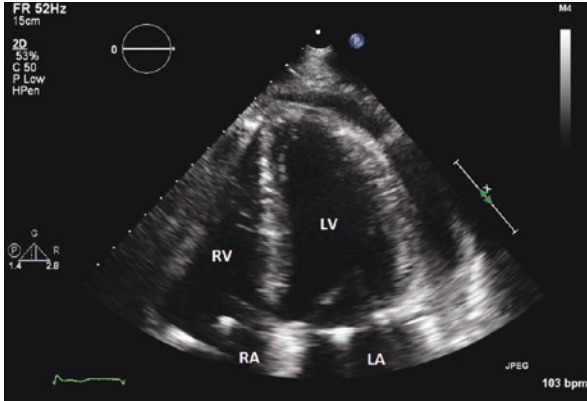


Fig. 7.7 The Physio ring is visible in both the mitral as tricuspid position on 4-chamber view

Operation

Patient is electively admitted at the Thoraxcenter and underwent surgery of the mitral and tricuspid valves. Operation was done via a median sternotomy. After central and bi-caval cannulation circulation is taken over by cardio pulmonary bypass and after aortic cross clamping St Thomas cardioplegia was admitted. The left atrium was opened through Waterson's groove and the mitral valve is exposed. The annulus is dilated, without structural defects of the leaflets. A mitral Physio-ring II (Edwards Lifescience) size 30 is implanted with Ticron 2×0 sutures. No mitral regurgitation is present after watertesting. The right atrium is opened and the tricuspid valve is exposed. Conform echographical findings, no structural defects of the tricuspid leaflets and sub-valvular apparatus is seen. A tricuspid Physio-ring (Edwards Lifescience) size 32 is implanted with Ticron 2×0 sutures. Thereafter, both atria were closed with Prolene sutures and patient was weaned of cardiopulmonary bypass. Peri-operative TEE revealed no residual mitral or tricuspid valve regurgitation, the echographical appearance of both Physio-rings is displayed in Fig. 7.7.

Postoperative Period

Postoperatively the patient was transferred to the intensive care. Here, post-operative bleeding persisted and the patient was re-explored in the operating room the next day and multiple cloths were removed retrosternal and intra-pericardial. Additionally, the

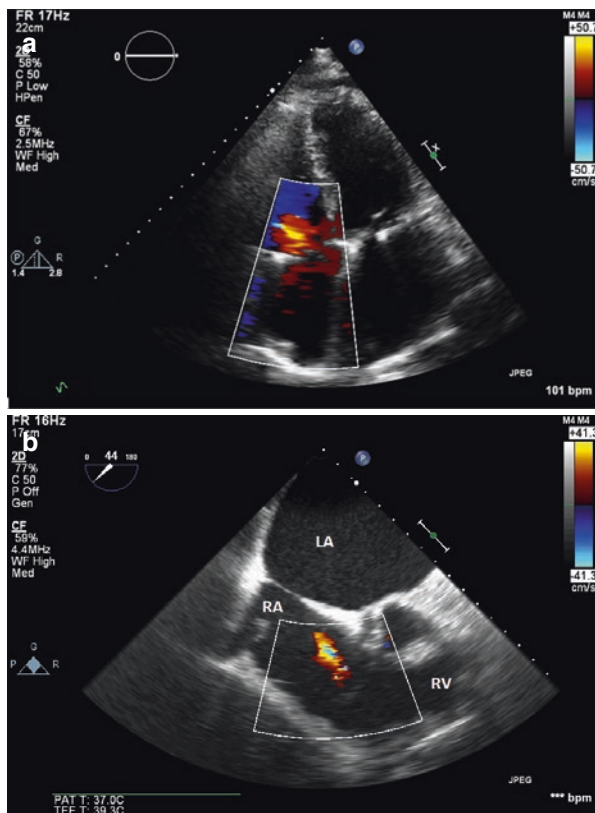


Fig. 7.8 (a) TTE 4-chamber view with Doppler of the tricuspid valve during systole. None to trivial regurgitation is present. (b) Doppler TEE of the tricuspid valve also shows trivial tricuspid regurgitation

postoperative course was complicated by rectal blood loss and delirium, which was treated by lowering anticoagulant dose and haloperidol and clonidine. The next month sternum dehiscence occurred which was re-fixed. Cultures of exudate did not show mediastinitis. Eventually, patient recovered successfully and left the hospital in reasonable good condition. Antibiotics were prescribed to prevent wound infection of the sternum. Postoperative TTE showed good results, as shown in Fig. 7.8a, b. Tricuspid regurgitation is reduced to none or trivial.

Discussion

2D echo imaging plays an important role in clinical decision making regarding tricuspid valve surgery. The four chamber view of trans thoracic echocardiography is especially helpful since it gives an excellent overview of the septal and anterior

leaflet. The septal leaflet is seen on the septal side and the anterior leaflet on the free wall [10], although the posterior leaflet is less frequently seen from this angle [11].

The posterior leaflet is surgically of less interest when performing a reduction annuloplasty with an down-sized rigid ring as this technique causes the posterior leaflet to enfold and therefore excluding it from its function. Therefore, structural defects of the posterior valve are of less significance for the post-operative tricuspid valve function when performing ring annuloplasty. The first case is an example in which echocardiographic imaging showed calcification and leaflet thickening of the anterior valve leaflet (Fig. 7.1a). An eccentric jet, pointing towards the septum is also visible, indicating a structural defect of the anterior valve leaflet. Nevertheless in this case, only a ring annuloplasty was performed, resulting in post-operative residual tricuspid regurgitation. Tricuspid valve replacement was not considered an option due to the increased mortality and morbidity risk. The postoperative echocardiography (Fig. 7.2) demonstrated a residual tricuspid regurgitation with an eccentric jet. Even though the tricuspid valve regurgitation has decreased after annuloplasty the residual tricuspid valve regurgitation suggests a persistent structural dysfunction of the valve leaflet. In conclusion, ring annuloplasty alone is not sufficient when valve leaflets are damaged or leaflet tissue is limited.

3D echocardiography might provided a better overview of all three leaflets in one view and more importantly in a dynamic moving manner [10].

The second case illustrates endovascular cardiac pacemaker lead interfering with the tricuspid valve. Lead entanglement, lead perforation, lead impingement and lead adherence to the valve annulus or valve leaflet may result in significant tricuspid regurgitation. In this particular case it is suspected that the right ventricular lead was partially causing the regurgitation, however 2D echocardiography fails to confirm this suspicion, because of the absence of a clear view of the leads, as is showed in Fig. 7.3a, b. On the other hand, 3D echocardiography clearly illustrated the anatomical position and interference of the cardiac pacemaker leads with the tricuspid valve, as shown in Fig. 7.3c. Lin et al. demonstrated in a series of 41 patients that lead inference can be diagnosed preoperatively using 2D echocardiography in a mere 5% of patients [12]. 3D echocardiography may prove to be an excellent tool in visualizing endovascular pacemaker lead interference and subsequent damage of the tricuspid valve. A recent study showed that cardiac leads can be identified in 74% of patients using 3D echocardiography [13]. Additionally, the patient in case two developed moderate tricuspid regurgitation after 2 weeks of surgery, while peri-operative TEE showed sufficient tricuspid valve function. The regurgitation is probably caused by fibroses and subsequent retraction of the sutured defect of the septal leaflet. In retrospect, simply suturing the defect without leaflet augmentation was probably not the best option.

The third case is an example of functional tricuspid regurgitation. Functional regurgitation is regurgitation due to annular dilation, without any structural damage on the leaflets and subvalvular apparatus itself. 2D TTE echocardiography showed annulus dilation (Fig. 7.5). Peri-operatively no structural abnormality was observed macroscopically in the (sub)valvular apparatus except for the expected annulus dilatation and an annuloplasty ring was implanted with a satisfactory outcome.

Therefore, this case also underlines the fact that a ring annuloplasty is generally sufficient in cases with functional tricuspid valve regurgitation without any form of structural abnormality of the valve leaflets.

Take Home Message

The septal and anterior leaflets of the tricuspid valve are surgically of more interest than the posterior leaflet. Therefore, routine 2D TTE four chamber view already provides the surgeon with sufficient information regarding annulus diameter and structural leaflet abnormalities. However, when structural deformations of the tricuspid valve are present or are suspected, 3D echocardiography has demonstrated its superiority in evaluating the complex tricuspid valve anatomy. Furthermore, annuloplasty by ring implantation is generally not enough to correct structural tricuspid valve regurgitation.

Review Questions

45. Which echocardiography finding is important in the decision making regarding tricuspid valve replacement or valvuloplasty?
 - (a) Annulus dilation >40 mm
 - (b) Annulus dilation <40 mm
 - (c) Structural valve damage
46. Which tricuspid valve leaflet is surgically of less interest when performing an annuloplasty?
 - (a) Anterior leaflet
 - (b) Septal leaflet
 - (c) Posterior leaflet
47. What is the incremental value of 3D echocardiography over in 2D echocardiography in tricuspid valve imaging?
 - (a) Imaging all tricuspid valve leaflets in one view more easily
 - (b) It provides real time images
 - (c) It is cheaper

References

1. Nath J, Foster E, Heidenreich PA. Impact of tricuspid regurgitation on long-term survival. *J Am Coll Cardiol.* 2004;43(3):405–9.
2. Fukuda S, Saracino G, Matsumura Y, Daimon M, Tran H, Greenberg NL, et al. Three-dimensional geometry of the tricuspid annulus in healthy subjects and in patients with functional tricuspid regurgitation: a real-time, 3-dimensional echocardiographic study. *Circulation.* 2006;114:1492–18.
3. Anwar AM, Soliman OII, Nemes A, Geuns RJM, Geleijnse ML, Cate FJ. Value of assessment of tricuspid annulus: real-time three-dimensional echocardiography and magnetic resonance imaging. *Int J Card Imaging.* 2007;23(6):701–5.
4. Vahanian A, Alfieri O, Andreotti F, Antunes MJ, Baron-Esquivias G, Baumgartner H, et al. Guidelines on the management of valvular heart disease (version 2012). The Joint Task Force on the Management of Valvular Heart Disease of the European Society of Cardiology (ESC) and the European Association for Cardio-Thoracic Surgery (EACTS). *Eur J Cardiothorac Surg.* 2012;42(4):S1–44.
5. Nishimura RA, Otto CM, Bonow RO, Carabello BA, Erwin JP 3rd, Guyton RA, et al. 2014 AHA/ACC guideline for the management of patients with valvular heart disease: a report of the American College of Cardiology/American Heart Association Task Force on Practice Guidelines. *J Am Coll Cardiol.* 2014;63(22):e57–185.
6. Grant AD, Thavendiranathan P, Rodriguez LL, Kwon D, Marwick TH. Development of a consensus algorithm to improve interobserver agreement and accuracy in the determination of tricuspid regurgitation severity. *J Am Soc Echocardiogr.* 2014;27(3):277–84.
7. Muraru D, Badano LP, Sarais C, Soldà E, Iliceto S. Evaluation of tricuspid valve morphology and function by transthoracic three-dimensional echocardiography. *Curr Cardiol Rep.* 2011;13(3):242–9.
8. Kobza R, Kurz DJ, Oechslin EN, Pretre R, Zuber M, Vogt P, et al. Aberrant tendinous chords with tethering of the tricuspid leaflets: a congenital anomaly causing severe tricuspid regurgitation. *Heart.* 2004;90(3):319–23.
9. Fukuda S, Song JM, Gillinov AM, McCarthy PM, Daimon M, Kongsarepong V, et al. Tricuspid valve tethering predicts residual tricuspid regurgitation after tricuspid annuloplasty. *Circulation.* 2005;111(8):975–9.
10. Anwar AM, Geleijnse ML, Soliman OII, McGhie JS, Frowijn R, Nemes A, et al. Assessment of normal tricuspid valve anatomy in adults by real-time three-dimensional echocardiography. *Int J Cardiovasc Imaging.* 2007;23(6):717–24.
11. Addetia K, Yamat M, Mediratta A, Medvedofsky D, Patel M, Ferrara P, et al. Comprehensive two-dimensional interrogation of the tricuspid valve using knowledge derived from three-dimensional echocardiography. *J Am Soc Echocardiogr.* 2016;29(1):74–82.
12. Lin G, Nishimura RA, Connolly HM, Dearani JA, Sundt TM 3rd, Hayes DL. Severe symptomatic tricuspid valve regurgitation due to permanent pacemaker or implantable cardioverter-defibrillator leads. *J Am Coll Cardiol.* 2005;45(10):1672–5.
13. Cheng Y, Gao H, Tang L, Li J, Yao L. Clinical utility of three-dimensional echocardiography in the evaluation of tricuspid regurgitation induced by implantable device leads. *Echocardiography.* 2016;33(11):1689–96.

Chapter 8

Imaging of the Tricuspid Valve: Magnetic Resonance Imaging

Soha Romeih and Sara El Fawal

Abstract Echocardiography is considered as the main modality for the assessment of tricuspid valve disease. However, echocardiography has technical limitations as well as anatomic limitations when comes to complex structures of the tricuspid valve and the right side of the heart. Cardiac magnetic resonance (CMR) is considered as the gold standard for the assessment of right ventricle. In this chapter, we will discuss potential role of CMR in tricuspid valve disease. Imaging protocols, advantages and limitations of CMR imaging of the tricuspid valve complex will be discussed. Furthermore, CMR role in assessment of tricuspid regurgitation severity will be addressed.

Keywords Tricuspid • Stenosis • Regurgitation • Magnetic resonance imaging • CMR • Masses • Right heart • Imaging protocol

Introduction

The primary imaging modality of choice for the tricuspid valve (TV) lesions is echocardiography. However, echocardiography has its own limitations due to the limited field of view, the retro-sternal location, complex anatomy of the TV and the subjective variability among echocardiographers as observers, particularly for quantification of the TV disease (lesion) severity [1–6].

Over the past 20 years, cardiovascular magnetic resonance (CMR) has evolved as an alternative non-invasive modality that does not use no ionizing radiation, and applicable to patients with valvular heart disease [1, 7–9].

S. Romeih, M.D., Ph.D., F.E.S.C. (✉)

Department of Pediatric Cardiology, Grown Up Congenital Heart Disease Unit,
Cardiovascular Imaging Unit, Aswan Heart Centre, Magdi Yacoub Foundation, Aswan, Egypt
e-mail: soha17@hotmail.com

S. El Fawal, M.D.

Department of Radiology, Alexandria University, Alexandria, Egypt

CMR is currently the gold standard for the assessment of right ventricle's (RV) morphology and function, as CMR provides images of valves anatomy, and allows quantitative evaluation of stenotic and regurgitant lesions, thus it can discern the consequences of the TV lesions, including their effects on the RV function [10, 11]. Therefore, CMR is of great interest in the field of TV evaluation. The purpose of the present chapter is to summarize the general principles and limitation of CMR as an imaging tool for evaluation of TV.

TV Anatomy

The TV is a complex entity of thin fibrous tissue, with three leaflets, chordae tendinae, papillary muscles and a fibrous annulus located between the right atrium and the RV [12, 13].

The normal area of the TV is 7–9 cm², making it the largest of the four cardiac valves. The TV is nearly vertical and is oriented at approximately 45° to the sagittal plane, so that the margins of the valve are antero-superior, inferior and septal [14].

Tricuspid valve leaflets: TV has three leaflets; the three leaflets are the anterior, septal and posterior leaflets. The septal leaflet is the smallest, and arises medially, directly from the annulus above the inter-ventricular septum. The septal leaflet is characteristically inserted less than 10 mm more apically than the septal insertion of the anterior mitral valve leaflet.

Tricuspid sub-valvular apparatus: The Tricuspid sub-valvular apparatus is similar to the mitral valve, but has greater variability. The tricuspid sub-valvular apparatus consists of anterior, posterior and septal papillary muscles, and their true chordae tendinae. The posterior papillary muscle is smaller, and is missing in 20% of healthy subjects [15].

Tricuspid valve annulus: The TV leaflets are attached to a fibrous annulus that is not as easy to define as it is around the mitral valve, although it remains identifiable [16]. The septal leaflet, the least mobile of the three leaflets, has more support from the fibrous trigone than other leaflets. The normal TV annulus is ovoid, and appears approximately one third longer in the medio-lateral than in the antero-posterior direction [17].

Comprehensive Evaluation of Tricuspid Valve by CMR

CMR offers a unique imaging modality for evaluation of TV anatomy and dys-/function in addition to the hemodynamic consequences on RV.

- 3.1. Assessment of TV anatomy.
- 3.2. Assessment of TV flow.
- 3.3. Assessment of RV volume and function.
- 3.4. Assessment of myocardial fibrosis.

Assessment of Tricuspid Valve Anatomy

CMR has the potential to visualize all parts of the TV (leaflets, chordae tendineae, and papillary muscles) throughout the entire cardiac cycle. Abnormal valve leaflets, aberrant papillary muscles or aberrant chordal attachments, leaflet thickening, presence, extent of calcification, leaflet redundancy and prolapse, and commissural fusion are all anatomic descriptions that have been reported by CMR [18, 19]. CMR provides visualization of valve masses such as vegetation, thrombi, or tumours, including attachment site and mobility.

In addition, CMR is useful for assessing TV annulus size and shape changes over the cardiac cycle. Compared with real-time 3D Echocardiography, CMR is accurate in measurements of TV annular area and fractional shortening or area change [6, 20].

CMR Sequence and Image Acquisition

- Most morphological information is obtained using cine CMR sequences, particularly *steady state free-precession (SSFP) sequences* with their high contrast between blood pool and surrounding structures Fig. 8.1. These have largely replaced the old *spoiled gradient echo (SGE) sequences*, though the latter remain useful on occasions for visualizing the extent of flow disturbance in selected cases [21–23].
- The visual assessment of turbulent flow in stenotic or regurgitant flow jets is also feasible with SSFP and SGE sequences, through visualisation of signal voids due to spin dephasing in moving protons. The location and direction of jets can be assessed, which can provide valuable information about the valve lesion [24] Fig. 8.2.
- Flow related signal loss seen on SSFP images occurs where voxels span a range of velocities, notably in the shear layers that can surround the more coherent jet

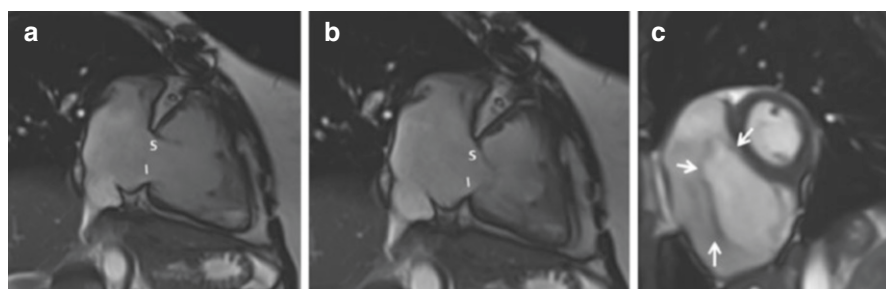
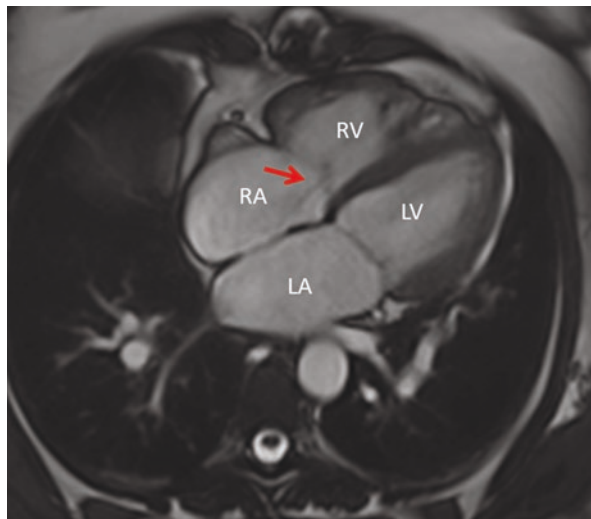


Fig. 8.1 Cine SSFP images; (a) two chamber right during diastole showing the opened tricuspid valve (b) two chamber right during systole showing closed tricuspid valve (c) short axis at atrio-ventricular level showing the tricuspid valve area (arrows). *S* superior leaflet, *I* inferior leaflet, *SSFP* steady state free-precession

Fig. 8.2 Cine image of SSFP showing four chambers during systole, jet of tricuspid valve incompetence in the right atrium (*red arrow*). SSFP steady state free-precession, RA right atrium, LA left atrium, LV left ventricle, RV right ventricle



core. This method can provide an approximate guide to the degree of regurgitation, and distinguishing mild and severe regurgitation is feasible, but finer differentiation of severity is rarely possible.

- For accurate assessment of the TV orifice, positioning the image slice precisely at TV tips is important and misalignment may result in significant error. Multiple parallel thin image slices in the plane of interest can help to locate the one slice at the optimal position of the valve tips.

Advantages

- Direct measurement of valve orifice area for stenosed valves by planimetry rather than calculation, and assessment of regurgitant orifices if required [25].
- A semi-automatic algorithm based on cine CMR images and 3D reconstruction can help to assess TV annulus morphology and motion and to better depict its ellipsoid saddle shape [6].

Limitations

- The thin nature of TV (1–2 mm) makes it particularly prone to partial volume effects due to the slice thickness of CMR images (typically 5–8 mm). Care is therefore required in placing image slices perpendicular to the valve plane to minimize these effects and in minimizing slice thickness to 4–5 mm, but some aspects of finer valve anatomy may be too difficult to visualize well with CMR.

- The need to acquire cine images over several cardiac cycles which results in suboptimal visualisation of small or more chaotically mobile objects such as vegetation.
- Signal voids seen on SSFP imaging are related to the acceleration of blood rather than the velocity alone, and may underestimate the degree of flow disturbance when assessing the degree of regurgitation. Narrow (mild) jets may be difficult to visualize due to the lack of shear layers at the edge of the jet. SGE sequences are more sensitive than SSFP sequences for evaluating the presence and magnitude of turbulent jets and this sensitivity is increased with lengthening echo time [26, 27].
- Assessing the severity of regurgitation with visual assessment of SSFP cine images requires care and caution as the technique is subject to slice positioning, and partial volume effects.

Assessment of Tricuspid Valve Flow

The ability to quantify flow directly using phase-contrast velocity mapping is a unique advantage of CMR, and does not rely on calculation based on complex equations, as echocardiography or invasive catheterization techniques require [28].

CMR Sequence and Image Acquisition

Phase-contrast velocity mapping (other names include velocity-encoded cine, Q flow, or velocity mapping) are used for velocity measurements, and based on the accumulated phase of moving protons. In this sequence, bipolar gradients oriented in the expected direction of blood flow are applied to each frame of the imaging slice of interest to induce phase shifts. Phase refers to the angular position of an individual proton's spin vector with respect to a frame of reference. Stationary objects within this slice have a net phase of zero, because all phase induced by the first lobe of the bipolar gradient is reversed by the second lobe. Moving objects (blood) gain a net phase depending on the direction of blood flow, and this net phase is proportional to the velocity of blood. This net phase can be displayed as a phase map with differences in signal intensity representing different velocities. Pixels depicting flow in the phase-encoding direction appear bright, and flow opposite to the phase encoding direction appears dark objects with a phase shift of zero (stationary) are grey or speckled, as can be seen in the lungs or chest wall.

Velocity mapping produces two sets of images: *magnitude image* and *phase velocity image*. The magnitude image is used for anatomic orientation of the imaging slice and to identify the boundaries of the vessel imaged Fig. 8.3. Blood has an increased signal, whereas turbulent flow is depicted with signal loss within the magnitude image. The phase image encodes the velocities within each pixel. Using both images, a region of interest can be traced on each time frame of the

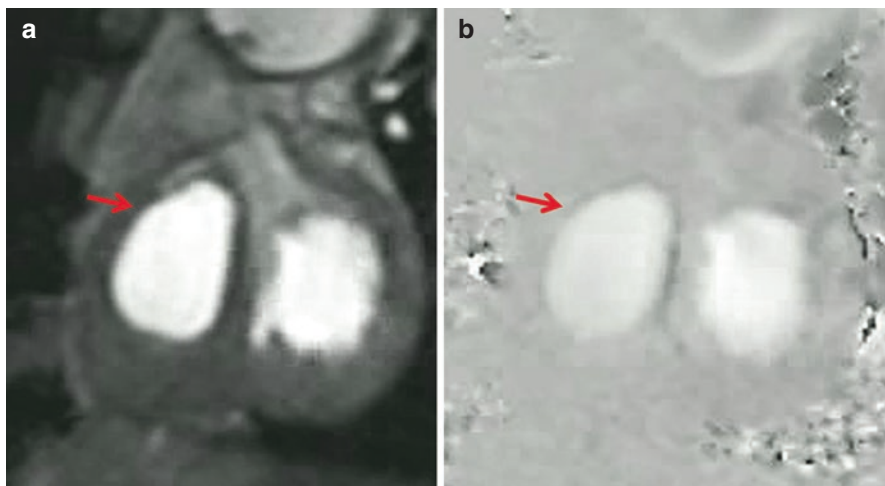


Fig. 8.3 Phase-contrast velocity mapping images, showing two sets of image (a) magnitude image, (b) phase velocity image, demonstrating the through plane phase-contrast velocity mapping through the tricuspid valve (*arrow*)

data set. The region of interest must be drawn for each frame of the cardiac cycle carefully because of movement and deformation of the vessel Fig. 8.4. Within each region of interest, the peak instantaneous velocity for each time frame can also be obtained with the simplified Bernoulli equation; the peak instantaneous gradient can be estimated by substituting in the peak instantaneous velocity. Mean pressure gradients are obtained by averaging all of the instantaneous velocities over systole [29].

- Limitations: Evaluation of TV with standard 2D phase-contrast velocity mapping sequence is hampered by cardiac motion because the imaging plane is fixed throughout the cardiac cycle [30, 31], but the TV may move up to 24 mm toward the apex during systole.

Importantly, in clinical practice there are alternative methods for calculating TV regurgitant volume:

- Subtract RV stroke volume (SV) (calculated by SSFP cine images) from forward flow volume in the pulmonary artery (measured on phase-contrast velocity mapping). The difference between the two volumes yields the TV regurgitant volume. The accuracy of this method for TV regurgitant measurement is lower in the presence of irregular rhythms or pulmonary valve regurgitation.
- TV regurgitation volume can also be obtained by calculating the difference in RV-SV and LV-SV if only the TV is involved [32].

Recently developed 4D CMR flow resolves the problem of TV annulus motion, owing to retrospective valve tracking and velocity encoding in three orthogonal

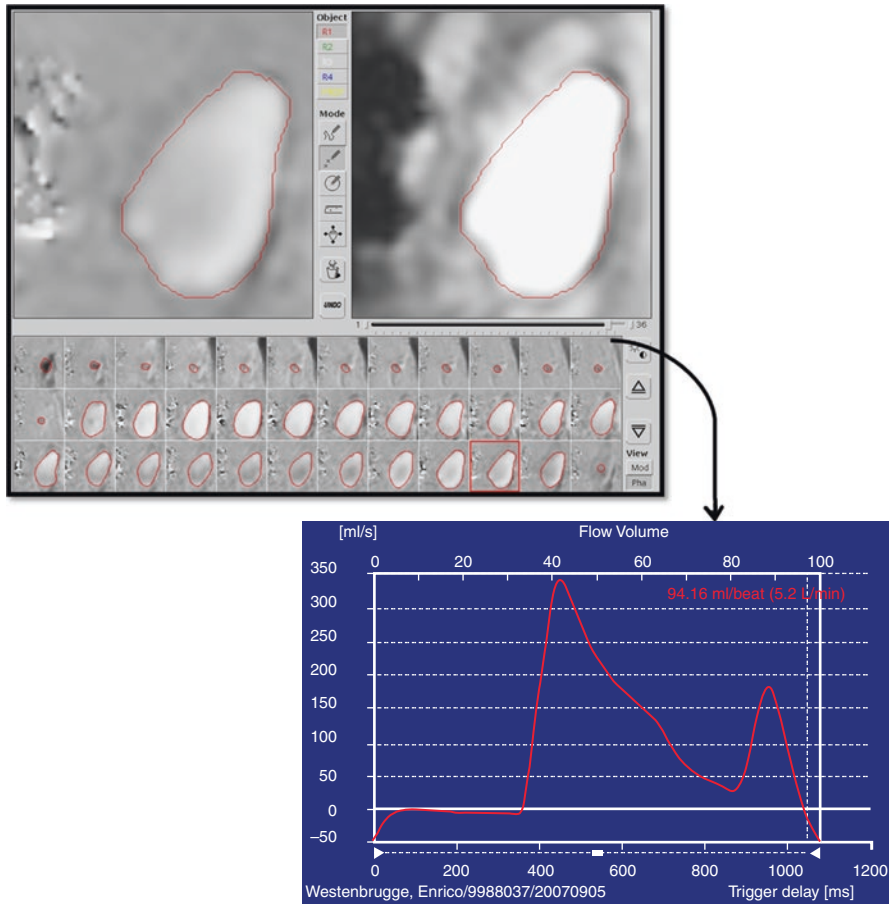


Fig. 8.4 Post processing analysis of through plane phase-contrast velocity mapping images across the tricuspid valve using MASS® program, *red contours* drawn around the tricuspid valve through the whole cardiac cycle that delivers a time flow curve of tricuspid valve flow

directions simultaneously during the cardiac cycle allowing the visualisation of complex flow patterns Fig. 8.5 [33]. 4D CMR Flow refers to phase-contrast CMR with flow-encoding in all three spatial directions that is resolved relative to all three dimensions of space and to the dimension of time along the cardiac cycle (3D + time = 4D).

4D CMR Flow visualizations offer more versatile and comprehensive depictions of flow fields than any other in-vivo imaging technique. Further, advanced 4D CMR Flow analysis parameters are currently used in the research setting but require testing for clinical utility. Future work explore the utility of this technique for TV lesions and other areas of clinical utility [34].

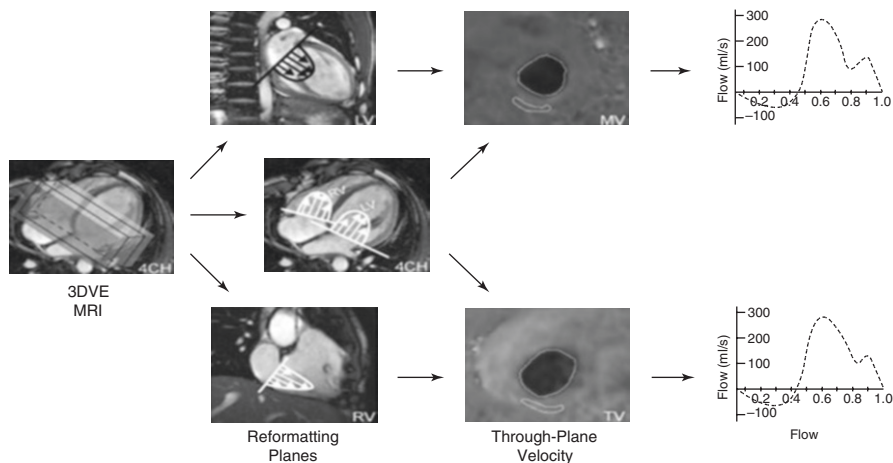


Fig. 8.5 Schematic representation of the reformation of MV flow and TV flow with 3D three-directional VE MR imaging. The 3D acquisition volume for three-directional VE MR imaging is placed at the basal level of the heart. Special attention is paid to the position of the MV and TV remaining inside this 3D volume during the whole cycle. The positions of the respective valvular planes are indicated manually in each of the phases of the cardiac cycle in the two- and four-chamber (4CH) views. The through-plane velocities in the MV plane and the TV plane are reconstructed. Integration of the velocities over the annulus, subtracted by the through-plane velocity acquired in the myocardium, results in the flow graph of the respective valve. *Arrows* indicate the order in which the steps of the procedure for flow assessment at the particular valves are performed. LV left ventricle, RV right ventricle [33]. *Adopted from Westenberget al., Radiology 2008 December;249(3):792–800*

Assessment of Right Ventricle Volume and Function

CMR provides accurate and reproducible assessment of cardiac function through acquisition of high spatial and temporal resolution images. It is recognized as the gold standard for quantification of ventricular volumes and function [35]. One of the main advantages of CMR is the ability to acquire images in any plane, which allows clear views of the cardiac valves and their inflow/outflow tracts, irrespective of thoracic anatomy or difficult cardiac anatomy. This is particularly useful for right-sided valves which can be challenging to visualize with echo [36, 37].

CMR Sequence and Image Acquisition

SSFP cine images assess the dynamic changes of cardiovascular geometry during the cardiac cycle, allowing non-invasive assessment of global and regional cardiac function. [38].

In practice, a slice thickness of 6–10 mm in adults and 5–8 mm in children can be recommended. Slices do not necessarily need to be contiguous, and a small slice gap (e.g., 2–4 mm) is acceptable to reduce the measurement and post-processing time without influencing the accuracy of measurements. Accurate measurement of ven-

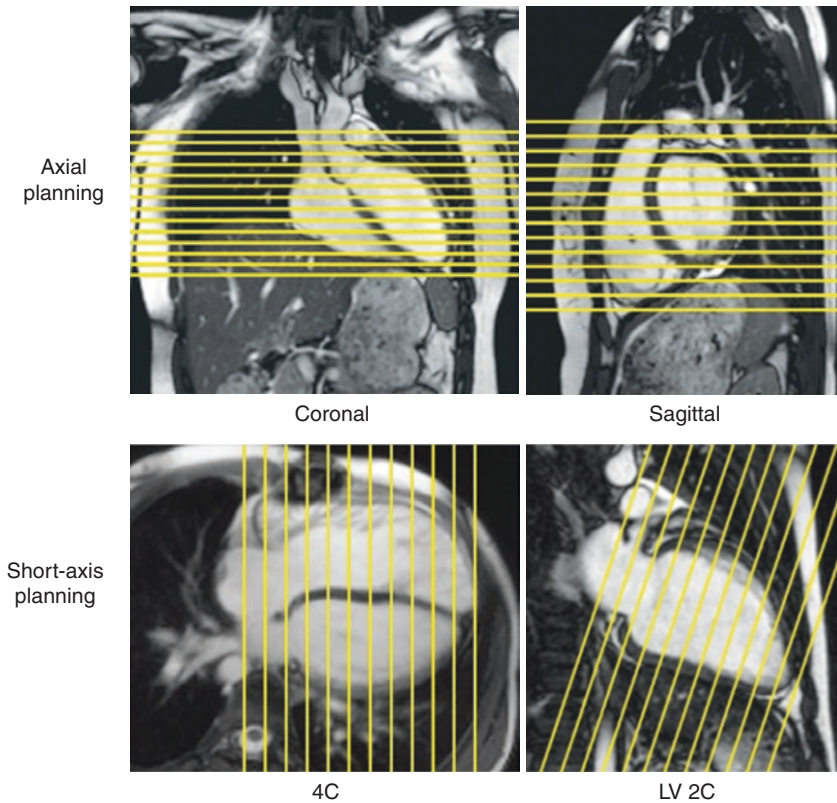


Fig. 8.6 Planning for ventriculography. An axial stack of cine images for ventriculography is planned by adjusting the slice locations on both coronal and sagittal images (*top row*). A short-axis stack of cine images for ventriculography is planned by adjusting the slice locations on 4-chamber (4C) and left ventricular 2-chamber (LV 2C) images in diastole (*bottom row*). Note that both the axial and short-axis stacks are prescribed to ensure complete coverage of the left and right ventricles. In this short-axis example, the slices are oriented perpendicular to the ventricular septum on the 4C view, and care is taken to ensure that coverage includes the anterior portion of the dilated right ventricle which extends above the tricuspid valve plane. An alternative short-axis planning approach is to orient the slices parallel to the atrioventricular valve plane on the 4C view (not shown) [40]

tricular volumes, function and mass are vital for assessing the impact of valve lesions on the ventricles. RV volumes are particularly useful as these are difficult to achieve by other methods. CMR-derived ventricular stroke volumes can also be used to quantify mitral and tricuspid regurgitation by stroke volume difference calculation [39].

The basic protocol for ventricular function assessment is very simple. A series of SSFP sequences are acquired for qualitative and quantitative assessment of regional and global systolic function. From the localizers we can obtain the vertical long axis images, followed by the horizontal long axis and the short axis images as shown in the image above Fig. 8.6 [40].

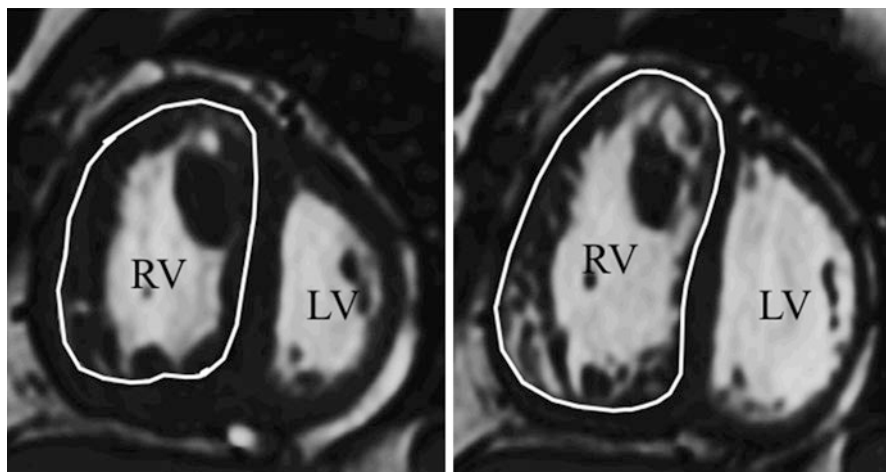


Fig. 8.7 Assessment of RV volumes in a patient with hypertrophied systemic RV after atrial switched for transposition. Short-axis view from a multi-phase steady state free precision sequence in end systole (*left*) and end diastole (*right*) showing inclusion of trabeculations and papillary muscles in the ventricular cavity. *LV* left ventricle, *RV* right ventricle

RV volumes assessment can be also obtained from acquiring an axial stack. Which can make the identification of the basal slice borders much easier [41]. There are some standardized recommendations by the society of CMR that can help maintain the accuracy and reproducibility of CMR volumetric assessment, with special emphasis on the RV [42]; (1) RV end-diastolic volumes, RV end-systolic volume, RV ejection fraction, RV-SV, and cardiac output, are better indexed to body surface area, (2) The contiguous stack of short axis or axial cine images is evaluated with computer-aided analysis packages, (3) Endocardial borders are contoured at end- diastole and end-systole phases. The RV end-diastolic image should be chosen as the image with the largest RV blood volume. For its identification, the full image stack has to be evaluated and one phase has to be identified as end-diastole for all short axis/axial locations. All contours are included just up to the pulmonary valve and but not superior to this level. Trabeculations of the RV are ignored and a smooth endocardial border is drawn to improve reader reproducibility Fig. 8.7.

Assessment of Myocardial Fibrosis

Imaging of myocardial injury or scarring has been described back in the mid-1980s. It was limited by insufficient contrast between normal and injured myocardium.

CMR Sequence and Image Acquisition

The procedure of late gadolinium enhancement (LGE) was described by Kim et al. in 2003. Injection of gadolinium chelate via an intravenous line in a bolus of 0.1–0.2 mmol/kg was described. After a 10–15 min delay the LGE sequence is acquired by a segmented T1 inversion recover gradient echo sequence [43]. An inversion time (TI) has to be properly selected to null the signal from normal myocardium, so that the contrast between scar tissue and normal myocardium is maximized Fig. 8.8 [43, 44]. The quality of LGE imaging depends on the effective nulling of signal from normal myocardium. This requires very precise selection of the appropriate inversion time.

This can also be achieved by performing a so-called TI-scout, which acquires images at multiple time delays after a single inversion pulse within the same acquisition. A sequence called TI scout is acquired with multiple inversion times to choose from before performing the actual IR-GRE sequences. The optimal TI is usually within the range of 200–250 ms [45].

Then the phase sensitive inversion recovery sequences (PSIR) was developed. It did not depend much on the choosing the accurate inversion time. Yet it showed a

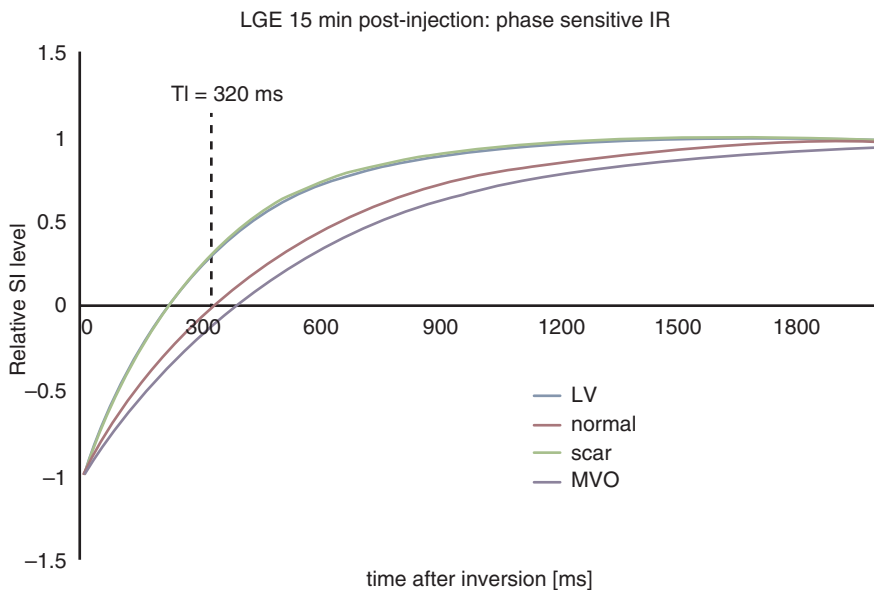


Fig. 8.8 Phase sensitive inversion recovery sequence. By using a phase sensitive reconstruction, the sign of magnetisation is reflected in the displayed signal intensity. The signal intensity is mapped onto a *grey scale* showing values of zero at the centre of the *grey scale*, positive values as higher pixel intensities (*towards white*) and negative values as lower pixel intensities (*towards black*). Using this method, the effect of a small error in the choice of optimal TI is reduced. The normal myocardial signal can be suppressed by careful windowing of grey scale [43]. Adopted from Ridgway et al. *Cardiovascular MR Manual*; 2015. p. 129–50

lower contrast to noise ratio compared to the regular inversion recovery sequences [46, 47]. 2D- and 3D-acquisition sequences are available. 3D acquisitions enable imaging of the entire heart in a single breath-hold, but are prone to image blurring.

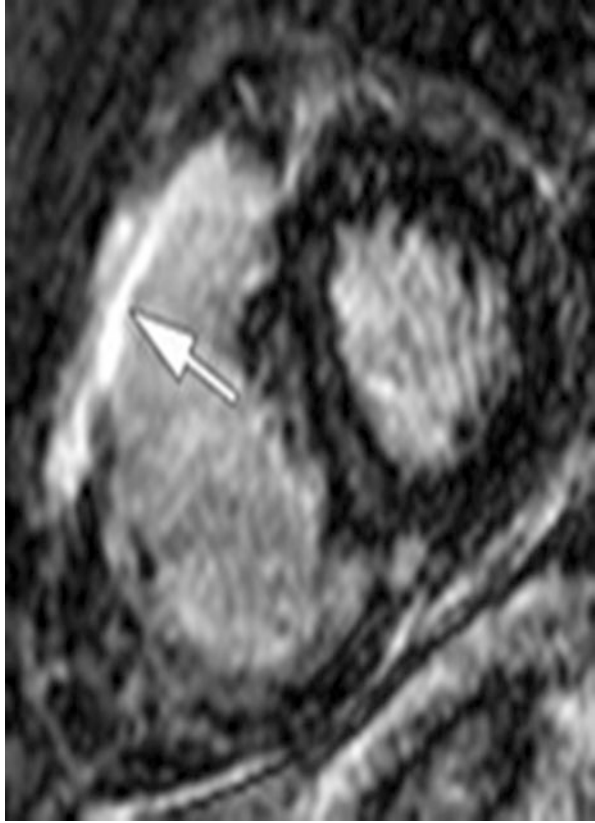
Limitations

Most studies with LGE have focused on the assessment of fibrosis in the LV. Desai and co-workers, as well as Amano et Kumazaki, suggested that the RV has a shorter optimal TI than LV. Others as Grosse-Wortmann et al. suggested that this was probably due to partial volume averaging caused by the thin wall of the RV. They suggested that if the spatial resolution was sufficient to visualize clearly the thickness of the RV myocardium, then the TIs for the RV and LV myocardium are most likely similar Fig. 8.9. In cases of TV disease, the presence or absence of myocardial fibrosis has not been proven to influence prognosis. It has been shown to be of more importance in cases of congenital anomalies of the TV [48].

Summary of CMR sequences used in evaluation of TV dysfunction

Target	CMR Pulse Sequence name	Evaluation
Anatomy	<ul style="list-style-type: none"> ▪ SSFP cine ▪ SGE cine 	<ul style="list-style-type: none"> ▪ TV Leaflet morphology ▪ TV Leaflet motion ▪ TV area ▪ Flow acceleration and turbulence ▪ Ventricular size and function ▪ Associated anatomic abnormalities of heart
Flow	<ul style="list-style-type: none"> ▪ Phase-contrast velocity mapping 	<ul style="list-style-type: none"> ▪ Forward, backward and Net flow ▪ Regurgitant volumes ▪ Maximum velocity
	<ul style="list-style-type: none"> ▪ 4D flow CMR 	<ul style="list-style-type: none"> ▪ TV flow pattern assessment ▪ TV Forward, backward, net flow ▪ Regurgitation volumes.
Tissue characterization	<ul style="list-style-type: none"> ▪ LGE 	<ul style="list-style-type: none"> ▪ Myocardial fibrosis. ▪ Tissue characterization of TV masses

Fig. 8.9 Delayed contrast hyper-enhancement (*arrow*) showing fibrosis in the RVOT using LGE sequence. *LGE* late gadolinium enhancement, *RVOT* right ventricle out flow tract



Classification of TV Dysfunction

Tricuspid Valve Regurgitation

The most common TV lesion is tricuspid regurgitation (TR). Trivial to mild TR is common (60–70%) and appears to be more common in patients more than 50 years old. [49] Although little is known about the significance of mild TR; moderate to severe TR has been associated with increased mortality [49, 50]. Causes of TR are either primary (i.e. intrinsic, organic, or structural) or secondary (i.e. functional TR with anatomically normal TV). The valve morphology can help differentiate the both groups.

Secondary Tricuspid Valve Regurgitation

This is the most common cause of the TR, representing 75% of all TR causes. TV is morphologically normal but its leaflets do not coapt completely during diastole because of valvular annulus dilation and traction of chordae tendinae secondary to

RV dilation. Function TR in RV dysfunction (due to left heart disease, RV dysplasia, ischemic RV, and systemic RV) or in RV increased afterload—due to pulmonary hypertension, pulmonary stenosis, or pulmonary embolism.

RV dilatation leads to a distortion of the normal geometric relationships of the TV leaflets, chords, and papillary muscles. With annulus flattening, the lowest point of the annulus is displaced away from the papillary muscles, resulting in tethering of the leaflets and regurgitation due to incomplete coaptation of the leaflets. The critical diameter for annular dilatation to cause functional TR is approximately 27 mm/m^2 [51].

Primary Tricuspid Valve Regurgitation

This represents 25% of all TR causes, sub-classified as either congenital or acquired lesions:

- *Congenital lesions: Ebstein anomaly (the most common), leaflet cleft, and double orifice TV.*
- *Acquired lesions: Rheumatic heart disease, infective endocarditis, endomyocardial fibrosis, carcinoid, tumors, traumatic, Iatrogenic (post VSD surgical closure, pacemaker, drugs or radiation).*

Tricuspid Valve Stenosis

It is a rare phenomenon and appears to be congenital (i.e. bicuspid, dysplastic) in most cases or, less likely, to be acquired due to endocarditis, rheumatic disease, or carcinoid [52–55].

CMR Imaging for Secondary Tricuspid Valve Regurgitation

The most important role of CMR in secondary TR is to assess the RV volumes and function, since both parameters have been considered independent predictors of TR significant [5]. CMR is considered the gold standard imaging modality to evaluate the ventricular volumes, due to its accuracy and reproducibility. Reference values of normal RV volumes and function for healthy adults are displayed in Table 8.1.

Although, there are no defined cut-off values in terms of RV volumes or EF% to indicate surgery in patients with TR, It has been stated that a preoperative RV end-diastolic volume of 164 mL/m^2 can effectively discriminated patients with normal RV EF from those with depressed EF at follow-up [56]. However, based on the European Society of Cardiology (ESC) guidelines for the management of grown-up congenital heart disease, significant RV enlargement exists when the end-diastolic volume is $\geq 150 \text{ mL/m}^2$ and significant RV dysfunction when the EF is $\leq 45\%$ [57].

Table 8.1 Reference values of normal RV parameters in healthy volunteers

Parameters	
• RV end-diastolic volume indexed	<108 mL/m ²
• RV end-systolic volume indexed	<48 mL/m ²
• Ejection Fraction (EF%)	>47%
• RV Mass indexed	>20 g/m ²

Patients with a systemic RV pose a challenging group for measuring RV volumes, as the method of delineating the cavity relative to the hypertrophied trabeculations and papillary muscles could affect RV volume and function measurements in this group of patients [58]. Although the influence of these structures on the measured ventricular volumes in individuals with normal cardiac anatomy seems of no clinical importance [59, 60].

It has been reported by Winter et al. [61] that including trabeculations and papillary muscles in the systemic RV cavity lead to a substantially higher measured RV volumes and a substantially lower calculated EF, compared to excluding these structures from the volume of the cavity.

Delineation of the RV cavity boundary outside the trabeculations and papillary muscles had the advantages of shorter analysis time and better inter-observer reproducibility. We therefore recommend the use of this approach in routine CMR measurements of systemic RV volumes Fig. 8.10.

Suggested CMR imaging protocol for the secondary TV regurgitation

Images	Goal	Interpretation/Report
1- Localizer/Scouts in 3 directions#	• Determine of heart anatomy.	-
2- SSFP cine images: • Axial stack (from base of the heart to apex) • 4 chamber view • 2 chamber right view • RVOT view	• Evaluation of RV, LV volumes and function • Evaluation of ventricular regional wall motion • Detect of TV incompetence jet	EDV-ESV-SV-EF-Mass* Ventricular wall motion abnormality TV annuls measurement
3- Velocity encoded phase contrast images: • QF tricuspid (through plane) • QF pulmonary (through plane)	• Direct assessment of TV flow+ • Indirect assessment of TR	Forward, backward, net flow RVSV-QF pulmonary = TR volume

Three directions are axial- sagittal- coronal views.

*Volumes should be indexed for BSA

+ Direct assessment of tricuspid valve flow is underestimated due to valve motion.

EDV end diastolic volume, ESV end systolic volume, SV stroke volume, EF ejection fraction, RV right ventricle, LV left ventricle, RVOT right ventricle outflow trac, TV tricuspid valve, TR tricuspid regurgitation, SSFP steady state free procession, SGE spoiled gradient echo.

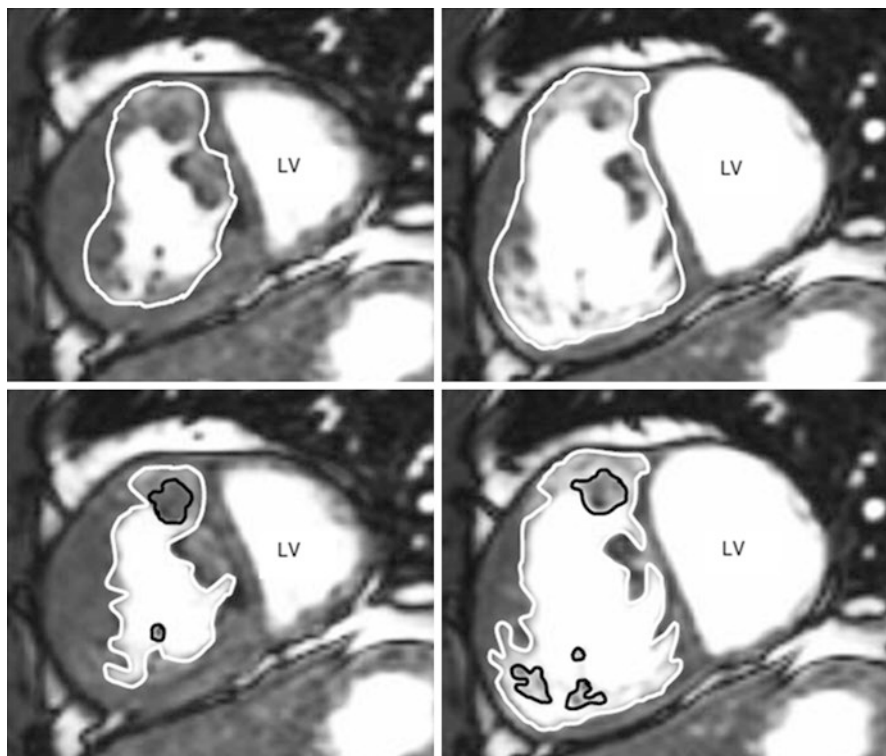


Fig. 8.10 Assessment of systemic right ventricular volumes using two different analysis protocols. Short axis view from a multi-phase steady-state free precession sequence in end systole (*left*) and end diastole (*right*) obtained in a patient with an atrially switched TGA demonstrating the two analysis protocols. Method A depicts the inclusion of trabeculations and papillary muscles in the ventricular cavity. Method B depicts the exclusion of trabeculations and papillary muscles from the ventricular cavity. LV left ventricle [60]. *Adopted from Winter et al., J Cardiovasc Magn Reson 2008 August 19;10:40*

CMR Imaging for Primary Tricuspid Valve Regurgitation

Ebstein's Anomaly

Ebstein's anomaly is a congenital abnormality that may present very early in neonatal life by severe cardiomegaly and heart failure, which can be seen on conventional radiography as the classic "box-shaped heart". It is a rare congenital anomaly of the TV (less than 1% of all congenital heart disease) occurring in about 1–5 per 200,000 live births [62].

The main diagnostic criteria of Ebstein's anomaly are; tethering of the TV leaflets (mainly the septal leaflet) to the underlying myocardium (failure of delamination); apical displacement of the functional annulus; Dilatation of the "atrialized" portion of the RV, with varying degrees of thinning of the RV wall; Redundancy of the anterior leaflet which becomes elongated "sail-like"; and dilatation of the right atrioventricular junction (true tricuspid annulus). The most typical feature is apical

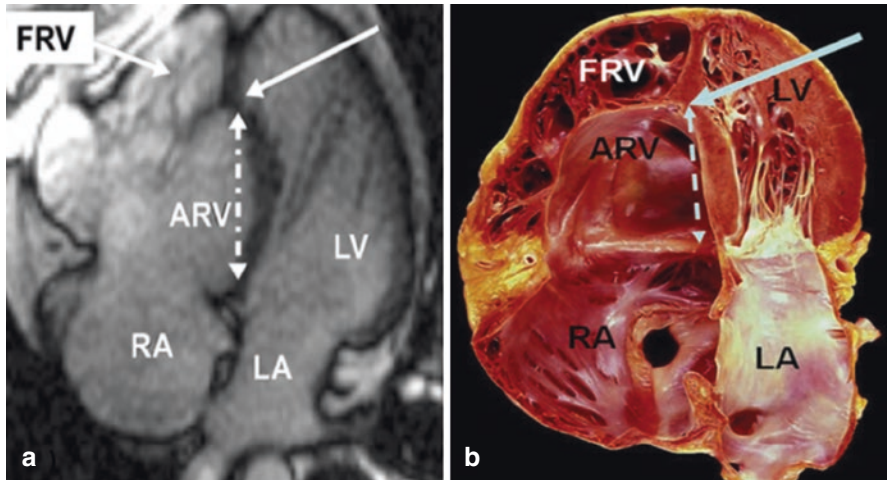


Fig. 8.11 Four chamber view from a patient with Ebstein's anomaly; (a) Cardiac magnetic resonance image. (b) Autopsy specimen. *Solid, short arrows* point to the FRV. *Solid, long arrows* point to insertion of the apically displaced septal tricuspid valve leaflet. *Broken arrows* show the measurement of displacement of the septal tricuspid leaflet. ARV atrialized right ventricle, FRV functional right ventricle, LA left atrium, LV left ventricle, RA right atrium [62]. *Adopted from Attenhofer et al. Int J Cardiovasc Imaging 2012 June;28(5):1147–59*

displacement of the hinge point of the valve from the atrioventricular ring of more than 8 mm/m² body surface area (Fig. 8.11) [63]. The anatomic severity of Ebstein's anomaly was classified based on echocardiographic appearance as mild, moderate or severe; primarily based on the amount of displacement of the leaflets, the degree of tethering of the anterior leaflet and the degree of RV dilatation [64].

In 1988, Carpentier et al. [65] proposed the following classification of Ebstein's anomaly; Type A: the volume of the true RV is adequate, Type B: a large atrialized component of the RV exists, but the anterior leaflet of the TV moves freely, Type C: the anterior leaflet is severely restricted in its movement and may cause significant obstruction of the right ventricular outflow tract, and Type D: almost complete atrialization of the RV except for a small infundibular component. The goals of surgery are to improve functional status and reduce the risk of sudden death in patients with Ebstein's anomaly.

The American College of Cardiology/American Heart Association (ACC/AHA) 2008 guidelines for surgical intervention included other criteria, as symptoms or deteriorating exercise capacity; cyanosis (O₂ saturation less than 90%); paradoxical embolism; progressive cardiomegaly on chest x-ray; and progressive RV dilation or reduction in RV systolic function. Nevertheless, the decision about whether to perform surgery in individual patients with Ebstein's anomaly is often debated because of unpredictable surgical outcomes [66].

Axial SSFP cine images used for visualizing the septal and anterior TV leaflets, coronal SSFP cine images used for assessing the atrialized RV, the RV, and the TV posterior leaflet and sagittal SSFP cine images show the infundibulum and the pattern of attachment of the TV anterior leaflet. Axial or short axis SSFP cine images are usually used for quantification of anatomical and functional RV in Ebstein's anomaly. Usually an axial stack is preferred, as the basal images in such patients are

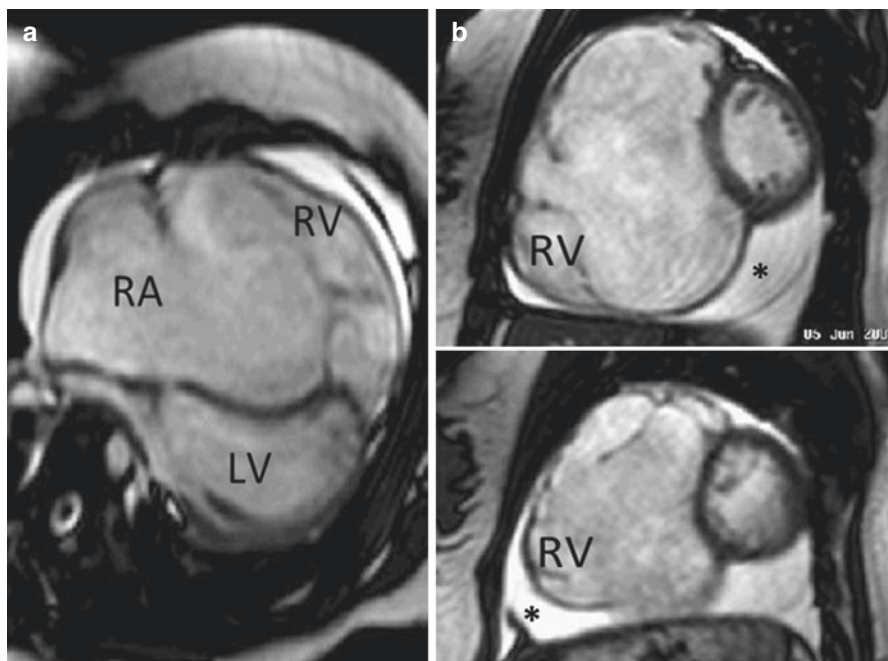


Fig. 8.12 A 14 year old girl known to suffer from Ebstein's anomaly with no previous surgical intervention. Image (a) is a long axis four chamber plane SSFP cine images showing the marked displacement of the septal leaflet of the tricuspid valve with marked dilatation of the RV which shows a large atrialized portion. Image (b) shows a series of short axis SSFP cine images. The RV is hugely dilated with very wide mouth of the TV and associated mild pericardial effusion (*). LV left ventricle, RV right ventricle, RA right atrium, SSFP steady state free procession

very difficult to assess in terms of there the outlines of the functional ventricle are Figs. 8.12 and 8.13.

CMR limitations patients with Ebstein's anomaly would be mainly the visualization of small atrial septal defects or patent foramen ovale, as well as sharp visualization of TV leaflet morphology which can be easily answered by echocardiography. Yet CMR offers quantifying of blood flow which allows reliable estimation of shunt volume. Old SGE sequences can replace SSFP sequences for better assessment of TV morphology and abnormal flow jets.

There are also emerging future CMR techniques such as T1-Mapping sequence and CMR Feature Tracking (CMR-FT) sequence that have been used in patients with Ebstein's anomaly on research basis but not established yet on the clinical. T1-Mapping measures the depiction of diffuse myocardial fibrosis through measurement of myocardial T1 times using the modified look-locker inversion recovery (MOLLI) sequence with and without gadolinium-enhanced inversion recovery-prepared sequences. CMR-FT measures the intra- and inter- ventricular dyssynchrony within, and between, the cardiac chambers by quantitating the differences in time to peak strain duration within the LV and RV and between the two chambers respectively demonstrating RV intra-ventricular dyssynchrony [67].

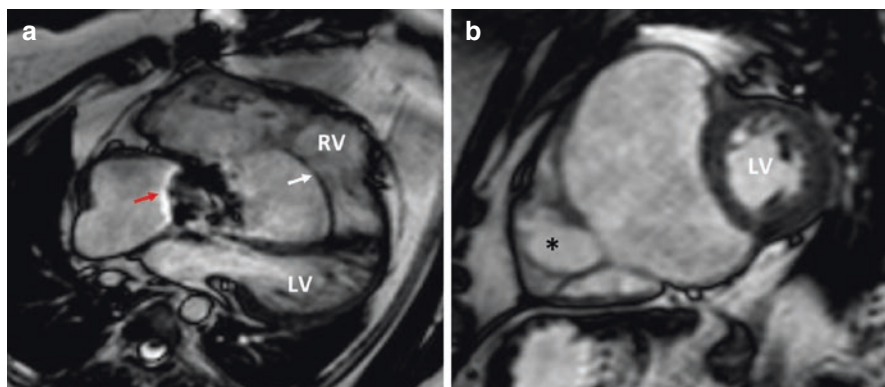


Fig. 8.13 A 16 year old boy with Ebstein's anomaly, s/p TV replacement. Long (a) and short axis (b) planes of SSFP cine images showing marked displacement of the leaflets of the TV, mainly the septal leaflet (*arrow*), with dilated anatomical RV and small functional portion of the RV (*star*). Susceptibility artifact is caused by the artificial TV (*red arrow*). LV left ventricle, RV right ventricle

Suggested CMR imaging protocol for Ebstein's anomaly

Images	Goal	Interpretation/Report
1- Localizer/Scouts in 3 directions#	Determine of heart anatomy.	-
2- SSFP versus SGE cine images: <ul style="list-style-type: none"> . Axial stack (from base of the heart to apex) . 4 chamber view . 2 chamber right view . Short axis view 	<ul style="list-style-type: none"> . Evaluation of RV, LV volumes and function, detect outlines of anatomical and functional RV . Detect of TV incompetence jet 	EDV-ESV-SV-EF-of RV* Associated atrial septal defects and TV morphology
3-Velocity encoded phase contrast images: <ul style="list-style-type: none"> . QF ascending aorta (through plane) . QF pulmonary (through plane) 	<ul style="list-style-type: none"> . Direct assessment of aortic flow . Direct assessment of pulmonary flow 	Shunt quantification by calculating Qp/Qs
4-LGE imaging (optional): <ul style="list-style-type: none"> . Axial or 4 chamber view . Short 	<ul style="list-style-type: none"> . Detection of myocardial fibrosis 	Presence or absence of myocardial fibrosis.

#Three directions are axial- sagittal- coronal views.

*Volumes should be indexed for BSAEDV end diastolic volume, ESV end systolic volume, SC stroke volume, EF ejection fraction, RV right ventricle, LV left ventricle, TV tricuspid valve, SSFP steady state free procession, SGE spoiled gradient echo

Rheumatic Heart Disease

Rheumatic heart disease remains a major origin of heart valve disease in the developing world [68, 69]. TV involvement is seen in 6.0–8.5% of cases, and TR develops in two-thirds of these patients. Imaging criteria include thickened leaflets with

restriction in motion, diastolic doming (i.e. hemispheric shape of the leaflets due to adhesion), and encroachment of the leaflet tips on the ventricular inlet [69].

Suggested CMR imaging protocol for rheumatic heart disease affecting TV

Images	Goal	Interpretation/Report
1. Localizer/Scouts in 3 directions*	Detect anatomy of the heart	-
2. SSFP cine images versus Gradient echo images:^ <ul style="list-style-type: none"> . 4 chamber view . 2 chamber right view . RVOT view . Axial stack (from base of the heart to apex) . Short axis images 	<ul style="list-style-type: none"> . Evaluation of valve leaflet morphology . Evaluation of valve leaflet motion . Detect of tricuspid valve incompetence jet . Evaluation of RV, LV volumes and function, detect outlines of anatomical and functional RV . TV area 	Description of the valve leaflet morphology and motion EDV-ESV-SV-EF- of RV*
3. Velocity encoded phase contrast images: <ul style="list-style-type: none"> . QF tricuspid valve (through plane) . QF pulmonary valve (through plane) 	<ul style="list-style-type: none"> . Direct assessment of TV flow* . Indirect assessment of TR. 	Forward, backward, net flow RVSV-QF pulmonary = TR volume

#Three directions are axial- sagittal- coronal views.
 ^ If the SSFP images are distorted by flow artefacts then SGE images are option.
 + Direct assessment of tricuspid valve flow is under estimated due to valve motion.
 *Volumes should be indexed for BSA
 EDV end diastolic volume, ESV end systolic volume, SV stroke volume, EF ejection fraction, RV right ventricle, LV left ventricle, RVOT right ventricle outflow tract, TV tricuspid valve, TR tricuspid regurgitation, SSFP steady state free procession, SGE spoiled gradient echo.

Infective Endocarditis

Infective endocarditis (IE) can involve a native TV or valve prosthesis (5–10%) [70]. TV IE is usually associated with the intravenous drug abuse. Associated findings include thickening, shortening, perforations, or complete destruction of the leaflets and intramural or para-valvular abscesses.

Infection-induced endothelial damage leads to cell death and surface deterioration [71]. Further damage may occur if endocarditis progresses into myocarditis, or if vegetation causes coronary artery embolization leading to ischemia, or if infection is spread causing destruction of the conductive tissues. Such effect of IE on the heart may be detected by CMR myocardial damage can be demonstrated non-invasively by detecting gadolinium contrast enhancement in the late phase [72]. These areas of LGE have been shown to be consistent with irreversible myocardial damage and fibrosis. Moreover, the recent CMR sequences T1 and T2 mapping help in tissue characterization [73].

In terms of detecting the vegetation or masses, the minimum size of the mass that CMR can efficiently detect has not been described; and CMR’s sensitivity and specificity have not been evaluated yet in comparison to the 2D echocardiography. However, the determination of LGE of the endothelial lining can reveal the diagno-

sis of endocarditis. CMR can also help in differential diagnosis of vegetation, such as differentiating myxomas, thrombi, lipomas, and papillary fibroelastomas (Fig. 8.14) [73, 74].

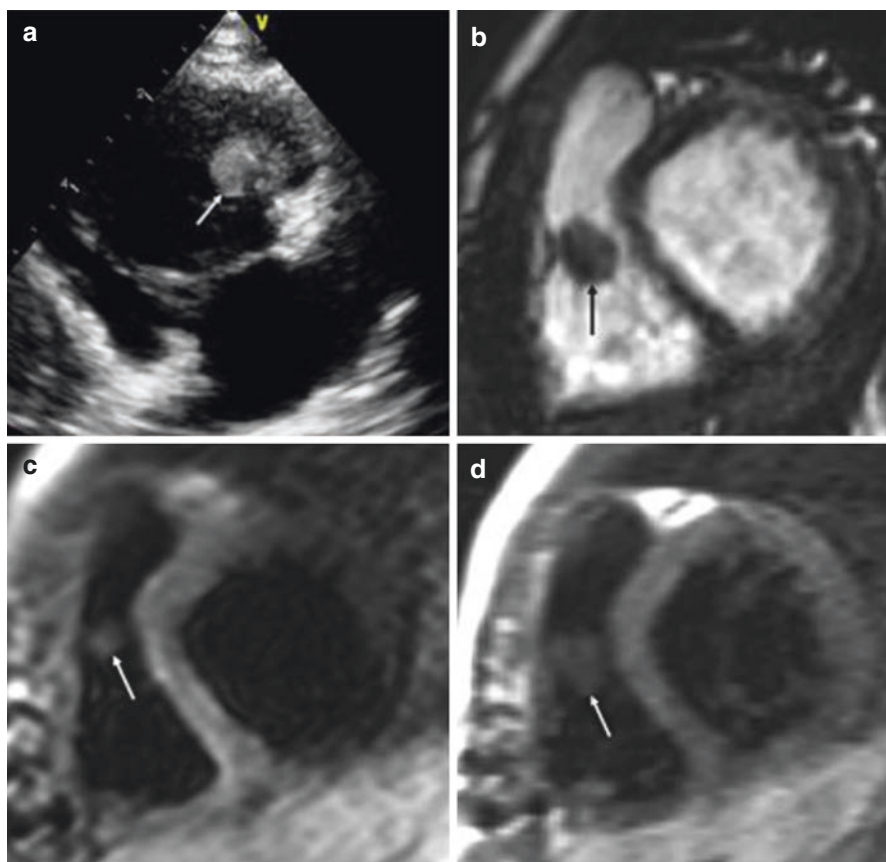


Fig. 8.14 A 4-year-old female with a vegetation in the right ventricle (RV). (a) Initial transthoracic echocardiography shows a 14×11 mm-sized highly mobile homogeneous mass (arrowhead) in RV, which is attached to the ventricular septal defect primary closure site. (b–e) CMR (b), Eight days after initial the echocardiography. The mass (white arrows) is seen in the RV, attached to the anterior wall on a short-axis-view cine MR image and shows iso-signal intensity as compared with the myocardium on T2-weighted (c) and T1-weighted (d) images. Late gadolinium-enhanced image in a short-axis view (e) demonstrates marginal rim enhancements (black arrows). (f, g) A T2 map (f) and postcontrast-T1 map image (g) show that the T2 relaxation time of the lesion is similar to that of normal left ventricular myocardium and that peripheral component (arrows) of the vegetation show lower T1 values than the myocardium. (h) Resected specimen shows a soft, round, encapsulated, and whitish mass consisting of granular tissue [73]. Adopted from *Investig Magn Reson Imaging*, 2016 Jun;20(2):114–119

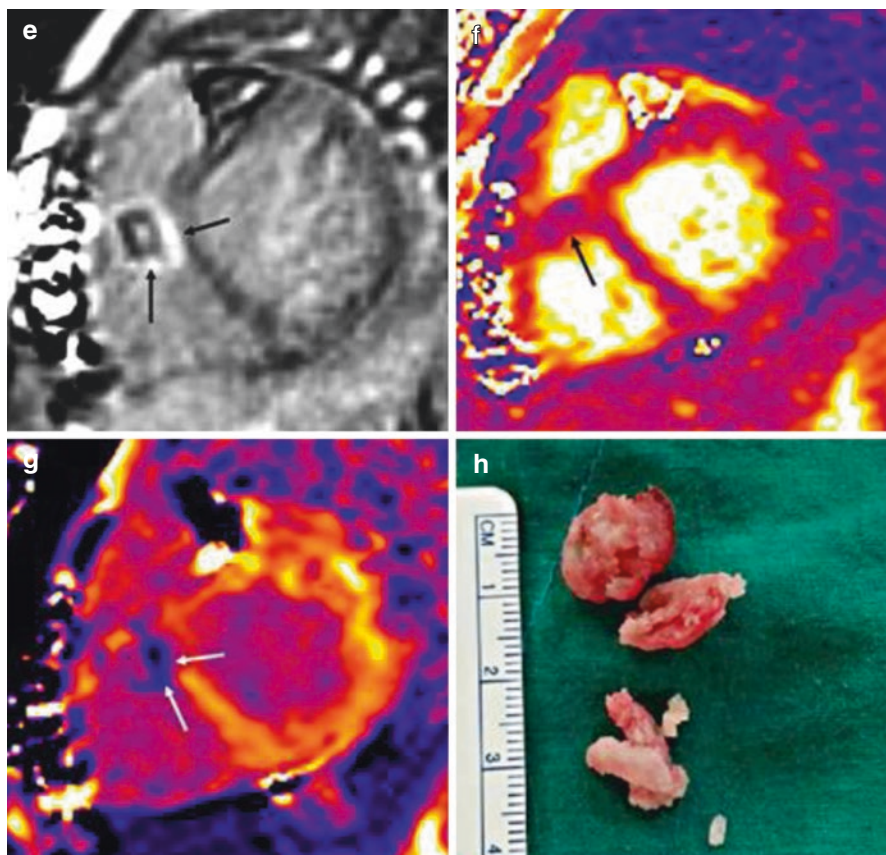


Fig. 8.14 (continued)

Carcinoid Syndrome

Carcinoid tumours are relatively rare neuroendocrine malignancies most commonly originating from enterochromaffin cells in the gastrointestinal tract and bronchus. Midgut carcinoid tumours grow slowly over years but metastasize frequently to the liver, and secrete large amounts of vasoactive substances, including 5-hydroxytryptamine, tachykinins, and prostaglandins which are largely inactivated by the liver. Carcinoid syndrome occurs when tumour cells metastasize to the liver as the vasoactive substances produced are able to reach the systemic circulation via the hepatic vein. Clinically, this is characterized by flushing, diarrhoea, and bronchospasm [75–77]. The large amount of vasoactive substances promotes deposition of fibrous tissue in a plaque-like configuration. This carcinoid plaque is composed of smooth muscle cells, myofibroblasts, extracellular matrix and an overlying endothelial cell layer. Carcinoid heart disease occurs in 40–70% of the cases with

carcinoid syndrome. The deposits occur most commonly on the endocardium of valvular cusps and leaflets, native underlying valve morphology is unharmed [78]. The right side of the heart is usually affected, in contrast the left side is less affected due to the protective inactivation of the vasoactive substances by the lungs. TV is the most frequently involved valve (97%), followed by the pulmonary valve (49%).

The TV plaques have a preponderance to develop on the ventricular side of the leaflets, causing adherence to mural endocardium and creating a substrate for regurgitation of blood volume in 90% of cases. Fibrous tissue at the valve annulus causes constriction at the ring, resulting in a degree of valvular stenosis in 10% of cases [79].

CMR has an additive value for evaluation of the RV function and quantification of the volumes of the right heart in a reproducible and accurate manner. This assessment has a central role in decision-making on the long term. Diagnostic accuracy is improved by CMR where echocardiographic image quality is suboptimal [3]. Also, quantification of the dysfunction of the tricuspid and pulmonary valve by phase encoding contrast images is informative [80]. Fibrotic carcinoid plaques can be detected using LGE mages. CMR gives a unique opportunity to detect this signal alteration in the valve, valvular annulus, sub-valvular apparatus and even endocardium. Cardiac nodular metastatic invasion is rare (less than 5% of patients) but can easily be demonstrated, as well as extension into extra-cardiac structures (Fig. 8.15) [79, 81].

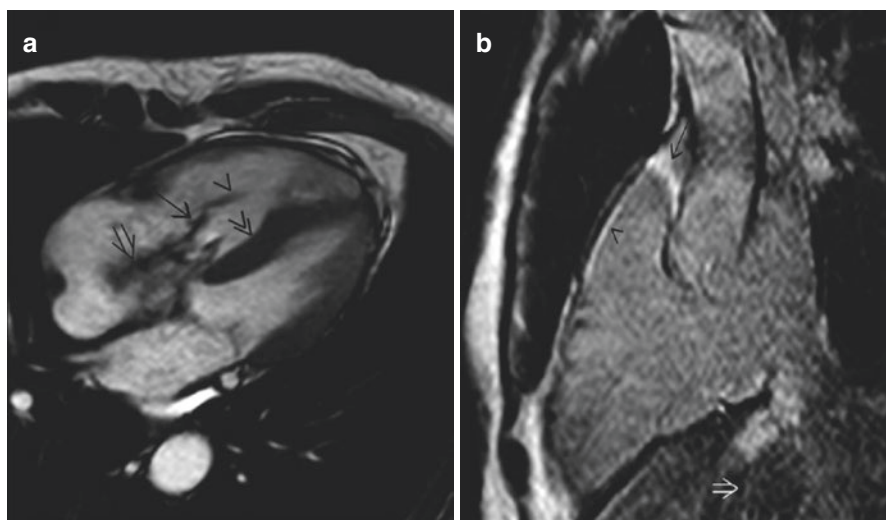


Fig. 8.15 CMR BFFE. (a) Dilatation of the right heart with tricuspid valve leaflet (arrow) and choralad thinking (head arrow). Fixed tricuspid valve, with severe regurgitation (black flow jet). Flattened interventricular septum. (b) Late enhanced T1 gradient echo 3D TFE sagittal view of the right ventricular outflow tract (RVOT). Pronounced abnormal enhancement of the leaflets of the pulmonary valve and the endocardial surface in the RVOT. Nodular liver lesion. BFFE balanced fast field echo, TFE turbo field echo [81]. Adopted from Moerman et al., *Acta Cardiol* 2012 April;67(2):245–8

Suggested CMR imaging protocol for infective endocarditis and carcinoid syndrome

Images	Goal	Interpretation / Report
1. Localizers/Scouts in 3 directions	Detect anatomy of the heart	-
2- SSFP cine images versus Gradient echo images: [^] <ul style="list-style-type: none"> . 4 chamber view . 2 chamber right view . RVOT view . Axial stack (from base of the heart to apex) . Short axis images 	<ul style="list-style-type: none"> . Evaluation of valve leaflet morphology . Evaluation of valve leaflet motion . Detect of tricuspid valve incompetence jet . Evaluation of RV, LV volumes and function, detect outlines of anatomical and functional RV . Valve area 	Description of the valve leaflet morphology and motion EDV-ESV-SV-EF-of RV*
3. Velocity encoded phase contrast images: <ul style="list-style-type: none"> . QF tricuspid valve (through plane) . QF pulmonary (through plane) 	<ul style="list-style-type: none"> . Direct assessment of tricuspid flow+ . Indirect assessment of TR. 	Forward, backward, net flow RVSV-QF pulmonary = TR volume
4. First pass perfusion images* <ul style="list-style-type: none"> . 4 chamber view . 2 chamber right view . RVOT view 	<ul style="list-style-type: none"> . Determine if the mass on TV is vascular or not 	Vascular or not
5. Late contract hyper-enhancement images <ul style="list-style-type: none"> . 4 chamber view . 2 chamber right view . RVOT view 	Detect fibrosis of the mass and RV wall	Site, size of the fibrosis Mass homogeneity

#Three directions are axial- sagittal- coronal views.

[^]Differentiate between vegetation, thrombus, and tumours

+ Direct assessment of tricuspid valve flow is underestimated due to valve motion.

*Volumes should be indexed for BSA

EDV end diastolic volume, ESV end systolic volume, SV stroke volume, EF ejection fraction, RV right ventricle, LV left ventricle, TV tricuspid valve, TR tricuspid regurgitation, RVOT right ventricle out flow tract, SSFP steady state free procession, SGE spoiled gradient echo.

Tumors

Cardiac tumours are rare, with prevalence at autopsy of 0.002–0.3%. About 75% of cardiac tumours are benign, the most common of which in adult population are cardiac myxomas, followed by papillary fibroelastomas, lipomas, and hemangiomas. Rhabdomyomas and fibromas are the main benign tumours in the paediatric age group. Valvular tumors are rare and they are characterized by a smaller size, greater mobility, and more significant tendency to embolise. The majority of valvular tumors are papillary fibroelastomas. Metastases are far more common than primary malignant cardiac tumours. They occur either by direct invasion from neighbouring organs or by hematogenous spread. The most common primary

tumours spreading to the heart are melanomas, bronchogenic and breast carcinomas. The most common primary malignant cardiac tumours are sarcomas and lymphomas [82].

CMR offers the value of its larger field of view, excellent tissue characterization, versatility in imaging planes, dynamic and post contrast CMR imaging giving additional tissue properties such as vascularity and fibrosis. CMR can contribute to the diagnosis of the nature of a cardiac mass as well as its relationship to other cardiac and extra-cardiac structures, which echocardiography is unable to identify. Serial CMR studies can be used to monitor tumour regression after surgery or chemotherapy [82]. The most important CMR features that can help differentiate mass lesions were suggested by several publications; motion, heterogeneity, and mobility, tissue characterization, first-pass perfusion, LGE, and TI scout and T1 mapping [83].

Papillary fibroelastomas are usually smaller than 1 cm, attached to the valve by a short stalk, thereby having greater freedom and mobility, which might explain the frequent occurrence of embolic events. They can be reliably diagnosed by echocardiography. Typical CMR imaging features are of a small, highly mobile homogeneous valvular mass (usually attached to the downstream side with a small pedicle); hypointense signal intensity and surrounding turbulent flow on cine images; and isointense T1 and hyperintense T2 signal intensity patterns.

Myxomas are the most common primary cardiac tumours with a growing predilection on the interatrial septum of the left atrium. Valvular myxomas are very rare accounting for 8.8% of cardiac myxomas. They are gelatinous, lobulated tumors, often solitary with a short stalk. Echocardiography is very helpful in the evaluation of a suspected valvular myxoma in determining the location, size, attachment, and influence on valve function. On CMR images, they appear isointense on T1-weighted images and have higher signal intensity on T2-weighted images owing to the high extracellular water content. Regions of acute haemorrhage within myxomas appear hypointense on both T1- and T2-weighted images, and older regions appear hyperintense as the haemoglobin becomes oxidized to methemoglobin. SSFP cine imaging is very useful in the work-up of myxomas as they are highly mobile, occasionally prolapsing through the mitral valve and causing obstruction. With SSFP cine techniques, myxomas appear hyperintense relative to the myocardium but hypointense relative to the blood pool. Internally, myxomas may contain cysts, regions of necrosis, haemorrhage, and calcification, which lead to a typically heterogeneous appearance at contrast enhancement. Many myxomas have a layer of surface thrombus, with low signal intensity on LGE images [82] (Fig. 8.16).

Primary cardiac malignancies are very rare; they include lymphomas, sarcomas and mesothelial tumours. Large, bulky masses with vascular encasement without obliteration of lumen are typical features of lymphoma. Sarcomas usually present as bulky masses with irregular margins and invasive features involving one or more chambers; they may show heterogeneous enhancement due to the presence of necrosis or haemorrhage. These tumours may be associ-

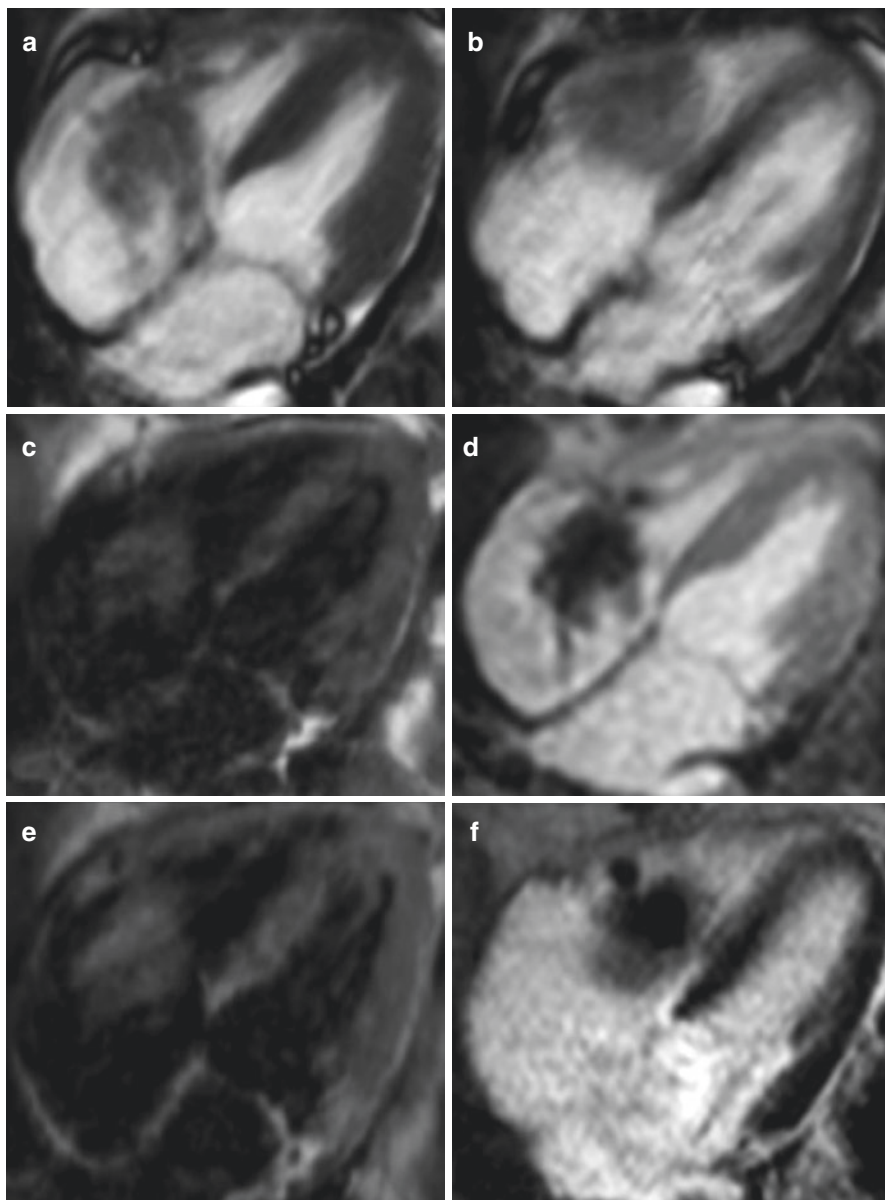
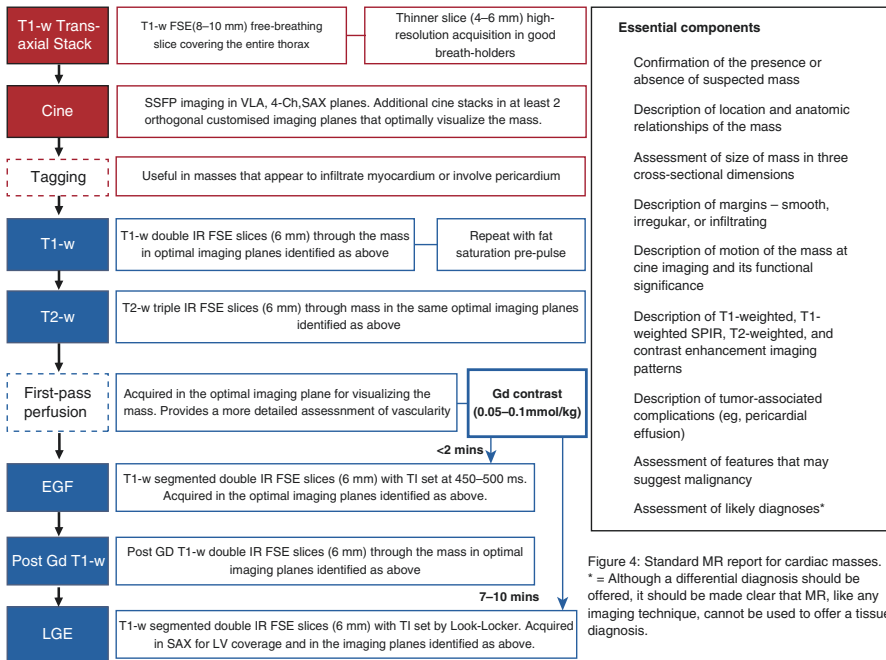


Fig. 8.16 A 54 year old female patient with a sizable mobile tricuspid valve mass seen by echocardiography. CME images: (a–b) cine SSFP images in four chamber plane in systole and diastole, showing the mass behind attached to the posterior leaflet of the tricuspid valve with no signs on invasive behavior. It is rather mobile with leaflet excursion. (c–e) T1 pre- and post-contrast images, as well as (d) first pass perfusion and (f) LGE images show patchy mainly peripheral enhancement of the sizable mass. Overall features are suggestive of a tricuspid valve myxoma

Table 8.2 Proposed core protocol for MR imaging of cardiac masses



Sequences in red are used for localization of the mass. Sequences in blue are used for tissue characterization. Tagging and rest-pass perfusion sequences are optional sequences that can supplement the core data set. The second bolus of gadolinium (*Gd*)-based contrast material is given with the rest-pass perfusion sequence, if performed, or alternatively as a top-up dose prior to early gadolinium enhancement (EGE) imaging [82]

4-Ch four chamber, *IR* inversion recovery, *LV* left ventricle, *SAX* short-axis, *T1-w* T1-weighted, *T2-w* T2-weighted, *VLA* vertical long axis

ated with pericardial effusions and metastasis to mediastinal nodes, lungs and other organs [81].

Secondary metastases to the heart are more common, most frequently from melanoma, lung, breast, and gastric carcinomas. They may show intramural or pericardial involvement and superior or inferior vena cava metastases. Signal characteristics and contrast enhancement features are variable in metastatic lesions [84].

However, the most common type of cardiac mass is in fact “pseudotumors,” such as intracardiac thrombus or misinterpreted normal anatomic variants [82]. **Cardiac thrombi** are more common than tumours, and timely diagnosis and treatment are mandatory. On CMR, a thrombus shows variable T1- and T2-weighted signal characteristics depending on its age. Contrast-enhanced MR imaging with first pass perfusion, early, and LGE imaging enables clear differen-

tiation of thrombus from surrounding myocardium because a thrombus is avascular and hence characterized by an absence of contrast material uptake [82, 85] (Table 8.2).

Suggested CMR imaging protocol for cardiac tumours

We agree upon the suggested protocol for cardiac masses as demonstrated by Motwani et al.⁸¹

Traumatic

Surgical closure of ventricular septal defect (VSD) considered one of the most common surgeries in patients with congenital heart diseases. For closing a VSD, temporary detachment of the TV leaflets may provide better exposure of the defect in the usual trans-atrial approach [86]. However, this technique carries the risk of TV regurgitation which might be needed to be repaired [87]. This traumatic TR should be considered as secondary TR (Sect. “[Secondary Tricuspid Valve Regurgitation](#)”).

Patients with a permanent pacemaker or automatic implantable cardioverter-defibrillator leads have an increased prevalence of significant TR. TR can be caused by direct lead interference with valve closure, laceration or perforation, infection, and fibrous adhesions. After lead implantation, 18% of patients with baseline mild TR develop moderate to severe TR [88]. Particularly on this group of patients CMR has a limited role as having implanted pacemaker or ICD still consider a contraindication for CMR.

CMR Imaging for Tricuspid Stenosis (TS)

TS is most commonly of rheumatic origin in underdeveloped countries. Other possible causes of TS are: congenital tricuspid atresia, carcinoid syndrome, endomyocardial fibrosis, metabolic or enzymatic diseases, or right atrial tumours.

It has been agreed upon that echocardiography enables a definitive diagnosis of the cause and severity of TS. The rheumatic aetiology is suggested by commissural fusion and diastolic doming with thickened leaflets and shortened chordae [89]. Although CMR is feasible in evaluating TS, it is not used routinely in this setting. Valve area can be assessed by placing of an image slice through the valve tips in diastole and measuring forward velocity through the valve. CMR is less effective than echocardiography in the detection of vegetation of the valvular leaflets [90]. CMR has a bigger role in assessment of congenital tricuspid valve

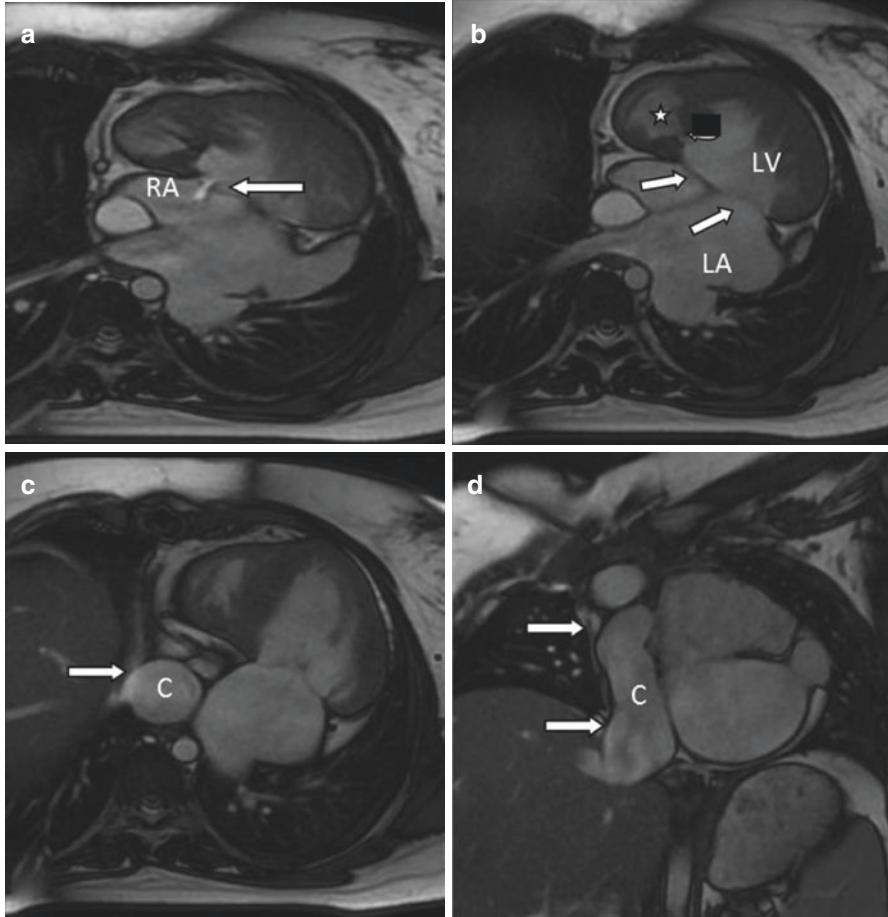


Fig. 8.17 A 16 year old female patient with double inlet left ventricle, severe tricuspid stenosis, S/P Fontan operation. Series of axial and coronal SSFP images. (a) Axial SSFP cine shows jet of tricuspid regurgitation and stenosis respectively (*arrow*). (b) Axial SSFP cine shows that both AV valves commit to the LV (*arrows*), with an associated small VSD (*curved arrow*) and a rudimentary RV (*star*). Images (c) axial SSFP cine and (d) coronal SSFP cine show patent extracardiac Fontan conduit (*arrows*). LA left atrium, LV left ventricle, RA right atrium, C conduit

atresia to solve unanswered clinical questions by echocardiography. This is especially important in cases of postoperative assessment. CMR can evaluate anatomical and functional data, with assessment of ventricular volumes and function, flow dynamics, shunt quantification, and postoperative sequelae or complications. Also, it helps to assess patients with TV atresia who undergoing several surgical procedures, e.g. bidirectional Glenn planned for completion on a Fontan

circulation. CMR allows assessment of the Fontan connections, branch pulmonary arteries, pulmonary, the atrioventricular valve(s), the ventricle(s), the ventricular outflow tract, and any residual leaks (with CMR) or collateral vessels using cine imaging as well as gadolinium enhanced angiography and 3D SSFP sequences. Velocity mapping can be used to assess flow through a suspected narrowing Fig. 8.17.

Suggested CMR imaging protocol of TS.
 PS: In clinical practice for TS evaluation CMR is not used on routine basis.

Images	Goal	Interpretation / Report
1. Localizers/Scouts in 3 directions*	Detect anatomy of the heart	-
2. SSFP cine images versus Gradient echo images: <ul style="list-style-type: none"> . 4 chamber view . 2 chamber right view . RVOT view . Short axis images . Oblique planes according to clinical question 	Evaluation of intra-cardiac anatomy Detect anatomy, surgical shunts, and vascular measurements	Description of cardiac morphology and function Detection of surgical baffles and Describe postoperative complications.
3. Velocity encoded phase contrast images: <ul style="list-style-type: none"> . QF tricuspid (In plane) 	<ul style="list-style-type: none"> . Direct assessment of TV flow velocity.+ 	Assessment of maximum velocity across the TV

#Three directions are axial- sagittal- coronal views.
 +Velocity measurement by CMR is underestimated compared to echocardiography.
 TV tricuspid valve, RVOT right ventricle out flow tract, SSFP steady state free procession, SGE spoiled gradient echo.

Conclusion

The strength of CMR in TV assessment is its ability to offer a comprehensive examination in terms of morphology and associated structures assessment, in addition to right ventricular volumes, mass and systolic function assessment. CMR may also provide a quantitative measure of TV stenosis and regurgitation, including regurgitant volume and fraction.

Unlike echocardiography, CMR imaging is not dependent on the presence of adequate acoustic windows, and less dependent on operator experience for consistently obtaining interpretable images. CMR offers excellent spatial resolution and, with ECG gating, has acceptable temporal resolution, which approaches echocardiography. When compared to multi-slice computerized tomography, CMR uses no

ionizing radiation, allowing for safe a serial examination which is an important consideration in following patients over many decades.

On the other hand, the disadvantages of CMR use include its current relative inability to be used for patients with certain types of metallic implants, most importantly pacemakers and internal cardioverters defibrillators. The initial setup of a CMR laboratory is considerably costly, and interpretation of CMR images is relatively more complex and experience/knowledge-demanding. In addition, echocardiographic criteria for TV lesions have been validated and compared with clinical outcomes, data that are not yet available for CMR criteria, a relatively young imaging modality.

Given the potential strengths of CMR, prospective studies of clinical outcome, using quantitative and qualitative CMR data to guide management of TV dysfunction, are needed to enhance CMR as a strong tool for guiding clinical practice.

Review Questions

Select the Single Best Sentence

48. Which of the following statement regarding Cardiac MRI (CMR) assessment of tricuspid valve is correct?
- (a) CMR slice thickness is often similar to TV leaflet thickness (1–2 mm)
 - (b) The slice thickness of CMR images is typically 5–8 mm
 - (c) The slice thickness of steady state free-precession (SSFP) sequences is 2 mm
 - (d) The slice thickness of the spoiled gradient echo (SGE) sequences is 1 mm
49. Which of the following statement regarding Cardiac MRI (CMR) assessment of tricuspid regurgitation volume is correct?
- (a) CMR 2D phase-contrast velocity mapping sequence is the standard method for tricuspid regurgitation fraction calculation
 - (b) 4D CMR flow is more accurate method for tricuspid regurgitation fraction calculation than 2D CMR phase-contrast flow
 - (c) Cardiac motion is a major limitation of 4D flow
 - (d) None of the above
50. Which of the following statement regarding Cardiac MRI (CMR) assessment of patients with tricuspid regurgitation is correct?
- (a) CMR is more accurate than echocardiography for the assessment of right heart function
 - (b) CMR is more accurate than echocardiography for the assessment of tricuspid valve leaflets
 - (c) CMR is more accurate than echocardiography for the assessment of papillary muscles
 - (d) CMR is less accurate than echocardiography for the assessment of tricuspid annulus

References

1. Choo WS, Steeds RP. Cardiac imaging in valvular heart disease. *Br J Radiol.* 2011;84(Spec No 3):S245–57.
2. Vogel M, Gutberlet M, Dittrich S, Hosten N, Lange PE. Comparison of transthoracic three dimensional echocardiography with magnetic resonance imaging in the assessment of right ventricular volume and mass. *Heart.* 1997;78(2):127–30.
3. Bastarrika G, Cao MG, Cano D, Barba J, de Buruaga JD. Magnetic resonance imaging diagnosis of carcinoid heart disease. *J Comput Assist Tomogr.* 2005;29(6):756–9.
4. Pignatelli RH, McMahon CJ, Chung T, Vick GW III. Role of echocardiography versus MRI for the diagnosis of congenital heart disease. *Curr Opin Cardiol.* 2003;18(5):357–65.
5. Fukuda S, Saracino G, Matsumura Y, et al. Three-dimensional geometry of the tricuspid annulus in healthy subjects and in patients with functional tricuspid regurgitation: a real-time, 3-dimensional echocardiographic study. *Circulation.* 2006;114(1 Suppl):I492–8.
6. Anwar AM, Soliman OI, Nemes A, van Geuns RJ, Geleijnse ML, Ten Cate FJ. Value of assessment of tricuspid annulus: real-time three-dimensional echocardiography and magnetic resonance imaging. *Int J Cardiovasc Imaging.* 2007;23(6):701–5.
7. Cawley PJ, Maki JH, Otto CM. Cardiovascular magnetic resonance imaging for valvular heart disease: technique and validation. *Circulation.* 2009;119(3):468–78.
8. Krombach GA, Kuhl H, Bucker A, et al. Cine MR imaging of heart valve dysfunction with segmented true fast imaging with steady state free precession. *J Magn Reson Imaging.* 2004;19(1):59–67.
9. Saremi F, Hassani C, Millan-Nunez V, Sanchez-Quintana D. Imaging evaluation of tricuspid valve: analysis of morphology and function with CT and MRI. *AJR Am J Roentgenol.* 2015;204(5):W531–42.
10. Boxt LM. Magnetic resonance and computed tomographic evaluation of congenital heart disease. *J Magn Reson Imaging.* 2004;19(6):827–47.
11. Helbing WA, Rebergen SA, Maliepaard C, et al. Quantification of right ventricular function with magnetic resonance imaging in children with normal hearts and with congenital heart disease. *Am Heart J.* 1995;130(4):828–37.
12. Gerola LR, Wafae N, Vieira MC, Juliano Y, Smith R, Prates JC. Anatomic study of the tricuspid valve in children. *Surg Radiol Anat.* 2001;23(3):149–53.
13. Silver MD, Lam JH, Ranganathan N, Wigle ED. Morphology of the human tricuspid valve. *Circulation.* 1971;43(3):333–48.
14. Martinez RM, O'Leary PW, Anderson RH. Anatomy and echocardiography of the normal and abnormal tricuspid valve. *Cardiol Young.* 2006;16(Suppl 3):4–11.
15. Aktas EO, Govsa F, Kocak A, Boydak B, Yavuz IC. Variations in the papillary muscles of normal tricuspid valve and their clinical relevance in medicolegal autopsies. *Saudi Med J.* 2004;25(9):1176–85.
16. Taramasso M, Vanermen H, Maisano F, Guidotti A, La CG, Alfieri O. The growing clinical importance of secondary tricuspid regurgitation. *J Am Coll Cardiol.* 2012;59(8):703–10.
17. Ton-Nu TT, Levine RA, Handschumacher MD, et al. Geometric determinants of functional tricuspid regurgitation: insights from 3-dimensional echocardiography. *Circulation.* 2006;114(2):143–9.
18. Duerk JL. Principles of MR image formation and reconstruction. *Magn Reson Imaging Clin N Am.* 1999;7(4):629–59.
19. Mugler JP III. Overview of MR imaging pulse sequences. *Magn Reson Imaging Clin N Am.* 1999;7(4):661–97.
20. Maeba S, Taguchi T, Midorikawa H, Kanno M, Sueda T. Four-dimensional geometric assessment of tricuspid annulus movement in early functional tricuspid regurgitation patients indicates decreased longitudinal flexibility. *Interact Cardiovasc Thorac Surg.* 2013;16(6):743–9.

21. Wintersperger BJ, Becker CR, Gulbins H, et al. Tumors of the cardiac valves: imaging findings in magnetic resonance imaging, electron beam computed tomography, and echocardiography. *Eur Radiol.* 2000;10(3):443–9.
22. Pollak Y, Comeau CR, Wolff SD. *Staphylococcus aureus* endocarditis of the aortic valve diagnosed on MR imaging. *AJR Am J Roentgenol.* 2002;179(6):1647.
23. Sievers B, Brandts B, Franken U, Trappe HJ. Cardiovascular magnetic resonance imaging demonstrates mitral valve endocarditis. *Am J Med.* 2003;115(8):681–2.
24. Evans AJ, Blinder RA, Herfkens RJ, et al. Effects of turbulence on signal intensity in gradient echo images. *Investig Radiol.* 1988;23(7):512–8.
25. Westermann Y, Geigenmuller A, Elgeti T, et al. Planimetry of the aortic valve orifice area: comparison of multislice spiral computed tomography and magnetic resonance imaging. *Eur J Radiol.* 2011;77(3):426–35.
26. Wagner S, Auffermann W, Buser P, et al. Diagnostic accuracy and estimation of the severity of valvular regurgitation from the signal void on cine magnetic resonance images. *Am Heart J.* 1989;118(4):760–7.
27. Suzuki J, Caputo GR, Kondo C, Higgins CB. Cine MR imaging of valvular heart disease: display and imaging parameters affect the size of the signal void caused by valvular regurgitation. *AJR Am J Roentgenol.* 1990;155(4):723–7.
28. Gatehouse PD, Keegan J, Crowe LA, et al. Applications of phase-contrast flow and velocity imaging in cardiovascular MRI. *Eur Radiol.* 2005;15(10):2172–84.
29. Mostbeck GH, Caputo GR, Higgins CB. MR measurement of blood flow in the cardiovascular system. *AJR Am J Roentgenol.* 1992;159(3):453–61.
30. Kayser HW, Stoel BC, Van der Wall EE, van der Geest RJ, de Roos A. MR velocity mapping of tricuspid flow: correction for through-plane motion. *J Magn Reson Imaging.* 1997;7(4):669–73.
31. Kilner PJ, Gatehouse PD, Firmin DN. Flow measurement by magnetic resonance: a unique asset worth optimising. *J Cardiovasc Magn Reson.* 2007;9(4):723–8.
32. Hundley WG, Li HF, Willard JE, et al. Magnetic resonance imaging assessment of the severity of mitral regurgitation. Comparison with invasive techniques. *Circulation.* 1995;92(5):1151–8.
33. Westenberg JJ, Roes SD, Ajmone MN, et al. Mitral valve and tricuspid valve blood flow: accurate quantification with 3D velocity-encoded MR imaging with retrospective valve tracking. *Radiology.* 2008;249(3):792–800.
34. Dyverfeldt P, Bissell M, Barker AJ, et al. 4D flow cardiovascular magnetic resonance consensus statement. *J Cardiovasc Magn Reson.* 2015;17:72.
35. Rajappan K, Livieratos L, Camici PG, Pennell DJ. Measurement of ventricular volumes and function: a comparison of gated PET and cardiovascular magnetic resonance. *J Nucl Med.* 2002;43(6):806–10.
36. Myerson SG. Heart valve disease: investigation by cardiovascular magnetic resonance. *J Cardiovasc Magn Reson.* 2012;14:7.
37. Bogaert J. Cardiac function. In: Bogaert J, Dymarkowski S, Taylor AM, Muthurangu V, editors. *Clinical cardiac MRI.* 2nd ed. Berlin: Springer-Verlag; 2012. p. 109–65.
38. Ridgway JP. Cardiovascular magnetic resonance physics for clinicians: part I. *J Cardiovasc Magn Reson.* 2010;12:71.
39. Thavendiranathan P, Phelan D, Collier P, Thomas JD, Flamm SD, Marwick TH. Quantitative assessment of mitral regurgitation: how best to do it. *JACC Cardiovasc Imaging.* 2012;5(11):1161–75.
40. Fratz S, Chung T, Greil GF, et al. Guidelines and protocols for cardiovascular magnetic resonance in children and adults with congenital heart disease: SCMR expert consensus group on congenital heart disease. *J Cardiovasc Magn Reson.* 2013;15:51.
41. Wright J, Bogaert J. CMR-Basic principles. In: Zambrano J, Bax J, Knuuti J, Sechtem U, Lancellotti P, Badano L, editors. *The ESC textbook of cardiovascular imaging.* 2nd ed. Oxford: Oxford Press; 2016. p. 55–63.
42. Schulz-Menger J, Bluemke DA, Bremerich J, et al. Standardized image interpretation and post processing in cardiovascular magnetic resonance: Society for Cardiovascular Magnetic

- Resonance (SCMR) board of trustees task force on standardized post processing. *J Cardiovasc Magn Reson.* 2013;15:35.
43. Biglands JD, Radjenovic A, Ridgway JP. Cardiovascular magnetic resonance physics for clinicians: part II. *J Cardiovasc Magn Reson.* 2012;14:66.
 44. Ridgway JP. Special pulse sequences for cardiac imaging. In: Plein S, Greenwood J, Ridgeway JP, editors. *Cardiovascular MR manual.* Heidelberg: Springer International Publishing; 2015. p. 129–50.
 45. Huber AM, Schoenberg SO, Hayes C, et al. Phase-sensitive inversion-recovery MR imaging in the detection of myocardial infarction. *Radiology.* 2005;237(3):854–60.
 46. Wildgruber M, Settles M, Kosanke K, et al. Evaluation of phase-sensitive versus magnitude reconstructed inversion recovery imaging for the assessment of myocardial infarction in mice with a clinical magnetic resonance scanner. *J Magn Reson Imaging.* 2012;36(6):1372–82.
 47. Satoh H, Sano M, Suwa K, et al. Distribution of late gadolinium enhancement in various types of cardiomyopathies: Significance in differential diagnosis, clinical features and prognosis. *World J Cardiol.* 2014;6(7):585–601.
 48. Grosse-Wortmann L, Macgowan CK, Vidarsson L, Yoo SJ. Late gadolinium enhancement of the right ventricular myocardium: is it really different from the left ? *J Cardiovasc Magn Reson.* 2008;10:20.
 49. Singh JP, Evans JC, Levy D, et al. Prevalence and clinical determinants of mitral, tricuspid, and aortic regurgitation (the Framingham Heart Study). *Am J Cardiol.* 1999;83(6):897–902.
 50. Hung J. The pathogenesis of functional tricuspid regurgitation. *Semin Thorac Cardiovasc Surg.* 2010;22(1):76–8.
 51. Ubago JL, Figueroa A, Ochoteco A, Colman T, Duran RM, Duran CG. Analysis of the amount of tricuspid valve annular dilatation required to produce functional tricuspid regurgitation. *Am J Cardiol.* 1983;52(1):155–8.
 52. Tutarel O, Westhoff-Bleck M. The double-orifice tricuspid valve: a review. *J Heart Valve Dis.* 2007;16(5):508–10.
 53. Hauck AJ, Freeman DP, Ackermann DM, Danielson GK, Edwards WD. Surgical pathology of the tricuspid valve: a study of 363 cases spanning 25 years. *Mayo Clin Proc.* 1988;63(9):851–63.
 54. Thatipelli MR, Uber PA, Mehra MR. Isolated tricuspid stenosis and heart failure: a focus on carcinoid heart disease. *Congest Heart Fail.* 2003;9(5):294–6.
 55. Lagarde O, Garabedian V, Coignard A, Duret JC, Piwnica A, Droniou J. Congenital tricuspid insufficiency due to valvular dysplasia. Review of the literature in light of a case in a 40-year-old adult. *Arch Mal Coeur Vaiss.* 1980;73(4):387–96.
 56. Kim HK, Kim YJ, Park EA, et al. Assessment of haemodynamic effects of surgical correction for severe functional tricuspid regurgitation: cardiac magnetic resonance imaging study. *Eur Heart J.* 2010;31(12):1520–8.
 57. Vahanian A, Alfieri O, Andreotti F, et al. Guidelines on the management of valvular heart disease (version 2012): the Joint Task Force on the Management of Valvular Heart Disease of the European Society of Cardiology (ESC) and the European Association for Cardio-Thoracic Surgery (EACTS). *Eur J Cardiothorac Surg.* 2012;42(4):S1–44.
 58. Tulevski II, Romkes H, Dodge-Khatami A, et al. Quantitative assessment of the pressure and volume overloaded right ventricle: imaging is a real challenge. *Int J Cardiovasc Imaging.* 2002;18(1):41–51.
 59. Papavassiliu T, Kuhl HP, Schroder M, et al. Effect of endocardial trabeculae on left ventricular measurements and measurement reproducibility at cardiovascular MR imaging. *Radiology.* 2005;236(1):57–64.
 60. Sievers B, Kirchberg S, Bakan A, Franken U, Trappe HJ. Impact of papillary muscles in ventricular volume and ejection fraction assessment by cardiovascular magnetic resonance. *J Cardiovasc Magn Reson.* 2004;6(1):9–16.
 61. Winter MM, Bernink FJ, Groenink M, et al. Evaluating the systemic right ventricle by CMR: the importance of consistent and reproducible delineation of the cavity. *J Cardiovasc Magn Reson.* 2008;10:40.

62. Ferguson EC, Krishnamurthy R, Oldham SA. Classic imaging signs of congenital cardiovascular abnormalities. *Radiographics*. 2007;27(5):1323–34.
63. Attenhofer Jost CH, Edmister WD, Julsrud PR, et al. Prospective comparison of echocardiography versus cardiac magnetic resonance imaging in patients with Ebstein's anomaly. *Int J Cardiovasc Imaging*. 2012;28(5):1147–59.
64. Kuhn A, De Pasquale MG, Muller J, et al. Tricuspid valve surgery improves cardiac output and exercise performance in patients with Ebstein's anomaly. *Int J Cardiol*. 2013;166(2):494–8.
65. Attenhofer Jost CH, Connolly HM, Edwards WD, Hayes D, Warnes CA, Danielson GK. Ebstein's anomaly – review of a multifaceted congenital cardiac condition. *Swiss Med Wkly*. 2005;135(19–20):269–81.
66. Arya P, Beroukhi R. Ebstein anomaly: assessment, management, and timing of intervention. *Curr Treat Options Cardiovasc Med*. 2014;16(10):338.
67. Hösch O, Charlotte Alt S, Paul T, Lotz J, Steinmetz M, Schuster A. Managing Ebstein's anomaly of the tricuspid valve: impact of cardiovascular magnetic resonance. *J Cardiol Ther*. 2014;1(7):154–9.
68. Marcus RH, Sareli P, Pocock WA, Barlow JB. The spectrum of severe rheumatic mitral valve disease in a developing country. Correlations among clinical presentation, surgical pathologic findings, and hemodynamic sequelae. *Ann Intern Med*. 1994;120(3):177–83.
69. Daniels SJ, Mintz GS, Kotler MN. Rheumatic tricuspid valve disease: two-dimensional echocardiographic, hemodynamic, and angiographic correlations. *Am J Cardiol*. 1983;51(3):492–6.
70. Akinosoglou K, Apostolakis E, Koutsogiannis N, Leivaditis V, Gogos CA. Right-sided infective endocarditis: surgical management. *Eur J Cardiothorac Surg*. 2012;42(3):470–9.
71. Bashore TM, Cabell C, Fowler V Jr. Update on infective endocarditis. *Curr Probl Cardiol*. 2006;31(4):274–352.
72. Dursun M, Yilmaz S, Yilmaz E, et al. The utility of cardiac MRI in diagnosis of infective endocarditis: preliminary results. *Diagn Interv Radiol*. 2015;21(1):28–33.
73. Jeong J, Kim HJ, Kim SM, Huh J, Yang JH, Choe YH. Diagnosis of right ventricular vegetation on late gadolinium-enhanced MR imaging in a pediatric patient after repair of a ventricular septal defect. *Investig Magn Reson Imaging*. 2016;20(2):114–9.
74. Eslami-Varzaneh F, Brun EA, Sears-Rogan P. An unusual case of multiple papillary fibroelastoma, review of literature. *Cardiovasc Pathol*. 2003;12(3):170–3.
75. Kulke MH, Mayer RJ. Carcinoid tumors. *N Engl J Med*. 1999;340(11):858–68.
76. Lundin L, Norheim I, Landelius J, Oberg K, Theodorsson-Norheim E. Carcinoid heart disease: relationship of circulating vasoactive substances to ultrasound-detectable cardiac abnormalities. *Circulation*. 1988;77(2):264–9.
77. Pellikka PA, Tajik AJ, Khandheria BK, et al. Carcinoid heart disease. Clinical and echocardiographic spectrum in 74 patients. *Circulation*. 1993;87(4):1188–96.
78. Simula DV, Edwards WD, Tazelaar HD, Connolly HM, Schaff HV. Surgical pathology of carcinoid heart disease: a study of 139 valves from 75 patients spanning 20 years. *Mayo Clin Proc*. 2002;77(2):139–47.
79. Moerman VM, Dewilde D, Hermans K. Carcinoid heart disease: typical findings on echocardiography and cardiac magnetic resonance. *Acta Cardiol*. 2012;67(2):245–8.
80. Sandmann H, Pakkal M, Steeds R. Cardiovascular magnetic resonance imaging in the assessment of carcinoid heart disease. *Clin Radiol*. 2009;64(8):761–6.
81. Fussen S, De Boeck BW, Zellweger MJ, et al. Cardiovascular magnetic resonance imaging for diagnosis and clinical management of suspected cardiac masses and tumours. *Eur Heart J*. 2011;32(12):1551–60.
82. Motwani M, Kidambi A, Herzog BA, Uddin A, Greenwood JP, Plein S. MR imaging of cardiac tumors and masses: a review of methods and clinical applications. *Radiology*. 2013;268(1):26–43.
83. Pazos-Lopez P, Pozo E, Siqueira ME, et al. Value of CMR for the differential diagnosis of cardiac masses. *JACC Cardiovasc Imaging*. 2014;7(9):896–905.

84. Tumma R, Dong W, Wang J, Litt H, Han Y. Evaluation of cardiac masses by CMR-strengths and pitfalls: a tertiary center experience. *Int J Cardiovasc Imaging*. 2016;32(6):913–20.
85. Yuan SM, Jing H, Lavee J. Tumors and tumor-like lesions of the heart valves. *Rare Tumors*. 2009;1(2):e35.
86. Aeba R, Katogi T, Hashizume K, et al. Liberal use of tricuspid valve detachment for transatrial ventricular septal defect closure. *Ann Thorac Surg*. 2003;76(4):1073–7.
87. Mahgoub A, Kamel H, Simry W, Hosny H. Repair of very severe tricuspid regurgitation following detachment of the tricuspid valve. *Glob Cardiol Sci Pract*. 2015;2015:14.
88. Najib MQ, Vittala SS, Challa S, et al. Predictors of severe tricuspid regurgitation in patients with permanent pacemaker or automatic implantable cardioverter-defibrillator leads. *Tex Heart Inst J*. 2013;40(5):529–33.
89. Popescu BA, Gurzun MM, Carmen Gingham Tricuspid and pulmonary valve disease. Zambrano J, Bax J, Knuuti J, Sechtem U, Lancellotti P, Badano L *The ESC textbook of cardiovascular imaging 2* Oxford: Oxford Press; 2015. 171–184.
90. Chiribiri A, Fairborn T. Valvular heart disease. In: Plein S, Greenwood J, Ridgeway JP, editors. *Cardiovascular MR manual*. Heidelberg: Springer International Publishing; 2015. p. 357–70.

Chapter 9

Tricuspid Valve Disease: A Computed Tomographic Assessment

Rahatullah Muslem, Mohammed Ouhlous, Sakir Akin,
Abd Alla Fares, and Osama I. Soliman

Abstract Current cardiovascular computed tomography (CT) scanners provide a three-dimensional full volumetric dataset that covers the entire heart and its vascular connections at one or more time points. Cardiovascular CT plays an increasingly important role in the era of transcatheter aortic and mitral valve therapy. Likewise, it has a potential importance in planning of transcatheter tricuspid valve (TV) interventions. Advantages in the CT assessment of the TV include its ability to show a complete overview of the complex anatomy, its submillimetre isotropic spatial resolution and a temporal resolution as low as 66 ms. In addition, CT measurements are generally simple and accurate on good-quality images. It allows for precise anatomic measurements, which is needed for optimal valve sizing and successful valve placement. However, the use of cardiovascular CT has certain limitations. In detail visualization of the right atrioventricular junction can be challenging. It is associated with ionizing radiation, and it has other related risks, especially in dynamic

R. Muslem, B.Sc.

Unit Heart Failure, Transplantation and Mechanical Circulatory, The Thoraxcenter, Department of Cardiology, Erasmus MC: University Medical Center Rotterdam, Rotterdam, The Netherlands

M. Ouhlous, M.D., Ph.D.

Department of Radiology, Erasmus MC: University Medical Center Rotterdam, Rotterdam, The Netherlands

S. Akin, M.D.

Department of Cardiology and Intensive Care Unit, The Thoraxcenter, Erasmus MC: University Medical Center Rotterdam, Rotterdam, The Netherlands

A.A. Fares, M.D.

Department of Radiology, University Hospital Kerry, Tralee, Co Kerry, Ireland

O.I. Soliman, M.D., Ph.D. (✉)

Department of Cardiology, The Thoraxcenter, Erasmus MC: University Medical Center Rotterdam, Rotterdam, The Netherlands

e-mail: o.soliman@erasmusmc.nl

imaging, and with the use of potentially nephrotoxic contrast agents. New TV therapies are evolving, although, evidence for the efficacy and safety is limited to case reports and small series. In this chapter, we will provide an overview of current and potential future applications of CT in the assessment of right heart disease with a focus on perioperative assessment of patients undergoing transcatheter TV therapy.

Keywords Tricuspid • Stenosis • Regurgitation • Computed tomography • Contrast • Radiation • Multiplanar reconstruction • ECG triggering • Annulus • Right ventricle • Annuloplasty • Preprocedural planning • Therapy • Outcome

Imaging Technics of the Tricuspid Valve Using CT

Scan Mode

Computed Tomography has proven itself in imaging of the heart in general and the tricuspid valve (TV) in particular. Dynamic anatomical information can be obtained with CT. But in case of the TV only static anatomical information is sufficient. As the majority of the hospitals today are equipped with at least a 64 slices CT scanner, the following modes can be used:

1. Conventional spiral CT (without ECG gating).
2. Prospective high pitch spiral CT mode (with or without ECG triggering), this technique is only possible with Dual Source CT scanners.
3. Prospective ECG triggering mode.
4. Retrospective ECG gating mode (with or without ECG pulsing).

The first imaging technique is the easiest protocol and is feasible on all scanners, but suffers from motion and/or breathing artefacts. Therefore, this protocol is usually not used to image the TV. With Dual Source CT scanners double temporal resolution and high pitch values can be achieved ($P = 3.4$) and therefore higher table speed up to 737 mm/s. Motion free heart imaging in less than a single heart beat can be performed with an effective radiation dose less than 1 mSv. This mode has no additional radiation dose penalty compared to the first mode. Using ECG triggered high pitch CT, one can choose which phase of the heart cycle should be imaged, provided that the heart rate is regular. For TV CT imaging the diastolic phase is relevant. The inconvenient of this imaging mode is that it requires a Dual Source CT scanner.

Prospective ECG triggered mode utilizes the step-and-shoot method. The scan is performed by imaging a series of axial images at a selected cardiac phase, usually the diastolic phase. The X-ray tube is turned off during the rest of the cycle. Only wide area detector CT (16 cm) can image the heart in one heartbeat. All other scanners require multiple heart beats which can lead to stack misalignment artefacts. Single source CT scanners have a limited temporal resolution requiring either beta blockers to rule out cardiac motion artefacts or to switch to a more dose intensive

retrospective protocol with multi-segment reconstruction. Dual Source scanners have sufficient temporal resolution to use prospective imaging also in high or irregular heart rates. Prospective step and shoot can provide dynamic information by using ECG-padding. With ECG padding the X-ray exposure time per heart beat will be increased or decreased depending on the desired heart phases. More dynamic information achieved by longer X-ray exposure will result in a higher radiation dose. However, in prospective step-and-shoot (SAS) mode will not obtain a full acquisition of the RR-interval. Retrospective ECG-gating exposes X-ray continuously with simultaneous ECG information acquisition. In retrospect, multiple phases of the ECG cycle can be reconstructed providing dynamic information over the full cardiac cycle. This will come at the cost of a significant higher radiation dose. ECG pulsing can be applied to select phases of the cardiac cycle where more noise can be tolerated and tube current and voltage is reduced to decrease the radiation dose. Data for a specific cardiac phase is used for image reconstruction. Retrospective ECG-gating with tube current modulation can allow 30–40% less radiation dose. This decrease in radiation dose is less effective with higher heart rates.

Contrast Injection

A similar approach to CT angiography where contrast is timed in the first pass, scans will suffer from beam hardening artefacts because the contrast agent has not sufficiently been diluted. This is worse when using low kVp. This can be partially solved by injecting a diluted contrast agent. But, although this protocol may decrease beam hardening artefacts, image quality still suffers from mixing artefacts. These are caused by the inflow of contrast free blood from the inferior vena cava (IVC). Imaging in the venous phase will provide homogeneous contrast agent enhancement. The attenuation will be lower than in the arterial phase. To compensate for this a larger contrast agent volume must be used. A well performed venous phase is sufficient to assess the TV anatomy. As the beam hardening artefacts are solved, a low kVp can help to obtain a higher attenuation with a lower radiation dose.

If a combination with a CT angiogram of the aorta is needed, a split bolus can be used. In this case a first bolus will enhance the IVC inflow and the right heart. While the second bolus will be used to image the left ventricle and the aorta in a single scan.

Clinical Utility of Computed Tomography in Right Heart Diseases

Most cardiac CT examinations are mainly focused on the left side of the heart. Therefore, injection protocols are optimized to visualize this side of the heart. However, the right side of heart (the right atrium, atrioventricular junction and the RV) can also be depicted through CT [1]. More importantly, it can be of added clinical value to detect and diagnose certain diseases such as arrhythmogenic right

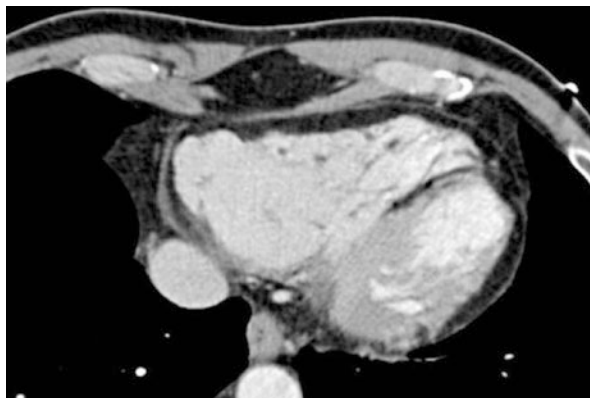


Fig. 9.1 Arrhythmogenic RV dysplasia on cardiac CT. Reprinted with permission from “Value of Cardiac CT in Patients with Heart Failure” by Deepa Mangalat et al., *J Curr Cardiovasc Imaging Rep.* 2009 Dec; 2(6): 410–417. Springer Science and Business Media, LLC 2009

ventricular (RV) dysplasia (Fig. 9.1) [2, 3]. In this section we will discuss the clinical utility of CT and the appropriate acquisition techniques to assess the right side of the heart.

Computed Tomography Acquisition Techniques for the Right Side of the Heart

As mentioned before, due to the fact that standard injection techniques are optimized for the left side of the heart, to acquire images of the right side of the heart the injection protocol has to be modified [1]. In order to acquire images of the right side of the heart, adequate contrast quantity has to be maintained in this area. By adjusting the amount of contrast medium and the flow, prolongation of the length of administration of the entire bolus can be achieved [4], and adequate contrast quantity can be maintained on the right side of the heart. To prevent streak artefacts and to achieve clear depiction of the endocardial contour, the multiphasic infusions technique instead of monophasic injection of contrast medium can be used [1]. Furthermore, the use of different combinations of contrast material can contribute to improve the homogeneous enhancement profile. Including saline contrast mixture or saline flush [5].

Different studies have assessed the optimum protocol and modes for the delivery of contrast material [6–9]. For RV functional analysis, biphasic infusion of contrast medium followed by a contrast saline mixture was found to be optimal, mainly due to the better delineation of the ventricular wall [6]. Furthermore, for the depiction of the right side of the heart, including the valves, split bolus infusion seemed to be the optimal method [7, 9]. For additional imaging of surrounding blood vessels, these injections parameters have to be adjusted, in order to have the optimal enhancement profile.

Clinical Utility of Cardiac CT

Although, MRI is the most accurate in assessing RV volumes and function [10], CT can be used to assess a variety of cardiopulmonary conditions and detect important prognostic markers [1]. Table 9.1 lists cardiac diseases in which the assessment of RV function is highly important. In patients with an acute pulmonary embolism (Fig. 9.2) the RV/Left ventricle (LV) diameter ratio is associated with higher mortality rates [11]. In addition, RV/LV diameter ratio score greater than 1.5, estimated through CT, indicates severe RV dysfunction [3]. Furthermore, both right- and left sided valvular diseases can lead to RV dysfunction [1]. However, TV regurgitation (TR) can also occur because of RV dysfunction and subsequent annular dilatation [12]. CT can provide an anatomical delineation of the right atrioventricular junction and the RV outflow tract, in order to depict dilation or enlargements. Finally, CT can be used to rapidly assess the RV function and ejection fraction in acute settings such as RV infarction, and in chronic diseases such as heart failure [1].

Comprehensive Assessment of Tricuspid Valve and Surrounding Structures by CT

Advanced TV disease such as severe TR is associated with increased morbidity and mortality [14, 15]. TR might not be recognized clinically until fairly late in its natural history. Early stages of TR are therefore often asymptomatic and

Table 9.1 Computed tomography assessment of the right heart

Condition	Impact	CT measurements/findings
Acute pulmonary embolism [3]	<ul style="list-style-type: none"> • ↑ RV afterload • RV dysfunction • ↑ RV end-systolic volumes • Leftward septal bowing • LV Compression • ↓ CO 	<ul style="list-style-type: none"> • RV/LV ratio • Maximum distance between inner surface of the free wall and the endocardial surface of the interventricular septum
Valvular heart disease	<ul style="list-style-type: none"> • RV dysfunction • RA enlargement • Dilated RVOT 	<ul style="list-style-type: none"> • RAJ & RVOT size • RV function • Morphologic changes
RV cardiomyopathy [13]	<ul style="list-style-type: none"> • RV dilatation • RVOT enlargement • RV intramyocardial fat deposition • Wall thinning 	<ul style="list-style-type: none"> • RVOT size • Morphologic changes • LV assessment • Subendocardial fatty tissue

RV right ventricle, LV left ventricle, CO cardiac output, RA right atrium, RVOT right ventricle outflow tract, RAJ right atrioventricular junction

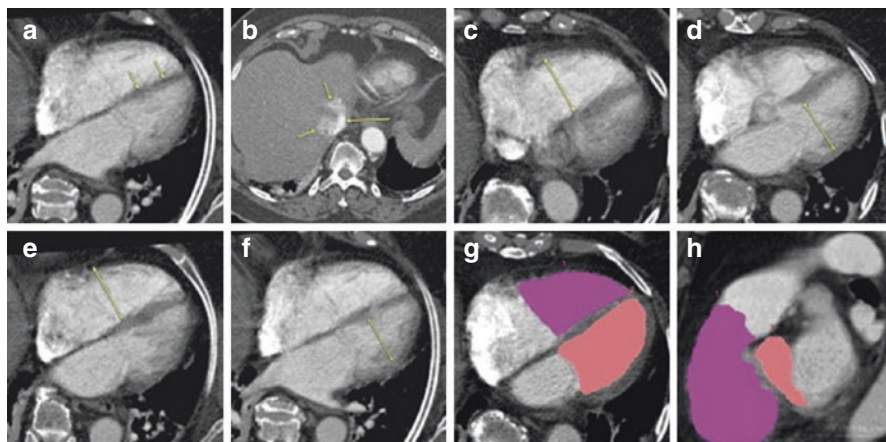


Fig. 9.2 Computed Tomography in a patient with acute pulmonary embolism. (a) Four-chamber view reconstruction with septal flattening (arrows). (b) Grade 4 reflux of contrast into the inferior vena cava (long arrow) and proximal hepatic veins (short arrows). (c) The maximal diameter on axial sections of (c) right and (d) left ventricular diameter. (e) The maximal diameter on four-chamber view of the right and (f) left ventricle. Right and left ventricle volumetric depicted on (g) axial section and (h) sagittal reformation. Reprinted with permission from “CT Signs of Right Ventricular Dysfunction: Prognostic Role in Acute Pulmonary Embolism” by Doo Kyoung Kang et al., *JACC Cardiovasc Imaging* 2011; Volume 4:8:841–849. Copyright (2017) by Elsevier Inc.

are often observed on echocardiography. Transthoracic echocardiography (TTE) is most often used to diagnose and to assess the cause and the severity of TR. When TTE images are inadequate, transoesophageal echocardiography (TEE) can be considered, although visualization of the anteriorly located TV can be difficult [16].

In advance of TV interventions, a detailed knowledge of the complex surgical anatomy of the TV is fundamental. The information gained through imaging may help to plan and guide surgical decision-making and transcatheter TV interventions. Different imaging techniques have been used for the assessment of the TV and the surrounding structures. However, due to the complex anatomy of TV apparatus a 3D imaging modality is often needed. Cardiac magnetic resonance (CMR) imaging and real-time three-dimensional techniques can provide 3D information as well as accurate quantification of TR severity [10, 17–19]. However, CMR is not widely available and often contraindicated due to the presence of pacemaker leads. On the other hand, 3D echocardiography suffers often a low spatial and temporal resolution. CT on the other hand has acquired an increasing importance in planning transcatheter interventions because of its accurate 3D information as well as high spatial and temporal resolution. CT can be used therefore to assess TV and the surrounding structures such as the RV and adjacent blood vessels [20, 21]. In this section we discuss the assessment of the TV and the surrounding structures with CT and the clinical utility of CT in preplanning for TR interventions.

The Tricuspid Valve

The most common abnormality of TV is TR, which is often due to incomplete leaflet coaptation or incomplete closure due to dilated annulus and dilated RV. Increasing TR severity is associated with poor survival [22]. Therapeutic decisions for TR often require 3D imaging modality to unravel its mechanism [14].

The normal tricuspid apparatus (Fig. 9.3) has been described previously in Chap. 1. In brief, the TV apparatus consist of three leaflets, a partly fibrous annulus, and a supporting tension apparatus. The supporting tension apparatus consist of the chordae tendinae and papillary muscles. The leaflets include anterior, septal and posterior [23, 24]. The PMs include anterior, inferior and medial. The commissure between the septal and anterior leaflets is located over the membranous septum and divides it into the atrioventricular and inter-ventricular components [24, 25]. The chordae to the anterior and septal leaflets, provided by the medial PM of the conus or RV septal wall, represents an important surgical landmark for the location of the right bundle branch [20].

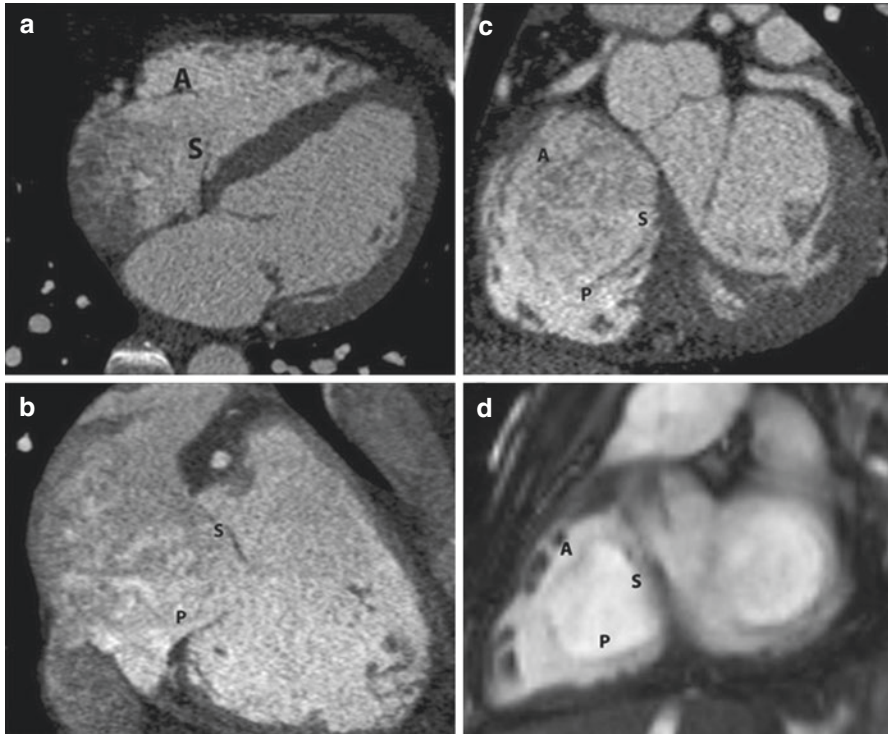


Fig. 9.3 Normal appearance of tricuspid valve. (a) Four-chamber CT image shows the septal (*S*) and anterior (*A*) leaflets. (b) Two-chamber CT image shows septal (*S*) and posterior (*P*) leaflets. (c) Short-axis CT image shows all the leaflets (*S*, *A*, *P*). (d) MRI appearance of the tricuspid annulus, with the short-axis steady-state free precession (SSFP) image showing all the leaflets (*S*, *A*, *P*). Reprinted with permission from Shah et al. [26] *Insights Imaging*. 2016 Oct;7(5):649–67

Tricuspid Annulus

The normal tricuspid annulus is an ellipsoid, non-symmetrical, saddle-shaped structure and appears nonplanar, with the posteroseptal part the most towards the RV apex. It becomes more circular as it dilates in an anterior-posterior direction in response to RV enlargement (Fig. 9.4) [14]. Among other reasons, the TV annulus differs from the mitral annulus because of the lack of extensive fibrous elements in the peripheral (mural) part of the valve to support its leaflets [25]. Measurements of TV annulus on CT can be performed in the four-chamber views by measuring maximum and minimum diameters.

CT Assessment of the Tricuspid Valve and Adjacent Anatomical Structures

In detail visualization of the right atrioventricular junction can be challenging. Clear depiction of this region requires homogenous enhancement of the structures around the TV annulus. ECG gated or triggered cardiac CT angiography (CTA) techniques can provide good-quality motion-free images of the RV outlet and trabeculated portions [20]. However, the quality may not be high enough to show the details of the RV inlet [27], partially because of streaming artefacts.

Advantages

Advantages of CT use in the assessment of the TV includes, its ability to show the extent of calcification, a complete overview of the complex anatomy, good spatial and temporal resolution, it enables evaluation of the TV annuloplasty ring

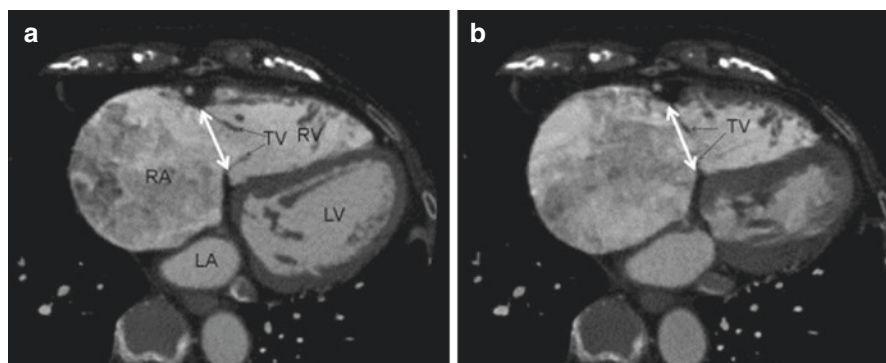


Fig. 9.4 Measurements of the tricuspid valve annual diameter. Presented are the measurements of the (a) maximum and (b) minimum tricuspid valve annual diameter on electrocardiogram gated 320-slice computed tomography. Reprinted with permission from “Relationship of maximum and minimum tricuspid valve annular diameter determined by 320-slice computed tomography with right atrial and ventricular volume and estimated right ventricular systolic pressure” by Nobusada Funabashi et al., *IJC* 2013;168(4):4578–81. Copyright (2017) by Elsevier Inc

Table 9.2 Advantages and limitations of the use of computed tomography

Advantages	Limitations
<ul style="list-style-type: none"> • Only modality for reliable assessment of calcification • Good spatial/temporal resolution • Complete overview of anatomy • Multiplanar reconstruction capabilities • Identifies inappropriate positioning of leads 	<ul style="list-style-type: none"> • Radiation • Potentially nephrotoxic contrast agents • Limited in detecting small vegetation's and small valve perforations • Limited in patients with high/irregular heart rates

dislodgement, it helps to identify inappropriate positioning of the RV pacemaker lead at the TV level, and, measurements are generally simple on good-quality four-chamber cardiac CT images [20, 21]. Moreover, CT can evaluate associated extra-cardiac lesions, for example in carcinoid heart disease. Advantages and limitations are summarized in Table 9.2.

Limitations

The use of CT has certain limitations. It is associated with ionizing radiation, its related risks and with use of potentially nephrotoxic contrast agents [26]. Furthermore, dynamic evaluation or ventricular functional evaluation is possible in retrospective ECG-gated scans. However, this is associated with a higher radiation dose [26]. The use of CT is limited in patients with high or irregular heart rates and also in the characterization of tissues [26]. Finally, CT has limited value in the assessment of the valve function or for the detection of small vegetation's (<4 mm) and small valve perforations. [26, 28].

The CT is technically limited in showing all TV leaflet positions at a specific time frame of the cardiac cycle in one short-axis plane, therefore, when assessing TV leaflets, a combination of different views is required. The four-chamber view is the most appropriate view to assess the septal leaflet, and in some cases, only in this projection small defects of the membranous septum can be seen [20]. Furthermore, the septal isthmus width, visualization of its relation with the coronary sinus orifice and the atrioventricular node artery can be measured with the four-chamber view [20]. The relationship of the anterior and posterior leaflets can be depicted with the two-chamber CT of the right heart, and, this is the optimum view to measure the cavotricuspid isthmus superior to the hinge of posterior TV leaflet, which might be difficult to visualize trough TTE. The long-axis views can be used for the evaluation of TV prolapse. Furthermore, when there is tethering of the leaflets and regurgitation due to incomplete coaptation of the leaflets, the distance and area of tethering (tenting) can be measured by CT. The dimensions of the TV annulus can be measured through the reconstructed short-axis view, by measuring the maximal antero-posterior and septal-lateral diameter of the annulus [21]. The perimeter and annulus area can be assessed by planimetry after the CT is performed [21].

The Right Coronary Artery

The distance of the right coronary artery (RCA) to the TV annulus and the course of the RCA through the right atrioventricular groove may vary in humans [29]. Information regarding the course of the RCA may be of added value when planning patients for transcatheter interventions that target the TV annulus, due to the risk for impingement of the RCA [30]. CT analysis can be used to determine detailed characterization of the spatial relationship between the RCA and the TV annulus (Fig. 9.5). The mid-diastolic phase volume rendered reconstructions, the two- and four-chamber long-axis and the short-axis views can be evaluated to determine the course and position of the RCA relative to the TV annulus [31]. The position of the RCA relative to the TV annulus can be classified as superior, inferior or at the same level as the TV annulus. The short-axis view can be used to measure the distance

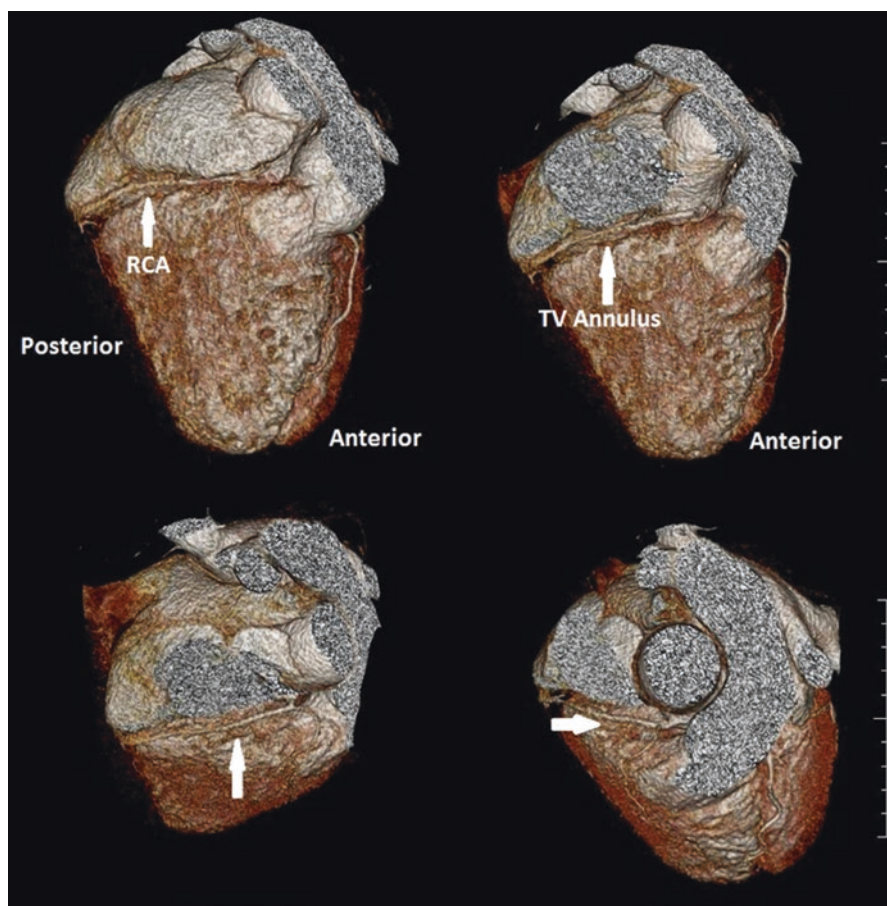


Fig. 9.5 Computed Tomography analysis of the right coronary artery. 3D reconstructions with computed tomography showing the relationship between the right coronary artery and the tricuspid valve annulus

between the RCA and the TV annulus at the level of the anterior and posterior tricuspid leaflets insertions, if the RCA courses at the same level as TV annulus [31].

The Right Ventricular Apex

Certain devices, like the Forma Repair System (Edwards Lifesciences, Irvine, California) interact directly with the tricuspid leaflets. Therefore, the TV annulus dimensions and the distance from the annulus to the RV apex should be evaluated, when planning patients for these interventions [32]. To measure the maximal distance between the TV annulus and the RV apex, the long-axis four-chamber view can be used [31].

The Vena Cava

Patients selected for transcatheter caval valve implantations (CAVI) require pre-CAVI imaging with contrast-enhanced, electrocardiogram-gated CTA to assess the IVC dimensions and the distance between the junction of the right atrium and IVC to the first hepatic vein (Fig. 9.6) [33].

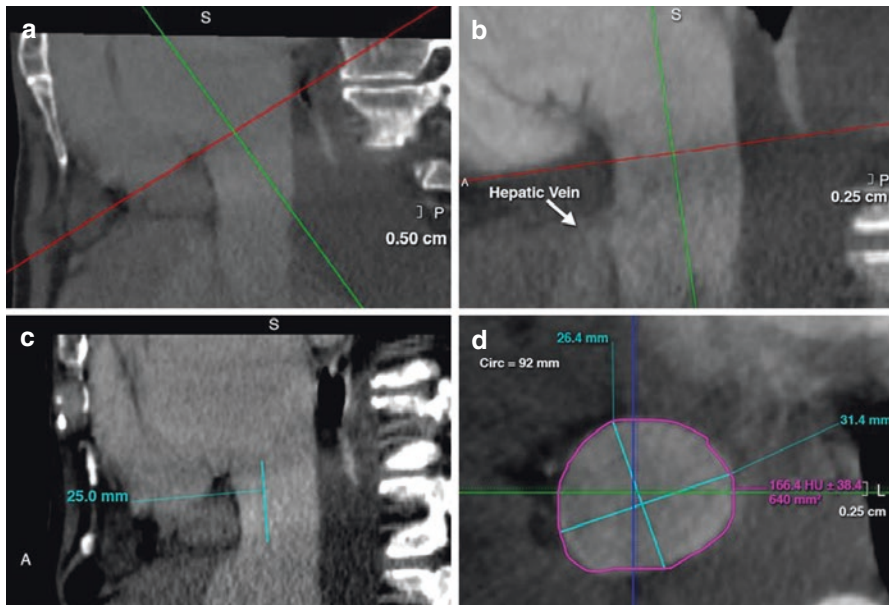


Fig. 9.6 Computed Tomography for Caval Valve Implantation. (a) Assessment of the right atrium-inferior vena cava junction plane. (b, c) Depiction of the hepatic vein and (d) Sequential measurements of the horizontal planes for the assessment of the optimal valve size (1 cm below the right atrium-inferior vena cava junction plane and 1 cm above the identified first hepatic vein). Reprinted with permission from “Transcatheter Caval Valve Implantation Using Multimodality Imaging. Roles of TEE, CT, and 3D Printing,” by Brian O’Neill et al., JIMG 2015;8:221–225. Copyright (2015) by Elsevier Inc

The axial view with the multi-planar reformation planes oriented along the RV apex and the coronary sinus can be used to assess the dimensions of the IVC at the transition level with the right atrium down to the level of the first hepatic vein [31, 33]. To reconstruct the double oblique transverse plane parallel to the transition level of the right atrium with the IVC, single oblique and coronal views can be used while aligning the multi-planar reformation planes to the basal part of the coronary sinus [33]. Furthermore, the diameter, perimeter and area of the IVC can be assessed at this level [31]. To assess the dimensions of the IVC at the first hepatic vein, these measurements can be repeated on the double oblique transverse plane at the level of the first hepatic vein (Fig. 9.7) [31].

Surgical Interventions for the Tricuspid Valve

Functional TR is the most common abnormality of TV. When indicated, surgical repair or replacement of the TV is the only currently approved treatment option. There are two surgical options for the TV, it can be either repaired or replaced. In symptomatic patients or patients with signs of RV remodelling and primary TR, surgery is recommended. Furthermore, it is recommended in patients undergoing surgery for the left sided valves with concomitant functional TR. The preference for one of these two techniques depends on the underlying cause of the TV disease. In patients with damaged leaflets due to rheumatic or carcinoid valve disease, as in patients with extreme annulus dilatation, valve replacement is favoured [34]. However, patients

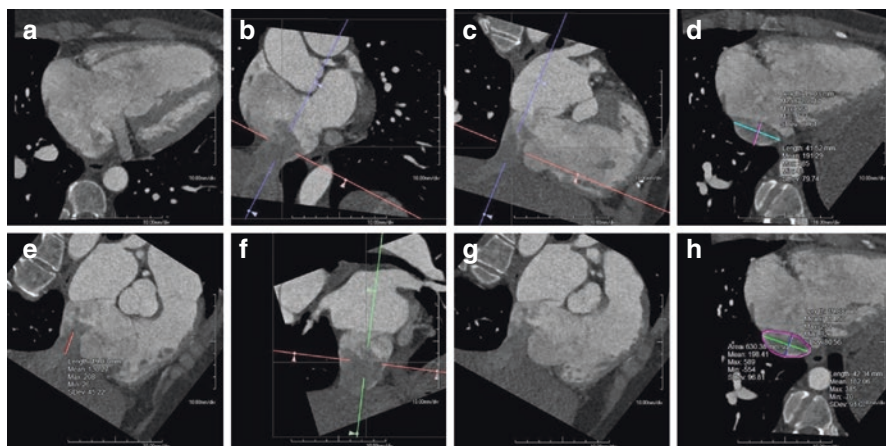


Fig. 9.7 Vena Cava dimensions assessed through computed tomography. Computed tomography assessment of the inferior vena cava (IVC) dimensions using the Orthogonal axial view (a), single oblique sagittal view (b, f) and the Coronal view (c, g). In order to reconstruct a transverse plane of the entrance of the IVC into the right atrium (d), multi-planar reformation planes were aligned along the transition of right atrium and IVC. Panel (e) depicts the distance between the first hepatic vein and the IVC. The maximal and minimal diameter, perimeter and area of the IVC are measured in h, using a double oblique transverse plane

require chronic anticoagulation after valve replacement, and in addition, valve replacement is associated with an increased mortality [35]. Therefore, the preferred option is valve repair (Fig. 9.8), which consists of several techniques. Incomplete band or De Vega's suture annuloplasty and Kay bicuspidization are the most frequently used techniques in patients undergoing left sided valve surgery to treat functional TR [36]. A suture repair has the advantage that it can be performed easily and quickly. However, due to the higher incidence of recurrent TR after suture repair compared to the use of an annuloplasty band, the latter one is more favoured. Detailed surgical TV repair and replacement techniques are presented in Chap. 17.

Clinical Utility of CT in Planning Transcatheter Interventions for Functional TR

Transcatheter TV therapy is a less invasive alternative to surgery for patients with functional TR and deemed to be high-risk surgical candidates [37]. Currently, transcatheter devices are designed to target TR via one or more of TV apparatus

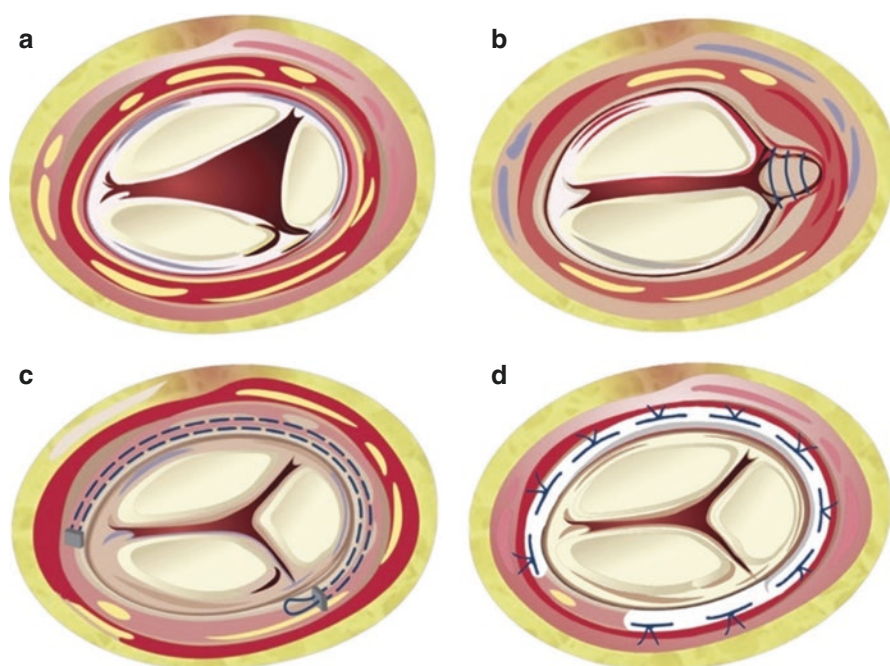


Fig. 9.8 Tricuspid annuloplasty repair techniques (a) Tricuspid valve before surgical intervention, (b) Kay bicuspidization repair, (c) De Vega suture repair and (d) ring annuloplasty with use of an incomplete semirigid prosthetic ring. Reprinted with permission from “Diagnosis and treatment of tricuspid valve disease: current and future perspectives,” by Josep Rodés-Cabau et al., *The Lancet* 388(10058), Pages 2431–2442 (November 2016) Copyright (2016) by Elsevier Inc

Table 9.3 Pre-procedural anatomic measurements using computed tomography

Therapeutic anatomic target	CT views	CT parameters
TV annulus	<ul style="list-style-type: none"> • Volume rendered reconstruction • Long-axis 4-chamber view • Long-axis 2-chamber view • Long-axis 4-chamber view • Short-axis view at TV annulus • Long-axis 4-chamber view • Short-axis view at TV annulus 	<ul style="list-style-type: none"> • RCA relationship to TV annulus • Distance between RCA and ATL insertion • Distance between RCA and PTL insertion
TV leaflets	<ul style="list-style-type: none"> • Short-axis view at TV annulus • Long-axis 4-chamber view 	<ul style="list-style-type: none"> • TV annular dimensions • Long-axis of RV (distance between TV annulus and RV apex)
Caval veins	<ul style="list-style-type: none"> • Orthogonal axial view • Single oblique sagittal view • Coronal view • Single oblique sagittal view • Coronal view 	<ul style="list-style-type: none"> • Entrance of the IVC into the right atrium • IVC dimensions assessment

components such as TV annulus, TV leaflets or caval veins. Annuloplasty devices such as TriAlign and the TriCinch System aim at reduction or modulation of TV annulus. Coaptation devices such as the Spacer aims at improving TV leaflets coaptation. Heterotopic caval vein implantation aims at secure a functioning valve(s) between right atrium and venous communication. Details of these devices and technical considerations are provided in other chapters of this book.

To minimize the risk for complications and to optimize the results, specific anatomical aspects should be taken into consideration before performing one of the currently available transcatheter procedures for the TV. In contrast to echocardiography, CT can provide better information on the anatomical spatial relationship of the TV apparatus and surrounding structures [31] Table 9.3. Lists key anatomic measurements, which are required for pre-procedural planning of transcatheter TV repair or replacement.

Percutaneous Tricuspid Annuloplasty

The Mitralign device (Mitralign, Inc. Tewksbury, USA), has been used to treat functional TR performing a transcatheter bicuspidization of the TV [38]. The TriCinch device (4Tech Cardio, Galway, Ireland) is a catheter-based device designed to perform tricuspid annular cinching [39], in order to reduce anteroseptal annular dimension and reduce TR improving leaflet coaptation. In the latter procedure, the

tricuspid annulus dimensions are reduced by positioning of a corkscrew anchor at the anterior tricuspid leaflet that is connected through a Dacron band to a self-expandable stent implanted in the inferior vena cava. [40]. A schematic view of the percutaneous interventions for the treatment of tricuspid regurgitation is presented in Fig. 9.9. Continuous monitoring with TEE and demarcation of the right coronary artery (RCA) course with wires and angiography are needed to safely perform the intervention with the Mitralgn device. In addition, before performing the annulus reduction with the TrinCinch device, the distance from the insertion of the anterior tricuspid leaflet into the annulus to the RCA should be studied (Fig. 9.10) [31]. One of the most feared complications in these procedures is impingement of the RCA. Even in normal human hearts the distance between the TV annulus and the RCA is variable. [29] According to an anatomical study by Ueda *et al.*, [33] the median nearest distance from the RCA to the base of the anterior tricuspid leaflet was 6.8 mm [range 5.9–11.0 mm] and to the posterior tricuspid leaflet 2.1 mm [range 2.0–4.0 mm] in normal human hearts. However, the distance between the RCA and the TV measured with CT was larger at the insertion level of the anterior tricuspid leaflet whereas the RCA coursed more closely to the annulus at the level of the insertion of the posterior leaflet, in a study including patients with and

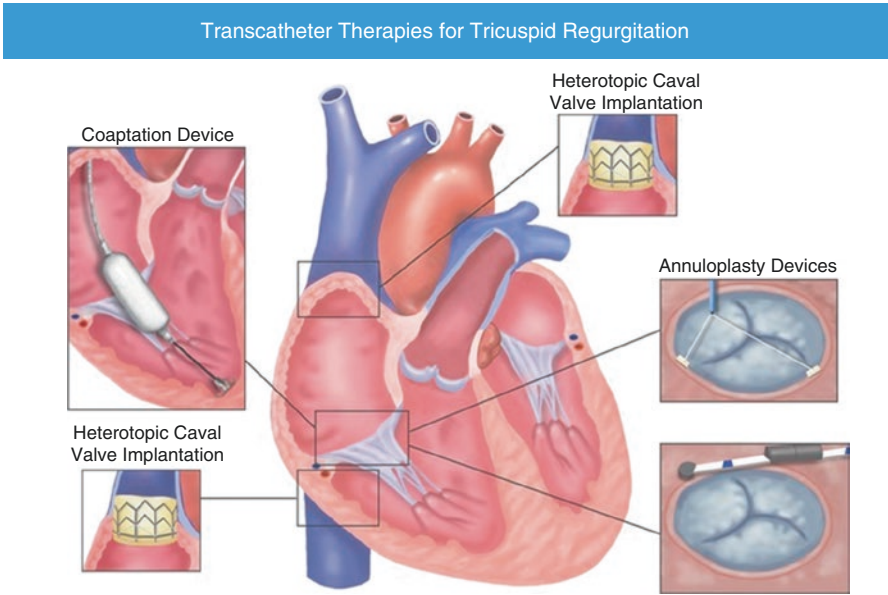


Fig. 9.9 Transcatheter therapies for tricuspid regurgitation. Transcatheter options, heterotopic caval valve implantation, coaptation devices, annuloplasty devices. Reprinted with permission from “Transcatheter Therapies for Treating Tricuspid Regurgitation” by Josep Rodés-Cabau *et al.*, J Am Coll Cardiol 2015 volume 67:15:1829–1845. Copyright (2017) by Elsevier Inc

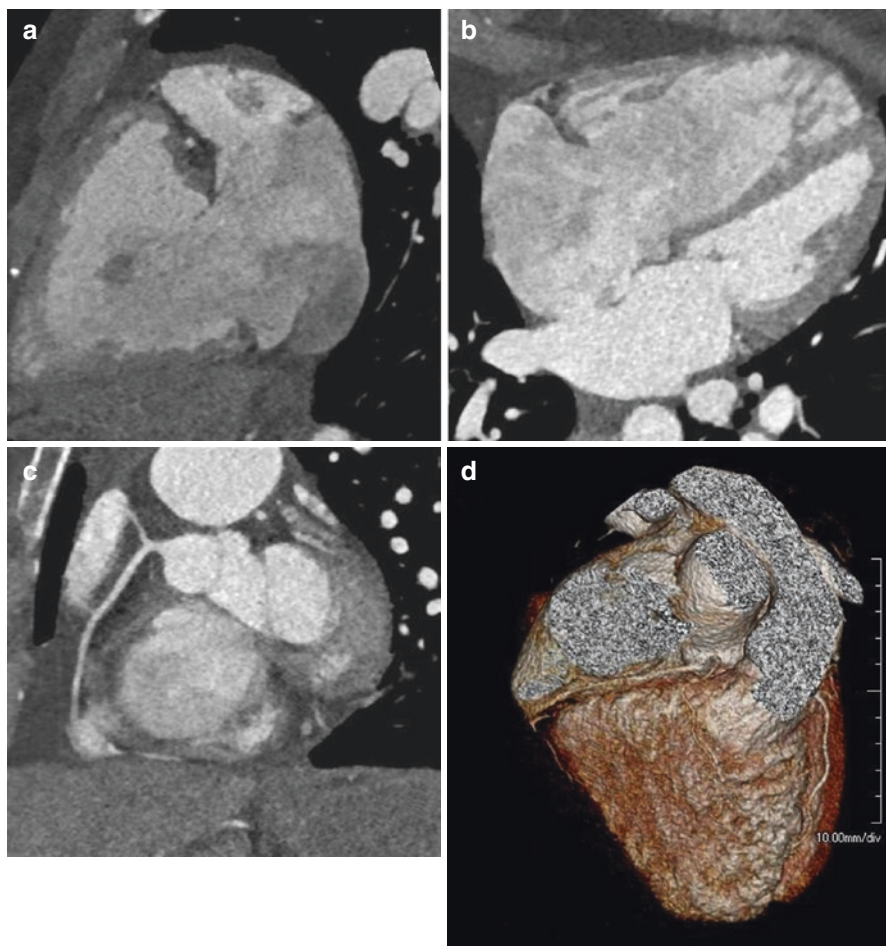
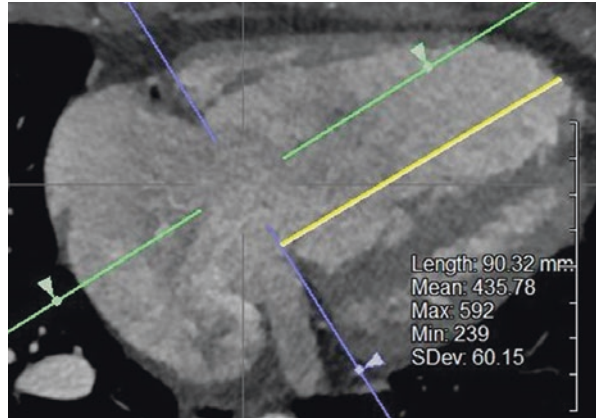


Fig. 9.10 Distance between RCA and TV annulus. Computed tomography assessment of the distance between the right coronary artery and the tricuspid valve annulus. Panel (a), long-axis two-chamber view and (b), long-axis four-chamber view. The (c) short-axis view was reconstructed using the long-axis views of (a) and (b). A 3D reconstruction spatial relationship between the RCA and the TV annulus is depicted in panel D

without significant TR. [31] Furthermore, a less favourable course of the RCA (≤ 2.0 mm distance to the annulus) was depicted through CT analysis in 12.5% of the patients with TR $\geq 3+$ at the anterior tricuspid leaflet and in 27.5% of the patients with TR $\geq 3+$ at the posterior tricuspid leaflet [39] Therefore, evaluation of the RCA course through CT analysis can be of value in patients with severe TR, awaiting percutaneous tricuspid annuloplasty.

Fig. 9.11 Tricuspid valve annulus relative to the right ventricular apex. Computed tomography assessment of the distance between the tricuspid valve annulus to the right ventricular apex in the long-axis four-chamber view



Tricuspid Orifice

CT assessment of the orientation of the TV annulus plane relative to the RV apex may be of value in pre-procedural planning of patients for devices that interfere or are placed within the TV orifice, like the Forma Repair System [31, 32]. This is an inflatable spacer device that is positioned within the regurgitant orifice area of the TV and provides a surface for native leaflet coaptation [32]. Through a rail, the inflatable spacer is attached to the RV apex. In order to reduce the TR grade effectively, the spacer needs to be positioned in the center of the regurgitant orifice area perpendicular to the valve plane [32], which is currently assisted by three-dimensional TEE. The implanting cardiologist could benefit from geometrical information of the TV annulus plane orientation and distance relative to the RV apex, assessed through CT (Fig. 9.11), to the benefit of catheter manoeuvring during the procedure [31].

Caval Valve Implantation Concept

Knowledge regarding the use of CT in the assessment of the right atriocaval junction, the vena cava and the distance to the first hepatic vein for prosthesis sizing and the avoidance of hepatic vein obstruction during CAVI remains limited. A small number of studies have reported about the success of this procedure [33]. The mean cross-sectional area of the right atriocaval junction and the distance from this point to the first hepatic vein can be assessed with the CT in patients with severe TR (Fig. 9.7) [31]. This study also discusses that the design of customized caval valve prosthesis fitted to the vena cava geometry of the patient assessed by CT may provide the most favourable results. The intraoperative TEE and post-CAVI CT are depicted in Fig. 9.12.

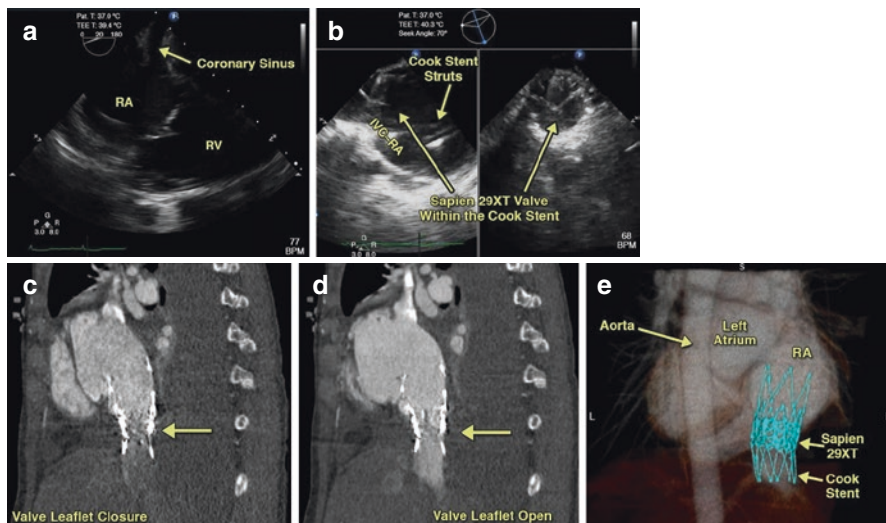


Fig. 9.12 Periprocedural multimodality imaging: role of intraoperative TEE and post-CAVI CT. Intraoperative TEE (a) at the level of the coronary sinus, (b) visualization of the mouth of the inferior vena cava. (c, d) 5 days post-procedure CT illustrating opening and closure of the SAPIEN XT valve (Edwards Lifesciences, Irvine, California) and (e) three-dimensional volumetric CT reconstruction of the SAPIEN XT valve within the Cook stent (Cook Medical, Bloomington, Indiana). *TEE* transesophageal echocardiography, *CAVI* caval valve implantation, *CT* Computed Tomography. Reprinted with permission from “Transcatheter Caval Valve Implantation Using Multimodality Imaging. Roles of TEE, CT, and 3D Printing,” by Brian O’Neill et al., *JIMG* 2015;8:221–225. Copyright (2015) by Elsevier Inc

Conclusion

CT scan plays an important role in the assessment of right heart disease. Moreover, CT role has been increasingly used in preinterventional percutaneous valve therapy. Assessment of patients with CT before percutaneous transcatheter tricuspid valve intervention could be of great value for implanting cardiologists, especially in locating the right coronary artery. New tricuspid valve therapies are evolving, although, evidence for the efficacy and safety is limited to case reports and small series. CT enables acquisition of high quality images of the tricuspid valve and the complex anatomical structures around it. Furthermore, CT provides important insights into the geometrical dimensions of the tricuspid valve and adjacent veins. These insights may help to guide the interventional cardiologists in the decision-making process and to prepare for the tricuspid valve intervention.

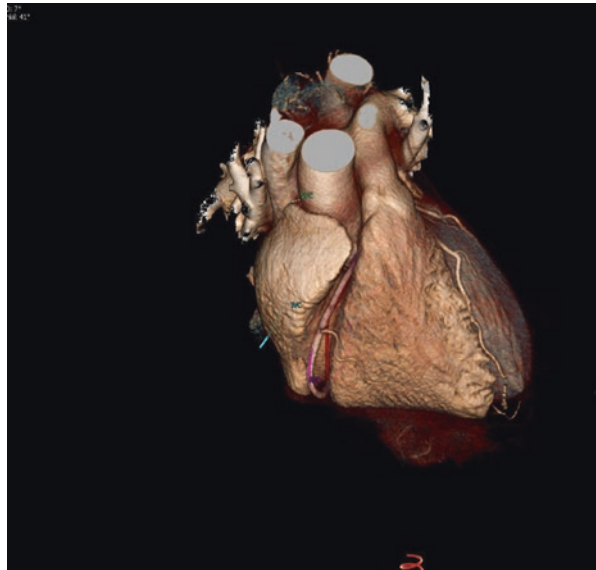
Appendix

Summary of MSCT planning of transcatheter tricuspid valve repair or replacement.

Due to increased attention and recognition of the need for TV repair or replacement, MSCT preplanning has gained more attention of analysis software developers. MSCT assists in patient selection, provides insight in anatomy and can serve as a roadmap to guide transcatheter valvular interventions. From single or multiphase CT scans e.g. the annulus shape and dimensions, relationship between annulus and right coronary artery position and location of right ventricular papillary muscles. Additionally, percutaneous access routes can be evaluated such as the vena cava inferior and jugular access. All information can be visualized as a virtual angiogram providing an essential link between the MSCT scan and the actual implantation procedure under X-ray. Currently dedicated MSCT planning software is being developed such as 3mensio Structural Heart.

The following figures (9.13–9.18) summarize a MSCT scan analysis using 3mensio Structural Heart.

Fig. 9.13 Volume rendering from MSCT scan showing atria, ventricles and coronary arteries (3mensio Structural Heart)



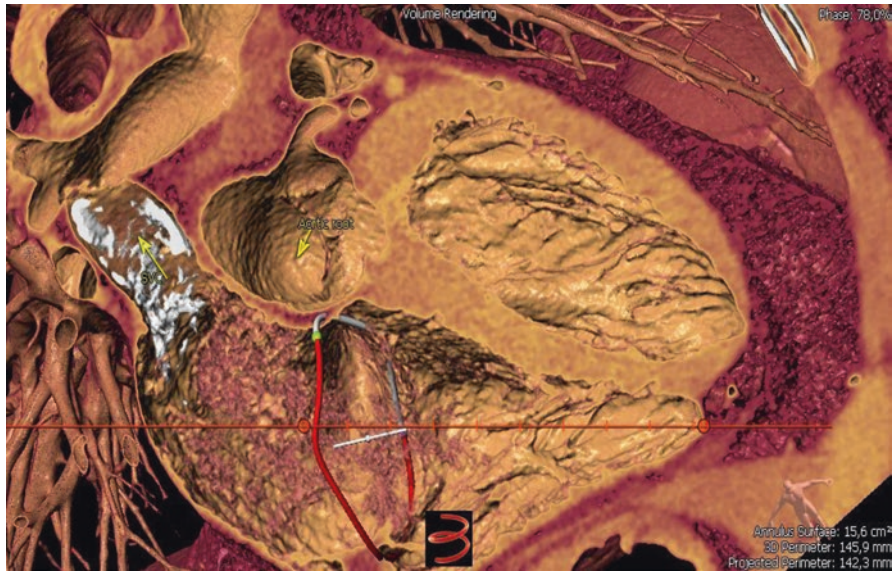


Fig. 9.14 Overview of the heart showing left and right ventricle, aortic root and superior vena cava (3mensio Structural Heart)

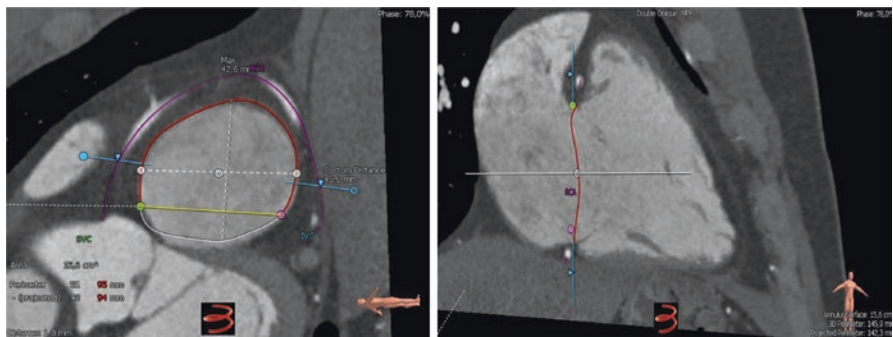


Fig. 9.15 Tricuspid annulus dimensions (*left*) and shape (*right*) (3mensio Structural Heart)

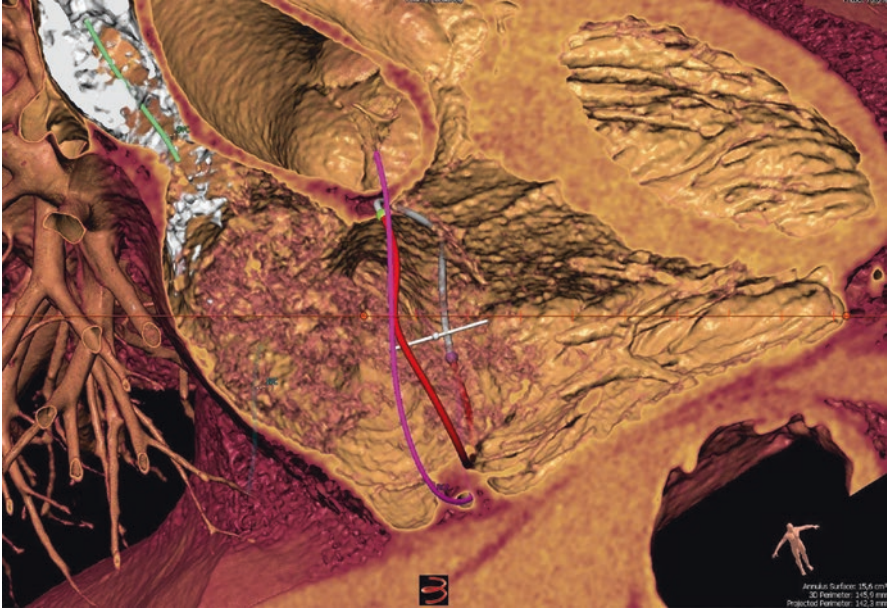

Fig. 9.16 Volume rendering showing tricuspid annulus and relationship with right coronary artery (purple) (3mensio Structural Heart)

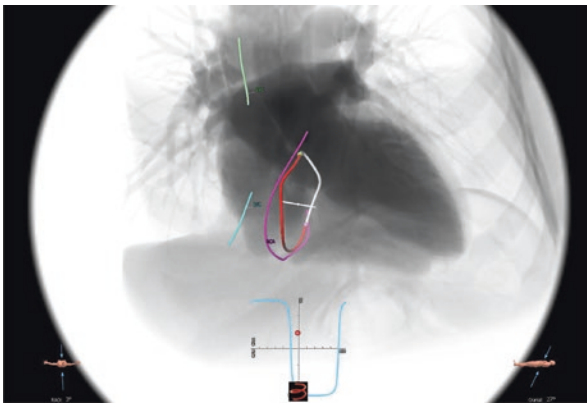


Fig. 9.17 Virtual angiogram showing tricuspid annulus, right coronary artery centerline (purple) and vena cava superior (green) and inferior centerlines (blue) (3mensio Structural Heart). The virtual angiogram shows what the operator can expect during the angiography guided procedure and shows optimal implantation views (bottom S-curve) on tricuspid annulus (e.g. co-axial, en-face), right ventricle and vena cava

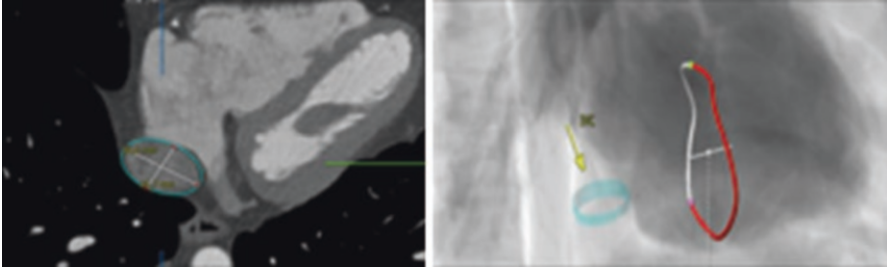


Fig. 9.18 Sizing of the inferior vena cava (left) and visualization on virtual angiogram (right) (3mensio Structural Heart)

Review Questions

Select the Single Best Sentence

51. Which of the following is the best imaging modality for the assessment of tricuspid valve leaflets?
 - (a) Cardiac MRI
 - (b) Echocardiography
 - (c) Cardiovascular Computed Tomography
 - (d) Angiography
52. Which of the following is the best imaging modality for the assessment of tricuspid valve annulus?
 - (a) Cardiac MRI
 - (b) 2D Echocardiography
 - (c) Cardiovascular Computed Tomography
 - (d) Angiography
53. Which of the following is the best imaging modality for the assessment of tricuspid valve vegetation and masses?
 - (a) Cardiac MRI
 - (b) Echocardiography
 - (c) Cardiovascular Computed Tomography
 - (d) Angiography
54. Which of the following is the best imaging modality for the assessment of right heart size?
 - (a) Cardiac MRI
 - (b) Echocardiography
 - (c) Cardiovascular Computed Tomography
 - (d) Angiography

55. Which of the following is the best imaging modality for the assessment of tricuspid valve regurgitation?
- (a) Cardiac MRI
 - (b) Echocardiography
 - (c) Cardiovascular Computed Tomography
 - (d) Angiography
56. Which of the following is the best imaging modality for intraprocedural guidance of tricuspid valve interventions?
- (a) Cardiac MRI
 - (b) Transoesophageal Echocardiography
 - (c) Cardiovascular Computed Tomography
 - (d) Angiography
57. Which of the following is the best imaging modality for the serial assessment of outcome of tricuspid valve interventions?
- (a) Cardiac MRI
 - (b) Echocardiography
 - (c) Cardiovascular Computed Tomography
 - (d) Angiography

References

1. Gopalan D. Right heart on multidetector CT. *Br J Radiol.* 2011;84(3):S306–23.
2. Schoepf UJ, Kucher N, Kipfmueller F, Quiroz R, Costello P, Goldhaber SZ. Right ventricular enlargement on chest computed tomography: a predictor of early death in acute pulmonary embolism. *Circulation.* 2004;110(20):3276–80.
3. Quiroz R, Kucher N, Schoepf UJ, Kipfmueller F, Solomon SD, Costello P, et al. Right ventricular enlargement on chest computed tomography: prognostic role in acute pulmonary embolism. *Circulation.* 2004;109(20):2401–4.
4. Johnson TR, Nikolaou K, Wintersperger BJ, Knez A, Boekstegers P, Reiser MF, et al. ECG-gated 64-MDCT angiography in the differential diagnosis of acute chest pain. *AJR Am J Roentgenol.* 2007;188(1):76–82.
5. Setty BN, Sahani DV, Ouellette-Piazzo K, Hahn PF, Shepard JA. Comparison of enhancement, image quality, cost, and adverse reactions using 2 different contrast medium concentrations for routine chest CT on 16-slice MDCT. *J Comput Assist Tomogr.* 2006;30(5):818–22.
6. Utsunomiya D, Awai K, Sakamoto T, Nishiharu T, Urata J, Taniguchi A, et al. Cardiac 16-MDCT for anatomic and functional analysis: assessment of a biphasic contrast injection protocol. *AJR Am J Roentgenol.* 2006;187(3):638–44.
7. Kerl JM, Ravenel JG, Nguyen SA, Suranyi P, Thilo C, Costello P, et al. Right heart: split-bolus injection of diluted contrast medium for visualization at coronary CT angiography. *Radiology.* 2008;247(2):356–64.
8. Cao L, Du X, Li P, Liu Y, Li K. Multiphase contrast-saline mixture injection with dual-flow in 64-row MDCT coronary CTA. *Eur J Radiol.* 2009;69(3):496–9.
9. Lu JG, Lv B, Chen XB, Tang X, Jiang SL, Dai RP. What is the best contrast injection protocol for 64-row multi-detector cardiac computed tomography? *Eur J Radiol.* 2010;75(2):159–65.

10. Sugeng L, Mor-Avi V, Weinert L, Niel J, Ebner C, Steringer-Mascherbauer R, et al. Multimodality comparison of quantitative volumetric analysis of the right ventricle. *JACC Cardiovasc Imaging*. 2010;3(1):10–8.
11. Ghaye B, Ghuyssen A, Bruyere PJ, D'Orio V, Dondelinger RF. Can CT pulmonary angiography allow assessment of severity and prognosis in patients presenting with pulmonary embolism? What the radiologist needs to know. *Radiographics*. 2006;26(1):23–39. discussion-40
12. Dreyfus GD, Corbi PJ, Chan KM, Bahrami T. Secondary tricuspid regurgitation or dilatation: which should be the criteria for surgical repair? *Ann Thorac Surg*. 2005;79(1):127–32.
13. Kimura F, Sakai F, Sakomura Y, Fujimura M, Ueno E, Matsuda N, et al. Helical CT features of arrhythmogenic right ventricular cardiomyopathy. *Radiographics*. 2002;22(5):1111–24.
14. Fukuda S, Saracino G, Matsumura Y, Daimon M, Tran H, Greenberg NL, et al. Three-dimensional geometry of the tricuspid annulus in healthy subjects and in patients with functional tricuspid regurgitation: a real-time, 3-dimensional echocardiographic study. *Circulation*. 2006;114(1 Suppl):I492–8.
15. Shah PM, Raney AA. Tricuspid valve disease. *Curr Probl Cardiol*. 2008;33(2):47–84.
16. Rodes-Cabau J, Taramasso M, O'Gara PT. Diagnosis and treatment of tricuspid valve disease: current and future perspectives. *Lancet*. 2016;388(10058):2431–42.
17. Nesser HJ, Tkalec W, Patel AR, Masani ND, Niel J, Markt B, et al. Quantitation of right ventricular volumes and ejection fraction by three-dimensional echocardiography in patients: comparison with magnetic resonance imaging and radionuclide ventriculography. *Echocardiography*. 2006;23(8):666–80.
18. Anwar AM, Soliman OI, Nemes A, van Geuns RJ, Geleijnse ML, Ten Cate FJ. Value of assessment of tricuspid annulus: real-time three-dimensional echocardiography and magnetic resonance imaging. *Int J Cardiovasc Imaging*. 2007;23(6):701–5.
19. van der Zwaan HB, Geleijnse ML, McGhie JS, Boersma E, Helbing WA, Meijboom FJ, et al. Right ventricular quantification in clinical practice: two-dimensional vs. three-dimensional echocardiography compared with cardiac magnetic resonance imaging. *Eur J Echocardiogr*. 2011;12(9):656–64.
20. Saremi F, Hassani C, Millan-Nunez V, Sanchez-Quintana D. Imaging evaluation of tricuspid valve: analysis of morphology and function with CT and MRI. *AJR Am J Roentgenol*. 2015;204(5):W531–42.
21. van Rosendael PJ, Joyce E, Katsanos S, Debonnaire P, Kamperidis V, van der Kley F, et al. Tricuspid valve remodeling in functional tricuspid regurgitation: multidetector row computed tomography insights. *Eur Heart J Cardiovasc Imaging*. 2016;17(1):96–105.
22. Nath J, Foster E, Heidenreich PA. Impact of tricuspid regurgitation on long-term survival. *J Am Coll Cardiol*. 2004;43(3):405–9.
23. Virmani R. The tricuspid valve. *Mayo Clin Proc*. 1988;63(9):943–6.
24. Anderson RH, Ho SY, Becker AE. Anatomy of the human atrioventricular junctions revisited. *Anat Rec*. 2000;260(1):81–91.
25. Restivo A, Smith A, Wilkinson JL, Anderson RH. Normal variations in the relationship of the tricuspid valve to the membranous septum in the human heart. *Anat Rec*. 1990;226(2):258–63.
26. Shah S, Jenkins T, Markowitz A, Gilkeson R, Rajiah P. Multimodal imaging of the tricuspid valve: normal appearance and pathological entities. *Insights Imaging*. 2016;7(5):649–67.
27. Saremi F, Ho SY, Cabrera JA, Sanchez-Quintana D. Right ventricular outflow tract imaging with CT and MRI: part 1, morphology. *Am J Roentgenol*. 2013;200(1):W39–50.
28. Feuchtner GM, Stolzmann P, Dichtl W, Schertler T, Bonatti J, Scheffel H, et al. Multislice computed tomography in infective endocarditis: comparison with transesophageal echocardiography and intraoperative findings. *J Am Coll Cardiol*. 2009;53(5):436–44.
29. Ueda A, McCarthy KP, Sanchez-Quintana D, Ho SY. Right atrial appendage and vestibule: further anatomical insights with implications for invasive electrophysiology. *Europace*. 2013;15(5):728–34.
30. Diez-Villanueva P, Gutierrez-Ibanes E, Cuerpo-Caballero GP, Sanz-Ruiz R, Abeytua M, Soriano J, et al. Direct injury to right coronary artery in patients undergoing tricuspid annuloplasty. *Ann Thorac Surg*. 2014;97(4):1300–5.

31. van Rosendael PJ, Kamperidis V, Kong WK, van Rosendael AR, van der Kley F, Ajmone Marsan N, et al. Computed tomography for planning transcatheter tricuspid valve therapy. *Eur Heart J*. 2017;38(9):665–74.
32. Campelo-Parada F, Perlman G, Philippon F, Ye J, Thompson C, Bedard E, et al. First-in-man experience of a novel transcatheter repair system for treating severe tricuspid regurgitation. *J Am Coll Cardiol*. 2015;66(22):2475–83.
33. O’Neill B, Wang DD, Pantelic M, Song T, Guerrero M, Greenbaum A, et al. Transcatheter caval valve implantation using multimodality imaging: roles of TEE, CT, and 3D printing. *JACC Cardiovasc Imaging*. 2015;8(2):221–5.
34. Shinn SH, Schaff HV. Evidence-based surgical management of acquired tricuspid valve disease. *Nat Rev Cardiol*. 2013;10(4):190–203.
35. Vassileva CM, Shabosky J, Boley T, Markwell S, Hazelrigg S. Tricuspid valve surgery: the past 10 years from the Nationwide Inpatient Sample (NIS) database. *J Thorac Cardiovasc Surg*. 2012;143(5):1043–9.
36. Fender EA, Nishimura RA, Holmes DR. Percutaneous therapies for tricuspid regurgitation. *Expert Rev Med Devices*. 2017;14(1):37–48.
37. Agarwal S, Tuzcu EM, Rodriguez ER, Tan CD, Rodriguez LL, Kapadia SR. Interventional cardiology perspective of functional tricuspid regurgitation. *Circ Cardiovasc Interv*. 2009;2(6):565–73.
38. Schofer J, Bijuklic K, Tiburtius C, Hansen L, Groothuis A, Hahn RT. First-in-human transcatheter tricuspid valve repair in a patient with severely regurgitant tricuspid valve. *J Am Coll Cardiol*. 2015;65(12):1190–5.
39. Latib A, Agricola E, Pozzoli A, Denti P, Taramasso M, Spagnolo P, et al. First-in-man implantation of a tricuspid annular remodeling device for functional tricuspid regurgitation. *JACC Cardiovasc Interv*. 2015;8(13):e211–4.
40. Taramasso M, Pozzoli A, Guidotti A, Nietlispach F, Inderbitzin DT, Benussi S, et al. Percutaneous tricuspid valve therapies: the new frontier. *Eur Heart J*. 2017;38(9):639–47.

Chapter 10

Tricuspid Annulus Measurements: Dynamic Changes in Health and Disease

Denisa Muraru and Luigi P. Badano

Abstract The most common cause of tricuspid regurgitation (TR) is the dilation of tricuspid annulus (TA). In patients with left-sided valve disease, an enlarged TA is currently regarded as a more reliable sign of associated tricuspid valve (TV) dysfunction, reflecting better the chronicity and the hemodynamic consequences of TR on TV apparatus over time than the actual severity of TR, which may vary significantly with loading conditions, respiration and technical factors. This paradigm shift has led to the more liberal indications for surgical annuloplasty at the time of left-sided valve surgical intervention and to the adoption of “prophylactic” TV annuloplasty if the TA diameter exceeds 40 mm (or 21 mm/m² body surface area), irrespective of TR severity. Due to limitations of conventional two-dimensional echocardiography in assessing maximal TA diameter, three-dimensional echocardiography is emerging as the future standard technique for accurately measuring the TA size. This chapter is focused on the characterization of TA geometry and function as a key component for maintaining the competency of the normal TV, and on its role in the pathophysiology and development of functional TR.

Keywords Tricuspid valve • Tricuspid annulus • Tricuspid regurgitation • Tricuspid insufficiency • Echocardiography • Three-dimensional echocardiography

Introduction

Since the ‘80s, it has been recognized that the most common cause of tricuspid regurgitation (TR) is not the intrinsic abnormality of the tricuspid valve (TV) itself, but the dilation of tricuspid annulus (TA) [1]. The awareness of the crucial role of TA dilation in the pathophysiology of functional TR has led to a renewed interest in the assessment of TA and to its identification as the main therapeutic target in symptomatic patients with significant TR. Unlike TR severity, TA size does not change as

D. Muraru, M.D., Ph.D. (✉) • L.P. Badano, M.D., Ph.D.
Department of Cardiac, Thoracic and Vascular Imaging, University of Padua, Padua, Italy
e-mail: denisa.muraru@gmail.com

swiftly and, once dilated, will not return to normal [2]. In patients with left-sided valve diseases, an enlarged TA is currently regarded as a more reliable sign of associated TV dysfunction, reflecting better the chronicity and the hemodynamic consequences of TR on TV apparatus over time than the actual severity of TR. The latter may vary significantly with loading conditions, respiration and technical factors [3]. This paradigm shift coupled with solid evidences showing a high mortality risk in case of redo surgery to treat late TR, have led to the more liberal indications for surgical annuloplasty in the recent guidelines and to the adoption of “prophylactic” TV annuloplasty at the time of left-sided valve surgical intervention by many surgeons. Finally, most of the current devices for percutaneous treatment of TR in high surgical risk patients act by downsizing the TA through various methods [4].

This chapter focuses on the TA geometry and function as a key component of the TV apparatus for maintaining the competency of normal TV, and on its role in the pathophysiology and development of functional TR. A thorough understanding of these mechanisms has profound implications for the imaging assessment of TV and to develop effective treatment options for patients with functional TR.

Normal Tricuspid Annulus: Size, Shape and Dynamics

Similar to the mitral annulus, the TA has a complex elliptical and saddle-shaped morphology [3]. Non-planar TA has higher points oriented in antero-posterior direction (i.e. anterior high point adjacent to the aortic valve and posterior high point at 180°) and lower points in medio-lateral direction [5] (Fig. 10.1).

It is worth noting, however, that the knowledge we have accumulated on the mitral annulus shape and dynamics does not apply to the TA, due to significant

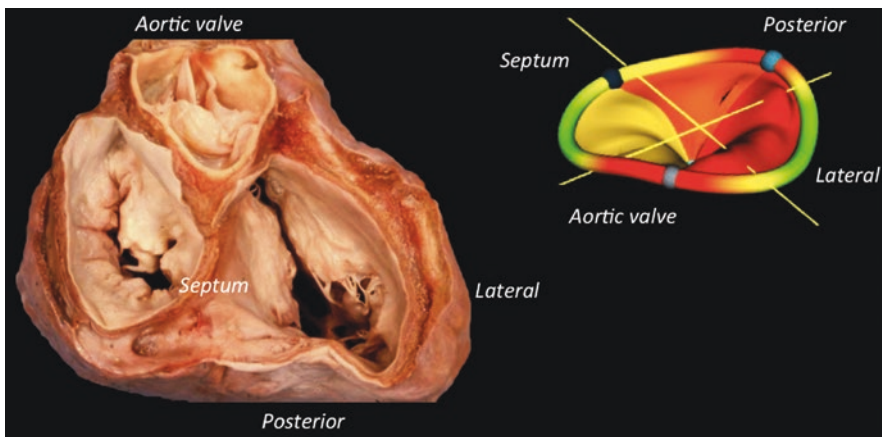


Fig. 10.1 Heart specimen (courtesy of Prof Cristina Basso, Cardiac Pathology, University of Padua) seen from atrial perspective, showing the tricuspid valve morphology and its spatial relationships with surrounding structures. At the right, a three-dimensional model of a normal tricuspid valve obtained by 3D echocardiography, illustrating the non-planar shape of tricuspid annulus (high annular points are color-coded in red, while low annular points are represented in green color; yellow leaflet—septal; red leaflet—anterior; orange leaflet—posterior)

differences in the anatomy and function, and in the spatial anatomic relationships of these two valves. For instance, mitral valve has two fibrous trigons (a right and a left one), while the TV has only one right fibrous trigon (Fig. 10.1). Between the two trigons, the mitral annulus has a fibrous part in continuity with the aortic valve, which is not surrounded by myocardium, possibly explaining the smaller systolic shortening of the mitral annulus area (28% on average) [6] in comparison with TA area (35%), which is surrounded by myocardium to a larger circumferential extent. In normal hearts, the mitral annulus is smaller and has a systolic longitudinal excursion towards the apex, while the TA is larger and has a more active and complex motion, combining longitudinal displacement and tilting (larger displacement at the free wall side than at the septal side). All these differences suggest that the normal anatomy and pathophysiology of TV should be understood and evaluated on its own, without translating prior knowledge derived from the mitral valve studies.

Using 2D echocardiography, the normal TA diameter in adults is 28 ± 5 mm and significant dilation is defined by a diastolic diameter >40 mm or >21 mm/mm² in the apical four-chamber view. Of note, it has been demonstrated that 2D echocardiography underestimates the maximal dimension of TA in comparison with 3D echocardiography (Fig. 10.2), cardiac magnetic resonance (CMR) and multi-detector computed tomography (MDCT) measurements [7–9].

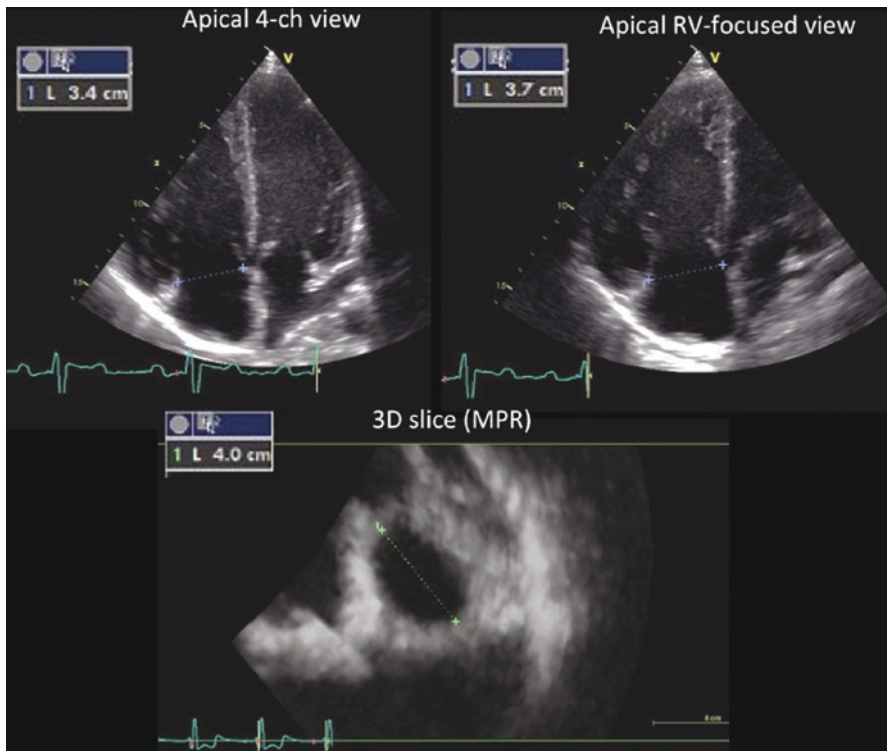


Fig. 10.2 Measurements of tricuspid annulus diameter by 2D echocardiography (a, b) and 3D echocardiography (c) in a patient with pulmonary arterial hypertension and functional tricuspid regurgitation. 2D echocardiography underestimated the maximal size of tricuspid annulus (particularly in the standard four-chamber view), with respect to the measurement obtained by 3D echocardiography

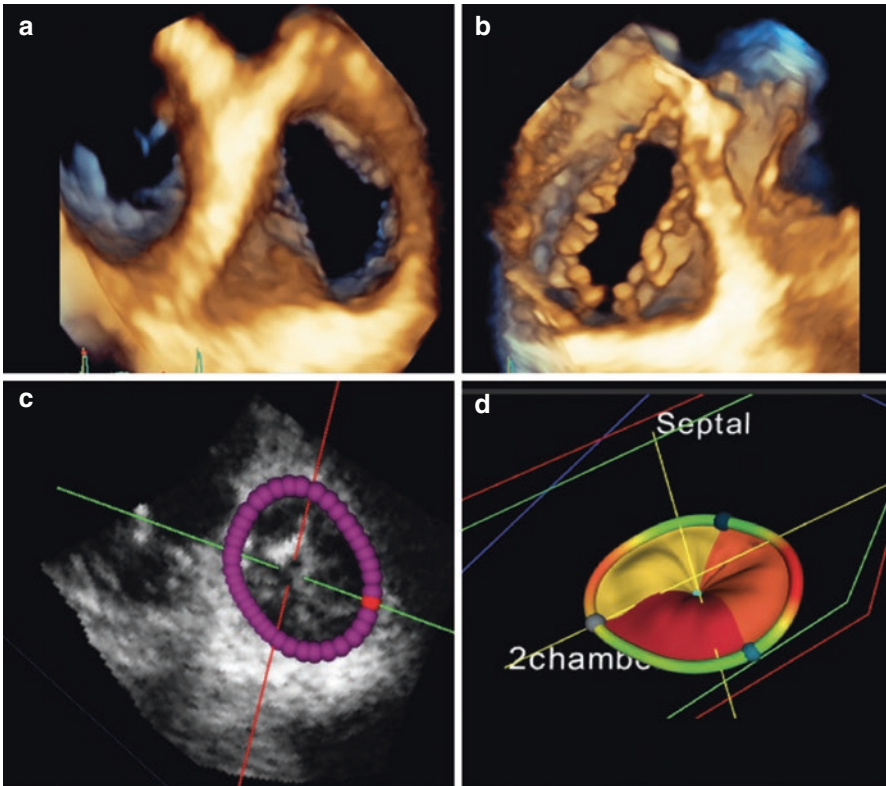


Fig. 10.3 Tricuspid valve anatomy by transthoracic 3D echocardiography in a patient with functional tricuspid regurgitation, as seen from atrial (a) and ventricular (b) perspective. Using custom prototype software (courtesy of Federico Veronesi, University of Bologna, Italy), the tricuspid annulus (c, d) and leaflets (d) geometry can be semi-automatically quantified

Using transthoracic 3D echocardiography, maximal and minimal linear dimensions of normal TA are 42 ± 5 mm (22 ± 2 mm/m²) and 36 ± 5 mm (19 ± 3 mm/m²). TA circularity (minimum:maximum diameters) is around 0.85 in late diastole, reflecting its elliptical shape (Fig. 10.3). Furthermore, normal values of TA geometry are 12 ± 1 cm² (6 ± 1 cm²/m²) for maximal area at late diastole, 12 ± 1 cm (7 ± 1 cm/m²) for maximal perimeter, while annular height between the highest and lowest point is around 7 mm (Fig. 10.1) [10, 11].

In healthy subjects, TA size and shape change significantly during the cardiac cycle. On average, TA linear dimensions and perimeter show >20% systolic shortening, while TA area shrinks by 35% during the cardiac cycle. TA area reaches a minimum in mid-to-late systole, then increases during isovolumic relaxation and diastole reaching a maximum value in late diastole after the onset of atrial contraction (end of P-wave) [5] (Fig. 10.4). Of note, the most significant reduction in TA size occurs in the pre-systolic phase of the cardiac cycle (after right atrial contraction and during isovolumic right ventricular contraction), with subsequent shortening during the first

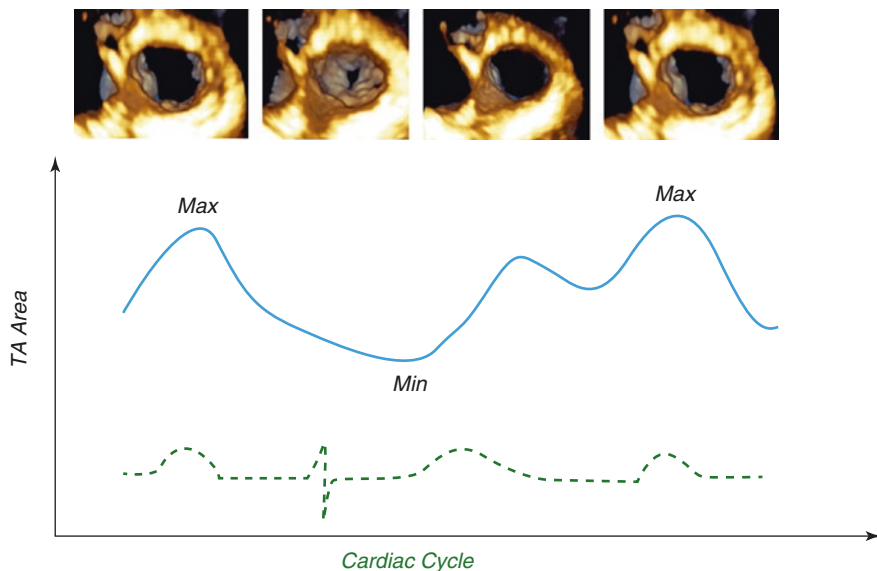


Fig. 10.4 Dynamic changes of tricuspid annulus (TA) area during the cardiac cycle. The maximal annular area is reached in late diastole, and the minimum area is reached during mid-late systole

part of systole. As seen in cross-section, TA shape becomes more circular during systole, and returns to more elliptical shape during diastole due to a relatively greater increase in antero-posterior dimension than in septo-lateral dimension.

TA size and function depend on gender, women having smaller and more dynamic TAs than men. However, indexing TA area by body size (i.e. body surface area) practically eliminates the differences between genders [11].

TA size depends also on the dimensions of right heart chambers, being more closely correlated with right atrial, than with right ventricular volumes [11, 12].

Changes in Tricuspid Annulus Geometry and Function in Functional Tricuspid Regurgitation

TA dilation, leaflet tethering, or both, can lead to secondary or functional TR.

With functional TR, the TA becomes larger, flatter and more circular [5]. The annulus becomes more circular with TR worsening due to the dilation of the TA preferentially along its free wall distance. Specifically, there is greater enlargement of the TA antero-posterior diameter (antero-septal commissure to posterior leaflet distance) than the medio-lateral diameter (septal-to-anterior leaflet distance) [5] (Fig. 10.5). This is likely due to the anterior high point of the TA being adjacent to the fibrous skeleton of the heart, providing more resistance to dilation than along the free wall. The ratio between the antero-posterior dimension and the annular height

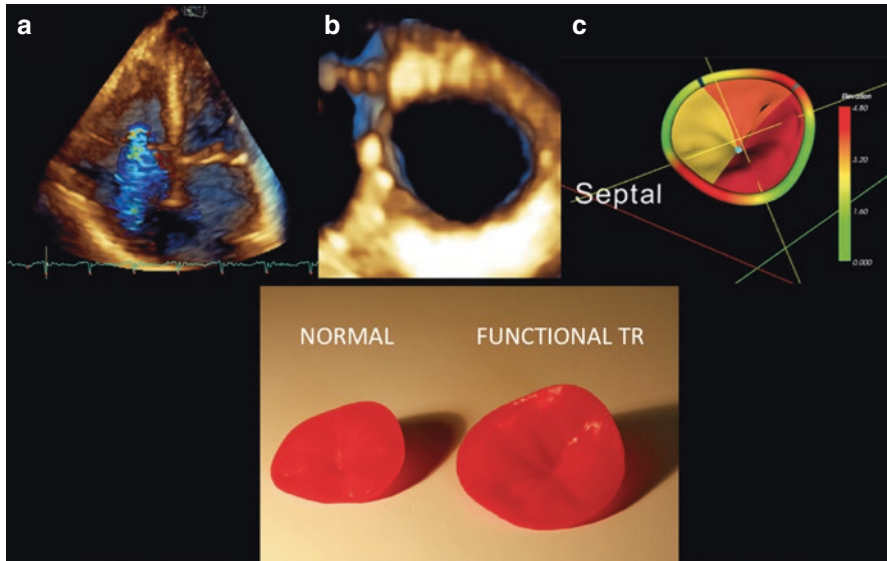


Fig. 10.5 Tricuspid annulus remodelling in severe functional tricuspid regurgitation (TR), as depicted by 3D echocardiography (a–c) and 3D printed models: the annulus becomes larger, rounder and flatter in comparison with normal annulus geometry

is a dimensionless index reflecting the TA remodelling (“stretch”) in dysfunctional TV, which increases markedly in functional TR in comparison with controls (13 ± 5 vs. 4 ± 1 , $p < 0.0001$) and together with TA area and circularity, are independent determinants of functional TR severity [5].

TA dilation is a constant feature in patients with functional TR and is poorly correlated with the severity of TR. Annular dilation is a reliable marker of TV dysfunction and a sign that the valve is prone to leak later on. In contrast with functional TR which may improve after the reduction of pulmonary pressures (i.e. after mitral valve surgery or after thromboendarterectomy in patients with chronic thromboembolic pulmonary hypertension [2]), TA dilation persists and will not return to normal values. The persistence of TA dilatation may explain why almost 40% of patients who underwent mitral valve surgery successfully may develop severe functional TR several years later despite absence of pulmonary hypertension [13]. However, almost 1 out of 2 patients *without* significant TA dilation at the time of mitral valve surgery (≥ 70 mm intraoperatively in Dreyfus series [14]) will still develop late TR, suggesting either that intraoperative TA diameter is an imperfect predictor of late TR, or that there are multiple contributing factors to TR late development in addition to TA size.

Functional TR is frequently associated with advanced stages of left-sided valve disease, myocardial or pulmonary diseases leading to increased pulmonary pressures, right ventricular dilation and/or dysfunction [3, 15]. Thus, it is an established belief that the dilation of right ventricle is the first mandatory step towards the TR development and univocally responsible for TA enlargement, even before significant TR is present [16]. However, this theory does not explain the occurrence of functional TR in chronic atrial fibrillation or its relatively low incidence in some conditions evolving with significant right ventricular dilatation (corrected tetralogy of Fallot, arrhythmogenic

cardiomyopathy etc) [17, 18]. Using 3D echocardiography-derived measurements of right heart chambers and TA in 59 patients with functional TR of various etiologies, we have found that right atrial volume was actually the most consistent determinant of TA area [19]. This may explain, at least in part, the onset of FTR in patients with dilated right atrium, but relatively small right ventricle (atrial fibrillation subgroup), and the absence of significant regurgitation in those with severely enlarged right ventricles, but preserved right atrial volumes (tetralogy of Fallot subgroup).

In patients with functional TR, there is also an impairment of TA “sphincteric” function and dynamics, with a significant decrease (up to 50%) in the systolic shortening of TA area and diameters [5].

Measurement of Tricuspid Annulus Dilation

Despite its importance for the diagnosis and therapy of functional TR, the sizing of TA remains an elusive goal. The best methodology for the noninvasive measurement of TA size is not clearly defined, and present thresholds for surgical annuloplasty based on TA diameter by conventional echocardiography are actually supported by limited evidence and have been questioned by several recent papers [20, 21].

So far, several approaches have been used to size the TA *in vivo* in TR studies. Dreyfus *et al.* have proposed the intraoperative sizing of TA from the antero-septal commissure to the antero-posterior commissure, and the 70 mm cut-off for defining significant TA dilation [14]. Performing an annuloplasty in all patients with TA above this threshold improved New York Heart Association functional class and prevented progression of functional TR at long-term follow-up. This approach was deemed reliable and reproducible by Dreyfus and coworkers [14], yet it has been criticized by others [20] due to its large variability with various degrees of TA stretching since the heart is unloaded and still during surgery.

Dreyfus *et al.* suggested that the intraoperative 70 mm diameter threshold corresponds to a 40 mm diameter measured in diastole by transthoracic 2D echocardiography between mid-anterior and mid-septal annulus in apical 4-chamber view [14, 22] (Fig. 10.2). This assumption actually has never been demonstrated experimentally and has been challenged recently by several recent 3D echocardiography studies showing that: (1) TA diameter in conventional 4-chamber view may represent the distance between septal leaflet and either anterior or posterior leaflet [23, 24] (Fig. 10.5); (2) the TA size by 2D echocardiography and surgical measurements correlate only modestly, and the difference between the two is much smaller (roughly 3 mm) [20] than the difference suggested in the seminal papers of Dreyfus *et al.* (30 mm) [14]; (3) 1 out of 5 healthy subjects have TA annulus >40 mm and would qualify for annuloplasty based on conventional 2D TA diameter [12]; (4) newer abnormality threshold for TA dilation could be larger—42 mm or 23 mm/m² [20].

Since the TA is a dynamic structure with an asymmetric saddle shape, even small variations in the angle of the ultrasound beam (Fig. 10.2) or in the timing of measurements can result in considerable discrepancies in TA size [12]. Although the TA measurement from apical four-chamber view seems to be preferred, being recommended by guidelines and different authors as more feasible and reproducible than

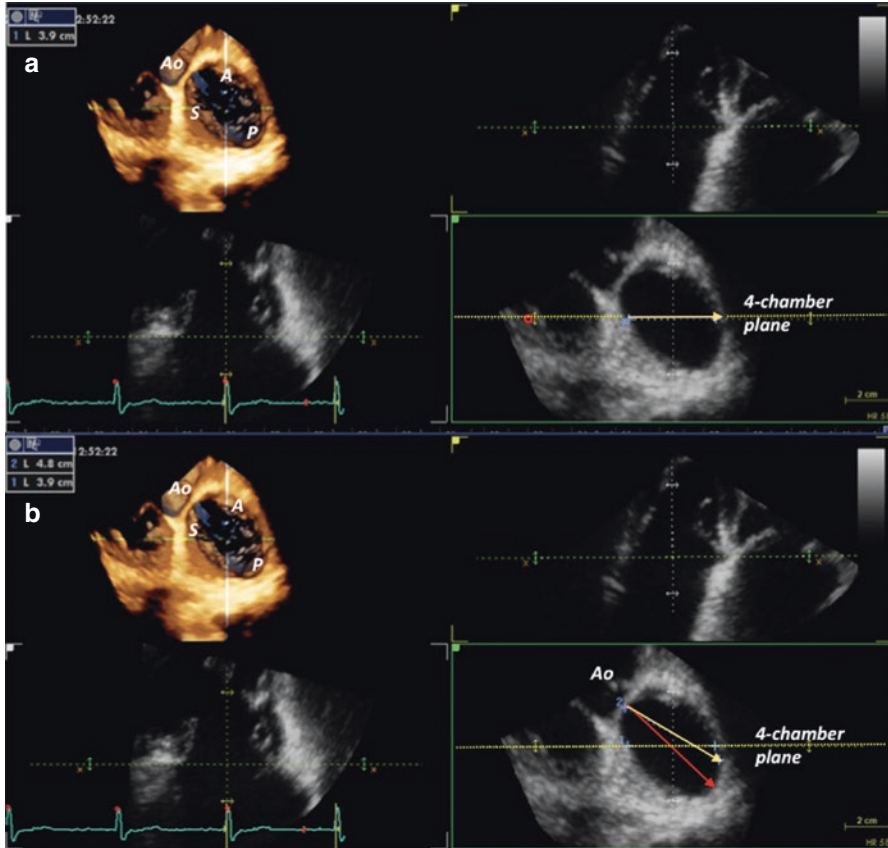


Fig. 10.6 Tricuspid annulus diameter in 4-chamber view (39 mm, panel **a**) is significantly smaller than the antero-posterior diameter (48 mm, *yellow arrow*—panel **b**) and both are smaller than the true maximal diameter of tricuspid annulus (50 mm, *red arrow*—panel **b**). All measurements pertain to the projected tricuspid annulus obtained from a 3D slice (MPR). *A* anterior, *Ao* aortic valve, *P* posterior, *S* septal

other views [8, 20], the best way and timing to measure the TA by conventional echocardiography still remain controversial [22] and require stronger evidence.

Two-dimensional echocardiography, either transthoracic or transesophageal, may underestimate the TA size. 3D echocardiography probably offers a more accurate evaluation of TA dilation by its ability to yield anatomically sound, quantitative measurements such as TA area, as well as true maximal and minimal diameters, irrespective of their spatial orientation [3]. In addition, semi-automated modeling of TV based on 3D echocardiography data offers unique quantitative measures of TA size and leaflet tenting volume, which account for the non-planarity of TA, as well as the asymmetry and inter-subject variability of leaflet size and tethering [25] (Fig. 10.3). Finally, current technology allows to obtain 3D prints of TV models and directly appreciate their different sizes and complex shapes (Figs. 10.6 and 10.7),

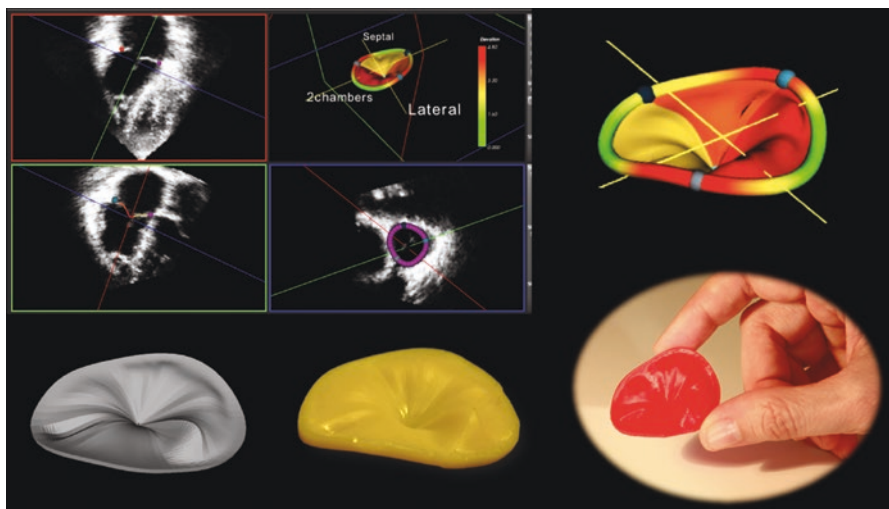


Fig. 10.7 Segmentation of normal tricuspid valve from transthoracic 3D dataset by custom software (courtesy of Federico Veronesi, University of Bologna, Italy), that can be used to obtain a 3D printed solid model of the valve

elevating our impressions from textured flat-panel coloured perspectives to actual exploration of the complex geometry of the TV, with the potential to guide personalized care of patients with functional TR [26.]

It can be foreseen that 3D echocardiography will become the standard technique for assessing the TV geometry and accurately measuring TA dimensions [22]. If so, there are a few caveats that have to be considered.

First of all, since 3D echocardiography provides larger values for TA annulus size than 2D echocardiography (Fig. 10.2), specific abnormality thresholds of TA should be used if measurements are obtained by 3D echocardiography. Secondly, due to the non-planarity of TA, software-derived semi-automated measurements (Fig. 10.3) may provide different results than manual measurements of TA diameters and area planimetry performed on a 3D slice of TA (Fig. 10.5). Thirdly, preliminary data using dedicated algorithms specifically developed for TA quantification showed that TA reference values should be gender-specific and indexed by body surface area, suggesting that the “one-size-fits-all” approach suggested for 2D TA diameter no longer holds true for 3DTA measurements. Finally, despite the use of a dedicated software algorithm applied on 3D echocardiographic data is the only way to account for TA non-planarity and peculiar geometry, at present there is no such software commercially available.

Other studies used either multi-detector computed tomography (MDCT) or magnetic resonance imaging (CMR) for measuring the TA size. Interestingly, the antero-posterior TA dimension by MDCT, and not the septal-lateral dimension, was an independent determinant of TR severity [9]. However, their clinical use of CMR and MDCT is limited at present for patients with unsatisfactory quality images.

Tricuspid Annulus Deformation: A “New” Pathophysiologic Entity for TR Development?

By virtue of its ability to image large volumes of the heart including multiple cardiac structures in vivo, 3D echocardiography has recently provided new mechanistic insights regarding the existence of a reciprocal functional interaction (“coupling”) between adjacent cardiac structures, such as aortic and mitral valves. Accordingly, it has been demonstrated that mitral valve repair with a rigid annuloplasty ring impacts on the function of untreated aortic valve [27] or that aortic stenosis impacts on mitral valve function through the calcification of aortic-mitral curtain [28].

As opposed to the mitral valve, the TV does not have a clear anatomic continuity with the aortic valve. However, looking at the base of the heart from the atrial perspective, one can appreciate that the posterior margins of the aortic root are wedged between the orifices of both atrio-ventricular valves (mitral and tricuspid, Fig. 10.1). Anatomically, the triangle between the non-coronary and the right coronary aortic sinuses incorporates the membranous septum, which is crossed on its right side by the hinge of the septal TV leaflet (which divides the septum into atrioventricular and interventricular components) [29]. Therefore, a possible geometric and functional interplay between TV and a dilated aortic root cannot be excluded.

Few isolated case reports advance the idea that TV dysfunction (regurgitation and/or stenosis) can rarely occur in acute type A aortic dissection [30], marked aortic tortuosity [31] or unruptured Valsalva sinus aneurysm [32, 33]. The suggested mechanism was the interference with the TV septal leaflet closure by the adjacent dilated aorta.

We recently studied and reported a clinical case of a patient with dilated ascending aorta and moderately-severe functional TR, that was likely due to the extrinsic compression and distortion of TV annulus by a dilated and tortuous aortic root [34] (Fig. 10.8). Using TA quantification by 3D echocardiography, we identified a small and severely elliptical TA which was clearly deformed by the adjacent aortic root, that most probably led to TR development by increasing the intercommissural distance and/or septal leaflet displacement.

Further studies are needed to clarify whether TA deformation by extrinsic compression may be an additional pathophysiological factor involved in the development of functional TR.

Unmet Needs and Future Research Directions

As TA dilation is the main player in the development of functional TR, it makes sense that the research in this area should focus on the quantitation of TA remodeling and function. However, leaflet size and tethering are the other key components that make the TV leak. In the presence of severe tethering of the leaflets, particularly if the leaflets are small, restrictive annuloplasty alone may not resolve functional TR and actually may worsen the regurgitation. In these cases, it may be safer to replace than to repair the TV [35].

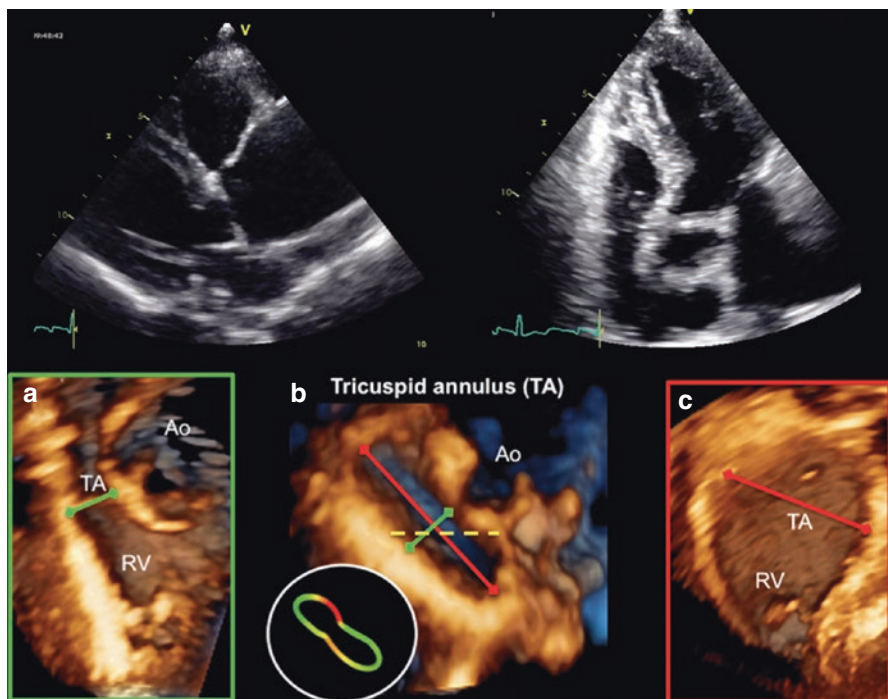


Fig. 10.8 Tricuspid annulus deformation due to extrinsic compression by dilated and tortuous ascending aorta demonstrated by 3D echocardiography, as the most likely cause of valve incompetency in a patient presenting with “idiopathic” tricuspid regurgitation. **(a)** minimal tricuspid annulus diameter (green); **(b)** en face view of tricuspid annulus, showing maximal (red) and minimal (green) diameters, as well as the 4-chamber diameter (yellow); **(c)** maximal tricuspid annulus diameter (red)

Further studies on the pathophysiology of functional TR, such as the relationships between TA area, extent of leaflets remodeling, right ventricular and atrial volumes and shape, and leaflet tethering are needed. The assessment of the relative contribution of annular dilations versus leaflet tethering to the occurrence of functional TR represents a challenge, which clarification is of critical importance for predicting which patients will benefit from annuloplasty-only repair techniques, and which patients require additional procedures (leaflet augmentation) or different treatment approaches (leaflet clipping, valve replacement, etc).

The various definitions of TA diameters used so far in tomographic imaging studies and the conflicting data regarding the correlation of TA size and TR severity highlights the need for standardization of TA linear measurements according to specific landmarks (mid-leaflet hinges, commissures, etc) which should be tested prospectively in future outcome studies.

Despite the lack of robust data and conflicting evidence, according to the 2012 ESC/EACTS [36] and 2014 AHA/ACC guidelines [37], we should still base our decision to indicate tricuspid annuloplasty on the 40 mm cut-off of TA diameter in apical 4-chamber view. When doing so, we have to be aware of its potential limitations and

that the current indications for the surgical treatment of functional TR are largely based on expert opinion. We definitely need prospective outcome studies and registries to specifically address the indications for functional TR treatment.

Conclusions

The tricuspid annulus is the main player in the development and progression of functional tricuspid regurgitation. Due to its complex, three-dimensional shape and highly dynamic structure, linear measurements of tricuspid annular size using conventional echocardiography have significant limitations, and 3D echocardiography seems more suitable and accurate for this purpose. The design of the future outcome studies and registries should take into account these peculiarities of tricuspid valve quantification, for a better understanding of tricuspid regurgitation pathophysiology and management.

Key Points The most common cause of tricuspid regurgitation is tricuspid annular dilation.

- However, not all functional tricuspid regurgitations can be explained by annulus dilation only; leaflet tethering, pulmonary hypertension and, possibly, tricuspid annulus distortion and dysfunction can also contribute to the development of tricuspid regurgitation.
- Normal tricuspid annulus is a complex-shaped, elliptical and dynamic structure. With progression of functional tricuspid regurgitation, annulus becomes larger, rounder, flatter and less dynamic.
- 3D echocardiography will become the standard technique for accurately measuring the tricuspid annulus dimensions, as conventional echocardiography significantly underestimates its maximal size.
- Normal tricuspid annulus area by 3D echocardiography depends on gender, body size, as well as right atrial and right ventricular volumes.
- Current guidelines advocate for an aggressive early tricuspid annuloplasty at the time of left-sided valve surgery, if the enlarged annulus measures more than 40 mm (or 21 mm/m²) in diastole in conventional apical four-chamber view. Lack of robust evidence and significant controversy exists around these cut-off values.

Review Questions

Select the Single Best Sentence

58. Which of the following statements about normal tricuspid annulus anatomy is true?

- (a) tricuspid annulus is larger than mitral annulus
- (b) similarly to mitral annulus, tricuspid annulus has two fibrous trigons
- (c) unlike the mitral annulus, tricuspid annulus has a circular shape
- (d) tricuspid annulus is less dynamic than mitral annulus

59. Which of the following statements about tricuspid annulus dilation is false?
- (a) is a more reliable sign of tricuspid valve dysfunction than the regurgitation itself
 - (b) may explain the functional tricuspid regurgitation in atrial fibrillation patients
 - (c) evolves in a symmetric fashion in all directions
 - (d) may be associated with various degrees of leaflet tethering
60. Which is the most reliable sign of tricuspid valve dysfunction?
- (a) tricuspid regurgitation severity
 - (b) tricuspid annulus dilation
 - (c) tricuspid leaflet tethering
 - (d) tricuspid coaptation distance
61. The largest tricuspid valve area is measured:
- (a) in early systole
 - (b) in mid-systole
 - (c) in early-diastole
 - (d) in late diastole
62. Normal absolute tricuspid annulus area in late diastole is around:
- (a) 6 cm²
 - (b) 10 cm²
 - (c) 12 cm²
 - (d) 20 cm²
63. Regarding the determinants of tricuspid annulus size by 3D echocardiography, which of the following statements is false?
- (a) tricuspid annulus size is smaller in women
 - (b) tricuspid annulus size should be indexed by body surface area
 - (c) tricuspid annulus size correlates with right ventricular volume, and not with right atrial volume
 - (d) tricuspid annulus size correlates with both right atrial and ventricular volumes
64. With respect to 3D echocardiography, the measurements of tricuspid annulus by 2D echocardiography are:
- (a) more accurate
 - (b) more reproducible
 - (c) do not allow the assessment of tricuspid annulus area
 - (d) may vary with the echocardiographic view and probe rotation
65. According to current guidelines, which is the cut-off of tricuspid annulus diameter in 4-chamber view for indicating surgical annuloplasty?
- (a) 35 mm
 - (b) 40 mm
 - (c) 42 mm
 - (d) 70 mm

66. Which of the following imaging methods can be used to size the tricuspid annulus?
- (a) 2D/3D echocardiography
 - (b) cardiac magnetic resonance
 - (c) multi-detector computerized tomography
 - (d) all of the above
67. Which of the following methods is the least accurate for assessing maximal TA diameter?
- (a) cardiac magnetic resonance
 - (b) 3D transthoracic echocardiography
 - (c) 2D transoesophageal echocardiography
 - (d) 2D transthoracic echocardiography

References

1. Tei C, Pilgrim JP, Shah PM, Ormiston JA, Wong M. The tricuspid valve annulus: study of size and motion in normal subjects and in patients with tricuspid regurgitation. *Circulation*. 1982;66:665–71.
2. Sadeghi HM, Kimura BJ, Raisinghani A, Blanchard DG, Mahmud E, Fedullo PF, et al. Does lowering pulmonary arterial pressure eliminate severe functional tricuspid regurgitation? Insights from pulmonary thromboendarterectomy. *J Am Coll Cardiol*. 2004;44:126–32.
3. Muraru D, Surkova E, Badano LP. Revisit of functional tricuspid regurgitation; current trends in the diagnosis and management. *Korean Circ J*. 2016;46:443–55.
4. Taramasso M, Pozzoli A, Guidotti A, Nietlispach F, Inderbitzin DT, Benussi S, et al. Percutaneous tricuspid valve therapies: the new frontier. *Eur Heart J*. 2017;38(9):639–647.
5. Ton-Nu TT, Levine RA, Handschumacher MD, Dorer DJ, Yosefy C, Fan D, et al. Geometric determinants of functional tricuspid regurgitation: insights from 3-dimensional echocardiography. *Circulation*. 2006;114:143–9.
6. Mihaila S, Muraru D, Piasentini E, Miglioranza MH, Peluso D, Cucchini U, et al. Quantitative analysis of mitral annular geometry and function in healthy volunteers using transthoracic three-dimensional echocardiography. *J Am Soc Echocardiogr*. 2014;27:846–57.
7. Anwar AM, Soliman OI, Nemes A, van Geuns RJ, Geleijnse ML, Ten Cate FJ. Value of assessment of tricuspid annulus: real-time three-dimensional echocardiography and magnetic resonance imaging. *Int J Cardiovasc Imaging*. 2007;23:701–5.
8. Anwar AM, Geleijnse ML, Ten Cate FJ, Meijboom FJ. Assessment of tricuspid valve annulus size, shape and function using real-time three-dimensional echocardiography. *Interact Cardiovasc Thorac Surg*. 2006;5:683–7.
9. van Rosendaal PJ, Joyce E, Katsanos S, Debonnaire P, Kamperidis V, van der Kley F, et al. Tricuspid valve remodelling in functional tricuspid regurgitation: multidetector row computed tomography insights. *Eur Heart J Cardiovasc Imaging*. 2016;17:96–105.
10. Fukuda S, Saracino G, Matsumura Y, Daimon M, Tran H, Greenberg NL, et al. Three-dimensional geometry of the tricuspid annulus in healthy subjects and in patients with functional tricuspid regurgitation: a real-time, 3-dimensional echocardiographic study. *Circulation*. 2006;114:1492–8.
11. Jenei C, Muraru D, Addetia K, Veronesi F, Cavalli G, Aruta P, et al. Determinants of normal tricuspid annulus area in healthy volunteers: a three-dimensional echocardiographic study [abstr]. *Eur Heart J*. 2015;Abstract Supplement:P85197.

12. Miglioranza MH, Mihaila S, Muraru D, Cucchini U, Iliceto S, Badano LP. Dynamic changes in tricuspid annular diameter measurement in relation to the echocardiographic view and timing during the cardiac cycle. *J Am Soc Echocardiogr*. 2015;28:226–35.
13. Anyanwu AC, Adams DH. Functional tricuspid regurgitation in mitral valve disease: epidemiology and prognostic implications. *Semin Thorac Cardiovasc Surg*. 2010;22:69–75.
14. Dreyfus GD, Corbi PJ, Chan KM, Bahrami T. Secondary tricuspid regurgitation or dilatation: which should be the criteria for surgical repair? *Ann Thorac Surg*. 2005;79:127–32.
15. Badano LP, Muraru D, Enriquez-Sarano M. Assessment of functional tricuspid regurgitation. *Eur Heart J*. 2013;34:1875–85.
16. Dreyfus GD, Chan KM. Functional tricuspid regurgitation: a more complex entity than it appears. *Heart*. 2009;95:868–9.
17. Rogers JH, Bolling SF. The tricuspid valve: current perspective and evolving management of tricuspid regurgitation. *Circulation*. 2009;119:2718–25.
18. Kobayashi J, Kawashima Y, Matsuda H, Nakano S, Miura T, Tokuan Y, et al. Prevalence and risk factors of tricuspid regurgitation after correction of tetralogy of fallot. *J Thorac Cardiovasc Surg*. 1991;102:611–6.
19. Surkova E, Bidviene J, Brunello G, Veronesi F, Cavalli G, Sokalskis V, et al. Tricuspid annulus area correlates more with right atrial than right ventricular volumes in patients with different mechanisms of functional tricuspid regurgitation. A 3-dimensional echocardiography study [abstr]. *Eur Heart J Cardiovasc Imaging*. 2016;Supplement.
20. Dreyfus J, Durand-Viel G, Raffoul R, Alkhoder S, Hvass U, Radu C, et al. Comparison of 2-dimensional, 3-dimensional, and surgical measurements of the tricuspid annulus size: clinical implications. *Circ Cardiovasc Imaging*. 2015;8:e003241.
21. Miglioranza MH, Mihaila S, Muraru D, Cucchini U, Iliceto S, Badano LP. Variability of tricuspid annulus diameter measurement in healthy volunteers. *JACC Cardiovasc Imaging*. 2015;8:864–6.
22. Dreyfus GD, Martin RP, Chan KM, Dulguerov F, Alexandrescu C. Functional tricuspid regurgitation: a need to revise our understanding. *J Am Coll Cardiol*. 2015;65:2331–6.
23. Addetia K, Yamat M, Mediratta A, Medvedofsky D, Patel M, Ferrara P, et al. Comprehensive two-dimensional interrogation of the tricuspid valve using knowledge derived from three-dimensional echocardiography. *J Am Soc Echocardiogr*. 2016;29:74–82.
24. Stankovic I, Daraban AM, Jasaityte R, Neskovic AN, Claus P, Voigt JU. Incremental value of the en face view of the tricuspid valve by two-dimensional and three-dimensional echocardiography for accurate identification of tricuspid valve leaflets. *J Am Soc Echocardiogr*. 2014;27:376–84.
25. Muraru D, Badano LP, Sarais C, Solda E, Iliceto S. Evaluation of tricuspid valve morphology and function by transthoracic three-dimensional echocardiography. *Curr Cardiol Rep*. 2011;13:242–9.
26. Muraru D, Veronesi F, Maddalozzo A, Dequal D, Frajhof L, Rabischoffsky A, et al. 3d printing of normal and pathologic tricuspid valves from transthoracic 3d echocardiography data sets. *Eur Heart J Cardiovasc Imaging* 2016;in press.
27. Veronesi F, Caiani EG, Sugeng L, Fusini L, Tamborini G, Alamanni F, et al. Effect of mitral valve repair on mitral-aortic coupling: a real-time three-dimensional transesophageal echocardiography study. *J Am Soc Echocardiogr*. 2012;25:524–31.
28. Tsang W, Meineri M, Hahn RT, Veronesi F, Shah AP, Osten M, et al. A three-dimensional echocardiographic study on aortic-mitral coupling in transcatheter aortic valve replacement. *Eur Heart J Cardiovasc Imaging*. 2013;14:950–6.
29. Anderson RH. Clinical anatomy of the aortic root. *Heart*. 2000;84:670–3.
30. Kurisu K, Baba H, Nakashima H, Kajiwara T, Hisahara M, Joo K, et al. Tricuspid regurgitation resulting from acute type a aortic dissection. *Ann Thorac Surg*. 2014;98:e5–6.
31. Mori S, Yagi T, Otomo K, Meguro T. Severe deformation of right atrium and tricuspid annulus due to compression by tortuous aorta. *J Cardiovasc Electrophysiol*. 2012;23:881.
32. Gibbs KL, Reardon MJ, Strickman NE, de Castro CM, Gerard JA, Rycyna JL, et al. Hemodynamic compromise (tricuspid stenosis and insufficiency) caused by an unruptured aneurysm of the sinus of valsalva. *J Am Coll Cardiol*. 1986;7:1177–81.

33. Bulkley BH, Hutchins GM, Ross RS. Aortic sinus of valsalva aneurysms simulating primary right-sided valvular heart disease. *Circulation*. 1975;52:696–9.
34. Muraru D, Bidviene J, Cavalli G, Cavaliere A, Badano LP. Tricuspid regurgitation in a patient with ascending aorta aneurysm. *Eur Heart J Cardiovasc Imaging* 2016;17 (12), 1435.
35. David TE. Functional tricuspid regurgitation: a perplexing problem. *J Am Soc Echocardiogr*. 2009;22:904–6.
36. Joint Task Force on the Management of Valvular Heart Disease of the European Society of Cardiology, European Association for Cardio-Thoracic Surgery, Vahanian A, Alfieri O, Andreotti F, Antunes MJ, et al. Guidelines on the management of valvular heart disease (version 2012). *Eur Heart J*. 2012;33:2451–96.
37. Nishimura RA, Otto CM, Bonow RO, Carabello BA, Erwin JP, 3rd, Guyton RA, et al. 2014 aha/acc guideline for the management of patients with valvular heart disease: a report of the american college of cardiology/american heart association task force on practice guidelines. *J Am Coll Cardiol* 2014;63:e57–185.

Chapter 11

Imaging of the Right Ventricle: Overview of Imaging Modalities for Assessing RV Volume and Function

Annemien van den Bosch and Roderick van Grootel

Abstract During recent years, the knowledge on right ventricular (RV) characteristics has become increasingly appreciated, as RV function has established itself as an important determinant of outcome in different cardiovascular diseases. Currently, echocardiography and cardiac magnetic resonance (CMR) imaging are the two imaging modalities most commonly used to visualize the RV. Most structural abnormalities of the RV can be reliably described by echocardiography but due its complex geometrical shape, echocardiographic assessment of RV function is more challenging. Newer promising echocardiographic techniques such as speckle tracking echocardiography are emerging into the clinical practise but lack of validation and limited normal reference data hamper their routine clinical application. CMR is generally considered the clinical reference technique due to its unlimited imaging planes, superior image resolution, and three-dimensional volumetric rendering. The accuracy and reliability of CMR makes it the ideal tool for serial examinations of RV function. Multidetector computed tomography (MDCT) can be used for assessing RV function, especially when CMR is contra-indicated. Radionuclide techniques have become more obsolete in the current era. In the setting of RV function and size assessment, echocardiography and CMR are the technique of choice.

Keywords Right ventricle • 2D echocardiography • MRI • MSCT • systolic function • regurgitation • radionuclide imaging

Sources of Funding: No sources of funding were received for this work. All authors have reported that they have no relationships to disclose.

A. van den Bosch, M.D., Ph.D. (✉) • R. van Grootel
Department of Cardiology, Thoraxcenter, Erasmus Medical Center,
Rotterdam, The Netherlands
e-mail: a.e.vandenbosch@erasmusmc.nl

Introduction

The right ventricle (RV), having a complex geometry, is often been neglected and hence undermining its importance in different cardiovascular diseases. RV function has been shown to be one of the major determinant in patients with chronic heart failure, pulmonary arterial hypertension and ischemic heart disease [1–10]. Identifying the most sensitive markers of RV dysfunction is of immense importance in daily clinical practice. RV function can be impaired by primary right sided heart disease, or secondary to left sided cardiomyopathy or valvular heart disease. For example, RV function can be influenced by pressure or volume overload from an incompetent valve or muscle pathology. Different imaging modalities can be used for imaging the RV and the role and clinical use of these imaging techniques are increasing.

Currently, echocardiography and cardiac magnetic resonance (CMR) imaging are the most commonly used imaging techniques for the assessment of RV morphology and function. Other imaging modalities such as computed tomography (CT) and radionuclide techniques are valuable alternatives but have limited value for the assessment of RV function and size.

Right Ventricular Anatomy and Physiology

The RV is located immediately behind the sternum and is positioned anteriorly to the left ventricle (LV). Correct identification of structural characteristics of the RV cavity is the start of a RV assessment, regardless of the used imaging modality. The morphology of the RV is clearly different from the LV as it has a more complex geometrical anatomic shape. The inlet part of the RV is much smaller than the LV and RV muscle mass is approximately 1/6 of the LV, which can be explained due to the different loading conditions. The RV is more triangular in shape and it curves over the near conical shape of the LV making the cavity a crescent—like shape in cross section. Morphologically, the RV is composed of several anatomical segments that can be described in terms of three component parts namely the inlet, apical trabecular and outlet or right ventricular outflow tract (Fig. 11.1). The fiber architecture of the LV and RV is also different. The LV wall has a three-layered structure with the epicardial cells oriented obliquely, the mid-myocardial cells more circumferentially, and the endocardial cells again obliquely [11]. The RV wall has a two-layered structure with the epicardial fibers oriented obliquely and contiguous with epicardial LV fibers, and the RV endocardial fibers are oriented longitudinally. This fiber arrangements elucidates that RV ejection is determined by longitudinal shortening rather than by circumferential deformation. Also there is a peristaltic contraction of the RV from inflow to outflow. The LV-RV interaction, caused by the shared interventricular septum and continuity between the muscle fibers of the LV and RV, plays an important role in RV and LV function. Also neurohormonal biomarkers

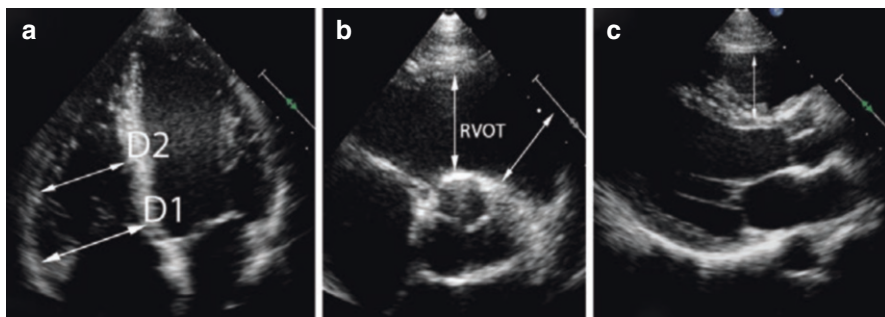


Fig. 11.1 Measurements of RV dimensions. The RV basal (D1) and mid cavity (D2) dimensions are shown in the RV focused apical four-chamber view (a). Measurements of the right ventricular outflow tract (RVOT) at the proximal level and at the distal level are shown in the parasternal short-axis (b) and parasternal basal long-axis (c)

have significant influence on the biventricular function. It is important to keep in mind, that left-sided valve disease and failure can result in elevated pulmonary venous pressure with or without an increase in vascular resistance. This has its consequences as it increases the afterload for the RV resulting in RV enlargement, tricuspid annular dilatation and functional tricuspid valve regurgitation. The mechanism of this cascade led to the concept that treatment of left-sided pathology will result in secondary improvement of tricuspid valve regurgitation. However, this paradigm has been advocated because treatment of left-sided pathology alone, will not directly improve RV function, correct TV annulus dilatation or reduce the functional tricuspid valve regurgitation.

Also, in patients with long standing pulmonary hypertension, RV dysfunction and tricuspid valve regurgitation might remain well established and irreversible. Therefore, imaging of the RV should be directed towards RV enlargement, TV annulus dilatation and RV function.

Imaging Modalities for Assessment of RV Function and Size, and Tricuspid Annulus Size

Echocardiography

In every echocardiographic examination, RV size and function should be assessed at the time of the first diagnosis and during serial follow up, particularly in patients with chronic diseases and heart failure. Guidelines for the echocardiographic evaluation of the RV have been published for the adult population and emphasize the importance of 2D multiple views for the assessment of the entire RV and to distinguish the different RV segments, including the apical views as well as the parasternal long-axis and short-axis views and subcostal view. The RV dimensions are best

estimated from a RV-focused apical four-chamber view obtained with either lateral or medial transducer orientation. Care should be taken to avoid foreshortening of the RV. Reference values for the adult population are reported in the echocardiographic guidelines for cardiac chamber quantification by the American Society of Echocardiography and the European Association of Cardiovascular Imaging [12] (Table 11.1). The tricuspid annulus dimensions are measured in end-diastole and end-systole in an apical four-chamber view.

Table 11.1 Reference value for right atrial and ventricular size and function, and TV annulus for echocardiography and CMR^a

	Abnormal	
	Women	Men
<i>Echocardiography</i>		
RA minor axis dimension (cm/m ²)	>2.5	>2.5
RA major axis dimension (cm/m ²)	>3.1	>3.0
2D echocardiographic RA volume (ml/m ²)	>33	>39
<i>RV diameter</i>		
– Basal diameter (mm)	>41	>41
– Mid diameter (mm)	>35	>35
– Longitudinal diameter (mm)	>83	>83
– RVOT PLAX diameter (mm)	>30	>30
– RVOT proximal diameter (mm)	>35	>35
– RVOT distal diameter (mm)	>27	>27
– Wall thickness (mm) RVOT, right ventricular outflow tract	>5	>5
<i>RV volume</i>		
– EDV indexed to BSA (ml/m ²)	>74	>87
– ESV indexed to BSA (ml/m ²)	>36	>44
<i>RV systolic function</i>		
– TAPSE (mm)	<17	<17
– Pulsed Doppler S' wave (cm/sec)	<9.5	<9.5
– Color Doppler S wave (cm/sec)	<6.0	<6.0
– RV fractional area change (%)	<35	<35
– RV 3D EF (%)	<45	<45
<i>TV annulus</i>		
– Diameter at end-systole (cm)	>3.4	>3.4
– Diameter at end-systole indexed to BSA (cm/m ²)	>1.9	>1.7
– Diameter at end-diastole (cm)	>3.9	>3.9
– Diameter at end-diastole indexed to BSA (cm/m ²)	>2.2	>2.0
<i>Cardiovascular magnetic resonance</i>		
– EDV indexed to BSA (ml/m ²)	>76	>91
– ESV indexed to BSA (ml/m ²)	>29	>40
– EF (%)	<57	<52

RA, Right Atrium; RVOT, Right Ventricular Outflow Tract; EDV, End Diastolic Volume; ESV, End Systolic Volume; TAPSE, Tricuspid Annular Plane Systolic Excursion; EF, Ejection Fraction; BSA, Body Surface Area.

^aLang R, Eur Heart J Cardiovasc Imaging, 2015

RV Function

RV systolic function can be evaluated by using multiple parameters, including TAPSE, 2D RV Fractional Area Change (FAC), 3D echocardiography, and longitudinal strain and strain rate by Doppler Tissue Imaging (DTI) and 2D speckle tracking.

A simple and very attractive tool for measuring systolic long-axis motion of the RV free wall or tricuspid annular plane systolic excursion (TAPSE) in the apical four-chamber view is the two dimensional guided M-mode, which has a good correlation with ejection fraction derived by radionuclide angiography (Fig. 11.2). Moreover, it has been demonstrated to be valuable in ischemic heart disease and cardiomyopathy. The main limitation of this method is that it only represents the longitudinal shortening of the RV lateral wall, thus excluding the RV outflow tract and septal contribution to the overall function of the right heart. Furthermore, in patients with dilated cavity and volume overloaded right ventricles as is the case in the presence of tricuspid regurgitation, TAPSE can erroneously overestimate RV function.

Right ventricular fractional area change (RV FAC) has been shown to correlate with RV Ejection Fraction (EF) calculated by CMR and is an independent predictor for outcome after myocardial infarction (Fig. 11.3). RV FAC provides an estimation of the global RV systolic function. However, poor image quality and visualization of the endocardial borders are often limiting this technique, especially in the RV lateral wall and RV apex.

RV index of myocardial performance (RIMP) or Tei index is a Doppler method that assesses the overall RV function. This can be achieved by dividing the total isovolumic time (the sum of the isovolumic contraction and isovolumic relaxation) by the pulmonary ejection time. The RIMP or Tei index is load dependent and due to the short RV isovolumic time intervals, its use remains controversial.

DTI is a robust technique used to assess RV function by reflecting RV free wall systolic and diastolic myocardial velocities in a reproducible way. The peak DTI systolic velocity of the tricuspid annulus is a measurement of RV longitudinal func-

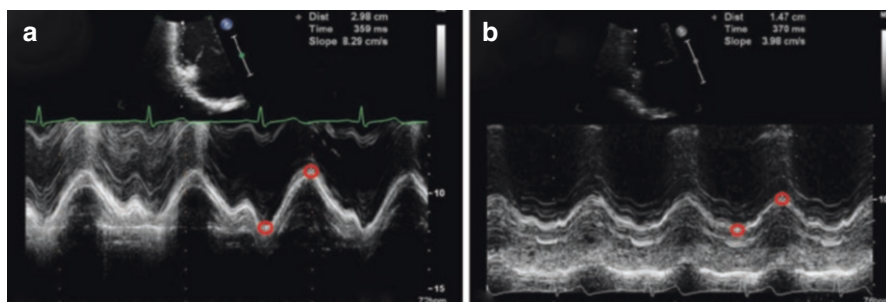


Fig. 11.2 Measurements of the tricuspid annular plane excursion (TAPSE) in a patients with normal RV function (a) and in a patients with RV dysfunction due to pulmonary hypertension (b)

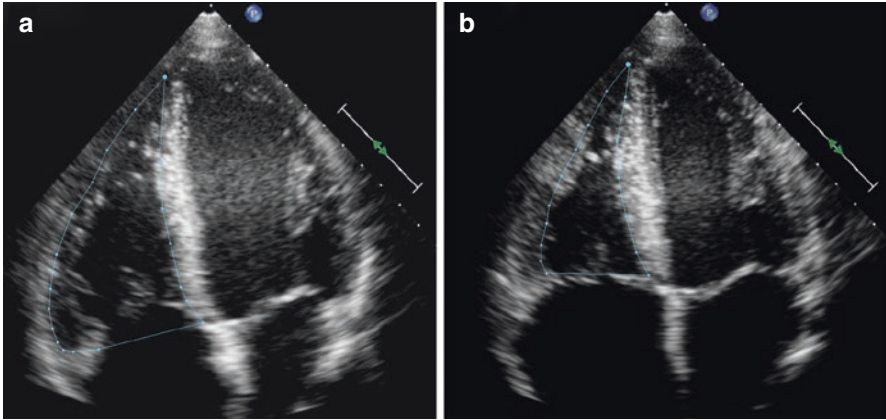


Fig. 11.3 Measurement of RV fraction area change (RV FAC). The endocardial border is traced in the RV focused apical four-chamber views from the tricuspid annulus along the free wall to the apex, then back to the annulus along the interventricular septum. This is performed in end-diastole (a) and systole (b). The RV FAC = (end-diastolic area—end-systolic area/end-diastolic area) \times 100%

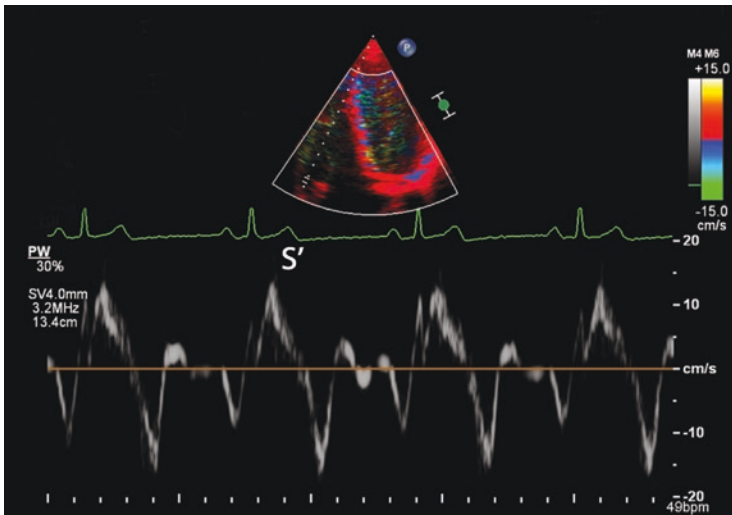


Fig. 11.4 Doppler Tissue Imaging of the tricuspid annulus, measuring the velocity of tricuspid annular systolic motion in a patients with normal RV systolic function. S' velocity <9.5 cm/s measured on the free-wall side indicates RV systolic dysfunction

tion (Fig. 11.4). This technique is easy and reproducible but has the limitations of being angle-dependent, load-dependent, and influenced by the global cardiac translation and tricuspid regurgitation. In the adult population, a normal cut-off value of ≥ 10 cm/s has been proposed.

With speckle-tracking echocardiography, strain and strain rate measurements are much easier to assess (Fig. 11.5). Strain is defined as the percentage change

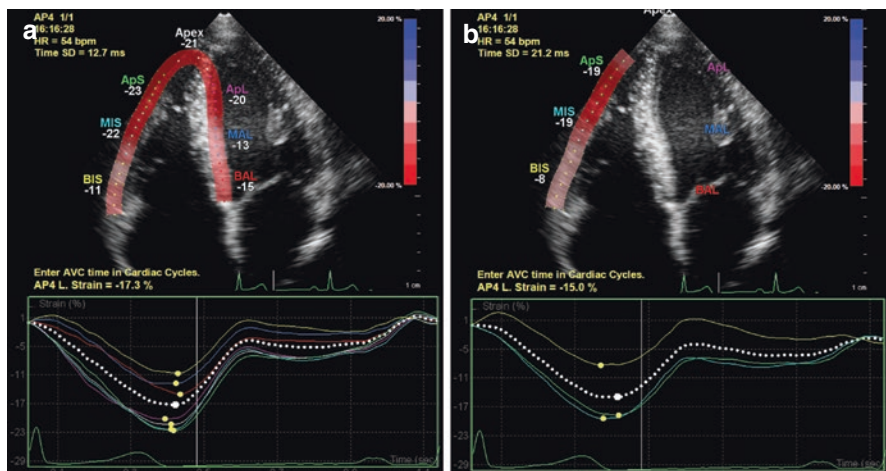


Fig. 11.5 Peak values of 2D longitudinal speckle tracking derived strain is assessed in the RV focused apical four-chamber view. In the literature, RV strain and strain rate is assessed as the averaged of all segments of the free wall and interventricular septum (a) or the three segments of the RV free wall (b)

in myocardial deformation and its derivative, strain rate represents the rate of change of deformation of a myocardium segment over time. Strain and strain rate imaging are used to measure regional and global contractile function using frame by frame tracking of unique speckles in the myocardium. Although developed for the LV, it is also applicable to the RV. Global longitudinal strain and strain rate measurement are independent from global cardiac motion and allow quantifying regional myocardial deformation in the different RV segments. Its main advantage is that it is angle independent and it can track in two or even three dimensions. Furthermore, it provides segmental as well as global assessment of the myocardium and it possesses an improved signal to noise ratio. On the other hand, the main disadvantage is that there is a lack of normal range for segmental and global measurements and strain values are influenced by loading conditions, RV size and stroke volume.

With simultaneous multi-plane imaging (X-plane and I-rotation), a comprehensive evaluation of the RV can be achieved, from one acoustic window based on anatomic landmarks. With this new approach for RV assessment, a rotation through the RV is performed and all RV walls, including the anterior, lateral, inferior and RV outflow tract (RVOT) anterior wall of the RV can be assessed. The rotation takes only a few minutes, making it very attractive for routine use in the echo-lab. Also, there is a high feasibility of the RV segments.

3D echocardiography has been developed for the last 15 years and RV volume and function can be accurately assessed as well, including more complete views of the valves. 3D echocardiography overcomes the geometric assumptions of 2D echocardiography and also overcomes some of the disadvantages of CMR as it can be routinely

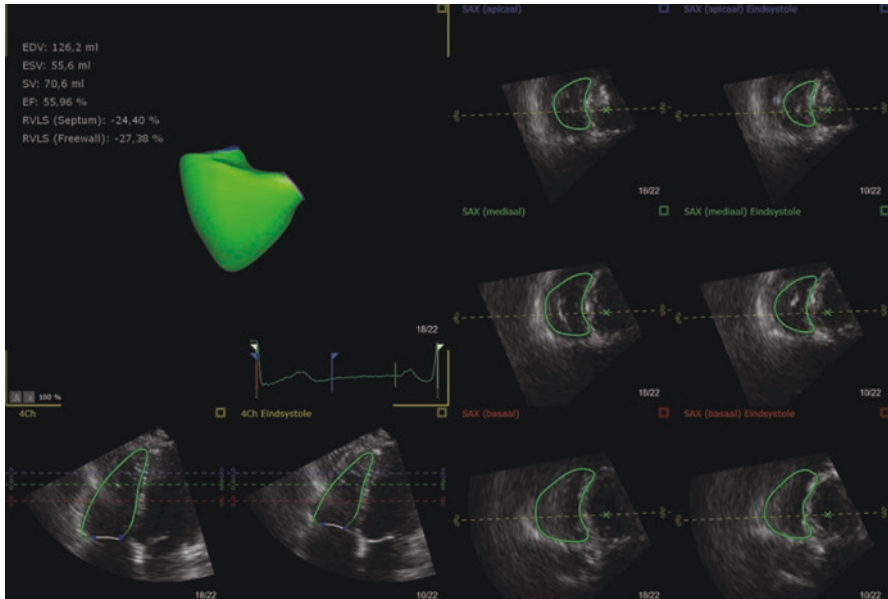


Fig. 11.6 Example of RV 3D volume assessment. Contouring is performed in three different perpendicular planes through the RV cavity and based on the semi-automatic contouring, the RV volume (end-diastole and end-systole) and ejection fraction is calculated and presented in a 3D model of the RV

used for serial imaging, particularly at the bed-side (Fig. 11.6). There are different methods for the analysis of 3D volumetric data sets; the recommended method is the volumetric semi-automated border detection approach. This method has been proven to be reliable and accurate in different conditions. The challenge is to acquire a good quality full volumetric 3D data set, including the RV anterior wall and the RV apical lateral segments in patients with poor imaging windows and arrhythmias.

Right Ventricular Size

Assessment of RV dimensions using 2D echocardiography is challenging due to the complex geometry as well as its heavy trabeculation of the RV wall. Recent data have suggested that RV linear measurements and volumetric measurements should be indexed to BSA in some circumstances. Reference values for RV dimensions are reported in Table 11.1.

Cardiovascular Magnetic Resonance

The role of CMR is well established for comprehensive RV evaluation and provides high resolution imaging with no need of geometric assumptions and lacks ionizing radiation. CMR is considered the clinical reference technique for accurate

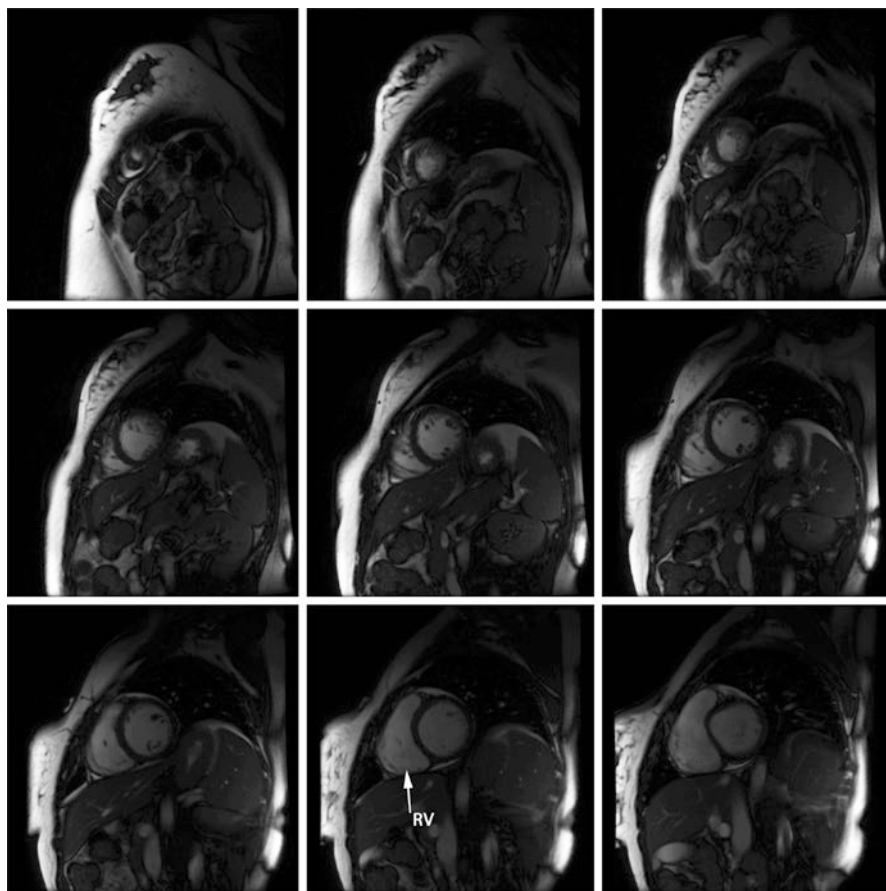


Fig. 11.7 CMR assessment of biventricular volumes and mass. Cross-sections of the left and right ventricle that are useful for volumetric measurements using the disk summations method

assessment of global RV function and volume. Ventricular volume is determined using short-axis or axial SSFP images without need for contrast administration and with the method of disk summation technique, RV volumes and EF is calculated (Fig. 11.7). Appropriate spatial and temporal resolution of the images is important for endocardial and epicardial contour tracing, either manually or with the use of semi-automated software on end-diastolic and systolic frames. Normative age- and gender-specific values for RV volumes and function have been published for the adult and the pediatric population. The CMR RV measurements have a high accuracy and reproducibility with a low intra- and interobserver variability. This makes CMR the ideal tool for serial examination of RV function. Regional RV function can be evaluated qualitatively at rest and during pharmacological stress on SSFP short-axis cine loops. Regional dysfunction can be assessed quantitatively with myocardial tagging or strain encoding CMR; both techniques have been shown to be feasible in the RV and correlate well with echocardiographic evaluation. However,

their application in the RV is technically demanding, due to the thin wall, and extensive post processing, which limits its clinical application.

Cardiac morphology is assessed using T1-weighted fast spin-echo sequences, tissue characterization using T2-weighted fast spin-echo and contrast-enhanced inversion-recovery gradient-echo sequences (the so-called late or delayed enhancement techniques). The velocity-encoded cine MRI (phase-contrast MRI) makes it possible to study flow patterns, and thus to accurately quantify valvular regurgitation or to calculate the presence and severity of cardiac shunts.

Multidetector Computed Tomography (MDCT)

MDCT is not a first-line technique for the assessment of RV function and volume, because it requires significant radiation exposure and the use of an iodinated contrast medium. RV function is usually evaluated as part of a whole cardiac examination or when there are concomitant thoracic or pulmonary disorders, such as pulmonary embolism (PE), suspected. MDCT is a valuable alternative to CMR in patients with a pacemaker, patients with CMR incompatible prosthetic material and claustrophobia. Improvements in temporal and spatial resolution and reduction in radiation dosage further improved this technique. The use of MDCT for the RV has mainly been validated for the detection of PE and for work up of pulmonary hypertension.

Structural evaluation of the RV by MDCT includes measurement of RV size and volumes, as well as RV free myocardial wall thickness (RV hypertrophy). Septal bowing into the LV indicates RV volume (diastolic bowing) or pressure overload (systolic bowing). The diameters of the systemic veins and pulmonary arteries are indirect measures of elevated preload and afterload, respectively. Normal values for RV structures measured by MDCT have been recently published.

Radionuclide Techniques

Radionuclide techniques have the advantage of relying on a count-based method that is independent of the geometry of the RV. Three methods are available: gated equilibrium radionuclide angiography, gated first-pass radionuclide angiography, and first-pass radionuclide angiography. For RV volume and function measurements, radionuclide techniques have been largely replaced by CMR and echocardiography. Nonetheless, radionuclide modalities still play a role in assessment of RV myocardial ischemia and in patients in whom CMR is contraindicated. Gated SPECT is able to provide RV volumetric and functional data, but validation studies are lacking. Radionuclide techniques are also of additional particular interest for assessing myocardial metabolism and perfusion, however for the RV its clinical value is limited.

Table 11.2 Advantages per imaging modality

	RV function	RV size	TV annulus	Clinical value
<i>Echocardiography</i>				
– 2DE	++	++	++	++
– Doppler	++	–	–	+
– Strain	++	–	–	+
– 3DE	++	++	++	++
– SMPI				
CMR	++	++	–	++
MDCT	+	+	–	+
Nuclear	+	+	–	–

Summary

Right ventricular function has prognostic value in multiple cardiovascular diseases. Therefore, accurate assessment of RV volume and function is of incremental importance. The complex geometric shape of the RV complicates its assessment.

Non-invasive imaging modalities such as echocardiography and CMR are available to assess the RV, each with their advantages and disadvantages (Table 11.2).

New techniques like speckle tracking are promising, but need to be validated. 3D echocardiography overcomes the disadvantages of 2D echocardiography, however the feasibility of 3D echocardiography in the assessment of RV volumes and function is low.

CMR is the golden standard to assess the RV, with high accuracy and reliability, also making it ideal for serial examinations. CMR can be used for both anatomical and functional assessment. However functional assessment is technically demanding and time consuming.

MDCT and radionuclide techniques are not a first-line modality. But MDCT may be a valuable alternative for CMR in patients with contra-indications, and radionuclide assessment can be used to evaluate the myocardial metabolism and perfusion.

References

1. Polak JF, Holman BL, Wynne J, Colucci WS. Right ventricular ejection fraction: an indicator of increased mortality in patients with congestive heart failure associated with coronary artery disease. *J Am Coll Cardiol.* 1983;2(2):217–24.
2. Di Salvo TG, Mathier M, Semigran MJ, Dec GW. Preserved right ventricular ejection fraction predicts exercise capacity and survival in advanced heart failure. *J Am Coll Cardiol.* 1995;25(5):1143–53.
3. Gavazzi A, Berzuini C, Campana C, Inserra C, Ponzetta M, Sebastiani R, et al. Value of right ventricular ejection fraction in predicting short-term prognosis of patients with severe chronic heart failure. *J Heart Lung Transplant.* 1997;16(7):774–85.
4. de Groote P, Millaire A, Foucher-Hossein C, Nague O, Marchandise X, Ducloux G, et al. Right ventricular ejection fraction is an independent predictor of survival in patients with moderate heart failure. *J Am Coll Cardiol.* 1998;32(4):948–54.

5. Karatasakis GT, Karagounis LA, Kalyvas PA, Manginas A, Athanassopoulos GD, Aggelakas SA, et al. Prognostic significance of echocardiographically estimated right ventricular shortening in advanced heart failure. *Am J Cardiol.* 1998;82(3):329–34.
6. Park SJ, Park JH, Lee HS, Kim MS, Park YK, Park Y, et al. Impaired RV global longitudinal strain is associated with poor long-term clinical outcomes in patients with acute inferior STEMI. *JACC Cardiovasc Imaging.* 2015;8(2):161–9.
7. McLaughlin VV, Presberg KW, Doyle RL, Abman SH, McCrory DC, Fortin T, et al. Prognosis of pulmonary arterial hypertension: ACCP evidence-based clinical practice guidelines. *Chest.* 2004;126(1 Suppl):78S–92S.
8. Simonneau G, Gatzoulis MA, Adatia I, Celermajer D, Denton C, Ghofrani A, et al. Updated clinical classification of pulmonary hypertension. *J Am Coll Cardiol.* 2013;62(25 Suppl):D34–41.
9. Farber HW, Loscalzo J. Pulmonary arterial hypertension. *N Engl J Med.* 2004;351(16):1655–65.
10. Vonk-Noordegraaf A, Souza R. Cardiac magnetic resonance imaging: what can it add to our knowledge of the right ventricle in pulmonary arterial hypertension? *Am J Cardiol.* 2012;110(6 Suppl):25S–31S.
11. Sengupta PP, Tajik AJ, Chandrasekaran K, Khandheria BK. Twist mechanics of the left ventricle: principles and application. *JACC Cardiovasc Imaging.* 2008;1(3):366–76.
12. Lang RM, Badano LP, Mor-Avi V, Afilalo J, Armstrong A, Ernande L, et al. Recommendations for cardiac chamber quantification by echocardiography in adults: an update from the American Society of Echocardiography and the European Association of Cardiovascular Imaging. *Eur Heart J Cardiovasc Imaging.* 2015;16(3):233–70.

Part IV
Hemodynamic Perspective

Chapter 12

Echocardiographic Assessment of Pulmonary Artery Pressure, Tips and Tricks

Anthonie L. Duijnhouwer and Arie P.J. van Dijk

Abstract Pulmonary hypertension (PHT) is often observed in the presence of left side heart disease and lung disease, it is rare in the presence of all other possible causes, like PHT associated with atrial septal defect. Regardless of the cause of PHT it is always a sign of poorer prognosis. Echocardiography can help making the diagnosis of PHT, keeping in mind that only invasive pressure measurements can confirm the diagnosis of pulmonary hypertension (PHT). Echocardiography plays an important role in the screening and can simultaneously determine the possible cardiac cause of the PHT.

Tricuspid regurgitation velocity is the most used method to assess the systolic right ventricular pressure. This is only possible in absence of an outflow obstruction of the right ventricle (like pulmonary valve stenosis or infundibular obstruction). Other features of PHT should be evaluated like right ventricle deformation (dilatation, loss of banana shape) and function, the later being important for the prognosis. Doppler interrogation of pulmonary regurgitation can give an estimation of the existing mean and diastolic pulmonary artery pressures. Patterns of the pulsed wave Doppler of the right ventricular outflow can also be used to estimate the existing pulmonary artery pressures.

Keywords Pulmonary hypertension • Right ventricular pressure estimation
• Pulmonary pressure estimation

Abbreviations

PHT	Pulmonary hypertension
PAH	Pulmonary arterial hypertension
RV	Right ventricle
RA	Right atrium

A.L. Duijnhouwer, M.D. (✉) • A.P.J. van Dijk, M.D., Ph.D.
Department of Cardiology, Radboud University Medical Center, Nijmegen, The Netherlands
e-mail: Toon.Duijnhouwer@radboudumc.nl

IVC	Inferior vena cava
RVOT	Right ventricle outflow tract
PA	Pulmonary artery

Introduction

Echocardiography plays an important role in the screening for PHT, because estimation of the blood pressure in the pulmonary artery is possible in a variety of ways.

Echocardiography is non-invasive, easy applicable and almost everywhere accessible. Several Causes of pulmonary hypertension can be differentiated using echocardiography, especially in left sided heart diseases and congenital heart defects. The presence of an increased pressure load in PHT causes remodeling of the right ventricle, which can easily be assessed by looking for changes in anatomy and function. Right ventricular function has an important role in determining prognosis in all patients with some form of PHT [1]. To understand the lung circulation, not only pulmonary artery pressure, left atrial pressure and the right ventricle function need to be known, but pulmonary blood flow is important as well. Both pressures and flow can be estimated by echocardiography.

To understand the pulmonary circulation the analogy with Ohm's law for electrical circuits can be used.

$$\text{Ohm's Law: } V = I \times R$$

(V = voltage difference between two points, I = current, R = resistance)

Ohm's law can be rewritten for a hemodynamic circuit, i.e. the pulmonary circulation as:

$$(MPAP - LAP) = Q_p \times PVR$$

(Q_p = pulmonary blood flow (L/min), MPAP = mean pulmonary arterial pressure (mmHg), LAP = left atrial pressure (mmHg), PVR = pulmonary vascular resistance (Wu))

Case

Mrs. K, a 65 years old woman complains of chest pain and dyspnea during moderate physical effort as walking stairs. She had hypothyroidism for which she uses substitution therapy. At the emergency department of a regional hospital she had elevated cardiac troponin, but on coronary angiography no significant stenosis were present.

For further evaluation of the dyspnea, she was referred to the outpatient pulmonary hypertension clinic.

All images shown in this chapter were obtained from Mrs. K's echocardiography.

The Anatomy of the Right Ventricle and the Effects of Elevated Pulmonary Arterial Pressures

Due to the limitations of two-dimensional echocardiography, the anatomy of the right ventricle is difficult to analyze. Ideally, three-dimensional echocardiography could resolve this problem, but in practice the retrosternal location of the right ventricle in the thorax makes it difficult to image the entire right ventricle. Especially imaging of the anterior right ventricular wall is troublesome [2]. To get a full picture using two-dimensional echocardiography, it is necessary to assess the right ventricle from multiple directions and views.

The right ventricle is a low-pressure volume pump and therefore has only thin myocardial wall and is wrapped around the thick walled spherical left ventricle. As shown in Fig. 12.1, the right ventricle has a more banana-shaped configuration.

In PHT, as a consequence of increased afterload, right ventricular hypertrophy develops in order to keep wall stress as low as possible and to increase contractility. To maintain stroke volume the right ventricle dilates, which also includes dilation of the tricuspid annulus. Eventually, with chronically increased afterload, right ventricular systolic and diastolic failure ensues leading to more dilation and tricuspid regurgitation.

To evaluate the anatomy of the right ventricle and pulmonary valve a minimal number of images should be made.

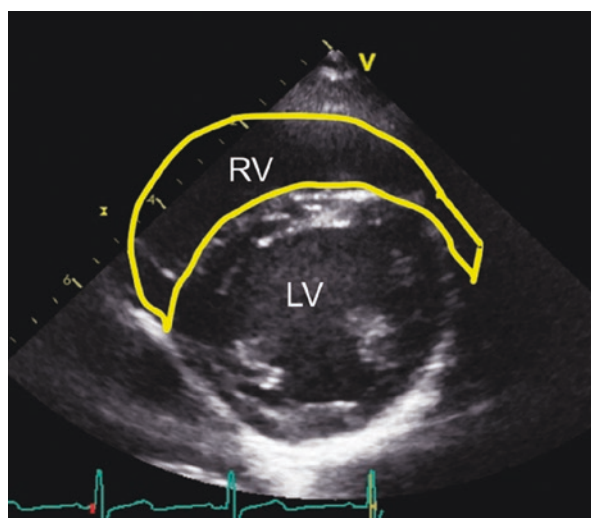


Fig. 12.1 Parasternal short axis view at the height of the papillary muscle

Parasternal Long Axis View of the Left Ventricle

One should keep in mind that the right ventricle consists of 3 parts, the inflow, the outflow and the trabecular part, that all parts should be visualized. The *outflow part* is best seen in the parasternal long axis view. In this view the abnormal position of the interventricular septum can be seen. The left ventricle, aortic valve and mitral valve can be evaluated (Fig. 12.2a).

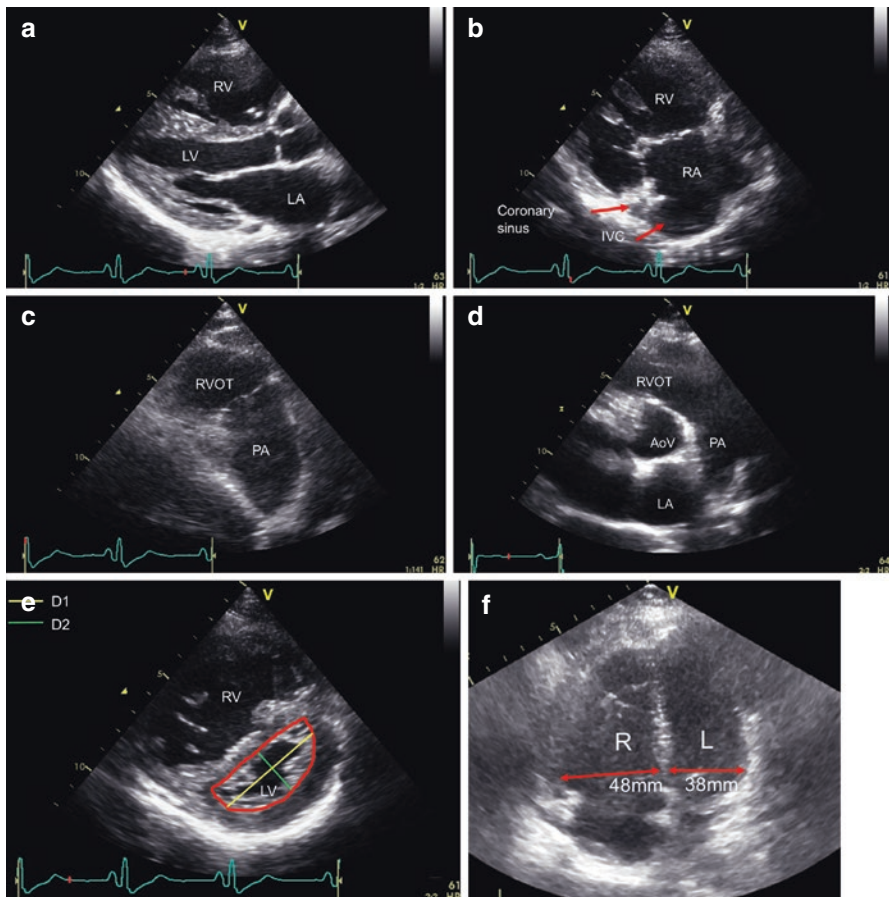


Fig. 12.2 (a) Parasternal long axis view. (b) Parasternal long axis view of the right ventricle. (c) Parasternal long axis view of pulmonary artery and right ventricle outflow tract. (d) Parasternal short axis view at the level of the aortic valve. (e) Parasternal short axis view at the level of the papillary muscles. (f) Apical 4-chamber view

Parasternal Long Axis of the Right Ventricle

This view can be obtained by tilting the probe to scan more anteriorly. The right ventricle *inflow part* can be visualized. This is the only view in which the right anterior (free) wall can be visualized completely, in order to assess the hypertrophic right anterior free wall and its systolic function. (Fig. 12.2b). The diaphragmatic, inferior right ventricular wall can also be seen.

Parasternal Long and Short Axis Views of the Pulmonary Valve and Main Pulmonary Artery

In order to evaluate the pulmonary valve the two most used views are the parasternal long axis view and short axis view. The long-axis view (Fig. 12.2c) is obtained by tilting the probe more cranial. In the parasternal short axis view (Fig. 12.2d), the infundibular portion or *outflow portion* of the right ventricle can be evaluated to assess whether a right ventricular outflow obstruction or pulmonary valve stenosis is present. Quantification of the severity of the obstruction can be done using continuous wave Doppler.

Parasternal Short Axis at the Level of the Papillary Muscles

The parasternal short axis at the level of the papillary muscles evaluates the mid segments of the left and right ventricle (Fig. 12.2e).

Progression of right ventricle pressure causes thickening of the wall and dilation of the lumen.

The pressure loaded right ventricle loses its crescent, banana-shape, configuration and becomes more spherical and dilated. The wall is thickened. The interventricular septum shows systolic flattening, which causes the left ventricle to get a typical D-shape in this view. This septal flattening can be quantified by the eccentricity index, which is the ratio of the left ventricular diameter perpendicular to the septum and the orthogonal diameter of the left ventricle at the same level. This index changes from 1 (normal) to >1 in elevated right ventricular systolic pressures. An index >1.0 is therefore one of the secondary echocardiographic signs of pulmonary hypertension. An index >1.7 denotes a poor prognosis.

Diastolic interventricular septal flattening can be seen in severe tricuspid valve regurgitation as a sign of volume overload.

$$\text{Eccentricity index} = D1/D2$$

Apical 4 Chamber View

The inflow of the right and left ventricle can be evaluated in the 4-chamber view, which further allows the comparison of the right and left ventricular dimensions. The ratio of the basal right to left ventricular diameters. >1.0 is a secondary sign of PHT (Fig. 12.2f). For a realistic measurement of these diameters one should avoid foreshortened images by placing the ultrasound probe on the apex of the heart. In some cases this can be challenging and difficult to accomplish.

Right atrial dilation is often present in the presence of PHT. In the apical 4-chamber view the maximal right atrial area (mid-systole) can be measured. A right atrial area $>18 \text{ cm}^2$ is indicative of right atrial dilatation and $>27 \text{ cm}^2$ indicates a poorer prognosis.

Beware of foreshortening with the consequence of measuring a larger right to left ventricular diameter ratio, due to oblique imaging of the right ventricle.

Tricuspid Valve Anatomy and Effect of High Pulmonary Artery Pressures and Right Ventricle Dilatation

The tricuspid valve is an anatomical structure belonging to the right ventricle. It consists of 3 valve leaflets which are kept in place by chordae, which on their part are mostly attached to the anterior papillary muscle. Chordae are also attached directly to the septum and to many smaller medial and inferior papillary muscles. The normal tricuspid valve annulus is an oval structure, with its largest diameter in the anterior to posterior direction. The tricuspid valve does not lie in one plane: the septal part is more cranially displaced in the perimembraneous region and the postero-septal region near the opening of the coronary sinus is lying more apically. During the cardiac cycle the annular area changes with a maximum area change during mid-diastole with the largest change in the septal to lateral axis. In diastole the annular plane is round and flat, while in systole the annulus becomes more oval and the curvature increases [3].

In the setting of right ventricular remodeling by pressure overload in PHT the morphology of the tricuspid valve changes. Dilation of the annulus is dominantly in the septal to lateral axis making the annular area larger, more round, and more planar during systole. As a consequence, a loss of leaflet coaptation area occurs. Additionally, right ventricle dilatation leads to a change in the geometry of the sub-valvular apparatus causing tenting of the valve leaflets. In Fig. 12.3a, b schematic drawing shows these changes.

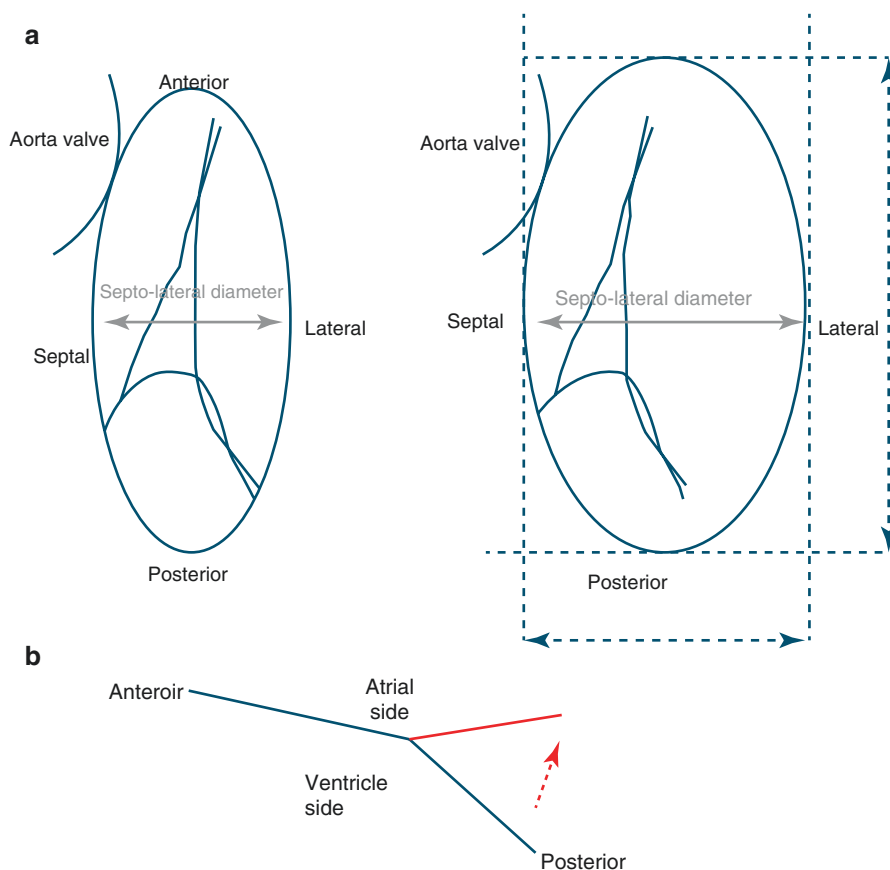


Fig. 12.3 (a) Change in tricuspid annulus geometry due to pressure overload of the right ventricle, the cranial view from atrium to right ventricle. (b) Change in tricuspid annulus geometry in the lateral view, due to pressure overload of the right ventricle

Pulmonary Pressure Estimation

As stated before it is important to realize that pulmonary artery pressure is dependent on left atrial pressure, pulmonary vascular resistance and pulmonary blood flow (cardiac output created by the right ventricular pump). During echocardiography, focus should lie on these parameters in order to understand and report the state of the pulmonary circulation completely.

In case of right ventricular outflow tract obstruction or pulmonary valve stenosis the estimated

A common mistake is to overlook the fact that pulmonary artery pressure is not equal to systolic right ventricular pressure in the presence of right ventricle outflow obstruction (on whatever level).

systolic right ventricular pressure is not equal to the systolic pulmonary artery pressure.

Pulmonary Artery Pressure Estimation Using Tricuspid Valve Regurgitation

Almost every tricuspid valve has some regurgitation, although sometimes hard to capture with Doppler interrogation. The regurgitation jet velocity can be used to estimate the systolic pressure differences between the right ventricle and the right atrium by using the simplified Bernoulli law equation (Fig. 12.4):

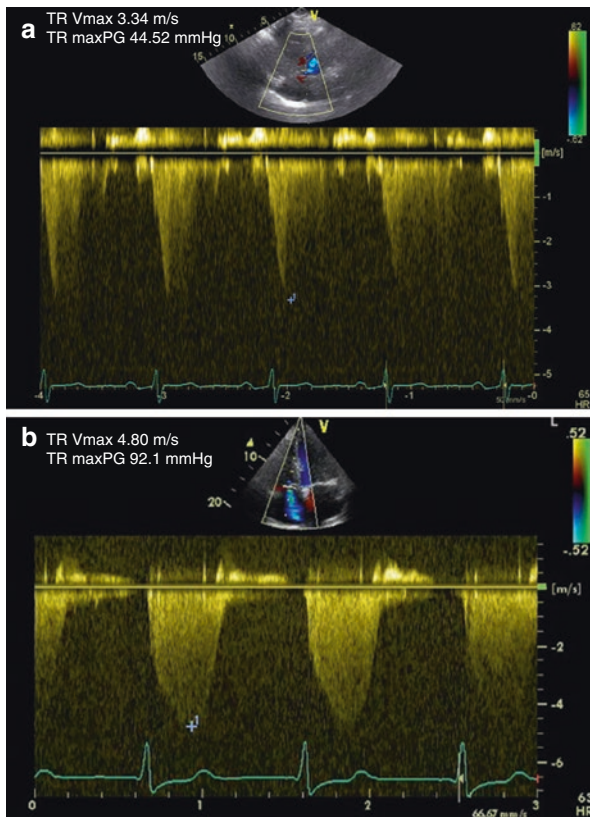


Fig. 12.4 (a) Continuous wave Doppler regurgitation velocity of the tricuspid valve. (b) Continuous wave Doppler regurgitation of the tricuspid valve of another pulmonary hypertension patient

Table 12.1 Right atrial pressure estimation

Right atrial pressure	3 mmHg (0–5 mmHg)	8 mmHg (5–10 mmHg)	> 15 mmHg
IVC diameter	≤ 21 mm	≤ 21 mm	> 21 mm
IVC collapse after sniff	> 50%	< 50%	> 50%

$$\Delta P = 4 V^2$$

In case of tricuspid regurgitation:

$$\Delta P = 4 TR-V_{max}^2$$

$$RV \text{ systolic pressure} - RA \text{ pressure} = 4 TR-V_{max}^2$$

$$RV \text{ systolic pressure} = 4 TR-V_{max}^2 + RA \text{ pressure}$$

RV systolic pressure = systolic PA pressure IF no right ventricular outflow tract obstruction.

ΔP = pressure differences; V = maximal velocity assessed with continuous wave Doppler. PA = pulmonary artery, RV = right ventricle, TR-V_{max} = maximal tricuspid regurgitation velocity.

To estimate right atrial pressure (see Table 12.1), the diameter of the inferior vena cava is measured either by 2D-mode or by M-mode and the variation induced by spontaneous breathing or sniff testing. This measurement should be taken just proximal of the right hepatic vein (Fig. 12.5).

So, for our patient it means that the estimated systolic pulmonary arterial pressure is 50 mmHg (pressure gradient across tricuspid valve 45 mmHg + right atrial pressure 5 mmHg), as no right ventricular outflow tract obstruction exists (Fig. 12.2c).

A common mistake is to presume that high right ventricular pressures are accompanied by severe tricuspid valve regurgitation. But severity of tricuspid regurgitation tells us little about the existing pressure difference between right atrium and the right ventricle.

According to current guidelines (ESC guidelines 2015) the probability of the presence of pulmonary hypertension is primarily based on the maximal velocity of the tricuspid valve regurgitation jet, although other characteristics are taken into account [4]. The height of right atrial pressure is not included in the ESC guideline for pulmonary artery pressure estimation, but it is important to reckon with it. In the presence of a reduced right ventricle function or more severe tricuspid valve regurgitation right atrial pressure will be elevated, which leads to underestimation of pulmonary pressures. The guideline-based probability determination of the presence of PHT is only valid in the absence of elevated right atrial pressures (as high right atrial pressure will reduce the pressure gradient across the tricuspid valve).

Care has to be taken to measure the proper maximal velocity. Not only Doppler angle should be kept as low as possible, blurred or faint Doppler signal should be

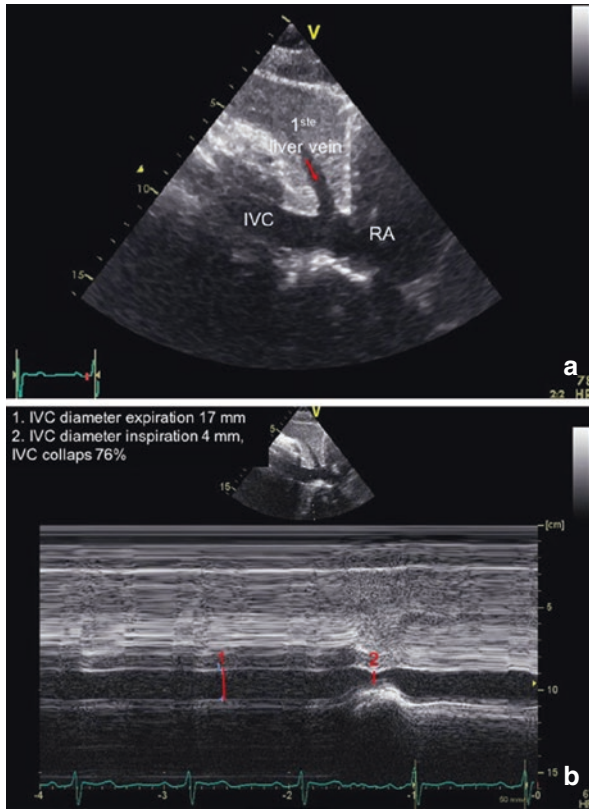


Fig. 12.5 (a) 2D subcostal view of the inferior vena cava. (b) M-mode during sniff-testing of the inferior vena cava

optimized in order to prevent over- or underestimation of velocity. Incomplete signals should not be used at all. Discrepancies in right atrial pressure estimation might lead to inaccurate pressure estimation too [5] (Fig. 12.6).

Be careful with the use of the maximal tricuspid valve regurgitation jet velocity method for the estimation of systolic pulmonary arterial pressure in the presence of severe tricuspid regurgitation, in which the pressure in the right atrium is elevated, antegrade flow through the pulmonary artery might be diminished and the simplified Bernoulli equation does not work.

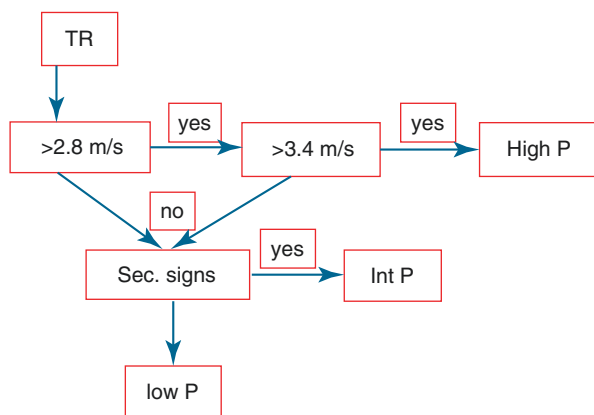


Fig. 12.6 Flow diagram of probability of pulmonary hypertension based on tricuspid valve regurgitation. *TR* tricuspid valve regurgitation, *high P* high probability of pulmonary hypertension, *int P* intermediate probability of pulmonary hypertension, *low P* low probability of pulmonary hypertension, *sec. signs* secondary signs of pulmonary hypertension

Pulmonary Artery Pressure Estimation Using Pulmonary Valve Regurgitation

The pulsed wave or continuous wave Doppler of the pulmonary valve regurgitation jet entails a lot of information about the gradient between pulmonary artery and right ventricle. In the same way as explained in paragraph 1.4.1 the Bernoulli equation can be used to calculate pressure difference between the pulmonary artery and the right ventricle in diastole. The calculated pressure gradient by using peak regurgitation velocity, occurring directly after closure of the pulmonary valve added to estimated right atrial pressure, nicely corresponds with the mean pulmonary artery pressure. In the ESC guidelines an early diastolic pulmonary regurgitation velocity > 2.2 m/s is seen as evidence for the presence of pulmonary hypertension. Care has to be taken to measure only the maximal regurgitation velocity just after pulmonary valve closure. In many patients the early pulmonary regurgitation velocity, i.e. the pressure difference between pulmonary artery and right ventricle is influenced by the early passive filling of the right ventricle through the tricuspid valve leading to loss or diminishing of the velocity signal. In the example case (Fig. 12.7a) the maximal regurgitation jet is difficult to establish, but was measured at 3.3 m/s corresponding to an estimated mean pulmonary artery pressure of 50 mmHg in case of adding a 5 mmHg right atrial pressure.

The end diastolic velocity of the pulmonary regurgitation, measured at the beginning of the QRS-complex of the ECG, corresponds well with the end-diastolic

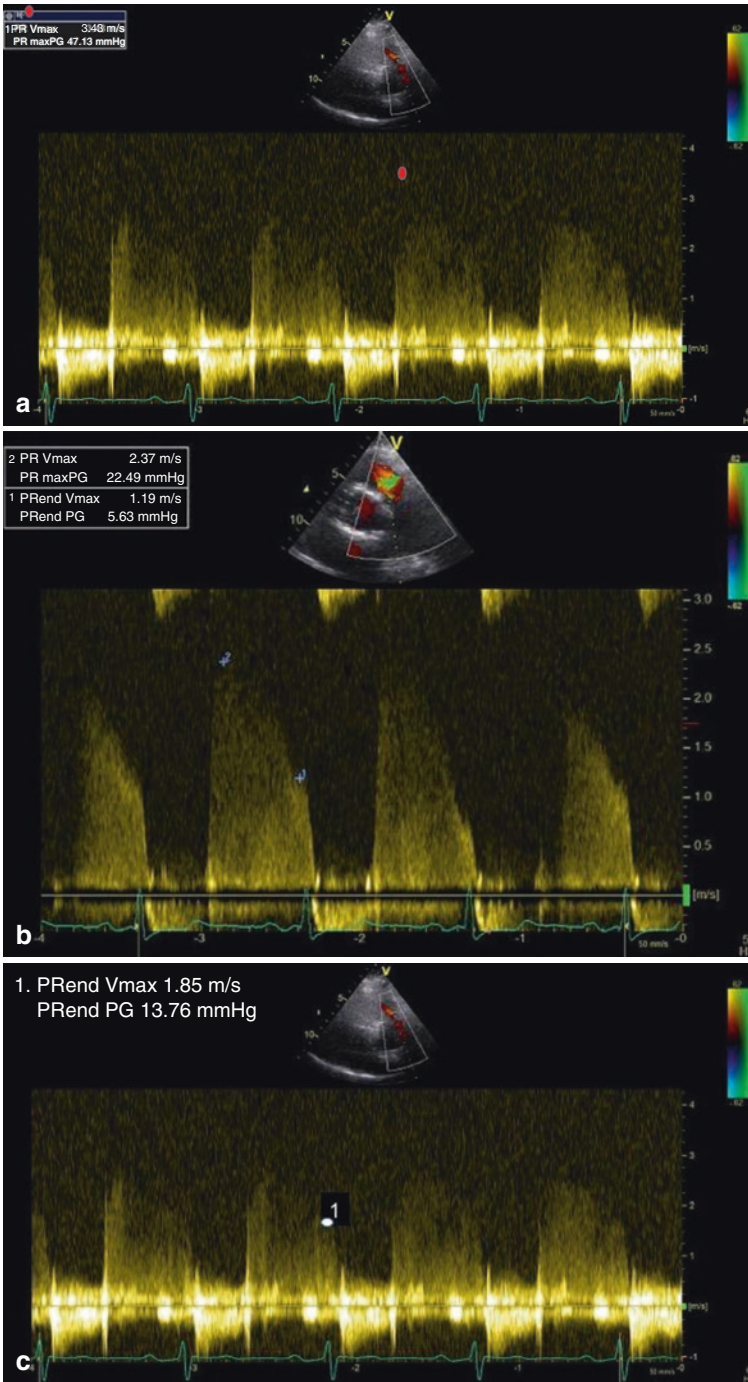


Fig. 12.7 (a) Continuous wave Doppler of the pulmonary valve regurgitation. (b) Shows another example of maximal regurgitation velocity and end diastolic regurgitation velocity. (c) End-diastolic velocity of pulmonary regurgitation

pulmonary arterial pressure. Right atrial pressure should be added to the calculated end-diastolic pulmonary to right ventricular pressure difference. (Fig. 12.7c).

The pulmonary regurgitation Doppler velocity is a good alternative for the tricuspid valve regurgitation Doppler velocity to estimate elevated pulmonary artery pressures.

Pulmonary Artery Pressure Estimation Using the Right Ventricle Outflow Pulsed Wave Doppler Velocity

According to ESC guideline, the acceleration time of the right ventricular outflow tract velocity as measured by pulsed wave Doppler <105 ms is a sign of PHT. The shape of the velocity curve is probably even more informative [6]. With advancing PHT the normally symmetrical parabolic shape of the curve becomes more triangular with shorter acceleration time and shorter ejection time as well. The ratio of acceleration to ejection time becomes lower meaning that acceleration time shortens more than ejection time. Eventually, by the influence of early returning reflected pressure waves in the case of elevated pulmonary vascular resistance, a notch will appear in the velocity curve. The presence of a notch is highly sensitive and predictive for the presence of elevated pulmonary vascular resistance.

Technically it can be difficult to obtain reliable Doppler signals. Placing the sample volume in the middle of the right ventricular outflow tract with a small Doppler angle can be a challenge or even impossible. Other factors as right ventricular dysfunction, the presence of tricuspid regurgitation and right bundle branch block influence the shape of the curve (Figs. 12.8 and 12.9).

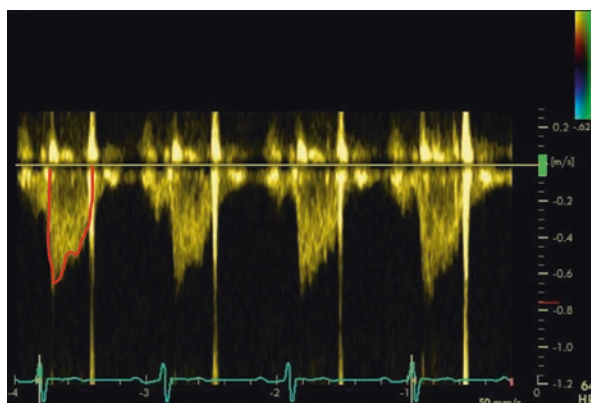


Fig. 12.8 Pulsed wave Doppler with sample in right ventricle outflow tract

According to López-Candales et al. pattern 1 can be seen in patients with a systolic pulmonary pressure up to 48 mmHg, pattern 2 in patients with a systolic pulmonary artery pressure between 48 and 68 mmHg, pattern 3 in patients with a systolic pulmonary artery pressure between 69 and 94 mmHg and pattern 4 in patients with a systolic pulmonary artery pressure above 95 mmHg [6].

Pulmonary Artery Diameter

Pulmonary artery dilatation can occur in many circumstances. The most common cause is high pulmonary pressures [7]. Measuring main pulmonary arterial diameter using echocardiography is, in our experience, inaccurate. The visibility of the pulmonary arterial wall is hindered by the fact the vessel wall runs parallel to the

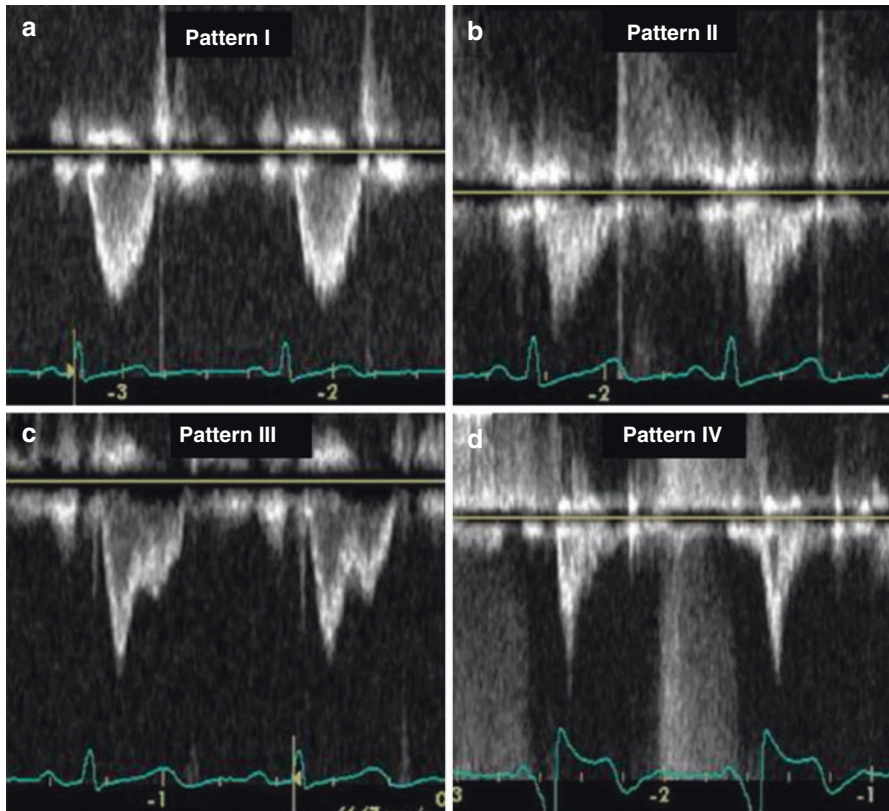


Fig. 12.9 Pulsed wave Doppler pattern of the right ventricle outflow

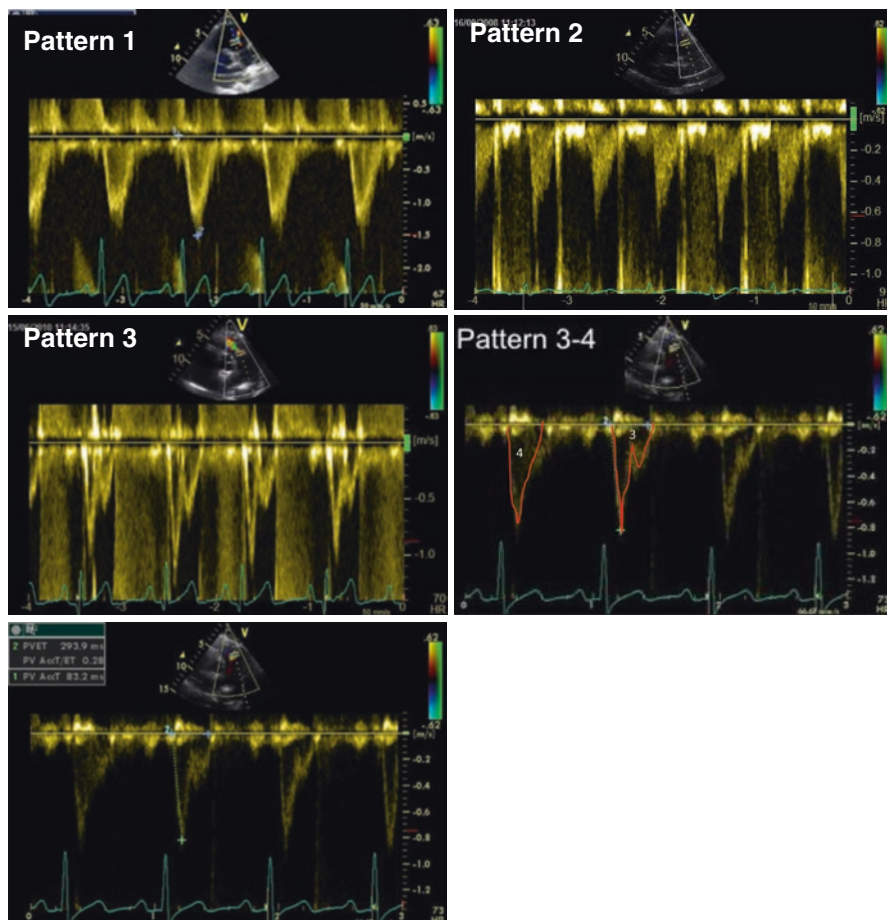


Fig. 12.9 (continued)

ultrasound beam. If well visualized a pulmonary arterial diameter > 25 mm is a secondary sign of PHT. The evidence for this recommendation is low and other conditions might lead to pulmonary arterial dilatation too, for example idiopathic pulmonary arterial dilatation or severe pulmonary regurgitation.

Key Points

1. Echocardiography can be used to screen for PHT. The diagnosis of PHT should be confirmed by invasive hemodynamic measurements.
2. Tricuspid valve regurgitation jet velocity is the best predictor of right ventricular pressure in the absence of right ventricular outflow obstruction and severe regurgitation.

3. Pulmonary valve regurgitation can be used to estimate mean and diastolic pulmonary artery pressure and is a good alternative of tricuspid valve regurgitation Doppler velocity method
4. Right atrial pressure estimation should be added to the Doppler derived regurgitation jet velocity. Derived pressure difference between right ventricle and right atrium or between right ventricle and pulmonary artery, are more reliable when incorporating right atrial pressure, especially in circumstances in which an elevated right atrial pressure is excised, like right ventricular failure or severe regurgitation.
5. Right ventricular outflow Doppler pulsed wave velocity signal can be used to evaluate the pulmonary artery pressure.

Questions

1. What is the effect of elevated high right ventricular pressure on the right ventricular shape?
2. What is the effect of elevated high right ventricular pressure on the annulus of tricuspid valve?
3. What condition(s) should be met to use the velocity of the tricuspid valve regurgitation to estimate systolic pulmonary artery pressure?
4. What could be the reason(s) to use right atrium pressure estimation in estimation pulmonary artery pressure?
5. Does the severity of tricuspid valve regurgitation tell us something about the height of the right ventricular pressure?
6. What does the maximal pulmonary valve regurgitation velocity tell us?
7. What does the end-diastolic pulmonary valve regurgitation velocity tell us?
8. What other parameters determine pulmonary artery pressure?

Review Questions

68. What is the effect of elevated high right ventricular pressure on the right ventricular shape?
 - (a) RV hypertrophy
 - (b) RV dilatation
 - (c) RV hypertrophy and later on dilatation
69. What is the effect of elevated high right ventricular pressure on the annulus of tricuspid valve?
 - (a) Dilatation of the anterior part only
 - (b) Dilatation of the septoanterior portion
 - (c) Dilatation of the anteroposterior portion
 - (d) Dilatation of the posterior part only

70. What condition(s) should be met to use the velocity of the tricuspid valve regurgitation to estimate systolic pulmonary artery pressure?
- (a) Effect of respiration
 - (b) Doppler alignment
 - (c) Effect of loading conditions
 - (d) All of the above

References

1. Ghio S, Gavazzi A, Campana C, Inserra C, Klersy C, Sebastiani R, et al. Independent and additive prognostic value of right ventricular systolic function and pulmonary artery pressure in patients with chronic heart failure. *J Am Coll Cardiol*. 2001;37(1):183–8.
2. Lang RM, Badano LP, Tsang W, Adams DH, Agricola E, Buck T, et al. EAE/ASE recommendations for image acquisition and display using three-dimensional echocardiography. *Eur Heart J Cardiovasc Imaging*. 2012;13(1):1–46.
3. Ring L, Rana BS, Kydd A, Boyd J, Parker K, Rusk RA. Dynamics of the tricuspid valve annulus in normal and dilated right hearts: A three-dimensional transoesophageal echocardiography study. *Eur Heart J Cardiovasc Imaging*. 2012;13(9):756–62.
4. Galie N, Humbert M, Vachiery JL, Gibbs S, Lang I, Torbicki A, et al. 2015 ESC/ERS guidelines for the diagnosis and treatment of pulmonary hypertension. *Eur Heart J*. 2016;37(1):67–119.
5. Amsallem M, Sternbach JM, Adigopula S, Kobayashi Y, Vu TA, Zamanian R, et al. Addressing the controversy of estimating pulmonary arterial pressure by echocardiography. *J Am Soc Echocardiogr*. 2016;29(2):93–102.
6. López-Candales A, Edelman K. Shape of the right ventricular outflow Doppler envelope and severity of pulmonary hypertension. *Eur Heart J Cardiovasc Imaging*. 2012;13(4):309–16.
7. Duijnhouwer AL, Navarese EP, APJ VD, Loeys B, Roos-hesselink JW, De Boer MJ. Aneurysm of the pulmonary artery, a systematic review and critical analysis of current literature. *Congenit Heart Dis*. 2016;11(2):102–9.

Chapter 13

Right Heart Catheterization for Hemodynamic Evaluation of Right Sided Heart Disease

Tim ten Cate, Tamara Aipassa, and Roland van Kimmenade

Abstract This chapter will describe the basics of right heart catheterization (RHC), and will address how to interpret the hemodynamic information that is obtained. RHC is the only way to adequately calculate the complete hemodynamic status of a patient. Especially in patients with complicated congenital cardiac anatomy or post-operative anatomy after congenital heart disease repair. It also allows for analysis of valvular function and the pulmonary vascular function. All non-invasive imaging modalities, e.g. echocardiography, MRI, CT and Nuclear, only provide part or indirect measurements of the hemodynamics.

By means of case based learning we will present tips and tricks how to properly carry out a RHC. The value of these hemodynamic calculations will be discussed.

Keywords Right heart catheterization • Pulmonary hypertension • Cardiac output

Introduction

Before the introduction and development of doppler echocardiography a right heart catheterization (RHC) was the only means to properly discern the hemodynamics of the cardiac and pulmonary circulation. The use has fallen, because with doppler echocardiography many hemodynamic questions can be answered in a non invasive manner [1]. With the decline in RHC performed in cath-labs worldwide, the knowledge of a properly carried out RHC declines likewise. However, the European Society of Cardiology (ESC) core curriculum updated in 2013 still finds that the skills to perform a proper RHC is a mandatory part of cardiology training [2].

T. ten Cate, M.D., Ph.D. (✉) • T. Aipassa, M.D. • R. van Kimmenade, M.D., Ph.D.
Department of Cardiology, Radboudumc, Nijmegen, The Netherlands
e-mail: Tim.tenCate@radboudumc.nl

With a complete RHC not only important information for diagnostic purposes, but also for prognostic purposes is obtained [3]. For precise measurement of the pulmonary arterial pressure and resistance, a RHC is the only means to quantitatively assess these parameters. But there is much more information that can be obtained. With a complete RHC appreciation of valvular function, vascular function and ventricular function is possible. Even for the diagnosis of diastolic dysfunction (heart failure with preserved ejection fraction) a RHC adds to non-invasive information as it can discern effects on the diastolic left ventricular pressures and left atrial pressures of exercise and fluid changes. However, the value of the findings is as reliable as the quality of the recordings and the completeness of the measurements.

The most important task of the operator is to get a precise measurement of the wave-forms, saturations and pressures in all compartments. Not only in all right sided compartments, but also in the aorta and if feasible and necessary in the left ventricle. Therefore it is of the utmost importance for the operator to have a proper understanding of the reason for the RHC and of the measurements necessary to answer the questions asked. Furthermore, it is important to understand the anatomy that one will encounter. Especially in cases of congenital heart disease, either corrected or native.

To understand the hemodynamics of patients with complex cardiac anatomy and those with complex hemodynamic pathology, a RHC still remains one of the cornerstones to adequately assess the hemodynamics and to advise the patient in his treatment.

Basics of the Right Heart Catheterization

For a complete RHC a special catheter (**Photo of Swan Ganz**) is inserted in the venous system and advanced through the heart towards the pulmonary artery. This pulmonary artery catheter, also known as Swan-Ganz catheter, usually consists of a balloon tipped catheter with two ports for pressure measurement and a thermistor for cardiac output measurement.

After the normal pre-requisites of a cardiac catheterization, venous access is obtained and a sheath is inserted. Any large vein is usable, but usually the jugular vein or the femoral vein is used for access. To measure the aortic pressure and left ventricular end diastolic pressure arterial access is also obtained and a sheath is introduced [4].

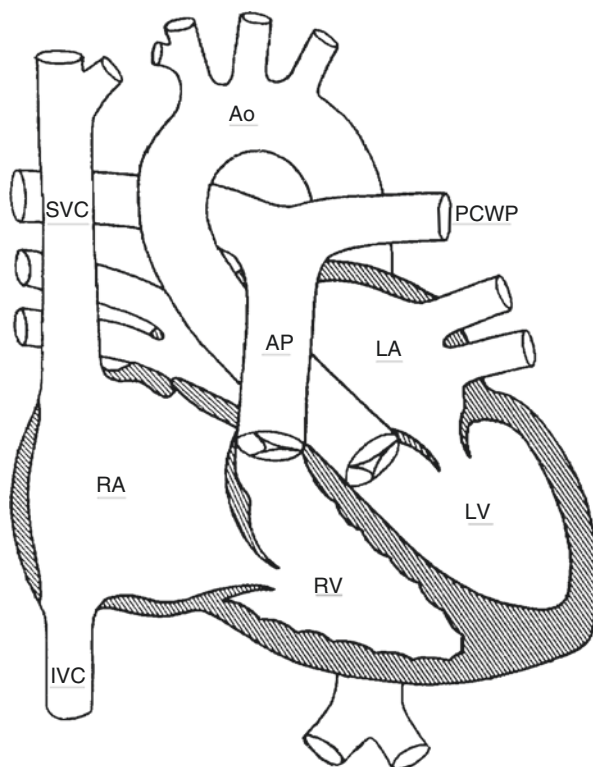
As any invasive procedure, RHC has its own complications. Naturally bleeding is an important complication. But as RHC is performed in a specific population the complications are also specific (Table 13.1) [5].

Blood samples for oxygen content, and pressure measurements are taken in all cardiac compartments (Fig. 13.1). Since the left atrium is not easily reached, as a representative of the left atrial pressure the pulmonary capillary wedge pressure (PCWP) is used. Figure 13.2 describes the principle of the PCWP measurement and how to measure it.

Table 13.1 Complications of right heart catheterization

Mortality	0.055% (pulmonary artery rupture, diffuse intrapulmonary haemorrhage)
Serious adverse events	1.1%
<i>Related to venous access site</i>	0.4%
<i>Related to right heart catheterization</i>	0.3%
– Supraventricular tachycardia	0.1
– Hypertensive crisis	0.03
– Haemoptysis	0.01
– New bundle branch block	0.01

Fig. 13.1 Cardiac compartments. *IVC* inferior vena cava, *SVC* superior vena cava, *RA* right atrium, *RV* right ventricle, *AP* pulmonary artery, *PCWP* pulmonary capillary wedge pressure, *Ao* aorta, *LA* left atrium, *LV* left ventricle



The order in which the various compartments are studied is left to the discretion of the operator. The only prerequisite is that every compartment is properly measured. The measurement of the pressures and registration of the wave-forms can best be obtained at end-expiration with open mouth.

Based on these measurements, calculation of various valvular, vascular function and cardiac output can be done using specific formula. Also, it allows for differentiation between various causes of pulmonary hypertension. Figure 13.3 explains the RA and PCWP wave forms. In Fig. 13.3b the typical wave forms of all right sided compartments are shown.

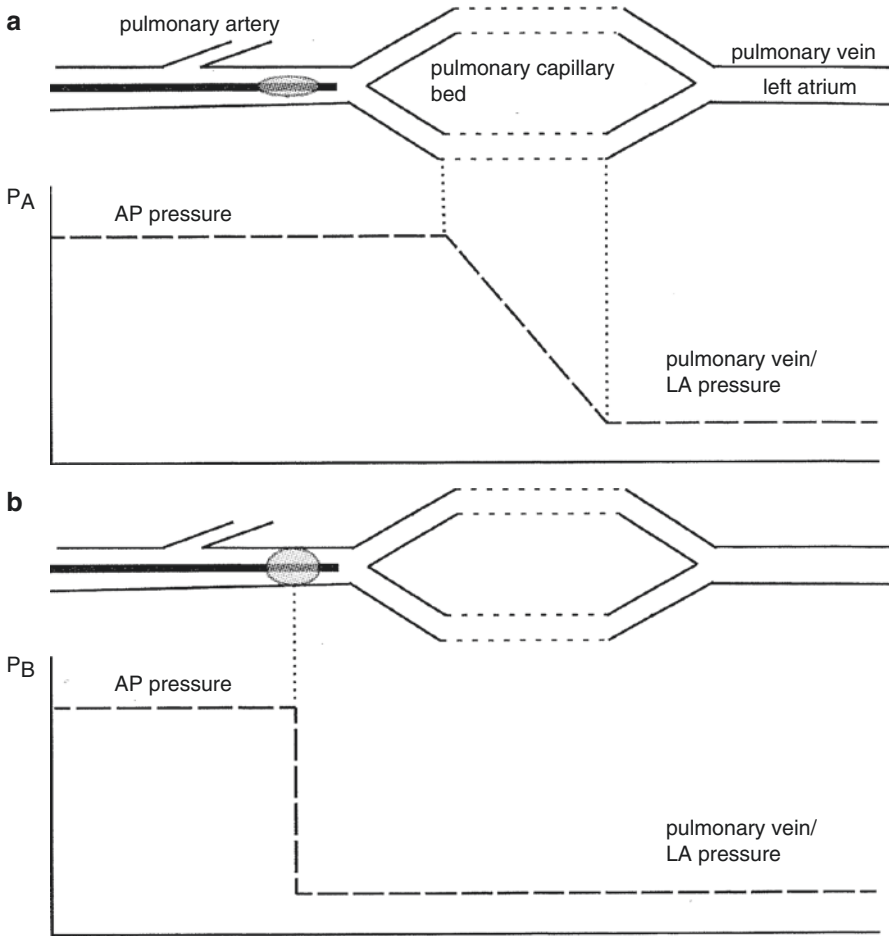


Fig. 13.2 Pulmonary capillary wedge pressure. Because the pulmonary veins that enter the left atrium form a continuous system with the pulmonary arteries through the pulmonary capillaries, the pressure that is registered when a distal artery is occluded by the balloon inflation at the tip of the Swan Ganz is the same as in the left atrium. **(a)** Represents the situation when the Swan-Ganz catheter is situated in a small pulmonary artery branch before balloon inflation. **(b)** Represents the situation with balloon inflation. Note that the pressure at the tip of the catheter behind the inflated balloon becomes the same as in the left atrium. *AP* pulmonary artery, *P_A* pulmonary arterial pressure, *P_B* pressure with balloon inflation. Adapted with permission from *Cardiale diagnostiek van pulmonale hypertensie, op zoek naar het cor pulmonale* (in Dutch), Vliegen editor, Fig. 4.4, p13, publisher TTMA BV, Oegstgeest, The Netherlands

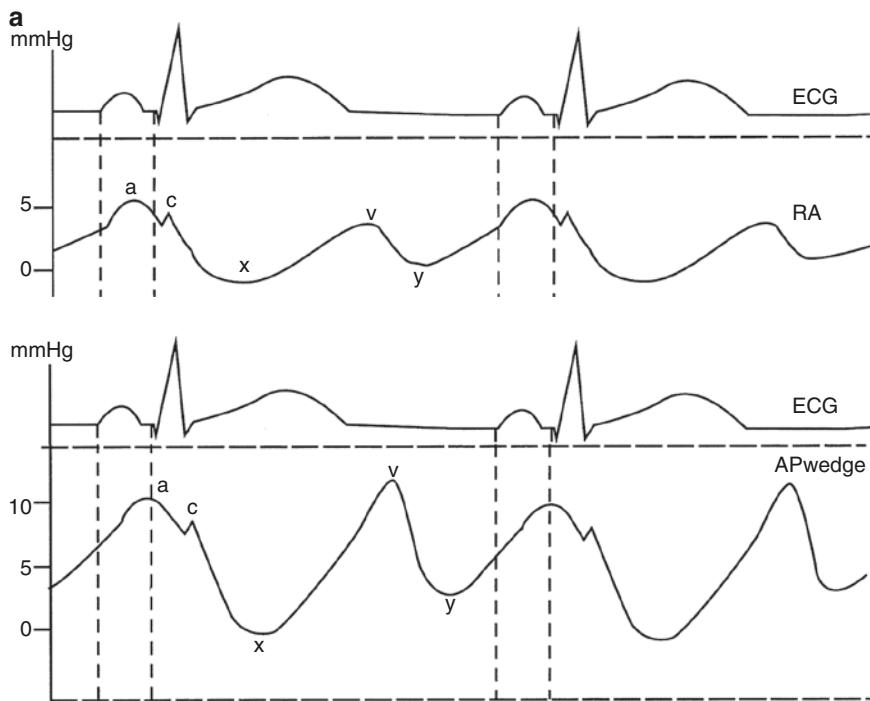


Fig. 13.3 (a) Specific pressure wave-forms of the RA and PCWP. Note that the atrial cycle is asynchronous with the ventricle, thus the atrial systole is the ventricular diastole and vice versa. A, C and V-are positive waves, X and Y are negative. And the ventricular systole is between C and Y. The a-wave is the atrial systole (the contraction of the atrium); the c-wave is formed by the rapid filling of the ventricle just before the AV-valve closes; The X descent is the atrial diastole (relaxation of the atrium); the V-wave is caused by filling of the atrium when the AV-valve is closed (the venous return towards the atrium). The height of the V-wave reflects the filling pressure of the ventricle. When the V-wave is high this may be a sign of heart failure. However, when the AV-valve is insufficient the regurgitation jet causes the filling of the atrium to increase and thus the V-wave to be more prominent. But when the AV-valve is insufficient the V-wave occurs early and is followed by a steep Y-descent. The Y-descent is the opening of the AV-valve and the rapid ventricular filling. As mentioned before the slope of the Y-descent points towards AV-valve insufficiency. But may also reflect pericardial constriction. Adapted with permission from *Cardiale diagnostiek van pulmonale hypertensie, op zoek naar het cor pulmonale* (in Dutch), Vliegen editor, Fig. 4.3, p12, publisher TTMA BV, Oegstgeest, The Netherlands. (b) Pressure wave forms in the various compartments of the right side of the heart. Every compartment has a characteristic pressure wave-form. The atrial (and AP-wedge) pressure wave forms have typical waves and descents that represent various parts of the cardiac cycle. ECG electrocardiogram, RA right atrium, AP pulmonary artery, AP-wedge pulmonary capillary wedge pressure, RV right ventricle

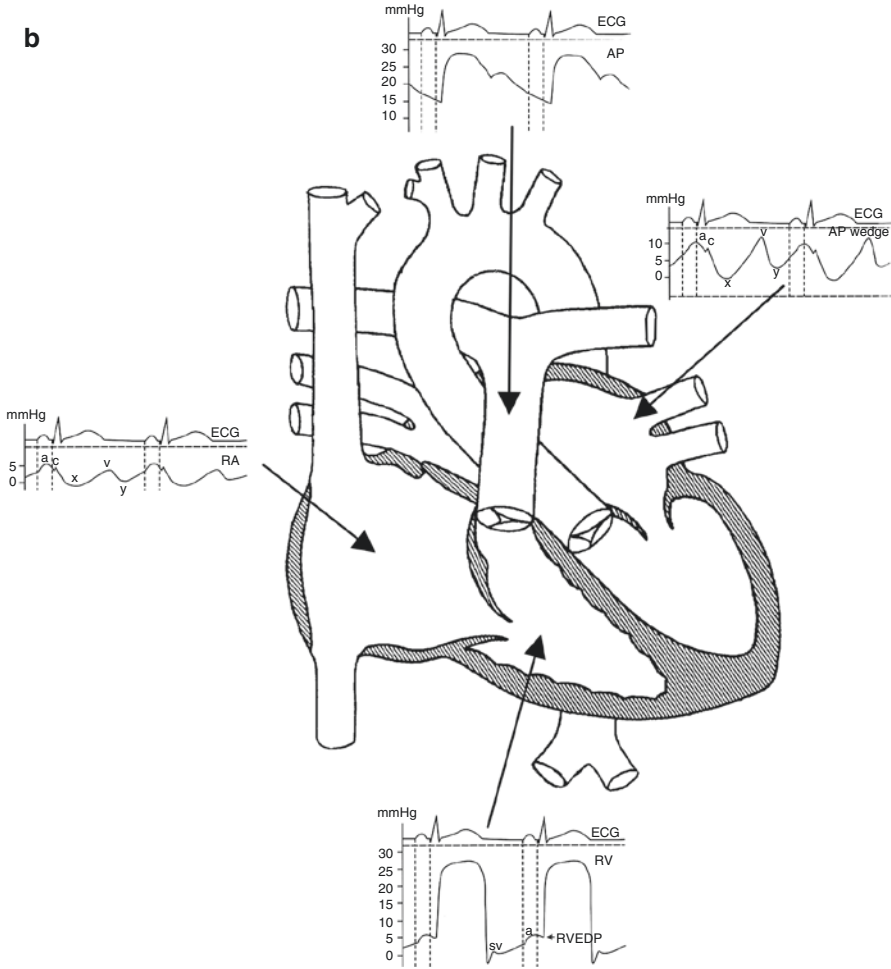


Fig. 13.3 (continued)

Tips and Tricks

Sometimes reaching the pulmonary artery can be a challenge. When there is tricuspid regurgitation the back-flow from the right ventricle into the right atrium may hamper advancing the catheter from the right atrium towards the right ventricle and the pulmonary artery.

There are several possible solutions. The first is to make a loop (Fig. 13.5c) in the right atrium and try to advance the catheter without inflated balloon tip. The backward pushing force is less with the deflated balloon and the loop in the right atrium increases the resistance of the catheter to overcome the backward pushing force of the regurgitant blood through the tricuspid valve.

If this is not sufficient one can insert a thin wire in the Swan Ganz catheter to stiffen the catheter and thus increase the pushability and steerability. When this is also not enough, then filling the balloon with saline in stead of air is the final easy resort. Usually any one of these tricks will help positioning the catheter at the site of interest.

When a tricuspid annuloplasty was performed any of the aforementioned tricks can be of help to finish the RHC successfully.

Hemodynamic Information from a RHC

As mentioned before, with a properly carried out RHC a multitude of hemodynamic information becomes available. As we will demonstrate this necessitates properly registered and measured wave-forms, saturations and pressures. Table 13.2 demonstrates the normal values of a RHC.

Calculation of Cardiac Output

For the calculation of Cardiac Output (CO) it is essential to obtain oxygen saturation measurements at various sites. Based on these values, CO can be calculated using Fick's equation. As well, this allows for the interpretation of possible intra-cardiac shunts. The basics of these calculations is that the circulation is a closed circuit.

The formula for this calculation is called after the inventor of the calculation, Adolf Eugen Fick (1829–1901). The value of this parameter is important for both prognosis and also in cases of hemodynamic instability where inotropic therapy is instigated, for assessment of the effects of therapy. To calculate the cardiac output first the amount of consumption of oxygen from the air is measured (or calculated).

Table 13.2 Normal pressure values

	Sat	Pressure (mean mm Hg)	Pressure (S/D mm Hg)
IVC	80	0–5	
SVC	70	0–5	
RA	75	0–5	
RV			30/4
PA	70–75	<24	30/15
PCWP		4–10	
Ao	95–98		
LVEDP	95–98	<12	

IVC inferior vena cava, *SVC* superior vena cava, *RA* right atrium, *RV* right ventricle, *PA* pulmonary artery, *PCWP* pulmonary capillary wedge pressure, *Ao* aorta, *LVEDP* left ventricular end diastolic pressure, *S/D* systolic/diastolic

When we then know the amount of oxygen that enters the lungs and the amount that exits the lungs, the amount of blood that has passed through to allow for this uptake can be calculated.

$$\text{Cardiac Output} = \frac{\text{O}_2 \text{ consumption}}{1.36 \times 1.6 \times \text{Hb} (\text{mmol} / \text{L}) \times [(\text{Sat Aorta}) - (\text{Sat mixed venous}) / 100]} \times 10$$

The best way to get the O₂ consumption is by means of real measurement. Since the O₂ consumption can vary a lot in time, it is best to measure this as close to the time of RHC as possible. This is especially true for patients with pulmonary pathology.

If measurement is not possible or not available. An educated guess can be obtained by calculating the O₂ consumption. For this calculation the following equation comes closest to the actual measured values [6].

O₂ consumption = (157.3 × BSA + 10 × constant (male = 1; female = 0) – 10.5 × ln (Age) + 4.8) mL/min [6]. This calculation is rather difficult to calculate.

Therefore, for rapid in cath-lab estimation of O₂ consumption while performing the RHC, the rule of thumb “O₂-consumption = 3.5mL × body weight (kg)” can be used.

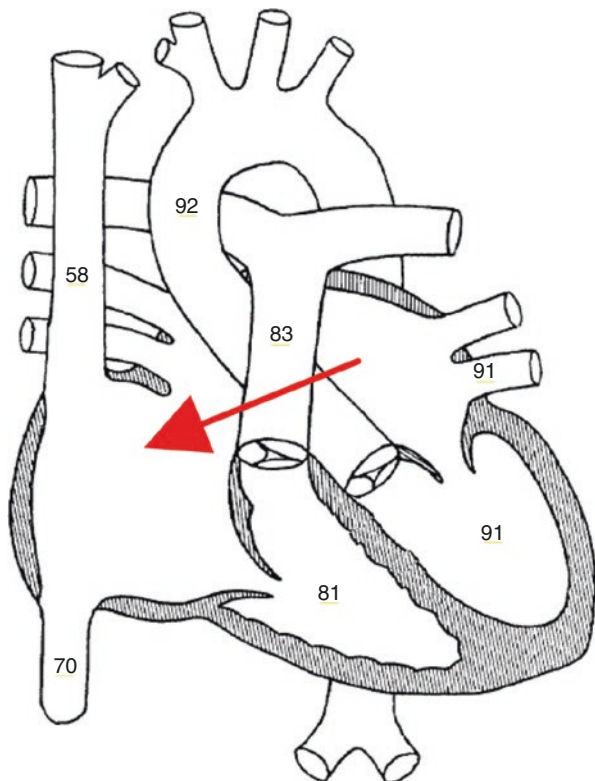
Assessment and Calculation of Intra-Cardiac Shunts

Based on the fact that the circulation is a closed circuit, the cardiac output of the right ventricle and the left ventricle should be the same. When a shunt is present, the flow in the right heart circulation and left heart circulation are not the same and therefore the shunt fraction can be calculated based on the ratio between the flow in the pulmonary circulation (Q_p) and systemic circulation (Q_s).

When one performs a RHC the saturations in the SVC, RA, RV and AP can point towards a shunt. In the normal situation, the saturation in the right side of the heart is more or less the same in all compartments. But with a left to right shunt on atrial or ventricular level this rule of thumb does not hold true. The oxygenated blood from the left heart circulation will mix with the blood in the right heart circulation. Based on the saturations in the various right sided compartments one can discern the location of the left to right shunt. In the presence of an atrial shunt, the mixed venous saturation is calculated as (3 × SVC + 1 × IVC)/4. Figure 13.4 shows an example of the actual saturations measured in a real patient with an atrial septal defect with left to right shunting. We passed the atrial septal defect with the Swan Ganz catheter to obtain a real pulmonary vein saturation.

In case of a right to left shunt the location is much more difficult to find with RHC. The calculation is the same as for the left to right heart shunt. However, the saturation in the pulmonary vein is not the same as the arterial saturation in these

Fig. 13.4 Example of shunt calculation. This real world case shows an illustrative example of the actual saturations in a patient with a known atrial septal defect (ASD). The saturation in the pulmonary vein was obtained by passing the ASD with the Swan-Ganz and taking a sample from the actual left lower pulmonary vein



cases. One assumes that in the absence of severe pulmonary disease the pulmonary vein saturation to be 95–96%. When severe pulmonary disease is present, a right to left heart shunt calculation by RHC is more or less impossible.

$$Q_p = \frac{O_2 \text{ consumption}}{1.36 \times 1.6 \times \text{Hb}(\text{mmol/L}) \times [(\text{Sat Pulmonary vein}) - (\text{Sat AP})/100] \times 10}$$

$$Q_s = \frac{O_2 \text{ consumption}}{1.36 \times 1.6 \times \text{Hb}(\text{mmol/L}) \times [(\text{Sat Aorta}) - (\text{Sat mixed venous})/100] \times 10}$$

$$\text{Thus } Q_p/Q_s = \frac{[\text{Sat Aorta} - \text{Sat Mixed Venous}]}{[\text{Sat Pulmonary vein} - \text{Sat AP}]}$$

Note: for the saturation in the pulmonary vein, the saturation of the aorta of left ventricle can be used. The mixed venous saturation is calculated as $(3 \times \text{SVC} + 1 \times \text{IVC})/4$.

Resistance of the Vascular Bed

Pulmonary and systemic resistance are the representatives of the resistance that is encountered by the blood to flow from the arterial compartment to the venous compartment.

Hagen-Poiseuille's equation describes the relationship between flow, pressure gradient and resistance in fluids. The essence is the same as Ohm's law that describes how current, voltage and resistance relate.

$$\text{Resistance} = \text{Pressure gradient} / \text{Flow}$$

If this simplification of the complete equation is translated into the values obtained with RHC we can calculate the pulmonary pulmonary vascular resistance by

$$\frac{\text{Mean pressure AP} - \text{mean Pressure LA (= PCWP)}}{\text{Cardiac Output}}$$

And the systemic vascular resistance by

$$\frac{\text{Mean pressure Aorta} - \text{mean pressure RA}}{\text{Cardiac Output}}$$

For the circulation, this means that the resistance of the circulation can be calculated with the pressure difference between the pre-capillary and post-capillary pressures.

For the pulmonary vasculature this means that we can calculate the resistance of the pulmonary capillary bed. This also allows for discrimination of pre- and post-capillary pulmonary hypertension. When there is pulmonary arterial hypertension present and the pressure gradient is high, e.g. a low LA pressure, this means that the problem is located before the capillary bed. However, when the pressure gradient is low, e.g. high pressures in the left atrium then the cause of pulmonary arterial hypertension is situated behind the capillary bed and thus caused by left sided cardiac pathology.

Case

To appreciate what information a right heart catheterization can add in the diagnosis and management of patients with right sided cardiac pathology we use the following case. We focus on how the RHC helped in the diagnosis and discuss how the aforementioned hemodynamic parameters were obtained and how it helped in the diagnosis and the subsequent treatment plan.

The patient is a 64 year old female who presented with complaints of chest-pain and shortness of breath to the emergency department of a local community hospital. In the work-up the lab results showed elevation of hs-troponin-t as sign of cardiac injury. Coronary angiography was performed without epicardial stenoses. The echocardiogram however showed enlargement of the right atrium and right ventricle

(RV), with signs of elevated RV pressures. The RV pressure was estimated at 50 mm Hg. It was concluded that the patient suffered from a non ST-elevation acute coronary syndrome without obstructive coronary disease. And also had signs of pulmonary hypertension on echocardiography.

She was then referred to our pulmonary hypertension center for further analysis and possible treatment. A VO_2 -exercise test revealed hypoxemia at rest and a severe cardiopulmonary limitation with increasing hypoxemia during exercise.

Because of the discrepancy of the echocardiogram that only showed limited elevation of right sided pressures and the severely abnormal VO_2 -exercise test the patient was referred for RHC.

The operator was asked to answer two important questions, (1) what are the pulmonary pressures and what is the pulmonary vascular resistance, (2) is there a cardiac cause to be found.

As mentioned earlier, the most important task for the operator when performing a RHC is to understand how to answer the questions asked. In this particular case the first question is straight forward. It only implicates that a proper pressure waveform is taken in the pulmonary artery.

However, the second question is much less straight forward. In the preparation of this case it was discussed that however unlikely, it was important to rule out restrictive cardiomyopathy as a cause. Therefore an LVEDP was also measured.

Because the right ventricle showed enlargement and the CT-scan showed a large pulmonary artery the RHC was also focussed on assessing a left to right shunt because in theory an atrial septal defect could be the basis of the problems.

In this particular case restrictive cardiomyopathy was a possibility. Therefore, the operator decided to advance a catheter to the left ventricle for continuous left ventricular pressure measurement.

Figure 13.5a–g demonstrate the stepwise approach to the RHC performed in this particular case. Note that the operator chose to first assess the SVC and then went on to PCWP. Also as seen in Fig. 13.5c, advancing the Swan Ganz catheter to the RV was difficult. Therefore a loop in the RA was made to increase the push towards the RV. Because the LVEDP and PCWP were both low restrictive cardiomyopathy was quickly ruled out. In restrictive cardiomyopathy the filling pressures, e.g. diastolic pressures are elevated.

Figure 13.5g shows all the pressures and saturations in the compartments that were assessed. It was concluded that there was proof of pulmonary arterial hypertension with a high pressure gradient across the pulmonary vasculature. Therefore a left ventricular cause for the increased pulmonary pressures was ruled out.

However, the left to right shunt possibility remained open. We will now discuss how to use the RHC values of this patient to assess the presence or absence of a left to right shunt.

By looking at the results we can already see that there will not be a left to right shunt present. The saturation in the right atrium, the site closest to the possible location of a left to right shunt is lower than that of the SVC and IVC. Therefore there will not be a left to right shunt, because in that case the RA saturation would have been higher.

As mentioned before the formula to calculate a shunt is the following

$$Q_p/Q_s = \frac{[\text{Sat Aorta} - \text{Sat Mixed Venous}]}{[\text{Sat Pulmonary vein} - \text{Sat AP}]}$$

Because we may expect a left to right shunt we can not use the pulmonary arterial saturation for the mixed venous saturation. Therefore we calculate the mixed venous saturation by the eq. $(3 \times \text{SVC} + 1 \times \text{IVC})/4$.

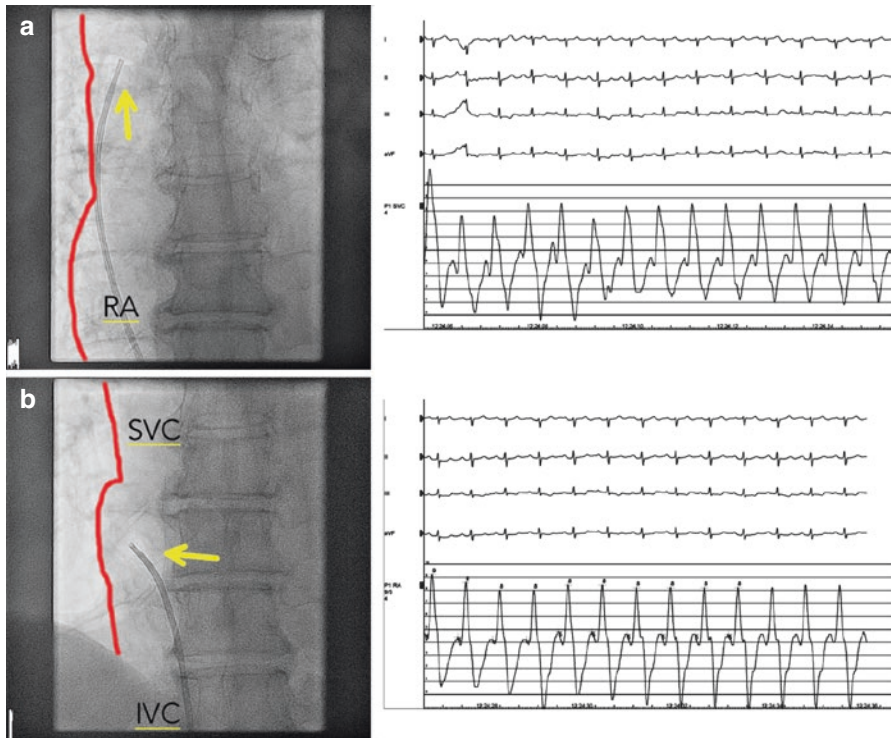


Fig. 13.5 (a) Image of the Swan-Ganz catheter with the tip in the SVC with the corresponding pressure measurement. The yellow arrow points to the location of the Swan-Ganz. (b) Image of the Swan-Ganz catheter with the tip in the RA with the corresponding pressure measurement. The yellow arrow points to the location of the Swan-Ganz. (c) Image of the Swan-Ganz catheter with the tip in the RV with the corresponding pressure measurement. The yellow arrow points to the location of the Swan-Ganz. (d) Image of the Swan-Ganz catheter with the tip in the PA with the corresponding pressure measurement. The yellow arrow points to the location of the Swan-Ganz. (e) Image of the Swan-Ganz catheter with the tip in the PCWP with the corresponding pressure measurement. The yellow ball depicts the inflated balloon at the tip of the Swan-Ganz to close of the pulmonary artery (as explained in Fig. 13.2). (f) Image of the Swan-Ganz catheter with the tip in the IVC with the corresponding pressure measurement. The green line represents the diaphragm, the red line is the right atrial wall. The yellow arrow points to the location of the Swan-Ganz. (g) Complete registration of all the pressures and saturations of the patient. IVC inferior vena cava, SVC superior vena cava, RA right atrium, RV right ventricle, PA pulmonary artery, PCWP pulmonary capillary wedge pressure, PV pulmonary valve, TV tricuspid valve

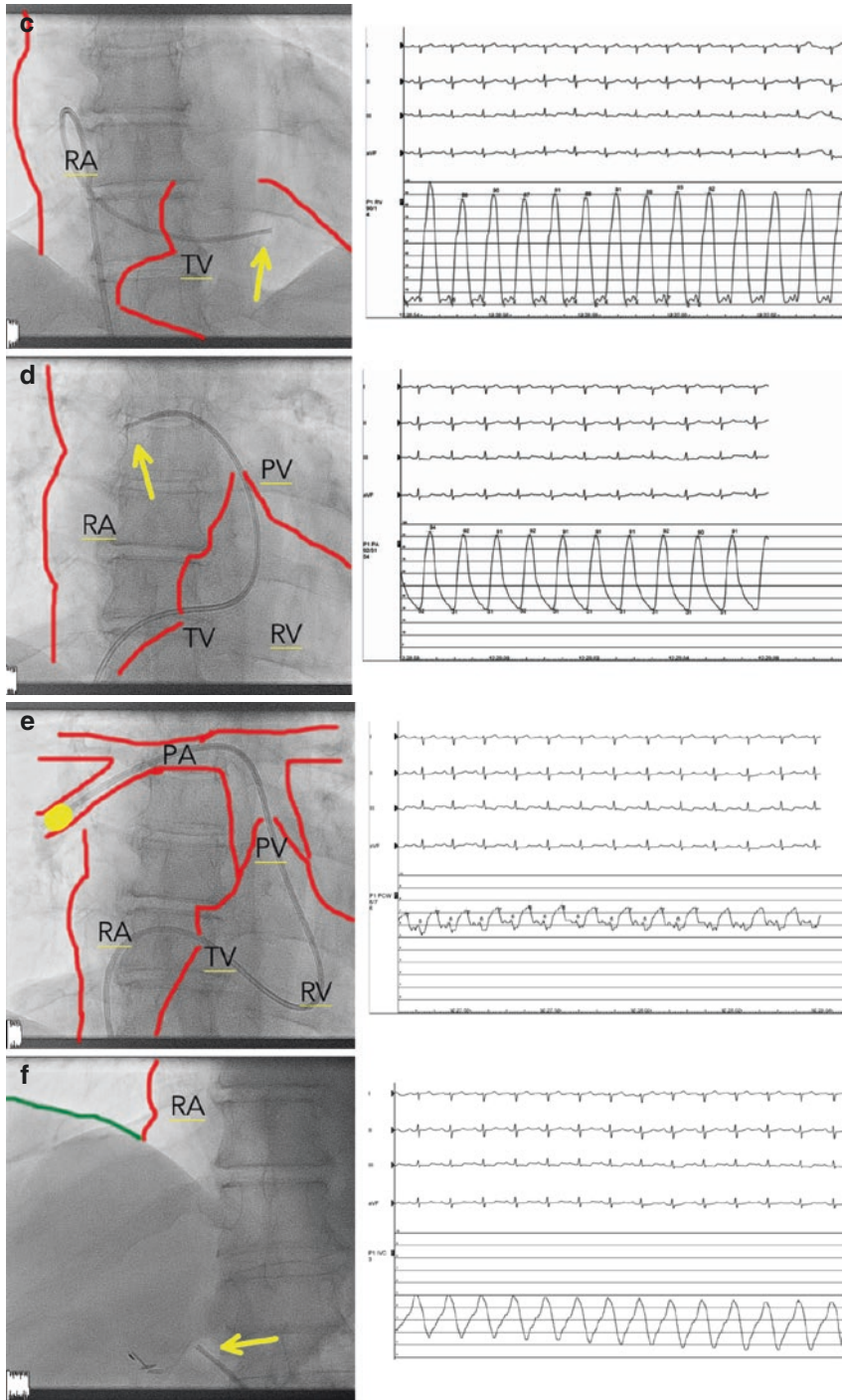
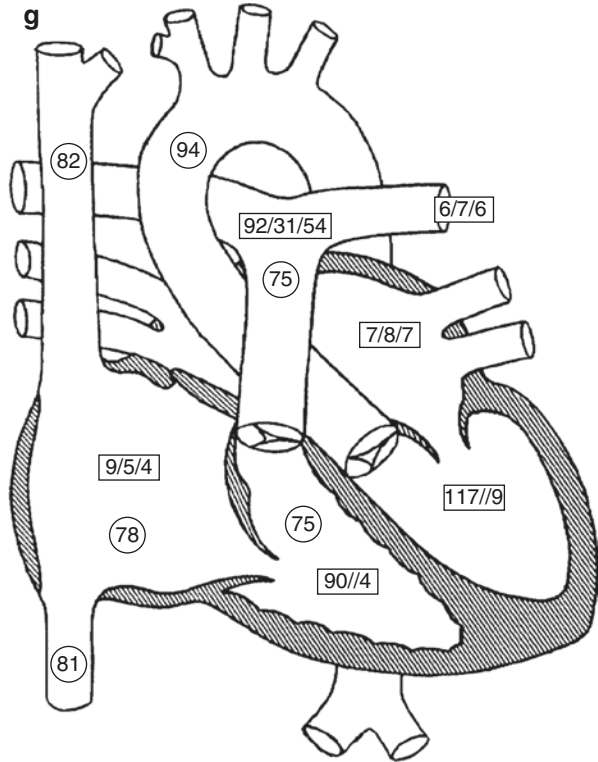


Fig. 13.5 (continued)

Fig. 13.5 (continued)



When we enter the various parameters, for this patient the equation results in

$$Q_p/Q_s = \frac{[94 - 81]}{[94 - 75]} = 0.68$$

This means that there is no sign of a left to right shunt. We now ruled out a cardiac cause of the pulmonary arterial hypertension. But the RHC gives much more hemodynamic information

First Cardiac Output.

$$\text{Cardiac Output} = \frac{\text{O}_2 \text{ consumption}}{1.36 \times 1.6 \times \text{Hb}(\text{mmol/L}) \times [(\text{Sat Aorta}) - (\text{Sat mixed venous})/100] \times 10}$$

The equation to calculate O₂-consumption for this patient is (157.3 × BSA + 10 × constant (male = 1; female = 0) – 10.5 × ln (Age) + 4.8) mL/min. Her BSA is 1.83; her age is 64. Her Hb was 9.6 mmol/L at the time of the study. The saturations were 94 and 75 respectively.

This leads to a calculated O₂-consumption of 251.1 mL/min and a cardiac output of

$$\text{Cardiac Output} = \frac{251.1}{1.36 \times 1.6 \times 9.6 \times [94 - 75 / 100] \times 10} = 6.6 \text{ L / min}$$

The rule of thumb 3.5 mL/kg (See paragraph Calculation of Cardiac Output) leads to an estimated O₂ consumption of 255.5 mL/min.

In this case because of her hypoxemia at rest in the referring hospital a higher resting O₂ consumption can be expected. Therefore O₂-consumption was measured prior to the RHC. This value was 312 mL/min.

The calculated cardiac outputs therefore range from 6.4–7.8. The operator also chose to measure cardiac output with thermodilution. This result was 7,3 L/min. So we can conclude that calculation of CO with the measured O₂-consumption corresponds well with the actual measured CO. Whereas the calculation of the CO with the assumed O₂-consumptions in this case underestimates the CO. As mentioned earlier, this is probably because this patient had pulmonary disease with hypoxemia at rest and thus a higher baseline O₂-consumption necessary to sustain the basic functions of the body.

Second Resistance.

We calculated the cardiac output above. And we measured the pressures in all compartments.

Therefore when we enter the numbers in the formula to calculate the pulmonary vascular resistance

$$\frac{\text{Mean pressure AP} - \text{mean Pressure LA} (= \text{PCWP})}{\text{Cardiac Output}}$$

This results in

$$\frac{54 - 6}{8} = 6 \text{ wood units or 480 dynes}$$

And the systemic vascular resistance by

$$\frac{99 - 4}{8} = 11.88 \text{ wood units or 950 dynes}$$

In summary, this real world case demonstrates that based on only non-invasive measurement of the pulmonary pressures this patient would not be a candidate for pulmonary vascular lowering therapy. The RHC demonstrated significant pulmonary arterial hypertension and ruled out a cardiac contribution to the pulmonary hypertension that otherwise would not be possible.

Because of the results of the RHC the treatment regimen of the patient was changed. She was started on bosentan, an endothelin-1 receptor antagonist that is a potent pulmonary arterial dilator.

Table 13.3 Classification of shock based on right heart catheterization

		CVP	PCWP/LA	CO	SVR	Specifics
Cardiogenic		High	High	Low	High	
Hypovolemic		Low	Low	Low	High	
Obstructive	Tamponade	High	High	Low	High	Pulsus paradoxus
	Pulmonary embolism	High	Low	Low	Pulmonary vascular resistance is high	
Distributive		Low	Unchanged/low	High	Low	

CVP central venous pressure (also right atrial pressure), *PCWP* pulmonary capillary wedge pressure, *LA* left atrium, *CO* cardiac output, *SVR* systemic vascular resistance, *PVR* pulmonary vascular resistance

Conclusion

Right heart catheterization allows for a complete assessment of the hemodynamic state of a patient. The results have important prognostic implications [3] but also help in the diagnosis of especially complex hemodynamic pathology [7, 8]. And although not shown to improve outcome when used in elective surgical patients [9] it also helps to discriminate the various types of shock (Table 13.3) and helps in the follow-up of instigated treatment [7].

Review Questions

71. In which cases of suspected pulmonary arterial hypertension noninvasive imaging is insufficient
 - (a) If only RV Pressures are measured
 - (b) No variables are known at exercise
 - (c) Possible restrictive CMP cannot be excluded
 - (d) All of the above
72. To calculate pulmonary resistance, which variables must be known
 - (a) Difference between PA pressure and Pulmonary capillary wedge pressures
 - (b) Cardiac output
 - (c) Both
73. In a case of severe TR RV catheterization can be cumbersome. How is your problem solved?
 - (a) Make a loop in the RA
 - (b) Insert a thin wire into the Swann Ganz catheter
 - (c) Both are right

References

1. Cruz K, Franklin C. The pulmonary artery catheter: uses and controversies. *Crit Care Clin.* 2001;17:271–91.
2. Gillebert TC, Brooks N, Fontes-Carvalho R, et al. ESC core curriculum for the general cardiologist. *Eur Heart J.* 2013;34:2381–411.
3. Humbert M, Sitbon O, Chaouat A, et al. Survival in patients with idiopathic, familial, and anorexigen-associated pulmonary arterial hypertension in the modern management era. *Circulation.* 2010;122:156–63.
4. Halpern SD, Taichman DB. Misclassification of pulmonary hypertension due to reliance on pulmonary capillary wedge pressure rather than left ventricular end-diastolic pressure. *Chest.* 2009;136:37–43.
5. Hoepfer MM, Lee SH, Voswinckel R, et al. Complications of right heart catheterization procedures in patients with pulmonary hypertension in experienced centers. *J Am Coll Cardiol.* 2006;48:2546–52.
6. Bergstra A, van Dijk RB, Hillege HL, Lie KI, Mook GA. Assumed oxygen consumption based on calculation from dye dilution cardiac output: an improved formula. *Eur Heart J.* 1995;16:698–703.
7. Chatterjee K. The Swan-Ganz catheters: past, present, and future. A viewpoint. *Circulation.* 2009;119:147–52.
8. Piazza G, Goldhaber SZ. The acutely decompensated right ventricle: pathways for diagnosis and management. *Chest.* 2005;128:1836–52.
9. Sandham JD, Hull RD, Brant RF, et al. A randomized, controlled trial of the use of pulmonary-artery catheters in high-risk surgical patients. *N Engl J Med.* 2003;348:5–14.

Part V
Therapeutic Perspective

Chapter 14

Pharmacotherapy of Tricuspid Valve Disease

Kadir Caliskan

Abstract In this section, pharmacological treatment of tricuspid regurgitation will be revised and illustrated by a case of patient with severe tricuspid regurgitation. The basic approach of pharmacological treatment of tricuspid valve disease is the treatment of volume overload/congestion, pulmonary hypertension and support of the right ventricle.

Keywords Tricuspid • Regurgitation • Heart failure • Pharmacotherapy • Outcome

Introduction

Primary tricuspid valvular disease is a relatively uncommon entity in the daily clinical practice and is mainly represented by tricuspid regurgitation (TR), secondary to dilatation of the tricuspid annulus due to right ventricular (RV) diseases and/or to elevation in the RV systolic pressure due the pulmonary hypertension. The clinical management is primary etiologic-based treatment. The conservative, pharmacological treatment is supportive with treatment of the symptoms and signs of heart failure like hepatomegaly, ascites and peripheral edema [1]. Given the rarity of the disease, there is no evidence-based specific treatment. In this chapter, we will give an overview of the pharmacological treatment, illustrated by a clinical case.

Electronic Supplementary Material The online version of this chapter (doi:[10.1007/978-3-319-58229-0_14](https://doi.org/10.1007/978-3-319-58229-0_14)) contains supplementary material, which is available to authorized users.

K. Caliskan, M.D., Ph.D.
Thoraxcenter, Department of Cardiology, Erasmus MC University Medical Center,
Rotterdam, The Netherlands
e-mail: k.caliskan@erasmusmc.nl

Case

A 48 years old women presented in 2009 with slowly progressive fatigue since a year. At presentation, she could only walk 15–20 min or one flight of stairs, consisting NYHA functional class III. She had no edema or congestion of the upper abdomen. Physical examination showed a heart rate of 72 bpm, blood pressure of 120/85 and a normal jugular venous pressure (JVP). Cardiac auscultation revealed a 2/6 systolic murmur at the 4th left intercostal space. Liver was not palpable and she had no edema. Her electrocardiogram (ECG) revealed sinus rhythm 72 bpm, PQ 178 ms, QRS width 75 ms, QTc 393 ms. The right precordial leads showed an increased R/S ratio resembling right ventricular (RV) hypertrophy (Fig. 14.1). Her echocardiography showed a severe dilated right atrium and RV with a preserved systolic RV function (Fig. 14.2a, b). The left ventricle (LV) dimensions and systolic function were normal. Her inter-ventricular septum bulged to the left. There was a severe tricuspid regurgitation (TR) due annular dilatation and restriction of septal leaflet. The insertion of the tricuspid leaflets looked further normal. Mid 2010, the patient underwent tricuspid valve (TV) valvuloplasty with Carpentier Edwards ring No. 30. Besides annulus dilatation, there was insufficient volume of the anterior leaflet with indentation. Therefore, the anterior leaflet was augmented with an autologous pericardial patch. Nevertheless, there was a residual grade 2+ TR. Further postoperative period was uncomplicated.

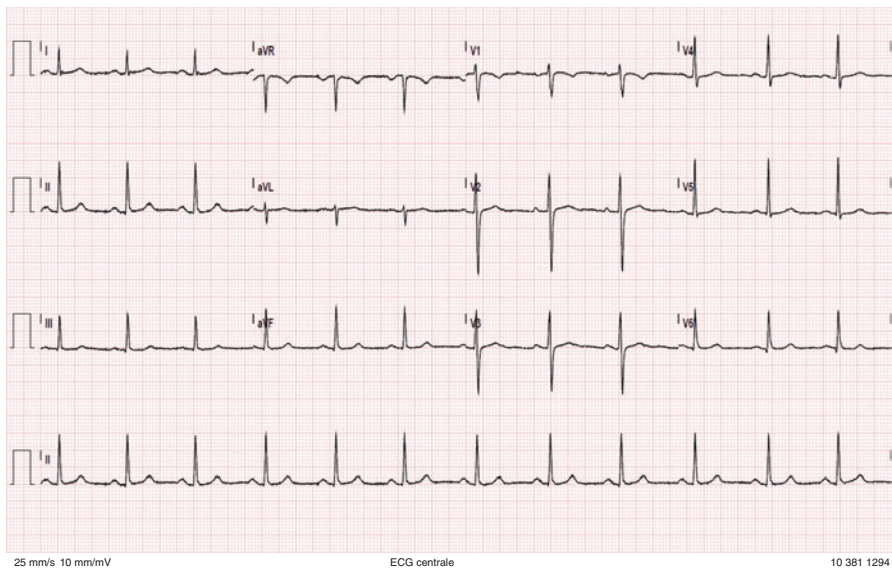


Fig. 14.1 Electrocardiography

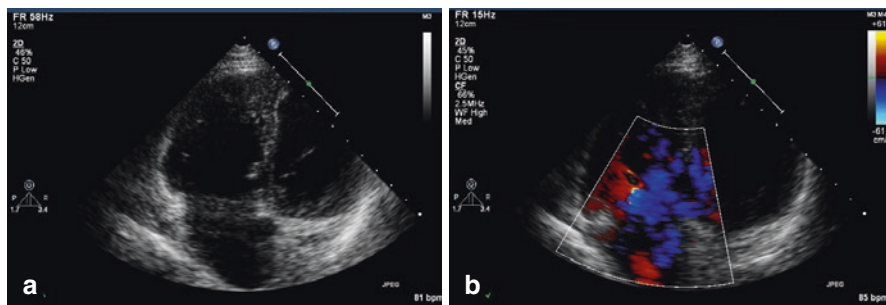


Fig. 14.2 (a, b) Showing dilated right atrium and right ventricle with interventricular septum bulged to the left. There is a severe tricuspid regurgitation due annular dilatation and restriction of septal leaflet. The insertion of the tricuspid leaflets looked further normal

In 2013 she was again presented with complaints of fatigue, dyspnea and some palpitations, with estimated NYHA class II a III. She had this time some signs of right-sided heart failure with elevated JVP and mild hepatomegaly. Cardiac auscultation revealed a 3/6 some rough systolic murmur at the 4th left sided intercostal spaces. There were no signs of ascites or peripheral edema. Her ECG showed sinus rhythm 66 bpm with frequent premature atrial extra systoles, PQ 182 ms, QRS width 102 ms and increased right precordial repolarisation abnormalities. Her echocardiography (Fig. 14.2a, b) showed severe RA and RV dilatation with diastolic D-sign of the interventricular septum at the parasternal short-axis view, and mobile intra-atrial septum. The RV function showed mild systolic dysfunction with TAPSE of 16 mm. There was again severe TR with a TR gradient of 24 m Hg with normal collapsing VCI of 18 mm. The patient was treated with low doses digoxin 0.0625 mg qd, bumetanide 1 mg bid, eplerenone 25 mg qd and bisoprolol 1.25 mg qd. Her case was discussed again in the heart team for redo surgery, but rejected due estimated low successful repair rate. Alternatively, the tricuspid valve could be replaced by a mechano-prothesis, but given the high long-term risk of complications, the redo surgery was postponed for the time being as long as the pharmacological treatment was sufficient for control of congestive symptoms. She was advised to do cardiac rehabilitation. At last follow-up in October, 2016, she was stable with some complaints of tiredness, but without any signs of heart failure. Her estimated functional NYHA class was II. Her ECG showed sinus rhythm 60 bpm, with signs of RV hypertrophy and secondary strain pattern.

Pharmacotherapy (See Fig. 14.3)

Lifestyle Advises

In patients with signs of fluid overload/congestion, mild salt (<5 g/day) and fluid restriction (1.5 or 2 L/day) is usually indicated, especially in patients needing high doses of loop diuretics and/or refractory congestion. The evidence in of these lifestyle advises is however far from conclusive [2].

Loop Diuretics

For patient with symptomatic heart failure and volume overload, the initial therapy is usually a loop diuretics like furosemide or bumetanide [3]. The usual starting dose for furosemide in our clinic is 40 mg qd (bumetanide 1 mg qd), but in more advanced heart failure patients with more severe elevated jugular venous pressure (JVP), hepatomegaly, ascites and/or peripheral edema, twice daily dose is usually need. Albeit no maximal doses toe give, in case of failing oral daily doses above furosemide 500 mg orally (or bumetanide 10 mg), continuous intravenous are usually need. In cases of non-response of progressive deterioration of the renal function, additional low doses inotropes (e.g. dobutamine 3–5 µg/kg/min or enoximone 0.5–2 µg/kg/min) could be added.

In case of euvolemia, maintenance dose of diuretics should be minimized, given potential aggravation of the neurohormonal stress, i.e. renine-angiotensine-aldosterone system, beside risks of gout, electrolyte disturbances and renal dysfunction.

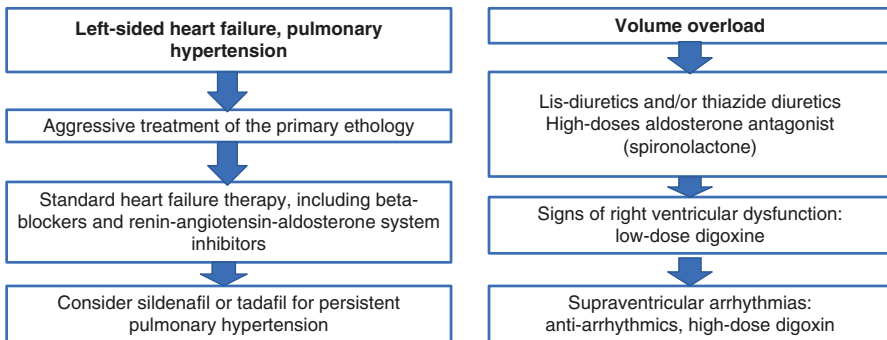


Fig. 14.3 The approach for the pharmacological treatment of tricuspid valve diseases

Mineralocorticoid Receptor Antagonist

The clinical use of the mineralocorticoid receptor antagonist (MRA) spironolactone and eplerenone in chronic HF is established with two landmark trials: RALES and EMPHASIS [4, 5]. The studies are however in predominantly, left-sided systolic HF patients. In predominant right-sided HF patients like in TR, the use of MRA is based on clinical experience. The usual start doses for spironolactone is 12.5–25 mg with maintenance doses of 25–50 mg daily and for eplerenone 25–50 mg. In refractory heart failure patients and/or diuretic resistances, usually higher doses (>100 mg) are needed. The common side effects include hyperkalemia, worsening renal function and/or gynecomastia. Eplerenone has however, significantly lower endocrine side effects, including gynecomastia and breast tenderness.

Digoxin

Since the eighteenth century, digitalis has been used for patients with heart failure. As a weak positive inotropic due to indirect increase in the intracellular calcium in the myocardium, it improves the cardiac hemodynamics, exercise tolerance and diuresis [6]. Currently, digoxin is commonly advised for persistent symptomatic HF patients with functional NYHA class 3 or more, in right-sided HF patients with refractory symptoms, RV dysfunction and/or concomitant atrial arrhythmias. Given the narrow therapeutic window, concerns of excess mortality, especially in women, the advised digoxin dose is much lower (“the HF dose”; i.e. 0.5–0.8 ng/mL) than in patients with atrial arrhythmias [7].

ACE-Inhibitors, Angiotensin II Receptor Blocker and Beta-Blockers

The blockade of activated renin-angiotensin (RAAS) and sympathetic nervous system (SNS) in chronic heart failure patients are essential elements of the current heart failure treatment given tremendous positive effect on the long-term outcome and survival [8, 9]. There are however no randomized trials in patients with TR, so the indication will be only on pathophysiological rationale. Given the same expected effects in RAAS and SNS system—lesser or more—in all heart failure patients regardless of the etiology, we treated most of the TR patient with ACE-R and beta-blocker. This is however usually much lower doses than what is used in left-sided HF patients, in our experience due to hypotensive effects and worsening renal function.

Key Points

- Treatment of volume overload and congestion by diuretics are the key approach in the pharmacological treatment of tricuspid valve disease.
- Any left sided heart failure and/or pulmonary hypertension should be treated aggressively.
- If signs of right ventricular dysfunction or supra-ventricular arrhythmias, digoxin should be prescribed in *low positive inotropic* heart failure dose or *high anti-arrhythmic* doses.

References

1. Nishimura RA, Otto CM, Bonow RO, Carabello BA, Erwin JP 3rd, Guyton RA, et al. 2014 AHA/ACC Guideline for the Management of Patients With Valvular Heart Disease: executive summary: a report of the American College of Cardiology/American Heart Association Task Force on Practice Guidelines. *Circulation*. 2014;129(23):2440–92.
2. Yancy CW, Jessup M, Bozkurt B, Butler J, Casey DE Jr, Drazner MH, et al. 2013 ACCF/AHA guideline for the management of heart failure: executive summary: a report of the American College of Cardiology Foundation/American Heart Association Task Force on practice guidelines. *Circulation*. 2013;128(16):1810–52.
3. Ponikowski P, Voors AA, Anker SD, Bueno H, Cleland JG, Coats AJ, et al. ESC Guidelines for the diagnosis and treatment of acute and chronic heart failure: the Task Force for the diagnosis and treatment of acute and chronic heart failure of the European Society of Cardiology (ESC). Developed with the special contribution of the Heart Failure Association (HFA) of the ESC. *Eur J Heart Fail*. 2016;18(8):891–975.
4. Pitt B, Zannad F, Remme WJ, Cody R, Castaigne A, Perez A, et al. The effect of spironolactone on morbidity and mortality in patients with severe heart failure. Randomized Aldactone Evaluation Study Investigators. *N Engl J Med*. 1999;341(10):709–17.
5. Zannad F, McMurray JJ, Krum H, van Veldhuisen DJ, Swedberg K, Shi H, et al. Eplerenone in patients with systolic heart failure and mild symptoms. *N Engl J Med*. 2011;364(1):11–21.
6. McMahan WS, Holzgrefe HH, Walker JD, Mukherjee R, Arthur SR, Cavallo MJ, et al. Cellular basis for improved left ventricular pump function after digoxin therapy in experimental left ventricular failure. *J Am Coll Cardiol*. 1996;28(2):495–505.
7. Rathore SS, Curtis JP, Wang Y, Bristow MR, Krumholz HM. Association of serum digoxin concentration and outcomes in patients with heart failure. *JAMA*. 2003;289(7):871–8.
8. The CONSENSUS Trial Study Group. Effects of enalapril on mortality in severe congestive heart failure. Results of the Cooperative North Scandinavian Enalapril wSurvival Study (CONSENSUS). *N Engl J Med*. 1987;316(23):1429–35.
9. Effect of metoprolol CR/XL in chronic heart failure. Metoprolol CR/XL Randomised Intervention Trial in Congestive Heart Failure (MERIT-HF). *Lancet*. 1999;353(9169):2001–7.

Chapter 15

Tricuspid Valve Interventions: Heart Team Discussion, When, Who and What?

Joachim Schofer

Abstract Tricuspid valve disease is mainly the consequence of RV annular dilatation (functional tricuspid regurgitation, TR) following RV pressure or volume overload. Moderate to severe TR is affecting a significant number of patients and impacts mortality.

Surgical tricuspid repair is indicated at time of left-sided valve surgery in the presence of an annulus diameter of >40 mm. The same is true for reoperation of patients with symptomatic severe TR, preserved RV function and not severe pulmonary hypertension as well as for primary surgery of patients with asymptomatic severe TR and progressive RV dysfunction. Suture or ring annuloplasty are the currently preferred surgical techniques.

Patients with severe TR and prior open-heart surgery and patients with functional TR and progressive RV dysfunction are often deemed at high or prohibitive operative risk and are mostly treated medically. Those patients are candidates for less invasive transcatheter techniques, which recently were developed for treating TR.

Percutaneous approaches for TR are valve implantation in the caval veins by using self-expandable or balloon expandable valves, devices to improve leaflet apposition or annuloplasty devices.

Initial in-human experiences with transcatheter devices have been demonstrated to be feasible, their effectiveness, however, remains to be shown in retrospective registries with larger number of patients with longer-term follow-up and finally, in prospective randomized trials to demonstrate the superiority of these new therapies over standard medical therapy. Before this data becomes available these interventions should be limited to patients with an extreme or prohibitive surgical risk.

Keywords Tricuspid valve regurgitation • Heart team • Outcome • Surgery • Catheter based interventions • Annuloplasty • Leaflet coaptation • TEE • TTE

J. Schofer, M.D., Ph.D.

Medical Care Center and Albertinen Heart Center, Hamburg, Germany

e-mail: schofer@herz-hh.de

Prevalence and Mechanism of Tricuspid Regurgitation

The prevalence of moderate or severe tricuspid regurgitation (TR) is estimated to affect 1.6 million people in the United States [1]. Primary tricuspid valve (TV) disease represents about 25% of TR and may be due to congenital, rheumatic, neoplastic, traumatic, infective endocarditis, endomyocardial fibrosis, or iatrogenic (following pacemaker lead implantation or right ventricular [RV] biopsy) causes [2].

Secondary (functional) TR most often is a consequence of RV annular dilation following RV pressure or volume overload. This causes tricuspid annular dilation, which is the dominant mechanism of functional TR [3, 4]. Significant TR occurs when anterior and posterior leaflets, which are fixed at the muscular part of the annulus, are pulled away from their coaptation point. The septal leaflet, in contrast, remains stable in position because it is fixed at the fibrous part of the annulus [4, 5].

Severe functional TR may appear in the context of left-sided heart disease or may arise following RV myocardial infarction and subsequent RV dilation (Table 15.1). RV dilation is associated with a shift of the interventricular septum to the LV,

Table 15.1 Etiologies of TR

Primary (leaflet abnormality): 25%	Congenital	Ebstein's anomaly
		Tricuspid valve tethering associated with perimembranous VSD and VSA
		Other (giant right atrium)
	Acquired disease	Carcinoid
		Degenerative (myxomatous)
		Endocarditis
		Endomyocardial fibrosis
		Iatrogenic (pacing leads, RV biopsy)
		Rheumatic
		Toxins
Trauma		
Other (e.g., ischemic papillary muscle rupture)		
Secondary (functional): 75%	Left heart disease	LV dysfunction or valve disease
	Right ventricular dysfunction	RV cardiomyopathy (e.g., ARVD) RV ischemia RV volume overload
	Pulmonary hypertension	Chronic lung disease Left-to-right shunt Pulmonary thromboembolism
	Right atrial abnormalities	Atrial fibrillation
Other	Post-operative	Recurrent TR post-surgical intervention

ARVD arrhythmogenic right ventricular dysplasia, LV left ventricle, RV right ventricle, TR tricuspid regurgitation, VSA ventricular septal aneurysm, VSD ventricular septal defect

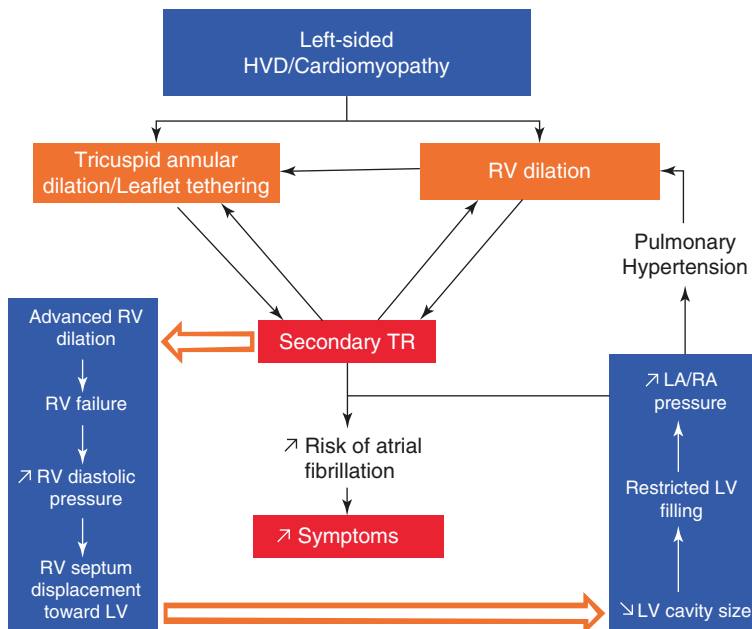


Fig. 15.1 Mechanisms of functional tricuspid regurgitation [6]

which decreases LV stroke volume and increases LV-filling pressure and thereby pulmonary artery pressure. The increase in RV afterload further deteriorates TR and RV function closing a vicious circle [6] (Fig. 15.1).

Right heart catheterization is important for determining the etiology of secondary TR. Evaluating both the degree and origin of PAH (pre-capillary, isolated post-capillary, or combined pre- and post-capillary) [7] impacts the decision to treat or not to treat severe functional TR. Interventions in patients with pre-capillary PAH or severe PAH may be associated with major negative clinical effects secondary to critical RV failure. Similarly, an early post-operative RV dysfunction after tricuspid surgery has been associated with a negative clinical outcome [5].

Outcomes

Significant secondary TR is frequently well tolerated in its early stages, however, progressive dilation of the tricuspid annulus and RV remodelling results in right heart failure over time. Irreversible RV damage is a common reason for the poor outcomes following late TV surgery.

Several observational studies have reported that moderate-to-severe TR is associated with excess mortality at follow-up, independent of RV function [8, 9]. It is important to optimize medical therapy of the underlying condition according to

guidelines. The use of pulmonary vasodilator therapies in post-capillary PAH is not recommended in patients with PAH secondary to left heart disease according to the 2015 European guidelines [7].

Surgery for TR

In patients with severe mitral regurgitation and normal left ventricular ejection fraction, the prevalence of at least moderate TR was 24% [10]. Following mitral valve surgery in case, this has not been combined with tricuspid repair in the presence of an annulus diameter of >40 mm, nearly 50% of the population demonstrated an increase in TR severity of more than two grades over time [11].

Despite the association of severe TR and poor survival, relatively few patients undergo TV surgery. In the absence of another indication for cardiac surgery patients are mostly managed with medical therapy. Isolated TV surgery accounts for only 20% of all tricuspid interventions [12], mostly because this is associated with a high operative risk. Results from isolated TV surgery series report an in-hospital mortality rate ranging from 2% to 9.8% [12–14]. Pre-operative hemoglobin, bilirubin, creatinine levels, and measures of RV function predicted clinical outcome [15].

In patients undergoing left-sided valve surgery, the guidelines (Fig. 15.2) recommend concomitant TV repair when the tricuspid annulus is dilated, even if TR

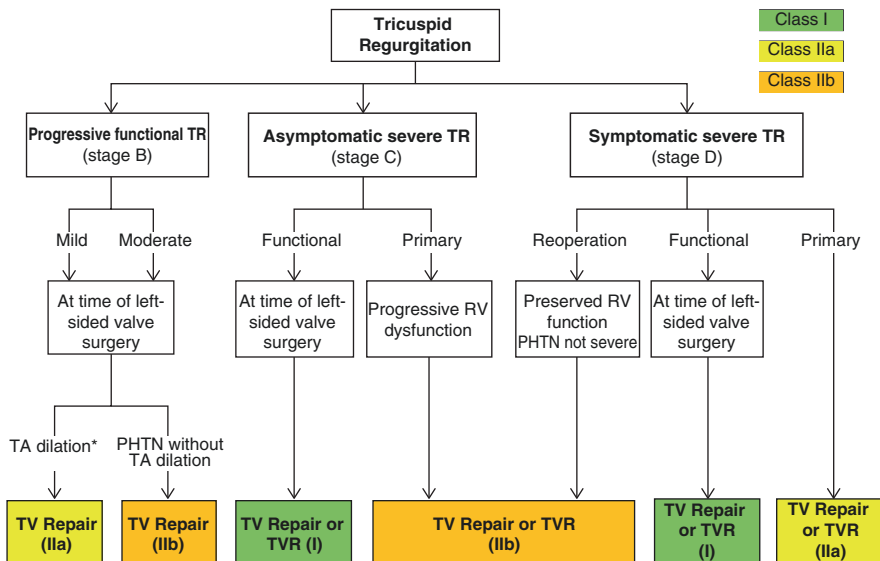


Fig. 15.2 Indications for surgery for tricuspid regurgitation [17]

severity is mild [16, 17]. This is done to prevent the need for TV reoperation at a later date, if severe TR and RV dysfunction develop. Tricuspid annuloplasty remains the surgical technique of first choice for functional TR, either by suture annuloplasty or ring annuloplasty, which is the currently preferred technique due to increased durability compared with suture techniques [18].

Transcatheter Interventions for TR

In recent years novel transcatheter interventional options were developed for treating TR. Patients with severe TR and prior open-heart surgery are often deemed at high or prohibitive operative risk for reoperation and are mostly treated medically. In particular, those patients and patients with functional TR and progressive RV dysfunction with right heart failure are candidates for less invasive transcatheter techniques.

When performing transcatheter interventions for TR the size of a device and its placement into the RA or RV should take into account close structures that can be injured by the procedure, such as the AV node, the coronary sinus, and the right coronary artery. Pacemaker or defibrillator leads, which may cause significant TR [19] could also impact the feasibility of a transcatheter technique. To date, this has been a contraindication for most of the transcatheter TV repair techniques.

Imaging of the Tricuspid Valve

Several catheter techniques for functional TR are currently under clinical evaluation. For the application of all these devices imaging is crucial. Most of the procedures are almost completely guided by transesophageal echocardiography.

Because visualisation of the tricuspid valve for guiding transcatheter procedures is a new field, a brief introduction into this specific issue seems to be reasonable.

Transthoracic Echocardiography

Visualizing the TV should be performed from multiple transthoracic windows (Fig. 15.3a–d). The European and American Heart Association/American College of Cardiology guidelines recommend the end-diastolic septolateral dimension from the transthoracic apical 4-chamber view (Fig. 15.3c) as a criterion for intervening. A dimension of 40 mm (or >21 mm/m²) indicates severe tricuspid annular dilation [16, 17].

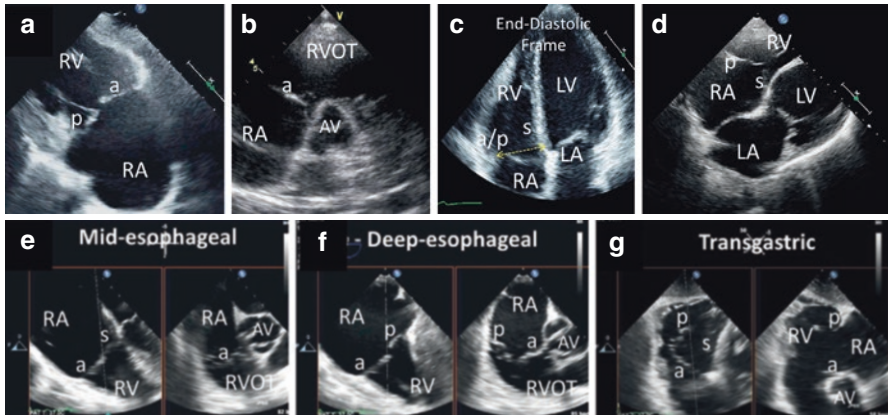


Fig. 15.3 Transthoracic and transesophageal imaging planes for the TV. Multiple transthoracic imaging planes (**a–d**) should be performed for comprehensive imaging of the tricuspid valve (TV). The parasternal inflow view (**a**) images the anterior (a) and posterior (p) leaflets when no ventricular septum is in the imaging plane. (**b**) Parasternal short-axis view at the level of the aortic valve; when the transducer is angled anteriorly, only the anterior (a) leaflet is seen (with no other leaflet coaptation). (**c**) On-axis 4-chamber view with the left ventricle (LV) in the apex of the sector. The end-diastolic frame shown should be used to measure the annular diameter (*dashed yellow double arrow*). A subcostal view is shown in **d**. Transesophageal imaging planes (**e–g**) should be performed from multiple levels. These examples from the mid-esophageal view (**e**), the deep-esophageal view (**f**), and the transgastric view (**g**) are simultaneous multiplane images showing the primary imaging plane on the left of each panel, and the orthogonal (rotated 90°) image on the right side of each panel. AV ¼ aortic valve; LA ¼ left atrium; RA ¼ right atrium; RV ¼ right ventricle; RVOT ¼ right ventricular outflow tract; s ¼ septal leaflet

Table 15.2 summarizes the parameters used for grading the severity of TR, which are described by the ASE and European Association of Echocardiography guidelines [20, 21]. Quantitative assessment of tricuspid regurgitant volume by the proximal iso-velocity surface area method has been validated [22, 23]. An effective regurgitant orifice area (EROA) >40 mm² and regurgitant volume of >45 mL has been considered an important sign of severe TR. Three-dimensional (3D) imaging studies of the color Doppler vena contracta, however, suggest that severe tricuspid regurgitation EROA may be >75 mm² [24, 25].

Transesophageal Echocardiography

Compared to transthoracic, transesophageal echocardiography (TEE) has higher spatial resolution and allows a larger number of windows to image the entire TV apparatus. The new ASE guidelines [26] advocate additional views of the TV (Fig. 15.3e–g). Low esophageal and high transgastric views may permit better imaging of the TV. Transgastric short-axis views allow simultaneous

Table 15.2 Assessment of TR severity

Parameters	Mild	Moderate	Severe
<i>Qualitative</i>			
TV morphology	Normal or mildly abnormal leaflets	Usually abnormal leaflets	Severe valve lesions (e.g., flail leaflet, severe tethering, malcoaptation)
Interventricular septal motion	Normal	Typically normal	Paradoxical/volume overload pattern (diastolic interventricular septal flattening)
Colour flow TR jet (note: not recommended for sole grading of severity)	Small RA penetration or not holosystolic	Moderate RA penetration or large penetration and late systolic	Deep RA penetration and holosystolic jet, or eccentric wall-impinging jet (variable size)
Flow convergence zone	Not visible, transient or small	Intermediate in size and duration	Large throughout systole
CW TR jet density/contour	Faint/parabolic or partial contour	Dense/parabolic, variable contour	Dense/triangular with early peaking (peak <2 m/s in massive TR)
IVC size	Usually normal	Usually normal or mild dilation	Usually dilated ^a with reduced respirophasic variability
RV and RA size	Usually normal	Usually normal or mild dilation	Usually dilated ^b
<i>Semi-quantitative</i>			
Tricuspid annulus	<40 mm ² or 21 mm ² /m ²	May be >40 mm ² or 21 mm ² /m ²	>40 mm ² or 21 mm ² /m ²
[‡] Color flow jet area (cm ²)	Not defined	Not defined but <10	>10
[‡] Vena contracta width (mm)	Not defined	<7	≥7
[§] PISA radius (mm)	≤5	6–9	>9
Hepatic vein flow	Systolic dominance	Systolic blunting ^c	Systolic flow reversal
Tricuspid inflow	A-wave dominant and/or E-wave <1 m/s	Variable	E wave dominant (≥1 cm/s)
<i>Quantitative</i>			
EROA (mm ²) [by PISA]	<20	20–39 ^d	≥40
Regurgitant volume (mL) [by PISA]	<30	30–45 ^d	≥45

Assessment of TR severity is by a combination of the American Society of Echocardiography and European Society of Echocardiography Recommendations for the Assessment of Valvular Regurgitation [20, 21] and the AHA/ACC Guideline [17]. Bolded signs are considered specific of their TR grade CW continuous wave, EROA effective regurgitant orifice area, RA right atrium, RV right ventricular, TR tricuspid regurgitation, TV tricuspid valve

^aIVC diameter of >2.5 cm as per ASE guidelines [20]

^bRV and RA can be within the "normal" range for patients with acute severe TR or with chronic severe TR associated with restrictive cardiomyopathy

^cSigns are non-specific and are influenced by many other factors (RV diastolic function, atrial fibrillation, RA pressure)

^dThere is little data to support further separation of these values

[‡]At a Nyquist limit of 50–60 cm/s

[§]With Baseline Nyquist limit shift of 28 cm/s

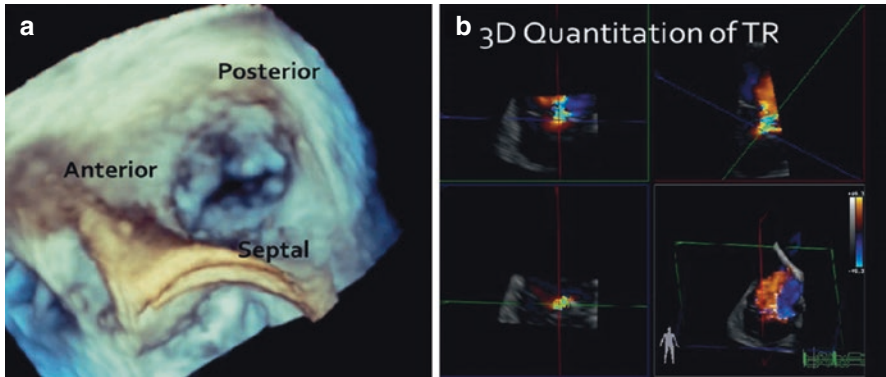


Fig. 15.4 3D Imaging of the TV. The surgical view of the tricuspid valve (TV) (a) places the interatrial septum inferiorly (at the 6 o'clock position), regardless of the atrial or ventricular orientation. Using 3-dimensional (3D) color Doppler (b), the effective regurgitant orifice area can be used to quantify the severity of regurgitation. TR $\frac{1}{4}$ tricuspid regurgitation

visualization of all valve leaflets (Fig. 15.3g, orthogonal plane). A deep transgastric view of the TV permits optimal color flow and spectral Doppler evaluation of TR jets.

Three-D imaging of the TV, which has also been addressed in the guidelines [27] has significantly improved the identification of the tricuspid leaflets and associated anatomic components.

Lang et al. [27] suggested a standardized imaging display for the en face view of the TV with the interatrial septum placed at the 6 o'clock position (Fig. 15.4). This standardization improves the communication with the interventionist when performing transcatheter interventions.

Transcatheter Treatment Modalities

Interventional strategies for functional TR comprise three different types of approaches (Fig. 15.5):

- Transcatheter valve implants at the level of the SVC and IVC or the IVC only, to treat the caval reverse backflow.
- Devices to improve valve leaflet coaptation by occupying the regurgitant orifice area (FORMA device) or by edge-to-edge repair (Mitraclip device).
- Devices to decrease the TA dimensions in order to reduce TR severity (Trialign, TriCinch, CardioBand). As preclinical upcoming devices, TRAIPTA and the Millipede IRIS Implant.

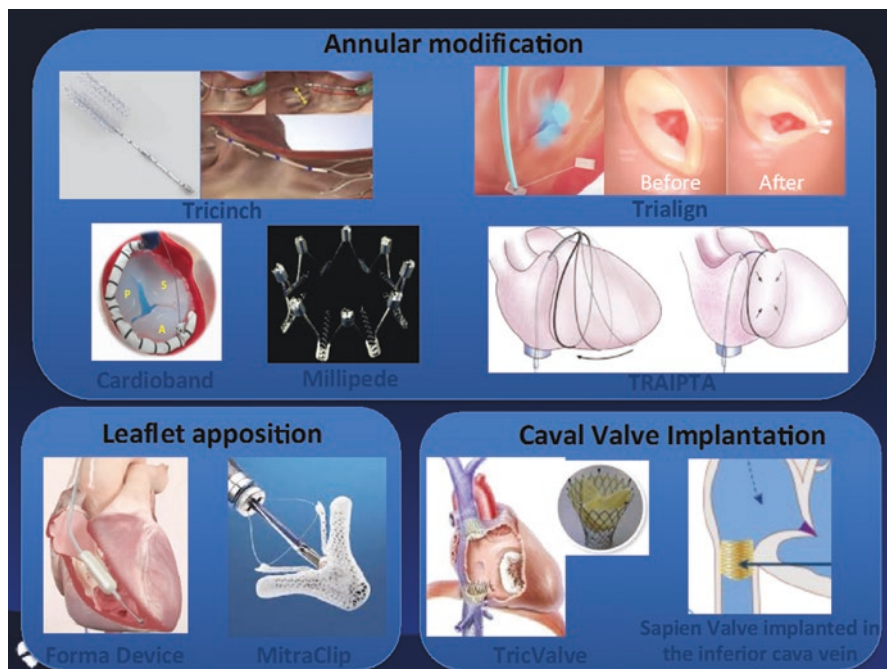


Fig. 15.5 Transcatheter treatment modalities

Bicaval Valve Implantation

Due to the challenging anatomy of the TV complex, there is a lack of in-human experiences of transcatheter TV replacement. However, experience with valve implantation for treating TR has targeted the inferior and superior vena cava in order to limit the reverse backflow associated with severe TR.

Caval valve implantation (CAVI) has been suggested for patients with severe TR and significant regurgitation of blood into the caval veins, which is often seen in the presence of severe, long-standing TR and RV enlargement. The main challenges for this approach are the large and variable diameter of the caval veins and the proximity of the right atrium and hepatic veins.

Self-expandable dedicated Valve devices: Self-expandable dedicated valve devices are currently under clinical evaluation for a transvenous approach (Fig. 15.6a–e) [28]. The Tric Valve (P&F Products & Features Vertriebs GmbH, Vienna, Austria, in cooperation with Braile Biomedica, São José do Rio Preto, Brazil) consists of two self-expandable bio-prosthetic valves that are anchored at the cavo-atrial inflow accommodating vein sizes from 28 to 43 mm. These self-expandable devices do not require a pre-stenting of the caval veins. They are designed with the upper segment protruding into the RA, to protect from backflow and, on the other hand, avoid occlusion of hepatic veins [28, 29].

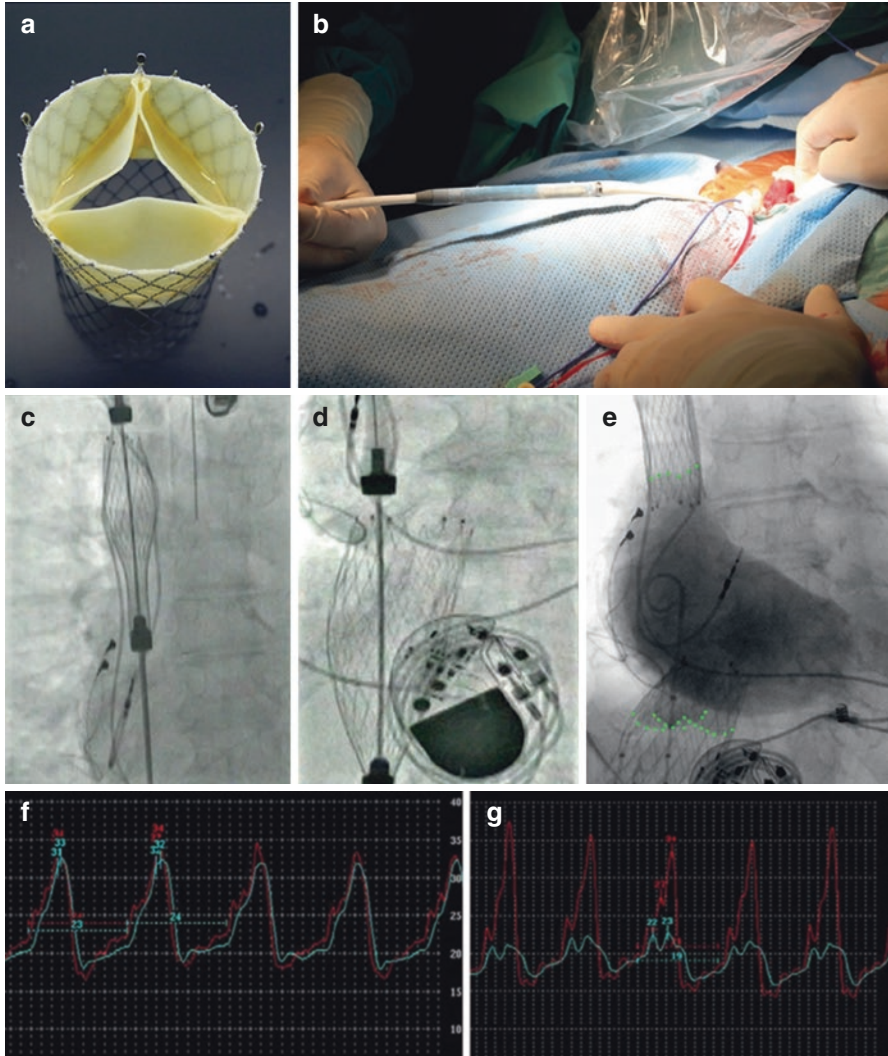


Fig. 15.6 CAVI with the Tric valve device. (a and b) The pericardial valve mounted on a self-expandable nitinol stent is loaded into a 27-F catheter for implantation. (c–e) After transfemoral access and under *fluoroscopic* and *echocardiographic* guidance, the SVC and IVC valves are sequentially deployed. Transjugular pacer leads are jailed by the SVC stent. Reprinted with permission from Lauten et al. [29]. (f and g) Pressure measurement confirms a reduction of the ventricular wave and mean pressure in IVC pressure from 32 mm Hg to 23 mm Hg and 24 mm Hg to 19 mm Hg, respectively. Blue tracing $\frac{1}{4}$ inferior vena cava; red tracing $\frac{1}{4}$ right atrium. CAVI $\frac{1}{4}$ caval valve implantation; IVC $\frac{1}{4}$ inferior vena cava; SVC $\frac{1}{4}$ superior vena cava

Chronic animal studies further showed excellent function of caval valves at mid-term follow-up [30]. Since 2011, five compassionate clinical use cases have been performed confirming the technical feasibility of CAVI, as well as the immediate and sustained hemodynamic improvement from the reduction of IVC and SVC backflow (Fig. 15.6f, g) [28]. The device was implanted successfully in four cases. In one patient, the devices could not be deployed as intended, and surgery was required. After a mean clinical follow-up of 7.4 ± 13.2 months, sustained valve function was observed. Midterm symptomatic relief and moderately improved physical capacity were observed [28, 29]. Warfarin anticoagulation was effective and sufficient to prevent thromboembolic complications during follow-up. However, the mortality rate was 80%, which reflects the significant comorbidities of this patient cohort. A prospective multicenter registry is planned in the near future.

Balloon-expandable caval implants: Caval implantations of balloon-expandable valves designed to treat aortic stenosis (29 mm Edwards Sapien XT or Sapien 3, Edwards Lifesciences, Irvine, California) have also been used off-label for the treatment of severe TR. Due to size limitations this approach requires preparation of a landing zone by implanting one or more self-expandable stents (Sinus XL, Optimed Medizinische Instrumente, Ettlingen, Germany), to facilitate valve fixation. This technique has been mostly limited to the IVC.

The procedure is performed through the right femoral vein via a 20-F eSheath. A self-expandable large stent (26–30 mm in diameter according to IVC diameter and 40–80 mm in length) is then implanted protruding approximately 5 mm into the RA. Thereafter, the 29-mm balloon-expandable valve is deployed inside the stent just superior to the confluence of the first hepatic vein (Fig. 15.7). For a dual-valve procedure, prior to IVC, the SVC prosthesis is implanted after positioning a self-expanding stent superior to the confluence of the RA. A total of ten compassionate clinical use patients have been treated to date. Ninety percent of patients had the valve implanted in the IVC only, and intact valve function was confirmed by echocardiography in all cases. Patients received unfractionated heparin and oral anticoagulation therapy thereafter.

There were no procedure-related complications. All, but one patient (with decompensated PAH at baseline) improved by at least one New York Heart Association (NYHA) functional class and had improved RV function [31]. The 30-day mortality rate was 20%, and no valve malfunction was detected at a follow-up of up to 913 days. Currently, this technology is under evaluation in a randomized single-center open-label study in Europe [32] and in a prospective single-center registry in the United States [33].

Devices to Improve Leaflet Apposition

The FORMA Repair System (Edwards Lifesciences): is a transcatheter device for patients with severe functional TR that acts as a coaptation device. It is composed of a rail, which is anchored at the apex of the RV, and a spacer, which is a

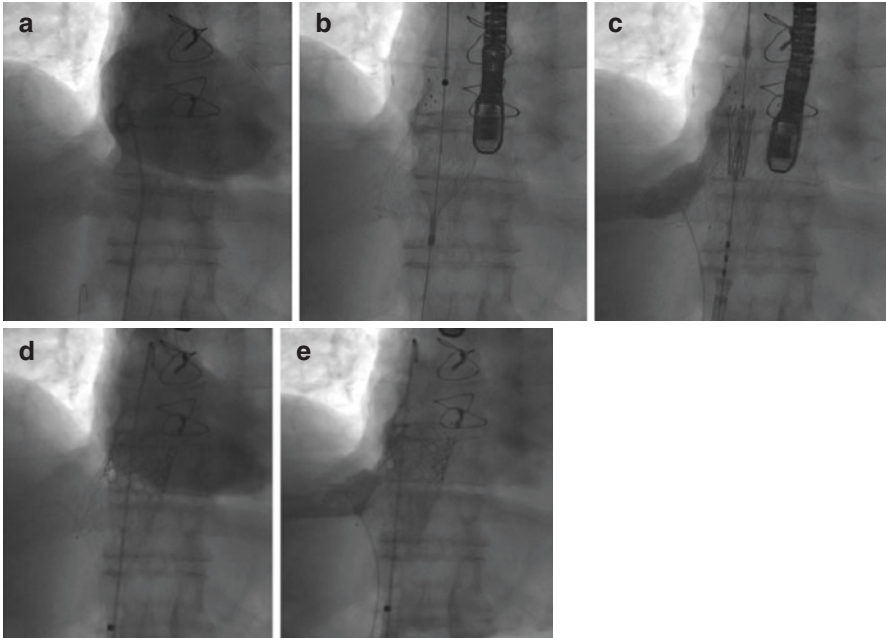


Fig. 15.7 CAVI With the Balloon-Expandable Edwards Valve. (a) Severe TR with hepatic vein reflux (*arrow*); (b) deployment of two self-expandable stents in IVC; (c) valve implantation above the confluence of the hepatic vein; (d) no regurgitation at the level of the transcatheter valve; (e) free confluence of the hepatic vein (*arrow*)

foam-filled polymer balloon, available in two sizes (12 and 15 mm) that serves as the coaptation element in order to improve leaflet malcoaptation (Fig. 15.8). Implantation of the device is performed via the left subclavian or axillary vein, which should accommodate a 24 F introducer sheath.

The anchoring zone at the RV apex is identified by right ventriculography. By using a steerable catheter the anchor is deployed perpendicular to the center of the TA plane, viewed by fluoroscopy. Thereafter, the spacer is moved forward and placed under fluoroscopy, and its position then verified by two-dimensional (2D) and 3D TEE. The device is locked and the extra rail length is placed into a subclavian subcutaneous pocket.

To date, seven patients treated with this device have been reported [34], with no in-hospital mortality, no cardiac tamponade, no need for conversion to open surgery, or access-site complications. Although the presence of the spacer makes TTE assessment of TR difficult, reduction in TR was sufficient to improve functional (NYHA) classification and reduce peripheral edema in all patients. Exercise capacity and results of quality-of-life tests at 30 days improved in four patients. An early feasibility trial is currently on-going in the United States [35] and larger feasibility studies are planned to start in the near future.

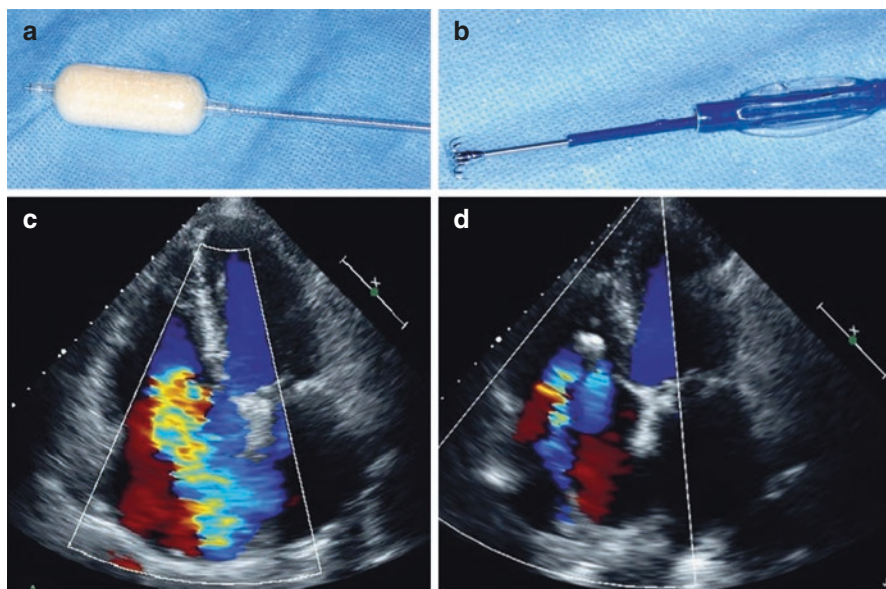


Fig. 15.8 The FORMA Repair System. (a) Spacer. (b) Steerable delivery catheter and anchoring system. Apical 4-chamber-view of TEE of the same patient before (c) and after (d) device implantation. Reprinted with permission from Campelo-Parada et al. [34]. EROA $\frac{1}{4}$ effective regurgitant orifice area; TEE $\frac{1}{4}$ transesophageal echocardiography

MitraClip for TR: An initial human experience with the MitraClip device (Abbott Vascular, Santa Clara, California) for treating severe TR via the transjugular or transfemoral vein was reported in four patients [36, 37]. The device was successfully implanted and associated with acute TR reduction in all patients. These first anecdotic reports were followed by a more comprehensive publication of the European experience comprising 64 patients [38]. Clipping was performed in 42 patients for TR only and in additional 22 patients in association with a MitraClip procedure. The results are promising (Table 15.3).

Annuloplasty Devices

Annular dilation (usually >40 mm or >21 mm/m²) is the most important mechanism underlying severe functional TR. In order to reduce the TA diameter percutaneous annuloplasty devices have been developed.

The Trialign device (Mitralign, Tewksbury, Massachusetts) (Fig. 15.9) is a percutaneous annuloplasty system that reproduces the Kay surgical procedure [39]. By plication of the muscular part of the tricuspid annulus this procedure converts an incompetent tricuspid into a competent bicuspid valve. The device components are an 8-F articulating wire delivery catheter, a pledget catheter, which is preloaded

Table 15.3 Echocardiographic and functional results at baseline and before discharge to 30 days separated after combined MR + TR or single TR clipping-procedure

	TR clip (n = 42)			TR + MR clip (n = 22)		
	Baseline	Discharge	p	Baseline	Discharge	p
TR vena contracta, cm	1.0 ± 0.4	0.5 ± 0.1	0.003	1.3 ± 0.6	0.8 ± 0.5	0.06
TR EROA, cm ²	0.8 ± 0.4	0.4 ± 0.2	<0.001	1.0 ± 0.3	0.4 ± 0.1	<0.001
Regurgitant volume, mL/beat	59.9 ± 18.4	30.8 ± 6.9	<0.001	56.3 ± 13.4	29.9 ± 8.2	<0.001
Septo-lateral diameter, mm	43.2 ± 7.6	30.5 ± 8.7	0.02	42.2 ± 9.7	32.7 ± 9.6	0.04
Leaflet tenting area, cm ²	3.4 ± 1.9	3.6 ± 3.1	0.7	4.5 ± 0.7	4.2 ± 0.8	0.5
Leaflet tenting distance, mm	13.6 ± 3.7	15.5 ± 4.9	0.3	13.3 ± 4.5	14.8 ± 6.7	0.5
6MWT, m	181.9 ± 44.1	209.5 ± 59.9	0.006	224.0 ± 143.1	268.2 ± 143.1	0.2

with 4 mm × 8 mm large pledgets, and a plication lock device (Fig. 15.9) [40]. Two 12 F sheaths are placed into the right internal jugular vein and the wire delivery catheter is positioned into the RV with fluoroscopy and 2D and 3D TEE guidance. The catheter is articulated under the annulus to either the antero-posterior or the septo-posterior commissure. To avoid right coronary artery perforation the artery is marked by a guidewire. Then an insulated radiofrequency wire is advanced and positioned 2–5 mm from the base of the leaflet within the annulus. The wire is advanced through the annulus toward the right atrium, which is confirmed by TEE, and t̂30p̂+.

9op hen externalized. A pledget delivery catheter is advanced across the RV annulus and half of the pledget is delivered and cinched in the subannular region of the ventricle. Upon withdrawal of the pledget delivery catheter, the second part of the pledget is extruded and cinched on the atrial surface of the annulus. The steps are repeated on the opposite commissure of the posterior leaflet. With a dedicated plication lock device, the two pledgeted sutures are brought together, thereby plicating the annulus.

The first-in-man procedure was performed in September 2014 [40] in a 89-year-old woman with right heart failure due to severe secondary TR. The procedure resulted in reduction of the TA area and EROA, which was reduced by >50% (Fig. 15.9e). This was associated with a significant decrease in right atrial pressure and increase in left ventricular stroke volume. The patient tolerated the procedure

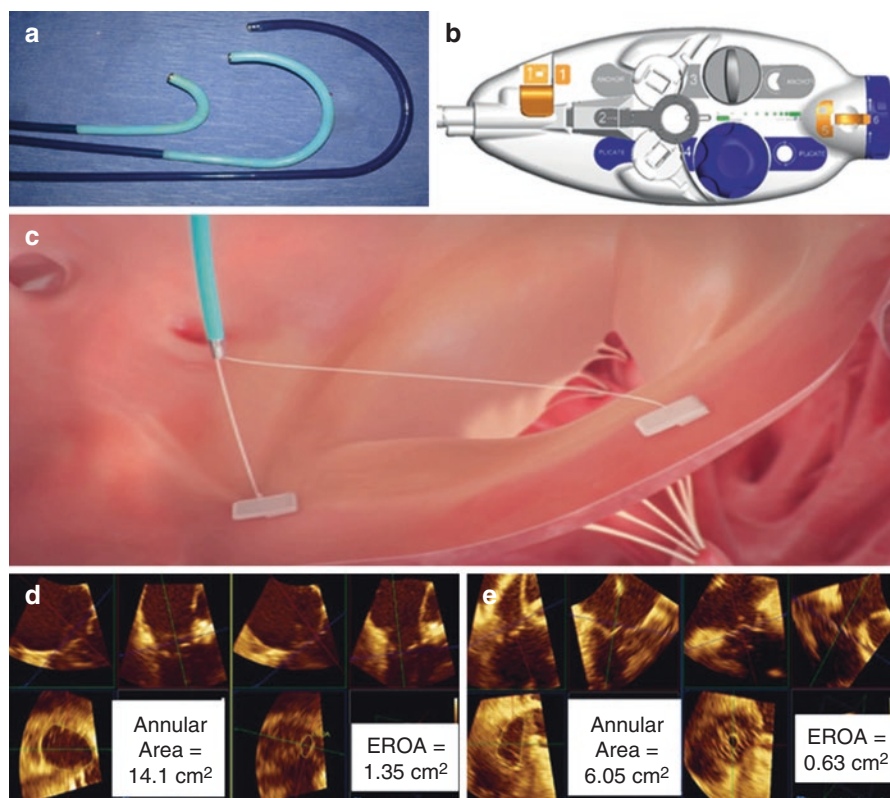


Fig. 15.9 The Mitralign Device (a) Steerable catheter. (b) Detail of the Mitralign system. (c) Pledgets delivered at the anteroposterior and septoposterior commissures. (d) TEE assessment of TR at baseline and (e) after device implantation

well, was extubated the same day, and was discharged 5 days post-procedure with significant improvements in effort tolerance.

Meanwhile, more than 30 patients have been treated with the Trialign device worldwide. At TCT 2016 the results of the first reported clinical cohort in a US early feasibility study of transcatheter tricuspid repair (SCOUT trial [41]) and the early European experience [42] were presented.

The SCOUT trial enrolled 15 patients with symptomatic functional TR and no left-side surgery planned. The study was performed at four US investigational sites. The primary endpoint was technical success at 30 days, freedom from death with successful access, delivery and retrieval of the device delivery system, deployment and correct positioning of the device and no need for additional unplanned or emergency surgery or re-intervention related to the device or access procedure.

Key inclusion criteria were

- Chronic functional tricuspid regurgitation with a minimum of moderate TR,
- ≥ 18 and ≤ 85 years of age

- Symptomatic despite Guideline Directed Medical Therapy GDMT; at minimum patient on diuretic use
- Systolic pulmonary artery pressure sPAP ≤ 60 mmHg
- LVEF $\geq 35\%$
- Right ventricle TAPSE ≥ 13 mm
- Tricuspid valve annular diameter ≤ 55 mm or 29 mm/m²
- Tricuspid EROA ≤ 1.2 cm²
- Sufficient posterior annular dimension for device implantation

Key exclusion criteria were

- Previous tricuspid valve repair or replacement
- Presence of trans-tricuspid pacemaker or defibrillator leads
- Chronic oral steroid use ≥ 6 months
- Tethering distance > 0.8 cm
- Aortic, mitral and/or pulmonic valve stenosis and/or regurgitation \geq moderate

The mean age of the patients was 73.6 ± 6.6 years, 86.7% were females, all patients were in NYHA class II or III, 66.7% had prior percutaneous or surgical mitral valve interventions, 66.7% were in atrial fibrillation and all patients were on diuretics.

The device implant success was 100%, in one patient (7%) an intraprocedural stenting of the right coronary artery was performed due to vessel impingement.

Results at 30 days were 100% freedom from death and technical success in 80%. In 3/15 patients single pledget dehiscence was observed. There were no major adverse events. Per protocol echocardiographic outcomes at 30 days showed significant reductions of TV annular diameter, TV annulus area, PISA EROA and quantitative EROA as well as a numerical reduction of TR regurgitant volume from 79.6 ± 17.5 mL at baseline to 57.1 ± 29.0 mL at 30 days. Interestingly LVOT stroke volume increased significantly from 63.6 ± 17.9 mL to 71.5 ± 25.7 mL.

The hemodynamic improvements translated into an intent to treat clinical outcomes improvement at 30 days with significant enhancement in the 6 MWT (from 245.2 to 298 m), in NYHA classification and in the Minnesota Living with Heart Failure Score.

It is planned to enroll 15 additional patients with the purpose to implant more than one pair of pledgets, patients with pacemaker leads, congenital heart disease or transplant tricuspid regurgitation.

Yzeiraj et al. reported the results of 14 patients who were treated on a compassionate use basis [42]. The EROA and the annulus area could be reduced by 51% and 34%, respectively. No serious adverse events like death, myocardial infarction, stroke/TIA, vascular access complications, acute kidney injury, coronary obstruction or perforation, valvular injury or ventricular perforation occurred. Only one patient experienced a transient conduction disturbance.

At the Albertinen Heart Center in Hamburg, in 2/14 patients for the first time a double pair of pledgets was implanted (Fig. 15.10). The results of the procedure in the first patient are summarized in the Table 15.4.

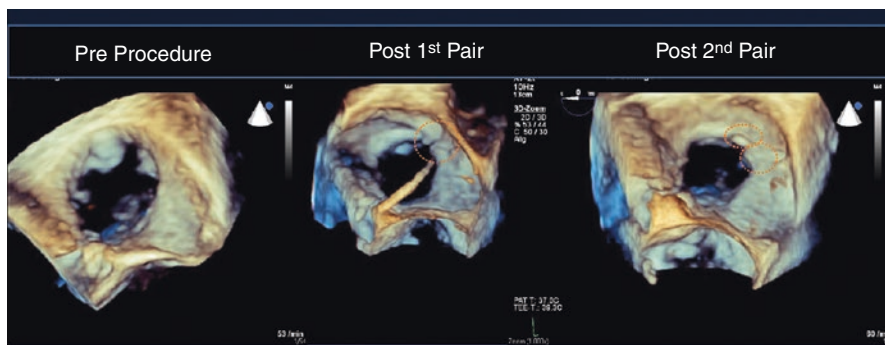


Fig. 15.10 3-D-Echo of a patient with two pairs of pledgets

Table 15.4 Echocardiographic results before and after Trialign procedure with two pairs of pledgets

Parameter	Baseline	Post-procedural	Reduction (%)
Vena contracta (mm)	16	4.4	73
TR volume (mL)	30	9	70
4 Ch diameter (cm)	5.01	3.87	23
Annular area (cm ²)	20.38	10.44	49
3D EROA (cm ²)	2.67	0.49	82
TR ERO (cm ²)	0.71	0.17	76
TR PISA radius (mm)	11	6	45

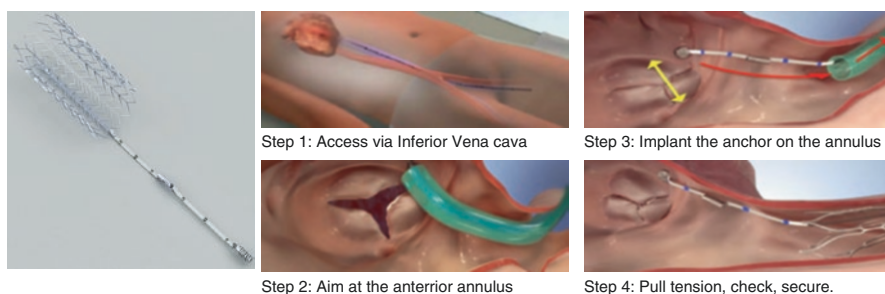


Fig. 15.11 The TriCinch System. The TriCinch System is composed of a corkscrew anchor, a self-expanding stent, and a Dacron band connecting them (*left*). Images show the step-by-step procedure for implantation of the TriCinch System (*right*). Reprinted with permission from Latib et al. [43]

The *TriCinch device* (4Tech Cardio, Galway, Ireland) is a percutaneous annuloplasty device designed for functional TR repair [43]. This device system (Fig. 15.11) consists of a corkscrew anchor, a self-expanding stent, and a Dacron band, which is connecting the anchor with the stent [43]. Four stent sizes are currently available (27, 32, 37, and 43 mm).

Implantation is performed using an 18-F steerable delivery system which is advanced through a 24-F femoral vein introducer sheath into the right atrium under fluoroscopy and echocardiographic guidance. The location of the anchor implantation is identified by baseline cardiac CT and, during the procedure, by fluoroscopy. A coronary wire within the right coronary artery serves as a landmark. The stainless steel corkscrew is fixed into the anteroposterior TV annulus. The stability of the anchor is checked by angiography and an echocardiographic “pull test.” An appropriately oversized self-expanding nitinol stent is then deployed in the IVC. The stent delivery system is advanced and connected to the corkscrew via the Dacron band. The system is then tensioned under TEE monitoring, to assess reduction of septolateral dimension and TR grade. Once sufficient TR reduction is obtained, TV tension is maintained while deploying the stent in the sub-hepatic region of the IVC.

The first-in-human implantation of this device was recently reported [43]. The device is currently being evaluated in an on-going feasibility trial, the PREVENT study [44]. The objectives are to demonstrate safety and efficacy in TR reduction in 24 patients [43]. As reported by Denti [45] to date 24 patients have been enrolled, all symptomatic with signs of right heart failure. The device could be successfully implanted in 18 patients (75%). Two patients (8%) developed hemopericardium and late detachment was seen in another four patients (17%). Thirty-day all-cause mortality was 0%.

In four patients at 6 months follow-up 6 MWT improved by 53%, quality of life by 38% and physical activity by 42%. Based on the early learning curve, several aspects of the delivery system have been improved. In addition, evaluation of tissue quality, perioperative echocardiographic guidance and the pre-operative identification of a safe location of the target position on the TA with respect to the right coronary artery turned out to be important requirements for a successful procedure. The next steps for this device will be the release of a 1-step version, to integrate the two current delivery systems into one, and the development of an alternative anchoring mechanism to avoid late anchor detachment.

CardioBand for TR: Recently, the CardioBand annuloplasty device, which is designed for treatment of functional MR, has been used for functional TR in a small number of patients. Maisano [46] (Fig. 15.12) did the first patient and the procedure resulted in a significant reduction in TA diameter as well as TR grade. A feasibility and safety study is currently being performed in Europe.

Preclinical Experience with Upcoming Devices

Successful preclinical experiences with transcatheter tricuspid devices include two annuloplasty devices, the transatrial intrapericardial tricuspid annuloplasty (TRAIPTA) device [47], and the Millipede IRIS Implant (Fig. 15.13a, b). This

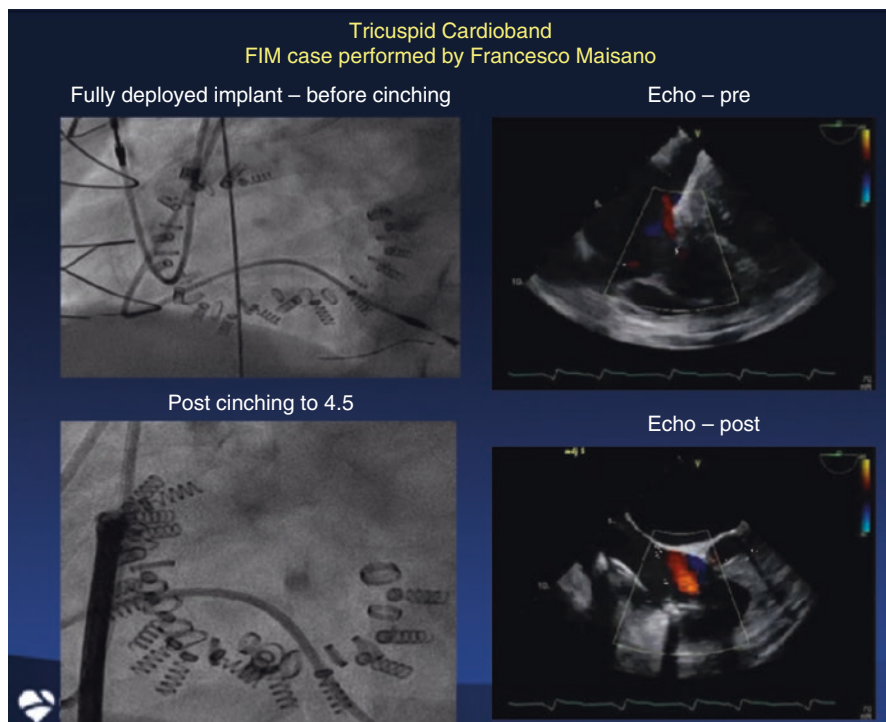


Fig. 15.12 Cardioband

device consists of a complete ring, which is fixed in the annulus from the atrial site by eight anchors that are screwed into the tissue. The distance between the anchors can then be reduced by turning a screw at the tip of the device. Advantages of the device are that it is customizable in size post-implantation, it preserves native valve leaflets and has no LVOT interference. It may serve as a stand-alone repair or as a valve docking station for a de novo valve.

Transcatheter Valve Replacement

There have also been successful pre-clinical experiences with fully transcatheter TV replacement using dedicated transcatheter valve platforms (Figs. 15.14 and 15.15) [48]. However, to the best of our knowledge, to date there have not been attempts of full transcatheter valve replacement in a native TV in humans.

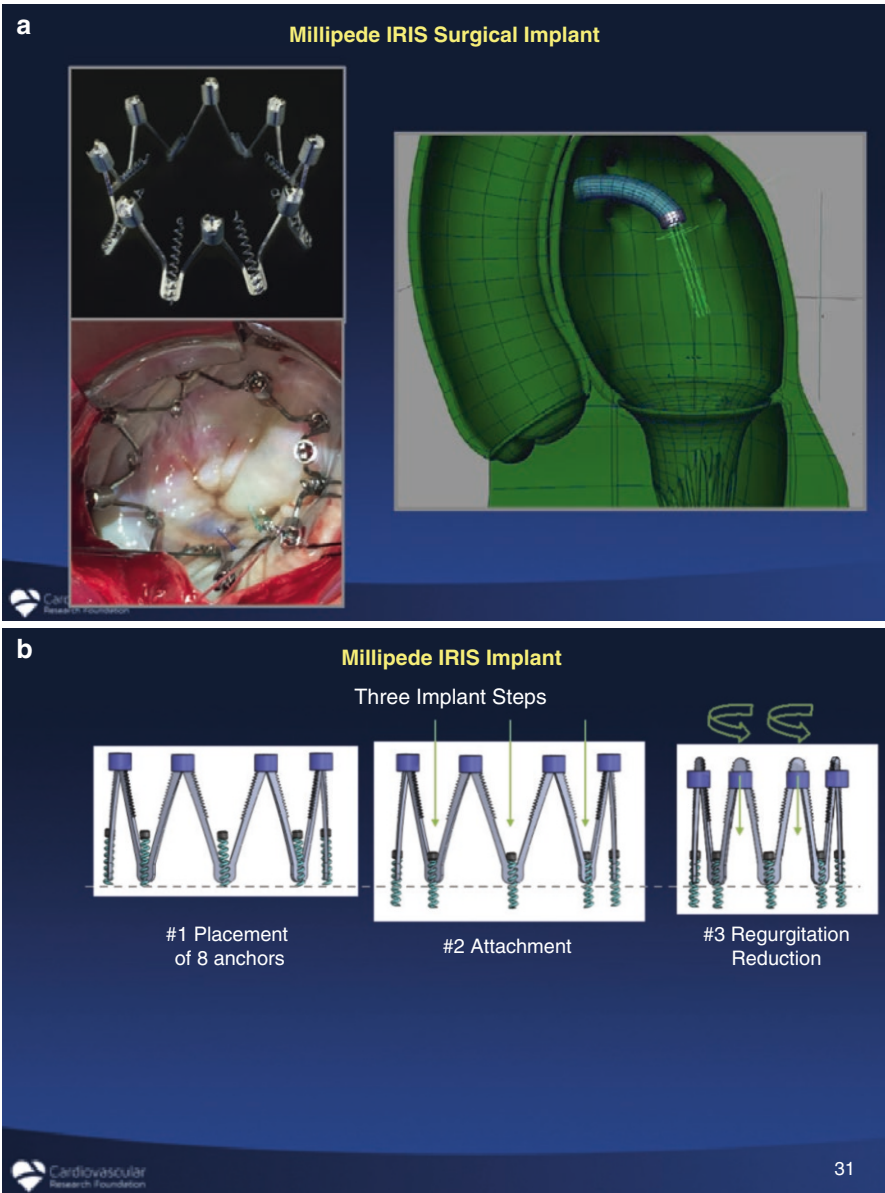


Fig. 15.13 Millipede implant

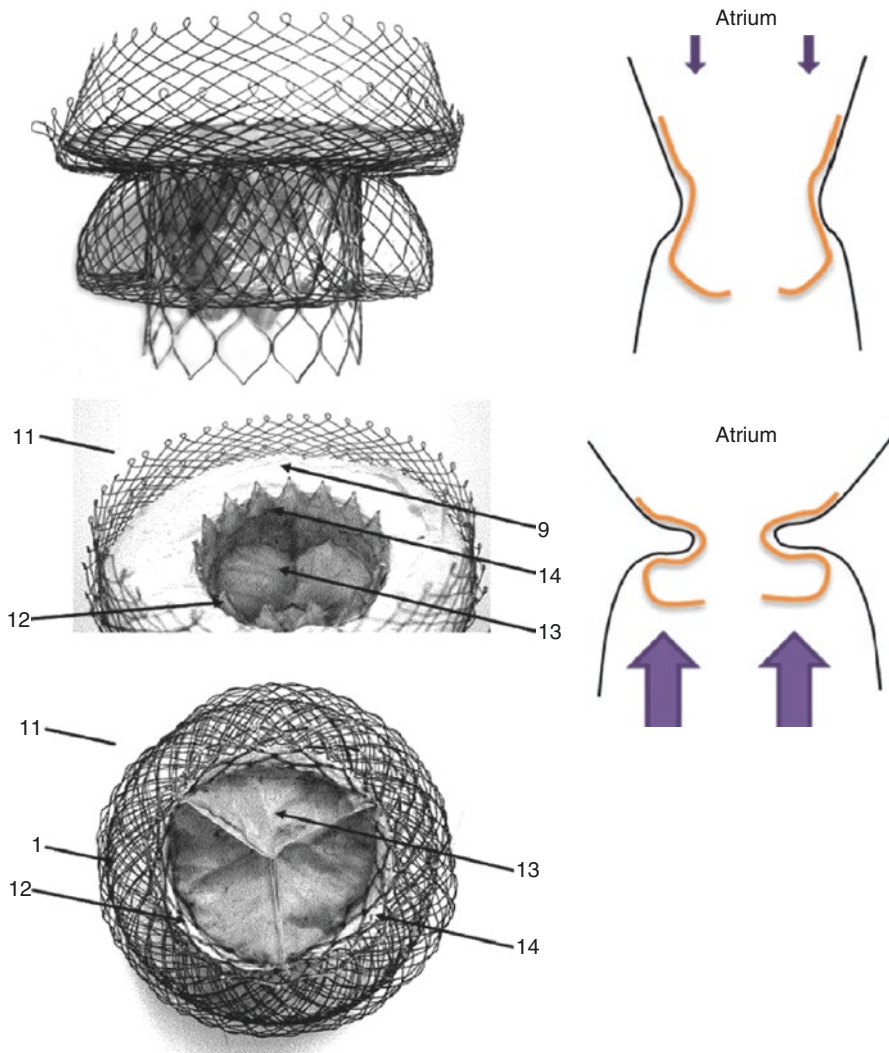


Fig. 15.14 Tricare

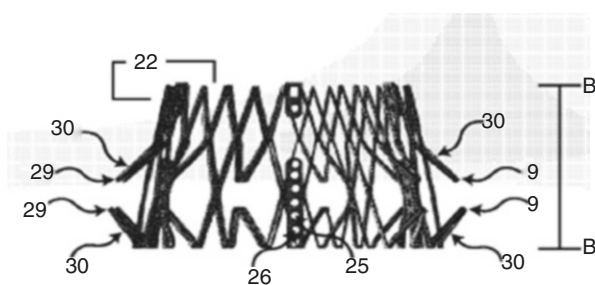


Fig. 15.15 Navigate

Conclusions

Functional TR is a consequence of RV and TA dilatation. It has a high prevalence and a significant impact on functional status and long-term survival. Isolated surgical tricuspid replacement/repair is associated with high operative risk, especially in patients with prior left-sided cardiac surgery. To date, for most of these patients medical therapy is the only treatment option. Less invasive interventions are therefore badly needed.

Interventional strategies for functional TR are still in the early stages. Three different types of approaches are under evaluation:

- Transcatheter valve implants at the level of the SVC and IVC or the IVC only, to treat the caval reverse backflow.
- Devices to improve valve leaflet coaptation by occupying the regurgitant orifice area (FORMA device) or by edge-to-edge repair (Mitraclip device).
- Devices to decrease the TA dimensions in order to reduce TR severity (Trialign, TriCinch, CardioBand). As preclinical upcoming devices TRAIPTA and the Millipede IRIS Implant.

The initial in-human experiences with transcatheter devices have been limited to patients at very high or prohibitive surgical risk. Although feasibility has been demonstrated in small patient cohorts, the effectiveness of these new therapies remains to be shown.

Prospective registries with larger number of patients and longer-term follow-up are needed. Finally, prospective trials will be required to demonstrate the superiority of these new therapies over standard medical therapy. Demonstrating the safety and efficacy of these transcatheter therapies would cause a major paradigm shift in the management of a large number of patients with severe functional TR. Before this data is available these interventions should be limited to patients with an extreme or prohibitive surgical risk.

References

1. Stuge O, Liddicoat J, Board HCA, et al. Emerging opportunities for cardiac surgeons within structural heart disease. *J Thorac Cardiovasc Surg.* 2006;132:1258–61.
2. Rogers JH, Bolling SF. The tricuspid valve. Current perspective and evolving management of tricuspid regurgitation. *Circulation.* 2009;119:2718–25.
3. Frater R. Tricuspid insufficiency. *J Thorac Cardiovasc Surg.* 2001;122:427–9.
4. Dreyfus GD, Martin RP, Chan KMJ, Dulguerov F, Alexandrescu C. Functional tricuspid regurgitation. *J Am Coll Cardiol.* 2015;65:2331–6.
5. Taramasso M, Vanermen H, Maisano F, Guidotti A, La Canna G, Alfieri O. The growing clinical importance of secondary tricuspid regurgitation. *J Am Coll Cardiol.* 2012;59:703–10.
6. Lancellotti P, Magne J. Tricuspid valve regurgitation in patients with heart failure: does it matter? *Eur Heart J.* 2013;34:799–801.

7. Galiè N, Humbert M, Vachiery J-L, et al. ESC/ERS Guidelines for the diagnosis and treatment of pulmonary hypertension. *Eur Heart J*. 2015;37:67–119.
8. Nath J, Foster E, Heidenreich PA. Impact of tricuspid regurgitation on long-term survival. *J Am Coll Cardiol*. 2004;43:405–9.
9. Topilsky Y, Nkomo VT, Vatury O, et al. Clinical outcome of isolated tricuspid regurgitation. *JACC Cardiovasc Imaging*. 2014;7:1185–94.
10. Varadarajan P, Pai RG. Tricuspid regurgitation in patients with severe mitral regurgitation and normal left ventricular ejection fraction: risk factors and prognostic implications in a cohort of 895 patients. *J Heart Valve Dis*. 2010;19:412–9.
11. Dreyfus GD, Corbi PJ, Chan KMJ, Bahrami T. Secondary tricuspid regurgitation or dilatation: which should be the criteria for surgical repair? *Ann Thorac Surg*. 2005;79:127–32.
12. Vassileva CM, Shabosky J, Boley T, Markwell S, Hazelrigg S. Tricuspid valve surgery: the past 10 years from the Nationwide Inpatient Sample (NIS) database. *J Thorac Cardiovasc Surg*. 2012;143:1043–9.
13. Kim JB, Jung S-H, Choo SJ, Chung CH, Lee JW. Clinical and echocardiographic outcomes after surgery for severe isolated tricuspid regurgitation. *J Thorac Cardiovasc Surg*. 2013;146:278–84.
14. Kim Y-J, Kwon D-A, Kim H-K, et al. Determinants of surgical outcome in patients with isolated tricuspid regurgitation. *Circulation*. 2009;120:1672–8.
15. Kwon D-A, Park J-S, Chang H-J, et al. Prediction of outcome in patients undergoing surgery for severe tricuspid regurgitation following mitral valve surgery and role of tricuspid annular systolic velocity. *Am J Cardiol*. 2006;98:659–61.
16. Vahanian A, Alfieri O, Andreotti F, et al. Guidelines on the management of valvular heart disease (version 2012): The Joint Task Force on the Management of Valvular Heart Disease of the European Society of Cardiology (ESC) and the European Association for Cardio-Thoracic Surgery (EACTS). *Eur J Cardio-Thoracic Surg*. 2012;42:S1–S44.
17. Nishimura RA, Otto CM, Bonow RO, et al. AHA/ACC Guideline for the management of patients with valvular heart disease. *J Am Coll Cardiol*. 2014;63:e57–e185.
18. Tang GHL, David TE, Singh SK, Maganti MD, Armstrong S, Borger MA. Tricuspid valve repair with an annuloplasty ring results in improved long-term outcomes. *Circulation*. 2006;114:I-577–81.
19. Kim JB, Spevack DM, Tunick PA, et al. The effect of transvenous pacemaker and implantable cardioverter defibrillator lead placement on tricuspid valve function: an observational study. *J Am Soc Echocardiogr*. 2008;21:284–7.
20. ZOGHBI W, Enriquez-Sarano M, Foster E, et al. Recommendations for evaluation of the severity of native valvular regurgitation with two-dimensional and doppler echocardiography. *J Am Soc Echocardiogr*. 2003;16:777–802.
21. Lancellotti P, Moura L, Pierard LA, et al. European Association of Echocardiography recommendations for the assessment of valvular regurgitation. Part 2: Mitral and tricuspid regurgitation (native valve disease). *Eur J Echocardiogr*. 2010;11:307–32.
22. Tribouilloy CM, Enriquez-Sarano M, Capps MA, Bailey KR, Tajik AJ. Contrasting effect of similar effective regurgitant orifice area in mitral and tricuspid regurgitation: a quantitative Doppler echocardiographic study. *J Am Soc Echocardiogr*. 2002;15:958–65.
23. de Agustin JA, Viliani D, Vieira C, et al. Proximal isovelocity surface area by single-beat three-dimensional color doppler echocardiography applied for tricuspid regurgitation quantification. *J Am Soc Echocardiogr*. 2013;26:1063–72.
24. Stankovic I, Daraban AM, Jasaityte R, Neskovic AN, Claus P, Voigt J-U. Incremental value of the en face view of the tricuspid valve by two-dimensional and three-dimensional echocardiography for accurate identification of tricuspid valve leaflets. *J Am Soc Echocardiogr*. 2014;27:376–84.
25. Velayudhan DE, Brown TM, Nanda NC, et al. Quantification of tricuspid regurgitation by live three-dimensional transthoracic echocardiographic measurements of vena contracta area. *Echocardiography*. 2006;23:793–800.

26. Hahn RT, Abraham T, Adams MS, et al. Guidelines for performing a comprehensive transesophageal echocardiographic examination: recommendations from the American Society of Echocardiography and the Society of Cardiovascular Anesthesiologists. *J Am Soc Echocardiogr.* 2013;26:921–64.
27. Lang RM, Badano LP, Tsang W, et al. EAE/ASE recommendations for image acquisition and display using three-dimensional echocardiography. *Eur Heart J Cardiovasc Imaging.* 2012;13:1–46.
28. Lauten A, Doenst T, Hamadanchi A, Franz M, Figulla HR. Percutaneous bicaval valve implantation for transcatheter treatment of tricuspid regurgitation: clinical observations and 12-month follow-up. *Circ Cardiovasc Interv.* 2014;7:268–72.
29. Lauten A, Ferrari M, Hekmat K, et al. Heterotopic transcatheter tricuspid valve implantation: first-in-man application of a novel approach to tricuspid regurgitation. *Eur Heart J.* 2011;32:1207–13.
30. Lauten A, Laube A, Schubert H, et al. Transcatheter treatment of tricuspid regurgitation by caval valve implantation-experimental evaluation of decellularized tissue valves in central venous position. *Catheter Cardiovasc Interv.* 2015;85:150–60.
31. Laule ME. Caval Sapien valve implants for tricuspid regurgitation. Paper presented at: Transcatheter valve therapies 2015; June 5, 2015; Chicago, IL.
32. ClinicalTrials.gov Identifier: NCT02387697. Treatment of Severe Secondary TRicuspid Regurgitation in Patients With Advance Heart Failure With CAval Vein Implantation of the Edwards Sapien XT VALve (TRICAVAL). Charite University, Berlin, Germany.
33. ClinicalTrials.gov Identifier:NCT02339974. Heterotopic Implantation Of the Edwards-Sapien XT Transcatheter Valve in the Inferior VEna Cava for the Treatment of Severe Tricuspid Regurgitation (HOVER). Temple University, Philadelphia, PA.
34. Campelo-Parada F, Perlman G, Philippon F, et al. First-in-man experience of a novel transcatheter repair system for treating severe tricuspid regurgitation. *J Am Coll Cardiol.* 2015;66:2475–83.
35. ClinicalTrials.gov Identifier:NCT02471807. Early Feasibility Study of the Edwards FORMA Tricuspid Transcatheter Repair System.
36. Schofer J, Tiburtius C, Hammerstingl C, et al. Transfemoral tricuspid valve repair using a percutaneous mitral valve repair system. *J Am Coll Cardiol.* 2016;67:889–90.
37. Hammerstingl C, Schueler R, Malasa M, Werner N, Nickenig G. Transcatheter treatment of severe tricuspid regurgitation with the MitraClip system. *Eur Heart J.* 2016;37:849–53.
38. Georg Nickenig et al. Transcatheter treatment of tricuspid regurgitation with the edge-to-edge MitraClip technique. *Submitt. Publ.*
39. Kay JH, Maselli-Campagna G, Tsuji KK. Surgical treatment of tricuspid insufficiency. *Ann Surg.* 1965;162:53–8.
40. Schofer J, Bijuklic K, Tiburtius C, Hansen L, Groothuis A, Hahn RT. First-in-human transcatheter tricuspid valve repair in a patient with severely regurgitant tricuspid valve. *J Am Coll Cardiol.* 2015;65:1190–5.
41. ClinicalTrials.gov Identifier:NCT02574650. Early Feasibility of the Mitralign Percutaneous Tricuspid Valve Annuloplasty System (PTVAS) Also Known as TriAlign™. (SCOUT). Presented by R. Hahn at TCT 2016.
42. Yzeiraj E, Sievert H, Nickenig G, Latib A, Hahn R, Schofer J. TCT-86 Early experience with the trialign system for transcatheter tricuspid valve repair: a multicenter experience. *J Am Coll Cardiol.* 2016;68:B35.
43. Latib A, Agricola E, Pozzoli A, et al. First-in-man implantation of a tricuspid annular remodeling device for functional tricuspid regurgitation. *JACC Cardiovasc Interv.* 2015;8:e211–4.
44. ClinicalTrials.gov Identifier:NCT02098200. Percutaneous Treatment of Tricuspid Valve Regurgitation With the TriCinch System™ (PREVENT).
45. Tchetché D, Denti P, Juliard JM, Latib A, Maisano F. TCT-88 Innovative transcatheter tricuspid valve repair system. Initial outcomes from the first in Human Multi-Centre Study. *J Am Coll Cardiol.* 2016;68:B36.

46. Maisano F. Presented at TCT 2016, Washington DC, United States.
47. Rogers T, Ratnayaka K, Sonmez M, et al. Transatrial intrapericardial tricuspid annuloplasty. *JACC Cardiovasc Interv.* 2015;8:483–91.
48. Boudjemline Y, Agnoletti G, Bonnet D, et al. Steps toward the percutaneous replacement of atrioventricular valves. *J Am Coll Cardiol.* 2005;46:360–5.

Chapter 16

Tricuspid Valve Disease: Surgical Outcome

Kevin M. Veen, Jonathan R.G. Etnel, and Johanna J.M. Takkenberg

Abstract Outcomes after tricuspid valve surgery were initially extremely poor but have improved over time thanks to innovations in diagnostics, guidelines for treatment, emerging surgical experience and technical advances. This chapter provides a contemporary overview of patient and procedural characteristics of tricuspid valve repair and replacement and early and late outcomes in different settings, such as functional tricuspid regurgitation, rheumatic, congenital, carcinoid tricuspid valve disease, iatrogenic tricuspid valve damage, and finally endocarditis of the tricuspid valve. For this purpose a systematic literature review and meta-analysis was conducted including 132 studies published after 2005 and reporting on outcome after tricuspid valve surgery. This thorough review of reported experience with tricuspid valve repair and replacement reveals a strong variation in patient presentation and outcome among the various indications and highlights that tricuspid valve replacement is still associated with high early and late mortality. Innovations in the treatment of tricuspid valve disease are direly needed to improve outcome in this complicated patient population.

Keywords Tricuspid valve surgery • Tricuspid valve replacement • Tricuspid valve repair • Outcomes • Functional • Congenital • Ebstein's anomaly • Endocarditis • Carcinoid • Iatrogenic • Systematic review • Meta-analysis

Introduction

The first valve ever to be operated on was the aortic valve in 1912, when Theodore Tuffnier attempted to dilate a stenotic aortic valve with his finger [1]. Next in line was the mitral valve; in 1923 Elliot Cutler performed the first successful mitral

K.M. Veen, M.D. • J.R.G. Etnel, M.D. • J.J.M. Takkenberg, M.D., Ph.D. (✉)
Department of Cardiothoracic Surgery, Erasmus University Medical Center,
Rotterdam, The Netherlands
e-mail: j.j.m.takkenberg@erasmusmc.nl

valve repair on a 12-year old girl. Right sided valves were only given attention much later. The first pulmonary valve stenosis was repaired in 1947 [4] and in the 1950s the first tricuspid valvotomy was performed by Dr. Bailey [5]. Subsequently, additional techniques were developed for tricuspid valve repair. Nowadays, most suture annuloplasty techniques are a variation on the Kay technique [2] or the DeVega technique [3]. Rings and bands have also become available for tricuspid valve repair. With the introduction of cardiopulmonary bypass, replacement of the tricuspid valve became an option.

Outcomes after tricuspid valve surgery were initially extremely poor. However, outcomes have improved over time thanks to innovations in diagnostics, guidelines for treatment, emerging surgical experience and technical advances. Nevertheless, nowadays tricuspid valve surgery is still associated with considerable early and late mortality, in particular when valve replacement is needed.

This chapter aims to provide an overview of contemporary outcomes after tricuspid valve surgery in different settings. Given the heterogeneity in the indications for tricuspid valve surgery and their interrelationship with surgical approach (replacement versus repair), first characteristics and outcomes of tricuspid valve repair and tricuspid valve replacement will be discussed separately. Next, reported outcomes after tricuspid valve surgery will be discussed for the following surgical indications: functional tricuspid regurgitation, rheumatic tricuspid valve disease, congenital tricuspid valve disease, carcinoid tricuspid valve disease, iatrogenic tricuspid valve damage, and finally endocarditis of the tricuspid valve.

In order to provide a contemporary overview of outcomes after tricuspid valve surgery we conducted a systematic review and meta-analysis of studies published after 2005. Several databases were searched for publications on outcome after tricuspid valve surgery. The search yielded 6026 abstracts and eventually 132 publications were included. Outcomes were pooled in a random-effects model.

Tricuspid valve Repair and Replacement

One-hundred thirty two publications encompassing a total of 20,559 patients with 82,103 patient-years were included in the meta-analysis [6–137]. Among all patients undergoing tricuspid valve surgery, mean age at the time of surgery is 56.8 years and 60.4% of patients are female. Pooled early mortality (<30 days or in-hospital) is 7.3% (95% CI [6.4–8.3%]). Meta regression shows that prior heart surgery is significantly associated with a higher early mortality, odds ratio of 3.4 (95% CI [1.8–6.1]), $p < 0.001$.

However, this early mortality is lower than the early mortality in the Society of Thoracic Surgeons (STS) database. The STS database, which describes 34,469 operations since 1993 involving the tricuspid valve, reports an early mortality of 10.0% for isolated tricuspid valve surgery and as high as 14.0% for patients undergoing triple valve surgery involving the tricuspid valve [138]. The difference between the STS database and our systematic review of published literature may be due in part to publication bias.

Tricuspid Valve Repair

Tricuspid valve repair is the procedure of choice for surgical treatment of tricuspid valve disease. There are two approaches to repair the tricuspid valve: valvoplasty, where the valve leaflets and chordae are repaired and annuloplasty, where the annulus diameter is reduced and stabilised by either sutures (DeVega and Kay) or a rigid/flexible ring. Since the most prevalent tricuspid valve disease by far is functional tricuspid valve regurgitation [139], in which the valve leaflets and chordae are generally unaffected, annuloplasty is performed more frequently than valvoplasty.

There were 75 publications on tricuspid valve repair [6, 10, 13, 14, 17–26, 28, 29, 32, 33, 36, 37, 39, 41, 42, 46, 47, 49, 52, 54, 56, 58, 59, 64, 66, 70, 72–77, 80–82, 84, 86, 87, 89–91, 95, 97, 98, 100, 101, 105, 107, 109, 110, 112, 115, 117, 118, 121–123, 127, 129, 130, 133, 135, 137, 140–145].

Patient Presentation and Intraoperative Details

Patient characteristics and etiology are presented in Table 16.1. The most prevalent etiology is functional tricuspid disease. In 98.6% of cases, patients present with isolated tricuspid valve regurgitation, in 0.5% of cases with isolated stenosis and in 0.9%

Table 16.1 Preoperative characteristics and etiology of replacement and repair of the tricuspid valve

Characteristic	Replacement	Repair
Number of patients	3,662	13,299
Follow up (years)	4.2 ± 4.3	4.7 ± 4.0
Age (years)	51.0 ± 13.8	58.9 ± 12.4
Male	34%	42%
Previous heart surgery	54%	31%
NYHA I–II	16%	32%
NYHA III–IV	84%	68%
<i>Etiology</i>		
Functional (%)	15.4%	84.9%
Primary disease (%)	84.3%	14.3%
– Congenital ^a	31.3%	51.9%
– Endocarditis ^a	7.3%	4.4%
– Degeneration ^a	7.4%	3.3%
– Rheumatic ^a	34.6%	29.7%
– Carcinoid ^a	13.4%	0.0%
– Iatrogen ^a	1.3%	1.3%
– Degenerated prosthesis ^a	3.9%	0.2%
Unknown (%)	0.3%	0.9%

Presented as “percentage” or “mean ± standard deviation”

^aPercentage of primary disease

with combined stenosis and regurgitation. Four out of 10 patients have a history of hypertension and 6 out of 10 patients have preoperative atrial fibrillation. Mean preoperative systolic pulmonary artery pressure is 50.1 ± 15.4 mm Hg. Isolated annuloplasty is performed in 96% of patients, isolated valvoplasty in 2% and a further 2% of patients undergo combined annuloplasty and valvoplasty. Of all patients undergoing annuloplasty, suture annuloplasty is performed in 3 out of 10 patients and ring annuloplasty in 7 out of 10 patients. Nearly all patients (97%) undergo concomitant procedures. Mitral valve procedures were performed in 88%, aortic in 19% and pulmonary valve procedures in 0.1%. CABG and maze procedures were performed in 16% and 20%, respectively.

Outcomes

Pooled early mortality is 4.4% (95% CI [3.6–5.3%]). Late outcomes are shown in Table 16.2. Late mortality is substantial and nearly half of all deaths are cardiac.

Low cardiac output syndrome occurs in 9.3% (95% CI[6.6%–13.2%]) of cases and the risk of early (<30 days) pacemaker implantation is 3.4% (95% CI[2.4–4.8%]). An early reintervention is necessary in 1 out of 100 patients.

Late pacemaker implantation rate is 0.8%/year (95% CI[0.5%/–1.2%/year]). Late reintervention rate is relatively low (0.6%/year). Pooled estimate shows that late endocarditis of the repaired tricuspid valve is rare (0.2%/year).

Tricuspid Valve Replacement

Tricuspid valve replacement is generally reserved for cases in which tricuspid valve repair is not technically feasible or when a tricuspid repair fails. The systematic review included 37 publications, 12 on mechanical and 15 on bioprosthetic valve replacement and 13 mixed. [9, 13, 16, 27, 30, 35, 40, 42, 48, 50, 55, 60–62, 67, 69, 79, 81, 88, 92, 94, 96–98, 100, 102, 103, 108, 111, 119, 128, 131, 132, 134, 135, 146–148].

Table 16.2 Late outcomes of tricuspid valve repair

Outcome	LOR	95% CI
Late mortality	2.6%/year	2.1–3.4
Late cardiac mortality	1.1%/year	0.8–1.7
Late valve-related mortality	0.6%/year	0.4–1.0
Reintervention	0.6%/year	0.2–0.4

LOR linearized occurrence rate, CI confidence interval

Patient Presentation and Intraoperative Details

Patient characteristics and etiology are shown in Table 16.1. Notably, more than half of the patients has undergone previous heart surgery. Primary tricuspid valve disease is the most common etiology. Isolated tricuspid valve regurgitation is present in 85.7%, isolated stenosis in 4.5% of patients, and 9.8% of patients present with combined stenosis and regurgitation. Ascites prior surgery is present in almost a quarter of patients at the time of surgery. Atrial fibrillation is present in approximately half of the patients. Mean pooled systolic pulmonary artery pressure is 47.1 ± 14.4 mm Hg. Approximately half of patients undergo at least one concomitant procedure, mostly mitral valve (36%), aortic valve (23%) and/or pulmonary valve (13%) procedures.

A bioprosthesis is implanted in 72% of patients and a mechanical prosthesis in 28%. None of the patients received an allograft. Patients receiving a bioprosthesis are generally younger (41.6 ± 16.2 years) compared with patients receiving a mechanical prosthesis (49.6 ± 13.1 years). This can be explained by the fact that patients receiving a bioprosthesis are diagnosed with congenital tricuspid disease more frequently than those receiving a mechanical prosthesis (72.5% vs. 22.2%). In the bioprostheses group 59.3% were female versus 76.7% in the mechanical group. Patients receiving a mechanical prosthesis underwent prior heart surgery more frequently compared with patients receiving a bioprosthesis (72.9 vs. 35.3%).

Outcome

Pooled early mortality risk is 14.5% (95% CI [11.9–17.3%]). This risk is markedly higher than in mitral and aortic valve replacement [149, 150]. The high early mortality may be explained in part by the poor preoperative state of patients, characterized by a high prevalence of ascites and poor functional status (NYHA class III-IV). Early mortality has declined significantly in more recent years of surgery (odds ratio/10 years [0.73 (95% CI: 0.57–0.93)]).

Low cardiac output syndrome occurred in 22.2% (95% CI [15.7–31.3%]) of patients. Early pacemaker implantation risk is 11.0% (95% CI [7.7–15.6%]) and late pacemaker implantation rate is 1.2%/year (95% CI [0.5–2.9%]). This can partly be explained by the close proximity of the atrioventricular conduction system to the tricuspid valve annulus. As a result, tricuspid valve replacement can cause a total atrioventricular block.

Table 16.3 Late outcomes after tricuspid valve replacement stratified by prosthesis type

Outcome	LOR Overall (95% CI)	LOR Bioprosthesis (95% CI)	LOR Mechanical prosthesis (95% CI)
Number of publications	37	15	13
Late mortality	3.9%/year (3.1–4.8)	2.8%/year (1.7–4.7)	3.1%/year (1.9–5.1)
Cardiac death	1.7%/year (1.3–2.4)	1.1%/year (0.5–2.3)	1.0%/year (0.5–2.3)
Valve-related mortality	0.3%/year (0.2–0.6)	0.3%/year (0.1–0.9)	0.2%/year (0.0–0.9)
Reintervention	1.1%/year (0.8–1.5)	1.2%/year (0.7–2.0)	0.9%/year (0.5–1.6)
Thromboembolism	0.4%/year (0.2–0.7)	0.3%/year (0.1–0.7)	0.6%/year (0.2–1.6)
Bleeding	1.2%/year (0.8–1.7)	0.6%/year (0.4–1.1)	2.2%/year (1.2–4.2)
SVD	0.9%/year (0.6–1.3)	1.1%/year (0.6–2.0)	0.2%/year (0.1–0.6)
NSVD	0.2%/year (0.1–0.4)	0.2%/year (0.1–0.4)	0.3%/year (0.1–1.0)
Valve thrombosis	0.9%/year (0.6–1.3)	0.2%/year (0.1–0.7)	1.8%/year (1.1–3.0)
Endocarditis	0.2%/year (0.1–0.4)	0.2%/year (0.1–0.5)	0.4%/year (0.1–1.2)

LOR linearized occurrence rate, CI confidence interval, SVD structural valve deterioration, NSVD non-structural valve deterioration

Late outcomes are presented in Table 16.3. Late mortality is substantial and the majority is cardiac. However, valve-related death is relatively low. Reintervention rate is 1.1%/year. Endocarditis of the tricuspid valve is also occurs rarely.

Outcomes of Bioprosthesis vs. Mechanical Prosthesis

Pooled early mortality for bioprosthesis is 14.0% (95% CI [9.2–21.4%]) and 14.1% (95% CI [9.0–21.0%]) for mechanical prosthesis. However, the substantial preoperative differences between patients receiving a bioprosthesis and those receiving a mechanical prosthesis preclude direct comparison of outcome between these prostheses.

Late outcomes are presented in Table 16.3. Bioprostheses are characterized by a high rate of SVD and subsequent reintervention and low, but not absent, rates of NSVD and valve thrombosis. On the contrary, mechanical prostheses are exceptionally durable in design, but require lifelong anticoagulation due to their thrombogenicity. This is reflected in the high rates of bleeding and valve thrombosis, but low rates of SVD. In conclusion, anticoagulation-related events remain an important limitation of mechanical valves. Most importantly, the lower risk of SVD compared to bioprostheses does not translate to a considerably lower risk of reintervention. This is due to the higher incidence of other indications for reintervention, in particular valve thrombosis. Thus, although valve thrombosis may often be successfully treated with thrombolytics, as evidenced by the low reintervention and valve-related mortality rates relative to the higher valve thrombosis rate, valve thrombosis still gives rise to a substantial reintervention risk in patients with a mechanical valve, which largely negates the advantage of the increased durability compared to bioprostheses.

Functional Tricuspid Regurgitation

Secondary tricuspid regurgitation, more commonly known as functional tricuspid regurgitation, is the most prevalent form of tricuspid valve disease [139]. Functional tricuspid regurgitation is defined as regurgitation with apparently normal leaflets and chords due to annular dilation of the tricuspid valve, mostly due to left sided valve disease [151]. Sometimes tethering is also present [152]. Functional tricuspid regurgitation (functional TR) has been found to be an independent risk factor for long term mortality [153]. Therefore, it has become common practice to repair the tricuspid valve during mitral valve surgery when deemed necessary. Among 46,500 mitral valve operations in the USA between 2011 and 2014, 4% of patients with no or mild TR underwent concomitant tricuspid valve repair, 35% of patients with moderate TR and 79% of patients with severe TR [154]. The systematic review for functional tricuspid disease encompassed 52 publications [7, 8, 10, 14, 18, 19, 22, 23, 28, 33, 34, 39, 45, 52, 54, 56, 63, 64, 66, 70–77, 80, 82, 84, 86, 90, 91, 93, 95, 105, 107, 112, 114, 115, 117, 121–123, 127, 129, 155–158].

Patient Presentation and Intraoperative Details

Characteristics are shown in Table 16.4. Notably, 6 out of 10 patients present with atrial fibrillation, probably due to the large proportion of patients with concomitant mitral valve disease. Only 79% of patients actually present with moderate or greater tricuspid regurgitation. This is due to the fact that current guidelines recommend tricuspid valve surgery if there is tricuspid annular dilatation of >40 mm, even when there is less than moderate tricuspid regurgitation, because this can help in prevent progressive regurgitation [159]. None of the patients presents with tricuspid stenosis. Intraoperative characteristics are presented in Table 16.5. The tricuspid valve is repaired in the vast majority of patients (99%), whereas replacement is performed rarely. Nearly all patients undergo concomitant surgery, usually a mitral valve

Table 16.4 Pooled characteristics of functional TR, rheumatic tricuspid valve disease and congenital tricuspid valve disease

Characteristic	Functional	Rheumatic	Congenital
Number of patients	10,558	1,808	1,555
Follow up (years)	3.7 ± 2.4	10.4 ± 7.4	5.8 ± 5.0
Age (years)	62.8 ± 11.8	45.3 ± 12.1	21.6 ± 15.8
Male	46%	23%	51%
Previous heart surgery	29%	23%	25%
NYHA I–II	35%	15%	37%
NYHA III–IV	65%	85%	63%

NYHA New York heart association

Table 16.5 Pooled intraoperative characteristics of functional TR, rheumatic tricuspid valve disease and congenital tricuspid valve disease

Intraoperative	Functional	Rheumatic	Congenital
Repair (%)	99%	88%	70%
Replacement (%)	1%	12%	30%
Concomitant procedure (%) ^a	98%	98%	88%
–MV procedure ^b	91.3%	97.3%	1.5%
–AV procedures ^b	18.4%	74.8%	0.0%
–PV procedures ^b	0.4%	0.0%	4.4%
–Maze ^b	22.3%	0.0%	10.1%
–CABG ^b	19.3%	0.5%	0.8%
–ASD/VSD closure ^b	1.7%	0.0%	69.8%

^aPercentage of patients that underwent at least 1 concomitant procedure

^bPercentage of patients that underwent that specific concomitant procedure (non-exclusive groups due multiple concomitant procedures in some patients). *MV* mitral valve, *AV* aortic valve, *PV* pulmonary valve, *CABG* coronary artery bypass graft, *ASD* atrial septal defect, *VSD* ventricular septal defect

Table 16.6 Late outcome after surgery for functional tricuspid valve disease

Outcome	LOR	95% CI
Late mortality	2.7%/year	2.1–3.4
Late cardiac mortality	1.1%/year	0.8–1.7
Late valve-related mortality	0.6%/year	0.4–1.0
Reintervention	0.3%/year	0.2–0.4

LOR linearized occurrence rate, *CI* confidence interval

operation. Some patients undergo multiple concomitant procedures, with a mean of 1.6 procedures per patient. Pulmonary valve procedures and tricuspid valve surgery for functional disease are rarely performed concomitantly.

Outcome

Early mortality is 3.6% (95% CI [2.9–4.5%]). The STS database describes a cohort of 21,056 double mitral and tricuspid valve procedures. For tricuspid valve repair concomitant with mitral valve replacement and repair, respectively, they report an operative mortality of 10.3% and 8.0%. The discrepancy between present meta-analysis and this study may be explained in part by the large proportion of non-elective surgeries in the STS cohort (31% and 29%), whereas only 5.8% of surgeries in this meta-analysis were non-elective [160]. Also, the STS database includes all etiologies. Late outcomes are presented in Table 16.6. Tricuspid valve surgery for functional disease is associated with high late mortality, with a vast majority being cardiac.

Pacemaker implantation is a common complication after tricuspid valve surgery for functional tricuspid regurgitation, as evidenced by the pooled estimate of early pacemaker implantation risk in the systematic review of 3.6% (95% CI [2.5–5.3%]) and a late pacemaker implantation hazard rate of 0.7%/year (95% CI [0.3–1.3%]).

Reintervention rate is low, only 0.3%/year. The reintervention rate alone suggests that surgery for functional tricuspid disease is associated with exceptional durability. However, taking hemodynamic dysfunction into account besides reintervention, paints a different picture. Overall hazard of valve dysfunction, defined as recurrent tricuspid regurgitation graded as moderate or severe or the necessity for an reintervention is 2.2%/year, which indicates a suboptimal result after tricuspid valve surgery for functional disease.

Little is known about outcomes related to replacement of the tricuspid valve for functional TR, but Huang et al. described patients who received a tricuspid valve replacement for functional TR and reported a valve thrombosis rate of 0.2%/year and structural valve deterioration (SVD) and non-structural valve deterioration (NSVD) each occurred at a rate of 0.2%/year [19].

In summary, surgery for functional tricuspid regurgitation is associated with acceptable early mortality and late outcomes are characterized by a considerable occurrence of valve dysfunction, with a low rate of subsequent reintervention.

Rheumatic Tricuspid Valve Disease

The prevalence of rheumatic heart disease has declined rapidly in industrialized and developed countries [161]. However, in third world countries the prevalence of rheumatic heart disease and subsequently the prevalence of rheumatic tricuspid valve disease remains high [162]. The systematic search of the literature resulted in seven publications [27, 31, 49, 99, 104, 144, 146], most of which originate from developing countries.

Patient Presentation and Intraoperative Details

Patient characteristics are presented in Table 16.4. In the included studies 77% is female. This is remarkable because no distinct gender difference in the incidence of rheumatic valve disease has been described in prior epidemiologic studies [162, 163]. Patients present in 84.6% of cases with isolated regurgitation, 8.6% with isolated stenosis and 6.8% with combined stenosis and regurgitation. Intraoperative details are presented in Table 16.5. When the valve is replaced, bioprostheses are used (60%) more frequently than mechanical prostheses (40%). Nearly all patients undergo concomitant surgery. Both mitral valve surgery and aortic valve surgery are performed frequently. Hence, most patients undergo triple valve surgery. The pulmonary valve is not operated on in this group of patients.

Table 16.7 Late outcomes after surgery for rheumatic tricuspid valve disease

Outcome	LOR	95% CI
Late mortality	3.2%/year	2.4–4.1
Late cardiac mortality	2.5%/year	2.0–3.4
Late valve-related mortality	0.9%/year	0.6–1.5
Reintervention	0.8%/year	0.6–1.2
Bleeding	1.2%/year	0.8–1.5
<i>Replacement</i>		
SVD ^a	0.4%/year	0.2–0.6
NSVD ^a	0.2%/year	0.1–0.5
Valve thrombosis ^a	0.2%/year	0.1–0.5

LOR linearized occurrence rate, CI confidence interval.

^aOutcomes only relate to valve replacement

Outcomes

Pooled early mortality of rheumatic tricuspid valve disease is 7.4% (95% CI [5.5–10.1%]). Late outcomes are presented in Table 16.7. Late mortality is excessive, with most patients dying from cardiac causes. Almost a third of cardiac deaths are valve-related.

Of the patients that undergo valve replacement, 40% received a mechanical prosthesis, which requires lifelong anticoagulation. Additionally, a proportion of patients in which the tricuspid valve is repaired, may have undergone concomitant mechanical mitral and/or aortic valve replacement, which may explain the high rate of bleeding in these patients.

In summary, surgery for rheumatic tricuspid valve disease is associated with high early and late mortality and late complications is characterized by bleeding.

Congenital Tricuspid Valve Disease

Congenital defects of the tricuspid valve are rare when compared to other congenital heart disease [164]. Generally, three entities of congenital tricuspid valve disease are recognized: Ebstein's anomaly, tricuspid valve dysplasia, hypoplasia or cleft and double orifice tricuspid valve [154]. The latter two are extremely rare and only a few cases have been reported to date [165, 166]. Ebstein's anomaly is more prevalent with an incidence of 1 in 20,000 live births in the general population [167]. The systematic search of the literature resulted in 23 publications [12, 20, 21, 24, 29, 32, 41, 46, 50, 51, 83, 87, 101, 102, 110, 116, 118, 130, 133, 136, 137, 143, 168].

Patient Presentation and Intraoperative Details

Patient characteristics are presented in Table 16.4. Of all patients, 99.4% of patients is diagnosed with Ebstein's anomaly. Patients are generally younger at the time of surgery than those with other etiologies of tricuspid valve disease. Approximately half of the patients is female, which is in line with the general belief that Ebstein's anomaly has no predilection for either gender. 99.9% of patients present with isolated regurgitation and 0.1% of patients present with isolated stenosis. No patients present with combined stenosis and regurgitation. The intraoperative characteristics are presented in Table 16.5. The tricuspid valve is repaired in 7 out of 10 patients and replaced in 3 out of 10 patients. Of replacements in 85% a bioprosthesis is used and in 15% a mechanical prosthesis is used. Atrial and ventricular septal defect closure and other concomitant procedures are frequently performed in patients with Ebstein's anomaly, with a mean of 2.2 procedures per patient.

Outcome

Pooled early mortality of congenital tricuspid disease is 4.0% (95% CI[2.6–6.2%]). Late mortality is low and deaths are mostly cardiac, a substantial proportion of which are valve-related. Late outcomes are presented in Table 16.8.

Early reintervention (<30 days) is relatively frequent in these patients (2.8%), mostly due to early failure of the repair.

Late morbidity is characterized by high rates of SVD after valve replacement, which may be due in part to the frequent use of bioprostheses in this younger population and it has been previously described that younger age is associated with higher rates of SVD [169]. Furthermore, these younger patients with relatively favorable long-term survival are more likely to outlive the implanted prosthesis. Additionally, some repairs of tricuspid valve tend to fail over time. Subsequently, reintervention is frequent in these patients.

Table 16.8 Late outcomes of congenital tricuspid valve disease

Outcome	LOR	95% CI
Late mortality	0.8%/year	0.5–1.4
Late cardiac mortality	0.6%/year	0.4–1.1
Late valve-related mortality	0.4%/year	0.2–0.7
Reintervention	1.4%/year	0.9–2.2
<i>Replacement</i>		
SVD ^a	1.0%/year	0.4–3.0
NSVD ^a	0.2%/year	0.0–1.1
Valve thrombosis ^a	0.4%/year	0.1–1.9

LOR linearized occurrence rate, CI confidence interval.

^aOutcomes only relate to valve replacement.

In summary, congenital tricuspid valve disease is associated with low late mortality, however some patients will eventually face a reoperation.

Carcinoid Disease of the Tricuspid Valve

Carcinoid heart disease may develop in patients with carcinoid syndrome, which is caused by the secretion of a range of vasoactive peptides by hepatic metastases of gastrointestinal carcinoid tumors. Symptoms of carcinoid heart syndrome are diarrhoea, flushing and bronchoconstriction [170].

Bhattachryya and colleagues reported on a series of 22 patients with carcinoid heart disease operated between 2006 and 2010. All tricuspid valves are replaced. In this series, 4 of 22 (18%) patients died within 30 days postoperative and actuarial 2-year survival is $44\% \pm 11.7\%$. During the follow up, one patient developed SVD (LOR 0.5 %/year) of the tricuspid valve but no patient required reintervention. NYHA class improvement with more than one grade is seen in 67% [111].

Another paper presented 195 patients operated between 1985 and 2012. All tricuspid valves are replaced. In this series overall 30-day mortality risk is 10%. After 2000 the 30-day mortality risk declines to 6% (8 deaths of 124 patients). Actuarial 10-year survival is 24%. During follow up, nine reinterventions on the tricuspid valve took place (during the initial intervention eight received a bioprosthesis and one received a mechanical prosthesis). NYHA class improvement is noted in 75% of patients that were in NYHA class III or IV preoperatively [132].

In conclusion, if patients undergo surgery for carcinoid tricuspid valve disease, a valve replacement is generally inevitable and long term prognosis is poor. However, with rapidly improving cancer treatment this may change in the near future.

Iatrogenic Damage of the Tricuspid Valve

The tricuspid valve may be damaged radiation or leads from a pacemaker or cardioverter-defibrillator (ICD). Lin et al. reported on 41 patients with tricuspid valves damaged by pacemaker or ICD leads. In only 5 of 41 (12%) malfunction of the tricuspid valve is diagnosed pre-operatively by echocardiography. The tricuspid valve is replaced in 22 patients. One patient died in the early postoperative period (2.4%). During follow-up (mean 8.2 years) five patients died. Functional status according to the NYHA classification improved in all surviving patients [171].

Endocarditis of the Tricuspid Valve

The incidence of community acquired endocarditis ranges from 1.7 to 6.2 cases per 100,000 person years [172] and approximately 5–10% of overall endocarditis is right sided [173]. Endocarditis vegetations on the tricuspid valve often dislodge and cause

pulmonary embolism. Therefore, in tricuspid valve endocarditis the presenting symptoms are more frequently pulmonary in nature rather than those of congestive heart failure. The majority of patients with right sided endocarditis are intravenous drug users, in whom *Staphylococcus aureus* is the most prevalent pathogen [174]. Among articles in our systematic literature review reporting on mixed etiology cohorts, endocarditis is diagnosed in 7.0% of patients. However, throughout literature only a few studies report on outcomes after tricuspid valve surgery for endocarditis specifically.

The STS database contains 910 tricuspid valve operations for tricuspid valve endocarditis between 2002 and 2009 (median age: 40 years, 50.6% male). Active infective endocarditis (IE) is present in 68.5% of patients. The tricuspid valve is replaced in 54% and repaired in 39% and a valvectomy is performed in 7%. Early mortality is 7.3% with no significant differences between the various surgical techniques employed [175].

Baraki et al. published a series of 33 patients (mean age 49 ± 21 , 68% male) operated on for tricuspid valve IE. Fourteen patients were intravenous drug abusers (of which ten were infected with *Staphylococcus aureus*). Three patients (9%) died within the first 30 days postoperative. During the mean follow-up of 6.0 ± 4.1 years seven patients died (LOR 3.1%/year) of which three died of cardiac causes (LOR 1.1%/year). Actuarial freedom from reoperation at 10 years is 88%.

Take Home Message

This chapter provides a contemporary overview of tricuspid valve surgery in the form of a systematic review and meta-analysis.

Reviewing the outcomes after tricuspid valve surgery it becomes clear that early mortality after tricuspid valve replacement is still poor. Nevertheless, some progress has been made over the years. Bioprosthetic and mechanical tricuspid valve replacement are associated with comparable reintervention rates. Moreover, mechanical prostheses require anticoagulation, which imparts a risk of anticoagulation-related events. Thus, outcomes for bioprostheses appear to be more favorable.

Outcomes after tricuspid valve repair, which is performed predominantly for functional tricuspid regurgitation, are more favorable than after tricuspid valve replacement, which is usually performed for primary tricuspid valve disease in patients in poorer preoperative clinical condition. These differences in indication preclude direct comparison between repair and replacement.

For functional tricuspid disease the valve is almost exclusively repaired and early and late outcomes are acceptable.

In patients diagnosed with rheumatic tricuspid valve disease, the mitral and aortic valve are often affected simultaneously, often resulting in triple valve surgery. Rheumatic valve disease is associated with high late mortality, of which the majority is cardiac.

Almost all patients suffering from congenital tricuspid disease are diagnosed with Ebstein's anomaly. A valve replacement is performed in 3 out of 10 patients. Congenital tricuspid disease is associated with relatively low late mortality, but a substantial reintervention rate.

Future surgical developments have the potential to change tricuspid valve surgery drastically. Percutaneous interventions may provide a promising solution in reducing operative mortality in patients in need of a tricuspid valve intervention. These techniques may prove particularly beneficial in patients requiring reintervention, since operative mortality is substantially higher in these patients [141].

Tissue engineering is another promising development, with the prospect of a durable living heart valve with growth potential, which may be especially useful in young patients with congenital tricuspid valve disease since reinterventions are frequent in these patients, partly due to the patients outgrowing their initial valve prosthesis.

Review Questions

74. What is early mortality for tricuspid valve replacement
 - (a) Comparable to aortic valve replacement
 - (b) Comparable to mitral valve replacement
 - (c) Less than 5%
 - (d) More than 10%
75. In tricuspid valve replacement, what are the advantages and drawbacks of a bioprosthesis compared with a mechanical valve?
 - (a) Less thrombosis, less bleeding and more reinterventions
 - (b) More thrombosis, less bleeding, more reinterventions
 - (c) Less thrombosis, less bleeding, comparable reintervention rates
76. What is the most widely employed technique for the surgical treatment of carcinoid tricuspid valve disease (in current literature)?
 - (a) Tricuspid valvotomy
 - (b) Tricuspid valvoplasty
 - (c) Tricuspid replacement

References

1. Tuffier T. Etat actuel de la chirurgie intrathoracique. *Trans Int Congr Med* 1913; (London 1914). p 2:249.
2. Kay JH, Maselli-Campagna G, Tsuji KK. Surgical treatment of tricuspid insufficiency. *Ann Surg.* 1965;162:53–8.
3. De Vega NG. La anuloplastia selectiva, regulable y permanente. Una técnica original para el tratamiento de la insuficiencia tricuspíde. *Rev Esp Cardiol.* 1972;25:555–6.
4. Cohn LH. The first successful surgical treatment of mitral stenosis: the 70th anniversary of Elliot Cutler's mitral commissurotomy. *Ann Thorac Surg.* 1993;56(5):1187–90.
5. Trace HD, Bailey CP, Wendkos MH. Tricuspid valve commissurotomy with a one-year follow-up. *Am Heart J.* 1954;47(4):613–8.

6. Yeates A, Marwick T, Deva R, Mundy J, Wood A, Griffin R, et al. Does moderate tricuspid regurgitation require attention during mitral valve surgery? *ANZ J Surg.* 2014;84(1):63–7.
7. Pettinari M, Bertrand P, Kerrebroeck CV, Vandervoort P, Gutermann H, Dion R. Mid-term results of leaflet augmentation in severe tricuspid functional tethering. *Eur JCardiothorac Surg.* 2016;50(3):504–8.
8. Koppers G, Verhaert D, Verbrugge FH, Reyskens R, Gutermann H, Kerrebroeck CV, et al. Clinical outcomes after tricuspid valve Annuloplasty in addition to mitral valve surgery. *Congest Heart Fail.* 2013;19(2):70–6.
9. Nooten GJV, Bové T, Bellegheem YV, François K, Caes F, Vandenplas G, et al. Twenty-year single-center experience with the medtronic open pivot mechanical heart valve. *Ann Thorac Surg.* 2014;97(4):1306–13.
10. Meester PD, Cock DD, Bruaene ADV, Gabriels C, Buys R, Helsen F, et al. Additional tricuspid annuloplasty in mitral valve surgery results in better clinical outcome. *Heart.* 2015;101(9):720–6.
11. Hermans H, Tjahjono M, Faes D, Belmans A, Meuris B, Herijgers P, et al. Mid-term follow up of triple valve surgery in a western community: predictors of survival. *J Heart Valve Dis.* 2010;19(5):644–51.
12. da Silva JP, da Silva LF, Moreira LF P, Lopes LM, Franchi SM, Lianza AC, et al. Cone reconstruction in Ebstein's anomaly repair: early and long-term results. *Arq Bras Cardiol.* 2011;97(3):199–208.
13. Marquis Gravel G, Bouchard D, Perrault LP, Pagé P, Jeanmart H, Demers P, et al. Retrospective cohort analysis of 926 tricuspid valve surgeries: clinical and hemodynamic outcomes with propensity score analysis. *Am Heart J.* 2012;163(5):851–858.e1.
14. Chan V, Burwash IG, Lam BK, Auyeung T, Tran A, Mesana TG, et al. Clinical and echocardiographic impact of functional tricuspid regurgitation repair at the time of mitral valve replacement. *Ann Thorac Surg.* 2009;88(4):1209–15.
15. Alsoufi B, Rao V, Borger MA, Maganti M, Armstrong S, Feindel CM, et al. Short- and long-term results of triple valve surgery in the modern era. *Ann Thorac Surg.* 2006;81(6):2172–8.
16. Singh SK, Tang GHL, Maganti MD, Armstrong S, Williams WG, David TE, et al. Midterm outcomes of tricuspid valve repair versus replacement for organic tricuspid disease. *Ann Thorac Surg.* 2006;82(5):1735–41.
17. Tang GHL, David TE, Singh SK, Maganti MD, Armstrong S, Borger MA. Tricuspid valve repair with an annuloplasty ring results in improved long-term outcomes. *Circulation.* 2006;114:I577–I81.
18. Huang X, Gu C, Li B, Li J, Yang J, Wei H, et al. Midterm clinical and echocardiographic results of a modified de vega tricuspid annuloplasty for repair of functional tricuspid regurgitation. *Can J Cardiol.* 2013;29(12):1637–42.
19. Huang X, Gu C, Men X, Zhang J, You B, Zhang H, et al. Repair of functional tricuspid regurgitation: comparison between suture annuloplasty and rings annuloplasty. *Ann Thorac Surg.* 2014;97(4):1286–92.
20. Wu Q, Huang Z, Pan G, Wang L, Li L, Xue H. Early and midterm results in anatomic repair of Ebstein anomaly. *J Thorac Cardiovasc Surg.* 2007;134(6):1438–42.
21. Li X, Wang SM, Schreiber C, Cheng W, Lin K, Sun JY, et al. More than valve repair: effect of cone reconstruction on right ventricular geometry and function in patients with Ebstein anomaly. *Int J Cardiol.* 2016;206:131–7.
22. Ren WJ, Zhang BG, Liu JS, Qian YJ, Guo YQ. Outcomes of tricuspid annuloplasty with and without prosthetic rings: a retrospective follow-up study. *J Cardiothorac Surg.* 2015;10:81.
23. Cao H, Chen Q, Li QZ, Chen LW, Zhang GC, Chen DZ, et al. A clinical study of thoracoscopy-assisted mitral valve replacement concomitant with tricuspid valvuloplasty, with domestically manufactured pipeline products for cardiopulmonary bypass. *J Cardiothorac Surg.* 2014;9:160.
24. Sha JM, Yan ZY, Zhu ZY, Tan L, Zheng L, Shen YH, et al. Early and midterm results of repair of Ebstein's anomaly with autologous pericardium. *Thorac Cardiovasc Surg.* 2011;59(5):287–92.

25. Chen Y, Liu JH, Chan D, Sit KY, Wong CK, Ho KL, et al. Prevalence, prevalence, predictors and clinical outcome of residual pulmonary hypertension following tricuspid annuloplasty. *J Am Heart Assoc.* 2016;5(7):e003353.
26. Wang J, Li Z, Zhu Q, Wu YH, Shao YF, Qin JW, et al. A modified tricuspid valve annuloplasty technique for functional tricuspid regurgitation. *Chin Med J.* 2013;126(18):3534–8.
27. Sun X, Zhang H, Aike B, Yang S, Yang Z, Dong L, et al. Tricuspid annular plane systolic excursion (TAPSE) can predict the outcome of isolated tricuspid valve surgery in patients with previous cardiac surgery? *J Thorac Dis.* 2016;8(3):369–74.
28. Lin Y, Wang Z, He J, Xu Z, Xiao J, Zhang Y, et al. Efficiency of different annuloplasty in treating functional tricuspid regurgitation and risk factors for recurrence. *IJC Heart Vascul.* 2014;5:15–9.
29. Liu J, Qiu L, Zhu Z, Chen H, Hong H. Cone reconstruction of the tricuspid valve in Ebstein anomaly with or without one and a half ventricle repair. *J Thorac Cardiovasc Surg.* 2011;141(5):1178–83.
30. Zhuang Y, Zhou J, Xiao M, Yuan Z, Lu C, Yu M, et al. Clinical results of tricuspid valve replacement—a 21-case report. *J Biomed Res.* 2010;24(1):73–6.
31. Han QQ, Xu ZY, Zhang BR, Zou LJ, Hao JH, Huang SD. Primary triple valve surgery for advanced rheumatic heart disease in mainland China: a single-center experience with 871 clinical cases. *Eur J Cardiothorac Surg.* 2007;31(5):846–51.
32. Liang Y, Liu L, Liu S, Chen Z, You B, He M, et al. Individualized quantified tricuspid valve annuloplasty for treating ebstein anomaly. *J Heart Valve Dis.* 2012;21(4):544–8.
33. He J, Shen Z, Yu Y, Huang H, Ye W, Ding Y, et al. Criteria for determining the need for surgical treatment of tricuspid regurgitation during mitral valve replacement. *J Cardiothorac Surg.* 2012;7:27.
34. Li ZX, Guo ZP, Liu XC, Kong XR, Jing WB, Chen TN, et al. Surgical treatment of tricuspid regurgitation after mitral valve surgery: a retrospective study in China. *J Cardiothorac Surg.* 2012;7:30.
35. Wei X, Yi W, Chen W, Ma X, Lau WB, Wang H, et al. Clinical outcomes with the Epictholorohydrin-modified porcine aortic heart valve: a 15-year follow-up. *Ann Thorac Surg.* 2010;89(5):1417–24.
36. Kunová M, Frána R, Toušek F, Mokráček A, Pešl L. Tricuspid annuloplasty using DeVega modified technique—short-term and medium-term results. *Cor Vasa.* 2016;58(4):e379–83.
37. Šmíd M, Čech J, Rokyta R, Roučka P, Hájek T. Mild to moderate functional tricuspid regurgitation: retrospective comparison of surgical and conservative treatment. *Cardiol Res Pract.* 2010;1(1):143878.
38. Jokinen JJ, Turpeinen AK, Pitkänen O, Hippeläinen MJ, Hartikainen JEK. Pacemaker therapy after tricuspid valve operations: implications on mortality, morbidity, and quality of life. *Ann Thorac Surg.* 2009;87(6):1806–14.
39. Jouan J, Mele A, Florens E, Chatellier G, Carpentier A, Achouh P, et al. Conduction disorders after tricuspid annuloplasty with mitral valve surgery: implications for earlier tricuspid intervention. *J Thorac Cardiovasc Surg.* 2016;151(1):99–103.
40. Anselmi A, Ruggieri VG, Harmouche M, Flécher E, Corbineau H, Langanay T, et al. Appraisal of long-term outcomes of tricuspid valve replacement in the current perspective. *Ann Thorac Surg.* 2016;101(3):863–71.
41. Hetzer R, Hacke P, Javier M, Miera O, Schmitt K, Weng Y, et al. The long-term impact of various techniques for tricuspid repair in Ebstein's anomaly. *J Thorac Cardiovasc Surg.* 2015;150(5):1212–9.
42. Minol JP, Boeken U, Weinreich T, Heimann M, Gramsch-zabel H, Akhyari P, et al. Isolated tricuspid valve surgery: a single institutional experience with the technique of minimally invasive surgery via right Minithoracotomy. *Thorac Cardiovasc Surg.* 2014;0
43. Baraki H, Saito S, Ahmad AA, Fleischer B, Haverich A, Kutschka I. Beating heart versus arrested heart isolated tricuspid valve surgery. *Int Heart J.* 2015;56(4):400–7.
44. Peterss S, Fortmann C, Pichlmaier M, Bagaev E, Shrestha ML, Hagl C, et al. Advanced age: a contraindication for triple-valve surgery? *J Heart Valve Dis.* 2012;21(5):641–9.

45. Pfanmüller B, Doenst T, Eberhardt K, Seeburger J, Borger MA, Mohr FW. Increased risk of dehiscence after tricuspid valve repair with rigid annuloplasty rings. *J Thorac Cardiovasc Surg.* 2012;143(5):1050–5.
46. Lange R, Burri M, Eschenbach LK, Badiu CC, JPd S, Nagdyman N, et al. Da Silva's cone repair for Ebstein's anomaly: effect on right ventricular size and function. *Eur J Cardiothorac Surg.* 2015;48(2):316–21.
47. Guenther T, Mazzitelli D, Noebauer C, Hettich I, Tassani-Prell P, Voss B, et al. Tricuspid valve repair: is ring annuloplasty superior? *Eur J Cardiothorac Surg.* 2013;43(1):58–65.; discussion.
48. Guenther T, Noebauer C, Mazzitelli D, Busch R, Tassani-Prell P, Lange R. Tricuspid valve surgery: a thirty-year assessment of early and late outcome. *Eur J Cardiothorac Surg.* 2008;34(2):402–9.
49. Pande S, Agarwal SK, Majumdar G, Kapoor A, Kale N, Kundu A. Valvuloplasty in the treatment of rheumatic tricuspid disease. *Asian Cardiovasc Thorac Ann.* 2008;16(2):107–11.
50. Prakash S, Agarwal S, Singh AK, Satsangi DK. Bioprosthetic valve replacement in Ebstein's anomaly. *Indian J Thorac Cardiovasc Surg.* 2010;26(3):179–84.
51. Sirivella S, Gielchinsky I. Surgery of the Ebstein's anomaly: early and late outcomes. *J Card Surg.* 2011;26(2):227–33.
52. Benedetto U, Melina G, Angeloni E, Refice S, Roscitano A, Comito C, et al. Prophylactic tricuspid annuloplasty in patients with dilated tricuspid annulus undergoing mitral valve surgery. *J Thorac Cardiovasc Surg.* 2012;143(3):632–8.
53. Davoodi S, Karimi A, Ahmadi SH, Marzban M, Movahhedi N, Abbasi K, et al. Short—and mid-term results of triple-valve surgery with an evaluation of postoperative quality of life. *Tex Heart Inst J.* 2009;36(2):125–30.
54. Roshanali F, Saidi B, Mandegar MH, Yousefnia MA, Alaeddini F. Echocardiographic approach to the decision-making process for tricuspid valve repair. *J Thorac Cardiovasc Surg.* 2010;139(6):1483–7.
55. Leviner DB, Medalion B, Baruch I, Sagie A, Sharoni E, Fuks A, et al. Tricuspid valve replacement: the effect of gender on operative results. *J Heart Valve Dis.* 2014;23(2):209–15.
56. Calafiore AM, Gallina S, Iacò AL, Contini M, Bivona A, Gagliardi M, et al. Mitral valve surgery for functional mitral regurgitation: should moderate-or-more tricuspid regurgitation be treated? A propensity score analysis. *Ann Thorac Surg.* 2009;87(3):698–703.
57. Lio A, Murzi M, Stefano GD, Miceli A, Kallushi E, Ferrarini M, et al. Triple valve surgery in the modern era: short- and long-term results from a single centre. *Interact Cardiovasc Thorac Surg.* 2014;19(6):978–84.
58. Bonis MD, Lapenna E, Taramasso M, Manca M, Calabrese MC, Buzzatti N, et al. Mid-term results of tricuspid annuloplasty with a three-dimensional remodelling ring. *J Card Surg.* 2012;27(3):288–94.
59. Lapenna E, Bonis MD, Verzini A, Canna GL, Ferrara D, Calabrese MC, et al. The clover technique for the treatment of complex tricuspid valve insufficiency: midterm clinical and echocardiographic results in 66 patients. *Eur J Cardiothorac Surg.* 2010;37(6):1297–303.
60. Buzzatti N, Iaci G, Taramasso M, Nisi T, Lapenna E, Bonis MD, et al. Long-term outcomes of tricuspid valve replacement after previous left-side heart surgery. *Eur J Cardiothorac Surg.* 2014;46(4):713–9.
61. Garatti A, Canziani A, Mossuto E, Gagliardotto P, Innocente F, Corain L, et al. Tricuspid valve replacement with mechanical prostheses: long-term results. *J Heart Valve Dis.* 2010;19(2):194–200.
62. Garatti A, Nano G, Bruschi G, Canziani A, Colombo T, Frigiola A, et al. Twenty-five year outcomes of tricuspid valve replacement comparing mechanical and biologic prostheses. *Ann Thorac Surg.* 2012;93(4):1146–53.
63. Giamberti A, Chessa M, Ballotta A, Varrica A, Agnetti A, Frigiola A, et al. Functional tricuspid valve regurgitation in adults with congenital heart disease: an emerging problem. *J Heart Valve Dis.* 2011;20(5):565–70.

64. Gatti G, Dell'Angela L, Morosin M, Maschietto L, Pinamonti B, Forti G, et al. Tricuspid Annuloplasty for tricuspid regurgitation secondary to left-sided heart valve disease: immediate outcomes and risk factors for late failure. *Can J Cardiol.* 2016;32(6):760–6.
65. Ricci D, Boffini M, Barbero C, Qarra SE, Marchetto G, Rinaldi M. Minimally invasive tricuspid valve surgery in patients at high risk. *J Thorac Cardiovasc Surg.* 2014;147(3):996–1001.
66. Izutani H, Nakamura T, Kawachi K. Flexible band versus rigid ring annuloplasty for functional tricuspid regurgitation. *Heart Int.* 2010;5(2):64–8.
67. Tokunaga S, Masuda M, Shioue A, Tomita Y, Morita S, Tominaga R. Long-term results of isolated tricuspid valve replacement. *Asian Cardiovasc Thorac Ann.* 2008;16(1):25–8.
68. Tsuda K, Koide M, Kunii Y, Watanabe K, Miyairi S, Ohashi Y, et al. Simplified model for end-stage liver disease score predicts mortality for tricuspid valve surgery. *Interact Cardiovasc Thorac Surg.* 2013;16(5):630–5.
69. Morimoto N, Matsushima S, Aoki M, Henmi S, Nishioka N, Murakami H, et al. Long-term results of bioprosthetic tricuspid valve replacement: an analysis of 25 years of experience. *Gen Thorac Cardiovasc Surg.* 2013;61(3):133–8.
70. Fukunaga N, Okada Y, Konishi Y, Murashita T, Koyama T. Late outcome of tricuspid annuloplasty using a flexible band/ring for functional tricuspid regurgitation. *Circ J.* 2015;79(6):1299–306.
71. Abbas S, Riaz W, Khan JF, Nassery S, Iqbal M, Waheed A. Amiodarone vs digoxin in the treatment of atrial fibrillation in postoperative rheumatic cardiac valvular patients. *J Pak Med Assoc.* 2016;66(9):1098–101.
72. Murashita T, Okada Y, Kanemitsu H, Fukunaga N, Konishi Y, Nakamura K, et al. Long-term outcomes of tricuspid annuloplasty for functional tricuspid regurgitation associated with degenerative mitral regurgitation: suture annuloplasty versus ring annuloplasty using a flexible band. *Ann Thorac Cardiovasc Surg.* 2014;20(6):1026–33.
73. Ariyoshi T, Hashizume K, Taniguchi S, Miura T, Matsukuma S, Nakaji S, et al. Which type of secondary tricuspid regurgitation accompanying mitral valve disease should be surgically treated? *Ann Thorac Cardiovasc Surg.* 2013;19(6):428–34.
74. Isomura T, Hirota M, Hoshino J, Fukada Y, Kondo T, Takahashi Y. Tricuspid annuloplasty with the MC3 ring and septal plication technique. *Asian Cardiovasc Thorac Ann.* 2015;23(1):5–10.
75. Hata H, Fujita T, Shimahara Y, Sato S, Kobayashi J. Early and mid-term outcomes of aggressive tricuspid annuloplasty with the MC3 ring. *J Heart Valve Dis.* 2014;23(5):601–8.
76. Kawaura H, Aoki A, Omoto T, Maruta K, Iizuka H. Effect of the septal adjustment technique for tricuspid annuloplasty with an MC3 ring. *Gen Thorac Cardiovasc Surg.* 2015;63(5):273–8.
77. Yoda M, Tanabe H, Kadoma Y, Suma H. Mid-term results of tricuspid annuloplasty using the MC3 ring for secondary tricuspid valve regurgitation. *Interact Cardiovasc Thorac Surg.* 2011;13(1):7–10.
78. Sakamoto Y, Hashimoto K, Okuyama H, Ishii S, Inoue T, Kinouchi K. Long-term result of triple-valve procedure. *Asian Cardiovasc Thorac Ann.* 2006;14(1):47–50.
79. Altaani HA, Jaber S. Tricuspid valve replacement, mechanical vs. biological valve, which is better? *Int Cardiovasc Res J.* 2013;7(2):71–4.
80. Pradhan S, Gautam NC, Singh YM, Shakya S, Timala RB, Sharma J, et al. Tricuspid valve repair: De Vega's tricuspid annuloplasty in moderate secondary tricuspid regurgitation. *Kathmandu Univ Med J.* 2011;9(33):64–8.
81. TH O, Wang TK, Sidhu K, Haydock DA. Isolated tricuspid valve surgery at a single centre: the 47-year Auckland experience, 1965–2011. *Interact Cardiovasc Thorac Surg.* 2014;18(1):27–32.
82. Naqshband MS, Abid AR, Akhtar RP, Waheed A, Khan JS. Functional tricuspid regurgitation in rheumatic heart disease: surgical options. *Ann Thorac Cardiovasc Surg.* 2010;16(6):417–25.
83. Bockeria L, Golukhova E, Dadasheva M, Revishvili A, Levant A, Bazaev V, et al. Advantages and disadvantages of one-stage and two-stage surgery for arrhythmias and Ebstein's anomaly. *Eur J Cardiothorac Surg.* 2005;28(4):536–40.

84. Calafiore AM, Iacò AL, Romeo A, Scandura S, Meduri R, Varone E, et al. Echocardiographic-based treatment of functional tricuspid regurgitation. *J Thorac Cardiovasc Surg.* 2011;142(2):308–13.
85. Fadel BM, Alsoufi B, Manlhiot C, McCrindle BW, Sibli G, Al-Halees Z, et al. Determinants of short- and long-term outcomes following triple valve surgery. *J Heart Valve Dis.* 2010;19(4):513–22.
86. Jonjev ŽS, Mijatov M, Fabri M, Popović S, Radovanović ND. Systematic reductive annuloplasty of the mitral and tricuspid valves in patients with end-stage ischemic dilated cardiomyopathy. *J Card Surg.* 2007;22(2):111–6.
87. Im YM, Park CS, Park JJ, Yun TJ. Restoration of tricuspid valve mechanism at the level of displaced Septal and posterior leaflets in Ebstein's anomaly. *J Card Surg.* 2016;31(3):168–73.
88. Cho WC, Park CB, Kim JB, Jung SH, Chung CH, Choo SJ, et al. Mechanical valve replacement versus bioprosthetic valve replacement in the tricuspid valve position. *J Card Surg.* 2013;28(3):212–7.
89. Kim JB, Jung SH, Choo SJ, Chung CH, Lee JW. Surgical outcomes of severe tricuspid regurgitation: predictors of adverse clinical outcomes. *Heart.* 2013;99(3):181–7.
90. Ro SK, Kim JB, Jung SH, Choo SJ, Chung CH, Lee JW. Mild-to-moderate functional tricuspid regurgitation in patients undergoing mitral valve surgery. *J Thorac Cardiovasc Surg.* 2013;146(5):1092–7.
91. Lee H, Sung K, Kim WS, Lee YT, Park SJ, Carriere KC, et al. Clinical and hemodynamic influences of prophylactic tricuspid annuloplasty in mechanical mitral valve replacement. *J Thorac Cardiovasc Surg.* 2016;151(3):788–95.
92. Sung K, Park PW, Park KH, Jun TG, Lee YT, Yang JH, et al. Is tricuspid valve replacement a catastrophic operation? *Eur J Cardiothorac Surg.* 2009;36(5):825–9.
93. Jeong DS, Kim KH. Tricuspid annuloplasty using the MC3 ring for functional tricuspid regurgitation. *Circ J.* 2010;74(2):278–83.
94. Hwang HY, Kim KH, Kim KB, Ahn H. Propensity score matching analysis of mechanical versus bioprosthetic tricuspid valve replacements. *Ann Thorac Surg.* 2014;97(4):1294–9.
95. Chang BC, Song SW, Lee S, Yoo KJ, Kang MS, Chung N. Eight-year outcomes of tricuspid Annuloplasty using autologous pericardial strip for functional tricuspid regurgitation. *Ann Thorac Surg.* 2008;86(5):1485–93.
96. Chang BC, Lim SH, Yi G, Hong YS, Lee S, Yoo KJ, et al. Long-term clinical results of tricuspid valve replacement. *Ann Thorac Surg.* 2006;81(4):1317–24.
97. Mestres CA, Fita G, Parra VM, Pomar JL, Bernal JM. Tricuspid valve surgery. *HSR Proc Intensive Care Cardiovasc Anesth.* 2012;4(4):261–7.
98. Rodriguez-Capitan J, Gomez-Doblas JJ, Fernandez-Lopez L, Lopez-Salguero R, Ruiz M, Leruite I, et al. Short- and long-term outcomes of surgery for severe tricuspid regurgitation. *Rev Esp Cardiol (Engl).* 2013;66(8):629–35.
99. Bernal JM, Pontón A, Diaz B, Llorca J, García I, Sarralde A, et al. Surgery for rheumatic tricuspid valve disease: a 30-year experience. *J Thorac Cardiovasc Surg.* 2008;136(2):476–81.
100. Chen SW, Tsai FC, Tsai FC, Chao YK, Huang YK, Chu JJ, et al. Surgical risk and outcome of repair versus replacement for late tricuspid regurgitation in redo operation. *Ann Thorac Surg.* 2012;93(3):770–5.
101. Palmen M, PLd J, Klieverik LMA, Venema AC, Meijboom FJ, Bogers AJJC. Long-term follow-up after repair of Ebstein's anomaly. *Eur J Cardiothorac Surg.* 2008;34(1):48–54.
102. YJv S, Freling HG, JpV M, Mulder BJ, Jongbloed MR, Ebels T, et al. Long-term tricuspid valve prosthesis-related complications in patients with congenital heart disease. *Eur J Cardiothorac Surg.* 2014;45(1):83–9.
103. Songur CM, Simsek E, Ozen A, Kocabeyoglu S, Donmez TA. Long term results comparing mechanical and biological prostheses in the tricuspid valve position which valve types are better—mechanical or biological prostheses? *Heart Lung Circul.* 2014;23(12):1175–8.

104. Akay TH, Gultekin B, Ozkan S, Aslim E, Saritas B, Sezgin A, et al. Triple-valve procedures: impact of risk factors on midterm in a rheumatic population. *Ann Thorac Surg.* 2006;82(5):1729–34.
105. Goncu T, Alur I, Gucu A, Tenekecioglu E, Toktas F, Kahraman N, et al. Clinical and echocardiographic results of the Kalangos biodegradable tricuspid ring for moderate and severe functional tricuspid regurgitation treatment. *Int J Clin Exp Med.* 2015;8(2):2839–45.
106. Aykut K, Celik B, Acikel U. The transseptal approach to the mitral valve during multivalvular surgery. *J Card Surg.* 2011;26(5):472–4.
107. Kara I, Koksali C, Cakalagaoglu C, Sahin M, Yanartas M, Ay Y, et al. Recurrent tricuspid insufficiency: is the surgical repair technique a risk factor? *Tex Heart Inst J.* 2013;40(1):34–41.
108. Civelek A, Ak K, Akgün S, Isbir SC, Arsan S. Tricuspid valve replacement: an analysis of risk factors and outcomes. *Thorac Cardiovasc Surg.* 2008;56(8):456–60.
109. Nurozler F, Kutlu TT, Kucuk G. Association of edge-to-edge repair to de Vega annuloplasty for tricuspid incompetence. *Scand Cardiovasc J.* 2007;41(3):192–6.
110. Ibrahim M, Tsang VT, Caruana M, Hughes ML, Jenkyns S, Perdreau E, et al. Cone reconstruction for Ebstein's anomaly: patient outcomes, biventricular function, and cardiopulmonary exercise capacity. *J Thorac Cardiovasc Surg.* 2015;149(4):1144–50.
111. Bhattacharyya S, Raja SG, Toumpanakis C, Caplin ME, Dreyfus GD, Davar J. Outcomes, risks and complications of cardiac surgery for carcinoid heart disease. *Eur J Cardiothorac Surg.* 2011;40(1):168–72.
112. Dreyfus GD, Corbi PJ, Chan KMJ, Bahrami T. Secondary tricuspid regurgitation or dilatation: which should be the criteria for surgical repair? *Ann Thorac Surg.* 2005;79(1):127–32.
113. Nikolaidis N, Roubelakis A, Karangelis D, Hanratty M, Barlow CW, Tsang GM, et al. The outcomes of triple-valve surgery: eleven years' experience from a single center. *J Heart Valve Dis.* 2014;23(2):240–5.
114. Teman NR, Huffman LC, Krajacic M, Pagani FD, Haft JW, Bolling SF. "prophylactic" tricuspid repair for functional tricuspid regurgitation. *Ann Thorac Surg.* 2014;97(5):1520–4.
115. Maghami S, Ghoreishi M, Foster N, Dawood MY, Hobbs GR, Stafford P, et al. Undersized rigid Nonplanar Annuloplasty: the key to effective and durable repair of functional tricuspid regurgitation. *Ann Thorac Surg.* 2016;102(3):735–42.
116. Knott-Craig CJ, Goldberg SP, Overholt ED, Colvin EV, Kirklin JK. Repair of neonates and young infants with Ebstein's anomaly and related disorders. *Ann Thorac Surg.* 2007;84(2):587–93.
117. Ghanta RK, Chen R, Narayanasamy N, McGurk S, Lipsitz S, Chen FY, et al. Suture bicuspization of the tricuspid valve versus ring annuloplasty for repair of functional tricuspid regurgitation: midterm results of 237 consecutive patients. *J Thorac Cardiovasc Surg.* 2007;133(1):117–26.
118. Shivapour JKL, Sherwin ED, Alexander ME, Cecchin F, Mah DY, Triedman JK, et al. Utility of preoperative electrophysiologic studies in patients with Ebstein's anomaly undergoing the cone procedure. *Heart Rhythm.* 2014;11(2):182–6.
119. Filsoufi F, Anyanwu AC, Salzberg SP, Frankel T, Cohn LH, Adams DH. Long-term outcomes of tricuspid valve replacement in the current era. *Ann Thorac Surg.* 2005;80(3):845–50.
120. Ailawadi G, LaPar DJ, Swenson BR, Siefert SA, Lau C, Kern JA, et al. Model for end-stage liver disease predicts mortality for tricuspid valve surgery. *Ann Thorac Surg.* 2009;87(5):1460–8.
121. Fukuda S, Gillinov AM, McCarthy PM, Matsumura Y, Thomas JD, Shiota T. Echocardiographic follow-up of tricuspid Annuloplasty with a new three-dimensional ring in patients with functional tricuspid regurgitation. *J Am Soc Echocardiogr.* 2007;20(11):1236–42.
122. Navia JL, Brozzi NA, Klein AL, Ling LF, Kittayarak C, Nowicki ER, et al. Moderate tricuspid regurgitation with left-sided degenerative heart valve disease: to repair or not to repair? *Ann Thorac Surg.* 2012;93(1):59–69.
123. Navia JL, Nowicki ER, Blackstone EH, Brozzi NA, Nento DE, Atik FA, et al. Surgical management of secondary tricuspid valve regurgitation: annulus, commissure, or leaflet procedure? *J Thorac Cardiovasc Surg.* 2010;139(6):1473–1482.e5.

124. Lee TC, Desai BS, Milano C, Jagers J, Glower DD. Comparison of minithoracotomy versus sternotomy in 304 consecutive tricuspid valve operations. *Innov Technol Tech Cardiothorac Vasc Surg*. 2010;5(1):3–6.
125. Pagni S, Ganzel BL, Singh R, Austin EH, Mascio C, Williams ML, et al. Clinical outcome after triple-valve operations in the modern era: are elderly patients at increased surgical risk? *Ann Thorac Surg*. 2014;97(2):569–76.
126. Mihos CG, Pineda AM, Davila H, Larrauri-Reyes MC, Santana O. Combined mitral and tricuspid valve surgery performed via a right minithoracotomy approach. *Innov Technol Tech Cardiothorac Vasc Surg*. 2015;10(5):304–8.
127. Chikwe J, Itagaki S, Anyanwu A, Adams DH. Impact of concomitant tricuspid annuloplasty on tricuspid regurgitation, right ventricular function, and pulmonary artery hypertension after repair of mitral valve prolapse. *J Am Coll Cardiol*. 2015;65(18):1931–8.
128. Raikhelkar J, Lin HM, Neckman D, Afonso A, Scurlock C. Isolated tricuspid valve surgery: predictors of adverse outcome and survival. *Heart Lung Circ*. 2013;22(3):211–20.
129. Shigemura N, Sareyyupoglu B, Bhama J, Bonde P, Thacker J, Bermudez C, et al. Combining tricuspid valve repair with double lung transplantation in patients with severe pulmonary hypertension, tricuspid regurgitation, and right ventricular dysfunction. *Chest*. 2011;140(4):1033–9.
130. Dearani JA, Said SM, Leary PWO, Burkhardt HM, Barnes RD, Cetta F. Anatomic repair of Ebstein's malformation: lessons learned with cone reconstruction. *Ann Thorac Surg*. 2013;95(1):220–8.
131. Topilsky Y, Khanna AD, Oh JK, Nishimura RA, Enriquez-Sarano M, Jeon YB, et al. Preoperative factors associated with adverse outcome after tricuspid valve replacement. *Circulation*. 2011;123(18):1929–39.
132. Connolly HM, Schaff HV, Abel MD, Rubin J, Askew JW, Li Z, et al. Early and late outcomes of surgical treatment in carcinoid heart disease. *J Am Coll Cardiol*. 2015;66(20):2189–96.
133. Brown ML, Dearani JA, Danielson GK, Cetta F, Connolly HM, Warnes CA, et al. The outcomes of operations for 539 patients with Ebstein anomaly. *J Thorac Cardiovasc Surg*. 2008;135(5):1120–36.e7.
134. Brown ML, Dearani JA, Danielson GK, Cetta F, Connolly HM, Warnes CA, et al. Comparison of the outcome of porcine bioprosthetic versus mechanical prosthetic replacement of the tricuspid valve in the Ebstein anomaly. *Am J Cardiol*. 2009;103(4):555–61.
135. Moraca RJ, Moon MR, Lawton JS, Guthrie TJ, Aubuchon KA, Moazami N, et al. Outcomes of tricuspid valve repair and replacement: a propensity analysis. *Ann Thorac Surg*. 2009;87(1):83–9.
136. Malhotra SP, Petrossian E, Reddy VM, Qiu M, Maeda K, Suleman S, et al. Selective right ventricular unloading and novel technical concepts in Ebstein's anomaly. *Ann Thorac Surg*. 2009;88(6):1975–81.
137. Nguyen HS, Vu TD, Nguyen TQ. A modified Carpentier's technique for Ebstein's anomaly repair. *J Card Surg*. 2014;29(4):554–60.
138. Lee R, Li S, Rankin JS, Brien SMO, Gammie JS, Peterson ED, et al. Fifteen-year outcome trends for valve surgery in North America. *Ann Thorac Surg*. 2011;91(3):677–84.
139. Mutlak D, Lessick J, Reisner SA, Aronson D, Dabbah S, Agmon Y. Echocardiography-based spectrum of severe tricuspid regurgitation: the frequency of apparently idiopathic tricuspid regurgitation. *J Am Soc Echocardiogr*. 2007;20(4):405–8.
140. JPd S, Baumgratz JF, Ld F, Franchi SM, Lopes LM, Tavares GMP, et al. The cone reconstruction of the tricuspid valve in Ebstein's anomaly. The operation: early and midterm results. *J Thorac Cardiovasc Surg*. 2007;133(1):215–23.
141. Schofer J, Bijuklic K, Tiburtius C, Hansen L, Groothuis A, Hahn RT. First-in-human transcatheter tricuspid valve repair in a patient with severely regurgitant tricuspid valve. *J Am Coll Cardiol*. 2015;65(12):1190–5.
142. Pfanmuller B, Davierwala P, Hirnle G, Borger MA, Misfeld M, Garbade J, et al. Concomitant tricuspid valve repair in patients with minimally invasive mitral valve surgery. *Ann cardiothorac surg*. 2013;2(6):758–64.

143. Badiu CC, Schreiber C, Hörer J, Ruzicka DJ, Wottke M, Cleuziou J, et al. Early timing of surgical intervention in patients with Ebstein's anomaly predicts superior long-term outcome. *Eur J Cardiothorac Surg*. 2010;37(1):186–92.
144. Sarralde JA, Bernal JM, Llorca J, Pontón A, Diez-Solorzano L, Giménez-Rico JR, et al. Repair of rheumatic tricuspid valve disease: predictors of very long-term mortality and reoperation. *Ann Thorac Surg*. 2010;90(2):503–8.
145. Huffman LC, Nelson JS, Lehman AN, Krajacic MC, Bolling SF. Identical tricuspid ring sizing in simultaneous functional tricuspid and mitral valve repair: a simple and effective strategy. *J Thorac Cardiovasc Surg*. 2014;147(2):611–4.
146. Davarpassand T, Hosseinsabet A. Triple valve replacement for rheumatic heart disease: short- and mid-term survival in modern era. *Interact Cardiovasc Thorac Surg*. 2015;20(3):359–64.
147. Blauwet LA, Burkhart HM, Dearani JA, Malouf JF, Connolly HM, Hodge DO, et al. Comprehensive echocardiographic assessment of mechanical tricuspid valve prostheses based on early post-implantation echocardiographic studies. *J Am Soc Echocardiogr*. 2011;24(4):414–24.
148. Blauwet LA, Danielson GK, Burkhart HM, Dearani JA, Malouf JF, Connolly HM, et al. Comprehensive echocardiographic assessment of the hemodynamic parameters of 285 tricuspid valve bioprostheses early after implantation. *J Am Soc Echocardiogr*. 2010;23(10):1045–1059.e2.
149. Huygens SA, Mokhles MM, Hanif M, Bekkers JA, Bogers AJ, Rutten-van Molken MP, et al. Contemporary outcomes after surgical aortic valve replacement with bioprostheses and allografts: a systematic review and meta-analysis. *Eur J Cardiothorac Surg*. 2016;50(4):605–16.
150. Mokhles MM, Siregar S, Versteegh MI, Noyez L, van Putte B, Vonk AB, et al. Male-female differences and survival in patients undergoing isolated mitral valve surgery: a nationwide cohort study in the Netherlands. *Eur J Cardiothorac Surg*. 2016;50(3):482–7.
151. Braunwald NS, Ross J Jr, Morrow AG. Conservative management of tricuspid regurgitation in patients undergoing mitral valve replacement. *Circulation*. 1967;35(4 Suppl):I63–9.
152. Fukuda S, Gillinov AM, Song JM, Daimon M, Kongsarepong V, Thomas JD, et al. Echocardiographic insights into atrial and ventricular mechanisms of functional tricuspid regurgitation. *Am Heart J*. 2006;152(6):1208–14.
153. Nath J, Foster E, Heidenreich PA. Impact of tricuspid regurgitation on long-term survival. *J Am Coll Cardiol*. 2004;43(3):405–9.
154. Rodes-Cabau J, Taramasso M, O'Gara PT. Diagnosis and treatment of tricuspid valve disease: current and future perspectives. *Lancet*. 2016;388(10058):2431–42.
155. Ratschiller T, Guenther T, Knappich C, Guenzinger R, Kehl V, Voss B, et al. Do transvalvular pacemaker leads influence functional outcome after tricuspid ring annuloplasty? *Eur J Cardiothorac Surg*. 2015;48(3):363–9.
156. Jung SH, Je HG, Song JM, Choo SJ, Chung CH, Yun SC, et al. Outcomes following use of a modified Duran ring tricuspid valve reconstruction procedure for secondary tricuspid regurgitation. *Circ J*. 2010;74(5):925–30.
157. Hwang HY, Kim KH, Kim KB, Ahn H. Treatment for severe functional tricuspid regurgitation: Annuloplasty versus valve replacement. *Eur J Cardiothorac Surg*. 2014;46(2):e21–e7.
158. Shinn SH, Dayan V, Schaff HV, Dearani JA, Joyce LD, Lahr B, et al. Outcomes of ring versus suture annuloplasty for tricuspid valve repair in patients undergoing mitral valve surgery. *J Thorac Cardiovasc Surg*. 2016;152(2):406–15.e3.
159. Colombo T, Russo C, Ciliberto GR, Lanfranchi M, Bruschi G, Agati S, et al. Tricuspid regurgitation secondary to mitral valve disease: tricuspid annulus function as guide to tricuspid valve repair. *Cardiovasc surg (London, England)*. 2001;9(4):369–77.
160. Rankin JS, Thourani VH, Suri RM, He X, Brien SMO, Vassileva CM, et al. Associations between valve repair and reduced operative mortality in 21 056 mitral/tricuspid double valve procedures. *Eur J Cardiothorac Surg*. 2013;44(3):472–7.
161. WHO Technical Report. Geneva: 2004 01–11-2001. Report No.

162. Rothenbuhler M, O'Sullivan CJ, Stortecky S, Stefanini GG, Spitzer E, Estill J, et al. Active surveillance for rheumatic heart disease in endemic regions: a systematic review and meta-analysis of prevalence among children and adolescents. *Lancet Glob Health*. 2014;2(12):e717–26.
163. Tibazarwa KB, Volmink JA, Mayosi BM. Incidence of acute rheumatic fever in the world: a systematic review of population-based studies. *Heart*. 2008;94(12):1534–40.
164. van der Linde D, Konings EE, Slager MA, Witsenburg M, Helbing WA, Takkenberg JJ, et al. Birth prevalence of congenital heart disease worldwide: a systematic review and meta-analysis. *J Am Coll Cardiol*. 2011;58(21):2241–7.
165. Dabirian M, Nabati M, Jalalian R, Shokri M. Double-orifice tricuspid valve: a case report and literature review. *Echocardiography*. 2016;33(3):479–83.
166. Veerhadran SP, Pillai VV, Sasidharan B, Karunakaran J. Surgery for congenital tricuspid valve cleft: tricuspid valve repair with Neochordae and Annuloplasty. *J Heart Valve Dis*. 2015;24(4):525–7.
167. Lupo PJ, Langlois PH, Mitchell LE. Epidemiology of Ebstein anomaly: prevalence and patterns in Texas, 1999–2005. *Am J Med Genet A*. 2011;155a(5):1007–14.
168. Al-Najashi KS, Balint OH, Oechslin E, Williams WG, Silversides CK. Mid-term outcomes in adults with Ebstein anomaly and Cavopulmonary shunts. *Ann Thorac Surg*. 2009;88(1):131–6.
169. Jamieson WR, Rosado LJ, Munro AI, Gerein AN, Burr LH, Miyagishima RT, et al. Carpentier-Edwards standard porcine bioprosthesis: primary tissue failure (structural valve deterioration) by age groups. *Ann Thorac Surg*. 1988;46(2):155–62.
170. Caplin ME, Buscombe JR, Hilsen AJ, Jones AL, Watkinson AF, Burroughs AK. Carcinoid tumour. *Lancet*. 1998;352(9130):799–805.
171. Lin G, Nishimura RA, Connolly HM, Dearani JA, Iii TMS, Hayes DL. Severe symptomatic tricuspid valve regurgitation due to permanent pacemaker or implantable cardioverter-defibrillator leads. *J Am Coll Cardiol*. 2005;45(10):1672–5.
172. Mylonakis E, Calderwood SB. Infective endocarditis in adults. *N Engl J Med*. 2001;345(18):1318–30.
173. Chan P, Ogilby JD, Segal B. Tricuspid valve endocarditis. *Am Heart J*. 1989;117(5):1140–6.
174. Frontera JA, Gradon JD. Right-side endocarditis in injection drug users: review of proposed mechanisms of pathogenesis. *Clinical infectious diseases : an official publication of the Infectious Diseases Society of America*. 2000;30(2):374–9.
175. Gaca JG, Sheng S, Daneshmand M, Rankin JS, Williams ML, Brien SMO, et al. Current outcomes for tricuspid valve infective endocarditis surgery in North America. *Ann Thorac Surg*. 2013;96(4):1374–81.

Chapter 17

Tricuspid Valve Disease: Surgical Techniques

Michele De Bonis, Benedetto Del Forno, Teodora Nisi,
Elisabetta Lapenna, and Ottavio Alfieri

Abstract Tricuspid valve disease remains an intricate and debated field in terms of pathophysiology, surgical indications and treatment options. In this chapter, surgical techniques, both for repair and replacement of the tricuspid valve will be described in details. Functional (secondary) and organic (primary) tricuspid regurgitation will be addressed and a challenging scenario, like late tricuspid regurgitation following previous mitral valve surgery, will be emphasized.

Keywords Surgery • Tricuspid valve repair • Annuloplasty • De Vega procedure • Kay procedure • Ring annuloplasty • Clover technique • Tricuspid valve surgery in redo cases • Tricuspid valve replacement

Preparation for Cardio-Pulmonary Bypass

Access

Longitudinal median sternotomy represents the most common used approach for acquired valve disease needing surgery. It offers an optimal exposure of the surgical field both to establish the cardiopulmonary bypass (CPB) and to explore and operate on aortic, mitral and tricuspid valve.

Actually it is possible to achieve an optimal opening of the sternum through a limited skin incision in order to offer to the patient a less traumatic and more cosmetic wound.

M. De Bonis (✉) • B. Del Forno • T. Nisi • E. Lapenna • O. Alfieri
Department of Cardiac Surgery, IRCCS San Raffaele Scientific Institute,
Vita Salute University, Milan, Italy
e-mail: debonis.michele@hsr.it

In tricuspid valve surgery a right anterolateral thoracotomy can also be used, especially in redo operation to limit as much as possible adhesions dissection and the risk of right ventricle injury during repeat sternotomy.

Cannulation

The usual setting to institute the cardiopulmonary bypass for tricuspid valve surgery includes cannulation of ascending aorta and both vena cavae.

Bicaval cannulation followed by snaring of both vena cavae is mandatory to obtain a bloodless surgical field. Tricuspid valve surgery can be performed both under cardioplegic arrest and on beating heart.

Venous drainage can also be obtained with peripheral percutaneous cannulation of superior vena cava and inferior vena cava through right internal jugular vein and right femoral vein respectively. Recently, introduction of specific two-stage femoral vein cannula, associated to opportune administration of vacuum-assisted drainage, represents an interesting tool in case of redo surgery or minimal invasive access.

When part of a left-sided valve surgery, tricuspid valve procedures can be performed during aortic clamping or at conclusion of the other procedure once the left heart has been de-aired and the cross clamp removed.

Exposure

The tricuspid valve is usually approached through an horizontal or vertical right atriotomy (Fig. 17.1).

In the first case, the incision is carried out starting close to the atrial appendage and directing it to the inferior vena cava. When a trans-atrial approach is planned to perform mitral valve surgery, the right atriotomy must be more extended to allow its exposure [1]. In this cases the incision is parallel and posterior to the atrioventricular groove, one centimeter far away from it, to avoid injury to the right coronary artery or to the sinus node.

The second approach consists in performing a vertical right atriotomy starting from the appendage and directing the incision straight towards the interatrial groove.

Some surgeons adopt a semicircular atriotomy proximally to the inferior vena cava. This kind of approach seems to provide direct visualization of the tricuspid valve and reduce the risk of damaging the conduction system (Fig. 17.1).

The accuracy of all those incisions is mandatory to perform a safe and seal closure of the atrium at the end of the procedure.

Once the atriotomy is completed, exposure can be obtained with the help of a standard retractor or using silk stay sutures passed through the pectinate muscles.

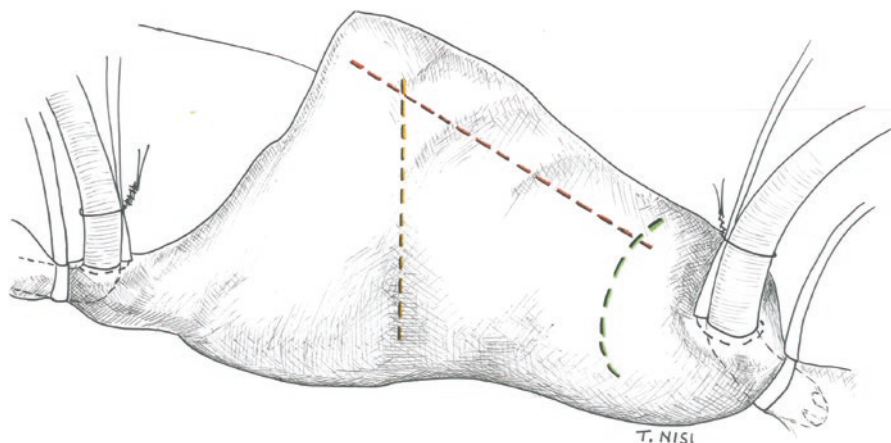


Fig. 17.1 Surgical incisions to access the right atrium and expose the tricuspid valve

Surgical Anatomy and Analysis

The tricuspid valve is composed of three leaflets, anterior, posterior and septal, and three interposed commissures.

The leaflets are implanted on the tricuspid annulus, a relatively indistinct fibrous structure localized about 2 mm external and deep from the hinge of each cusp. This structure has several significant relationships so understanding its exact position is fundamental to safely perform any annuloplasty technique.

In the first instance, it is crucial to identify the triangle of Koch that is defined by the tendon of *Todaro*, the septal leaflet of the tricuspid valve and the orifice of the coronary sinus. The atrioventricular node and the conduction system are localized at the apex of the triangle (Fig. 17.2). Staying away from this area is essential to avoid rhythm disturbances.

Secondly, during annuloplasty the strict relationship of the antero-septal commissure and the first part of the anterior leaflet with the aortic root must be considered. In this segment, inadvertent stitches may damage the aortic valve.

Finally, right coronary artery (RCA) runs very close to the tricuspid annulus in the area between the anteroposterior commissure and the posterior leaflet especially in the presence of anatomic variations of RCA distribution or whenever relationship between the RCA and the tricuspid annulus is altered due to right ventricle remodeling or severe tricuspid annulus dilatation. Both during suture annuloplasty and ring annuloplasty, careless stitches may distort or occlude the RCA in the segment from the acute margin to the crux. During the operation, once the right atrium is opened, a carefully inspection must be performed to peculiarly visualize jet lesions on the atrial wall. They indicate which is the prolapsing leaflet, which is usually the one opposite to the lesion.

The tricuspid valve is inspected to detect leaflet lesions. Every cusp is analyzed using a nerve hook to expose the subvalvular apparatus.

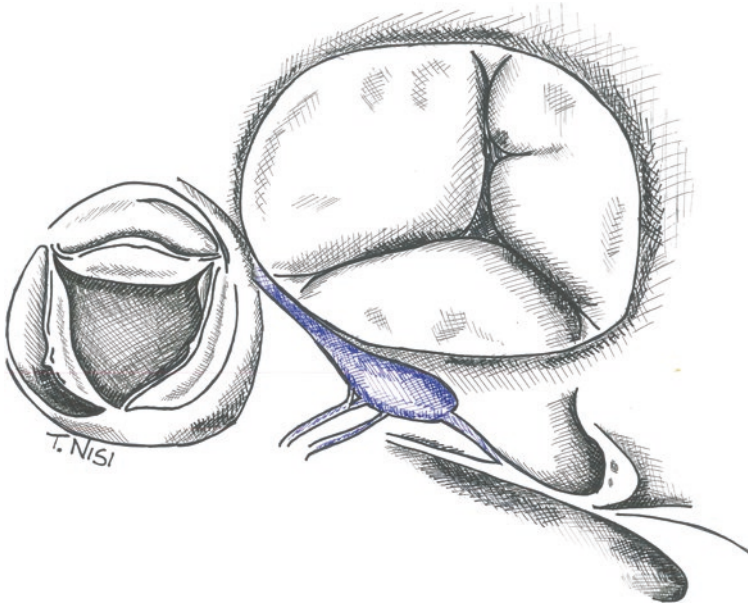


Fig. 17.2 Localization of the atrioventricular node and the conduction system and their relationship with the tricuspid valve annulus

Tricuspid Valve Repair for Functional Disease

Functional (or secondary) tricuspid regurgitation refers to a disease occurring as result of left-sided heart pathology (LHP) or pulmonary hypertension in the absence of organic lesions of the tricuspid valve.

However, this definition may be somewhat misleading since functional tricuspid regurgitation is more than a functional entity, as it entails intrinsic anatomical abnormalities of the tricuspid apparatus, such as annular dilation and deformation.

The surgical treatment of secondary tricuspid regurgitation is still under debate both in terms of timing and surgical techniques.

Severe secondary tricuspid regurgitation should be corrected at the same time as left-heart surgery is performed. Less than severe functional tricuspid regurgitation should be surgically corrected in cases of concomitant LHP requiring surgery in the presence of tricuspid annular dilation (≥ 40 mm or > 21 mm/m² between the septal and the anterior leaflet in diastole [2]). Indeed, in those circumstances, the diameter of the tricuspid annulus rather than the grade of regurgitation (which is highly subjective and variable) should be the criterion to indicate the need for concomitant tricuspid valve repair. The principles of therapy for secondary tricuspid regurgitation include elimination of increased after-load to the right ventricle (by correction of LHP and optimization of left ventricular function) and correction of tricuspid annulus dilation and dysfunction, usually by tricuspid valve annuloplasty.

If severe tricuspid valve tethering is present, the use of adjunctive surgical techniques to tricuspid annuloplasty (such as enlargement of the anterior leaflet) or tricuspid valve replacement should be considered. Tricuspid annular dilatation has always been the primary target of the surgical treatment of secondary tricuspid regurgitation and has usually been corrected by two main surgical methods: suture annuloplasty and ring annuloplasty [3].

Suture Annuloplasty

Kay Procedure

The repair described by *Kay* et al. in 1965 represents the oldest one to treat secondary tricuspid regurgitation. The main principle of this technique is to exclude the posterior leaflet to obtain a competent bicuspid valve. In the original description a 1-0 silk suture is passed in the annulus beginning at the anteroposterior commissure, then at the center of the posterior leaflet, and then through the annulus at the postero-septal commissure. The suture is pulled taut and the size of the orifice is checked. At this point additional sutures are placed and then tightened when the desired size is reached. Usually three or four sutures are required to decrease the size of the annulus [4] (Fig. 17.3a).

Several modifications to the first bicuspidalization technique have been proposed over the years such as the use of figure-of-eight sutures, pledget mattress sutures, 2-0 or 3-0 polyester sutures instead of silk suture, and few others.

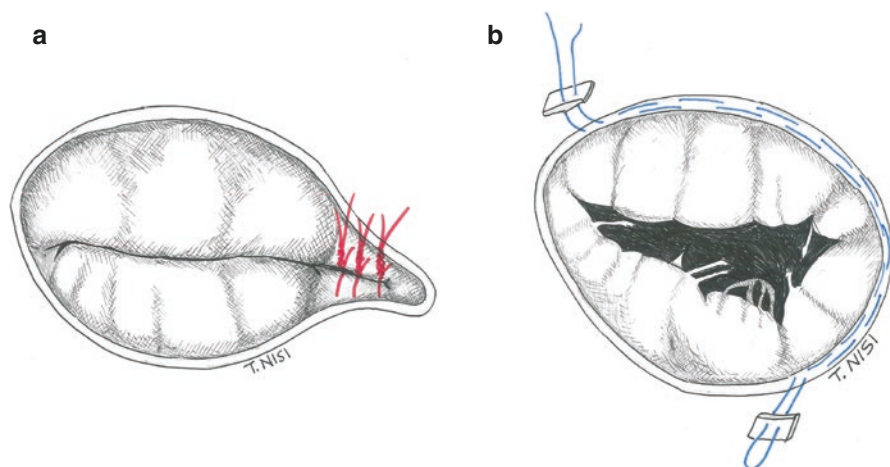


Fig. 17.3 (a) Original *Kay* procedure. (b) Original *De Vega* procedure

De Vega Procedure

The *De Vega* annuloplasty is definitely the most popular and widely used suture technique to correct annular dilatation.

Described in 1972, the aim of this technique is to shorten the area of the tricuspid annulus corresponding to the anterior and posterior leaflets.

Two pledgeted parallel running stitches, usually 2-0 Ti-cron or 4-0 polypropylene, are used for this procedure. The suture is started on the annulus at the level of postero-septal commissure and directed around the perimeter of the orifice in a counterclockwise direction reaching the antero-septal commissure. Every 5–6 mm a single bite is placed into the fibrous annulus through the endocardium.

The second extremity of the suture is placed 1–2 mm outside the previous one making the same route. Once reached the antero-septal commissure the suture is tied, possibly using an annular sizer into the valve to properly obtain the desired size (Fig. 17.3b) [5].

Pitfall of this technique is the possibility that stitches placed in a fragile tricuspid annulus cut the endocardium. For this reason a number of modifications have been proposed. One of the most interesting was developed by *Antunes* and *Girdwood* in 1983 that suggested to use a pledget between every bite on the annular tissue [6].

Ring Annuloplasty

In 1971, *Carpentier* proposed a new revolutionary concept in the conservative valve surgery introducing the idea of annular remodeling using a prosthetic ring [7].

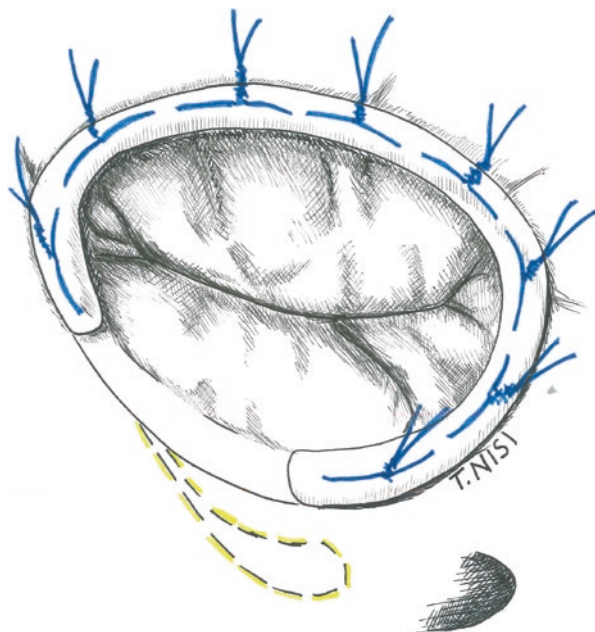
With rigid or semi-rigid prosthetic tricuspid ring annuloplasty, the annulus is permanently fixed in a systolic position and the physiologic shape of the valve is restored [8]. Flexible rings may be used as well. Although they do decrease the size of the annulus, they are unable to restore its normal morphology.

Imaging studies of the tricuspid annulus, by means of echocardiographic and magnetic resonance, showed its three-dimensional geometry. The area close to the aortic valve and the right ventricular outflow tract, at the level of the antero-septal commissure, is the most prominent part of the annulus whereas the deepest part is at the level of the postero-septal commissure adjacent to the coronary sinus ostium [9]. Giving this finding, specific rigid rings with a three-dimensional (3-D) shape have been proposed to re-establish as much as possible the annulus geometry.

Classically, measurement of the distance from the antero-septal to postero-septal commissures, or surface of the anterior leaflet, are used for ring sizing.

Once the right size of the ring is chosen, it is implanted using eight to ten 2-0 Ti-cron stitches. The tricuspid annulus is not as distinct as the mitral annulus, therefore each leaflet must be grasped and pulled away from its attachment for a properly exposure.

Fig. 17.4 Tricuspid ring annuloplasty



Usually, suturing starts posteriorly to the midpoint of the septal leaflet, very close to its hinge to prevent injury to the conduction system. Proceeding counterclockwise, the second stitch is placed like the first one, very close to the leaflet and towards the postero-septal commissure. The sutures corresponding to the posterior leaflet, and to the portion of the anterior leaflet away from the aortic segment, have to be placed 2 mm far from the junction between the atrium and the valve. Giving the closeness of the aortic root, the other stitches for the anterior leaflet must be passed through its hinge paying particular attention not to accidentally place a suture into the leaflet itself or to damage the aortic wall. The last stitch must be placed superiorly to the antero-septal commissure, to stay away from the conduction system.

At this point the sutures are passed through the ring using the same spacing for those originating from the septal portion of the annulus, then reducing the space for all the others. The ring is parachuted and fixed, reducing the dimension of the annulus, restoring its geometry and obtaining adequate surface of leaflets coaptation (Fig. 17.4).

Enlargement of the Anterior Leaflet

When severe tethering of one or more leaflets is present, an isolated annuloplasty is not enough to correct the insufficiency and adjunctive procedures are necessary.

In 2008 *Dreyfus et al.* have proposed the technique described as enlargement of the anterior leaflet to deal with this situation. The anterior leaflet is detached from the annulus and an oval shaped piece of autologous pericardium is prepared. The diameter of the patch is measured on the distance between the antero-septal and the anteroposterior commissures, whereas the height on the greatest distance between the detached leaflet and the annulus. The patch is then sutured with a polypropylene 5-0 suture to the annulus and to the leaflet to fill the gap. The procedure is concluded implanting a semi-rigid tricuspid annuloplasty ring [10].

“Clover Technique”

Another adjunctive procedure which can be associated to the annuloplasty in case of severe functional tricuspid regurgitation due to important tethering, is represented by the so-called “clover technique”.

This procedure was conceived and then proposed by *Alferi et al.* in 2003 [11]: initially introduced for the treatment of post-traumatic tricuspid regurgitation, afterward it has proven to be effective even in complex cases both of primary or secondary tricuspid regurgitation [12] (Fig. 17.5).

The technique consists of stitching together the middle point of the free edges of the tricuspid leaflets, producing a clover-shaped valve. In all cases a 5.0 polipropylene suture without pledgets is used. Then a semi-rigid tricuspid ring is implanted to correct the dilated and deformed annulus and to stabilize the repair.

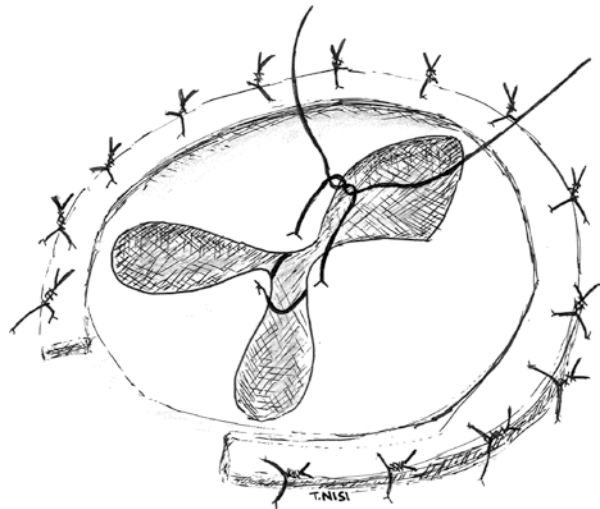


Fig. 17.5 The “Clover Technique”

Results

Neither suture nor ring annuloplasty consistently eliminate functional tricuspid regurgitation. After tricuspid annuloplasty, the recurrence rate of significant tricuspid insufficiency at 1 month after surgery ranges from 8 to 15% [13, 14].

This rate of failure has been attributed to a number of factors, including severity of preoperative tricuspid regurgitation, pulmonary hypertension, presence of pacemakers, left ventricular dysfunction, increased left ventricular remodeling, severe tethering of the tricuspid leaflets and the use of suture rather than ring annuloplasty [13–16].

The type of annuloplasty procedure remains one of the most investigated aspects in functional tricuspid regurgitation repair. In several published studies, both randomized and observational, the ring annuloplasty has showed a more durable repair compared to suture annuloplasty, particularly in patients with severe tricuspid annular dilation or pulmonary hypertension [13–16].

Besides being more durable, ring repairs also provide better long-term and event-free survival up to 15 years after surgery, compared to suture annuloplasty [17]. This is not surprising considering that moderate and severe tricuspid regurgitation is an important predictor of late mortality, independent of ventricular function and pulmonary artery pressure [18].

When a significant leaflet tethering is associated to the dilatation of the tricuspid annulus, annuloplasty alone is unlikely to be durable [19] so an additional procedure, such as patch augmentation of the anterior leaflet or “clover technique”, may be used to achieve a more durable repair [10, 12]. Although preliminary results with these approaches are encouraging, more data and longer follow-up are necessary to prove their effectiveness in the long-term and define their role as an alternative to tricuspid valve replacement in selected patients.

Tricuspid Valve Repair for Primary Disease

Primary tricuspid valve insufficiency represents an organic disease with involvement of the tricuspid valve apparatus that results affected by one or more lesions.

In Western countries, the most common etiologies of primary tricuspid regurgitation are degenerative valve disease or bacterial endocarditis, whereas rheumatic disease is the most prevalent form in developing countries.

The leaflets may be affected by excess of tissue, thickening, perforation and tear. The chordae tendinae and the papillary muscles may be elongated or damaged. On the other hand chordal or commissures thickening and fusion are typical of rheumatic disease.

The aim of tricuspid valve repair is to restore a normal leaflet mobility ensuring an adequate surface of coaptation. Several techniques, already well-adopted in the context of mitral valve repair, are used to repair these organic defects, and usually a prosthetic ring implantation completes the procedure.

Intervention on the Leaflets

In case of limited chordal rupture or elongation, a small triangular resection of the leaflet can be performed. This technique may be applied when the prolapsing segment is less than one tenth of the leaflet surface area.

Once resected the planned portion, the margins are approximated using a 5-0 polypropylene running suture or interrupted stitches depending on surgeon preferences.

If the prolapsing segment is extensive, usually due to bacterial endocarditis, the resection must be extensive itself and sometimes an annular plication and/or a patching of the resected area must be adopted (Fig. 17.6).

Intervention on the Chordae

When the prolapse of the leaflet is caused by an extensive chordal rupture, a small resection is not adequate and a procedure correcting the subvalvular apparatus should be performed.

Like in mitral valve repair surgery, this kind of defect may be fixed adopting both chordal transposition and artificial chordae implantation.

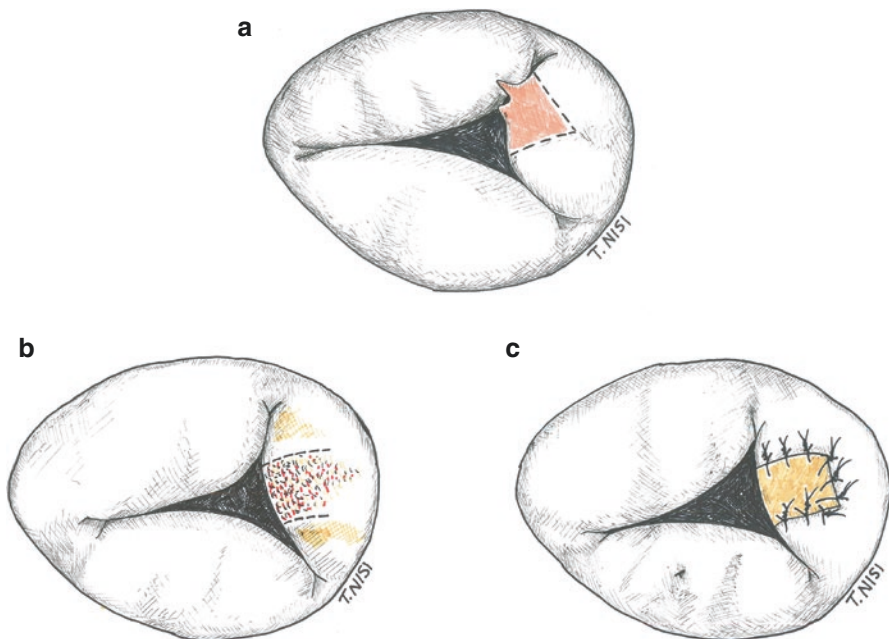


Fig. 17.6 (a) Triangular resection to correct the flail of the leaflet due to chordal rupture. (b) Extensive resection of the leaflet due to bacterial endocarditis. (c) The gap is closed using an autologous pericardium patch

In the first case, a small segment of adjacent non prolapsing leaflet is resected and then implanted on the prolapsing one using 5-0 polypropylene running suture.

If artificial chordae are preferred, accurate measurement of native chordae of a non prolapsing leaflet is performed and used to choose the proper length. After that, artificial chordae are first implanted on the corresponding papillary muscle, then on the free margin of the prolapsing leaflet.

Intervention on the Papillary Muscles

Papillary muscles or extensive chordal elongation may be corrected adopting a sliding papillary muscle plasty technique. The elongated papillary muscle, or the papillary muscle underlying the elongated chordae, is lowered to the proper level and fixed to the adjacent one using 5-0 polypropylene interrupted stitches.

Intervention on the Commissures

Fusion of the three commissures is the specific feature of the rheumatic disease. In these cases fusion of the underlying chordae is often associated.

The surgical technique consists of performing commissurotomy and dividing fused chordae using an 11 blade under direct visualization; in some cases, with the purpose to improve leaflets motion, cutting of secondary chordae is associated.

Tricuspid Valve Replacement

When the tricuspid valve is dramatically compromised to the point that an adequate reconstructive procedure can not be performed, the decision for tricuspid valve replacement should be taken.

This condition frequently occurs for advanced rheumatic disease, for heavily damaged valves due to endocarditis, for carcinoid syndrome, radiation induced disorder and severe forms of *Ebstein's* anomaly.

In functional tricuspid regurgitation valve repair is the first choice. Sometimes, severe tethering does not permit a good immediate results so a tricuspid valve replacement should be considered.

Tricuspid valve replacement (TVR) can be done both under cardioplegic heart arrest or on beating heart. The choice of the strategy is influenced by the surgeon's preference, accessibility of the tricuspid valve, and overall length of aortic cross-clamping. A combined procedure can also be done, i.e. placement of the principal and most difficult stitches during cross clamp and then finishing the valve implantation on beating heart after aortic declamping.

Choice of the Prosthetic Valve

The choice of implanting a biological or a mechanical prosthesis in tricuspid position should follow the same algorithm used for other cardiac valves. Patients age, contraindication to anticoagulation therapy, female sex, social and working issue must be considered with the purpose to make the right choice.

Some surgeons prefer to implant a mechanical prosthesis in order to avoid the problem of bio-prosthesis structural valve deterioration [20]. However mechanical valves in low-pressure right-heart circulation are more predisposed to valve thrombosis. Moreover, lower level of prostacyclin, a powerful inhibitor of platelet aggregation produced in the lung, is present in the right-sided chamber and it could represent an adjunctive risk factor for mechanical valve thrombosis [21].

Furthermore, introduction of pacemaker leads through the prosthesis into the right ventricle is not possible with mechanical valves.

Given that, biological prostheses would seem to be an ideal solution for tricuspid valve replacement since they do not require anticoagulation therapy and are expected to have a slower degeneration than in mitral position.

Reoperations rate after bio-prosthetic tricuspid valve replacement seems to be lower compared to bio-prosthetic mitral valve replacements. This might be explained by the fact that right heart chambers produce lower pressure and thus generate lower stress on the bio-prostheses. Moreover, patients undergoing TVR usually have a limited life expectancy so the long-term durability of a bio-prosthesis in this position is enough for their natural history [22].

On the other hand, some series have been consistent in demonstrating that there is no survival benefit of biological over mechanical prostheses and also the reoperation rate is similar [23, 24]. In addition a recent meta-analysis showed no statistically significant difference between mechanical and biological valves in terms of survival, reoperation, or prosthetic valve failure, even if mechanical tricuspid valve prostheses had a higher risk of thrombosis [25]. Regarding that, bileaflet valve thrombosis is rarely fatal and often is successfully treated increasing anticoagulation therapy or using thrombolysis [26].

Some other factors should be considered in choosing the optimal prosthesis. First of all, small size patients could take advantage from implanting low profile bileaflet valve to achieve better hemodynamics performance. Secondly, many patients undergoing tricuspid valve replacement are already receiving anticoagulant treatment, making the need for anticoagulation an unreliable criterion for the choice of the tricuspid prosthesis [27].

On these basis, it is not possible to state that there is a “gold standard” for prosthetic selection in tricuspid valve replacement and its choice should be strictly tailored on the patient.

Surgical Technique

Tricuspid valve replacement is usually performed using pledgeted everting mattress sutures.

In case of non-infective lesions, the tricuspid valve leaflets are left in place and incorporated in suturing the prosthesis to the annulus, in order to preserve the sub-valvular structures and to avoid injury to the conduction system. If prolapsing leaflets may obstruct the right ventricular outflow tract, they can be fenestrated along their radial axis.

In case the leaflets are severely damaged, the valve must be resected. The resection is started by incising the anterior and posterior leaflets, leaving a 2–3 mm fringe of tissue on the annulus, and dividing the chordal attachments deep in the right ventricle. Usually the septal leaflet is left in situ.

Everting 2-0 or 3-0 pledgeted Ti-cron sutures are placed along the circumference of the annulus from the atrial to the ventricular side of the valve, starting at the anterior leaflet and proceeding clockwise. Careful suture placement in the septal leaflet area is mandatory to avoid conduction system injury.

Alternatively, when a quicker procedure is needed, pledgets sutures are used only at the level of the septal leaflet, while two continuous 2-0 Ti-cron sutures are used for the remaining circumference of the valve.

Standard valve sizers are used to choose the proper size of the valve to implant. Size selection is based not only on the diameter of the atrioventricular ring but also on the diameter of the ventricular cavity. However, serious injury to the interventricular septum may occur if a too large prosthesis is placed into the right ventricle.

The bio-prosthetic valve must be properly oriented to avoid obstruction of the right ventricle outflow tract by its stent posts. From the surgeons view, the posts should stay at the 12, 4 and 8 o'clock positions. The sutures are then passed through the sewing ring of the prosthesis and once it is slipped down, the sutures are secured starting from the septal leaflet (Fig. 17.7).

The atriotomy is closed in the usual manner.

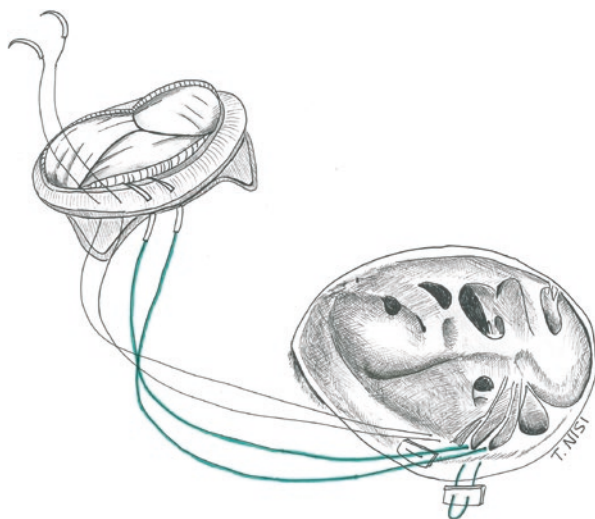


Fig. 17.7 Tricuspid valve replacement with bio-prosthesis using everting 2-0 or 3-0 pledgeted Ti-cron sutures

Results

Tricuspid valve replacement is commonly burdened by sub-optimal immediate and long-term outcomes. Late referral represents the main issue in the management of this kind of patients, severely conditioning the operative results. Moreover, TVR is frequently performed as a reoperative case, that represents itself an adjunctive intrinsic risk for postoperative morbidity and mortality [23, 28].

In some series, the operative mortality reaches 18%, highlighting the complexity of these patients. Female gender, NYHA class, serum bilirubin level, preoperative loop diuretic dose, preoperative haemoglobin level and reoperative surgeries are associated with increased operative mortality [28, 29].

In the setting of redo cases, an optimal tool is represented by performing the replacement without clamping the aorta. This approach can be done with acceptable acute mortality, especially if performed in the absence of ascites, significant right ventricular dysfunction and pulmonary hypertension [30].

Regarding the outcomes on long-term, they are acceptable considering the clinical conditions of these patients. Age at intervention, redo surgery and pulmonary hypertension seem to impact on survival at follow-up [29, 30].

Special Condition

Tricuspid Valve Endocarditis

Isolated tricuspid valve endocarditis is uncommon and usually strictly correlated with intravenous drug use, intra-cardiac catheters or cardiac anomalies.

In a report of patients addicted to intravenous drugs, 83% of them were affected by tricuspid valve endocarditis [31].

Causative organisms are represented in 50–75% of cases by *Staphylococcus aureus*, whereas *Candida* species, *Bartonella*, *Salmonella* and *Listeria* are more frequent in patients who are infected with the human immunodeficiency virus [32].

The organisms form masses or erode and destroy large portions of the valve leaflets and chordae.

In case of intravenous drug addiction, surgery should be preferably performed after controlling the drug dependence, given the high recurrence rate of infective endocarditis due to continued drug abuse.

Surgical options include debridement of the infected area, excision of the vegetations followed by valve repair, or excision of the tricuspid valve followed by prosthetic valve replacement [33].

Vegetations are usually localized on the atrial surface of the leaflets which can frequently be destroyed.

The leaflet affected, its necrotic area and a margin of healthy tissue are removed. If the resection involves the posterior leaflet, a *Kay* technique is performed to exclude the posterior annulus, using 2-0 Ti-cron horizontal mattress sutures with or without autologous pericardial pledgets.

When septal or anterior leaflet are involved, a trapezoidal resection of the affected portion is performed and the margins are re-approximated with interrupted 6-0 or 7-0 polypropylene sutures. A limited annuloplasty with horizontal mattress sutures of 2-0 Ti-cron completes the procedure.

In particularly destroying disease, tricuspid valve replacement should be considered even if the risk of early prosthetic valve endocarditis is high. During valve replacement some additional procedures, such as soaking the prosthesis in antibiotic solution or swabbing the annulus with antiseptic or antibiotics may be helpful.

Ebstein's Anomaly

Ebstein's anomaly of the tricuspid valve is a rare congenital malformation that accounts for about 1% of all congenital heart defects and about 50% of the affected do not survive to adulthood [34].

There are three distinctive features of this condition: first of all, the origin of the septal or posterior leaflets or both is displaced downward into the right ventricle. The leaflets usually appear deformed and the commissure between the anterior and posterior cusps may be absent.

Secondly, the right ventricle is atrialized in the portion between the true tricuspid annulus (demarcated by the right coronary artery) and the insertion of the displaced leaflet.

Finally, the right ventricle is usually small with an impairment of the systolic function (Fig. 17.8).

Surgical techniques used in adults with *Ebstein's* anomaly are the same used in children. Various procedures can be adopted, according to the grade of the disease.

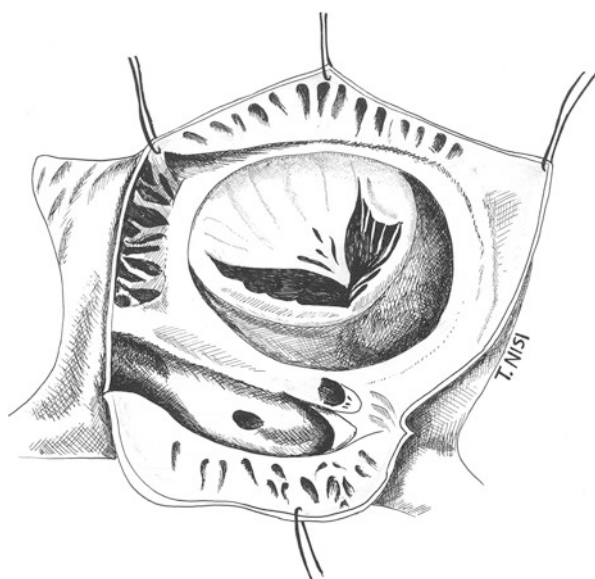


Fig. 17.8 *Ebstein's* anomaly

Tricuspid valve repair is the preferred operation. If the repair is not feasible, tricuspid valve replacement must be done.

When the right atrium is dilated, the redundant wall can be resected as well.

The keystone in repairing this condition is to establish valve competence converting the native tricuspid valve into a monoleaflet valve using the anterior cusp. To assess if a repair is feasible, saline is injected into the right ventricle. If an adequate zone of apposition between the free edge of the anterior leaflet and the septum (or the septal leaflet when present) is observed, a repair technique can be performed.

Several repair techniques can be considered.

- *Danielson's* technique: this operation consists in plicating the atrialized portion of the right ventricle plus a right atrial reduction and a posterior tricuspid annuloplasty performed with interrupted pledget sutures. The reconstruction of the valve is based on the use of the anterior leaflet to create a mono leaflet competent valve [35].
- *Dearani's* technique: this approach is characterized by displacing each papillary muscle towards the ventricular septum and fixing them at the appropriate level with horizontal pledget mattress sutures. The posterior leaflet is plicated and posterior annuloplasty is performed to narrow the diameter of the tricuspid annulus taking the coronary sinus as posterior mark of its extension. Moreover, to further narrow the tricuspid annulus, an anterior purse-string annuloplasty is performed [36].
- *Carpentier's* technique: the major portion of the anterior leaflet plus the adjacent posterior leaflet are temporary detached from the annulus forming a single piece and then everted to expose the subvalvular apparatus. At this point, to achieve leaflets mobilization, the interchordal space is fenestrated and any fibrous band, connecting the leaflets to the ventricular wall, is resected. A longitudinal plication of the atrialized portion of the right ventricle is performed placing interrupted 3-0 pledget-reinforced sutures. A 4-0 polypropylene running sutures is used both to reinforce this portion (paying attention to avoid coronary branches), and to plicate the right atrium behind the coronary sinus. The detached tricuspid leaflets are rotated clockwise to cover the circumference of the orifice and are then reattached to the annulus with continuous 5-0 polypropylene running suture. The last step of the procedure consists in implanting a Carpentier annuloplasty ring [37].
- The “cone” procedure: this technique proposed by *da Silva* represents a modification of the *Carpentier* procedure. The main differences consist in the absence of plication of the atrialized right ventricle and in the use of a limited posterior suture annuloplasty [38].

During the last three decades, important contributions in the development of repair techniques were driven from the experience of *Danielson* and *Dearani*, *Carpentier* and *da Silva*.

A recent report of the Mayo Clinic experience including both techniques of *Danielson* and *Dearani*, applied on 539 patients, showed satisfactory long-term results with a survival rate at 5, 10, 15, and 20 years of 94%, 90%, 86%, and 76%,

respectively whereas freedom from late reoperation was 86%, 74%, 62%, and 46% [39]. *Carpentier* et al. reported the results of his technique on 191 patients: actuarial survival was 82% at 20 years, tricuspid valve insufficiency at the discharge was 1 or 2+ in 80% of the cases and reoperation during follow-up occurred in 8% (16 patients). These results confirm that this conservative technique ensures acceptable long-term outcome [40]. Finally, the reported results of the *da Silva* technique showed low operative mortality and morbidity, significant reduction of tricuspid insufficiency, and low incidence of reoperation at follow-up [38].

Sometimes the severity of the disease prevents the repair, and the valve has to be replaced. This occurs in about 20–30% of the cases [41].

Tricuspid valve replacement can be done only in presence of adequate right ventricle systolic function and geometry, otherwise a partial cavo-pulmonary connection is mandatory.

In order to perform a tricuspid valve replacement, the valve is excised, leaving the basal portion of the anterior leaflet. The sutures are placed through the usual location of the tricuspid ring, but since the atrialized ventricle have to be plicated, the sutures are passed first through the attachment of the displaced septal and posterior leaflets, then through the true anatomic tricuspid ring, and at least through the prosthesis. Usual attention in preventing damage to the penetrating bundle must be paid.

Carcinoid Disease

The carcinoid syndrome occurs in patients with malignant gastrointestinal carcinoid tumors and hepatic metastasis secreting a range of vasoactive peptides and hormones (i.e. 5-hydroxytryptamine—serotonin). These products of the metastatic tumor cells are able to reach the systemic circulation eliciting several effects such as flushing, diarrhea, broncho-constriction as well as the development of carcinoid heart disease [42].

Heart involvement is due to deposition of fibrotic plaques on endocardial surface of the valves and ventricles mediated by high serotonin levels [43]. The right chambers and right valves are mainly involved. Usually the tricuspid valve, and less frequently the pulmonary valve, are severely affected with a combination of stenosis and regurgitation. In addition, a dysfunction of the right ventricle can be observed.

Since the prognosis of medical therapy alone is very poor in these patients [44], the only solution is represented by valve replacement surgery.

Tricuspid valve replacement is performed as previously described. In these patients the choice of the type of the prosthesis must take into account several variables like the potential need of abdominal surgery, the anomalous liver profile and the associated coagulopathy which are supposed to make the choice of bio-prosthetic valve more acceptable. On the other hand, in some cases of high tumoral activity, which might produce premature bio-prosthesis degeneration, a mechanical valve could be preferred with acceptable event-free survival [45].

Traumatic Lesion

Severe tricuspid regurgitation is an unusual event that can occur following blunt chest trauma.

In this setting tricuspid insufficiency is due to rupture of papillary muscle or chordae, usually producing a flail of the anterior leaflet.

The real prevalence of this lesion is probably underestimated.

Tricuspid valve repair can be performed with a combination of the techniques previously described including the so called “clover technique”, which has also been proposed to treat these complex cases [10].

Pacemaker Lead-Induced Tricuspid Regurgitation

Pacemaker or defibrillator lead may distort and eventually become adherent to a tricuspid leaflet causing valvular insufficiency.

In these cases a resection of the involved portion of the leaflet and a subsequent reconstruction is performed. The lead is removed and substituted by an epicardial one.

Rarely, the leaflets are severely injured and a valve replacement is mandatory. In this case, the pacemaker lead can be positioned between the sewing ring of the valve and the patient’s annulus.

Late Tricuspid Regurgitation Following Previous Left-Sided Valve Surgery

A particularly challenging problem is represented by the development of significant tricuspid regurgitation late after left-sided valve surgery. This condition may occur from progression of seemingly insignificant tricuspid regurgitation (untreated at the time of the first surgery) or from failure of a previously performed tricuspid annuloplasty.

In this subgroup with long-standing tricuspid insufficiency, surgical indication can be more challenging due to the presence of variable degrees of right ventricular dysfunction and pulmonary vascular disease.

The dilatation of the tricuspid annulus is usually associated with important tethering of the tricuspid leaflets, secondary to advanced remodeling of the right ventricle.

According to *Fukuda* et al., severe tricuspid valve tethering is the major predictor of residual tricuspid regurgitation after tricuspid annuloplasty [46]. Enlargement of the anterior tricuspid leaflet has been successfully adopted in those cases. However this approach requires cardioplegic arrest. Alternatively beating heart tricuspid valve replacement represents a valuable option.

Indeed, these patients can benefit from avoiding aortic clamping to preserve the dysfunctional right ventricle. Surgical dissection should be minimized to reduce post-operative bleeding considering that those patients usually have some degrees of coagulopathy. Finally the cardio-pulmonary bypass time should be as short as possible.

Case Report

As paradigmatic example we briefly describe the case of a 66 year-old female who underwent mitral valve replacement with mechanical prosthesis in 1995 and had a first echocardiographic diagnosis of severe tricuspid valve regurgitation in 2005. Since then she had regular clinical and echocardiographic follow-ups documenting progressive increase in right atrial and right ventricle dimensions and required progressive increment of furosemide dosage.

Ten years later, in 2015, she was referred for surgery. At the presentation she was in NYHA functional class IIB, suffering for fatigue and upper abdominal pain. Peripheral edema and hepatomegaly were present. The hematologic samples highlighted chronic kidney disease as well as an initial impairment of liver function.

The echo performed showed severe tricuspid regurgitation (vena contracta 11 mm) due to annular dilatation (46 mm) and severe tethering and fibrosis of the leaflets (tenting area 2.9 cm²; coaptation distance 1.37 mm) Fig. 17.9. The right ventricle was dilated (end-diastolic diameter 57 mm) and a dysfunction was present (TAPSE 13 mm; tricuspid annulus systolic velocity (S-TDI) 8 cm/s) (Figs. 17.9 and 17.10). The systolic pulmonary pressure was 50 mmHg. The right atrium was severely enlarged (550 mL) (Fig. 17.10).

Giving this situation an echo-dobutamine test was performed to asses the right ventricle contractile reserve. Using a dobutamine dose up to 15 µg/kg/min an increase in right ventricle function was observed (TAPSE 19 mm; S-TDI 11 cm/s).

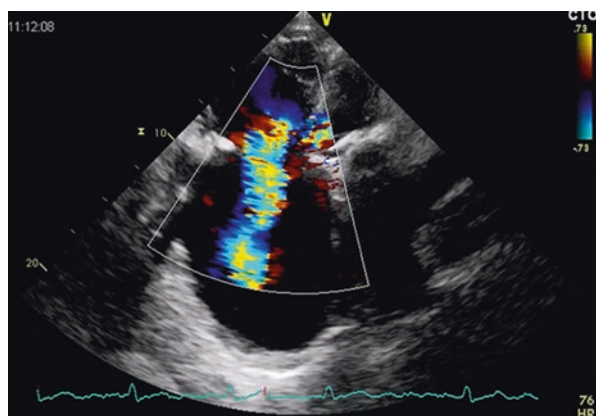


Fig. 17.9 Echocardiographic image showing severe tricuspid regurgitation

Fig. 17.10 Echocardiographic image showing severe enlargement of the right atrium

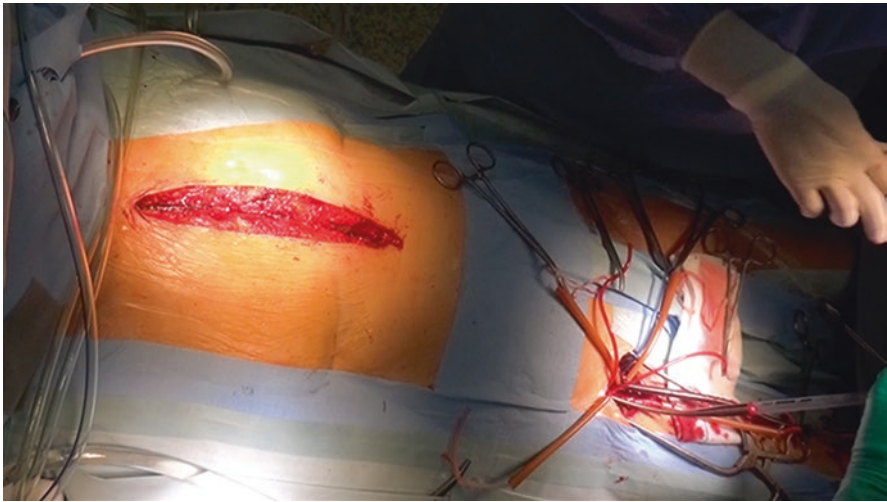
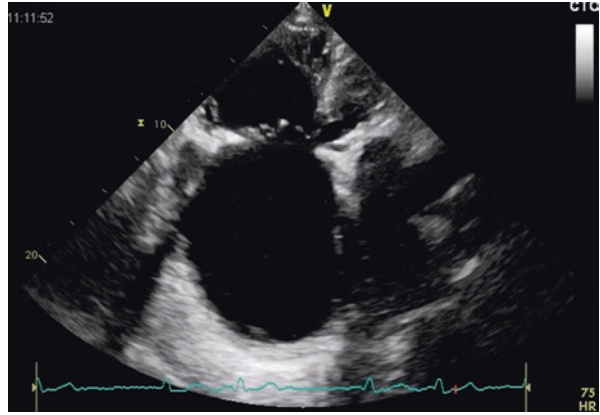


Fig. 17.11 Groin vessels cannulation to establish cardio-pulmonary bypass

A surgical beating heart tricuspid bio-prosthesis implantation with preservation of native tricuspid valve apparatus was considered the best option.

In order to minimize tissue dissection and postoperative bleeding, peripheral arterial and vein cannulation for cardiopulmonary bypass with vacuum assisted drainage was used (Fig. 17.11). After median re-sternotomy, the inferior and superior venae cavae were not isolated and left unsnared. Only the right atrium was identified and opened through the pericardium (Fig. 17.12). The aorta was not cross-clamped and the heart was left beating in order to preserve the right ventricular function.

Fig. 17.12 Intraoperative image showing dissection of the adhesions limited to the right atrium which is opened through the pericardium

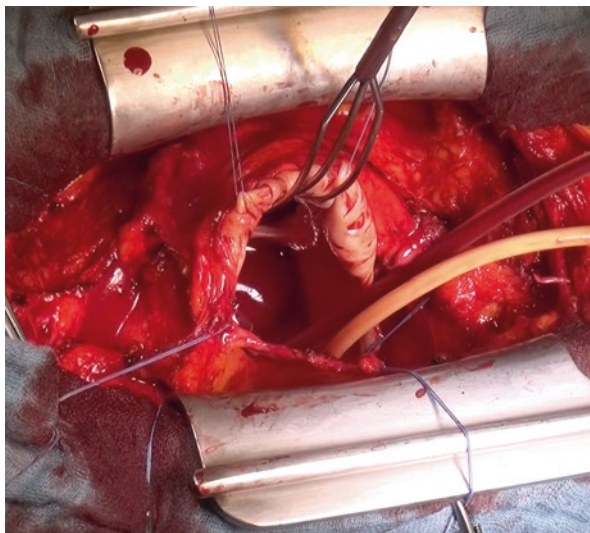
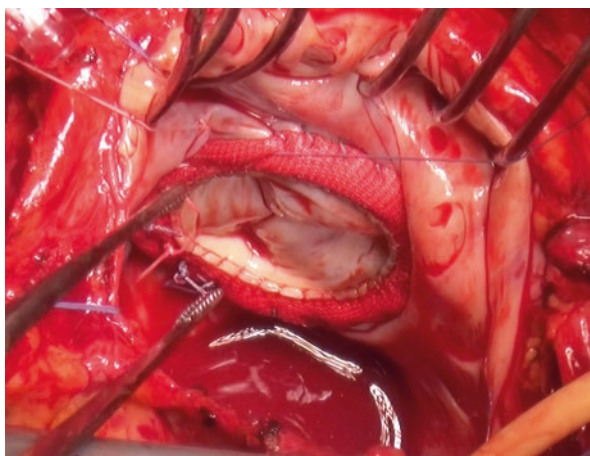


Fig. 17.13 Standard technique to implant a bio-prosthesis in tricuspid position



The tricuspid valve was not excised. The bio-prosthesis was implanted using pledget sutures only at the level of the septal leaflet, and two continuous 2-0 Ti-cron sutures were used for the remaining circumference of the orifice with the purpose of reducing cardiopulmonary bypass time (Fig. 17.13).

By adopting this technique, the post-operative course was uneventful and the patient was discharged on sixth post-operative day.

This approach, in our experience, is associated with reasonable hospital mortality and satisfactory late survival despite the seriousness of the pre-operative condition of these kind of patients [29].

References

1. Guiraudou GM, Ofiesh AG, Kaushik R. Extended vertical translatorial septal approach to the mitral valve. *Ann Thorac Surg.* 1991;52:1058–62.
2. Vahanian A, Alfieri O, Andreotti F, Antunes MJ, Barón-Esquivias G, Baumgartner H, Borger MA, Carrel TP, Mde B, Evangelista A, Falk V, Iung B, Lancellotti P, Pierard L, Price S, Schäfers H, Schuler G, Stepinska J, Swedberg K, Takkenberg J, Otto VOU, Windecker S, Zamorano JL, Zembala M. Guidelines on the management of valvular heart disease (version 2012). *Eur Heart J.* 2012;33:2451–96.
3. De Bonis M, Taramasso M, Lapenna E, Alfieri O. Management of tricuspid regurgitation. *F1000 Prime Rep.* 2014;6:58.
4. Kay JH, Maselli-Campagna G, Tsuji KK. Surgical treatment of tricuspid insufficiency. *Ann Surg.* 1965;162:53–8.
5. De Vega NG. La anuloplastia selectiva, regulable y permanente. Una técnica original para el tratamiento de la insuficiencia tricúspide. *Rev Esp Cardiol.* 1972;25:555–6.
6. Antunes MJ, Girdwood RW. Tricuspid annuloplasty: a modified technique. *Ann Thorac Surg.* 1983;35(6):676–8.
7. Carpentier A, Deloche A, Dauptain J, et al. A new reconstructive operation for correction of mitral and tricuspid valve disease. *J Thorac Cardiovasc Surg.* 1971;61:1–13.
8. Carpentier A, Deloche A, Hanania G, Forman J, Sellier P, Piwnica A, Dubost C, McGoon DC. Surgical management of acquired tricuspid valve disease. *J Thorac Cardiovasc Surg.* 1974;67:53–65.
9. Fukuda S, Saracino G, Matsumura Y, et al. Three-dimensional geometry of the tricuspid annulus in healthy subjects and in patients with functional tricuspid regurgitation: a real-time, 3-dimensional echocardiographic study. *Circulation.* 2006;114(1 Suppl):I492–8.
10. Dreyfus GD, Raja SG, John Chan KM. Tricuspid leaflet augmentation to address severe tethering in functional tricuspid regurgitation. *Eur J Cardiothorac Surg.* 2008;34(4):908–10.
11. Alfieri O, De Bonis M, Lapenna E, Agricola E, Quarti A, Maisano F. The “clover technique” as a novel approach for correction of post-traumatic tricuspid regurgitation. *J Thorac Cardiovasc Surg.* 2003;126(1):75–9.
12. Lapenna E, De Bonis M, Verzini A, La Canna G, Ferrara D, Calabrese MC, Taramasso M, Alfieri O. The clover technique for the treatment of complex tricuspid valve insufficiency: midterm clinical and echocardiographic results in 66 patients. *Eur J Cardiothorac Surg.* 2010;37(6):1297–303.
13. McCarthy PM, Bhudia SK, Rajeswaran J, Hoercher KJ, Lytle BW, Cosgrove DM, Blackstone EH. Tricuspid valve repair: durability and risk factors for failure. *J Thorac Cardiovasc Surg.* 2004;127:674–85.
14. Navia JL, Nowicki ER, Blackstone EH, Brozzi NA, Nento DE, Atik FA, Rajeswaran J, Gillinov AM, Svensson LG, Lytle BW. Surgical management of secondary tricuspid valve regurgitation: annulus, commissure, or leaflet procedure? *J Thorac Cardiovasc Surg.* 2010;139:1473–1482.e5.
15. Ghanta RK, Chen R, Narayanasamy N, McGurk S, Lipsitz S, Chen FY, Cohn LH. Suture bicuspidization of the tricuspid valve versus ring annuloplasty for repair of functional tricuspid regurgitation: midterm results of 237 consecutive patients. *J Thorac Cardiovasc Surg.* 2007;133:117–26.
16. Matsuyama K, Matsumoto M, Sugita T, Nishizawa J, Tokuda Y, Matsuo T, Ueda Y. De Vega annuloplasty and Carpentier-Edwards ring annuloplasty for secondary tricuspid regurgitation. *J Heart Valve Dis.* 2001;10(4):520.
17. Tang GH, David TE, Singh SK, Maganti MD, Armstrong S, Borger MA. Tricuspid valve repair with an annuloplasty ring results in improved long-term outcomes. *Circulation.* 2006;114:1577–81.
18. Nath J, Foster E, Heidenreich PA. Impact of tricuspid regurgitation on long-term survival. *J Am Coll Cardiol.* 2004;43:405–9.

19. Fukuda S, Gillinov AM, McCarthy PM, Matsumura Y, Thomas JD, Shiota T. Echocardiographic follow-up of tricuspid annuloplasty with a new three-dimensional ring in patients with functional tricuspid regurgitation. *J Am Soc Echocardiogr.* 2007;20:1236–42.
20. Kaplan M, Kut MS, Demirtas MM, Cimen S, Ozler A. Prosthetic replacement of tricuspid valve: bioprosthetic or mechanical. *Ann Thorac Surg.* 2002;73:467–73.
21. Hwang HY, Kim KH, Kim KB, Ahn H. Propensity score matching analysis of mechanical versus bioprosthetic tricuspid valve replacements. *Ann Thorac Surg.* 2014;97:1294–9.
22. Ohata T, Kigawa I, Tohda E, Wanibuchi Y. Comparison of durability of bioprostheses in tricuspid and mitral positions. *Ann Thorac Surg.* 2001;71(5 Suppl):S240–3.
23. Filsoufi F, Anyanwu AC, Salzberg SP, et al. Long-term outcomes of tricuspid valve replacement in the current era. *Ann Thorac Surg.* 2005;80:845.
24. Songur CM, Simsek E, Ozen A, Kocabeyoglu S, Donmez TA. Long term results comparing mechanical and biological prostheses in the tricuspid valve position: which valve types are better—mechanical or biological prostheses? *Heart Lung Circ.* 2014;23(12):1175–8.
25. Liu P, Qiao WH, Sun FQ, Ruan XL, Ai Shirbini M, Hu D, Chen S, Dong NG. Should a mechanical or biological prosthesis be used for a tricuspid valve replacement? A meta-analysis. *J Card Surg.* 2016;31(5):294–302.
26. Shapira Y, Sagie A, Jortner R, Adler Y, Hirsch R. Thrombosis of bileaflet tricuspid valve prosthesis: clinical spectrum and the role of non-surgical treatment. *Am Heart J.* 1999;137:721–5.
27. Rizzoli G, Vendramin I, Nesseris G, Bottio T, Guglielmi C, Schiavon L. Biological or mechanical prostheses in tricuspid position? A meta-analysis of intra-institutional results. *Ann Thorac Surg.* 2004;77:1607–14.
28. TH O, Wang TK, Sidhu K, Haydock DA. Isolated tricuspid valve surgery at a single centre: the 47-year Auckland experience, 1965-2011. *Interact Cardiovasc Thorac Surg.* 2014;18(1):27–32.
29. Leviner DB, Medalion B, Baruch I, Sagie A, Sharoni E, Fuks A, Aravot D, Sharony R. Tricuspid valve replacement: the effect of gender on operative results. *J Heart Valve Dis.* 2014;23(2):209–15.
30. Buzzatti N, Iaci G, Taramasso M, Nisi T, Lapenna E, De Bonis M, Maisano F, Alfieri O. Long-term outcomes of tricuspid valve replacement after previous left-side heart surgery. *Eur J Cardiothorac Surg.* 2014;46:713–9.
31. Robbins MJ, Frater RWM, Soeiro R, Frishman WH, Strom JA. Influence of vegetation size on clinical outcome of right-sided infective endocarditis. *Am J Med.* 1986;80:165–71.
32. Wilson LE, Thomas DL, Astemborski J, Freedman TL, Vlahov D. Prospective study of infective endocarditis among injection drug users. *J Infect Dis.* 2002;185:1761–6.
33. The Endocarditis Working Group of the International Society of Chemotherapy, Petterson G, Carbon C. Recommendations for the surgical treatment of endocarditis. *Clin Microbiol Infect.* 1998;4(Suppl 3):S34–46.
34. Celermajer DS, Cullen S, Sullivan ID, Spiegelhalter DJ, Wyse RK, Deanfield JE. Outcome in neonates with Ebstein’s anomaly. *J Am Coll Cardiol.* 1992;19:1041–6.
35. Danielson GK, Fuster V. Surgical repair of Ebstein’s anomaly. *Ann Surg.* 1982;196:499.
36. Dearani JA, O’Leary PW, Danielson GK. Surgical treatment of Ebstein’s malformation: state of the art in 2006. *Cardiol Young.* 2006;16:S12–20.
37. Carpentier A, Chauvaud S, Mace L, Relland J, Mihaileanu S, Marino JP, et al. A new reconstructive operation for Ebstein’s anomaly of the tricuspid valve. *J Thorac Cardiovasc Surg.* 1988;96:92.
38. da Silva JP, Baumgratz JF, da Fonseca L, Franchi SM, Lopes LM, Tavares GM, et al. The cone reconstruction of the tricuspid valve in Ebstein’s anomaly. The operation: early and midterm results. *J Thorac Cardiovasc Surg.* 2007;133:215–23.
39. Brown ML, Dearani JA, Danielson GK, Cetta F, Connolly HM, Warnes CA, Li Z, Hodge DO, Driscoll DJ. Functional status after operation for Ebstein anomaly: the Mayo Clinic experience. *J Am Coll Cardiol.* 2008;52(6):460–6.
40. Chauvaud S, Berrebi A, d’Attellis N, Mousseaux E, Hernigou A, Carpentier A. Ebstein’s anomaly: repair based on functional analysis. *Eur J Cardiothorac Surg.* 2003;23(4):525–31.

41. Danielson GK, Driscoll DJ, Mair DD, Warnes CA, Oliver WC Jr. Operative treatment of Ebstein's anomaly. *J Thorac Cardiovasc Surg.* 1992;104:1195.
42. Caplin ME, Buscombe JR, Hilson AJ, Jones AL, Watkinson AF, Burroughs AK. Carcinoid tumour. *Lancet.* 1998;352(9130):799–805.
43. Bhattacharyya S, Davar J, Dreyfus G, Caplin ME. Carcinoid heart disease. *Circulation.* 2007;116(24):2860–5.
44. Pellikka PA, Tajik AJ, Khandheria BK, Seward JB, Callahan JA, Pitot HC, Kvols LK. Carcinoid heart disease. Clinical and echocardiographic spectrum in 74 patients. *Circulation.* 1993;87(4):1188–96.
45. Mokhles P, van Herwerden LA, de Jong PL, de Herder WW, Siregar S, Constantinescu AA, van Domburg RT, Roos-Hesselink JW. Carcinoid heart disease: outcomes after surgical valve replacement. *Eur J Cardiothorac Surg.* 2012;41(6):1278–83.
46. Fukuda S, Song J, Gillinov AM, McCarthy PM, Daimon M, Kongsarepong V, Thomas JD, Shiota T. Tricuspid valve tethering predicts residual tricuspid regurgitation after tricuspid annuloplasty. *Circulation.* 2005;111:975–9.

Chapter 18

Transcatheter Interventions for Tricuspid Regurgitation: Rationale, Overview of Current Technologies, and Future Perspectives

Mohammad Abdelghani, Joachim Schofer, and Osama I. Soliman

Abstract Tricuspid regurgitation (most commonly functional) is a challenging therapeutic target in many patient subgroups such as patients with prior left-side valve surgery, congenital heart disease, cardiac transplantation, or heart failure with intractable systemic venous congestion. In these conditions, and others, tricuspid regurgitation is associated with decreased quality of life and survival, but its surgical management is also associated with a considerable risk, especially if considered late in the disease course. Many transcatheter approaches have been extended from the mitral valve (e.g. some annuloplasty and clipping repair systems) or specifically designed to adapt to the tricuspid valve and include, in addition to repair, orthotopic and heterotopic tricuspid valve implantation options. Most of these transcatheter technologies are still in early clinical feasibility stage, but the candidate patient population is enormous and has limited surgical and pharmacological options.

Keywords Tricuspid valve • Regurgitation • Transcatheter • Percutaneous • Minimally-invasive

M. Abdelghani, M.D., M.Sc.
Department of Cardiology, The Academic Medical Center, University of Amsterdam,
Amsterdam, The Netherlands

J. Schofer, M.D., Ph.D.
Department for Percutaneous Treatment of Structural Heart Disease, Albertinen Heart Center,
Hamburg, Germany

O.I. Soliman, M.D., Ph.D. (✉)
Department of Cardiology, Thoraxcenter, Erasmus MC: University Medical Center
Rotterdam, Rotterdam, The Netherlands
e-mail: o.soliman@erasmusmc.nl

Rationale for Transcatheter Interventions for Tricuspid Regurgitation

Irrespective of the presence of left-side heart disease and/or pulmonary hypertension, tricuspid regurgitation (TR) per se adversely impacts on survival [1, 2]. In spite of this association with mortality, only small proportion of TR patients undergoes tricuspid valve (TV) surgery [3]. Patients with moderate-severe TR, especially those with a history of prior left-side valve surgery [4–8], are often at high-risk and in an advanced disease state when referred for TV surgery. Accordingly, tricuspid surgery carries an operative mortality risk of up to 25% [4–9] and is therefore frequently denied. The gap between the number of patients with predominant high-grade TR and the actual number undergoing TV surgery resulted in a large population of patients that may benefit from a lower risk alternative to surgery [10].

Some subgroups of TR patients represent ideal candidates for less invasive (transcatheter) techniques; due to a high-grade TR (requiring intervention) and a high surgical risk (precluding safe surgical correction of TR). Such subgroups include, but are not limited to the following conditions:

1. Moderate-severe TR is common in patients undergoing **left-side valve surgery** and, when left untreated, independently portends worse symptoms and lower survival [11, 12]. Overall, moderate-severe TR is seen in up to 67% of patients following isolated mitral valve surgery [13–15] and portends worse prognosis [12]. In patients undergoing aortic valve surgery, moderate-severe TR is seen in 15% of cases and persists after aortic valve surgery in 50% of instances [11]. Patients with residual moderate-severe TR after aortic valve surgery have more than 5-fold increased risk of cardiac mortality at 10 years compared to patients with mild or less TR [11]. Patients with severe TR and prior left-side valve surgery are frequently deemed at high or prohibitive operative risk at the time when isolated TV surgery is indicated.
2. Patients with **prior surgical TV repair** (isolated or combined with left-side valve surgery) show a high rate of recurrence of moderate-severe TR (17–24% at 5 years [16, 17]). This residual high-grade TR was shown to portend a poor event-free survival [5]. Those patients are usually denied isolated redo TV surgery until heart failure (HF) becomes intractable and surgical risk is unacceptably high.
3. Moderate-severe TR after cardiac surgery for **adult complex congenital heart disease (CHD)** is associated with an increased risk of death, transplant, or reoperation (hazard ratio = 6.12 [1.84–20.3]) [18]. In the setting of surgery for CHD, concomitant TV annuloplasty is still associated with a considerable rate of residual high-grade TR [19, 20]. Fifty percent of patients who received a surgical TV prosthesis in the setting of CHD surgery require re-replacement within 14 years because of valve-related complications [21]. In the largest series of transcatheter valve-in-valve implantation in the tricuspid position [22], 56% of patients had a CHD as the primary pathology. Accordingly, whether or not TR is addressed during surgery for complex CHD, residual/recurrent TR remains significant. Transcatheter TV intervention is an appealing option for these patients especially those with a history of \geq one sternotomy and, hence, a high surgical risk.

Combination with other transcatheter interventions (e.g. transcatheter pulmonary valve implantation to treat right ventricular outflow tract conduit dysfunction) was shown to be feasible in selected cases [23].

4. Patients with functional TR in the setting of progressive **right ventricular (RV) dysfunction and HF** not responding to optimal medical therapy [24]. Those patients, who might benefit from unloading of their RV, are typically at a late stage in their clinical course and have an extremely high surgical risk.
5. Elderly patients with **long-standing atrial fibrillation (AF)** commonly develop high grade “idiopathic” TR [25, 26], which is characterized by excessive dilation and impaired contractility of the tricuspid annulus [25]. Different from TR secondary to left-side heart disease, TR in these patients is associated with a lower pulmonary artery pressure and a better biventricular function [25], making a significant clinical improvement likely if TR is averted.
6. **Pacemaker/defibrillator lead-induced TV damage** [27] is associated with a high burden of morbidity, especially when high-grade TR develops on top of advanced HF. This damage has been reported in up to 25% of pacemaker/defibrillator recipients [28] and is associated with worse prognosis [29]. Laser lead extraction and leadless pacemaker implantation to free the TV from tethering, followed by TV transcatheter repair have been reported as a successful bail out approach to manage those patients [30].
7. **Post-heart transplantation moderate-severe TR** is common at discharge (>25% in many series [31–34]) regardless of the operative technique used and portends an increased risk of mortality and HF [32, 33, 35]. The incidence of moderate-severe TR dramatically increases (more than doubles in some series [31]) within four years post-transplantation, largely owing to endomyocardial biopsy-related TV damage [31, 34].
8. Similar to patients with a history of prior mitral valve surgery, high-risk patients with severe mitral regurgitation (MR) undergoing **MitraClip percutaneous repair** show a high prevalence of left-untreated TR [36–38]. Increasing TR severity was shown to be associated with failure of functional improvement, higher rates of HF re-hospitalizations, and increased mortality [36–40]. Those patients may benefit from a same-session double-valve transcatheter solution [41]. *Ad-hoc* transcatheter TV repair is another option in patients with prior MitraClip and residual symptomatic high-grade TR. It has also been reported that TR improves in some patients after MitraClip and remains unchanged or deteriorates in others, and that patients who sustain an improvement of TR have a better prognosis [37, 38]. Some baseline and procedural predictors of TR improvement have been identified [37, 38] and can guide the choice between a concomitant vs. staged *ad-hoc* transcatheter mitral and tricuspid repair.
9. Similar to patients with a history of prior aortic valve surgery, the outcome of patients who undergo **transcatheter aortic valve implantation (TAVI)** due to prohibitive/high surgical risk is influenced by concomitant TR. Moderate-severe TR is seen at baseline before TAVI in 13–29% and persists after the procedure in 50–67% of instances [42–45]. Residual moderate-severe TR after TAVI is associated with increased mid- and long-term mortality [42, 43] especially in patients without high grade MR [44] or severe left ventricular systolic dysfunction [45].

Transapical TAVI followed, one week later, by transcatheter TV edge-to-edge repair was recently reported with success in a high-risk patient who had severe aortic stenosis and severe TR, but only mild MR [46].

Anatomical Challenges to Transcatheter Tricuspid Valve Interventions

In the majority of patients with high-grade TR, the mechanism of valve incompetence is annular dilation and leaflet tethering (in the setting of RV dilation). The annulus usually dilates towards the RV free wall (away from the septal leaflet) [47, 48]. Annular dilation is associated with progressive deterioration of the normal saddle-elliptical geometry of the tricuspid valve annulus (TA), which eventually assumes a planar orientation [47] and a circular contour [48]. The volume overload imposed on the RV by progressive TR results in progressive RV enlargement and further annular dilatation and leaflet tethering, which in turn accentuates TR. In the setting of high-grade TR, transcatheter tricuspid valve interventions (TTVIs) are confronted with a set of anatomical/geometrical heralds related to the peculiar anatomy of the TV and to the continuum of geometric adverse remodeling of the TV apparatus and the right heart chambers (Table 18.1 and Fig. 18.1).

Table 18.1 The anatomical and pathophysiological constraints of transcatheter tricuspid valve interventions

-
- Flexibility of the TA and the surrounding myocardium (calcification is rare) counteracts fixation and long-term stability of transcatheter tricuspid valve replacement devices and increases the risk of dehiscence of annuloplasty devices.
-
- The TA is significantly larger than all other valves with an average area of 21 cm² in patients with RV dilation.
-
- The valve is adjacent to important structures including the ostium of the coronary sinus, the AVN and His bundle, the vena cavae, and the right coronary artery (Fig. 1). In surgical repair, direct visualization of the valve apparatus facilitates avoidance of AVN injury (by appropriate positioning of e.g. Kay bicuspidization sutures, De Vega suture annuloplasty and open annuloplasty bands). Such direct visualization is lacking in transcatheter interventions which require a multimodality imaging guidance to minimize the risk of injury of adjacent structures.
-
- The loss of anatomical landmarks under pathologic conditions (right atrial and ventricular dilation) complicates catheter navigation and interferes with proper positioning of repair/replacement devices.
-
- The angulation between the annular plane and the superior and inferior venae cavae complicates the transvenous access.
-
- The RV is thin-walled and the risk of device entanglement in the subvalvular region is high due to the presence of complex subvalvular chordal attachments and RV trabeculations and muscle bands. These factors preclude transapical access.
-
- Pacemaker/defibrillator leads might interfere with device delivery, deployment, and/or function.
-
- The low pressure and slow flow in the right heart chambers might provoke device thrombosis.
-

AVN atrio-ventricular node, RV right ventricle, TA tricuspid annulus

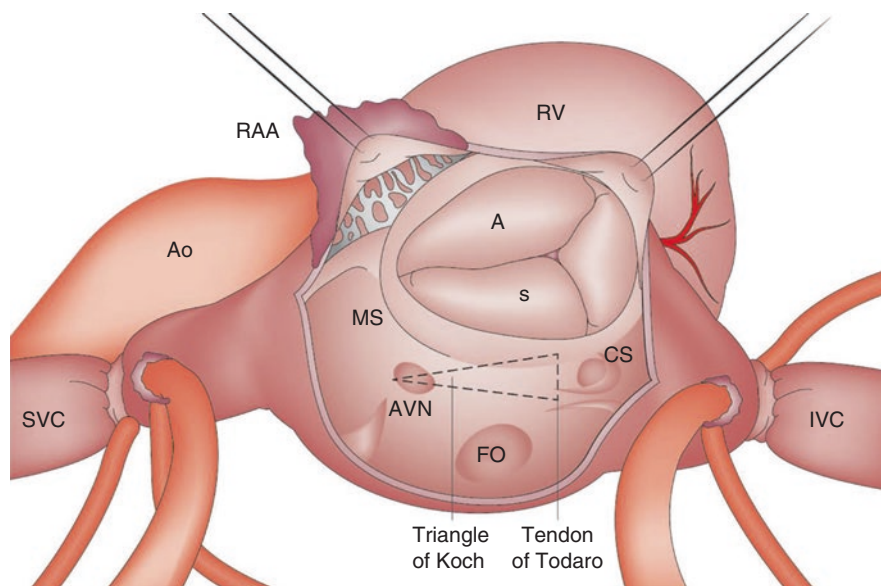


Fig. 18.1 Important structures adjacent to the tricuspid valve apparatus (as seen in a surgical view through a standard right atriotomy). Reproduced with permission from Shinn et al. [68]. *A* anterior, *Ao* aorta, *AVN* atrioventricular node, *CS* coronary sinus, *FO* foramen ovale, *IVC* inferior vena cava, *MS* membranous septum, *P* posterior, *RAA* right atrial appendage, *RV* right ventricle, *S* septal, *SVC* superior vena cava. Figure 2. Approaches for transcatheter tricuspid valve interventions

Approaches for Transcatheter Tricuspid Valve Interventions

Although relatively recently introduced, many approaches are now available for TTVI and are under preclinical/clinical evaluation. Table 18.2 and Figure 18.2 summarize these approaches.

Orthotopic Valve Implantation

Native Tricuspid Valve Replacement

Dedicated Transcatheter TV Bioprosthesis

Boudjemline et al. developed a transcatheter bioprosthetic valve dedicated for fixation to the native TA [49]. The self-expandable double-disc nitinol stent consisted of two flat disks (spontaneous diameter = 40 mm) and a tubular portion (spontaneous diameter = 18 mm), with an overall length of 15 mm when deployed. The whole device is braided from a single nitinol wire (i.e. all parts are connected in one unit). Animal implantations were performed through the right jugular vein and deployment is similar to devices for closure of atrial septal defects (RV disk deployment

Table 18.2 Approaches for of transcatheter tricuspid valve interventions

TV implantation:

1) Orthotopic:

- a) In native TV (dedicated and non-dedicated devices)
- b) In surgical bioprosthesis or in surgical annuloplasty ring

2) Heterotopic (vena caval):

- a) Dedicated self-expanding caval valves
- b) Off-label balloon-expandable transcatheter heart valves

TV repair:

1) Annular reduction/remodeling devices:

- a) The Mitralign device
- b) The TriCinch system
- c) The Millipede annular ring
- d) The transatrial intrapericardial tricuspid annuloplasty (TRAIPTA) device
- e) The Cardiac Implants annuloplasty device

2) Coaptation devices:

- a) Regurgitant orifice occupation (the FORMA Repair System and the TV Occluder device)
- b) Edge-to-edge repair (the MitraClip device)

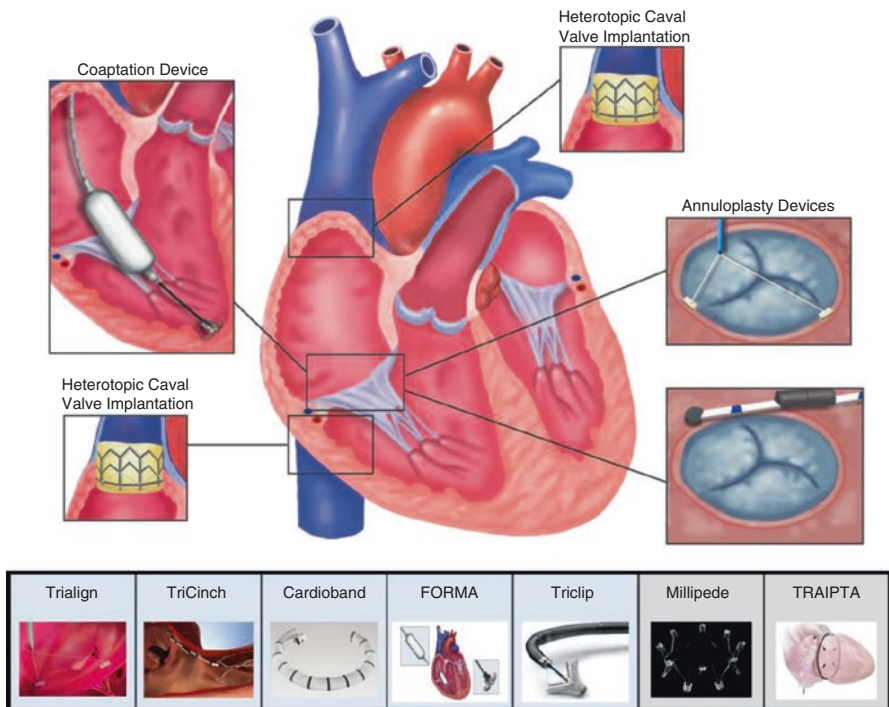


Fig. 18.2 Examples of transcatheter repair and, heterotopic, valve implantation approaches to treat tricuspid regurgitation. In the lower panel, different examples of transcatheter repair devices are displayed. Reproduced with permission from Rodés-Cabau et al. [24] and Latib et al. *J Am Coll Cardiol.* 2017;11;69:1807–1810.

and traction against the TA, followed by deployment of the leaflet-containing tubular part, and finally the atrial disk). In eight ewes (maximum TA diameter: average, 30 mm; range, 27–35 mm), deployment was attempted and failed in one (entrapped in the subvalvular apparatus leading to underexpansion) while one prosthesis showed a significant paravalvular leakage [49]. The device was not clinically used.

The GATE™ tricuspid atrioventricular valved stent (NaviGate Cardiac Structures Inc., CA) is another dedicated transcatheter TV bioprosthesis (available in sizes: 30/40, 33/44 and 36/48 mm) which was successfully implanted in an animal model through a beating-heart minimally-invasive surgical and transjugular percutaneous implantation [50]. The first in man implant took place in November 2016 [51].

Non-Dedicated Transcatheter Heart Valve Implantation in the Tricuspid Position

Very few clinical attempts were made to implant a transcatheter heart valve (THV) in the native TA. Kefer et al. reported balloon-expandable aortic THV implantation to replace a native TV in the absence of prosthetic material and radiographic landmarks [52]. Implantation was performed under general anesthesia and extracorporeal membrane oxygenation, through a femoral vein access. Balloon sizing was used to decide the THV size and the TA was pre-stented with two covered stents. Implantation of a 26-mm Sapien valve (Edwards Lifesciences, Irvine, CA) was followed by another 26-mm Sapien (valve-in-valve) implantation due to paravalvular leakage of the first. The clinical and echocardiographic outcomes were favorable up to 5 months.

Transcatheter Valve in Malfunctioning Surgical Bioprosthetic Valve

There are many reports on successful implantation of the self-expanding Melody valve (Medtronic Inc., Minneapolis, Minnesota) and the balloon-expandable Sapien, Sapien XT, and Sapien 3 valves (Edwards Lifesciences, Irvine, CA) in malfunctioning stented [53–55] and stent-less [23] bioprosthetic tricuspid valves. Given the small sizes available for the Melody valve (≤ 22 mm), it has been utilized mainly in children or young adults with CHD. The first implants were done mainly via a transatrial or transjugular access. More recently, the transfemoral access under local anesthesia and fluoroscopic guidance or general anesthesia and transesophageal echocardiography (TEE) guidance was shown to be feasible and safe. Unless the patient has a previously implanted permanent pacemaker, rapid pacing (which is usually needed for valve deployment) is performed by positioning the temporary lead in the left ventricle or in the coronary sinus. Predilatation of the bioprosthesis is not recommended to avoid the risk of leaflet rupture and embolization [56]. Deciding the size of the transcatheter valve to be implanted within the degenerated bioprosthesis, or within the dysfunctioning annuloplasty ring, should be guided by the nominal internal degenerated device area, by multi-modality imaging planning (combining computed tomography and echocardiography), and by balloon-sizing. Due to lower closing pressures, oversizing of the prosthesis is considered to be less crucial in the tricuspid position (as compared to aortic and mitral positions) [56].

A large recently published multicenter series included 152 patients who underwent implantation of a THV within a malfunctioning surgical bioprosthetic valve [22]. Melody valve was used in 94 and Edwards valves in 58 (Sapien in 12, Sapien XT in 41, and Sapien 3 in 5). Procedural success was achieved in 98% of attempts, and freedom from residual TV dysfunction (significant stenosis and/or regurgitation) was achieved in 97%. Five patients (3%) died and one patient underwent TV reintervention (due to valve thrombosis) within 30 days of implantation. During follow up (median: 13.3 months), 17 additional deaths (11%) and 10 TV reinterventions (7%; 2 due to TR, 2 due to TV stenosis, 2 due to combined TR and stenosis, 2 due to multiorgan failure, 1 due to endocarditis, and 1 due to cardiac transplant graft failure) took place. Four patients (all with a Melody valve) were diagnosed with endocarditis and four patients (3 Melody, 1 Sapien) were diagnosed with sterile thrombus or immobility or thickening of the valve.

Transcatheter Valve in Tricuspid Repair Ring

Although fewer cases have been reported than valve-in-valve implantations, transcatheter implantation of tricuspid valve-in-ring was shown to be feasible and safe. There have been reports of implantation of Sapien XT and Melody [57] THVs in Carpentier-Edwards classic and rigid [58] annuloplasty rings through transfemoral [58–60] and transatrial (off-pump through a minithoracotomy) [61] approaches. Some relevant technical considerations are worth mentioning. The ring should be used as a fluoroscopic landmark and paravalvular leak (due to the non-circular landing zone created by the ring, especially the incomplete rings) should always be anticipated and effectively managed [57].

Heterotopic (Vena Caval) Valve Implantation

Implantation of percutaneous valves into the caval veins targets amelioration of the systemic venous congestion without correcting TR itself. Therefore, the risk of progressive RV and right atrial (RA) deterioration, RV failure, and AF persists. Although intracardiac manipulations are not needed and the valve is implanted in a vascular tube rather than in a complex valvular apparatus, fixation of a rigid percutaneous valve within a highly compliant thin-walled vascular tube is challenging. Other challenges include, the large variable diameters of inferior and superior vena cavae (IVC and SVC) in the presence of chronic severe TR and the proximity to the RA and to hepatic veins. Demonstration of pulsatile blood flow and systolic flow reversal in the caval veins are prerequisites for the proper function of the caval valves. Because of existing pacemaker/implantable cardioverter-defibrillator leads in many cases and the lack of evidence of clinically-relevant SVC congestion in most cases, 90% of implants are done in the IVC only. Two currently available technologies involve vena caval valve implantation:

Self-Expanding (Dedicated) Valve

The TricValve (P&F Products & Features Vertriebs GmbH, Vienna, Austria, in cooperation with Braile Biomedica, São José do Rio Preto, Brazil) consists of two separate tri-leaflet pericardial tissue valves which are mounted on a self-expanding nitinol stent [62]. The size ranges from 28 to 43 mm (IVC valve) or 38 mm (SVC valve). The upper segment of the IVC valve protrudes into the RA while the lower segment is located above the diaphragm to avoid occlusion of the hepatic veins. The SVC valve stent has a funnel-shaped design to fit to the superior cavo-atrial junction. Both IVC and SVC valves are delivered transfemorally through a dedicated flexible catheter. So far, clinical implantations are limited to compassionate use in a few patients [63, 64]. In a patient who was followed up for 12 months after implantation, the functional status was significantly improved and the clinical signs of right-side HF were completely resolved, while echocardiography revealed excellent valve function, unchanged position, and no paravalvular leakage [64].

Balloon-Expandable Transcatheter Heart Valves

Off-label clinical use of Edwards Sapien, Sapien XT or Sapien 3 valves implanted into the cavo-atrial junction has been reported [65, 66]. The large diameter of the caval veins in the presence of severe chronic TR, the lack of calcification, and the confluence of hepatic veins preclude direct implantation and require pre-stenting of the landing zone. In cases with markedly dilated caval veins, minimally-invasive surgical banding can help reduce the lumen diameter by wrapping the vein with a longitudinally opened Gore-Tex prosthesis simultaneously with balloon inflation within the vein to control lumen reduction [65]. In a small case series, valve function remained excellent with no transvalvular or paravalvular regurgitation up to 30 days after implantation. All patients experienced an improvement of their dyspnea and of the clinical signs of systemic venous congestion, as well as improvement of RV function, RV and RA volumes, and the diameters of the hepatic veins [66].

Transcatheter Tricuspid Valve Repair

Annular Reduction/Remodeling Devices

Understanding the mechanism of incompetence in functional TR (basically, annular dilation and remodeling) and the favorable outcome of annuloplasty compared to other surgical repair techniques of TR [68], jointly led to a significant interest in developing transcatheter annuloplasty techniques developing transcatheter annuloplasty techniques to treat TR. These techniques generally reproduce the established surgical annuloplasty approaches, e.g. Kay bicuspidization (Mitralign) and ring annuloplasty (Millipede). The ideal annuloplasty device to treat high-grade

functional TR should restore the normal three dimensional elliptical shape of the TA to reduce leaflet stress and tethering. It should tackle the selective propensity of the anterior-posterior- commissure sector of the annulus to remodel (along the RV free wall) and also be 'open' at its septal- leaflet sector to spare the atrio-ventricular conduction system [67]. Ideally, it should also be flexible maintaining annular dynamicity and preventing ring dehiscence [67].

The Mitralign/Trialign Device

The Mitralign device (Mitralign, Tewksbury, Massachusetts) is a percutaneous annuloplasty system that reproduces the Kay bicuspidization surgical procedure [69], which converts an incompetent tricuspid into a competent bicuspid valve by plicating the posterior leaflet. Mitralign system comprises an articulating wire delivery catheter, a pledget catheter (preloaded with 4×8 mm polyester pledgets), and a stainless steel plication lock. Transjugular access with two sheaths is obtained, and the steerable catheter is advanced across the TV into the RV and is articulated under the annulus to position its tip beneath either the anteroposterior or the septoposterior commissure. An insulated radiofrequency wire is advanced to burn through the annulus (2–5 mm from the hinge point of the leaflet) into the RA and is then externalized and replaced by the pledget delivery catheter. Two pledgets (2.4–2.8 cm apart) are usually released and are cinched onto the annulus and finally are brought together using the plication lock (Fig. 18.3). Right coronary artery wiring is performed at the start of the procedure and angiography is performed at its end [70]. In a number of published clinical implantations, the procedure resulted in a significant reduction in annular circumference (24%) [71] and area (57%) [72] and effective regurgitant orifice area (53%) [72]. Although immediate complete elimination of TR was reported in some cases [71], acute recurrence due to pledget dehiscence has also been observed in some cases [71]. The importance of the risk of pledget dehiscence and TR recurrence was further confirmed by the early results of the Percutaneous Tricuspid Valve Annuloplasty System [PTVAS] for Symptomatic Chronic Functional Tricuspid Regurgitation (SCOUT) study, where three patients out of 15 (20%) had a single-pledget annular detachment within 30 days after repair [70]. The study included 13 females and two males, with an average age of 74 years who had moderate-severe functional TR (average vena contracta diameter, 13 mm). Patients with severe pulmonary hypertension or severe right or left ventricular systolic dysfunction were excluded. Two thirds of patients had prior mitral valve intervention and two thirds had AF. Immediate procedural success was achieved in all 15 cases, with no procedural death or major complication with the exception of one case of right coronary artery compromise (treated with a stent placement). At 30 days, three patients had an echocardiographic evidence of single pledget detachment and showed no improvement of TR severity, but required no reintervention. In the remaining 12 patients, tricuspid annulus area (12.3 ± 3.1 cm² vs. 11.3 ± 2.7 cm², $p = 0.019$) and TR vena contracta diameter (13 ± 4 vs. 10 ± 3 mm, $p = 0.022$) were modestly reduced while the quality of life was significantly improved at 1 month after repair.

Although technically challenging with risk of dehiscence especially with inadequate size or unfavorable tissue quality of the posterior annular shelf, this device has a

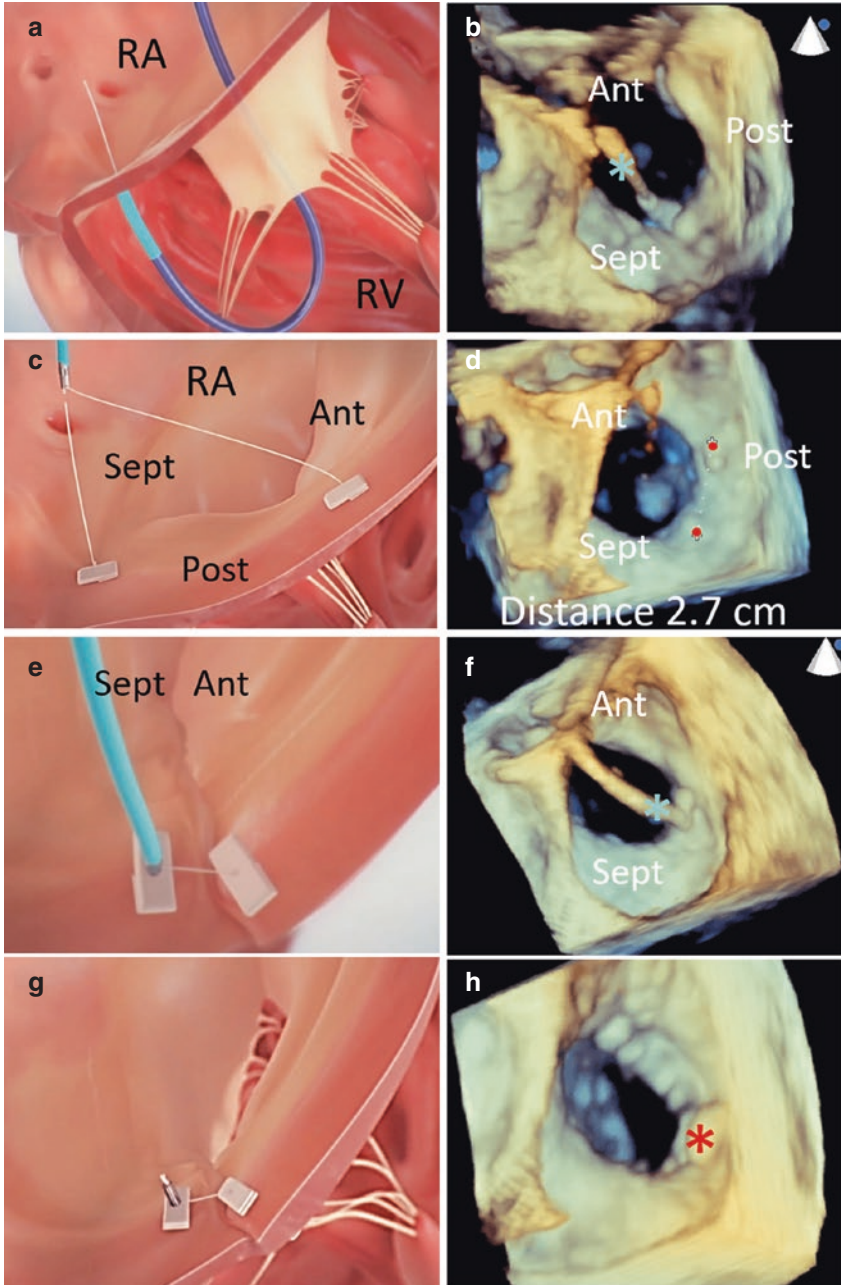


Fig. 18.3 Summary of the procedural steps of the Trialign transcatheter annuloplasty technique: Through a deflectable guide catheter, a wire delivery catheter followed by an insulated radiofrequency wire (a) and pledgeted sutures (c) are advanced through the tricuspid annulus. The 2 sutures are plicated and locked (e) and then cut leaving a bicuspidized valve (g). b, d, f, and h are 3D transesophageal echocardiographic images corresponding to the a, c, e, and g cartoons. Reproduced with permission from Hahn et al. [70]. *Ant* anterior, *Post* posterior, *RA* right atrium, *RV* right ventricle, *Sept* septum

small footprint and largely preserves the underlying anatomy and the procedure can be customized/repeated to address different severities of annular dilatation. Moreover, a controlled 'partial' correction of TR is possible, thus avoiding the acute hemodynamic burden on the RV of a sudden complete correction of a severe long-standing TR.

The TriCinch System

The TriCinch system (4Tech Cardio, Galway, Ireland) consists of a Dacron band connecting a corkscrew anchor attached anterior to the TV annulus (typically between the anteroposterior commissure and the mid-point of the anterior leaflet) to a self-expanding subhepatic IVC stent. By pulling the anchor towards the IVC, by means of the Dacron band, the TA antero-posterior and antero-septal dimensions are remodeled, and the tension is maintained by fixation of the stent in the IVC. The stent is 60 mm long and is available in a range of diameters (from 27 to 43 mm) to allow for adequate oversizing in the IVC [73]. The device is retrievable and the procedure is relatively easy to perform. Right coronary artery wiring and *ad-hoc* angiography are usually needed to exclude coronary injury. Hemopericardium, failure of implantation, and anchoring system detachment lead to failure of the procedure in up to 50% of attempts [56].

This approach of TA remodeling, changes the geometry rather than reduces the size of the annulus, leading to an unpredictable extent of TR reduction. In one case report, TA septolateral diameter decreased from 41 mm to 38 mm, and TR severity improved from 4+ to 3+ [73]. In another case report, severe TR was reduced to mild, with a 50% reduction of the effective regurgitant orifice area [41]. In a third case [74], severe TR was reduced to mild, and the procedure was performed under sedative anesthesia and intracardiac and transthoracic (but not transesophageal) echocardiographic guidance.

The Transatrial Intrapericardial Tricuspid Annuloplasty (TRAIPTA) Device

TRAIPTA is an external (epicardial) nitinol annuloplasty loop which is wrapped around the atrioventricular groove. The pericardial space is reached via a puncture in the RA appendage, which is closed with a percutaneous occluder device at the end of the procedure. The loop is passed around the cardiac apex and then retracted until it encircles the atrioventricular groove, and is eventually tightened using a wire within it [75]. The TRAIPTA device has not been used in humans. Animal studies were performed under general anesthesia and mechanical ventilation and the suture was tightened under guidance by real-time magnetic resonance imaging and intracardiac echocardiography [75].

Postimplantation magnetic resonance imaging demonstrated a 49% reduction of the septolateral TA diameter, a 31% reduction in the anteroposterior diameter, and a 59% reduction of TA area. The effect on the mitral valve annulus was modest (15% diameter reduction), and a non-hemodynamically significant pericardial effusion that resolved spontaneously was seen after all swine implantations [75].

Reproducing these results in humans is, however, doubtful. The spatial orientation of the tricuspid and mitral annuli relative to the atrioventricular groove is different in humans than in swine and is variable from patient to patient. In most human

cases, at least one epicardial coronary artery crosses the projected course of the TRAIPTA implant [75]. The high RA pressure in patients with long standing TR may increase the risk of tamponade, and pericardial adhesions from previous cardiac surgery may preclude safe epicardial access in many patients [10].

Surgical-Like Annuloplasty Rings

This is a group of transcatheter annuloplasty rings that aim at reproducing the surgical ring annuloplasty approach. In addition to the proven superiority of ring annuloplasty over other approaches of surgical TV repair [17], this approach has the potential of combination with a coaptation repair procedure (in the same session or *ad-hoc*) and allows for and facilitates subsequent valve-in-ring implantation; by acting as a landmark and by securing transcatheter valve fixation. Flexible and adjustable complete (Millipede™ [76] and Cardiac Implants™ [77]) and incomplete (CardioBand™ [78]) annular rings are at different stages of clinical testing.

The Cardiac Implants annuloplasty device is implanted on the atrial surface of the tricuspid annulus and is awaited to heal for 6–8 weeks by tissue reaction. After that, the device can be cinched to reduce the TA diameter or be used as a platform for valve-in-ring implantation [77].

Coaptation Devices

In addition to annular dilatation, leaflet tethering and malcoaptation are the second most important mechanisms of functional TR. Two basic concepts make the platform for the coaptation devices, occupation of the regurgitant orifice and leaflet edge-to-edge clipping.

The FORMA Repair System and the TV Occluder Device

The transcatheter Forma Repair System (Edwards Lifesciences, Irvine, California) is designed to reduce TR by occupying the regurgitant orifice and providing a surface for native leaflets coaptation. It is composed of a rail, which is anchored at the apex of the RV, and a spacer, which serves as the coaptation element. The spacer consists of a foam-filled polymer balloon and is currently available in two sizes (12 and 15 mm), with a length of 42 mm. The spacer expands passively within the vascular system to its final size by air through eight vents in its shaft. Access is via the left subclavian or axillary vein, which should be sizable to accommodate a large introducer. Following achievement of a satisfactory degree of TR reduction, the device is locked within the subclavian region, and extra rail length is placed into a subcutaneous pocket. The entire device is fully retrievable during all stages of the procedure. Seven compassionate clinical implants have been published, all the seven had residual moderate TR at 30 days post-repair [79]. It should be noted however that the echocardiographic assessment of residual TR after spacer implantation between the leaflets is challenging, given the resulting distortion of the regurgitant orifice and the vena contracta.

The TV Occluder Device (Cleveland Clinic Foundation, Cleveland, Ohio) is utilizing the same concept on which the Forma system is based; occupation (and consequently reduction) of the regurgitant orifice area and facilitating leaflet coaptation [80]. Similar to the Forma device, the TV Occluder system has a proximal end that is left in a subcutaneous pocket (similar to a pacemaker). This allows for an extended potential for control of the degree of the regurgitant orifice occlusion. The distal end of the system consists of a screw that is parked in the RV apex. The occluder itself is made of a nitinol mesh skeleton and an internal membrane of polyester fabric. Small-scale animal studies (through a transjugular approach) show a reasonable degree of TR reduction [81].

The MitraClip Device

Surgical edge-to-edge tricuspid valve plasty was shown to be an effective adjuvant procedure for patients who have severe residual TR after traditional ring repair [82]. The transcatheter MitraClip system (Abbott Vascular, Santa Clara, CA, USA) has been established as an effective treatment of mitral regurgitation in high risk patients [83]. The device is a 4-mm-wide cobalt-chromium, polyester-covered clip that can be opened and closed by control mechanisms on the clip delivery system. Multiple reports of TV transcatheter clipping using the MitraClip system are published [84–88].

In an *ex vivo* model of functional TR in a porcine heart connected to a pulsatile pump, the effectiveness of the edge-to-edge technique using the MitraClip device was tested [89]. Transvenous valve clipping led to an increase in the RV stroke volume without a significant increase in the transvalvular gradient. Procedural success was strongly influenced by the position where the clips were applied (medial vs. commissural) and the pair of leaflets being grasped. Clips that involved the septal leaflet in the medial position were the most effective in restoring the physiological hemodynamics (cardiac output, mean pulmonary pressure, and mean diastolic valve pressure gradient), while those that did not involve the septal leaflet (i.e. grasping the anterior and posterior leaflets) did not reduce TR [89] (Fig. 18.4).

In clinical human cases [84–88], femoral and jugular venous approaches have been used, and clips were deployed at the anteroposterior, anteroseptal, and/or posteroseptal lines of coaptation. Although the technique is simpler than most other TTVIs, two challenges of TV clipping should be considered. First, the acute angle between the IVC and the TA plane makes coaxial positioning difficult. This can be overcome by using the transjugular approach, which is, however, unsuitable for the large sheath in some patients. Secondly, regurgitation can develop at any point along the line of coaptation between the three leaflets of the TV valve. Clipping all three leaflets might be required and increases the risk of inducing valve stenosis. Moreover, more than three leaflets can be identified in many patients.

Open Issues and Future Perspective

While TTVIs are generally promising, there remain several important issues to be addressed:

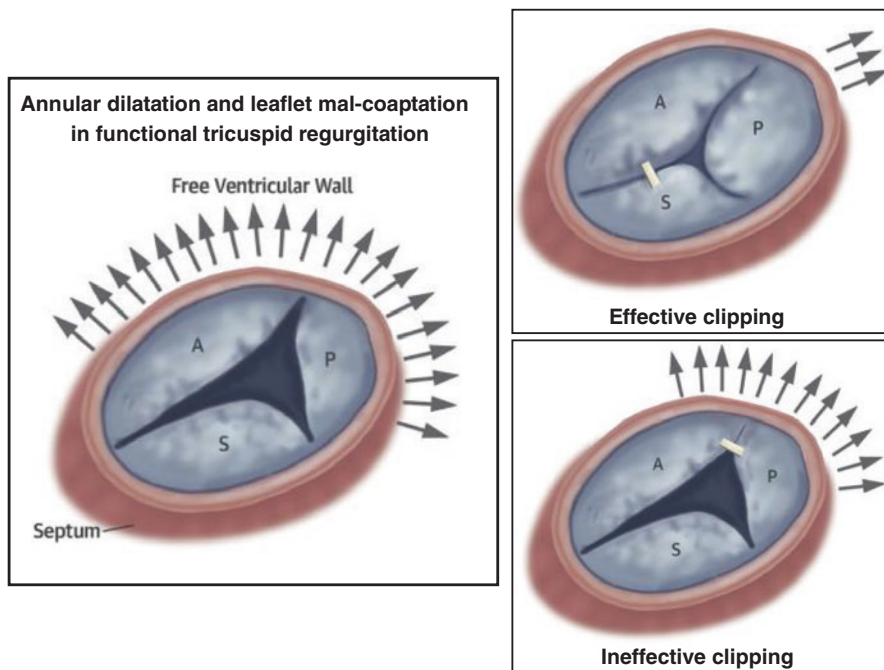


Fig. 18.4 Evaluation of the effectiveness of transcatheter edge-to-edge treatment of functional tricuspid regurgitation in an ex vivo model: (*Left*) In functional tricuspid regurgitation, the tricuspid valve annulus expands more towards the right ventricular free wall (i.e. the anterior (A) and posterior (P) leaflets are pulled (*arrows*) away from the septal (S) leaflet. (*Right upper*) In an ex vivo porcine model of tricuspid regurgitation, the clip is applied to the S and A leaflets (in a medial position) restoring the coaptation lines between all the 3 leaflet-pairs, with consequent restoration of valve competence. (*Right lower*) The clip is applied to the A and P leaflets (in a medial position) leaving the gap between A-P and S leaflets unaltered and the regurgitation persistent. (Reproduced and modified from Vismara et al. [89])

Safety Issues

The risk of device thrombosis: Devices in the TV position may be at a significant risk of thrombosis due to the lower intracardiac pressures in the right side of the heart [10]. However, as per practice guidelines, long term anticoagulation is not recommended in patients with surgical bioprosthetic valves, even those present in the caval valve implant of the heart. In the published series of three patients treated with the caval valve implant (Sapien XT) [66], routine anticoagulation was employed and no cases of thrombosis were observed. In the tricuspid valve-in-valve implantation series by McElhinney et al. (n = 152), the proportion of the overall cohort treated with anticoagulation is not reported; however four patients (2.6%) developed severe valve obstruction due to valve thrombosis, 2 while on aspirin, 1 on warfarin, and 1 on both aspirin and warfarin [22]. In patients treated with non-valve replacing TV repair devices such as the Forma, Mitralign, and TriCinch devices, the need for anticoagulation is even less clear. However, all but one patient received anticoagulation in the Forma early feasibility study [79], possibly due to

the high prevalence of AF requiring anticoagulation. Notably, in the feasibility study of the Mitralign device (SCOUT), two thirds of the patients had AF [70]. Although these observations cannot lead to any conclusions, they obviate the need for longitudinal studies that focus on this question. It is important to note that, unlike left-side valve devices where thrombosis typically presents with sudden systemic embolism, right-side valve device thrombosis tends to present with obstructive manifestations. Therefore, a rise in transvalvular velocity and gradient on serial Doppler surveillance should serve as a surrogate marker of device thrombosis. Although echo-Doppler can suspect/detect thrombus formation on a bioprosthetic valve or a coaptation device, this can be more challenging in annuloplasty devices. Whether computed tomographic (CT) scanning can fill the gaps in this surveillance process is not yet investigated.

The risk of endocarditis: The risk of repair device-related infective endocarditis is likely as low as the risk of infective endocarditis in patients with pacemakers [90] in whom infective endocarditis prophylaxis is not recommended [10]. However, the risk in the case of valve replacement (e.g. valve-in-valve) might be considerable, especially when bovine jugular vein is the precursor of the bioprosthetic valve leaflets (e.g. the Melody valve) [22].

Preprocedural Planning and Procedural Guidance

The role of imaging in pre-procedural planning and procedural guidance:

Computed tomography can give a comprehensive assessment of many relevant structures in the setting of TTVI [56]: (a) The TA geometry and size and the localization of the three commissures. (b) The tissue characteristics in the right atrioventricular junction (based on the measurements of the tissue density) allowing differentiation of calcification, epicardial fat, myocardium, and fibrous tissue. (c) The adjacent structures to the TV, including the caval and hepatic veins, the coronary arteries, and the coronary sinus. It is also possible to assess the angle between the caval veins and the TA plane, and the distance between the right coronary artery and the TA. (d) In the setting of caval vein implantation, detailed measurements of IVC and SVC dimensions can be accurately performed. (e) In the setting of valve-in-ring implantation, geometric evaluation of TV surgical annuloplasty rings including size, deformation, and position is possible.

Because of the complexity of the TV anatomy and the need to improve communication and guidance during intervention, it is crucial that both the interventionist and the echocardiographer define before the procedure a limited number of imaging views with conventional orientation and anatomical landmarks [56]. It is also crucial to set a common nomenclature in order to standardize procedural echocardiographic guidance and facilitate communication between the echocardiographer and the interventionist who should both speak the same language [91].

Although 3D transesophageal echocardiography imaging of the TV yields a lower quality images than that of the mitral valve, an “en face” view of the TV from the RA perspective provides an adequate identification of TV leaflets and precise localization of the commissures. This accurate identification of leaflets and commissures is of paramount importance to almost all repair techniques (e.g. Mitralign, TriCinch, and MitraClip) [56]. Intra-cardiac echocardiographic imaging from the

RA provides excellent visualization of the IVC-right atrial junction, tricuspid annulus and relative position of the right coronary artery to the insertion of the TV leaflet, and is superior to transesophageal echocardiography in visualizing the TA in the case of shadowing from prosthetic materials [56].

Echocardiographic assessment of TR severity following device implantation:

Due to the high dependency of TR on loading conditions, periprocedural hemodynamic fluctuations might lead to over/under-estimation of TR. Therefore, although transesophageal echocardiography at the end of the procedure may be superior in image quality, transthoracic echocardiography after the procedure when the patient is awake and the hemodynamics are more stable is probably more dependable in determining the degree of TR reduction. Echocardiographic assessment is also likely to be confounded by TV coaptation devices which may result in a highly eccentric residual TR jet, or fractionation of the jet around the device (e.g. with the MitraClip and Forma devices). New echocardiographic criteria, possibly validated against invasive hemodynamic studies or magnetic resonance imaging, will be needed to accurately assess the degree of residual TR, especially when considering the fact that the goal of many of these techniques is to reduce rather than eliminate TR [10]. Moreover, some techniques (e.g. TriCinch, Cardiac Implants, and MitraClip) provide a completely controlled reduction of TR that needs for guidance an accurate on-line assessment of TR severity.

What Efficacy Endpoints are Suitable for TTVIs Studies?

In general, approval of a new device therapy requires proven long-term efficacy and safety.

Severe TR is characterized by right heart failure syndrome. The latter is characterized by systemic venous congestion and is closely linked to hepatic and renal failure. The hallmark of right heart failure is the reduced quality of life, frequent hospitalization and ultimately hepato-renal syndrome. Although TR is usually reduced by TTVIs from severe to moderate rather than completely corrected, most patients gain a measurable clinical improvement [70, 73, 79, 85, 92]. These clinical gains (e.g. less edema and improved functional status) are probably more important to those patients with long-standing severe TR in the setting of advanced HF where the quality of life and reduced hospitalizations and number of pills are more pertinent to the patients' interest, than a mere survival gain. Therefore, improved symptoms and quality of life, reduced HF hospitalizations, and hepatic and renal functions are considered key clinical components of the efficacy endpoints.

Isolating the clinical impact of TR in the setting of pulmonary hypertension, AF, and left heart pathology is challenging [3]. This is a source of confusion at the time of decision making as whether to intervene to treat severe TR in the setting of multiple and/or advanced cardiopathies. Moreover, the clinical response to a TTVI is again difficult to be judged in the presence of those conditions. This might promote considering surrogate mechanistic endpoints in addition to the clinical endpoints when assessing the efficacy of these interventions. Therefore, imaging evidence of valvular remodeling, such as annular diameter/area reduction and/or leaflet coaptation improvement, and TR severity reduction represent important efficacy measures. Table 18.3 summarizes the ongoing/planned trials of TTVIs which apply different combinations of these endpoints.

Table 18.3 Summary of the ongoing/planned trials of transcatheter tricuspid valve interventions^a

Trial acronym and NCT code	Technology	Manufacturer	Title of the trial	Sponsor	No of patients planned for enrollment	Description	Estimated completion date	Key outcome measure
SCOUT study (NCT02574650)	The Mitralign Percutaneous Annuloplasty System	Mitralign Inc., MA, USA	Early Feasibility of the Mitralign Percutaneous Tricuspid Valve Annuloplasty System for Symptomatic Chronic Functional Tricuspid Regurgitation	Mitralign Inc., MA, USA	30	A prospective, single-arm, multi-center study, enrolling symptomatic patients with chronic functional tricuspid regurgitation in whom left-sided valve surgery is not planned. The study includes 2-years post-implantation follow up.	May 2018	Technical success at 30-days, defined as: freedom from death with successful access, delivery and retrieval of the device delivery system, and deployment and correct positioning of the intended device(s), and no need for additional unplanned or emergency surgery or re-intervention related to the device or access procedure.
PREVENT study (NCT02098200)	TriCinch System	4Tech Cardio, Galway, Ireland	Percutaneous Treatment of Tricuspid Valve Regurgitation With the TriCinch System™	4Tech Cardio, Galway, Ireland	24	A prospective, single-arm, open label, multi-center study enrolling patients with functional symptomatic tricuspid regurgitation (moderate to severe), with annular dilatation greater than 40 mm.	December 2016	Safety: Freedom from major adverse event (death, Q-wave myocardial infarction, cardiac tamponade, cardiac surgery for failed TriCinch implantation, stroke, or septicemia) within 30 days. Performance: Ability to reduce tricuspid regurgitation by at least 1 degree.
TRI-REPAIR study (NCT02981953)	Cardioband Tricuspid	Valtech Cardio Ltd	Tricuspid Regurgitation RePAIR With Cardioband Transcatheter System	Valtech Cardio Ltd	30	A prospective, single-arm, open label, multi-center study enrolling patients with functional symptomatic tricuspid regurgitation (moderate to severe), with annular dilatation greater than 40 mm and pulmonary artery systolic pressure ≤ 60 mmHg.	October 2017	Overall rate of major serious adverse events and serious adverse device effects at 30 days. Successful access, deployment and positioning of the Cardioband device. Change in septolateral dimension intra procedure and at 30 days.

<p>Early feasibility study (NCT02471807)</p>	<p>FORMA Repair system</p>	<p>Edwards Life sciences, Irvine, California</p>	<p>Early Feasibility Study of the Edwards Tricuspid Transcatheter Repair System</p>	<p>Edwards Life sciences, Irvine, California</p>	<p>15</p>	<p>A multi-center, prospective, early feasibility study to measure safety and function of the investigational system as well as up to 3 year clinical outcomes.</p>	<p>December 2016</p>	<p>Procedural Success: Device success and freedom from device or procedure related serious adverse events at 30 days.</p>
<p>SPACER study (NCT02787408)</p>	<p>Repair of Tricuspid Valve Regurgitation Using the Edwards Tricuspid TrAnsCatheter REpair System</p>	<p>Edwards Life sciences, Irvine, California</p>	<p>75</p>	<p>A multi-center, international, prospective, single arm, safety study to assess the safety and device performance of the Edwards Tricuspid Transcatheter Repair System in patients with clinically significant, symptomatic, tricuspid regurgitation who are at high surgical risk for standard tricuspid repair/replacement. Enrolled subjects are to be followed-up at 1 month, 6 months, 1 year and annually for 3 years post-implantation.</p>	<p>September 2017</p>	<p>Cardiac mortality of the as treated cohort at 30 days compared to a literature derived performance goal based on high-risk surgical outcomes for tricuspid regurgitation.</p>		
<p>MitraClip for Severe TR (TVrepair) (NCT02863549)</p>	<p>Mitraclip</p>	<p>Abbott Vascular, Santa Clara, California</p>	<p>Transcatheter Treatment of Severe Tricuspid Regurgitation Using the MitraClip System</p>	<p>Klinikum der Universitaet Muenchen, Munich, Germany</p>	<p>100</p>	<p>A single-center, prospective, single arm study aiming at determining the feasibility in terms of success rate and short-term clinical follow-up at 30 days.</p>	<p>December 2017</p>	<p>TR grade on echocardiography at 1-12 months. Major adverse cardiac and cerebrovascular events at 1-12 months.</p>

(continued)

Table 18.3 (continued)

Trial acronym and NCT code	Technology	Manufacturer	Title of the trial	Sponsor	No of patients planned for enrollment	Description	Estimated completion date	Iry outcome measure
[TRIC-AVAL: RCT] NCT02387697	Edwards Sapien XT or Sapien 3	Edwards Lifesciences, Irvine, California	Treatment of Severe Secondary TRicuspid Regurgitation in Patients With Advanced Heart Failure With CAval Vein Implantation of the Edwards Sapien XT VALve	Charite University, Berlin, Germany	40	A single-center, prospective, single arm study. The purpose of this study is to assess the efficacy and safety of implanting an Edwards Sapien XT Valve into the inferior vena cava and its impact on clinical variables, exercise tolerance and well-being in patients with severe tricuspid regurgitation and signs of right heart failure.	December 2016	Maximum relative VO ₂ uptake at 3 month compared to control group.
[HOVER] NCT02339974			Heterotopic Implantation Of the Edwards-Sapien XT Transcatheter Valve in the Inferior VEna Cava for the Treatment of Severe Tricuspid Regurgitation	Temple University, Philadelphia, USA	30	A prospective, single center, open label, non-randomized safety and feasibility study enrolling patients who have symptomatic severe tricuspid regurgitation and are at extremely high risk for standard tricuspid valve surgery.	January 2017	Procedural success (at 30 days) including both device success and no device/procedure related serious adverse events (all death, all stroke, myocardial infarction, new acute kidney injury grade 3, life threatening bleeding, major vascular complications, pericardial effusion or tamponade requiring drainage, superior vena caval syndrome). Individual patient success (at 1 year) defined as device success and the following: no re-hospitalizations for right sided heart failure, new listing for heart transplant, circulatory mechanical support; KCCQ improvement > 10 vs. baseline and 6 MWT improvement > 50 meters vs. baseline.

^aData from <https://clinicaltrials.gov/>

References

1. Topilsky Y, Nkomo VT, Vatury O, Michelena HI, Letourneau T, Suri RM, et al. Clinical outcome of isolated tricuspid regurgitation. *JACC Cardiovasc Imaging*. 2014;7(12):1185–94.
2. Nath J, Foster E, Heidenreich PA. Impact of tricuspid regurgitation on long-term survival. *J Am Coll Cardiol*. 2004;43(3):405–9.
3. O'Neill WW, O'Neill BP. Transcatheter tricuspid valve intervention: the next frontier. *J Am Coll Cardiol*. 2015;65(12):1196–8.
4. Vassileva CM, Shabosky J, Boley T, Markwell S, Hazelrigg S. Tricuspid valve surgery: the past 10 years from the Nationwide Inpatient Sample (NIS) database. *J Thorac Cardiovasc Surg*. 2012;143(5):1043–9.
5. Kim JB, Jung SH, Choo SJ, Chung CH, Lee JW. Clinical and echocardiographic outcomes after surgery for severe isolated tricuspid regurgitation. *J Thorac Cardiovasc Surg*. 2013;146(2):278–84.
6. Kim YJ, Kwon DA, Kim HK, Park JS, Hahn S, Kim KH, et al. Determinants of surgical outcome in patients with isolated tricuspid regurgitation. *Circulation*. 2009;120(17):1672–8.
7. Kaplan M, Kut MS, Demirtas MM, Cimen S, Ozler A. Prosthetic replacement of tricuspid valve: bioprosthetic or mechanical. *Ann Thorac Surg*. 2002;73(2):467–73.
8. Ratnatunga CP, Edwards MB, Dore CJ, Taylor KM. Tricuspid valve replacement: UK Heart Valve Registry mid-term results comparing mechanical and biological prostheses. *Ann Thorac Surg*. 1998;66(6):1940–7.
9. Filsofi F, Anyanwu AC, Salzberg SP, Frankel T, Cohn LH, Adams DH. Long-term outcomes of tricuspid valve replacement in the current era. *Ann Thorac Surg*. 2005;80(3):845–50.
10. Fender EA, Nishimura RA, Holmes DR. Percutaneous therapies for tricuspid regurgitation. *Expert Rev Med Devices*. 2017;14(1):37–48.
11. Jeong DS, Sung K, Kim WS, Lee YT, Yang JH, Jun TG, et al. Fate of functional tricuspid regurgitation in aortic stenosis after aortic valve replacement. *J Thorac Cardiovasc Surg*. 2014;148(4):1328–1333 e1.
12. Calafiore AM, Gallina S, Iaco AL, Contini M, Bivona A, Gagliardi M, et al. Mitral valve surgery for functional mitral regurgitation: should moderate-or-more tricuspid regurgitation be treated? a propensity score analysis. *Ann Thorac Surg*. 2009;87(3):698–703.
13. Dreyfus GD, Corbi PJ, Chan KM, Bahrami T. Secondary tricuspid regurgitation or dilatation: which should be the criteria for surgical repair? *Ann Thorac Surg*. 2005;79(1):127–32.
14. Porter A, Shapira Y, Wurzel M, Sulkes J, Vaturi M, Adler Y, et al. Tricuspid regurgitation late after mitral valve replacement: clinical and echocardiographic evaluation. *J Heart Valve Dis*. 1999;8(1):57–62.
15. Matsuyama K, Matsumoto M, Sugita T, Nishizawa J, Tokuda Y, Matsuo T. Predictors of residual tricuspid regurgitation after mitral valve surgery. *Ann Thorac Surg*. 2003;75(6):1826–8.
16. Navia JL, Nowicki ER, Blackstone EH, Brozzi NA, Nento DE, Atik FA, et al. Surgical management of secondary tricuspid valve regurgitation: annulus, commissure, or leaflet procedure? *J Thorac Cardiovasc Surg*. 2010;139(6):1473–1482 e5.
17. McCarthy PM, Bhudia SK, Rajeswaran J, Hoercher KJ, Lytle BW, Cosgrove DM, et al. Tricuspid valve repair: durability and risk factors for failure. *J Thorac Cardiovasc Surg*. 2004;127(3):674–85.
18. Lewis MJ, Ginns JN, Ye S, Chai P, Quaegebeur JM, Bacha E, et al. Postoperative tricuspid regurgitation after adult congenital heart surgery is associated with adverse clinical outcomes. *J Thorac Cardiovasc Surg*. 2016;151(2):460–5.
19. Kogon B, Patel M, Leong T, McConnell M, Book W. Management of moderate functional tricuspid valve regurgitation at the time of pulmonary valve replacement: is concomitant tricuspid valve repair necessary? *Pediatr Cardiol*. 2010;31(6):843–8.
20. Kanter KR, Doelling NR, Fyfe DA, Sharma S, Tam VK. De Vega tricuspid annuloplasty for tricuspid regurgitation in children. *Ann Thorac Surg*. 2001;72(4):1344–8.

21. van Slooten YJ, Freling HG, van Melle JP, Mulder BJ, Jongbloed MR, Ebels T, et al. Long-term tricuspid valve prosthesis-related complications in patients with congenital heart disease. *Eur J Cardiothorac Surg*. 2014;45(1):83–9.
22. McElhinney DB, Cabalka AK, Aboulhosn JA, Eicken A, Boudjemline Y, Schubert S, et al. Transcatheter tricuspid valve-in-valve implantation for the treatment of dysfunctional surgical bioprosthetic valves: An International, Multicenter Registry Study. *Circulation*. 2016;133(16):1582–93.
23. Mahadevan VS, Dua J, Hoschtitzky A. Combined tricuspid and pulmonic valve percutaneous replacement in a patient with a Glenn shunt. *Int J Cardiol*. 2016;204:128–30.
24. Rodes-Cabau J, Hahn RT, Latib A, Laule M, Lauten A, Maisano F, et al. Transcatheter Therapies for Treating Tricuspid Regurgitation. *J Am Coll Cardiol*. 2016;67(15):1829–45.
25. Utsunomiya H, Itabashi Y, Mihara H, Berdejo J, Kobayashi S, Siegel RJ, et al. Functional tricuspid regurgitation caused by chronic atrial fibrillation: a real-time 3-dimensional transesophageal echocardiography study. *Circ Cardiovasc Imaging*. 2017;10(1):e004897.
26. Yamasaki N, Kondo F, Kubo T, Okawa M, Matsumura Y, Kitaoka H, et al. Severe tricuspid regurgitation in the aged: atrial remodeling associated with long-standing atrial fibrillation. *J Cardiol*. 2006;48(6):315–23.
27. Lin G, Nishimura RA, Connolly HM, Dearani JA, Sundt TM 3rd, Hayes DL. Severe symptomatic tricuspid valve regurgitation due to permanent pacemaker or implantable cardioverter-defibrillator leads. *J Am Coll Cardiol*. 2005;45(10):1672–5.
28. Kim JB, Spevack DM, Tunick PA, Bullinga JR, Kronzon I, Chinitz LA, et al. The effect of transvenous pacemaker and implantable cardioverter defibrillator lead placement on tricuspid valve function: an observational study. *J Am Soc Echocardiogr*. 2008;21(3):284–7.
29. Al-Bawardy R, Krishnaswamy A, Rajeswaran J, Bhargava M, Wazni O, Wilkoff B, et al. Tricuspid regurgitation and implantable devices. *Pacing Clin Electrophysiol*. 2015;38(2):259–66.
30. Tang GH, Kaple R, Cohen M, Dutta T, Undemir C, Ahmad H, et al. First percutaneous micra leadless pacemaker implantation and tricuspid valve repair with MitraClip NT for lead-associated severe tricuspid regurgitation. *EuroIntervention*. 2017;12(15):e1845–8.
31. Lo CY, Chang HH, Hsu CP, Lai ST, Shih CC. Endomyocardial biopsy-related tricuspid regurgitation after orthotopic heart transplantation: single-center experience. *J Chin Med Assoc*. 2007;70(5):185–92.
32. Wartig M, Tesan S, Gabel J, Jeppsson A, Selimovic N, Holmberg E, et al. Tricuspid regurgitation influences outcome after heart transplantation. *J Heart Lung Transplant*. 2014;33(8):829–35.
33. Chan MC, Giannetti N, Kato T, Kornbluth M, Oyer P, Valentine HA, et al. Severe tricuspid regurgitation after heart transplantation. *J Heart Lung Transplant*. 2001;20(7):709–17.
34. Williams MJ, Lee MY, DiSalvo TG, Dec GW, Picard MH, Palacios IF, et al. Biopsy-induced flail tricuspid leaflet and tricuspid regurgitation following orthotopic cardiac transplantation. *Am J Cardiol*. 1996;77(15):1339–44.
35. Kalra N, Copeland JG, Sorrell VL. Tricuspid regurgitation after orthotopic heart transplantation. *Echocardiography*. 2010;27(1):1–4.
36. Ohno Y, Attizzani GF, Capodanno D, Cannata S, Dipasqua F, Imme S, et al. Association of tricuspid regurgitation with clinical and echocardiographic outcomes after percutaneous mitral valve repair with the MitraClip System: 30-day and 12-month follow-up from the GRASP Registry. *Eur Heart J Cardiovasc Imaging*. 2014;15(11):1246–55.
37. Frangieh AH, Gruner C, Mikulicic F, Attinger-Toller A, Tanner FC, Taramasso M, et al. Impact of percutaneous mitral valve repair using the MitraClip system on tricuspid regurgitation. *EuroIntervention*. 2016;11(14):e1680–6.
38. Yzeiraj E, Bijklic K, Tiburtius C, Witt J, Krause K, Steude J, et al. Tricuspid regurgitation is a predictor of mortality after percutaneous mitral valve edge-to-edge repair. *EuroIntervention*. 2017;12(15):e1817–24.
39. Schueler R, Ozturk C, Sinning JM, Werner N, Welz A, Hammerstingl C, et al. Impact of baseline tricuspid regurgitation on long-term clinical outcomes and survival after interventional edge-to-edge repair for mitral regurgitation. *Clin Res Cardiol*. 2016;

40. Kalbacher D, Schafer U, Von Bardeleben RS, Zuern CS, Bekerredjian R, Ouarrak T, et al. Impact of tricuspid valve regurgitation in surgical high-risk patients undergoing MitraClip implantation: results from the TRAMI registry. *EuroIntervention*. 2017;12(15):e1809–16.
41. Taramasso M, Nietlispach F, Zuber M, Maisano F. Transcatheter repair of persistent tricuspid regurgitation after MitraClip with the TriCinch system: interventional valve treatment toward the surgical standard. *Eur Heart J*. 2016;
42. Hutter A, Bleiziffer S, Richter V, Opitz A, Hettich I, Mazzitelli D, et al. Transcatheter aortic valve implantation in patients with concomitant mitral and tricuspid regurgitation. *Ann Thorac Surg*. 2013;95(1):77–84.
43. Schindler J, Cavalcante J, Althouse A, Sharbaugh MS, Kliner D, Katz W, et al. TCT-676 Prevalence of Residual Mitral and Tricuspid Regurgitation (MR/TR) following Transcatheter Aortic Valve Replacement (TAVR): Residual Mod/Severe MR and TR is Associated with Higher Mortality post TAVR. *J Am Coll Cardiol*. 2016;68(18S):B273–4.
44. Lindman BR, Maniar HS, Jaber WA, Lerakis S, Mack MJ, Suri RM, et al. Effect of tricuspid regurgitation and the right heart on survival after transcatheter aortic valve replacement: insights from the Placement of Aortic Transcatheter Valves II inoperable cohort. *Circ Cardiovasc Interv*. 2015;8(4):e002073.
45. Barbanti M, Binder RK, Dvir D, Tan J, Freeman M, Thompson CR, et al. Prevalence and impact of preoperative moderate/severe tricuspid regurgitation on patients undergoing transcatheter aortic valve replacement. *Catheter Cardiovasc Interv*. 2015;85(4):677–84.
46. Kowalski M, Franz N, Hofmann S, Ritter F, Thale J, Warnecke H. Transapical transcatheter aortic valve implantation followed by transfemoral transcatheter edge-to-edge repair of the tricuspid valve using the MitraClip system - a new treatment concept for an inoperable patient with significant aortic stenosis and severe tricuspid valve regurgitation. *Postepy Kardiologii Interwencyjnej*. 2016;12(3):262–6.
47. Fukuda S, Saracino G, Matsumura Y, Daimon M, Tran H, Greenberg NL, et al. Three-dimensional geometry of the tricuspid annulus in healthy subjects and in patients with functional tricuspid regurgitation: a real-time, 3-dimensional echocardiographic study. *Circulation*. 2006;114(1 Suppl):I492–8.
48. Ton-Nu TT, Levine RA, Handschumacher MD, Dorer DJ, Yosefy C, Fan D, et al. Geometric determinants of functional tricuspid regurgitation: insights from 3-dimensional echocardiography. *Circulation*. 2006;114(2):143–9.
49. Boudjemline Y, Agnoletti G, Bonnet D, Behr L, Borenstein N, Sidi D, et al. Steps toward the percutaneous replacement of atrioventricular valves an experimental study. *J Am Coll Cardiol*. 2005;46(2):360–5.
50. *Gate™ Tricuspid Valved Stent*. <http://www.navigatecsi.com/technology/gatetricuspid-valved-stent/>.
51. *First Implant of a Transcatheter Tricuspid Valved Stent Marks New Frontier in Percutaneous Valve Care*. <https://consultqd.clevelandclinic.org/2017/01/first-implant-transcatheter-tricuspid-valved-stent-marks-new-frontier-percutaneous-valve-care/>.
52. Kefer J, Sluysmans T, Vanoverschelde JL. Transcatheter Sapien valve implantation in a native tricuspid valve after failed surgical repair. *Catheter Cardiovasc Interv*. 2014;83(5):841–5.
53. Roberts PA, Boudjemline Y, Cheatham JP, Eicken A, Ewert P, McElhinney DB, et al. Percutaneous tricuspid valve replacement in congenital and acquired heart disease. *J Am Coll Cardiol*. 2011;58(2):117–22.
54. Godart F, Baruteau AE, Petit J, Riou JY, Sassolas F, Lussion JR, et al. Transcatheter tricuspid valve implantation: a multicentre French study. *Arch Cardiovasc Dis*. 2014;107(11):583–91.
55. Eicken A, Schubert S, Hager A, Horer J, McElhinney DB, Hess J, et al. Percutaneous tricuspid valve implantation: two-center experience with midterm results. *Circ Cardiovasc Interv*. 2015;8(4):e002155.
56. Jean-Michel Juliard AV, Latib A, Brochet E, Ou P, Himbert D, Taramasso M, Maisano F. Transcatheter tricuspid valve interventions. In: SP EE, Wijns W, Vahanian A, van Sambeek

- M, De Palma R, editors. *The PCR-EAPCI Textbook: Percutaneous interventional cardiovascular medicine*. Toulouse, France: Europa Digital and Publishing; 2016.
57. Condado J, Leonardi R, Babaliaros V. Percutaneous tricuspid valve-in-ring replacement for the treatment of recurrent severe tricuspid regurgitation. *Catheter Cardiovasc Interv*. 2015;86(7):1294–8.
 58. Bouleti C, Himbert D, Brochet E, Ou P, Iung B, Nejjar M, et al. Transfemoral tricuspid valve-in-ring implantation using the edwards Sapien XT valve: one-year follow-up. *Circ Cardiovasc Interv*. 2015;8(3):e002225.
 59. Fassa AA, Himbert D, Brochet E, Labbe JP, Vahanian A. Transfemoral valve-in-ring implantation for a failing mitral homograft in the tricuspid position. *EuroIntervention*. 2014;10(2):269.
 60. Cabasa AS, Eleid MF, Rihal CS, Villarraga HR, Foley TA, Suri RM. Tricuspid valve replacement: a percutaneous transfemoral valve-in-ring approach. *JACC Cardiovasc Interv*. 2015;8(8):1126–8.
 61. Mazzitelli D, Bleiziffer S, Noebauer C, Ruge H, Mayr P, Opitz A, et al. Transatrial antegrade approach for double mitral and tricuspid "valve-in-ring" implantation. *Ann Thorac Surg*. 2013;95(1):e25–7.
 62. Lauten A, Figulla HR, Willich C, Laube A, Rademacher W, Schubert H, et al. Percutaneous caval stent valve implantation: investigation of an interventional approach for treatment of tricuspid regurgitation. *Eur Heart J*. 2010;31(10):1274–81.
 63. Lauten A, Ferrari M, Hekmat K, Pfeifer R, Dannberg G, Ragooschke-Schumm A, et al. Heterotopic transcatheter tricuspid valve implantation: first-in-man application of a novel approach to tricuspid regurgitation. *Eur Heart J*. 2011;32(10):1207–13.
 64. Lauten A, Doenst T, Hamadanchi A, Franz M, Figulla HR. Percutaneous bicaval valve implantation for transcatheter treatment of tricuspid regurgitation: clinical observations and 12-month follow-up. *Circ Cardiovasc Interv*. 2014;7(2):268–72.
 65. Duerr GD, Endlich M, Sinning JM, Esmailzadeh B, Werner N, Mellert F. Surgical banding of the inferior vena cava for the facilitation of transcatheter valve implantation in a patient with severe secondary tricuspid regurgitation. *Eur Heart J*. 2014;35(40):2839–49.
 66. Laule M, Stangl V, Sanad W, Lembcke A, Baumann G, Stangl K. Percutaneous transfemoral management of severe secondary tricuspid regurgitation with Edwards Sapien XT bioprosthesis: first-in-man experience. *J Am Coll Cardiol*. 2013;61(18):1929–31.
 67. El-Eshmawi A, Tang GH, Verma S, Yanagawa B, Ruel M, Adams DH. Innovations in tricuspid valve intervention. *Curr Opin Cardiol*. 2017;32(2):166–73.
 68. Shinn SH, Schaff HV. Evidence-based surgical management of acquired tricuspid valve disease. *Nat Rev Cardiol*. 2013;10(4):190–203.
 69. Kay JH, Maselli-Campagna G, Tsuji KK. Surgical Treatment of Tricuspid Insufficiency. *Ann Surg*. 1965;162:53–8.
 70. Hahn RT, Meduri CU, Davidson CJ, Lim S, Nazif TM, Ricciardi MJ, et al. Early feasibility study of a transcatheter tricuspid valve annuloplasty. SCOUT trial 30-day results. *JACC*. 2017;69(14):1795–806.
 71. Lurz P, Besler C, Kiefer P, Ender J, Seeburger J. Early experience of the trialign system for catheter-based treatment of severe tricuspid regurgitation. *Eur Heart J*. 2016;37(47):3543.
 72. Schofer J, Bijklic K, Tiburtius C, Hansen L, Groothuis A, Hahn RT. First-in-human transcatheter tricuspid valve repair in a patient with severely regurgitant tricuspid valve. *J Am Coll Cardiol*. 2015;65(12):1190–5.
 73. Latib A, Agricola E, Pozzoli A, Denti P, Taramasso M, Spagnolo P, et al. First-in-Man Implantation of a Tricuspid Annular Remodeling Device for Functional Tricuspid Regurgitation. *JACC Cardiovasc Interv*. 2015;8(13):e211–4.
 74. Latib A, Mangieri A, Vicentini L, Ferri L, Montorfano M, Ismeno G, et al. Percutaneous tricuspid valve annuloplasty under conscious sedation (with only fluoroscopic and intracardiac echocardiography monitoring). *J Am Coll Cardiol Intv*. 2017;10(6):620–1.
 75. Rogers T, Ratnayaka K, Sonmez M, Franson DN, Schenke WH, Mazal JR, et al. Transatrial intrapericardial tricuspid annuloplasty. *JACC Cardiovasc Interv*. 2015;8(3):483–91.

76. Rogers JH. Transcatheter Tricuspid Valve Therapies 5: Millipede Description, Results and a Case. Presented at: Transcatheter Cardiovascular Therapeutics 2016; Nov 1, 2016; Washington, DC. In.
77. Kuck KH. The Cardiac Implants annuloplasty device. Cardiac Implants' Complete Ring Delivery System for Mitral and Tricuspid Valve Annuloplasty. Presented at: Transcatheter Cardiovascular Therapeutics 2015; October 12, 2015; San Francisco, CA. In.
78. Kuwata S, Taramasso M, Nietlispach F, Maisano F. Transcatheter tricuspid valve repair toward a surgical standard: first-in-man report of direct annuloplasty with a cardioband device to treat severe functional tricuspid regurgitation. *Eur Heart J*. 2017;
79. Campelo-Parada F, Perlman G, Philippon F, Ye J, Thompson C, Bedard E, et al. First-in-Man Experience of a Novel Transcatheter Repair System for Treating Severe Tricuspid Regurgitation. *J Am Coll Cardiol*. 2015;66(22):2475–83.
80. Ailawadi G, Kron IL. Catheter Based Valve and Aortic Surgery. New York: Springer; 2016.
81. Kapadia S. The Tricuspid Valve Occluder: A Novel Device for Tricuspid Regurgitation. Presented at: Transcatheter Cardiovascular Therapeutics 2015; October 15, 2015; San Francisco, CA. In.
82. Lai YQ, Meng X, Bai T, Zhang C, Luo Y, Zhang ZG. Edge-to-edge tricuspid valve repair: an adjuvant technique for residual tricuspid regurgitation. *Ann Thorac Surg*. 2006;81(6):2179–82.
83. Feldman T, Kar S, Elmariah S, Smart SC, Trento A, Siegel RJ, et al. Randomized Comparison of Percutaneous Repair and Surgery for Mitral Regurgitation: 5-Year Results of EVEREST II. *J Am Coll Cardiol*. 2015;66(25):2844–54.
84. Schofer J, Tiburtius C, Hammerstingl C, Dickhaut PO, Witt J, Hansen L, et al. Transfemoral Tricuspid Valve Repair Using a Percutaneous Mitral Valve Repair System. *J Am Coll Cardiol*. 2016;67(7):889–90.
85. Hammerstingl C, Schueler R, Malasa M, Werner N, Nickenig G. Transcatheter treatment of severe tricuspid regurgitation with the MitraClip system. *Eur Heart J*. 2016;37(10):849–53.
86. Wengenmayer T, Zehender M, Bothe W, Bode C, Grundmann S. First transfemoral percutaneous edge-to-edge repair of the tricuspid valve using the MitraClip system. *EuroIntervention*. 2016;11(13):1541–4.
87. Braun D, Nabauer M, Massberg S, Hausleiter J. Transcatheter Repair of Primary Tricuspid Valve Regurgitation Using the MitraClip System. *JACC Cardiovasc Interv*. 2016;9(15):e153–4.
88. Braun D, Nabauer M, Orban M, Gross L, Englmaier A, Rosler D, et al. Transcatheter treatment of severe tricuspid regurgitation using the edge-to-edge repair technique. *EuroIntervention*. 2017;
89. Vismara R, Gelpi G, Prabhu S, Romitelli P, Troxler LG, Mangini A, et al. Transcatheter Edge-to-Edge Treatment of Functional Tricuspid Regurgitation in an Ex Vivo Pulsatile Heart Model. *J Am Coll Cardiol*. 2016;68(10):1024–33.
90. Ozcan C, Raunso J, Lamberts M, Kober L, Lindhardt TB, Bruun NE, et al. Infective endocarditis and risk of death after cardiac implantable electronic device implantation: a nationwide cohort study. *Europace*. 2017;
91. Taramasso M, Zuber M, Nietlispach F, Maisano F. Clipping of the Tricuspid Valve: proposal of a "Rosetta Stone" nomenclature for procedural 3D transesophageal guidance. *EuroIntervention*. 2016;
92. Malasa M, Werner N, Nickenig G, Hammerstingl C. Transcatheter tricuspid valve repair in a patient with isolated functional tricuspid valve regurgitation. *Eur Heart J*. 2016;37(10):855.

Chapter 19

Catheter-Based Therapy for Tricuspid Valve Disease: Practical Considerations for Interventionalists

Shingo Kuwata, Alberto Pozzoli, Francesco Maisano,
and Maurizio Taramasso

Abstract Tricuspid valve (TV) disease is mainly represented by functional tricuspid regurgitation (TR), which is a predictor of poor quality of life and increased mortality. Transcatheter therapies are attractive alternatives for the increasingly older and high-risk patient population with native TR or with failing surgical tricuspid valve replacement or annuloplasty (valve in valve and valve in ring procedures). At the present stage, different open issues are still under discussion, including clinical and anatomical patients selection, imaging guidance, technical aspects and how to report the outcomes of these new therapies.

Keywords Tricuspid regurgitation • Tricuspid valve • Transcatheter tricuspid regurgitation

Introduction

Tricuspid valve (TV) disease is mainly represented by tricuspid regurgitation (TR), which is a predictor of poor quality of life and increased mortality [1]. Among them, functional (or secondary) TR is the most frequent tricuspid valve disease [2]. Similar to other valve pathologies, TV disease includes stenosis and regurgitation. Stenosis is more seldom than regurgitation and can result from congenital or acquired factors.

S. Kuwata • A. Pozzoli • F. Maisano • M. Taramasso, M.D. (✉)
University Heart Center Zürich, University of Zürich, Zürich,
Switzerland Rämistrasse 100, 8091 Zurich, Switzerland
e-mail: maurizio.taramasso@usz.ch

The impact of TV disease on long-term morbidity and mortality has made a discussion about assessment and treatment recommendations for the not only in combination with left-sided heart surgery but also singular TV surgery. With advanced surgical and transcatheter therapies, singular TV management comes in hand with decreased risk of adverse events, positive impact on overall heart function and better long term outcomes [3, 4]. Both American and European guidelines recommend the same threshold of TV treatment for a dilated tricuspid annulus of ≥ 40 mm or >21 mm/m², regardless of the severity of the TR [5, 6]. Transcatheter therapies are attractive alternatives for the increasingly older and high-risk patient population with native TR or with failing surgical tricuspid valve replacement or annuloplasty (valve in valve and valve in ring procedures).

Transcatheter therapies are so far in a really initial phase of clinical evaluation and are mainly used to address native functional TR, while no experiences are available in the context of organic TR. At the present stage, different open issues are under discussion, (including clinical and anatomical patients selection, imaging guidance, technical aspects and how to report the outcomes of these new therapies).

Patients' Selection: Which Patient Could Benefit the Most from Interventional Tricuspid Therapies?

The presence of significant TR has a negative prognostic impact on survival and is independently associated with a 1.5–2-fold increased risk of cardiovascular events. Similarly, the late development of FTR after left-sided valve surgery is also associated with reduced survival. The consequence of these observations is that there is a large number of patients that could potentially benefit from a less invasive transcatheter tricuspid valve therapy. However, it is at the moment quite challenging to predict which patient could really benefit from a prognostic and symptomatic standpoint from an intervention. In fact, in patients with advanced heart failure, the presence severe TR is likely to be a marker of disease severity, rather than an incremental risk factor that could be treated and revert the natural history. In order to aim to any clinical benefit, ideally tricuspid intervention should be performed before the onset of severe right ventricular dysfunction and distortion, with consequent advanced leaflet tethering and huge annular dilatation with complete lack of valve coaptation. In this regard, proper timing of the treatment would play a fundamental role, and several clinical data will be needed in order to clarify this aspect.

Anatomical Considerations

A deep knowledge of the complex surgical anatomy of the TV is a mandatory prerequisite to understand the challenges, which are encountered in developing percutaneous tricuspid therapy.

Table 19.1 The anatomical challenges regarding transcatheter tricuspid valve therapy

Large tricuspid annulus dimensions with a non-planar and elliptical shape
Absence of calcifications
RV morphology (trabeculae, muscle bands, thin apical wall)
Proximity/contiguity of other structures (coronary sinus, atrioventricular node and His bundle, vena cava, right coronary artery)
Angulation of the annulus in relation to the superior vena cava and inferior vena cava

The normal TV apparatus is composed of three leaflets (septal, posterior and anterior), chordae tendineae, and two or three well developed papillary muscles. The posterior and anterior leaflets could be considered scallops of a single mural leaflet, similar to the posterior leaflet of the mitral valve. As a consequence, variable distribution of the scallops is possible and more than three leaflets can be identified in many patients, depending on the pattern of the subdivision of the mural leaflet. Papillary muscle anatomy is also variable, with a septal and an anterior papillary muscle. The septal leaflet has direct chordal attachments to the septum without the presence of a developed papillary muscle in most occasions. Several structures of major surgical importance surround the TV, such as the right coronary artery (which is very often in close contiguity with the parietal portion of the tricuspid annulus), the atrioventricular node, the bundle of His and the coronary sinus. The non-planar and non-circular structure of the tricuspid annulus must be taken into account when considering tricuspid repair technologies. The normal shape of the tricuspid annulus is semi-lunar and it is larger compared to the mitral one. In physiologic conditions, the tricuspid annulus has a non-planar three-dimensional saddle-shape configuration. Such a characteristic is lost in case of functional TR, since the annulus became larger and flat. In presence of functional TR, as a consequence of RV enlargement and dysfunction, the tricuspid annulus becomes more circular as it dilates in its anterior-posterior aspect. The consequence of severe functional TR is further RV dilatation with progressive papillary muscles displacement and consequent leaflets tethering. Table 19.1 summarizes the major anatomical challenges to be overcome in the development of transcatheter tricuspid valve therapies.

The Importance of Imaging: Patients' Eligibility and Intraprocedural Guidance

With the advent and availability of transcatheter TV therapies, computed tomography (CT) has become a mandatory in defining patients' anatomy and eligibility.

Since it offers a comprehensive assessment of the real three-dimensional (3D) anatomy, CT allows the operator to assess the TV anatomy as well as the adjacent structures including the proximity of the right coronary artery to the tricuspid annulus, the coronary sinus, the hepatic veins and vena cava (Fig. 19.1a). For some

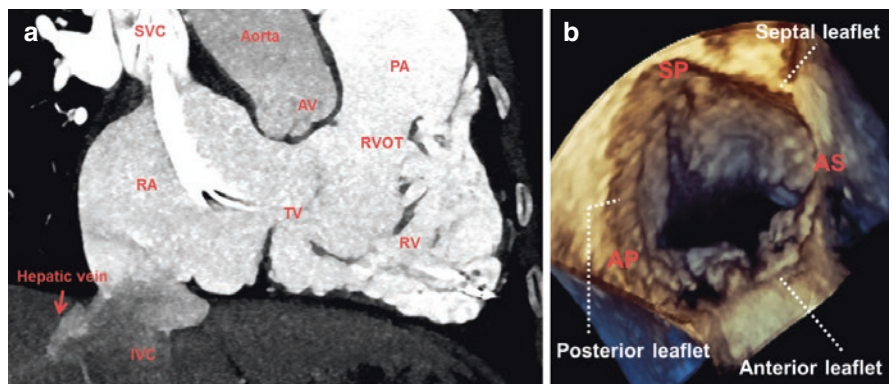


Fig. 19.1 Imaging of the tricuspid valve. (a) Angio-computed tomography of tricuspid valve and right heart structures characterization for pre-procedural planning. *TV* tricuspid valve, *APC* antero posterior commissure, *ASC* antero septal commissure, *RCA* right coronary artery, *AV* aortic valve, *RA* right atrium, *RV* right ventricle, *SVC* superior vena cava, *IVC* inferior vena cava, *RVOT* right ventricular outflow tract, *Pa* pulmonary artery. (b) Identification of TV leaflets and localization of the each commissures with tree dimensional transesophageal echocardiography; *SP* septoposterior, *AS* anteroseptal, and *AP* anteroposterior, commissures

devices it is crucial also the assessment of the shape and dimension of the RV, including the distant between the RV apex and the annular plane (this is the case for the valve spacer). Moreover, angio-CT allow the operator to have a qualitative assessment of the tissue quality, which is particular important for annuloplasty devices which rely on anchor fixation, in order to identify the optimal target zone for the implant. Another features of CT scan is that it allows for each patient an easy and reliable prediction of the fluoroscopic working plane during the procedure, which are usually 2, one en-face view (normally LAO) and one view parallel to the annulus (normally RAO).

Transesophageal 2D and 3D echocardiography (TEE) is also the essential imaging technique in the assessment of patients with TR (Fig. 19.1b), in order to assess the mechanism and location of regurgitation, to quantify the annular dimensions and to assess the RV function and valve tethering.

Although preliminary experience showed the feasibility of TV interventions, intraprocedural guidance remain a major issue, since in many patients the echocardiographic window for the TV may be suboptimal and the procedural steps have not yet been standardized. Both two-dimensional (2D) and 3D TEE as well as intracardiac echocardiography (ICE) also play an essential role during transcatheter TV interventions. In some patients, transthoracic echocardiography (TTE) may help to define TV morphology and right ventricular anatomy to identify the target zone of the device implantation. This is particular helpful in MitraClip procedures, in which a proper assessment of the leaflets insertion is mandatory to achieve procedural success [8]. Procedural guidance with 3D-TEE represents a fundamental tool to orient the navigation in the right atrium. However, in many patients the quality of intra-procedural guidance can often be suboptimal, mainly depending on patient

variability and individual echo window. Moreover, the three-leaflet configuration of the TV precludes the visualization of all the leaflets in the same view in conventional 2D echo. This aspect contributes to increase technical complexity of TV interventions. A detailed intra-procedural imaging is of particular importance not only to guide the operator to the segment of the valve which represent the target leaflet or commissure, but is crucial to define the orientation of the anatomy and to assess leaflet insertion. The use of the EchoNavigator[®]-system (Philips Healthcare, Best, the Netherlands) may help to overcome the intrinsic limits of imaging guidance in TV interventions, since multimodality fusion imaging may define the target zone increases tremendously the chance of procedural success [7]. Additionally, it is of crucial importance to define a common nomenclature in order to standardize procedural 3D TEE guidance. It should be shared between the one who is performing the procedure and the one who is guiding. With this in mind, a communication between the heart team (e.g. echo-cardiologist, interventionalist and surgeon) is fundamental; therefore, all the operators involved in the procedure should speak “the same language”. This is even more important at this stage, and this can avoid some misunderstand “the eyesight” in each staff. We recently propose a “Rosetta Stone” nomenclature for 3D TEE navigation during transcatheter TV interventions as practical considerations for the heart team [13]. The identification of the location of the aortic valve (AV) is fundamental to understand the orientation of the leaflets: the leaflet opposite to the AV is the posterior leaflet. Anterior and septal leaflets are easily identified counterclockwise (Fig. 19.2).

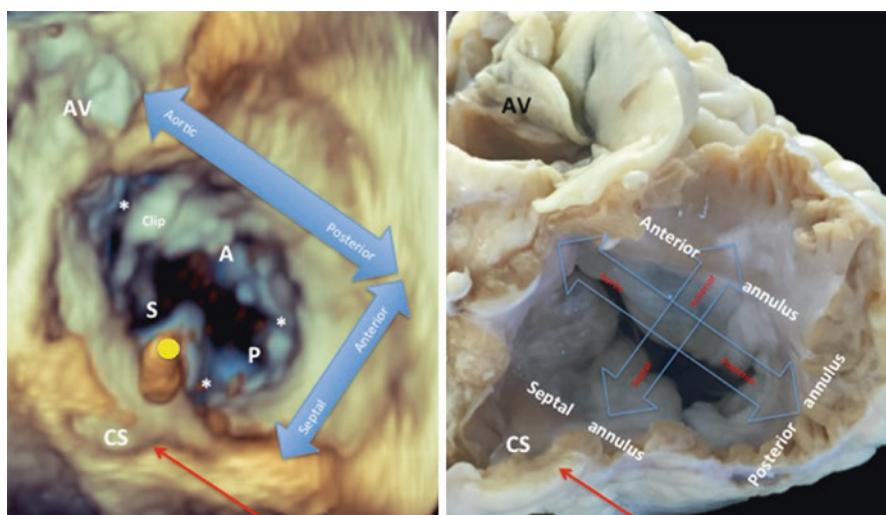


Fig. 19.2 Navigation in the right atrium with 3D TEE during transcatheter tricuspid intervention (AV aortic valve, A anterior, S Septal, P Posterior, CS, coronary sinus). The three stars indicate the valve commissure; the yellow spot indicate an intravalvular pacemaker lead; the red arrow indicated the inferior vena cava

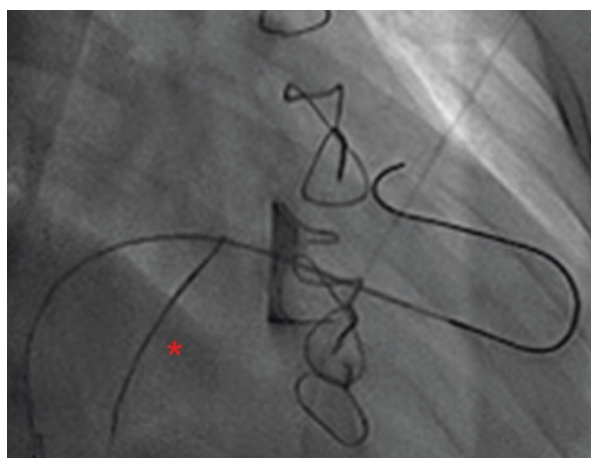
Specific Considerations for Transcatheter Tricuspid Valve in Valve and Valve in Ring

In patients with previous tricuspid surgery, transcatheter valve-in-valve or valve-in-ring procedures can be performed using a transfemoral or transjugular approach even in patients with pre-existing transvalvular pacemaker leads [9–11]. Different prostheses have been used to perform tricuspid valve in valve and valve in ring (mainly Sapien XT, Sapien 3 and Melody).

The transfemoral approach may be technically challenging in most cases, due to an unfavorable narrow angle between the inferior vena cava (IVC) and the TV, which may preclude positioning of the prosthesis valve, especially in case of Sapien XT and Sapien 3 valve, which have a pretty stiff delivery system. By snaring the Commander catheter, flexion of the system can be increased by simple pulling on the snare, thereby adapting the angle of the catheter to the patient's anatomy (Fig. 19.3) [9].

Regarding valve in ring, in the tricuspid position surgical rings usually are incomplete ring and have a non-circular and non-planar shape. As a result, compared to mitral position, tricuspid valve-in-ring presents some specific difficulties. On the other hand, unlike the mitral position, the risk of right ventricle (RV) outflow obstruction is absent, and residual paravalvular leak and risk of embolization are less of an issue as a result of the low-pressure RV system. As a support for prosthesis sizing, during the procedure, balloon sizing may be useful to determine the annulus dimension more precisely [12]. Although the ring has the advantage of providing the landmarks and necessary anchoring for a percutaneous valve, it also has the drawback of creating a non-circular landing zone with the inability to seal completely the open segment with the implanted valve. Therapeutic advances with more conformable or repositionable valves with additional sealing capacity are required to reduce regurgitation after transcatheter valve-in-ring implantation.

Fig. 19.3 Transcatheter tricuspid valve replacement. “Snare-guided” (*asterisk*) crossing technique of the tricuspid valve to optimise the angle and obtain coaxiality with tricuspid valve



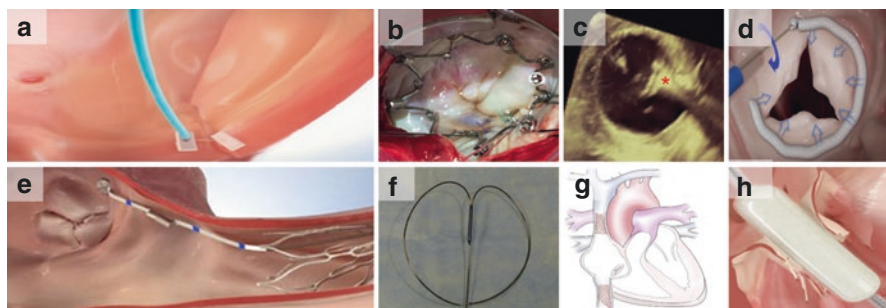


Fig. 19.4 Transcatheter therapies for severe tricuspid regurgitation. (a) Trialign device, (b) Millipede device, (c) MitraClip device, (d) Cardioband device, (e) Tricinch device, (f) TRAIPTA device, (g) Caval valve implantation, (h) FORMA device

Specific Considerations for Transcatheter Tricuspid Valve Repair Devices

In patients with native TV disease, many percutaneous techniques mimic surgical techniques is innovated. Novel transcatheter devices have begun to emerge for the treatment of TR, and these transcatheter devices are currently under preliminary clinical evaluation to treat functional TR. Risks and limitations of each devices have to be taken in consideration in the patient selection process (Fig. 19.4).

Tricuspid Clipping

More than 60 cases of MitraClip implants in tricuspid position have been performed worldwide [14], but procedural steps have not been standardized yet. The major challenge of this technique is the imaging guidance, since in most of the patients a proper visualization of the leaflet and therefore of the grasping and proper may be problematic. Usually a combination of TEE and TTE may help to overcome the difficulty in visualization. Another open issue of MitraClip is the access: while the first cases have been performed through a transjugular approach, now the preferred route seems to be the femoral one, considering also that in many cases tricuspid clipping is performed concomitantly to a MitraClip in mitral position. A modified delivery system for tricuspid clipping is under development and multicenter feasibility trial should start in Europe in the next months.

Tricuspid Annuloplasty Devices

A possible drawback of the tricuspid annuloplasty devices (Trialign procedure (Mitralign Inc., Tewksbury, MA), TriCinch system (4Tech Cardio Ltd., Dublin, Ireland), Millipede annular ring (Millipede, Santa Rosa, CA) or Cardioband

(Edwards Lifesciences, Irvine, CA)), is that they are mostly technically challenging and require advanced imaging guidance and operators' skills.

Especially, it is mandatory to pay attention the risk of leaflet or right coronary artery damage due to the positioning of the devices and to the annular plication. In this regard, the use of ICE is particularly useful to guide precise implant in the annular tissue avoiding leaflet tears.

Caval Valve Implantation

Heterotopic TV implantation is an alternative approach to an orthotopic implantation. There are still some unsolved issues concerning the tolerability of this palliative technique, especially regarding the risk of deterioration of RV function by increasing preload in patients with prior depressed RV function. These procedures were performed in patients with sufficiently preserved RV function.

Pericardial Device

In common with all permanent implants, potential failure modes are implant migration and tissue erosion. The main limitation of pericardial approach that could importantly limit the clinical adoption of the TRAIPTA system (Cardiovascular Intervention Program at National heart, lung, and blood institute) is that in a large majority of the cases functional TR is observed in patients with previous open-heart operation, in whom the pericardium was opened. Therefore, navigation in the pericardial space is challenging if not impossible due to the surgical adhesions.

Tricuspid Valve Spacer

The FORMA Repair System (Edwards Lifesciences, Irvine, CA) is achieved under general anesthesia under fluoroscopic and 2D or 3D TEE guidance. However, the presence of the spacer between the valve leaflets makes the accurate assessment of the degree of TR after the procedure difficult.

How to Report the Outcome?

Another practical consideration that has to be done refers to how to report the outcomes of these new tricuspid therapies, since no standardized definitions are present. First of all, it would be recommendable to report precise quantitative

measurements of TR reduction (like EROA and Regurgitant Volume). Secondly, it is not really clear which will be the best outcome to evaluate in these patients, since most likely improvement in quality of life would be more appropriate than improvement in survival. Anyway, similarly to what has been done for aortic and mitral valves, there is an urgent need for a consensus regarding standardized endpoint and reporting outcomes in transcatheter tricuspid interventions.

Conclusions

Although only very preliminary data are available to date, TV interventions have been rapidly evolving over the last few years. However, it is important to point out that at the present stage of the development of these therapies, due to limited availability of clinical data, it appears not possible to provide sufficient clinical evidence for efficacy or safety of these various strategies and techniques. All the heart team should share “the same language” and “the same eyesight” in the procedure, since the complexity and specifics of anatomical features of the TV apparatus and right heart chambers have made TV intervention challenging. In the future, transcatheter TV repair and replacement will probably become a standard option for patients with high surgical risk. Specific algorithms with specific indications will be required to guide the optimal treatment for each patient.

Review Questions for Chapters 15, 18 and 19

Select the Single Best Sentence

77. Which of the following statements is false?
- (a) Moderate-severe TR is seen in up to 67% of patients following isolated mitral valve surgery
 - (b) Moderate-severe TR is seen in 15% of patients undergoing aortic valve surgery
 - (c) Moderate-severe TR is seen in 40% of patients undergoing aortic valve surgery
 - (d) Patients with residual moderate-severe TR after aortic valve surgery have 5-fold increased risk of cardiac mortality at 10 years compared to patients with mild or less TR
78. Which of the following statements about cardiac surgery for adult congenital heart disease (CHD) is correct?
- (a) Residual moderate-severe TR is associated with 6-fold increased risk of death, transplant, or reoperation
 - (b) Residual moderate-severe TR is associated with 2-fold increased risk of death, transplant, or reoperation
 - (c) Residual moderate-severe TR is associated with 4-fold increased risk of death, transplant, or reoperation
 - (d) Residual moderate-severe TR is associated with 1.5-fold increased risk of death, transplant, or reoperation
79. Which of the following statements about idiopathic TR is false?
- (a) Commonly seen in elderly patients with long-standing atrial fibrillation.
 - (b) characterized by excessive dilation and impaired contractility of the tricuspid annulus
 - (c) Idiopathic TR is associated with less pulmonary artery pressure and better biventricular function than functional TR
 - (d) Clinical improvement is less likely in idiopathic TR than functional TR
80. Which of the following statements about management of post TAVR TR is correct?
- (a) Moderate-severe TR is seen in 10–12% after TAVR procedure
 - (b) Moderate-severe TR is seen in 20–24% after TAVR procedure
 - (c) Moderate-severe TR is seen in 24–30% after TAVR procedure
 - (d) Moderate-severe TR is seen in 50–67% after TAVR procedure

81. Which of the following statements about catheter based therapy of TR is correct?
- (a) Caval vein valve implantation is established catheter based therapy for TR
 - (b) The TriCinch system is a form of edge-to-edge repair for TR
 - (c) The Mitralign device is a form of edge-to-edge repair for TR
 - (d) Orthotropic tricuspid valve implantation has been tried for patients with failed TV prosthesis as well as in surgical annuloplasty rings
82. Which of the following statements about catheter based devices for treatment of functional TR is correct?
- (a) Risk of device thrombosis is higher due to relatively low pressure on the right side of the heart
 - (b) The risk of endocarditis in the case of valve replacement (e.g. valve-in-valve) might be higher than repair devices
 - (c) Pre-procedural computed tomography is required in almost all patients before catheter based therapy of tricuspid valve.
 - (d) All of the above
83. Caval vein valve implantation is a potential method to treat severe TR with backflow into caval veins. What is the main technical limitation of this approach?
- (a) The large and variable diameter of the caval veins
 - (b) The proximity of the right atrium
 - (c) The proximity of the hepatic veins
 - (d) All of the above
84. What determines clinical benefit from treating patients with TR?
- (a) The onset of severe right ventricular dysfunction and distortion
 - (b) Advanced tricuspid leaflet tethering
 - (c) Massive annular dilatation with complete lack of valve coaptation
 - (d) All of the above
85. Regarding tricuspid valve-in-valve implantation, trans femoral approach is more challenging than jugular approach most importantly due to:
- (a) Diameter of femoral vessels
 - (b) The unfavourable narrow angle between the inferior vena cava (IVC) and the TV may preclude positioning of the prosthesis valve
 - (c) Calcified prosthesis
 - (d) Direction of TR jet

References

1. Rodes-Cabau J, Taramasso M, O'Gara PT. Diagnosis and treatment of tricuspid valve disease: current and future perspectives. *Lancet*. 2016;388(10058):2431–42.
2. Taramasso M, Pozzoli A, Guidotti A, et al. Percutaneous tricuspid valve therapies: the new frontier. *Eur Heart J*. 2016;38(9):639–47.
3. Jeganathan R, Armstrong S, Al-Alao B, David T. The risk and outcomes of reoperative tricuspid valve surgery. *Ann Thorac Surg*. 2013;95:119–24.
4. Topilsky Y, Khanna AD, Oh JK, et al. Preoperative factors associated with adverse outcome after tricuspid valve replacement. *Circulation*. 2011;123:1929–39.
5. Joint Task Force on the Management of Valvular Heart Disease of the European Society of Cardiology, European Association for Cardio-Thoracic Surgery, Vahanian A, et al. Guidelines on the management of valvular heart disease (version 2012). *Eur Heart J*. 2012;33:2451–96.
6. Nishimura RA, Otto CM, Bonow RO, et al. 2014 AHA/ACC guideline for the management of patients with valvular heart disease: a report of the American College of Cardiology/American Heart Association Task Force on Practice Guidelines. *J Am Coll Cardiol*. 2014;63:e57–185.
7. Taramasso M, Zuber M, Ruiz CE, Maisano F. Echo-navigation to guide transfemoral tricuspid edge-to-edge repair. *Eur Heart J*. 2016;37(45):3420.
8. Lancellotti P, Tribouilloy C, Hagendorff A, et al. Recommendations for the echocardiographic assessment of native valvular regurgitation: an executive summary from the European Association of Cardiovascular Imaging. *Eur Heart J Cardiovasc Imaging*. 2013;14:611–44.
9. Taramasso M, Nietlispach F, Dvir D, et al. Transfemoral tricuspid valve-in-valve implantation: snare it to make it simpler! *EuroIntervention*. 2016;12:402.
10. McElhinney DB, Cabalka AK, Aboulhosn JA, et al. Transcatheter tricuspid valve-in-valve implantation for the treatment of dysfunctional surgical bioprosthetic valves: an international, multicenter registry study. *Circulation*. 2016;133:1582–93.
11. Eleid MF, Asirvatham SJ, Cabalka AK, et al. Transcatheter tricuspid valve-in-valve in patients with transvalvular device leads. *Catheter Cardiovasc Interv*. 2016;87:E160–5.
12. Condado J, Leonardi R, Babaliaros V. Percutaneous tricuspid valve-in-ring replacement for the treatment of recurrent severe tricuspid regurgitation. *Catheter Cardiovasc Interv*. 2015;86:1294–8.
13. Taramasso M, Zuber M, Kuwata S, Nietlispach F, Maisano F. Clipping of the tricuspid valve: proposal of a “Rosetta Stone” nomenclature for procedural 3D transoesophageal guidance. *EuroIntervention*. 2017;12(15):1825–7.
14. Nickenig G, Kowalski M, Hausleiter J, Braun D, Schofer J, Yzeiraj E, Rudolph V, Friedrichs K, Maisano F, Taramasso M, Fam N, Bianchi G, Bedogni F, Denti P, Alfieri O, Latib A, Colombo A, Hammerstingl C, Schueler R. Transcatheter treatment of severe tricuspid regurgitation with the edge-to-edge MitraClip Technique: Clinical perspective. *Circulation*. 2017;135(19):1802–14.

Answers

Question	Correct answer/Answers	Question	Correct answer/Answers
1	A	44	D
2	D	45	D
3	B	46	D
4	D	47	D
5	D	48	B
6	D	49	B
7	C	50	A
8	C	51	B
9	C	52	B
10	B	53	B
11	A	54	A
12	B	55	B
13	C	56	B
14	B	57	B
15	D	58	A
16	D	59	C
17	B	60	B
18	D	61	D
19	B	62	C
20	C	63	C
21	C	64	D
22	B	65	B
23	A	66	D
24	A	67	D
25	C	68	C
26	A	69	C
27	A	70	D
28	D	71	D
29	C	72	C
30	D	73	C
31	A	74	D
32	C	75	C
33	A	76	C
34	C, D	77	C
35	E	78	A
36	E	79	D
37	B	80	D
38	E	81	D
39	A	82	D
40	E	83	D
41	B	84	D
42	B	85	B
43	D		

Index

A

- Accessory atrioventricular pathways, 14
- Acquired lesions, 13, 156
- Acute pulmonary embolism, 183, 184
- American Society of Echocardiography (ASE) guideline, 117
- Angiotensin converting enzyme (ACE) inhibitors, 36, 277
- Annuloplasty devices, 192
 - Cardioband, 296, 297
 - Mitralign device, 362
 - superiority of ring annuloplasty, 365
 - TRAIPTA, 364
 - Trialign device, 291–295
 - TriCinch device, 295, 364
- Anterior leaflet, 80, 118, 128, 140, 185, 336, 381
- Anterosuperior leaflet (AS), 7, 8
- Anti-arrhythmics, 36
- Aortic valve (AV), 383
- Arrhythmogenic right ventricular dysplasia, 182
- Atrial arrhythmias, 36
- Atrial fibrillation (AF), 25, 355
- Atrial septal defect (ASD), 261
- Atrialis, 9

B

- Balloon valvotomy, 29
- Balloon-expandable caval implants, 289, 290
- Balloon-expandable transcatheter heart valves, 361
- Bernoulli law equation, 242, 245
- Bicaval cannulation, 330
- Bicaval valve implantation, 287, 288

- Bicuspidalization technique, 333
- Bioprosthetic valves, 68
- Biotronik pacemaker, 134

C

- Carcinoid heart disease, 39, 316
- Carcinoid tumours, 27, 164, 165
- Cardiac catheterization, 29, 35, 254
- Cardiac magnetic resonance (CMR) imaging, 184
 - ICD, 65
 - PPM, 65
 - right atrial size and function, 224
 - RV function and volume assessment, 228, 229
 - TA, 207, 213, 224
 - TR, 35
- Cardiac murmurs, 40
- Cardiac output (CO), calculation of, 259, 260, 266, 267
- Cardiac thrombi, 169
- Cardioband, 296, 297, 365, 385
- Cardiopulmonary bypass (CPB)
 - access, 329
 - cannulation, 330
 - exposure, 330
 - surgical anatomy and analysis, 331
- Cardiovascular magnetic resonance (CMR)
 - myocardial fibrosis, assessment of, 152, 153, 155
 - primary TR
 - carcinoid tumours, 164, 165
 - Ebstein's anomaly, 158–161
 - IE, 162, 163
 - rheumatic heart disease, 161
 - traumatic, 170
 - tumors, 166, 168

- Cardiovascular magnetic resonance (CMR) (*cont.*)
- RV volumes and function, 150–152
 - secondary TR, 156, 158
 - tricuspid valve flow, assessment of, 147–149
 - TS, 170–172
 - TV anatomy, assessment of
 - advantages, 146
 - limitations, 146
 - sequence and image acquisition, 145–146
 - valve masses, visualization of, 145
 - Carpentier's technique, 344
 - Carvalho's maneuver, 63
 - Caval valve implantation (CAVI), 189, 195, 287, 288, 290
 - Chordae, 338
 - Clover technique, 336, 337, 346
 - Coaptation devices, 192
 - Collagen fibres, 10
 - Colour flow Doppler, 64, 96, 98
 - Commander catheter, 384
 - Computed tomography (CT)
 - contrast injection, 181
 - right heart diseases, 183
 - acute pulmonary embolism, 183
 - arrhythmogenic right ventricular dysplasia, 182
 - contrast material, 182
 - optimum protocol and modes, 182
 - RV, 222
 - scan modes, 180–181
 - surgical interventions, 190
 - transcatheter tricuspid valve therapy, 381
 - transcatheter TV therapy, 193
 - annuloplasty devices, 192
 - CAVI, 195
 - coaptation devices, 192
 - percutaneous tricuspid annuloplasty, 192
 - TV orifice, 195
 - TV and surrounding structures, 185
 - adjacent anatomical structures, 186–187
 - chordae tendinae, 185
 - RCA, 188
 - RV apex, 189
 - TR, 185
 - tricuspid annulus, 186
 - vena cava, 189–190
 - Cone procedure, 344
 - Congenital heart disease (CHD), 354, 359
 - Congenital lesions, 156
 - Congenital tricuspid disease, 309, 311, 312, 314–317
 - Congenital tricuspid stenosis, 15, 27
 - Continuous wave Doppler, 102, 104, 105, 239, 242, 245, 246
 - Coronary artery bypass graft (CABG), 134, 308
 - CPB. *See* Cardiopulmonary bypass (CPB)
 - CT. *See* Computed tomography (CT)
- D**
- Danielson's technique, 344
 - Dearani's technique, 344
 - Delayed enhancement techniques, 230
 - Device thrombosis, risk of, 367
 - Digoxin, 36, 55, 277
 - Dilated cardiomyopathy, 50
 - Diuretics, 36
 - Doppler Tissue Imaging (DTI), 225, 226
 - De Vega* annuloplasty, 191, 333, 334
- E**
- Early gadolinium enhancement (EGE)
 - imaging, 169
 - Ebstein's anomaly, 14, 35, 38, 158–161, 314, 315, 339, 343
 - Eccentricity index, 239
 - ECG. *See* Electrocardiogram (ECG)
 - Echocardiography, 241, 274
 - advantages, 127
 - apical four-chamber view, 224
 - aspects of, 128
 - cardiac endovascular pacemaker-lead interference, 131, 133, 135, 139
 - eccentric jet, 139
 - functional TR
 - left sided heart disease, 135–137, 139
 - with structural component, 130, 132
 - morphology, 129
 - posterior leaflet, 139
 - postoperative, 139
 - right atrial size and function, 224
 - RV size, 228
 - septal leaflet, 139
 - systolic function, 225–228
 - TA, 224
 - tethering, 129
 - TR, 35
 - tricuspid annulus, 128
 - tricuspid regurgitation, 129
 - TTE, 138
 - EchoNavigator®-system, 383
 - Effective regurgitant orifice area (EROA), 284, 292, 294

Ejection fraction (EF), 225
 Elastic fibres, 9, 10
 Electrocardiogram (ECG), 35, 181, 274
 Endocarditis, 317, 342, 368
 Endovascular DDD pacemaker system, 132
 Epicardial DDD pacemaker system, 134
 Eplerenone, 277
 EROA. *See* Effective regurgitant orifice area (EROA)
 European Society of Cardiology (ESC) guidelines, 243, 245, 247
 Extracellular matrix, 10

F
 Flail tricuspid valve, 36, 38
 FORMA repair system, 36, 38, 69, 189, 195, 289–291, 365, 386
 4D CMR flow, 148, 150
 Functional tricuspid regurgitation, 13
 anterior leaflet, 335–336
 clover technique, 336, 337
 concomitant LHP requiring surgery, 332
 definition, 311
 enlarged/dilated ventricle, 13
 intraoperative details, 311
 left sided heart disease, 135–139
 outcome, 312
 patient presentation, 311
 ring annuloplasty, 334, 335, 337
 with structural component, 130–132
 suture annuloplasty, 337
 De Vega procedure, 333, 334
 Kay procedure, 333

TA
 deformation, 211–215
 geometry and function, 209–211
 remodelling, 210
 TR severity, assessment of, 107
 transcatheter treatment modalities, 286, 287, 291
 annuloplasty devices (*see* Annuloplasty devices)
 bicuspid valve implantation, 287–289
 leaflet coaptation, 289–291
 transcatheter TV therapy
 annuloplasty devices, 192
 CAVI, 195
 coaptation devices, 192
 percutaneous tricuspid annuloplasty, 192
 TV orifice, 195
 tricuspid annular dilatation, 333
 Furosemide, 50, 276

G
 GATE™ tricuspid atrioventricular valved stent, 359

H
 Hagen-Poiseuille's equation, 262
 Heart failure (HF), 369
 Heart transplantation (HTx), 50, 51, 53, 54
 clinical features, 55
 epidermiology, 53
 pathophysiology, 54
 prognosis, 55
 Heart valve disease, 13
 Hepatic venous flow, 105, 106
 Heterotopic caval transcatheter valve implantation, 68
 HTx. *See* Heart transplantation (HTx)

I
 Iatrogenic lesions, 13
 ICD. *See* Implantable cardioverter defibrillators (ICD)
 IE. *See* Infective endocarditis (IE)
 Implantable cardioverter defibrillators (ICD), 316
 clinical presentation, 62–63
 imaging, 64
 management
 lead extraction, 66
 medical, 65
 percutaneous transcatheter techniques, 68
 valvular surgery, 66
 mechanisms, 60
 pathophysiology, 60
 prevention
 lead location, 70
 lead type, 69
 Micra Transcatheter Pacing Study, 71
 prolapsing technique, 70
 subcutaneous cardioverter defibrillators, 71
 surveillance, 71
 Infective endocarditis (IE), 27, 162–164, 317
 Inferior leaflet, 7, 8, 14
 Inferior vena cava (IVC), 181, 190, 244, 263, 264, 288, 296, 360, 368
 Inotropic therapy, 259
 Intracardiac echocardiography (ICE), 382, 386
 IVC. *See* Inferior vena cava (IVC)

J

Jugular venous pressure (JVP), 274, 276

K

Kay surgical procedure, 291, 306, 333

L

Lanoxin. *See* Digoxin

Late gadolinium enhancement (LGE),
153–155, 162

Left ventricle (LV), 11, 16, 171, 183, 184, 222,
238, 274

Left ventricular assist device (LVAD), 39

Left ventricular ejection fraction (LVEF), 63

Left-sided heart pathology (LHP), 332

Left-sided valve surgery, 346

LGE. *See* Late gadolinium enhancement
(LGE)

LV. *See* Left ventricle (LV)

LVAD. *See* Left ventricular assist device
(LVAD)

M

Matrix metalloproteinases (MMP), 10

MDCT. *See* Multidetector computed
tomography (MDCT)

Mean pulmonary artery pressure (mPAP), 133

Millipede IRIS Implant, 296, 298, 300

Mineralocorticoid receptor antagonist
(MRA), 277

MitraClip implants, 69, 291, 366, 382, 385

Mitral regurgitation (MR), 355

Mitral valve repair, 305–306

Mitralign device, 68, 192, 293, 362, 368

Modified look-locker inversion recovery
(MOLLI) sequence, 160

Multi-detector computed tomography
(MDCT), 207, 213, 230

Multiplanar reconstruction (MPR) mode, 101

Multiplane iRotate mode, 80

Muscle of Lancisi, 11

Myocardial fibrosis, 152–155

Myxomas, 167

N

New York Heart Association (NYHA), 131,
135, 274, 289, 290, 294, 316, 347

Non-structural valve deterioration (NSVD),
310, 313

O

Ohm's law, 236, 262

Orthotopic valve implantation, 357–360

native tricuspid valve replacement

dedicated transcatheter TV

bioprosthesis, 357–360

non-dedicated THV implantation, 359

surgical bioprosthetic valve, 359–360

tricuspid valve-in-ring, 360

P

PA. *See* Pulmonary artery (PA)

Papillary fibroelastomas, 167

Papillary muscles (PMs), 80

anterior, 4, 11

antero-superior leaflet, 11

CT, 185

medial, 4, 12

PHT, parasternal short axis

view, 237, 239

primary disease, 339

right ventricle, 11, 14

smaller, 11

PCWP. *See* Pulmonary capillary wedge
pressure (PCWP)

Percutaneous transcatheter techniques, 68

Percutaneous tricuspid annuloplasty, 192

Percutaneous Tricuspid Valve Annuloplasty
System (PTVAS), 362

Pericardial approach, 386

Permanent pacemakers (PPM)

clinical presentation

clinical symptoms, 62

physical examination, 63

risk factors, 63

imaging, 64

management

lead extraction, 66

medical, 65

percutaneous transcatheter

techniques, 68

valvular surgery, 66

mechanisms, 60–62

pathophysiology, 60

prevention

lead location, 70

lead type, 69

Micra Transcatheter Pacing Study, 71

prolapsing technique, 70

subcutaneous cardioverter

defibrillators, 71

surveillance, 71

- Pharmacotherapy
 ACE-R, 277
 beta-blocker, 277
 digoxin, 277
 heart failure, 273
 lifestyle advises, 276
 loop diuretics, 276
 MRA, 277
 progressive fatigue, 274
 RAAS, 277
 TS, 29
- Phase sensitive inversion recovery sequences (PSIR), 153
- Phase-contrast velocity mapping, 147
 4D CMR flow, 148, 150
 limitations, 148
 magnitude image, 147, 148
 moving objects, 147
 phase velocity image, 147, 148
 phase, definition, 147
 post processing analysis, 148, 149
 stationary objects, 147
 TV regurgitation volume, 148
- PHT. *See* Pulmonary hypertension (PHT)
- PISA. *See* Proximal isovelocity surface area (PISA) method
- Pledget delivery catheter, 292
- PMS. *See* Papillary muscles (PMs)
- Posterior leaflet, 80, 118, 128, 139, 193, 381
- PPM. *See* Permanent pacemakers (PPM)
- Proximal isovelocity surface area (PISA) method
 apical 4-chamber view, 101
 estimation, 103
 quantification, 102
 3DE, quantification on, 104
 TR, grading severity of, 123
- Pulmonary arterial hypertension (PAH), 281, 282
- Pulmonary artery (PA)
 dilatation, 248
 parasternal long axis view, 239
 pressure estimation
 pulmonary valve regurgitation, 245
 right ventricle outflow pulsed wave
 Doppler velocity, 247
 TR, 242
- Pulmonary capillary wedge pressure (PCWP), 254, 257, 263, 264
- Pulmonary embolism (PE), 230
- Pulmonary hypertension (PHT), 34, 36, 39, 255, 262, 263, 267
 causes, 236
 4-chamber view, 240
 high pulmonary artery pressures, 240
 Ohm's law, pulmonary circulation, 236
- PA pressure estimation
 pulmonary valve regurgitation, 245–247
 right ventricle outflow pulsed wave
 Doppler velocity, 247, 248
 TR, 242–245
- parasternal long axis view
 LV, 238
 PA, 238, 239
 pulmonary valve, 238, 239
 RV, 238, 239
- parasternal short axis views
 main pulmonary artery, 238, 239
 papillary muscles, 237–239
 pulmonary valve, 238, 239
 pulmonary artery dilatation, 248
 right ventricle dilatation, 240
 right ventricular function, 236
 tricuspid valve anatomy, 240
- Pulsed wave Doppler, 247, 248
- R**
- Radiation dose, 180, 187
- Radionuclide techniques, 222, 230
- RCA. *See* Right coronary artery (RCA)
- Real-time three-dimensional techniques, 184
- Regurgitant orifice area (ROA), 102, 103, 123
- RHC. *See* Right heart catheterization (RHC)
- Rheumatic heart disease, 27, 161, 313, 317
- Right atrial pressure, 243
- Right coronary artery (RCA), 188, 193
- Right heart catheterization (RHC), 281
 cardiac compartments, 254, 255
 CO, calculation of, 259
 complication, 254, 255
 diastolic dysfunction, diagnosis of, 254
 hemodynamic information, 259
 intra-cardiac shunts, 260, 261
 loop making, 258
 normal pressure values, 259
 PCWP, 254, 256, 257
 RA, 255, 257
 Swan-Ganz catheter, 254, 259, 264
 vascular bed, resistance of, 262, 263
 CO, 266, 267
 Hagen-Poiseuille's equation, 262
 Ohm's law, 262
 pulmonary vascular resistance, 262, 267
 shunt calculation, 264
 systemic vascular resistance, 262
 venous access, 254

- Right heart diseases, 181–183, 253
- Right ventricle (RV)
- anatomy, 222
 - banana-shaped configuration, 237
 - canal valve implantation, 386
 - function, 222
 - ICD, 62
 - imaging modalities
 - advantages, 231
 - CMR, 228–230
 - disadvantages, 231
 - echocardiography, 223–228
 - MDCT, 228–230
 - radionuclide techniques, 230
 - PHT
 - dilatation, 240
 - parasternal long axis view, 239
 - parasternal short axis views, 239
 - physiology, 222
 - PPM, 62
 - RHC, 262–263
- Right ventricle index of myocardial performance (RIMP), 225
- Right ventricular apex, 189
- Right ventricular ejection fraction (RVEF), 62, 64
- Right ventricular fractional area change (RV FAC), 225, 226
- Right ventricular outflow tract (RVOT), 62, 70, 90, 155, 165, 223, 227
- Ring annuloplasty, 67, 334, 335, 337
- Rosetta Stone nomenclature, 383
- RV. *See* Right ventricle (RV)
- RV FAC. *See* Right ventricular fractional area change (RV FAC)
- RVOT. *See* Right ventricular outflow tract (RVOT)
- S**
- Secondary tricuspid regurgitation. *See* Functional tricuspid regurgitation
- Self-expandable dedicated valve devices, 287
- Septal leaflet, 7, 8, 14, 80, 144, 381
- CT, 185
 - echocardiography, 139, 140
 - multiple tendinous cord attachments, 8
 - TOE, 118
 - tricuspid annulus, 128
- Septomarginal trabeculation (SMT), 4, 12
- SGE sequences. *See* Spoiled gradient echo (SGE) sequences
- Speckle-tracking echocardiography, 226
- Spironolactone, 277
- Spoiled gradient echo (SGE) sequences, 145, 147
- Steady state free-precession (SSFP) imaging, 145, 147, 150, 159, 167, 171, 185, 229
- Stenosis, 15, 309, 315, 360, 379
- Stenotic aortic valve, 305
- Step-and-shoot method, 180
- Strain, definition of, 226–227
- Structural valve deterioration (SVD), 310, 313, 315, 316
- Subcutaneous cardioverter defibrillators, 71
- Superior vena cava (SVC), 263, 264, 288, 360, 361, 368
- Suture annuloplasty technique, 67, 337
- SVC. *See* Superior vena cava (SVC)
- SVD. *See* Structural valve deterioration (SVD)
- Swan-Ganz catheter, 254, 259, 264
- Sympathetic nervous system (SNS), 277
- T**
- TA. *See* Tricuspid annulus (TA)
- TAVR. *See* Transcatheter aortic valve replacement (TAVR)
- TEE. *See* Trans-esophageal echocardiography (TEE)
- Tei index, 225
- Tendon of Todaro, 5, 331
- 3D color Doppler, 124
- 3D echocardiography, 139, 140, 206, 208, 211, 213, 227, 228
- RV, 237
 - TOE, 121
- Three-dimensional transthoracic echocardiography (3D TTE), 70, 82, 88, 383
- ICD, 64
 - PPM, 64
- Ti-cron sutures, 341
- Tissue engineering, 318
- Tissue homeostasis, 61
- Tissue inhibitor of matrix metalloproteinases (TIMP), 10
- TOE imaging. *See* Transesophageal echocardiographic (TOE) imaging
- TR. *See* Tricuspid regurgitation (TR)
- Transatrial intrapericardial tricuspid annuloplasty (TRAIPTA) device, 296, 298, 364
- Transcatheter aortic valve implantation (TAVI), 355

- Transcatheter aortic valve replacement (TAVR), 68
- Transcatheter tricuspid valve annuloplasty, 68
- Transcatheter tricuspid valve interventions (TTVIs)
 - annuloplasty device
 - Mitralign device, 362–364
 - superiority of ring annuloplasty, 365
 - TRAIPTA, 364
 - TriCinch system, 364
 - coaptation devices
 - Forma Repair System, 365–366
 - MitraClip system, 366
 - efficacy, 368–373
 - heterotopic valve implantation
 - balloon-expandable transcatheter heart valves, 361
 - IVC and SVC, 360
 - self-expanding nitinol stent, 361
 - orthotopic valve implantation, 357
 - pre-procedural planning, 368–369
 - procedural guidance, 368
 - safety issues, 367–368
- Transcatheter tricuspid valve therapy
 - anatomical considerations, 380–381
 - annuloplasty devices, 192
 - canal valve implantation, 386
 - CAVI, 195
 - coaptation devices, 192
 - imaging guidance, 381–384
 - MitraClip implants, 385
 - outcomes, 386
 - patients selection, 380
 - percutaneous tricuspid annuloplasty, 192–194
 - pericardial approach, 386
 - tricuspid annuloplasty devices, 385
 - tricuspid valve spacer, 386
 - TV orifice, 195
 - valve-in-ring procedures, 384
- Transcatheter valve-in-ring procedure, 381–384
- Transesophageal echocardiographic (TOE) imaging
 - anterior leaflet, 118
 - commissure, 118
 - mid-esophageal level, 118, 119
 - posterior leaflet, 118
 - septal leaflet, 118
 - 3D echocardiography, 121
 - three-dimensional imaging, 119
 - TR, grading severity of, 121
 - transgastric level, 119
- Trans-esophageal echocardiography (TEE), 81, 130, 134, 136, 137, 139, 193, 284, 286, 382
- Transfemoral approach, 384
- Transthoracic echocardiography (TTE)
 - acquisitions, 82
 - advantages, 80
 - analysis, 85, 86
 - bi-plane mode, 89
 - display, 85–87
 - 4-chamber view
 - iRotate mode, 90–92
 - modes, 81
 - simultaneous multiplane imaging, 89
 - 3D-TTE, 82, 87–89
 - TR (*see* Tricuspid regurgitation (TR))
 - tricuspid valve assessment, 92
 - 2D-TTE, 82–85
 - TV annulus, 108, 109
 - TV apparatus, 80–81
 - TV stenosis, 92, 93
- Traumatic lesion, 346
- Trialign device, 291, 293, 295
- Triangle of Koch, 331
- Tric valve device, 287, 288
- TriCinch device, 68, 295, 364
- Tricuspid annular plane systolic excursion (TAPSE), 90, 225
- Tricuspid annuloplasty repair techniques, 191
- Tricuspid annulus (TA), 6, 144, 195, 241
 - annular dilation, 356
 - CT, 186
 - deformation, 214, 215
 - diameters, 215
 - dilation measurement, 13, 211–214
 - dimension measurement, 224
 - Doppler Tissue Imaging, 226
 - dynamics, 206
 - echocardiography, 128
 - geometry and function, in functional TR, 209
 - shape of, 206, 381
 - size, 206–209
- Tricuspid atresia, 15, 16
 - complication, 41
 - investigations, 40
 - management, 40
 - presentation, 40
 - prognosis, 41
- Tricuspid regurgitation (TR)
 - acquired lesions, 13
 - adhesions, 13
 - antero-superior leaflet, 14
 - approach considerations, 37

- Tricuspid regurgitation (TR) (*cont.*)
- carcinoid heart disease, 39
 - cardiac catheterisation, 35
 - cardiac magnetic resonance, 35
 - chest X ray, 35
 - colour flow Doppler, 96, 98
 - congenital tricuspid malformations, 15
 - continuous-wave Doppler, jet on, 104, 105
 - CT, 185
 - defibrillators-induced TR, 38
 - diagnostic algorithm, 95
 - differential diagnosis, 34
 - DTI, 226
 - Ebstein anomaly, 14, 38
 - ECG, 35
 - echocardiography, 35, 129
 - etiology, 95
 - flail TV, 38
 - grading severity, TOE, 121
 - hepatic venous flow, 105
 - HTx, 50–54
 - clinical features, 55
 - epidemiology, 53
 - management, 55–56
 - pathophysiology, 54–55
 - iatrogenic lesions, 13
 - ICD, 60
 - clinical symptoms, 62–63
 - lead extraction, 65–66
 - lead location, 70–71
 - lead type, 69
 - mechanisms, 60
 - medical management, 65
 - Micra Transcatheter Pacing Study, 71
 - pathophysiology, 60
 - percutaneous transcatheter techniques, 68–69
 - physical examination, 63
 - prolapsing technique, 70
 - risk factors, 63
 - subcutaneous cardioverter defibrillators, 71
 - surveillance, 71
 - valvular surgery, 66–68
 - jet area, 96, 100
 - jet VC, 100, 101
 - left-sided valve surgery, 346
 - long-term monitoring, 36–37
 - LVAD, 39
 - mechanism of, 95, 280, 281
 - medical therapy, 36
 - mild, 94, 155
 - moderate, 94
 - moderate-to-severe, prevalence of, 30
 - natural history, 35
 - outcome, 281–282
 - pacemakers, 38
 - pathophysiology, 30–31
 - PHT, PA pressure estimation, 242
 - physical examination, 31–34
 - physiologic, 30
 - PISA, 101–104
 - PPM, 60
 - clinical symptoms, 62
 - imaging, 64, 65
 - lead extraction, 66
 - lead location, 70
 - lead type, 69
 - mechanisms, 60
 - medical management, 65
 - Micra Transcatheter Pacing Study, 71
 - pathophysiology, 60
 - percutaneous transcatheter techniques, 68
 - physical examination, 63
 - prolapsing technique, 70
 - risk factors, 63
 - subcutaneous cardioverter defibrillators, 71
 - surveillance, 71
 - valvular surgery, 66
 - pregnancy, 39
 - prevalence of, 280, 281
 - primary, 30, 31, 156
 - carcinoid tumours, 164–166
 - Ebstein's anomaly, 158–161
 - IE, 162, 163
 - rheumatic heart disease, 161
 - traumatic, 170
 - tumours, 166–169
 - prognosis, 35
 - RHC, 258
 - secondary, 30, 31, 39, 155–158
 - septal leaflet, 14
 - severity, 94
 - assessment of, 285
 - grading of, 96
 - signs of, 105–107
 - surgery, 282, 283
 - TAPSE, 225
 - transcatheter interventions, 283, 354–356
 - TTVI (*see* Transcatheter tricuspid valve interventions (TTVIs))
- Tricuspid repair, 354
- annuloplasty, 307
 - functional tricuspid regurgitation
 - anterior leaflet, 336
 - clover technique, 336, 337
 - concomitant LHP requiring surgery, 332

- ring annuloplasty, 334, 337
 - suture annuloplasty, 337
 - suture annuoplasty, 333
 - tricuspid annular dilatation, 333
- intra operative details, 307
- mortality, 306
- outcomes, 308
- patient presentation, 307
- preoperative characteristics and etiology, 307
- primary disease
 - chordae, 338–339
 - commissures, 339
 - leaflet, intervention on, 338
 - papillary muscle, 339
- valvoplasty, 307
- Tricuspid stenosis (TS)
 - aetiology and pathogenesis
 - carcinoid tumors, 27
 - congenital TS, 27
 - infective endocarditis, 27
 - rheumatic heart disease, 27
 - unusual causes, 28
 - cardiac catheterization, 29
 - CMR, 156, 170, 171
 - common symptoms, 24
 - consultation, 29
 - CXR, 28
 - differential diagnosis, 28
 - echocardiography, 28
 - electrocardiogram, 28
 - frequency, 24
 - less common symptoms, 25
 - management, 29
 - natural history, 24
 - physical examination, 25
 - stages of, 26
 - TTE, 92–94
- Tricuspid valve (TV)
 - anatomy, 144
 - commissures, 8
 - components
 - medial and anterior papillary muscles, 4
 - triangle of Koch, 5
 - tricuspid and pulmonary valves,
 - position of, 5
 - tricuspid annulus, 6
 - CT (*see* Computed tomography (CT))
 - echocardiography
 - advantages, 127
 - aspects of, 128
 - cardiac endovascular pacemaker-lead
 - interference, 131–135, 139
 - eccentric jet, 139
 - functional TR, 130, 132, 135–137, 139
 - morphology, 129
 - posterior leaflet, 139
 - postoperative, 139
 - septal leaflet, 139
 - tethering, 129
 - 3D, 139, 140
 - tricuspid annulus, 128
 - tricuspid regurgitation, 129
 - TTE, 138
- ICD, 60
- leaflets
 - anterosuperior, 7, 8
 - atrialis, 9
 - basal zone, 9
 - collagen fibres, 10
 - complete closure and apposition, 7
 - composed of, 10
 - connective tissue fibres, 9, 10
 - connective tissue integrity, 10
 - external factors, 10
 - extracellular matrix, 10
 - fibrosa layer, 9
 - inferior, 7, 8
 - interstitial fibroblasts, 9
 - matrix enzymes, 10
 - septal, 7, 8
 - trifoliate configuration, 7
 - ventricularis, 9
- papillary muscles
 - anterior, 4, 11
 - antero-superior leaflet, 11
 - medial, 4, 12
 - right ventricle, 11, 14
 - smaller, 11
- PHT, 240–241
- physiological changes, 13
- PPM, 60
- tendinous cords, 10, 11
- TOE
 - anterior leaflet, 118
 - commissure, 118
 - mid-esophageal level, 118, 119
 - posterior leaflet, 118
 - septal leaflet, 118
 - 3D echocardiography, 121
 - three-dimensional imaging, 119
 - TR, grading severity of, 121–124
 - transgastric level, 119
- triangle of Koch, 4
- tricuspid and pulmonary valves,
 - position of, 4
- tricuspid annulus, 6
- tricuspid orifice, 6
- TTE images, 184

- Tricuspid valve annulus
 - 3D-TTE over 2D-TTE, 88
 - TTE, 108, 109
 - Tricuspid valve (TV)
 - disease, 13, 23, 92, 273, 274
 - carcinoid syndrome, 345
 - CPB, 329–332
 - Ebstein’s anomaly, 343–345
 - endocarditis, 342–343
 - JVP findings, 25
 - late tricuspid regurgitation, 346–349
 - pharmacotherapy, 276–277
 - stenosis, 15, 16, 156, 170, 171, 379
 - straddling TV, 17
 - traumatic lesion, 346
 - tricuspid atresia, 40–41
 - TVR, 340–342
 - Tricuspid valve replacement
 - (TVR), 297–300, 342
 - bioprostheses vs. mechanical prosthesis, 309, 317
 - carcinoid syndrome, 345
 - Ebstein’s anomaly, 345
 - mortality, 306
 - outcomes, 310
 - preoperative characteristics and
 - etiology, 307
 - prosthetic value, 340
 - surgical technique, 340, 341
 - Tricuspid valve surgery
 - carcinoid heart disease, 316
 - congenital defects, 314–315
 - endocarditis, 316–317
 - functional tricuspid regurgitation
 - definition, 311
 - intraoperative details, 311
 - outcome, 312
 - patient presentation, 311
 - ICD, 316
 - percutaneous interventions, 318
 - rheumatic heart disease, 313, 314, 317
 - tissue engineering, 318
 - tricuspid repair, 317
 - annuloplasty, 307
 - intra operative details, 307
 - mortality, 306
 - outcomes, 308
 - patient presentation, 307
 - preoperative characteristics and
 - etiology, 307
 - valvoplasty, 307
 - TV replacement
 - bioprostheses vs. mechanical
 - prosthesis, 309, 317
 - mortality, 306
 - outcomes, 310
 - preoperative characteristics and
 - etiology, 307
 - Tricuspid valvulotomy, 306
 - TricValve, 361
 - TrinCinch device, 193
 - TS. *See* Tricuspid stenosis (TS)
 - TTE. *See* Trans thoracic echocardiography (TTE)
 - TTVIs. *See* Transcatheter tricuspid valve interventions (TTVIs)
 - TV. *See* Tricuspid valve (TV)
 - TVR. *See* Tricuspid valve replacement (TVR)
 - 2D echocardiography, 139, 207, 211, 212, 227
 - ICD, 64
 - PPM, 64
 - RV, 237
 - 2-dimensional transthoracic echocardiography
 - (2D TTE), 62, 81–85, 87, 89, 129, 139
 - Two-stage femoral vein cannula, 330
- V**
- Valvar stenosis, 15–16
 - Valvular surgery, 66
 - Velocity timed integral (VTI), 93
 - Vena cava inferior (VCI), 50
 - Vena contracta area (VCA), 89, 100, 101, 124
 - Vena saphenous magna (VSM) graft, 134
 - Ventricular septal defect (VSD), 170, 171
 - Vertical right atriotomy, 330
 - VSD. *See* Ventricular septal defect (VSD)
 - VVI-pacemaker system, 133