

Pathology for Clinicians

Kyle Perry

# Soft Tissue Pathology for Clinicians

 Springer

---

# Pathology for Clinicians

## **Series Editor**

Ivan Damjanov

University of Kansas School of Medicine

Kansas City, KS, USA

More information about this series at <http://www.springer.com/series/13438>

---

Kyle Perry

# Soft Tissue Pathology for Clinicians

 Springer

Kyle Perry  
Department of Pathology  
University of Manitoba Max Rady College of Medicine  
Winnipeg, MB, Canada

Pathology for Clinicians  
ISBN 978-3-319-55653-6 ISBN 978-3-319-55654-3 (eBook)  
DOI 10.1007/978-3-319-55654-3

Library of Congress Control Number: 2017935816

© Springer International Publishing AG 2017

This work is subject to copyright. All rights are reserved by the Publisher, whether the whole or part of the material is concerned, specifically the rights of translation, reprinting, reuse of illustrations, recitation, broadcasting, reproduction on microfilms or in any other physical way, and transmission or information storage and retrieval, electronic adaptation, computer software, or by similar or dissimilar methodology now known or hereafter developed.

The use of general descriptive names, registered names, trademarks, service marks, etc. in this publication does not imply, even in the absence of a specific statement, that such names are exempt from the relevant protective laws and regulations and therefore free for general use.

The publisher, the authors and the editors are safe to assume that the advice and information in this book are believed to be true and accurate at the date of publication. Neither the publisher nor the authors or the editors give a warranty, express or implied, with respect to the material contained herein or for any errors or omissions that may have been made. The publisher remains neutral with regard to jurisdictional claims in published maps and institutional affiliations.

Printed on acid-free paper

This Springer imprint is published by Springer Nature  
The registered company is Springer International Publishing AG  
The registered company address is: Gewerbestrasse 11, 6330 Cham, Switzerland

*This book is dedicated to my wife,  
Anamarija, and my daughter, Anabelle,  
for the support they have given me during  
my career. I would also like to thank  
my mother and father in-law, Vojimira  
Morovic and Ante Surac, for their support.*

---

## Preface

Similar to other areas of oncology, the diagnosis and treatment of sarcomas are increasingly accomplished as a collaboration of a diverse team of subspecialists. This allows modern medicine to maintain a holistic and pragmatic approach when caring for cancer patients. However, the ability of physicians to effectively administer care in this manner largely depends on clear communication across specialty boundaries.

Soft tissue pathology encompasses a vast amount of neoplasms that are typically not unique to a particular anatomic location, and pathologists are increasingly incorporating an expanding catalogue of immunohistochemical and genetic tests when making a diagnosis. With this in mind, this book was written to give perspective in the diagnosis of soft tissue tumors to those practicing outside of pathology. In particular, this book will focus on the key characteristics of common soft tissue neoplasms and the approach taken to render a diagnosis. It will also cover critical aspects of soft tissue pathology that are encountered by a treating physician, such as tumor staging, intraoperative consultation, and considerations in processing soft tissue surgical specimens.

Many excellent reference books have been written to discuss soft tissue pathology in a comprehensive manner. By focusing on the interdisciplinary interactions involving soft tissue pathology, it is hoped that this concise booklet will be of value to oncologists, surgeons, medical oncology trainees, and mid-level providers by further facilitating meaningful communication in a team practice environment.

Winnipeg, Manitoba, Canada

Kyle Perry

---

# Contents

<b>1</b>	<b>Critical Concepts in Soft Tissue Pathology</b> . . . . .	1
1.1	General Principles of Classification. . . . .	1
1.2	Acquisition, Handling, and Processing of Soft Tissue Specimens. . . . .	4
	References. . . . .	6
<b>2</b>	<b>Histologic Examination and Ancillary Studies in Soft Tissue Pathology</b> . . . . .	7
2.1	Pathologist Approach to Diagnosis . . . . .	7
2.2	Diagnostic Ancillary Studies . . . . .	15
2.2.1	Immunohistochemistry . . . . .	15
2.2.2	Karyotyping . . . . .	15
2.2.3	Molecular Fluorescence In Situ Hybridization . . . . .	18
2.2.4	Reverse transcription PCR . . . . .	18
2.3	Intraoperative Consultation . . . . .	18
	References. . . . .	21
<b>3</b>	<b>Grading, Staging, and Reporting of Soft Tissue Tumors</b> . . . . .	23
3.1	Assigning a Pathologic Grade to Soft Tissue Tumors . . . . .	23
3.2	Assigning a Pathologic Stage to Soft Tissue Tumors . . . . .	25
3.3	Interpreting a Soft Tissue Pathology Report . . . . .	25
	References. . . . .	28
<b>4</b>	<b>Lipomatous Tumors</b> . . . . .	29
4.1	Lipoma . . . . .	29
4.2	Angiolipoma . . . . .	31
4.3	Spindle Cell/Pleomorphic Lipoma. . . . .	33
4.4	Hibernoma . . . . .	35
4.5	Lipoblastoma . . . . .	36
4.6	Atypical Lipomatous Tumor/Well-Differentiated Liposarcoma. . . . .	37
4.7	Dedifferentiated Liposarcoma . . . . .	40
4.8	Myxoid Liposarcoma . . . . .	41
4.9	Pleomorphic Liposarcoma. . . . .	43
	References. . . . .	45

<b>5</b>	<b>Fibroblastic/Myofibroblastic Tumors</b> . . . . .	49
5.1	Nodular Fasciitis and Similar Lesions . . . . .	49
5.2	Fibroma of Tendon Sheath . . . . .	53
5.3	Nuchal-Type Fibroma . . . . .	54
5.4	Gardner-Associated Fibroma . . . . .	56
5.5	Elastofibroma . . . . .	57
5.6	Superficial Fibromatosis . . . . .	59
5.7	Deep (Desmoid-Type) Fibromatosis . . . . .	60
5.8	Solitary Fibrous Tumor . . . . .	62
5.9	Inflammatory Myofibroblastic Tumor . . . . .	65
5.10	Dermatofibrosarcoma Protuberans . . . . .	67
5.11	Congenital/Infantile Fibrosarcoma . . . . .	70
5.12	Low-Grade Fibromyxoid Sarcoma . . . . .	71
5.13	Myxofibrosarcoma . . . . .	74
5.14	Adult-Type Fibrosarcoma . . . . .	76
	References . . . . .	78
<b>6</b>	<b>Fibrohistiocytic Lesions</b> . . . . .	81
6.1	Fibrous Histiocytoma . . . . .	81
6.2	Solitary Xanthogranuloma . . . . .	85
6.3	Tenosynovial Giant Cell Tumor, Localized Type . . . . .	87
6.4	Tenosynovial Giant Cell Tumor, Diffuse Type . . . . .	89
	References . . . . .	91
<b>7</b>	<b>Smooth Muscle and Perivascular Tumors</b> . . . . .	93
7.1	Glomus Tumor . . . . .	93
7.2	Cutaneous Leiomyoma . . . . .	97
7.3	Deep Leiomyoma . . . . .	99
7.4	Cutaneous Leiomyosarcoma . . . . .	101
7.5	Deep Leiomyosarcoma . . . . .	103
	References . . . . .	106
<b>8</b>	<b>Skeletal Muscle Tumors</b> . . . . .	109
8.1	Rhabdomyoma . . . . .	109
8.2	Embryonal Rhabdomyosarcoma . . . . .	112
8.3	Alveolar Rhabdomyosarcoma . . . . .	115
8.4	Pleomorphic Rhabdomyosarcoma . . . . .	118
	References . . . . .	121
<b>9</b>	<b>Neural and Nerve Sheath Lesions</b> . . . . .	123
9.1	Schwannoma . . . . .	123
9.2	Neurofibroma . . . . .	126
9.3	Perineurioma . . . . .	130
9.4	Granular Cell Tumor . . . . .	133
9.5	Malignant Peripheral Nerve Sheath Tumor . . . . .	135
	References . . . . .	138



<b>10</b>	<b>Vascular Lesions</b> . . . . .	139
10.1	Kaposi Sarcoma . . . . .	139
10.2	Epithelioid Hemangioendothelioma . . . . .	143
10.3	Kaposiform Hemangioendothelioma . . . . .	145
10.4	Angiosarcoma . . . . .	148
	References . . . . .	152
<b>11</b>	<b>Cartilaginous and Osseous Tumors of Soft Tissue</b> . . . . .	155
11.1	Extraskelatal Chondroma . . . . .	155
11.2	Extraskelatal Mesenchymal Chondrosarcoma . . . . .	158
11.3	Extraskelatal Osteosarcoma . . . . .	160
	References . . . . .	162
<b>12</b>	<b>Tumors of Uncertain Differentiation</b> . . . . .	163
12.1	Intramuscular Myxoma . . . . .	163
12.2	Superficial Angiomyxoma . . . . .	165
12.3	Hemosiderotic Fibrolipomatous Tumor . . . . .	167
12.4	Myoepithelioma of Soft Tissue . . . . .	169
12.5	Ossifying Fibromyxoid Tumor . . . . .	171
12.6	Alveolar Soft Part Sarcoma . . . . .	173
12.7	Clear Cell Sarcoma of Soft Tissue . . . . .	175
12.8	Extraskelatal Ewing Sarcoma . . . . .	177
12.9	Desmoplastic Small Round Cell Tumor . . . . .	179
12.10	PEComa (and Similar Neoplasms) . . . . .	180
12.11	Epithelioid Sarcoma . . . . .	182
12.12	Extrarenal Rhabdoid Tumor . . . . .	185
12.13	Synovial Sarcoma . . . . .	186
12.14	Extraskelatal Myxoid Chondrosarcoma . . . . .	188
12.15	Undifferentiated High-Grade Pleomorphic Sarcoma . . . . .	190
	References . . . . .	192
<b>13</b>	<b>Gastrointestinal Stromal Tumor</b> . . . . .	197
13.1	Introduction . . . . .	197
13.2	Gastrointestinal Stromal Tumor . . . . .	197
	References . . . . .	201
	<b>Index</b> . . . . .	203

---

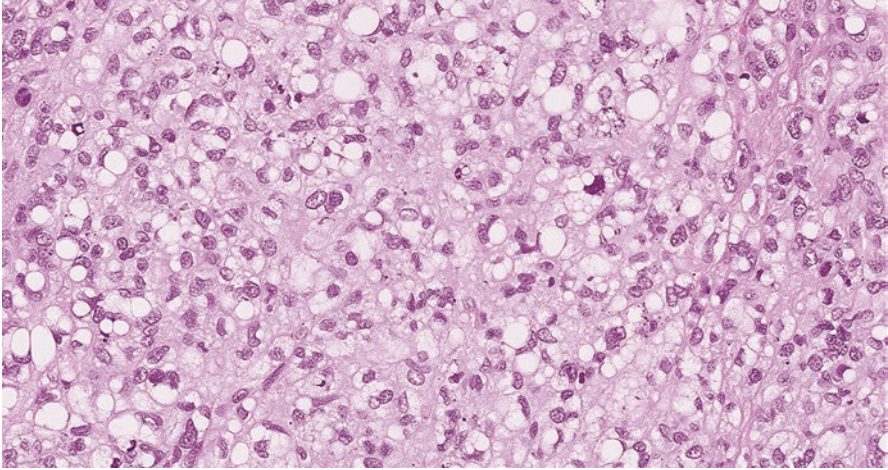
## 1.1 General Principles of Classification

Soft tissue pathology is a subspecialty that involves the diagnosis of lesions that are neither epithelial nor skeletal and do not originate from the central nervous system. This includes neoplasms of muscle, connective fascia, vasculature, and the peripheral nervous system [1]. With such an ambitious definition, the scope of this subspecialty is broad and encompasses a formidable number of entities with specific histologic, genetic, and clinical features.

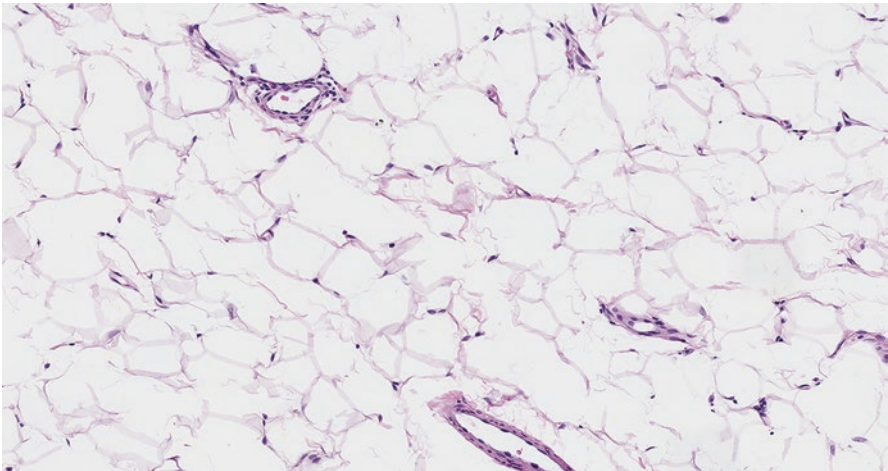
When encountering such an abundance of terms and neoplasms, one can be tempted to view soft tissue tumors simply by histologic grade. Although this approach simplifies several hundred neoplasms into low-, intermediate-, or high-grade sarcoma, it overgeneralizes and is incompatible with increasingly individualized treatment regimens. By classifying soft tissue neoplasms to a particular histologic entity, pathologists have been able to attribute unique clinical behaviors to specific tumors and establish a conceptual framework for future advances in soft tissue oncology [2]. Consequently, clinicians who frequently treat sarcoma patients can benefit from understanding the diagnostic terms and approach of soft tissue pathologists.

In order to maintain consistency, the diagnostic nomenclature of soft tissue pathology is determined by a consensus of international experts. Every few years, this terminology is edited to reflect the addition of newly discovered neoplasms or reassignment of entities to different categories. These efforts are published as a volume in the World Health Organization Classification of Tumours book series, titled *Pathology and Genetics of Tumours of Soft Tissue and Bone* [3].

Unlike carcinomas that are often classified by site of occurrence (e.g. colorectal adenocarcinoma, gastric adenocarcinoma), a soft tissue tumor can arise in multiple areas and is not amenable to description by anatomic location. Instead, these neoplasms are described according to the connective tissue that they most closely



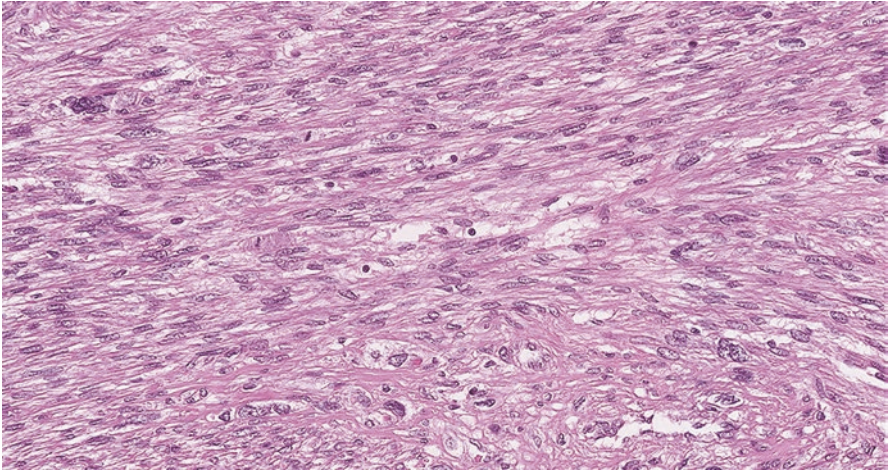
**Fig. 1.1** Pleomorphic liposarcoma with lipoblasts



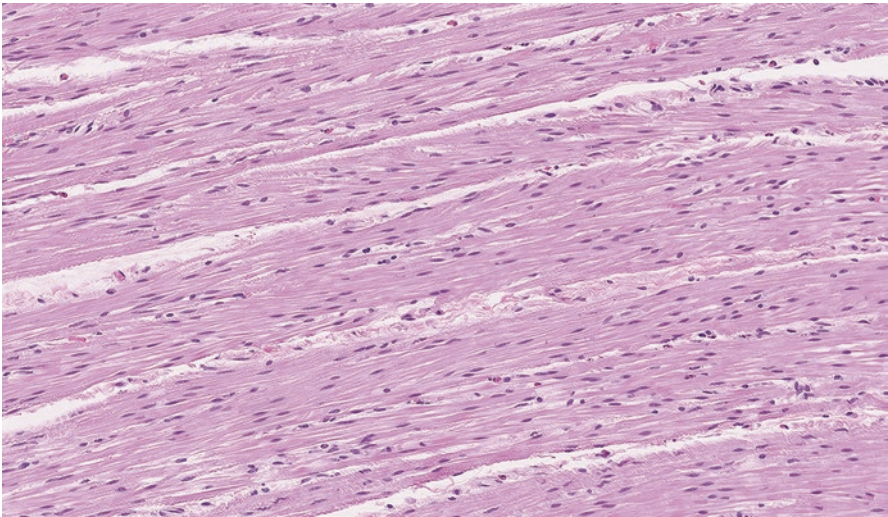
**Fig. 1.2** Normal adipose tissue

resemble. Such entities include pleomorphic liposarcoma (Fig. 1.1) that resembles fat (Fig. 1.2) or leiomyosarcoma (Fig. 1.3) that resembles smooth muscle (Fig. 1.4). Many soft tissue tumors do not resemble any specific mesenchymal tissue and are simply designated as “tumors of uncertain differentiation” [3].

Following primary histologic classification, soft tissue tumors are further subdivided into clinical categories of benign, intermediate (locally aggressive), intermediate (rarely metastasizing), and malignant. Most benign lesions do not recur, and rare instances of recurrence are easily cured by complete local excision. Intermediate



**Fig. 1.3** Leiomyosarcoma with neoplastic muscle cells showing mitoses and nuclear atypia



**Fig. 1.4** Normal smooth muscle

(locally aggressive) tumors will not metastasize but are prone to recurrence and require wide excision given their infiltrative growth pattern. Intermediate (rarely metastasizing) soft tissue tumors are typically locally aggressive, but demonstrate the capability to occasionally metastasize (less than 2% risk). Malignant tumors are locally destructive and often metastasize. Generally, high-grade tumors tend to metastasize more frequently than low-grade tumors [3].

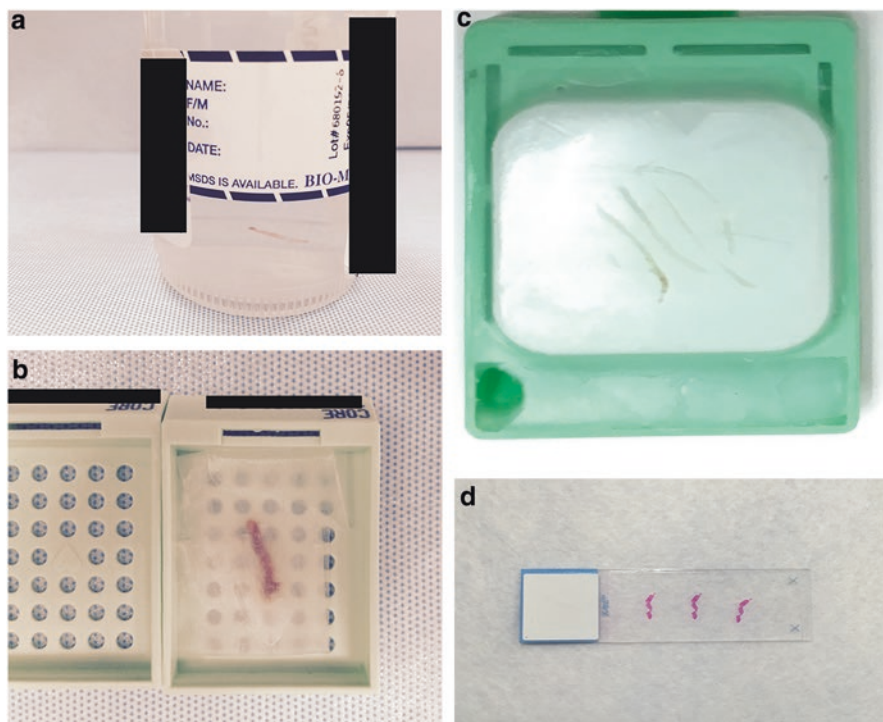
## 1.2 Acquisition, Handling, and Processing of Soft Tissue Specimens

Ultrasound or computed tomography (CT)-guided needle core biopsies have become the preferred procedure for diagnosing soft tissue neoplasms, as they are minimally invasive and less prone to surgical complications. Histologic interpretation of these biopsies is both sensitive (99.4%) and specific (98.7%) when distinguishing benign from malignant tumors [5]. The accuracy of needle core biopsies for a specific histologic diagnosis is also impressive (approximately 95% correct) [6]. Assessment of tumor grade in biopsies (low vs. intermediate vs. high) is helpful but slightly less accurate (approximately 85% correct) [7]. The interpretation of a needle core biopsy often represents a critical juncture in the care of a patient with a soft tissue neoplasm. A benign lesion might be monitored or undergo simple excision. A low-grade sarcoma is resected without neoadjuvant therapy, and an intermediate- or high-grade sarcoma often receives presurgical adjuvant treatment.

Following a biopsy or resection, the tissue is submitted to the pathology laboratory for evaluation. In order to prevent tissue degradation, many hospitals or clinics will place the biopsies directly into formalin in the operating suite. However, if a clinician or pathologist has an interest in culturing or freezing a representative part of the biopsy for possible cytogenetic or molecular studies, then at least some of the tissue must be maintained in a fresh, viable state and transported in cell culture media. Close communication with the pathologist is helpful in assuring the tissue is appropriately handled.

Upon arrival to the laboratory, the specimen must pass through a standardized process prior to visualization as a glass slide under the microscope. The tissue initially arrives in a labeled container with an accompanying requisition form that is reviewed by lab personnel (Fig. 1.5a). Including critical information on this form about the history of the patient or nature of the lesion facilitates a timely and accurate diagnosis. Awareness of the site and size of the mass helps the pathologist formulate a differential diagnosis based on anatomic location. Knowledge of previous malignancies (including prior diagnosis of carcinoma, melanoma, or hematolymphoid neoplasm) alerts the pathologist to recurrent or metastatic tumors that might mimic a sarcoma. Communication of familial syndromes, such as neurofibromatosis, helps raise a suspicion of certain malignant neoplasms like malignant peripheral nerve sheath tumor [4].

After reviewing the requisition and confirming the specimen is appropriately labeled, the pathologist or pathology assistant will typically describe the appearance of the tissue received (i.e. gross examination). For needle core biopsies, the number and size of the biopsies are documented. With resection specimens, the pathologist describes the location and size of the mass, as well as the distance from the surgical resection margin. The surgeon will often designate multiple anatomically specific margins by orienting the specimen with sutures (e.g., long suture, superior margin; short suture, medial margin). To preserve this orientation, the pathologist will typically paint the corresponding margins with an ink that can be seen under the microscope after processing. If there is a particular area of concern for margin involvement,



**Fig. 1.5** (a) Specimen container with a needle core biopsy, (b) needle core biopsy wrapped in tissue paper for processing, (c) needle core biopsy embedded in paraffin wax after tissue processing, (d) needle core biopsy after being processed, cut and stained with hematoxylin and eosin

specific designation by the surgeon can assure this focus is appropriately examined and referenced in the report. Moreover, if the margin has become artificially ruptured, proactively notifying the pathologist can help avoid an erroneous report.

Once gross examination is complete, the tissue is submitted for processing. For needle core biopsies, the objective is to have sufficient tissue for diagnosis and grading. Consequently, many pathology laboratories will submit all of the received biopsies in a formalin fixative solution that suspends enzymatic processes and halts tissue degradation (Fig. 1.5b). Following formalin fixation, the biopsy is processed and ultimately immersed in paraffin wax, termed a “paraffin block” (Fig. 1.5c). A thin slice of this biopsy is then cut, placed on a glass slide and stained for microscopic examination (Fig. 1.5d).

For resection specimens, the pathologist must select which tissue fragments to submit for microscopic examination. Generally, multiple sections of tumor (often one per centimeter) are submitted to confirm the diagnosis or assess for treatment effect. Other sections are typically submitted to evaluate the relation of the tumor with various surgical margins. Following submission, the tissue is processed for microscopic examination similar to a needle core biopsy.

## Facts to Remember

1. Soft tissue tumors are described according to the connective tissue they most resemble and are further categorized as benign, malignant, or intermediate in clinical behavior.
2. The needle core biopsy has become the primary specimen for diagnosis of soft tissue neoplasms. Appropriate and timely handling of the tissue is critical for successful classification.
3. Documentation of key clinical features on the requisition form, such as the anatomic site and size of the mass, previous malignancies, familial syndromes, and previous therapy can be immensely helpful for accurate and efficient diagnosis.
4. Communication of specimen orientation or areas that are suspicious for tumor involvement can facilitate clear pathologic reporting.

---

## References

1. Goldblum J, Weiss S, Folpe AL, editors. *Enzinger and Weiss's soft tissue tumors*. 6th ed. Philadelphia: Elsevier; 2013.
2. Fletcher CD. The evolving classification of soft tissue tumours – an update based on the new 2013 WHO classification. *Histopathology*. 2014;64(1):2–11.
3. Fletcher CDM, Bridge JA, Hogendoorn PC, Mertens F, editors. *Pathology and genetics of tumours of soft tissue and bone*. 4th ed. Lyon: World Health Organization; 2013.
4. Lester S. *Manual of surgical pathology*. 3rd ed. Philadelphia: Elsevier Saunders; 2010.
5. Hoerber I, Spillane AJ, Fisher C, Thomas JM. Accuracy of biopsy techniques for limb and limb girdle soft tissue tumors. *Ann Surg Oncol*. 2001;8(1):80–7.
6. Fisher C, Montgomery EA, Thway K. *Biopsy interpretation series: biopsy interpretation of soft tissue tumors*. 2nd ed. Philadelphia: Wolters Kluwer; 2016.
7. Deyrup AT, Weiss SW. Grading of soft tissue sarcomas: the challenge of providing precise information in an imprecise world. *Histopathology*. 2006;48(1):42–50.

---

## 2.1 Pathologist Approach to Diagnosis

Soft tissue biopsies are often challenging specimens to diagnose. There is an almost overwhelming amount of entities to consider, many of which are very rare. Moreover, numerous ancillary studies, such as immunohistochemical or molecular tests, are often necessary for appropriate investigation [1].

Visualization of a tumor on an hematoxylin and eosin (H&E) slide remains central to the diagnosis of soft tissue neoplasms. This H&E staining technique, which is over 100 years old, allows the pathologist to examine tumor cells by highlighting nuclei in blue (by hematoxylin) and cytoplasm in red (by eosin).

When viewing an H&E slide, a pathologist assesses the overall architecture at a low power magnification and then analyzes the cytological features of the tumor cells at higher power. Groups of soft tissue tumors manifest characteristic patterns that can be utilized by pathologists in considering diagnostic possibilities. Familiarity with these patterns and associated terminology can lend insight into the diagnostic process [2]. Frequent histologic patterns include spindle cell, epithelioid, round cell, pleomorphic, myxoid, cartilaginous, osseous, and vascular.

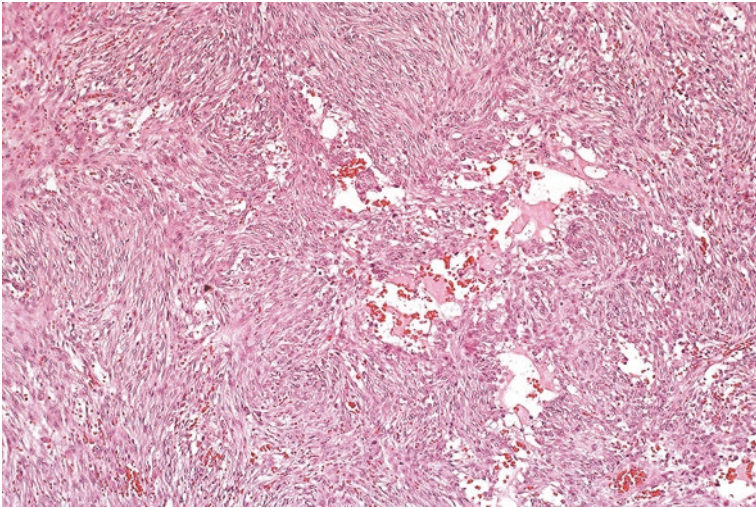
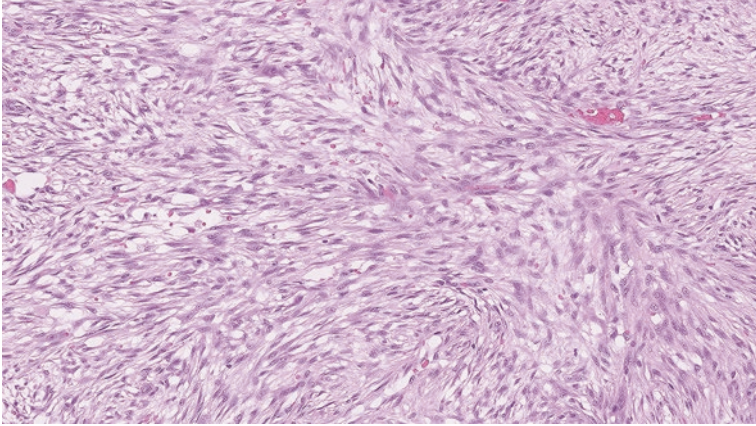
### Spindle Cell Tumors

One of the most frequent morphologies encountered in soft tissue tumors is a spindled cell pattern, in which the tumor cells exhibit slender and elongated nuclei and cytoplasmic borders. These spindle cells can be arranged in haphazard manner (Figs. 2.1 and 2.2) as seen in nodular fasciitis or placed in organized bundles (often termed a “fascicular” or “herringbone pattern”) as seen in malignant peripheral nerve sheath tumor (Fig. 2.3). Finally, the spindle cells can be arranged in a whirling or storiform architecture, as seen in dermatofibrosarcoma protuberans (Fig. 2.4).

### Epithelioid Tumors

Although mesenchymal in nature, soft tissue tumor cells can have an epithelioid appearance. Morphologically, these cells have cytoplasmic and nuclear borders that



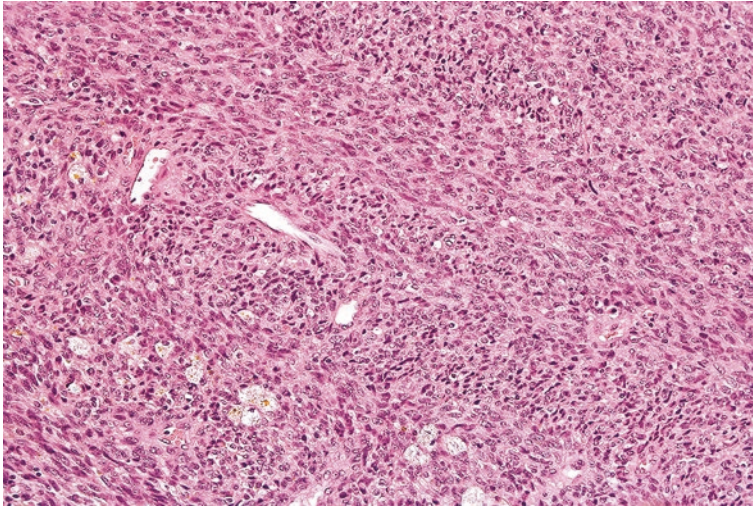


**Figs. 2.1 and 2.2** Nodular fasciitis with haphazard arrangement of spindle cells

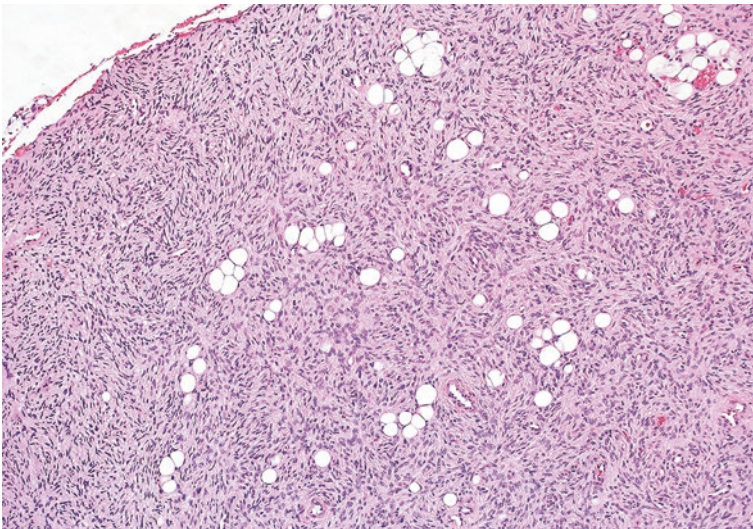
are round or oval (Fig. 2.5). Examples of epithelioid type soft tissue neoplasms include epithelioid sarcoma, epithelioid hemangioendothelioma, and epithelioid gastrointestinal stromal tumor. Epithelioid-type sarcomas can be mistaken for poorly differentiated carcinomas, particularly if the pathologist is unaware of the anatomic location or clinical history of the lesion.

### **Round Cell Tumors**

Round cell tumors encompass a broad range of soft tissue neoplasms that are made up of cells that have a high nuclear to cytoplasmic ratio, similar to the appearance of a lymphocyte. As hematoxylin will stain the nucleus of a cell violet or blue, round cell neoplasms generally appear blue at low magnification. Examples of round cell

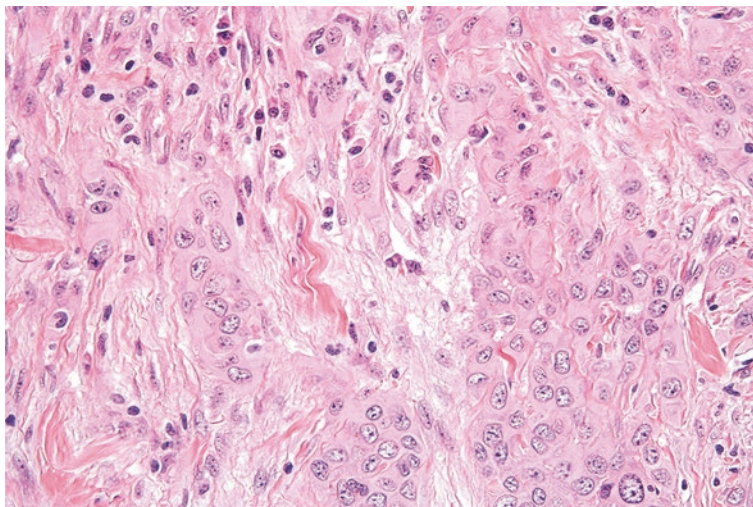


**Fig. 2.3** Malignant peripheral nerve sheath tumor with spindle cells that are organized in bundles, often called a fascicular pattern

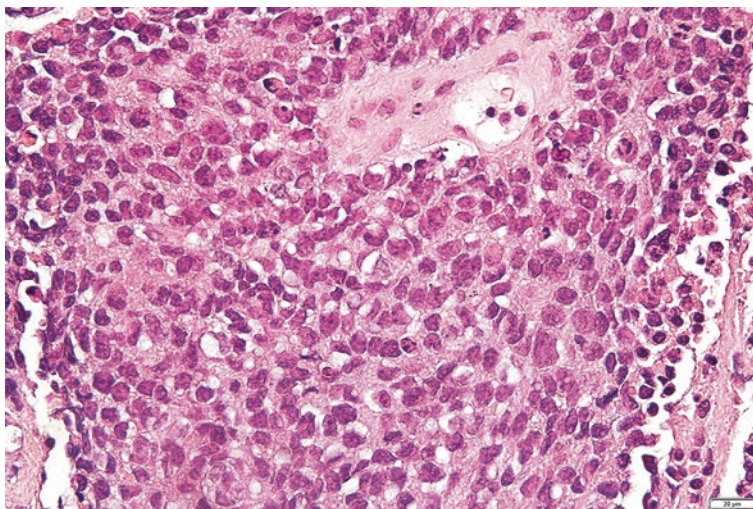


**Fig. 2.4** Dermatofibrosarcoma protuberans with spindle cells arranged in a vague whirling or storiform pattern

soft tissue neoplasms include embryonal rhabdomyosarcoma or Ewing sarcoma (Fig. 2.6). Although these neoplasms have substantially overlapping morphologic appearances, many exhibit unique genetic features that facilitate diagnosis. Round cell tumors can also be confused for neuroendocrine carcinomas or lymphomas.



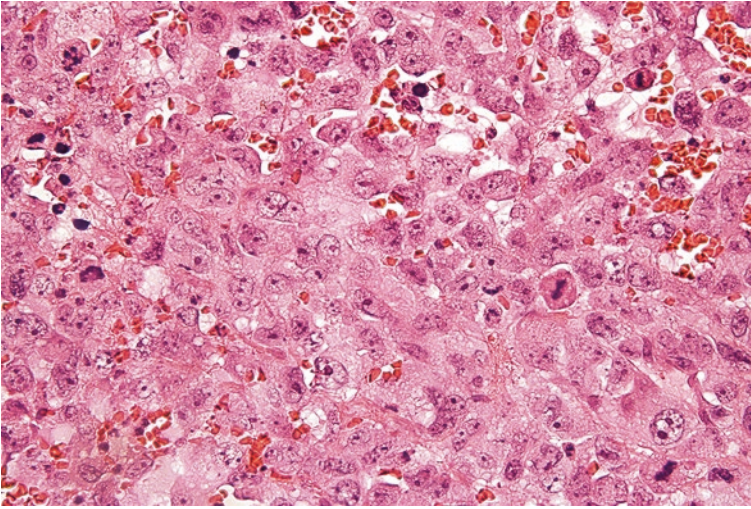
**Fig. 2.5** This epithelioid sarcoma contains epithelioid-appearing tumor cells with round to ovoid nuclei



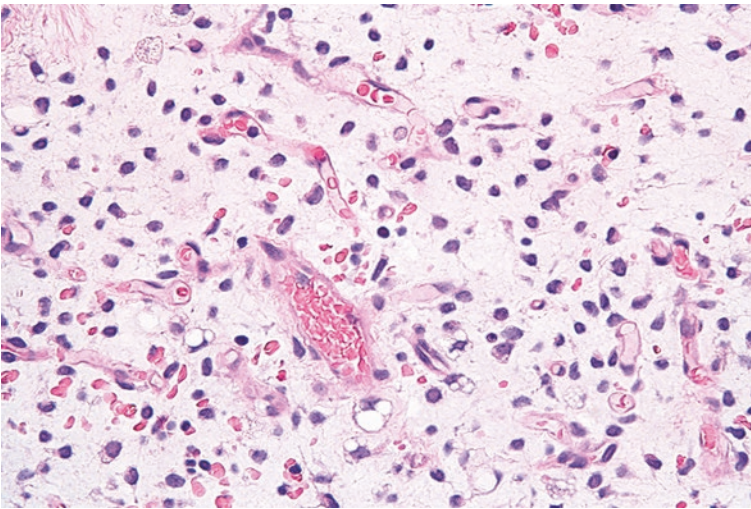
**Fig. 2.6** Ewing sarcoma containing round tumor cells with a high nuclear to cytoplasmic ratio

### **Pleomorphic Tumors**

Many high-grade sarcomas can exhibit pleomorphic or bizarre-appearing cells. The tumor cells of this pattern demonstrate substantial variation in the size and shape of the nuclei (Fig. 2.7). Highly atypical mitoses can often be identified. One of the most frequently occurring pleomorphic soft tissue neoplasms is an undifferentiated high-grade pleomorphic sarcoma, previously designated as “high-grade malignant fibrous histiocytoma (MFH).” Pleomorphic sarcomas must be distinguished from pleomorphic carcinoma, hematolymphoid neoplasms, or melanomas that can have a similar appearance.



**Fig. 2.7** Undifferentiated pleomorphic sarcoma with tumor cells that contain large and irregular nuclei with increased mitoses



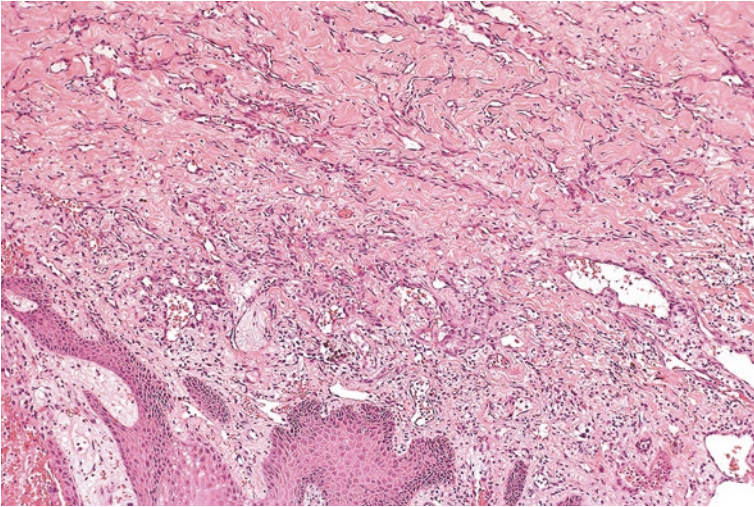
**Fig. 2.8** Myxoid liposarcoma with substantial amount of background myxoid material and delicate capillaries

### Myxoid Tumors

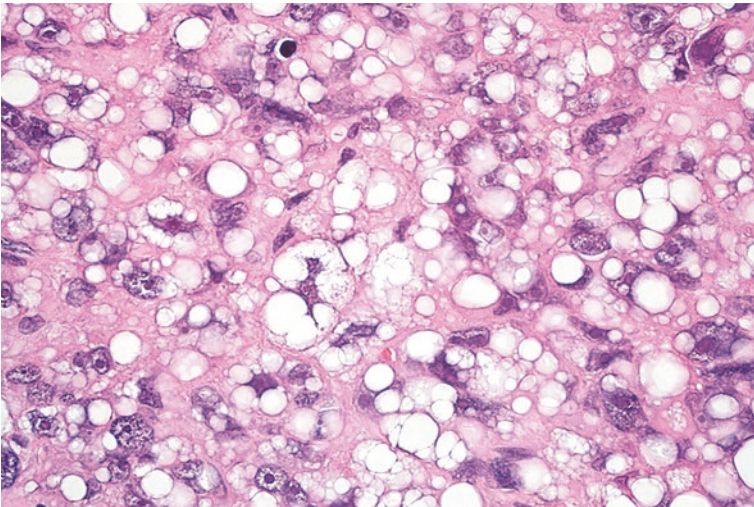
Myxoid soft tissue tumors exhibit varying amounts of a background bluish mucoid-like substance (Fig. 2.8). The neoplasms in this pattern can be difficult to differentiate based on architecture, as the tumor cells often freely float in this myxoid material. Examples of these tumors include myxoid liposarcoma, myxofibrosarcoma, and aggressive angiomyxoma.

### **Cartilaginous, Osseous, Adipocytic, and Vascular Tumors**

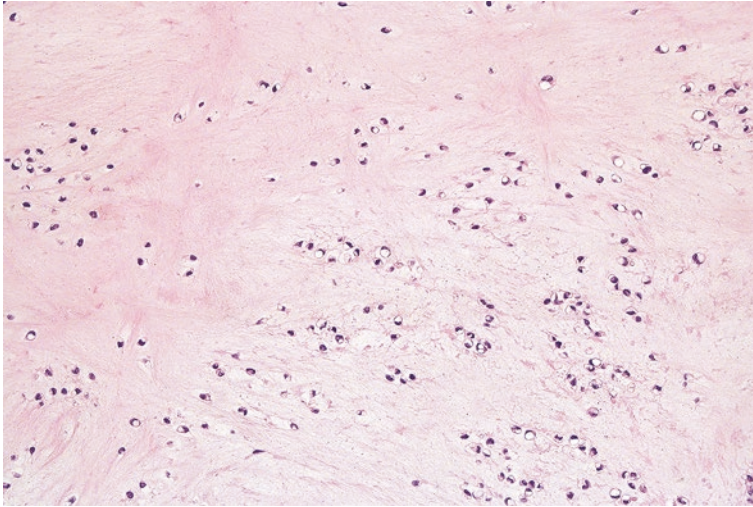
The endothelial nature of vascular tumors is frequently apparent by the formation of infiltrative vascular channels (Fig. 2.9). Adipocytic tumors can often be identified by obvious fat cells or lipoblasts that contain large clear vacuoles in the cytoplasm (Fig. 2.10). Cartilaginous tumors will exhibit deposition of a blue or pink background chondroid-like matrix (Fig. 2.11). Osseous tumors show at least focal dense and eosinophilic extracellular osteoid material (Fig. 2.12).



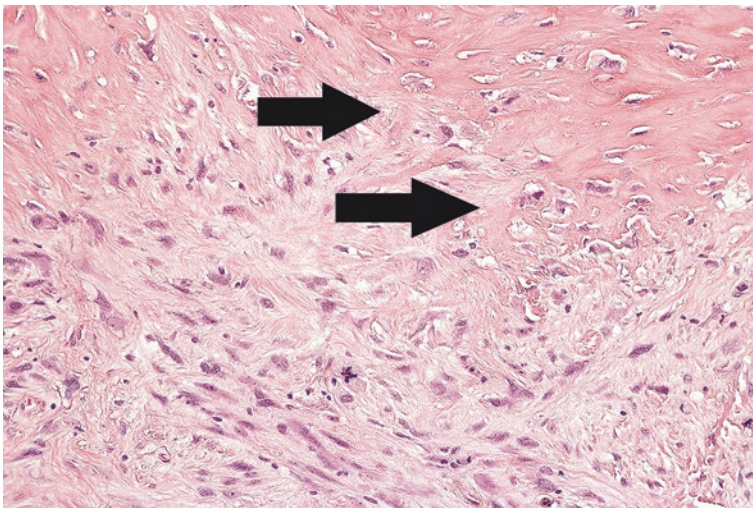
**Fig. 2.9** Well-differentiated angiosarcoma with vascular channels that dissect through tissue



**Fig. 2.10** Lipoblasts seen in a pleomorphic liposarcoma

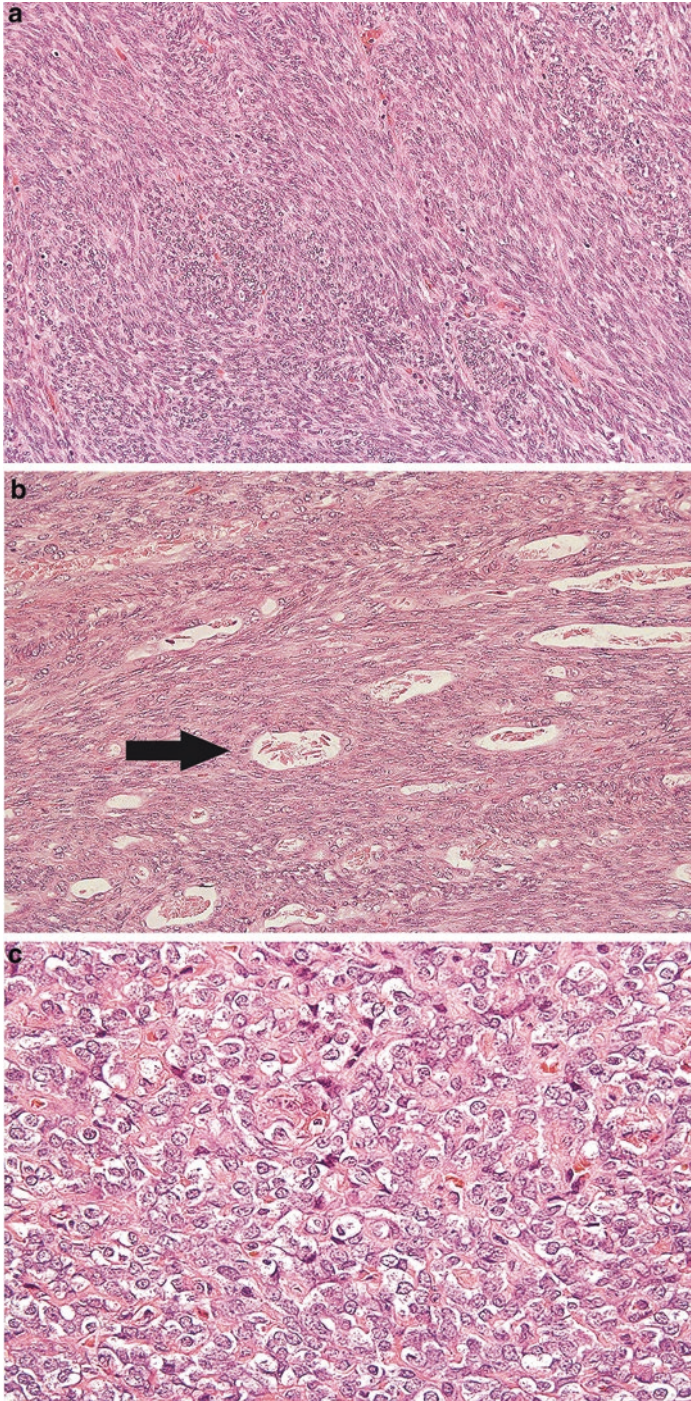


**Fig. 2.11** Variably blue and pink background chondroid matrix in a soft tissue chondroma



**Fig. 2.12** Extraskelatal osteosarcoma with deposition of pink osteoid material (*arrows*)

It is important to understand that these patterns serve as a starting point in investigating the ultimate differentiation and diagnosis of a particular soft tissue tumor. At the microscope, an individual tumor may manifest multiple patterns, such as a synovial sarcoma, which can contain spindle cells, epithelioid cells, and round cells in the same tumor (Fig. 2.13a–c). After assessing for these patterns and features, the pathologist can then progress to a more detailed examination and incorporate various ancillary tests to evaluate specific diagnostic considerations.



**Fig. 2.13** (a) Synovial sarcoma showing a spindle cell pattern, (b) Epithelioid-like cells in a synovial sarcoma forming glandular appearing spaces (*arrow*), (c) round cells in a poorly differentiated synovial sarcoma

## 2.2 Diagnostic Ancillary Studies

While many tumors can be diagnosed from their appearance on an H&E slide, numerous soft tissue neoplasms have overlapping microscopic features that can complicate interpretation. Fortunately, there is now a large arsenal of ancillary studies available to facilitate classification. Familiarity with these different techniques can be helpful in understanding the particular approach to a diagnosis or potential issues when submitting a specimen to the pathology lab. Frequently used ancillary studies include immunohistochemistry, chromosomal karyotyping, fluorescence in situ hybridization (FISH), and reverse transcription PCR.

### 2.2.1 Immunohistochemistry

Immunohistochemical staining and interpretation have profoundly impacted the diagnosis of soft tissue neoplasms. The core concept of immunohistochemistry is to take an antibody that is specific for a particular cell protein and attach a chromogenic enzyme such as peroxidase [3]. If the enzyme-attached antibody binds to a cell of interest, a coloring reaction allows direct visualization under the microscope (Fig. 2.14a, b).

Immunohistochemical staining has its pitfalls. Insufficient or delayed fixation can result in a false positive or negative staining pattern. Failure to interpret the appropriate cells or misinterpret a nonspecific staining pattern can result in an erroneous diagnosis. Most immunohistochemical stains will highlight multiple types of tumor cells. For example, an S100 immunohistochemical stain will highlight neoplastic cells from both a benign nerve sheath tumor or a malignant melanoma. Consequently, appropriate use and interpretation of this test in the context of the morphologic findings is critical.

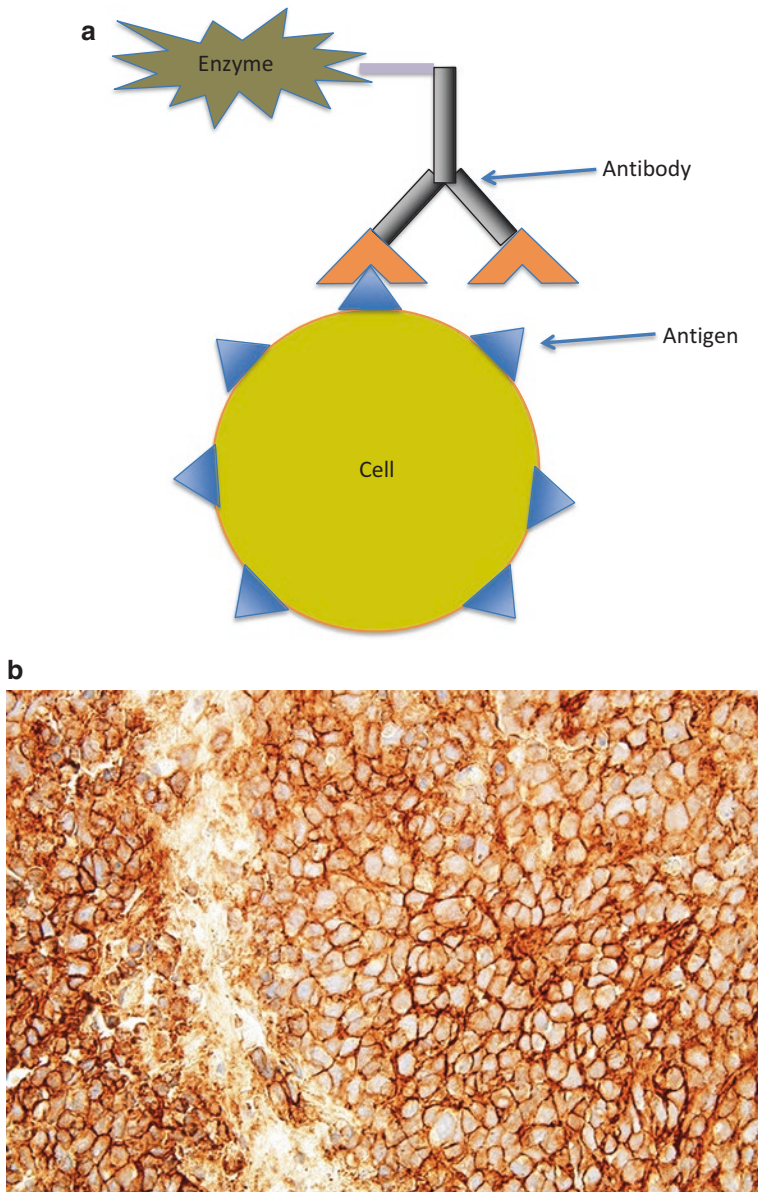
### 2.2.2 Karyotyping

Numerous soft tissue tumors have been found to manifest recurring chromosomal and genetic aberrations (Table 2.1).

Over the past few decades, pathologists have been able to identify genetic mutations by submitting fresh tumor tissue for cell culture and subsequent chromosomal analysis. With this technique, a representative fragment (about a cubic centimeter) of viable tumor is submitted to a cytogenetic laboratory in the appropriate culture medium as soon as possible. Genetic mutations can be deduced from the chromosomal aberrations identified [4].

Unlike many genetic tests, chromosomal karyotyping allows for a broad analysis of suspected or unsuspected cytogenetic abnormalities. This can be helpful when the histologic impression offers no clues to tumor differentiation or numerous diagnostic possibilities are being simultaneously considered. However, as this process requires culturing tissue, a fresh, representative, and viable specimen is required.





**Fig. 2.14** (a) Illustration of the underlying principle of immunohistochemistry. An enzyme attached to an antibody signals the presence of a specific nuclear, cytoplasmic, or membranous antigen associated with a cell. (b) Positive immunohistochemical staining of tumor cells

**Table 2.1** Common diagnostic genetic translocations in soft tissue tumors

<b>Tumor type</b>	<b>Chromosomal abnormality</b>	<b>Genetic aberration</b>
Well-differentiated liposarcoma	12q14-15 amplification	<i>MDM2, CDK4</i> amplification
Dedifferentiated liposarcoma	12q14-15 amplification	<i>MDM2, CDK4</i> amplification
Myxoid liposarcoma	t(12;16) or t(12;22)	<i>FUS-DDIT3</i> or <i>EWSR1-DDIT3</i>
Fibroblastic/myofibroblastic tumors		
Nodular fasciitis	t(17;22)	<i>USP6-MYH9</i>
Solitary fibrous tumor	12q13	<i>NAB2-STAT6</i>
Inflammatory myofibroblastic tumor	Alterations of chromosome 2	Multiple translocations involving <i>ALK</i>
Dermatofibrosarcoma protuberans	t(17;22)	<i>COL1A1-PDGFB</i>
Infantile fibrosarcoma	t(12;15)	<i>ETV6-NTRK3</i>
Low-grade fibromyxoid sarcoma	t(7;16), t(11;16)	<i>FUS-CREB3L2</i> or <i>FUS-CREB3L1</i>
Myxoinflammatory fibroblastic sarcoma	t(1;10)	<i>TGFB3-MGEA5</i>
Skeletal muscle tumors		
Alveolar rhabdomyosarcoma	t(X;17)	<i>ASPSCR1-TFE3</i>
Spindle cell rhabdomyosarcoma	t(6;8)	<i>SRF-NCOA2</i>
Vascular tumors		
Epithelioid hemangioendothelioma	t(1;3) or t(X;11)	<i>WWTR1-CAMTA1</i> or <i>YAP1-TFE3</i>
Chondroid and osseous tumors		
Extraskeletal mesenchymal chondrosarcoma	t(8;8)	<i>HEY1-NCOA2</i>
Soft tissue tumors of uncertain differentiation		
Myoepithelioma of soft tissue	Chromosome 22 translocations	Multiple translocations involving <i>EWSR1</i>
Ossifying fibromyxoid tumor	t(6;12)	<i>EP400-PHF1</i>
Alveolar soft part sarcoma	t(X;17)	<i>ASPSCR1-TFE3</i>
Clear cell sarcoma	t(12;22)	<i>EWSR1-ATF1</i>
Ewing sarcoma	t(11;22), t(21;22)	<i>EWSR1-FLI1</i> , <i>EWSR1-ERG</i>
Desmoplastic round cell tumor	t(11;22)	<i>EWSR1-WT1</i>
Epithelioid sarcoma	Del 22q	Inactivation of <i>SMARCB1</i>
Extrarenal rhabdoid tumor	Del 22q	Mutation of <i>SMARCB1</i>
Synovial sarcoma	t(X;18)	<i>SS18-SSX1</i> , <i>SS18-SSX2</i>
Extraskeletal myxoid chondrosarcoma	Chromosome 9 translocations	Multiple translocations involving <i>NR4A3</i>

In hospitals or clinics where a biopsy or resection specimen is usually placed in formalin prior to transit, this requires planning prior to the procedure. Critical considerations include timely delivery and use of appropriate transport media. Additionally, the pathologist needs to ensure procurement of sufficient material for routine processing and morphologic assessment.

### **2.2.3 Molecular Fluorescence In Situ Hybridization**

In a method known as fluorescence in situ hybridization (FISH), instead of reviewing an entire set of chromosomes, pathologists can assess for specific genes by using complementary DNA probes. These probe sequences are tagged with dye and bind to genes of interest.

Fluorescence in situ hybridization has many advantages. It can be performed on tumors that have been previously fixed in formalin. Also, the morphology of the tumor cells is retained, allowing the pathologist to be confident that a positive or negative genomic finding is occurring in the actual cells of interest.

This technique also has limitations as it assesses for a single genetic aberration, as opposed to chromosomal karyotyping which assesses for all cytogenetic abnormalities. Therefore, successful use is predicated on appropriate suspicion for a particular diagnosis.

### **2.2.4 Reverse transcription PCR**

Reverse transcription polymerase chain reaction (RT-PCR) is another way a pathologist can confirm or exclude the presence of a genetic aberration in a soft tissue tumor.

Reverse transcription PCR has its advantages and disadvantages. It can be performed on paraffin-embedded blocks and is highly sensitive. However, with this sensitivity comes an increased risk for contamination and false positive results. Moreover, unlike FISH and immunohistochemical stains, the underlying cellular morphology is lost during analysis. Consequently, a pathologist has to be careful to submit tissue that is representative of viable tumor, as there is potential for a false negative result from sampling error [1].

---


## **2.3 Intraoperative Consultation**

Long ago, physicians recognized the value of immediate feedback from a pathologist during a surgical operation. Long ago, pathologists developed a method that would allow for intraoperative microscopic assessment, often referred to as a frozen section procedure [6].


After a surgeon submits tissue with a specific question, the pathologist or pathology assistant will embed the specimen in a gel-like medium that solidifies in

freezing temperatures. This frozen block is then mounted in a cryostat that cuts a thin slice of tissue (approximately 5  $\mu\text{m}$ ) that can be placed on a glass slide (Figs. 2.15 and 2.16). The slide is subsequently stained with hematoxylin and eosin and interpreted by a pathologist (Fig. 2.17).

The real-time feedback offered by a frozen section interpretation can greatly assist the surgeon in the key decision points of a procedure, but the method has



**Fig. 2.15** Tissue fragment submitted in gel media that is frozen and being cut by the pathologist assistant



**Fig. 2.16** Thin section of frozen tissue is placed on a glass slide



**Fig. 2.17** Frozen section slide is being stained with hematoxylin and eosin

limitations. Some tissue, such as adipose tissue, does not freeze well enough for effective cutting in the cryostat, resulting in limited examination on a slide. Moreover, immunohistochemical stains are generally not available during frozen section diagnosis. The ideal turnaround time from receipt to diagnosis for a routine frozen section case with one piece of tissue is approximately 20 min. However, this time can be substantially prolonged if the procedure involves multiple pieces of tissue or the case is especially complex.

In addition to technical issues, there are also interpretive limitations. The nuclei in a frozen section slide are not well preserved and sometimes manifest artifactual atypia. Therefore, it can sometimes be difficult to distinguish involvement by a low-grade tumor such as deep fibromatosis from previous surgical site changes. Similarly, specimens previously subjected to neoadjuvant radiation can exhibit a reactive atypia in the mesenchymal tissue that can complicate an intraoperative diagnosis. Finally, tumor cells which are not present on the frozen section slide will sometimes become apparent when cutting deeper into the tissue after routine processing. Thus, although intraoperative consultations are typically accurate, discrepancies do occur [7].

In light of these considerations, intraoperative consultations have value, but it is prudent to utilize them when the result will impact the course of the procedure. When performing a needle core biopsy of a soft tissue mass, a frozen section will likely not result in a definitive histologic diagnosis. Frozen section interpretation can detect margin involvement by a high-grade sarcoma; however, determining involvement by some soft tissue neoplasms, such as angiosarcoma, is virtually impossible. A presurgical discussion with the pathologist can be helpful in clarifying expectations of a frozen section diagnosis for specific types of tumors.

---

## Facts to Remember

1. When diagnosing a tumor, pathologists will examine a slide to assess for morphologic patterns.
2. Available ancillary tests for diagnosis include karyotyping, immunohistochemistry, FISH, and RT-PCR.
3. These tests are utilized based on the clinical and histologic features of the tumor.
4. A frozen section diagnosis can be of value in soft tissue pathology. However, these preliminary diagnoses have limitations, and consultations should be requested with prudence.

---

## References

1. Goldblum J, Weiss S, Folpe AL, editors. *Enzinger and Weiss's soft tissue tumors*. 6th ed. Philadelphia: Elsevier; 2013.
2. Hornick JL, editor. *Practical soft tissue pathology: a diagnostic approach*. 1st ed. Philadelphia: Saunders; 2013.
3. Dabbs D, editor. *Diagnostic immunohistochemistry: theranostic and genomic applications*. 4th ed. Philadelphia: Elsevier Saunders; 2014.
4. Hornick JL, editor. *Practical soft tissue pathology: a diagnostic approach*. Philadelphia: Saunders; 2013.
5. Chmielecki J, Crago AM, Rosenberg M, O'Connor R, Walker SR, Ambrogio L, et al. Whole-exome sequencing identifies a recurrent NAB2-STAT6 fusion in solitary fibrous tumors. *Nat Genet*. 2013;45(2):131–2.
6. Gal AA, Cagle PT. The 100-year anniversary of the description of the frozen section procedure. *JAMA*. 2005;294(24):3135–7.
7. Ferreiro JA, Myers JL, Bostwick DG. Accuracy of frozen section diagnosis in surgical pathology: review of a 1-year experience with 24,880 cases at Mayo Clinic Rochester. *Mayo Clin Proc*. 1995;70(12):1137–41.

---

## 3.1 Assigning a Pathologic Grade to Soft Tissue Tumors

As with most other malignancies, soft tissue sarcomas are assigned a histological grade. The French Federation of Cancer Centers Sarcoma Group (FNCLCC) is the most commonly used methodology and is preferred by the American Joint Committee on Cancer (AJCC) [1]. This system assesses tumor differentiation, mitosis, and necrosis and assigns a score for each characteristic (Table 3.1) [2, 3].

The differentiation score generally reflects how closely the tumor resembles benign mesenchymal tissue. For example, a well-differentiated liposarcoma (which closely mimics adipose tissue) would receive a low score (of 1), and a dedifferentiated liposarcoma (which has lost its lipogenic differentiation) would receive a high score (of 3).

A mitotic score is assigned according to the number of mitosis identified after viewing ten standard high-power fields through the microscope. One point is assigned for 0–9 mitosis, two points are assigned for 10–19 mitosis, and three points are assigned for 20 or more mitosis over ten high-power fields.

A necrosis score is rendered according to the amount of tumor necrosis present. Two points are assigned for more than 50% necrosis. One point is assigned for less than 50% necrosis, and no points are assigned if there is no necrosis.

These scores are then summated, and a numeric grade (1–3) is assigned accordingly (Table 3.2). This approach successfully categorizes a diverse group of malignant soft tissue sarcomas in a manner that independently predicts metastasis, but it is not used for all sarcomas. Some tumors that are classified as “malignant,” such as epithelioid sarcoma, clear cell sarcoma, and alveolar soft part sarcoma, carry less risk for early (less than 5 years) metastasis and greater risk for late metastasis (greater than 5 years). Consequently, these tumors are not given an FNCLCC grade. Other tumors, like alveolar or embryonal rhabdomyosarcoma, have their own risk stratification system (such as the Intergroup Rhabdomyosarcoma Study Postsurgical Clinical Grouping System) and are not assigned a FNCLCC grade [4].

**Table 3.1** Scoring parameters for the FNCLCC grading system [5, 6]

<b>Histologic type</b>	<b>Score</b>
Well-differentiated liposarcoma	1
Myxoid liposarcoma	2
Round cell liposarcoma	3
Pleomorphic liposarcoma	3
Dedifferentiated liposarcoma	3
Fibrosarcoma	2
Myxofibrosarcoma MFH	2
Pleomorphic sarcoma NOS, with giant cell or inflammatory cells	3
Well-differentiated leiomyosarcoma	1
Conventional leiomyosarcoma	2
Poorly differentiated, pleomorphic or epithelioid leiomyosarcoma	3
Biphasic or monophasic synovial sarcoma	3
Poorly differentiated synovial sarcoma	3
Pleomorphic rhabdomyosarcoma	3
Mesenchymal chondrosarcoma	3
Extraskeletal osteosarcoma	3
Ewing sarcoma	3
Malignant rhabdoid tumor	3
Undifferentiated (spindle cell and pleomorphic) sarcoma	3
<b>Tumor mitosis</b>	<b>Score</b>
0–9 mitoses per 10 high-power fields	1
10–19 mitoses per 10 high-power fields	2
Greater than 19 mitoses per 10 high-power fields	3
<b>Tumor necrosis</b>	<b>Score</b>
No tumor necrosis	0
Less than 50% tumor necrosis	1
50% or more tumor necrosis	2

Points are assigned for tumor differentiation, mitosis, and necrosis

**Table 3.2** Grade assignment for the FNCLCC grading system. After points are assigned for tumor differentiation, mitosis, and necrosis, a grade (1–3) is assigned according to the total score calculated

FNCLCC grading of soft tissue tumors	
Grade 1	2–3 points
Grade 2	4–5 points
Grade 3	6–8 points

Grading can be challenging on needle core biopsies, primarily due to issues with sampling. Biopsies that fail to capture increased mitosis or tumor necrosis can result in assignment of an inaccurate lower grade [2]. Thus, it is important to consider a reported grade in light of the radiologic findings when determining whether or not the biopsy is representative.



Often, intermediate or high-grade soft tissue tumors receive neoadjuvant radiation or chemotherapy. Following presurgical therapy, it is impossible to distinguish between original tumor necrosis and treatment-related necrosis on the resection specimen. Also, this neoadjuvant therapy will artificially lower the mitotic rate, and resected soft tissue neoplasms treated with neoadjuvant therapy are not eligible for grading. The grade listed for a previously treated resected tumor is assigned based on the original biopsy.

---

## 3.2 Assigning a Pathologic Stage to Soft Tissue Tumors

Similar to carcinomas, resected sarcomas are assigned a pathologic stage according to the American Joint Committee on Cancer (AJCC) staging system (Table 3.3). This follows a TNM format that reports a value for the primary tumor (T stage), involvement of lymph nodes (N stage), and presence of metastasis (M stage). In soft tissue pathology, size has been the primary determinant for calculating the T stage. Recently, the eighth edition of the AJCC Cancer Staging Manual has been published and will be clinically implemented on January 1, 2018. To better account for location in predicting local recurrence or metastatic disease, there are now particular staging definitions for sarcomas in specific anatomic sites. Categories include the head and neck, trunk/extremities, abdominal/thoracic viscera and retroperitoneum. In the abdominal/thoracic viscera, T stage of a tumor is primarily defined by the amount of extension from the primary organ. In the other sites, size remains the principle determinant of T categorization [1, 5].

In the 8th edition of the AJCC Cancer Staging Manual, the N stage is categorized as “N0” when the regional lymph nodes are negative for tumor or if the lymph node status is unknown. Tumors that have an involved lymph node are classified as “N1.” If distant metastasis is pathologically documented, a designation of “M1” is given. If not, the tumor is designated as “M0”.

When the pathology stage is listed on the report, it frequently begins with the prefix of “p” and continues with a value for the T, N, and M components.

In tumors that have received neoadjuvant therapy, the pathologic stage is first preceded by a “y” prefix.[1].

---

## 3.3 Interpreting a Soft Tissue Pathology Report

Pathology diagnoses include an increasing amount of data elements from the gross examination, microscopic interpretation, and supporting immunohistochemical and molecular studies of a case. Developing an understanding of these elements and the general structure of a pathology report can help facilitate communication within the treatment group. While the exact format and approach to reporting varies between institutions, there are common principles that can be discussed.

**Table 3.3a** AJCC categorization (8th edition) for T staging of soft tissue tumors

<b>Primary tumor (T) for soft tissue sarcomas of the head and neck</b>	
TX	Primary tumor cannot be assessed
T1	Tumor $\leq 2$ cm
T2	Tumor $> 2$ to $\leq 4$ cm
T3	Tumor $> 4$ cm
T4	Tumor with invasion of adjoining structures
T4a	Tumor with orbital invasion, skull base/dural invasion, invasion of central compartment viscera, involvement of facial skeleton, or invasion of pterygoid muscles
T4b	Tumor with brain parenchymal invasion, carotid artery encasement, prevertebral muscle invasion, or central nervous system via perineural spread
<b>Primary tumor (T) for soft tissue sarcomas of the trunk and extremities</b>	
TX	Primary tumor cannot be assessed
T0	No evidence of primary tumor
T1	Tumor 5 cm or less in greatest dimension
T2	Tumor more than 5 cm and less than or equal to 10 cm in greatest dimension
T3	Tumor more than 10 cm and less than or equal to 15 cm in greatest dimension
T4	Tumor more than 15 cm in greatest dimension
<b>Primary tumor (T) for soft tissue sarcomas of the abdomen and thoracic visceral organs</b>	
TX	Primary tumor cannot be assessed
T1	Organ confined
T2	Tumor extension into tissue beyond organ
T2a	Invades serosa or visceral peritoneum
T2b	Extension beyond serosa (mesentery)
T3	Invades another organ
T4	Multifocal involvement
T4a	Multifocal (2 sites)
T4b	Multifocal (3–5 sites)
T4c	Multifocal ( $> 5$ sites)
<b>Primary tumor (T) for soft tissue sarcomas of the retroperitoneum</b>	
TX	Primary tumor cannot be assessed
T0	No evidence of primary tumor
T1	Tumor 5 cm or less in greatest dimension
T2	Tumor more than 5 cm and less than or equal to 10 cm in greatest dimension
T3	Tumor more than 10 cm and less than or equal to 15 cm in greatest dimension
T4	Tumor more than 15 cm in greatest dimension

The criterion for assignment depends on the anatomic location in which the tumor arises

**Table 3.3b** AJCC categorization (8th edition) for N and M staging of soft tissue tumors

<b>Regional lymph nodes (N)</b>	
N0	No regional lymph node metastasis or unknown lymph node status
N1	Regional lymph node metastasis
<b>Distant metastasis (M)</b>	
M0	No distant metastasis
M1	Distant metastasis

**Patient and Specimen Identifiers**

Pathology reports will generally contain at least two patient identifiers at the heading of each page of a report. These can include the patient's name, medical record number, and date of birth. Given the substantial impact a pathology report will have on patient care, laboratory personnel vigilantly confirm and reconfirm that these identifiers match those on the received requisition form and containers. Nevertheless, developing a habit of checking these patient identifiers when reviewing a report can help the clinician prevent a rare but potentially egregious patient identification error.

**Gross Examination**

The gross examination includes the findings seen by a pathologist or pathology assistant when receiving a surgical specimen in the lab. For simplification, each container received is generally labeled as a specific part (e.g., part A, part B, part C, etc.). When reviewing the gross examination for a needle core biopsy, a clinician can confirm that the amount and length of the biopsies received correspond to what was submitted. However, it should be understood that needle core biopsies shrink from formalin fixation and occasionally fragment in transport. For resection specimens, a physician can confirm that directions regarding the orientation of the specimen were correctly interpreted. Additionally, the size of the tumor can be compared to the radiologic examination, and the reported gross distance of the tumor from the surgical margins can be correlated with the intraoperative impression.

**Microscopic Examination**

The microscopic examination includes a description of histologic features, immunohistochemical stains, or molecular tests ordered to arrive at the diagnosis.

**Final Diagnosis**

The final diagnosis includes the most critical elements of the report such as the histologic classification and margin status.

**Diagnostic Comment**

The diagnostic comment expresses important information that does not conform to other listed categories. This can include opinions from outside experts who were consulted on the case. Insights into anticipated clinical behavior or suggestions for follow-up treatment can also be included in this section.

**Synoptic Report**

The synoptic report summarizes the information from all other parts of the document into a standardized format that is easily readable and searchable. The elements included in the report are suggested by professional organizations such as the College of American Pathology and include items such as type of procedure, tumor site, tumor size, histologic type, mitosis, necrosis, grade, margins, and pathologic stage [1, 6].

Familiarity with the elements and structure of a pathology report can help streamline communication between the treating physician and pathologists. If questions arise about the wording or findings, a direct telephone call can be enormously helpful in providing greater clarity.

### **Facts to Remember**

1. Malignant sarcomas are usually assigned a FNCLCC grade based on mitosis, necrosis, and how closely they resemble benign connective tissue.
2. The tumor grade rendered on biopsies can be affected by sampling and should be interpreted in the context of radiologic imaging.
3. Tumors treated with adjuvant therapy are graded based on the original biopsy.
4. Sarcomas are assigned an AJCC stage based on parameters such as size and extent of tumor. The criteria for T categorization depends on the anatomic location of the malignancy.
5. With the increasingly nuanced characterization of soft tissue malignancies, familiarity with a laboratories reporting format is critical for successful coordination of diagnosis and treatment.

---

### **References**

1. Edge S, Greene F, Byrd D, Brookland R, Washington M, Gershenwald J, et al. AJCC cancer staging manual. 8th ed. Philadelphia: Springer; 2017.
2. Oliveira AM, Nascimento AG. Grading in soft tissue tumors: principles and problems. *Skelet Radiol*. 2001;30(10):543–59.
3. Costa J, Wesley RA, Glatstein E, Rosenberg SA. The grading of soft tissue sarcomas. Results of a clinicohistopathologic correlation in a series of 163 cases. *Cancer*. 1984;53(3):530–41.
4. Deyrup AT, Weiss SW. Grading of soft tissue sarcomas: the challenge of providing precise information in an imprecise world. *Histopathology*. 2006;48(1):42–50.
5. Goldblum J, Weiss S, Folpe AL, editors. *Enzinger and Weiss's soft tissue tumors*. 6th ed. Philadelphia: Elsevier; 2013.
6. Rubin BP, Cooper K, Fletcher CD, Folpe AL, Gannon FH, Hunt JL, et al. Protocol for the examination of specimens from patients with tumors of soft tissue. *Arch Pathol Lab Med*. 2010;134(4):e31–9.

---

## 4.1 Lipoma

A lipoma rarely elicits much excitement in the clinic or at the microscope. However, many unusual or malignant soft tissue tumors are initially presumed to be a lipoma, and familiarity with this entity can prove useful when discussing an alternative diagnosis. Lipomas commonly occur as superficial subcutaneous masses in the shoulder, back, neck, abdomen, and extremities, often arising in the fifth to seventh decade of life [1, 2]. Less frequently, they present as larger and more deeply located masses in the muscles of the arm, thigh, or thorax [3].

### Pathology

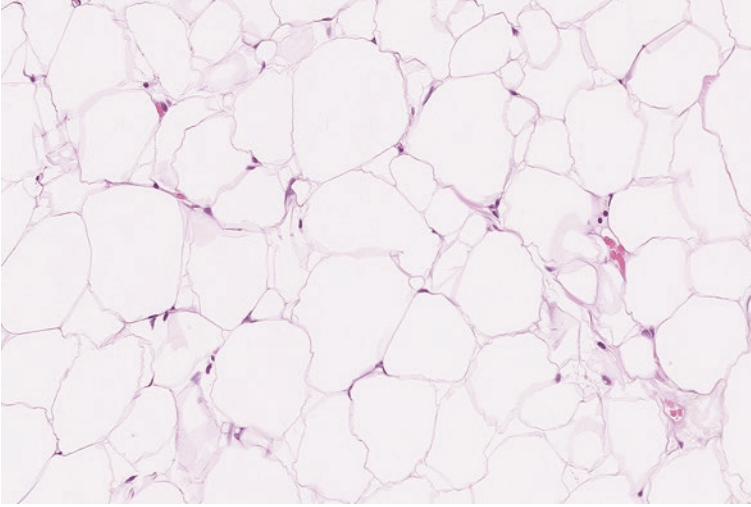
On gross examination, lipomas consist of yellow and translucent adipose tissue. Microscopic examination shows relatively unremarkable adipocytes with inconspicuous eccentrically located nuclei. Sometimes, focal areas of fat necrosis are present, but areas of significant nuclear atypia are generally not identified (Fig. 4.3).

### Ancillary Studies

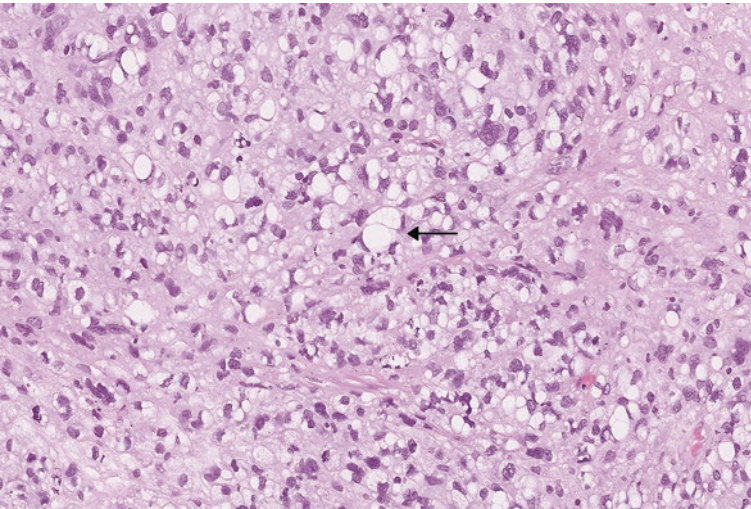
- Lipomas are positive for S100 immunohistochemical stain and often contain mutations involving the *HMBA2* gene. However, these ancillary studies are not typically utilized for diagnosis.

### Differential Diagnosis

- Well-differentiated liposarcoma



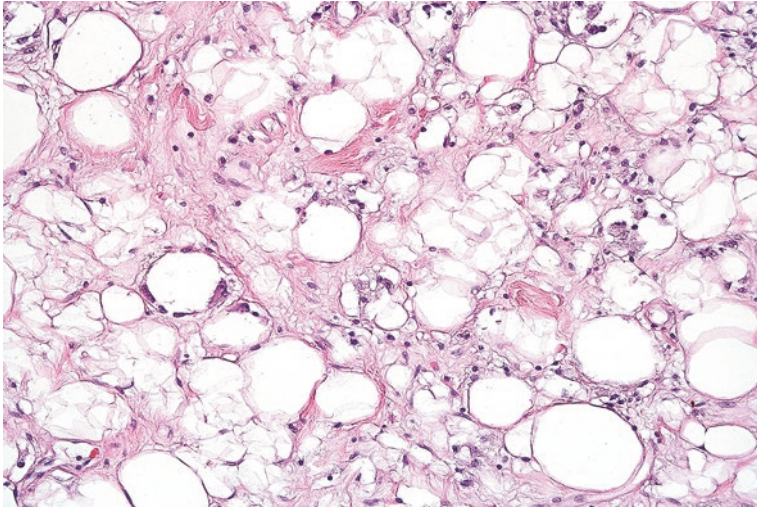
**Fig. 4.1** Numerous adipocytes with abundant clear cytoplasm and eccentric inconspicuous nuclei



**Fig. 4.2** Multiple lipoblasts in a pleomorphic liposarcoma (*arrow*). These cells contain one or more clear vacuoles that indent or displace the nuclei. These particular lipoblasts demonstrate substantial nuclear atypia consistent with their malignant nature

### Comments

1. Because lipomas and well-differentiated liposarcomas can appear remarkably similar under the microscope, knowledge of the clinical presentation of a lipomatous lesion is helpful for a pathologist.
2. Pathologists have increased suspicion for liposarcoma when confronted with adipocytic lesions that are large (greater than 10 cm) and recurrent, or have



**Fig. 4.3** Unremarkable adipocytes in a lipoma with focal areas of fat necrosis

concerning radiologic features. Fatty tumors arising in the abdomen, pelvis, and retroperitoneum are highly suspicious for a well-differentiated liposarcoma [4].

3. Well-differentiated liposarcoma can often be excluded by demonstrating the absence of *MDM2* or *CDK4* gene amplification by fluorescence in situ hybridization.
4. Lipomas are benign, but can rarely recur, particularly if they are deeply located. Lipomas that are intimately associated with muscle (intramuscular lipomas) have an increased risk for recurrence [5].

---

## 4.2 Angiolipoma

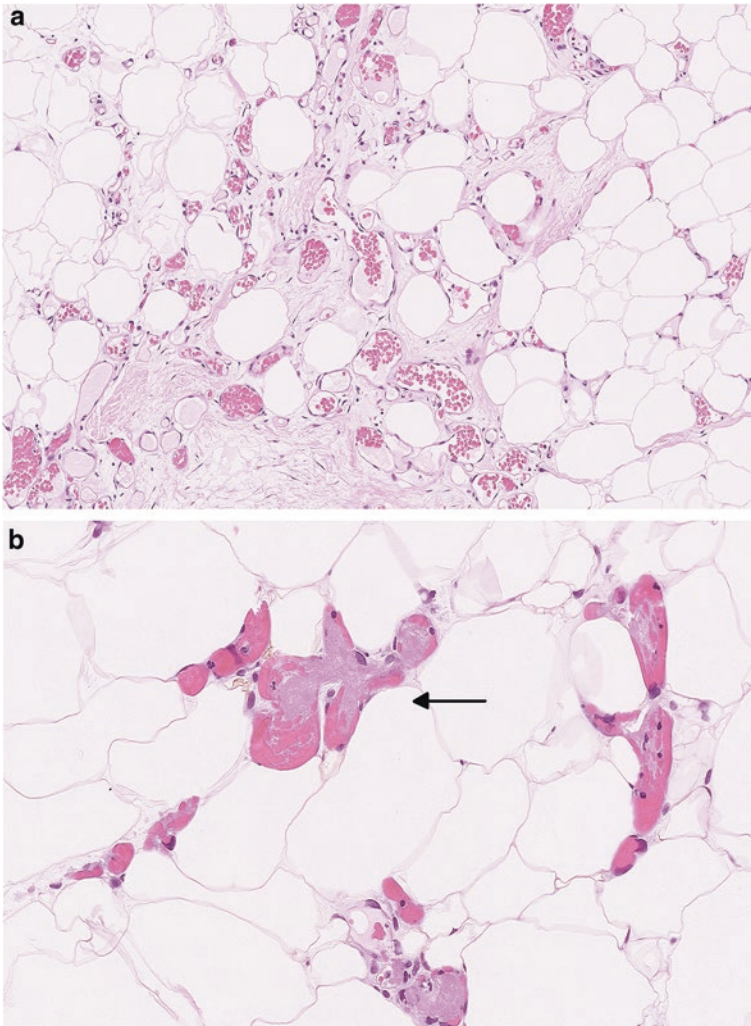
Angiolipomas are fatty tumors that arise as single or multiple subcutaneous nodules on the forearm, upper arm, or trunk. These often arise in young adult males and are painful. Approximately 5% of patients will have a family history of angiolipomas [2, 6].

### Pathology

On gross examination, resected angiolipomas tend to appear as fatty tissue. Microscopic examination demonstrates bland-appearing adipose tissue with prominent blood vessels (Fig. 4.4a). Occasionally, this vascular network can be the predominant component of the lesion. At least a few of the vessels will contain fibrin thrombi (Fig. 4.4b) [7].

### Ancillary Studies

- The vessels in an angiolipoma are highlighted by CD34, CD31, and ERG immunohistochemical stains.



**Fig. 4.4** (a) Angioliipoma with network of dilated vessels in association with benign-appearing adipose tissue. (b) Vessels of angioliipoma with fibrin thrombi (*arrow*)

### Differential Diagnosis

- Lipoma
- Kaposi sarcoma
- Intramuscular hemangioma
- Spindle cell lipoma



---

**Comments**

1. Lipomas contain scattered capillaries, but these are compressed and lack the intravascular thrombi seen in angiolipoma.
2. Highly cellular angiolipomas can be mistaken for a more aggressive neoplasm such as Kaposi sarcoma. The endothelial tumor cells in Kaposi sarcoma are distinguished by positive HHV-8 staining.
3. Sometimes hemangiomas in the muscle can have associated adipose tissue. However, the vessels in intramuscular hemangiomas are much larger than those seen in a subcutaneous angiolipoma [2].
4. A cellular angiolipoma can have areas of vague spindling which can be confused for a spindle cell lipoma. While the cells in spindle cell lipoma will also stain with CD34, they lack more specific endothelial markers like CD31.
5. Angiolipomas are benign lesions that are cured by complete excision and typically do not recur [5].

---

**4.3 Spindle Cell/Pleomorphic Lipoma**

Spindle cell/pleomorphic lipomas are benign lesions that arise in the subcutaneous tissue of the posterior neck, back, and shoulders of middle-aged to older adults. These occasionally can occur in other areas such as the head and extremities [8].

**Pathology**

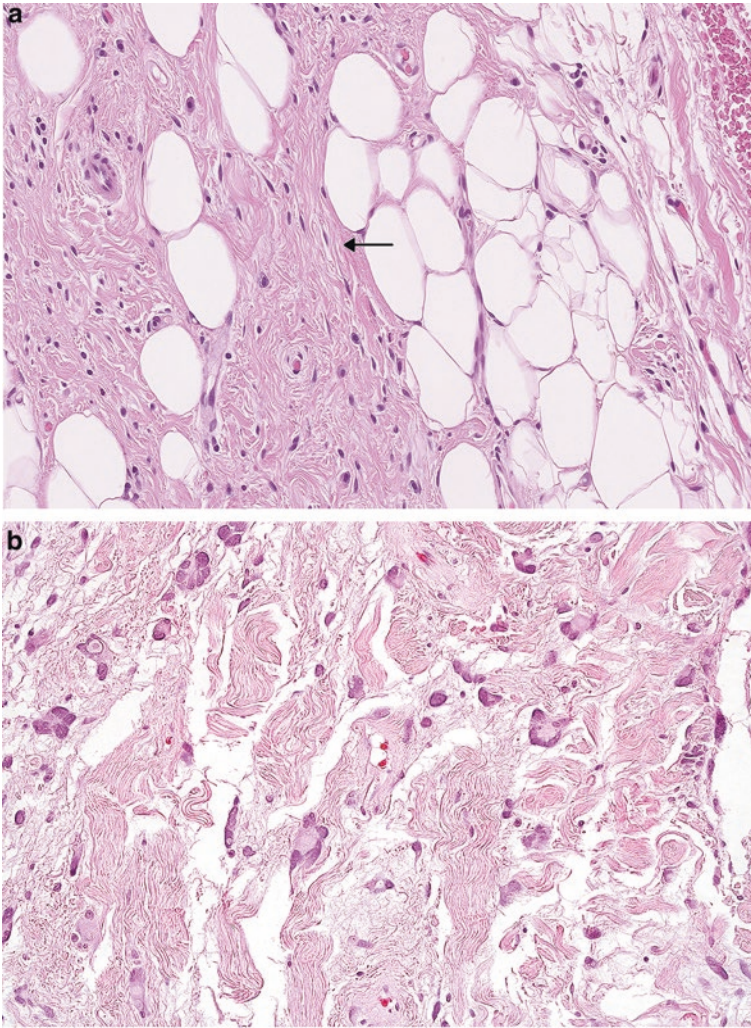
Spindle cell lipomas contain bland adipose tissue that is traversed by a vaguely organized population of benign-appearing spindle cells. These spindle cells are usually associated with thick and dense collagen fibers (Fig. 4.5a). The more pleomorphic forms of this neoplasm will contain cells with multiple peripherally arranged nuclei that are referred to as “floret cells” (Fig. 4.5b) [8, 9].

**Ancillary Studies**

- Although not specific, spindle cell lipomas are positive for a CD34 immunohistochemical stain [10].

**Differential Diagnosis**

- Neurofibroma
- Solitary fibrous tumor
- Well-differentiated liposarcoma



**Fig. 4.5** (a) Spindle cell/pleomorphic lipoma with dense collagen and scattered spindle cells (*arrow*). (b) Occasional multinucleated “floret cell” in a spindle cell/pleomorphic lipoma

### Comments

1. Unlike neurofibroma, most spindle cell lipomas are negative for S100.
2. Solitary fibrous tumor can be distinguished from spindle cell lipomas by positive staining with STAT6.
3. More atypical forms of spindle cell/pleomorphic lipoma can be confused for well-differentiated liposarcoma. Well-differentiated liposarcomas only rarely occur in the subcutaneous tissue and do not typically exhibit ropey collagen fibers.
4. If the microscopic features are particularly concerning, negative FISH studies for *MDM2* gene amplification can help exclude well-differentiated liposarcoma [2].

## 4.4 Hibernoma

Hibernomas are benign adipocytic tumors that are similar to lipomas, except that the cells resemble the adipocytes seen in brown fat. These neoplasms occur over a broad age range, with the average age of occurrence being 38 years-old. Frequent locations include the thigh, shoulder, back, neck, chest, and arm, among others. Clinically, these present as progressively and slowly enlarging masses [11].

### Pathology

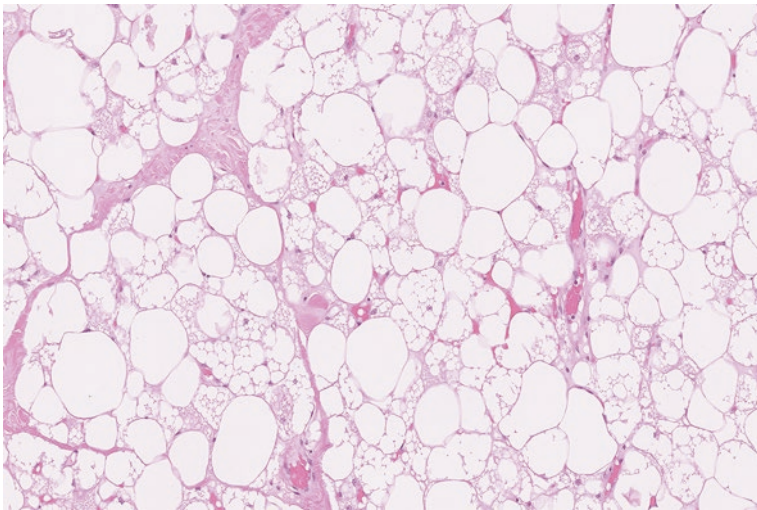
The neoplasm is composed of adipocytes with eosinophilic granular or vacuolated cytoplasm (Fig. 4.6). Varying amounts of usual appearing adipocytes with clear cytoplasm can also be interspersed among these cells [5].

### Ancillary Studies

- Ancillary studies are not typically utilized to diagnose a hibernoma.

### Differential Diagnosis

- Rhabdomyoma
- Granular cell tumor
- Well-differentiated liposarcoma or myxoid liposarcoma with hibernomatous cells



**Fig. 4.6** Hibernoma with numerous adipocytes containing vacuolated and eosinophilic cytoplasm

### Comment

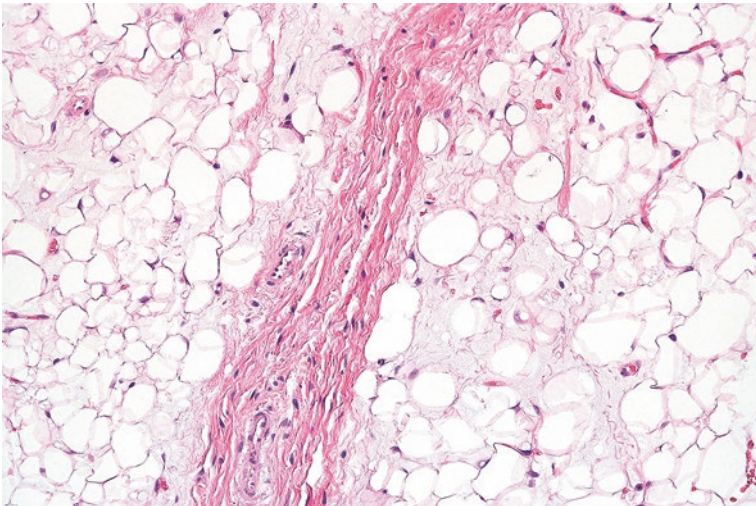
1. Rhabdomyoma can be distinguished from hibernoma by cross striations in the cytoplasm and positive skeletal muscle markers.
2. A granular cell tumor also has neoplastic cells with eosinophilic cytoplasm, but the cytoplasmic granules are much finer than seen in rhabdomyoma [2].
3. Well-differentiated liposarcoma and myxoid liposarcoma can rarely contain fat cells with hibernoma-like changes. A careful eye for other malignant features and molecular cytogenetics can identify these more ominous entities.
4. Hibernomas are benign lesions that do not recur.

## 4.5 Lipoblastoma

Lipoblastomas are benign lipomatous neoplasms of infants and young children. These occur as superficial soft tissue masses in the upper and lower extremities, head and neck, or trunk. Although benign, lipoblastomas have been associated with disorders such as autism, seizures, congenital anomalies, developmental delay, Sturge-Weber syndrome, or a family history of lipomas [12, 13].

### Pathology

Grossly, these lesions appear to be yellow or tan in color, and myxoid areas are frequently present. In lesions that have a less “mature” appearance, microscopic examination shows immature adipocytes and occasional lipoblasts that are partitioned by fibrous septa to form a lobulated architecture (Fig. 4.7). Myxomatous areas and a delicate capillary architecture can be identified [14].



**Fig. 4.7** Lipoblastoma with immature adipocytes and myxoid changes

### Ancillary Studies

- Lipoblastomas exhibit mutations involving the *PLAG* gene on chromosome 8.
- These tumors are negative for genetic mutations involving the *DDIT3* gene on chromosome 12.

### Differential Diagnosis

- Myxoid liposarcoma

### Comment

1. “Immature lipoblastomas” can look almost identical to a myxoid liposarcoma, since both can have a myxoid background, lipoblasts, and a delicate network of capillaries.
2. While pediatric myxoid liposarcomas rarely occur, these usually only do so in the second decade of life and should be cautiously diagnosed only after molecular confirmation [15].
3. Myxoid liposarcomas can be distinguished by their genetic translocations involving the *DDIT3* gene.
4. Lipoblastomas are benign, but they can recur. Patients with diffuse lesions that are incompletely excised are particularly at risk for recurrence [2].

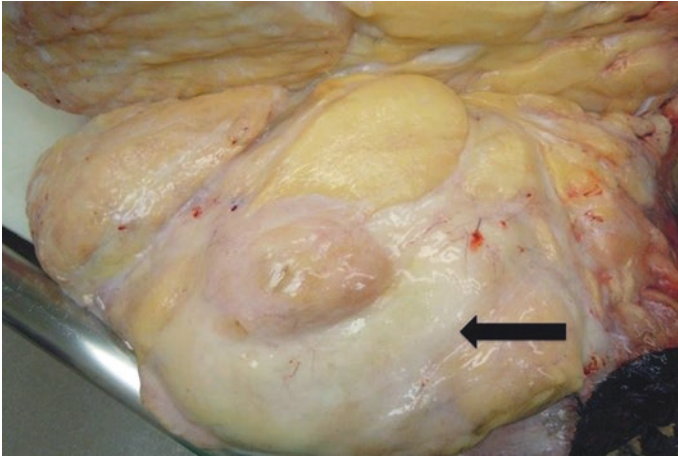
---

## 4.6 Atypical Lipomatous Tumor/Well-Differentiated Liposarcoma

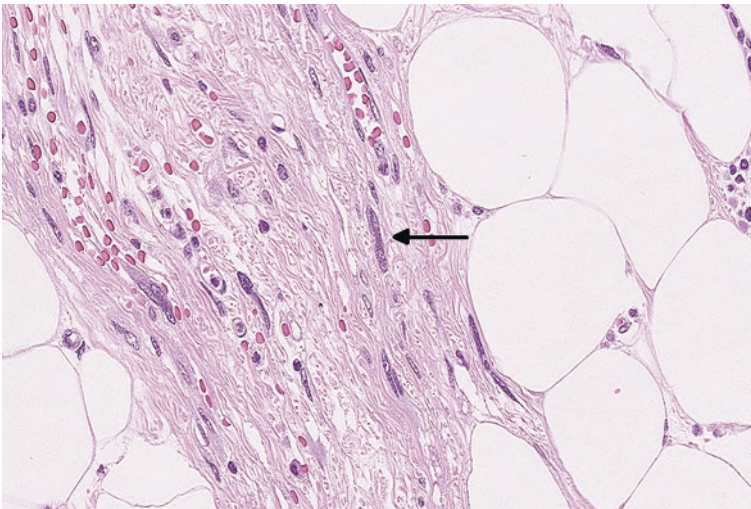
Atypical lipomatous tumor/well-differentiated liposarcoma represents almost half of adipocytic malignancies and has a predilection for deep locations, such as the retroperitoneum and deep proximal extremities. Other sites of occurrence include the mediastinum or spermatic cord. Superficial locations, such as subcutaneous tissue, are extraordinarily rare. Clinically, these arise as painless and slowly enlarging masses that can grow quite large prior to discovery. The diagnosis can sometimes be suspected from the size, location, and appearance of prominent fibrous septations on imaging [16–18].

### Pathology

It is usually apparent to the naked eye that these neoplasms are adipocytic. However, on gross examination the adipose tissue has a vaguely opaque and creamy appearance (Fig. 4.8). Microscopically, liposarcomas contain adipose tissue that is partitioned by thickened fibrous septa that contains cells with dark and hyperchromatic nuclei (Fig. 4.9). Sometimes, fibrosis or associated chronic inflammation can be particularly prominent (Fig. 4.10) [19, 20].



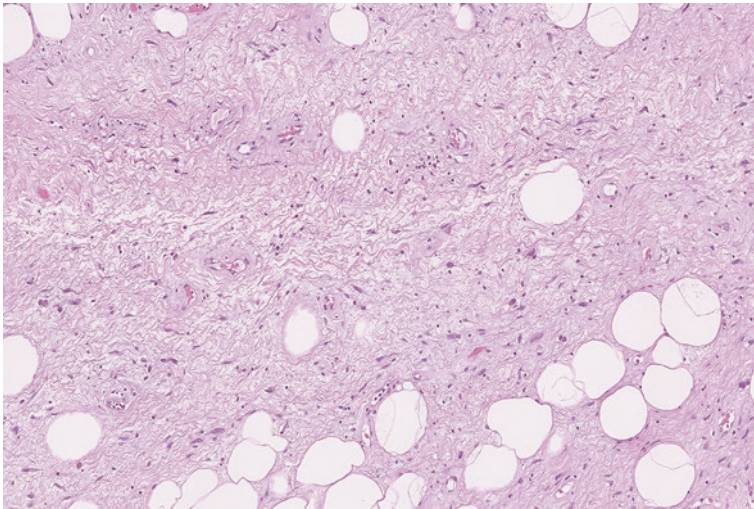
**Fig. 4.8** Gross appearance of a well-differentiated liposarcoma. The adipose tissue demonstrates a whitish, creamy appearance (*arrow*)



**Fig. 4.9** Well-differentiated liposarcoma with cells containing enlarged and hyperchromatic nuclei (*arrow*) in fibrous septa

### Ancillary Studies

- Well-differentiated liposarcoma demonstrates genetic amplification of a region on chromosome 12 (12q13–15).
- This can be confirmed by FISH studies for genes corresponding to this area, such as *MDM2* or *CDK4* [21, 22].



**Fig. 4.10** Sclerosing well-differentiated liposarcoma with an extensively fibrotic background

### Differential Diagnosis

- Lipoma
- Spindle cell/pleomorphic lipoma
- Angiomyolipoma

### Comment

1. Areas of fat necrosis in a lipoma or multinucleated cells in a spindle cell/pleomorphic lipoma can be mistaken for well-differentiated liposarcoma. These lesions usually are more superficial and lack *MDM2* amplification by FISH studies.
2. Angiomyolipoma is a tumor that contains fat and arises in the retroperitoneum, which can cause suspicion for well-differentiated liposarcoma. The cells in angiomyolipoma are positive for HMB-45 or MART-1 immunohistochemical stains, distinguishing this neoplasm from well-differentiated liposarcoma.
3. Well-differentiated liposarcomas do not metastasize but will recur if not completely excised [23, 24].
4. Complete removal of well-differentiated liposarcoma in the retroperitoneum is virtually impossible, and recurrence is almost certain (91% of cases). Tumors arising in the extremity have a less frequent recurrence rate of approximately 43% [23].
5. Approximately a third of patients with retroperitoneal well-differentiated liposarcoma will die from the disease, while tumors in the extremity have been shown to have virtually no mortality. Retroperitoneal tumors have a greater probability of evolving to higher-grade sarcomas (dedifferentiated liposarcoma).

## 4.7 Dedifferentiated Liposarcoma

Dedifferentiated liposarcoma can be viewed as a previously well-differentiated liposarcoma that has lost its adipocytic nature and transformed into a more aggressive sarcoma with metastatic potential. Radiographic imaging and gross examination can suggest a dedifferentiated component when a nonfatty mass is associated with a predominantly adipocytic tumor [25, 26].

### Pathology

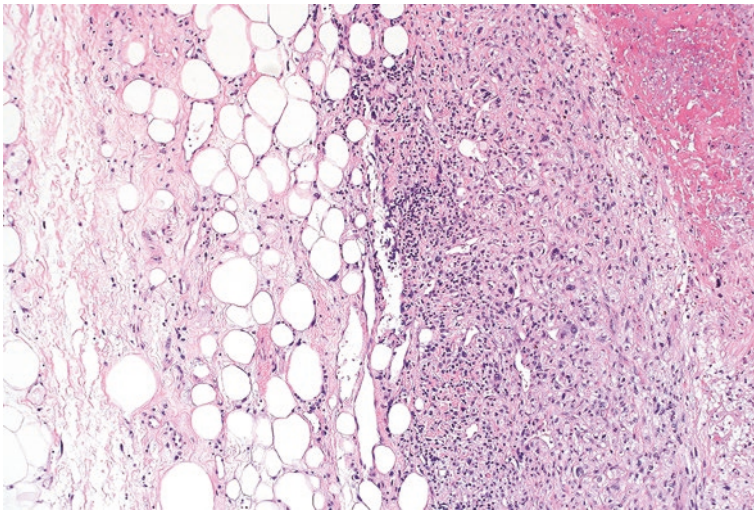
On gross examination, the pathologist will often see a fibrous-like area within an adipocytic tumor. Microscopic examination of this area will reveal highly atypical tumor cells without any lipomatous features (Figs. 4.11 and 4.12) [26].

### Ancillary Studies

- The amplification identified on chromosome 12 (12q13–15) in well-differentiated liposarcomas is also present in dedifferentiated liposarcomas [27].
- This can also be confirmed by FISH studies showing *MDM2* or *CDK4* gene amplification.

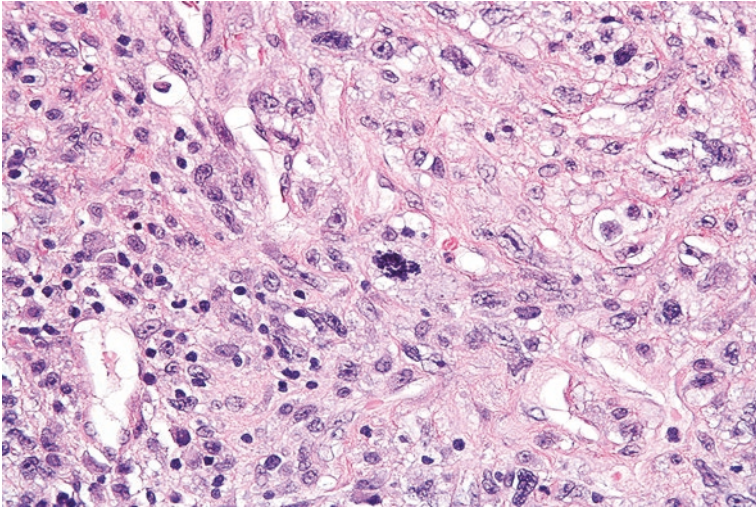
### Differential Diagnosis

- Undifferentiated high-grade pleomorphic sarcoma
- Another high-grade sarcoma infiltrating benign adipose tissue



**Fig. 4.11** Well-differentiated liposarcoma that abruptly transitions to a high-grade dedifferentiated liposarcoma





**Fig. 4.12** Dedifferentiated liposarcoma with nuclear pleomorphism and increased mitosis

### Comment

1. Although the appearances can be virtually identical, positive *MDM2* amplification usually distinguishes dedifferentiated liposarcoma from an undifferentiated high-grade pleomorphic sarcoma.
2. Most dedifferentiated liposarcomas will retain the features of residual well-differentiated liposarcoma in other areas of the lesion. Identification of this well-differentiated component helps exclude a sarcoma that is infiltrating into benign adipose tissue [2].
3. Dedifferentiated sarcomas frequently recur (41%) and have a mortality of 28% that usually results from direct extension of the primary tumor mass [26].
4. Unlike well-differentiated liposarcomas, these higher-grade tumors can metastasize (17%) [26].
5. Wide surgical excision often with adjuvant therapy is recommended for treatment [28].

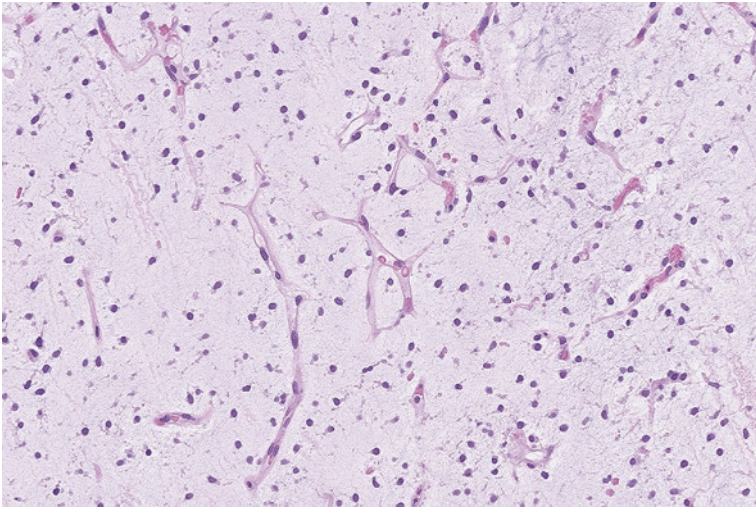
---

## 4.8 Myxoid Liposarcoma

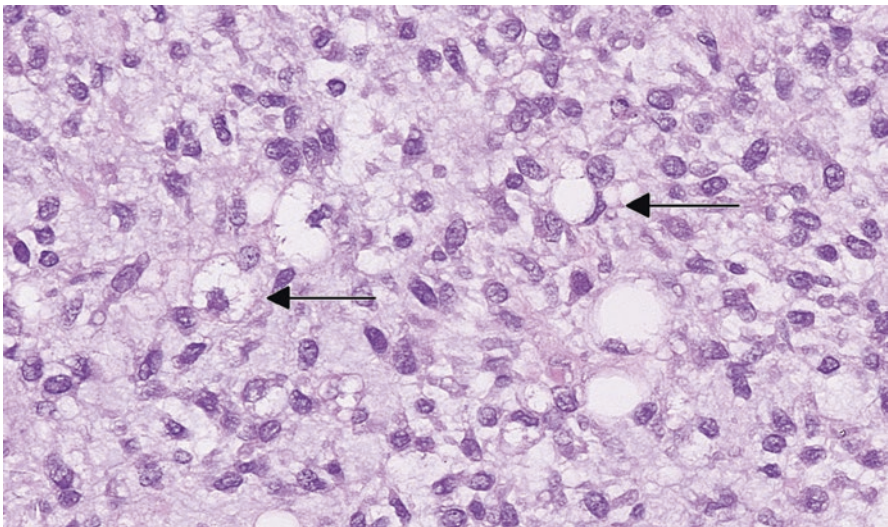
Myxoid liposarcoma is an adipocytic malignancy that most frequently occurs in the deep proximal lower extremities of adults, most often in the fifth decade of life. These tumors can also arise in young adults [2]. Unlike well-differentiated liposarcoma, this tumor rarely if ever occurs in the retroperitoneum and can metastasize [29].

**Pathology**

When encountered in the gross examination room, myxoid liposarcomas are typically multinodular and gelatinous. True to their name, microscopic examination reveals substantial background myxoid material with delicate capillaries, bland-appearing mesenchymal cells, and scattered lipoblasts (Fig. 4.13). Higher-grade tumors contain areas of overlapping round cells with enlarged nuclei and prominent nucleoli (Fig. 4.14) [30].



**Fig. 4.13** Myxoid liposarcoma with a myxoid background and delicate capillary network



**Fig. 4.14** High-grade round cell component of a myxoid/round cell liposarcoma. The *arrow* points out scattered lipoblasts

### Ancillary Studies

- Myxoid liposarcomas consistently show a translocation involving the *DDIT* gene (on chromosome 12) and *FUS* gene (on chromosome 16), which can be identified by FISH studies.
- 5–10% of tumors have an alternate translocation involving the *DDIT* gene (on chromosome 12) and *EWS* gene (on chromosome 22) [31].

### Differential Diagnosis

- Well-differentiated liposarcoma with myxoid changes
- Extraskelatal myxoid chondrosarcoma
- Lipoblastoma
- Myxofibrosarcoma

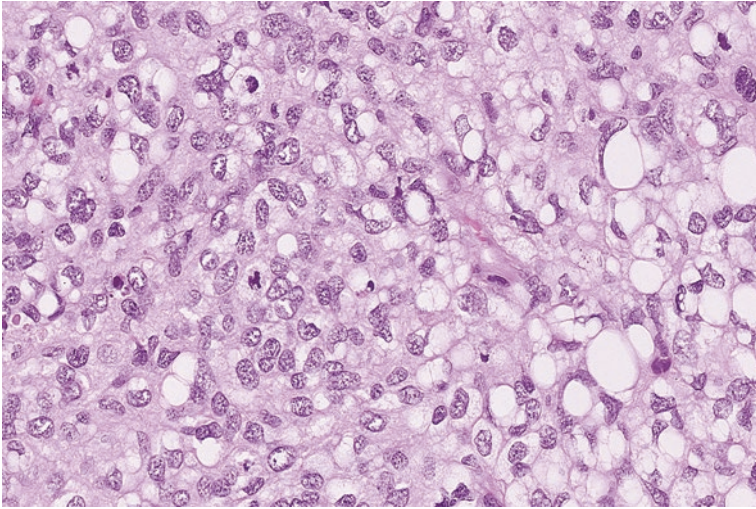
### Comment

1. Myxoid liposarcomas do not contain the atypical hyperchromatic cells seen in myxofibrosarcoma or well-differentiated liposarcoma.
2. Although lipoblastomas and myxoid liposarcomas can look virtually identical, myxoid liposarcomas almost never occur in the first decade of life.
3. Extraskelatal myxoid chondrosarcoma also arises in the proximal extremities but lacks the delicate capillary network seen in myxoid liposarcoma.
4. FISH studies can be used to confirm the diagnosis with highly specific translocations involving the *DDIT3* gene.
5. Approximately a third of myxoid liposarcomas will metastasize and approximately a third of patients will die from this tumor [2].
6. Tumors with a significant population of round cells with vesicular nuclei (over 5%) or necrosis (sometimes referred to as round cell sarcoma) have an increased risk for metastasis and a worse prognosis [32].
7. Wide surgical excision is the standard approach to treatment. High-grade lesions will often receive radiation or chemotherapy [33].

---

## 4.9 Pleomorphic Liposarcoma

Pleomorphic liposarcoma is a rare sarcoma of adipocytic differentiation that is distinct from well-differentiated liposarcoma or myxoid liposarcoma. These often occur in the retroperitoneum or thigh of older adults, most frequently in the seventh decade of life [5, 34].



**Fig. 4.15** Pleomorphic sarcoma with scattered bizarre lipoblasts containing vacuolated cytoplasm

### Pathology

Microscopically, this tumor can appear as a high-grade sarcoma with focal areas of lipoblasts that indicate the lipogenic nature of the neoplasm (Fig. 4.15). Alternatively, these tumors can appear as sheets of bizarre-appearing lipogenic cells. In either case, nuclear atypia and mitoses are easily found in this high-grade tumor.

### Ancillary Studies

- Unlike other malignant lipogenic tumors, pleomorphic liposarcoma lacks a consistent cytogenetic abnormality.

### Differential Diagnosis

- Dedifferentiated liposarcoma
- Undifferentiated high-grade pleomorphic sarcoma
- Carcinoma (e.g., renal cell carcinoma)

### Comment

1. Dedifferentiated liposarcoma can have areas similar to pleomorphic liposarcoma. When in doubt, the absence of *MDM2* gene amplification can exclude dedifferentiated liposarcoma as a diagnostic possibility.
2. Negative immunohistochemical stains for epithelial cells (e.g., cytokeratin) can sometimes help differentiate pleomorphic liposarcoma from a poorly differentiated carcinoma.

3. Pleomorphic liposarcoma is an aggressive high-grade tumor in which 30–40% of patients will develop metastasis [2]. The 5-year disease-free survival is 39% [35].
4. Treatment typically consists of wide resection and adjuvant therapy.

### Facts to Remember

1. Spindle cell/pleomorphic lipomas are benign subcutaneous tumors that often occur in the neck and back and can contain atypical appearing multinucleated cells.
2. Hibernomas are benign fatty tumors that are similar to lipomas but exhibit features reminiscent of brown fat.
3. Angiolipomas often manifest as painful subcutaneous nodules on the forearm of young adults. These benign lesions contain numerous capillaries admixed with unremarkable adipose tissue.
4. Clinicians and pathologists should be vigilant not to dismiss a well-differentiated liposarcoma as a benign lipoma.
5. Special attention should be given to recurrent lipomatous lesions or prominent deep lesions in older adults. All retroperitoneal fatty tumors should be carefully assessed for features of well-differentiated liposarcoma.
6. Well-differentiated and dedifferentiated liposarcoma consistently manifest amplification of the *MDM2* gene on chromosome 12.
7. Myxoid liposarcoma is a liposarcoma with metastatic potential that often occurs in the proximal extremities of adults. It can be confirmed by mutations involving the *DDIT3* gene.
8. Pleomorphic liposarcoma is another distinct form of liposarcoma distinguished by anaplastic tumor cells and bizarre lipoblasts.
9. Dedifferentiated, myxoid, and pleomorphic liposarcomas have metastatic potential and can often recur.

---

### References

1. Rydholm A, Berg NO. Size, site and clinical incidence of lipoma. Factors in the differential diagnosis of lipoma and sarcoma. *Acta Orthop Scand.* 1983;54(6):929–34.
2. Goldblum J, Weiss S, Folpe AL, editors. *Enzinger and Weiss's soft tissue tumors*. 6th ed. Philadelphia: Elsevier; 2013.
3. Fletcher CD, Martin-Bates E. Intramuscular and intermuscular lipoma: neglected diagnoses. *Histopathology.* 1988;12(3):275–87.
4. Clay MR, Martinez AP, Weiss SW, Edgar MA. *MDM2* amplification in problematic lipomatous tumors: analysis of FISH testing criteria. *Am J Surg Pathol.* 2015;39(10):1433–9.
5. Fletcher CDM, Bridge JA, Hogendoorn PC, Mertens F, editors. *Pathology and genetics of tumours of soft tissue and bone*. 4th ed. Lyon: World Health Organization; 2013.
6. Abbasi NR, Brownell I, Fangman W. Familial multiple angiolipomatosis. *Dermatol Online J.* 2007;13(1):3.

7. Lin JJ, Lin F. Two entities in angiolipoma. A study of 459 cases of lipoma with review of literature on infiltrating angiolipoma. *Cancer*. 1974;34(3):720–7.
8. Enzinger FM, Harvey DA. Spindle cell lipoma. *Cancer*. 1975;36(5):1852–9.
9. Fletcher CD, Martin-Bates E. Spindle cell lipoma: a clinicopathological study with some original observations. *Histopathology*. 1987;11(8):803–17.
10. Chen BJ, Marino-Enriquez A, Fletcher CD, Hornick JL. Loss of retinoblastoma protein expression in spindle cell/pleomorphic lipomas and cytogenetically related tumors: an immunohistochemical study with diagnostic implications. *Am J Surg Pathol*. 2012;36(8):1119–28.
11. Furlong MA, Fanburg-Smith JC, Miettinen M. The morphologic spectrum of hibernoma: a clinicopathologic study of 170 cases. *Am J Surg Pathol*. 2001;25(6):809–14.
12. Collins MH, Chatten J. Lipoblastoma/lipoblastomatosis: a clinicopathologic study of 25 tumors. *Am J Surg Pathol*. 1997;21(10):1131–7.
13. Coffin CM, Lowichik A, Putnam A. Lipoblastoma (LPB): a clinicopathologic and immunohistochemical analysis of 59 cases. *Am J Surg Pathol*. 2009;33(11):1705–12.
14. Mentzel T, Calonje E, Fletcher CD. Lipoblastoma and lipoblastomatosis: a clinicopathological study of 14 cases. *Histopathology*. 1993;23(6):527–33.
15. Dadone B, Refae S, Lemarie-Delaunay C, Bianchini L, Pedeutour F. Molecular cytogenetics of pediatric adipocytic tumors. *Cancer Genet*. 2015;208(10):469–81.
16. Brisson M, Kashima T, Delaney D, Tirabosco R, Clarke A, Cro S, et al. MRI characteristics of lipoma and atypical lipomatous tumor/well-differentiated liposarcoma: retrospective comparison with histology and MDM2 gene amplification. *Skelet Radiol*. 2013;42(5):635–47.
17. Dei Tos AP. Liposarcoma: new entities and evolving concepts. *Ann Diagn Pathol*. 2000;4(4):252–66.
18. Lucas DR, Nascimento AG, Sanjay BK, Rock MG. Well-differentiated liposarcoma. The Mayo Clinic experience with 58 cases. *Am J Clin Pathol*. 1994;102(5):677–83.
19. Coindre JM, Pedeutour F, Aurias A. Well-differentiated and dedifferentiated liposarcomas. *Virchows Arch*. 2010;456(2):167–79.
20. Argani P, Facchetti F, Inghirami G, Rosai J. Lymphocyte-rich well-differentiated liposarcoma: report of nine cases. *Am J Surg Pathol*. 1997;21(8):884–95.
21. Sirvent N, Coindre JM, Maire G, Hostein I, Keslair F, Guillou L, et al. Detection of MDM2-CDK4 amplification by fluorescence in situ hybridization in 200 paraffin-embedded tumor samples: utility in diagnosing adipocytic lesions and comparison with immunohistochemistry and real-time PCR. *Am J Surg Pathol*. 2007;31(10):1476–89.
22. Binh MB, Sastre-Garau X, Guillou L, de Pinieux G, Terrier P, Lagace R, et al. MDM2 and CDK4 immunostainings are useful adjuncts in diagnosing well-differentiated and dedifferentiated liposarcoma subtypes: a comparative analysis of 559 soft tissue neoplasms with genetic data. *Am J Surg Pathol*. 2005;29(10):1340–7.
23. Weiss SW, Rao VK. Well-differentiated liposarcoma (atypical lipoma) of deep soft tissue of the extremities, retroperitoneum, and miscellaneous sites. A follow-up study of 92 cases with analysis of the incidence of “dedifferentiation”. *Am J Surg Pathol*. 1992;16(11):1051–8.
24. Sommerville SM, Patton JT, Luscombe JC, Mangham DC, Grimer RJ. Clinical outcomes of deep atypical lipomas (well-differentiated lipoma-like liposarcomas) of the extremities. *ANZ J Surg*. 2005;75(9):803–6.
25. Kransdorf MJ, Meis JM, Jelinek JS. Dedifferentiated liposarcoma of the extremities: imaging findings in four patients. *AJR Am J Roentgenol*. 1993;161(1):127–30.
26. Henricks WH, Chu YC, Goldblum JR, Weiss SW. Dedifferentiated liposarcoma: a clinicopathological analysis of 155 cases with a proposal for an expanded definition of dedifferentiation. *Am J Surg Pathol*. 1997;21(3):271–81.
27. Horvai AE, DeVries S, Roy R, O’Donnell RJ, Waldman F. Similarity in genetic alterations between paired well-differentiated and dedifferentiated components of dedifferentiated liposarcoma. *Mod Pathol*. 2009;22(11):1477–88.
28. Bonvalot S, Rivoire M, Castaing M, Stoeckle E, Le Cesne A, Blay JY, et al. Primary retroperitoneal sarcomas: a multivariate analysis of surgical factors associated with local control. *J Clin Oncol*. 2009;27(1):31–7.

29. de Vreeze RS, de Jong D, Tielen IH, Ruijter HJ, Nederlof PM, Haas RL, et al. Primary retroperitoneal myxoid/round cell liposarcoma is a nonexisting disease: an immunohistochemical and molecular biological analysis. *Mod Pathol*. 2009;22(2):223–31.
30. Smith TA, Easley KA, Goldblum JR. Myxoid/round cell liposarcoma of the extremities. A clinicopathologic study of 29 cases with particular attention to extent of round cell liposarcoma. *Am J Surg Pathol*. 1996;20(2):171–80.
31. Panagopoulos I, Hoglund M, Mertens F, Mandahl N, Mitelman F, Aman P. Fusion of the EWS and CHOP genes in myxoid liposarcoma. *Oncogene*. 1996;12(3):489–94.
32. Antonescu CR, Tschernyavsky SJ, Decuseara R, Leung DH, Woodruff JM, Brennan MF, et al. Prognostic impact of P53 status, TLS-CHOP fusion transcript structure, and histological grade in myxoid liposarcoma: a molecular and clinicopathologic study of 82 cases. *Clin Cancer Res*. 2001;7(12):3977–87.
33. Hornick JL, editor. *Practical soft tissue pathology: a diagnostic approach*. Philadelphia: Saunders; 2013.
34. Gebhard S, Coindre JM, Michels JJ, Terrier P, Bertrand G, Trassard M, et al. Pleomorphic liposarcoma: clinicopathologic, immunohistochemical, and follow-up analysis of 63 cases: a study from the French Federation of Cancer Centers Sarcoma Group. *Am J Surg Pathol*. 2002;26(5):601–16.
35. Hornick JL, Bosenberg MW, Mentzel T, McMenamin ME, Oliveira AM, Fletcher CD. Pleomorphic liposarcoma: clinicopathologic analysis of 57 cases. *Am J Surg Pathol*. 2004;28(10):1257–67.

Fibroblastic and myofibroblastic tumors represent a large group of soft tissue neoplasms that are made up of cells resembling those found in tendons or ligaments. Fibroblasts appear as spindle cells with elongated nuclei and variable amounts of associated eosinophilic collagen deposition (Fig. 5.1). Myofibroblasts can be spindled or star-shaped and demonstrate some muscle-type antigens (e.g. smooth muscle actin) by immunohistochemistry. The behavior of these tumors can span from completely benign to malignant [1].

---

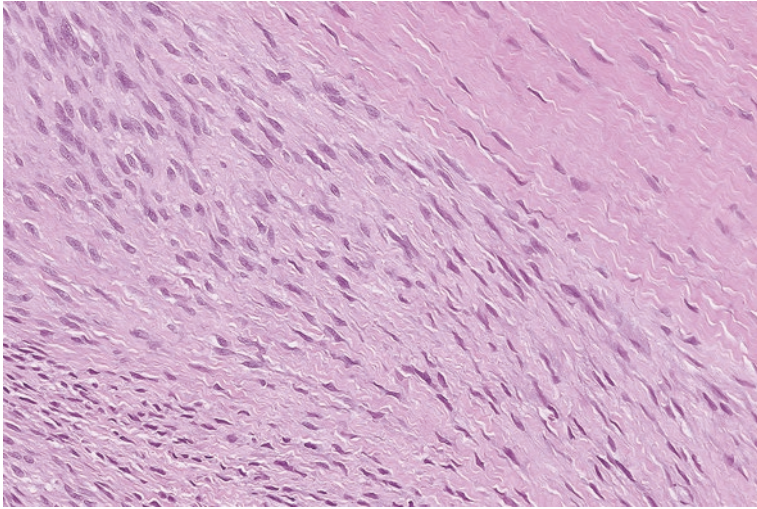
## 5.1 Nodular Fasciitis and Similar Lesions

Nodular fasciitis is a lesion that typically presents in the subcutaneous tissue of adults in the third to fifth decade of life. It most commonly occurs in the upper extremities but can also arise in the head and neck and trunk, among other areas. Because nodular fasciitis can rapidly enlarge over the course of weeks, patients and their physicians can become quite concerned about an aggressive neoplasm, prompting biopsy. Over time, the growth of these tumors typically plateaus and they reach a size of no more than 3 cm in greatest dimension [2–4].

### Pathology

Grossly, nodular fasciitis appears to be well circumscribed and gelatinous or fibrous in consistency. The microscopic features are thought to depend on the age of the lesion. If biopsied soon after onset, the slides show a haphazard arrangement of slender fibroblasts in the background of myxoid material (Fig. 5.2a). This is sometimes referred to as a “tissue culture” appearance, given the morphologic similarity to viral cultures in a microbiology lab. Background inflammation, focal areas of microhemorrhage, and mitosis can be seen (Fig. 5.2b). Multinucleated giant cells





**Fig. 5.1** Fibroblastic cells of superficial fibromatosis with elongated and slender nuclei with varying amounts of associated collagen

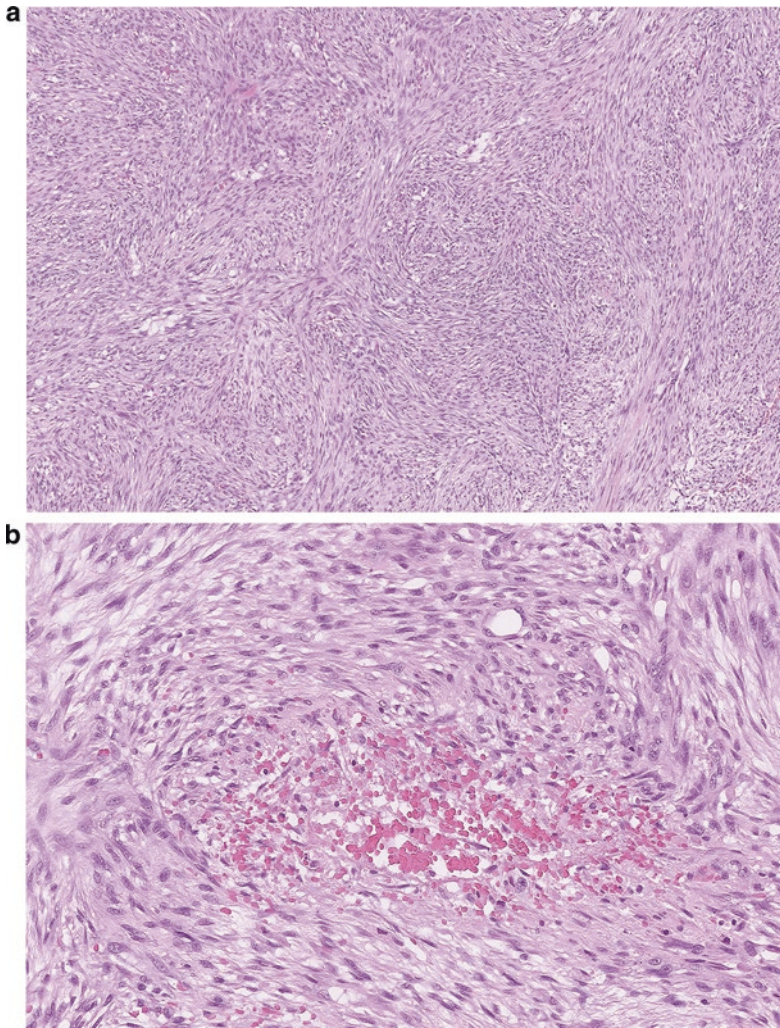
can often be identified. Lesions of medium duration are more cellular and lose their myxoid appearance. Long-standing lesions often exhibit dense sclerosis reminiscent of a scar [4].

### Neoplasms similar to nodular fasciitis

- Proliferative fasciitis and proliferative myositis are benign rapidly growing lesions that occur in the extremities of adults and have a somewhat similar morphologic appearance to nodular fasciitis. These lesions can also have large epithelioid or ganglion-like cells with enlarged nuclei and conspicuous nucleoli (Fig. 5.3a) [5].
- Ischemic fasciitis occurs in older adults who have limited mobility. They tend to arise at bony prominences such as the shoulder. In addition to a haphazard arrangement of myofibroblasts, these lesions also contain juxtaposed areas of necrosis and scattered ganglion-like cells, similar to those seen in proliferative fasciitis (Fig. 5.3b) [6, 7].

### Ancillary Studies

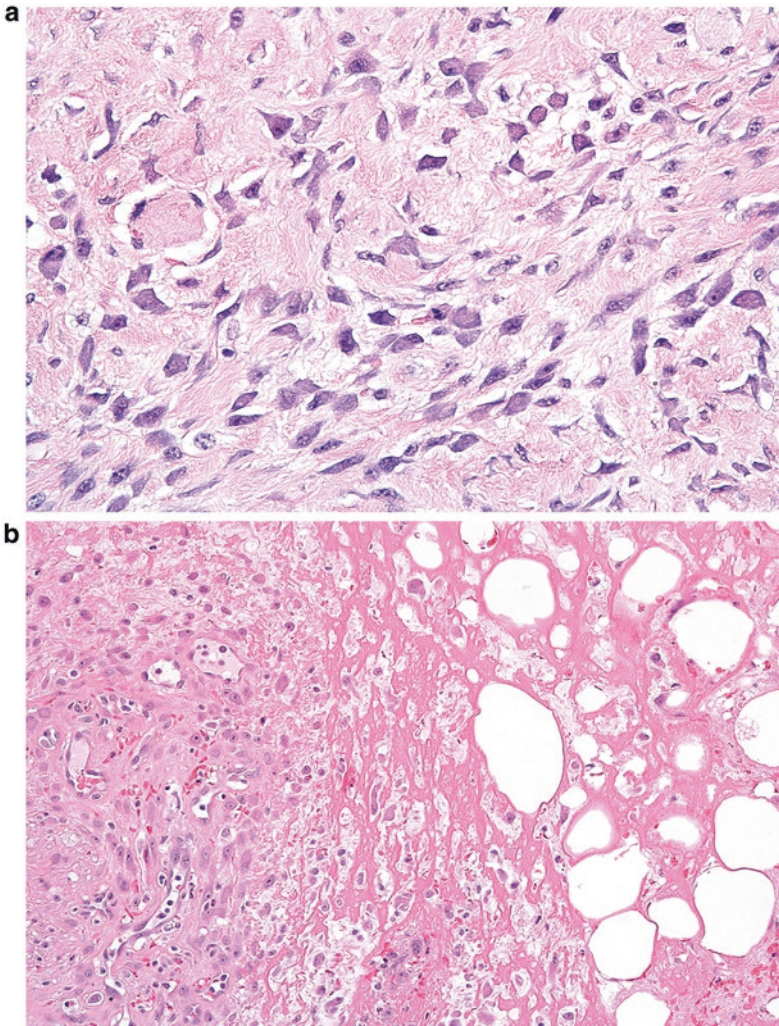
- Nodular fasciitis manifests chromosomal translocations involving the *USP6* gene.
- The *USP6* translocation can be detected by FISH.



**Fig. 5.2** (a) Nodular fasciitis with haphazard arrangement of fibroblastic cells. (b) Area of microhemorrhage in nodular fasciitis

### Differential Diagnosis

- Myxofibrosarcoma
- Low-grade myofibroblastic sarcoma
- Superficial or deep fibromatosis
- Fibroma of tendon sheath



**Fig. 5.3** (a) Proliferative fasciitis with plump epithelioid- or ganglion-like cells. (b) Ischemic fasciitis with area of necrosis and scattered plump epithelioid cells

### Comment

1. Nodular fasciitis often presents as a rapidly growing lesion that displays disorganized spindle cells and multiple mitoses. This morphology and clinical presentation can be mistaken for more aggressive lesions such as myxofibrosarcoma, low-grade myofibroblastic sarcoma, and fibromatosis.
2. However, nodular fasciitis is usually smaller in size and lacks the atypical mitoses seen in these more aggressive neoplasms.

3. Although fibromatosis can have focal areas resembling nodular fasciitis, it typically is more infiltrative in nature.
4. Nodular fasciitis is a benign lesion that almost never recurs.
5. Recurrent lesions originally diagnosed as nodular fasciitis should be carefully assessed for features of a sarcoma. In difficult cases, FISH studies for *USP6* can help confirm the diagnosis of nodular fasciitis.

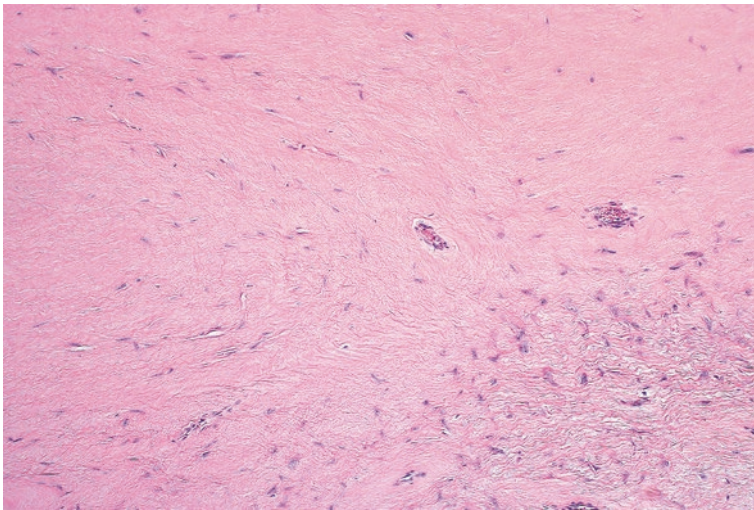
---

## 5.2 Fibroma of Tendon Sheath

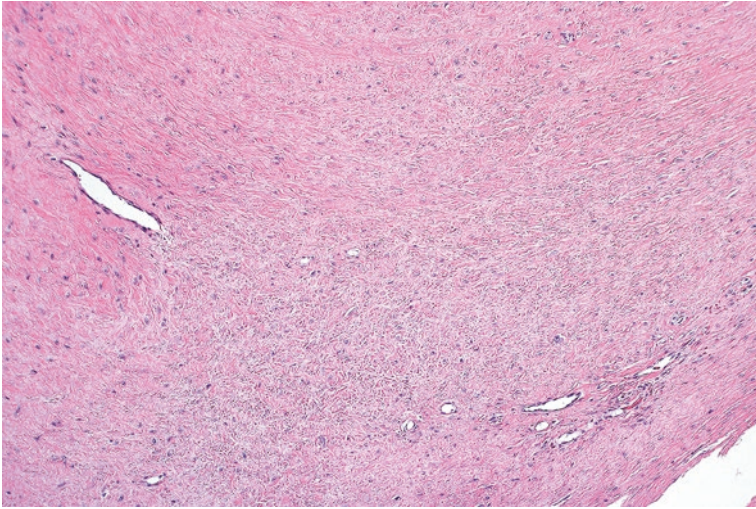
Fibromas of the tendon sheath arise in adult patients between the third and fifth decades of life and typically measure less than 2 cm in size [1, 8]. They present as slow-growing nodules that are attached to the tendons of the hands or feet. The thumb, index, and middle finger are the digits most commonly involved, and some patients can experience tenderness or limited range of motion in the involved digit [9, 10]. Given the location, these are often clinically presumed to be ganglion cysts [11].

### Pathology

Grossly, fibroma of tendon sheath appears as a fibrous nodule. The microscopic sections display single or multiple lobules of stellate cells with extensive amounts of associated dense sclerosis (Fig. 5.4). Compressed vascular spaces are often located at the periphery of the lesion (Fig. 5.5). Although frequently hypocellular, there can be focally more cellular areas that appear similar to nodular fasciitis [1].



**Fig. 5.4** Fibroma of tendon sheath with stellate cells and dense fibrosis



**Fig. 5.5** Compressed vascular spaces at the periphery of a fibroma of tendon sheath

### Differential Diagnosis

- Nodular fasciitis
- Giant cell tumor of tendon sheath

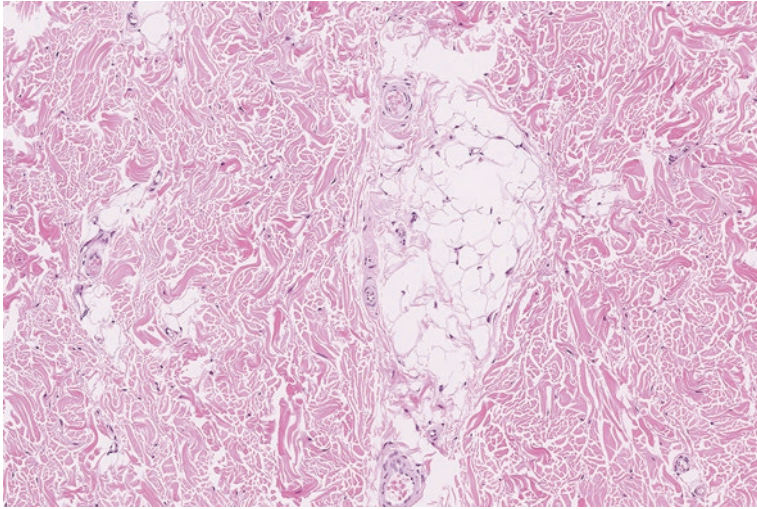
### Comment

1. Although focal areas of fibroma of tendon sheath can resemble nodular fasciitis, nodular fasciitis only rarely arises in the hands and feet. Furthermore, nodular fasciitis clinically arises more rapidly than fibroma of tendon sheath [11].
2. Giant cell tumor of tendon sheath also arises in the hands and feet and can demonstrate fibrosis in long-standing lesions. However, giant cell tumor of tendon sheath will typically retain at least focal areas of hemorrhage or foamy macrophages.
3. Fibroma of tendon sheath is a benign lesion, but does carry a moderate risk of recurrence (approximately 25%) [8]. Patients with recurrence can be cured with a second excision [12].

---

## 5.3 Nuchal-Type Fibroma

Nuchal-type fibromas often arise as subcutaneous masses in adults around the head and neck area. Most measure 1–6 cm in greatest dimension [1]. Despite the designation as “nuchal,” approximately a third of these lesions will occur at other anatomic sites. Curiously, many patients (approximately 44%) with nuchal-type fibroma also have diabetes mellitus [13].



**Fig. 5.6** Nuchal-type fibroma with dense ropey collagen and focal area of entrapped adipose tissue

### Pathology

Microscopically, these lesions are predominantly composed of dense, ropey collagen with scattered fibroblasts and nests of adipose tissue (Fig. 5.6). This fibrous tissue can entrap focal nerves and adnexal structures [13, 14].

### Ancillary Studies

- Ancillary studies are not usually employed for the diagnosis of nuchal-type fibroma. The diagnosis is typically based on the morphologic appearance alone.

### Differential Diagnosis

- Elastofibroma
- Gardner-associated fibroma

### Comment

1. Elastofibromas also occur in the back or upper neck area. They can be distinguished by the identification of beaded cords of elastin fibers.
2. Nuchal-type fibroma can be difficult if not impossible to distinguish from Gardner-associated fibroma.

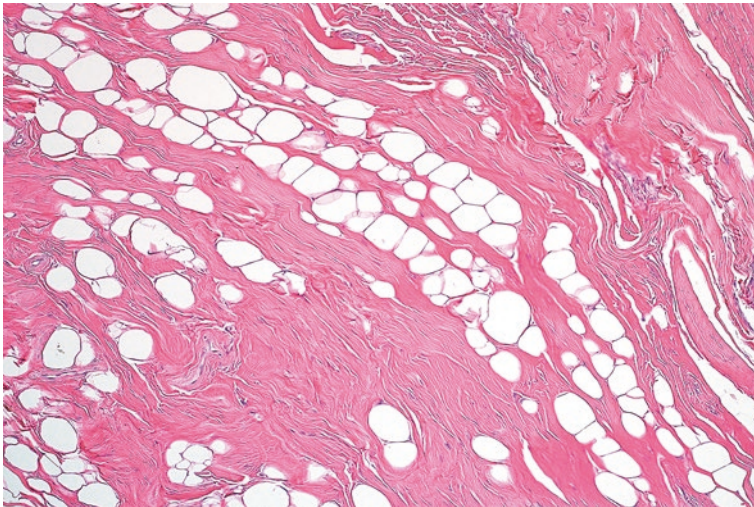
3. Consequently, nuchal-type fibroma lesions are often diagnosed as nuchal-type/Gardner-associated fibroma with a comment recommending assessment for clinical features of Gardner syndrome.
4. Lesions with nuchal-type fibroma morphology in children are generally considered to be Gardner-associated fibroma [12].
5. These are benign lesions that are treated with surgical resection. If incompletely excised they can recur.

## 5.4 Gardner-Associated Fibroma

Gardner-associated fibromas occur in young children and are associated with familial adenomatous polyposis. A timely diagnosis can result in appropriate screening and prevention of future intestinal adenocarcinoma. It often arises as a subcutaneous lesion on the back or head and neck region [15]. In addition to fibromas and intestinal polyposis, patients with Gardner syndrome also present with epidermal inclusion cysts, osteomas, and deep fibromatosis (desmoid tumors) [16].

### Pathology

On gross examination, Gardner-associated fibroma appears as a fibrous lesion that can measure up to 12 cm in size. Microscopically, these tumors contain ropey, densely collagenized fibrous tissue with some associated mature adipose tissue (Fig. 5.7). Only focal entrapment of nerves is seen.



**Fig. 5.7** Gardner-associated fibroma with ropey collagen. The appearance is very similar to nuchal-type fibroma

### Ancillary Studies

- Gardner-associated fibromas are typically diagnosed based on their morphologic appearance.
- Beta-catenin immunohistochemistry alone is neither sufficiently sensitive nor specific for definitive exclusion or confirmation of the diagnosis [17].

### Differential Diagnosis

- Deep fibromatosis (desmoid tumor)
- Nuchal type fibroma

### Comment

1. Deep fibromatosis is a fibrotic lesion that can also arise in patients with Gardner syndrome. These neoplasms typically have a more organized arrangement of fibroblasts in a streaming and fascicular architecture.
2. Differentiation between Gardner-associated fibroma and nuchal-type fibroma can be virtually impossible at times. Sometimes, the diagnosis of “nuchal-type/Gardner-associated fibroma” is rendered.
3. Gardner-associated fibromas are treated surgically and may recur if not completely resected.
4. Arranging appropriate screening for other manifestations of Gardner syndrome, such as familial adenomatous polyposis, is key in preventing later onset of a colonic adenocarcinoma [1].

---

## 5.5 Elastofibroma

Elastofibroma is a benign fibrous proliferation that usually occurs beneath the muscles around the scapula or chest wall. This lesion predominantly manifests in older adults in the 6th to 7th decade. It is more common in females, and approximately half of patients have bilateral lesions [10, 18].

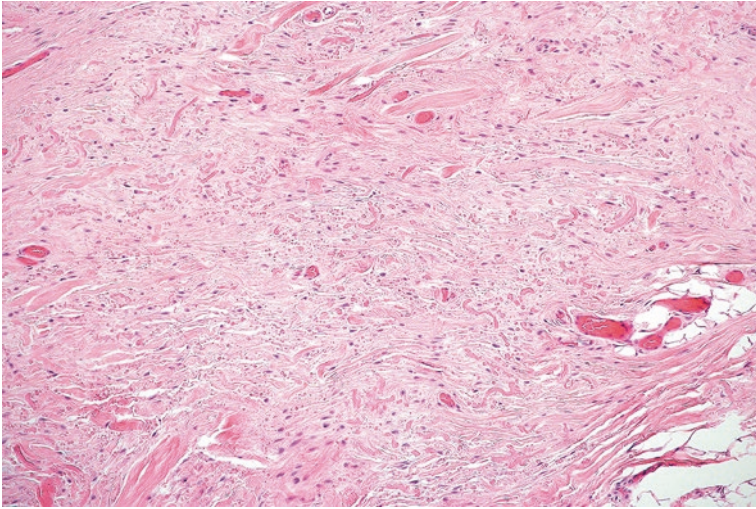
### Pathology

Microscopically, these lesions are primarily composed of fibrous tissue admixed with adipose tissue (Fig. 5.8). On closer examination the fibrous tissue contains vaguely refractive globules and beads of elastin fibers (Fig. 5.9).

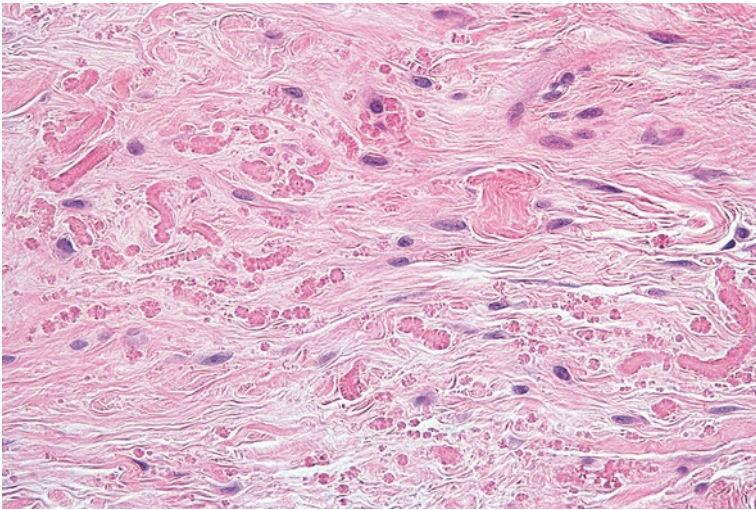
### Ancillary Studies

- A special stain (Verhoeff elastin stain) will also highlight elastin fibers.





**Fig. 5.8** Elastofibroma appears as a fibrotic lesion at low power



**Fig. 5.9** High-power examination of an elastofibroma shows beaded elastin fibers

### Differential Diagnosis

- Gardner-associated or nuchal-type fibroma
- Spindle cell lipoma

### Comment

1. The extensive amount of fibrous tissue intermixed with adipose tissue can suggest entities such as nuchal-type fibroma or spindle cell lipoma.

2. High-power examination of the H&E slide will typically reveal elastin fibers.
3. Knowledge of the site of origin (beneath the scapula or chest wall) can trigger the pathologist to closely assess for these features.
4. These are benign lesions that can be treated with conservative excision. Recurrence is rare.

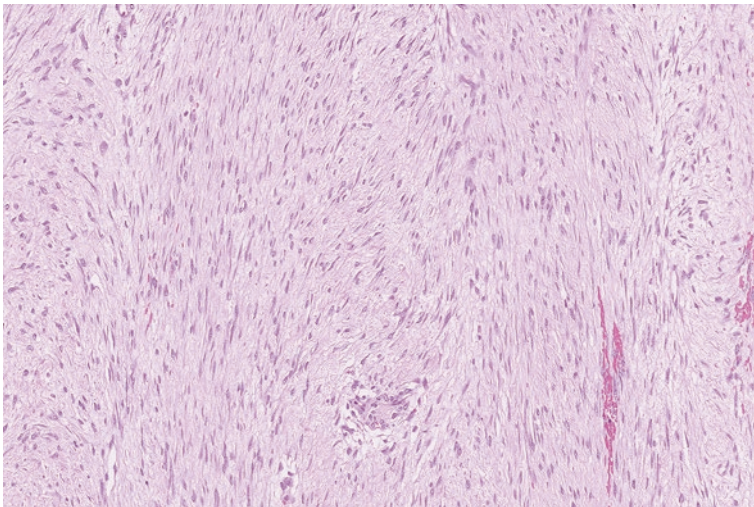
---

## 5.6 Superficial Fibromatosis

Superficial fibromatosis is a benign proliferation of fibroblasts that can occur in the hand (palmar fibromatosis), foot (plantar fibromatosis), or penis (penile fibromatosis/Peyronie disease). Palmar fibromatosis predominantly occurs in Caucasian men over 65 years. These lesions arise slowly and evolve to the point of causing flexion contractures [1]. Plantar fibromatosis has a broader age distribution and can be found in young adults [19]. Both have been associated with numerous medical conditions such as type I and II diabetes mellitus and alcoholism [20, 21].

### Pathology

Superficial fibromatosis grossly appears as fibrous nodules that are typically less than 1 cm in size. Microscopically, they are composed of long bundles of fibroblasts with varying amounts of associated collagen material (Fig. 5.10). Although these can be cellular, there is minimal mitosis or atypical nuclei.



**Fig. 5.10** Superficial fibromatosis with long fascicles of spindle cells in the background of fibrous tissue

### Ancillary Studies

- A percentage of superficial fibromatosis lesions (approximately 60%) will show nuclear staining for beta-catenin [17].

### Differential Diagnosis

- Malignant peripheral nerve sheath tumor
- Synovial sarcoma

### Comment

1. While the architecture and cellularity of superficial fibromatosis can mimic more aggressive soft tissue tumors, fibromatosis lacks the nuclear atypia or increased mitoses found in malignant peripheral nerve sheath tumor or synovial sarcoma.
2. Although benign, these lesions frequently recur.
3. Fasciectomy/aponeurosectomy is a common treatment approach [1, 12].

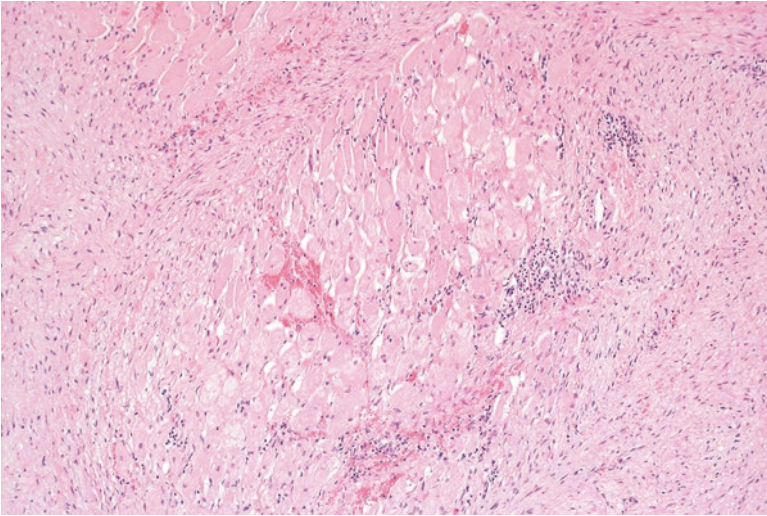
---

## 5.7 Deep (Desmoid-Type) Fibromatosis

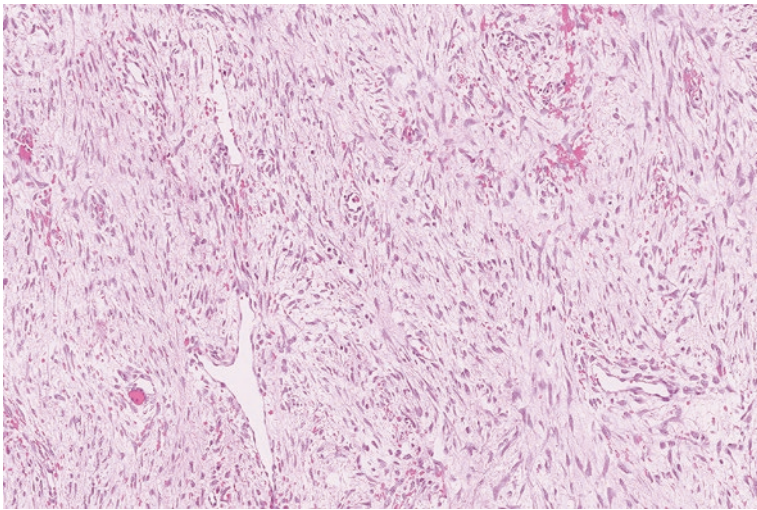
Deep or desmoid-type fibromatosis is a fibrous proliferation thought to arise from the connective tissue of muscle, overlying fascia, or aponeurosis. Conceptually, these tumors are divided into tumors that arise in the abdominal wall (abdominal fibromatosis), within the abdomen (intra-abdominal fibromatosis), or outside the abdomen (extra-abdominal fibromatosis). Abdominal fibromatosis is usually seen in young women after childbirth [22]. Extra-abdominal fibromatosis often occurs in young adults (median age of 37 years) and arises in the shoulder, spine, thorax, hip, or thigh [23]. Intra-abdominal fibromatosis also occurs in young adults (average age of 41 years). A small subset of these arises as a manifestation of Gardner syndrome, a familial condition that includes deep fibromatosis, Gardner-associated fibroma, and familial adenomatous polyposis [24].

### Pathology

Grossly, these tumors have a fibrotic appearance. The microscopic sections show long bundles of bland-appearing fibroblasts that are typically less cellular than superficial fibromatosis. There are varying amounts of background collagenous and myxoid stroma (Fig. 5.11). Occasional prominent capillaries are lodged in between the fascicles and focal extravasated erythrocytes can be seen (Fig. 5.12) [10].



**Fig. 5.11** Deep fibromatosis infiltrating around skeletal muscle fibers



**Fig. 5.12** Lodged capillaries and extravasated red blood cells in deep fibromatosis

### Ancillary Studies

- Deep fibromatosis is primarily a histologic diagnosis.
- Occasionally, a positive beta-catenin stain or finding of a *CTNNB1* mutation can help confirm the diagnosis [25].

## Differential Diagnosis

- Nodular fasciitis
- Retroperitoneal fibrosis
- Gastrointestinal stromal tumor

## Comment

1. Deep fibromatosis can focally demonstrate areas of disorganized spindle cells, reminiscent of nodular fasciitis; however, nodular fasciitis typically presents as a more circumscribed lesion in the subcutaneous tissue.
2. Retroperitoneal fibrosis usually presents as a perivascular mass in the abdomen and often contains aggregates of plasma cells that are sometimes positive for IgG4.
3. CD117 and DOG1 immunohistochemical stains are positive in a gastrointestinal stromal tumor and negative in deep fibromatosis.
4. Although deep fibromatosis does not metastasize, it can be locally aggressive.
5. The particular clinical behavior of a deep fibromatosis depends on the site of occurrence.
6. Extra-abdominal deep fibromatosis has a recurrence rate of approximately 35–65%, while abdominal lesions have a recurrence rate of 15–30%.
7. Sporadic intra-abdominal lesions have a low rate of recurrence (12%), while those associated with Gardner syndrome almost always recur (90%) [1].
8. Treatment options include observation. If the lesion is symptomatic or is endangering vital structures, surgical resection can be pursued, though excised lesions can recur. Other treatment options include tamoxifen, non-steroidal anti-inflammatory drugs (NSAIDs), and chemotherapy regimens [26].

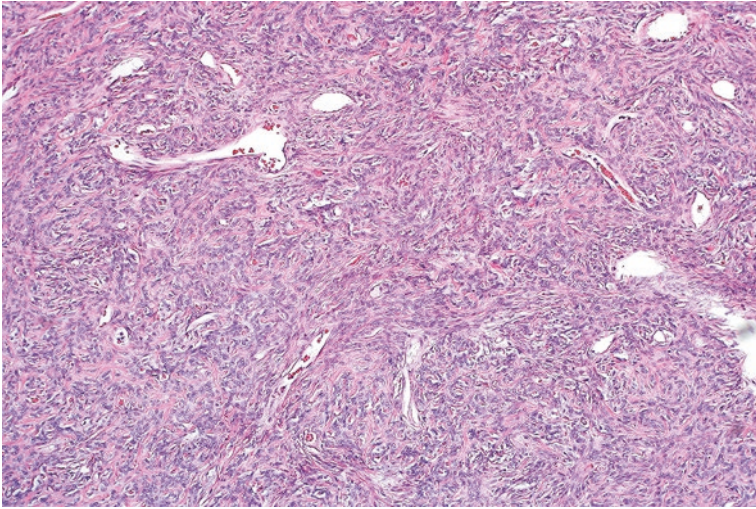
---

## 5.8 Solitary Fibrous Tumor

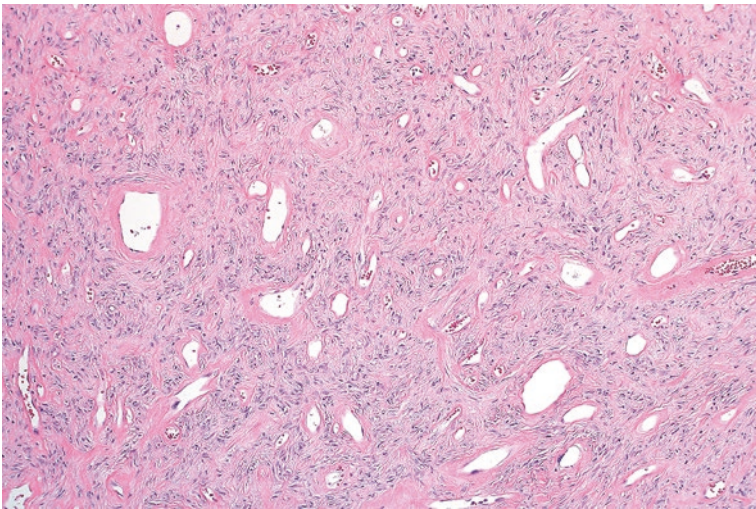
Solitary fibrous tumor is a fibroblastic neoplasm that can arise in multiple locations, including the extremities, pelvis, retroperitoneum, pleura, chest wall, and abdominal serosa. These tumors arise in patients of all ages with most extrathoracic lesions occurring in the sixth decade [27]. Rarely, these tumors can induce hypoglycemia, sweating, or even coma by secretion of insulin growth factor [28].

### Pathology

Grossly, these neoplasms are fibrotic but can exhibit cystic degeneration. Under the microscope, solitary fibrous tumors are said to demonstrate a “patternless pattern”, which refers to the highly variable appearances that a pathologist can encounter in a single tumor. In more cellular portions of a solitary fibrous tumor, ovoid to spindle cells are arranged around branching vessels of varying shapes and sizes (Fig. 5.13). In less cellular portions, there are scattered ovoid cells in the background of dense collagen and vessels with perivascular hyalinization (Figs. 5.14 and 5.15).



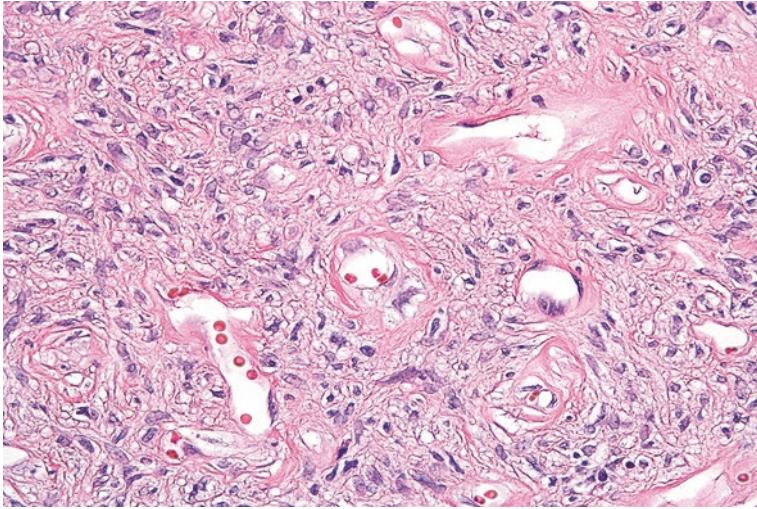
**Fig. 5.13** Cellular solitary fibrous tumor with a dense population of ovoid tumor cells



**Fig. 5.14** Scattered vascular spaces in a less cellular area of solitary fibrous tumor

### Ancillary Studies

- Solitary fibrous tumor is often positive for CD34 and bcl-2 immunohistochemical stains [29].
- Recently, solitary fibrous tumor has been found to have a unique translocation between the *NAB2* and *STAT6* genes.
- Positive nuclear staining with a STAT6 immunohistochemical stain is fairly specific for solitary fibrous tumor [30].



**Fig. 5.15** Solitary fibrous tumor with bland ovoid cells in a background of fibrosis

### Differential Diagnosis

- Synovial sarcoma
- Schwannoma
- Spindle cell lipoma

### Comments

1. Given its highly variable morphologic appearance, solitary fibrous tumor has a broad differential diagnosis.
2. Synovial sarcoma can have spindle cells and branching vessels, but is usually negative for CD34.
3. Schwannomas with degenerative changes can exhibit the perivascular hyalinization seen in solitary fibrous tumor. Unlike schwannomas, solitary fibrous tumors are negative for S100.
4. Both spindle cell lipomas and solitary fibrous tumors are positive for CD34; however, spindle cell lipoma will not stain for STAT6.
5. Since solitary fibrous tumors can metastasize, these are overall considered to be intermediate in behavior. However, predicting which tumors will result in metastasis has been problematic.
6. A recently published stratification model utilizes age, size, and mitosis to calculate risk for metastasis and disease free survival.

7. Using this algorithm, tumors considered low-risk have no risk for metastasis and no disease-specific mortality. Patients with intermediate-risk have a 10-year metastasis-free and disease-specific survival rates of 64% and 93%, respectively. High-risk lesions inevitably result in metastasis and disease-specific mortality after 10 years [31].
8. Complete excision is the standard treatment for solitary fibrous tumors.

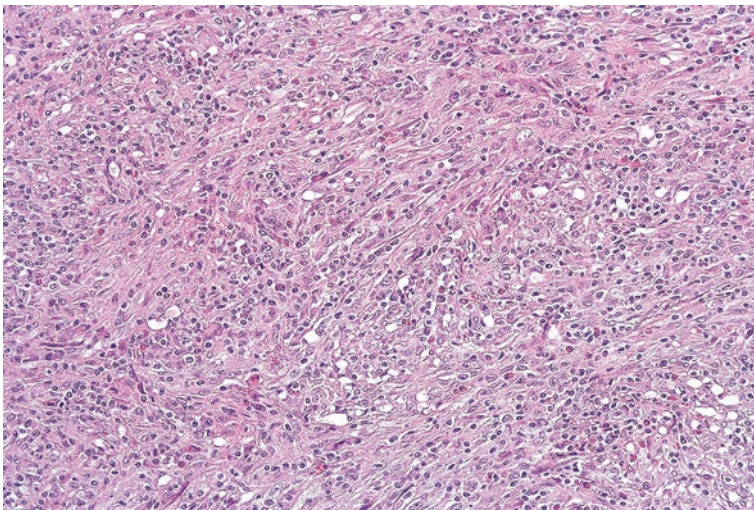
---

## 5.9 Inflammatory Myofibroblastic Tumor

Inflammatory myofibroblastic tumor is a soft tissue neoplasm that often arises in children and young adults in the abdomen, pelvis, or retroperitoneum [32]. Patients with these tumors can rarely present with constitutional symptoms of fever or weight loss, increased erythrocyte sedimentation rate, thrombocytosis, or microcytic anemia [33].

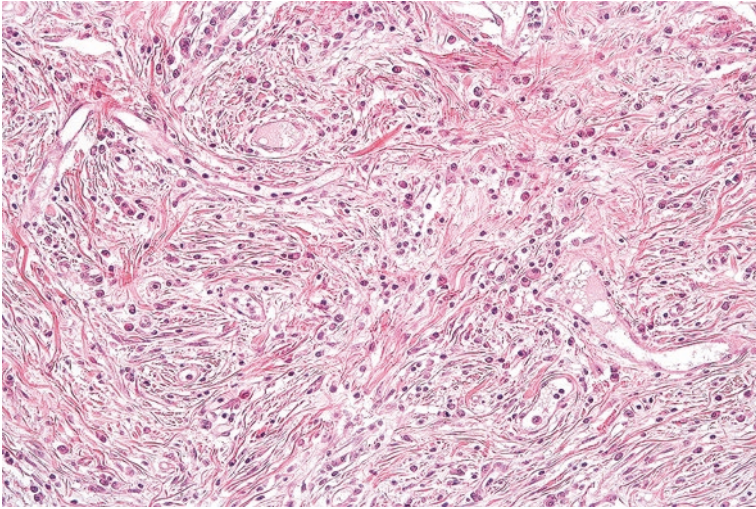
### Pathology

Microscopically, these neoplasms are composed of haphazardly arranged bland-appearing spindle cells and an associated inflammatory cell population (Fig. 5.16). Other areas of inflammatory myofibroblastic tumors can be less cellular and demonstrate increased collagen deposition (Fig. 5.17) [32].



**Fig. 5.16** Inflammatory myofibroblastic tumor with a haphazard arrangement of spindle cells and associated chronic inflammation





**Fig. 5.17** Long-standing inflammatory myofibroblastic tumor with extensive collagen deposition

### Ancillary Studies

- Fifty percent of inflammatory myofibroblastic tumors are positive for ALK immunohistochemical stain and demonstrate clonal rearrangements involving the *ALK* gene (2p23).

### Differential Diagnosis

- Gastrointestinal stromal tumor
- Dedifferentiated liposarcoma
- Desmoid fibromatosis

### Comments

1. Inflammatory myofibroblastic tumor arising in the abdomen can be mistaken for gastrointestinal stromal tumor. However, inflammatory myofibroblastic tumors are negative for a CD117 immunohistochemical stain.
2. Dedifferentiated liposarcomas also arise in the abdomen and can have associated inflammation. If this diagnosis is in question, FISH studies will show inflammatory myofibroblastic tumor to be negative for the *MDM2* gene amplification found in well-differentiated and dedifferentiated liposarcoma.
3. Desmoid fibromatosis can have focal areas of disorganization, but examination of other parts of the tumor will reveal a more organized fascicular pattern of spindle cells.

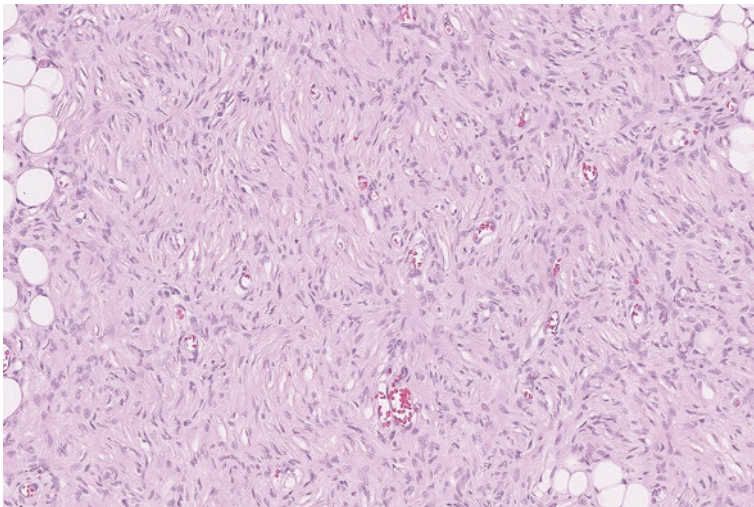
4. Although inflammatory myofibroblastic tumors often recur, incidence of metastasis is less than 5%. A rare variant of inflammatory myofibroblastic tumor with a more epithelioid morphology behaves in a more aggressive fashion [34].
5. Surgical resection is the primary treatment. Adjuvant radiation or chemotherapy is sometimes administered for recurrent lesions. Crizotinib, an ALK inhibitor, can prove helpful for adjuvant treatment.

## 5.10 Dermatofibrosarcoma Protuberans

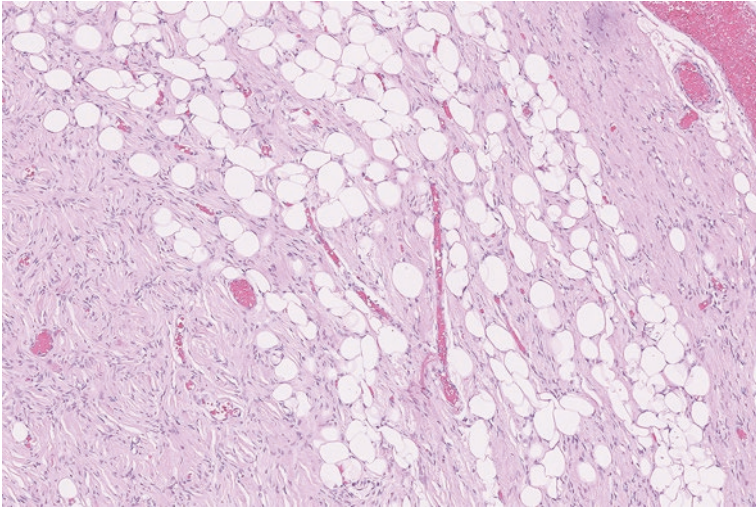
Dermatofibrosarcoma protuberans (DFSP) is a neoplasm that typically arises in young adults, with the peak incidence occurring in the third decade of life. Clinically, this begins as a plaque-like thickening of the skin and steadily progresses to a subcutaneous nodular mass over the course of several years. Frequent sites of involvement include the trunk and proximal upper and lower extremities [35].

### Pathology

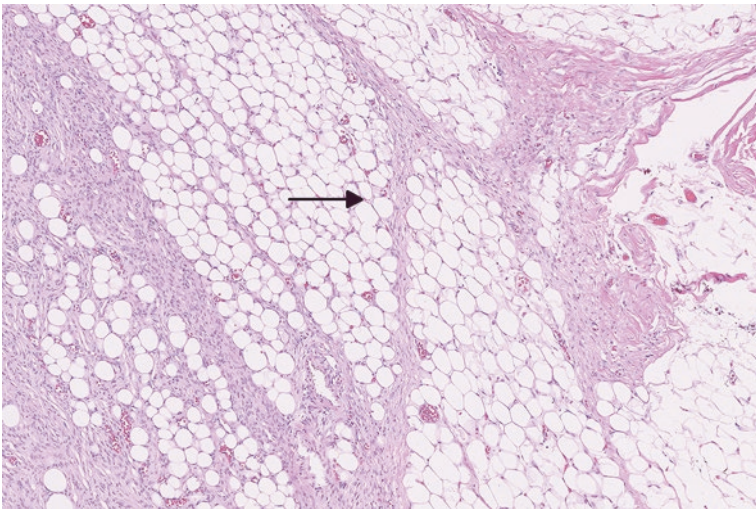
Grossly, these are typically solitary masses that are multinodular and measure several centimeters in size (average of 5.0 cm). Although these are highly infiltrative tumors, they can appear deceptively well circumscribed to the naked eye [35]. Microscopically, dermatofibrosarcoma protuberans is composed of bland-appearing spindled fibroblasts that are arranged in an irregularly whorled or storiform pattern (Fig. 5.18). The tumor is notorious for percolating into underlying subcutaneous adipose tissue (Fig. 5.19) [36]. Additionally, the cells extend along connective tissue septa, making resection particularly difficult (Fig. 5.20).



**Fig. 5.18** Dermatofibrosarcoma protuberans with a whorled, storiform pattern

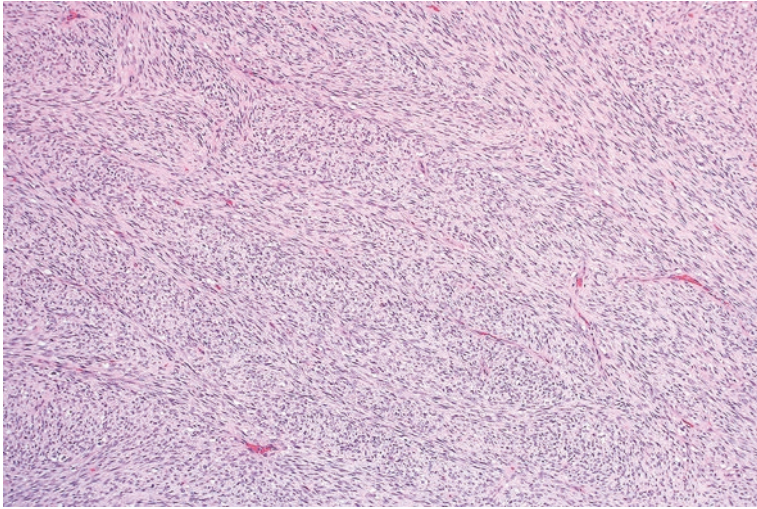


**Fig. 5.19** Dermatofibrosarcoma protuberans entrapping the underlying adipocytes of the subcutaneous tissue



**Fig. 5.20** Dermatofibrosarcoma protuberans extending long tentacles into the surrounding adipose tissue (*arrow*)

Occasionally, a DFSP can have a more aggressive component where the spindle cells organize in a bundled or fascicular arrangement (Fig. 5.21). This variant is referred to as the fibrosarcomatous variant of dermatofibrosarcoma protuberans [37].



**Fig. 5.21** Fibrosarcomatous variant of dermatofibrosarcoma protuberans. The cells have a more organized and bundled arrangement

### Ancillary Studies

- Dermatofibrosarcoma protuberans is strongly positive for a CD34 immunohistochemical stain.
- This neoplasm manifests a unique (and diagnostic) fusion of the *COL1A1* and *PDGFB* genes, which can be detected by FISH.

### Differential Diagnosis

- Fibrous histiocytoma (dermatofibroma)

### Comment

1. Unlike dermatofibrosarcoma protuberans, fibrous histiocytoma tends to be limited to the dermis.
2. Assessment for the *COL1A1-PDGFB* fusion gene can be helpful in difficult cases.
3. Treatment is primarily surgical; however, the infiltrative nature of DFSP can sometimes complicate resection. With only conservative excision, these tumors frequently recur (43%) and rarely metastasize.
4. The generous margins provided by a wide excision reduce recurrence to approximately 18%. Mohs micrographic surgery has an average recurrence rate of 0.6% [38].
5. The fibrosarcomatous variant of DFSP has been associated with higher rates of recurrence (58%) and metastasis (15%) in patients that receive conservative excision [39].

6. However, a fibrosarcomatous variant of DFSP that is completely resected by wide excision behaves similarly to conventional DFSP, with almost no reported metastasis [37].

### 5.11 Congenital/Infantile Fibrosarcoma

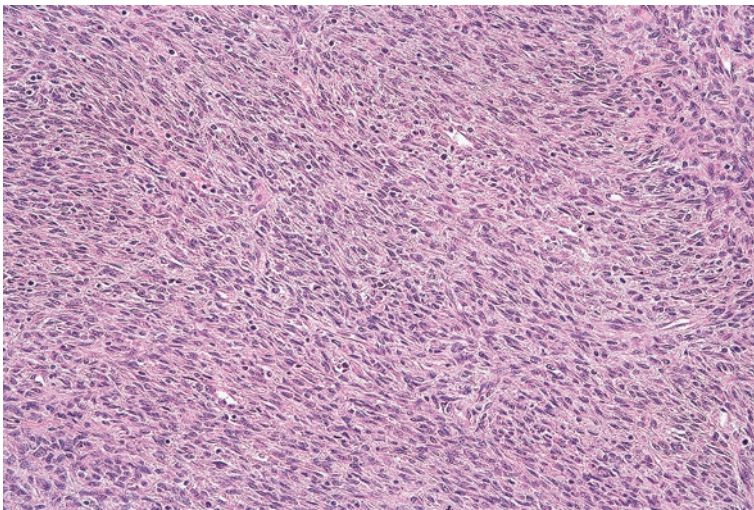
Congenital/infantile fibrosarcoma is a fibroblastic neoplasm that almost always arises in the first year of life. In fact, approximately a third of these tumors will be present at the time of birth. Frequent sites of involvement include the superficial and deep soft tissues of the extremities, trunk, and head and neck. These lesions can measure up to 20 cm in greatest dimension [40, 41].

#### Pathology

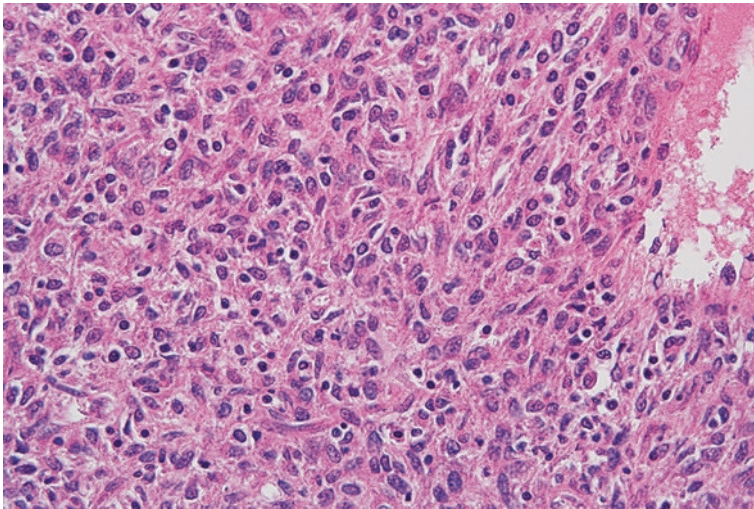
Grossly, infantile fibrosarcoma appears as a poorly circumscribed fleshy mass that can contain hemorrhage or necrosis. The microscopic sections show highly cellular intersecting bundles of ovoid to spindle cells (Fig. 5.22). Substantial mitoses, chronic inflammation, or necrosis can be present (Fig. 5.23). Varying amounts of associated branching vessels and hyalinized fibrosis can be seen [9].

#### Ancillary Studies

- Infantile fibrosarcoma exhibits a t(12;15) chromosomal translocation which results in the formation of an *ETV6-NTRK3* fusion transcript [42].
- This fusion transcript can also be found in many other malignancies including congenital mesoblastic nephroma, acute myeloid leukemia, secretory carcinoma of the breast, and radiation association papillary thyroid carcinoma [43].



**Fig. 5.22** Infantile fibrosarcoma with intersecting bundles of spindle cells arranged in a fascicular pattern



**Fig. 5.23** Infantile fibrosarcoma with elongated nuclei showing scattered mitoses

### Differential Diagnosis

- Spindle cell rhabdomyosarcoma
- Infantile fibromatosis

### Comment

- Although spindle cell rhabdomyosarcoma occurs in young patients and can demonstrate a fascicular pattern, these tumors will be positive for desmin and MyoD1 immunohistochemical stains.
- Congenital/infantile fibrosarcoma is typically more organized and has higher cellularity than fibromatosis. The finding of an *ETV6-NTRK3* fusion transcript distinguishes infantile fibrosarcoma from fibromatosis.
- Despite its intimidating appearance, infantile fibrosarcoma only occasionally (17%) recurs and rarely metastasizes. The 5-year survival is 84% [1, 9].
- Wide local excision is the primary treatment for congenital/infantile fibrosarcoma.

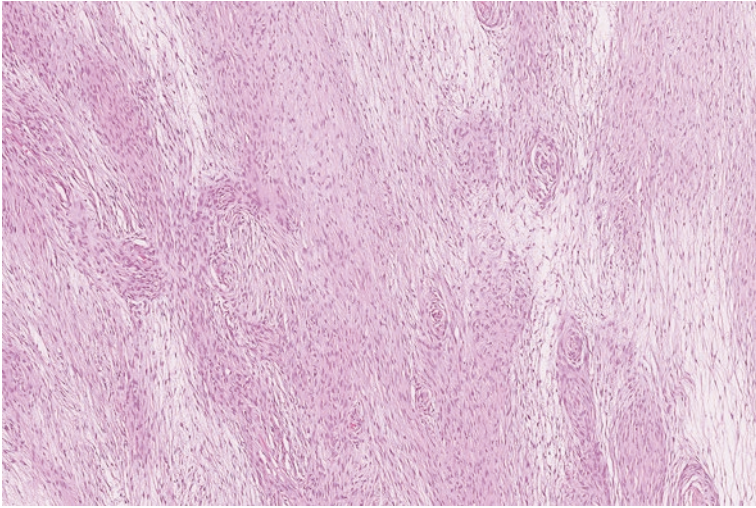
---

## 5.12 Low-Grade Fibromyxoid Sarcoma

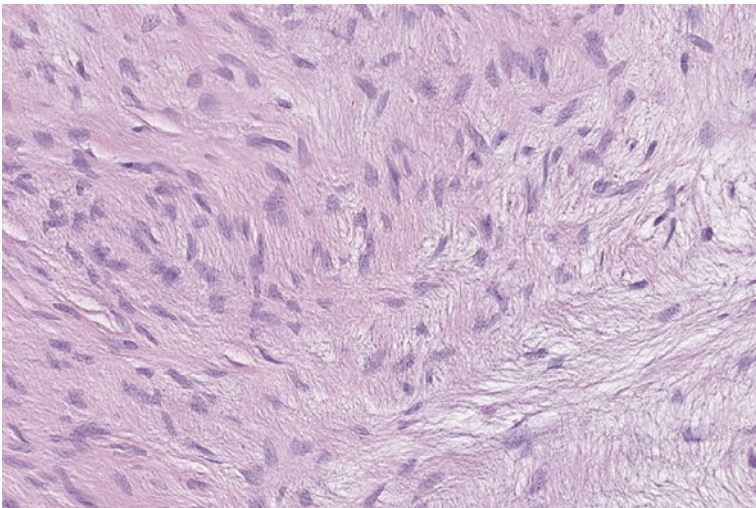
Low-grade fibromyxoid sarcoma is a malignancy that often arises in the deep soft tissue of the trunk and extremities. These tumors occur over a broad age range (median age of 34 years), and pediatric patients are occasionally affected. Typically, low-grade fibromyxoid sarcoma arises as a slowly growing mass that eventually reaches an average size of 8–10 cm [1, 44].

**Pathology**

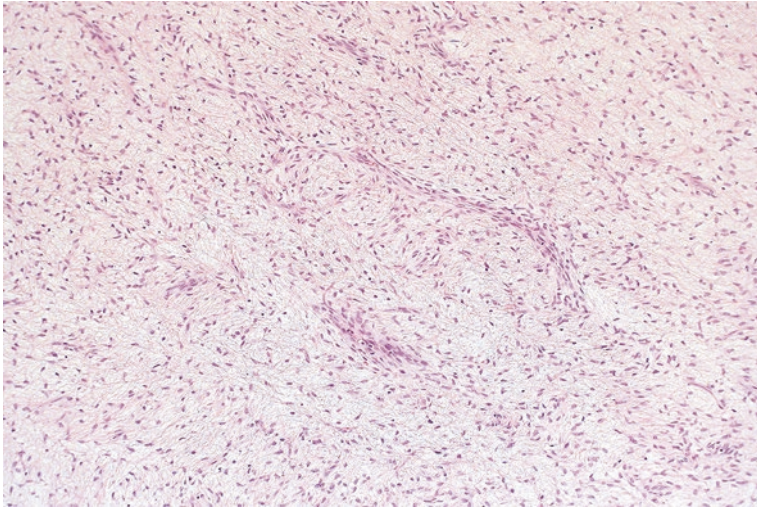
On gross examination these tumors appear well circumscribed. Microscopically, they are composed of bland-appearing fibroblasts embedded in variably myxomatous and collagenous stroma (Figs. 5.24 and 5.25). A delicate branching capillary network is present (Fig. 5.26) [45].



**Fig. 5.24** Low-grade fibromyxoid sarcoma with an alternating hyalinized and myxoid background



**Fig. 5.25** Fibroblastic cells of low-grade fibromyxoid sarcoma are deceptively bland in appearance



**Fig. 5.26** Delicate branching network of low-grade fibromyxoid sarcoma

### Ancillary Studies

- A MUC4 immunohistochemical stain is positive in low-grade fibromyxoid sarcoma [46].
- This tumor has a unique translocation of t(7;16) that results in a *FUS-CREB3L2* fusion transcript [47].
- Rare tumors will exhibit a variant t(11;16) translocation that produces a *FUS-CREB3L1* fusion transcript [48].

### Differential Diagnosis

- Myxofibrosarcoma
- Perineurioma
- Deep fibromatosis

### Comment

- Tumor cells in myxofibrosarcoma exhibit more nuclear atypia and hyperchromasia than seen in low-grade fibromyxoid sarcoma.
- The deceptively bland appearance of the cells in low-grade fibromyxoid sarcoma often causes it to be mistaken for less aggressive lesions such as deep fibromatosis or a perineurioma.
- The finding of a positive MUC4 stain or *FUS-CREB3L2* fusion transcript helps differentiate low-grade fibromyxoid sarcoma from alternative diagnoses.
- Although low-grade fibromyxoid sarcoma is clinically indolent in the short term, recurrence and metastasis can occur decades after resection of the primary lesion.



- In a study with long-term follow-up, 64% of patients had local recurrence and 45% of patients experienced metastasis [49].
- Standard treatment consists of wide excision and close clinical follow-up.

### 5.13 Myxofibrosarcoma

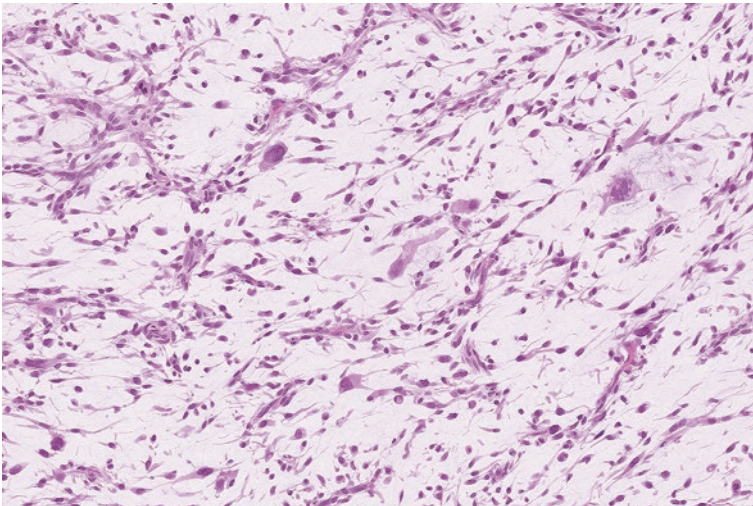
Myxofibrosarcoma frequently manifests in the proximal extremities of adults with a peak incidence in the seventh decade of life [50]. These tumors are often relatively superficial, with two thirds arising in the dermis or subcutaneous tissue [51]. Although myxofibrosarcomas clinically have a nodular appearance, they are particularly infiltrative in nature and generous margins are often taken to ensure complete resection.

#### Pathology

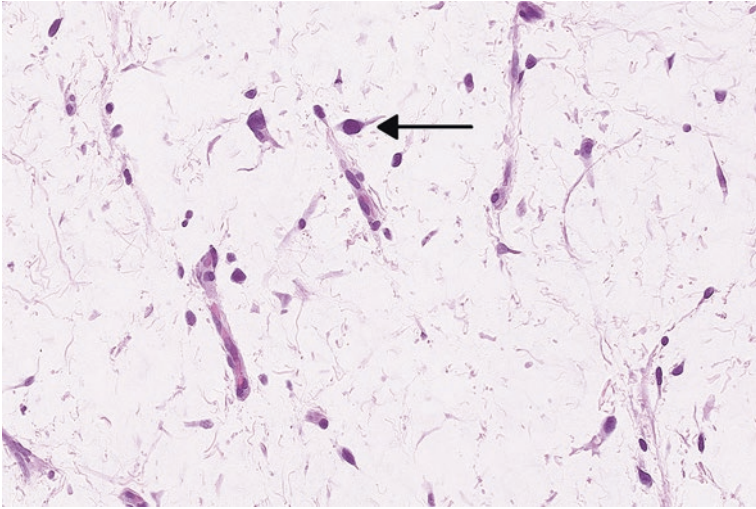
The tumor grossly demonstrates a mucoid appearance. Histologically, myxofibrosarcomas contain myxoid material that surrounds a conspicuous network of curved vessels and mesenchymal cells with nuclear hyperchromasia (Figs. 5.27 and 5.28). Occasional cells can have a vacuolated cytoplasm that mimics immature fat cells. In higher-grade tumors, the neoplastic cells are more prevalent and aggregate in a clustered or sheet-like arrangement (Fig. 5.29). In the past, these high-grade myxofibrosarcomas have been referred to as “myxoid malignant fibrous histiocytoma” [51, 52].

#### Ancillary Studies

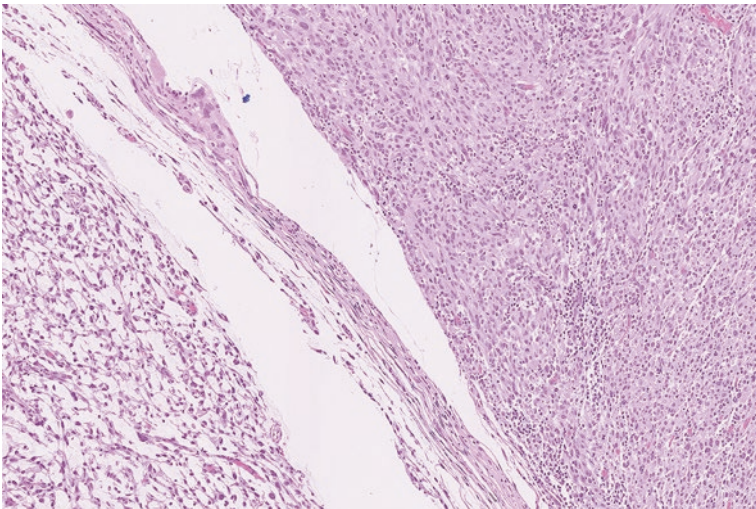
- Immunohistochemical stains or genetics studies are not particularly helpful in confirming the diagnosis.



**Fig. 5.27** Myxofibrosarcoma with myxoid background and curvilinear vessels



**Fig. 5.28** Cells containing enlarged, hyperchromatic, and highly atypical nuclei in a myxofibrosarcoma (*arrow*)



**Fig. 5.29** Transition to high-grade myxofibrosarcoma. The high-grade component demonstrates sheets of anaplastic tumor cells with little to no myxoid background

### Differential Diagnosis

- Low-grade fibromyxoid sarcoma
- Myxoid liposarcoma
- Intramuscular myxoma

## Comment

- Myxofibrosarcoma contains cells with nuclear atypia and hyperchromasia that are not usually seen in myxoma, low-grade fibromyxoid sarcoma, or myxoid liposarcoma.
- Myxofibrosarcomas frequently recur with an overall rate of recurrence of 50–60% [12].
- The metastatic potential of these tumors is highly dependent on the histologic grade. The overall metastatic rate of myxofibrosarcoma is 35%, but grade 1 tumors were found not to metastasize [53].
- Tumors measuring greater than 5 cm or containing less than 75% myxoid component or necrosis, are at increased risk for disease-specific mortality [54].
- Complete surgical excision with a clear margin of at least 2 cm or an intact anatomic barrier is the primary treatment for myxofibrosarcoma. If the margins are involved or close, then adjuvant radiation therapy can be administered [12].

---

## 5.14 Adult-Type Fibrosarcoma

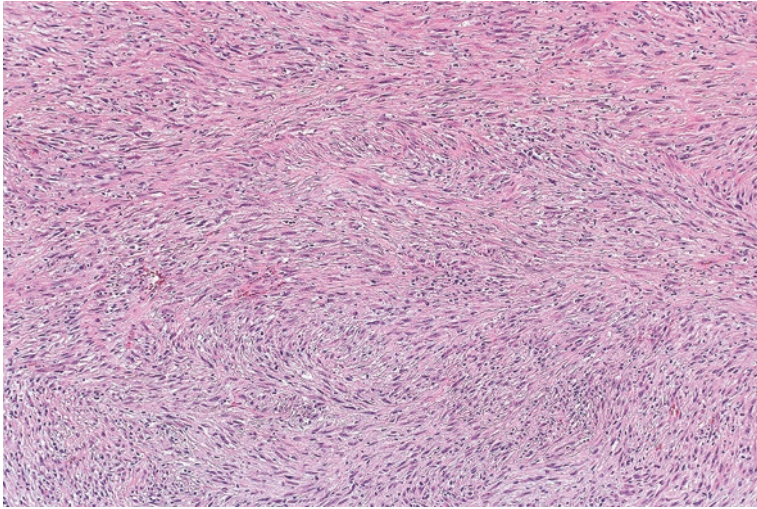
Several decades ago, adult-type fibrosarcoma was one of the most frequently diagnosed soft tissue sarcomas; however, pathologists have since recognized that other soft tissue neoplasms can manifest a fibrosarcoma-like morphology, such as fibrosarcomatous variant of dermatofibrosarcoma protuberans. As classification has become much more detailed, the diagnosis of adult fibrosarcoma has become increasingly rare [55]. These tumors often present as a deep mass in the lower extremities in association with the fascia or skeletal muscle. They typically occur in older adults [56].

### Pathology

Adult-type fibrosarcomas are composed of organized intersecting bundles of spindle cells with nuclear hyperchromasia and some associated collagen (Fig. 5.30). Importantly, other features of more specific variants of fibrosarcoma (e.g., myxofibrosarcoma, fibromyxoid sarcoma) are not present [55].

### Differential Diagnosis

- Low-grade fibromyxoid sarcoma or myxofibrosarcoma
- Deep fibromatosis
- Malignant peripheral nerve sheath tumor
- Monophasic synovial sarcoma
- Fibrosarcomatous variant of dermatofibrosarcoma protuberans
- Undifferentiated pleomorphic sarcoma



**Fig. 5.30** Spindle cells arranged in a fascicular architecture in an adult-type fibrosarcoma

### Comment

- A diagnosis of adult-type fibrosarcoma should be made only after all other possibilities have been excluded.
- Careful examination and appropriate cytogenetic studies and immunohistochemical stains are needed to consider these alternatives [10].
- Fifty percent of patients die from recurrent or metastatic disease [55].

### Facts to Remember

1. Nodular fasciitis is a benign lesion that can be clinically concerning due to its initial rapid enlargement.
2. Recognition of Gardner-associated fibroma is critical as this can initiate timely screening for familial adenomatous polyposis.
3. Although not metastatic, deep fibromatosis is a locally aggressive soft tissue neoplasm that can infiltrate vital structures. Recurrence can occur, particularly in patients with Gardner syndrome.
4. Solitary fibrous tumor is a fibrous neoplasm which can arise in numerous locations and can metastasize. Risk factors for metastasis include older age, size of tumor, and mitosis.
5. Dermatofibrosarcoma protuberans is a highly infiltrative lesion that can recur and rarely metastasize. However, wide excision with generous margins is often curative.
6. Low-grade fibromyxoid sarcoma is a deceptively bland appearing lesion under the microscope, but is capable of metastasis many years after diagnosis. Close clinical follow-up is warranted.

7. Myxofibrosarcoma is a soft tissue sarcoma that usually arises in the subcutaneous tissue of older adults. Approximately a third of these tumors metastasize.
8. Adult-type fibrosarcoma is now a rare entity. Diagnosis should only be made when other possibilities are excluded.

---

## References

1. Goldblum J, Weiss S, Folpe AL, editors. Enzinger and weiss's soft tissue tumors. 6th ed. Philadelphia: Elsevier; 2013.
2. Allen PW. Nodular fasciitis. *Pathology*. 1972;4(1):9–26.
3. Bernstein KE, Lattes R. Nodular (pseudosarcomatous) fasciitis, a nonrecurrent lesion: clinicopathologic study of 134 cases. *Cancer*. 1982;49(8):1668–78.
4. Shimizu S, Hashimoto H, Enjoji M. Nodular fasciitis: an analysis of 250 patients. *Pathology*. 1984;16(2):161–6.
5. Chung EB, Enzinger FM. Proliferative fasciitis. *Cancer*. 1975;36(4):1450–8.
6. Montgomery EA, Meis JM, Mitchell MS, Enzinger FM. Atypical decubital fibroplasia. A distinctive fibroblastic pseudotumor occurring in debilitated patients. *Am J Surg Pathol*. 1992;16(7):708–15.
7. Liegl B, Fletcher CD. Ischemic fasciitis: analysis of 44 cases indicating an inconsistent association with immobility or debilitation. *Am J Surg Pathol*. 2008;32(10):1546–52.
8. Chung EB, Enzinger FM. Fibroma of tendon sheath. *Cancer*. 1979;44(5):1945–54.
9. Fletcher CDM, Bridge JA, Hogendoorn PC, Mertens F, editors. *Pathology and genetics of tumours of soft tissue and bone*. 4th ed. Lyon: World Health Organization; 2013.
10. Goldblum JR, Folpe AL, Weiss SW, editors. Enzinger and weiss's soft tissue tumors. 6th ed. Philadelphia: Saunders; 2013.
11. Pulitzer DR, Martin PC, Reed RJ. Fibroma of tendon sheath. A clinicopathologic study of 32 cases. *Am J Surg Pathol*. 1989;13(6):472–9.
12. Hornick JL, editor. *Practical soft tissue pathology: a diagnostic approach*. Philadelphia: Saunders; 2013.
13. Michal M, Fetsch JF, Hes O, Miettinen M. Nuchal-type fibroma: a clinicopathologic study of 52 cases. *Cancer*. 1999;85(1):156–63.
14. Balachandran K, Allen PW, MacCormac LB. Nuchal fibroma. A clinicopathological study of nine cases. *Am J Surg Pathol*. 1995;19(3):313–7.
15. Coffin CM, Hornick JL, Zhou H, Fletcher CD. Gardner fibroma: a clinicopathologic and immunohistochemical analysis of 45 patients with 57 fibromas. *Am J Surg Pathol*. 2007;31(3):410–6.
16. Wehrli BM, Weiss SW, Yandow S, Coffin CM. Gardner-associated fibromas (GAF) in young patients: a distinct fibrous lesion that identifies unsuspected Gardner syndrome and risk for fibromatosis. *Am J Surg Pathol*. 2001;25(5):645–51.
17. Carlson JW, Fletcher CD. Immunohistochemistry for beta-catenin in the differential diagnosis of spindle cell lesions: analysis of a series and review of the literature. *Histopathology*. 2007;51(4):509–14.
18. Hayes AJ, Alexander N, Clark MA, Thomas JM. Elastofibroma: a rare soft tissue tumour with a pathognomonic anatomical location and clinical symptom. *Eur J Surg Oncol*. 2004;30(4):450–3.
19. Allen PW. The fibromatoses: a clinicopathologic classification based on 140 cases. *Am J Surg Pathol*. 1977;1(3):255–70.
20. Noble J, Arafa M, Royle SG, McGeorge G, Crank S. The association between alcohol, hepatic pathology and Dupuytren's disease. *J Hand Surg (Br)*. 1992;17(1):71–4.
21. Arkkila PE, Kantola IM, Viikari JS. Dupuytren's disease: association with chronic diabetic complications. *J Rheumatol*. 1997;24(1):153–9.

22. Stojadinovic A, Hoos A, Karpoff HM, Leung DH, Antonescu CR, Brennan MF, et al. Soft tissue tumors of the abdominal wall: analysis of disease patterns and treatment. *Arch Surg*. 2001;136(1):70–9.
23. Mankin HJ, Hornicek FJ, Springfield DS. Extra-abdominal desmoid tumors: a report of 234 cases. *J Surg Oncol*. 2010;102(5):380–4.
24. Burke AP, Sobin LH, Shekitka KM, Federspiel BH, Helwig EB. Intra-abdominal fibromatosis. A pathologic analysis of 130 tumors with comparison of clinical subgroups. *Am J Surg Pathol*. 1990;14(4):335–41.
25. Le Guellec S, Soubeyran I, Rochaix P, Filleron T, Neuville A, Hostein I, et al. CTNNB1 mutation analysis is a useful tool for the diagnosis of desmoid tumors: a study of 260 desmoid tumors and 191 potential morphologic mimics. *Mod Pathol*. 2012;25(12):1551–8.
26. Kasper B, Strobel P, Hohenberger P. Desmoid tumors: clinical features and treatment options for advanced disease. *Oncologist*. 2011;16(5):682–93.
27. Miettinen M, editor. *Modern soft tissue pathology: tumors and non-neoplastic conditions*. 1st ed. New York: Cambridge University Press; 2010.
28. Fukasawa Y, Takada A, Tateno M, Sato H, Koizumi M, Tanaka A, et al. Solitary fibrous tumor of the pleura causing recurrent hypoglycemia by secretion of insulin-like growth factor II. *Pathol Int*. 1998;48(1):47–52.
29. Chilosi M, Facchetti F, Dei Tos AP, Lestani M, Morassi ML, Martignoni G, et al. Bcl-2 expression in pleural and extrapleural solitary fibrous tumours. *J Pathol*. 1997;181(4):362–7.
30. Yoshida A, Tsuta K, Ohno M, Yoshida M, Narita Y, Kawai A, et al. STAT6 immunohistochemistry is helpful in the diagnosis of solitary fibrous tumors. *Am J Surg Pathol*. 2014;38(4):552–9.
31. Demicco EG, Park MS, Araujo DM, Fox PS, Bassett RL, Pollock RE, et al. Solitary fibrous tumor: a clinicopathological study of 110 cases and proposed risk assessment model. *Mod Pathol*. 2012;25(9):1298–306.
32. Coffin CM, Hornick JL, Fletcher CD. Inflammatory myofibroblastic tumor: comparison of clinicopathologic, histologic, and immunohistochemical features including ALK expression in atypical and aggressive cases. *Am J Surg Pathol*. 2007;31(4):509–20.
33. Gleason BC, Hornick JL. Inflammatory myofibroblastic tumours: where are we now? *J Clin Pathol*. 2008;61(4):428–37.
34. Marino-Enriquez A, Wang WL, Roy A, Lopez-Terrada D, Lazar AJ, Fletcher CD, et al. Epithelioid inflammatory myofibroblastic sarcoma: an aggressive intra-abdominal variant of inflammatory myofibroblastic tumor with nuclear membrane or perinuclear ALK. *Am J Surg Pathol*. 2011;35(1):135–44.
35. Taylor HB, Helwig EB. Dermatofibrosarcoma protuberans. A study of 115 cases. *Cancer*. 1962;15:717–25.
36. Fletcher CD, Evans BJ, MacArtney JC, Smith N, Wilson Jones E, McKee PH. Dermatofibrosarcoma protuberans: a clinicopathological and immunohistochemical study with a review of the literature. *Histopathology*. 1985;9(9):921–38.
37. Goldblum JR, Reith JD, Weiss SW. Sarcomas arising in dermatofibrosarcoma protuberans: a reappraisal of biologic behavior in eighteen cases treated by wide local excision with extended clinical follow up. *Am J Surg Pathol*. 2000;24(8):1125–30.
38. Gloster Jr HM, Harris KR, Roenigk RK. A comparison between Mohs micrographic surgery and wide surgical excision for the treatment of dermatofibrosarcoma protuberans. *J Am Acad Dermatol*. 1996;35(1):82–7.
39. Mentzel T, Beham A, Katenkamp D, Dei Tos AP, Fletcher CD. Fibrosarcomatous (“high-grade”) dermatofibrosarcoma protuberans: clinicopathologic and immunohistochemical study of a series of 41 cases with emphasis on prognostic significance. *Am J Surg Pathol*. 1998;22(5):576–87.
40. Chung EB, Enzinger FM. Infantile fibrosarcoma. *Cancer*. 1976;38(2):729–39.
41. Schofield DE, Fletcher JA, Grier HE, Yunis EJ. Fibrosarcoma in infants and children. Application of new techniques. *Am J Surg Pathol*. 1994;18(1):14–24.

42. Rubin BP, Chen CJ, Morgan TW, Xiao S, Grier HE, Kozakewich HP, et al. Congenital mesoblastic nephroma t(12;15) is associated with ETV6-NTRK3 gene fusion: cytogenetic and molecular relationship to congenital (infantile) fibrosarcoma. *Am J Pathol.* 1998;153(5):1451–8.
43. Leeman-Neill RJ, Kelly LM, Liu P, Brenner AV, Little MP, Bogdanova TI, et al. ETV6-NTRK3 is a common chromosomal rearrangement in radiation-associated thyroid cancer. *Cancer.* 2014;120(6):799–807.
44. Folpe AL, Lane KL, Paull G, Weiss SW. Low-grade fibromyxoid sarcoma and hyalinizing spindle cell tumor with giant rosettes: a clinicopathologic study of 73 cases supporting their identity and assessing the impact of high-grade areas. *Am J Surg Pathol.* 2000;24(10):1353–60.
45. Evans HL. Low-grade fibromyxoid sarcoma. A report of two metastasizing neoplasms having a deceptively benign appearance. *Am J Clin Pathol.* 1987;88(5):615–9.
46. Doyle LA, Moller E, Dal Cin P, Fletcher CD, Mertens F, Hornick JL. MUC4 is a highly sensitive and specific marker for low-grade fibromyxoid sarcoma. *Am J Surg Pathol.* 2011;35(5):733–41.
47. Matsuyama A, Hisaoka M, Shimajiri S, Hashimoto H. DNA-based polymerase chain reaction for detecting FUS-CREB3L2 in low-grade fibromyxoid sarcoma using formalin-fixed, paraffin-embedded tissue specimens. *Diagn Mol Pathol.* 2008;17(4):237–40.
48. Mertens F, Fletcher CD, Antonescu CR, Coindre JM, Coicchia M, Domanski HA, et al. Clinicopathologic and molecular genetic characterization of low-grade fibromyxoid sarcoma, and cloning of a novel FUS/CREB3L1 fusion gene. *Lab Invest.* 2005;85(3):408–15.
49. Evans HL. Low-grade fibromyxoid sarcoma: a clinicopathologic study of 33 cases with long-term follow-up. *Am J Surg Pathol.* 2011;35(10):1450–62.
50. Weiss SW, Enzinger FM. Myxoid variant of malignant fibrous histiocytoma. *Cancer.* 1977;39(4):1672–85.
51. Mentzel T, Calonje E, Wadden C, Camplejohn RS, Beham A, Smith MA, et al. Myxofibrosarcoma. Clinicopathologic analysis of 75 cases with emphasis on the low-grade variant. *Am J Surg Pathol.* 1996;20(4):391–405.
52. Nascimento AF, Bertoni F, Fletcher CD. Epithelioid variant of myxofibrosarcoma: expanding the clinicomorphologic spectrum of myxofibrosarcoma in a series of 17 cases. *Am J Surg Pathol.* 2007;31(1):99–105.
53. Merck C, Angervall L, Kindblom LG, Oden A. Myxofibrosarcoma. A malignant soft tissue tumor of fibroblastic-histiocytic origin. A clinicopathologic and prognostic study of 110 cases using multivariate analysis. *Acta Pathol Microbiol Immunol Scand Suppl.* 1983;282:1–40.
54. Huang HY, Lal P, Qin J, Brennan MF, Antonescu CR. Low-grade myxofibrosarcoma: a clinicopathologic analysis of 49 cases treated at a single institution with simultaneous assessment of the efficacy of 3-tier and 4-tier grading systems. *Hum Pathol.* 2004;35(5):612–21.
55. Bahrami A, Folpe AL. Adult-type fibrosarcoma: a reevaluation of 163 putative cases diagnosed at a single institution over a 48-year period. *Am J Surg Pathol.* 2010;34(10):1504–13.
56. Hansen T, Katenkamp K, Brodhun M, Katenkamp D. Low-grade fibrosarcoma – report on 39 not otherwise specified cases and comparison with defined low-grade fibrosarcoma types. *Histopathology.* 2006;49(2):152–60.

---

## 6.1 Fibrous Histiocytoma

Fibrous histiocytoma, otherwise referred to as dermatofibroma, typically arises as a skin lesion in the extremities of adults between the second and fourth decades of life [2]. These clinically present as elevated and sometimes pigmented lesions that are usually less than 1 cm in diameter [3]. Approximately a third of affected patients can have multiple lesions, which have been reported to sometimes occur in patients who are immunosuppressed [4]. Rarely, benign fibrous histiocytomas can present as deeper lesions in the subcutaneous or soft tissue that are several centimeters in size [5]. These deep fibrous histiocytomas have been noted to occur at any age [6].

### Pathology

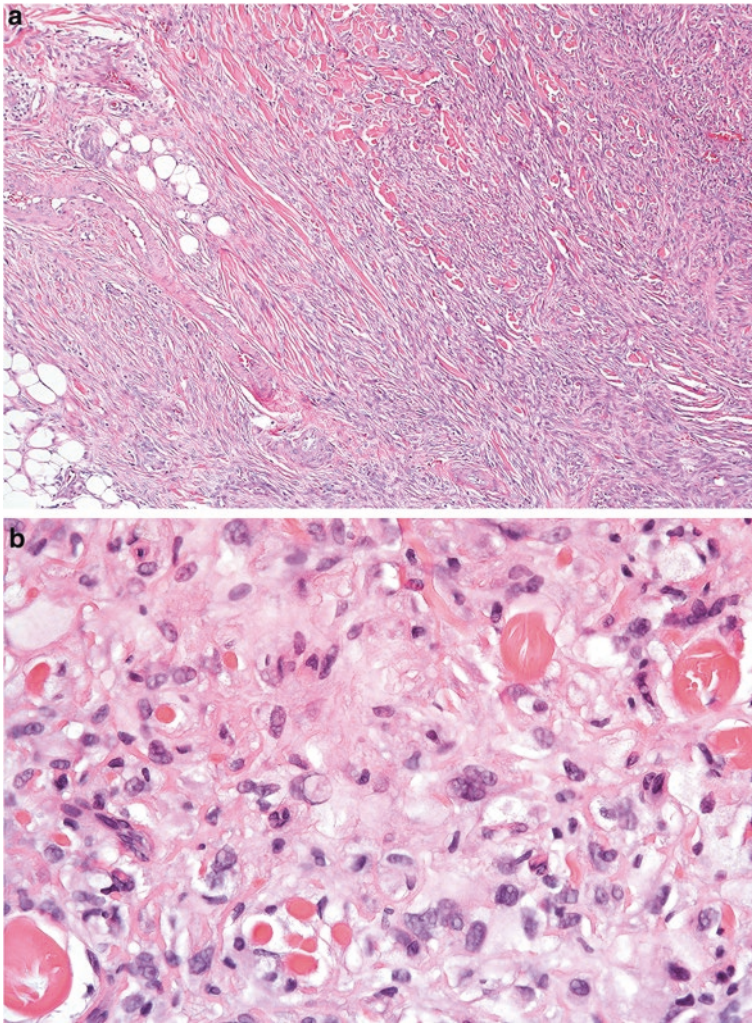
Cutaneous fibrous histiocytomas are usually centered in the dermis and are composed of haphazardly arranged cells with fibrous and histiocytic features that percolate between dense sclerotic collagen fibers (Figs. 6.2 and 6.3). Scattered foamy histiocytes and multinucleated giant cells can be identified. There is typically only limited extension into the underlying subcutaneous adipose tissue [1].

The less frequent deep fibrous histiocytomas are more circumscribed. Microscopically, these neoplasms are typically cellular and can exhibit a more organized fascicular arrangement. Prominent branching vessels, similar to solitary fibrous tumor, can be identified (Fig. 6.4) [6].

### Histologic Variants

- Cellular fibrous histiocytoma—The cells in cellular fibrous histiocytoma show increased cellularity with a more organized fascicular arrangement (Fig. 6.5) [7].
- Aneurysmal fibrous histiocytoma—This variant of fibrous histiocytoma has central blood-filled spaces with associated hemosiderin deposition (Fig. 6.6) [8].





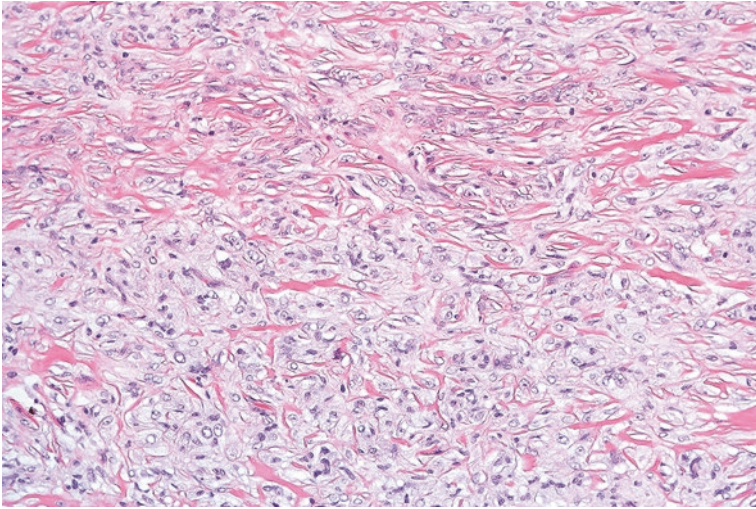
**Fig. 6.1** (a) Spindle fibrous-like cells in a fibrous histiocytoma. (b) Histiocytic-appearing cells in a fibrous histiocytoma

### Ancillary Studies

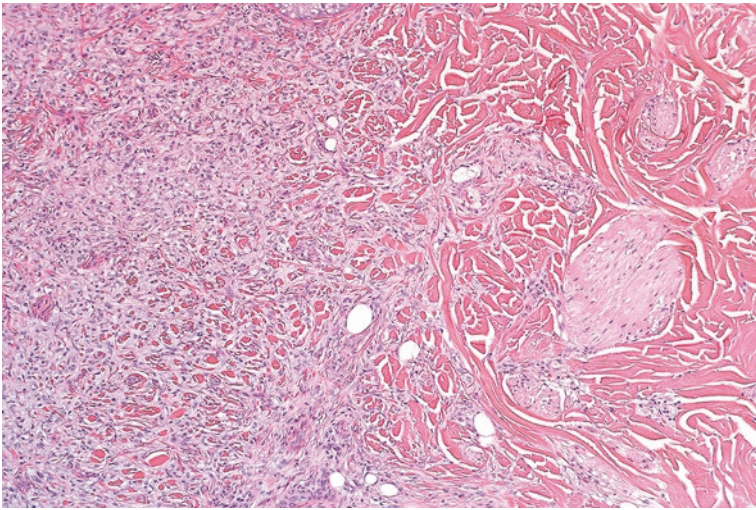
- Although neither sensitive nor specific, fibrous histiocytomas are often positive for Factor XIIIa and lack significant staining for CD34.

### Differential Diagnosis

- Dermatofibrosarcoma protuberans
- Leiomyoma
- Neurofibroma



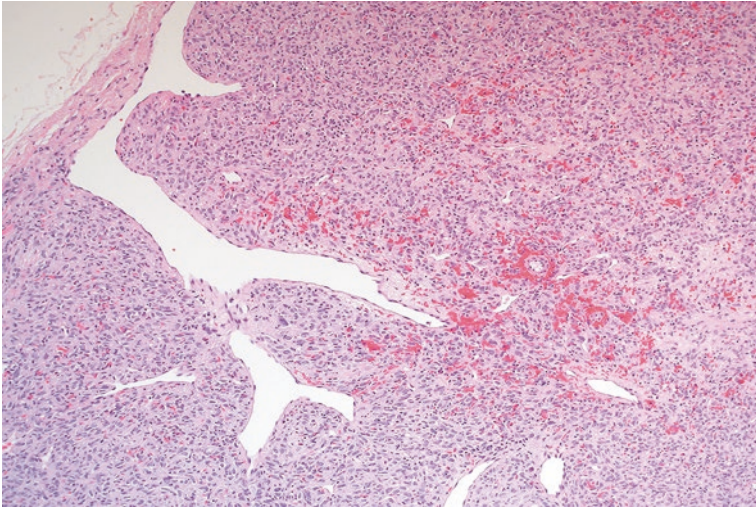
**Fig. 6.2** Cutaneous fibrous histiocytoma containing cells with a fibrohistiocytic appearance



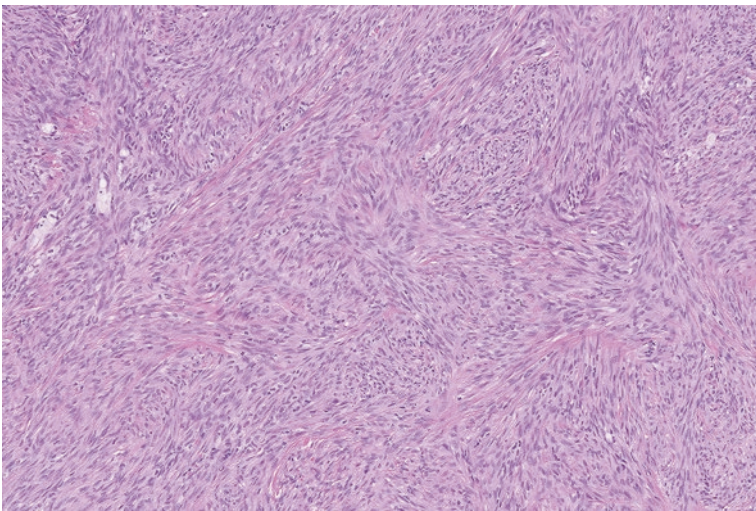
**Fig. 6.3** At the periphery of this fibrous histiocytoma, the cells percolate in between dense collagen fibers

### Comments

1. Fibrous histiocytoma can sometimes be difficult to distinguish from dermatofibrosarcoma protuberans, which is a more aggressive neoplasm.
2. Dermatofibrosarcoma protuberans extensively infiltrates into the underlying subcutaneous adipose tissue.

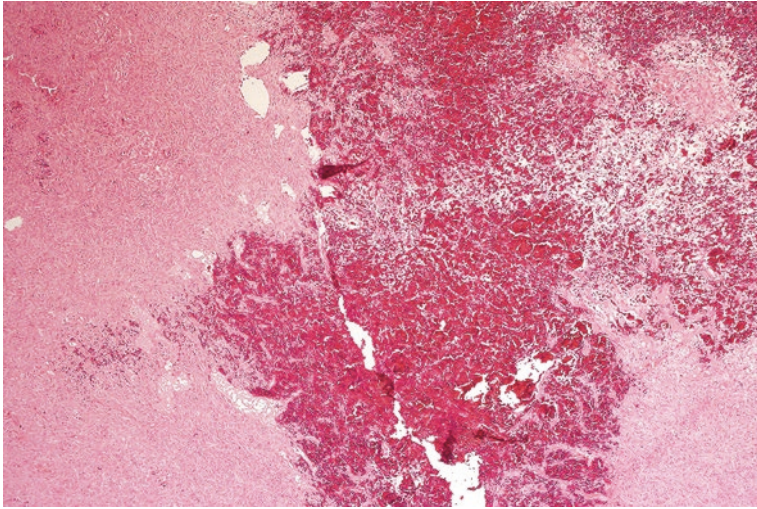


**Fig. 6.4** Deep fibrous histiocytoma with a branching vascular pattern



**Fig. 6.5** Cellular fibrous histiocytoma with fascicles of spindle cells

3. If the morphologic features are ambiguous, immunohistochemical stains for CD34 and Factor XIIIa can be helpful, as dermatofibrosarcoma protuberans is frequently strongly positive for CD34 and negative for Factor XIIIa.
4. FISH studies can exclude dermatofibrosarcoma protuberans by confirming the absence of the *COL1A-PDGFB* fusion transcript.



**Fig. 6.6** Aneurysmal fibrous histiocytoma with cells surrounding a central pool of blood

5. Fibrous histiocytoma can be confused with other dermal-based spindle cell lesions, such as neurofibroma or leiomyoma. Fibrous histiocytoma lacks the S100 or SOX-10 staining found in neurofibroma, or the desmin staining found in leiomyoma.
6. Fibrous histiocytomas are benign neoplasms and are treated with conservative surgical resection. Once excised, they rarely recur [1].
7. Cellular fibrous histiocytoma and aneurysmal fibrous histiocytoma have increased rates (26% and 19%, respectively) of recurrence following excision [7, 8].
8. Deep fibrous histiocytomas recur in approximately 20% of cases.

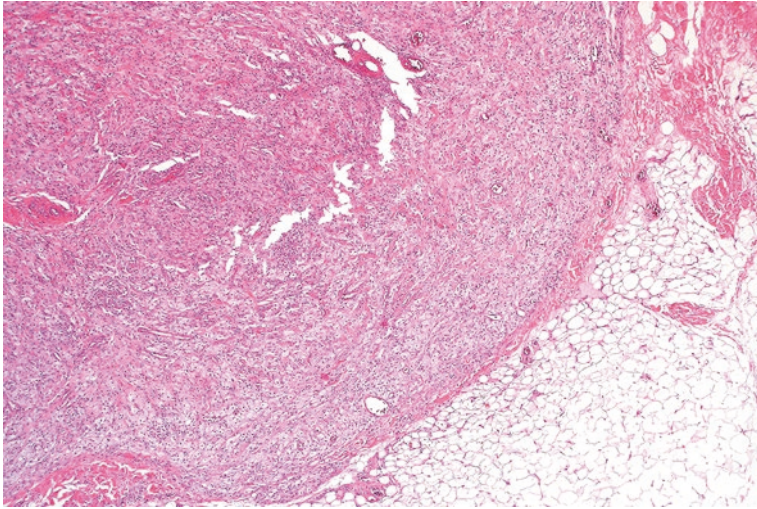
---

## 6.2 Solitary Xanthogranuloma

Solitary xanthogranuloma often occurs in children (sometimes referred to as juvenile xanthogranuloma) but can also be seen in adults. These most commonly present as dermal lesions that frequently arise in the head and neck or trunk as skin papules. In occasional cases (particularly in very young children), patients can have multiple lesions arising on the skin and even organ involvement, such as the eye [9].

### Pathology

Histologically, a solitary xanthogranuloma is composed of a dermal concentration of cells with eosinophilic or foamy cytoplasm that extends up to the epidermis and around associated adnexal structures (Fig. 6.7). Characteristic giant cells with peripherally arranged nuclei (Touton giant cells) are present (Fig. 6.8). Associated inflammatory cells can also be identified [9, 10].



**Fig. 6.7** Solitary xanthogranuloma with foamy histiocytic cells centered in the dermis

### Ancillary Studies

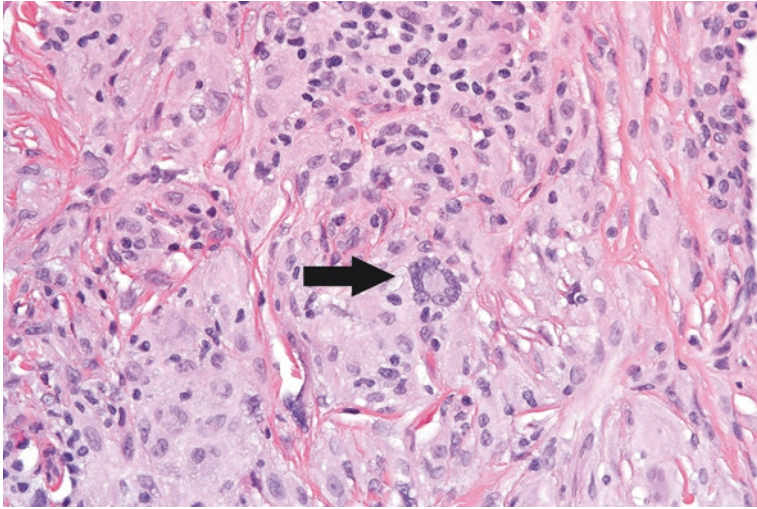
- Although not specific, solitary xanthogranulomas are positive for CD68, a stain that highlights histiocytes.
- They are negative for S100 and CD1a immunohistochemical stains.

### Differential Diagnosis

- Langerhans cell histiocytosis
- Xanthoma
- Fibrous histiocytoma

### Comments

1. Solitary xanthogranuloma can mimic other histiocytic-appearing neoplasms, such as Langerhans cell histiocytosis, xanthoma, or fibrous histiocytoma.
2. Unlike solitary xanthogranuloma, Langerhans cell histiocytosis is positive for S100 and CD1a immunohistochemical stains.
3. Xanthomas contain cells that are consistently foamy in appearance.
4. Fibrous histiocytoma typically contains less foamy cells and Touton giant cells and usually manifests a more prominent population of spindle cells.
5. Dermal solitary xanthogranulomas are benign lesions. Excision is curative in over 80% of cases. Lesions that are incompletely excised often regress [9].



**Fig. 6.8** Touton giant cells (*arrow*) with peripherally arranged nuclei in a solitary xanthogranuloma

6. The prognosis is much more concerning in patients who have systemic involvement by xanthogranulomas, as young patients with organ involvement can die of disease. These patients are often treated with chemotherapy [1, 11].

---

### 6.3 Tenosynovial Giant Cell Tumor, Localized Type

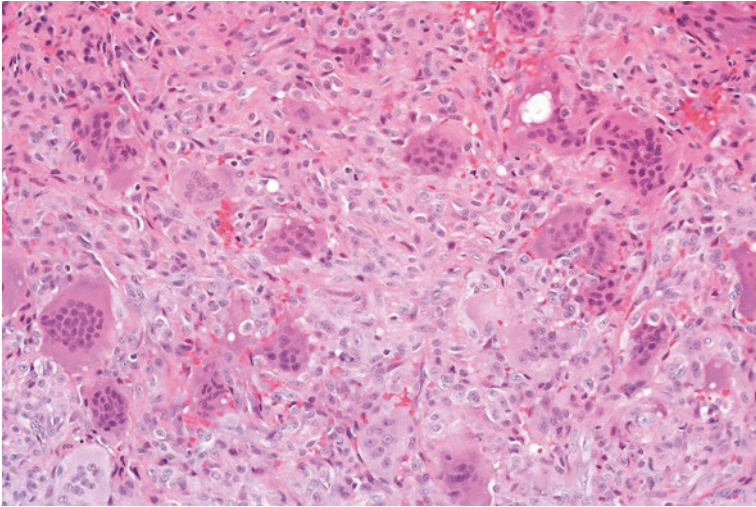
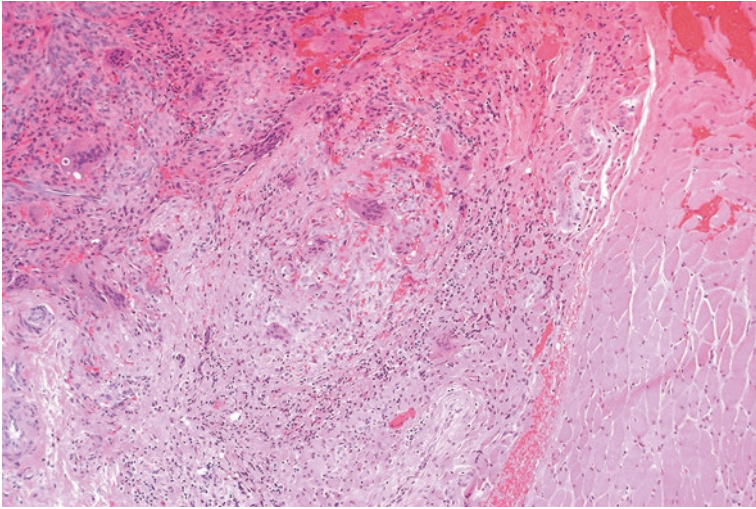
Tenosynovial giant cell tumor, localized type, otherwise known as giant cell tumor of the tendon sheath (localized type) is a well-circumscribed benign lesion that occurs in adults between the fourth and sixth decade of life. These lesions arise in the hands or feet, typically close to the interphalangeal joints or synovium of the tendon sheath [6, 12, 13].

#### Pathology

Grossly, these tumors are well circumscribed and lobulated. The microscopic sections show mononuclear cells with eosinophilic cytoplasm, osteoclast-like giant cells, and foamy histiocytes (Figs. 6.9 and 6.10). Hemosiderin pigment can be identified [12].

#### Ancillary Studies

- The cells can stain for CD68 and desmin, but this is rarely used for diagnosis.



**Figs. 6.9 and 6.10** Multinucleated giant cells and associated mononuclear cells with eosinophilic cytoplasm in tenosynovial giant cell tumor, localized type.

### Differential Diagnosis

- Tenosynovial giant cell tumor, diffuse type
- Fibroma of tendon sheath

### Comments

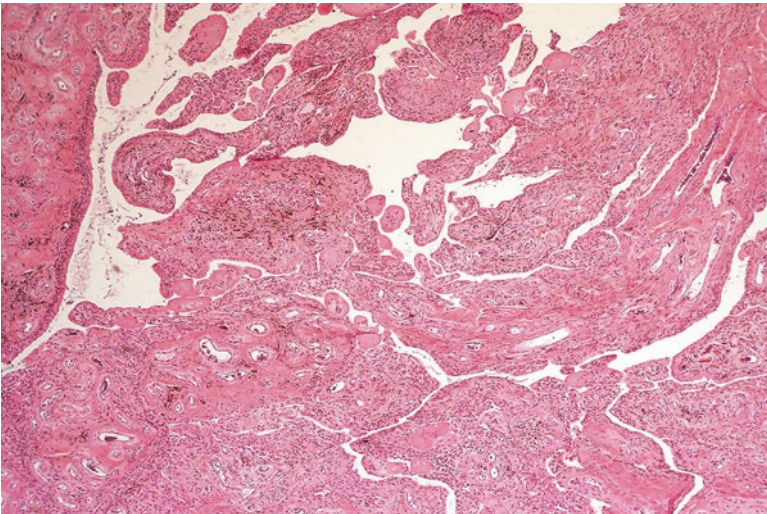
- Tenosynovial giant cell tumor, localized type, is distinguished from tenosynovial giant cell tumor, diffuse type by its well-circumscribed border and lack of infiltration into adjacent tissue.
- These are benign lesions. Approximately 10% will recur following excision [14].

## 6.4 Tenosynovial Giant Cell Tumor, Diffuse Type

Tenosynovial giant cell tumor, diffuse type, otherwise known as pigmented villonodular tenosynovitis (PVNS), often occurs in the articular space of the knee or hip in patients less than 40 years old [15]. These tumors can also arise as predominantly soft tissue masses in the wrist, knee, thigh, and foot [16]. They are more aggressive than their localized counterpart and present with swelling and tenderness of the affected joint [3].

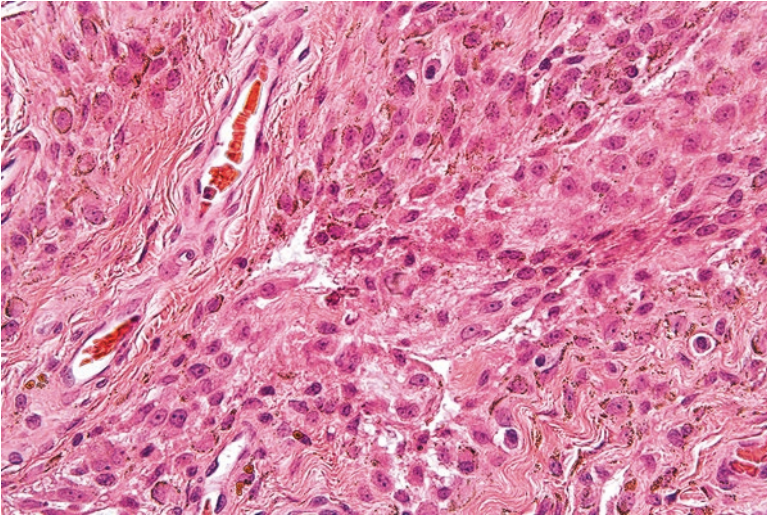
### Pathology

This type of giant cell tumor is not well circumscribed and often has a sheetlike or villous architecture (Fig. 6.11). Similar to tenosynovial giant cell tumor, localized type, the sections show mononuclear cells with eosinophilic cytoplasm and multinucleated giant cells. Hemosiderin deposition, foamy histiocytes, chronic inflammation, and fibrosis can also be present (Fig. 6.12).



**Fig. 6.11** Tenosynovial giant cell tumor, diffuse type, showing a villous-like architecture





**Fig. 6.12** Mononuclear cells with hemosiderin deposition in a tenosynovial giant cell tumor, diffuse type

### Ancillary Studies

- Similar to tenosynovial giant cell tumor, localized type, the cells can be positive for CD68.

### Differential Diagnosis

- Undifferentiated high-grade pleomorphic sarcoma
- Synovial sarcoma
- Tenosynovial giant cell tumor, localized type

### Comments

1. The numerous giant cells in a tenosynovial giant cell tumor, diffuse type, can cause concern for a high-grade sarcoma such as undifferentiated pleomorphic sarcoma. Tenosynovial giant cell tumor typically does not contain the nuclear atypia seen in these high-grade malignancies.
2. The intimate association of tenosynovial giant cell tumor with residual synovium in a joint can mimic a synovial sarcoma. However, synovial sarcoma would demonstrate positivity with cytokeratin or TLE-1 immunohistochemical stains.
3. Clinically, the localized type of tenosynovial giant cell tumor is more circumscribed and usually involves the smaller joints of the hands and feet.

4. Tenosynovial giant cell tumor, diffuse type, can recur in 20–60% of cases.
5. The primary treatment is complete surgical excision, as incompletely resected tumors are more likely to recur. Synovectomy is often performed for intra-articular tumors and wide excision is typically performed for extra-articular lesions [3, 13].

### Facts to Remember

1. Fibrous histiocytoma is typically a benign cutaneous neoplasm which is composed of fibrous and histiocytic cells. Cellular and aneurysmal fibrous histiocytoma variants have a higher incidence of recurrence.
2. Solitary xanthogranuloma is typically a benign dermal lesion which can affect both children and adults. Patients with systemic solitary xanthogranulomas with organ involvement have a poorer prognosis and may require systemic chemotherapy.
3. Tenosynovial giant cell tumor, localized type, is a benign neoplasm that primarily affects the tendons of the hands and feet. Only a limited number of these neoplasms will recur.
4. Tenosynovial giant cell tumor, diffuse type, can be intra-articular or extra-articular. Intra-articular lesions usually arise in spaces of the larger joints, such as the knees and hips. Recurrence in these tumors is more frequent, and the focus should be on complete excision.

---

### References

1. Goldblum J, Weiss S, Folpe AL, editors. *Enzinger and Weiss's soft tissue tumors*. 6th ed. Philadelphia: Elsevier; 2013.
2. Gonzalez S, Duarte I. Benign fibrous histiocytoma of the skin. A morphologic study of 290 cases. *Pathol Res Pract*. 1982;174(4):379–91.
3. Hornick JL, editor. *Practical soft tissue pathology: a diagnostic approach*. Philadelphia: Saunders; 2013.
4. Newman DM, Walter JB. Multiple dermatofibromas in patients with systemic lupus erythematosus on immunosuppressive therapy. *N Engl J Med*. 1973;289(16):842–3.
5. Gleason BC, Fletcher CD. Deep “benign” fibrous histiocytoma: clinicopathologic analysis of 69 cases of a rare tumor indicating occasional metastatic potential. *Am J Surg Pathol*. 2008;32(3):354–62.
6. Fletcher CDM, Bridge JA, Hogendoorn PC, Mertens F, editors. *Pathology and genetics of tumours of soft tissue and bone*. 4th ed. Lyon: World Health Organization; 2013.
7. Calonje E, Mentzel T, Fletcher CD. Cellular benign fibrous histiocytoma. Clinicopathologic analysis of 74 cases of a distinctive variant of cutaneous fibrous histiocytoma with frequent recurrence. *Am J Surg Pathol*. 1994;18(7):668–76.
8. Calonje E, Fletcher CD. Aneurysmal benign fibrous histiocytoma: clinicopathological analysis of 40 cases of a tumour frequently misdiagnosed as a vascular neoplasm. *Histopathology*. 1995;26(4):323–31.

9. Janssen D, Harms D. Juvenile xanthogranuloma in childhood and adolescence: a clinicopathologic study of 129 patients from the Kiel pediatric tumor registry. *Am J Surg Pathol.* 2005;29(1):21–8.
10. Tahan SR, Pastel-Levy C, Bhan AK, Mihm Jr MC. Juvenile xanthogranuloma. Clinical and pathologic characterization. *Arch Pathol Lab Med.* 1989;113(9):1057–61.
11. Dehner LP. Juvenile xanthogranulomas in the first two decades of life: a clinicopathologic study of 174 cases with cutaneous and extracutaneous manifestations. *Am J Surg Pathol.* 2003;27(5):579–93.
12. Monaghan H, Salter DM, Al-Nafussi A. Giant cell tumour of tendon sheath (localised nodular tenosynovitis): clinicopathological features of 71 cases. *J Clin Pathol.* 2001;54(5):404–7.
13. Ushijima M, Hashimoto H, Tsuneyoshi M, Enjoji M. Giant cell tumor of the tendon sheath (nodular tenosynovitis). A study of 207 cases to compare the large joint group with the common digit group. *Cancer.* 1986;57(4):875–84.
14. Williams J, Hodari A, Janevski P, Siddiqui A. Recurrence of giant cell tumors in the hand: a prospective study. *J Hand Surg [Am].* 2010;35(3):451–6.
15. Myers BW, Masi AT. Pigmented villonodular synovitis and tenosynovitis: a clinical epidemiologic study of 166 cases and literature review. *Medicine (Baltimore).* 1980;59(3):223–38.
16. Somerhausen NS, Fletcher CD. Diffuse-type giant cell tumor: clinicopathologic and immunohistochemical analysis of 50 cases with extraarticular disease. *Am J Surg Pathol.* 2000;24(4)

Smooth muscle is present in almost any part of the body, including the gastrointestinal, genitourinary, and vascular systems. Similarly, smooth muscle tumors can also be found in almost any anatomic location. Morphologically, the neoplastic cells of smooth muscle tumors are noted to have eosinophilic cytoplasm and elongated or ovoid nuclei (Fig. 7.1a).

Perivascular tumors contain a modified type of myoid cell that is associated with the vascular system. These are identified as glomus cells and can have an epithelioid or spindled appearance (Fig. 7.1b) [1].

---

## 7.1 Glomus Tumor

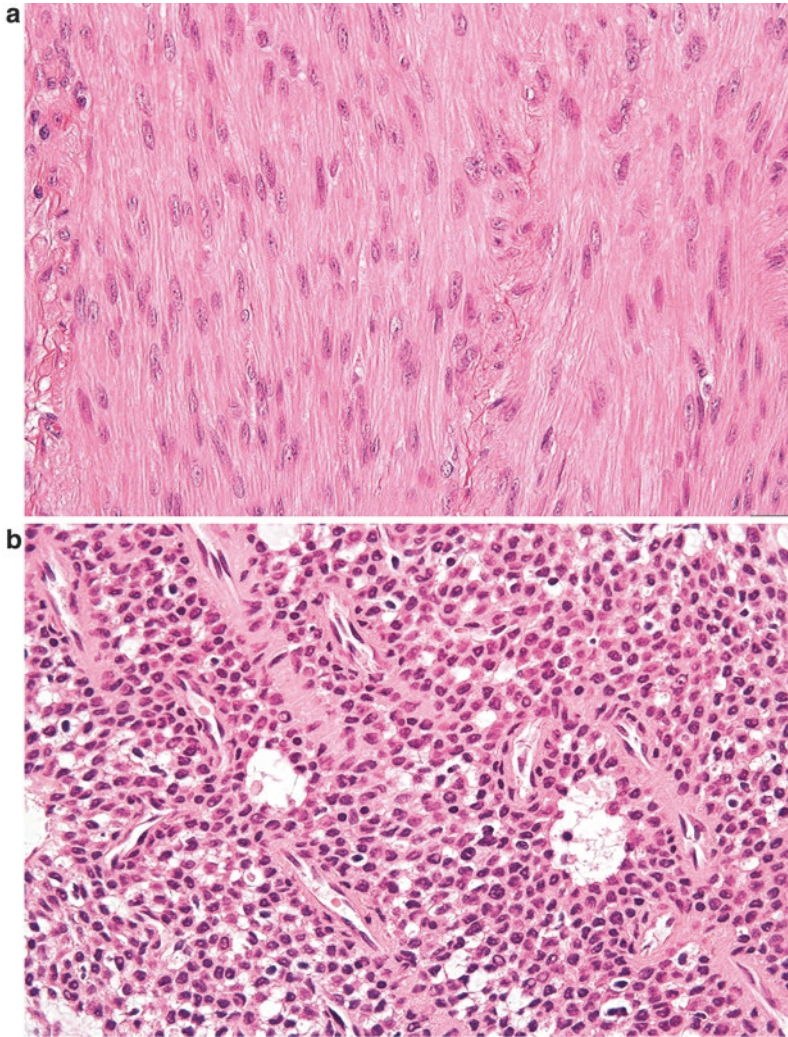
Glomus tumors are neoplasms that show differentiation analogous to the glomus body, a structure that is intimately associated with the vascular system and regulates body temperature by altering blood flow in the distal extremities. Glomus tumors often arise as painful lesions measuring less than 1.0 cm in greatest dimension. They tend to occur in the distal extremities, particularly beneath the fingernail [2]. Numerous other sites of occurrence, such as the gastrointestinal tract, have been described [3].

### Pathology

Grossly, glomus tumors are well-circumscribed lesions that can be blue or red in appearance. Microscopically, these neoplasms are composed of vascular spaces surrounded by cells with clear to purple cytoplasm and round nuclei (Fig. 7.2). These cells can be enlarged and have an epithelial-like appearance (Fig. 7.3) [2].

### Morphologic Variants

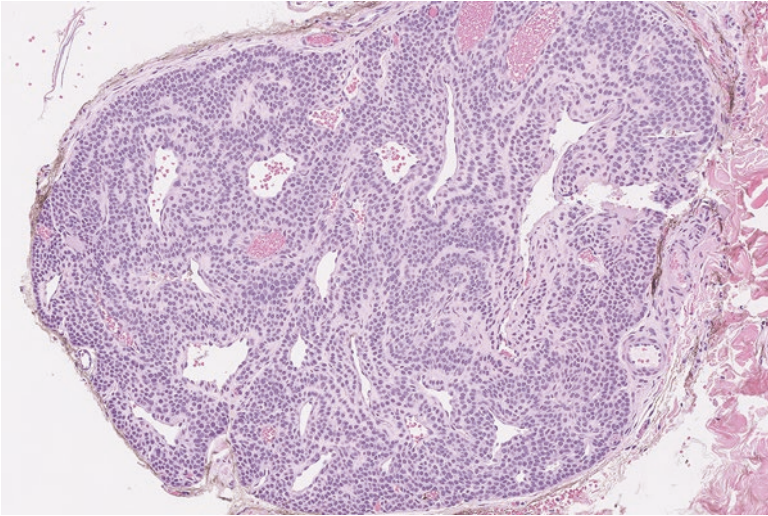
Glomuvenous malformation (Glomangioma) – In this variant, the vascular spaces are enlarged and have a thin rim of associated glomus cells (Fig. 7.4). These usually



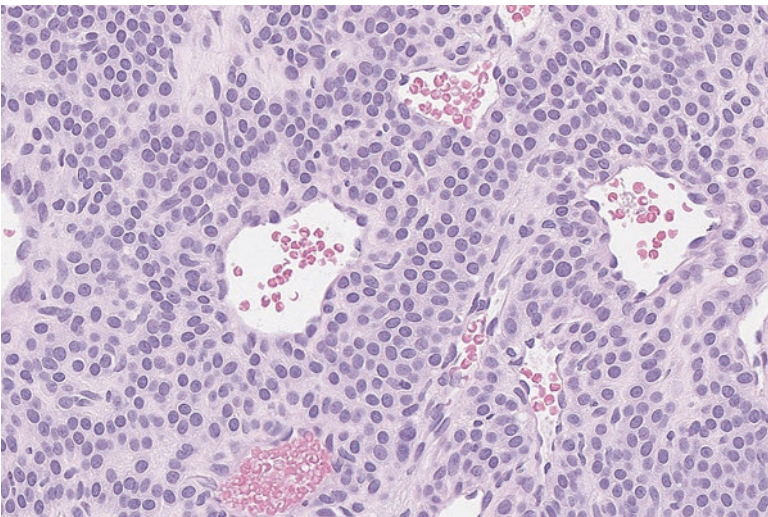
**Fig. 7.1** (a) Smooth muscle cells with a spindled appearance and long, ovoid, “cigar-shaped” nuclei. (b) Perivascular glomus cells with a more rounded and epithelioid appearance

arise in the hand or forearm of children. This entity is particularly known to arise in patients who have a familial history of glomus tumors [4].

Glomangiomyoma - In this variant, the glomus cells demonstrate areas of spindled smooth muscle differentiation (Fig. 7.5) [5].



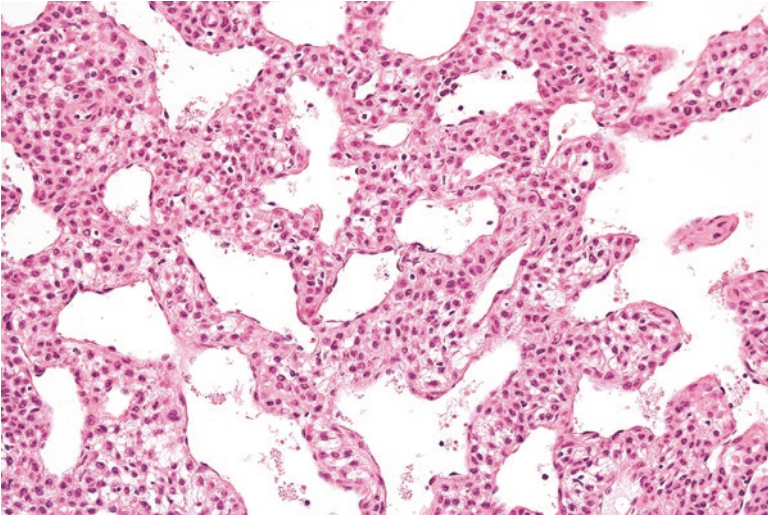
**Fig. 7.2** Glomus tumor of the skin with epithelioid-like cells in close proximity to vascular spaces



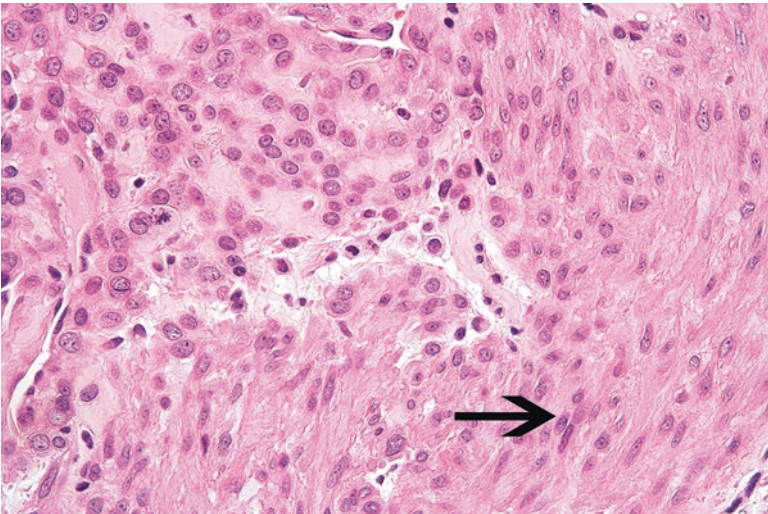
**Fig. 7.3** High-power view of glomus tumor. The epithelioid-like cells contain vesicular and bland nuclei

### Ancillary Studies

- The cells of glomus tumors are diffusely positive for smooth muscle markers such as h-caldesmon, muscle-specific actin, and smooth muscle actin.



**Fig. 7.4** In this glomuvenous malformation, the vascular spaces are more dilated and have a thinner rim of glomus cells



**Fig. 7.5** The glomus cells in this glomangiomyoma begin to take on features more similar to the cigar-shaped nuclei of smooth muscle cells (*arrow*)

### Differential Diagnosis

- Adnexal tumors (e.g., hidradenoma)
- Melanocytic nevi [6]

---

**Comment**

1. Positive staining for smooth muscle markers differentiates glomus tumors from adnexal and melanocytic neoplasms.
2. Glomus tumors are usually benign lesions and are treated with simple excision. Following surgery, approximately 11% recur [7].
3. Glomus tumors can behave more aggressively. Malignant glomus tumors are defined as lesions with cells containing nuclei with moderate to severe atypia and having over five mitosis per 50 high power fields (hpf). Alternatively, a designation of malignant can be given if a glomus neoplasm has atypical mitotic figures. Malignant tumors have a metastatic rate of 38% [8].
4. Glomus tumors of uncertain malignant potential are lesions which contain over five mitosis per 50 hpf without nuclear atypia or lesions that are deeply situated and measure over 2 cm. Since they rarely metastasize, patients should be closely monitored following excision [6].

---

**7.2 Cutaneous Leiomyoma**

Cutaneous leiomyomas are benign neoplasms of smooth muscle that either arise from the smooth muscle cells of the pilar arrector muscles (pilar leiomyoma) or from the smooth muscle cells in the genital region or nipple area (genital leiomyoma) [9].

Clinically, pilar leiomyomas manifest as skin papules in adolescents that measure less than 2 cm and are painful when exposed to low temperatures [6, 10]. Patients who have multiple cutaneous leiomyomas may have hereditary leiomyomatosis and renal cell cancer syndrome (HLRCC), which is associated with a germline mutation in the fumarate hydratase gene. Consequently, these patients should be referred for appropriate testing and screening for renal tumors [11].

Genital leiomyomas can arise in the vulva, scrotum, nipple, and perianal areas. These are often deeper and more nodular than their pilar counterpart [9].

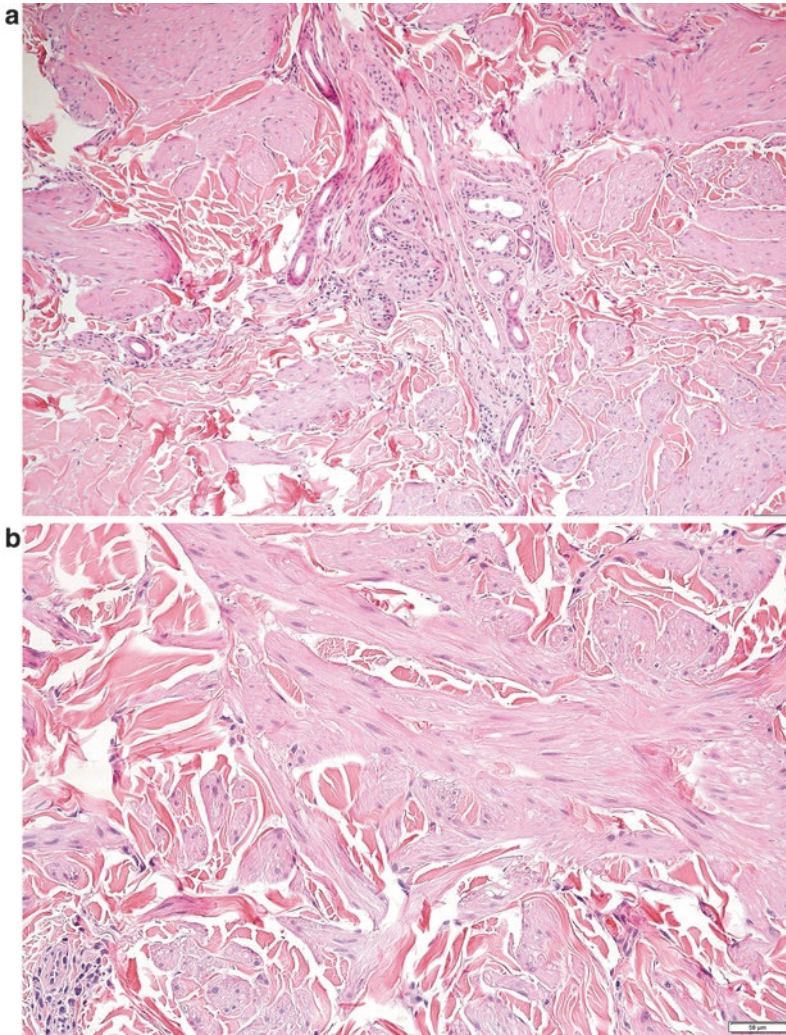
**Pathology**

Microscopically, pilar leiomyomas are composed of spindle cells with “cigar-shaped” nuclei that are haphazardly arranged and infiltrate the surrounding dermis (Fig. 7.6a, b). Genital leiomyomas contain a similar smooth muscle cell proliferation but are usually more circumscribed (Fig. 7.7).

**Ancillary Studies**

- Leiomyomas are positive for desmin and smooth muscle markers such as smooth muscle actin and caldesmon.





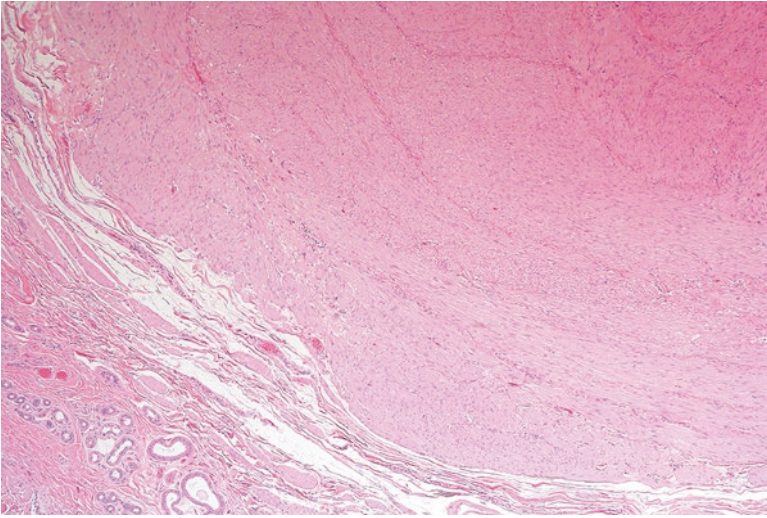
**Fig. 7.6** (a) Pilar leiomyoma extending outward from the adnexal structures of the skin. (b) Pilar leiomyoma with small fascicles of smooth muscle with associated fibrotic tissue

### Differential Diagnosis

- Leiomyosarcoma
- Atypical intradermal smooth muscle neoplasm

### Comments

1. When encountering smooth muscle tumors in the skin or subcutaneous tissue, a pathologist should exclude the possibility of a leiomyosarcoma, which has metastatic potential.



**Fig. 7.7** Well-circumscribed genital leiomyoma arising from the dartos muscle in the scrotum

2. Cutaneous leiomyoma lacks the cellular atypia and substantial mitoses of leiomyosarcoma or atypical intradermal smooth muscle neoplasm. Furthermore, these are usually limited to the dermis [12].
3. Cutaneous leiomyomas are benign and simple excision is the general approach to treatment.
4. Patients with multiple lesions are sometimes treated with laser therapy, given that multiple excisions are not possible [6].
5. Patients with multiple cutaneous leiomyomas should be assessed for a mutation in the fumarate hydratase gene, which is associated with hereditary leiomyomatosis and renal cell cancer syndrome.

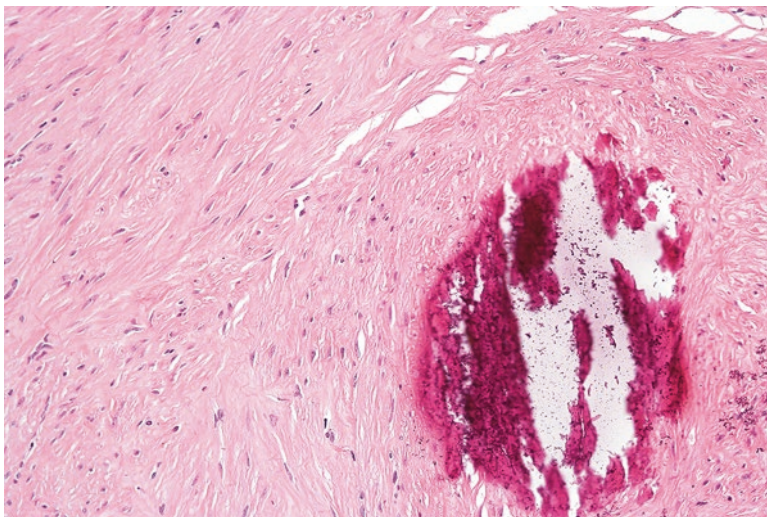
---

### 7.3 Deep Leiomyoma

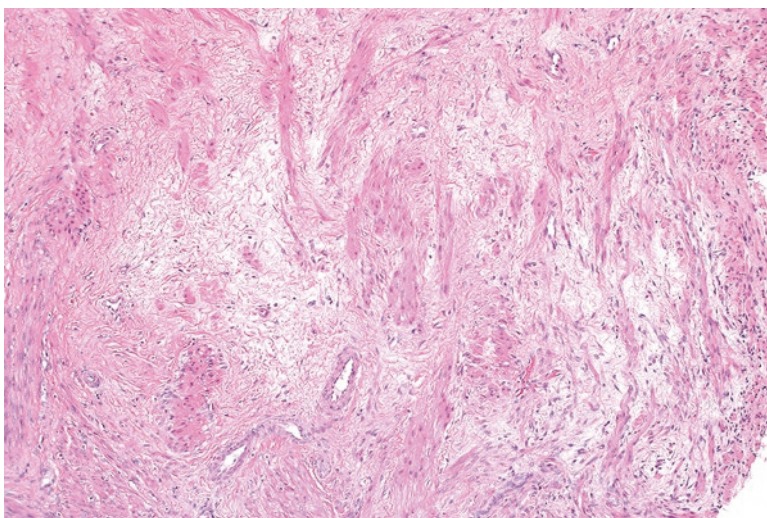
Leiomyomas arising in the deep soft tissue are rare and are divided into two separate categories. Leiomyomas arising deep in the upper and lower extremities (of both males and females) are extraordinarily rare and are designated somatic leiomyomas. Leiomyomas arising in the abdominal cavity or retroperitoneum of females (separate from the uterus) are termed gynecologic leiomyomas [13].

#### Pathology

Microscopically, somatic leiomyomas (such as those arising in the extremities) contain spindle cells that are organized in bundles. Sometimes calcifications can be seen in these tumors (Fig. 7.8). Importantly, substantial nuclear atypia is not identified, and less than one mitosis is found in 50 hpf examined.



**Fig. 7.8** Deep leiomyoma of the extremity showing unremarkable smooth muscle cells and focal calcification



**Fig. 7.9** Gynecologic leiomyoma in the pelvis of a female. Substantial areas of fibrosis are present

Gynecologic leiomyomas are usually more cellular and often contain areas of hyalinized fibrosis (Fig. 7.9). Significant atypia or mitotic activity (more than five mitosis per 50 hpf) are not identified [6, 13].

### Ancillary Studies

- Similar to other smooth muscle tumors, deep leiomyomas are positive for desmin, smooth muscle actin, and caldesmon.

### Differential Diagnosis

- Well-differentiated leiomyosarcoma

### Comment

1. Deep leiomyomas are extraordinarily rare neoplasms and should be diagnosed with caution.
2. Extensive sampling is critical for assessing for the mitoses and atypia seen in leiomyosarcoma [13, 14].
3. Tumors that lack atypia or necrosis but have an increased mitotic rate are designated as smooth muscle tumors of uncertain malignant potential.
4. Somatic leiomyomas of the extremity generally do not recur. Gynecologic leiomyomas of the retroperitoneum very rarely (less than 2%) recur [13].
5. Treatment generally consists of surgical excision and long-term follow-up [15].

---

## 7.4 Cutaneous Leiomyosarcoma

Cutaneous leiomyosarcomas often arise in the dermis of the trunk, extremities, or scalp in the fifth to seventh decades of life [16, 17]. Typically, they measure less than 2 cm in greatest dimension and emanate from the arrector pili or the dartorial smooth muscle [6].

### Pathology

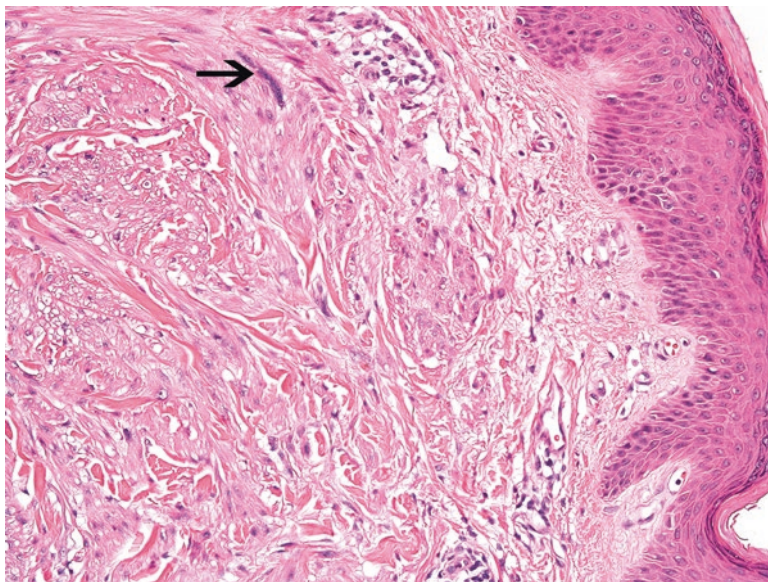
Microscopically, the sections of the tumor show spindle cells with ovoid nuclei that display nuclear atypia and mitoses (Fig. 7.10). Cutaneous leiomyosarcomas originate in the dermis and infiltrate into the underlying subcutaneous tissue (Fig. 7.11).

### Ancillary Studies

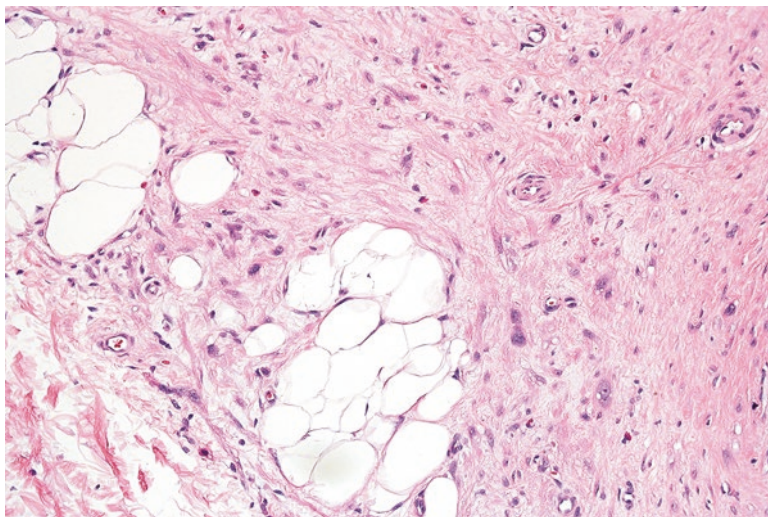
- These smooth muscle tumors are positive for desmin, h-caldesmon, and smooth muscle actin.

### Differential Diagnosis

- Cutaneous leiomyoma
- Angioleiomyoma
- Metastatic leiomyosarcoma



**Fig. 7.10** Cutaneous leiomyosarcoma with vaguely ovoid nuclei exhibiting atypia and mitoses (arrow)



**Fig. 7.11** Cutaneous leiomyosarcoma infiltrating into the underlying subcutaneous adipose tissue

### Comment

1. Cutaneous leiomyosarcomas that are confined to the dermis have an excellent prognosis without risk of metastasis. Consequently, these are often now designated as atypical intradermal smooth muscle neoplasms [12].

2. Leiomyosarcomas from another site can metastasize to the skin; however, these metastatic foci are more circumscribed than a primary leiomyosarcoma. Patients with multiple skin tumors should be assessed for an undiscovered deeper leiomyosarcoma in the retroperitoneum or extremities.
3. Approximately 30–40% of cutaneous leiomyosarcomas with subcutaneous involvement will metastasize [17, 22].
4. These tumors are treated with wide excision [6].

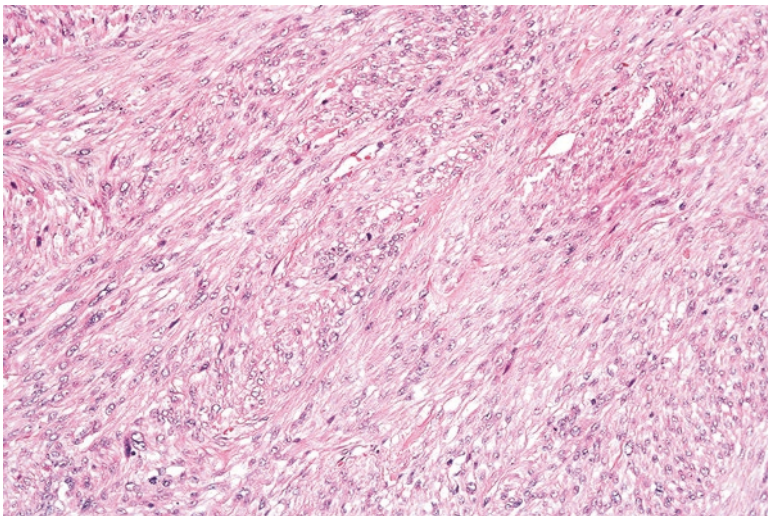
---

## 7.5 Deep Leiomyosarcoma

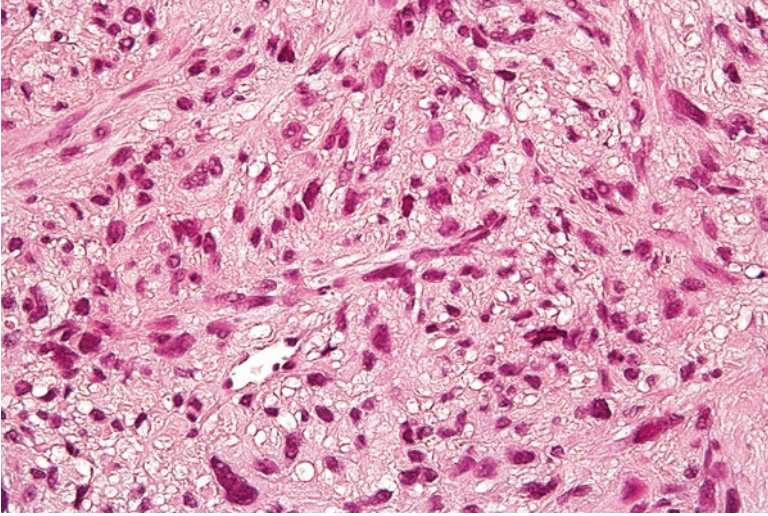
Although leiomyosarcoma is often associated with the uterus, it can also occur in the deep soft tissue [18]. Similar to leiomyomas, leiomyosarcomas can arise in the extremities or trunk (somatic leiomyosarcomas) or retroperitoneum. Approximately 50–75% of leiomyosarcomas arise in the retroperitoneum. Occurrences in the deep soft tissue are less frequent [6, 19]. Once discovered, retroperitoneal leiomyosarcomas are quite large (over 10 cm) and involve adjacent organs. Somatic leiomyosarcomas tend to be smaller in size (median size of 4.0 cm) [20].

### Pathology

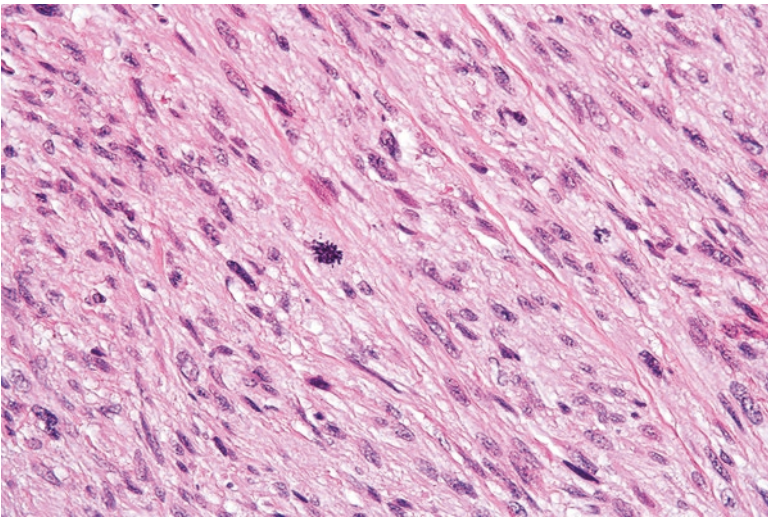
Depending on the degree of tumor differentiation, leiomyosarcomas show varying residual features of smooth muscle differentiation. This includes bundles of intersecting atypical spindle cells with eosinophilic cytoplasm (Fig. 7.12). In poorly differentiated tumors, there can be highly irregular nuclei and bizarre giant cells (Fig. 7.13). Numerous and atypical mitoses are also seen (Fig. 7.14).



**Fig. 7.12** Intersecting bundles of spindle cells in a leiomyosarcoma



**Fig. 7.13** Poorly differentiated leiomyosarcoma in which the cells have bizarre nuclei and have partially lost their spindled appearance



**Fig. 7.14** Numerous and atypical mitoses

### Ancillary Studies

- Leiomyosarcomas are positive for desmin, smooth muscle actin and h-caldesmon.

## Differential Diagnosis

- Cellular schwannoma
- Gastrointestinal stromal tumor
- Leiomyoma
- Undifferentiated high-grade pleomorphic sarcoma

## Comment

1. Leiomyosarcoma must be distinguished from other spindle cell neoplasms that can occur in the affected site. Common considerations include leiomyoma, gastrointestinal stromal tumor, cellular schwannoma, and undifferentiated high-grade pleomorphic sarcoma.
2. Unlike leiomyosarcoma, gastrointestinal stromal tumor and cellular schwannoma are positive for CD117 and S100 immunohistochemical stains, respectively.
3. Leiomyosarcoma has more atypia, necrosis, or mitoses than seen in leiomyoma.
4. Retroperitoneal leiomyosarcomas are highly aggressive tumors that can metastasize and have poor survival. Chances of survival can be improved with more aggressive resection and adjuvant therapies [6, 21].
5. Approximately 34% of somatic leiomyosarcomas metastasize. Somatic leiomyosarcoma has a 5-year and 10-year overall survival rate of 69% and 49%, respectively [20, 23].
6. Treatment for retroperitoneal and somatic leiomyosarcoma includes complete surgical resection and radiation therapy. Chemotherapy is typically administered for metastatic disease [20, 24–25].

## Facts to Remember

1. Glomus tumors are painful lesions that arise in the distal extremities and are usually benign.
2. Cutaneous leiomyomas are benign dermal smooth muscle neoplasms that lack significant atypia or mitoses.
3. Deep leiomyomas are benign smooth muscle tumors that can arise in the retroperitoneum (gynecologic) or extremities (somatic). They do not have any atypical features or necrosis, and mitosis is rare.
4. Although superficially located, cutaneous leiomyosarcomas are malignant soft tissue tumors that have substantial metastatic potential. These tumors originate from the dermis and invade the underlying subcutaneous tissue.
5. Deep leiomyosarcomas frequently arise as large masses in the retroperitoneum. Approximately a third metastasize and the prognosis is grave.



## References

1. Fletcher CDM, Bridge JA, Hogendoorn PC, Mertens F, editors. Pathology and genetics of tumours of soft tissue and bone. 4th ed. Lyon: World Health Organization; 2013.
2. Chung EB, Enzinger FM. Infantile myofibromatosis. *Cancer*. 1981;48(8):1807–18.
3. Daimaru Y, Hashimoto H, Enjoji M. Myofibromatosis in adults (adult counterpart of infantile myofibromatosis). *Am J Surg Pathol*. 1989;13(10):859–65.
4. Hornick JL, editor. Practical soft tissue pathology: a diagnostic approach. Philadelphia: Saunders; 2013.
5. Azzam R, Abboud M, Muwakkit S, Khoury N, Saab R. First-line therapy of generalized infantile myofibromatosis with low-dose vinblastine and methotrexate. *Pediatr Blood Cancer*. 2009;52(2):308.
6. Chou T, Pan SC, Shieh SJ, Lee JW, Chiu HY, Ho CL. Glomus tumor: twenty-year experience and literature review. *Ann Plast Surg*. 2016;76(Suppl 1):S35–40.
7. Miettinen M, Paal E, Lasota J, Sobin LH. Gastrointestinal glomus tumors: a clinicopathologic, immunohistochemical, and molecular genetic study of 32 cases. *Am J Surg Pathol*. 2002;26(3):301–11.
8. Pulitzer DR, Martin PC, Reed RJ. Epithelioid glomus tumor. *Hum Pathol*. 1995;26(9):1022–7.
9. Boon LM, Mulliken JB, Enjolras O, Vikkula M. Glomuvenous malformation (glomangioma) and venous malformation: distinct clinicopathologic and genetic entities. *Arch Dermatol*. 2004;140(8):971–6.
10. Yang JS, Ko JW, Suh KS, Kim ST. Congenital multiple plaque-like glomangiomyoma. *Am J Dermatopathol*. 1999;21(5):454–7.
11. Goldblum J, Weiss S, Folpe AL, editors. Enzinger and Weiss's soft tissue tumors. 6th ed. Philadelphia: Elsevier; 2013.
12. Tsuneyoshi M, Enjoji M. Glomus tumor: a clinicopathologic and electron microscopic study. *Cancer*. 1982;50(8):1601–7.
13. Folpe AL, Fanburg-Smith JC, Miettinen M, Weiss SW. Atypical and malignant glomus tumors: analysis of 52 cases, with a proposal for the reclassification of glomus tumors. *Am J Surg Pathol*. 2001;25(1):1–12.
14. Yokoyama R, Hashimoto H, Daimaru Y, Enjoji M. Superficial leiomyomas. A clinicopathologic study of 34 cases. *Acta Pathol Jpn*. 1987;37(9):1415–22.
15. Archer CB, Whittaker S, Greaves MW. Pharmacological modulation of cold-induced pain in cutaneous leiomyomata. *Br J Dermatol*. 1988;118(2):255–60.
16. Kiuru M, Launonen V. Hereditary leiomyomatosis and renal cell cancer (HLRCC). *Curr Mol Med*. 2004;4(8):869–75.
17. Kraft S, Fletcher CD. Atypical intradermal smooth muscle neoplasms: clinicopathologic analysis of 84 cases and a reappraisal of cutaneous “leiomyosarcoma”. *Am J Surg Pathol*. 2011;35(4):599–607.
18. Billings SD, Folpe AL, Weiss SW. Do leiomyomas of deep soft tissue exist? An analysis of highly differentiated smooth muscle tumors of deep soft tissue supporting two distinct subtypes. *Am J Surg Pathol*. 2001;25(9):1134–42.
19. Paal E, Miettinen M. Retroperitoneal leiomyomas: a clinicopathologic and immunohistochemical study of 56 cases with a comparison to retroperitoneal leiomyosarcomas. *Am J Surg Pathol*. 2001;25(11):1355–63.
20. Hornick JL, editor. Practical soft tissue pathology: a diagnostic approach. 1st ed. Philadelphia: Saunders; 2013.
21. Kaddu S, Beham A, Cerroni L, Humer-Fuchs U, Salmhofer W, Kerl H, et al. Cutaneous leiomyosarcoma. *Am J Surg Pathol*. 1997;21(9):979–87.
22. Jensen ML, Jensen OM, Michalski W, Nielsen OS, Keller J. Intradermal and subcutaneous leiomyosarcoma: a clinicopathological and immunohistochemical study of 41 cases. *J Cutan Pathol*. 1996;23(5):458–63.

23. Gustafson P, Willen H, Baldetorp B, Ferno M, Akerman M, Rydholm A. Soft tissue leiomyosarcoma. A population-based epidemiologic and prognostic study of 48 patients, including cellular DNA content. *Cancer*. 1992;70(1):114–9.
24. Svarvar C, Bohling T, Berlin O, Gustafson P, Folleras G, Bjerkehagen B, et al. Clinical course of nonvisceral soft tissue leiomyosarcoma in 225 patients from the Scandinavian sarcoma group. *Cancer*. 2007;109(2):282–91.
25. Shmookler BM, Lauer DH. Retroperitoneal leiomyosarcoma. A clinicopathologic analysis of 36 cases. *Am J Surg Pathol*. 1983;7(3):269–80.

Histologically, skeletal muscle cells are distinguished by eosinophilic cytoplasm containing light and dark striations that correspond to the alternating arrangement of thin and thick myofilaments (Fig. 8.1). These cells can be seen in varying degrees in soft tissue tumors with skeletal muscle differentiation. However, in tumors that are poorly differentiated, rhabdomyoblastic differentiation must sometimes be confirmed by immunohistochemical stains for skeletal muscle markers (e.g., myogenin) [1].

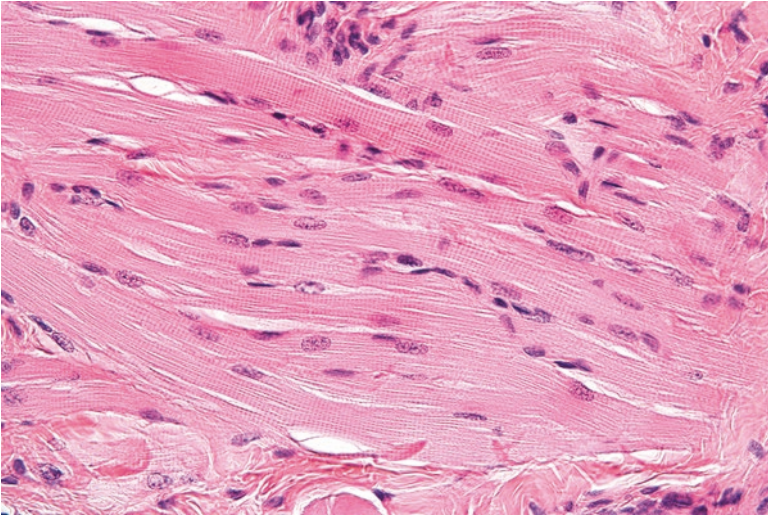
---

## 8.1 Rhabdomyoma

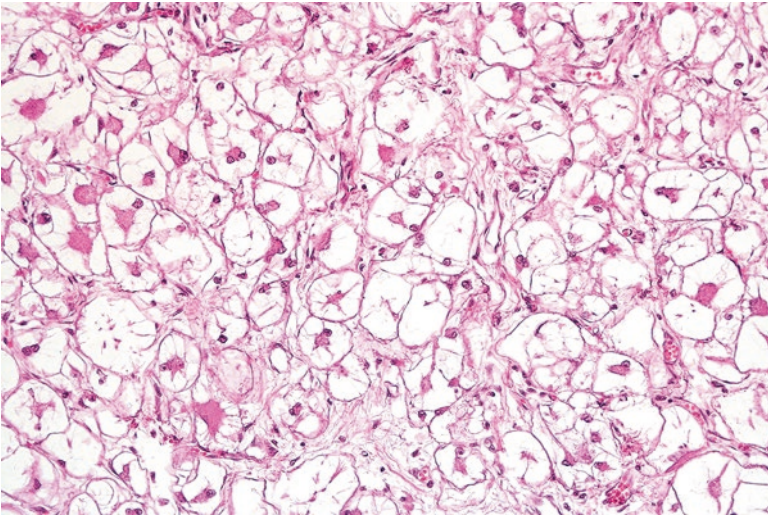
Rhabdomyomas are rare and benign neoplasms of skeletal muscle differentiation. These are divided into cardiac, adult, fetal, and genital types. Cardiac rhabdomyomas typically arise as single or multiple tumors in the right or left heart ventricles and are often associated with tuberous sclerosis. Patients can present with symptoms of arrhythmia or cardiac dysfunction [2, 3]. Adult rhabdomyomas arise as slow-growing lesions in the head and neck in adults after the fifth decade of life. Patients can present with problems swallowing or experience vocal cord dysfunction [4–6]. Fetal rhabdomyomas predominantly occur in the head and neck in children and have been reported in patients with nevoid basal cell carcinoma syndrome [7, 8]. Genital rhabdomyoma usually arises as a slowly growing polypoid mass in the vagina or vulva in middle-aged women (average age of 45 years) [9].

### Pathology

The histologic appearance of rhabdomyomas depends on the subtype. Cardiac rhabdomyomas contain sheets of polygonal cells that are highly vacuolated, otherwise known as “spider cells” (Fig. 8.2). Adult rhabdomyomas show polygonal cells with eosinophilic and granular cytoplasm. Scattered vacuolated cells can also be seen. Fetal rhabdomyomas demonstrate spindle cells with thin and elongated nuclei



**Fig. 8.1** Normal skeletal muscle cells with striated and eosinophilic cytoplasm

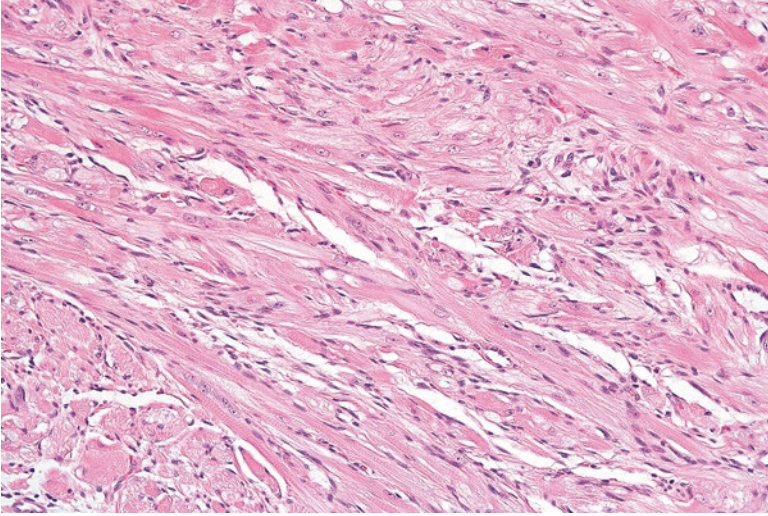


**Fig. 8.2** Cardiac rhabdomyoma with “spider cells”

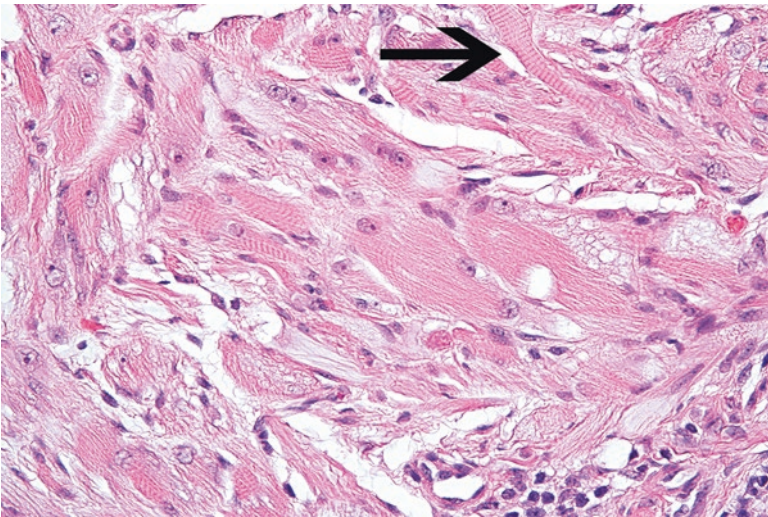
(Figs. 8.3 and 8.4). Depending on the morphologic maturity of the tumor, these tumor cells may contain cytoplasmic cross striations. Genital rhabdomyomas demonstrate an aggregate of muscle cells with scattered cross striations (Fig. 8.5) [6].

### Ancillary Studies

- Consistent with their myogenic nature, rhabdomyomas stain with desmin.



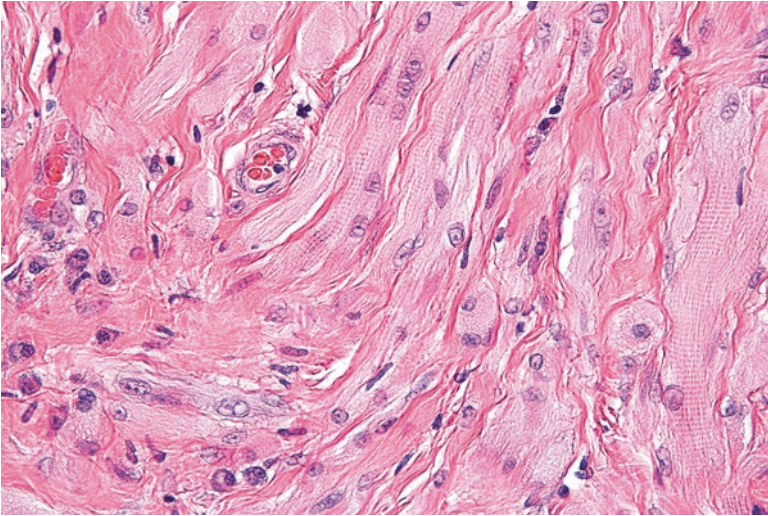
**Fig. 8.3** Fetal rhabdomyoma with spindle cells



**Fig. 8.4** Fetal rhabdomyoma with spindle cells with very focal cross striations (*arrow*). These cells can sometimes be difficult to distinguish from a rhabdomyosarcoma

### Differential Diagnosis

- Hibernoma
- Embryonal rhabdomyosarcoma



**Fig. 8.5** Genital rhabdomyoma with skeletal muscle cells containing cross striations

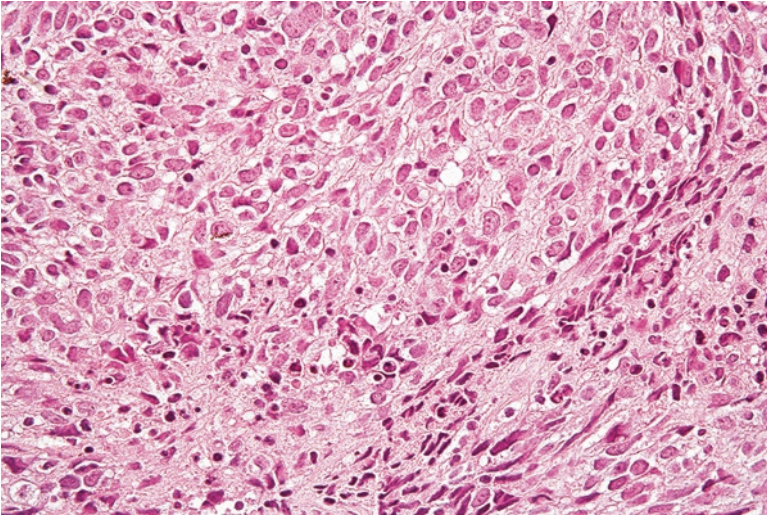
### Comment

1. While hibernomas can have cells with eosinophilic cytoplasm, they usually contain scattered adipocytes that indicate their lipogenic differentiation. Unlike rhabdomyomas, hibernomas are negative for muscle markers such as desmin.
2. Rhabdomyomas with particularly immature cells, such as fetal rhabdomyoma, can be difficult to discern from embryonal rhabdomyosarcoma.
3. Embryonal rhabdomyosarcoma is typically more infiltrative and has increased mitosis and necrosis compared to a rhabdomyoma [6].
4. Adult rhabdomyomas are treated by simple excision. Up to 40% of lesions can recur, but these are typically treated with re-excision [4].
5. Given that cardiac rhabdomyomas often spontaneously regress, surgical excision is only performed in patients who are experiencing arrhythmias or hemodynamic compromise.
6. Patients who are diagnosed with cardiac rhabdomyoma should be assessed for tuberous sclerosis [6, 10].
7. Fetal rhabdomyomas are typically cured by simple excision. Less than 10% recur [7].

---

## 8.2 Embryonal Rhabdomyosarcoma

Embryonal rhabdomyosarcoma is a malignant soft tissue sarcoma of skeletal muscle differentiation that predominantly occurs in young children, often under 10 years of age [11]. Frequent sites of occurrence include the head and neck and hollow organs, such as the nasopharynx, bladder, and vagina [6, 12].



**Fig. 8.6** Embryonal rhabdomyosarcoma with highly immature tumor cells with limited cytoplasm

### Pathology

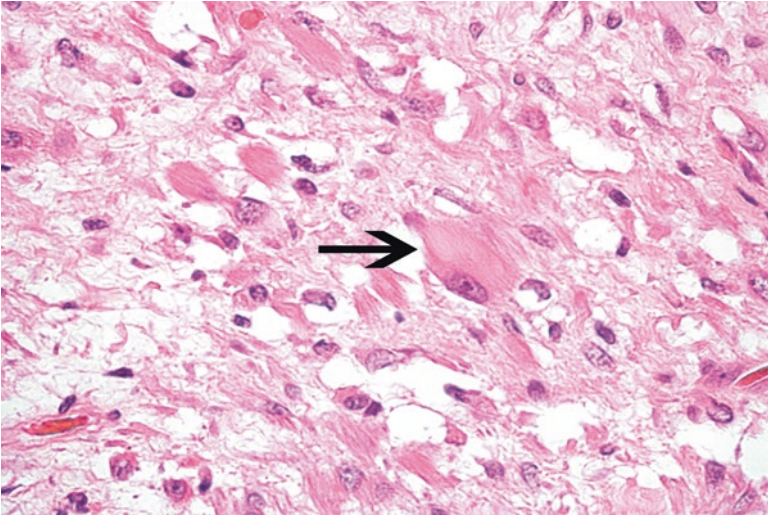
Grossly these tumors have a white and friable appearance [9]. Microscopically, they are composed of highly immature cells in a variably myxoid background (Fig. 8.6). The neoplastic cells have scant cytoplasm, and only occasionally contain skeletal muscle type striations, otherwise known as rhabdomyoblasts (Fig. 8.7). These rhabdomyoblasts are increased in tumors that have been previously treated with chemotherapy (Fig. 8.8) [13]. In the botryoid variant of embryonal rhabdomyosarcoma, the tumor cells approach but do not overrun the overlying squamous or urothelial mucosa (Fig. 8.9).

### Ancillary Studies

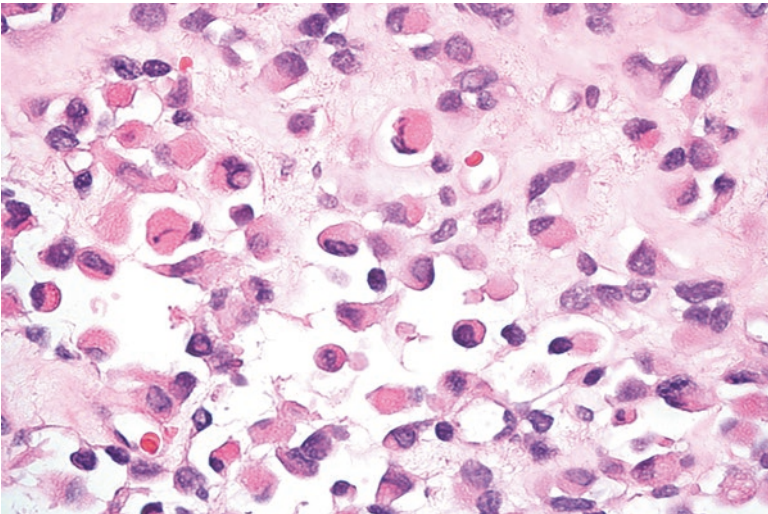
- The tumor cells are positive for desmin, consistent with their myogenic nature.
- Additionally, the neoplastic cells show nuclear expression of myogenin and MyoD1.

### Differential Diagnosis

- Alveolar rhabdomyosarcoma
- Ewing sarcoma
- Pleomorphic rhabdomyosarcoma
- Fetal rhabdomyoma



**Fig. 8.7** Rare rhabdomyoblast demonstrating eosinophilic cytoplasm and cross striations (*arrow*) in an embryonal rhabdomyosarcoma

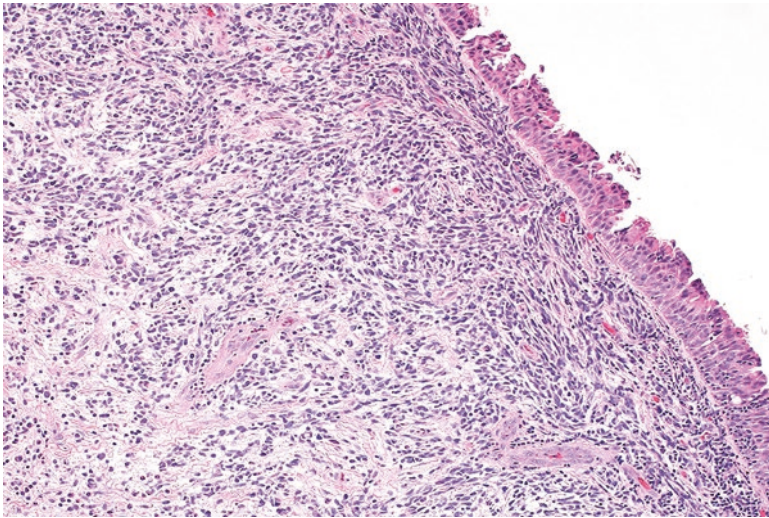


**Fig. 8.8** Rhabdomyosarcoma previously treated with chemotherapy showing multiple rhabdomyoblasts

### Comment

- Embryonal rhabdomyosarcoma lacks the characteristic translocations involving the *EWSR1* gene or *FOXO1* gene seen in Ewing sarcoma or alveolar rhabdomyosarcoma, respectively.





**Fig. 8.9** The tumor cells in this botryoid variant of embryonal rhabdomyosarcoma condense around the adjacent urothelium

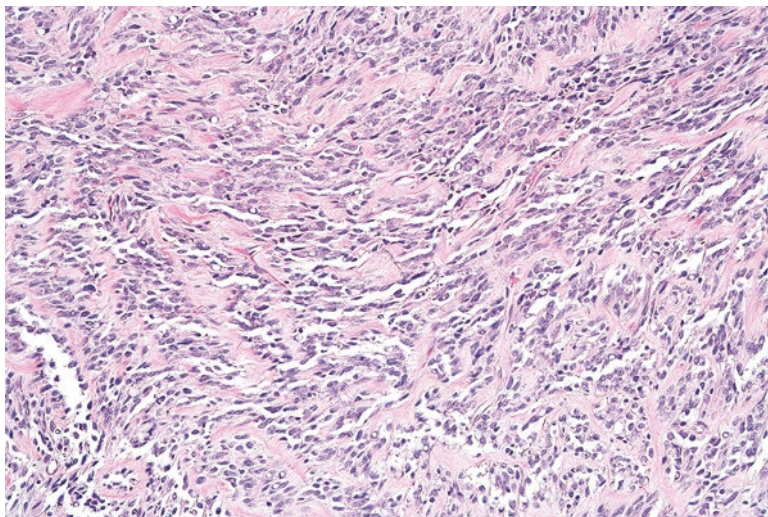
- Although embryonal rhabdomyosarcoma can exhibit focal areas of pleomorphism, pleomorphic rhabdomyosarcoma is diffusely anaplastic and typically arises in the extremities of adults.
- Although fetal rhabdomyoma can have immature cells, these tumors lack the mitosis and necrosis seen in embryonal rhabdomyosarcoma.
- Botryoid rhabdomyosarcoma has an overall 5-year survival rate of approximately 95% [14].
- Non-botryoid embryonal rhabdomyosarcoma has an overall 5-year survival rate of approximately 67% [14].
- Treatment consists of a combination of chemotherapy and surgical resection. Radiation therapy can be used in cases of nodal metastasis, positive margins, or poor response to chemotherapy [6].

### 8.3 Alveolar Rhabdomyosarcoma

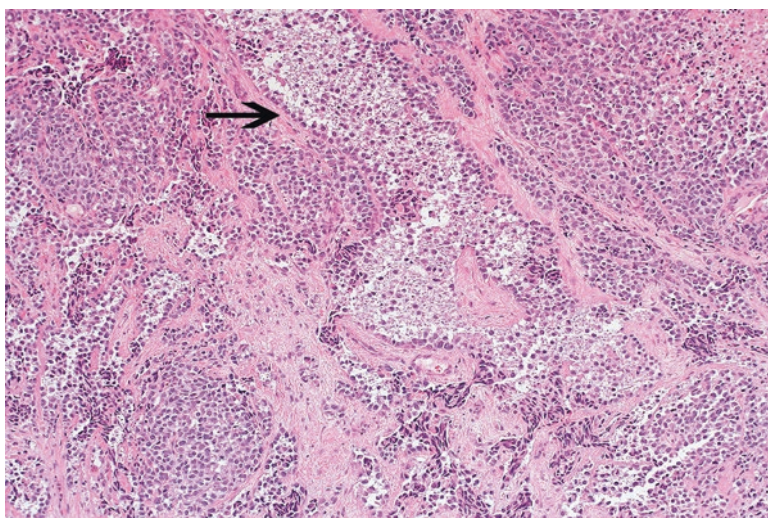
Alveolar rhabdomyosarcoma is a malignant soft tissue tumor that frequently arises during the second and third decades of life. Common sites of involvement include the extremities, head, neck, and trunk [14].

#### Pathology

Histologically, alveolar rhabdomyosarcoma shows highly immature tumor cells with very little cytoplasm that are partitioned by fibrous septae (Fig. 8.10). Although tumor cells adhere to these fibrous bands, the more centrally located neoplastic cells drop out and give the tumor an “alveolar” appearance similar to lung parenchyma (Figs. 8.11 and 8.12). Scattered neoplastic giant cells can also be seen (Fig. 8.13). Only rarely can any rhabdomyoblasts be identified (Fig. 8.14) [15].



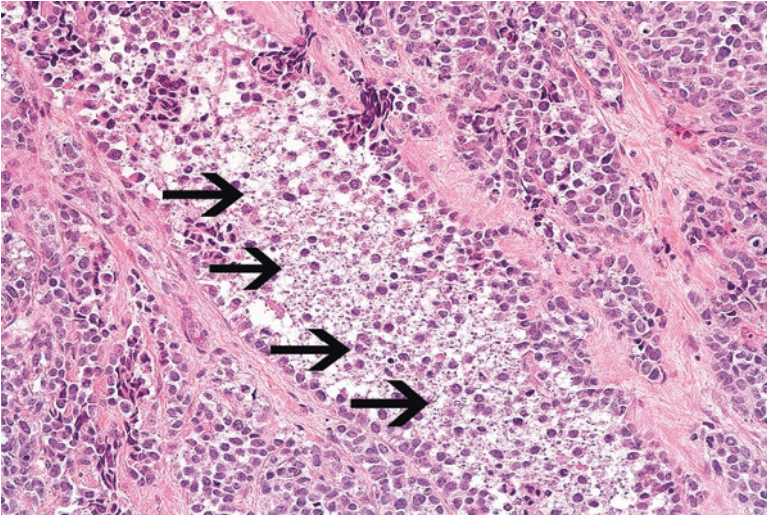
**Fig. 8.10** Alveolar rhabdomyosarcoma showing poorly differentiated tumor cells partitioned by fibrous septa



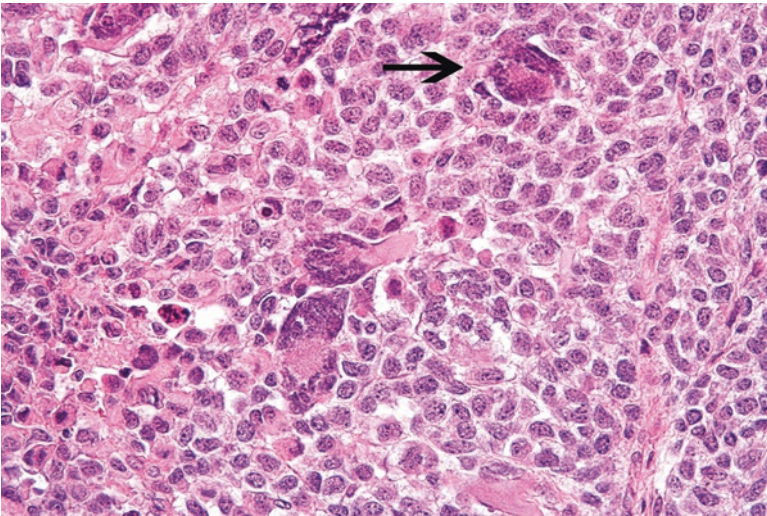
**Fig. 8.11** The tumor cells in this alveolar rhabdomyosarcoma are adherent to the fibrous septa

### Ancillary Studies

- Alveolar rhabdomyosarcomas are positive for desmin, myogenin, and MyoD1 immunohistochemical stains.
- Approximately 60% of alveolar rhabdomyosarcomas manifest a t(2;13) translocation that results in a *PAX3-FOXO1A* fusion transcript.
- Approximately 20% of alveolar rhabdomyosarcomas demonstrate a t(1;13) translocation that results in a *PAX7-FOXO1A* fusion transcript [16].



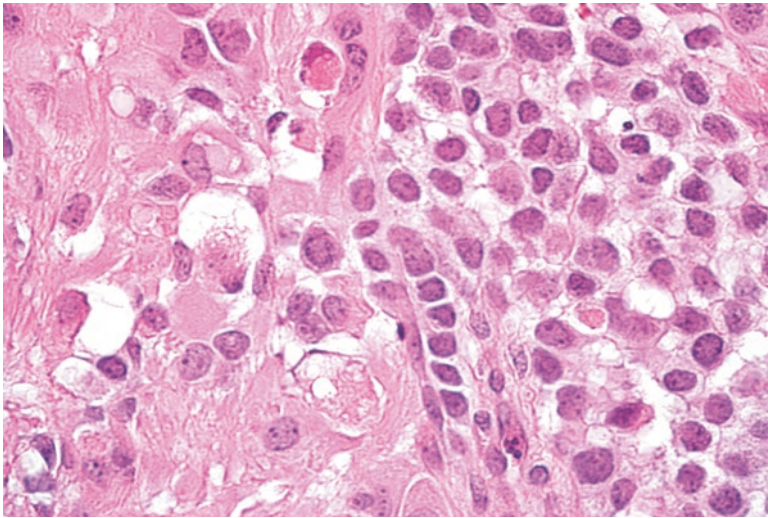
**Fig. 8.12** Central dropout of tumor cells (*arrows*) among the fibrous septa creates an “alveolar”-like appearance in the tumor



**Fig. 8.13** Scattered neoplastic giant cells (*arrow*) are often present in an alveolar rhabdomyosarcoma

### Differential Diagnosis

- Ewing sarcoma
- Desmoplastic round cell tumor
- Embryonal rhabdomyosarcoma



**Fig. 8.14** Scattered rhabdomyoblasts are rarely found in alveolar rhabdomyosarcoma

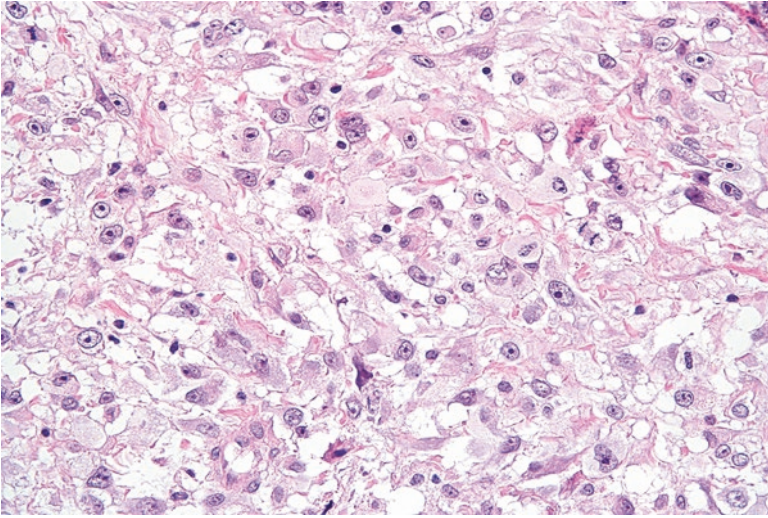
### Comment

- Alveolar rhabdomyosarcoma can be difficult to distinguish from other poorly differentiated round cell tumors such as Ewing sarcoma or desmoplastic round cell tumor.
- Ewing sarcoma and desmoplastic round cell tumor characteristically manifest mutations involving the *EWSR1* gene.
- Although alveolar rhabdomyosarcoma and embryonal rhabdomyosarcoma can have the same immunohistochemical staining pattern, alveolar rhabdomyosarcoma can be diagnosed by detection of the *PAX3-FOXO1A* or *PAX7-FOXO1A* fusion transcripts.
- The distinction of alveolar rhabdomyosarcoma from embryonal rhabdomyosarcoma is relevant as alveolar rhabdomyosarcoma has a poorer survival (5-year survival of 54%) [14].
- The prognosis is better in alveolar rhabdomyosarcomas with a *PAX7-FOXO1A* fusion transcript than a *PAX3-FOXO1A* fusion transcript [17].
- Frequent sites of metastasis include the lung and lymph nodes.
- Treatment usually includes chemotherapy and radiation therapy. Second-line chemotherapy is administered for tumors that do not respond to initial treatment [9].

---

## 8.4 Pleomorphic Rhabdomyosarcoma

Pleomorphic rhabdomyosarcoma is a malignant soft tissue neoplasm that arises later than other rhabdomyosarcomas, typically after the fourth decade of life. These most commonly arise in the deep extremities, such as the thigh, but can arise in other sites. When diagnosed, these tumors are usually greater than 10 cm in size [6, 18].



**Fig. 8.15** Pleomorphic rhabdomyosarcoma with highly atypical tumor cells

### Pathology

In contrast to embryonal and alveolar rhabdomyosarcomas which are predominantly composed of immature cells with scant cytoplasm, pleomorphic rhabdomyosarcomas are composed of cells with abundant eosinophilic cytoplasm and bizarre nuclei (Fig. 8.15).

### Ancillary Studies

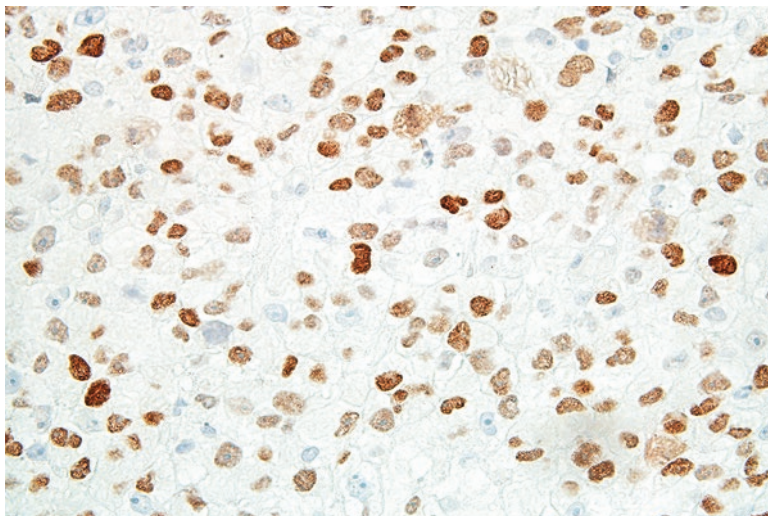
- The tumor cells are positive for desmin, myogenin, and MyoD1 (Fig. 8.16).

### Differential Diagnosis

- Embryonal or alveolar rhabdomyosarcoma
- Undifferentiated pleomorphic sarcoma
- Pleomorphic leiomyosarcoma

### Comment

- Embryonal and alveolar rhabdomyosarcoma can focally have pleomorphic areas, but these are limited to only a portion of the tumor. Also, pleomorphic rhabdomyosarcoma usually occurs in older adults.
- Pleomorphic rhabdomyosarcomas can look similar to other pleomorphic sarcomas, such as undifferentiated pleomorphic sarcoma or pleomorphic leiomyosarcoma.



**Fig. 8.16** The tumor cells in this pleomorphic rhabdomyosarcoma are positive for MyoD1, consistent with skeletal muscle differentiation

By definition, these other tumors lack the morphologic or immunohistochemical features of skeletal muscle differentiation.

- Pleomorphic rhabdomyosarcoma is a highly aggressive tumor. The majority will metastasize and the median survival is approximately 20 months [6, 15].
- Treatment usually consists of wide excision and adjuvant radiation therapy [9].

### Facts to Remember

1. Rhabdomyomas are rare soft tissue tumors that manifest skeletal muscle differentiation. Different subtypes of rhabdomyomas have specific clinical and morphologic features.
2. Embryonal rhabdomyosarcoma often arises in infants and children in the head and neck and genitourinary area. The botryoid variant of rhabdomyosarcoma has a particularly good prognosis.
3. Alveolar rhabdomyosarcoma occurs in young adults, frequently in the extremities. This type of rhabdomyosarcoma is more aggressive than embryonal rhabdomyosarcoma and contains either *PAX3-FOXO1A* or *PAX7-FOXO1A* fusion transcripts.
4. Pleomorphic rhabdomyosarcomas arise in older adults and contain bizarre tumor cells. These tumors are highly aggressive and carry a poor prognosis.

## References

1. Cessna MH, Zhou H, Perkins SL, Tripp SR, Layfield L, Daines C, et al. Are myogenin and myoD1 expression specific for rhabdomyosarcoma? A study of 150 cases, with emphasis on spindle cell mimics. *Am J Surg Pathol*. 2001;25(9):1150–7.
2. De Rosa G, De Carolis MP, Pardeo M, Bersani I, Tempera A, De Nisco A, et al. Neonatal emergencies associated with cardiac rhabdomyomas: an 8-year experience. *Fetal Diagn Ther*. 2011;29(2):169–77.
3. Burke AP, Virmani R. Cardiac rhabdomyoma: a clinicopathologic study. *Mod Pathol*. 1991;4(1):70–4.
4. Kapadia SB, Meis JM, Frisman DM, Ellis GL, Heffner DK, Hyams VJ. Adult rhabdomyoma of the head and neck: a clinicopathologic and immunophenotypic study. *Hum Pathol*. 1993;24(6):608–17.
5. Pichi B, Manciocco V, Marchesi P, Pellini R, Ruscito P, Vidiri A, et al. Rhabdomyoma of the parapharyngeal space presenting with dysphagia. *Dysphagia*. 2008;23(2):202–4.
6. Goldblum J, Weiss S, Folpe AL, editors. *Enzinger and Weiss's soft tissue tumors*. 6th ed. Philadelphia: Elsevier; 2013.
7. Kapadia SB, Meis JM, Frisman DM, Ellis GL, Heffner DK. Fetal rhabdomyoma of the head and neck: a clinicopathologic and immunophenotypic study of 24 cases. *Hum Pathol*. 1993;24(7):754–65.
8. DiSanto S, Abt AB, Boal DK, Krummel TM. Fetal rhabdomyoma and nevoid basal cell carcinoma syndrome. *Pediatr Pathol*. 1992;12(3):441–7.
9. Hornick JL, editor. *Practical soft tissue pathology: a diagnostic approach*. 1st ed. Philadelphia: Saunders; 2013.
10. Fesslova V, Villa L, Rizzuti T, Mastrangelo M, Mosca F. Natural history and long-term outcome of cardiac rhabdomyomas detected prenatally. *Prenat Diagn*. 2004;24(4):241–8.
11. Ognjanovic S, Linabery AM, Charbonneau B, Ross JA. Trends in childhood rhabdomyosarcoma incidence and survival in the United States, 1975–2005. *Cancer*. 2009;115(18):4218–26.
12. Newton Jr WA, Soule EH, Hamoudi AB, Reiman HM, Shimada H, Beltangady M, et al. Histopathology of childhood sarcomas, intergroup rhabdomyosarcoma studies I and II: clinicopathologic correlation. *J Clin Oncol*. 1988;6(1):67–75.
13. Miettinen M, editor. *Modern soft tissue pathology: tumors and non-neoplastic conditions*. 1st ed. New York: Cambridge University Press; 2010.
14. Newton Jr WA, Gehan EA, Webber BL, Marsden HB, van Unnik AJ, Hamoudi AB, et al. Classification of rhabdomyosarcomas and related sarcomas. Pathologic aspects and proposal for a new classification – an intergroup rhabdomyosarcoma study. *Cancer*. 1995;76(6):1073–85.
15. Fletcher CDM, Bridge JA, Hogendoorn PC, Mertens F, editors. *Pathology and genetics of tumours of soft tissue and bone*. 4th ed. Lyon: World Health Organization; 2013.
16. Parham DM, Qualman SJ, Teot L, Barr FG, Morotti R, Sorensen PH, et al. Correlation between histology and PAX/FKHR fusion status in alveolar rhabdomyosarcoma: a report from the Children's oncology group. *Am J Surg Pathol*. 2007;31(6):895–901.
17. Sorensen PH, Lynch JC, Qualman SJ, Tirabosco R, Lim JF, Maurer HM, et al. PAX3-FKHR and PAX7-FKHR gene fusions are prognostic indicators in alveolar rhabdomyosarcoma: a report from the children's oncology group. *J Clin Oncol*. 2002;20(11):2672–9.
18. Gaffney EF, Dervan PA, Fletcher CD. Pleomorphic rhabdomyosarcoma in adulthood. Analysis of 11 cases with definition of diagnostic criteria. *Am J Surg Pathol*. 1993;17(6):601–9.

Peripheral nerves are composed of axons that are supported and insulated by a myelin substance produced by surrounding Schwann cells. These axons are further organized into bundles that are supported and surrounded by connective tissue and covered by perineurium. In neural and nerve sheath neoplasms, one or a combination of these anatomic structures proliferate to form a soft tissue mass.

---

## 9.1 Schwannoma

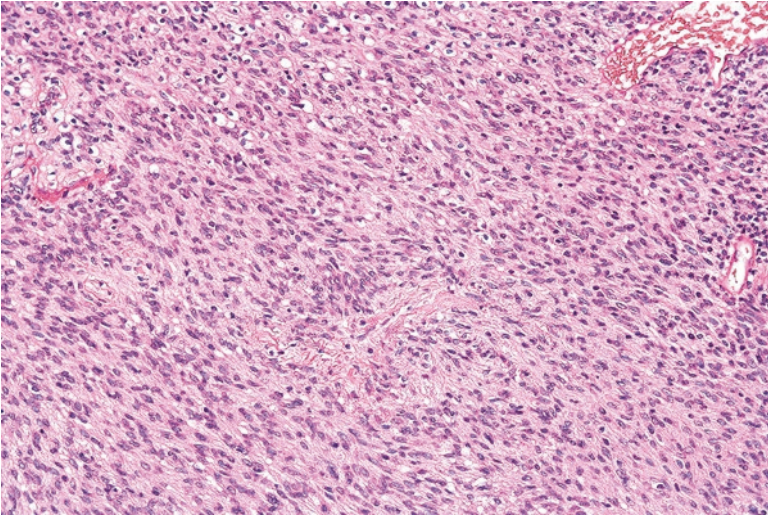
Schwannomas arise from the myelin-producing Schwann cells that surround the nerve and often occur in adults between 20 and 50 years of age. Frequent sites of involvement include the head and neck or flexor surfaces of the extremities [1]. Although benign, these tumors can cause clinical concern when they arise in the deep portions in the extremities, retroperitoneum, or posterior mediastinum [2]. Although schwannomas can be suspected on radiologic examination, needle core biopsies are often performed to exclude other malignant neoplasms, such as malignant peripheral nerve sheath tumor.

### Pathology

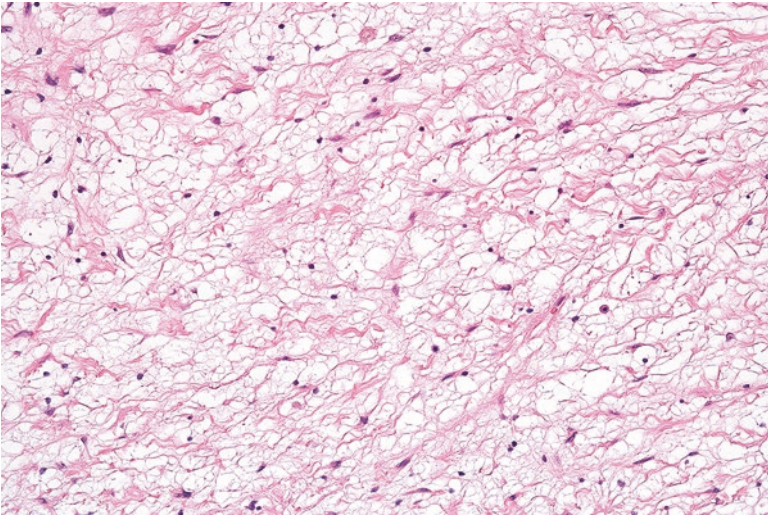
Microscopically, schwannomas show spindle cells with dense homogenous eosinophilic cytoplasm (Antoni A areas) admixed with less cellular areas of cells intermixed with looser background collagen (Antoni B areas) (Figs. 9.1 and 9.2). Sometimes, the nuclei of the spindle cells can form parallel arrangements, termed Verocay bodies (Fig. 9.3).

Schwannomas can vary in appearance. A cellular schwannoma is predominantly composed of dense Antoni A areas. A schwannoma with degenerative changes (ancient schwannoma) can show perivascular hyalinization (Fig. 9.4) or cells with degenerative atypia (Fig. 9.5).





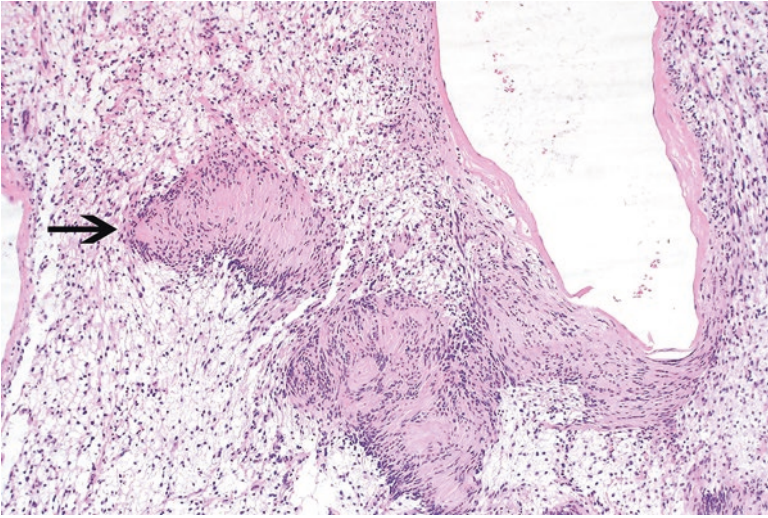
**Fig. 9.1** Hypercellular Antoni A area of a schwannoma



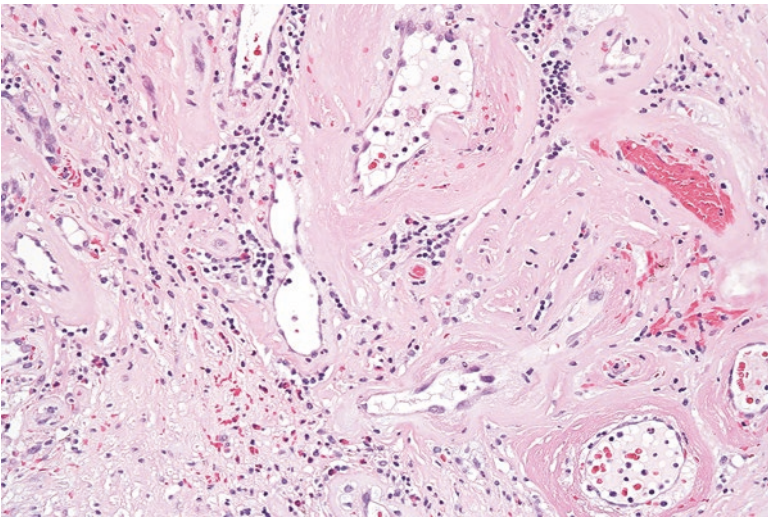
**Fig. 9.2** Hypocellular Antoni B area of a schwannoma. The cells have nuclei that are less plump and the background stroma has a vaguely myxoid appearance

### Ancillary Studies

- The spindle cells of a schwannoma are diffusely positive for S100 and SOX-10 immunohistochemical stains.



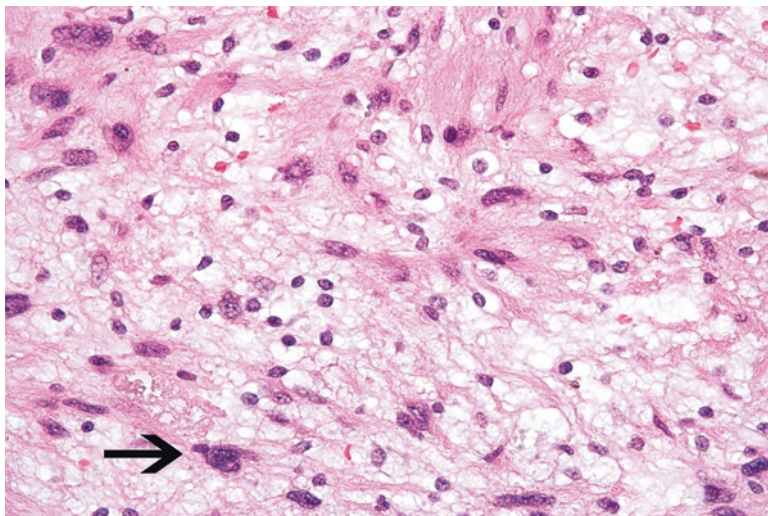
**Fig. 9.3** In this Verocay body found in a schwannoma, the nuclei are arranged in a parallel formation



**Fig. 9.4** Perivascular hyalinization in a schwannoma with degenerative changes

### Differential Diagnosis

- Malignant peripheral nerve sheath tumor
- Neurofibroma



**Fig. 9.5** Focal nuclear atypia (*arrow*) in a schwannoma with degenerative changes

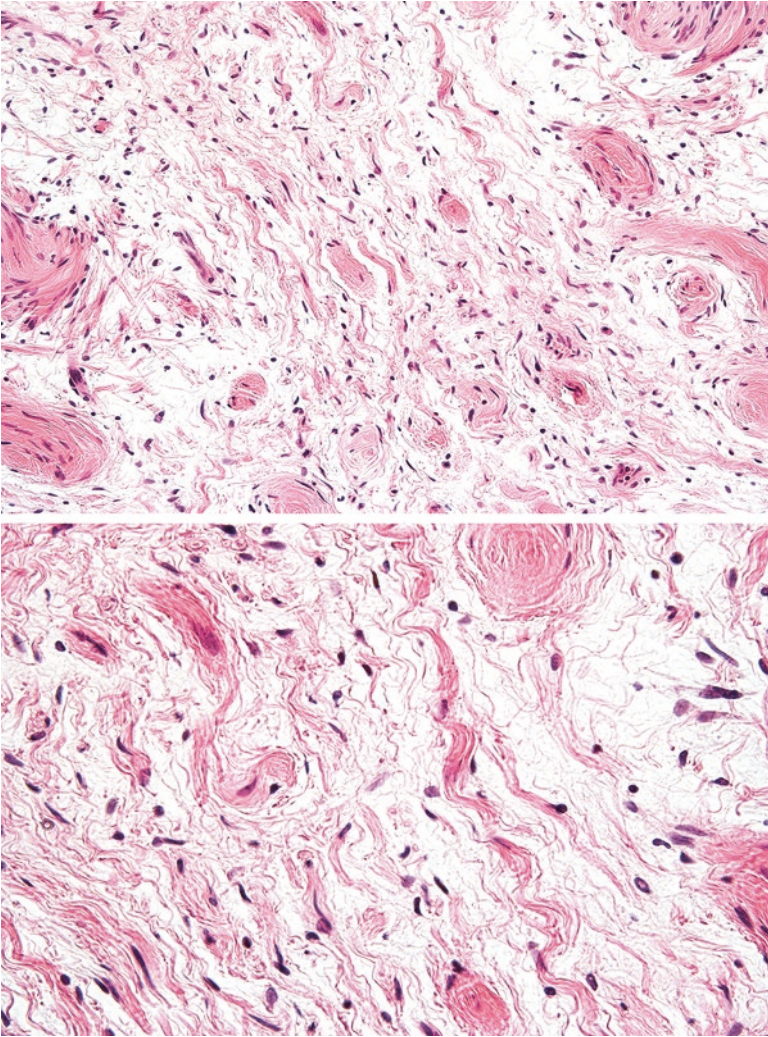
### Comments

1. Schwannomas that lack less cellular areas can sometimes be confused for a malignant peripheral nerve sheath tumor.
2. Although a portion of malignant peripheral nerve sheath tumors can stain for S100, the staining is typically weak or focal in nature.
3. The less cellular areas of a schwannoma can sometimes mimic a neurofibroma. However, neurofibromas are composed of multiple nerve elements, including perineurial cells, fibroblasts, and axons that can be detected by immunohistochemistry.
4. Schwannomas can rarely arise as multiple lesions in certain syndromes, such as schwannomatosis or neurofibromatosis type 2. Patients with multiple schwannomas should be assessed for these conditions [3, 4].
5. Schwannomas are benign and only rarely recur after conservative excision [5].

---

## 9.2 Neurofibroma

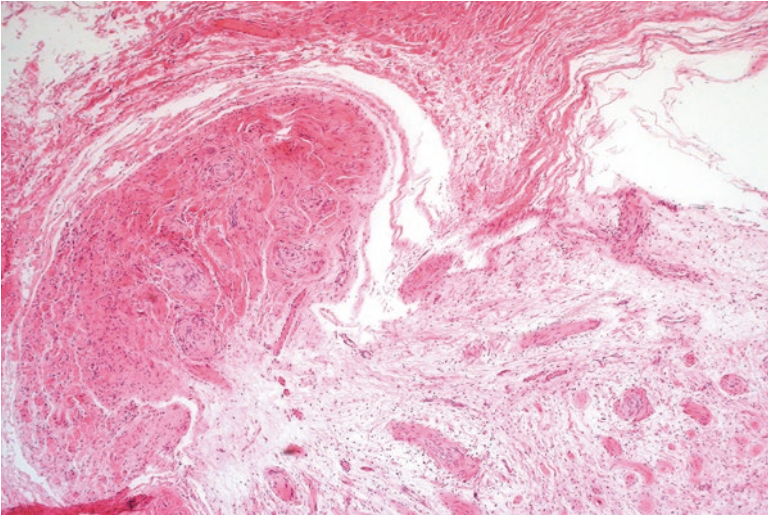
Neurofibroma is a benign nerve tumor that frequently arises in the skin as a painless circumscribed nodule. It can also manifest as a large mass in association with larger nerves in deeper sites such as the abdomen [6]. Multiple and large neurofibromas occur in patients with neurofibromatosis type 1 (NF1) or neurofibromatosis type 2 (NF2). Additional findings of NF1 include café-au-lait spots of the skin, Lisch nodules, and optic gliomas. Additional features of NF2 include bilateral vestibular schwannomas, meningiomas, and gliomas [7].



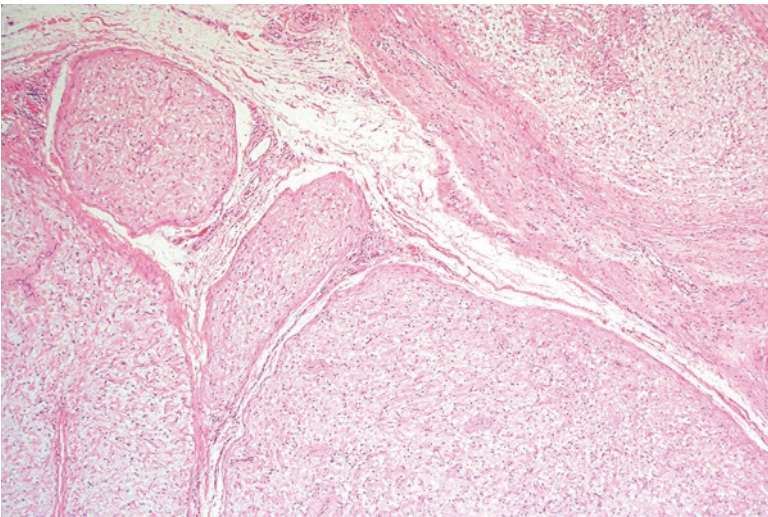
**Figs. 9.6 and 9.7** Neurofibroma with disorganized collagen and wavy nuclei. Some refer to the haphazard collagen arrangement as a “shredded carrot” appearance

### Pathology

These tumors contain a mixture of perineurial cells, fibroblasts, and Schwann cells. Microscopically, the sections show a haphazard arrangement of spindle cells with wavy nuclei and disorganized collagen fibers (Figs. 9.6 and 9.7). These tumors can be well circumscribed (Fig. 9.8), plexiform (Fig. 9.9), or diffusely infiltrative into surrounding soft tissue (Figs. 9.10 and 9.11) [7].



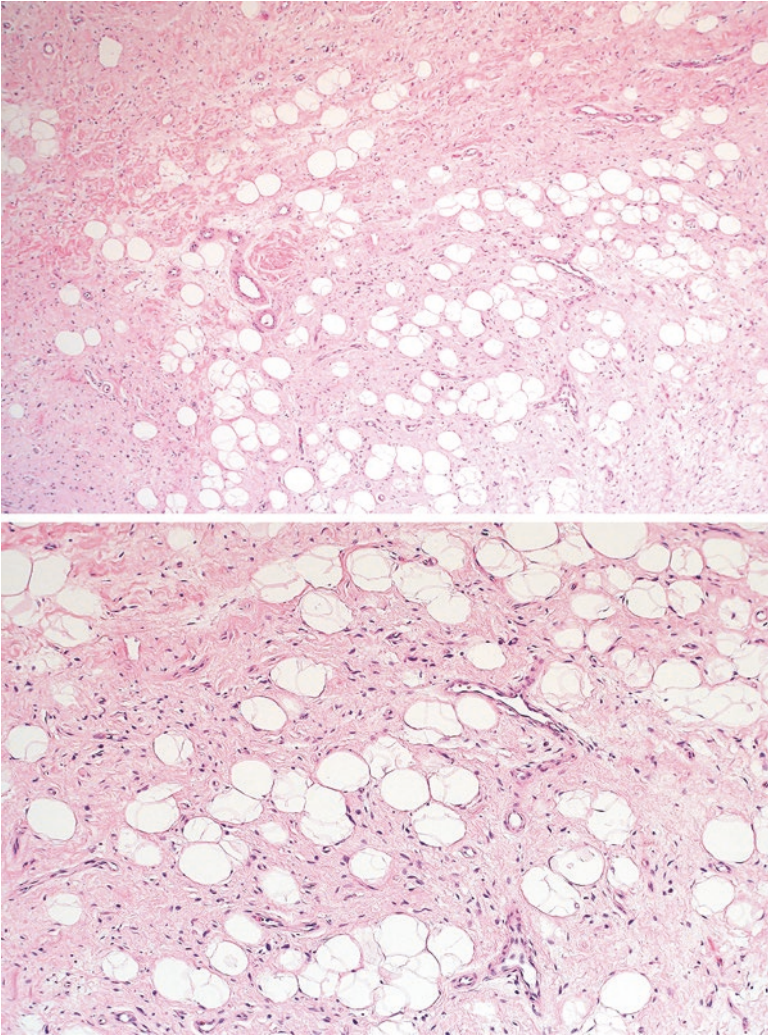
**Fig. 9.8** Well-circumscribed neurofibroma in the subcutaneous tissue



**Fig. 9.9** Plexiform neurofibroma with multiple well-circumscribed bundles of tumor cells pushing through the surrounding soft tissue

### Ancillary Studies

- The Schwann cells in neurofibroma are positive for S100. Additionally, an EMA stain highlights scattered perineurial cells and a neurofilament stain identifies scattered axons.



**Figs. 9.10 and 9.11** Diffuse neurofibroma with extensive infiltration into the adjacent adipose tissue

**Differential Diagnosis**

- Malignant peripheral nerve sheath tumor
- Schwannoma
- Perineurioma

## Comment

1. Because neurofibromas are composed of multiple cell types, these can be confused for other nerve sheath tumors, such as schwannoma, perineurioma, or malignant peripheral nerve sheath tumor.
2. Malignant peripheral nerve sheath tumor can sometimes arise from a neurofibroma, but the sections show more nuclear atypia, mitosis, and organized arrangement of spindle cells.
3. Schwannomas contain a more homogenous population of Schwann cells with associated hyalinized fibrosis.
4. Perineuriomas contain a more homogenous population of cells that are positive for EMA but negative for S100.
5. Neurofibromas with a plexiform architecture are highly suspicious for neurofibromatosis and should trigger appropriate clinical evaluation [7].
6. Timely diagnosis of NF1 can initiate appropriate clinical screening for malignant peripheral nerve sheath tumor, which often arises in patients with this syndrome [8].
7. Neurofibromas are usually benign and can be cured with simple excision. However, deeply situated neurofibromas in patients with NF1 occasionally transform to a much more aggressive malignant peripheral nerve sheath tumor and should be appropriately managed [5].

---

## 9.3 Perineurioma

Perineuriomas are neoplasms composed of the connective tissue cells that surround nerve bundles. These can occur in the gastrointestinal tract and subcutaneous or soft tissue. [9] Perineuriomas occurring in the soft tissue can be found in the extremities, trunk, or retroperitoneum, among other sites. These lesions average approximately 4.0 cm in size [10].

### Pathology

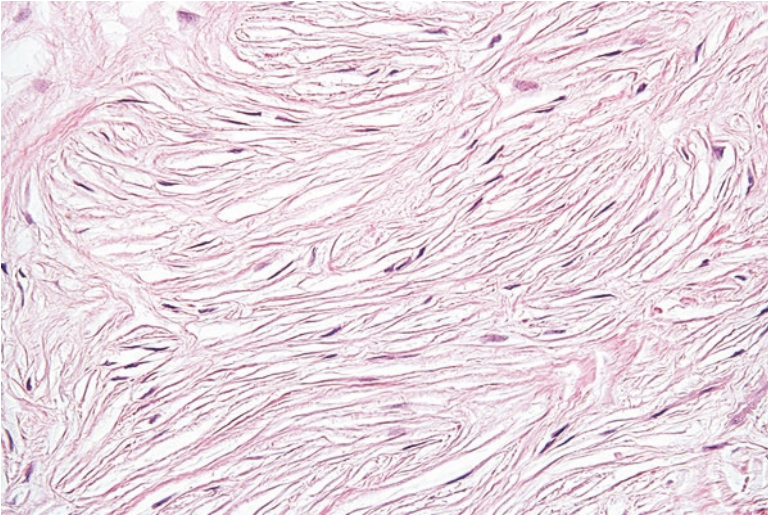
Perineuriomas are typically well-circumscribed lesions that contain spindle cells with slender and wavy nuclei (Fig. 9.12). The background stroma can be myxoid or collagenous in nature (Fig. 9.13). Often the cells will have long cytoplasmic extensions or a vague whorling (storiform) pattern (Fig. 9.14).

### Ancillary Studies

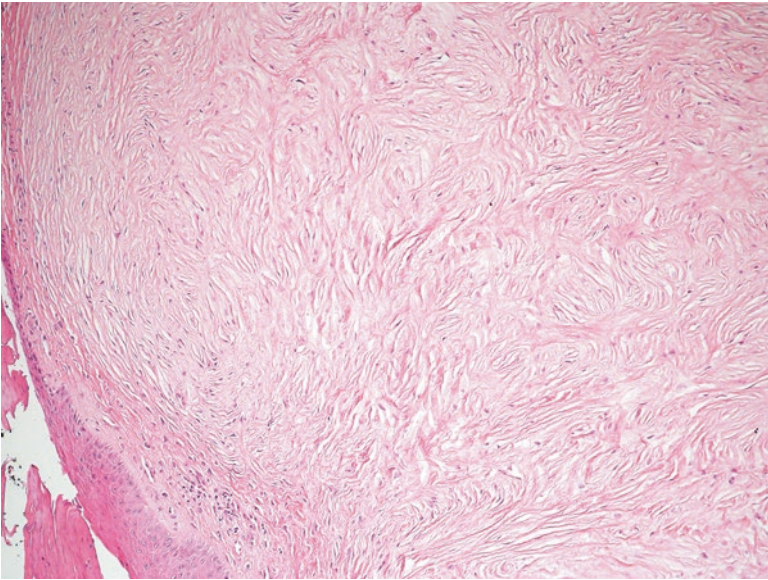
- Perineural cells often demonstrate focal or weak staining with EMA (Fig. 9.15).

### Differential Diagnosis

- Low-grade fibromyxoid sarcoma
- Solitary fibrous tumor



**Fig. 9.12** Perineurioma containing bland cells with elongated nuclei

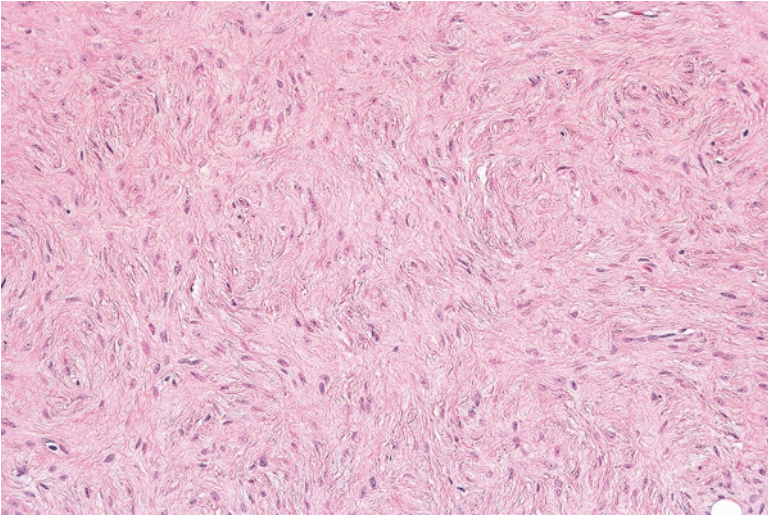


**Fig. 9.13** Perineurioma with extensive background fibrosis

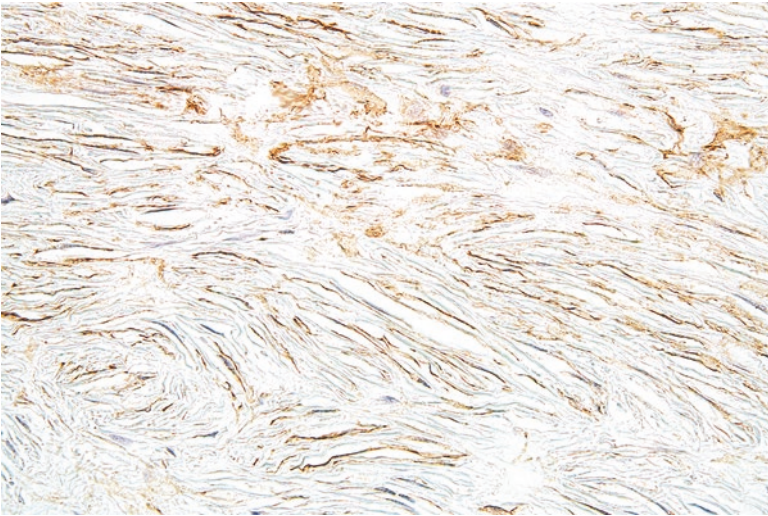
**Comment**

- With its fibrotic background, perineurioma can mimic other fibrosing tumors such as low-grade fibromyxoid sarcoma or solitary fibrous tumor.
- Unlike perineurioma, low-grade fibromyxoid sarcoma is positive for a MUC4 immunohistochemical stain.





**Fig. 9.14** Whorling pattern of tumor cells in a perineurioma



**Fig. 9.15** Positive EMA staining in a perineurioma highlights the elongated cytoplasmic processes of the cells

- A negative STAT6 immunohistochemical stain helps differentiate solitary fibrous tumor from perineurioma.
- Soft tissue perineuriomas are benign and rarely (less than 3%) recur following conservative excision [9, 10].

## 9.4 Granular Cell Tumor

Granular cell tumor is a neoplasm of neural differentiation that can arise in the skin or gastrointestinal tract (particularly the esophagus). They frequently present in the second to sixth decades of life, with the fourth decade being the most common period of occurrence [11].

### Pathology

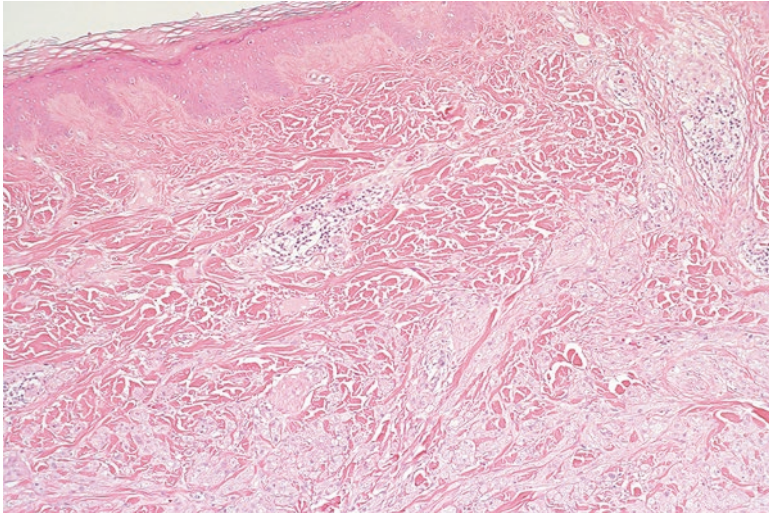
At low power, granular cell tumor has an infiltrative appearance (Fig. 9.16). True to the name, the cytoplasm of the tumor cells has an eosinophilic and granular appearance (Fig. 9.17). In the skin and esophagus, these neoplasms are often associated with changes in the overlying epidermis (pseudoeitheliomatous hyperplasia) that can be mistaken for squamous cell carcinoma (Fig. 9.18) [12].

### Ancillary Studies

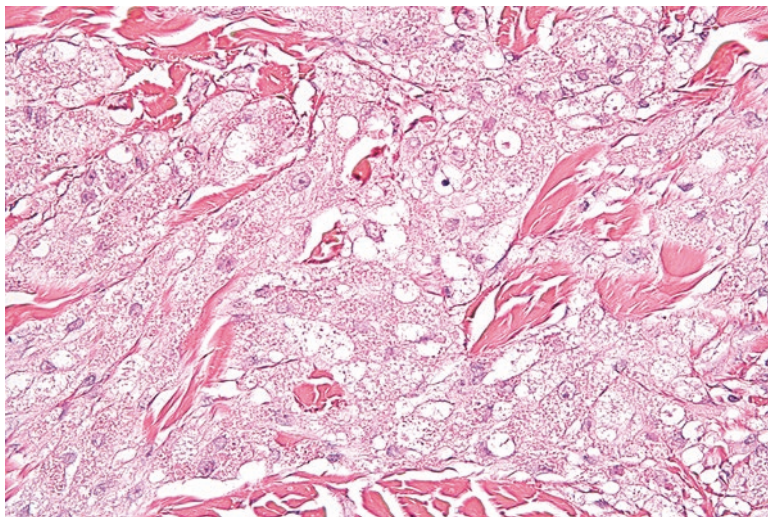
- The cells in granular cell tumor are commonly positive for S100, CD68, inhibin, and calretinin immunohistochemical stains [13].

### Differential Diagnosis

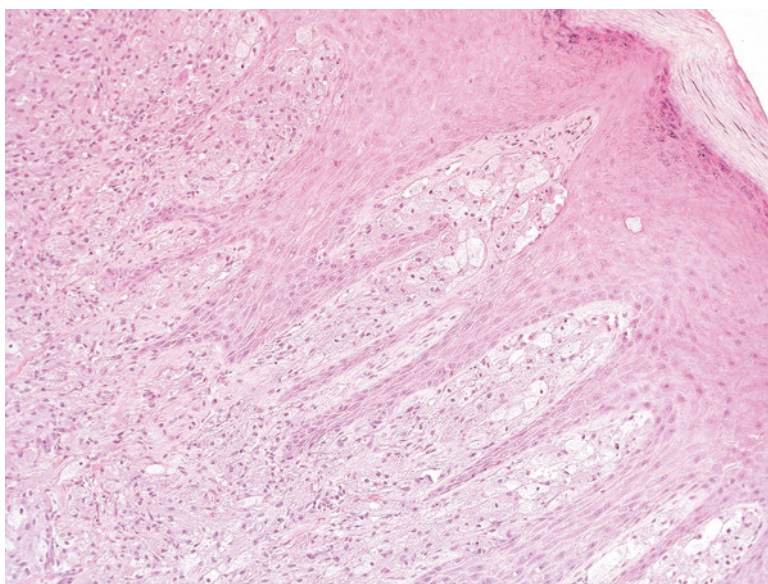
- Hibernoma
- Rhabdomyoma



**Fig. 9.16** Granular cell tumor in the skin infiltrating the dermal collagen fibers



**Fig. 9.17** Tumor cells in a granular cell tumor. The cytoplasm is eosinophilic and finely granular



**Fig. 9.18** Granular cell tumor with reactive changes in the overlying skin epithelium (pseudoepitheliomatous hyperplasia)

### Comments

1. Granular cell tumors can appear similar to other neoplasms with eosinophilic cytoplasm, such as hibernoma or rhabdomyoma.
2. Unlike rhabdomyomas, granular cell tumors are positive for S100 and are negative for desmin.

3. Hibernomas usually contain admixed adipocytes that distinguish them from granular cell tumor.
4. Granular cell tumors are typically benign and simple excision is curative. These tumors recur less than 10% of the time [14].
5. In very rare cases, granular cell tumors can be malignant. Malignant tumors show necrosis, spindling, vesicular nuclei, conspicuous nucleoli, increased mitosis, pleomorphism, and a high nuclear to cytoplasmic ratio [15].
6. Thirty-nine percent of patients with malignant granular cell tumor died after a 3-year follow-up [15].

---

## 9.5 Malignant Peripheral Nerve Sheath Tumor

Malignant peripheral nerve sheath tumor is a sarcoma that often arises around nerves, such as those in the brachial or sacral plexus. Although half of affected patients have a diagnosis of neurofibromatosis, tumors can arise sporadically or after radiation exposure [16]. The average age of diagnosis is approximately 40 years in patients without NF1 and 29 years in patients with NF1 [16, 17].

### Pathology

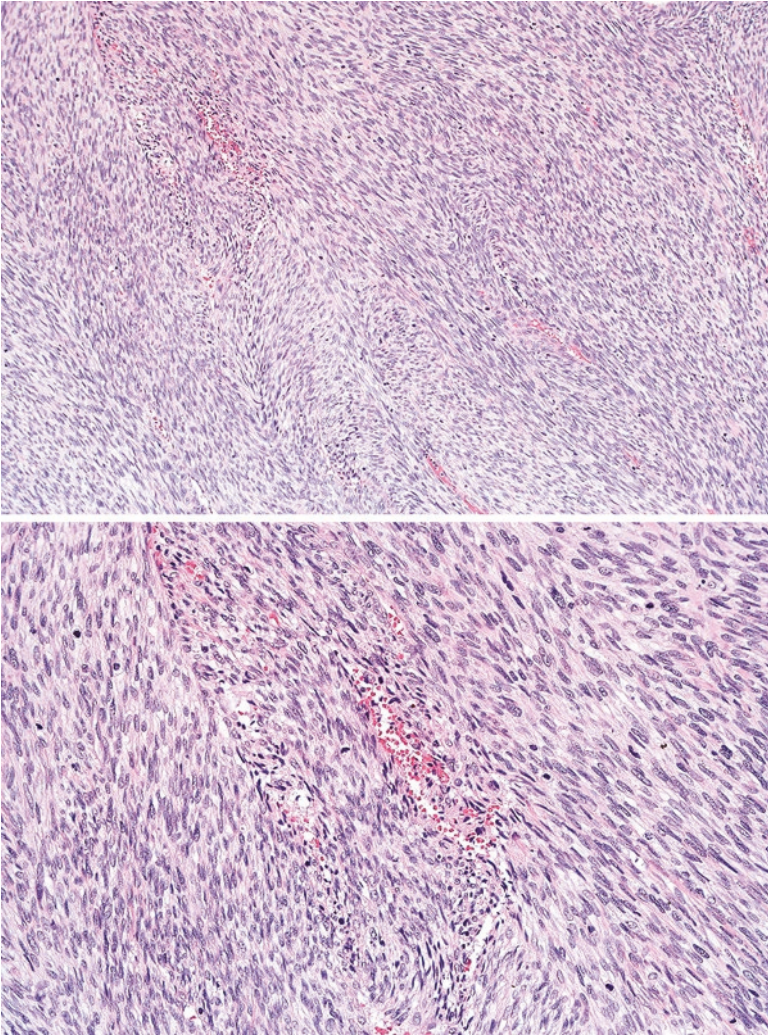
Under the microscope, malignant peripheral nerve sheath tumor demonstrates a fascicular arrangement of spindle cells with enlarged and hyperchromatic nuclei (Figs. 9.19 and 9.20). There is frequent mitosis and areas of necrosis can typically be seen. Subtle clues of nerve sheath differentiation may be identified, including nuclear palisading, perivascular whorling, or wavy nuclei (Fig. 9.21). Alternatively, an associated nerve or adjacent neurofibroma can also indicate nerve sheath differentiation [1].

### Ancillary Studies

- S100 may show focal weak staining in approximately half of high-grade malignant peripheral nerve sheath tumors. Strong and diffuse S100 staining is not usually seen.

### Differential Diagnosis

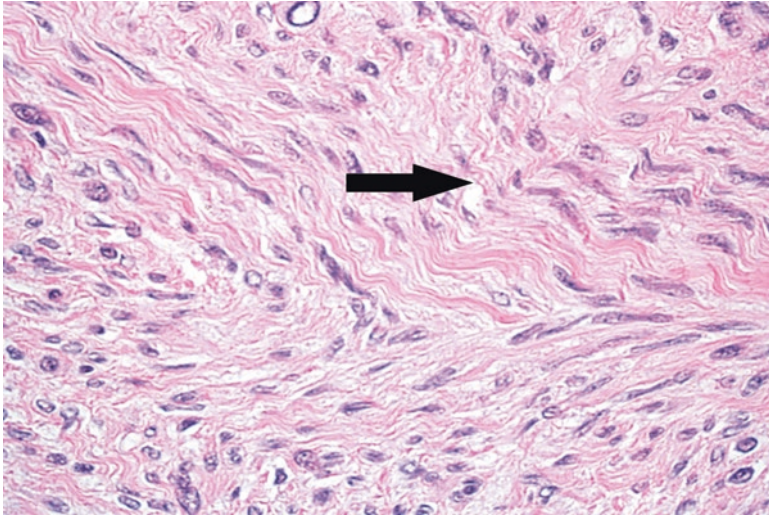
- Synovial sarcoma (monophasic type)
- Leiomyosarcoma
- Fibrosarcomatous variant of dermatofibrosarcoma protuberans



**Figs. 9.19 and 9.20** Malignant peripheral nerve sheath tumor with a fascicular architecture

### Comments

1. Given its fascicular architecture, high-grade malignant peripheral nerve sheath tumor can be mistaken for other spindle cell malignancies such as synovial sarcoma, leiomyosarcoma, and fibrosarcomatous variant of dermatofibrosarcoma protuberans.
2. Synovial sarcoma will often stain for TLE1 and demonstrates highly specific *SYT-SSX1* or *SYT-SSX2* fusion transcripts.
3. Leiomyosarcomas are positive for muscle markers such as desmin and caldesmon.



**Fig. 9.21** The tumor cells of the malignant peripheral nerve sheath tumor are wavy, suggesting nerve sheath differentiation (*arrow*)

4. Dermatofibrosarcoma usually demonstrates a *COL1A-PDGFB* fusion transcript.
5. If the tumor is negative for S100, clinical involvement of an associated nerve or neurofibroma component can help indicate nerve sheath differentiation of a malignant peripheral nerve sheath tumor.
6. Patients with neurofibromatosis have an 8–13% risk of developing a malignant peripheral nerve sheath tumor over the course of their lifetime [4].
7. High-grade malignant peripheral nerve sheath tumors are highly aggressive and frequently metastasize. The 5-year survival is approximately 34% [17].
8. Treatment consists of complete surgical excision and radiation therapy [5].

### Facts to Remember

1. Schwannomas are benign nerve sheath tumors composed of myelin-producing Schwann cells. Simple excision is generally curative.
2. Neurofibromas are benign; however, patients with multiple or plexiform neurofibromas should be assessed for neurofibromatosis.
3. Perineuriomas are benign neoplasms that can mimic other fibroblastic neoplasms.
4. Granular cell tumors are benign neural neoplasms that can arise in the skin or gastrointestinal tract. Their presence can elicit a reactive overlying epithelial proliferation that can be confused for a carcinoma.
5. Malignant peripheral nerve sheath tumor is typically a high-grade sarcoma with a poor prognosis. These tumors can arise in a neurofibroma and patients with NF1 are at particular risk.

## References

1. Fletcher CDM, Bridge JA, Hogendoorn PC, Mertens F, editors. Pathology and genetics of tumours of soft tissue and bone. 4th ed. Lyon: World Health Organization; 2013.
2. Goldblum J, Weiss S, Folpe AL, editors. Enzinger and Weiss's soft tissue tumors. 6th ed. Philadelphia: Elsevier; 2013.
3. MacCollin M, Woodfin W, Kronn D, Short MP. Schwannomatosis: a clinical and pathologic study. *Neurology*. 1996;46(4):1072–9.
4. Evans DG. Neurofibromatosis type 2 (NF2): a clinical and molecular review. *Orphanet J Rare Dis*.
5. Hornick JL, editor. Practical soft tissue pathology: a diagnostic approach. Philadelphia: Saunders; 2013.
6. Agaimy A, Vassos N, Croner RS. Gastrointestinal manifestations of neurofibromatosis type 1 (Recklinghausen's disease): clinicopathological spectrum with pathogenetic considerations. *Int J Clin Exp Pathol*. 2012;5(9):852–62.
7. McClatchey AI. Neurofibromatosis. *Annu Rev Pathol*. 2007;2:191–216.
8. Woodruff JM. Pathology of tumors of the peripheral nerve sheath in type 1 neurofibromatosis. *Am J Med Genet*. 1999;89(1):23–30.
9. Macarenco RS, Ellinger F, Oliveira AM. Perineurioma: a distinctive and underrecognized peripheral nerve sheath neoplasm. *Arch Pathol Lab Med*. 2007;131(4):625–36.
10. Hornick JL, Fletcher CD. Soft tissue perineurioma: clinicopathologic analysis of 81 cases including those with atypical histologic features. *Am J Surg Pathol*. 2005;29(7):845–58.
11. Lack EE, Worsham GF, Callihan MD, Crawford BE, Klappenbach S, Rowden G, et al. Granular cell tumor: a clinicopathologic study of 110 patients. *J Surg Oncol*. 1980;13(4):301–16.
12. Miettinen M, editor. Modern soft tissue pathology: tumors and non-neoplastic conditions. 1st ed. New York: Cambridge University Press; 2010.
13. Fine SW, Li M. Expression of calretinin and the alpha-subunit of inhibin in granular cell tumors. *Am J Clin Pathol*. 2003;119(2):259–64.
14. Strong EW, McDivitt RW, Brasfield RD. Granular cell myoblastoma. *Cancer*. 1970;25(2):415–22.
15. Fanburg-Smith JC, Meis-Kindblom JM, Fante R, Kindblom LG. Malignant granular cell tumor of soft tissue: diagnostic criteria and clinicopathologic correlation. *Am J Surg Pathol*. 1998;22(7):779–94.
16. Ducatman BS, Scheithauer BW, Piegras DG, Reiman HM, Ilstrup DM. Malignant peripheral nerve sheath tumors. A clinicopathologic study of 120 cases. *Cancer*. 1986;57(10):2006–21.
17. Zou C, Smith KD, Liu J, Lahat G, Myers S, Wang WL, et al. Clinical, pathological, and molecular variables predictive of malignant peripheral nerve sheath tumor outcome. *Ann Surg*. 2009;249(6)

Vascular lesions are primarily composed of the endothelial cells that line the arteries, veins, or lymphatics (Fig. 10.1a–c). Given the ubiquitous nature of these circulatory elements within the human body, it should come as no surprise that vascular neoplasms can arise in numerous anatomic locations.

Benign vascular lesions include numerous entities such as vascular malformations, reactive vascular proliferations, and hemangiomas. As multidisciplinary musculoskeletal groups tend to focus on the more aggressive vascular tumors in daily practice, this chapter will primarily discuss vascular tumors that are intermediate or malignant in behavior.

---

## **10.1 Kaposi Sarcoma**

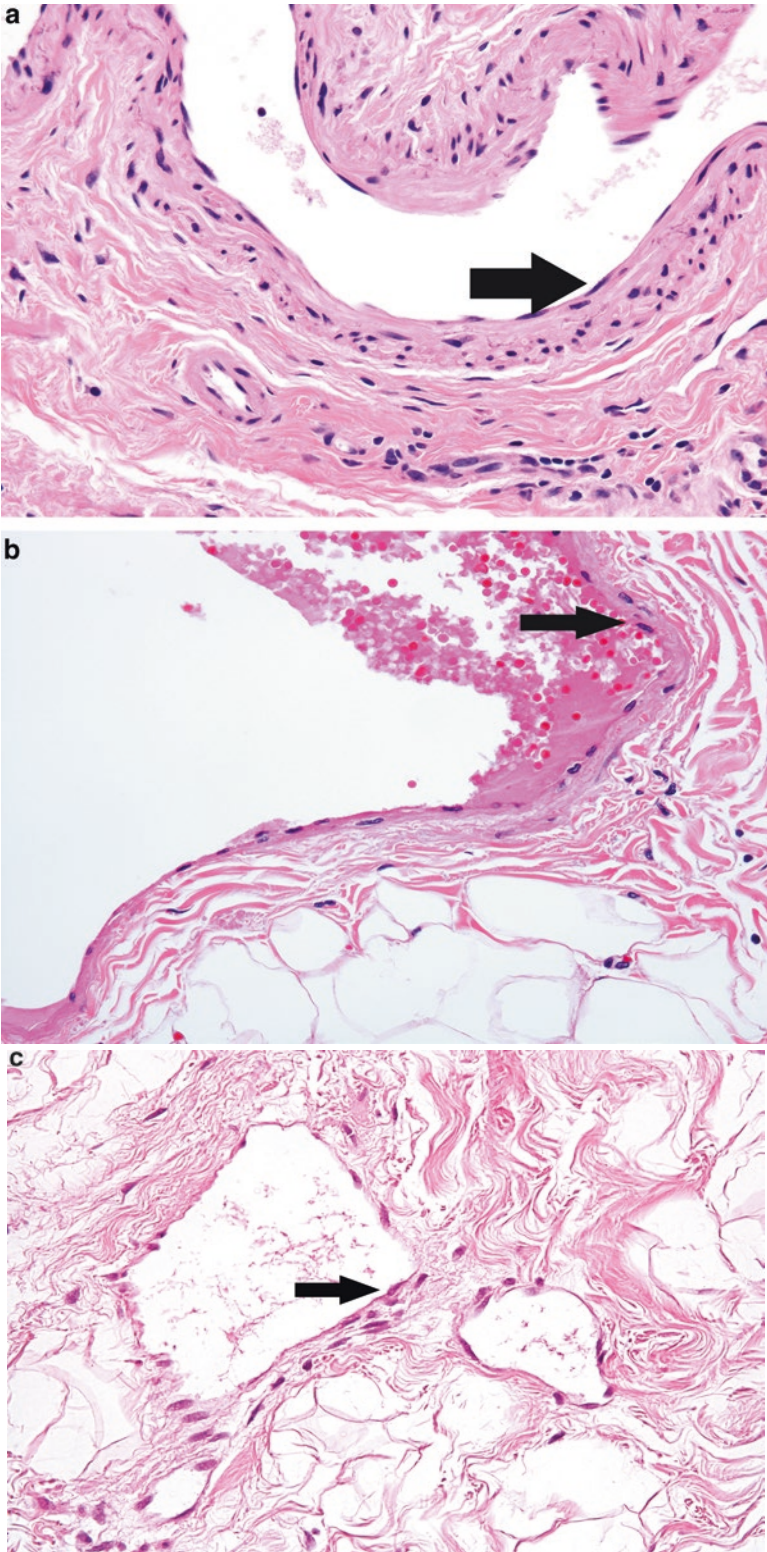
Kaposi sarcoma is a malignant vascular tumor that was frequently encountered in North America during the HIV epidemic. It can arise in multiple locations, such as the skin, lymph nodes, or gastrointestinal tract. This tumor is associated with the human herpes virus 8 (HHV-8) infection and is subcategorized based on clinical presentation.

In AIDS-related Kaposi sarcoma, the lesions occur in the skin, mucosal surfaces, and internal organs in patients with advanced HIV. In endemic (African) Kaposi sarcoma, the tumor presents in young African males as multiple enlarged lymph nodes. In classic Kaposi sarcoma, patients are typically men of African, Eastern, or Middle European descent that present with multiple blue cutaneous lesions. Iatrogenic (transplantation-related) Kaposi sarcoma can be seen in renal transplant patients [1].

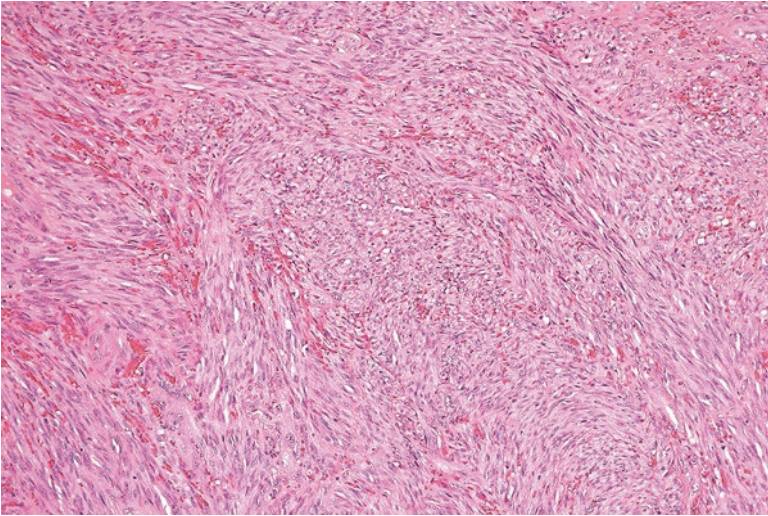
### **Pathology**

The microscopic appearance of Kaposi sarcoma depends on the stage of clinical progression. In the earliest (patch) stage of Kaposi sarcoma, the features are extremely subtle, with the skin showing a vague increase in dermal vascular spaces

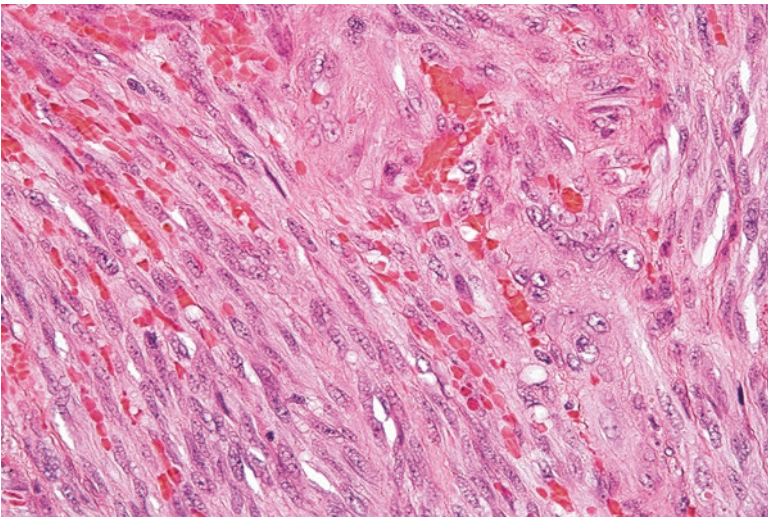




**Fig. 10.1** (a) Flat endothelial cells lining an arteriole (*arrow*). (b) Endothelial cells lining a vein (*arrow*). (c) Endothelial cells lining a lymphatic space (*arrow*)

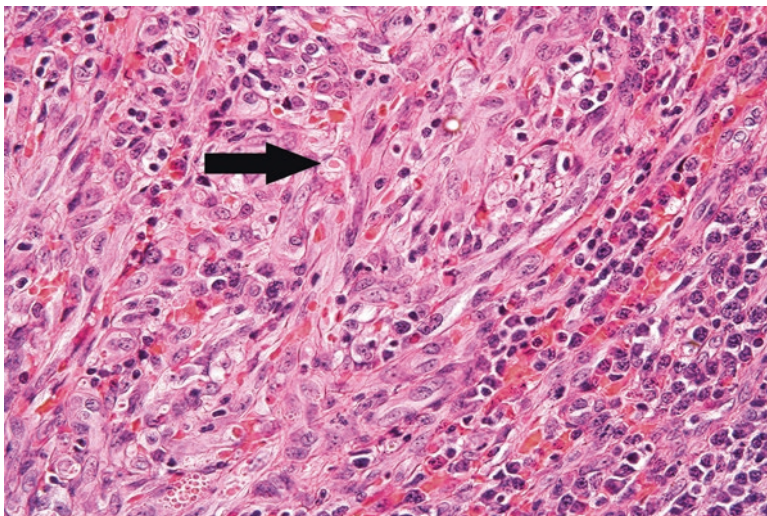


**Fig. 10.2** Spindle cells of a Kaposi sarcoma arranged in a fascicular architecture

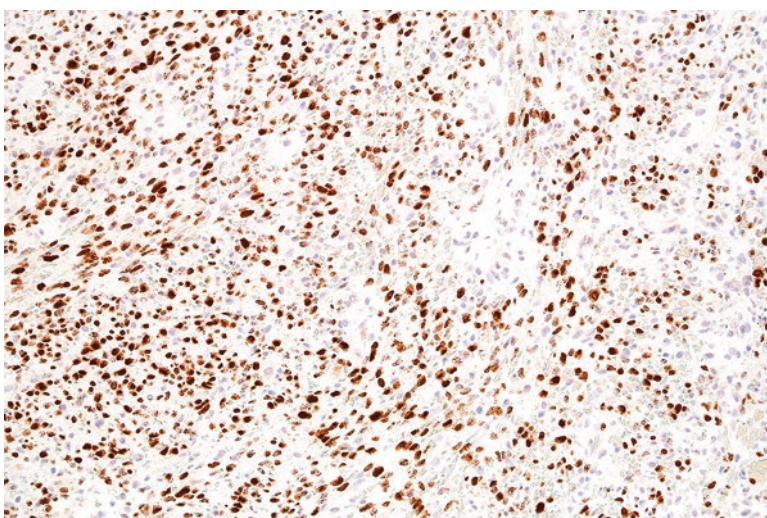


**Fig. 10.3** The spindle cells of this Kaposi sarcoma do not show extensive atypia

lined by bland endothelial cells and mild associated chronic inflammation. As this lesion progresses to the plaque stage, this neoplasm encompasses most of the dermis with the endothelial cells displaying a spindled appearance and a vaguely fascicular architecture (Figs. 10.2 and 10.3). Associated scattered round eosinophilic globules and chronic inflammatory cells can be seen (Fig. 10.4) [2].



**Fig. 10.4** Kaposi sarcoma has prominent chronic inflammation. Rare eosinophilic globules can also be identified (*arrow*)



**Fig. 10.5** Endothelial cells of Kaposi sarcoma are positive for LANA-1, consistent with HHV-8 infection

### Ancillary Studies

- Kaposi sarcomas are positive for endothelial cell markers such as CD31, CD34, and ERG.
- Latency-associated nuclear antigen (LANA-1) is associated with HHV-8 infection. Positive immunohistochemical staining for this protein in an endothelial lesion is both sensitive and specific for Kaposi sarcoma (Fig. 10.5) [3].

### Differential Diagnosis

- Angiosarcoma
- Spindle cell hemangioma

### Comment

1. The spindling nature of Kaposi sarcoma can be confused for angiosarcoma or spindle cell hemangioma. HHV-8 staining distinguishes Kaposi sarcoma from these other vascular tumors.
2. Appropriate suspicion based on the patient's clinical presentation (e.g. organ transplant, HIV) is helpful in assuring appropriate morphologic assessment and use of the HHV-8 stain.
3. If left untreated, AIDS-associated Kaposi sarcoma has a mortality rate of 90% [4].
4. In patients who have an intact immune system, Kaposi sarcoma has a mortality rate of approximately 10–20%.
5. Systemic therapy is used for persistent, metastatic, or systemic disease [4].
6. Kaposi sarcoma arising in HIV can be appropriately treated with HAART therapy. After the introduction of this treatment regimen, the incidence of AIDS and Kaposi sarcoma in North America has dramatically decreased [5].

---

## 10.2 Epithelioid Hemangioendothelioma

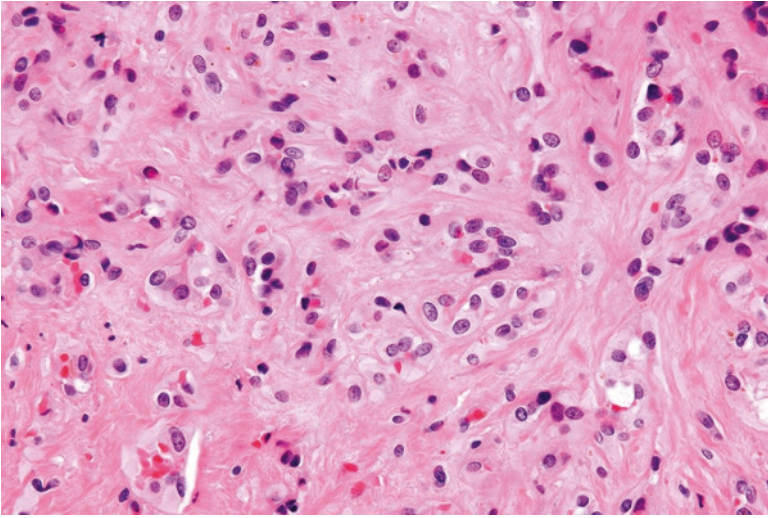
Epithelioid hemangioendothelioma is a malignant vascular tumor that often presents as a painful mass associated with a vessel. These occur in adults (median age of 50 years) and frequently arise in the extremities, head and neck, trunk, and mediastinum. Other sites of occurrence include the lung, bone, and liver [2, 6].

### Pathology

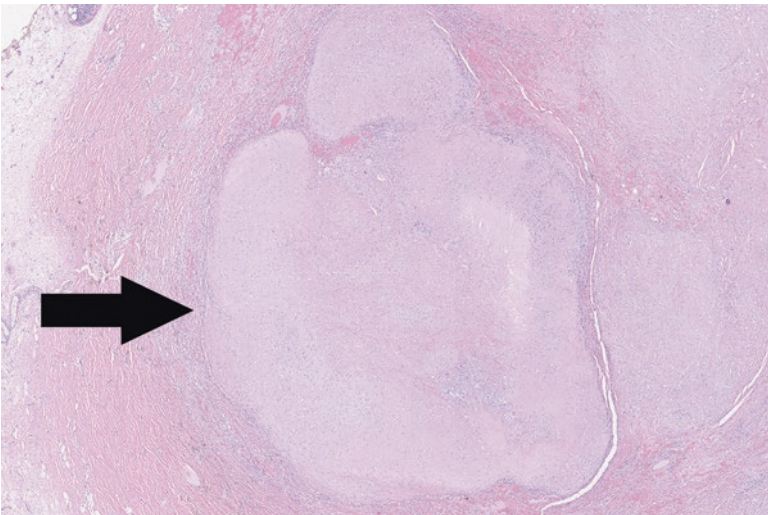
Microscopically, these tumors are composed of round to ovoid cells arranged in strands and sheets in the background of myxoid or hyalinized stroma (Fig. 10.6). These cells can obstruct and circumscribe a vascular space (Fig. 10.7). Intracellular lumens containing erythrocytes are often seen (Fig. 10.8) [7].

### Ancillary Studies

- Immunohistochemically, the tumor cells are positive for endothelial markers such as CD31, ERG, and CD34.
- Epithelioid hemangioendotheliomas show characteristic *WWTR1-CAMTA1* or *YAP1-TFE3* fusion transcripts.
- Epithelioid hemangioendotheliomas are often positive for an anti-CAMTA1 antibody [8].



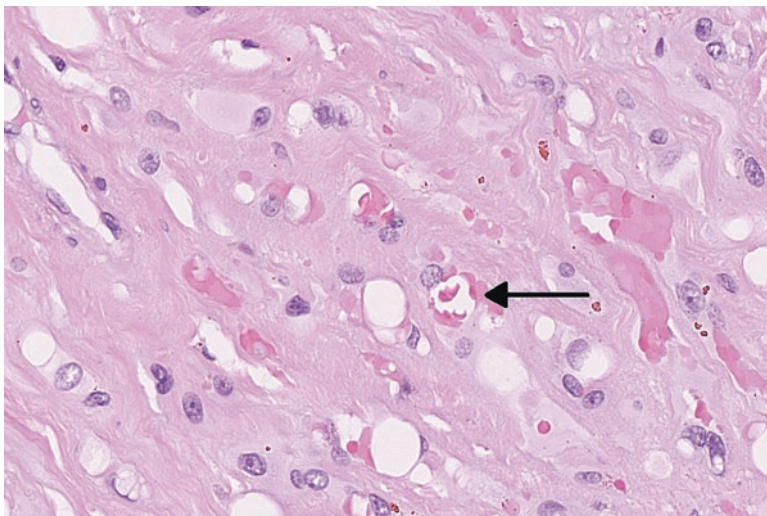
**Fig. 10.6** Neoplastic endothelial cells of epithelioid hemangioendothelioma in a myxoid and hyalinized background



**Fig. 10.7** Vein obstructed by tumor cells (*arrow*) of an epithelioid hemangioendothelioma

### Differential Diagnosis

- Epithelioid angiosarcoma
- Carcinoma
- Epithelioid hemangioma



**Fig. 10.8** Occasional erythrocytes are present in the intracellular lumens of this epithelioid hemangioendothelioma (*arrow*)

### Comment

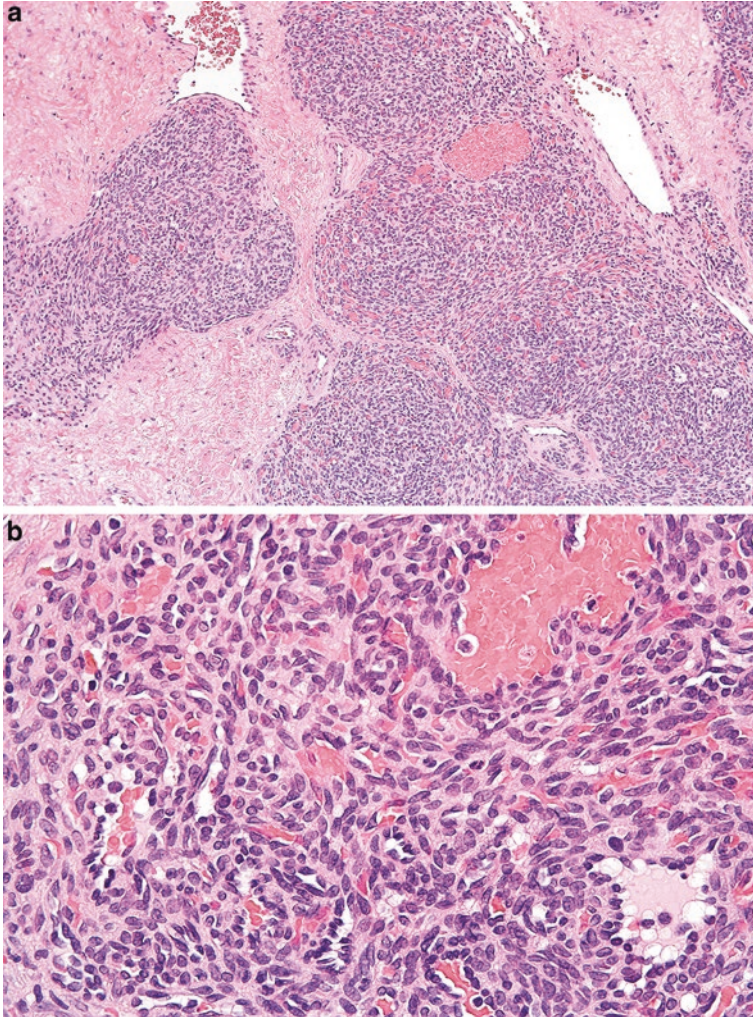
1. Epithelioid hemangioendothelioma can be mistaken for other epithelioid neoplasms such as epithelioid angiosarcoma, carcinoma, or epithelioid hemangioma.
2. Epithelioid angiosarcoma shows greater nuclear atypia and mitosis than epithelioid hemangioendothelioma. A positive anti-CAMTA1 antibody can be helpful in distinguishing the two lesions.
3. Epithelioid hemangioendotheliomas can focally stain for keratin stains such as AE1/AE3. However, carcinomas are virtually never positive for CD34 or other vascular markers.
4. Epithelioid hemangiomas typically have associated inflammation and lack the hyalinized or myxoid background seen in epithelioid hemangioendothelioma.
5. Overall, 20–30% of epithelioid hemangioendotheliomas metastasize, usually either to the lung or lymph node.
6. Consequently, these tumors are now considered malignant and have an overall 5-year survival rate of 80%.
7. However, tumors with less than three mitoses per 50 high power fields (hpf) and less than 3 cm in size demonstrate a 5-year disease-specific survival rate of 100% [9].

## 10.3 Kaposiform Hemangioendothelioma

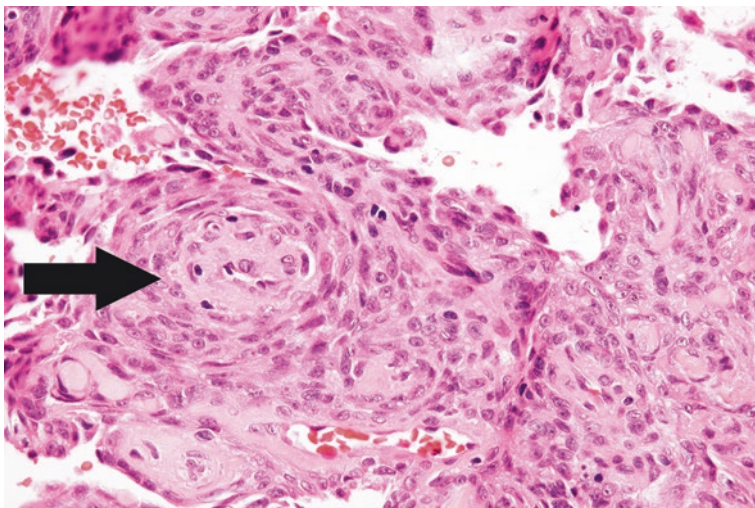
Kaposiform hemangioendothelioma is a vascular tumor that arises in the skin or soft tissues in early childhood or infancy. Clinically, they can appear as violaceous plaques or nodules in the soft tissue. This tumor can be associated with a consumptive thrombocytopenia and coagulopathy, known as Kasabach-Merritt syndrome [10].

**Pathology**

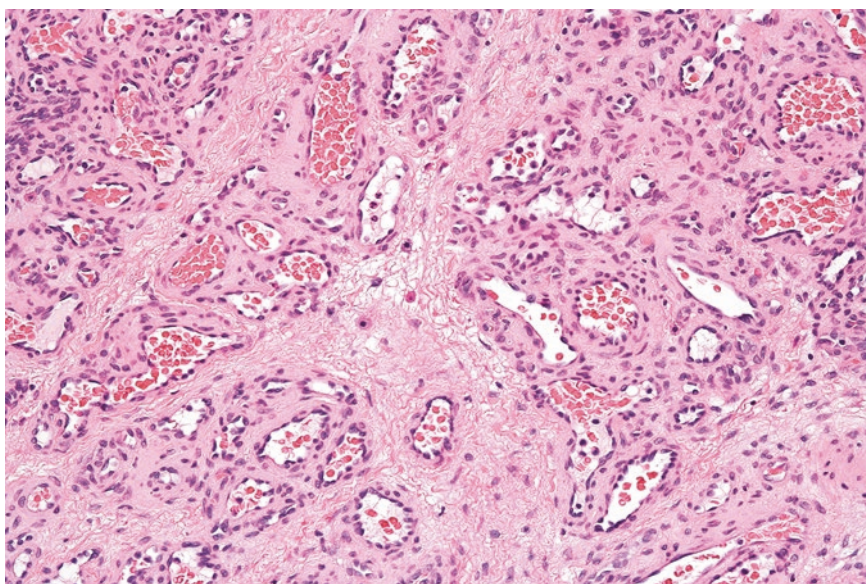
These tumors are composed of prominent lobules of endothelial cells in the background of dense fibrous tissue (Fig. 10.9). Closer examination reveals the cells to be spindle-shaped, reminiscent of Kaposi sarcoma (Fig. 10.9b). These foci of spindle cells can occasionally form glomeruloid-like structures (Fig. 10.10). Other areas show a lobular arrangement of vascular spaces reminiscent of a lobular hemangioma (Fig. 10.11) [11].



**Fig. 10.9** (a) Endothelial cells of a kaposiform hemangioendothelioma arranged in a lobular pattern in the background of fibrous tissue. (b) Kaposiform hemangioendothelioma with spindling of the endothelial cells



**Fig. 10.10** Glomeruloid-like structures of endothelial cells in a kaposiform hemangioendothelioma (*arrow*)



**Fig. 10.11** Areas of kaposiform hemangioendothelioma showing a lobular arrangement of vascular spaces reminiscent of an infantile hemangioma

### Ancillary Studies

- The cells are positive for endothelial markers such as CD31 and CD34.
- The cells are negative for HHV-8 and lack staining for GLUT-1.



## Differential Diagnosis

- Kaposi sarcoma
- Infantile hemangioma

## Comment

1. Kaposiform hemangioendothelioma shows features similar to Kaposi sarcoma and infantile hemangioma.
2. The endothelial cells of infantile hemangioma can be densely packed; however, these lack spindling and are positive for a GLUT-1 immunohistochemical stain.
3. Although areas of kaposiform hemangioendothelioma can show spindling similar to Kaposi sarcoma, the cells of Kaposi sarcoma are positive for HHV-8.
4. Unlike infantile hemangioma, kaposiform hemangioendothelioma does not spontaneously regress and generally requires surgical resection or a combination of medical therapies for treatment.
5. The mortality rate of kaposiform hemangioendothelioma is approximately 10%. Death often occurs secondary to thrombocytopenia or local extension of the tumor [2, 11].

---

## 10.4 Angiosarcoma

Angiosarcomas are highly malignant soft tissue sarcomas whose characteristics and behavior depend on the nature of their clinical presentation.

Primary cutaneous angiosarcoma often arises as single or multiple lesions in the superficial skin in the head and neck area of elderly patients [12].

Angiosarcoma can arise in association with long-standing lymphedema (Stewart-Treves syndrome), which is often secondary to axillary lymph node dissection or mastectomy for a breast malignancy [13].

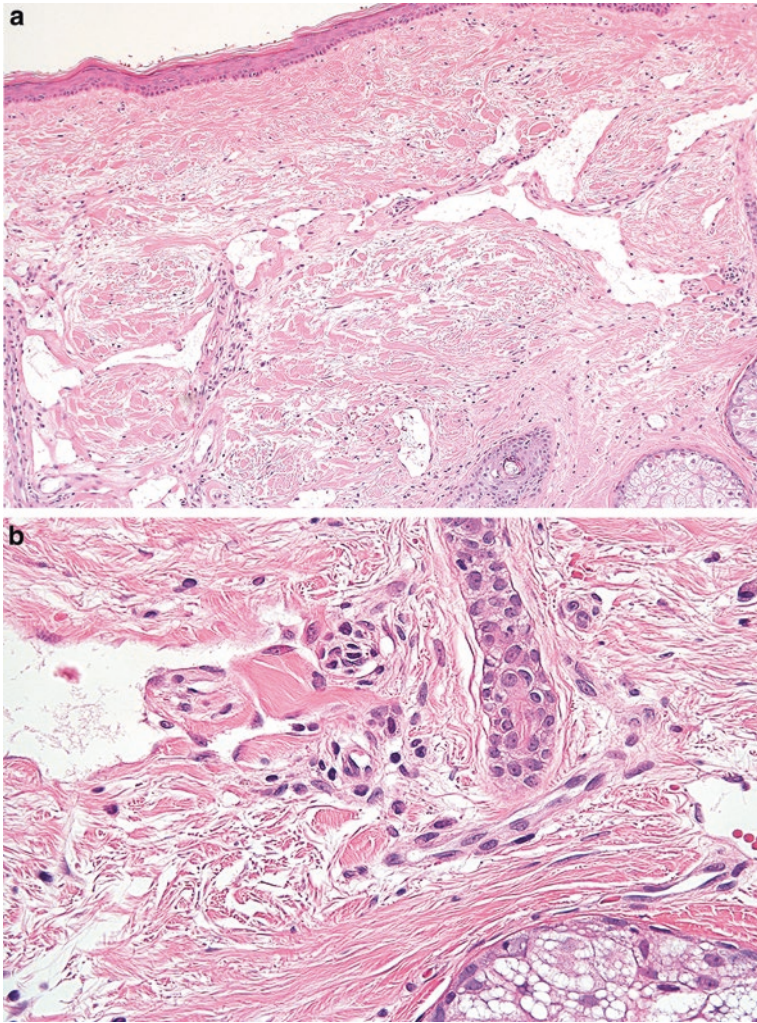
Primary angiosarcoma of the breast typically arises in women in the third or fourth decade of life [14].

Postirradiation angiosarcoma is the most common soft tissue malignancy to arise as a consequence of radiation therapy. With the common use of radiation as adjuvant treatment for mammary carcinomas, the breast is the most common site of occurrence [15].

Soft tissue angiosarcomas can arise in the deep soft tissue of the extremities, trunk, and head and neck area [16].

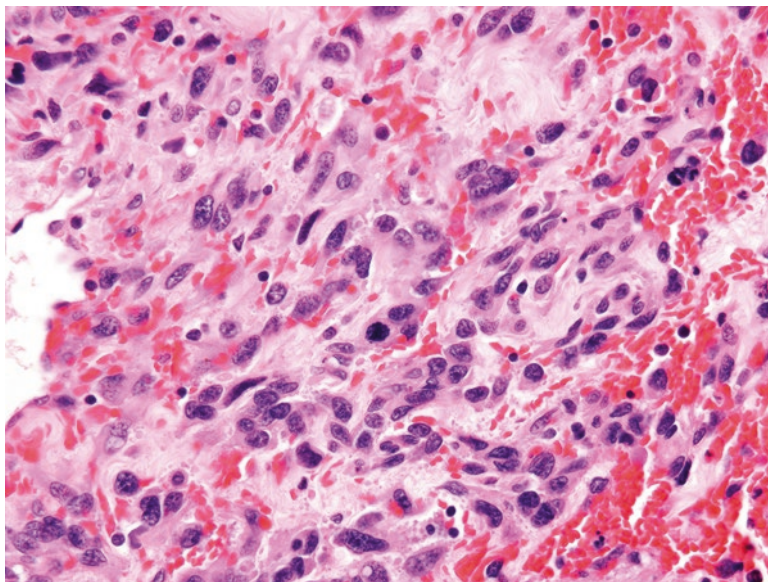
## Pathology

On gross examination, cutaneous angiosarcomas often have a violet appearance. In the soft tissue, these can appear as hemorrhagic masses. Microscopically, these tumors usually manifest their endothelial differentiation by forming infiltrating vascular channels in cutaneous or soft tissue (Fig. 10.12a, b). Endothelial cells with



**Fig. 10.12** (a) Well-differentiated angiosarcoma with irregular vascular channels coursing through subepithelial collagen. (b) Although there is little cytologic atypia, the vascular channels invade through collagen and adnexal structures, indicating their malignant nature

nuclear hyperchromasia and mitoses are typically seen (Fig. 10.13). As the tumor becomes less differentiated, the tumor cells no longer form vascular channels and infiltrate as sheets of epithelioid or spindle cells (Fig. 10.14a–c).



**Fig. 10.13** The endothelial cells of an angiosarcoma with multilayering and nuclear atypia

### Ancillary Studies

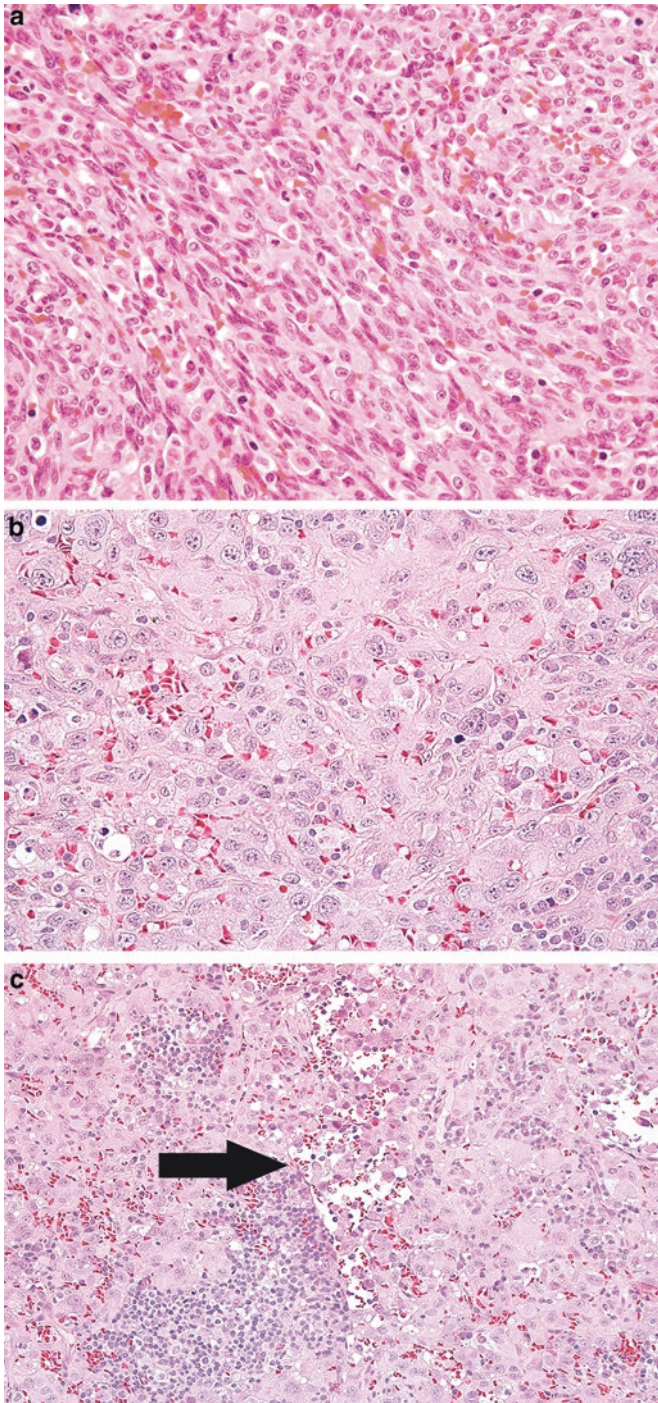
- Angiosarcomas usually stain for endothelial markers such as CD31, CD34, FLI-1, and ERG.
- *MYC* gene amplification is consistently seen in postirradiation-associated angiosarcomas.

### Differential Diagnosis

- Carcinoma
- Hemangioma

### Comments

1. Difficulties in diagnosing angiosarcomas tend to occur when these tumors are either very well or poorly differentiated.
2. Poorly differentiated angiosarcomas with an epithelioid morphology can be confused for primary or metastatic carcinoma, as these can also stain for epithelial markers such as cytokeratin or EMA.
3. Careful search for a vascular-like architecture and use of endothelial immunohistochemical stains such as CD31 or CD34 can help differentiate angiosarcomas from epithelial malignancies.
4. Well-differentiated angiosarcoma can sometimes show limited cellular atypia and be mistaken for normal blood vessels or a benign hemangioma.



**Fig. 10.14** (a) Poorly differentiated angiosarcoma with a spindled appearance. (b) Poorly differentiated angiosarcoma with sheets of epithelioid cells. (c) Poorly differentiated angiosarcoma with only a subtle vasoformative architecture that hints at the tumor's endothelial nature (*arrow*)

5. However, well-differentiated angiosarcomas typically have a more infiltrative pattern than hemangioma.
6. Given the subtle features of these tumors, frozen sections are not useful for intra-operative assessment of the surgical margins in resections of angiosarcoma [17].
7. Cutaneous angiosarcoma has a 5-year disease-specific survival of 12–48% [12, 18].
8. Angiosarcoma associated with lymphedema from previous mastectomy has been noted to have a 50% survival over 19 months [19].
9. The reported outcome for postirradiation angiosarcoma has been highly variable [20, 21].
10. At least 60% of patients with breast primary angiosarcoma develop metastatic disease [14].
11. Angiosarcomas of the soft tissue are particularly aggressive. Approximately 53% of patients die within the first year [16].
12. Complete surgical resection is the primary treatment for angiosarcomas. Often adjuvant radiation therapy is administered for close margins [22].

### Facts to Remember

1. Kaposi sarcoma is an aggressive vascular tumor that is associated with HHV-8 infection. In patients with AIDS, effective therapy includes appropriate HAART therapy for the patient's underlying HIV.
2. Epithelioid hemangioendothelioma is a malignant vascular tumor in which the neoplastic cells have a rounded or oval appearance. Although 20–30% of these tumors metastasize, tumors with less than three mitosis per 50 hpf and less than 3 cm in size have a 5-year disease-specific survival rate of 100%.
3. Kaposiform hemangioendothelioma is an aggressive vascular tumor that can mimic an infantile hemangioma or Kaposi sarcoma.
4. Kaposiform hemangioendothelioma is often associated with thrombocytopenia.
5. Angiosarcoma is a vascular tumor that has different clinical presentations. Subtypes include primary cutaneous angiosarcoma, angiosarcoma in association with lymphedema, primary angiosarcoma of the breast, postirradiation angiosarcoma, and soft tissue angiosarcoma.
6. Overall, angiosarcomas are highly malignant and primary treatment consists of surgical resection with possible adjuvant radiation therapy.
7. Frozen sections are not particularly useful in assessing margin involvement by an angiosarcoma.

---

### References

1. Pantanowitz L, Dezube BJ. Advances in the pathobiology and treatment of Kaposi sarcoma. *Curr Opin Oncol*. 2004;16(5):443–9.
2. Hornick JL, editor. *Practical soft tissue pathology: a diagnostic approach*. 1st ed. Philadelphia: Saunders; 2013.

3. Patel RM, Goldblum JR, Hsi ED. Immunohistochemical detection of human herpes virus-8 latent nuclear antigen-1 is useful in the diagnosis of Kaposi sarcoma. *Mod Pathol.* 2004;17(4):456–60.
4. Goldblum J, Weiss S, Folpe AL, editors. *Enzinger and Weiss's soft tissue tumors.* 6th ed. Philadelphia: Elsevier; 2013.
5. Uldrick TS, Whitby D. Update on KSHV epidemiology, Kaposi sarcoma pathogenesis, and treatment of Kaposi sarcoma. *Cancer Lett.* 2011;305(2):150–62.
6. Mentzel T, Beham A, Calonje E, Katenkamp D, Fletcher CD. Epithelioid hemangioendothelioma of skin and soft tissues: clinicopathologic and immunohistochemical study of 30 cases. *Am J Surg Pathol.* 1997;21(4):363–74.
7. Weiss SW, Enzinger FM. Epithelioid hemangioendothelioma: a vascular tumor often mistaken for a carcinoma. *Cancer.* 1982;50(5):970–81.
8. Doyle LA, Fletcher CD, Hornick JL. Nuclear expression of CAMTA1 distinguishes epithelioid hemangioendothelioma from histologic mimics. *Am J Surg Pathol.* 2016;40(1):94–102.
9. Deyrup AT, Tighiouart M, Montag AG, Weiss SW. Epithelioid hemangioendothelioma of soft tissue: a proposal for risk stratification based on 49 cases. *Am J Surg Pathol.* 2008;32(6):924–7.
10. Zukerberg LR, Nickoloff BJ, Weiss SW. Kaposiform hemangioendothelioma of infancy and childhood. An aggressive neoplasm associated with Kasabach-Merritt syndrome and lymphangiomas. *Am J Surg Pathol.* 1993;17(4):321–8.
11. Lyons LL, North PE, Mac-Moune Lai F, Stoler MH, Folpe AL, Weiss SW. Kaposiform hemangioendothelioma: a study of 33 cases emphasizing its pathologic, immunophenotypic, and biologic uniqueness from juvenile hemangioma. *Am J Surg Pathol.* 2004;28(5):559–68.
12. Deyrup AT, McKenney JK, Tighiouart M, Folpe AL, Weiss SW. Sporadic cutaneous angiosarcomas: a proposal for risk stratification based on 69 cases. *Am J Surg Pathol.* 2008;32(1):72–7.
13. Heitmann C, Ingianni G, Stewart-Treves syndrome: lymphangiosarcoma following mastectomy. *Ann Plast Surg.* 2000;44(1):72–5.
14. Nascimento AF, Raut CP, Fletcher CD. Primary angiosarcoma of the breast: clinicopathologic analysis of 49 cases, suggesting that grade is not prognostic. *Am J Surg Pathol.* 2008;32(12):1896–904.
15. Billings SD, McKenney JK, Folpe AL, Hardacre MC, Weiss SW. Cutaneous angiosarcoma following breast-conserving surgery and radiation: an analysis of 27 cases. *Am J Surg Pathol.* 2004;28(6):781–8.
16. Meis-Kindblom JM, Kindblom LG. Angiosarcoma of soft tissue: a study of 80 cases. *Am J Surg Pathol.* 1998;22(6):683–97.
17. Pawlik TM, Paulino AF, McGinn CJ, Baker LH, Cohen DS, Morris JS, et al. Cutaneous angiosarcoma of the scalp: a multidisciplinary approach. *Cancer.* 2003;98(8):1716–26.
18. Holden CA, Spittle MF, Jones EW. Angiosarcoma of the face and scalp, prognosis and treatment. *Cancer.* 1987;59(5):1046–57.
19. Woodward AH, Ivins JC, Soule EH. Lymphangiosarcoma arising in chronic lymphedematous extremities. *Cancer.* 1972;30(2):562–72.
20. Rao J, Dekoven JG, Beatty JD, Jones G. Cutaneous angiosarcoma as a delayed complication of radiation therapy for carcinoma of the breast. *J Am Acad Dermatol.* 2003;49(3):532–8.
21. Strobbe LJ, Peterse HL, van Tinteren H, Wijnmaalen A, Rutgers EJ. Angiosarcoma of the breast after conservation therapy for invasive cancer, the incidence and outcome. An unforeseen sequela. *Breast Cancer Res Treat.* 1998;47(2):101–9.
22. Abraham JA, Hornicek FJ, Kaufman AM, Harmon DC, Springfield DS, Raskin KA, et al. Treatment and outcome of 82 patients with angiosarcoma. *Ann Surg Oncol.* 2007;14(6):1953–67.

Although usually associated with the bone, tumors with osteoid or chondroid matrix can occur in the soft tissue and are primarily identified by their associated matrix material. Chondroid material has an amorphous eosinophilic to basophilic appearance (Fig. 11.1). The unmineralized part of the bone known as osteoid has an eosinophilic appearance (Fig. 11.2).

---

## 11.1 Extraskkeletal Chondroma

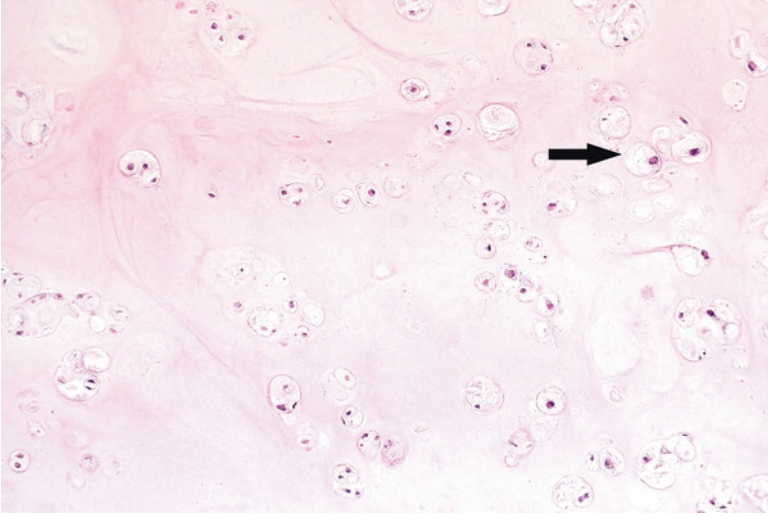
Extraskkeletal chondroma is a lesion that most often occurs as a slow growing soft tissue nodule in the fingers, toes, and hands and feet of adults in the third and fourth decades of life [1]. On radiologic examination, these neoplasms will display punctate or curvilinear patterns of calcification characteristic of cartilaginous matrix [2].

### Pathology

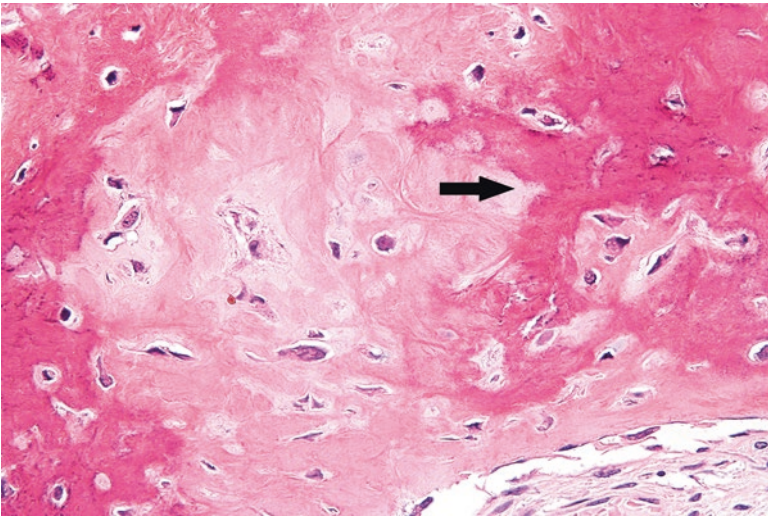
On gross examination, these are well-circumscribed and lobulated lesions that are typically less than 3 cm in size. Microscopically, they are primarily composed of hyalinized cartilage that surrounds bland chondrocytes (Fig. 11.3). Focal areas of myxoid change (Fig. 11.4) and calcification (Fig. 11.5) can be identified [1, 3].

### Ancillary Studies

- Although soft tissue chondromas can stain for S-100, the diagnosis is primarily based on the identification of chondroid matrix on an H&E slide.



**Fig. 11.1** Chondroid material with a variably blue and pink appearance. Scattered benign chondrocytes are present (*arrow*)

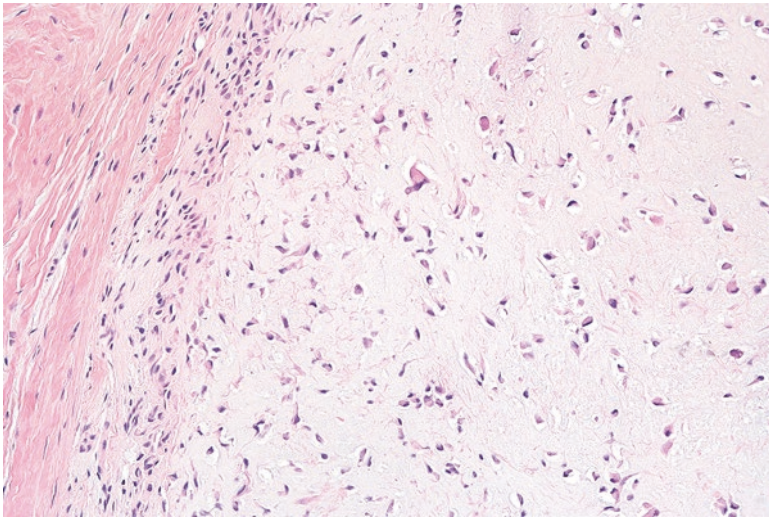


**Fig. 11.2** Dense eosinophilic osteoid material with areas of early calcification (*arrow*) in an extraskeletal osteosarcoma

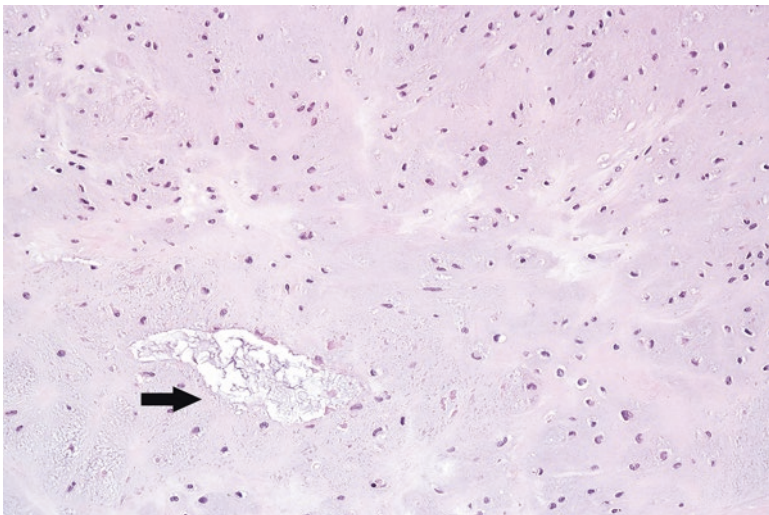
### Differential Diagnosis

- Synovial chondromatosis
- Enchondroma





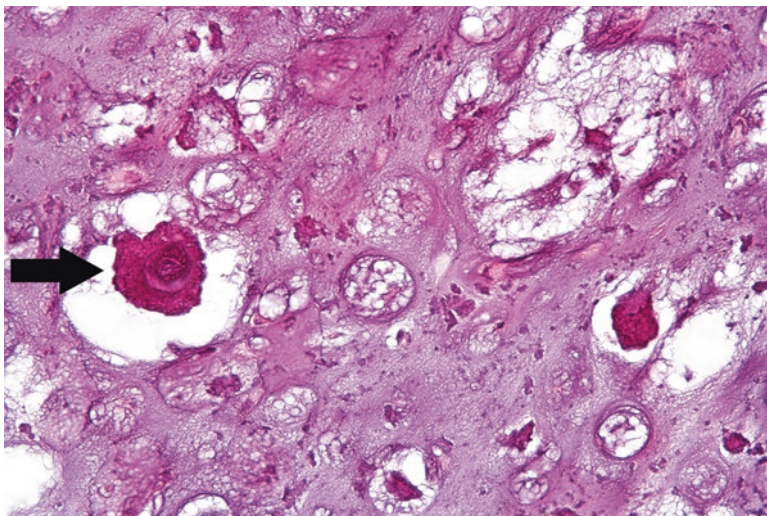
**Fig. 11.3** Soft tissue chondroma with mildly increased chondrocytes in the background of a chondroid matrix



**Fig. 11.4** Focal myxoid changes (*arrow*) in the cartilaginous matrix of a soft tissue chondroma

### Comments

1. Soft tissue chondromas can be confused with other cartilaginous tumors such as synovial chondromatosis or enchondroma.
2. Synovial chondromatosis usually arises within the intra-articular space of large joints such as the knee. Instead of a solitary well-circumscribed nodule, synovial chondromatosis manifests as multiple cartilaginous nodules associated with the synovial membrane.



**Fig. 11.5** Scattered areas of calcification in the chondroid matrix of a soft tissue chondroma. These correspond to the punctate calcifications seen on radiologic imaging

3. Unlike soft tissue chondroma, enchondroma arises within the bone. Correlation with the radiologic findings helps the pathologist determine whether the lesion arises in the bone or soft tissue.
4. Soft tissue chondromas are benign tumors. Approximately 15% will recur [4].
5. These are generally treated with local excision.

---

## 11.2 Extraskelletal Mesenchymal Chondrosarcoma

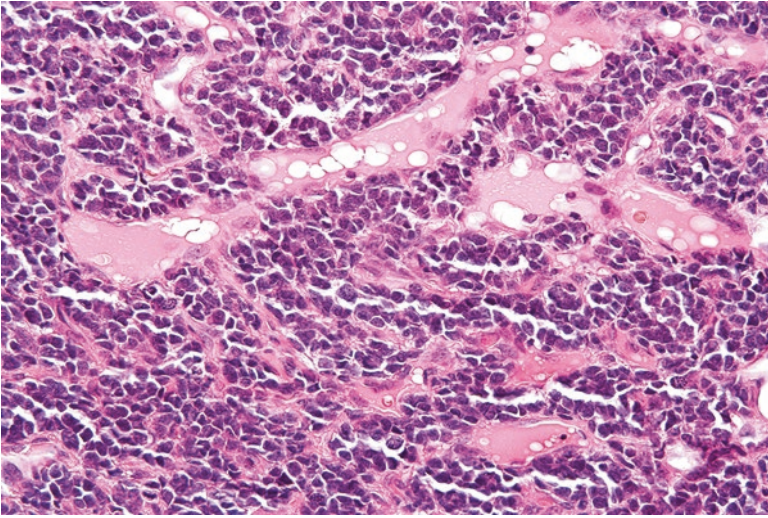
Extraskelletal mesenchymal chondrosarcoma is a malignancy that most frequently arises in young adults in the second to fourth decades of life [5]. Although this neoplasm most frequently arises in the bone, a minority of cases can present in soft tissue sites such as the head and neck, meninges, and thigh [6].

### Pathology

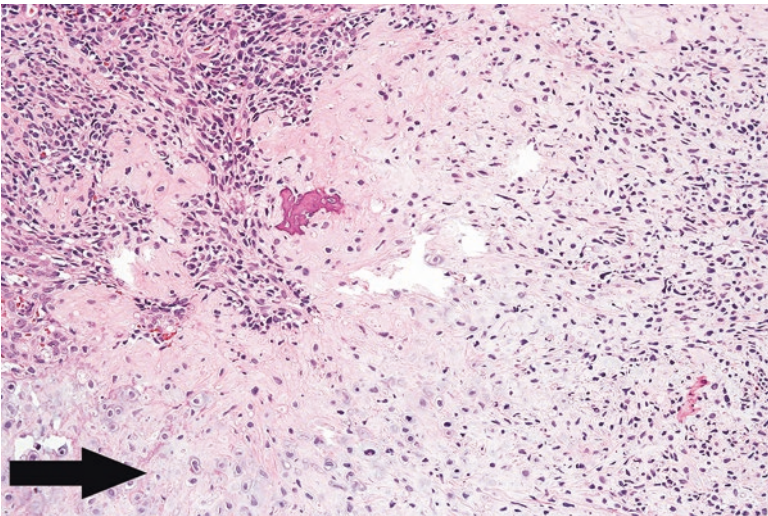
These tumors grossly appear as lobulated and circumscribed masses. Microscopically, they are composed of round cells with scant cytoplasm. A background pattern of branching vessels is present (Fig. 11.6). Focal areas of the tumor show a more mature cartilaginous matrix (Fig. 11.7) [7].

### Ancillary Studies

- An immunohistochemical stain for SOX-9, a regulator of chondrogenesis, is consistently positive in mesenchymal chondrosarcoma [8].
- The *HEY1-NCOA2* fusion transcript has been consistently detected in mesenchymal chondrosarcomas, which can be used to confirm the diagnosis [9].



**Fig. 11.6** Immature portions of an extraskeletal mesenchymal chondrosarcoma. The tumor is composed of “small cells” with scattered vessels



**Fig. 11.7** Focal areas of chondroid matrix in a mesenchymal chondrosarcoma (*arrow*)

### Differential Diagnosis

- Ewing sarcoma
- Synovial sarcoma
- Metastatic extraskeletal mesenchymal chondrosarcoma of the bone

## Comments

1. Extraskelatal mesenchymal chondrosarcoma can be mistaken for other “small round cell” tumors such as poorly differentiated synovial sarcoma or Ewing sarcoma.
2. Immunohistochemistry for SOX-9 and molecular studies for *HEY1-NCOA2* can distinguish this neoplasm from these other entities.
3. Radiologic imaging can be used to exclude a primary extraskelatal mesenchymal chondrosarcoma of the bone that has metastasized to the soft tissue.
4. This tumor is an aggressive soft tissue malignancy with a 5-year survival of approximately 55% [4].
5. Radical surgery with adjuvant radiotherapy or chemotherapy is the preferred treatment.

---

## 11.3 Extraskelatal Osteosarcoma

Extraskelatal osteosarcoma is a malignant osteoid producing sarcoma that most commonly arises in the soft tissue in older adults (sixth to seventh decades of life). These are often found in the deep muscle of the thigh, shoulder, and pelvis and measure 5–10 cm in size [10, 11]. In approximately 5% of cases, the patient has undergone previous radiation treatment [12]. Radiologic examination demonstrates varying amounts of calcification in these tumors, consistent with their osteogenic nature [13].

### Pathology

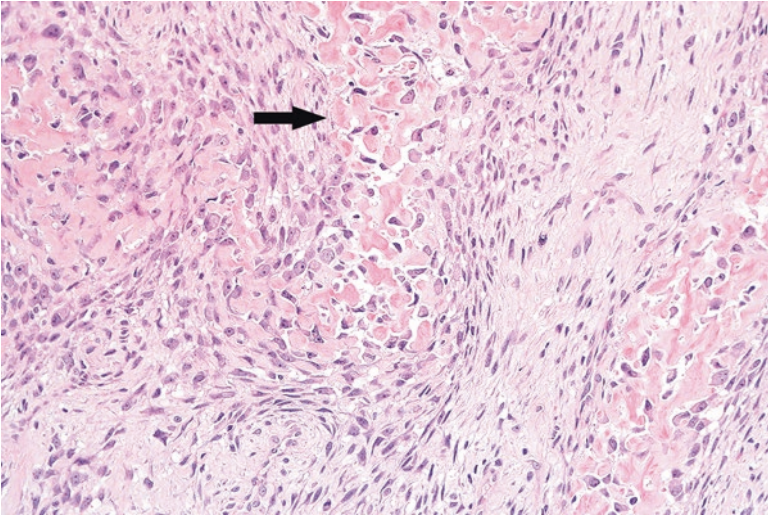
Morphologically, the features are identical to those of an osteosarcoma arising in the bone. The sections show tumor cells with varying amounts of associated osteoid material in a lacelike distribution (Figs. 11.8 and 11.9). Areas of fibroblastic and chondroblastic differentiation can also be seen.

### Differential Diagnosis

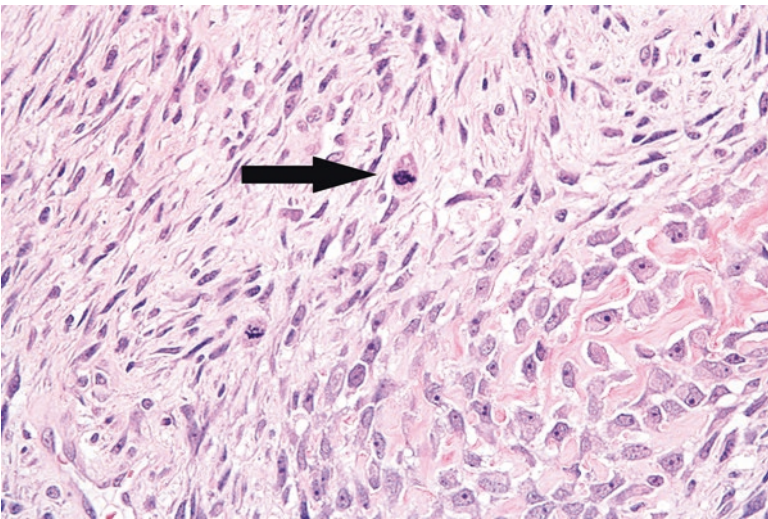
- Undifferentiated high-grade pleomorphic sarcoma
- Myositis ossificans
- High-grade surface or metastatic osteosarcoma of the bone

### Comments

- Undifferentiated high-grade pleomorphic sarcoma lacks the osteoid deposition seen in extraskelatal osteosarcoma.
- Extraskelatal osteosarcoma must be distinguished from benign soft tissue lesions that can deposit osteoid material, such as myositis ossificans.
- Although myositis ossificans contains osteoid material, ossification is more organized and is at the periphery of the lesion.
- Correlation with the radiologic imaging is required to exclude metastatic or direct extension of osteosarcoma from the bone.



**Fig. 11.8** Extraskelletal osteosarcoma with deposition of eosinophilic osteoid material (*arrow*)



**Fig. 11.9** The tumor cells in the extraskelletal osteosarcoma show nuclear hyperchromasia and scattered mitosis (*arrow*)

- Extraskelletal osteosarcoma is a highly malignant sarcoma.
- Approximately 45% of tumors recur, usually within 3 years after resection.
- Metastasis occurs in 65% of affected patients, with the lung being the most common site.
- The 5-year survival rate is 37% [10].
- Treatment generally consists of radical surgery with adjuvant radiation and multi-agent chemotherapy [4].

## Facts to Remember

1. Extraskelletal chondroma is a benign cartilaginous neoplasm that typically arises in acral locations.
2. Extraskelletal mesenchymal chondrosarcoma is a malignant soft tissue tumor that has areas of poorly differentiated cells admixed with chondroid material.
3. Extraskelletal osteosarcoma is a malignant osteoid-producing sarcoma that can occur in the soft tissue.
4. Extraskelletal osteosarcoma is highly aggressive and is treated with radical surgery as well as adjuvant radiation and multiagent chemotherapy.
5. When diagnosing an extraskelletal mesenchymal chondrosarcoma or extraskelletal osteosarcoma, it is critical to first exclude soft tissue metastasis from an undiscovered primary bone tumor.

---

## References

1. Chung EB, Enzinger FM. Chondroma of soft parts. *Cancer*. 1978;41(4):1414–24.
2. Bansal M, Goldman AB, DiCarlo EF, McCormack R. Soft tissue chondromas: diagnosis and differential diagnosis. *Skelet Radiol*. 1993;22(5):309–15.
3. Dahlin DC, Salvador AH. Cartilaginous tumors of the soft tissues of the hands and feet. *Mayo Clin Proc*. 1974;49(10):721–6.
4. Goldblum J, Weiss S, Folpe AL, editors. *Enzinger and Weiss's soft tissue tumors*. 6th ed. Philadelphia: Elsevier; 2013.
5. Huvos AG, Rosen G, Dabska M, Marcove RC. Mesenchymal chondrosarcoma. A clinicopathologic analysis of 35 patients with emphasis on treatment. *Cancer*. 1983;51(7):1230–7.
6. Nakashima Y, Unni KK, Shives TC, Swee RG, Dahlin DC. Mesenchymal chondrosarcoma of bone and soft tissue. A review of 111 cases. *Cancer*. 1986;57(12):2444–53.
7. Bertoni F, Picci P, Bacchini P, Capanna R, Innao V, Bacci G, et al. Mesenchymal chondrosarcoma of bone and soft tissues. *Cancer*. 1983;52(3):533–41.
8. Fanburg-Smith JC, Auerbach A, Marwaha JS, Wang Z, Rushing EJ. Reappraisal of mesenchymal chondrosarcoma: novel morphologic observations of the hyaline cartilage and endochondral ossification and beta-catenin, Sox9, and osteocalcin immunostaining of 22 cases. *Hum Pathol*. 2010;41(5):653–62.
9. Wang L, Motoi T, Khanin R, Olshen A, Mertens F, Bridge J, et al. Identification of a novel, recurrent HEY1-NCOA2 fusion in mesenchymal chondrosarcoma based on a genome-wide screen of exon-level expression data. *Genes Chromosom Cancer*. 2012;51(2):127–39.
10. Lee JS, Fetsch JF, Wasdhal DA, Lee BP, Pritchard DJ, Nascimento AG. A review of 40 patients with extraskelletal osteosarcoma. *Cancer*. 1995;76(11):2253–9.
11. Lidang Jensen M, Schumacher B, Myhre Jensen O, Steen Nielsen O, Keller J. Extraskelletal osteosarcomas: a clinicopathologic study of 25 cases. *Am J Surg Pathol*. 1998;22(5):588–94.
12. Hornick JL, editor. *Practical soft tissue pathology: a diagnostic approach*. Philadelphia: Saunders; 2013.
13. Murphey MD, Robbin MR, McRae GA, Flemming DJ, Temple HT, Kransdorf MJ. The many faces of osteosarcoma. *Radiographics*. 1997;17(5):1205–31.

Although numerous soft tissue neoplasms resemble various connective tissues in the body, some have no identifiable histologic counterpart. Like other diagnostic groups, the behavior of tumors of uncertain differentiation varies from benign to highly malignant. Repetitive genetic aberrations are frequent among these neoplasms and can be used for diagnostic purposes.

---

## 12.1 Intramuscular Myxoma

Intramuscular myxoma is a benign neoplasm that most frequently occurs as a well-delineated and deeply situated mass in the thigh. It arises in adults in the fifth to seventh decade of life, and some patients note symptoms of pain or tenderness [1, 2]. Patients with Mazabraud syndrome have a combination of multiple intramuscular myxomas and fibrous dysplasia of the bone [3].

### Pathology

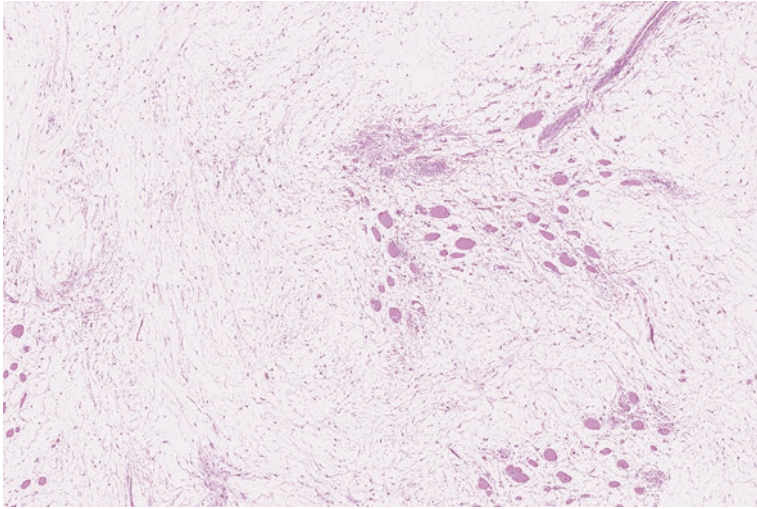
Microscopically, these tumors show abundant background myxoid substance that contains scattered stellate cells with small, bland nuclei (Figs. 12.1 and 12.2). Macrophages containing mucinous material can sometimes be seen [4].

### Ancillary Studies

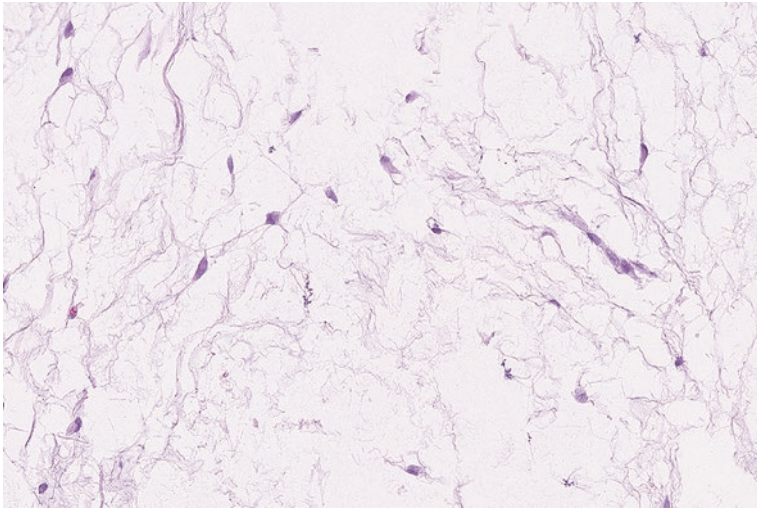
- The diagnosis is primarily based on histologic features.
- The majority of intramuscular myxomas contain mutations in the *GNAS1* gene [5].

### Differential Diagnosis

- Myxoid liposarcoma
- Myxofibrosarcoma
- Low-grade fibromyxoid sarcoma



**Fig. 12.1** Skeletal muscle fibers surrounded and dissected by intramuscular myxoma



**Fig. 12.2** Intramuscular myxoma with occasional cells with small and stellate nuclei

### Comment

1. Intramuscular myxomas can have similar features with other myxoid tumors, such as myxofibrosarcoma, myxoid liposarcoma, and low-grade fibromyxoid sarcoma.
2. Myxoid liposarcoma has a more conspicuous interconnecting “chicken wire” capillary network with scattered lipoblasts.



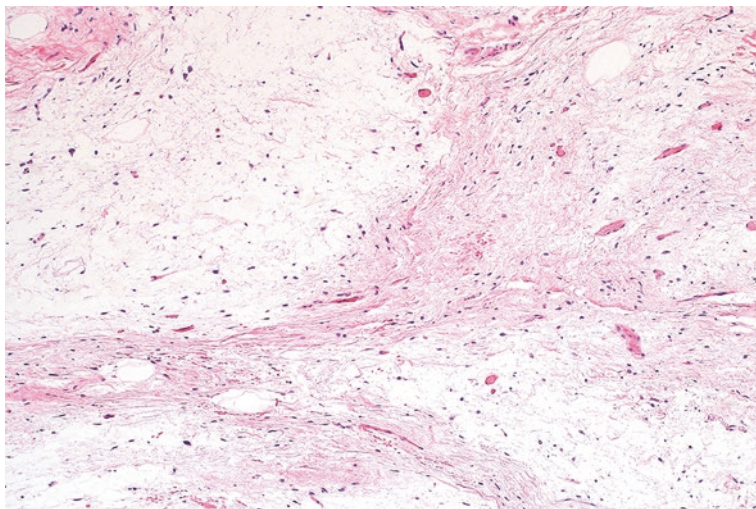
3. Myxofibrosarcoma contains more atypical mesenchymal cells with nuclear hyperchromasia that are associated with curvilinear vessels.
4. Low-grade fibromyxoid sarcoma shows a more organized pattern of alternating fibrous and myxoid stroma and is positive for a MUC4 immunohistochemical stain.
5. Given limited material, the diagnosis of intramuscular myxoma on a needle core biopsy can be difficult. A descriptive interpretation of “low-grade myxoid neoplasm” is sometimes made.
6. Intramuscular myxoma is a benign neoplasm. Surgical excision is generally curative [4].

## 12.2 Superficial Angiomyxoma

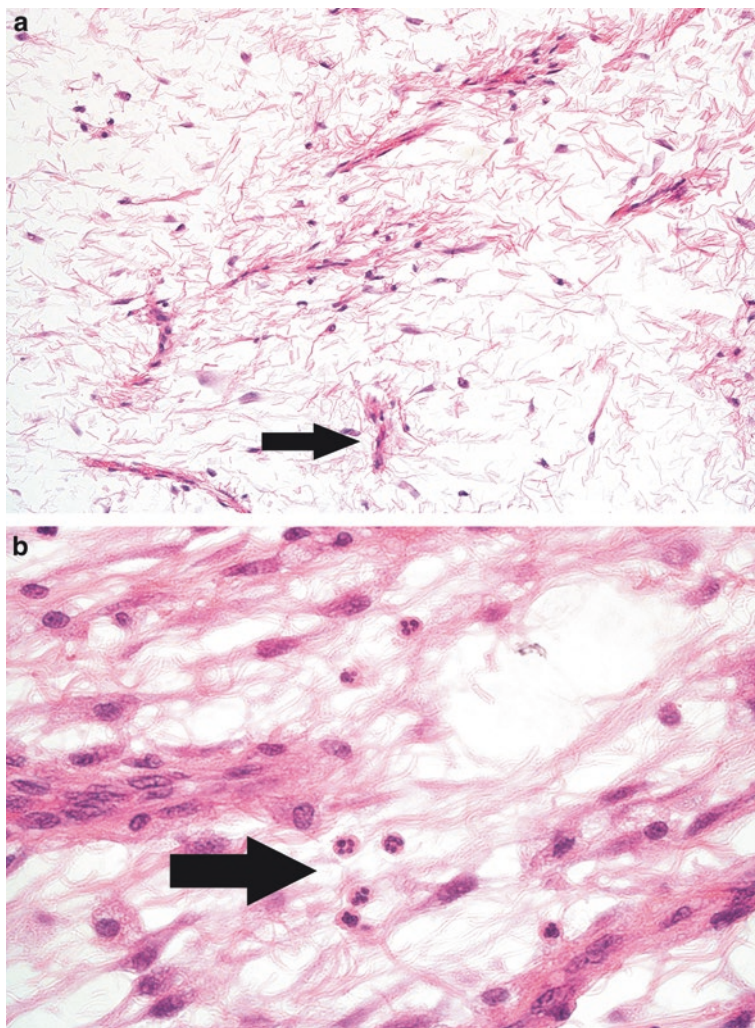
Superficial angiomyxomas present as polypoid or nodular lesions in the dermis of the head and neck, trunk, or lower limbs in children and adults [6]. The majority of these lesions measure from 1 to 5 cm in greatest dimension [7]. They are morphologically identical to the myxomas in Carney syndrome, a condition associated with endocrine overactivity, spotty pigmentation, and multiple myxomas [8].

### Pathology

Superficial angiomyxomas often have a multinodular architecture and contain a myxoid background with bland-appearing stromal cells (Fig. 12.3). Small to medium delicate blood vessels course through the lesion, and scattered associated neutrophils and lymphocytes can be seen (Fig. 12.4). Some angiomyxomas are associated with an epidermoid cyst [7].



**Fig. 12.3** Superficial angiomyxoma with conspicuous blood vessels in the background of myxoid material



**Fig. 12.4** (a) Superficial angiomyxoma with small blood vessels (*arrow*) (b) Higher power examination of these vessels reveals associated scattered neutrophils (*arrow*)

### Differential Diagnosis

- Superficial acral fibromyxoma
- Myxofibrosarcoma
- Myxoid liposarcoma

### Comment

1. Superficial angiomyxoma should be distinguished from other myxomatous neoplasms that occur in the extremities, such as myxoid liposarcoma, superficial acral fibromyxoma, and myxofibrosarcoma.

2. Superficial acral fibromyxomas are confined to the distal extremities and lack the associated inflammatory infiltrate of superficial angiomyxoma.
3. Myxofibrosarcoma contains mesenchymal cells with more nuclear atypia.
4. Myxoid liposarcoma arises in the deep soft tissue of the extremities, has scattered lipoblasts, and manifests highly specific translocations involving the *DDIT3* gene.
5. Superficial angiomyxomas are benign tumors, but can recur if incompletely excised [7, 9].

---

## 12.3 Hemosiderotic Fibrolipomatous Tumor

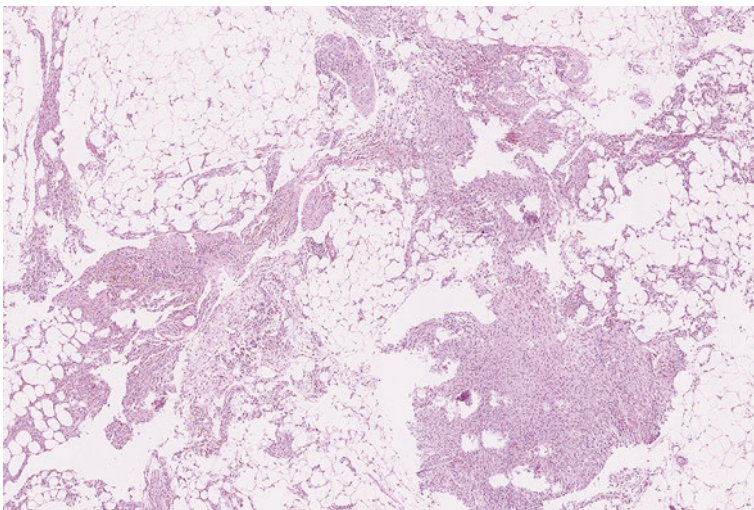
Hemosiderotic fibrolipomatous tumor (HFLT) is a lesion that often arises in the subcutaneous tissue around the ankles of adult women, most commonly in the fifth decade of life. Prior to pathologic examination, these can be mistaken for lipomas or ganglion cysts [10–12].

### Pathology

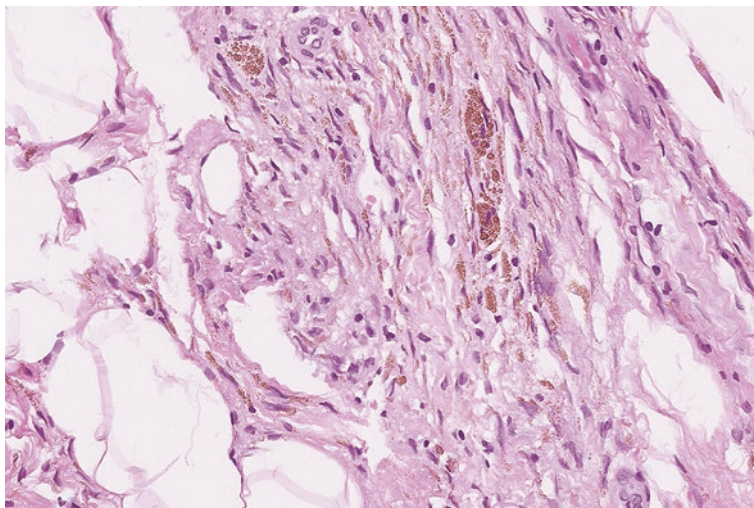
Under the microscope, HFLT shows background adipocytic tissue that is traversed by fibrous septa containing bland-appearing spindle cells (Fig. 12.5). Associated lymphocytes, mast cells, and hemosiderin deposition are typically seen (Fig. 12.6). Small to medium sized blood vessels with thickened walls typically course through the fat as well.

### Ancillary Studies

- The spindle cells are positive for a CD34 immunohistochemical stain.
- Genetic translocations involving *TGFBR3* and *MGEA5* have been identified in these tumors [13].



**Fig. 12.5** Hemosiderotic fibrolipomatous tumor with adipose tissue that is traversed by bands of fibrous tissue



**Fig. 12.6** High-power examination of this hemosiderotic fibrolipomatous tumor shows deposition of *golden-brown* hemosiderin pigment

### Differential Diagnosis

- Dermatofibrosarcoma protuberans
- Fibrous histiocytoma
- Pleomorphic hyalinizing angiectatic tumor

### Comment

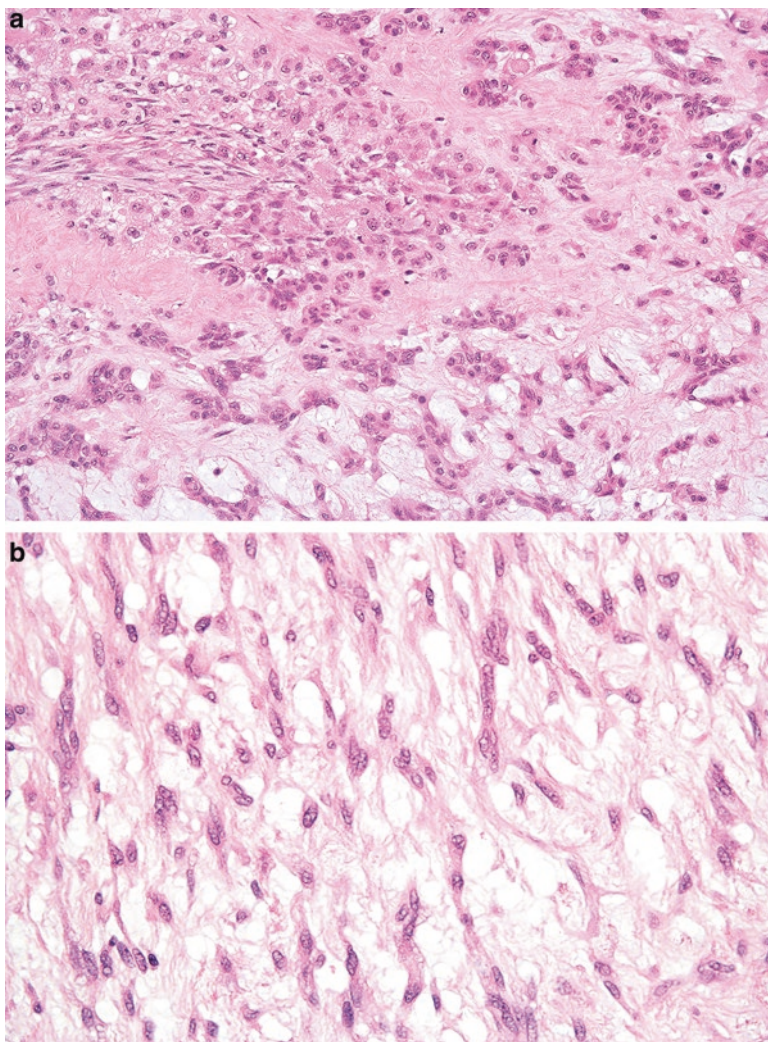
1. Hemosiderotic fibrolipomatous tumor can resemble fibrous and fibrohistiocytic tumors such as dermatofibrosarcoma protuberans, fibrous histiocytoma, and pleomorphic hyalinizing angiectatic tumor.
2. The spindle cells in dermatofibrosarcoma exhibit a whorling pattern and entrap the surrounding adipose tissue in a "honeycomb" pattern.
3. Fibrous histiocytoma does not demonstrate the septated pattern of hemosiderotic fibrolipomatous tumor.
4. Hemosiderotic fibrolipomatous tumors share morphologic and cytogenetic features with pleomorphic hyalinizing angiectatic tumor and are suspected to be related lesions [14].
5. Approximately 25–50% of hemosiderotic fibrolipomatous tumors recur [10, 15]. Treatment consists of complete excision [12].

## 12.4 Myoepithelioma of Soft Tissue

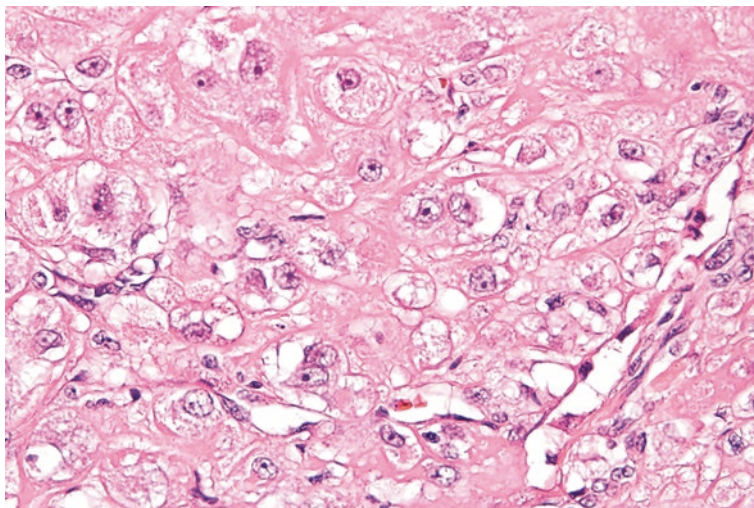
Myoepitheliomas of the soft tissue occur in children and adults over a broad age range. They often arise in the extremities or the head and neck area. These can be infiltrative or well circumscribed and measure up to 20 cm in size [16, 17].

### Pathology

Myoepitheliomas display a wide variety of morphologic appearances. The myoepithelial cells can appear as epithelioid, ovoid, or spindle cells that are arranged in sheets, clusters, cords, or interconnected strands (Fig. 12.7a, b). Benign myoepitheliomas



**Fig. 12.7** (a) Myoepithelioma of soft tissue with epithelioid cells. (b) Myoepithelioma with an interconnected network of more spindled cells



**Fig. 12.8** Malignant myoepithelioma of soft tissue with vesicular nuclei and prominent nucleoli

contain bland appearing nuclei while malignant ones contain either hyperchromatic or vesicular nuclei and prominent nucleoli (Fig. 12.8).

### Ancillary Studies

- Myoepithelial cells are positive for S100, calponin, pancytokeratin, and sometimes GFAP [18].
- Translocations involving the *EWSR1* gene are detected in approximately half of cases. Partner genes include *POU5F1*, *ZNF444*, and *PBX1* [19].

### Differential Diagnosis

- Ossifying fibromyxoid tumor
- Extraskelatal chordoma
- Extraskelatal myxoid chondrosarcoma

### Comments

1. Given their highly variable appearance, myoepitheliomas can mimic many types of neoplasms. Common considerations include extraskelatal myxoid chondrosarcoma, extraskelatal chordoma, and ossifying fibromyxoid tumor.
2. Ossifying fibromyxoid tumor has ovoid cells but usually has at least a partial peripheral shell of bone surrounding the lesion.
3. Cells in a chordoma can have a similar appearance to some myoepithelial tumors. Unlike soft tissue myoepithelioma, chordomas rarely arise in the peripheral soft tissue and are positive for a brachyury immunohistochemical stain.

4. Extraskeletal myxoid chondrosarcoma also demonstrates rearrangements involving the *EWSR1* gene; however, these tumors have different partner genes (e.g. *NR4A3*) than myoepithelioma.
5. The behavior of soft tissue myoepithelioma is difficult to predict.
6. Of myoepithelial tumors that appeared histologically benign, 18% recurred locally and none metastasized [17].
7. Of myoepithelial tumors that had histologically malignant features, 42% recurred locally and 32% metastasized [17].
8. Complete surgical excision is the primary treatment for these tumors [12].

---

## 12.5 Ossifying Fibromyxoid Tumor

Ossifying fibromyxoid tumors arise in the subcutaneous tissue or muscle in the upper and lower extremities and head and neck region. These occur in adults with a median age of presentation of 50 years. They are typically painless and develop slowly [20].

### Pathology

Ossifying fibromyxoid tumors are composed of round to oval cells with vesicular nuclei that are arranged in a linear or reticular pattern (Fig. 12.9a). On closer examination, the tumor cells contain bland nuclei and are in the background of a fine collagenous or myxoid stroma (Fig. 12.9b). A partial shell of mature bone often surrounds the lesion (Fig. 12.10).

### Ancillary Studies

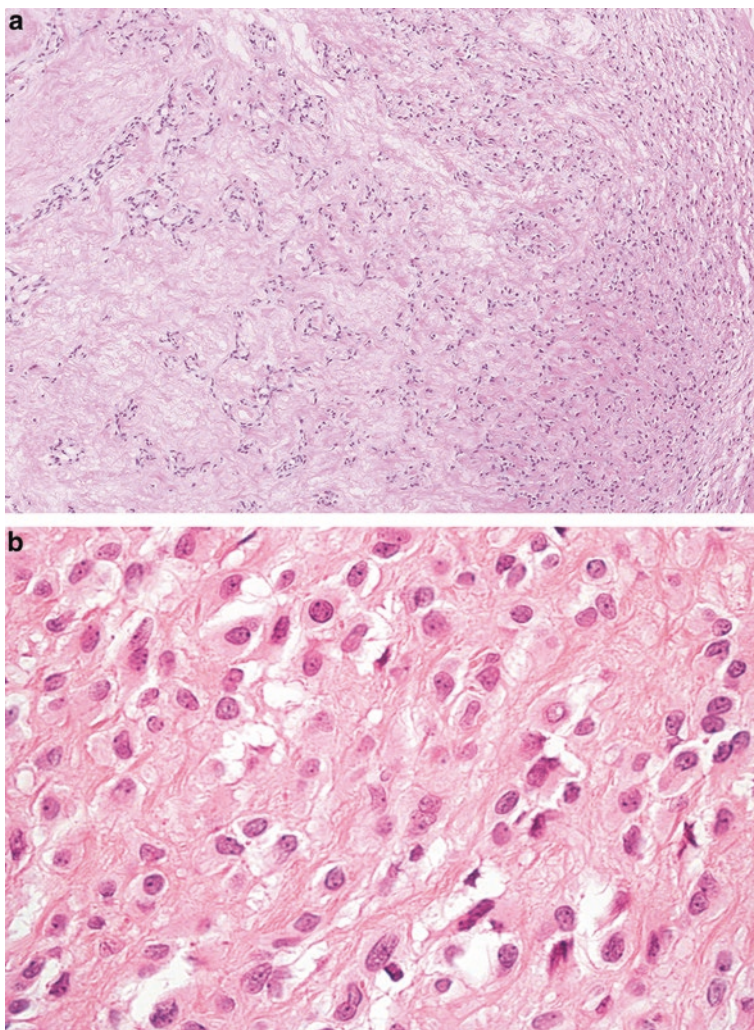
- The cells in this tumor usually express S100 and can be positive for desmin [21].
- Ossifying fibromyxoid tumors frequently have translocations involving the *PHF1* gene [22].

### Differential Diagnosis

- Myoepithelioma of soft tissue
- Chondroid syringoma
- Extraskeletal myxoid chondrosarcoma

### Comment

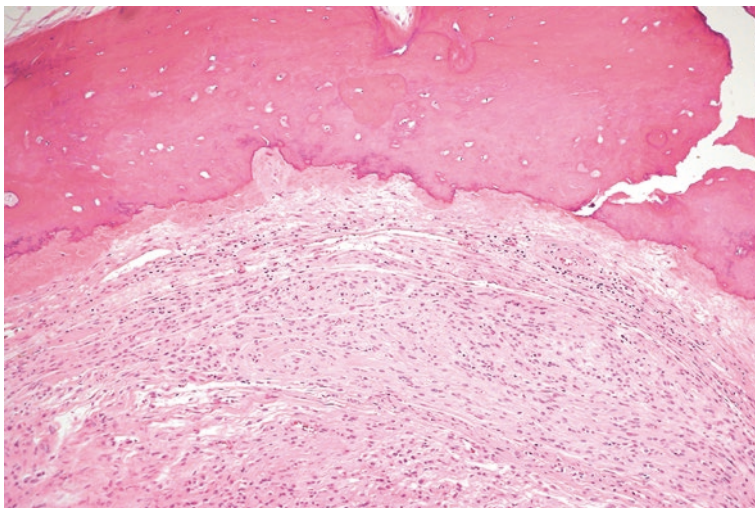
1. The cord-like arrangement of cells in ossifying fibromyxoid tumor can resemble patterns seen in extraskeletal myxoid chondrosarcoma, chondroid syringoma, or myoepithelioma of soft tissue.
2. Unlike chondroid syringoma and myoepithelioma of soft tissue, ossifying fibromyxoid tumor only rarely expresses cytokeratins and usually has at least focal peripheral osteoid deposition.



**Fig. 12.9** (a) Ossifying fibromyxoid tumor with a cord-like and reticular arrangement of ovoid cells. (b) Neoplastic cells of ossifying fibromyxoid tumor with bland nuclei and fine collagen background

3. Extraskelletal myxoid chondrosarcoma typically has translocations involving the *EWSR1* gene.
4. Typical ossifying fibromyxoid tumor has a recurrence rate of 17% and a metastatic rate of 5% [23].
5. Histologically malignant ossifying fibromyxoid tumors demonstrate high cellularity, increased mitoses (over 2 per 10 high power fields), and high nuclear grade [23].
6. Malignant ossifying fibromyxoid tumors have a metastatic rate of 22% [21].





**Fig. 12.10** Peripheral bone of an ossifying fibromyxoid tumor

---

## 12.6 Alveolar Soft Part Sarcoma

Alveolar soft part sarcoma is a malignant tumor that primarily arises in adolescents and young adults (median age of 22 years). The most common sites of occurrence include the buttock, leg, and trunk [24]. In younger patients, these can arise in the head and neck [25]. A subset of patients have metastasis at the time of diagnosis.

### Pathology

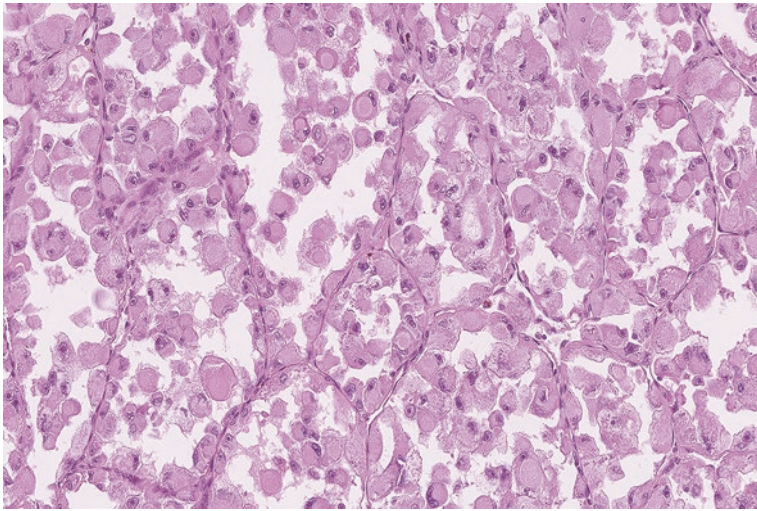
Microscopically, these tumors are composed of nests of neoplastic cells with eosinophilic and granular cytoplasm. The central cells in these nests drop out, giving the tumor an alveolar appearance similar to lung tissue (Fig. 12.11). The nuclei of the tumor cells are enlarged and prominent nucleoli can be seen (Fig. 12.12).

### Ancillary Studies

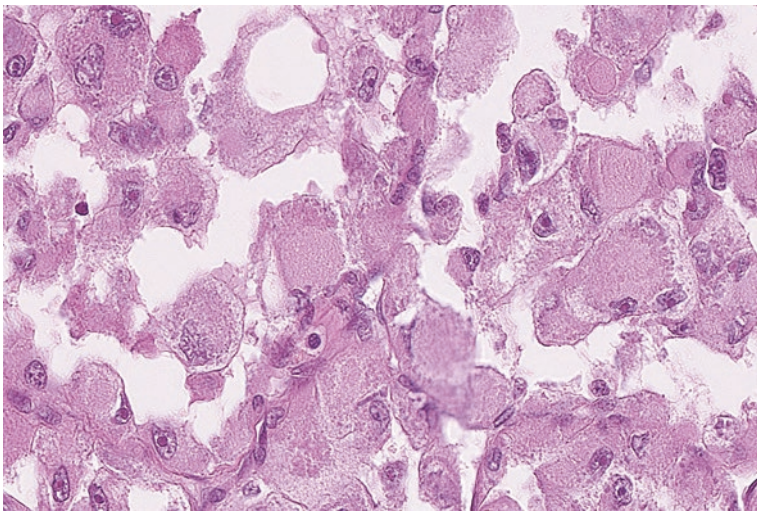
- The neoplastic cells are positive for a TFE3 immunohistochemical stain [26].
- These tumors exhibit an *ASPCRI-TFE3* fusion transcript that can be used to confirm the diagnosis by molecular studies [26].

### Differential Diagnosis

- Granular cell tumor
- Renal cell carcinoma



**Fig. 12.11** Nests of eosinophilic cells forming an alveolar architecture in this alveolar soft part sarcoma



**Fig. 12.12** Neoplastic cells of an alveolar soft part sarcoma with enlarged nuclei and prominent nucleoli

### Comments

1. Alveolar soft part sarcoma can be confused for other tumors with eosinophilic cytoplasm, such as granular cell tumor and renal cell carcinoma.
2. Alveolar soft part sarcoma lacks the S100 staining seen in granular cell tumor and cytokeratin or PAX-8 staining seen in renal cell carcinoma.

3. These tumors are aggressive from a long-term perspective. While the 5-year overall survival is 87%, the 20-year survival is 15%.
4. The 5-year overall survival for patients with metastatic disease is only 20% [24, 27].
5. Treatment consists of radical surgical excision and possible radiotherapy and chemotherapy [9].

---

## 12.7 Clear Cell Sarcoma of Soft Tissue

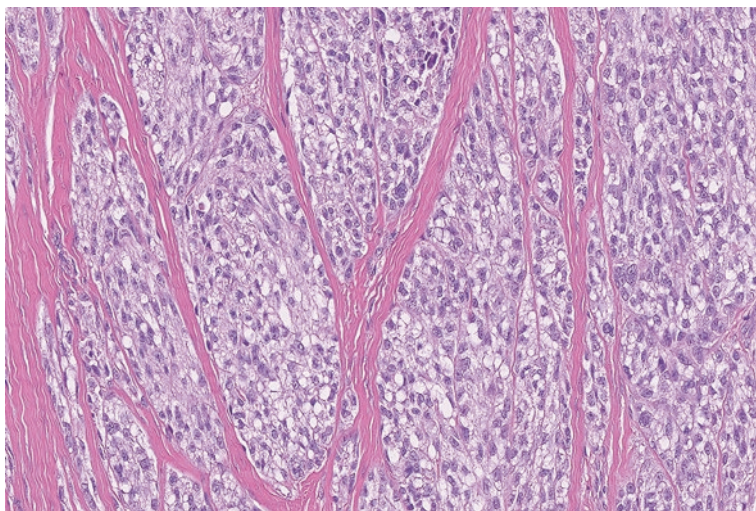
Clear cell sarcoma is a malignant soft tissue tumor that arises in young adults at a median age of 30 years. These typically occur as slow-growing nodules in the foot, ankle, or hands and are intimately associated with a tendon [28, 29].

### Pathology

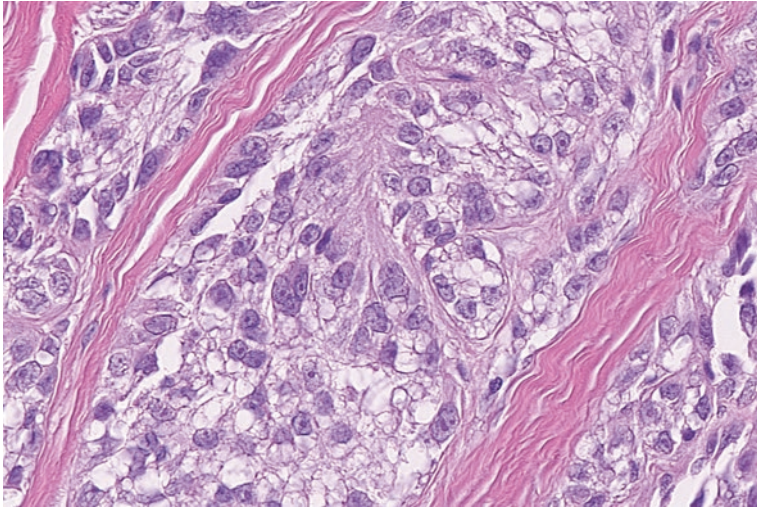
Microscopically, these tumors are composed of bundles of spindle cells with eosinophilic to clear cytoplasm in the background of fibrotic stroma (Fig. 12.13). The cells contain enlarged vesicular nuclei and prominent nucleoli (Fig. 12.14). Scattered associated giant cells and melanin pigment can occasionally be seen.

### Ancillary Studies

- Tumor cells are positive for S100, HMB-45, and Melan-A immunohistochemical stains [30].
- Clear cell sarcoma of soft tissue has been found to have *EWSR1-ATF1* or *EWSR1-CREB1* fusion transcripts [31, 32].



**Fig. 12.13** Clear cell sarcoma of soft tissue with vaguely spindle cells containing clear and eosinophilic cytoplasm



**Fig. 12.14** The cells in this clear cell sarcoma contain large nuclei and prominent nucleoli

### Differential Diagnosis

- Spindle cell or desmoplastic melanoma
- Malignant peripheral nerve sheath tumor
- Leiomyosarcoma

### Comments

1. Clear cell sarcoma of the soft tissue can be confused for other spindle cell neoplasms such as desmoplastic melanoma, leiomyosarcoma, or malignant peripheral nerve sheath tumor.
2. The absence of an overlying skin lesion helps differentiate this lesion from a melanoma. Melanoma typically lacks mutations involving the *EWSR1* gene.
3. Malignant peripheral nerve sheath tumor demonstrates only focal (if any) S100 staining.
4. Leiomyosarcoma lacks S100 staining and is positive for desmin and smooth muscle actin.
5. Clear cell sarcoma is an aggressive tumor. Approximately 14% recur and 63% metastasize [29].
6. The 5-year survival rate is approximately 66%. Complete surgical excision is the primary treatment, and radiation therapy has been used if the surgical margins are positive [28].

## 12.8 Extraskelletal Ewing Sarcoma

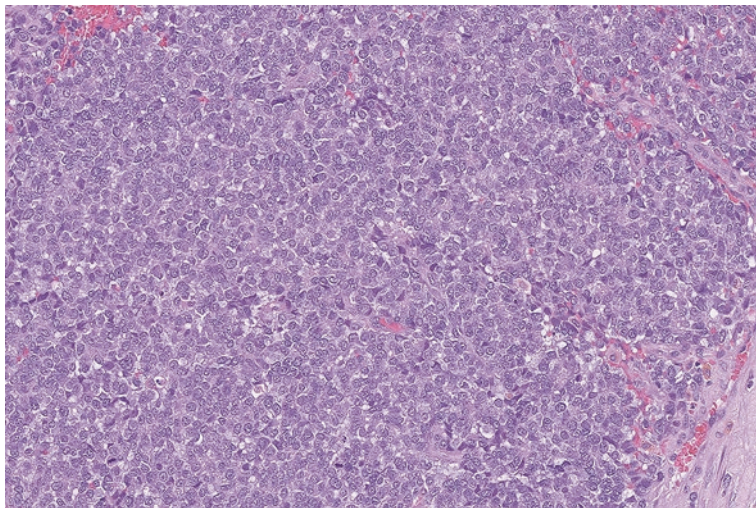
Ewing sarcoma is a malignancy that is usually associated with the bone; however, approximately 20% of these tumors will arise in extraskelletal locations such as the pelvis, thigh, paraspinal area, or foot [33, 34]. Most patients with Ewing sarcoma are between 5 and 20 years old, and the median occurrence is at 14 years of age [35].

### Pathology

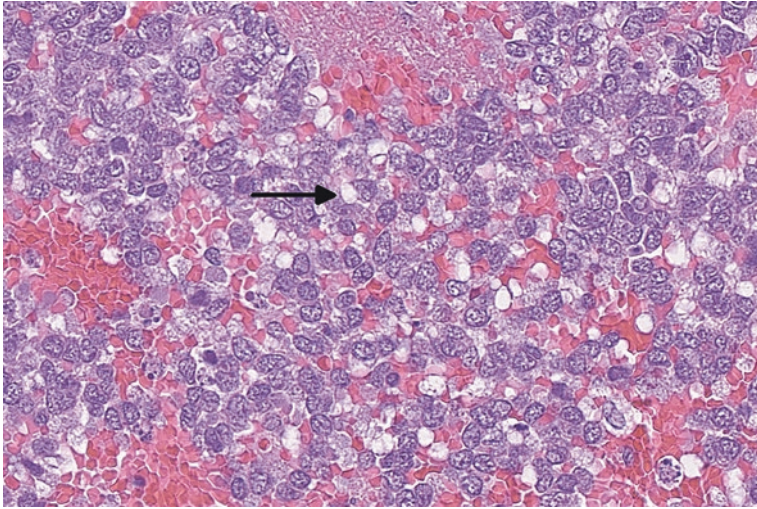
This tumor is a classic example of a “small round cell sarcoma.” Compared to other aggressive mesenchymal tumors, the cells are smaller in size and have a high nuclear to cytoplasmic ratio (Fig. 12.15). Sometimes this limited cytoplasm can have a clear appearance due to increased glycogen (Fig. 12.16). The cells are usually arranged in sheets but sometimes can be seen in a circular arrangement, termed a Homer-Wright rosettes [36].

### Ancillary Studies

- The tumor cells are strongly positive for CD99, but this is not in itself diagnostic [37].
- Ewing sarcoma often exhibits a fusion between the *EWSRI* and *FLI-1* genes. It can also have alternative genetic translocations, resulting in fusion transcripts such as *EWSRI-ERG* [38].



**Fig. 12.15** The high nuclear to cytoplasmic ratio of the tumor cells of this Ewing sarcoma can be confused for other malignancies, such as lymphoma



**Fig. 12.16** The tumor cells of this Ewing sarcoma contain scattered clear cytoplasmic vacuolizations consistent with increased glycogen content (*arrow*)

### Differential Diagnosis

- Rhabdomyosarcoma
- Desmoplastic round cell tumor
- Poorly differentiated synovial sarcoma

### Comment

1. Ewing sarcoma must be differentiated from other tumors that are composed of similar undifferentiated “small round cells,” such as rhabdomyosarcoma, desmoplastic synovial sarcoma, and poorly differentiated synovial sarcoma.
2. Rhabdomyosarcoma typically expresses MyoD1 and myogenin, which is usually not seen in Ewing sarcoma.
3. Desmoplastic round cell tumor contains a similar “small round cell” population, but these are usually positive for desmin.
4. Unlike Ewing sarcoma, synovial sarcoma frequently expresses TLE-1 and has distinct translocations involving the *SYT* gene.
5. Modern treatment consists of surgical resection and either radiotherapy or chemotherapy. Survival for localized tumors is approximately 75%. However, approximately 25% of patients have clinically identifiable metastasis at diagnosis [12, 39].

## 12.9 Desmoplastic Small Round Cell Tumor

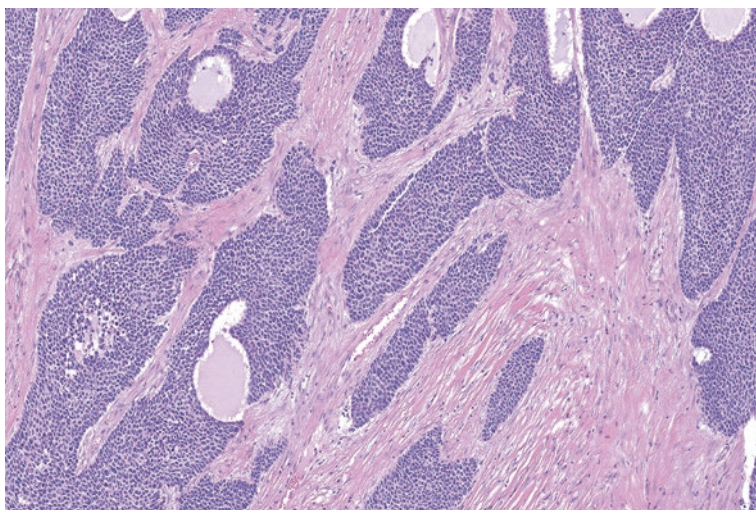
Desmoplastic small round cell tumor is a rare sarcoma that occurs in the abdomen or pelvic peritoneum of adolescent or young adult males. The average age of occurrence is 22 years [40]. Patients can present with abdominal pain, weight loss, increased abdominal girth, ascites, and constipation and are usually found to have a primary tumor mass with multiple associated peritoneal implants [41].

### Pathology

The name of this tumor accurately describes its microscopic appearance. Similar to Ewing sarcoma, the tumor cells contain minimal cytoplasm and are arranged in scattered sheets, nests, and cords. However, in desmoplastic round cell tumor, these cells are typically seen in the background of dense fibrous tissue (Fig. 12.17). Scattered areas of coagulative necrosis are frequently identified.

### Ancillary Studies

- Desmoplastic round cell tumors are positive for epithelial (cytokeratin), myogenic (desmin staining in a dot-like pattern), and neurogenic (S100) immunohistochemical stains [40].
- These tumors contain a unique genetic translocation that forms an *EWSR1-WT1* fusion transcript [42].



**Fig. 12.17** Desmoplastic small round cell tumor with nests of tumor cells in the background of fibrotic stroma

### Differential Diagnosis

- Ewing sarcoma
- Poorly differentiated carcinoma
- Rhabdomyosarcoma
- Mesothelioma

### Comment

1. Desmoplastic round cell tumor can be confused with other tumors that demonstrate “round cell” morphology. These include Ewing sarcoma and rhabdomyosarcoma. They also must be distinguished from other tumors such as poorly differentiated carcinoma and mesothelioma.
2. Ewing sarcoma has morphologic similarities but does not display desmin positivity or contain the *EWSR1-WTI* fusion transcript seen in desmoplastic round cell tumor.
3. Poorly differentiated carcinomas, rhabdomyosarcomas, and mesotheliomas do not exhibit coexpression of mesenchymal, epithelial, and neural antigens [9].
4. Desmoplastic round cell tumor is a highly malignant sarcoma. Only approximately 28% of affected patients survive [43].
5. Treatment approaches include total surgical resection, external beam radiation therapy, and hyperthermic intraperitoneal chemotherapy [44].

---

## 12.10 PEComa (and Similar Neoplasms)

Perivascular epithelioid cell neoplasms (PEComas) are tumors that arise in middle-aged females, most often in the fourth decade. Common sites include the gynecologic tract, omentum, pelvis, retroperitoneum, and falciform ligament [45]. These tumors are part of a larger perivascular epithelioid cell family of neoplasms, which includes angiomyolipoma, lymphangiomyoma, and pulmonary clear cell sugar tumor [9, 46].

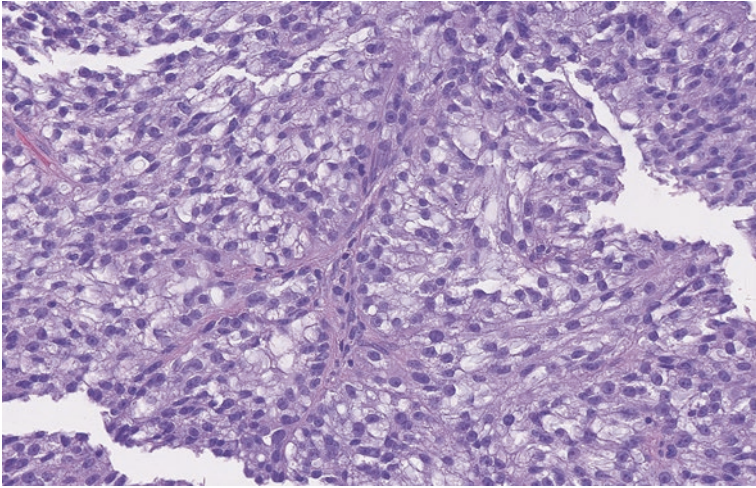
### Pathology

Microscopically, PEComas are composed of eosinophilic and clear cells that are both spindle and epithelioid in appearance. They are arranged in nests and sheets around blood vessels (Fig. 12.18).

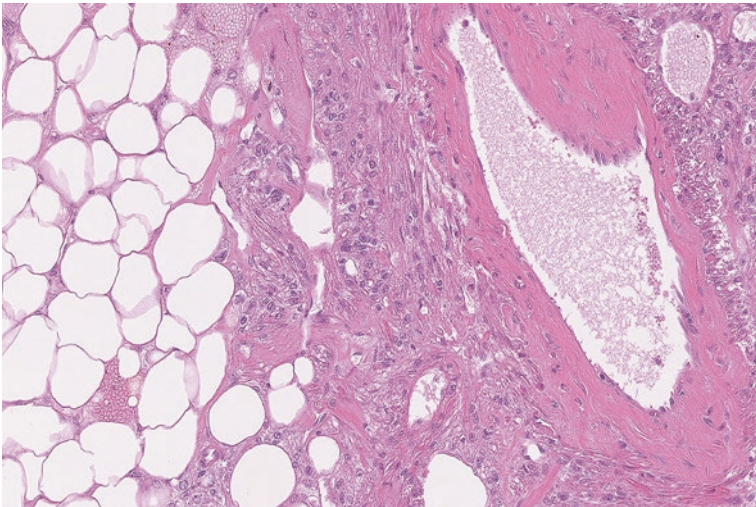
### Ancillary Tests

- PEComas usually show expression of both smooth muscle actin and melanocytic markers (HMB-45, and MART-1) [9].





**Fig. 12.18** PEComa with epithelioid cells with clear and eosinophilic cytoplasm



**Fig. 12.19** Angiomyolipoma with adipocytes, vessels, and clear epithelioid-like cells

### Related Neoplasms

- Angiomyolipoma
  - Angiomyolipomas arise in the kidney in women around the fifth decade of life. They are composed of a combination of adipose tissue, thick-walled blood vessels, and epithelioid cells arranged around vascular spaces (Fig. 12.19) [47].
- Lymphangiomyoma
  - Lymphangiomyoma presents in women as multiple nodules or cysts around the lymph nodes and lymphatics of the mediastinum and pulmonary interstitium. Microscopic sections show lymphatic or vascular spaces surrounded by epithelioid-like cells with clear cytoplasm [48].

## Differential Diagnosis

- Clear cell sarcoma
- Melanoma
- Leiomyosarcoma

## Comments

1. The combined expression of smooth muscle actin and melanocytic markers (HMB-45, MART-1) differentiates PEComas from other similar appearing neoplasms such as clear cell sarcoma and melanoma. Leiomyosarcomas typically lack the numerous small vessels seen in PEComa and do not usually express MART-1.
2. Approximately 13% of PEComas recur and 21% will metastasize [45].
3. Concerning clinical or histologic features in a PEComa include a tumor size greater than 5 cm, infiltrative border, highly atypical nuclei, increased cellularity, greater than one mitosis per 50 high power field (hpf), coagulative necrosis, or vascular invasion.
4. Tumors that have two or more of these findings are considered malignant.
5. In addition to complete resection, some patients have been treated with adjuvant therapies such as mTOR inhibitors [49].

---

## 12.11 Epithelioid Sarcoma

Epithelioid sarcoma is a soft tissue neoplasm that arises in adolescents and young adults as a nodule in the hand, forearm, or pretibial region. These dermal, subcutaneous, or soft tissue lesions can be solitary or multiple and grow slowly [9, 50, 51]. Proximal-type epithelioid sarcoma, a particularly aggressive form of this tumor, often arises as a deep-seated mass in the pelvis, perineum, axilla, pubis, or buttocks [52].

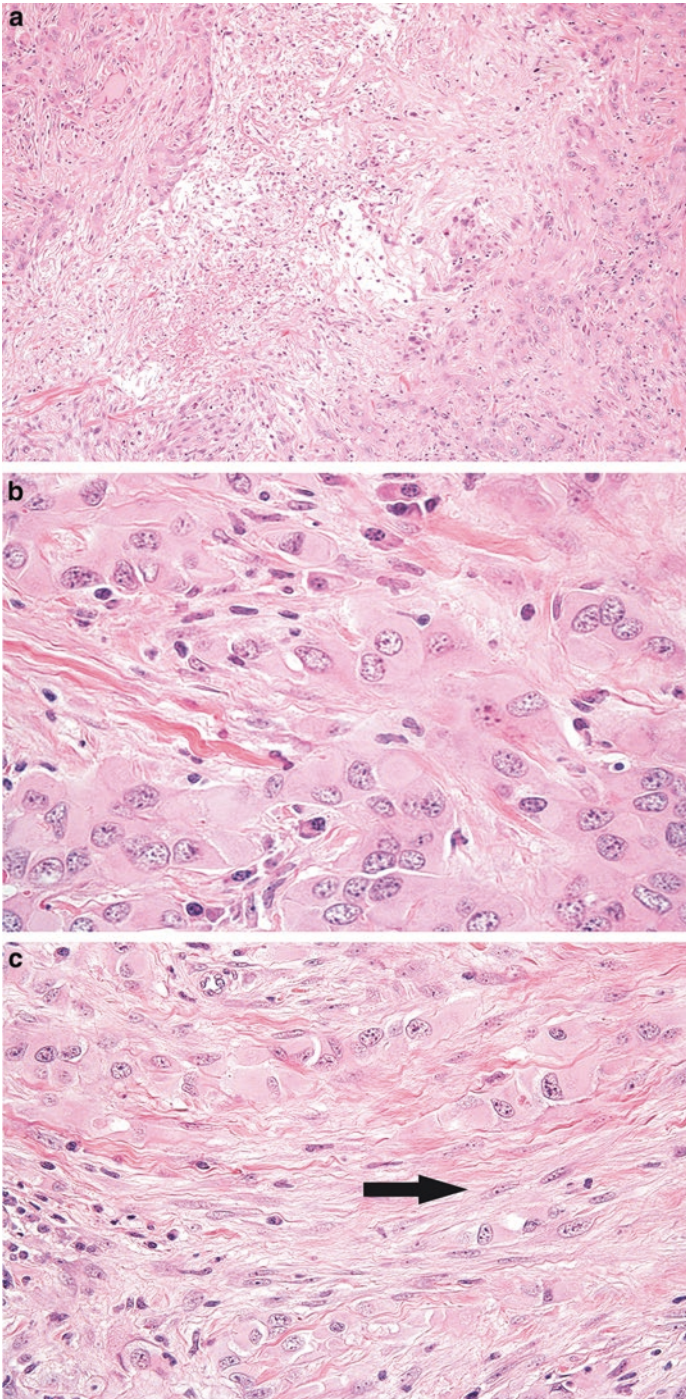
### Pathology

The conventional type of epithelioid sarcoma shows cells arranged around areas of degeneration or necrosis which can be mistaken for granulomatous inflammation (Fig. 12.20a). Closer inspection, however, will reveal ovoid and vesicular nuclei with atypical features such as multiple nucleoli and irregular borders (Fig. 12.20b). Although predominantly epithelioid, the tumor cells can transition into areas of a more spindled appearance (Fig. 12.20c).

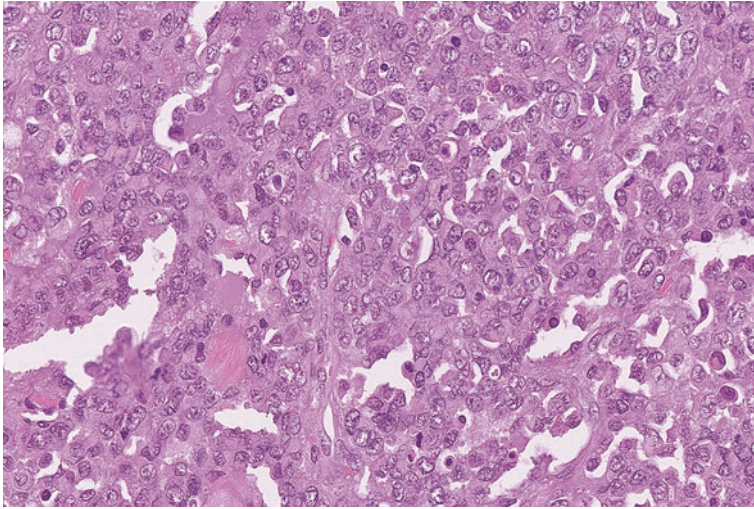
The proximal type of epithelioid sarcoma demonstrates larger tumor cells with vesicular nuclei. These cells contain eosinophilic cytoplasmic inclusions that are typically described as “rhabdoid,” given the vague similarity to immature skeletal muscle (Fig. 12.21).

### Ancillary Tests

- The tumor cells are usually positive for EMA or various cytokeratin stains. A CD34 stain is positive in approximately half of cases [53].
- The tumors show loss of nuclear INI-1 expression.



**Fig. 12.20** (a) Epithelioid sarcoma with cells arranged around central area of necrosis. (b) High-power examination shows epithelioid-like cells with multiple nucleoli and nuclei of varying shape and size. (c) Other areas of epithelioid sarcoma show occasional cells which have a more spindled appearance (*arrow*)



**Fig. 12.21** Proximal variant of epithelioid sarcoma with larger tumor cells that contain eosinophilic cytoplasm

### Differential Diagnosis

- Epithelioid angiosarcoma
- Carcinoma
- Malignant extrarenal rhabdoid tumor

### Comments

1. Epithelioid sarcoma must be distinguished from other tumors with an epithelioid morphology such as epithelioid angiosarcoma, carcinoma, or malignant extrarenal rhabdoid tumor.
2. Although epithelioid sarcoma can be positive for CD34, this tumor lacks the staining for CD31 or ERG seen in epithelioid angiosarcoma.
3. Both epithelioid sarcoma and carcinoma are positive for cytokeratins; however, carcinomas typically have intact INI-1 nuclear expression and usually do not express CD34.
4. Malignant extrarenal rhabdoid tumor has similar morphologic and immunohistochemical features as the proximal variant of epithelioid sarcoma. However, malignant extrarenal rhabdoid tumors typically occur in the pediatric population and are negative for CD34.
5. Epithelioid sarcomas can metastasize to the lymph nodes as well as the lungs.
6. In one study 77% of tumors were found to recur and 45% metastasized. Tumors that are more proximal and larger and have vascular invasion, mitosis, or necrosis are associated with more aggressive behavior [54].
7. Treatment primarily consists of radical excision or amputation and regional lymph node dissection [9].

## 12.12 Extrarenal Rhabdoid Tumor

Malignant extrarenal rhabdoid tumors are highly malignant soft tissue tumors that are analogous to the rhabdoid tumors of the kidney or atypical teratoid/rhabdoid tumors of the central nervous system [55]. These occur in the pediatric population, particularly in the second decade of life, and often arise in the abdomen, pelvis, retroperitoneum, and neck [12, 56]. Rarely, an affected patient can have a family history or present with multiple rhabdoid tumors [57].

### Pathology

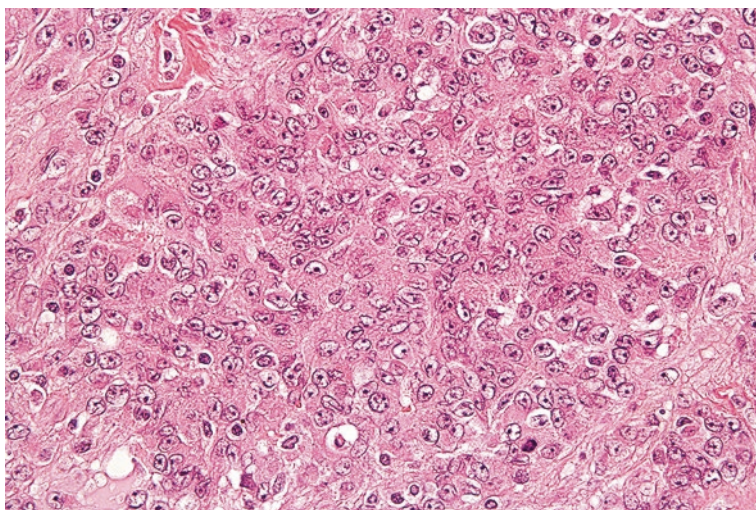
Microscopically, the cells in this neoplasm have eosinophilic cytoplasmic globules that have been described as having a “rhabdoid” appearance (Fig. 12.22). The tumor cell nuclei are enlarged and vacuolated and contain prominent nucleoli.

### Ancillary Studies

- Extrarenal rhabdoid tumors are positive for epithelial markers such as EMA and cytokeratins.
- The cells consistently lose nuclear expression of INI-1 protein due to mutations or deletions of the corresponding *SMARCB1* gene [58].

### Differential Diagnosis

- Proximal variant of epithelioid sarcoma
- Pleomorphic rhabdomyosarcoma
- Carcinoma with rhabdoid features



**Fig. 12.22** The cells of this extrarenal rhabdoid tumor have eosinophilic cytoplasm and large vesicular nuclei with prominent nucleoli

## Comment

1. Extrarenal rhabdoid tumors must be distinguished from other soft tissue and epithelial neoplasms which can have cells with a “rhabdoid appearance,” including pleomorphic rhabdomyosarcoma, proximal variant of epithelioid sarcoma, and various types of carcinoma with rhabdoid features.
2. Proximal variant of epithelioid sarcoma usually arises in young adults and can express CD34 in about half of cases.
3. Pleomorphic rhabdomyosarcoma has highly anaplastic tumor cells with eosinophilic cytoplasm, but these cells show myogenic differentiation by desmin.
4. Carcinomas, such as renal cell carcinoma, can have rhabdoid features. However, there is often a more apparent residual epithelial element in a portion of the tumor. Also, carcinomas usually retain nuclear expression of INI-1.
5. Extrarenal rhabdoid tumors are highly aggressive. Approximately 82% of patients experience metastasis and 64% pass away after 19 months [56].
6. Treatment involves combinations of multiagent radiation and chemotherapy. Unfortunately, the response to chemotherapy tends to be temporary [12].

---

## 12.13 Synovial Sarcoma

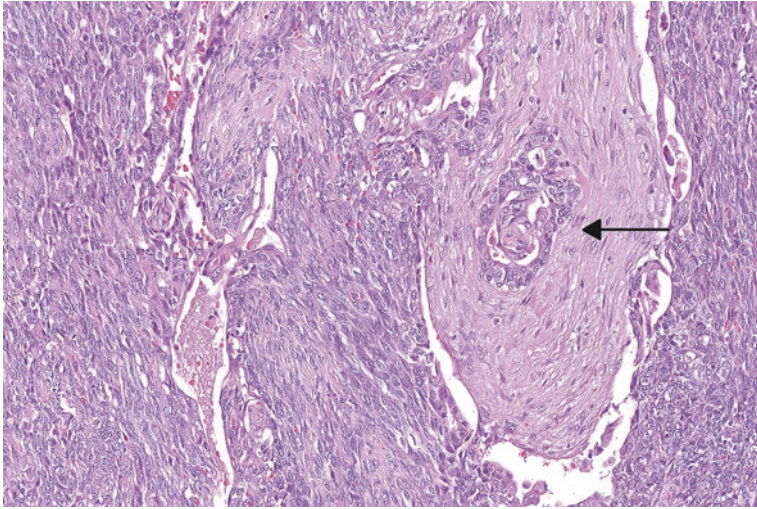
Synovial sarcoma is a malignant soft tissue neoplasm that can arise in younger and older patients, with an average age of presentation of 35 years. Despite the name, the tumor does not originate from the synovium but is frequently found adjacent to major joint spaces in the proximal or distal extremities [59]. Numerous other anatomic sites have been documented, including the head and neck, chest wall, and abdominal, and thoracic cavity [60]. These tumors can grow at a deceptively slow rate, sometimes delaying appropriate diagnosis and treatment for years [60, 61].

### Pathology

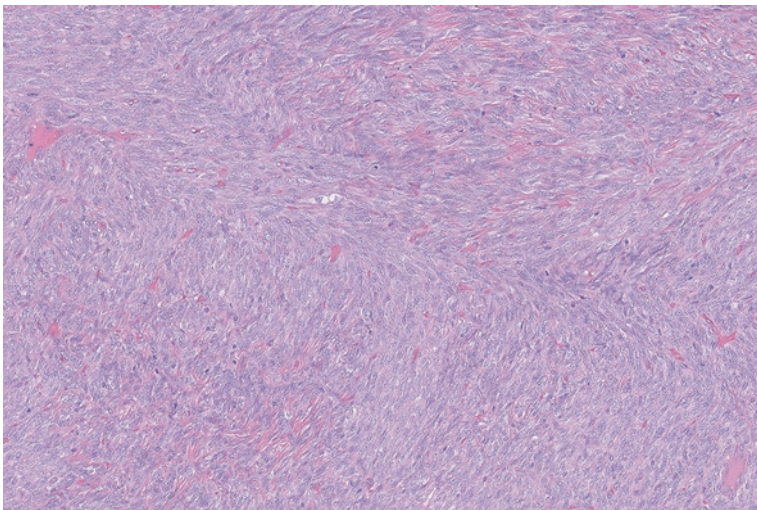
Synovial sarcomas are known to have three distinct morphologic patterns. The biphasic type contains intersecting bundles of spindle cells and a second component of epithelioid-like cells that can be arranged in a glandular-like architecture (Fig. 12.23). The monophasic type contains only bundles of spindle cells (Fig. 12.24). Poorly-differentiated synovial sarcoma manifests as sheets of cells that lack a glandular or spindle cell arrangement (Fig. 12.25).

### Ancillary Studies

- Synovial sarcomas are at least focally positive pancytokeratin or EMA, particularly in the epithelioid-like areas, but also in the spindled component [62].
- TLE-1, a stain that highlights expression of a transcriptional corepressor protein, is positive in synovial sarcoma [63].
- Synovial sarcoma exhibits one of two highly specific translocations resulting in the creation of a *SYT-SSX1* or *SYT-SSX2* fusion transcript [64].



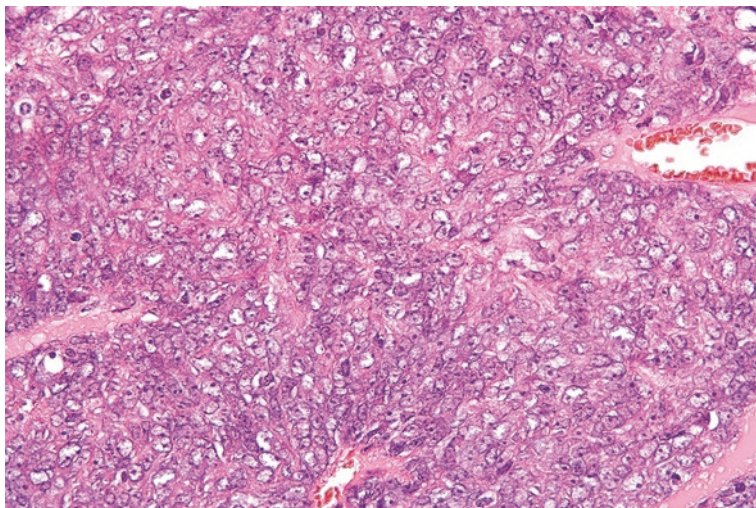
**Fig. 12.23** Synovial sarcoma with a biphasic appearance. The spindle cells merge with epithelioid cells with a glandular appearance (*arrow*)



**Fig. 12.24** Monophasic synovial sarcoma. This morphologic type is composed exclusively of intersecting bundles of spindle cells

### Differential Diagnosis

- The differential diagnosis of synovial sarcoma depends on the morphology type.
- Biphasic tumors with an epithelioid component must be distinguished from sarcomatoid carcinoma or mesothelioma.



**Fig. 12.25** Poorly differentiated synovial sarcoma. The tumor cells lack either a glandular or spindled architecture

- Monophasic tumors need to be separated from other tumors with a “spindled and fascicular pattern,” such as malignant peripheral nerve sheath tumor, leiomyosarcoma, solitary fibrous tumor, or fibrosarcoma.
- Poorly differentiated synovial sarcoma should be distinguished from other small round blue cell neoplasms such as Ewing sarcoma.

### Comments

1. Although the differential of synovial sarcoma is broad, the finding of a *SYT-SSX1* or *SYT-SSX2* fusion transcript differentiates synovial sarcoma from these histologic mimics.
2. The 5-, 10-, and 15-year event-free survival of synovial sarcoma is 60%, 50%, and 45%, respectively. Occurrence at an adult age, larger tumor size, and poorly differentiated tumors have a worse prognosis [65, 66].
3. Synovial sarcomas are often treated with radical local excision and adjuvant chemotherapy and/or radiotherapy [9].

---

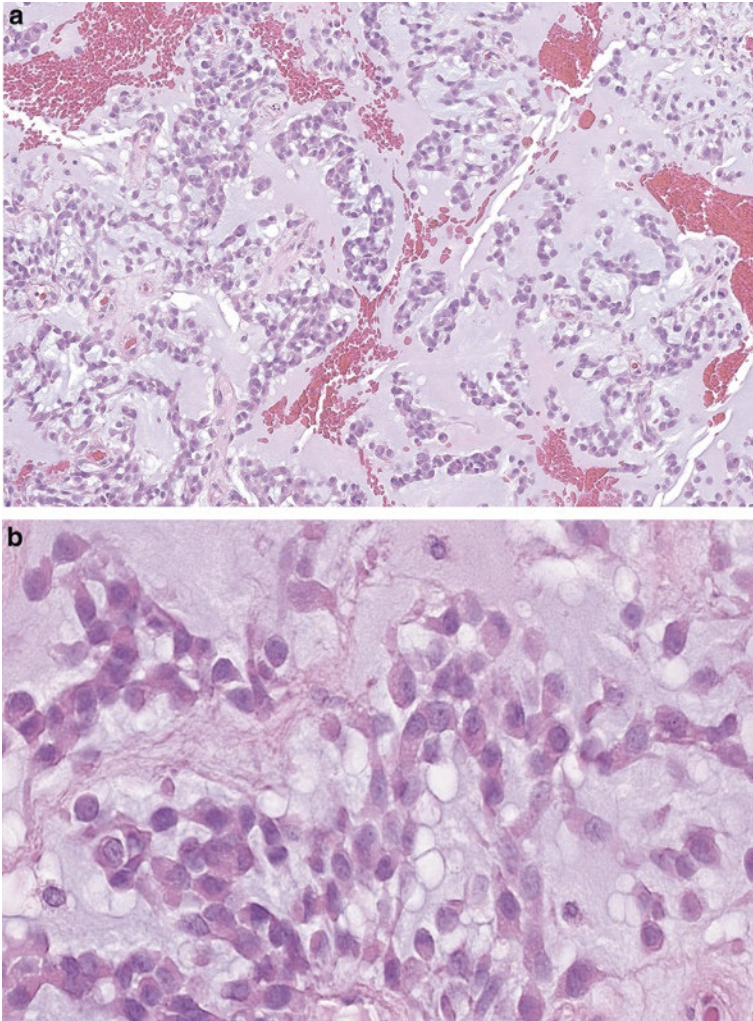
## 12.14 Extraskelletal Myxoid Chondrosarcoma

Extraskelletal myxoid chondrosarcoma is a vaguely chondroid-like neoplasm that occurs as a slow-growing deep subcutaneous or soft tissue mass in adults. It occurs in the proximal extremities or trunk and most frequently arises in the sixth decade of life. Males tend to be affected twice as often as females [67, 68].



**Pathology**

Grossly, these tumors appear as multicystic lesions with substantial associated gelatinous material. Microscopically, there is abundant background myxoid matrix with strands and cords of neoplastic cells with characteristically eosinophilic cytoplasm (Fig. 12.26a, b).



**Fig. 12.26** (a) Extraskeletal myxoid chondrosarcoma with strands and cords of cells in a myxoid background. (b) The cells of this extraskeletal myxoid chondrosarcomas have a prominently eosinophilic cytoplasm

### Ancillary Studies

- Extraskelatal myxoid chondrosarcoma typically demonstrates a translocation involving the *NR4A3* gene.
- Fusion transcripts include *NR4A3-EWSR1*, *NR4A3-TAF15*, or *NR4A3-TCF12* [9, 69].

### Differential Diagnosis

- Myxoid liposarcoma
- Myxofibrosarcoma
- Conventional chondrosarcoma

### Comment

1. Extraskelatal myxoid chondrosarcoma lacks the delicate thin-walled capillaries or aberrations of the *DDIT3* gene found in myxoid liposarcoma.
2. Extraskelatal myxoid chondrosarcoma does not exhibit the curvilinear vessels or hyperchromatic cells noted in myxofibrosarcoma.
3. Correlation with the radiologic findings is necessary to exclude soft tissue extension of a conventional chondrosarcoma.
4. This is a malignant tumor. Approximately 35–50% of patients experience local recurrence, and 25–50% encounter distant metastasis.
5. The 10-year overall survival rate is 70% [12].
6. Larger tumor size (greater than 10 cm), increased mitotic activity (greater than 2 per 10 hpf), high cellularity, and anaplasia or rhabdoid features are associated with more aggressive behavior.
7. Extraskelatal myxoid chondrosarcoma is treated with wide excision and possible adjuvant radiation therapy [70].

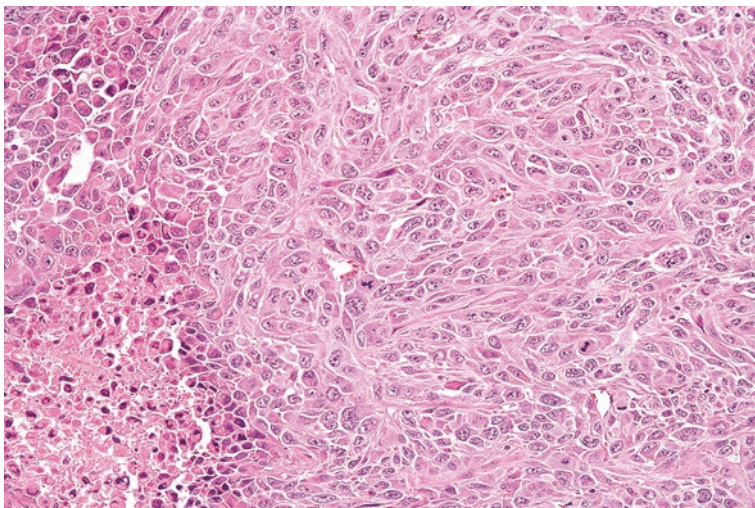
---

## 12.15 Undifferentiated High-Grade Pleomorphic Sarcoma

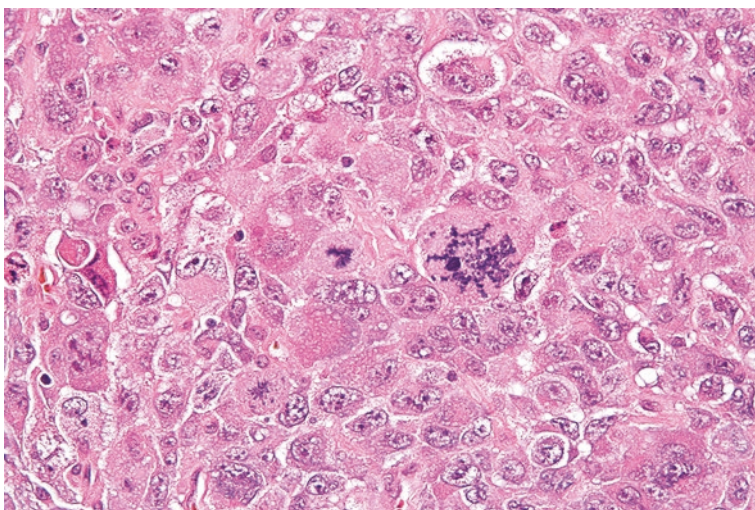
Previously designated as “malignant fibrous histiocytoma (MFH),” undifferentiated high-grade pleomorphic sarcoma is common among soft tissue malignancies. This classification likely encompasses multiple entities in which the current lack of specific morphologic, immunohistochemical, or genetic findings precludes a more definitive diagnosis. They often arise in older adults as a large painless mass in the thigh or upper extremity.

### Pathology

Microscopically, these tumors demonstrate a wide range of appearances. Highly pleomorphic cells are arranged in varying patterns with numerous mitoses and areas of necrosis (Figs. 12.27 and 12.28). Bizarre giant cells, background myxoid stroma, or inflammation can be present.



**Fig. 12.27** Undifferentiated high-grade pleomorphic sarcoma with sheets of poorly differentiated cells



**Fig. 12.28** Undifferentiated high-grade pleomorphic sarcoma with bizarre-appearing tumor cells with both epithelioid and spindled appearances

### Ancillary Studies

- By definition, these tumors do not have a defining immunohistochemical or genetic finding which allows for classification as another soft tissue neoplasm.

## Differential Diagnosis

- Dedifferentiated liposarcoma
- Pleomorphic leiomyosarcoma or rhabdomyosarcoma
- Pleomorphic liposarcoma
- High-grade myxofibrosarcoma
- Poorly differentiated carcinoma
- Anaplastic lymphoma
- Melanoma

## Comment

1. Undifferentiated high-grade pleomorphic sarcoma must be distinguished from other tumors that have bizarre tumor cells, such as melanoma, carcinoma, or lymphoma.
2. In the retroperitoneum, dedifferentiated liposarcoma can mimic an undifferentiated high-grade pleomorphic sarcoma. However, undifferentiated high-grade pleomorphic sarcoma lacks the *MDM2* gene amplification found in dedifferentiated liposarcoma.
3. The lack of myogenic staining (e.g. desmin) helps exclude pleomorphic myogenic tumors.
4. Pleomorphic liposarcoma can be excluded by the lack of lipoblasts.
5. Over a 5-year period, a third of undifferentiated high-grade pleomorphic sarcomas will recur or metastasize.
6. Given the aggressive nature of these tumors, wide excision with adjuvant radiation therapy is administered.
7. The 5-year event-free survival is approximately 70% [71].

---

## References

1. Enzinger FM. Intramuscular myxoma; a review and follow-up study of 34 cases. *Am J Clin Pathol.* 1965;43:104–13.
2. Kindblom LG, Stener B, Angervall L. Intramuscular myxoma. *Cancer.* 1974;34(5):1737–44.
3. Zoccali C, Teori G, Prencipe U, Erba F. Mazabraud's syndrome: a new case and review of the literature. *Int Orthop.* 2009;33(3):605–10.
4. Nielsen GP, O'Connell JX, Rosenberg AE. Intramuscular myxoma: a clinicopathologic study of 51 cases with emphasis on hypercellular and hypervascular variants. *Am J Surg Pathol.* 1998;22(10):1222–7.
5. Delaney D, Diss TC, Presneau N, Hing S, Berisha F, Idowu BD, et al. *GNAS1* mutations occur more commonly than previously thought in intramuscular myxoma. *Mod Pathol.* 2009;22(5):718–24.
6. Calonje E, Guerin D, McCormick D, Fletcher CD. Superficial angiomyxoma: clinicopathologic analysis of a series of distinctive but poorly recognized cutaneous tumors with tendency for recurrence. *Am J Surg Pathol.* 1999;23(8):910–7.
7. Allen PW, Dymock RB, MacCormac LB. Superficial angiomyxomas with and without epithelial components. Report of 30 tumors in 28 patients. *Am J Surg Pathol.* 1988;12(7):519–30.

8. Ferreiro JA, Carney JA. Myxomas of the external ear and their significance. *Am J Surg Pathol.* 1994;18(3):274–80.
9. Goldblum J, Weiss S, Folpe AL, editors. *Enzinger and Weiss's soft tissue tumors.* 6th ed. Philadelphia: Elsevier; 2013.
10. Browne TJ, Fletcher CD. Haemosiderotic fibrolipomatous tumour (so-called haemosiderotic fibrohistiocytic lipomatous tumour): analysis of 13 new cases in support of a distinct entity. *Histopathology.* 2006;48(4):453–61.
11. Kazakov DV, Sima R, Michal M. Hemosiderotic fibrohistiocytic lipomatous lesion: clinical correlation with venous stasis. *Virchows Arch.* 2005;447(1):103–6.
12. Hornick JL, editor. *Practical soft tissue pathology: a diagnostic approach.* Philadelphia: Saunders; 2013.
13. Antonescu CR, Zhang L, Nielsen GP, Rosenberg AE, Dal Cin P, Fletcher CD. Consistent t(1;10) with rearrangements of TGFBR3 and MGEA5 in both myxoinflammatory fibroblastic sarcoma and hemosiderotic fibrolipomatous tumor. *Genes Chromosom Cancer.* 2011;50(10):757–64.
14. Carter JM, Sukov WR, Montgomery E, Goldblum JR, Billings SD, Fritchie KJ, et al. TGFBR3 and MGEA5 rearrangements in pleomorphic hyalinizing angiectatic tumors and the spectrum of related neoplasms. *Am J Surg Pathol.* 2014;38(9):1182–92.
15. Marshall-Taylor C, Fanburg-Smith JC. Hemosiderotic fibrohistiocytic lipomatous lesion: ten cases of a previously undescribed fatty lesion of the foot/ankle. *Mod Pathol.* 2000;13(11):1192–9.
16. Kilpatrick SE, Hitchcock MG, Kraus MD, Calonje E, Fletcher CD. Mixed tumors and myoepitheliomas of soft tissue: a clinicopathologic study of 19 cases with a unifying concept. *Am J Surg Pathol.* 1997;21(1):13–22.
17. Hornick JL, Fletcher CDM. Myoepithelial tumors of soft tissue: a clinicopathologic and immunohistochemical study of 101 cases with evaluation of prognostic parameters. *Am J Surg Pathol.* 2003;27(9):1183–96.
18. Hornick JL, Fletcher CDM. Cutaneous myoepithelioma: a clinicopathologic and immunohistochemical study of 14 cases. *Hum Pathol.* 2004;35(1):14–24.
19. Antonescu CR, Zhang L, Chang NE, Pawel BR, Travis W, Katabi N, et al. EWSR1-POU5F1 fusion in soft tissue myoepithelial tumors. A molecular analysis of sixty-six cases, including soft tissue, bone, and visceral lesions, showing common involvement of the EWSR1 gene. *Genes Chromosom Cancer.* 2010;49(12):1114–24.
20. Enzinger FM, Weiss SW, Liang CY. Ossifying fibromyxoid tumor of soft parts. A clinicopathological analysis of 59 cases. *Am J Surg Pathol.* 1989;13(10):817–27.
21. Graham RP, Dry S, Li X, Binder S, Bahrami A, Raimondi SC, et al. Ossifying fibromyxoid tumor of soft parts: a clinicopathologic, proteomic, and genomic study. *Am J Surg Pathol.* 2011;35(11):1615–25.
22. Gebre-Medhin S, Nord KH, Moller E, Mandahl N, Magnusson L, Nilsson J, et al. Recurrent rearrangement of the PHF1 gene in ossifying fibromyxoid tumors. *Am J Pathol.* 2012;181(3):1069–77.
23. Folpe AL, Weiss SW. Ossifying fibromyxoid tumor of soft parts: a clinicopathologic study of 70 cases with emphasis on atypical and malignant variants. *Am J Surg Pathol.* 2003;27(4):421–31.
24. Lieberman PH, Brennan MF, Kimmel M, Erlandson RA, Garin-Chesa P, Flehinger BY. Alveolar soft-part sarcoma. A clinico-pathologic study of half a century. *Cancer.* 1989;63(1):1–13.
25. Fanburg-Smith JC, Miettinen M, Folpe AL, Weiss SW, Childers EL. Lingual alveolar soft part sarcoma; 14 cases: novel clinical and morphological observations. *Histopathology.* 2004;45(5):526–37.
26. Tsuji K, Ishikawa Y, Imamura T. Technique for differentiating alveolar soft part sarcoma from other tumors in paraffin-embedded tissue: comparison of immunohistochemistry for TFE3 and CD147 and of reverse transcription polymerase chain reaction for ASPSCR1-TFE3 fusion transcript. *Hum Pathol.* 2012;43(3):356–63.
27. Portera Jr CA, Ho V, Patel SR, Hunt KK, Feig BW, Respondek PM, et al. Alveolar soft part sarcoma: clinical course and patterns of metastasis in 70 patients treated at a single institution. *Cancer.* 2001;91(3):585–91.

28. Ferrari A, Casanova M, Bisogno G, Mattke A, Meazza C, Gandola L, et al. Clear cell sarcoma of tendons and aponeuroses in pediatric patients: a report from the Italian and German Soft Tissue Sarcoma Cooperative Group. *Cancer*. 2002;94(12):3269–76.
29. Lucas DR, Nascimento AG, Sim FH. Clear cell sarcoma of soft tissues. Mayo Clinic experience with 35 cases. *Am J Surg Pathol*. 1992;16(12):1197–204.
30. Hisaoka M, Ishida T, Kuo TT, Matsuyama A, Imamura T, Nishida K, et al. Clear cell sarcoma of soft tissue: a clinicopathologic, immunohistochemical, and molecular analysis of 33 cases. *Am J Surg Pathol*. 2008;32(3):452–60.
31. Antonescu CR, Tschernyavsky SJ, Woodruff JM, Jungbluth AA, Brennan MF, Ladanyi M. Molecular diagnosis of clear cell sarcoma: detection of EWS-ATF1 and MITF-M transcripts and histopathological and ultrastructural analysis of 12 cases. *J Mol Diagn*. 2002;4(1):44–52.
32. Wang WL, Mayordomo E, Zhang W, Hernandez VS, Tuvin D, Garcia L, et al. Detection and characterization of EWSR1/ATF1 and EWSR1/CREB1 chimeric transcripts in clear cell sarcoma (melanoma of soft parts). *Mod Pathol*. 2009;22(9):1201–9.
33. Rud NP, Reiman HM, Pritchard DJ, Frassica FJ, Smithson WA. Extrasosseous Ewing's sarcoma. A study of 42 cases. *Cancer*. 1989;64(7):1548–53.
34. Fletcher CDM, Bridge JA, Hogendoorn PC, Mertens F, editors. *Pathology and genetics of tumours of soft tissue and bone*. 4th ed. Lyon: World Health Organization; 2013.
35. Khoury JD. Ewing sarcoma family of tumors. *Adv Anat Pathol*. 2005;12(4):212–20.
36. Goldblum JR, Folpe AL, Weiss SW, editors. *Enzinger and Weiss's soft tissue tumors*. 6th ed. Philadelphia: Saunders; 2013.
37. Devoe K, Weidner N. Immunohistochemistry of small round-cell tumors. *Semin Diagn Pathol*. 2000;17(3):216–24.
38. Shing DC, McMullan DJ, Roberts P, Smith K, Chin SF, Nicholson J, et al. FUS/ERG gene fusions in Ewing's tumors. *Cancer Res*. 2003;63(15):4568–76.
39. Balamuth NJ, Womer RB. Ewing's sarcoma. *Lancet Oncol*. 2010;11(2):184–92.
40. Gerald WL, Ladanyi M, de Alava E, Cuatrecasas M, Kushner BH, LaQuaglia MP, et al. Clinical, pathologic, and molecular spectrum of tumors associated with t(11;22)(p13;q12): desmoplastic small round-cell tumor and its variants. *J Clin Oncol*. 1998;16(9):3028–36.
41. Lae ME, Roche PC, Jin L, Lloyd RV, Nascimento AG. Desmoplastic small round cell tumor: a clinicopathologic, immunohistochemical, and molecular study of 32 tumors. *Am J Surg Pathol*. 2002;26(7):823–35.
42. Ladanyi M, Gerald W. Fusion of the EWS and WT1 genes in the desmoplastic small round cell tumor. *Cancer Res*. 1994;54(11):2837–40.
43. Ordenez NG. Desmoplastic small round cell tumor: I: a histopathologic study of 39 cases with emphasis on unusual histological patterns. *Am J Surg Pathol*. 1998;22(11):1303–13.
44. Hayes-Jordan A, Anderson PM. The diagnosis and management of desmoplastic small round cell tumor: a review. *Curr Opin Oncol*. 2011;23(4):385–9.
45. Folpe AL, Mentzel T, Lehr HA, Fisher C, Balzer BL, Weiss SW. Perivascular epithelioid cell neoplasms of soft tissue and gynecologic origin: a clinicopathologic study of 26 cases and review of the literature. *Am J Surg Pathol*. 2005;29(12):1558–75.
46. Martignoni G, Pea M, Reghellin D, Zamboni G, Bonetti F. PEComas: the past, the present and the future. *Virchows Arch*. 2008;452(2):119–32.
47. Eble JN. Angiomyolipoma of kidney. *Semin Diagn Pathol*. 1998;15(1):21–40.
48. Taylor JR, Ryu J, Colby TV, Raffin TA. Lymphangiomyomatosis. Clinical course in 32 patients. *N Engl J Med*. 1990;323(18):1254–60.
49. Wagner AJ, Malinowska-Kolodziej I, Morgan JA, Qin W, Fletcher CD, Vena N, et al. Clinical activity of mTOR inhibition with sirolimus in malignant perivascular epithelioid cell tumors: targeting the pathogenic activation of mTORC1 in tumors. *J Clin Oncol*. 2010;28(5):835–40.
50. Enzinger FM. Epithelioid sarcoma. A sarcoma simulating a granuloma or a carcinoma. *Cancer*. 1970;26(5):1029–41.
51. Chbani L, Guillou L, Terrier P, Decouvelaere AV, Gregoire F, Terrier-Lacombe MJ, et al. Epithelioid sarcoma: a clinicopathologic and immunohistochemical analysis of 106 cases from the French sarcoma group. *Am J Clin Pathol*. 2009;131(2):222–7.

52. Guillou L, Wadden C, Coindre JM, Krausz T, Fletcher CD. "Proximal-type" epithelioid sarcoma, a distinctive aggressive neoplasm showing rhabdoid features. Clinicopathologic, immunohistochemical, and ultrastructural study of a series. *Am J Surg Pathol.* 1997;21(2):130–46.
53. Miettinen M, Fanburg-Smith JC, Virolainen M, Shmookler BM, Fetsch JF. Epithelioid sarcoma: an immunohistochemical analysis of 112 classical and variant cases and a discussion of the differential diagnosis. *Hum Pathol.* 1999;30(8):934–42.
54. Chase DR, Enzinger FM. Epithelioid sarcoma. Diagnosis, prognostic indicators, and treatment. *Am J Surg Pathol.* 1985;9(4):241–63.
55. Weeks DA, Beckwith JB, Mierau GW, Luckey DW. Rhabdoid tumor of kidney. A report of 111 cases from the National Wilms' Tumor Study Pathology Center. *Am J Surg Pathol.* 1989;13(6):439–58.
56. Fanburg-Smith JC, Hengge M, Hengge UR, Smith Jr JS, Miettinen M. Extrarenal rhabdoid tumors of soft tissue: a clinicopathologic and immunohistochemical study of 18 cases. *Ann Diagn Pathol.* 1998;2(6):351–62.
57. Roberts CW. Genetic causes of familial risk in rhabdoid tumors. *Pediatr Blood Cancer.* 2006;47(3):235–7.
58. Sigauke E, Rakheja D, Maddox DL, Hladik CL, White CL, Timmons CF, et al. Absence of expression of SMARCB1/INI1 in malignant rhabdoid tumors of the central nervous system, kidneys and soft tissue: an immunohistochemical study with implications for diagnosis. *Mod Pathol.* 2006;19(5):717–25.
59. Ladanyi M, Antonescu CR, Leung DH, Woodruff JM, Kawai A, Healey JH, et al. Impact of SYT-SSX fusion type on the clinical behavior of synovial sarcoma: a multi-institutional retrospective study of 243 patients. *Cancer Res.* 2002;62(1):135–40.
60. Fisher C. Synovial sarcoma. *Ann Diagn Pathol.* 1998;2(6):401–21.
61. Ferrari A, Gronchi A, Casanova M, Meazza C, Gandola L, Collini P, et al. Synovial sarcoma: a retrospective analysis of 271 patients of all ages treated at a single institution. *Cancer.* 2004;101(3):627–34.
62. Smith TA, Machen SK, Fisher C, Goldblum JR. Usefulness of cytokeratin subsets for distinguishing monophasic synovial sarcoma from malignant peripheral nerve sheath tumor. *Am J Clin Pathol.* 1999;112(5):641–8.
63. Foo WC, Cruise MW, Wick MR, Hornick JL. Immunohistochemical staining for TLE1 distinguishes synovial sarcoma from histologic mimics. *Am J Clin Pathol.* 2011;135(6):839–44.
64. Brodin B, Haslam K, Yang K, Bartolazzi A, Xie Y, Starborg M, et al. Cloning and characterization of spliced fusion transcript variants of synovial sarcoma: SYT/SSX4, SYT/SSX4v, and SYT/SSX2v. Possible regulatory role of the fusion gene product in wild type SYT expression. *Gene.* 2001;268(1–2):173–82.
65. Palmerini E, Staals EL, Alberghini M, Zanella L, Ferrari C, Benassi MS, et al. Synovial sarcoma: retrospective analysis of 250 patients treated at a single institution. *Cancer.* 2009;115(13):2988–98.
66. Bergh P, Meis-Kindblom JM, Gherlinzoni F, Berlin O, Bacchini P, Bertoni F, et al. Synovial sarcoma: identification of low and high risk groups. *Cancer.* 1999;85(12):2596–607.
67. Meis-Kindblom JM, Bergh P, Gunterberg B, Kindblom L. Extraskeletal myxoid chondrosarcoma: a reappraisal of its morphologic spectrum and prognostic factors based on 117 cases. *Am J Surg Pathol.* 1999;23(6):636–50.
68. Enzinger FM, Shiraki M. Extraskeletal myxoid chondrosarcoma. An analysis of 34 cases. *Hum Pathol.* 1972;3(3):421–35.
69. Stenman G, Andersson H, Mandahl N, Meis-Kindblom JM, Kindblom LG. Translocation t(9;22)(q22;q12) is a primary cytogenetic abnormality in extraskeletal myxoid chondrosarcoma. *Int J Cancer.* 1995;62(4):398–402.
70. Oliveira AM, Sebo TJ, McGrory JE, Gaffey TA, Rock MG, Nascimento AG. Extraskeletal myxoid chondrosarcoma: a clinicopathologic, immunohistochemical, and ploidy analysis of 23 cases. *Mod Pathol.* 2000;13(8):900–8.
71. Le Doussal V, Coindre JM, Leroux A, Hacene K, Terrier P, Bui NB, et al. Prognostic factors for patients with localized primary malignant fibrous histiocytoma: a multicenter study of 216 patients with multivariate analysis. *Cancer.* 1996;77(9):1823–30.

---

## 13.1 Introduction

The gastrointestinal tract (GI) can be affected by many of the same soft tissue neoplasms that involve other parts of the body, such as leiomyosarcoma, leiomyoma, schwannoma, and perineurioma. A few soft tissue neoplasms, however, are unique to the gastrointestinal tract. Of these, gastrointestinal stromal tumor is one of the most common. This tumor emanates from the interstitial cells of Cajal that normally coordinate peristalsis for digestion.

---

## 13.2 Gastrointestinal Stromal Tumor

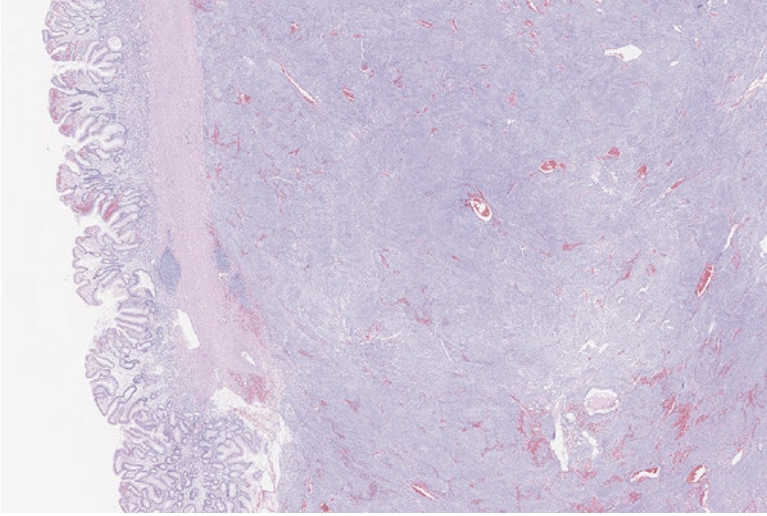
On average, gastrointestinal stromal tumors (GISTs) arise in the sixth decade of life, but can be found in patients in all ages, including children. The annual incidence of these tumors is 1.1 per 100,000 people [1]. They can occur anywhere along the enteric tract, but most frequently arise within the wall of the stomach and small bowel [2]. Presenting symptoms include GI bleeding, anemia, or bowel obstruction [3].

These tumors are usually sporadic, but can arise in association with various syndromes, which should be suspected if multiple lesions are identified or if the affected patient is particularly young. Associated syndromes include Carney triad (paraganglioma, pulmonary chondroma, gastrointestinal stromal tumor), Carney-Stratakis syndrome (paraganglioma and gastrointestinal stromal tumor), familial gastrointestinal stromal tumors, and neurofibromatosis [4–6].

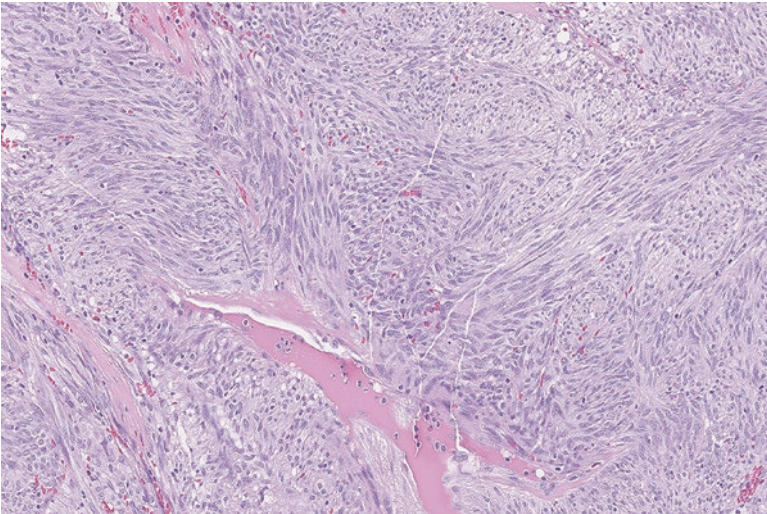
### Pathology

On gross examination, GISTs are usually fibrous masses in the wall or serosa of the bowel that measure several centimeters in size (Fig. 13.1). Microscopically, they typically show bundles of spindle cells with varying cellularity (Fig. 13.2). Nuclear





**Fig. 13.1** Gastrointestinal stromal tumor arising in the wall of the stomach. The overlying gastric epithelium is uninvolved

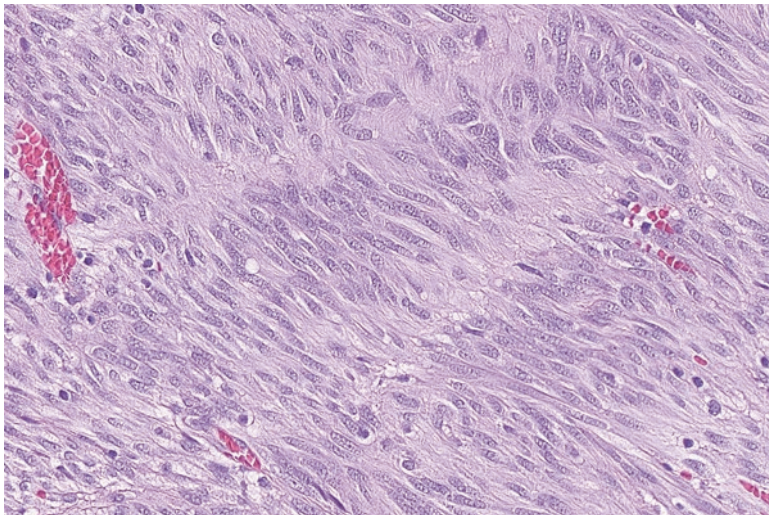


**Fig. 13.2** Gastrointestinal stromal tumor with bundles of relatively bland spindle cells

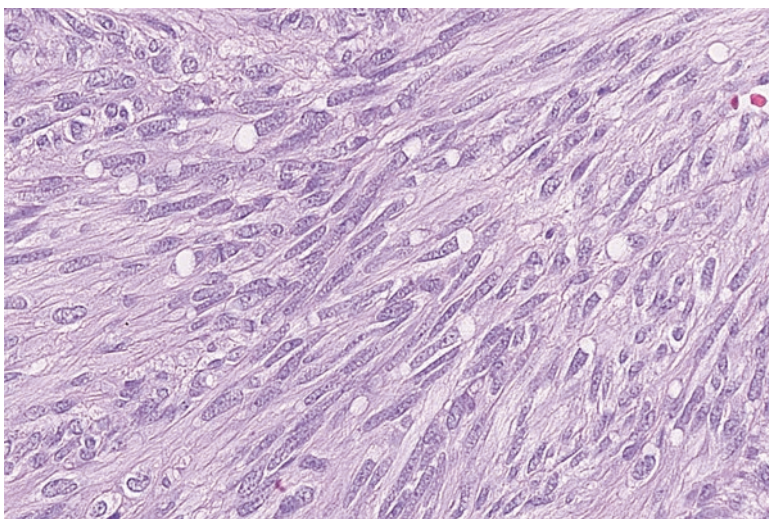
palisading or perinuclear vacuolization can be identified (Figs. 13.3 and 13.4). The tumor cells can also be epithelioid in appearance (Figs. 13.5 and 13.6).

### Ancillary Studies

- Gastrointestinal stromal tumors are positive for cKIT (CD117) or DOG1 immunohistochemical stains [7].

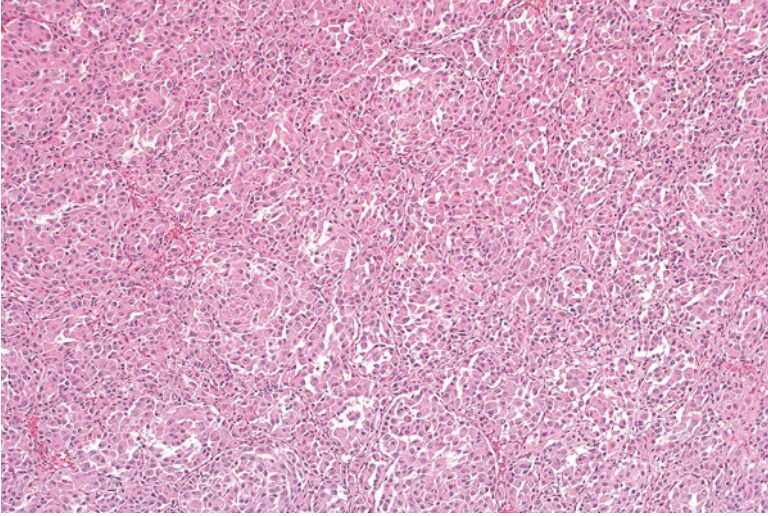


**Fig. 13.3** The spindle cells align to form a palisading-type pattern

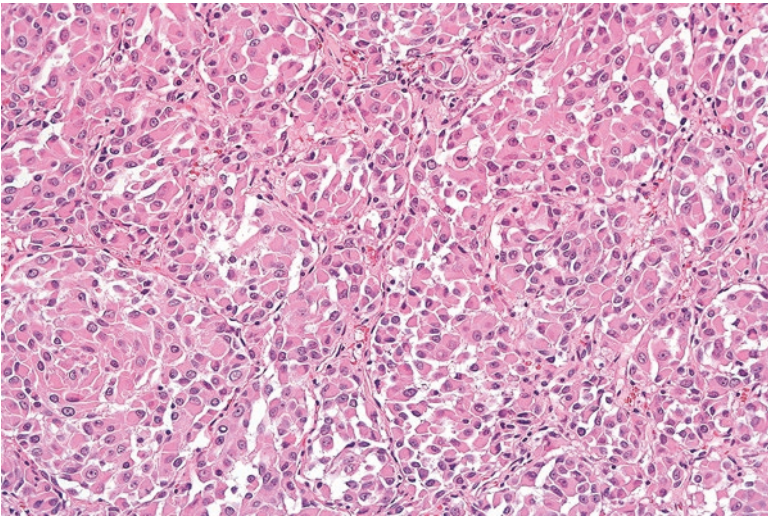


**Fig. 13.4** The spindle cells have clear vacuoles adjacent to the elongated nuclei

- Approximately 80% of GISTs will harbor a mutation in the *KIT* gene and 7% will harbor a mutation in the *PDGFRA* gene [8].
- GISTs that show no mutation in *KIT* or *PDGFRA* have been termed “wild-type” GISTs. These GISTs are still positive for cKIT and/or DOG1 immunohistochemical stains.
- Wild-type GISTs disproportionately occur in children and are often associated with Carney-Stratakis syndrome, Carney Triad, or neurofibromatosis [9].



**Fig. 13.5** This epithelioid appearing gastrointestinal stromal tumor exhibits tumor cells arranged in a vaguely nested architecture



**Fig. 13.6** The cells are more rounded and could be mistaken for epithelioid malignancies like carcinoma

### Differential Diagnosis

- Leiomyoma
- Schwannoma
- Inflammatory fibroid polyp

---

**Comments**

1. Gastrointestinal stromal tumor is usually distinguished from other spindle cell tumors in the GI tract by positive staining for CD117 or DOG1.
2. Gastrointestinal stromal tumors have a wide range of behaviors and are capable of recurrence and metastasis [10].
3. Studies have demonstrated that tumor size, mitoses, and site of occurrence can stratify GISTs into very low-, low-, intermediate-, and high-risk categories for risk of metastasis or tumor-related death [11–13].
4. Moderate-risk tumors have a 10–24% risk of progressive disease, while high-risk tumors have a 34–90% risk of progressive disease [13].
5. The primary treatment is complete surgical resection. As recurrence can occur decades after the original tumor resection, long-term follow-up is needed.
6. Recurrent or metastatic GISTs generally respond to imatinib mesylate, which targets the mutated KIT or PDGFRA tyrosine kinase receptors on tumor cells.
7. The location of the *PDGFRA* or *KIT* mutation can help predict the patient's response to imatinib and prognosis [8].
8. GISTs with mutations in exon 11 respond well to imatinib, while tumors with mutations in exon 9 require an increased dose for optimum response [14].
9. Approximately half of patients treated with imatinib will develop resistance within 2 years of treatment. These patients can be given second line tyrosine kinase inhibitors such as sunitinib [15].

---

**References**

1. Tryggvason G, Gislason HG, Magnusson MK, Jonasson JG. Gastrointestinal stromal tumors in Iceland, 1990–2003: the icelandic GIST study, a population-based incidence and pathologic risk stratification study. *Int J Cancer*. 2005;117(2):289–93.
2. Emile JF, Brahimi S, Coindre JM, Bringuier PP, Monges G, Samb P, et al. Frequencies of KIT and PDGFRA mutations in the MolecGIST prospective population-based study differ from those of advanced GISTs. *Med Oncol*. 2012;29(3):1765–72.
3. Hornick JL, editor. *Practical soft tissue pathology: a diagnostic approach*. 1st ed. Philadelphia: Saunders; 2013.
4. Miettinen M, Fetsch JF, Sobin LH, Lasota J. Gastrointestinal stromal tumors in patients with neurofibromatosis 1: a clinicopathologic and molecular genetic study of 45 cases. *Am J Surg Pathol*. 2006;30(1):90–6.
5. Nishida T, Hirota S, Taniguchi M, Hashimoto K, Isozaki K, Nakamura H, et al. Familial gastrointestinal stromal tumours with germline mutation of the KIT gene. *Nat Genet*. 1998;19(4):323–4.
6. Stratakis CA, Carney JA. The triad of paragangliomas, gastric stromal tumours and pulmonary chondromas (Carney triad), and the dyad of paragangliomas and gastric stromal sarcoma (Carney-Stratakis syndrome): molecular genetics and clinical implications. *J Intern Med*. 2009;266(1):43–52.
7. Miettinen M, Wang ZF, Lasota J. DOG1 antibody in the differential diagnosis of gastrointestinal stromal tumors: a study of 1840 cases. *Am J Surg Pathol*. 2009;33(9):1401–8.
8. Hornick JL, editor. *Practical soft tissue pathology: a diagnostic approach*. Philadelphia: Saunders; 2013.

9. Patil DT, Rubin BP. Genetics of gastrointestinal stromal tumors: a heterogeneous family of tumors? *Surg Pathol Clin.* 2015;8(3):515–24.
10. Miettinen M, Sobin LH, Lasota J. Gastrointestinal stromal tumors of the stomach: a clinicopathologic, immunohistochemical, and molecular genetic study of 1765 cases with long-term follow-up. *Am J Surg Pathol.* 2005;29(1):52–68.
11. Joensuu H. Risk stratification of patients diagnosed with gastrointestinal stromal tumor. *Hum Pathol.* 2008;39(10):1411–9.
12. Joensuu H, Vehtari A, Riihimaki J, Nishida T, Steigen SE, Brabec P, et al. Risk of recurrence of gastrointestinal stromal tumour after surgery: an analysis of pooled population-based cohorts. *Lancet Oncol.* 2012;13(3):265–74.
13. Miettinen M, Lasota J. Gastrointestinal stromal tumors: pathology and prognosis at different sites. *Semin Diagn Pathol.* 2006;23(2):70–83.
14. Debiec-Rychter M, Sciort R, Le Cesne A, Schlemmer M, Hohenberger P, van Oosterom AT, et al. KIT mutations and dose selection for imatinib in patients with advanced gastrointestinal stromal tumours. *Eur J Cancer.* 2006;42(8):1093–103.
15. Heinrich MC, Maki RG, Corless CL, Antonescu CR, Harlow A, Griffith D, et al. Primary and secondary kinase genotypes correlate with the biological and clinical activity of sunitinib in imatinib-resistant gastrointestinal stromal tumor. *J Clin Oncol.* 2008;26(33):5352–9.

---

# Index

## A

Abdominal fibromatosis, 60  
Accuracy, 4  
    Adipocytes, 29–31, 35, 36  
Adipocytic tumors, 12  
Adult-type fibrosarcoma, 76–78  
AIDS-related Kaposi sarcoma, 139  
Alcoholism, 59  
ALK, 66, 67  
ALK immunohistochemical stain, 66  
Alveolar/embryonal rhabdomyosarcoma, 23  
Alveolar rhabdomyosarcoma, 115, 116  
Alveolar soft part sarcoma, 173–175  
American Joint Committee on Cancer (AJCC), 23  
Amilial gastrointestinal stromal tumors, 197  
Aneurysmal fibrous histiocytoma, 81  
Angiolipoma, 31–33  
Angiomyolipoma, 180  
Angiosarcoma, 148–152  
Angiosarcoma of the breast, 148  
Anti-CAMTA1, 143, 145  
Antoni A areas, 123  
Antoni B areas, 123  
Arrhythmia, 109, 112  
Arteries, 139  
ASPSR1-TFE3, 173  
Atypical lipomatous tumor/well-differentiated liposarcoma, 37–39  
Atypical teratoid/rhabdoid tumors of the central nervous system, 185  
Axons, 123, 126, 128

## B

Benign, 2, 4, 6  
Benign vascular lesions, 139  
Beta-catenin, 57  
Bilateral vestibular schwannomas, 126

Botryoid variant of embryonal rhabdomyosarcoma, 113, 115, 120  
Brown fat, 35, 45

## C

café-au-lait spots of the skin, 126  
Cardiac dysfunction, 109  
Cardiac rhabdomyoma, 109, 110  
Carney-Stratakis syndrome, 197  
Carney syndrome, 165  
Carney triad, 197  
Cartilaginous tumors, 12  
CDK4, 31, 38, 40  
Cellular fibrous histiocytoma, 81  
Chondroid, 12, 13, 17, 155  
Chromosomal analysis, 15  
Chromosomal karyotyping, 15  
Cigar-shaped, 94  
Classification, 1–3, 6  
Clear Cell Sarcoma of Soft Tissue, 175–176  
COL1A1, 69  
College of American Pathology, 27  
Congenital/infantile fibrosarcoma, 70, 71  
Congenital mesoblastic nephroma, 70  
Consumptive thrombocytopenia, 145  
Crizotinib, 67  
Cryostat, 19, 20  
CTNNB1, 61  
Culture, 15  
Curvilinear vessels, 74  
Cutaneous angiosarcoma, 148, 152  
Cutaneous leiomyoma, 97–99  
Cutaneous leiomyosarcomas, 101

## D

DDIT, 43  
Dedifferentiated liposarcoma, 40, 41

- Deep (desmoid-type) fibromatosis, 60–62  
 Deep fibrous histiocytoma, 84  
 Deep leiomyoma, 99–101  
 Deep leiomyosarcoma, 103–105  
 Dermatofibroma, 81  
 Dermatofibrosarcoma protuberans (DFSP), 67–70  
 Desmin, 97  
 Desmoplastic small round cell tumor, 179  
 Diabetes mellitus, 54, 59  
 Diagnostic comment, 27  
 Differentiation score, 23  
 Diffuse neurofibroma, 129  
 DOG1, 198
- E**
- Elastin fibers, 55, 57–59  
 Elastofibroma, 57–59  
 Embryonal rhabdomyosarcoma, 112, 113  
 Endemic (African) Kaposi sarcoma, 139  
 Endothelial cells, 150  
 Eosinophilic granular/vacuolated cytoplasm, 35  
 Epidermal inclusion cysts, 56  
 Epithelioid hemangioendothelioma, 143  
 Epithelioid sarcoma, 182  
 Epithelioid tumors, 7  
 Erythrocytes, 145  
 ETV6-NTRK3, 70, 71  
 Ewing sarcoma, 10, 177  
 EWS, 43  
 EWSR1, 170, 177  
 EWSR1-ATF1, 175  
 EWSR1-CREB1, 175  
 EWSR1-ERG, 177  
 EWSR1-WT1, 179  
 Extra-abdominal fibromatosis, 60  
 Extrarenal rhabdoid tumor, 185–186  
 Extraskeletal chondroma  
   diagnosis, 156  
   pathology, 155  
 Extraskeletal mesenchymal chondrosarcoma, 158  
 Extraskeletal myxoid chondrosarcoma, 188  
 Extraskeletal osteosarcoma, 13, 160  
   diagnosis, 160  
   pathology, 160
- F**
- Familial adenomatous polyposis, 56, 57, 60, 77  
 Familial syndromes, 4, 6  
 Fascicular/herringbone pattern, 7  
 Fascicular pattern, 9  
 Fasciectomy/aponeurosectomy, 60  
 Fat necrosis, 29, 31, 39  
 Fetal rhabdomyoma, 111  
 Fibroblastic cells, 50  
 Fibroblasts, 49  
 Fibroma of tendon sheath, 53, 54  
 Fibrosarcomatous variant of  
   dermatofibrosarcoma protuberans, 68, 69, 76  
 Fibrous dysplasia, 163  
 Fibrous histiocytoma, 69, 81–85  
 Final diagnosis, 27  
 FLI-1, 177  
 Floret cells, 33  
 Fluorescence in situ hybridization, 18  
 FNCLCC grading system, 24  
 Foamy cytoplasm, 81  
 French Federation of Cancer Centers Sarcoma Group (FNCLCC), 23  
 Fresh tumor tissue, 15  
 Frozen section procedure, 18  
 Frozen tissue, 19  
 Fumarate hydratase gene, 97  
 FUS, 43  
 FUS-CREB3L1, 73  
 FUS-CREB3L2, 73
- G**
- Ganglion-like cells, 50, 52  
 Gardner-associated fibroma, 56, 57  
 Gardner syndrome, 56  
 Gastrointestinal stromal tumors (GISTs)  
   diagnosis, 200  
   pathology, 197  
 Gastrointestinal tract, 197  
 Genital leiomyomas, 97  
 Genital rhabdomyoma, 112  
 Giant cell tumor of the tendon sheath, 87  
 Gliomas, 126  
 Glomangioma, 93  
 Glomus  
   body, 93  
   cells, 94  
   neoplasm, 97  
   tumors, 93  
 Glomuvenous malformation, 93  
 GLUT-1, 47, 48  
 GNAS1, 163  
 Grade, 23–25, 27  
 Granular cell tumor, 133–135  
 Gross examination, 25, 27  
 Gynecologic leiomyomas, 100

**H**

HAART therapy, 143, 154  
h-caldesmon, 95  
Hematoxylin and eosin (H&E), 7  
Hemosiderotic fibrolipomatous tumor (HFLT),  
167, 168, 170  
Hereditary leiomyomatosis and renal cell  
cancer syndrome (HLRCC), 97  
HEY1-NCOA2, 158  
Hibernoma, 35–36  
Histologic grade, 1  
HIV epidemic, 139  
HMBA2, 29  
Human herpes virus 8 (HHV-8), 139, 142,  
143, 147, 148, 152  
Hypoglycemia, 62

**I**

Iatrogenic (transplantation-related) Kaposi  
sarcoma, 139  
Immunohistochemical staining, 15, 16  
Immunohistochemistry, 15, 16  
Infantile fibrosarcoma, 70, 71  
Inflammatory myofibroblastic tumor, 65–67  
INI-1, 182  
Insulin growth factor, 62  
Intermediate (locally aggressive), 2–3  
Intermediate (rarely metastasizing), 2, 3  
Intra-abdominal fibromatosis, 60  
Intramuscular myxoma, 163–165  
Intraoperative consultation, 18–21  
Ischemic fasciitis, 50

**J**

Juvenile xanthogranuloma, 85

**K**

Kaposiform hemangioendothelioma, 145  
Kaposi sarcoma, 139  
Karyotyping, 15, 18  
Kasabach-Merritt syndrome, 145  
KIT, 199

**L**

Labeled, 4  
Latency-associated nuclear antigen  
(LANA-1), 142  
Leiomyoma, 97, 200  
Leiomyoma of the extremity, 100  
Leiomyosarcoma, 3

Lipoblastoma, 36, 37  
Lipoblasts, 30, 36, 37, 42, 44  
Lipoma, 29–31, 39  
intramuscular lipomas, 31  
Lipomatous tumors, 29–45  
Lisch nodules, 126  
Low-grade fibromyxoid sarcoma,  
71–74  
Lymphangiomyoma, 180  
Lymphatics, 139  
Lymphomas, 9

**M**

Malignant, 2–4, 6  
Malignant fibrous histiocytoma  
(MFH), 190  
Malignant myoepithelioma, 170  
Malignant peripheral nerve sheath tumor,  
135–137  
Margin, 4, 5  
Mazabraud syndrome, 163  
Mediastinum/spermatic cord, 37  
Meningiomas, 126  
MGEA5, 167  
Microscopic examination, 27  
Mitotic score, 23  
Mohs micrographic surgery, 69  
M stage, 25  
mTOR inhibitors, 182  
MUC4, 73  
MYC, 150  
Myelin, 123  
MyoD1, 113, 116, 119, 120  
Myoepithelioma, 169–171  
Myofibroblasts, 49  
Myofilaments, 109  
Myogenin, 109, 113, 116, 119  
Myxofibrosarcoma, 74–76  
Myxoid liposarcoma, 11, 41–43  
Myxoid malignant fibrous histiocytoma, 74  
Myxoid tumors, 11

**N**

Necrosis score, 23  
Needle core biopsies, 4–6  
Neoadjuvant therapy, 25  
Neural and nerve sheath lesions  
neurofibroma, 126–130  
schwannoma, 123  
Neuroendocrine carcinomas, 9  
Neurofibroma, 126  
Neurofibroma adjacent adipose tissue, 129



Neurofibromatosis, 197  
 type 1, 126  
 type 2, 126  
 NF1, 126  
 NF2, 126  
 Nodular fasciitis, 49  
 Normal smooth muscle, 3  
 NR4A3, 190  
 NR4A3-EWSR1, 190  
 NR4A3-TAF15, 190  
 NR4A3-TCF12, 190  
 N stage, 25  
 Nuchal-type fibromas, 54–56

## O

Optic gliomas, 126  
 Orientation, 4, 6  
 Osseous tumors, 12  
 Ossifying fibromyxoid tumors, 171  
 Osteoid, 12, 13  
 Osteomas, 56

## P

Palmar fibromatosis, 59  
 Paraffin block, 5  
 Pathologic stage, 25, 27  
*Pathology and Genetics of Tumours of Soft Tissue and Bone*, 1  
 Pathology report, 25, 27  
 Patternless pattern, 62  
 PAX3-FOXO1A, 116, 118, 120  
 PAX7-FOXO1, 116, 118, 120  
 PBX1, 170  
 PDGFB, 69  
 PDGFRA, 199  
 PEComa, 180–182  
 Penile fibromatosis, 59  
 Perineurioma, 130–132  
 Perineurium, 123  
 Peripheral nerves, 123  
 Perivascular epithelioid cell neoplasms (PEComas), 180  
 Perivascular tumors, 93  
 Peroxidase, 15  
 Peyronie disease, 59  
 PHF1, 171  
 Pigmented villonodular tenosynovitis (PVNS), 89  
 Pilar leiomyomas, 97  
 PLAG, 37  
 Plantar fibromatosis, 59  
 Pleomorphic liposarcoma, 2, 43–45

Pleomorphic rhabdomyosarcoma, 118, 119  
 Pleomorphic tumors, 10  
 Plexiform neurofibroma, 128  
 Poorly differentiated carcinomas, 8  
 Postirradiation angiosarcoma, 148, 152  
 POU5F1, 170  
 Proliferative fasciitis, 50  
 Proximal-type epithelioid sarcoma, 182  
 Pseudoepitheliomatous hyperplasia, 133  
 Pulmonary clear cell sugar tumor, 180

## R

Radiation therapy, 148, 152  
 Requisition form, 4, 6  
 Resection, 4, 5  
 Retroperitoneal fibrosis, 62  
 Retroperitoneal leiomyosarcomas, 103  
 Reverse transcriptase polymerase chain reaction (RT-PCR), 18  
 Rhabdoid tumors of the kidney, 185  
 Rhabdomyoblast, 114  
 Round cell tumors, 8

## S

Sacral plexus, 135  
 Schwann cells, 123  
 Schwannoma, 123–126, 200  
 Secretory carcinoma of the breast, 70  
 Skeletal muscle cells, 110  
 Skeletal muscle tumors  
 diagnosis, 111  
 pathology, 109  
 rhabdomyomas, 109  
 SMARCB1, 185  
 Smooth muscle, 93  
 actin, 97, 100, 101, 104  
 tumors, 93, 101  
 Soft tissue chondroma, 157  
 Soft tissue pathology, 1  
 classification, 1, 3  
 diagnosis, 27  
 patient and specimen identifiers, 27  
 synoptic report, 27  
 Soft tissue tumors, 17  
 Solitary fibrous tumor, 62–65  
 Solitary xanthogranuloma, 85–87  
 SOX-9, 158  
 Spider cells, 109, 110  
 Spindle cell lipoma, 32–34  
 Spindle cell/pleomorphic lipomas, 33, 34, 45

Spindle cell tumors, 7  
  storiform, 7  
STAT6, 63, 64  
STAT6 immunohistochemical stain, 63  
Stewart-Treves syndrome, 148  
Storiform pattern, 67  
Superficial angiomyxomas, 165  
  diagnosis, 166  
Superficial fibromatosis, 59, 60  
Synovial sarcoma, 186–188  
SYT-SSX1, 186  
SYT-SSX2, 186

**T**

t(2;13), 116  
t(7;16), 73  
t(11;16), 73  
t(12;15), 70  
Tenosynovial giant cell tumor  
  diffuse type, 87–91  
  localized type, 87–90  
TFE3, 173  
TGFBR3, 167  
Tissue culture, 49  
Tissue paper, 5  
TNM, 25  
Touton giant cells, 85–87  
T stage, 25  
Tuberous sclerosis, 109, 112

**U**

Ultrasound guided needle core  
  biopsies, 4  
Undifferentiated high-grade pleomorphic  
  sarcoma, 190–192  
USP6 mutation, 50

**V**

Vascular lesion, 139–152  
Vascular tumors, 12  
Veins, 139  
Verhoeff elastin stain, 57  
Verocay bodies, 123

**W**

Well-differentiated liposarcoma,  
  38, 39  
World Health Organization Classification of  
  Tumours, 1  
WWTR1-CAMTA1, 143

**Y**

YAP1-TFE3, 143

**Z**

ZNF444, 170