

Suicide By Asphyxiation Due to Helium Inhalation

Matthew O. Howard, PhD,* Martin T. Hall, PhD,† Jeffrey D. Edwards, MSW,* Michael G. Vaughn, PhD,‡
Brian E. Perron, PhD,§ and Ruth E. Winecker, PhD¶

Abstract: Suicide by asphyxiation using helium is the most widely promoted method of “self-deliverance” by right-to-die advocates. However, little is known about persons committing such suicides or the circumstances and manner in which they are completed. Prior reports of suicides by asphyxiation involving helium were reviewed and deaths determined by the North Carolina Office of the Chief Medical Examiner to be helium-associated asphyxial suicides occurring between January 1, 2000 and December 31, 2008 were included in a new case series examined in this article. The 10 asphyxial suicides involving helium identified in North Carolina tended to occur almost exclusively in non-Hispanic, white men who were relatively young (M age = 41.1 ± 11.6). In 6 of 10 cases, decedents suffered from significant psychiatric dysfunction; in 3 of these 6 cases, psychiatric disorders were present comorbidly with substance abuse. In none these cases were decedents suffering from terminal illness. Most persons committing suicide with helium were free of terminal illness but suffered from psychiatric and/or substance use disorders.

Key Words: asphyxia, helium, suicide, right-to-life

(*Am J Forensic Med Pathol* 2010;XX: 000–000)

Publication, in 1991, of the right-to-die manifesto and suicide “how-to” guide, *Final Exit: The Practicalities of Self-Deliverance and Assisted Suicide for the Dying*,¹ raised a maelstrom of controversy regarding the appropriateness of suicide as a response to terminal or “hopeless” physical illness and exposed divisions within the right-to-die movement itself. In the 1990s, many right-to-die advocates were engaged in public education as to the purported virtues of advanced directives, living wills, and legalized physician-assisted suicide.² At the same time, other elements of this movement, including the Self-Deliverance New Technology (NuTech) Group, were developing technologies to “empower people to die on their own terms by controlling the timing and manner of their own death.”² (p. 8) NuTech members, including Derek Humphry, author of *Final Exit*, sought to identify multiple suicide methods that were swift, painless, failure-proof, inexpensive, and nondisfiguring. The group also considered it vital that the method be simple, leave little or no indication that the death was unnatural in nature, and not require a physician’s assistance or prescription.²

With its detailed descriptions of diverse suicide methods and specific endorsement of the plastic bag asphyxiation method, publication of *Final Exit* brought an easily understood and generally

effective suicide method to the masses. The book was a commercial success, appearing on the New York Times bestseller list and selling more than 1.5 million copies in the decade following its publication. In 2007, *Final Exit* was named one of the 25 most influential books of the past quarter-century by book critics and editors of *USA Today*.³

Concerns that suicides in nonterminally ill depressed persons might follow exposure to methods elucidated in *Final Exit* were soon raised,⁴ and dramatic increases in plastic bag asphyxial suicides were observed in New York City⁵ and the United States⁶ in the year following publication of *Final Exit*. Investigators concluded that “most persons exposed to *Final Exit* were not terminally ill and had used it as a suicide manual ... (and that) it is likely that a psychiatric disorder would have been diagnosed in most of these people.”⁵ (p. 1509)

Efforts by NuTech and others to develop a more effective suicide method and widely disseminate it to the public have continued to the present. In 2000, a supplement to *Final Exit* was published that presented the first description of helium-assisted plastic bag asphyxiation.⁷ Advocates emphasized the enhanced lethality of this approach, reduction in time required for death to occur to less than 5 minutes, and elimination of the need for a sedative prescription. Proponents of the method also noted that materials needed to complete such suicides are readily accessible and that asphyxiation due to helium inhalation is often undetected by autopsy (where findings are typically nonspecific) or toxicological analysis (because special sampling and assay methods are required). Thus, such suicides are likely to remain undetected in cases where the helium delivery apparatus and plastic bag are removed before the death scene is examined and no other information is available implicating death by helium-assisted asphyxiation. Modifications of the helium method were published in 2002⁸ and 2009,⁹ a DVD including a step-by-step demonstration of the method is available for purchase,¹⁰ and instructional videos depicting the method are accessible on the internet. A schematic of the helium delivery apparatus is presented in Figure 1.⁹

Given the recent development, broad dissemination, and notable lethality of helium-assisted suicide, we endeavored to better understand characteristics of suicides by this method. First, we reviewed findings of extant studies examining suicides by asphyxiation due to helium inhalation. Second, we report new findings from the largest series of these suicides heretofore examined. Results of this investigation may lead to improved identification of helium-assisted suicides by medical examiners, enhanced screening and prevention efforts on the part of physicians and other professionals treating individuals at risk for suicide, and shed new light on unintended deleterious consequences of widespread dissemination of detailed suicide methods to the general public.

MATERIALS AND METHODS

The current report presents findings from 2 related studies. The first is a review of published investigations of suicides by asphyxiation due to helium inhalation. The second is a case series of suicides by asphyxiation due to helium inhalation occurring in North Carolina between 2000 (the year in which the method was first described) and December 31, 2008.

Manuscript received January 19, 2010; accepted March 3, 2010.

From the *School of Social Work, University of North Carolina at Chapel Hill; †Department of Behavioral Medicine, School of Medicine, University of Kentucky; ‡School of Public Health, Saint Louis University; §Department of Psychiatry, School of Medicine, University of Michigan; and ¶North Carolina Office of the Chief Medical Examiner.

Supported by NIH grants DA15929, DA15556, DA021405 (M.O.H.) and DA007304 (M.T.H.).

Correspondence: Matthew O. Howard, Frank Daniels Distinguished Professor, Tate-Turner-Kuralt Building, 325 Pittsboro, CB 3550, Chapel Hill, NC 27599–3550. E-mail: mohoward@email.unc.edu

Copyright © 2010 by Lippincott Williams & Wilkins

ISSN: 0195-7910/10/0000-0001

DOI: 10.1097/PAF.0b013e3181ed7a2d

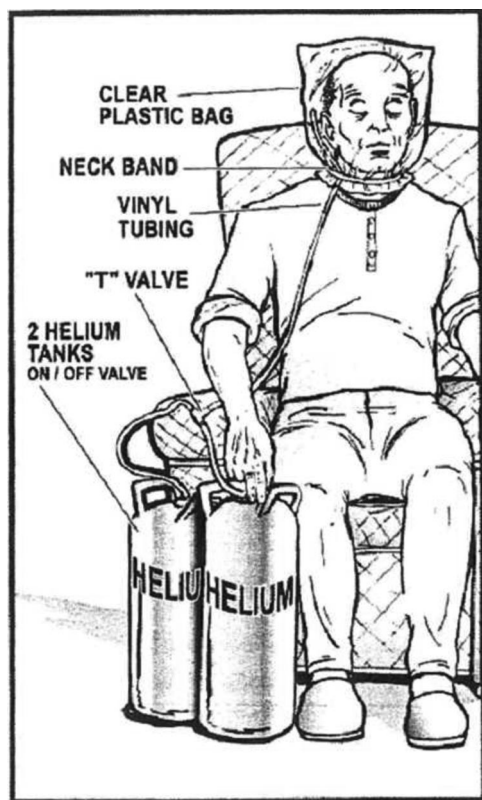


FIGURE 1. Schematic of plastic bag asphyxiation suicide using helium gas in final exit. Reprinted with permission from *Final Exit: The Practicalities of Self-deliverance and Assisted Suicide for the Dying*.⁹ (p.4)

Identification of Published Reports

A broad search of the general medical literature was undertaken for any relevant reports addressing suicide by asphyxiation due to helium inhalation. This process entailed searching the PubMed database for the period January 1, 1957 to November 1, 2009 using the search phrase “suicide and helium.” Seven pertinent records were identified as follows: 6 English-language case studies^{11–16} and a Danish-language case study.¹⁷ A search of EMBASE using the identical approach for the period January 1, 1988 to November 1, 2009 identified the same 7 reports. The 6 English-language reports relevant to this review were published between 2002 and 2007 and present a total of 14 cases.^{11–16} The Danish study included a synoptic abstract in English indicating that the decedent was a 35-year-old man who had committed suicide with a plastic bag and helium using a “new and highly lethal technique.”¹⁷ The case reports included in this review constitute the entirety of published research on helium-assisted suicide and are presented in Table 1.

Identification of Suicides by Asphyxiation Due to Helium Inhalation in North Carolina

All deaths determined by the North Carolina Office of the Chief Medical Examiner (NCOCME) to be asphyxial suicides due to helium inhalation that occurred between January 1, 2000 and December 31, 2008, were included in this study. These suicides were identified through a search of the manner and cause of death fields of the electronic records maintained by the NCOCME. The presence of helium was confirmed by toxicological testing in 9 of 10 identi-

fied cases. Only the first reported case (ie, 2001) was not subjected to toxicological testing for helium. Specimens from suspected helium asphyxiation cases autopsied at the NCOCME are collected in 20 mL headspace vials. In some cases, given that one central laboratory conducts testing for all medical examiner cases in the state, blood samples are delivered to the NCOCME in standard collection vials. Immediately upon arrival, 5 mL of blood from the standard autopsy vial is transferred to a headspace vial for later analysis. Medical records associated with these deaths were manually reviewed and abstracted including the OCME Report of Investigation, State of North Carolina Death Certificate, Report of Autopsy, Toxicology Report, Case Encounter Form, Pathologist’s Notes, and Supplemental Report of Cause of Death. On January 5, 2010, the University of North Carolina Institutional Review Board determined that the reported research does not require Institutional Review Board approval under pertinent federal regulations. Characteristics of the 10 cases identified are presented in Table 2.

RESULTS

Review of Published Cases

The first death attributed to suicide by asphyxiation due to helium inhalation reported in the medical literature occurred in September 2000,¹¹ shortly after the description of the method was published. Several investigators asserted that suicides by the helium method had not been seen in their localities prior to publication of the 2000 Supplement to Final Exit.^{11,12,15,16}

The 14 decedents whose cases were presented in the 6 published reports ranged in age from 19 to 81 (M age = 50.0, SD = 21.8, median = 48.5). Between these extremes, decedents were approximately evenly divided between those in their 20s, 30s, 40s, 60s, and 70s. Medical and psychiatric histories were scant or entirely unreported for some cases, but revealed a history of depression, prior suicide attempt(s), paranoid schizophrenia, or some combination thereof in 4 (25.6%) cases. In 4 (25.6%) additional cases, psychiatric dysfunction may have contributed to the suicide, given that 3 of these decedents were determined to be in good health (ages 49, 49, and 76) and one mentioned the recent death of his wife as a reason for his suicide in a note left at the death scene. In 5 other cases (including 4 decedents in their 20s or 30s), no medical or psychiatric histories were reported. A terminal disease process was present in only 2 of 14 (14.3%) cases. In 2 (14.3%) additional cases involving men ages 71 and 78, “failing health” and “unspecified health problems” were possible contributing factors. Medical disorders were not implicated in 10 of 14 (71.4%) suicides.

In all reported cases, routine toxicological testing did not reveal the presence of helium and manner and cause of death determinations relied heavily on death scene investigations. Autopsy findings tended to be absent or nonspecific in the 12 cases that involved an autopsy.

In 8 cases (57.1%), a suicide note was found, and in 4 cases (28.6%) right-to-die literature was found at the death scene.

A number of helium delivery devices were employed. Five cases involved use of a mask; 4 of these cases were reported in 2002 or 2003, before plastic bag asphyxiation (without use of a mask) became preferred by advocates of the helium method.⁸ Characteristics of the plastic tubing used, use of rubber bands and Velcro straps to secure plastic bags to the neck, types of helium canisters employed, and use of multiple plastic bags in 1 case were consistent with published descriptions of helium-assisted suicide.⁸

Characteristics of Suicides by Asphyxiation due to Helium Inhalation in North Carolina

Asphyxial suicides in North Carolina involving helium inhalation tended to occur almost exclusively in non-Hispanic, white

TABLE 1. Published Case Reports of Suicides by Asphyxia Due to Helium Inhalation

Authors/Date/Location	Characteristics of Decedent	Medical/Psychiatric History	Helium-Delivery Apparatus	Death Scene	Autopsy Findings	Toxicology Findings
Ogden and Wooten (2002), South Carolina ¹¹	Woman, 60, white, suffering from adenoid cystic carcinoma with related eye involvement and diplopia. Death occurred 9/2000	History of depression and a prior suicide attempt. Unclear whether depression/suicide attempt antedated carcinoma diagnosis.	Found with surgical mask over face and clear plastic bag over head. Next to body was refillable industrial tank of helium. Clear plastic tube led from plastic bag to helium tank valve.	Decedent discovered on living room floor of home with suicide note and copy of her will. The book <i>Final Exit, Final Exit</i> videotape, and Spring 2000 Hemlock society newsletter were found on a nearby coffee table.	Does not appear an autopsy was conducted. It was noted at death scene that decedent's skin color was unremarkable and no external signs of poisoning were observed.	Blood/urine tests for medications and psychoactive substances were negative.
Gilson et al. (2003) Tucson, Arizona ¹²	Cases 1 and 2: man, 49 and woman, 48, who were common-law married. Cases 3 and 4: husband, 78; wife, 76	No specific information presented; decedents were reportedly in good health. Motivation for suicide unclear. Husband reportedly in "failing health" and "depressed"; wife in "good health" other than a recent minor elective surgery.	Each decedent had 3 plastic bags over their heads, which were secured by elastic straps around their necks. Both decedents were wearing filter cartridge-style masks attached to helium tanks with plastic tubing. Plastic bag over head with plastic tube running from inside plastic bag to helium tank.	Couple found lying supine by police on floor of master bedroom in their residence. Couples' attorney had called police after receiving a mailed suicide note. No right-to-die materials found. Couple found dead in bed by neighbor. Suicide notes were found close to bodies. Notes referring to the Hemlock society were found in apartment. No other right-to-die materials found. Found by daughter in bed. Family unable to provide information as to whether "right-to-die" literature or suicide note were found at death scene.	Remarkable only for early decomposition changes.	Unremarkable for both decedents.
Gilson et al. (2003) Tucson, Arizona (continued)	Case 5: man, 81	Advanced squamous cell carcinoma of throat, cleftic.	Plastic bag over head with plastic tube running from inside plastic bag to helium tank.	Found by daughter in bed. Family unable to provide information as to whether "right-to-die" literature or suicide note were found at death scene.	Not clear that an autopsy was conducted.	Blood and urine tests were negative, but it was not clear what substances were assayed.
	Case 6: man, 71	Decedent mentioned unspecified health problems and the recent death of his wife as principal reasons for his suicide.	Plastic bag over head secured with elastic band and Velcro strap at neck. Plastic tube from helium tank connected to the mask inside plastic bag.	Found expired in chair in living room of home by police. A suicide note found, but no right-to-die literature.	External exam unremarkable except for decomposition.	Toxicology tests not performed due to decomposition.
	Case 7: man, 25	Medical history unknown; motivation for suicide unclear.	Plastic bag over head with plastic tube running from helium tank to bag with tube passing through a sink where warm water was running.	Found dead in empty bathtub of his apartment by landlord. Right-to-die literature and suicide note were not found.	Unremarkable except for decomposition changes.	Remarkable only for ethanol (234 mg/dL) in decomposition fluid.
Gallagher et al. (2003), Indiana ¹³	Woman, 19, well-nourished	History of prior suicide attempts (number and nature not described). No description of medical history. Had searched methods of suicide on the internet.	Decedent wore air filter gas mask coated with a substance similar to correction fluid. A helium tank obtained from a local supply company was attached via clear plastic tubing to the mask. Duct tape sealed mask to skin of face covering nose and mouth.	Decedent found supine in backseat of car with helium tank on floor and valve between knees. Many signed suicide notes and a page from the "Church of Euthanasia" website entitled "How to kill yourself" were left in an envelope on the driver's seat. A hand-written map to a local general store was also found in the envelope with a list including tubing, mask and duct tape. A letter was found in decedent's residence describing where her body was located.	Conjunctival petechial hemorrhages bilaterally. Nares and oral cavity contained frothy white edema fluid. R lung = 670 g; L lung = 620 g. Lungs congested with severe pulmonary edema. No evidence of trauma, injury, or explanation for death other than helium inhalation.	Routine toxicology unremarkable. Presents a method by which specimens can be collected and analyzed for the presence of helium.
Auwaerter et al. (2007) Freiburg, Germany ¹⁴	Man, 23	No information presented.	A helium gas canister was connected to a plastic bag with polypropylene tubing. The bag was over the decedent's head and affixed to neck with a rubber band.	Decedent found dead in "lying" position in unidentified location. A nearly empty bottle of tequila, blister pack of travel sickness medication, and pack of Ibuprofen tablets were found.	Nonspecific findings included "an aqueous swelling of the brain and of the lungs and an acute hyperemia of the kidneys." No evidence of severe illness or injury.	Routine tests revealed a BAC of 0.9 mg/g; diphenhydramine in heart serum (0.81 µg/mL) and urine (2.2 µg/mL). Ibuprofen found in urine and gastric content. A positive test for helium by novel assay method was reported.

(Continued)

TABLE 1. (Continued)

Authors/Date/ Location	Characteristics of Decedent	Medical/Psychiatric History	Helium-Delivery Apparatus	Death Scene	Autopsy Findings	Toxicology Findings
Grassberger & Krauskopf (2007) Vienna, Austria ¹⁵	Case 1: man, 28	History of paranoid schizophrenia; otherwise, no medical history reported.	Found with plastic bag over head sealed at neck with duct tape. A 10 L tank of party balloon helium was connected to the bag via plastic tubing.	Decedent found expired in his apartment reclining in a chair. Mouth contained frothy white edema fluid. A suicide note was left which named his mental illness as the primary reason for his suicide. No right-to-die literature found in domicile.	External exam unremarkable. Engorgement of right atrium and ventricle, pulmonary edema, and a few subpleural petechiae.	Blood/urine tests for 6 classes of illicit drugs were negative. Not clear whether ethanol was assayed.
	Case 2: man, 39	Not reported	Plastic tubing led from industrial helium tank into plastic mask.	Found expired in an empty bathtub wearing a plastic mask over face. Right-to-die literature and suicide note were found.	Autopsy remarkable, only for early decompositional changes.	Tests of decomposition fluid identified a BAC of 1 mg/L.
	Case 3: man, 39	Not reported.	Plastic bag over head connected via plastic tubing to a 10 L helium tank affixed to neck with rubber band.	Found supine on floor of his apartment with plastic bag over head. A suicide note was found.	External/internal exams unremarkable except for advanced decompositional changes.	Negative except for traces of benzodiazepines in urine.
Schon & Ketterer (2007) Bern, Switzerland ¹⁶	Man, 64, white	Not reported	A gas canister labeled "helium" was found on a table at side of room opposite from where body was found. The helium canister was not connected to the 17 L blue plastic garbage bag that was found over the decedent's head. In addition to the plastic ribbon used to tie the bag, the decedent had inserted a rubber band into the bag's collar. The bag was secured tightly around decedent's neck.	Decedent found expired in hotel room lying supine on bed with garbage bag over head. No alcohol bottles, medications or drug paraphernalia were found. A rental receipt for the helium canister was found, but no suicide note or self-help materials. An inquiry at the decedent's home town revealed that another person in the area had committed suicide using the same method within the same week.	No external injuries/petechial hemorrhages found, except for a ligature mark impression attributed to a rubber band around neck. Nose, mouth, and airways filled with frothy reddish fluid. Lungs/brain edematous. Internal organs acutely congested. Pulmonary emphysema and hypertrophy/dilation of right atrium/ventricle noted. No other potential causes of death were identified.	No obvious evidence of alcohol/drug abuse, but no toxicology assays performed.

TABLE 2. Characteristic of Suicides by Asphyxiation due to Helium Inhalation in North Carolina: 2000–2008

Year of Death	Characteristics of Decedent	Medical/Psychiatric History	Helium-Delivery Apparatus	Death Scene Description	Autopsy Findings	Toxicology Exam Findings
2001	Man, 47, never-married, white (non-Hispanic) graduate school education	Long history of depression treated by his physician. Depression listed as a contributing cause of suicide. Little information available about medical or psychiatric history or acute precipitants of suicide.	Plastic bag over head, secured with velcro tie around neck. Plastic tubing was taped to top of head, extended down left arm under shirt sleeve and exited at left cuff. The tubing was connected to a T-valve and attached to 2 helium tanks.	Found in living room of his home by a co-worker and police. Two bottles of temazepam and a will and suicide note found at scene.	Early decompositional changes noted at death scene; no autopsy conducted.	Trace levels of 7-aminoclonazepam, and temazepam (0.016 mg/L) were identified in a 1 mL sample of vitreous humor.
2003	Man, 31, married, white (non-Hispanic), 13 yr of education	Suicide note mentioned "chronic pain" as a reason for suicide. However, medical and psychiatric history are not known.	Clear blue, thin plastic bag over head secured with 2 large yellow rubber bands around neck. Clear plastic bag taped to inside of plastic bag, extending out of bag, looping around left arm and connected to helium tank.	Decedent found in his apartment. Had left a suicide note describing how he planned the suicide. No medications found in apartment.	Pathological diagnosis: bilateral pulmonary congestion. No significant external/internal injuries. Lungs: R lung: 750 g; L lung: 640 g. Parenchyma of both lungs show extensive congestion w/o obvious consolidation or focal lesions. Brain: 1500 g. Leptomeninges thin, delicate and congested. Cerebral hemispheres unremarkable w/mild generalized edema w/o evidence of herniation. Microscopic exams of lungs, kidneys, and brain show vascular congestion. No evidence of injury.	Two 8.0 mL aortic blood samples were positive for helium as was one lung sample. No ethanol detected in an 18.0 mL aortic blood sample.
2005	Man, 37, married, white (non-Hispanic); 16 yr of education	Medical and psychiatric history and acute precipitants of suicide are unclear.	Found with white plastic trash bag around head with tube hooked to helium tank valve at one end and the other end within the plastic bag. Tubing was connected to the helium tank with electrical tape. The bag was secured to neck with bow knot on right anterior neck. A clear vinyl plastic tube extended into the bag through a hole made in the rear of the bag space, held in place by black electrical tape.	Death occurred in motel. Decedent found supine in bed. Medications found at scene were an OTC sleep aid, Ibuprofen, and hydrocodone. Receipts from a local hardware store were found for helium tank, tubing, and tape. No suicide note or right-to-die materials were found.	Pathological diagnoses: pulmonary vascular congestion and edema, slight diffuse cerebral swelling, moderate coronary atherosclerosis. R lung: 920 g; L lung 700 g. Lungs on section demonstrate marked vascular congestion. Bronchial branches contain clear fluid and intra-alveolar edema. Brain: 1500 g with mild diffuse swelling and narrowing of sulci. No evidence of acute trauma.	10 mL aortic blood sample revealed trace levels of cyclobenzaprine and propoxyphene and was positive (0.91 mg/L) for helium. Diphenhydramine, and diphendramine, and helium. Diphenhydramine was believed to have contributed to the death. No ethanol or organic bases were identified.
2005	Man, 21, never married, white (non-Hispanic) 12 yr of education	History of symptoms, treatment, and hospitalization for paranoia/suicidal ideation. Not clear whether patient suffered from psychotic illness.	Plastic bag over head with elastic strap securing bag around neck. An empty helium canister found on floor beside decedent. A cylinder of helium and plastic tubing were found in decedent's bedroom closet.	Found in bedroom at parent's home sitting in chair. The following medications were found in home: Trazodone (100mg), Geodon (80mg), Risperdal (3mg), Trileptal (300mg), and Zoloft (50mg).	Pathological diagnosis: pulmonary vascular congestion and edema, cerebral edema, and early decompositional changes. R lung: 640 g; L lung: 590 g. Brain: 1,500 g. Microscopic lung sections show variable degrees of pulmonary vascular congestion and intra-alveolar hemorrhage.	Post-mortem exam revealed an ethanol level of .40 mg/dL and the presence of helium in 15.0 mL and 5.0 mL aortic blood samples, respectively.
2005	Man, 39, never married, white (non-Hispanic), 12 yr of education	No history of suicide attempts per family. Little information available about medical or psychiatric history and acute precipitants of suicide.	Found with plastic bag over head secured with a metal clip to hold bag tight around neck. Plastic tubing ran from a nearby helium tank to the back of the plastic bag. Duct tape covered front of bag and had 0.5 cm circular hole in it. Tube was connected to helium tank, which was turned on and near decedent's hand.	Found lying supine in bed at home by mother. No suicide note left, but insurance policy and will were found on coffee table.	Final anatomic diagnosis: congestion of lungs with early pulmonary edema. Brain: 1,325 g. Vessels over right hemisphere congested. R lung: 610 g; L lung: 560 g. Lungs boggy with congestion. Microscopic sections show that alveolar spaces were partially filled with clear edema fluid.	Positive for helium in 4.0 mL subclavian vessel blood sample, but negative for ethanol in 17.0 mL subclavian blood sample.

(Continued)

TABLE 2. (Continued)

Year of Death	Characteristics of Decedent	Medical/Psychiatric History	Helium-Delivery Apparatus	Death Scene Description	Autopsy Findings	Toxicology Exam Findings
2005	Man, 34, unmarried, white (non-Hispanic); 9 yr of education	History of alcohol dependence and bipolar disorder. Prior psychiatric treatment for both disorders. Was living in car and taking Zolof.	Had clear plastic bag over head with tubing connecting it to a helium tank. A velcro closure secured the bag around neck.	Found dead in driver's seat of a car parked in the yard of a relative's house. A picture of his girlfriend was found on dashboard.	Pathological diagnoses: pulmonary edema and vascular congestion; atherosclerotic coronary artery disease, focal, mild to moderate. R lung: 960 g; L lung 820 g. Lungs heavy and congested. Lung sections revealed areas of atelectasis, pulmonary edema, and collections of pigment-laden intra-alveolar macrophages.	20.0 mL and 6.0 mL aortic blood samples were positive for ethanol (70 mg/dL) and helium, respectively. Ethanol was listed as a contributing cause of suicide.
2006	Woman, 60, never married white (non-Hispanic), 12 yr of education	Obese (5'9", 303 lbs). No medical or psychiatric history information available except that EKG leads were found on right lower leg, left lower leg and left arm. No acute precipitants of suicide were identified.	Decedent had clear plastic bag over head with 1/2 inch plastic tubing attached to helium tank in back car seat and inside of plastic bag. A tan elastic band was used to secure bag to neck. The plastic tubing was taped to lower margin of plastic bag.	Decedent found in front passenger seat of car in motel parking lot where she had stayed. Letters to different people and "a very organized" suicide note were found in car. Note referred to pgs. 132–137 in Final Exit 3rd edition which describe helium-assisted suicide. Decedent had set e-mail to respond to messages with "Return to Sender due to Suicide."	Pathological diagnoses: Plastic bag over head with evidence of helium inhalation; pulmonary vascular congestion (R lung: 430 g; L lung: 400 g); decomposition. Sectioned lungs showed vascular congestion with patchy intra-alveolar edema. No evidence of acute trauma.	A 20-mL-blood sample from pleural cavity was positive for helium and ethanol (40 mg/dL). Elevated BAC may have been partially or totally due to decomposition.
2007	Man, 41, married (but recently separated from wife), white (non-Hispanic), 14 yr of education	Previously disabled in motor vehicle accident with neck and back injuries. Was reportedly depressed due to recent separation from wife and pending sale of home. Wife reported that decedent was taking prescribed antidepressants, Neurontin, Oxycodone, and Vicodin.	Clear blue plastic bag covered head and was wrapped with duct tape. Black tubing was connected at one end to the inside of bag and at the other end to a 65lb helium tank used to fill balloons for parties.	Found expired at home sitting in chair in basement. No suicide note left.	No autopsy.	A 13.0 mL subclavian blood sample was negative for ethanol, but positive for helium.
2007	Man, 45, never married, white (non-Hispanic)	History of alcohol and drug abuse and diabetes. Decedent has been very depressed per family's report. Family noted a history of social, medical and emotional problems. Was taking Coumadin, Clonidine, Aspirin, Verapamil, Atenolol, and Lovastatin.	Clear plastic bag was found over head. Two black tubes led from helium tank into the plastic bag. Had purchased these materials at local hardware store. The helium tank was from a party store balloon-filling kit.	Found sitting in chair in parent's home. Patient was pulseless and not breathing. The book Final Exit was lying open and face down on the bed. A suicide note was left describing how severely depressed the decedent had felt and apologizing for the suicide.	No autopsy, but blue nail beds and burst capillaries in lower legs bilaterally were observed at death scene.	19.0 mL subclavian blood sample was negative for ethanol and positive for helium.
2008	Man, 56, married, white (non-Hispanic), 12 yr of education	History of depression and substance abuse.	Decedent had a bag over his head with a tube attached to it and to a helium tank positioned on car passenger seat.	Found in car in garage at home by wife with car running and exhaust piped into the vehicle. A suicide note was found.	No autopsy.	18.0 mL subclavian blood sample was positive for helium and negative for ethanol. Carbon monoxide detected at <5.0% saturation.

OTC indicates over-the-counter; BAC, blood alcohol concentration; EKG, electrocardiogram.

men who were relatively young (M age, 41.1; SD, 11.6; range, 21–60; median, 40.0). In 6 of 10 cases, decedents suffered from significant psychiatric dysfunction; in 3 of these 6 cases, psychiatric problems were present comorbidly with substance abuse. Medical histories identified chronic pain, disability, and chronic pain associated with injuries suffered in a motor vehicle accident, and diabetes (with probable coronary artery disease in 3 decedents). One decedent was found with electrocardiogram leads attached to her body, but autopsy and toxicological findings were negative for potential explanations for the death other than helium-assisted suicide. In none of the 10 cases were decedents suffering from terminal illness.

Helium delivery devices were consistent with those recommended in Final Exit (eg, use of T-valves, 2 helium tanks, Velcro and other neck fasteners), and all were associated with use of a plastic bag rather than mask.⁸ In 5 cases, a suicide note was found; in 2 cases, a will was left; in 1 case, insurance papers were left; and in 2 cases, right-to-die materials were found.

Autopsies were performed in a majority of cases and typically revealed evidence of pulmonary vascular congestion and mild cerebral edema. Ethanol and diphenhydramine were considered contributing causes of death in 1 case each.

DISCUSSION

Despite reports identifying a plethora of prosuicide internet sites providing detailed instructions in methods of suicide including helium-assisted asphyxiation,¹⁸ media accounts of helium-assisted suicides,^{19–21} and the recent arrests of Final Exit Network members for allegedly assisting in asphyxial suicides involving helium,²² scientific investigations of such suicides are largely absent from the medical literature. This dearth of information is unfortunate given the tragic consequences of such acts and because it is possible that suicides by the helium method are underestimated and increasingly common for reasons described later in the text.

The methods by which helium-assisted suicides are carried out have been carefully detailed and widely publicized and the approach is promoted as simple, painless, and quick.⁸ Materials needed for helium-assisted suicides are easily obtained and inexpensive. One well-known internet vendor currently sells disposable helium tanks for less than \$50, and reports that customers who bought helium tanks also often bought the book Final Exit.²³ Unless there is a high index of suspicion for helium involvement in a death, the death may be erroneously attributed to natural causes or underlying illness because standard toxicological assays are unlikely to detect helium and autopsy findings are generally nonspecific.^{14,16} Standard toxicological assays using GC/MS employ helium as the carrier gas and therefore cannot detect helium unless another gas (eg, nitrogen) is substituted for the helium. Auwaeter et al¹⁴ and Gallagher et al¹³ developed useful methods of collecting, preserving, and analyzing gas samples taken from decedents' for qualitative detection of helium. In all North Carolina cases, helium-delivery devices were found at the death scene, and toxicological testing was conducted in 9 of 10 cases. However, it is possible that an unknown number of such suicides went undetected, if and when helium-delivery devices and plastic bags were removed from the death scene prior to investigation. The author of Final Exit states that a person may choose to leave right-to-die materials to be found to make an ethical statement that they are committing "rational suicide" or, conversely, make plans to have the helium delivery apparatus and plastic bag removed following their death if they prefer to keep the suicidal nature of the death concealed.⁸ Toxicological testing for helium has been conducted at the NCOCME in suspected cases since 2003 by a novel testing procedure using a dual cell thermal conductivity detector.²⁴

Of particular concern, are recent national reports of notable increases in the prevalence of suicide due to suffocation (a category that includes deaths by plastic bag asphyxiation with or without helium assistance as well as hanging and strangulation) since the 1990s and especially since 2000.^{25–27} Such increases have been observed in respondents of widely varying ages, including adolescents, and both genders. Observers have noted that the reasons for these increases are poorly understood, that declining rates of suicide observed in the 1990s have been largely reversed, and that recent increases in suicides due to suffocation account for most of the recent overall increases in rates of suicide.²⁸ It is possible that greater awareness of the plastic bag asphyxiation method and the enhanced lethality of the method when used with helium may account for the significant increases in suicides due to suffocation reported since 2000.

Given the national growth in adolescent, young adult, and adult suffocation suicides since 2000,^{25,26} and relatively young age, psychiatric dysfunction, and absence of terminal illness characteristic of many identified cases, it is possible that many persons committing suicide by the helium method are neither hopelessly nor terminally ill, but rather psychiatrically disordered. Although the author of Final Exit cautions readers to be certain they are hopelessly ill, and not just depressed and to talk to their doctor,⁸ depressive illness and substance dependency often impair the very capacities required to make these assessments and undertake these actions.

Prospective studies are needed to better understand the prevalence, incidence, predictors, and characteristics of asphyxial suicides due to helium inhalation. It is important to learn more about decedents' medical and psychiatric histories and the circumstances in which depressed and/or suicidal persons encounter descriptions of the helium method (eg, internet demonstrations of the process). At present, professionals working with persons at risk for suicide should routinely assess whether patients have read or viewed instructional materials describing specific methods of suicide such as helium-assisted plastic bag asphyxiation. Inquiries of this nature do not increase subsequent risk for suicide and can provide critically important information to guide appropriate preventative actions where indicated.^{29,30} Medical examiners should also increase their index of suspicion for suicides by asphyxiation associated with helium inhalation. Medical ethicists and the general public may also want to carefully weigh the unintended adverse consequences of widely disseminated suicide methods likely to appeal to some depressed persons (irrespective of their physical health status or age) against the putative benefits associated with making these methods more widely known and available.

ACKNOWLEDGMENTS

The authors thank P. Barnes, Administrative Services Manager, and other staff of the North Carolina Office of the Chief Medical Examiner for their assistance.

REFERENCES

1. Humphry D. *Final Exit: The Practicalities of Self-Deliverance and Assisted Suicide for the Dying*. New York, NY: Delta; 1991.
2. Côté R. *In Search of Gentle Death: A Brief History of the NuTech Group*. Mt. Pleasant, SC: Corinthian; 2008.
3. The most memorable books of the last 25 years: 25 books that leave a legacy. April 9, 2007. Available at: <http://www.usatoday.com/life/top25-books.htm>. Accessed November 6, 2009.
4. Sacks MH, Kemperman I. Final exit as a manual for suicide in depressed patients. *Am J Psychiatry*. 1992;149:842.
5. Marzuk PM, Tardiff K, Hirsch CS, et al. Increase in suicide by asphyxiation in New York City after the publication of final exit. *N Engl J Med*. 1993;329:1508–1510.
6. Marzuk PM, Tardiff K, Leon AC. Increase in fatal suicidal poisonings and

- suffocations in the year final exit was published. *Am J Psychiatry*. 1994;151:1813–1814.
7. Humphry D. *Supplement to Final Exit: The Latest How-to and Why of Euthanasia/Hastened Death*. Junction City, OR: Norris Lane and ERGO; 2000.
 8. Humphry D. *Final Exit: The Practicalities of Self-Deliverance and Assisted Suicide for the Dying*. 3rd ed. New York, NY: Delta; 2002.
 9. Humphry D. *Final Exit: The Practicalities of Self-deliverance and Assisted Suicide for the Dying*. 3rd ed. Addendum. Junction City, OR: ERGO; 2009.
 10. Humphry D. *Final Exit on DVD: The Art of Self-deliverance From a Terminal Illness*. Junction City, OR: ERGO; 2006. ISBN: 978–0–9768283–0–3.
 11. Ogden RD, Wooten RH. Asphyxial suicide with helium and a plastic bag. *Am J Forensic Med Pathol*. 2002;23:234–237.
 12. Gilson T, Parks BO, Porterfield CM. Suicide with inert gases: Addendum to Final Exit. *Am J Forensic Med Pathol*. 2003;24:306–308.
 13. Gallagher KE, Smith DM, Mellen PF. Suicidal asphyxiation by using pure helium gas: case report, review, and discussion of the influence of the internet. *Am J Forensic Med Pathol*. 2003;24:361–363.
 14. Auwaeter V, Perdekamp MG, Kempf J, et al. Toxicological analysis after asphyxial suicide with helium and a plastic bag. *Forensic Sci Int*. 2007;170:139–141.
 15. Grassberger M, Krauskopf A. Suicidal asphyxiation with helium: Report of three cases. *Wien Klin Wochenschr*. 2007;119:323–325.
 16. Schon CA, Ketterer T. Asphyxial suicide by inhalation of helium inside a plastic bag. *Am J Forensic Med Pathol*. 2007;28:364–367.
 17. Barnung SK, Feddersen C. Suicide by inhaling helium inside a plastic bag [In Danish]. *Ugeskr Laeger*. 2004;166:3506–3507.
 18. Recupero PR, Harms SE, Noble JM. Googling suicide: suicide information on the internet. *J Clin Psychiatry*. 2008;69:878–888.
 19. Tyson AS. Military investigates West Point suicides. *Washington Post*. January 30, 2009.
 20. Ward D. Helium in an “exit bag” new choice for suicide: at least 19 people in B.C. have used method since 1999. *Vancouver Sun*. December 8, 2007.
 21. Lam A. Asian Americans’ rising suicide rates—three students take their lives. *New American Media*. August 13, 2009.
 22. Bowers P. Final exit: compassion or assisted suicide? *Time*. March 2, 2009.
 23. Disposable helium tank for sale at Amazon.com. Available at: http://www.amazon.com/BuyCostumes-Disposable-Helium-Tank/dp/B000WR8QQG/ref=pd_sbs_hpc_3. Accessed November 6, 2009.
 24. Poklis JL, Garside D, Gaffney-Kraft M, et al. A qualitative method for the detection of helium in postmortem blood and tissues. In: Proceedings from the Society of Forensic Toxicologists; October 17–21, 2005; Nashville, TN.
 25. Lubell KM, Swahn MH, Crosby AE, et al. Methods of suicide among persons aged 10–19 years—United States, 1992–2001. *MMWR Morb Mortal Weekly Rep*. 2004;53:471–474.
 26. Lubell KM, Kegler SR, Crosby AE, et al. Suicide trends among youths and young adults aged 10–24 years—United States, 1990–2004. *MMWR Morb Mortal Weekly Rep*. 2007;56:905–908.
 27. Hu G, Wilcox HC, Wissow L, et al. Midlife-suicide: an increasing problem in U. S. Whites, 1999–2005. *Am J Prev Med*. 2008;35:589–593.
 28. Barber C. Trends and rates in methods of suicide: United States, 1985–2004. Harvard Injury Control Research Center (cbarber@hsph.harvard.edu). Report based on data from the Web-based Injury Statistics and Reporting System (WISQARS), National Center for Injury Prevention and Control, Centers for Disease Control and Prevention, U.S. Vital Statistics. Available at: <http://www.cdc.gov/ncipc/wisqars>.
 29. Gould MS, Marrocco FA, Kleinman MS, et al. Evaluating iatrogenic risk of youth suicide screening programs: a randomized controlled trial. *JAMA*. 2005;293:1635–1643.
 30. American Psychiatric Association. Practice guidelines for the assessment and treatment of patients with suicidal behaviors. In: *Practice Guidelines for the Treatment of Psychiatric Disorders Compendium*. 2nd ed. Arlington, VA: American Psychiatric Association; 2004:835–1027.