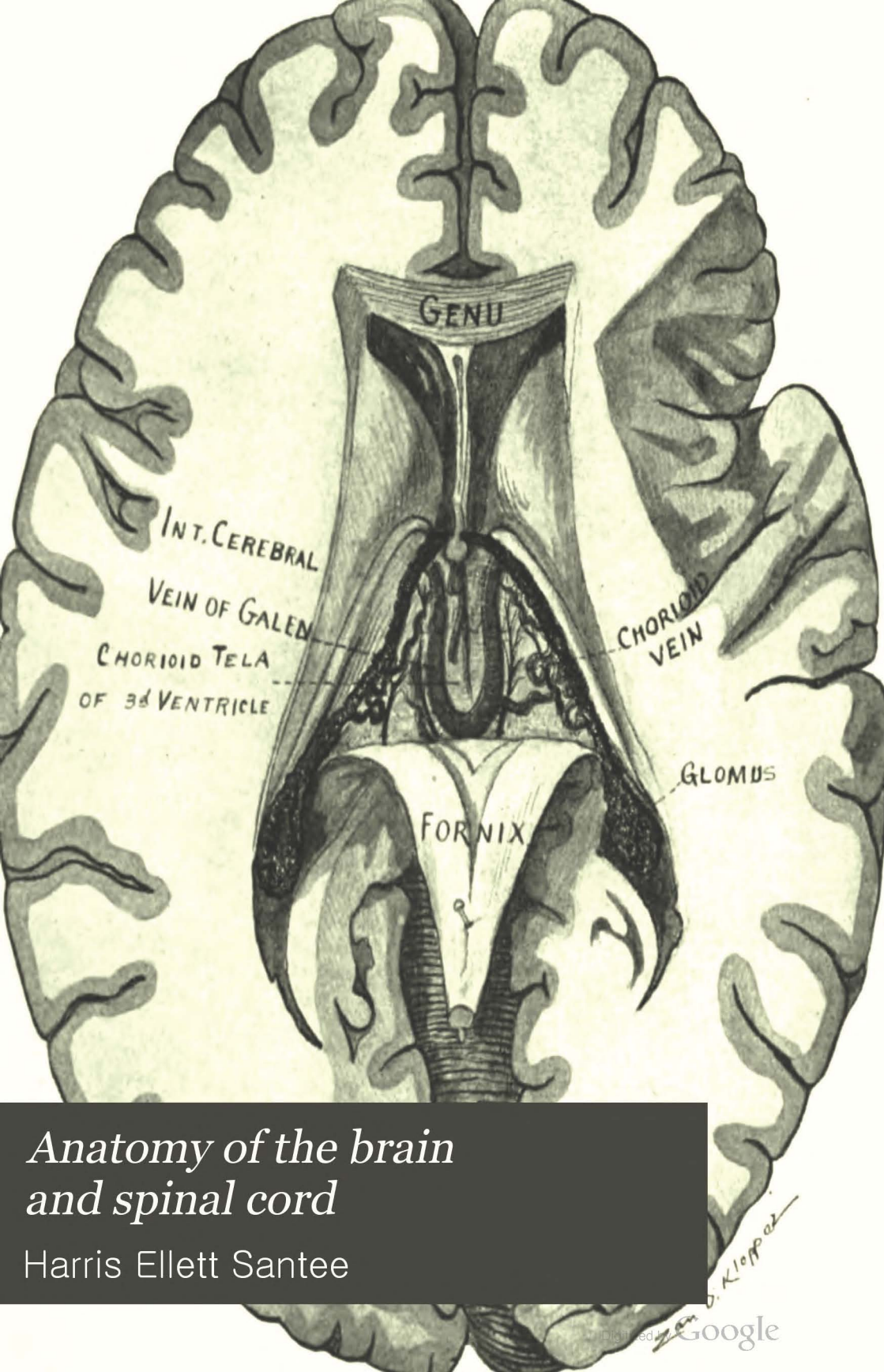

*Anatomy of the brain
and spinal cord*

Harris Ellett Santee



EX LIBRIS
DR. JAMES W. WARD

ANATOMY
OF THE
BRAIN AND SPINAL CORD

SANTEE

ANATOMY
OF THE
BRAIN AND SPINAL CORD

WITH SPECIAL REFERENCE TO
MECHANISM AND FUNCTION

FOR STUDENTS AND PRACTITIONERS

BY

HARRIS E. SANTEE, M. D., Ph. D.

PROFESSOR OF ANATOMY IN THE COLLEGE OF PHYSICIANS AND SURGEONS, MEDICAL DEPARTMENT, UNIVERSITY OF ILLINOIS; PROFESSOR OF ANATOMY IN JENNER MEDICAL COLLEGE, CHICAGO; MEMBER OF ASSOCIATION OF AMERICAN ANATOMISTS.

FOURTH EDITION, REVISED AND ENLARGED

WITH 128 ILLUSTRATIONS, 33 OF WHICH ARE PRINTED IN COLORS

PHILADELPHIA
P. BLAKISTON'S SON & CO.
1012 WALNUT STREET
1907

COPYRIGHT, 1907, BY P. BLAKISTON'S SON & CO.

*Printed by
The Maple Press,
York, Pa.*

523
1927

PREFACE

THE author hopes that the present edition of this work may receive from his colleagues the same generous consideration accorded to the former editions. His endeavor has been to set forth the present status of the anatomy of the human brain and spinal cord. To do this the facts have been gleaned from many sources; and, so far as was possible, from the original sources. Being designed for a text-book, the subject-matter is presented in the order found convenient to the dissector. The description proceeds from the gross structures to the constituent neurones in each successive region. Wherever the embryology will assist the student to comprehend the adult forms, the development is briefly given in the text; but a special chapter is also devoted to embryology, which presents a concise and connected statement of the development of the entire brain and spinal cord.

The special objects held in view throughout the book are the location of functional centers and the tracing of their afferent, associative and efferent connections. Particular emphasis is laid upon the origin, course, termination and function of conduction paths as they are met in the regular study, and the more important and better known of these paths are summed up in a final chapter on the tracing of impulses. Function is everywhere correlated with structure; and so far as present knowledge permits, the function of each group of neurones is given in connection with its anatomical description.

The BNA Nomenclature is followed almost without exception, the English equivalents of the Latin terms being very largely employed.

Keeping pace with the lectures, every student is expected to dissect the human brain in the laboratory, exposing, studying and sketching every macroscopic structure as it occurs in the work;

and, then with the microscope, examine the minute structure and picture the histology of the same parts. For these purposes the class should be taken in small sections, divided into groups of two to four students, and each group should be provided with a well hardened human brain. It is desirable that each student should receive a well stained microscopic section of every important part. This is, however, often impossible; and the instructor may get along with considerable satisfaction, by having the students exchange, if he has but a few sets of slides.

The author wishes to acknowledge his indebtedness to recent literature and to standard works on anatomy. McMurrich's "Development of The Human Body," Barker's "BNA" and Barker's "Nervous System," the work of Dr. Alfred W. Campbell, "Histological Studies on the Localization of Cerebral Function," the "Text-book of Anatomy" and "Memoirs" of D. J. Cunningham, F. R. S., and the fourth edition of Morris's "Human Anatomy" have been especially useful.

I desire to express my appreciation of the kindly assistance of my colleague, Prof. Wm. T. Eckley, M. D.; and to say that the artistic merit of the new illustrations in this book belongs to my friend and pupil, Mr. Zan D. Klopper, of Chicago, who sketched the original drawings from my own specimens. My thanks are also due to the publishers of this little monograph, for many favors and courtesies shown me, particularly for allowing me to select illustrations from Gordinier, McMurrich and Morris, works published by them.

HARRIS E. SANTEE.

TABLE OF CONTENTS.

CHAPTER I.

THE MENINGES OF THE BRAIN.

	PAGE
Dura Mater of the Brain:.....	I
Structure and relations.....	I
Processes	I
Sinuses	2-5
Arachnoid granulations (Pacchioni).....	5
Arteries	6-7
Nerves	7
Contrasted with dura of spinal cord.....	7
Arachnoid of the Brain:.....	8
Structure	8
Relations, subarachnoid spaces.....	8-9
Vessels and nerves.....	9
Contrasted with arachnoid of the cord.....	9
Pia Mater of the Brain:.....	9
Structure and relations.....	9-10
Chorioid tela of third and fourth ventricles	10
Arteries and veins.....	10-13
Nerves	13
Contrasted with pia of spinal cord.....	13
Blood Supply of the Brain:.....	14-30
Carotid and vertebral arteries.....	14
A. Cerebral Circulation, Arteries:.....	14-21
Arterial circle (Willisi) and branches.....	14-15
A1. Cortical system of arteries.....	15-18
Anterior cerebral artery.....	16
Middle cerebral artery.....	16-17
Posterior cerebral artery.....	17
Chorioidal arteries, posterior and anterior.....	17-18
A2. Ganglionic system of arteries	18-21

	PAGE
Antero-median ganglionic arteries.....	18
Antero-lateral ganglionic arteries.....	18
Postero-median ganglionic arteries.....	18-21
Postero-lateral ganglionic arteries.....	21
The Veins of the Cerebrum:.....	21-24
Internal veins of the cerebrum.....	21
Great vein of the cerebrum (Galeni).....	21-22
External veins of the cerebrum.....	22-23
Superior.....	22
Medial.....	22-23
Inferior.....	23
Lymphatics of cerebrum.....	23-24
B. Circulation of the Rhombencephalon:.....	24-30
B1. The medulla oblongata.....	24
B2. The pons (Varolii).....	24-27
B3. The cerebellum.....	27-30
Superior cerebellar artery.....	27-28
Anterior inferior cerebellar artery.....	29
Posterior inferior cerebellar artery.....	29
Internal cerebellar veins.....	29
External cerebellar veins.....	29-30
Superior.....	29
Inferior.....	29-30
Lymphatics of cerebellum.....	30
Table I. Embryologic Divisions of the Brain.....	30-33
Components of cerebrum.....	33
Components of rhombencephalon.....	33

CHAPTER II.

GENERAL CONSIDERATION OF THE BRAIN.

Embryonic Brain Vesicles.....	34
Their cavities—the ventricles.....	34
Superior view.....	34-35
Posterior view.....	35-36
Inferior view.....	36-41
Anterior area.....	36-37
Middle area.....	37-38
Posterior area.....	38-41

TABLE OF CONTENTS.

ix

	PAGE
Roots of the Twelve Cerebral Nerves:.....	42-49
Nuclei, genetic and terminal.....	42
Olfactory nerves.....	42
Optic nerve.....	42
Oculo-motor nerve.....	42-45
Trochlear nerve.....	45
Trigeminal nerve.....	45
Abducent nerve.....	45
Facial nerve.....	45-46
Intermediate nerve.....	45-46
Acoustic nerve.....	46
Glossopharyngeal nerve.....	46
Vagus nerve.....	46-49
Accessory nerve.....	49
Hypoglossal nerve.....	49

CHAPTER III.

THE CEREBRUM.

Subdivisions:.....	
End-brain.....	50
Inter-brain.....	50
Mid-brain.....	50
SECTION I. THE FORE-BRAIN OR PROSENCEPHALON.	50-144
Exterior surface of fore-brain.....	51-98
Definition of fissure and sulcus.....	52
Subdivisions and borders.....	52
Convex, medial and basal.....	52
Fissures and sulci of convex surface.....	52-73
Longitudinal fissure of cerebrum.....	52-55
Transverse fissure of cerebrum.....	55
Lateral fissure of cerebrum (Sylvii).....	55-56
Sulcus centralis (Rolandi).....	56
Occipito-parietal sulcus.....	56-59
Lobes and gyri of convex surface.....	59-73
Frontal lobe, its gyri and sulci.....	59-63
Parietal lobe, its gyri and sulci.....	63-67
Occipital lobe, its gyri and sulci.....	67-69

	PAGE
Temporal lobe, its gyri and sulci.....	69-71
Superior surface.....	70
External surface.....	70-71
Island (Reili), its sulci and gyri.....	71-73
The base of the fore-brain.....	73-85
Frontal lobe, inferior surface.....	73-74
Island (Reili), inferior surface.....	74-77
Rhinecephalon.....	77-79
Olfactory lobe.....	77-79
Olfactory bulb.....	77-78
Olfactory tract and striæ.....	78
Olfactory triangle.....	79
Parolfactory area (Brocæ).....	79
Anterior perforated substance.....	79
Tentorial area of basal surface.....	79-82
Chorioidal fissure.....	80
Hippocampal fissure.....	80
Ectorhinal sulcus.....	80-81
Fissura collateralis.....	81
Inferior temporal sulcus.....	81
Gyrus fusiformis.....	81
Gyrus lingualis.....	81
Limbic lobe, inferior part.....	81-82
Gyrus hippocampi and uncus.....	81-82
Dentate fascia.....	82
Hypothalamus.....	82-85
Pars optica hypothalami.....	82-84
Lamina cinerea terminalis.....	83
Optic chiasma, nerves and tracts.....	83-84
Tuber cinereum and infundibulum.....	84
Hypophysis (pituitary body).....	84
Pars mammillaris hypothalami.....	82 and 84
Corpora mammillaria.....	84
Fissures and sulci of medial and tentorial surface.....	84-98
Sulcus cinguli (calloso-marginal).....	86
Subparietal sulcus.....	86
Callosal sulcus.....	86-89
Occipito-parietal sulcus.....	89
Calcarine fissure.....	89-90
Hippocampal fissure.....	90

TABLE OF CONTENTS.

xi

	PAGE
Chorioidal fissure.....	90
Collateral fissure.....	90-93
Ectorhinal sulcus.....	90-93
Inferior temporal sulcus.....	93
Gyri of medial and tentorial surface.....	93-98
Gyrus fornicatus.....	93-97
Gyrus cinguli.....	93-94
Gyrus hippocampi.....	94-97
Uncus.....	94-97
Lobus pyraformis.....	97
Limbic lobe, rhinencephalon.....	97
Gyrus rectus.....	97
Gyrus frontalis superior (g. marginalis).....	97
Lobulus paracentralis.....	97
Præcuneus.....	97
Cuneus.....	97
Gyrus lingualis.....	97
Gyrus fusiformis.....	97
Summary of lobes of the cerebrum.....	98
Neopallium.....	98
Rhinencephalon (archipallium).....	98
Corpus striatum.....	98
Interior surface of the fore-brain.....	98-144
Internal capsule.....	99-104
Inferior lamina.....	99-100
Motor fibers.....	100
Sensory fibers.....	100
Superior lamina.....	100-104
Genu, frontal and occipital parts.....	103
Motor fibers.....	103
Common sensory fibers.....	103-104
Special sense fibers.....	104
Corpus callosum:.....	104-108
Upper surface.....	107
Gyri supracallosus and subcallosus.....	107
Inferior surface.....	107
Borders, posterior and anterior.....	107-108
Splenum, rostrum, genu, truncus.....	108
Boundaries of general cavity of fore-brain.....	108-109
Body of fornix.....	109

	PAGE
Crus fornicis.....	110
Columnæ fornicis.....	110
Septum pellucidum.....	111
Fifth ventricle.....	111-112
Lateral ventricle and its boundaries.....	112-127
Central part (body).....	112-120
Corpus striatum.....	115-119
Lentiform nucleus.....	116
Nucleus caudatus.....	116-119
Stria terminalis.....	119
Thalamus.....	119
Chorioid plexus of lateral ventricle.....	120
Anterior horn of the lateral ventricle.....	120-123
Posterior horn.....	123
Inferior horn.....	123-127
Trigonum collaterale.....	124
Hippocampus, its digitations.....	124
Chorioid epithelium.....	124
Third Ventricle and Inter-Brain.....	127-144
Posterior commissure.....	132
Roof epithelium.....	132
Pineal body.....	132-135
Chorioid tela of third ventricle.....	135-136
Anterior commissure.....	136-139
Lamina terminalis.....	139
Thalamus.....	139-143
Extremities—anterior and posterior.....	140
Surfaces—medial, superior, lateral and inferior..	140-143
Tegmental hypothalamic region.....	143
Nucleus hypothalamicus (Luysi).....	143
Lateral geniculate body.....	143
Medial geniculate body.....	143-144
SECTION II. THE MID BRAIN (MESENCEPHALON):.....	144-164
Surfaces—superior, inferior, anterior, posterior.....	144-146
Bases pedunculi.....	147-151
Intermediate bundle.....	148
Temporo-pontal tract.....	148
Pyramidal tract.....	148-151
Fronto-pontal tract.....	151

TABLE OF CONTENTS.

xiii

	PAGE
Substantia nigra.....	151
Tegmenta.....	152-163
Cerebral aqueduct (Sylvii).....	152
Nuclei of oculo-motor and trochlear nerves.....	152-155
Mesencephalic nucleus of trigeminal nerve.....	155
Formatio-reticularis.....	155-163
Tegmental decussations.....	155
Tracts of fibers in the tegmentum.....	155-163
Medial (or posterior) longitudinal bundle.....	155-158
Anterior longitudinal bundle.....	158-159
Fillet or lemniscus.....	159-161
Medial fillet—superior fillet.....	159-160
Lateral fillet.....	160-161
Spino-thalamic tract.....	161-162
Brachium conjunctivum.....	162
Rubro-spinal tract.....	162
Olivary fasciculus.....	162
Descending root of trigeminal nerve.....	163
Quadrigeminal lamina.....	163-164
Colliculus superior.....	163
Colliculus inferior.....	163-164
Brachium superius.....	164
Brachium inferius.....	164
SECTION III. STRUCTURE OF THE CEREBRUM:.....	164-241
The neurone or nerve cell.....	167-173
Cell-body, perikaryon, or neurone center.....	167
Dendrites.....	167
Axone.....	168
Myelin sheath.....	168
Types of neurones (three).....	168
Orders of neurones (1st, 2d, etc.).....	168-171
Functions of neurones.....	171
Degeneration of neurones.....	171-172
Development of neurones.....	172-173
Sustentacular tissue.....	173
Epiblastic.....	173-174
Neuroglia and ependyma.....	173-174
Mesoblastic connective tissue.....	174
Cortical gray matter.....	174-204

	PAGE
Cortical or cerebral localization	177-183
Motor area, emissive	177
Psychic motor area	178
Common sensory area	178
Psychic sensory area	178
Acoustic center	181
Optic center	181
Olfactory and gustatory centers	181
Naming center	181
Centers of intonation, equilibration and orientation	181
Anterior association center, abstract conceptions	182
Posterior association center, concrete conceptions	182-183
Middle association center	183
Cell and fiber lamination	183-204
Plexiform layer	184-187
Layer of small pyramids	184 and 187
Layer of medium-sized pyramids	184 and 187
External layer of large pyramids	184 and 187-188
Layer of stellate cells	184 and 188
Internal layer of large pyramids	184 and 188-191
Layer of fusiform cells	184 and 191
Radiations of Meynert	192
Association fibers of Meynert	192
Atypical cortex:	192-204
Visual cortex	192-195
Olfactory cortex	195-204
Olfactory bulb	195-196
Uncus hippocampi	196-199
Nucleus amygdalæ	199
Subiculum	199
Fascia dentata	200
Trigonum olfactorium, etc.	200-203
Gyrus cinguli	203
Clastrum	204
Ganglionic gray matter	204-221
Corpus striatum	204-208
Centrifugal fibers	207-208
Centripetal fibers	208
Thalamus	208-217
Thalamic nuclei	208-211

TABLE OF CONTENTS.

XV

	PAGE
White matter of the thalamus.....	211-217
Cortical fillet.....	216-217
Occipito-thalamic radiation (optic).....	217
Temporo-thalamic radiation (acoustic).....	217
Red nucleus.....	217
Nucleus hypothalamicus.....	218
Metathalamus.....	218
Lateral geniculate body.....	218
Medial geniculate body.....	218-219
Superior colliculi of corpora quadrigemina.....	219-220
Anterior longitudinal bundle.....	219-220
Inferior colliculi of corpora quadrigemina.....	220
Nucleus lateralis superior.....	220
Substantia nigra.....	221
Central or ventricular gray matter.....	221-224
Hypothalamus.....	221-222
Pars optica.....	221
Pars mammillaris.....	221-222
Massa intermedia (middle commissure).....	222
Stratum griseum centrale of mid-brain.....	222-224
Oculomotor nucleus.....	223
Trochlear nucleus.....	223
Trigeminal nucleus of mid-brain.....	224
Projection fibers of the cerebrum.....	224-234
Corticifugal, or motor fibers.....	225-231
Intermediate tract.....	225
Fronto-pontal tract.....	225
Tempora-pontal tract.....	225-226
Pyramidal tract.....	226-231
Head and neck fibers.....	227
Upper extremity fibers.....	228
Trunk fibers.....	228
Lower extremity fibers.....	228-231
Destruction of by clot, etc.....	231
Sensory or corticpetal fibers.....	231-234
Medial fillet, spino-thalamic tract and brachium con-	
funiculum.....	231
Olfactory projection fibers.....	232
Cortical fillet (common sensory).....	232-233
Taste fibers (not located).....	233

	PAGE
Auditory.....	233
Lateral fillet and brachium inferius.....	233
Temporo-thalamic radiation.....	233
Occipito-thalamic radiation (optic).....	234
Commissural fibers of cerebrum	234-236
Corpus callosum.....	234
Anterior commissure.....	234-235
Commissura hippocampi.....	236
Association fibers of cerebrum	236-241
Short association fibers.....	236-238
Long association fibers.....	238-241
Cingulum of gyrus fornicatus.....	238
Fornix	238-240
Uncinate fasciculus.....	240
Superior longitudinal fasciculus.....	240
Inferior longitudinal fasciculus.....	240-241
Fasciculus occipito-frontalis.....	241
Perpendicular fasciculus.....	241

CHAPTER IV.

THE RHOMBENCEPHALON.

SECTION I. THE CEREBELLUM:.....	242-266
Function	242
Divisions:.....	242
Cerebellar hemispheres.....	242-243
Vermis cerebelli or worm.....	243
Cerebellar notches, anterior and posterior.....	244
Medullary Body:.....	244-247
Inferior medullary velum	244
Brachia conjunctiva.....	245
Superior medullary velum (Vieussensi).....	246
Corpora restiformia.....	246-247
Brachia pontis.....	247
Horizontal sulcus of cerebellum	247-248
Superior Surface of Cerebellum:.....	248-251
Sulci of upper surface.....	248-249
Precentral sulcus.....	248
Postcentral sulcus.....	249

TABLE OF CONTENTS.

xvii

	PAGE
Predeclivil sulcus.....	249
Postdeclivil sulcus.....	249
Lobes of superior surface.....	250-251
Lobus lingulæ.....	250
Lobus centralis.....	250
Lobus culminis monticuli.....	250
Lobus declivis monticuli.....	251
Lobus folii vermis.....	251
Inferior Surface of Cerebellum:.....	251-256
Sulci of lower surface.....	252-253
Postnodular sulcus.....	252
Prepyramidal sulcus.....	252-253
Postpyramidal sulcus.....	253
Midgracile and postgracile.....	253
Lobes of lower surface.....	253-256
Lobus noduli.....	253-254
Lobus uvulæ.....	254
Lobus pyramidis.....	254-255
Lobus tuberis.....	255-256
Cortical Gray Matter of the Cerebellum.....	256-260
Superficial layer.....	256-258
Stratum cinereum.....	256
Stratum gangliosum.....	257
Cells of Purkinje and stellate cells.....	257
Fibers of superficial layer.....	257-258
Deep layer (stratum granulosum).....	258-260
Cells of granular layer.....	258-259
Fibers of granular layer.....	260
Function of stellate, granule and Purkinje cells.....	260
Neuroglia of cerebellum.....	260
Ganglionar Gray Matter of Cerebellum.....	260-262
Function, relay stations.....	260
Nucleus dentatus.....	260-261
Nn. emboliformis, globosus and fastigii.....	261
White Substance—Corpus Medullare:.....	262-266
Projection fibers.....	263-265
Brachium conjunctivum.....	263
Superior medullary velum.....	263-264
Brachium pontis.....	264
Corpus restiforme.....	264-265

	PAGE
Commissural fibers	265
Association fibers.....	265-266
SECTION II. THE PONS (VAROLII)	266-284
Surfaces:.....	266-270
Superior and inferior.....	266
Anterior (Tuber annulare).....	266-269
Posterior—ventricular, and attached part.....	269-270
Transverse fibers of the pons.....	271-272
Superficial of pars basilaris pontis.....	271
Deep transverse of pars basilaris pontis.....	271
Transverse of pars dorsalis pontis.....	271-272
Trapezoid body.....	272
Longitudinal fibers of the pons.....	272-278
Ventral	272
Dorsal	272-278
Medial fillet and superior fillet	273-274
Lateral fillet.....	272
Spino-thalamic tract.....	272
Ascending anterior cerebello-spinal tract.....	272-276
Gowers's tract.....	276
Medial longitudinal bundle.....	276
Anterior longitudinal bundle.....	276
Rubro-spinal tract.....	276-277
Olivary bundle.....	277
Descending root of trigeminal nerve.....	277
Spinal tract n. trigemini	277
Gray Matter of the pons.....	277-284
Nucleus pontis.....	277
Stratum nucleare.....	278-284
Superior olivary nucleus.....	278-279
N. præolivaris and n. semilunaris.....	279
Nucleus of trapezoid body.....	279
Nuclei of reticular formation.....	279-280
Ponto-spinal tracts (Collieri).....	280
Nuclei of trigeminal nerve.....	281
Genetic (motor).....	281
Terminal (sensory)	281
Nucleus of abducent nerve.....	281-282
Nucleus of facial nerve.....	282

TABLE OF CONTENTS.

xix

	PAGE
Salivary nucleus.....	283
Vestibular nucleus of auditory.....	283
Lesions in pons	283
SECTION III. MEDULLA OBLONGATA (MYELENCEPHALON)..	284-313
Origin	285
Ventricle	285
Surfaces.....	286-290
Anterior lateral sulcus.....	286
Posterior lateral sulcus.....	286
Anterior surface.....	286-287
Lateral surface.....	287-288
Olive	287
Lateral column.....	287-288
Posterior surface	288-290
Restiform body.....	288
Roof epithelium of fourth ventricle.....	289
Floor of fourth ventricle.....	290
White matter of medulla	290-302
Substantia reticularis	291
Raphe	291
Transverse fibers.....	291-292
Pyramidal decussation	291
Arcuate fibers, external and internal	291-292
Fillet decussation.....	292
Cerebello-olivary fibers.....	292
Dorso-ventral fibers.....	292-293
Anterior external arcuate.....	292
Roots of eighth to twelfth cerebral nerves.....	293
Longitudinal fibers of anterior area:.....	293-298
Pyramid, anterior and lateral tracts.....	294
Medial fillet (interolivary stage).....	295
Medial longitudinal bundle (posterior).....	296
Anterior longitudinal bundle.....	297
Longitudinal fibers of lateral area	298-300
Fasciculus lateralis proprius.....	298
Descending anterior cerebello-spinal tract.....	298
Ascending anterior cerebello-spinal tract	299
Rubro-spinal tract.....	300
Longitudinal fibers of posterior area	300-302

	PAGE
Funiculus gracilis.....	300
Funiculus cuneatus.....	300
Spinal tract of trigeminal nerve.....	301
(Posterior) Cerebello-spinal tract	301
Restiform body	301
Vestibular and cochlear nuclei.....	302
Tractus solitarius.....	302
Gray matter of the medulla	302-313
Nucleus of external arcuate fibers.....	302
Nuclei in floor of ventricle (s. nucleare).....	303-310
Hypoglossal nucleus	303
Nucleus lateralis inferior.....	303-304
Nucleus ambiguus.....	303-304
Nuclei alæ cinereæ	304 and 306
Nucleus tractus solitarii.....	306
Nucleus tractus spinalis n. trigemini.....	306
Vestibular nuclei	307-308
Cochlear nuclei	309-310
Special nuclei in medulla	310-313
Nucleus funiculi gracilis.....	310-311
Nucleus funiculi cuneati.....	310-311
Nucleus olivaris inferior.....	312
SECTION IV. THE FOURTH VENTRICLE.....	313-325
Boundaries	313-314
Floor of fourth ventricle.....	314-318
Colliculus facialis.....	317
Fovea superior.....	317
Locus cæruleus	317
Hypoglossal triangle.....	317
Ala cinerea (trigonum vagi).....	317
Area acustica.....	320
Origin of cerebral nerves.....	320-325
Table II. Sensory Nerves and Roots.....	320-321
Table III. Motor Nerves and Roots	321-322
Terminal nuclei.....	322-324
Common sensory.....	322
Cortical and reflex connections.....	322
Special sense.....	322-324
Cortical and reflex connections.....	324

	PAGE
Genetic nuclei.....	324-325
Cortical and reflex connections.....	324-325

CHAPTER V.

MEMBRANES OF THE SPINAL CORD.

Dura mater.....	326
Arachnoid	326-329
Pia mater	329-330
Blood Supply of the Spinal Cord:.....	330-332
Spinal arteries, anterior and posterior	330-332
Fissural or centrifugal.....	331
Centripetal	331-332
Venæ spinales internæ	332
Root and fissural veins.....	332
Venæ spinales externæ.....	332
Internal vertebral plexus.....	332
Lymphatics.....	332

CHAPTER VI.

THE SPINAL CORD.

Extent	333
Diameters	333-335
Cervical enlargement.....	333-334
Lumbar enlargement.....	334-335
Sixth ventricle (canalis centralis spinalis)	337
Fissures of the cord:.....	337-338
Anterior median fissure	337
Posterior median fissure.....	337
Posterior lateral sulcus.....	337-338
Anterior root-line (s. lateralis anterior).....	338
Posterior intermediate sulcus.....	338
1. Gray Matter of the Cord:.....	338-351
H-shaped column.....	339
Substantia gelatinosa	339
Substantia spongiosa.....	339
Gray crescent.....	339-349
Anterior columna.....	339-344
Cells of anterior columna	340-344

	PAGE
Golgi cells.....	340
Deiters cells	340
Medial column.....	340
Lateral column	340, 343-344
Cortical connection.....	343
Reflex mechanism	343-344
Lesions of anterior column.....	344
Center of crescent and columna lateralis.....	344-347
Intermedio-lateral column of cell-bodies (efferent sympathetic neurones)	344-347
Posterior column.....	347-349
Neurones of head of posterior column.....	347-348
Nucleus dorsalis (Clarki) terminal nucleus of sym- pathetic)	348-349
Gray commissure of spinal cord	350
Gray anterior commissure	350
Posterior commissure	350
Lesions of gray substance.....	350
2. White Matter of the Spinal Cord:.....	351-362
Transverse fibers.....	351
White anterior commissure.....	351
Dorso-ventral fibers.....	351-352
Longitudinal fibers	352
Funiculus anterior.....	352
Funiculus lateralis.....	352
Funiculus posterior.....	352
Ascending tracts	352
Descending tracts	352
Mixed tracts.....	352
Embryological method of locating tracts.....	352-353
Pathological and experimental method	353
Tracts of the Spinal Cord	354-362
Antero-lateral fasciculus proprius.....	354
Medial longitudinal bundle.....	354
Anterior pyramidal tract.....	355
Anterior longitudinal bundle.....	355
Descending anterior cerebello-spinal tract.....	356
Ascending anterior cerebello-spinal tract.....	356-357
Spino-thalamic tract	356-357
Triangular tract of Helwig.....	357

TABLE OF CONTENTS.

xxiii

	PAGE
(Posterior) Cerebello-spinal tract	357-358
Spino-vestibular tract	357-358
Lateral pyramidal tract	358
Rubro-spinal tract	358
Lesions of anterior and lateral funiculi	359
Marginal tract (Lissaueri)	359
Entry zone	359-360
Fasciculus gracilis (Golli)	360-361
Fasciculus cuneatus (Burdachi)	361
Descending tracts from posterior roots	361
Descending postero-medial tract (comma, oval, septo- marginal and median triangular tract)	361
Descending postero-lateral tract	362
Posterior fasciculus proprius	362
Cornu-commissural tract	362
Lesions of posterior columns	362
Roots of the spinal nerves	362-365
Anterior root	363
Apparent origin	363
Real origin (genetic nuclei)	363
Voluntary motor fibers	363
Sympathetic efferent fibers	363
Lesions	360-364
Posterior root	364-365
Spinal ganglion (origin)	364
Apparent central termination	364
Real central termination, terminal nuclei	364
Gray matter of the cord	364-365
Nuclei of medulla oblongata	365
Physiological groups of posterior root-fibers	365
Lesions of posterior roots	365

CHAPTER VII.

TRACING OF IMPULSES.

I. Efferent, or Motor Paths	366-374
Cerebro-spinal or pyramidal paths	366-369
Through spinal nerves	366
Through cerebral nerves	369
Cerebro-pontal paths	369-370
Fronto-pontal	370

	PAGE
Temporo-pontal.....	370
Intermediate.....	370
Spinal and cerebral.....	370
Paths through red nucleus.....	370-373
Rubro-spinal path, direct.....	370-373
Indirect via brachium conjunctivum.....	373
Ponto-spinal paths (Collieri).....	373
Medial ponto-spinal tract.....	373
Lateral ponto-spinal tract.....	373
Short fiber paths in formatio-reticularis.....	373-374
II. Afferent, or Sensory Paths, General Sensations:.....	377-383
Tactile, muscular, pain, and temperature sense.....	377
(I). Muscular and tactile impulses from muscles, skin, etc.....	377-381
Through fasciculi gracilis et cuneati.....	377-378
Direct route.....	378
Indirect route.....	378
Through cerebral nerves and medial fillet.....	378-381
(II). Muscular and tactile impulses from viscera.....	381
Through posterior cerebello-spinal tract.....	381
(III). Paths for pain, temperature and tactile impulses ..	381-382
Through spino-thalamic tract.....	381-382
Through ascending anterior cerebello-spinal tract....	381-382
Through cerebral nerves and spino-thalamic tract....	382
Short fiber paths.....	382-383
Afferent Paths—Special Sensations:.....	383-390
Olfactory path.....	383-384
Optic path.....	384-385
Auditory path.....	385-389
Cochlear (hearing proper).....	386
Vestibular (equilibrium).....	386-389
Reflex connections.....	389
Gustatory path.....	389
Lesions of special sense paths.....	389-390
III. Reflex Paths:.....	390-394
Reflex arcs.....	390
(1) Spinal reflexes.....	390-392
Coordinating reflexes.....	390
Defecation reflexes.....	391-392
(2) Cerebral reflexes.....	392-393

	PAGE
(3) Spino-cerebral reflexes.....	393
(4) Cerebro-spinal reflexes.....	393-394
Respiratory reflexes.....	393
Equilibrium reflexes.....	393
Pupillary reflexes.....	394

CHAPTER VIII.

EMBRYOLOGY OF THE BRAIN AND SPINAL CORD.

Medullary plate and ridges.....	395
Neural Tube:.....	395-400
Brain vesicles.....	395 and 402
Ependymal cells.....	397
Indifferent cells.....	397-398
Neuroblasts, neurones.....	398
Spongioblasts, neuroglia.....	398-399
Zones, roof-plate and floor-plate.....	399-400
Neural Crest:.....	400-401
Cephalic portion.....	400
Cerebral nerve ganglia.....	400
Unipolar and bipolar neurones.....	400-401
Spinal portion of crest.....	401
THE BRAIN:	401-426
Flexures.....	402
Table IV. Brain Vesicles and Derivatives.....	403
Table V. Secondary Brain Vesicles.....	403-404
Telencephalon (end-brain).....	404-415
Table VI. Derivatives of.....	404-405
Optic vesicle, cup and retina.....	405
Hemisphere of cerebrum.....	405-415
Rhinencephalon.....	406-409
Primary fissures.....	409-410
Secondary sulci and fissure.....	410-411
Transverse fissure of cerebrum.....	411
Cerebral cortex and medulla.....	411-412
Fornix.....	412
Stria terminalis.....	412
Internal capsule.....	412-413
Anterior commissure.....	413-414
Corpus callosum.....	414

	PAGE
Septum pellucidum	415
Pars optica hypothalami	415
Diencephalon (inter-brain)	415-417
Table VII. Derivatives of	415
Roof-plate	416
Dorsal lamina	417
Ventral lamina and floor-plate	417
Mesencephalon (mid-brain)	417-418
Table VIII. Derivatives of	417-418
Metencephalon (hind-brain)	418-424
Table IX. Derivatives of	419
Cerebellum	418-421
Vermis and hemispheria	419-420
Sulci	420-421
Cortex and ganglia	421
Corpus restiforme and brachia	421
Pons (Varolii)	421-422
Myelencephalon (medulla oblongata)	422-426
Internal surface	423
External surface	423-424
Table X. Derivatives of Myelencephalon	424
Ependymal layer	424-425
Mantle layer	425
Neuroglia layer, marginal velum	425-426
THE SPINAL CORD:	426-430
Ventriculus terminalis	426
Filum terminale	426
Cauda equina	426
Meninges	426
Zones, ventral and dorsal	426-427
Histologic layers	427-428
Marginal velum, neuroglia layer	428
Mantle layer	428-429
Ependymal layer	429
Longitudinal tracts	429-430
Order of medullation	429-430
Fissures of cord	430
Posterior median fissure	430
Posterior lateral sulcus	430
Anterior median fissure	430

LIST OF ILLUSTRATIONS.

FIG.	PAGE
1. Sagittal section of skull, showing falx cerebri, falx cerebelli, a part of the tentorium cerebelli and the sinuses of the dura mater. (After <i>Morris's Anatomy</i>).....	3
2. Upper surface of tentorium cerebelli, tentorial notch and certain sinuses of the dura. (After <i>Morris's Anatomy</i>)..	4
3. Sinuses of the dura mater in the base of cranium, etc. (After <i>Morris's Anatomy</i>).....	5
4. Coronal section of meninges showing falx cerebri, superior sagittal sinus and the arachnoid granulations. (<i>Gordinier</i> after <i>Key</i> and <i>Retzius</i>).....	6
5. Middle meningeal artery inside the cranium. (After <i>Morris's Anatomy</i>).....	7
6. Diagram of pia mater and arachnoid, showing subarachnoid spaces. (After <i>Morris's Anatomy</i>).....	9
7. Horizontal section of the cerebrum. Fornix turned back to show the chorioid tela of third ventricle. (<i>Original</i>)..	11
8. Roof and lateral walls of fourth ventricle and its chorioid plexus. (After <i>Morris's Anatomy</i>).....	13
9. Arterial circle of Willis and its branches. The base of the brain. (After <i>Morris's Anatomy</i>).....	15
10. Arterial circle (Willisi) and base of the cerebrum. (After <i>Gordinier</i> from <i>Quain</i>).....	19
11. Middle cerebral artery, and its branches. (After <i>Gordinier</i> from <i>Quain</i>).....	22
12. Anterior and posterior cerebral arteries. (After <i>Spalteholz</i>)..	25
13. Arteries of the medulla oblongata. (<i>Gordinier</i> after <i>Duret</i>)...	27
14. Median section of embryonic brain of third month. (After <i>McMurrich</i> from <i>His</i>).....	28
15. Divisions of the brain, diagrammatic. (After <i>Morris's Anatomy</i>).....	31
16. Neural tube and brain vesicles. (After <i>Morris's Anatomy</i>)..	35
17. Diagrammatic horizontal section of vertebrate brain, showing vesicles and ventricles. (After <i>Morris</i> from <i>Huxley</i>)	36

FIG.	PAGE
18. Diagrammatic median section of vertebrate brain showing vesicles, ventricles and olfactory diverticulum. (After Morris from Huxley).....	37
19. Antero-superior surface of the brain. (Original).....	39
20. The posterior aspect of the brain. (Original).....	43
21. The base of brain. (Original).....	47
22. Latero-superior aspect of the brain, showing great fissures, lobes, poles and borders. (Original).....	53
23. The convex surface of the cerebrum, showing the fissures and sulci. (Original).....	57
24. Gyri of the convex surface of the cerebrum. (Original).....	61
25. Lateral aspect of the brain. Part of frontal and parietal lobes are cut away to show the island (Reili) and the superior surface of the temporal lobe, arachnoid granulations, etc. (Original).....	65
26. Base of the fore-brain and cut surface of mid-brain. Right temporal pole is cut away. (Original).....	75
27. The median section of the brain. (Original).....	87
28. Medial surface of left cerebral hemisphere, showing lobes and sulci. (Original).....	91
29. Gyri on medial surface of hemisphere. (Original).....	95
30. Transverse section of the brain, directed from the pons obliquely upward and forward, showing internal capsule, corpus callosum, ganglia and ventricles of the fore-brain. (Original).....	101
31. Horizontal section of right cerebral hemisphere cutting corpus callosum, internal capsule, corpus striatum, thalamus, and the island. (Original).....	105
32. Sagittal section of basal part of right cerebral hemisphere showing inferior lamina of internal capsule, hippocampus, inferior horn of lateral ventricle. (Original)....	113
33. Diagram of internal capsule in colors. (Original).....	115
34. Dorsal surface of corpus callosum, cerebral hemisphere cut away to expose it. (Original).....	117
35. Horizontal section of cerebrum, cutting splenium and genu of corpus callosum, showing lateral ventricles, septum pellucidum, fornix and transverse temporal gyri. (Original).....	121
36. Horizontal section of cerebrum just below splenium of corpus callosum, showing commissura hippocampi, fornix, sep-	

FIG.	PAGE
tum pellucidum, the island and lateral ventricles. (<i>Original</i>)	125
37. Horizontal section of cerebrum. Fornix turned back, showing chorioid tael of third ventricle, and internal cerebral veins. (<i>Original</i>).....	129
38. Transverse section of left cerebral hemisphere cutting the splenium and showing the posterior horn and the floor of the inferior horn of the lateral ventricle. (<i>Original</i>)	131
39. The inferior and posterior horns of the lateral ventricle, shown by removal of their lateral walls. (<i>Original</i>).....	133
40. Horizontal section of cerebrum through genu and below splenium of corpus callosum, fornix and chorioid tela turned back, to show inter-brain and third ventricle. (<i>Original</i>).....	137
41. Lateral and dorsal view of the ventricles. Diagrammatic. (<i>Original</i>)	141
42. Transverse section of brain, cutting corpora mammillaria. (After <i>Told. Morris's Anatomy</i>).....	145
43. The region of the mid-brain showing pulvinar of the thalamus, the geniculate bodies, the corpora quadrigemina and brachia, the pineal body, the optic tract and the fourth nerve. (<i>Original</i>)	147
44. The dorsal or posterior aspect of the inter-brain, the mid-brain, the pons and the medulla. (<i>Original</i>).....	149
45. Anterior aspect of the mid-brain, pons, and medulla. (<i>Original</i>).....	153
46. Transverse section through the corpora mammillaria and the superior colliculi of the corpora quadrigemina. (<i>Original</i>)	157
47. Section of the mid-brain through superior colliculi and the apparent origin of the oculo-motor nerve. (<i>Original</i>) ..	159
48. Section of the mid-brain cutting the inferior colliculi of the corpora quadrigemina. (<i>Original</i>).....	161
49. Varieties of neurones in the human nervous system. (After <i>Morris's Anatomy</i>)	165
50. Motor neurone. (After <i>Barker's Nervous System</i>)	169
51. An efferent neurone and an afferent neurone. (After <i>Bru-baker's Physiology</i>).....	171
52. Diagram showing development of neurones in the spinal cord. (<i>McMurrich after Schäffer</i>).....	172

FIG.	PAGE
53. Neuroglia cells and ependyma cells of the spinal cord. (After <i>Lenhossek, Gordinier's Nervous System</i>)	173
54. Cortical areas on convex surface of cerebral hemisphere. (<i>Original</i>)	175
55. Cortical areas on the medial and tentorial surface of the cerebral hemisphere. (<i>Original</i>).....	179
56. Cortical areas after C. K. Mills. Convex surface of cerebral hemisphere. (<i>Brubaker's Physiology</i>).....	182
57. Cortical areas after C. K. Mills. Medial and tentorial surface of cerebral hemisphere. (<i>Brubaker's Physiology</i>)....	183
58. Cell and fiber lamination in the posterior half of the anterior central gyrus. The motor area. (After <i>A. W. Campbell</i>)	185
59. Cell and fiber lamination in the anterior half of the posterior central gyrus. The common sensory area. (After <i>A. W. Campbell</i>).....	189
60. Cell and fiber lamination in the calcarine region. Receptive visual area. (After <i>A. W. Campbell</i>)	193
61. Cell and fiber lamination in the uncus hippocampi (lobus pyramiformis). The area of smell. (After <i>A. W. Campbell</i>)	197
62. Transverse section of the hippocampal region. (After <i>Edinger</i>)	201
63. Chief elements of the olfactory bulb. (<i>Gordinier after Van Gehuchten</i>)	203
64. Horizontal section of the cerebrum through genu and below splenium of corpus callosum, fornix and chorioid tela turned back to show inter-brain and third ventricle. (<i>Original</i>).....	205
65. Dissection of brain to show geniculate bodies, optic tract, nucleus amygdalæ, etc. (After <i>Morris's Anatomy</i>) ...	207
66. Transverse section of the brain in the line of the pyramidal tracts, showing basal ganglia, internal capsules, corpus callosum, lateral and third ventricles, etc. Viewed from front. (<i>Morris's Anatomy after Toldt</i>).....	209
67. The optic path. (<i>Original</i>).....	213
68. Section of mid-brain through superior colliculi and the apparent origin of the oculomotor nerve. (<i>Original</i>).....	215
69. Section of the mid-brain cutting the inferior colliculi of the corpora quadrigemina. (<i>Original</i>).....	216
70. Horizontal and sagittal section through internal capsule, much enlarged. (<i>Original</i>).....	226

FIG.	PAGE
71. Diagram of internal capsule in colors. (<i>Original</i>).....	227
72. A diagram showing motor and sensory paths, motor red, sensory blue. (After <i>Gordinier's Central Nervous System</i>).....	229
73. Transverse section of cerebrum, cutting corpus callosum, anterior commissure and optic chiasma. Viewed from front. Commissural fibers. (<i>Morris's Anatomy</i> after <i>Toldt</i>)	235
74. Diagram of association fibers in the cerebral hemisphere. (<i>Gordinier</i> and <i>Quain</i> after <i>Meynert</i>).....	237
75. Fasciculus occipito-frontalis. Stria terminalis and fasciculus uncinatus. (<i>Gordinier</i> after <i>Dejerine</i>)	239
76. Dorsal view of inter-brain, mid-brain and cerebellum. Superior surface of cerebellum. (<i>Original</i>).....	243
77. Anterior aspect of cerebellum. (<i>Original</i>).....	245
78. Dissection of rhombencephalon to show brachium conjunctivum, brachium pontis and corpus restiforme. (<i>Gordinier</i> , <i>Sappey</i> after <i>Hirschfeld</i> and <i>Leveille</i>).....	246
79. Median section of cerebellum, pons and medulla. (<i>Original</i>)	247
80. Inferior surface of cerebellum. (<i>Original</i>).....	252
81. Sagittal section of cerebellum, cutting nucleus dentatus. (<i>Original</i>).....	255
82. Section of cerebellar gyrus made parallel with its free border. Diagrammatic. (<i>Cunningham</i> after <i>Kölliker</i>).....	258
83. Section across a cerebellar gyrus at a right angle to the free border. Diagrammatic. (<i>Gordinier</i> after <i>Van Gehuchten</i>).....	259
84. Horizontal section of cerebellum cutting nuclei and brachia conjunctiva. (<i>Morris's Anatomy</i> after <i>Toldt</i>).....	261
85. Anterior aspect of mid-brain, pons and medulla. (After <i>Morris's Anatomy</i>).....	267
86. Dorsal surface of pons and medulla. (<i>Morris's Anatomy</i> modified from <i>Spalteholz</i>)	270
87. Superior transverse section of the pons. (<i>Original</i>).....	275
88. Inferior transverse section of the pons together with the cerebellum. (<i>Original</i>)	277
89. Diagram of the auditory paths in the pons. (After <i>Morris's Anatomy</i>)	280
90. Section of embryonic medulla, embryo measuring 9.1 mm. in length. (<i>Gordinier</i> and <i>Minot</i> after <i>His</i>).....	285

FIG.	PAGE
91. Roof and lateral walls of fourth ventricle, and its chorioid plexuses. (After <i>Morris's Anatomy</i>)	289
92. Section of medulla oblongata near the pons. (<i>Original</i>) ...	295
93. Section of the medulla oblongata at the middle of olive. (<i>Original</i>).....	297
94. Section of the medulla oblongata at the fillet decussation. (<i>Original</i>).....	305
95. Section of the medulla oblongata at the pyramidal decussation. (<i>Original</i>)	311
96. Nuclei of the cerebral nerves in the medulla, pons, mid-brain, inter-brain, and olfactory bulb. Motor (or genetic) nuclei red, terminal (or sensory) nuclei blue. (After <i>Morris's Anatomy</i>)	315
97. Meninges of the spinal cord. A. Transverse section. (After <i>Key and Retzius.</i>) B. Anterior view. (After <i>Ellis.</i>) (<i>Morris's Anatomy</i>).....	327
98. Diagrammatic section of the spinal meninges and spinal cord. (After <i>Morris's Anatomy</i>).....	329
99. The arteries and veins in the spinal cord. Diagrammatic. (After <i>Morris's Anatomy</i>).....	331
100. Posterior view of the spinal cord, the dura mater and the arachnoid being laid open and turned aside. (<i>Brubaker</i> after <i>Sappey</i>).....	334
101. Sections of the spinal cord: A. The cervical. B. The thoracic. C. The lumbar, and D. The lower sacral. (<i>Original</i>).....	335
102. Tracts of fibers and columns of cells, in the cervical and thoracic regions of the cord. Diagrammatic. (In part after <i>Bruce and Cunningham</i>).....	341
103. Tracts of fibers and columns of cells in the lumbar and sacral regions of the cord. Diagrammatic. (In part after <i>Bruce and Cunningham</i>).....	345
104. The roots of the spinal nerves. Diagrammatic. (<i>Original</i>). ...	349
105. Direct motor paths from cerebral cortex, to cerebral and spinal nerve. Diagrammatic. (<i>Original</i>).....	367
106. Indirect motor paths to the spinal nerves. Diagrammatic. (<i>Original</i>)	371
107. Common sensory paths, muscular and tactile, by way of the posterior column and (posterior) cerebello-spinal tract. Diagrammatic. (<i>Original</i>)	375

FIG.	PAGE
108. Common sensory paths, pain, temperature and touch, by way of ascending anterior cerebello-spinal and spino-thalamic tracts. Diagrammatic. (<i>Original</i>)	379
109. Chief elements of the olfactory bulb. (<i>Gordinier after Van Gehuchten</i>)	384
110. The chief retinal elements. (<i>After Brubaker's Physiology</i>)..	385
111. The optic path. (<i>Original</i>)	387
112. A simple spinal reflex arc. (<i>Brubaker after Morat and Dayon</i>)	391
113. A more complicated spinal reflex arc, involving the fasciculi proprii. (<i>Brubaker after Kölliker</i>)	392
114. Medullary groove, neural tube, etc. (<i>Gordinier after E. A. Schäfer</i>)	396
115. Two histologic layers in the embryonic spinal cord, embryo 4.25 mm. long. (<i>McMurrich after His</i>)	397
116. Diagram showing development of neurones in the spinal cord. (<i>McMurrich after Schäfer</i>)	398
117. Ventral and dorsal zones of the spinal cord. (<i>Gordinier and Quain after Kölliker</i>)	399
118. Median section of embryonic brain of the third month. (<i>McMurrich after His</i>)	406
119. Transverse section through the fore-brain of a four and one half weeks' embryo. (<i>Gordinier and Quain after His</i>)	407
120. Diagrammatic sagittal section of vertebrate brain. (<i>Morris's Anatomy after Huxley</i>)	409
121. Medial sagittal section through the brain of an embryo of three months showing the primitive fissures on the medial surface of the cerebral hemisphere. (<i>McMurrich after Mihalkovicz</i>)	411
122. The fossa cerebri lateralis, in embryonic brain of fourth month. (<i>After McMurrich's Development of the Human Body</i>)	413
123. Permanent fissures and sulci on the convex surface of the cerebrum as seen in a seven months' embryo. (<i>McMurrich after Cunningham</i>)	414
124. Dorsal view of an embryonic brain, the roof of the lateral ventricles having been cut away. Embryo of 12.6 mm. (<i>McMurrich after His</i>)	416
125. Transverse section of medulla from an embryo of 9.1 mm. (<i>McMurrich after His</i>)	422

FIG.	PAGE
126. Transverse section of the medulla from an embryo of eight weeks. (<i>McMurrich</i> after <i>His</i>).....	423
127. Transverse section of the spinal cord, from an embryo of (A) four and one-half weeks, and (B) of three months. (<i>McMurrich</i> after <i>His</i>).....	427
128. Mode of origin of anterior and posterior roots of spinal nerves. Diagrammatic. (<i>Brubaker</i> and <i>Edinger</i> after <i>His</i>).....	428

ERRATA.

Page 30. Paragraph two, last line, last word should be **brain-vesicles**.

Page 57. Fig. 23. "Intraparietal sulcus," and wherever found should be written **Interparietal sulcus**.

Page 108. Paragraph four, fourth line, second word is **sulcus**, instead of "fissure."

Page 184. Paragraph one, last line and first word is **Alfred**, instead of "Arthur."

Page 264. Fourth line, the phrase "anterior ascending cerebello-spinal tract," and wherever it occurs, should read **Ascending anterior cerebello-spinal tract**.

Page 265. Paragraph two, third line, the phrase "anterior descending cerebello-spinal tract," should stand **Descending anterior cerebello-spinal tract**: likewise, wherever the quoted phrase is found.

Page 277. Third line, last word is (**Horsley**).

Page 286. Paragraph three, last sentence, the phrase "fasciculus cerebello-spinalis," and wherever else it occurs should stand thus—**fasciculus cerebello-spinalis (posterior)**.

Page 288. Paragraph three, fifth line, the substantive "cerebello-spinal fasciculus" should have "posterior" prefixed so as to read **posterior cerebello-spinal fasciculus**. This is a necessary variation from the BNA and applies wherever the phrase is found.

Page 291. Last line, there should be added a fifth item, viz., (e) the medullary striæ.

Page 319. Fifth line, **common sensory** should be added under intermediate nerve.

Page 351. Paragraph three, third item, (3) should be omitted, as no posterior root-fibers decussate. Intrinsic fibers only cross through the gray commissure (Mott and Russell).

Page 358. To the last sentence should be added: **and according to Sir Victor Horsley has to do with locomotion (Brain, 1906).**

Page 410. Fourth line, "callosal fissure" should be **callosal sulcus.**

BRAIN AND SPINAL CORD.

CHAPTER I.

THE MENINGES OF THE BRAIN.

(*Meninges Encephali.*)

Three membranes invest the brain and spinal cord. They are, from without inward, the dura mater, the arachnoid, and the pia mater. Each membrane forms a protecting sheath for the cerebral or spinal nerves piercing it.

THE DURA MATER OF THE BRAIN.

(*Dura Mater Encephali.*)

Structure and Relations.—It is a very dense and inelastic membrane composed of white fibrous and yellow elastic tissue lined with flat endothelial cells, which constitute its internal surface. In children it is closely adherent to the cranial bones of which it forms the real periosteum; but it is attached chiefly at the foramina and along the sutures in adults. The dura of the brain is made up of two layers which are separable up to the eighth or tenth year. The *external layer* constitutes the endosteum of the cranial bones. It is their nutrient membrane. Through the cranial foramina and sutures it is continuous with the external periosteum. In the adult the *internal layer* of the dura separates from the outer layer only over the apex of the petrous bone, to form Meckel's space for the semilunar ganglion (Gasseri); at the foramina, to form sheaths for the nerves; and, along the sinuses, to form their internal boundary and to produce the great incomplete partitions, called processes, which project centrally into the great fissures of the brain.

Processes. (*Processus duræ matris*).—From the inner surface of the dura the great processes are given off. The **falx cerebri**

and **falx cerebelli** hang vertically in the longitudinal fissure of the cerebrum and the posterior notch of the cerebellum; and, into the transverse fissure of the cerebrum, extends horizontally the **tentorium cerebelli**. The falx cerebri (Figs. 1, and 4) is attached in front to the crista galli and behind to the internal occipital protuberance and superior surface of the tentorium; the falx cerebelli (Fig. 1) continues from the inferior surface of the tentorium, along the occipital crest, to the posterior border of the foramen magnum. The bony attachment of the tentorium cerebelli (Fig. 2) is to the internal protuberance and the lateral arms of the crucial ridge forward to the petrous bone; and, then, it is along the superior border of the petrous bone to the clinoid processes of the sphenoid. Between its clinoid attachments there is a deep bay, the *incisura tentorii*, which transmits the midbrain. The **diaphragma sellæ** is a small centrally perforated sheet of dura which covers the hypophyseal fossa.

Sinuses. (*Sinus duræ matris*).—Large venous passages lined with endothelial cells, and called sinuses, are situated between the layers of the dura (Figs. 1, 2, 3 and 4). In the convex and in the free border of the falx cerebri are, respectively, the **superior sagittal sinus** (*s. sagittalis superior*) and the **inferior sagittal sinus** (*s. sagittalis inferior*). The superior (Fig. 1) extends from the foramen cæcum back to the **confluens sinuum** (torcular Herophili,) located at the internal occipital protuberance. Having run through the posterior two-thirds of the concave border of the falx cerebri, the inferior sagittal sinus joins the great cerebral vein at the margin of the tentorium and forms the **straight sinus** (*s. rectus*). The latter runs through the middle of the tentorium to the confluens (Fig. 2). The **occipital sinus** (*s. occipitalis*) traverses the falx cerebelli from the foramen magnum upward to the same point. In the confluens sinuum the **transverse sinuses** (*s. transversi*) rise (Fig. 2). Grooving the horizontal arms of the crucial ridge, each runs outward in the tentorium to the base of the petrous bone, where it receives the superior petrosal sinus; it then turns downward through the sigmoid fossa, communicates with the occipital sinus and unites with the inferior petrosal sinus in the jugular foramen. Situated on either side

of the sella Turcica is a continuation of the ophthalmic vein, the large **cavernous sinus** (*s. cavernosus*) (Fig. 3), which receives at the sphenoidal fissure the **spheno-parietal sinus** (*s. alæ parvæ*), the course of which is along the posterior border of the lesser wing of the sphenoid bone. At the posterior clinoid process the

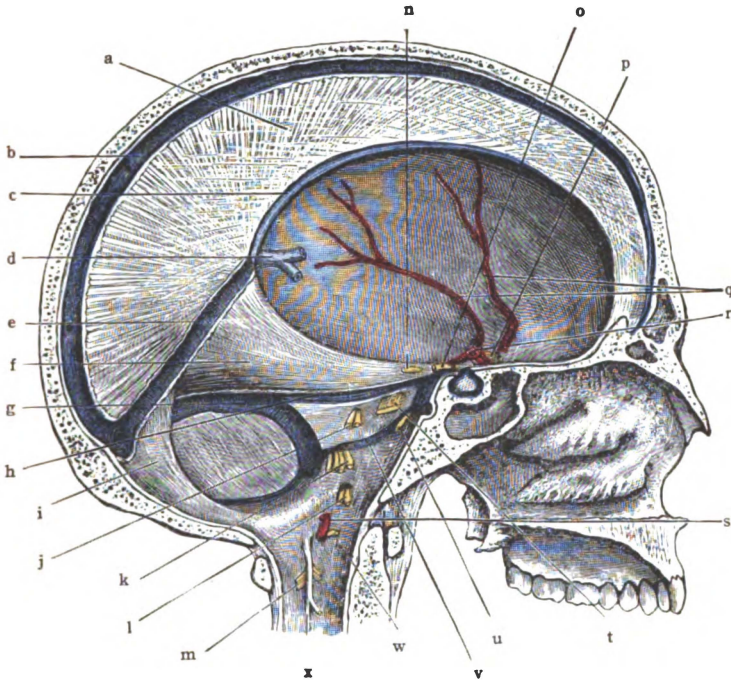


Fig. 1.—Sagittal section of skull, showing falx cerebri, falx cerebelli, part of tentorium cerebelli and sinuses. (After *Morris's Anatomy*.)

a. Falx cerebri. b. Superior sagittal sinus. c. Inferior sagittal sinus. d. Great cerebral vein. e. Straight sinus. f. Tentorium cerebelli. g. Transverse sinus. h. Superior petrosal sinus. i. Falx cerebelli. j. Seventh and eighth nerves. k. Ninth, tenth, and eleventh nerves. l. Twelfth nerve. m. Second cervical nerve. n. Fourth nerve. o. Third nerve. p. Second nerve. q. Middle meningeal artery. r. Internal carotid artery. s. Vertebral artery. t. Fifth nerve. u. Sixth nerve. v. Inferior petrosal sinus. w. First cervical nerve. x. Ligamentum denticulatum.

cavernous sinus divides into the **superior petrosal sinus** (*s. petrosus superior*) and the **inferior petrosal sinus** (*s. petrosus inferior*). The *sinus intercavernosus anterior* and *sinus intercavernosus posterior* extend across the hypophyseal fossa, and join the two cavernous sinuses together, and these four communicating sinuses

constitute the **circular sinus** (*s. circularis*) (Fig. 3). From the bifurcation of the cavernous sinus at the apex of the petrous bone, the petrosal sinuses run outward along the corresponding superior and inferior borders of that bone. The *superior petrosal sinus*

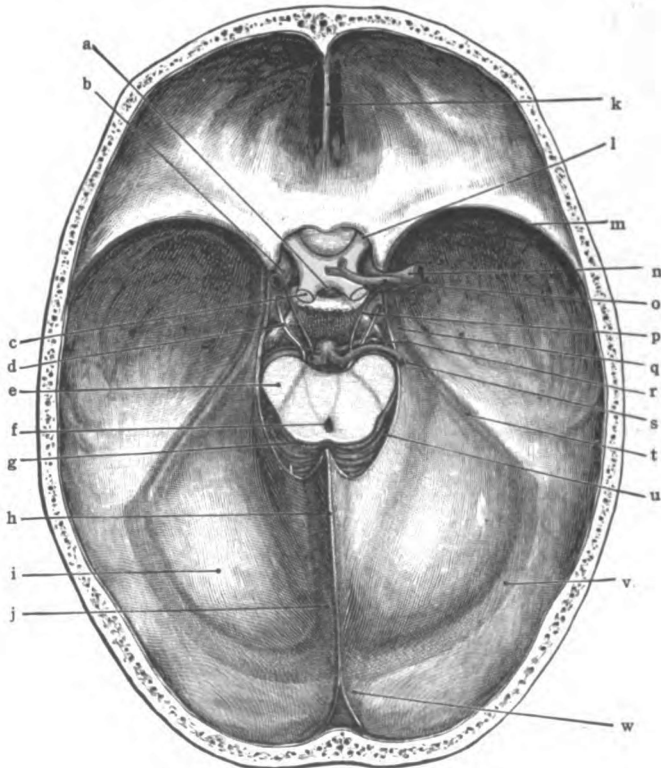


Fig. 2.—Horizontal section of skull, showing tentorium cerebelli, tentorial notch and sinuses. (After *Morris's Anatomy*.)

a. Infundibulum. b. Internal carotid artery. c. Optic tract. d. Third nerve. e. Basis pedunculi. f. Cerebral aqueduct (Sylvii). g. Quadrigeminal body. h. Falx cerebri. i. Tentorium cerebelli. j. Straight sinus. k. Crista galli. l. Optic nerve. m. Sphenoparietal sinus. n. Middle cerebral artery. o. Anterior cerebral artery. p. Posterior communicating artery. q. Cavernous sinus. r. Superior cerebellar artery. s. Posterior cerebral artery. t. Superior petrosal sinus. u. Free border of tentorium bounding tentorial notch. v. Transverse sinus. w. Superior sagittal sinus.

(Figs. 1 and 2) empties into the transverse sinus at the base of the petrous bone; the *inferior petrosal sinus*, in its course to the jugular foramen, is joined to its fellow, across the basilar process of the occipital bone, by the **basilar plexus** (*p. basilaris*) and, in

the jugular foramen, unites with the transverse sinus in forming the internal jugular vein.

Arachnoid Granulations (Fig. 25).—Along and within the

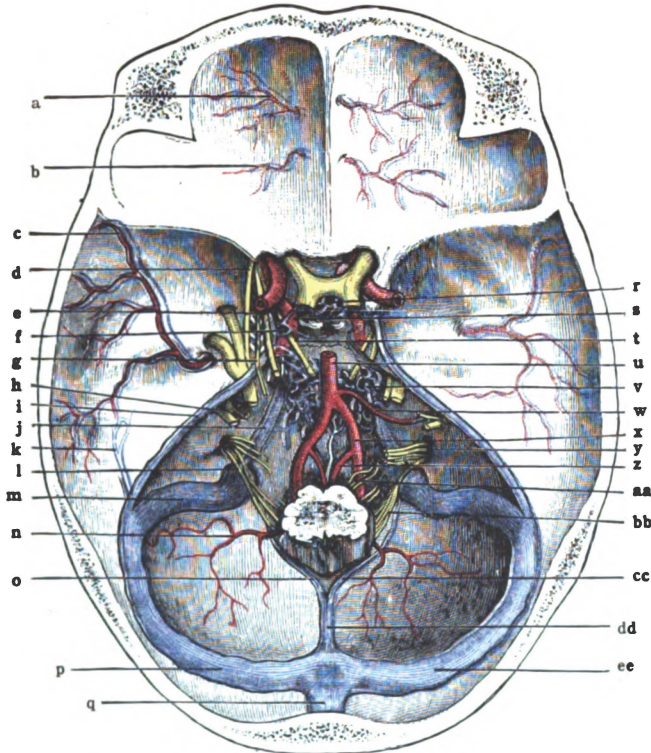


Fig. 3.—Sinuses in the base of the cranium, also meningeal arteries.
(After *Morris's Anatomy*.)

a. Meningeal branch of anterior ethmoidal artery. b. Meningeal branch of posterior ethmoidal artery. c. Middle meningeal artery. d. Ophthalmic division of fifth nerve. e. Third nerve. f. Cavernous sinus. g. Fourth nerve. h. Auditory and facial nerves. i. Superior petrosal sinus. j. Inferior petrosal sinus. k. Petro-squamosal sinus. l. Accessory nerve. m. Sigmoid part of transverse sinus. n. Posterior meningeal branch of vertebral artery. o. Left marginal sinus. p. Left transverse sinus. q. Superior sagittal sinus. r. Circular sinus. s. Carotid artery. t. Sixth nerve. u. Basilar artery. v. Basilar plexus of veins. w. Auditory artery. x. Vertebral artery. y. Glossopharyngeal and vagus nerves. z. Anterior spinal artery. aa. Hypoglossal nerve. bb. Accessory nerve. cc. Right marginal sinus. dd. Occipital sinus. ee. Right transverse sinus.

superior sagittal, the straight, the transverse, the petrosal and the cavernous sinuses are the *granulationes arachnoideales* (Pacchionian bodies). These granulations are enlarged villi of the

arachnoid (Fig. 4) and seem to afford an outlet for the subarachnoid fluid into the sinuses. They are said to make their appearance about the tenth year and to be more numerous and larger in the male sex. Some of them by absorption produce depressions in the cranial bones called *joveola granulares*.

The arteries which supply the dura are (1) The anterior meningeal from the anterior ethmoidal branch of the ophthalmic. (2) The middle meningeals, viz., the great and the small middle meningeal from the internal maxillary, the meningeal branch

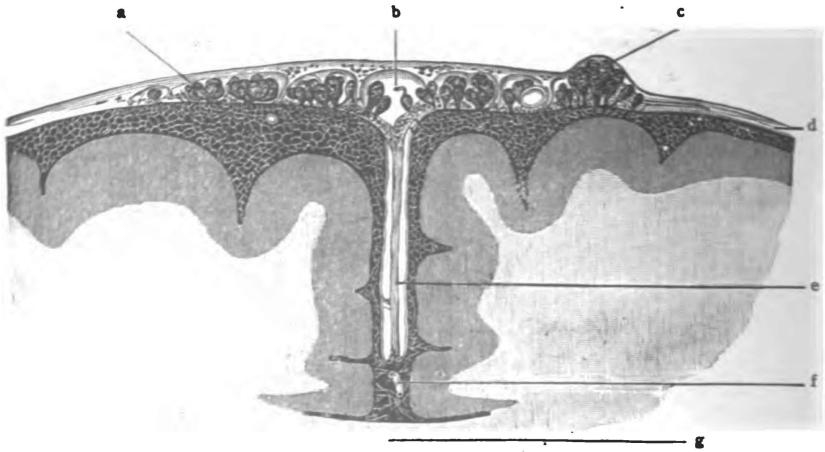


Fig. 4.—Coronal section showing falx cerebri, superior sagittal sinus and arachnoid granulations. (*Gordinier after Key and Retzius.*)

a. Subarachnoid space. b. Superior sagittal sinus. c. Arachnoid granulations (*Pacchioni*). d. Dura mater. e. Falx cerebri. f. Anterior cerebral artery. g. Corpus callosum.

of the lacrimal and of the internal carotid, and the meningeal branch of the ascending pharyngeal which enters the middle fossa of the cranium through the lacerate foramen. (3) The posterior meningeal arteries, which rise from the ascending pharyngeal, the occipital and the vertebral and are distributed to the dura over the posterior cranial fossa.

The **great middle meningeal artery** (*arteria meningea media*) is much the largest and is most important (Fig. 5). It overlies the motor and somæsthetic areas of the brain. Like the other meningeal arteries it is usually accompanied by two veins. Ascend-

ing from the foramen spinosum it divides near the upper border of the squamosa into two large branches, the anterior and posterior. The posterior runs horizontally backward just below the squamoparietal suture and then ascends over the posterior half of the parietal bone. The anterior branch runs upward a half-inch behind the coronal suture. It may be located, according to Quain, at one inch, at one inch and a half, and at two inches

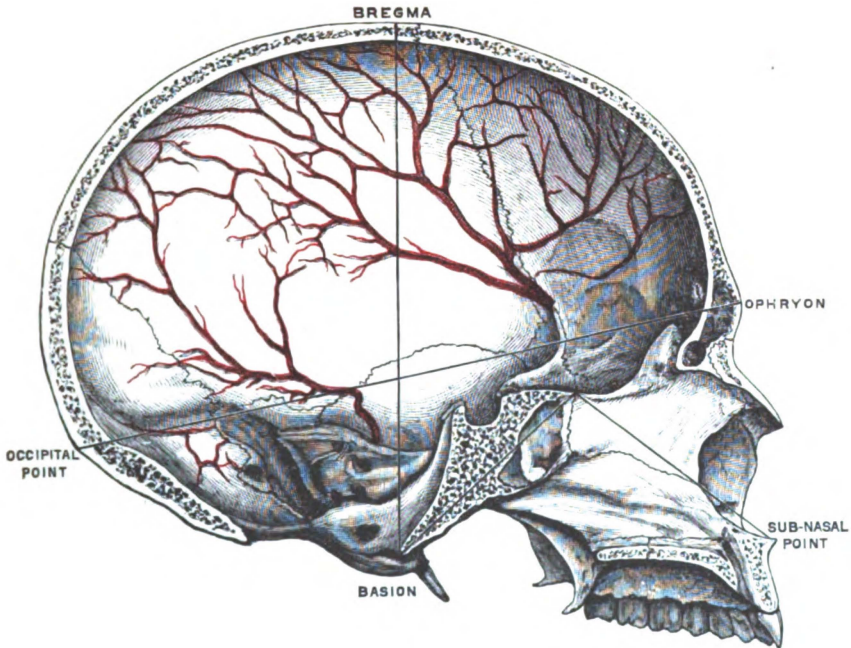


Fig. 5.—Median section of skull showing middle meningeal artery.
(After *Morris's Anatomy*.)

behind the zygomatic process of the frontal bone and above the zygomatic process of the temporal bone.

The following nerves give branches to the dura:—Trochlear, ophthalmic, semilunar ganglion, vagus and hypoglossal of the cerebral group; and the sympathetic. The motor fibers supply the meningeal arteries.

Six Points of Difference in the Dura of the Cord.—Absence of processes, of sinuses, of arachnoid granulations, and of periosteal

function. It is covered on both surfaces by endothelium and is separated from the vertebræ by areolar tissue, fat and the plexus of internal vertebral veins.

THE ARACHNOID OF THE BRAIN.

(*Arachnoidea Encephali.*)

In structure it is a delicate, fibrous, web-like membrane covered externally with endothelium. Internally it is joined to the pia mater by innumerable fibrous trabeculæ, the subarachnoid tissue (Fig. 4). The trabeculæ are ensheathed and all subarachnoid spaces lined with a single layer of endothelial cells, hence both surfaces are formed of endothelium. Conical elevations of fibrous tissue with their investing endothelium constitute the villi seen on the outer surface.*

Relations.—The arachnoid follows the inner surface of the dura and is prolonged, as a sheath, upon the nerves which pierce it. It does not dip into the sulci of the cerebrum (Fig. 6); but only into the lateral fissure and the longitudinal fissure, and does not reach to the bottom of the latter. From the pia it is separated by the **subarachnoid spaces** (*cava subarachnoidealìa*). The *anterior subarachnoid space* (Fig. 6) includes the cisterna pontis, cisterna interpeduncularis, cisterna chiasmatis and cisterna fossæ lateralis cerebri. It is located in front of the medulla, pons and mid-brain and between the temporal lobes of the cerebrum. The *posterior subarachnoid space* (Fig. 6) is located behind the medulla and cerebellum. It embraces the cisterna cerebello-medullaris, a space between the medulla and cerebellum, and the cisterna venæ cerebri magnæ, situated along the straight sinus and the great cerebral vein. These two, the anterior and posterior, are the largest subarachnoid spaces and they contain much of the subarachnoid fluid. But in the cerebral sulci and fissures there are streams of this fluid which constitute the *subarachnoid rivulets*. The anterior subarachnoid space has *slit-like com-*

*Some authors consider this membrane, as just described above, merely as a visceral layer of the arachnoid, and regard the endothelial lining of the dura mater as its parietal layer. According to such, therefore, the subdural space becomes the arachnoid space.

munications with the inferior horn of the lateral ventricle; the posterior space communicates with the fourth ventricle (Fig. 8) through the *median aperture* (*apertura mediana ventriculi quarti, Magendi*) and the *lateral apertures* (*aperturae laterales ventriculi quarti, Key and Retzii*).

The **vessels** seen for a short distance in the arachnoid belong to the pia mater. Its **nerves** are doubtful. Perhaps branches of the mandibular, of the facial and of the accessory supply it.

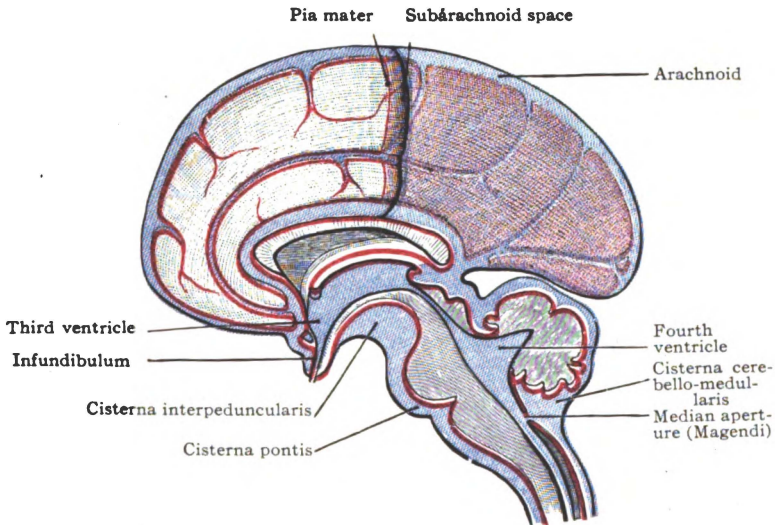


Fig. 6.—Diagram of pia and arachnoid, showing subarachnoid spaces.
(After *Morris's Anatomy*.)

In the arachnoid of the cord fewer trabeculae join it to the pia; and these, in great part, are collected to form a fenestrated septum in the posterior median line (Fig. 97, A). The external spinal veins are covered by the spinal arachnoid, they lie between it and the pia.

THE PIA MATER OF THE BRAIN.

(*Pia Mater Encephali*.)

Structure and Relations.—It is a vascular membrane composed of a close network of veins and arteries held together by

fibro-elastic areolar tissue (Fig. 9). The endothelium covering its outer surface is continuous with that ensheathing the subarachnoid trabeculæ. The pia closely follows the brain surface (Fig. 6). Internally, it sends supporting trabeculæ into the brain, which transmit blood-vessels; and externally it forms an investing sheath for each cerebral nerve.

Folds.—Two important processes are formed by the pia mater: (1) The **chorioid tela of the third ventricle** (*tela chorioidea ventriculi tertii*) is pushed forward into the anterior part of the transverse fissure of the cerebrum between the fornix and the interbrain (Fig. 6). Hence the old name, velum interpositum. It is triangular in shape, with apex directed forward (Fig. 7). Each lateral border is tucked into the chorioidal fissure of the cerebral hemisphere and enters into the floor of the lateral ventricle, while the median part of the fold is in the roof of the third ventricle. Between the two layers of this chorioid tela is some areolar tissue through which run backward the two *internal cerebral veins* and unite near the base of the tela to form the *great cerebral vein*. The *chorioid plexuses* of the lateral and the third ventricles occupy, respectively, the lateral borders and the median area of this chorioid tela. (2) A second fold of pia mater is tucked into the transverse fissure of the cerebellum, dorsal to the medulla oblongata and ventral to the posterior median part of the cerebellum (Fig. 6). It is called the **chorioid tela of the fourth ventricle** (*tela chorioidea ventriculi quarti*) because its inferior layer enters into the roof and contains the *chorioid plexus* of that ventricle. This lower layer invests the posterior surface of the medulla and the roof-epithelium of the fourth ventricle (Fig. 8). It is pierced by three foramina which are situated as follows: One over each lateral angle of the fourth ventricle, the *lateral apertures* (Key and Retzii), and one over its inferior angle. The latter is the largest and is called the median aperture (*Magendi*). Those three foramina establish communication between the posterior subarachnoid space and the fourth ventricle.

The arteries of the pia mater supply the brain (Figs. 9, 10, 11 and 12). They are the anterior, middle and posterior cerebrals; the anterior and posterior chorioidals; and the anterior and pos-

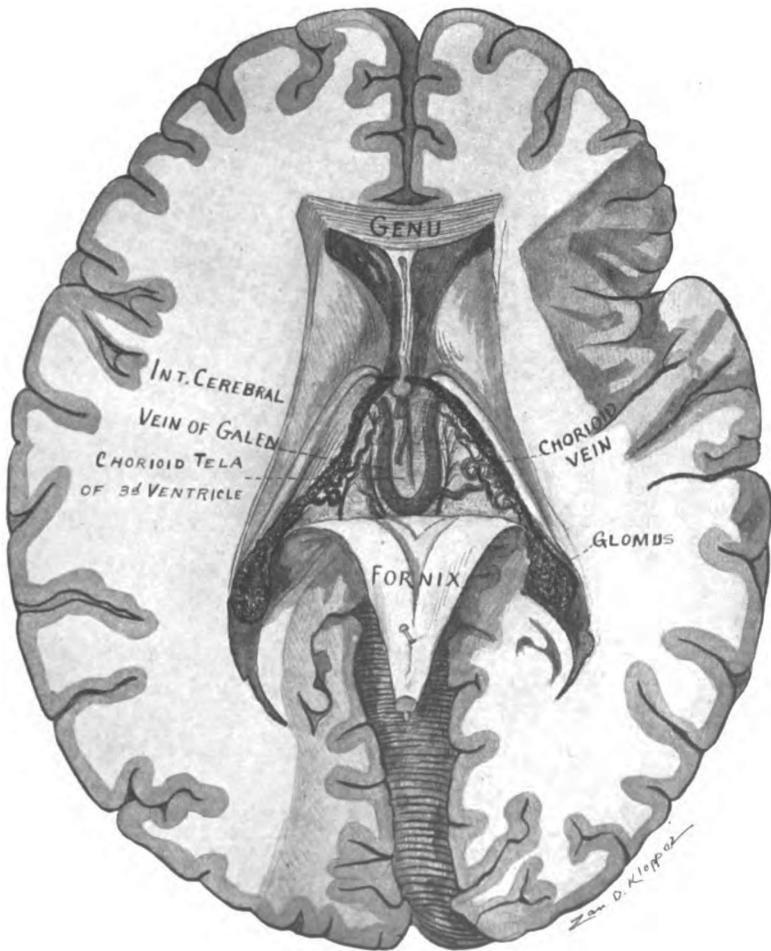


Fig. 7.—Horizontal section of cerebrum. Fornix turned back, showing chorioid tela of third ventricle, and internal cerebral veins. (Original.)

terior inferior cerebellar and the superior cerebellar with many branches.

The veins are more numerous than the arteries in the pia: the internal and great cerebral veins, the veins of the chorioid plexuses of the lateral, third and fourth ventricles and the basilar vein; the cerebral veins, superior, medial and inferior; and the superior and inferior cerebellar veins. All of them empty into the sinuses (see page 2).

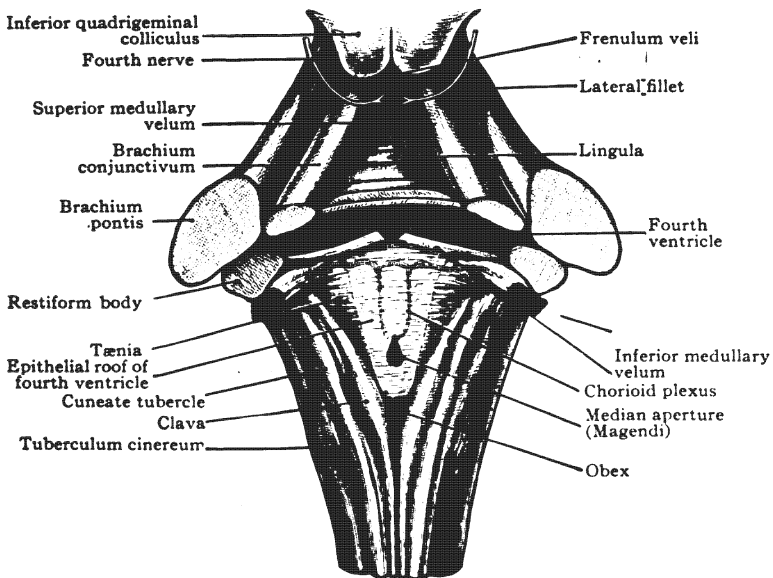


Fig. 8.—Roof and lateral walls of fourth ventricle, and its chorioid plexuses.
(After Morris's Anatomy.)

Seven cerebral nerves—3d, 5th, 6th, 7th, 9th, 10th and 11th—and the sympathetic supply the pia mater and its blood-vessels.

The pia mater of the spinal cord has two layers, the outer of which is the more vascular and contains the spinal arteries and the tributaries of the external spinal veins. It forms three processes, namely, the anterior septum, which occupies the anterior median fissure, and the ligamentum denticulatum of each side.

THE BLOOD SUPPLY OF THE BRAIN.

The brain is furnished with blood by the internal carotid and vertebral arteries (Fig. 9). The **internal carotid artery** (*a. carotis interna*) gives origin to the anterior and the middle cerebral, the anterior chorioidal and the posterior communicating; the **vertebral artery** (*a. vertebralis*) gives off the anterior and posterior spinal and the posterior inferior cerebellar and then unites with its fellow at the inferior border of the pons and forms the basilar artery. The **basilar artery** (*a. basilaris*) runs upward the length of the pons and terminates in the two posterior cerebral arteries and, furthermore, gives off the following collateral branches, viz., the anterior inferior cerebellar, the pontal, the internal auditory and the superior cerebellar. Certain of these arteries form a wonderful *circular anastomosis* at the base of the brain, called the **arterial circle** and the distribution of that circle is to the cerebrum (Figs. 9 and 10); while the rhombencephalon (pons, cerebellum and medulla) is supplied by the remainder of the arteries above enumerated. It is therefore convenient to describe the circulation of the brain under two heads: (A) **The circulation of the cerebrum**, and (B) **The circulation of the rhombencephalon**.

A. THE CEREBRAL CIRCULATION, ARTERIES.

The Arterial Circle. (*Circulus arteriosus, Willisii*).—The arteries which supply the cerebrum freely communicate in the arterial circle, which is really a heptagon extending from a point in the longitudinal fissure anterior to the optic chiasma, back to the pons (Fig. 9). It is about an inch and a half long, and from a half to one inch in transverse diameter. In front are the anterior cerebral arteries converging forward from the internal carotids and, through the anterior communicating artery (*a. communicans anterior*), uniting just as they enter the longitudinal fissure of the cerebrum. These vessels form three sides of the heptagon and the front of the circle. On either side, the posterior communicating artery (*a. communicans posterior*) which connects the internal carotid with the posterior cerebral artery, forms the lateral bound-

ary of the circle. The posterior cerebral arteries bound the circle behind, and so complete it (Fig. 10). The large **distal branches** of the arteries which are connected with the arterial circle are distributed chiefly to the cortex and medulla of the hemispheres; while the small **proximal branches** supply the

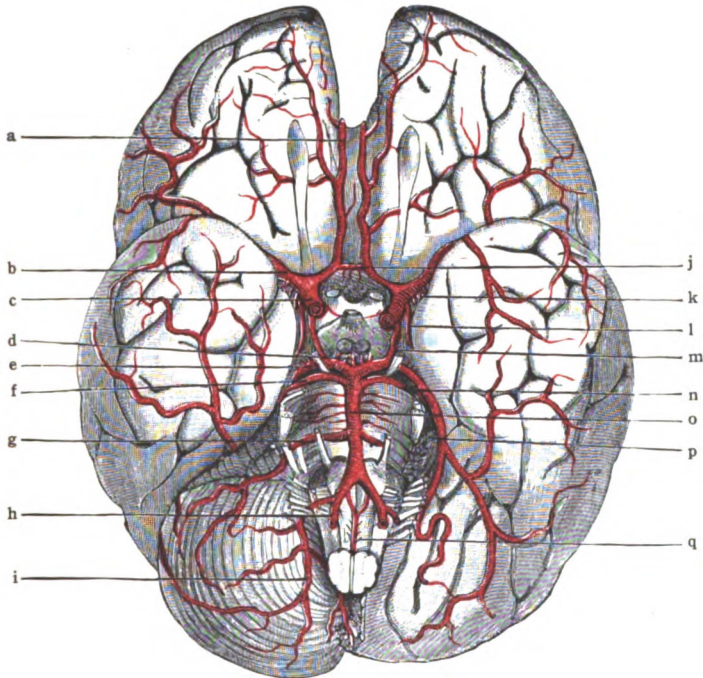


Fig. 9.—Arterial circle and its branches on the base of the brain.
(After *Morris's Anatomy*.)

a. Anterior cerebral artery. b. Middle cerebral artery. c. Internal carotid artery. d. Postero-median ganglionic. e. Posterior cerebral artery. f. Superior cerebellar artery. g. Anterior inferior cerebellar artery. h. Vertebral artery. i. Posterior inferior cerebellar artery. j. Anterior communicating artery. k. Antero-lateral ganglionic. l. Anterior chorioid. m. Posterior communicating artery. n. Posterior chorioid. o. Basilar artery. p. Hemisphere of cerebellum cut away. q. Anterior spinal artery.

ganglia and the inter-brain. The former belong to the cortical system (A₁), the latter to the ganglionic system (A₂).

A1. The Cortical System of Arteries.—The cortical arterial system comprises the distal portions of the anterior, middle and posterior cerebral and the chorioidal arteries. The branches of

these great vessels pierce the hemispheres perpendicularly to the surface. They are distributed, *the short*, to the cortex, and *the long*, to the medulla of the hemispheres. To a limited extent they anastomose with one another, but they do not communicate with the ganglionic system.

The anterior cerebral artery (*a. cerebri anterior*, Figs. 9 and 12), a branch of the internal carotid, runs forward and toward the median line above the optic nerve and enters the longitudinal fissure; it is here joined to its mate by a very short artery, the *anterior communicating*. Winding around the genu of the corpus callosum, it runs back on the medial surface of the hemisphere to the occipito-parietal sulcus. It gives origin to the antero-median ganglionic arteries, and to **four groups of cortical branches**: (1) *The internal orbital artery* (Figs. 9 and 10) which supplies the medial orbital gyrus, the gyrus rectus, the optic chiasma and the olfactory bulb, tract, medial and intermediate striæ, triangle, and parolfactory area. (2) *The anterior internal frontal* (Fig. 12) which enters the anterior parts of the gyrus cinguli and superior frontal gyrus on the medial surface and of the superior and middle frontal gyri on the convex surface. (3) *The middle internal frontal branches*, which are distributed to the middle part of the gyrus cinguli, to the paracentral lobule and to the upper portions of the superior frontal and the anterior and posterior central gyri. (4) *The posterior internal frontal branches*, which run back to the occipito-parietal sulcus. They supply nearly the whole corpus callosum, the posterior half of the gyrus cinguli, a part of the paracentral lobule, the præcuneus, and the superior parietal lobule.

The middle cerebral artery (*a. cerebri media*, Figs. 10 and 11) crosses the anterior perforated spot and runs in the lateral fissure of the cerebrum to the posterior sulcus circularis (Reili) where it breaks up into several parieto-temporal branches. It gives origin to the antero-lateral ganglionic arteries, and to **four cortical branches**: (1) *The lateral orbital branches* are distributed to the anterior and posterior orbital and the inferior frontal gyri. (2) *The ascending frontal*, two branches, which follow the pre-central and central sulci, supply the anterior central gyrus and

the posterior fourth of the middle frontal gyrus. (3) *The ascending parietal*, whose course is along the interparietal sulcus, furnishes blood to the posterior central gyrus and the adjacent parts of the superior and inferior parietal lobules. (4) *The parieto-temporal arteries*, which comprise two polar branches to the temporal lobe and a large posterior branch. The latter runs in the posterior ramus of the lateral cerebral fissure to its upturned posterior end and there bifurcates into a parietal and a temporal branch, which just pass the anterior limit of the occipital lobe. The entire distribution of the parieto-temporal arteries is to the temporal pole and to the superior, middle and part of the inferior temporal gyri; to the major parts of the supramarginal, angular and post-parietal gyri, and to a very small portion of the superior and lateral occipital gyri.

The posterior cerebral artery (*a. cerebri posterior*), a terminal branch of the basilar, lies in the posterior boundary of the arterial circle and is joined to the internal carotid by the posterior communicating artery (Figs. 10 and 12). It winds backward between the midbrain and gyrus hippocampi to the tentorial surface of the cerebral hemisphere where, just beyond the splenium of the corpus callosum, it terminates in the calcarine and occipitoparietal branches. From the posterior cerebral arteries originate the postero-median and the postero-lateral ganglionic, and two or more **posterior chorioidal arteries** and **three cortical branches**: (1) *The temporal* branches, often an anterior, middle and posterior temporal, which supply the hippocampal and the fusiform gyri and a part of the lingual and of the inferior temporal gyrus.

(2) *The calcarine artery*, which runs along the fissure of the same name and supplies the cuneate and lingual gyri; also the pole and the lateral and superior gyri of the occipital lobe. (3) *The occipito-parietal artery*, a single branch, which runs along the sulcus occipito-parietalis over the supero-medial border to the convex surface of the cerebral hemisphere and is distributed to the cuneus, the præcuneus and the superior occipital gyrus.

The posterior chorioidal arteries (*arteriæ chorioideæ posteriores*, Figs. 7, 9 and 10) two or more in number are branches of

the posterior cerebral which run forward in the transverse and chorioidal fissures of the cerebrum to the chorioid plexuses of the lateral and third ventricles (Fig. 7).

The anterior chorioidal arteries (*a. chorioidea anterior*) rises from the internal carotid artery just proximal to its anterior and middle cerebral branches, and runs backward and outward along the optic tract to the anterior inferior end of the chorioidal fissure, which it enters (Fig. 10). It terminates in the chorioid plexus of the inferior horn of the lateral ventricle, and gives collateral branches to the optic tract, the gyrus hippocampi, the fascia dentata, the hippocampus, the crus of the fornix and the posterior part of the internal capsule.

A2. The Ganglionic System of Arteries.—Small arteries from the arterial circle and from the cerebral arteries near the circle constitute this system (Fig. 10). The arteries pass to their distribution without communicating with one another or with the cortical arteries. They are the *end-arteries* of Cohnheim. Between the cortical and ganglionic systems, there is an area poorly supplied with blood. That is the area of cerebral softening in old age. The ganglionic system of arteries is made up of six groups of small vessels: The antero-median, the right and left antero lateral, the postero-median and the right and left postero-lateral.

The antero-median ganglionic arteries rise from the anterior cerebrals in front of the optic chiasma (Fig. 10). They supply the chiasma, the lamina terminalis, the rostrum of the corpus callosum, the septum pellucidum and the head of the caudate nucleus.

The antero-lateral ganglionic arteries take their origin, on either side, from the middle cerebral artery, a little outside the arterial circle (Fig. 10). They pierce the anterior perforated substance and are distributed to the striated body, internal capsule and thalamus. The largest one of this group is the *lenticulo-striate artery*. It supplies the greater part of the corpus striatum. On account of its frequent rupture, it is called the *artery of cerebral hemorrhage* (Charcot).

Postero-median Ganglionic Arteries.—These are branches

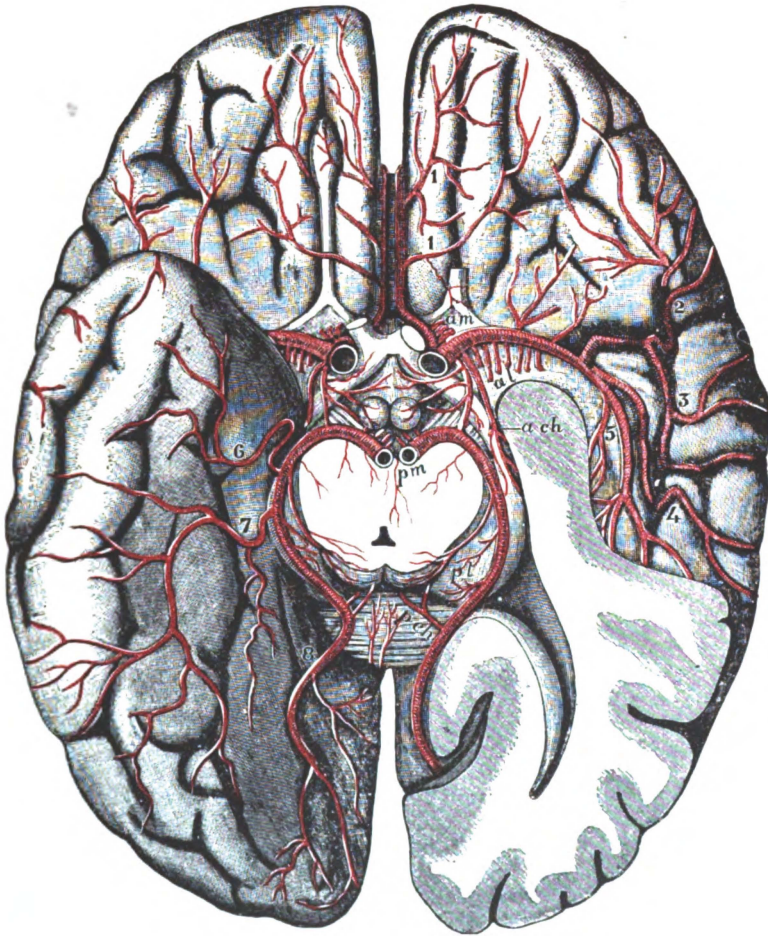


Fig. 10.—Arterial circle and its branches on the base of the cerebrum.
(Gordinier after Duret.)

On the left side of the brain the temporal lobe is cut away so as to open the inferior and posterior horns of the lateral ventricle. The mid-brain is divided close above the pons and the posterior cerebral arteries are cut at their origin from the basilar.

Ganglionic arteries: *am*. Antero-median group arising from the anterior cerebral. *al*. Antero-lateral group, from the middle cerebral. *pm, pl* (on the optic thalamus). Postero-median and postero-lateral groups, from the posterior cerebral.

Chorioidal arteries: *a ch*. Anterior, from the internal carotid. *p ch* (on the splenium). Posterior, from the posterior cerebral.

Cortical arteries: 1, 1. Inferior internal frontal, from the anterior cerebral. 2. Inferior external frontal. 3. Ascending frontal. 4. Ascending parietal, and 5, temporo-parietal from the middle cerebral. 6. Anterior temporal, 7, posterior temporal, and 8, occipital, from the posterior cerebral.

of the posterior cerebral and posterior communicating arteries (Figs. 9 and 10). They supply the interpeduncular structures, the peduncles and, after piercing the posterior perforated substance, the walls of the third ventricle and the medial parts of the thalami.

Postero-lateral Ganglionic Arteries.—They rise, on either side, from the posterior cerebral artery after it has wound around the base of the peduncle (Fig. 10). They are distributed to the posterior part of the thalamus; the geniculate, quadrigeminal and pineal bodies; the quadrigeminal brachia and the pedunculus cerebri. The superior cerebellar arteries send several branches to the dorsum of the mid-brain, and complete the arterial supply of the cerebrum.

VEINS OF THE CEREBRUM.

The Internal Veins of the Cerebrum.—The veins of the cerebrum (*venæ cerebri*) are classed as *internal* and *external*. The trunks of the internal veins are located largely in the chorioid tela of the third ventricle, near the apex of which the internal cerebral vein is formed: while at the base of this chorioid tela the internal cerebral vein unites with its mate in forming the great cerebral vein.

The internal cerebral vein (*v. cerebri interna*) is formed by the union of the chorioidal, the terminal and the vein of the septum pellucidum. It runs backward between the layers of the chorioid tela of the third ventricle (Fig. 7), receiving several small collaterals from the tela, from the pineal and quadrigeminal bodies and the corpus callosum; and, finally, it receives the basilar vein from the inferior surface of the cerebral hemisphere. Under the splenium of the corpus callosum it joins the internal cerebral vein of the opposite side and forms the great cerebral vein.

The great cerebral vein (*v. cerebri magna*, Galeni) is a short, thick, median trunk, a half-inch long (Fig. 1). At the posterior border of the tentorial notch it is joined by the inferior sagittal sinus and then continued as the sinus rectus. This short vein receives collateral tributaries from the gyrus cinguli, from the

medial and tentorial surfaces of the occipital lobe and from the superior surface of the cerebellum (Cunningham).

Small *nameless internal veins* issue from all parts of the exterior surface of the cerebrum and form the external veins.

The External Veins of the Cerebrum.—The external cerebral veins (*venæ cerebri externæ*) are numerous and of large size. They ramify in the pia mater and in the subarachnoid space. They empty into the dural sinuses, as a rule, against the current in the sinuses, and they form two principal groups: The superior

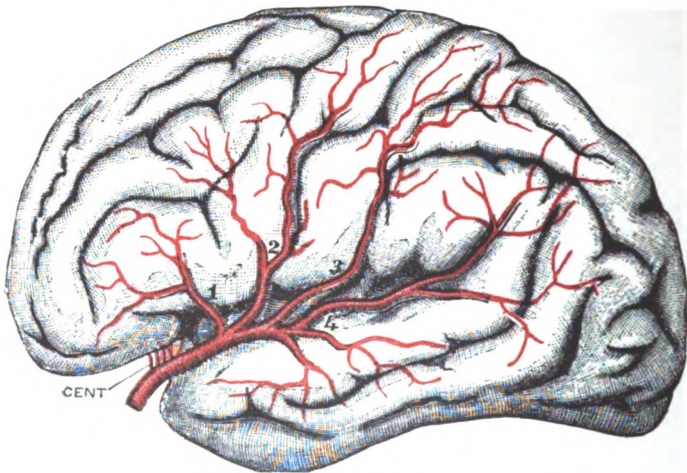


Fig. 11.—Middle cerebral artery and branches. (*Gordinier after Quain and Charcot.*)

CENT. Antero-lateral group of ganglionic arteries. 1. Inferior external frontal artery. 2. Ascending frontal artery. 3. Ascending parietal artery. 4. Parieto-temporal artery.

cerebral and the inferior cerebral, and a very small group, on the medial cerebral surface, called the medial cerebral veins.

The superior cerebral veins (*venæ cerebri superiores*), twelve or more in number, carry away the blood from the superior surface of the hemisphere. They run obliquely upward and forward into the superior sagittal sinus. Just before emptying into the sinus they receive most of the medial veins.

The Medial Cerebral Veins. (*Venæ cerebri mediales*).—They drain the marginal part of the medial surface of the hemisphere.

The veins of this group which do not empty into the superior cerebral veins unite and form the inferior sagittal sinus, and the anterior cerebral vein which drains much of the medial surface.

The inferior cerebral veins (*venæ cerebri inferiores*) drain the base of the cerebrum and the lower border of its convex surface. On the tentorial surface of the hemisphere, from three to five of these veins empty into the transverse and superior petrosal sinuses. Those from the temporal and frontal lobes empty into the sphenoparietal sinus and cavernous sinus, excepting the small anterior cerebral vein and the deep middle cerebral vein, which unite with the inferior striate veins in forming the basilar vein. The *anterior cerebral vein* accompanies the artery of the same name. It drains the gyrus cinguli and corpus callosum, chiefly; and, in the fossa lateralis cerebri, unites with vessels that descend from the corpus striatum, the *inferior striate veins*, and with the deep middle cerebral vein. The *deep vena cerebri media* drains the insula and the opercula, in part, and deep in the fissure runs medianward to the fossa lateralis cerebri and helps to form the basilar. The **basilar vein** (*v. basilaris*), is formed at the anterior perforated spot by the deep middle cerebral, the inferior striate and the anterior cerebral veins. Running backward it receives additional blood from the interpeduncular structures, the hippocampal gyrus and the inferior horn of the lateral ventricle, and from the mid-brain, as it winds around it to empty into the corresponding internal cerebral vein near its termination. In the fissura lateralis cerebri (Sylvii) runs also a superficial vein, called the *superficial middle cerebral (v. cerebri media)* which receives tributaries from the surfaces adjacent to the posterior ramus and the stem of that fissure and empties into the cavernous sinus; but it may have two other outlets, viz., the transverse sinus and the superior sagittal sinus. The connection occasionally established between the superficial middle cerebral vein and the transverse sinus is called the *posterior anastomotic vein*; while the *great anastomotic vein* (of Trolard) is produced when it joins one of the superior cerebral veins. The great anastomotic vein connects the superior sagittal with the cavernous sinus.

There are no lymphatic vessels in either the brain or spinal

cord; perivascular lymph spaces carry the fluid from the interior to the subarachnoid spaces.

B. THE CIRCULATION OF THE RHOMBENCEPHALON.

B1. The medulla oblongata is supplied with blood by the following branches of the vertebral artery: The posterior and the anterior spinal, the posterior inferior cerebellar and several short bulbar arteries (Fig. 9). The *posterior inferior cerebellar* (*a. cerebelli inferior posterior*) winds from before backward around the medulla, runs between the vagus and accessory nerves, enters the vallecule cerebelli and gives branches to the medulla and to the chorioid tela of the fourth ventricle. The *anterior spinal artery* (*a. spinalis anterior*) formed by the y-like union of a branch from each vertebral artery, descends along the anterior median fissure; and the *posterior spinal artery* (*a. spinalis posterior*) of either side, rising from the vertebral near the lower end of the medulla, descends in front of the posterior lateral sulcus. Both distribute branches along their course. The branches for the most part enter the median raphe or follow the roots of the bulbar nerves, suggesting the centrifugal and centripetal arteries of the spinal cord (Fig. 13). **The veins** pursue much the same course as the arteries. The *anterior median vein* joins the ventral veins of the pons and is drained into the cerebellar veins or directly into the superior petrosal sinus. The *posterior median vein* bifurcates y-like at the middle of the medulla and the two branches wind around the medulla to its anterior surface and empty into the inferior petrosal sinus or the basilar plexus. Issuing from the medulla with the roots of the ninth to the twelfth cerebral nerves are three or four small veins, the *radicular veins*, which run into the occipital and inferior petrosal sinuses (Cunningham). Both arteries and veins possess *perivascular lymph spaces*, but there are in the medulla no lymphatic vessels.

B2. The pons Varolii is supplied by the pontal, the superior cerebellar and the posterior cerebral branches of the basilar artery (Fig. 9). The short and transverse branches of the basilar artery, the *pontal arteries* (*aa. pontales*), furnish the greater portion of blood to the basilar area of the pons, while the superior cere-

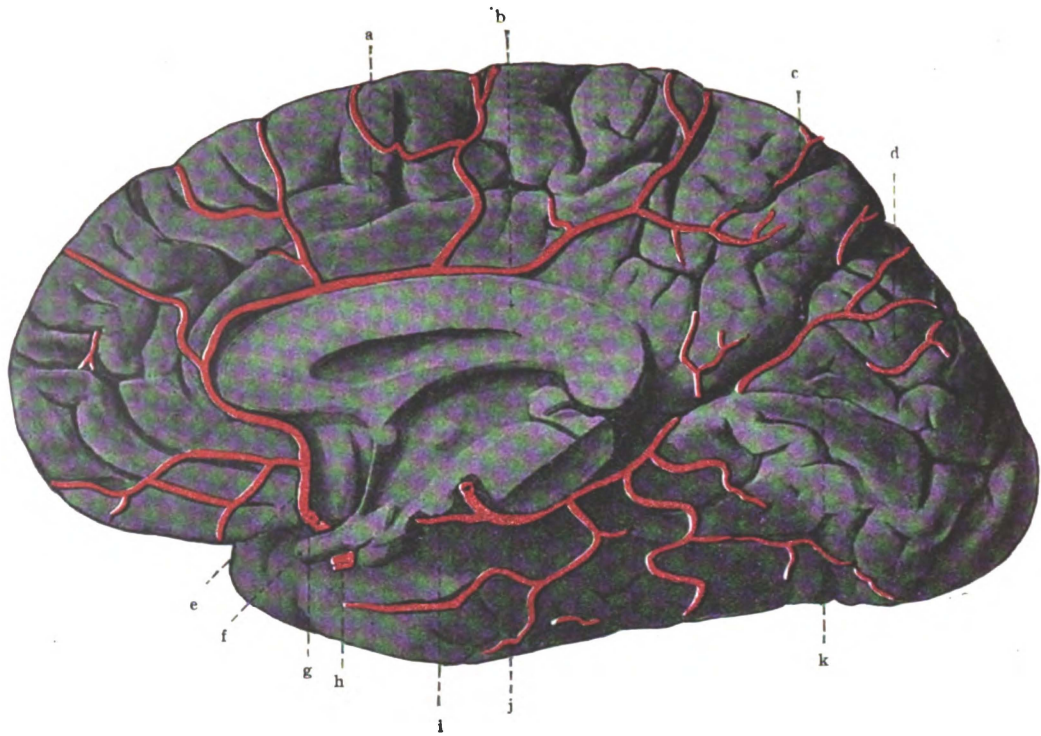


Fig. 12.—Anterior and posterior cerebral arteries. (After *Spalteholz*.)

- a. Sulcus cinguli. b. Corpus callosum. c. Fissura parieto-occipitalis. d. Cuneus. e. A. Cerebri anterior. f. N. Opticus. g. A. Communicans anterior. h. A. Carotis interna. i. A. Communicans posterior. j. A. Cerebri posterior. k. Fissura calcarina.

bellar artery supplies the superior medullary velum and the brachia conjunctiva cerebelli. The branches enter the median raphe, also the substance of the pons elsewhere, especially along the nerve roots, and run at right angles to the surface into it. The *deep veins* of the pons run forward and form a plexus on its surface which, according to Cunningham, is drained by a *superior efferent* into the basilar vein and by an *inferior efferent* into the cerebellar veins or the superior petrosal sinus. There are no

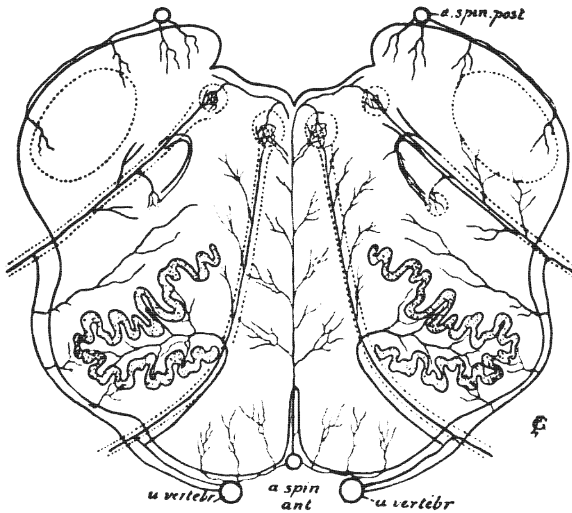


Fig. 13.—Arteries of the medulla oblongata. (Modified from Gordinier after Duret.)

a. spin. post. Posterior spinal artery. *a. vertebr.* Vertebral artery. *a. spin. ant.* Anterior spinal artery.

lymphatic vessels in the pons; but, as elsewhere in the central nervous system, there are lymph spaces about the blood-vessels.

B3. The blood supply of the cerebellum is furnished by three pairs of arteries (Fig. 9). The *superior cerebellar*, from the basilar, supplies all the superior surface except a narrow zone at the posterior border; the *anterior inferior cerebellar*, also from the basilar, and the *posterior inferior cerebellar*, from the vertebral, supply the inferior surface and the posterior part of the superior surface.

The Superior Cerebellar Artery. (*A. cerebelli superior*).—Rising from the basilar just behind the posterior cerebral, from

which it is separated by the oculomotor nerve, it winds dorsally around the mid-brain to the sulcus lateralis, where it bifurcates into a medial and a lateral branch (Fig. 9). The *medial branch* continues along the trochlear nerve in the groove between the cerebellum and the mid-brain almost to the median line; and then, bending backward, runs along the superior worm of the cerebellum to its posterior extremity. It distributes branches to the geniculate bodies, corpora quadrigemina, tela chorioidea

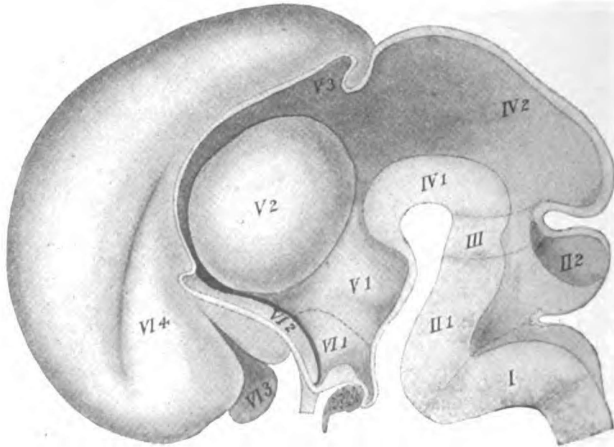


Fig. 14.—Median section of embryonic brain of the third month.
(McMurrich after His.)

I. Myelencephalon. II. Metencephalon: 1, Pons, 2, Cerebellum. III. Isthmus rhombencephali. IV. Mesencephalon: 1, Pedunculi, 2, Corpora quadrigemina. V. Diacephalon: 1, Pars mammillaris hypothalami, 2, Thalamus, 3, Epithalamus. VI. Telencephalon: 1, Pars optica hypothalami, 2, Corpus striatum, 3, Rhinencephalon, 4, Neopallium.

ventriculi tertii and posterior surface of the pons, besides the vermis superior cerebelli and the medial part of the superior surface of the hemisphere. The *lateral branch* of the superior cerebellar artery passes from its point of origin near the sulcus lateralis of the mid-brain onto the superior surface of the cerebellum. It runs backward a half-inch from the border of that surface, giving off collaterals along its course. The lateral branch, together with the medial, supplies the superior cerebellar surface almost as far back as the horizontal sulcus of the cerebellum, along which the superior cerebellar artery anastomoses with both the inferior cerebellar arteries.

The anterior inferior cerebellar artery (*a. cerebelli anterior inferior*, Fig. 9) is given off by the basilar near the junction of its inferior and middle thirds. (Sometimes it is replaced by two or three small vessels.) It runs lateralward, behind the flocculus, keeping close to the anterior border of the hemisphere. In its course it passes anterior to the abducent nerve and posterior to the facial and auditory nerves. It supplies the anterior part of the under surface and border of the cerebellar hemisphere.

The posterior inferior cerebellar artery (*a. cerebelli inferior posterior*, Fig. 9) is the largest branch of the vertebral and is given off just before the vertebral arteries unite and form the basilar. Passing first between the root-bundles of the hypoglossal nerve and then between those of the accessory and vagus nerves, the posterior inferior cerebellar artery bends at a right angle backward and runs between the medulla and the cerebellar hemisphere, where it divides into a medial and a lateral branch. The *medial branch* follows the sulcus valleculæ and gives branches to the medial part of the hemisphere and the vermis inferior. It anastomoses with its fellow of the opposite side. The *lateral branch*, runs lateralward from the posterior cerebellar notch over the inferior surface of the hemisphere; its terminal branches wind around the postero-lateral border and communicate with the superior cerebellar artery on the upper surface of the hemisphere. The undivided trunk of the posterior inferior cerebellar artery gives small branches to the medulla oblongata and supplies the chorioid tela of the fourth ventricle.

The internal cerebellar veins bring the blood from the interior of the organ and pour it into the superior and inferior external veins.

The superior external cerebellar veins (*venæ cerebelli superiores*) converge forward into a medial vein, which empties into the great cerebral vein, and several lateral veins, which end in the transverse or the superior petrosal sinus.

The inferior external cerebellar veins (*venæ cerebelli inferiores*) also form one small *medial vein*, which runs backward and upward either into the straight or transverse sinus, and a number of *lateral veins*. The lateral inferior cerebellar veins terminate in the inferior petrosal and in the occipital sinus.

Lymphatics.—There are no lymphatic vessels in the cerebellum, but the perivascular lymph spaces carry out the lymph and pour it chiefly into the subarachnoid space.

TABLE I.
EMBRYOLOGIC DIVISIONS OF THE BRAIN.

In accordance with its development the *brain* or *encephalon* is naturally divided into three embryologic divisions which comprise the derivatives of the anterior, the middle and the posterior brain-vessels (Fig. 14).

Cerebrum	I. Fore-Brain, or Prosencephalon (Ant. vesicle)	1. End-brain, or Telencephalon	Cerebral Hemispheres
			Corpus Callosum
			Fornix
			Anterior Commissure
	2. Inter-brain, or Diencephalon	Septum Pellucidum	
		Lamina Terminalis	
II. Mid-Brain, or Mesencephalon (Middle vesicle)	1. Pedunculi Cerebri	Tuber Cinereum	
		Optic Chiasma (grows into it)	
	2. Lamina Quadrigenina	Lateral Ventricles	
		Foramina interventricularia	
		Aula of third Ventricle.	
		Thalami	
		Corpora Mammillaria	
		Corpus Pineale	
		Corpora Geniculata	
		Third Ventricle, excepting the aula.	
		Bases Pedunculi	
		Substantia Nigra	
		Tegmenta	
		Cerebral Aqueduct (of Sylvius)	
		Corpora Quadrigenina.	
		Brachia.	

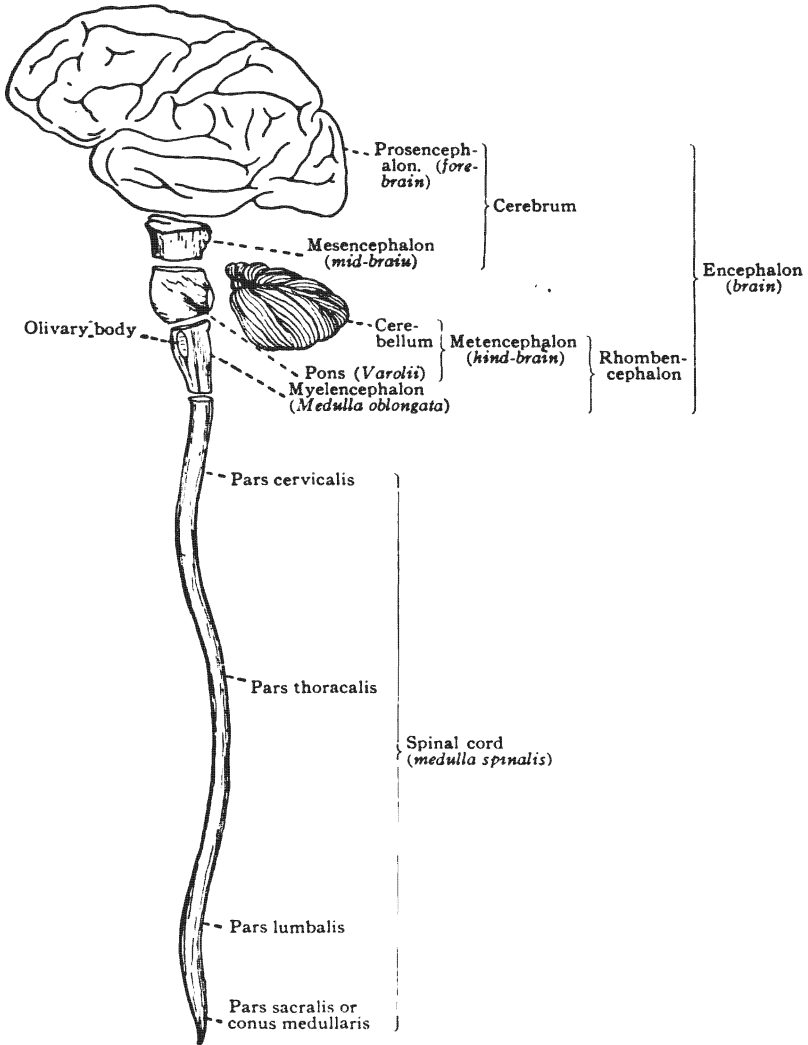


Fig. 15.—Divisions of the brain. Diagrammatic. (After *Morris's Anatomy*.)

III. Rhombencephalon (Post. vesicle)	}	1. Metencephalon (Hind-brain)	{	Isthmus Rhombencephali Cerebellum, Pons Upper half of Fourth Ven- tricle
		2. Myelencephalon (After-brain)	{	Medulla Oblongata Lower half of Fourth Ven- tricle

The **cerebrum** embraces the *fore-brain* and the *mid-brain*, as shown by the table. So we may make a more comprehensive division of the brain into only two grand divisions: The *great brain* or *cerebrum* and the *rhombencephalon* (Fig. 15). We may now simplify the above table as follows:

- I. Cerebrum, embracing—
 - End-brain, or Cerebral Hemispheres, etc.
 - Inter-brain
 - Mid-brain.
- II. Rhombencephalon, comprising—
 - Isthmus
 - Cerebellum
 - Pons
 - Medulla Oblongata.

CHAPTER II.

GENERAL CONSIDERATIONS OF THE BRAIN OR ENCEPHALON.

Before taking up the special study of the cerebrum the student should notice certain prominent features of the entire brain. To do this the arachnoid and pia mater must be removed, and great care and patience should be exercised to preserve the integrity of the brain substance and to guard against evulsion of the roots of the cerebral nerves.

The human brain forms the greatly expanded superior extremity of the cerebro-spinal axis. It is derived from three sack-like dilatations of the epiblastic neural tube, called the **anterior, the middle and the posterior brain-vesicles** (Fig. 16).

Cavities.—The cavities of these brain-vesicles constitute the adult ventricles, which form a continuous median series extending from the canal of the spinal cord up to the level of the cerebral hemispheres; at that level the central cavity bifurcates into a branch for each hemisphere of the cerebrum (Figs. 17 and 18). Thus is formed the *lateral ventricle* in the cerebral hemisphere and, below the cerebral hemispheres, the median series of cavities comprises the *third ventricle* in the inter-brain, the *cerebral aqueduct* in the mid-brain, and the *fourth ventricle* in the hind-brain and after-brain. The walls of these simple embryonic cavities undergo wonderful development and specialization; ultimately they produce all the multifiform and complicated structures of the adult human brain.

Superior View.—The superior surface of the brain is markedly convex (Figs. 19 and 22). It is elliptical in outline, the major axis being contained in the median line; the greatest transverse axis is situated a little behind the middle and runs between the points which, when the brain is in the skull, underlie the tubera parietalia. This surface is closely adapted to the interior of the

calvaria. Only the great convoluted hemispheres of the cerebrum are visible from the superior view-point. The two hemispheres are separated by a deep, median cleft, called the **longitudinal fissure of the cerebrum** (*fissura longitudinalis cerebri*) from which the falx cerebri has been removed.

Posterior View.—When the brain is viewed from behind, three great structures and two transverse fissures are visible (Fig. 20):

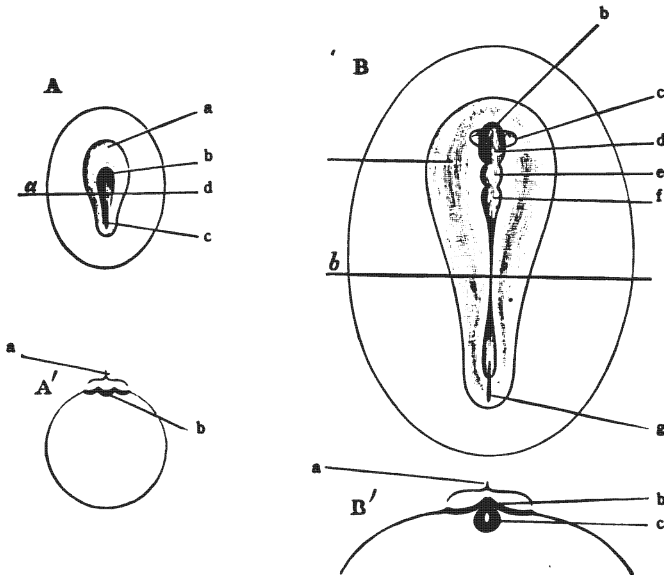


Fig. 16.—Diagrams of surface views and sections of germinal areas showing the development of the primitive streak, neural groove, neural tube and brain vesicles. (After *Morris's Anatomy*.)

A. Earlier stage. a. Germinal area. b. Neural groove. c. Primitive streak. B. Later stage. a. Germinal area. b. Fore-brain (rudiment of cerebral hemispheres). c. Optic vesicle. d. First cerebral vesicle. e. Second cerebral vesicle. f. Third cerebral vesicle. g. Primitive streak. A'. Section through area A along the line a. a. Germinal area. b. Neural groove. B'. Section through area B along line b. a. Germinal area. b. Neural crest. c. Neural tube.

First, the occipital end of the **cerebral hemispheres** with their irregular gyri and sulci; *second*, the transversely laminated **cerebellum**, lying below the cerebrum and separated from it by the **transverse fissure of the cerebrum** (*fissura transversa cerebri*); and *third*, the inferior extremity of a relatively small median structure, the **medulla oblongata**. The cerebellum is especially

characterized by its parallel crescentic sulci, which give it a stratified appearance. It shows a partial subdivision into lateral hemispheres produced by a posterior median depression, called the *posterior cerebellar notch*, and by a longitudinal groove on its inferior surface, called the *vallecula cerebelli*. The vallecula is fitted over the posterior surface of the medulla. The cerebellum is, therefore, separated from the medulla oblongata by a sharply

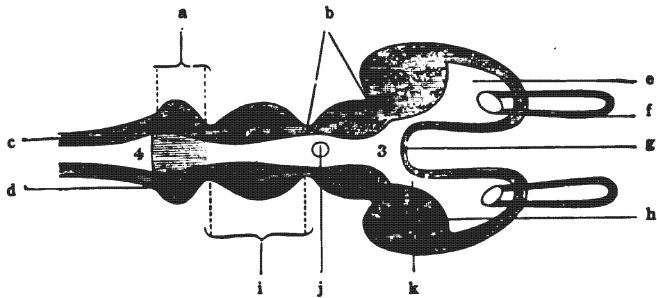


Fig. 17.—Diagrammatic horizontal section of vertebrate brain.
(*Morris's Anatomy after Huxley.*)

a. Metencephalon. b. Thalamus. c. Medulla oblongata. d. Cerebellum. e. Lateral ventricle. f. Olfactory diverticulum. g. Lamina terminalis. h. Corpus striatum. i. Mid-brain. j. Pineal body. k. Interventricular foramen.

curved, rainbow-shaped fissure. That fissure is the **transverse fissure of the cerebellum** (*fissura transversa cerebelli*) which, as already pointed out, is bridged over by the arachnoid and contains the cisterna cerebello-medullaris.

Inferior View.—The base of the brain presents three areas, situated in three successive levels, which correspond in location and extent to the great fossæ in the base of the cranium (Figs. 21 and 27). The *anterior area*, situated in the anterior cranial fossa, occupies the highest level; the *middle area* is intermediate in position; it occupies the middle fossa and together with the anterior area comprises all of the base of the cerebrum which is visible in the complete brain; and, the *posterior area*, which is but the base of the rhombencephalon, is situated at the lowest level in the posterior fossa of the cranium.

The **anterior area** of the base of the brain is divided into lateral halves by the longitudinal fissure of the cerebrum, and

separated from the middle area by the fossa and fissura lateralis cerebri. The **frontal lobe** of the cerebral hemisphere, on either side of the longitudinal fissure, makes up nearly all this area. The inferior surface of the frontal lobe is concave and is adapted to the convex orbital plate of the frontal bone; its medial border is most prominent and presents, near the longitudinal fissure, an elongated gray mass, the **olfactory bulb** (if it has not been torn

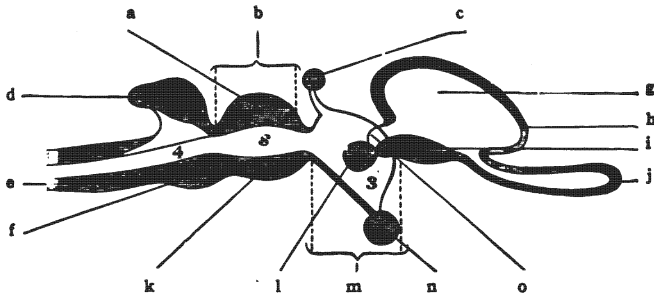


Fig. 18.—Diagrammatic sagittal section of vertebrate brain.
(Morris's Anatomy after Huxley.)

a. Corpora quadrigemina. b. Mid-brain. c. Pineal body. d. Cerebellum (hind-brain). e. Medulla oblongata (after-brain). f. Pons Varolii (hind-brain). g. Lateral ventricle. h. Cerebral hemisphere. i. Corpus striatum. j. Olfactory diverticulum. k. Pedunculi cerebri. l. Thalamus. m. Inter-brain. n. Hypophysis. o. Interventricular foramen. 4. Fourth ventricle. s. Aqueduct of cerebrum. 3. Third ventricle.

off) and a white strand, the olfactory tract. Running backward from the bulb, parallel with the longitudinal fissure of the cerebrum to the fossa lateralis cerebri, the olfactory tract is seen to bifurcate into two distinct striæ, a medial and a lateral.

The **middle area** of the inferior surface of the brain is prominent laterally where it is formed by the **temporal lobes** of the cerebrum. It is depressed in its median portion and thus adapted to the hypophyseal region of the cranial floor. This **median hypophyseal region** extends from the end of the longitudinal fissure, in front, backward to a great white, transversely striated eminence, called the pons; it contains several important structures, viz., the bases pedunculi; posterior perforated substance; the mammillary bodies; tuber cinereum and stem of the infundibulum; optic chiasma, tracts and nerves; lamina cinerea terminalis; and the anterior perforated substance.

Issuing from the under surface of the cerebral hemisphere and

running downward toward the median line, there may be seen a white striated band, a half-inch broad, called the **basis pedunculi**, which, on approximating its fellow in the median plane disappears into the pons. Anteriorly, the X-like **optic chiasma** (*chiasma opticum*) is easily identified near the longitudinal fissure; its anterior limbs are the **optic nerves** and its posterior, the **optic tracts** (Fig. 21). The optic tract, when traced backward and outward, under the overhanging temporal lobe, is observed to cross the basis pedunculi at its point of emergence from the cerebral hemisphere. Thus the optic tract and the basis pedunculi form the lateral boundary of a diamond-shaped space extending from the optic chiasma, in front, backward to the pons. This is commonly called the **interpeduncular space**. You observe in it three structures: (1) A gray eminence just behind the optic chiasma called the *tuber cinereum*; (2) a pair of white, nipple-like bodies, an eighth of an inch in diameter, known as the *white* or *mammillary bodies* (*corpora mammillaria*), and (3) a triangular, perforated mass of dark gray substance, called the *posterior perforated substance* (*substantia perforata posterior*). In the normal condition, the *infundibulum* projects downward and forward from the center of the tuber cinereum and connects it with the *hypophysis cerebri*; but it is usually broken in removing the brain and the hypophysis left behind in the hypophyseal fossa.

If the optic chiasma be drawn slightly downward and backward, a transverse and nearly vertical sheet of gray matter will be seen extending upward from it, between the cerebral hemispheres, toward the corpus callosum. That is the **lamina cinerea terminalis**. It bounds posteriorly the frontal part of the longitudinal fissure of the cerebrum. Lateral to the optic chiasma and anterior to the optic tract, the gray substance is perforated by many vessels; it is called the **anterior perforated substance** (*substantia perforata anterior*) to distinguish it from a similar posterior region located between the bases pedunculi.

Posterior Area.—The posterior area of the base of the brain is formed by the *pons*, the *cerebellum*, and the *medulla oblongata*, which constitute the **rhombencephalon** (Fig. 21). The **pons** and **medulla** are median structures. They are separated by a

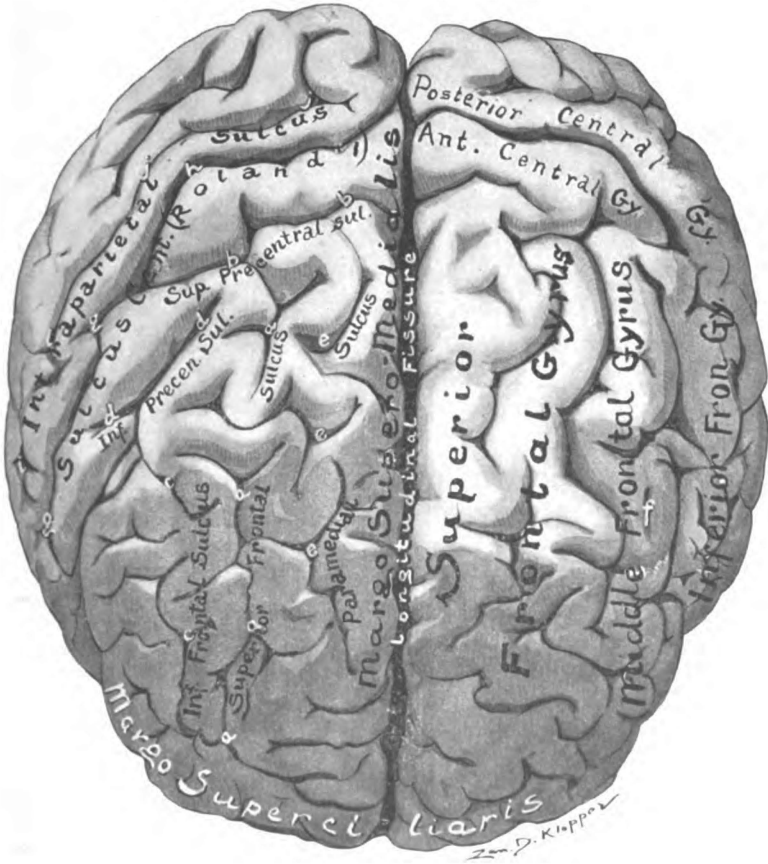


Fig. 19.—Fronto-superior surface of cerebrum. (Original.)

well marked transverse groove containing the roots of the sixth, the seventh, the intermediate and the eighth cerebral nerves. The transverse strands of the pons traced lateralward are observed to form a large round bundle, called the *brachium pontis*, which extends into the *hemisphere of the cerebellum* on either side. Between those pontine strands, at the lateral border of the pons, there should be noticed the roots of the great *trigeminal nerve*. A sagittal line through this nerve at its attachment to the pons may be regarded as the boundary between the pons and the cerebellar hemisphere. The hemispheres of the cerebellum form the lateral part of the posterior area; their stratified appearance is already familiar. Inferior to the pons is the medulla oblongata. The medulla is about an inch long and three-quarters of an inch broad near the pons, but measures less than one-half inch in width at the lower end. It is partially divided into lateral halves by the *anterior median fissure*, which is deep, above, but is almost obliterated in the lower half of the medulla by the crossing of the lateral pyramidal tracts, the *decussatio pyramidum*. On either side of the anterior median fissure, the student should notice, in this order, the *pyramid*, the *olive*, and the *restiform body*. The *pyramid* (*pyramis*) bounds the anterior median fissure. It is an eighth of an inch in width, is most prominent near the pons and tapers off inferiorly because about 80 per cent. of its fibers cross over to the opposite side and sink backward in the medulla. It is bounded laterally by a slight longitudinal furrow, the *anterior lateral sulcus* (*sulcus lateralis anterior*) which contains the roots of the twelfth cerebral nerve, and separates the pyramid from the olive and from a flat surface, called the lateral funiculus of the medulla. The *olive* (*oliva*) occupies the upper half of the lateral surface of the medulla; the lateral funiculus, the lower half. The olive is equal in breadth to the pyramid. It is quite prominent, is white in color and is elliptical in outline. The *posterior lateral sulcus* (*sulcus lateralis posterior*) separates it from the restiform body. The roots of the ninth, tenth and eleventh cerebral nerves, which are contained in that groove and the restiform body which lies beyond it, can be seen only by pressing aside the hemisphere of the cerebellum.

The Roots of the Twelve Cerebral Nerves (Fig. 21).—The cerebral nerves (*nervi cerebrales*) are numbered from before backward according to the order of their *points of attachment* to the brain surface. Those points of attachment are, for the motor roots, *points of exit* from the brain (apparent origins); and are *points of entrance* into the brain (apparent central terminations), for all the sensory roots. The **genetic nucleus** (*nucleus originis*), which is the real origin of each motor root, and the **terminal nucleus** (*nucleus terminalis*), which contains the real central termination of every sensory root, are imbedded within the brain substance and do not at present concern us.

1. **The olfactory nerves** (*nervi olfactorii*) are the first. They are the nerves of smell. They are composed of twenty or thirty scattered bundles of non-medullated fibers which *rise* from the olfactory cells in the nasal mucous membrane and, passing through the cribriform plate of the ethmoid bone, enter the under surface of the olfactory bulb. The surface of the bulb is, therefore, their *apparent central termination*. The fibers proceed some distance into the gray substance of the olfactory bulb, which constitutes the *terminal nucleus* of the first nerves, and there branch richly and end in relation with the mitral and bush-cells (real central termination).

2. **Optic Nerve.** (*Nervus opticus*).—The second nerve, the nerve of sight, is really a brain tract rather than a nerve, and its fibers are imbedded in neuroglia. It *rises* in the ganglionic layer of the retina. Passing through the chorioid and sclera of the eyeball and the optic foramen of the sphenoid bone, it enters into the optic chiasma where the “nerve” is said to end; but the fibers of the nerve continue without interruption through the optic tracts and their lateral roots to the inter-brain and the mid-brain, whose surfaces they pierce (*apparent central termination*); they end (real central termination) in the lateral geniculate body, in the pulvinar of the thalamus, and in the superior colliculus of the quadrigeminal bodies.

3. **The oculomotor nerve** (*n. oculomotorius*) is the great motor nerve to the eye (Fig. 21). It issues from the mid-brain at the medial border of the basis pedunculi, which is its *apparent origin*,

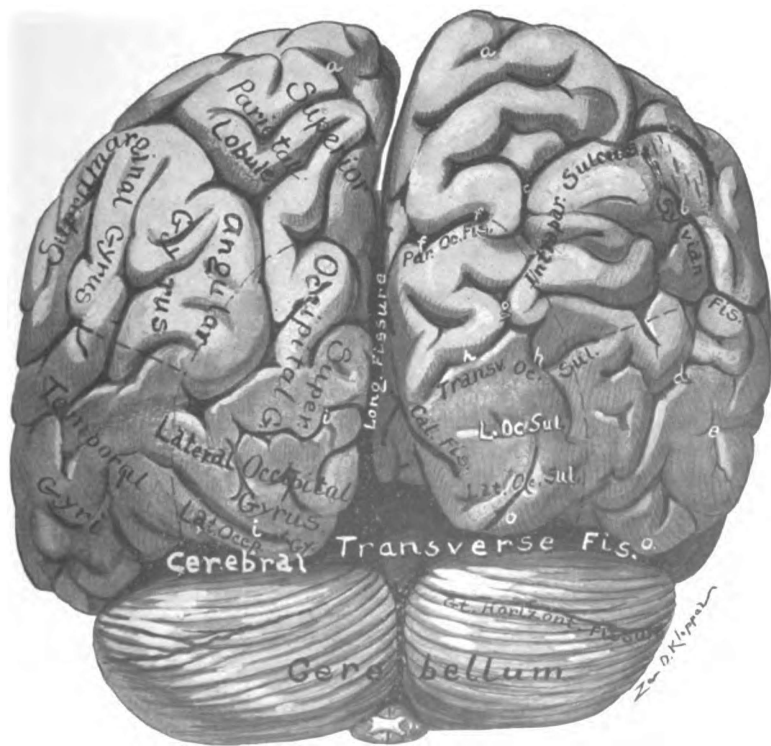


Fig. 20.—Posterior view of the brain. (Original.)

but its real origin is in a mass of gray substance, the genetic nucleus (*n. originis*), situated within the depths of the mid-brain.

4. Trochlear Nerve. (*N. trochlearis*).—The fourth is a motor nerve to the eye and is the smallest of the cerebral nerves. It may be seen winding forward over the basis pedunculi (Fig. 21). Its *apparent origin* is from the dorsal surface of the brain stem at the junction of the mid-brain with the hind-brain (the isthmus, Fig. 44); this apparent origin cannot be seen in the complete brain. The genetic nucleus of the fourth nerve is located below that of the third in the mid-brain.

5. Trigeminal Nerve. (*N. trigeminus*).—The trigeminal nerve is a mixed nerve, motor and sensory (Fig. 21). It is attached to the ventral surface of the pons a little above the middle of its lateral border. The small anterior **motor root** emerges from this point (*apparent origin*); but this is the *apparent central termination* of the large sensory root, which *rises* in the semilunar ganglion (*Gasseri*) and enters the pons close to the emergence of the motor root.

6. The abducent nerve (*n. abducens*) is a motor nerve to the eye. It *issues* from the pons at its inferior border, or from the transverse groove between the pons and the medulla, just above the pyramid of the medulla and nearly in line with the anterior lateral sulcus (Fig. 21).

In the transverse groove between the pons and the medulla, lateralward from the root of the sixth nerve, are the roots of the seventh, intermediate and eighth. The seventh is smaller in diameter than the eighth and medial to it in position; the intermediate is between these two (Figs. 21 and 45).

7. The facial nerve (*n. facialis*) is the motor nerve to the muscles of expression (Figs. 21 and 45). Rising from a nucleus in the pons, its emergence from the transverse groove between the medulla and pons constitutes its *apparent origin*. The **intermediate nerve** (*n. intermedius*) is so closely associated with the facial nerve that many regard it as the sensory root of that nerve; but the intermediate nerve is in reality a mixed nerve with efferent fibers of vasodilator, secretory and trophic functions and afferent fibers whose function is taste. The *efferent fibers* rise from the

salivary nucleus (the dorsal part of the facial nucleus) in the pons. They issue from the transverse ponto-medullary groove between the facial and auditory nerves (*apparent origin*) at the point where the afferent fibers enter the brain. The *sensory part* of the intermediate nerve, which is the nerve of taste to the anterior part of the tongue, takes its *origin* in the ganglion geniculi situated within the canalis facialis (Follopilii); its *apparent central termination* is in the ponto-medullary groove.

8. The acoustic nerve (*n. acusticus*) is a sensory nerve, having the double function of hearing and equilibrium (Figs. 21, 44 and 45). It *rises* from the spiral and vestibular ganglia situated in the petrous bone, and its *apparent central termination* is in the bottom of the transverse groove separating the pons from the medulla. The roots of both the seventh and eighth nerves are near the upper end of the posterior lateral sulcus of the medulla oblongata.

9. Glossopharyngeal Nerve. (*N. glosso-pharyngeus*).—This is a complex mixed nerve, containing *efferent fibers* (motor, vasodilator, secretory and trophic) and *afferent fibers*, which are both common sensory and gustatory. It is joined to the medulla in the bottom of the superior end of the posterior lateral sulcus (Figs. 21 and 45). This point of attachment is the *apparent origin* of its efferent and the *apparent central termination* of its afferent fibers. The latter fibers *rise* in the superior and petrosal glossopharyngeal ganglia situated in the jugular foramen. The genetic nucleus of the efferent fibers is located inside the medulla.

Behind the ninth nerve in the same groove are the roots of the tenth and eleventh nerves. The roots of the ninth and tenth are situated between the olive and the restiform body; but, if the nerve trunks have been cut, it is impossible to determine which of the ten or a dozen root bundles belong to each of them.

10. The Vagus Nerve. (*N. vagus*).—The *efferent fibers* of the vagus, like the glossopharyngeal, take their apparent origin from the posterior lateral sulcus, and in the same sulcus the *afferent fibers* enter the medulla, *apparent central termination* (Figs. 21 and 45). It is a very complex nerve. Its efferent fibers comprise motor, inhibito-motor, vasodilator, secretory, trophic and inhibito-

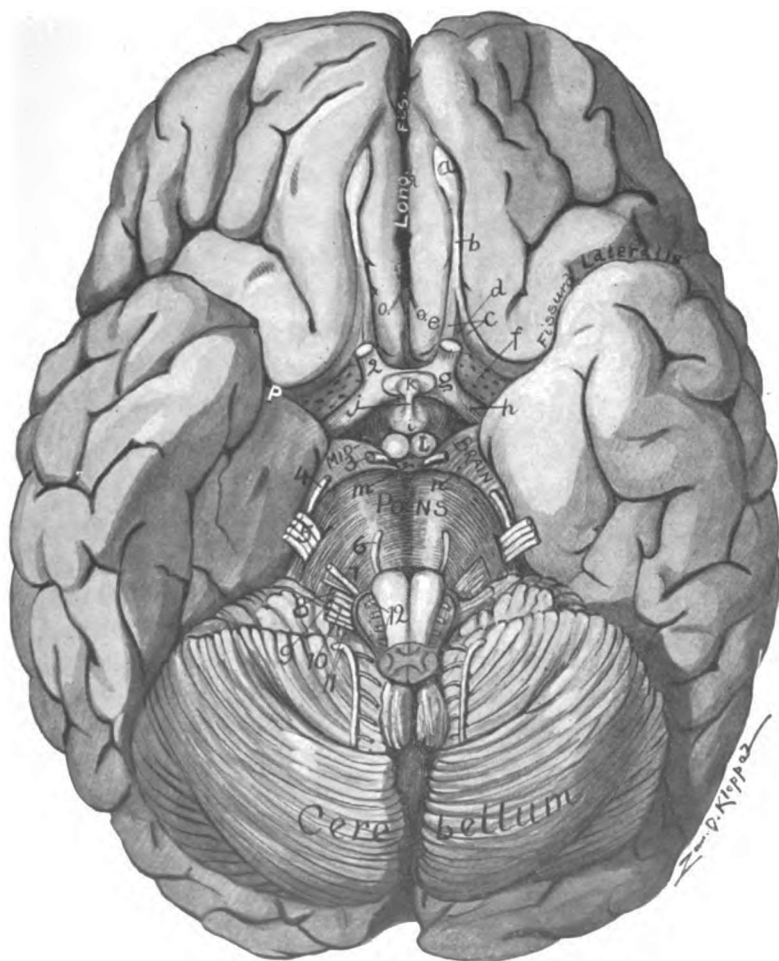


Fig. 21.—Base of brain. (Original.)

a. Olfactory bulb. b. Olfactory tract. c. Medial and lateral olfactory striæ. d. Trigonum olfactorium. e. Area parolfactoria (Brocæ). f. Anterior perforated substance. g. Optic chiasma. h. Optic tract. i. Tuber cinereum. j. Infundibulum. k. Hypophysis. l. Corpus mammillare. m. Posterior perforated substance. n. Basis pedunculi. o. Sulcus parolfactorius anterior. 2 to 12, the cerebral nerves.

secretory fibers (Pawlow). The afferent or sensory fibers of the vagus *rise* in the jugular and nodular ganglia of the nerve (*g. jugulare* and *g. nodosum*) within and just below the jugular foramen. Within the medulla are the genetic nuclei of the efferent fibers.

11. **The accessory nerve** (*n. accessorius*) is composed of a cerebral and a spinal root both of which are efferent in function (Fig. 45). The *cerebral root* (*radix cerebialis*) rises within the medulla and issues from the posterior lateral sulcus below the level of the olive and immediately inferior to the roots of the vagus (*apparent origin*). This is distributed entirely by way of the vagus. The *spinal root* (*radix spinalis*), having taken its *apparent origin* from the lateral surface of the spinal cord and passed through the foramen magnum, joins the cerebral (accessory) root near the jugular foramen.

12. **Hypoglossal Nerve.** (*N. hypoglossus*).—The twelfth is the great motor nerve to the tongue (Figs. 21 and 45). A half dozen or more radicals make it up; they rise in the medulla and issue in linear series from the anterior lateral sulcus of the medulla between the pyramid and the olive (*apparent origin*). The root bundles which emerge from the same sulcus below the level of the olive belong to the anterior root of the first cervical nerve.

The student should now turn back to Table I. Study it carefully and identify all the primary and secondary divisions of the brain (Figs. 14, 15, 16, 17, 18, and 28).

CHAPTER III.

THE CEREBRUM.

The cerebrum with its great hemispheres is that part of the brain which especially characterizes man. In man only do the hemispheres reach such predominant development. Though they are mere outgrowths of the anterior brain-vesicle in the beginning, they completely overshadow all other parts of the brain by the seventh month of embryonic life, extending farther forward, backward and lateralward than any other part. Within the cerebral hemispheres lies the physical basis of all mental function; they constitute the central mechanism of thought and consciousness.

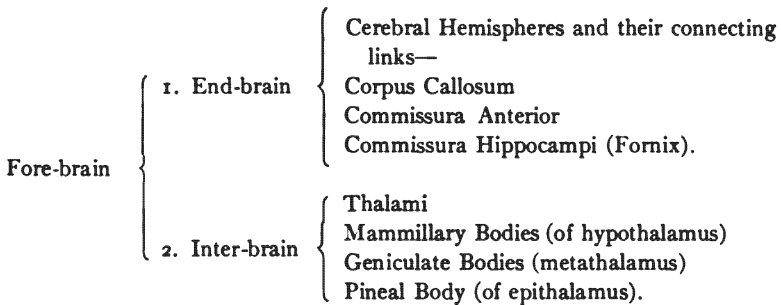
Reference to the table given above shows that the cerebrum is made up of three parts: (1) *The end-brain*, which includes the cerebral hemispheres and their connecting links; (2) *the inter-brain*, comprising the thalami and their associated nuclei, which with the former constituted the **fore-brain**; and (3) the *mid-brain* (Figs. 17, 18, and 27). The cerebrum is an ovoid mass, flattened inferiorly, which fills the vault of the cranium and rests, below, upon the floor of the cranial cavity in the anterior and middle fossæ and upon the tentorium cerebelli over the posterior fossa (Fig. 2). Viewed from above, it is sufficiently round to suggest a sphere; and, being divided in the median line by the longitudinal fissure, the lateral halves are called *hemispheres*. The most anterior point is the *frontal pole*, and the most posterior is the *occipital pole* (Fig. 22). In the floor of the longitudinal fissure of the cerebrum the corpus callosum can be seen joining the hemispheres together; and beneath it, concealed from view, are the fornix and anterior commissure. Those are the connecting links, proper, of the hemispheres (Figs. 34, 36 and 37). Inferior to them is found the inter-brain. The latter form an additional union of the hemispheres, as may be seen by viewing



the base of the brain. Just caudal to the inter-brain is the mid-brain which occupies the tentorial notch of the dura mater; and, situated in the median line, is so overhung by the cerebral hemispheres as to reveal only its anterior surface. It resembles the inter-brain in this respect. Inferiorly the mid-brain joins the rhombencephalon. Their plane of union cuts the isthmus (Fig. 44).

In studying the gross structures of the cerebrum it is most convenient to divide it into its embryologic divisions, viz., the fore-brain and the mid-brain.

SECTION I. THE FORE-BRAIN OR PROSENCEPHALON.



In order to fix important landmarks and to learn the location and relations of the gross structures of the fore-brain it is necessary to study in detail the topography of the *exterior surface* and the *interior surface*. It is that with which the present section deals. For the minute anatomy of the cerebral structures, see Section III of the Cerebrum.

EXTERIOR SURFACE OF FORE-BRAIN.

The exterior surface of the fore-brain is composed of a thin sheet of gray matter varying in thickness from one-sixth to one-quarter of an inch. That gray matter forms a bark-like covering for the underlying white substance and is, therefore, called the *cortex* (Figs. 34 and 35). It is thrown into irregular elongated

folds named convolutions, or *gyri*, by deep linear depressions, which greatly increase the relative amount of cortical substance. The linear depressions are called *fissures*, or *sulci*; and, in consequence of them, the gray substance is increased in bulk to fifty-eight and one-half per cent. of the entire cerebrum (DeRegibus).

The name **fissure** is properly applied, *first* to those deep furrows which represent clefts between embryonic vesicles, viz., the median, vertical cleft between the cerebral hemispheres, and the two arched clefts, one between the cerebellum and the cerebral hemispheres and the other between the cerebellum and the posterior surface of the medulla oblongata (Figs. 19 and 20); and, *second*, the deep linear depressions in the cerebral hemisphere which indent the entire ventricular wall and produce eminences on the interior surface are properly called fissures. All other furrows in the cerebral surface are called **sulci**.

The exterior surface of the fore-brain is divided by distinct borders into three regions, namely, the **convex surface**, the **medial surface**, and the **basal surface** (Figs. 22, 26 and 27). The basal surface comprises the *orbital* and *tentorial areas*, separated by the stem of the fissura lateralis cerebri (Sylvii). The convex surface is separated from the medial surface by the *supero-medial border* (*margo supero-medialis*), from the tentorial area of the basal surface by the *injero-lateral border* (*margo injero-lateralis*, or *m. occipitalis lateralis*), and from the orbital area of the basal surface by the *superciliary border* (*margo superciliaris*). The *medial orbital border* (*margo orbitalis medialis*) separates the orbital area of the basal surface from the medial surface, and the *medial occipital border* (*margo occipitalis medialis*) divides the medial surface from the tentorial area of the basal surface (Figs. 19, 22 and 26).

FISSURES AND SULCI OF CONVEX SURFACE.

The convex surface of the cerebral hemisphere (*facies convexa cerebri*) is related to two very extensive fissures, viz., the longitudinal and the transverse. The **longitudinal fissure of the cerebrum** (*fissura longitudinalis cerebri*) is the vertical median

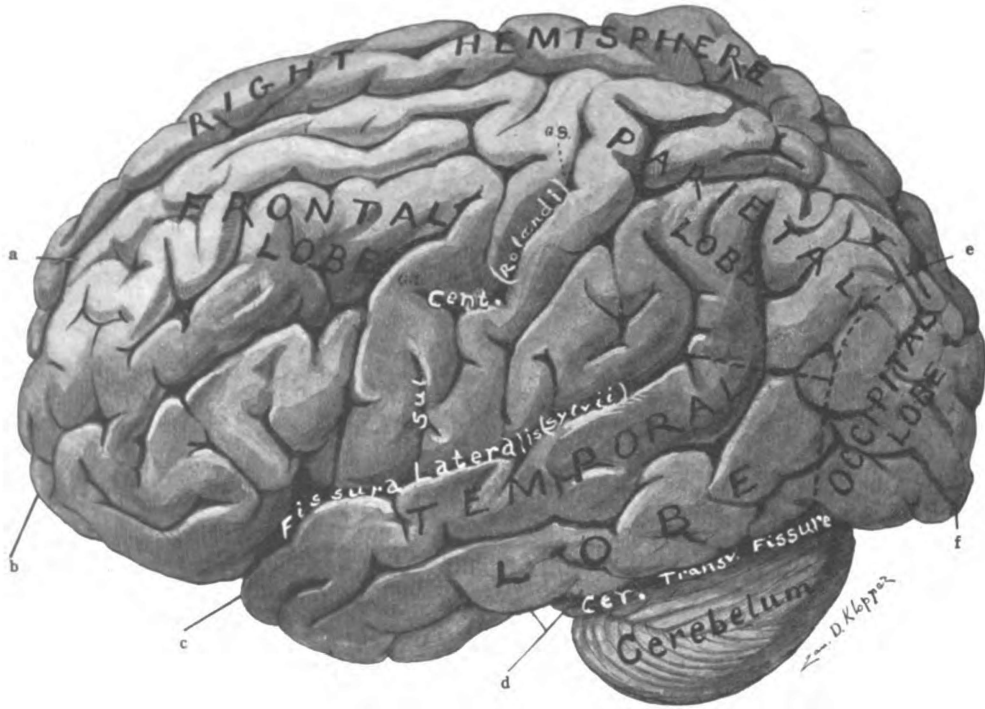


Fig. 22.—Latero-superior view of brain, showing fissures and lobes. (Original.)
 a. Longitudinal fissure. b. Frontal pole. c. Temporal pole. d. Impressio petrosa. e. Occipito-parietal sulcus. f. Occipital pole.

cleft between the hemispheres of the cerebrum (Figs. 19 and 22). It contains the falx cerebri (Fig. 1). Its floor is formed by the corpus callosum. The cerebrum is separated from the cerebellum by the **transverse fissure of the cerebrum** (*fissura transversa cerebri*, Figs. 20, 27, 1 and 6). This fissure continues forward above the mid-brain, and terminates in the cerebrum between the inter-brain and the fornix, where it is continuous, by its lateral extremities, with the chorioidal fissures of the hemispheres. The tentorium occupies the posterior part. The anterior part of the transverse fissure contains the chorioid tela of the third ventricle.

There are three great furrows in the convex surface of each cerebral hemisphere which form **interlobar boundaries** and constitute very important landmarks: The *fissura cerebri lateralis*, the sulcus centralis, and the sulcus occipito-parietalis (Figs. 22 and 23).

The lateral fissure (*fissura cerebri lateralis*, [Sylvii]) begins in the fossa of the same name at the base of the brain (Fig. 21). It runs outward between the frontal and the temporal lobe, along the lesser wing of the sphenoid bone; and, turning upward, on the convex surface, it divides three-fourth inch behind the *Sylvian point* into an anterior horizontal, and anterior ascending and a posterior ramus (Fig. 23). Into the frontal lobe project the small anterior rami. They are separated by the foot (posterior end) of the inferior frontal gyrus, called the *pars triangularis*. Below the anterior horizontal ramus is a knuckle of the same frontal gyrus which forms the *pars orbitalis*; and, between the ascending and posterior rami, is located the *pars opercularis*, constituting the connecting gyrus between the anterior and posterior central gyri. The inferior frontal gyrus forms the frontal part of the operculum (*pars frontalis operculi*). The operculum (operculum, a cover) covers the island. The posterior limb of the lateral cerebral fissure separates the temporal lobe from the parietal. Near the crotch and within the fissure is situated the *island*. A line drawn from the **Sylvian point**, one and one-quarter inches behind the zygomatic process of the frontal bone and one and a half inches above that of the temporal, backward to the **subparietal**

point, three-quarters of an inch below the tuber parietale, lies directly over the posterior ramus of this fissure.

The Sulcus Centralis (Rolandi, Figs. 22, 23, 24 and 27).—Beginning just above the posterior limb of the lateral cerebral fissure, is the central sulcus, which extends upward and backward to the longitudinal fissure of the cerebrum. Its upper extremity is about half an inch (or 5.7 per cent.) behind the middle of a line drawn from the nasal eminence to the external occipital protuberance. With this sagittal meridian the sulcus centralis forms an anterior angle of 69 to 74 degrees. The average *Rolandic angle* is $71^{\circ} 7'$ (Cunningham). The sulcus centralis is three and three-eighths inches long and forms the boundary between the frontal and the parietal lobe. It is developed in two parts a *superior third* and an *inferior two-thirds*, which join at an angle open backward, called the **genu superius**; both parts may present an anterior concavity. Often a concealed gyrus separates the two parts of the sulcus at the genu superius (Fig. 22). This superior genu is in line with the superior frontal sulcus and marks the probable location of the trunk center and the boundary between the arm and leg areas in the anterior central gyrus. There is a less constant angle, the **genu inferius**, in the lower part of the central sulcus; it is in line with the inferior frontal sulcus and marks the lower limit of the *arm area* and the upper limit of the *face area*.

The Occipito-parietal Sulcus. (*Sulcus occipito-parietalis*).—If the line on the skull locating the posterior limb of the lateral cerebral fissure be extended back to the sagittal meridian its posterior end marks the location of the occipito-parietal sulcus. The sulcus is located one-sixth of an inch above the *lambda* in the adult, and is from one and a half to two inches above the occipital pole. The greater part of the occipito-parietal sulcus is situated on the medial surface of the cerebral hemisphere, hence, it is divided into an *internal part* and an *external part* which are continuous through the supero-medial border (Figs. 26, 22 and 28). To the extent of its depth, which is about one inch, the external occipito-parietal sulcus separates the occipital from the parietal lobe on the convex surface of the hemisphere. Cunningham

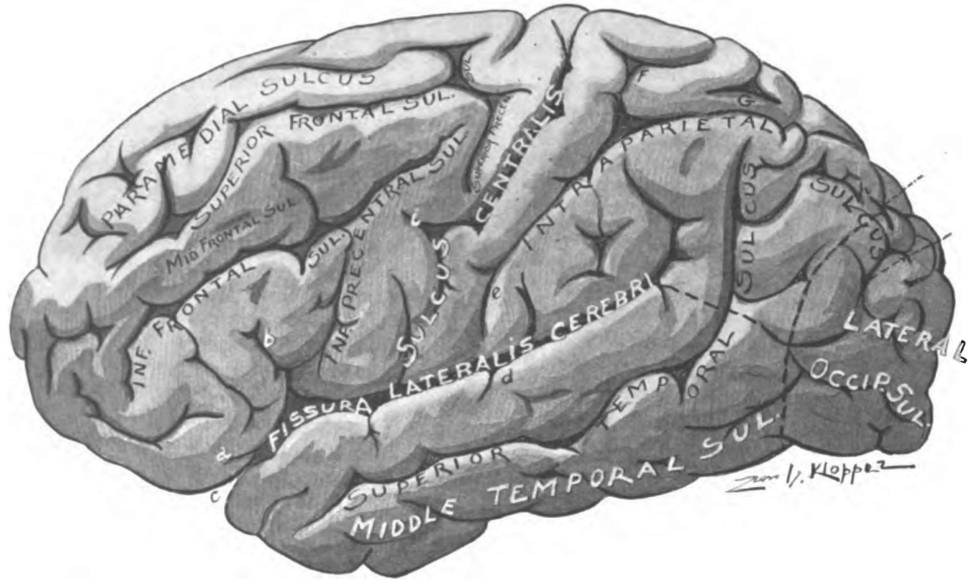


Fig. 23.—Convex surface of left cerebral hemisphere showing fissures and sulci. (Original.)

Lateral fissure of cerebrum: a. Horizontal anterior ramus. b. Ascending anterior ramus. c. The stem. d. Posterior ramus. Interparietal sulcus: e. Inferior postcentral. f. Superior postcentral. g. Horizontal part. h. Occipital part.

considers the occipito-parietal sulcus a true fissure because in the embryo it produces a ventricular eminence, though it disappears during development.*

LOBES AND GYRI OF THE CONVEX SURFACE.

(1) **The frontal lobe** (*lobus frontalis*) comprises the anterior polar region of the hemisphere and forms a part of all three surfaces (Figs. 22, 28 and 26). On the convex surface, it extends as far back as the central sulcus and the lateral cerebral fissure; on the basal surface, it is bounded behind by the stem of the lateral cerebral fissure and the anterior perforated spot; and it is limited posteriorly by the sulcus cinguli on the medial surface of the cerebral hemisphere.

On the convex surface, the frontal lobe has the following *sulci* and *gyri* (Figs. 23 and 24):

Sulci	{	Superior precentral (s. præcentralis superior) Inferior precentral (s. præcentralis inferior) Superior frontal (s. frontalis superior) Inferior frontal (s. frontalis inferior) Middle frontal (s. frontalis medius) Paramedial (s. paramedialis).
Gyri	{	Anterior central (g. centralis anterior) Superior frontal (g. frontalis superior) Middle frontal (g. frontalis medius) Inferior frontal (g. frontalis inferior).

The *precentral sulci* (Fig. 23) are parallel with the central sulcus and are located about a half inch in front of it, the lower end of the inferior precentral being insinuated between the central sulcus and the ascending ramus of the lateral fissure of the cerebrum. They form the anterior boundary of the *anterior central gyrus*. The *superior frontal sulcus* and the *inferior frontal sulcus* are respectively continuous with the corresponding precentral sulcus from which they trend downward and forward parallel

*The name of this sulcus is written "occipito-parietal" rather than "parieto-occipital;" this is a simpler word to pronounce as it avoids having "oocc" in the middle of it.

with the supero-medial border of the hemisphere. They separate from each other three gyri of nearly equal width, viz., the *superior*, *middle* and *inferior frontal gyri* (Fig. 24).

The **superior frontal gyrus** is incompletely divided in the human brain by an interrupted sulcus, called the *sulcus paramedialis* (Fig. 23) which is located near the supero-medial border of the hemisphere and is said by Cunningham to be better developed in the higher types of the human race and to be rare in the higher apes.

A series of shallow furrows, described by Eberstaller as the *middle frontal sulcus* (*s. frontalis medius*, Fig. 23) partially subdivides the **middle frontal gyrus** into an upper and a lower part. The middle frontal sulcus, not found below the anthropoid apes (Cunningham), is best marked anteriorly and, at the superciliary border of the hemisphere, bifurcates and forms a horizontal furrow, the *fronto-marginal sulcus*. The posterior end, the foot, of the middle frontal gyrus, like that of the superior and inferior frontal, lies in the psychic-motor zone of the brain. It contains the writing center (Gordinier) in the left hemisphere of right-handed people.

The **inferior frontal gyrus** is highly developed in the human brain, especially in the left hemisphere of right-handed people. It is deeply cleft along its lower border by the *anterior ascending* and *anterior horizontal rami* of the lateral fissure of the cerebrum and is thus divided into a *pars orbitalis*, situated below the anterior horizontal ramus, a *pars triangularis*, inclosed between the anterior horizontal and ascending rami, and a *pars basilaris*, located between the anterior ascending ramus of the lateral fissure and the inferior precentral sulcus. The *pars basilaris* constitutes the foot of the inferior frontal gyrus and is continuous with the gyrus *centralis anterior*; on the left side it contains the *speech center*. The anterior portions of the superior middle and inferior frontal gyri comprise a psychic center, center of attention, volition, inhibition, etc., "of abstract concept" (Mills).

The **anterior central gyrus** (*g. centralis anterior*) lies between the precentral sulci and the central sulcus. It is joined to the posterior central gyrus by the paracentral lobule, above the

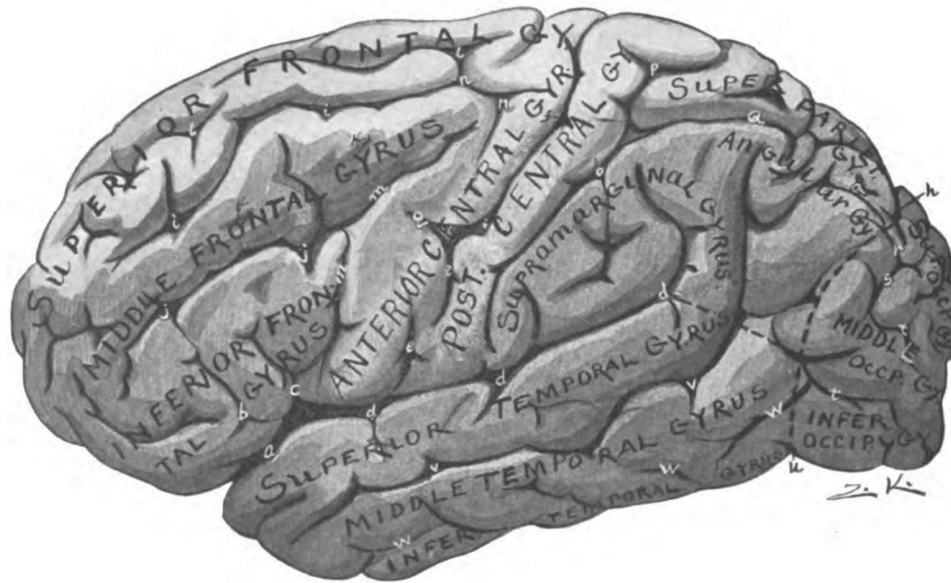


Fig. 24.—Gyri of convex surface of left cerebral hemisphere. (Original.)

Fissura lateralis cerebri: a. Stem. b. Horizontal anterior ramus. c. Ascending anterior ramus. d. Posterior ramus. e, e. Sulcus centralis (Rolandi). f. Genu superius. g. Genu inferius. h. Sul. occipito-parietalis. i, i, i. Sul. frontalis superior. j, j. Sul. frontalis inferior. k, k. Sul. frontalis medius. l, l. Sul. paramedialis. m, m. Sul. præcentralis inferior. n, n. Sul. præcentralis superior. o. Sul. post-centralis inferior. p. Sul. post-centralis superior. q. Ramus horizontalis and r, ramus occipitalis of interparietal sulcus. s. Sul. transversus. t. Sulci superior and lateralis. u. Incisura præoccipitalis. v. Sul. temporalis superior. w. Sul. temporalis medius.

central sulcus, and by the fronto-parietal part of the operculum, below it. The anterior central gyrus, together with the paracentral lobule constitutes the *emissive motor zone* of the human cerebrum.

(2) **The parietal lobe** (*lobus parietalis*) is situated behind the central sulcus and above the posterior limb of the lateral fissure of the cerebrum (Figs. 22 and 28). From the curve near the posterior end of the latter to the occipito-parietal sulcus the lobe is separated from the temporal, below, and the occipital, behind, by an imaginary line. This imaginary line runs backward parallel with the infero-lateral border of the hemisphere to the boundary of the occipital lobe; and then, obliquely upward toward the supero-medial border in a line drawn from the pre-occipital notch to the occipito-parietal sulcus. Extending over the supero-medial border, the lobe on the medial surface is inclosed between the occipito-parietal sulcus behind and the marginal part of the sulcus cinguli in front, and is bounded antero-inferiorly by the subparietal sulcus.

On the convex surface of the hemisphere the parietal lobe possesses the following *sulci* and *gyri* (Figs. 23 and 24).

Sulci	}	Interparietal (s. interparietalis) four parts—
		Inferior post-central (s. post-centralis inferior)
		Superior post-central (s. post-centralis superior)
		Horizontal limb (ramus horizontalis)
		Occipital limb (ramus occipitalis).
Sulci	}	Upturned ends of
		Lateral fissure (f. cerebri lateralis)
		Superior temporal sulcus (s. temporalis superior)
		Middle temporal sulcus (s. temporalis medius).
Gyri	}	Posterior central (g. centralis posterior)
		Superior parietal lobule (l. parietalis superior)
		Inferior parietal lobule (l. parietalis inferior)
		Supramarginal (g. supramarginalis)
		Angular (g. angularis)
Gyri	}	Postparietal (g. postparietalis).

The **interparietal sulcus** (Figs. 20 and 23) is the only one belonging to the parietal lobe. The *inferior* and *superior post-*

central sulci, constituting its anterior parts, are parallel with the central sulcus and are located a half or three-quarters of an inch behind it, separated from the central sulcus by the gyrus centralis posterior. The post-central sulci are often not continuous. The inferior is about twice the length of the superior, in this resembling the central sulcus, and usually it is joined at its upper end to the horizontal limb of the interparietal sulcus. The *horizontal part* of the sulcus lies about an inch below the supero-medial border of the hemisphere with which it is parallel; it separates the superior parietal lobule from the inferior parietal lobule and is continued as *ramus occipitalis* into the occipital lobe where it bifurcates.

The **posterior central gyrus** reaches from the posterior limb of the lateral fissure upward and backward, between the central and post-central sulci, to the longitudinal fissure of the cerebrum (Fig. 24). It is joined to the anterior-central gyrus around the ends of the central sulcus by *superficial annectant gyri* (*gyri transitivi*) and sometimes is connected with it by a *buried gyrus* (*g. profundus transitivus*) which, deeply, separates the superior from the inferior part of the central sulcus. The annectant gyrus which closes the central sulcus superiorly and links together the central gyri is the **paracentral lobule** (*lobulus paracentralis*); the **fronto-parietal part of the operculum** joins them below the central sulcus. The posterior central gyrus and paracentral lobule constitute the receptive area of common sensation, the *somæsthetic area*, so far as it extends on the convex surface.

The **superior parietal lobule** (Figs. 20 and 24) forms the supero-medial border of the hemisphere from the superior post-central to the occipito-parietal sulcus. It is separated from the inferior parietal lobule by the horizontal part of the interparietal sulcus; posteriorly, it is joined to the occipital lobe by a curved annectant gyrus, called the *arcus occipito-parietalis*, which closes the superior end of the occipito-parietal sulcus; and, over the supero-medial border, it is continuous with the præcuneus of the medial surface. In the præcuneus and the superior parietal lobule Mills locates the *stereognostic center* (Figs. 56 and 57).

The Inferior Parietal Lobule.—The inferior parietal lobule is incompletely divided into two or three gyri. Named from

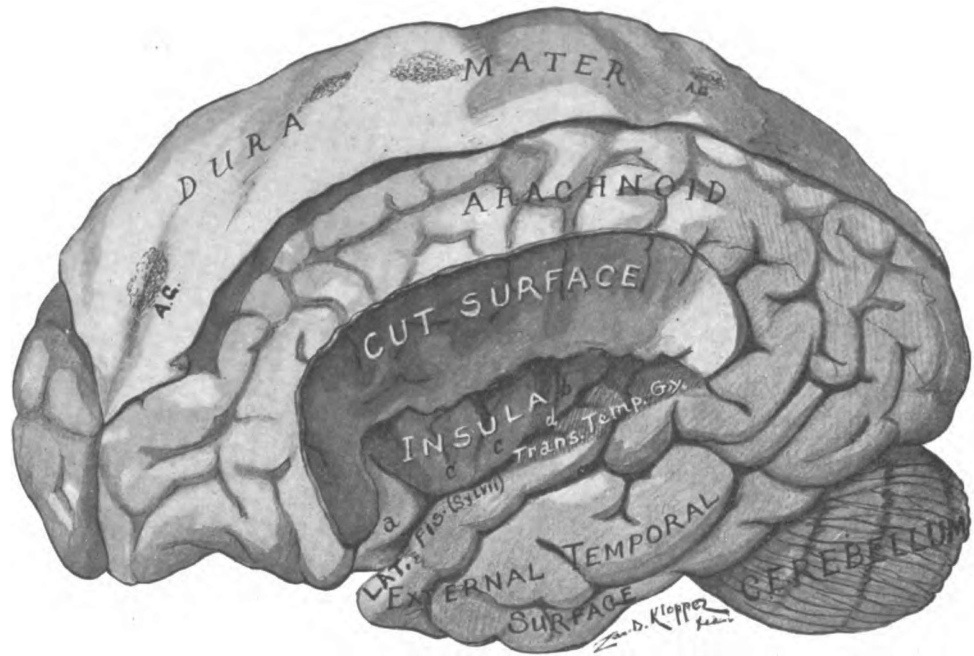


Fig. 25.—Lateral aspect of brain. Part of frontal and parietal lobes cut away to show the island and the superior surface of the temporal lobe. Arachnoid granulations. (Original.)
 a. Pars orbitalis of inferior frontal gyrus. b. Gyrus longus. cc. Gyri breves. d. Sulcus centralis insulae. A.G. Arachnoid granulations.

before backward they are as follows: The supramarginal, the angular and the post-parietal (Figs. 20 and 24).

The **supramarginal gyrus** arches over and closes the upturned end of the posterior ramus of the lateral fissure of the cerebrum (Fig. 24). The anterior segment of the arch is continuous with the posterior central gyrus and is comprised in the *psychic-sensory area*; the posterior segment of the arch fuses with the angular gyrus, behind, and the superior temporal gyrus, below, and belongs to the psychic-sensory area, also, the *motor memory center* (Fig. 56).

The **angular gyrus** forms an arch over the end of the superior temporal sulcus (Figs. 20 and 24). The angular arch is in direct continuity with the superior and middle temporal gyri and the posterior segment of it is continuous with the post-parietal gyrus when that gyrus is present.

The **post-parietal gyrus** is present only when the middle temporal sulcus bends upward and terminates in the parietal lobe; in which case this gyrus curves over and closes that sulcus (not figured). It connects the posterior ends of the inferior and middle temporal gyri and also blends with the superior occipital gyrus. The angular, post-parietal and superior occipital gyri on the left side, according to Mills and others, constitute the *center for visual memories*. The studies of A. W. Campbell render it probable that the visual cortex does not extend into the parietal lobe of man at all. The receptive visual *center for macular vision* (vision in the macula lutea of the retina) is likewise located in the angular or post-parietal gyrus by Mills, but it is probably situated on the medial surface of the occipital lobe; unlike the memory center, this is present in both hemispheres.

(3) **Occipital Lobe.** (*Lobus occipitalis*, Figs. 20, 22, 24, 26 and 28).—The occipital lobe forms the posterior pole of the hemisphere. With the parietal and temporal lobes it is directly continuous, being marked off from them by an imaginary line drawn from the *preoccipital notch* to the *occipito-parietal sulcus*. This sulcus, on the convex surface, bounds it to the extent of about an inch; rarely, the *external perpendicular sulcus* bounds it in front. On the medial and basal surfaces of the hemisphere the

occipital lobe extends from the occipito-parietal sulcus to the pre-occipital notch, and is separated from the temporal lobe on the basal surface by an imaginary line drawn from this notch toward the posterior end of the corpus callosum, to the isthmus of the limbic lobe. The occipital lobe has the form of a *triangular pyramid* whose borders are the supero-medial, the infero-lateral and the medial occipital borders of the cerebral hemisphere. Those borders meet at its apex, the *occipital pole*.

The occipital lobe is somewhat rudimentary in man, though present only in apes and men (Cunningham). It makes its appearance at the fourth month in utero, and is distinctly outlined by fissures on all three surfaces at the sixth month, when it resembles the same lobe in the adult ape's brain (Cunningham Memoirs). After the sixth month the fissural boundaries largely disappear from the human brain on the convex and basal surfaces; hence, the artificial boundaries in the adult. Its rudimentary character probably accounts for the great variability in the sulci and gyri of the occipital lobe. On the convex surface they are usually as follows:

Sulci	{	Ramus occipitalis of interparietal sulcus.
		Transverse occipital (s. occipitalis transversus)
		Lateral occipital (ss. occipitales laterales).
Gyri	{	Superior occipital (gg. occipitales superiores)
		Lateral occipital (gg. occipitales laterales).

The **lateral occipital sulcus** is the only one properly belonging to the convex surface of the occipital lobe (sometimes there are two of them). It divides that surface almost equally into a *superior* and *lateral gyrus*, both of which may be double. The sulcus begins near the supero-medial border. It follows a meridian which is nearly parallel with the infero-lateral border of the lobe and runs forward, often presenting one interruption, to the occipito-temporal boundary line where it bifurcates and forms a short perpendicular sulcus, which represents the affenspalte of the ape (Elliot Smith). When the lateral occipital sulcus is double there are two lateral gyri (Figs. 20, 23 and 24).

The **occipital limb** of the interparietal sulcus descends in

the occipital lobe a variable distance (Fig. 20). It is not always continuous with the horizontal limb. Running about an inch from the supero-medial border of the hemisphere, it passes the occipito-parietal sulcus, from which it is separated by the *arcus occipito-parietalis*, and bifurcates in the superior occipital gyrus into two more or less oblique branches, constituting the **transverse occipital sulcus**. The medial end of the transverse sulcus may or may not cut the supero-medial border of the lobe.

The **lateral occipital gyrus** (Figs. 20 and 24) lies below the lateral occipital sulcus and extends from the occipital pole forward along the infero-lateral border of the hemisphere to the preoccipital notch. Sometimes it is divided into two lateral gyri by an inferior lateral sulcus. It is continuous with the inferior temporal gyrus, except rarely, when the two are separated by the *external perpendicular sulcus*.

The **superior occipital gyrus** forms the upper half of the convex surface of the lobe (Figs. 20 and 24). It is incompletely separated from the lateral occipital gyrus by the lateral occipital sulcus and is often divided into two gyri. It is continuous with the post-parietal gyrus around the lateral end of the transverse occipital sulcus; and, around the medial end of that sulcus, it is joined to the superior parietal lobule by the *arcus occipito-parietalis*. The latter is a sharply curved annectant gyrus which bounds the occipito-parietal sulcus. When the middle temporal sulcus does not turn upward at its posterior end and terminate in the parietal lobe, the superior occipital gyrus is continuous in front with the middle temporal and angular gyri. As already mentioned, the superior occipital gyrus, according to Mills, belongs to the *center for visual memories*.

(4) The **temporal lobe** (*lobus temporalis*, Figs. 20, 22, 23, 24, 25 and 26) is that part of the cerebral hemisphere behind the main stem and below the posterior limb of the lateral cerebral fissure. It rests in the middle fossa of the skull; forms the temporal pole of the hemisphere; and is continuous posteriorly with the occipital and parietal lobes, from which it is marked off only by the imaginary lines already described. On the basal surface of the hemisphere, the temporal lobe along its medial

border is separated from the limbic lobe by the collateral fissure and by a short furrow, which is shallow in the adult human brain, called the sulcus ecto-rhinalis. The temporal lobe is attached to the hemisphere posteriorly and medially; but it presents three free surfaces—a superior, an external and an inferior—which meet at the anterior point, called the *temporal pole*.

The **superior surface of the temporal lobe** forms the inferior wall of the lateral cerebral fissure (Fig. 25). It looks somewhat medianward toward the island and constitutes the *temporal part of the operculum*. It is separated from the island by the *inferior circular sulcus* (s. *circularis insulæ*). Anteriorly, the superior surface of the temporal lobe is smooth; posteriorly, it possesses one or two shallow *transverse temporal sulci* which feebly outline two or three gyri, called the *transverse temporal gyri* of Heschl (*gyri temporales transversi*). These transverse gyri belong to the *receptive auditory center* (Figs. 31, 35, 36 and 54).

The **external surface of the temporal lobe** presents the following *sulci* and *gyri* (Figs. 23 and 24):

Sulci	{	Superior temporal (s. <i>temporalis superior</i>)
		Middle temporal (s. <i>temporalis medius</i>)
		Inferior temporal (s. <i>temporalis inferior</i>). This is really on the inferior surface of the lobe.
Gyri	{	Superior temporal (g. <i>temporalis superior</i>)
		Middle temporal (g. <i>temporalis medius</i>)
		Inferior temporal (g. <i>temporalis inferior</i>).

The *superior temporal* and *middle temporal sulci* (Fig. 23) divide the external surface into three nearly equal gyri; they run parallel with each other, with the infero-lateral border and with the lateral cerebral fissure. The superior temporal sulcus, like the lateral fissure, bends upward at its posterior extremity; it terminates in the concavity of the angular gyrus. The middle temporal sulcus is usually an interrupted one. It may present an upward curve at its posterior end which is bounded and closed by the post-parietal gyrus; or it may continue in its original direction toward the occipital lobe.

The *inferior temporal sulcus*, situated in the tentorial area of

the basal surface, runs interruptedly close to the infero-lateral border of the hemisphere and parallel with it (Fig. 26). It separates the inferior temporal gyrus from the fusiform gyrus.

The **superior temporal**, the middle temporal and the inferior temporal gyri are of nearly equal width (Figs. 24 and 26). They fuse with one another and with the fusiform gyrus at the temporal pole. The superior temporal gyrus is continuous with the supra-marginal and angular gyri, posteriorly: in its third and fourth fifths and in the transverse temporal gyri is the *receptive auditory center* (Barker).

The **middle temporal gyrus** fuses at its posterior end with the angular gyrus and either with the post-parietal or the superior occipital. Along the superior temporal sulcus, in the middle two-fourths of the superior and middle temporal gyri is the center for auditory memories, the *psychic auditory center*. This center is in the left hemisphere of right handed people (Figs. 54 and 56).

The **inferior temporal gyrus** forms the infero-lateral border of the hemisphere (Figs. 24 and 26). It is continuous with the lateral occipital gyrus and sometimes, also, with the superior occipital and post-parietal gyri. If this gyrus and the lower half of the middle temporal gyrus be divided into four equal parts, each fourth, according to Mills, belongs to a definite center. From behind forward they are the *center of orientation*; the *center of equilibration* (?); the *naming center*; and, in the anterior fourth and the pole of the temporal lobe, the *center of intonation* (Fig. 56).

(5) **The island** (*insula*, Reili) is also called the central lobe (Figs. 25, 26, 31 and 36). It is situated in the medial wall of the lateral fissure of the cerebrum, between the frontal, parietal and temporal lobes, whose growth, after the fifth month in utero, gradually covers it over. At the end of the first year of extrauterine life it is entirely concealed by temporal, parietal, and frontal parts of the operculum. The island is thus separated from the general surface of the cerebral hemisphere by a distance of half or three-quarters of an inch. It is triangular in shape. Its apex is directed downward and forward toward the fossa lateralis cerebri, and is called the **pole** (*polus insulae*). If the lips of the lateral fissure be widely separated, the **sulcus circularis insulae**

may be seen separating the island from the frontal, parietal and temporal lobes (Figs. 25, 26 and 36). The circular sulcus is lacking only at the antero-inferior part, at the pole, where the cortex of the island is continuous with that of the posterior orbital gyrus and with the anterior perforated substance, and is on the same level as the orbital area of the basal surface. The imaginary line separating the anterior perforated substance from the island is called the *threshold* of the island (*limen insulæ*).

In the island there is one named *sulcus* and *four to six gyri* which have a radial or fan-like grouping (Fig. 25):

Sulcus	{	Central of the island (s. centralis insulæ).
Gyri	{	Short (gyri breves), three or four of them. Long (gyrus longus—furcalis).

The *sulcus centralis insulæ* begins at the apex, or pole, of the island and runs obliquely upward and backward dividing the lobe into two lobules (Fig. 25). It is in the same transverse plane as the central sulcus (of Rolando). In front of it, is the **pre-central lobule** composed of the short gyri and continuous with the frontal lobe; the **post-central lobule** lies behind it and is in continuity with the parietal, temporal and limbic lobes.

The **gyri breves insulæ**, three or four in number, are separated by shallow furrows which diverge upward and backward from the smooth apex of the precentral lobule (Fig. 25). They are joined to the orbital operculum by a short annectant gyrus (*gyrus transversus insulæ* of Eberstaller) which extends from the apex around the lower end of the anterior circular sulcus. Their connection under the circular sulcus with the foot of the inferior frontal gyrus suggests a participation in the speech center, and they are figured by Mills in that center. However, the paraphasia which results from lesions in the short gyri may be due to the involvement of an association tract of fibers running underneath them.

Gyrus Longus (Furcalis) (Fig. 25).—It lies behind the central sulcus of the island and trends obliquely backward and upward. Posteriorly, it bifurcates for a short distance forming two short branches which are continuous under the circular sulcus with the

parietal lobe; it fuses with the temporal lobe and the gyrus hippocampi of the limbic lobe, inferiorly.

The *olfactory lobe* and the *limbic lobe*, comprising the rhinencephalon and a part of the neopallium, also belong to the cerebral hemisphere; but no part of either can be seen on the convex surface (Figs. 28, 21 and 18).

THE BASE OF THE FORE-BRAIN.

The basal or inferior surface of the fore-brain comprises the inferior surface, first, of the *end-brain*, including the pars optica hypothalami and the cerebral hemispheres; and, second, of the *inter-brain*, which embraces the pars mammillaris hypothalami. It is completely exposed only when a section is made through the mid-brain and the rhombencephalon removed (Figs. 21 and 26). This should now be done with a thin, moistened brain-knife. Make the section from before backward and upward, at a right angle to the axis of the mid-brain. Now notice, *first*, the section of the mid-brain and, just anterior to that, the median structures of the fore-brain, occupying the center of the field; and, *second*, the surrounding inferior surface of the cerebral hemispheres. The latter form the very large peripheral zone.

The **base of the cerebral hemisphere** extends from the frontal to the occipital pole. In front it is composed of the orbital area bounded by the medial orbital and superciliary borders; and, posteriorly, is made up of the tentorial area, which is bounded, laterally, by the infero-lateral border, and, medially, by the chorioidal fissure and the medial occipital margin of the hemisphere (Fig. 26). The orbital area embraces the inferior surface of the frontal lobe and of the island, and the whole olfactory lobe; while the inferior surface of the temporal and occipital lobes, and the gyrus hippocampi and fascia dentata of the limbic lobe are included in the tentorial area.

Frontal Lobe, Inferior Surface (Fig. 26).—The inferior surface of the frontal lobe, resting on the orbital plate of the frontal bone, is often called the *orbital lobe*. It is separated from its fellow by the longitudinal fissure of the cerebrum, and is bounded behind

by the lateral fossa and lateral fissure of the cerebrum, overlapped by the temporal lobe. More accurately, the posterior boundary is the anterior perforated substance and the anterior part of the circular sulcus. The orbital lobe is concave transversely and is divided by the triradiate or *H-shaped sulcus orbitalis*, made up of the *medial orbital*, the *transverse orbital* and the *lateral orbital sulci*; and by the **olfactory sulcus**, which is close to the longitudinal fissure and parallel with it. Five gyri are thus formed:

Gyri	{	Straight (g. rectus) Medial orbital (g. orbitalis medialis) Lateral orbital (g. orbitalis lateralis), not constant Anterior orbital (g. orbitalis anterior) Posterior orbital (g. orbitalis posterior).
------	---	---

The **gyrus rectus** (Fig. 26) forms the medial border of this surface. It is separated from the medial orbital gyrus by the sulcus olfactorius in which lie the olfactory bulb and tract. Over on the medial surface it forms a part of the marginal gyrus and it joins the superior frontal at the frontal pole. Posteriorly, the gyrus rectus is separated from the parolfactory area (of Broca) by a slight furrow, the *anterior parolfactory sulcus*.

The **medial orbital gyrus** lies between the sulcus of the same name and the sulcus olfactorius (Fig. 26). It extends from the frontal pole to the anterior perforated substance and the island. The **anterior** and **posterior orbital gyri** lie within the H-shaped orbital sulcus separated from each other by the transverse orbital sulcus. The former is continuous with the frontal gyri at the superciliary border; the latter is only partially separated, behind, from the island by the anterior circular sulcus; the posterior orbital gyrus is likewise continuous with the posterior end of the lateral orbital gyrus and with the orbital portion of the inferior frontal. The **lateral orbital gyrus**, which is a distinct gyrus only when the lateral orbital sulcus is long, is situated external to the H-shaped sulcus. It is continuous with both middle and inferior frontal gyri at the superciliary border of the hemisphere.

The Island (of Reil), Inferior Surface (Fig. 26).—If the anterior part of the temporal lobe be removed, the under surface of the island (insula) is brought into view. The circular sulcus

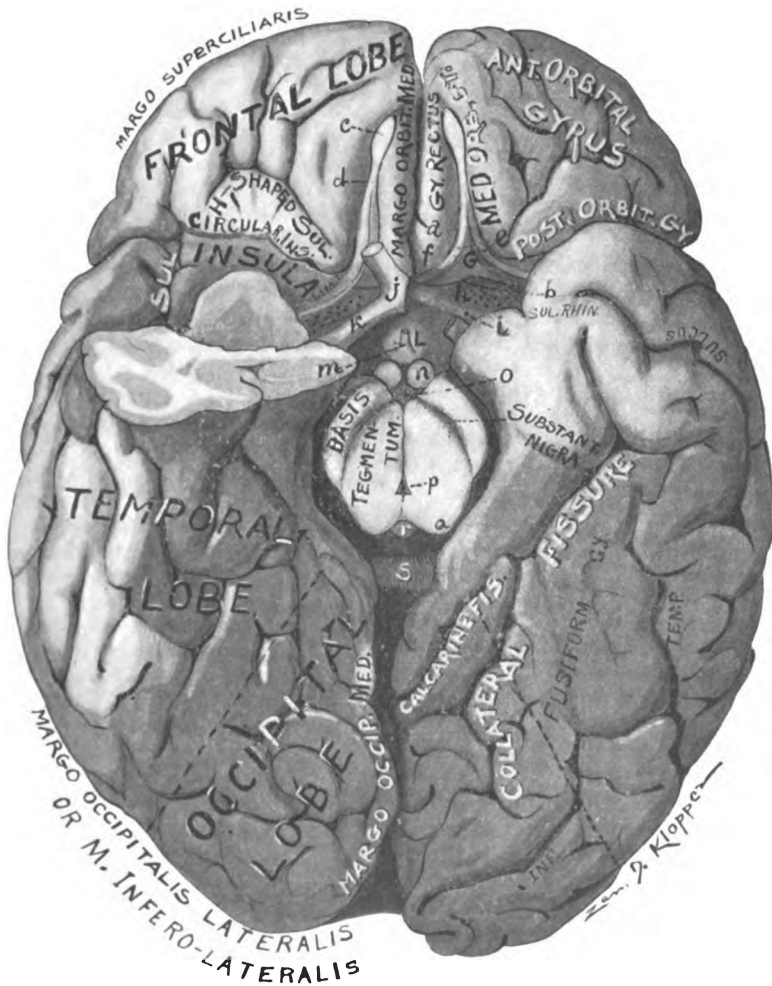


Fig. 26.—Base of fore-brain and cut surface of mid-brain. Right temporal pole cut away, to show inferior surface of the island. (Original.)

- a. Sulcus parolfactorius anterior. b. Sulcus parolfactorius posterior. c. Olfactory bulb.
- d. Olfactory tract. e. Olfactory stria. f. Area parolfactoria. g. Trigonum olfactorium.
- h. Substantia perforata anterior. i. Gyrus subcallosus (peduncle of corpus callosum).
- j. Optic chiasma. k. Optic tract. l. Tuber cinereum. m. Infundibulum. n. Corpus mammillare. o. Substantia perforata posterior. p. Aqueductus cerebri. q. Quadrigeminal colliculus. r. Corpus pineale. s. Splenium.

bounds it on two sides and separates it from the posterior orbital gyrus, in front; and from the temporal lobe, behind. Laterally it is separated from the frontal and the parietal parts of the operculum by an antero-posterior cleft continuous with the lateral cerebral fissure.

The insula is continuous with the anterior perforated substance, and the area of transition from one to the other is called the *threshold*, or *limen insulæ* (Fig. 26).

Rhinencephalon.—The *smelling brain* belongs to the basal surface. It is rudimentary in man. Many connected parts make it up. It is divided into two parts by the *sulcus parolfactorius posterior*. These are designated as the **pars anterior rhinencephali** and the **pars posterior rhinencephali**. The pars anterior of the rhinencephalon embraces, *first*, the *olfactory lobe*, which is made up of the olfactory bulb, tract, triangle and the medial and intermediate striæ; and *second*, the *area parolfactoria*. In the *pars posterior rhinencephali* are included the anterior perforated substance, the gyrus subcallosus, the lateral olfactory stria, and the limen insulæ.

Olfactory Lobe. (*Lobus olfactorius*).—There is one lobe that is studied only on the basal surface of the fore-brain. That is the olfactory lobe (Fig. 26). Belonging to the *pars anterior rhinencephali*, it comprises many connected parts; and the reason for calling them the olfactory lobe is found in the lower animals and in the human embryo, where it exists as a prominent hollow process of the cerebral hemisphere (Figs. 17 and 18).

Olfactory Lobe	{	Bulbus olfactorius Tractus olfactorius Trigonum olfactorium Stria medialis Stria intermedia.
----------------	---	--

The *olfactory bulb* (*bulbus olfactorius*) is an ovoid mass of brain matter about half an inch long, one-sixth of an inch wide and a quarter of an inch in vertical diameter (Fig. 26). It is lodged in the olfactory sulcus of the frontal lobe and rests upon the cribriform plate of the ethmoid bone through which it receives the twenty or thirty olfactory nerves. The center of the bulb

is formed by a *gray core* derived from the ependymal lining of the embryonic ventricle. The gray core is surrounded by a *white sheath* of medullated fibers running longitudinally; posterior to the bulb these fibers form the olfactory tract. Five layers of gray substance thicker on the ventral side, surround the white sheath and constitute the surface of the bulb. The gray substance forms the terminal nucleus of the olfactory nerves and gives origin to the fibers of the olfactory tract.

Olfactory Tract (Tractus olfactorius).—The tract is triangular in section, slightly more than an inch long and one line in width (Fig. 26). It is partially concealed in the olfactory sulcus, and is a continuation backward of the medullated mitral axones which ensheath the gray core of the olfactory bulb. At its posterior end the olfactory tract divides into three striæ—lateral, intermediate and medial, two of which are easily seen. These *striæ olfactoriæ* are continuous with the three angles of the tract. The lateral and medial striæ diverge and inclose the olfactory triangle between them. The *lateral stria (stria lateralis)* courses outward and backward and terminates in the uncus at the anterior extremity of the hippocampal gyrus. According to Retzius, the lateral olfactory stria terminates in the rudimentary gyri, *circumambiens* and *semilunaris*, which form the anterior end of the hippocampal gyrus. The lateral stria bounds on the outer side the anterior perforated space. The *medial stria (stria medialis)* bends sharply inward, toward the median line, and runs between the triangle and parolfactory area (of Broca). Its fibers turn into Broca's area and the gyrus cinguli, chiefly, but some of them enter the triangle, the gyrus subcallosus, and the hippocampus through septum pellucidum and fornix. Thus the medial and lateral striæ unite the opposite ends of the gyrus fornicatus. From the dorsal angle of the olfactory tract, a bundle of fibers proceeds into the triangle and frontal lobe, constituting the *intermediate stria (stria intermedia)*. The intermediate olfactory stria is often not visible on the surface, as it turns at once upward into the frontal lobe. Upon reaching the level of the anterior commissure, it passes through that commissure to the opposite hemisphere, where it divides into two bundles; one of which (the commissural

bundle) turns down into the intermediate stria of the opposite olfactory tract, and the other (the decussating bundle) runs backward and outward toward the uncinatè region of the limbic lobe.

The Olfactory Triangle and the Parolfactory Area (of Broca).—The triangular portion of the cortex between the medial and lateral olfactory striæ, called the *triangle (trigonum olfactorium)* is continuous medially with the *area parolfactoria*. The medial stria marks the boundary between them (Figs. 26 and 27). Both are bounded behind by the *sulcus parolfactorius posterior* (transverse part), and the oblique part of the same fissure separates the parolfactory area from the gyrus subcallosus (peduncle of the corpus callosum). The area parolfactoria (Brocæ) is limited in front by a slight curved depression, the *sulcus parolfactorius anterior*. On the medial surface, this area joins the gyrus cinguli.

The *anterior perforated substance (substantia perforata anterior)* of the pars posterior rhinencephali requires further mention (Fig. 26). It is separated from the triangle by a very faint groove, the posterior sulcus parolfactorius. Medially, it is in direct continuity with the tuber cinereum. The optic tract bounds it, postero-medially. Laterally, it forms the *limen insulæ* in the floor of the fossa cerebri lateralis, where it is overlapped by the temporal lobe. Superiorly, it is continuous with the base of the corpus striatum. Coursing along the inner and outer border of the anterior perforated substance are, respectively, the gyrus subcallosus and lateral olfactory stria, which converge and meet in the hippocampal gyrus. The perforations of this area are for the antero-lateral ganglionic arteries.

Tentorial Area of the Basal Surface (Figs. 26, 24 and 28).—From the temporal pole backward, the basal surface of the cerebral hemisphere presents three nearly parallel gyri, viz., the *inferior temporal gyrus*, which forms the infero-lateral border; the *fusiform gyrus*, the middle one, and the *gyrus hippocampi* which lies next the mid-brain. The last belongs to the gyrus fornicatus of the limbic lobe; it is continuous, posteriorly, with the lingual gyrus, which forms a part of the medial occipital border of the cerebral hemisphere. The fusiform and inferior temporal gyri belong to the inferior surface of the temporal and

occipital lobes. These two lobes are directly continuous with each other on their inferior surfaces, and are only separated arbitrarily by an imaginary line drawn from the preoccipital notch to the anterior end of the calcarine fissure. They are only partially separated from the gyrus hippocampi; the ectorhinal sulcus (*s. rhinalis*) and the anterior part of the collateral fissure lie between the temporal lobe and the hippocampal gyrus of the limbic lobe; while the inferior surface of the occipital lobe is separated from the gyrus cinguli, of the limbic lobe, by the anterior calcarine fissure. The fissures and sulci of the tentorial area are the following:

- Chorioidal fissure (*f. chorioidea*)
- Hippocampal fissure (*f. hippocampi*).
- Ectorhinal sulcus (*s. ectorhinalis*)
- Collateral fissure (*f. collateralis*)
- Inferior temporal sulcus (*s. temporalis inferior*).

The **chorioidal fissure** (*j. chorioidea*) forms a part of the medial boundary of the tentorial area (Figs. 26 and 28). At the surface it appears to be identical with the hippocampal fissure; but, upon looking deeper, the two are found to be separated by the fascia dentata and the crus of the fornix. This fissure is separated from the inferior horn of the lateral ventricle, only by a layer of epithelium, derived from the roof plate of the telencephalon. It contains the *chorioid plexus* of the inferior horn.

Hippocampal Fissure. (*F. hippocampi*, Fig. 28).—Along the medial and concave border of the hippocampal gyrus is the crescentic fissure known as the hippocampal fissure. The fissure in front is closed by the uncus. It extends backward to the splenium of the corpus callosum where, in the adult, it is continuous with the furrow behind and above the corpus callosum, called the *callosal sulcus*. The hippocampal is a true fissure as it indents the whole ventricular wall; the long ventricular eminence produced by it is the *hippocampus* seen in the inferior horn of the lateral ventricle (see medial surface of the cerebral hemisphere).

Ectorhinal Sulcus. (*Incisura temporalis*, Figs. 26 and 29).—Midway between the temporal pole and the hook-point of the hippocampal gyrus is a slight notch, called the ectorhinal sulcus,

which represents an important lateral boundary of the rhinencephalon in animals with highly developed sense of smell. It indicates in man the boundary between the hippocampal and fusiform gyri. A half inch behind the ecto-rhinal sulcus is the anterior end of the collateral fissure.

Fissura Collateralis (Figs. 26 and 28).—The collateral fissure extends in a somewhat curved course from near the temporal pole almost to the occipital pole. Its anterior two-thirds separates the hippocampal from the fusiform gyrus; its posterior one-third completes the medial and upper boundary of the fusiform gyrus and separates it from the gyrus lingualis.

Inferior Temporal Sulcus (Fig. 26).—Only one sulcus belongs wholly within the inferior surface of the temporal and occipital lobes. It extends from a point near the occipital pole forward along the infero-lateral border of the hemisphere almost to the temporal pole, and incompletely separates the inferior temporal gyrus and the lateral occipital gyrus from the gyrus fusiformis. Very frequently the sulcus has two or more interruptions. It may be called the *temporo-occipital sulcus*.

Gyrus Fusiformis.—One gyrus only is found entirely within the inferior temporo-occipital region (Figs. 26 and 29). That is the fusiform (temporo-occipital gyrus). It extends from near the occipital pole forward and forms the temporal pole. The posterior nine-tenths of its medial boundary is formed by the collateral fissure and the anterior one-tenth by an imaginary line and the ecto-rhinal sulcus; laterally, it is bounded by the inferior temporal sulcus.

Gyrus Lingualis.—The gyrus lingualis lies above and medial to the posterior one-third of the collateral fissure; inferior and lateral from the calcarine fissure. It is continuous with the gyrus hippocampi of the limbic lobe in front. The gyrus lingualis (Fig. 29) forms nearly all of the medial occipital border of the hemisphere. It contains a part of the *receptive visual center* (Figs. 55 and 57).

Limbic Lobe (Lobus Limbus), Inferior Part.—The **gyrus hippocampi** of this lobe is visible on the inferior surface of the fore-brain (Fig. 26). Notice how this crescentic gyrus embraces

in its concavity the section of the mid-brain. It is separated from the fusiform gyrus by the collateral fissure and the ectorhinal sulcus; and bounded medially by the hippocampal fissure. The anterior end of the gyrus is flexed inward and backward over the end of the hippocampal fissure and the whole anterior part constitutes the **uncus hippocampi**. The region of the uncus is somewhat irregular and appears to comprise the *gyrus circumambiens* and the *gyrus semilunaris* described by Retzius. It represents the greater part of the lobus pyraformis of osmatic mammals and is probably the chief *receptive center of smell*; it receives the lateral stria of the olfactory tract and fuses with a low oblique ridge, the gyrus subcallosus (or peduncle of the corpus callosum).

If the hippocampal gyrus be drawn downward somewhat, a rudimentary gyrus may be seen between the hippocampal and chorioidal fissures. That is the **dentate fascia**. It is continuous with the *reflected part of the uncus* in front, and behind is in continuity with the *fasciola cinerea* and gyrus supracallosus. Like the hippocampal gyrus it forms a part of the limbic lobe. We shall recur to this lobe on the medial surface of the hemisphere.

Having studied the basal structures of the cerebral hemispheres, it is now in order to examine the median structures in the inferior surface of the fore-brain. They occupy the interpeduncular or hypophyseal region. They constitute the hypothalamus and form part of the floor of the third ventricle.

The **hypothalamus** is the name applied to the fore-brain structures under the thalamus. Posteriorly it blends with the mid-brain. Its free portion is divided into two parts, viz., the **pars optica hypothalami** and the **pars mammillaris hypothalami**. The former belongs to the telencephalon, the latter to the diencephalon. They include the following:

Pars Optica Hypothalami	{	Lamina cinerea terminalis Optic chiasma (chiasma opticum) Tuber cinereum Infundibulum and Hypophysis.
Pars Mammillaris Hypothalami	{	Corpora mammillaria.

The **lamina cinerea terminalis** (Fig. 27) is most superior of the median structures. It is a thin lamina of ash-colored (cinereum) gray matter closing the end of the neural tube. It extends from the anterior superior surface of the optic chiasma upward and backward to the anterior commissure, just in front of which it becomes continuous with the lamina rostralis of the corpus callosum. Laterally, it is continuous with the cortex of the cerebral hemisphere. Behind it, is the third ventricle; in front of it, a part of the longitudinal fissure of the cerebrum.

Optic Chiasma. (*Chiasma opticum*).—The optic chiasma is a quadrilateral sheet of nerve fibers whose anterior angles receive the optic nerves and whose posterior angles give off the optic tracts (Fig. 21). With the nerves and tracts attached, it is x-shape. The chiasma is a median structure and is situated beneath the lamina cinerea, in the optic groove of the sphenoid bone. The fibers of the optic nerves and tracts compose it. There are three sets of these fibers, namely, the *intercerebral*, the *direct*, and the *decussating*. A fourth group of fibers, called the *inter-retinal* and said to be commissural for the retinae, has been hitherto described, but their existence is very doubtful. The *intercerebral* fibers are not found in the optic nerves, but form the *inferior commissure* (Guddeni) which joins together the medial geniculate bodies (Fig. 43). The *direct* (or *temporal*) and *decussating* (or *nasal*) fibers run through nerve and tract and join the retina with the brain on the same and the opposite side, respectively. In most vertebrates below mammals, and in the mouse and guinea pig, it is said that the optic fibers all decussate in the chiasma. Normally in man and the higher mammals, the temporal half of each retina contributes to the chiasma *direct* fibers and the nasal half crossed fibers (Fig. 67). The **optic nerves** (*nervi optici*) extend from the foramen scleræ of each eyeball back to the front of the chiasma, through the optic foramina; they rise in the ganglionar cells of the retinae, which are connected with the rods and cones by the bipolar neurones. The **optic tracts** (*tractus optici*) connect the chiasma with the brain. Each tract winds outward and backward around the cerebral peduncle, and divides into a *medial* and a *lateral root* (Fig. 43). The roots

wind under the thalamus and disappear at the corresponding geniculate body. The lateral root contains all the retinal fibers, the medial root has nothing to do with vision. The fibers of the lateral root (*radix lateralis*) may be traced to the lateral geniculate body (80 per cent., Von Monokow), to the pulvinar of the thalamus (nearly all the 20 per cent. remaining), and the rest to the superior quadrigeminal colliculus. The optic radiation of the capsule connects these centers with the medial occipital cortex. The *medial root* rises and ends in the medial geniculate body and thalamus. Its fibers form the commissura inferior (Guddeni).

Tuber Cinereum.—The posterior border of the optic chiasma is continuous with the tuber cinereum (Figs. 21 and 26). Here the gray matter is thickened and centrally prominent. The bulbous *infundibulum* projects downward from it to rest in the sella Turcica, where it forms the posterior lobe of the *hypophysis*. The upper end of the infundibulum is hollow (funnel-like). Its cavity forms the lowest part of the third ventricle. In man the bulb of the infundibulum is solid at maturity, though hollow in the embryo. It is composed largely of fibrous tissue, notwithstanding the fact that it is developed from the floor of the telenkephalon. From the base (superior end) of the infundibulum, the tuber cinereum extends in continuity with the anterior perforated substance on each side of it; and, behind, the corpora mammillaria mark the boundary between it and the posterior perforated substance of the mid-brain.

The lamina cinerea and tuber cinereum form the *inferior gray commissure* of the fore-brain.

The **hypophysis** (pituitary body, Fig. 21) is composed of two lobes bound together by connective tissue. A sheet of dura mater (*diaphragma sellæ*) holds them in the hypophyseal fossa. The *anterior lobe*, the larger, is derived from the epithelium of the mouth cavity; and, in structure, resembles the thyroid gland. Its closed vesicles, lined with columnar epithelium (in part ciliated), contains a viscid jelly-like material (pituita), which suggested the old name for the body. The anterior lobe is hollowed out on its posterior surface (kidney-shape) and receives the *posterior lobe*, the infundibulum, into the concavity. The hypophysis

has an internal secretion which appears to have an inhibitive action on growth and has been found diseased in acromegalia.

Corpora Mammillaria (Figs. 21 and 26).—Two white bodies (*corpora albicantia*), as large as a small pea, are situated one on either side of the median line, between the tuber cinereum and the pigmented gray matter of the posterior perforated substance. Each is formed superficially by a loop in the columna of the fornix and is, therefore, composed of white substance at the surface. There is gray matter in the interior which forms a *medial* and a *lateral nucleus* (Fig. 46). In the medial nucleus the fornix fibers terminate and an ascending bundle rises, called the *fasciculus thalamo-mammillaris* (*Vicq d'Azyri*). The latter terminates in the anterior nucleus of the thalamus. From the medial nucleus of the corpus mamillare also rises the *tegmental* part of the *fasciculus pedunculo-mammillaris*; the *basilar* portion of the same bundle rises in the lateral nucleus and both parts of this pedunculo-mammillary bundle run downward into the mid-brain to an unknown termination.

Immediately behind the corpora mammillaria is the posterior perforated substance (Figs. 21 and 26). This is the exposed part of the substantia nigra of the mid-brain, perforated for the passage of the postero-median ganglionic arteries. The pons and bases pedunculi bound it behind. Issuing from the inner side of the basis pedunculi is the large oculomotor nerve; and coursing over its surface from behind forward, is the smaller trochlear nerve. The bases pedunculi will be described with the mid-brain to which they belong.

FISSURES OF THE MEDIAL AND TENTORIAL SURFACE.

To expose the medial surface of the cerebral hemispheres, a median sagittal section must be made through the connecting links of the hemispheres and the inter-brain, dividing the fore-brain into lateral halves. Separate the lips of the longitudinal fissure of the cerebrum; drop the moistened brain-knife down onto the corpus callosum; and make one quick sweep of the knife toward you. Of the surface now exposed the middle one-third is produced by section.

It is convenient to study the tentorial area of the basal surface with the medial surface (Fig. 26). In this medial and tentorial surface there are *six important sulci* and *four fissures* (Fig. 28).

Sulci	{	Of cingulum (s. cinguli)
		Callosal (s. corporis callosi)
		Subparietal (s. subparietalis)
		Occipito-parietal (s. occipito-parietalis)
		Inferior temporal (s. temporalis inferior)
	{	Ectorhinal (s. ectorhinalis).
Fissures	{	Calcarine (fissura calcarina)
		Hippocampal (f. hippocampi)
		Chorioidal (f. chorioidea)
		Collateral (f. collateralis).

Sulcus Cinguli (Calloso-marginal Sulcus).—Beginning under the middle cut surface and extending in a curve forward, upward, and backward, until it half encircles the corpus callosum; and, then, turning upward to the supero-medial border and ending just behind the central sulcus is the sulcus cinguli (Figs. 27 and 28). It separates the gyrus cinguli and a marginal gyrus, including the straight and superior frontal, from one another by its anterior part; and, by its marginal end, separates the paracentral lobule from the præcuneus. The sulcus cinguli is usually interrupted by one annectant gyrus and often by two. These indicate its development in three separate parts.

At its beginning under the corpus callosum, the sulcus cinguli is almost continuous with a small curved sulcus, which runs nearly vertically downward, called the **anterior parolfactory sulcus** (Figs. 28 and 29). Behind that little sulcus there is a small curved gyrus, the *parolfactory area* (of Broca), which is continuous with the gyrus cinguli and bounded behind by another slight sulcus, called the **posterior parolfactory sulcus**. The latter separates the area parolfactoria from the gyrus subcallosus.

Subparietal Sulcus.—About one inch above and behind the posterior end of the corpus callosum there is an irregular sulcus, called the subparietal, which separates the gyrus cinguli of the limbic lobe from the præcuneus of the parietal lobe (Fig. 28).

The **callosal sulcus** is the deep furrow between the corpus

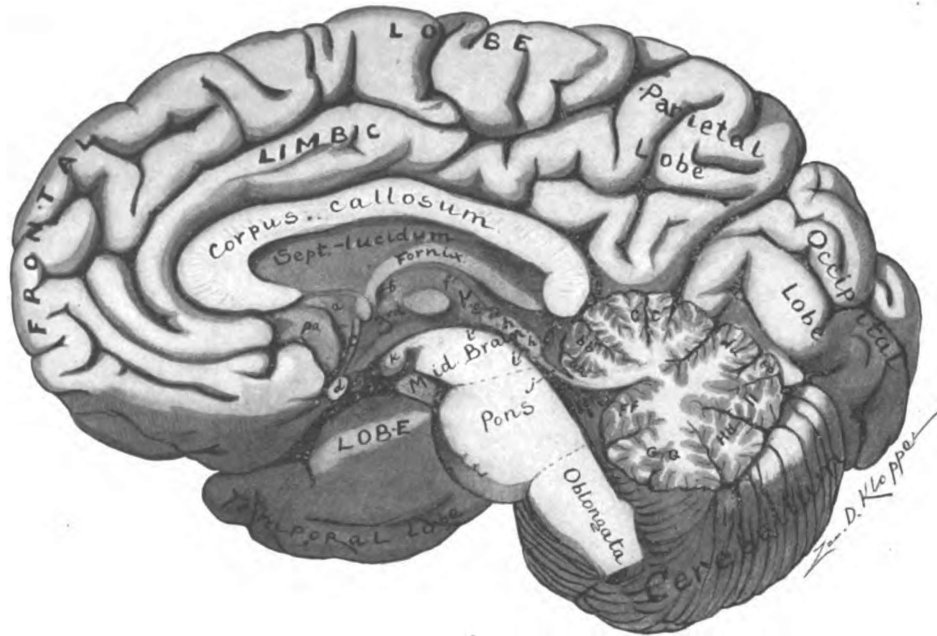


Fig. 27.—Median section of the brain. (Original.)

- a. Gyrus subcallosus (peduncle corpus callosum). b. Foramen interventriculare. c. Lamina terminalis. d. Optic chiasma. e. Tuber cinereum. f. Stria medullaris. g. Stalk of pineal body. h. Quadrigeminal colliculi. i. Cerebral aqueduct. j. Superior medullary velum. k. Corpus mammillare. pa. Parolfactory are. aa. Lingula. bb. Lobulus centralis. cc. Culmen monticuli. dd. Declive monticuli. ee. Folium vermis. ff. Nodus. gg. Uvula. hh. Pyramis. ii. Tuber vermis.

callosum and the gyrus cinguli. It follows the convexity of the corpus callosum and was formerly called the *ventricle* of it (Fig. 28). The callosal sulcus, behind the corpus callosum, is continuous with the hippocampal fissure.

The **occipito-parietal sulcus** (Figs. 27, 28 and 20), the internal part, extends downward from the supero-medial border to the middle of the calcarine fissure. The two form a lambda-shaped fissure \sphericalangle (Fig. 28); the lambda being tilted toward the frontal pole has one anterior and two posterior rami. The anterior ramus and the lower of the posterior rami constitute the calcarine fissure; the posterior superior ramus, is the occipito-parietal sulcus. This latter sulcus cuts the supero-medial border at the junction of the posterior one-sixth with the anterior five-sixths of that border; it is situated about two inches above the occipital pole, and lies one-sixth of an inch anterior to the point in the skull called the lambda. It separates the parietal lobe from the cuneus of the occipital lobe. The occipito-parietal sulcus is a deep one. In the embryo the primary occipito-parietal fissure produces an eminence in the posterior horn of the lateral ventricle (Cunningham). It is then a true fissure. But that primitive fissure and the ventricular eminence entirely disappear, and the adult sulcus is a secondary and superficial furrow, hence it is properly called a sulcus and not a fissure. At the inferior end of the occipito-parietal sulcus a buried annectant gyrus, the *gyrus cunei*, separates the occipito-parietal sulcus from the calcarine fissure, with which superficially it is continuous.

The **calcarine fissure** begins a quarter of an inch below the posterior end of the corpus callosum and runs backward and slightly upward to the lower end of the occipito-parietal sulcus; and, then, curves downward to a point near the occipital pole; where it ends bifid (Figs. 28 and 26). It is thus divided by the sulcus occipito-parietalis into an *anterior calcarine* and a *posterior calcarine fissure*. These three furrows are continuous with one another superficially in the human brain; but buried annectant gyri actually separate them from each other: the *gyrus cunei* separates the occipito-parietal sulcus from the calcarine fissure

and the anterior calcarine fissure is separated from the posterior calcarine by the *gyrus cuneo-lingualis* (Cunningham). The anterior calcarine fissure indents the medial wall of the posterior horn of the lateral ventricle, producing the *calcar avis*.

Hippocampal Fissure (Figs. 26 and 28).—A crescentic fissure, convex downward begins under the splenium of the corpus callosum in continuity with the callosal sulcus, and winds forward beneath the thalamus to within an inch of the temporal pole, where it is closed by the uncus. It is the hippocampal fissure. On the surface of the temporal lobe this fissure appears to be identical with the temporal extension of the *chorioidal fissure*; but, deeply, it lies posterior to that fissure and is separated from it by the *fascia dentata*. The hippocampal fissure produces a long ridge in the inferior horn of the lateral ventricle, called the *hippocampus*.

The **chorioidal fissure** (Figs. 28 and 39) describes about two-thirds of a circumference along the concavity of the fornix. It extends from the foramen interventriculare backward over the thalamus; and then downward and forward along the hippocampal fissure, but separated from it by the dentate fascia. The chorioidal fissure is a complete one, involving the whole hemisphere wall. A single layer of epithelium separates it from the lateral ventricle. The pia mater, dipping into it, forms the *chorioid plexus* of that ventricle. The fissure is peculiar in the fact that between the inter-brain and the fornix there is a transverse slit by means of which it is continuous with the same fissure on the opposite side. In this antero-superior part, which is in direct continuity with the transverse fissure of the cerebrum, is the border of the *chorioid tela of the third ventricle*.

Collateral Fissure.—The collateral is a long fissure (Figs. 26 and 28). It reaches from near the occipital almost to the temporal pole. It is situated below and parallel with the calcarine and hippocampal fissures, being separated from the former by the lingual gyrus and from the latter by the hippocampal gyrus. The *gyrus fusiformis* lies below and external to this fissure. Anterior to the collateral fissure, there is a small sulcus between the *gyrus hippocampi* and the temporal pole, called the **ectorhinal**

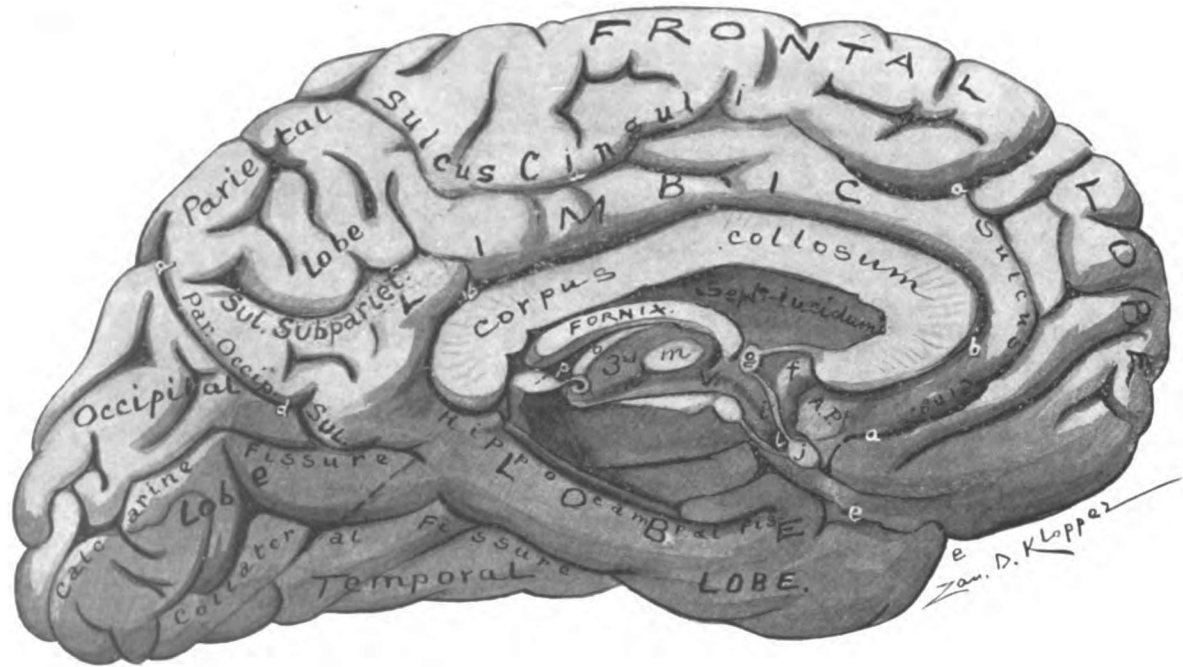


Fig. 28.—Medial surface of left cerebral hemisphere, showing lobes and sulci. (Original.)

aaa. Sulcus cinguli. bb. Callosal sulcus. ee. Fissura lateralis cerebri f. Gyrus subcallosus. i. Lamina terminalis. l. Optic recess.
 n. Sulcus hypothalamicus. o. Stria medullaris. p. Pineal body. A. P. Area parolfactoria.

sulcus, which represents a very important fissure (*f. rhinalis*) in osmatic animals. The collateral fissure is occasionally interrupted by two annectant gyri and divided into a *temporal*, an *occipital* and an *intermediate part*. This signifies a persistence of its embryonic condition. The intermediate portion, sometimes assisted by the anterior part, indents the ventricular wall and produces the *eminentia collateralis* in the inferior horn of the lateral ventricle.

The **inferior temporal sulcus** is usually a series of indentations rather than a continuous sulcus (Figs. 26 and 28). It is about equal in extent to the collateral fissure from which it is separated by the fusiform gyrus. It is parallel with the inferolateral border of the cerebral hemisphere. As the inferior temporal gyrus, which forms this border reaches over onto the tentorial area a variable distance, even in the two sides of the same brain, the position of the inferior temporal sulcus is not constant; but it is usually one-quarter or one-half inch medial to the border.

LOBES AND GYRI OF MEDIAL AND TENTORIAL SURFACE.

The gyri form two concentric rings, interrupted antero-inferiorly at the fossa cerebri lateralis, which encircle the corpus callosum and thalamus (Fig. 28). The two rings are separated from one another by a broken fissure, the *limbic fissure*, made up of the sulcus cinguli (except its marginal end), the subparietal sulcus, and the anterior part of the calcarine and of the collateral fissures.

Gyrus Fornicatus.—The *gyrus cinguli* and the *gyrus hippocampi*, joined together at the posterior border of the corpus callosum by the *isthmus*, and together constituting the gyrus fornicatus, form the *central ring*. The *gyrus cinguli* begins anteriorly under the corpus callosum in continuity with the area parolfactoria anterior to the fossa cerebri lateralis; and the hippocampal terminates as uncus just behind that fossa. The gyrus fornicatus forms the chief part of the *limbic lobe*.

The **gyrus cinguli** is the arched gyrus which is inclosed between the callosal sulcus and the sulcus cinguli, except above the posterior

end of the corpus callosum; there it is bounded on its convexity by the subparietal sulcus (Fig. 28). Underneath the corpus callosum, the anterior end of the gyrus cinguli is continuous with a small vertical gyrus, called the *area parolfactoria* (Brocæ), which is embraced between the anterior and posterior parolfactory sulci and is continuous with the area of the same name on the base of the cerebral hemisphere. This part belongs to the *cortical area of smell*. The posterior end of the callosal gyrus is almost separated from the hippocampal gyrus by the anterior calcarine fissure; the narrow link left between this fissure and the splenium of the callosum is the *isthmus gyri fornicati*. It is claimed by Schäfer and others, that the superior part of the gyrus cinguli constitutes a portion of the somæsthetic area; but the histological investigations of Dr. A. W. Campbell appear to disprove such a claim. According to Paul Flechsig, the gyrus cinguli contains the *center of taste*. He locates the center in the posterior part of the gyrus adjacent to the splenium of the corpus callosum; it forms a thin zone bounding the callosal sulcus (Fig. 55).

The **gyrus hippocampi** (Figs. 26 and 28) extends downward and forward, along the hippocampal fissure, from the isthmus to within a half-inch of the temporal pole. Its anterior extremity is separated from the pole by the ectorrhinal sulcus, and is bent upward and backward over the end of the hippocampal fissure, forming a sharply curved hook, the *uncus*. The hippocampal gyrus is bounded below and laterally by the collateral fissure. Posteriorly, it is continuous with the gyrus lingualis. The reflected part of the uncus hippocampi is continuous with a concealed gyrus, located between the hippocampal and chorioidal fissures, viz., the dentate fascia; a narrow band, which winds over the uncus near its free point and is called the *hrenulum of Giacomini* establishes this junction with the dentate fascia.

The **uncus** and the **area parolfactoria** constitute the greater part of the *receptive center of smell* (Figs. 55 and 57). In the uncus anterior to the end of the hippocampal fissure, Retzius locates the *gyrus circumambiens* and *gyrus semilunaris*, which he has identified in the human embryo; and he declares them to contain the end of the lateral olfactory stria and of the gyrus

subcallosus, and he thinks they form the most important part of the *receptive olfactory center*. This region represents the **lobus pyraformis** of osmatic animals and, according to Elliot Smith (as quoted by Cunningham) it is the only part of the gyrus hippocampi which properly belongs to the **rhinencephalon**.

Limbic Lobe.—The parts of the limbic lobe may now be enumerated as follows: (1) The gyrus fornicatus (*g. cinguli and g. hippocampi*); (2) the fascia dentata, fasciola cinerea, supracallosal gyrus (longitudinal striæ), and subcallosal gyrus (peduncle of the corpus callosum); (3) one-half of the septum pellucidum; and (4) a lateral half of the fornix. The limbic lobe is rudimentary in the human brain. The structures enumerated above under No. 2 and No. 3 are but faint representatives of the strong dentate gyrus seen in animals having no corpus callosum. The development of the corpus callosum encroaches upon and partially destroys the dentate gyrus. The limbic lobe in part belongs to the **rhinencephalon**. According to the researches of Elliot Smith the posterior inferior part of the gyrus hippocampi, that part behind the uncus and below the subiculum, and the whole gyrus cinguli belong to the neopallium and not to the rhinencephalon.

The **peripheral ring** on the medial and tentorial surface of the cerebral hemisphere is composed of five gyri (Figs. 28 and 26). Beginning under the corpus callosum anterior to the area parolfactoria and going forward to the frontal pole, then along the supero-medial border to the occipital pole and, finally, along the infero-lateral border to the temporal pole, these gyri are as follows: The **gyrus rectus** and **gyrus frontalis superior** (*g. marginalis*) ending behind as *lobulus paracentralis* which closes the superior end of the central sulcus; the **præcuneus** inclosed between the marginal end of the sulcus cinguli and the sulcus occipito-parietalis; the **cuneus**, located between the occipito-parietal sulcus and the posterior calcarine fissure; the **gyrus lingualis**, which forms much of the medial occipital border and lies between the calcarine and collateral fissures; and lastly, the *gyrus fusiformis* (*temporo-occipital gyrus*), which lies below the collateral fissure and extends from the temporal pole almost to the occipital pole,

being separated from the inferior temporal gyrus by an interrupted sulcus near the infero-lateral border of the hemisphere. The inferior temporal gyrus is chiefly on the convex surface.

The paracentral lobule contains the *motor center* for the opposite foot, just in front of the central sulcus; and immediately behind that sulcus is the superior part of the *receptive somæsthetic area* (Figs. 55 and 57). In the præcuneus is a part of the *stereognostic center*; the remainder is in the superior parietal lobule; this center belongs to the psychic-sensory area. The cuneus and lingual gyrus, along the calcarine fissure of each hemisphere constitute the *receptive visual center* for the corresponding halves of both retinae and perhaps for both maculae luteæ. Probably the anterior part of the fusiform gyrus, that part just below the uncus, contains the *center of taste* (Mills).

The peripheral ring of gyri seen on this surface belongs to lobes which have their largest exposure on the convex surface of the cerebral hemisphere. Thus seven lobes belong to the exterior surface of each hemisphere.

Cerebral Hemisphere	{ 1. Seven lobes Frontal Parietal Temporal Occipital Island (of Reil) Limbic Olfactory, etc. }	I. Neopallium
		II. Rhinencephalon (archipallium)
	2. Basal ganglion	III. Corpus striatum.

INTERIOR SURFACE OF THE FORE-BRAIN.

The boundaries of the fore-brain ventricles constitute the interior surface. Considering these cavities together, we notice that they occupy a wedge-like space (Figs. 30 and 42). In shape the wedge is rectangular; and it stands, base upward, against the corpus callosum. Its beveled surfaces look toward the hemispheres. The blade is driven downward as if to split the fore-brain into lateral halves, the edge resting on the medial structures at the base of the brain. The space is inclosed laterally between

the diverging internal capsules, which, within the hemispheres, decussate with the lateral extremities of the corpus callosum. The two structures most necessary to an understanding of the cavities and interior surface of the fore-brain, therefore, are the internal capsule and the corpus callosum.

Internal Capsule. (*Capsula Interna*).—Looking at the base of the brain, we see two broad bands of nerve fibers, the bases pedunculi, issue from the cerebral hemispheres under cover of the optic tracts and, converging downward and backward, disappear in the pons (Figs. 21 and 45). Traced in their reverse direction, the fibers of each basis pedunculi enter the hemisphere of the cerebrum and are reinforced by a great number of additional fibers from the thalamus. The fibers then radiate toward the cerebral cortex in the form of a hollow cone or funnel. *This funnel-like group of fibers is the internal capsule* (Fig. 33). The bell of the funnel opens upward and outward and contains the lentiform nucleus; its solid spout, directed toward the pons and medially, is the basis pedunculi. Antero-inferiorly the fibers in the bell of the funnel diverge to opposite sides of the fissura cerebri lateralis (Sylvii) and produce a break in its continuity, the *hiatus Sylvii*; otherwise the funnel is complete. As the internal capsule proceeds into the hemisphere, it impales the corpus striatum in such manner as to place the caudate nucleus upon its circumference and to inclose within its walls (to capsulate) the lentiform nucleus. The lentiform nucleus is separated externally from the claustrum by a thin layer of fibers called the external capsule.

The internal capsule is directed obliquely outward and upward and is flattened from above downward. It has, therefore, a *superior* and an *inferior lamina*, which, posteriorly, are continuous with each other but, anteriorly, are separated by the hiatus Sylvii.

The **inferior lamina** (or inferior ramus, as seen in sagittal section) is thick behind but bevels down to a sharp edge anteriorly (Figs. 32, 33, and 70). In front it presents a free border. Its fibers pass outward beneath the lentiform nucleus and, after winding over the inferior horn of the lateral ventricle, terminate in the parietal, the insular and temporal lobes.

Motor Fibers.—The inferior lamina of the internal capsule contains most of the **temporo-pontal tract** (*tractus cerebro-cortico-pontalis temporalis*) which extends from the temporal cortex beneath and behind the lentiform nucleus to the nucleus of the pons and nuclei of the motor cerebral nerves. The **intermediate tract** (*tractus intermedius*) rises in the lentiform nucleus and runs through the anterior part of the inferior lamina, in its course to the substantia nigra and nucleus pontis in which it terminates.

Sensory Fibers (Figs. 32, 33 and 70).—The following sensory fibers are found in the inferior lamina, viz., the **ventral stalk** (*ansa peduncularis*) of the thalamus (common sensory) running from the thalamus chiefly to the somæsthetic cortex; and part of the **acoustic or temporo-thalamic radiation** (special sensory), which extends from the medial geniculate body to the auditory cortex in the superior and transverse temporal gyri. In part at least the ventral stalk rises from nuclei lower down than the thalamus—from the substantia nigra and the nuclei of the gracile and cuneate columns probably. The fibers of the *ventral stalk* of the thalamus are separated into an upper and a lower lamina by a thin sheet of gray substance. The *lower lamina* (inferior peduncle of the thalamus) runs for the most part beneath the lentiform nucleus into the external capsule and terminates in the temporal lobe and the island. The *upper lamina* (*ansa lenticularis*) enters the lentiform nucleus in *two vertical sheets* that separate the three zones of that nucleus. Its fibers to a large extent terminate in the lentiform nucleus, whose axones continue the path through the parietal stalk, in the superior lamina of the capsule, to the somæsthetic area of the cortex. In the angle between the inferior horn and the central part of the lateral ventricle, the inferior lamina joins the superior.

The **superior lamina** (or superior ramus) of the internal capsule contains most of the basis pedunculi (Fig. 30). It is a thick and strong sheet of fibers. Often it is considered as the entire "internal capsule," the inferior lamina being disregarded. The superior lamina extends, fan-like, from the basis pedunculi to the lateral extremity of the corpus callosum, with which it inter-

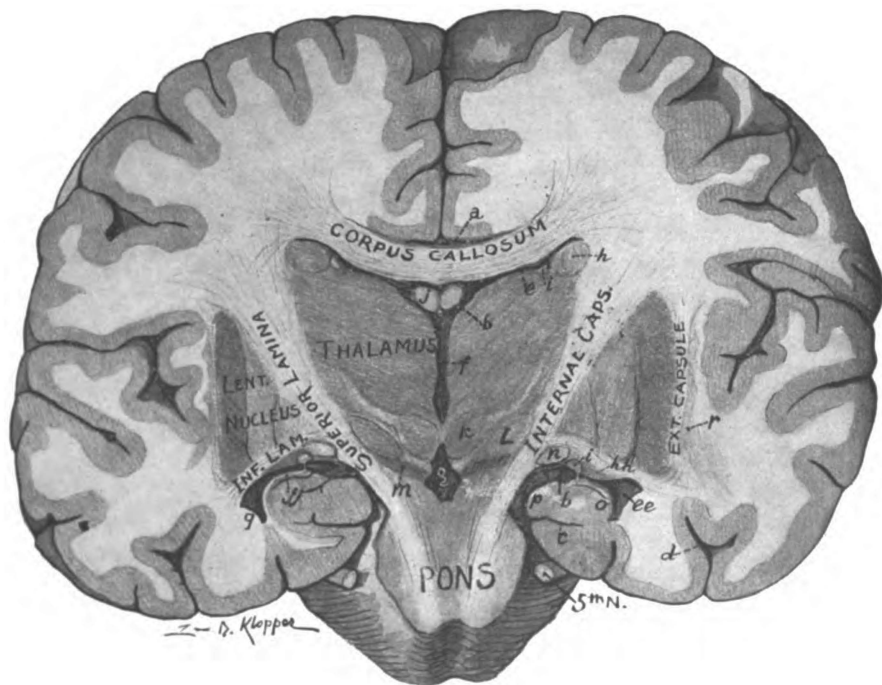


Fig. 30.—Transverse section of the brain, directed from the pons obliquely upward and forward, showing internal capsule, corpus callosum, ganglia and ventricles of the fore-brain. (Original.)

a. Callosal sulcus. bb. Chorioidal fissure. c. Hippocampal fissure. d. Collateral fissure. ee. Inferior horn of lateral ventricle. f. Third ventricle. g. Fossa interpenduncularis. h. Caudate nucleus. hh. Cauda. i. Stria terminalis. j. Body of fornix. jj. Crus of fornix. k. Red nucleus. l. Hypothalamic nucleus. m. Substantia nigra. o. Hippocampus. p. Dentate fascia. r. Claustrum.

crosses. It has a free border anteriorly, though imbedded in the corpus striatum (Fig. 32). Upon its medial surface rest the thalamus, below and behind, and the caudate nucleus, above and farther forward. It thus separates the thalamus and caudate nucleus from the lentiform nucleus. A bend seen in horizontal section near the middle of the superior lamina, called the **genu**, divides it into a **frontal part** (*pars frontalis*) and an **occipital part** (*pars occipitalis*) which tend slightly outward from the genu and form an angle with each other of about 120 degrees.

Motor Fibers of Superior Lamina (Figs. 32, 33 and 70).—The fibers of the *genu* and anterior two-thirds of the *occipital part* of the internal capsule are very largely motor and constitute the **pyramidal tract**. They may be traced from the motor area of the cortex (Figs. 54 and 56) through the internal capsule and the middle three-fifths of the basis pedunculi, and on down into the spinal cord. They end in ramifications about the cell-bodies in the gray matter of the cord and in the motor cerebral nuclei. From these same spinal and cerebral nuclei other fibers rise which constitute the motor part of the spinal and cerebral nerves. The *pars frontalis* of the internal capsule contains a motor tract which extends from the frontal cortex through the inner one-fifth of the basis pedunculi to the nucleus of the pons and motor nuclei of the cerebral nerves (Flechsig). It is the **fronto-pontal tract** (*tractus cerebro-cortico-pontalis frontalis*).

Sensory Fibers of Superior Lamina (Figs. 32, 33 and 70).—In both parts of the superior lamina of the capsule there are common sensory fibers which rise chiefly in the thalamus and end in the somæsthetic cortex (Figs. 54 and 56). They convey ordinary sensations. In the *frontal part* is the **frontal stalk** of the thalamus, which ends chiefly in the caudate and lentiform nuclei, though some of its fibers reach the frontal cortex. The tract is relayed in the lentiform nucleus, whence it is continued to the somæsthetic cortex by way of the parietal stalk, which is entered high up near the corpus callosum. The *pars occipitalis* of the superior lamina contains the **parietal stalk** of the thalamus, which conveys ordinary sensations from the thalamus to the somæsthetic cortex, chiefly to the posterior central gyrus.

In the extreme upper part of the capsule the region of the **parietal stalk** contains nearly all of the common sensory fibers. The recent investigations of Paul Flechsig show that it is built up of six bundles of fibers, two of which (alpha and gamma) proceed from the globus pallidus and four from the thalamus. According to Flechsig there are corticifugal fibers intermingled with the corticopetal in all of the sensory tracts of the capsule. The common sensory fibers of the internal capsule constitute the *cortical fillet*.

Special Sense Fibers (Figs. 32, 33 and 70).—At the junction of the superior and inferior laminae of the internal capsule are the special sense fibers. The **optic radiation** (*radiatio occipito-thalamica*) and **acoustic radiation** (*radiatio temporo-thalamica*) occupy the retro-lentiform part of the internal capsule. The former extends through it from the lateral geniculate body and thalamus to the cuneus and lingual gyrus; the latter rises in the medial geniculate body and ends in the superior and transverse temporal gyri. The optic and acoustic radiations both contain corticifugal fibers which rise in the visual and auditory cortex, respectively, and run through the capsule to the lateral and medial geniculate bodies and perhaps on to lower nuclei.

Many fibers of the internal capsule give off branches (collaterals) which pass through the corpus callosum to the opposite hemisphere; other fibers may be traced entire through the same course to the cortical cells of the opposite side. A bundle of thalamic fibers has been so traced.

The superior lamina of the internal capsule, proceeding outward and upward into the hemisphere, intermingles with the corpus callosum and enters into the corona radiata. Together with the caudate nucleus, thalamus and stria terminalis (*tænia semi-circularis*), which lie on its medial surface, it forms the entire lateral boundary of the general cavity of the fore-brain. It thus determines the lateral part of the interior surface.

Corpus Callosum (Figs. 29, 30, 34 and 42).—The entire roof of the fore-brain cavity, representing the base of the wedge, is formed by the corpus callosum. A part of the anterior boundary is also formed by it. The corpus callosum is a thick sheet of

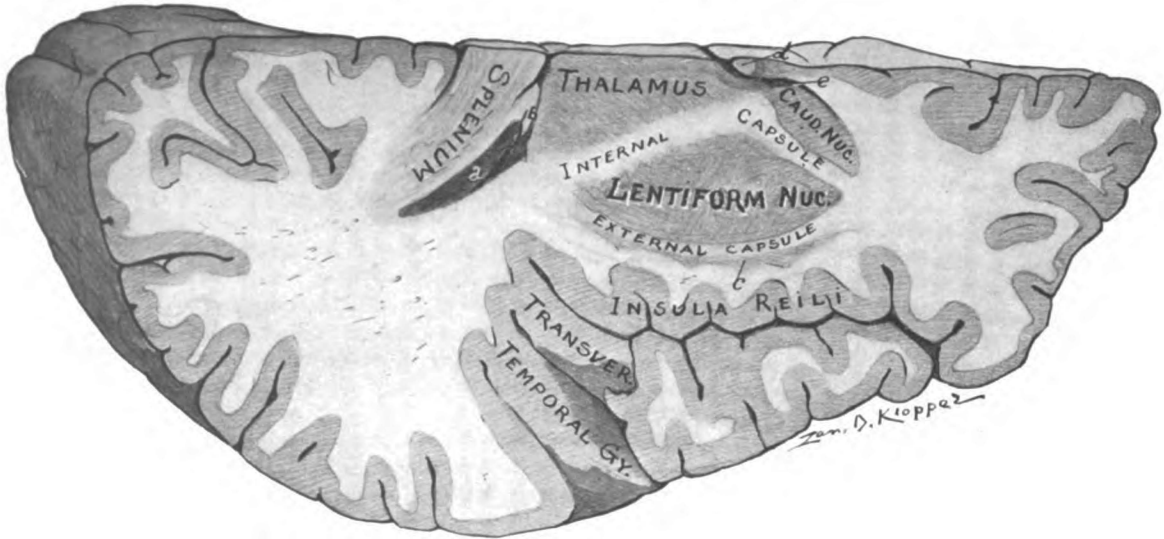


Fig. 31.—Horizontal section of right cerebral hemisphere cutting corpus callosum, internal capsule, corpus striatum, thalamus, and the island. (*Original.*)

- a. Beginning of posterior and inferior horns of lateral ventricle.
- b. Crus fornicis.
- c. Claustrum.
- d. Columna fornicis.
- e. Lateral ventricle, anterior horn.

fibers four and a half inches broad, from before backward, which joins the hemispheres together. It constitutes the great commissure, being composed chiefly of those medullated cortical axones which end in arborizations about cortical cells of the opposite hemisphere. It contains some fibers which belong to the internal capsule; and, also, collaterals from capsular and association fibers. The corpus callosum is placed nearer to the anterior than the posterior pole of the hemispheres. Separating the hemispheres above, it is seen in the bottom of the longitudinal fissure. It is about an inch in transverse length.

The **upper surface** is concave from side to side, and divided in the median line by a longitudinal raphe (Figs. 30 and 34). Transverse striæ are plainly visible. Two longitudinal striæ are also found running on either side of the raphe; one next the raphe, the *medial longitudinal stria*; and the other near the lateral end of the callosum, the *lateral longitudinal stria*. The medial and lateral longitudinal striæ are imbedded in a thin sheet of gray substance spread over the corpus callosum; altogether they constitute the **gyrus supracallosus**. If traced around the posterior border of the callosum, this supracallosal gyrus is found to be continuous with the fasciola cinerea and, through that, with the fascia dentata. The gyrus supracallosus becomes the **gyrus subcallosus** (*peduncle of corpus callosum*) after it winds around the anterior border of the corpus callosum. As such it is continued downward between the lamina terminalis and the posterior parolfactory sulcus to the base of the cerebrum, and then across the anterior perforated substance to the uncus. At the anterior and at the posterior border, the corpus callosum is bent downward (scroll-like); hence, it is superiorly convex from before backward.

Its **inferior surface** (Figs. 29 and 30) is concave antero-posteriorly and near its posterior border is fused with the body of the fornix. Anterior to that fusion, it is joined to the fornix, along the median line, by the septum pellucidum.

The **posterior border** (Fig. 29) is flexed downward from the horizontal about forty-five degrees. Giving passage to the fibers which join the middle and posterior parts of the hemispheres,

the posterior border is the thickest part of the corpus callosum. It is on that account called the pad, or *splenium*.

The **anterior border** is bent downward and then backward, sweeping through 180 degrees of flexion (Fig. 29). It tapers down to a sharp edge, called the *rostrum*. A very thin sheet-like extension of the rostrum, called the *lamina rostralis*, proceeds backward from the beak and becomes continuous with the lamina terminalis at the base of the brain. Running downward on either side is a low ridge, continuous with the striæ longitudinales, which constitutes the gyrus subcallosus. Each gyrus subcallosus, after passing across the anterior perforated substance, ends in the uncus of the hippocampal gyrus. The transverse fibers of the rostrum, in the hemisphere, form the floor of the anterior horn of the lateral ventricle.

Genu and Truncus (Fig. 29).—The down-turned anterior part of the corpus callosum is the genu. It joins the rostrum to the main body, the truncus. The genu forms part of the anterior boundary of the cerebral cavity; the truncus forms the roof. Fibers uniting the frontal lobes of the cerebrum pass through the genu, and in the hemisphere, bound the anterior horn of the lateral ventricle above and in front. Those fibers arching forward and forming the roof of the anterior horn are called the *forceps minor*. The *forceps major*, composed of fibers from the splenium which bend backward into the occipital lobe, lies in the roof and inner wall of the posterior horn and produces the eminence called the *bulb* (Fig. 38).

Each **lateral extremity** of the corpus callosum is overhung by the gyrus cinguli, which covers the lateral longitudinal stria. Inclosed between the gyrus cinguli and corpus callosum is the callosal fissure (ventricle of the callosum). The lateral extremity of the corpus callosum, within the cerebral hemisphere, intermingles with the superior lamina of the internal capsule and thus stretches entirely across the fore-brain cavities (Figs. 30 and 42).

The boundaries of the general cavity of the fore-brain may be given as follows:

Roof (base of wedge)—

Corpus callosum.

Floor (edge of wedge)—

Tegmenta of mid-brain,
 Posterior perforated substance of mid-brain,
 Tuber cinereum,
 Infundibulum,
 Optic chiasma.

Lateral wall (beveled surface)—

Internal capsule (superior lamina),
 Caudate nucleus,
 Stria terminalis,
 Thalamus.

Anterior wall (border of wedge)—

Lamina terminalis,
 Anterior commissure,
 Genu of corpus callosum.

Posterior wall—

Posterior commissure with cerebral aqueduct beneath it,
 Corpora quadrigemina of mid-brain,
 Pineal body,
 Transverse fissure of cerebrum, containing the chorioid tela
 of third ventricle,
 Splenium of corpus callosum.

The fore-brain cavity thus bounded is subdivided by two partitions (Figs. 29, 35 and 42). The body of the fornix, together with the chorioid tela of the third ventricle and the roof epithelium of the third ventricle, forms a *horizontal partition* which divides the cavity into an upper and lower chamber. The superior chamber is divided into two lateral chambers, the lateral ventricles, by a *double vertical partition*, the septum pellucidum. The inferior chamber is the third ventricle

The body of the fornix (*corpus fornicis*, Figs. 29 and 36) is a triangular sheet of fibers, whose base is attached to the under surface of the splenium of the corpus callosum, and whose bifid apex extends forward to the rostrum and the anterior commissure. Its lateral borders rest on the thalami, the chorioid tela alone intervening (Fig. 42). And the narrow chamber between

the thalami, the third ventricle, is separated from the broader, superior part of the fore-brain cavity by the body of the fornix together with the chorioid tela and a layer of epithelium. The body of the fornix is produced by the approximation of two bundles of white fibers, one belonging to each hemisphere. These bundles are the crura of the fornix.

The **crus fornicis** (Figs. 29, 38 and 39) may be traced from the uncus and the hippocampus, its chief origin, upward through the inferior horn and into the floor of the body of the lateral ventricle, where it unites with its fellow of the opposite side in forming the body of the fornix. At the apex of the body of the fornix, which is the anterior end, the bundles again separate and become the columnæ of the fornix. The crura are united at the back part of the body of the fornix by a few transverse and oblique fibers which form the lyre, or *commissura hippocampi* (Fig. 36). The commissure is best seen when the corpus callosum and fornix are viewed from below; its fibers connect each crus of the fornix with the hippocampus and uncus of the opposite side.

The **columnæ fornicis** (Figs. 29 and 40), one on either side pass down in front of the thalami, bounding the foramina interventricularia (Monroi); and then descend to the corpora mammillaria, at the base of the brain. On the way down, each columna (*pars libera*) passes behind the anterior commissure, beyond which (*pars tecta*) it pierces the inner part of the thalamus of the same side. The fibers of the columna fornicis for the most part terminate in the medial nucleus of the corpus mammillare, from which other fibers take their origin, forming the *fasciculus mammillaris princeps*. This bundle divides Y-like; the anterior branch is the *fasciculus thalamo-mammillaris* (Vicq d'Azyri) and ascends to the anterior nucleus of the thalamus; the posterior bundle is the tegmental part of the *fasciculus pedunculo-mammillaris* and probably ends in the stratum griseum centrale of the mid-brain.

At the lower border of the interventricular foramen a small bundle of fibers leaves the columna of the fornix and, bending backward, runs as *medullary stria* along the thalamus to the nucleus of the habenula; some of the fibers decussate through

the stalk of the pineal body to the opposite nucleus habenulæ and constitute the *commissura habenularum*. The columna of the fornix is joined by a small fasciculus from the medial root of the olfactory tract, which runs backward to the hippocampus and uncus.

The upper surface of the body of the fornix is convex from before backward (Figs. 29 and 36). It forms the postero-medial part of the floor of the lateral ventricle. Along the median line, it is joined to the corpus callosum by the septum pellucidum.

The **septum pellucidum** (Figs. 29, 35, 40 and 73), a double-walled median partition, divides the superior chamber of the fore-brain cavity into lateral halves, the *lateral ventricles*. The septum pellucidum is crescentic in outline. Its convex border fits into the concave surface of the body, genu and rostrum of the corpus callosum. Its concave border rests upon the fornix. Between the rostrum of the corpus callosum and the anterior commissure, the septum pellucidum is continuous with the gyrus subcallosus with which it is associated in development and function.

The septum pellucidum, like the anterior commissure, corpus callosum and fornix, is developed from the thickened upper border of the lamina terminalis and the adjacent medial wall of the cerebral hemisphere in front of the interventricular foramen. These several structures extend upward and backward with the development and rotation of the hemispheres and, together, roof over the inter-brain. A lymph space, the *cavum septi pellucidi*, appears in the septum and is commonly called the *fifth ventricle*. The fore-brain cavity thus embraces four ventricles, viz.:

- Two lateral ventricles (the ventricles of the hemispheres),
- Fifth ventricle (the ventricle of the septum), and
- Third ventricle (ventricle of the inter-brain).

THE FIFTH VENTRICLE.

(*Cavum Septi Pellucidi*.)

This is the ventricle of the septum (Figs. 35 and 73). The fifth ventricle is a very narrow, antero-posterior cleft between the walls of the septum pellucidum, with which it coincides in

extent. It is situated within the concavity of the corpus callosum between the lateral ventricles, above and anterior to the third ventricle. Below and posteriorly it is bounded by the fornix. It is not a part of the embryonic brain cavity, but a mere lymph space. Therefore it does not communicate with any other ventricle, each of the others being a part of the cavity of the neural tube from which both brain and cord are developed. Instead of ependyma, which lines other ventricles, the lining of the fifth is endothelium. A lymph-like fluid fills it.

THE LATERAL VENTRICLE.

(*Ventriculus Lateralis.*)

The hemispheres contain the largest of the six ventricles (Figs. 30, 35, 41, 42 and 73). Situated one on either side of the median line, the ventricles of the hemispheres are very naturally called the lateral ventricles. Each represents a branch of the cavity of the embryonic neural tube (Figs. 17 and 41). In consequence, the lateral ventricles communicate with all others except the fifth. By the interventricular foramen (of Monro), each directly communicates with the third ventricle; and through that, indirectly, with the fourth and sixth. The *foramen interventriculare* is situated between the front of the thalamus and the calumna of the fornix (Fig. 29). It extends between the anterior extremity of the third ventricle (the aulla) and the junction of the anterior horn with the central part of the lateral ventricle. The lateral ventricles are lined with ependyma, which is a transparent membrane composed of two layers when complete, viz., neuroglia and a covering of columnar ciliated epithelial cells. Over the thalamus (the part seen in the lateral ventricle) and the choroid plexus, the neuroglial layer is absent.

The lateral ventricle may be studied best in four parts: the central part (or body); the anterior horn; the inferior horn; and the posterior horn.

The **central part of the lateral ventricle** (Figs. 36, 39 and 40) is the ventricle of the parietal lobe of the cerebrum. The following are its boundaries:

Roof—Corpus callosum.

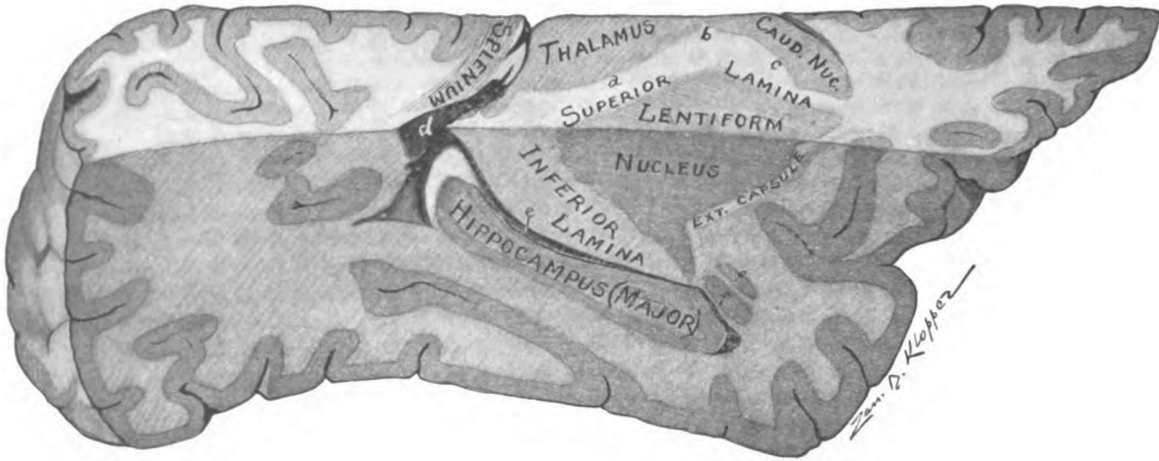


Fig. 32.—Sagittal section of basal part of right cerebral hemisphere showing inferior lamina of internal capsule, hippocampus, inferior horn of lateral ventricle. (*Original.*)

- a. Pars occipitalis. b. Genu. c. Pars frontalis of internal capsule. d. Beginning of posterior horn and e, inferior horn of lateral ventricle. ff. Nucleus amygdalæ.

Floor (from before, backward and inward)—

Caudate nucleus of the corpus striatum,
 Stria terminalis (tænia semicircularis),
 Thalamus (covered by epithelium),
 Lamina chorioidea epithelialis and chorioid plexus,
 Fornix.

Medial wall—Septum pellucidum.

External wall—Internal capsule.

The corpus callosum forms a complete roof for the central part of the lateral ventricle. The roof inclines upward and outward from the septum pellucidum, the inner wall of the ventricle, to

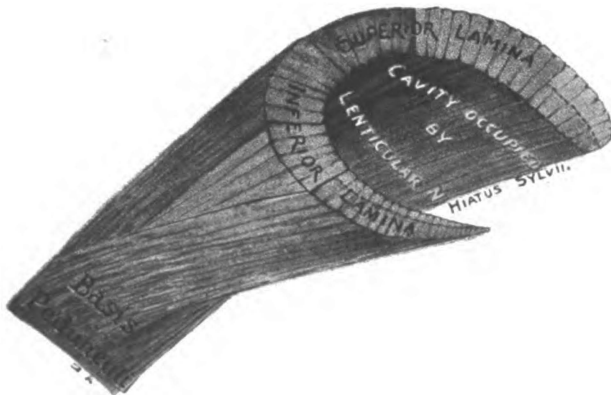


Fig. 33.—Diagram of internal capsule in colors. (*Original.*)
 RED, motor; BLUE, common sensory; PURPLE, special sensory.

the superior lamina of the internal capsule, which forms its outer wall. The floor of the central part of the ventricle is formed by the five parts, as named above, which will now be considered in the order given.

Corpus Striatum (Figs. 30, 31, 32 and 40).—The striated body is the basal ganglion of the hemisphere. It is an ovoid mass of gray matter imbedded, for the most part, in the cerebral medulla; but it is continuous below with the anterior perforated substance, and extends above to the lateral ventricle. It measures two and a half inches from before backward, an inch and a quarter

transversely, and, from above downward, one inch and a half. It is placed anterior and external to the thalamus and forms the third of the great divisions of the cerebral hemisphere, viz., the neopallium, the rhinencephalon and the corpus striatum. It is a reddish-gray body, and its streaked appearance is due to the white capsular fibers which pierce it. The striated body is an important relay in the motor conduction path and one of less importance in the sensory path. The internal capsule divides it into two nuclei, namely, the *lentiform nucleus* (extraventricular part), and the *caudate nucleus*, which is seen in the boundary of the lateral ventricle. Anterior to the free borders of the superior and inferior capsular laminæ, the two nuclei are united with each other, with the anterior perforated substance and with the lower end of the claustrum.

The **lentiform nucleus** (*nucleus lentiformis*) occupies the cone-like cavity of the internal capsule, by whose laminæ it is separated from the ventricle (Fig. 32). It is shorter fore and aft than the caudate nucleus. It resembles a biconvex lens with a somewhat thickened anterior border, when viewed in horizontal section (Fig. 31). In transverse vertical section through its center, it is triangular in shape. The hypotenuse and base are formed, respectively, by the superior and inferior laminæ of the internal capsule. The external capsule forms the perpendicular and separates the lentiform nucleus from the *claustrum*. The latter is a thin sheet of isolated gray matter, found just medial to the island (of Reil). In extent and position, fore and aft, the island and lentiform nucleus coincide. The lentiform nucleus is subdivided by two white laminæ, parallel with its external surface, into three zones. (Fig. 30). The outer zone, called the *putamen*, is deeply pigmented, and, like the caudate nucleus, is of a reddish-gray color; but the two inner zones, having less pigment, are of a pale yellowish tint. They form the *globus pallidus*.

The **nucleus caudatus** (the tailed nucleus) is a pear-shaped body of reddish-gray color, situated on the perimeter of the internal capsule (Figs. 30, 32 and 40). It is the intraventricular part of the striated body and forms a strip of the ventricular floor along the outer wall. The *head (caput)* of the caudate nucleus

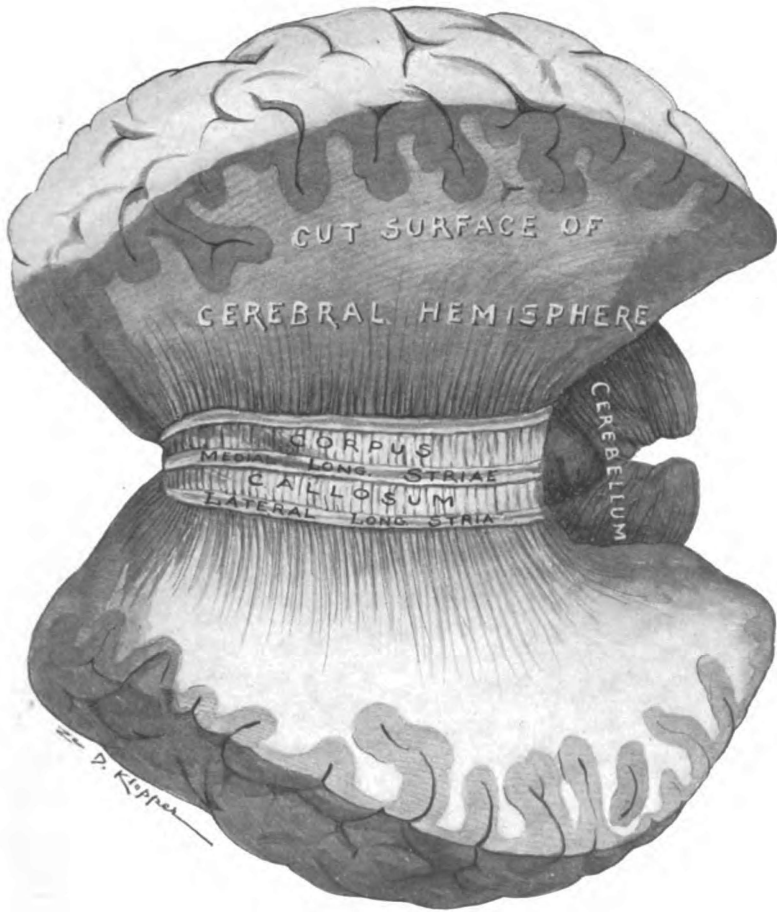

Fig. 34.—Dorsal surface of corpus callosum, cerebral hemisphere cut away to expose it. (*Original.*)

is directed forward. It is seen in the anterior horn of the lateral ventricle. From the head the nucleus tapers as it proceeds backward through the central part of the ventricle. Its *tail (cauda)* turns downward in the roof of the inferior horn, and ends in a considerable mass of gray substance called the *nucleus amygdalæ*, which appears to be an ingrowth of cortex from the region of the uncus hippocampi (Fig. 32). The caudate nucleus is covered on its ventricular surface by ependyma. The opposite surface, resting against the fibers of the internal capsule, is irregular and serrated.

The **stria terminalis** (*tænia semicircularis*, Figs. 30 and 36) lies just medial to the nucleus caudatus. It is a band of white fibers traversing the floor of the central part of the ventricle and the roof of its inferior horn, but covered by the terminal vein and by the ependyma. It may be said to rise from the nucleus amygdalæ. Ascending to the ventricle, it passes forward between the caudate nucleus and the thalamus to the interventricular foramen, where it divides into two bundles. One of them accompanies the column of the fornix for a little way. The other, passing over the anterior commissure, descends in front of it; and, according to Kölliker, both bundles end in the anterior perforated substance (Cunningham). The thin medial border of the substance covering the vena terminalis, which is attached to the thalamus, is called the *lamina affixa*; it is present only in the body of the ventricle. The lamina affixa is joined by a single layer of epithelium, the *lamina chorioidea epithelialis*, to the lateral border of the fornix. This lamina invests the chorioid plexus of the lateral ventricle. If the chorioid epithelium be torn away, the edge which remains on the stria terminalis is called the *tænia terminalis*.

Thalamus (Figs. 30, 31, 36 and 40).—A fusiform part of this ganglion of the inter-brain is visible in the floor of the lateral ventricle, between the stria terminalis and the chorioid plexus. It extends throughout the central part of the ventricle from the interventricular foramen to the inferior horn. A transparent layer of epithelium, the lamina chorioidea epithelialis, extending from the fornix to the stria terminalis and representing the hemi-

sphere wall, covers it. The thalamus will be described with the third ventricle and inter-brain.

The **chorioid plexus** (*plexus chorioideus*, Figs. 35, 36 and 37) of the lateral ventricle is the vascular border of the chorioid tela of the third ventricle. It projects, laterally, from beneath the fornix and its crus through the chorioidal fissure into the floor of the central part of the ventricle and the inner wall of the inferior horn. The epithelium, above mentioned, invests it; and it borders the fornix like a ruffle. It is called chorioid plexus (*chorion*, a membrane) because it is membrane-like. At the junction of the central part and inferior horn of the lateral ventricle the chorioid plexus presents a large skein-like mass called the *glomus chorioideum* (Fig. 36). The anterior chorioidal artery from the internal carotid and the postero-lateral chorioidal, a branch of the posterior cerebral, supply the plexus. The former pierces the temporal lobe and enters the apex of the inferior horn of the ventricle; the latter passes in through the transverse and chorioidal fissures of the cerebrum, following the chorioid tela. The chorioidal vein carries the blood away. At the foramen interventriculare, it is joined by the terminal vein of the striated body and the veins of the septum pellucidum and forms the internal cerebral vein. The internal cerebral vein courses backward in the chorioid tela and unites with its fellow of the opposite side, proximal to which union it receives the basilar vein; and then the great cerebral vein (of Galen), uniting with the inferior sagittal sinus, forms the straight sinus.

The floor of the central part of the lateral ventricle is completed by the superior surface of the fornix.

The **horns of the lateral ventricle** are three in number; the anterior, inferior and posterior (Figs. 39, 40 and 41).

The **anterior horn** (*cornu anterius*, Figs. 35, 36 and 73) projects from the central part of the ventricle forward and outward around the head of the caudate nucleus. It is the ventricle of the frontal lobe and is deep and narrow. Its boundaries are as follows:

Roof—Corpus callosum (forceps minor).

Floor—Rostrum.

Anterior wall—Genu.

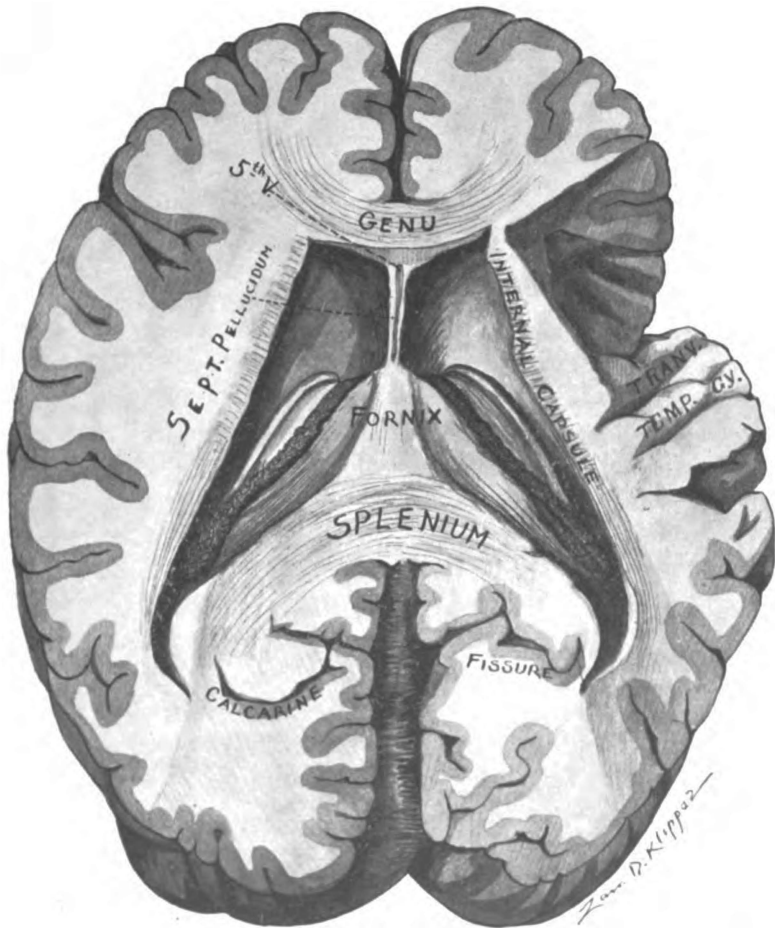


Fig. 35.—Horizontal section of cerebrum, cutting splenium and genu of corpus callosum, showing lateral ventricles, septum pellucidum, fornix and transverse temporal gyri. (Original.)

Inner wall—Septum pellucidum.

Outer wall—Caudate nucleus.

The **posterior horn** (*cornu posterius*, Figs. 35, 36, 38, 39, 40 and 41) is directed backward and downward in a curve concave inward, from the ventricular center into the occipital lobe; and, like the occipital lobe, it first makes its appearance in the fifth month of embryonic life. Its extremity bends medially toward the posterior calcarine fissure, with which the horn is parallel. The anterior calcarine fissure produces the ridge along the inner wall called the *calcar avis*. The posterior horn is roofed over by fibers from the splenium of the corpus callosum, which turn down outside the horn and also form part of the external boundary. In the external wall and in the roof and floor is also the optic radiation. A well-marked bundle of fibers from the splenium, *forceps major*, is found passing along the medial border of the roof into the occipital lobe. It produces an eminence above the calcar avis, called the *bulb*. The anterior extremity of the posterior horn is continuous, inferiorly, with the beginning of the inferior horn. At the junction of the two is a triangular area, the *trigonum collaterale*.

The **inferior horn** (*cornu inferius*, Figs. 32, 38, 39 and 41) is the ventricle of the temporal lobe. Its course is crescentic, as it follows the perimeter of the internal capsule. It first runs outward and backward from the body of the ventricle, then it turns downward, and finally it proceeds horizontally forward and inward to within an inch of the pole of the temporal lobe. In horizontal section just below the general cavity of the ventricle, the inferior horn is triangular. In that position it has a *posterior wall* (or floor in the horizontal part), a *medial wall*, and a curved *antero-lateral wall* (or roof in the horizontal portion) which is continuous above with the outer wall and floor of the central part of the ventricle.

The parts found in the walls of the inferior horn may be enumerated as follows:

Roof (or antero-lateral wall)—

Inferior lamina of internal capsule, partially covered by tail of caudate nucleus, stria terminalis and amygdala.

Tapetum Floor (or posterior wall)—

Eminentia collateralis (trigonum collaterale),
Hippocampus,
Crus of fornix.

Inner wall (medial)—

Epithelium (of hemisphere wall) covering
Pulvinar,
Chorioid plexus,
Chorioidal fissure, and
Dentate fascia.

The structures in the **roof** of the inferior horn have been sufficiently described. They are easily understood when it is recalled that the roof of the horn is continuous with the outer wall and floor of the central part of the ventricle; the *tapetum*, the *internal capsule* (inferior lamina), the *cauda*, *amygdala* and the *stria terminalis* form it.

Beginning at the *trigonum collaterale* (Figs. 38 and 39) and extending along the outer border of the **floor** to the end of the inferior horn there is sometimes a low ridge caused by the collateral fissure. It is the *eminencia collateralis*, and is present only when the anterior part of the collateral fissure, as well as the middle part, is a complete fissure. The short eminence at the entrance to the inferior horn, called the trigonum collaterale, is constant in its presence; it is produced by the middle division of the collateral fissure. In front of this eminence and internal to it is a prominent ridge, the *hippocampus*, which enlarges downward to a lobulated extremity, called the digitations (*digitationes hippocampi*, Fig. 39). The ridge is due to the infolding of the floor over the hippocampal fissure on the medial surface of the cerebrum. The ventricular surface of the hippocampus is formed by a lamina of white matter, the *alveus*, but the deeper part is cortical matter composed almost entirely of pyramidal cell-bodies. The *crus of the fornix* (*fimbria hippocampi*) rests in the concavity of the hippocampus, where most of its fibers originate, though a small bundle of them passes beyond it to its origin in the uncus.

The *chorioid epithelium* (*lamina chorioidea epithelialis*) (Figs. 118, 62 and 35), representing the hemisphere wall, forms the floor of the chorioidal fissure and the whole **medial wall** of the

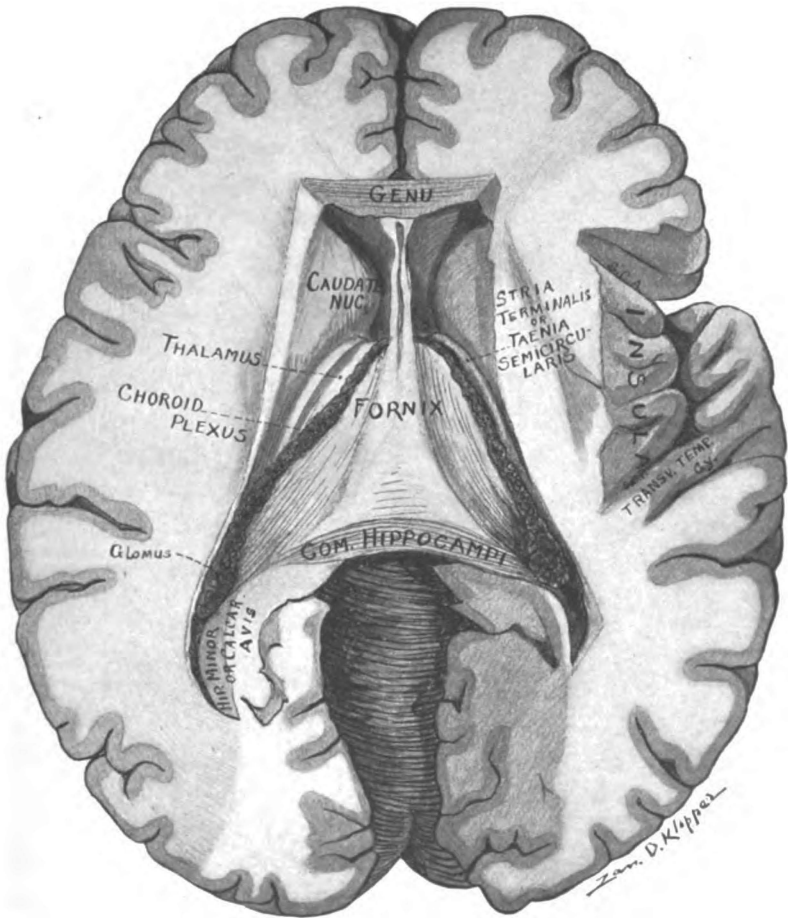


Fig. 36.—Horizontal section of cerebrum just below splenium of corpus callosum, showing commissura hippocampi, fornix, septum pellucidum, the island and lateral ventricles. (*Original.*)

S. C. A. Sul. circularis anterior. S. C. P. Sul. circularis posterior.

inferior horn. It covers the cushion-like projection (the pulvinar) of the thalamus, which forms a small part of both roof and inner wall. Behind, it is attached to the crus of the fornix, from which it extends forward to the stria terminalis. The epithelium covers the *chorioidal fissure* except at the lower part, where there is a small cleft which forms a communication between the horn and the anterior subarachnoid space. Through the chorioidal fissure a fold of pia mater projects toward the ventricle, and pushing the epithelium before it into the horn, forms the *chorioid plexus* (Figs. 35 and 36). Bounding this part of the chorioidal fissure below and behind, there is a serrated free border of cortex called the *dentate fascia*. The dentate fascia (Figs. 38, 42 and 62) folds medially in front of the hippocampal fissure and with the hippocampus, the gyrus hippocampi and the eminentia collateralis forms an *S-shaped fold* of the cortex. The S-shape is perfect in the left hemisphere, when the anterior segment of a coronal section is viewed from behind. The top of the letter is the dentate fascia; the superior curve is the hippocampus, produced by the hippocampal fissure; the lower convexity is the gyrus hippocampi; the lower concavity, open toward the ventricle, is the groove between the hippocampus and the eminentia collateralis.

THE THIRD VENTRICLE AND INTER-BRAIN.

(*Ventriculus Tertius and Diencephalon.*)

The *inter-brain* (*diencephalon*) is median in position (Figs. 27, 28, 29, 30 and 40). It is situated beneath the fornix and the layer of epithelium extending from the border of the fornix to the stria terminalis. The chorioid tela of the third ventricle only intervenes between them. Laterally, it is bounded by the superior laminæ of the internal capsules. The ventricle of the inter-brain is the third in number. The **third ventricle**, therefore, is located in the median plane; and is at a lower level than the ventricles of the hemispheres. Through the interventricular foramina, its anterior part (the aula) communicates with each lateral ventricle, and the cerebral aqueduct connects it, behind, with the fourth ventricle (Figs. 17 and 41). The third ventricle is fissure-like.

It is a narrow, vertical cleft about an inch in length from before backward and a quarter of an inch broad at its widest part. It separates the thalami, and extends almost to the inferior surface of the cerebrum. The **roof** (Figs. 29, 36, 37, 40 and 42) follows the curve of the fornix and arches from the posterior commissure forward to the anterior commissure. There is a little recess above the anterior commissure and between the columnæ of the fornix, bounded in front by the inferior angle of the septum pellucidum, called the *recessus triangularis*, in which the roof and anterior wall meet. The **anterior wall** extends from the triangular recess down to the optic recess, at the angle between the lamina cinerea and the optic chiasma. This angle is so named because, on either side of it, there is a lateral extension of the third ventricle between the lamina terminalis and the columna of the fornix, which is located in the root of the embryonic optic vesicle. The **floor** (Fig. 28) describes two arches, convex toward the ventricle. The *first arch*, very convex and short, stretches between the optic recess and the infundibulum, in which the floor reaches its lowest point. The distance from the infundibulum to the anterior orifice of the cerebral aqueduct is spanned by the **second arch**. It is long and flat. Its posterior extremity is but a sixteenth of an inch below the posterior commissure; the anterior orifice of the cerebral aqueduct separates them. The ventricle is thus contracted behind to the size of the cerebral aqueduct, with which it is continuous. The **lateral walls** (Figs. 28 and 29) are close together throughout. At one point near the middle they come together and are joined by the massa intermedia (middle commissure). Antero-superiorly, the lateral wall is perforated by the *interventricular foramen* (of Monro). That foramen constitutes the slight separation between the front of the thalamus and the columna of the fornix. It opens into the lateral ventricle at the junction of the anterior horn with the central part. The ependyma which lines the third ventricle is continuous through the interventricular foramen with the lining of the lateral ventricle. But one layer of the ependyma is present in the roof of the ventricle; that is the epithelial layer. The third ventricle, like all true ventricles, is occupied by cerebro-spinal fluid.

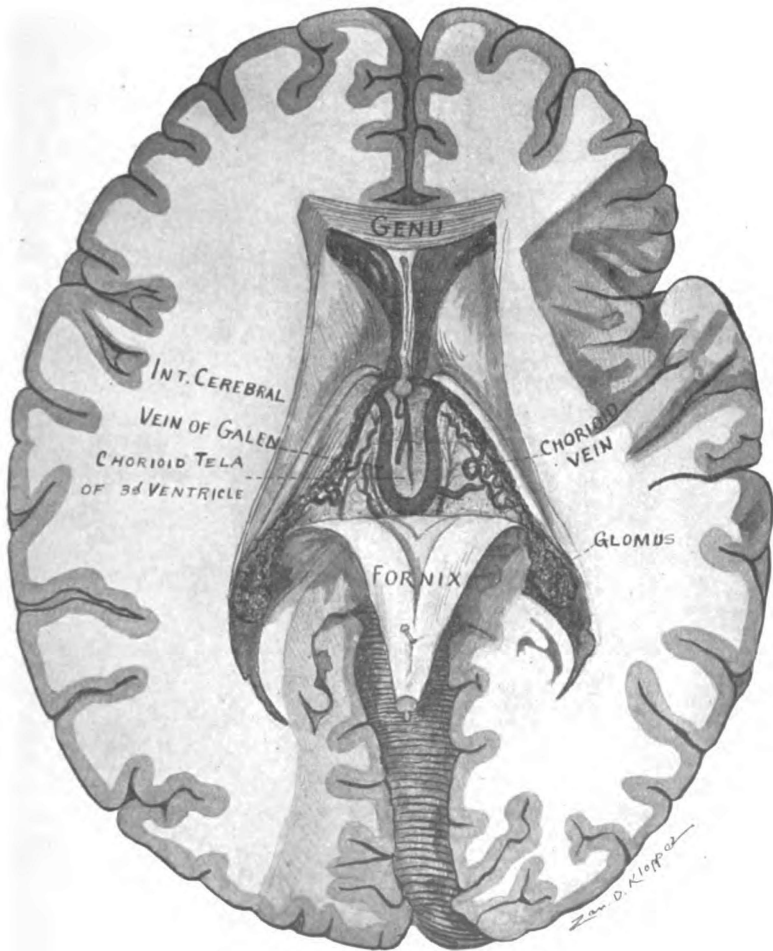


Fig. 37.—Horizontal section of cerebrum. Fornix turned back, showing chorioid tela of third ventricle, and internal cerebral veins. (Original.)

The following are the boundaries of the third ventricle:

Roof—

Posterior commissure and commissura habenularum,
Roof epithelium and pineal body,
Chorioid tela and plexuses,
Fornix and commissura hippocampi.

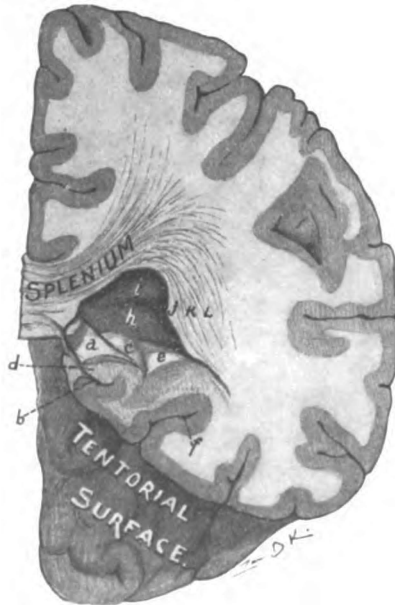


Fig. 38.—Transverse section of left cerebral hemisphere cutting the splenium and showing the posterior horn and the floor of the inferior horn of the lateral ventricle. (*Original.*)

a. Crus fornicis. b. Fis. hippocampi. c. Hippocampus. d. Fascia dentata. e. Eminentia collateralis. f. Fis. collateralis. h. Calcar avis. i. Bulb caused by forceps major. j. Tape-
tum. k. Radiatio occipito-thalamica. l. Fasciculus longitudinalis inferior.

Anterior wall—

Epithelium, covering
Columnæ of fornix, anterior commissure, and
Lamina terminalis.

Floor—

Optic commissure,
Tuber cinereum and infundibulum,
Corpora mammillaria,

Posterior perforated substance (of mid-brain),
Tegmenta (of mid-brain).

Posteriorly—

Ventricle is continuous with cerebral aqueduct.

Lateral walls—

Thalamus, and reflected hypothalamic substance,
Columna of the fornix, and

Foramen interventriculare between them.

Roof.—A band of white fibers passes across the back part of the third ventricle and supports the posterior end of the roof epithelium. That band is the **posterior commissure** (*commissura posterior*, Figs. 28 and 40). It crosses immediately in front of the corpora quadrigemina. Beneath it is the anterior orifice of the cerebral aqueduct. The pineal body is above and behind it, and the commissure fuses with the ventral pineal lamina. The posterior commissure stretches from the central gray substance of the mid-brain on one side, over the aqueduct, to the gray substance of the opposite side and also contains decussating fibers of the medial longitudinal bundle (Heald). The commissure is in need of further investigation.

The **roof epithelium** (Figs. 42 and 37) of the third ventricle stretches from the posterior commissure to the anterior commissure, and laterally, is attached to the upper internal border of the thalamus. It is the superficial layer of the ependyma; but it is, here, the only adult representative of the roof of the diencephalon. The roof epithelium presents two longitudinal folds suspended in the ventricle. The lower layer of the *chorioid tela of the third ventricle*, invests the roof epithelium superiorly; and, dipping down into the longitudinal folds, that inferior layer forms the *chorioid plexuses of the third ventricle*, which are continuous with those of the lateral ventricles through the interventricular foramina. At the back part in the middle line, there is a pouch-like evagination of the roof of the diencephalon in the embryo, which develops into the pineal body; and there remains a slight pit, called the *pineal recess*, in the adult condition. A second evagination occurs just above the pineal recess, which forms the *epipineal recess*.

Pineal Body. (*Corpus pineale*, Figs. 40, 43 and 76).—It is a

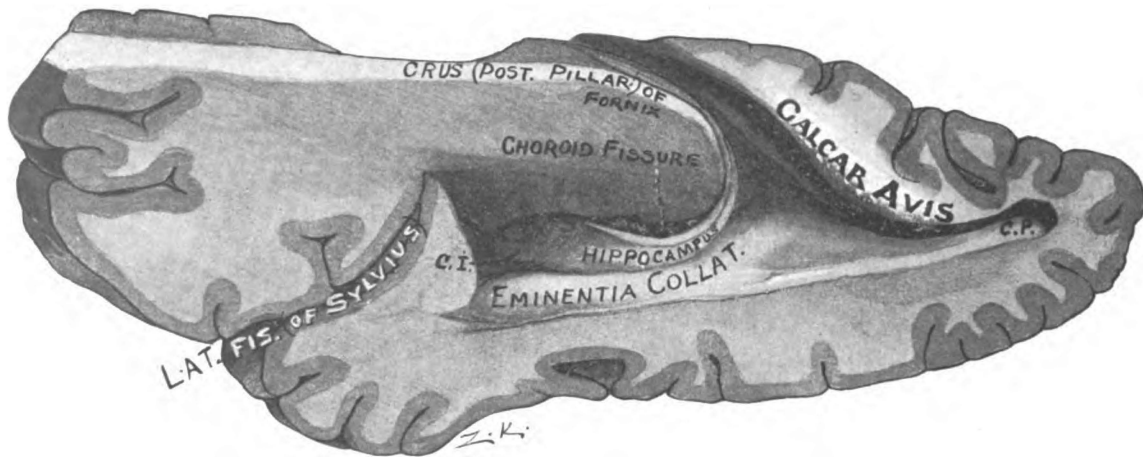


Fig. 39.—The inferior and posterior horns of the lateral ventricle, shown by removal of their lateral walls. (*Original.*)

C. I. Cornu inferius. C. P. Cornu posterius.

cone-shaped body, a quarter of an inch high and one-sixth of an inch in diameter, joined to the roof of the third ventricle by a flattened stalk or peduncle. It is also called the *epiphysis*. The pineal body is situated in the floor of the transverse fissure of the cerebrum, directly below the splenium of the corpus callosum and rests between the superior colliculi of the quadrigeminal bodies on the posterior surface of the mid-brain. It is closely invested by pia mater. The *pineal stalk* splits into a dorsal and a ventral lamina, which are separated by the pineal recess. The ventral lamina fuses with the posterior commissure; but the dorsal stretches forward over the commissure in continuity with the roof epithelium. The border of the dorsal lamina is thickened along the line of attachment to the thalamus and forms the *stria medullaris thalami* (*pineal stria*). The thickening is due to the presence of a bundle of fibers derived from the column of the fornix and the medial stria of the olfactory tract. Between the medullary striæ, at the posterior end, there is a transverse band, called the habenula. The habenula contains the *commissura habenularum*, through which the fibers of the striæ partially decussate to the nucleus habenulæ in the thalamus.

The interior of the pineal body is made up of closed follicles surrounded by ingrowths of connective tissue. The follicles are filled with epithelial cells mixed with calcareous matter, the brain-sand (*acervulus cerebri*). Calcareous deposits are found also on the pineal stalk and along the chorioid plexuses. The function of the pineal body is unknown. It is supposed to represent a cycloplan eye. In the Hatteria, a New Zealand lizard, it projects through the parietal foramen and presents an imperfect lens and retina and, in its long stalk, nerve fibers.

The **chorioid tela of the third ventricle** (*velum interpositum*, Figs. 37, 40 and 42) is the double triangular fold of pia mater spread over the dorsum of the inter-brain. It lies underneath the fornix and the chorioid epithelial lamina which stretches from the body of the fornix lateralward to the stria terminalis. Its apex is just behind the anterior commissure, and its base, directed backward, is continuous, by the upper layer, with the pia mater of the occipital lobes; and, by the inferior layer, it is

continuous with the pia on the posterior surface of the mid-brain and cerebellum. Each border constitutes the *chorioid plexus of the lateral ventricle*, and is seen (through the epithelium) in the floor of its central part. The median part of the inferior lamina of the chorioid tela invests the roof epithelium of the third ventricle, and, the lateral portion covers the medial half of the upper surface of each thalamus. This layer forms the two *chorioid plexuses of the third ventricle*, which depend from its median portion. Between the inferior and superior laminæ is enclosed some connective tissue through which the *internal cerebral veins* run backward to the base of the tela; there they unite and form the *great cerebral vein* (Galen).

Anterior Wall.—The **anterior commissure** (*commissura anterior cerebri*, Figs. 29, 40 and 73) is a very distinct round bundle of white fibers about an eighth of an inch in diameter. It is seen in the anterior wall of the third ventricle supporting the roof epithelium. The epithelium there bends down between the columnæ of the fornix and invests the ventricular surface of the commissure. The columnæ of the fornix and the commissure bound the *recessus triangularis*, in which the roof and anterior wall of the third ventricle meet. The anterior commissure rests upon the upper extremity of the lamina terminalis, between the columnæ fornicis, behind, and the lamina rostralis of the corpus callosum, in front. With the last two structures it is developed in the lamina terminalis. It is the most important connecting link between the hemispheres in vertebrates without a corpus callosum (all below mammals). Bending sharply backward in the cerebral hemisphere the anterior commissure pierces the inferior part of the globus pallidus and then radiates toward the cortex, some of its fibers entering the external capsule. It contains two groups of fibers: (1) The anterior group, which is the commissure of the rhinencephalon, called the *pars olfactoria*; and (2) the posterior group, the *pars occipito-temporalis*. The *pars olfactoria* probably contains two fasciculi: (a) A commissural bundle which bends sharply downward to the olfactory tracts and joins the two olfactory bulbs together; and (b) a decussating bundle which joins each olfactory bulb to the opposite

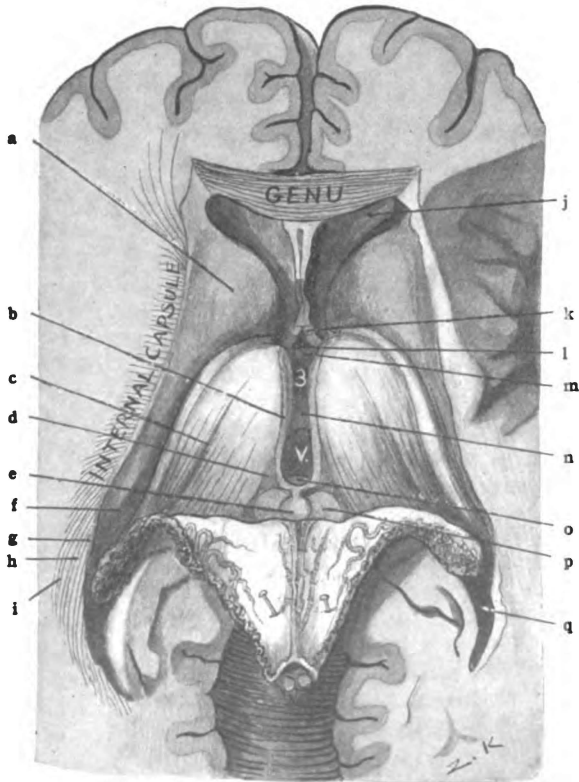


Fig. 40.—Horizontal section of cerebrum through genu and below splenium of corpus callosum. Fornix and chorioid tela turned back, to show inter-brain and third ventricle. (Original.)

a. Head of caudate nucleus. b. Stria medullaris thalami (or pineal stria.) c. Chorioid groove. d. Trigonum habenulae. e. Pineal body. f. Tail of caudate nucleus. g. Tapetum. h. Occipito-thalamic radiation. i. Inferior longitudinal fasciculus. j. Anterior horn of lateral ventricle. k. Columna of fornix. l. Recessus triangularis. m. Anterior commissure. n. Massa intermedia (or middle commissure). o. Posterior commissure. p. Superior quadrigeminal colliculus. q. Posterior horn of lateral ventricle.

uncus and amygdala. The *pars occipito-temporalis* connects the tentorial areas of the two hemispheres together, regions which are not connected by the corpus callosum. In man it is larger than the pars olfactoria. A thin transverse sheet of gray matter, called the **lamina terminalis**, extends downward and forward from the anterior commissure to the optic chiasma and completes the anterior wall of the ventricle (Figs. 17, 28 and 73). Between the chiasma and the lamina terminalis is a sharp angle which terminates on either side in a small pit, called the *optic recess*.

The **floor of the third ventricle** is very narrow (Figs. 21 and 27). It is formed by the interpeduncular structures plus the tegmenta, namely: optic chiasma, tuber cinereum and infundibulum, corpora mammillaria, posterior perforated substance and the tegmenta. The last two are portions of the mid-brain; the others belong to the fore-brain with the surface of which we have already studied them, and all extend laterally beneath the thalami.

The third ventricle has its **lateral wall** formed chiefly by the thalamus and the column of the fornix (Figs. 27 and 28). Below a slight longitudinal groove, extending from the optic recess to the cerebral aqueduct and called the *sulcus hypothalamicus*, the thalamus is covered by upturned hypothalamic gray matter and by the upper part of the central gray substance of the mid-brain. The thalamus forms the immediate lateral wall above this hypothalamic groove. The *columna of the fornix*, diverging from its fellow, proceeds downward and backward to the corpus mammillare through the medial part of the thalamus. In the ventricle, the pars libera of the columna fornicis is covered by the ependymal epithelium. It bounds the interventricular foramen in front.

Thalamus. (*Thalamus—a bed*, Figs. 40, 42, 43 and 44).—It is the great ganglion of the inter-brain. The thalamus is an important sensory relay station. In it or in the hypothalamic nuclei almost every impulse of general sensation, in its journey to the cerebral cortex, is transferred to a higher neurone. The third ventricle separates the thalami from each other, except at the mid-point where they are joined by the *massa intermedia*. The thalamus is situated behind and medial to the corpus striatum,

and projects backward over the mid-brain. Laterally, it rests against the superior lamina of the internal capsule, which separates it from the lentiform nucleus. The thalamus is shaped like an egg, with the small end directed forward. It has an anterior and a posterior extremity and four surfaces: Superior, inferior, medial and lateral.

Extremities.—The *anterior extremity* of the thalamus is lost in a large group of fibers (frontal stalk) which runs through the frontal part of the internal capsule. The *posterior end* (Fig. 44) presents a large pillow-like prominence, the *pulvinar*, and beneath it, are two smaller swellings; the outer one, which forms the lowest point of the thalamus, is the *lateral geniculate body*; the *medial geniculate body* is the other. The two geniculate bodies constitute the *metathalamus* (Fig. 43).

Surfaces.—The **medial surface** of the thalamus forms the immediate lateral wall of the third ventricle as far down as the sulcus hypothalamicus (Fig. 28). It is joined to the internal surface of the opposite thalamus by the massa intermedia. It is bounded above by the medullary stria. The **superior surface** is composed of a thin lamina of longitudinal white fibers, derived from the optic tract and radiation, called the *stratum zonale*. The superior surface of the thalamus is divided by an oblique groove, the *chorioidal groove*, corresponding in position to the border of the fornix, into two areas—a medial and lateral (Fig. 44). The *medial area* is covered by the chorioid tela of the third ventricle and the fornix. Internally, it is bounded by the medullary stria of the thalamus. Posteriorly, next the stria, is a triangular depression bounded, behind, by a transverse groove in front of the corpora quadrigemina, and by a slight groove, the sulcus habenulæ, externally. That depressed surface is called the *triangle of the habenula* (trigonum habenulæ). Beneath the triangle is one of the thalamic nuclei, the *nucleus habenulæ*. The *lateral area* of the superior surface is seen in the floor of the lateral ventricle. It presents an anterior elevation, the *anterior tubercle* (*tuberculum anterior thalami*), beneath which is the *anterior nucleus* of the thalamus. The chorioid sheet of epithelium, extending from the fornix to the stria terminalis, covers this outer

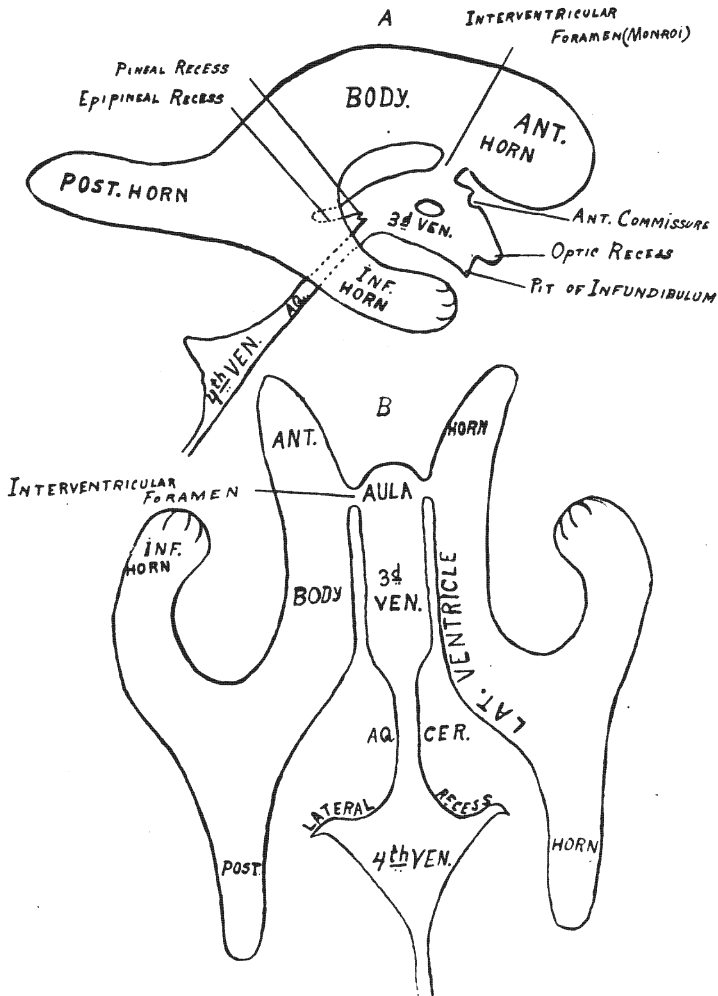


Fig. 41.—Lateral and dorsal view of the ventricles. Diagrammatic. (Original.)

A. Lateral view of the ventricles. B. Dorsal view of the ventricles.

area and separates it from the ventricular cavity. A lamina of fibers, the external medullary lamina, forms the **lateral surface** of the thalamus and rests upon the superior lamina of the internal capsule. Its fibers are continuous with those of the capsule. The **inferior surface** blends with the superior surface of the tegmentum and substantia nigra, and forms the laminæ and nuclei of the *tegmental hypothalamic region*. (See below.)

Tegmental Hypothalamic Region (Figs. 30 and 42).—The *regio tegmentalis hypothalami* is composed of three layers: (1) Stratum dorsale next the thalamus; (2) zona incerta, the middle; and (3) hypothalamic nucleus, the inferior. The **nucleus hypothalamicus** (*Luysi*) is ventro-lateral in position and lies between the base of the internal capsule and the zona incerta. Like the substantia nigra just below it, it is composed of pigmented gray matter. The reticular formation of the tegmentum, continuing beneath the thalamus, forms the **zona incerta**. The **stratum dorsale** is made up as follows: (a) Fibers from the medial longitudinal bundle (Meynert); (b) the brachium conjunctivum (Forel), in which is the upper end of the red nucleus of the tegmentum; and (c) the medial fillet, which runs lateral and slightly ventral to the red nucleus.

The **lateral geniculate body** (*corpus geniculatum laterale*, Fig. 43) forms a slight swelling at the lowest point of the thalamus. It marks the apparent end of the lateral root of the optic tract and is the terminal nucleus of eighty per cent. of its fibers. It is joined to the superior quadrigeminal eminence by the brachium superius. In appearance it is dark colored and laminated; its gray matter, which contains pigmented multipolar cell-bodies, is divided into thick layers by thin laminæ of fibers from the optic tract and radiation. The processes of the multipolar cell-bodies help to form the optic radiation.

The **medial geniculate body** (*corpus geniculatum mediale*), also belongs to the inter-brain and, together with the lateral geniculate body, constitutes the *metathalamus* (Fig. 43). It is placed at the end of the medial root, as the lateral geniculate is at the end of the outer root, of the optic tract. It rises up from the groove between the thalamus and corpora quadrigemina,

and is joined to the inferior quadrigeminal eminence by the brachium inferius. The brachium superius sweeps around it in front. The medial geniculate body is gray in color and is not laminated. Its cell-bodies are small, and fusiform in shape. They perhaps give origin to the intercerebral fibers (Guddeni) of the optic tract and to a large part of the acoustic radiation.

CEREBRUM.

SECTION II. THE MID-BRAIN.

(MESENCEPHALON.)

The third division of the cerebrum is the mid-brain (Figs. 44 and 45). It is situated below and behind the inter-brain and forms the connecting link between the fore-brain and the hind-brain. This has suggested the name "isthmus," sometimes applied to it: *though isthmus rhombencephali* refers only to the constriction below the corpora quadrigemina. The mid-brain is developed from the middle of the brain vesicles, the *mesencephalon* (Figs. 16, 17 and 18). The cavity of the mesencephalon persists as the cerebral aqueduct, which is reduced to a slender canal by the thickening of its walls, roof and floor, due largely to the ingrowth of fibers from other parts of the brain. The cerebral hemispheres almost conceal the mid-brain from view; they overhang it dorsally, and the temporal lobes, inclosing it between them, bend medially and cover part of its anterior surface. Only the median part of the anterior surface is visible in the complete brain (Fig. 21). The form of the mid-brain resembles a flattened cylinder. Its axis, a half inch long, is pointed upward and forward, and its long diameter, which varies from an inch to an inch and a half in length, is directed transversely.

SURFACES.

The mid-brain has four surfaces, viz., the anterior and posterior, which are free, and the superior and inferior, representing the ends of the cylinder, which are attached. The two latter are parallel with each other and are formed by section.

The **superior surface**, sloping downward and forward, meets

the anterior surface at an acute angle. Its inclination is that of the posterior end of the floor of the third ventricle. External to the floor of the ventricle, it is attached to the thalami and internal capsules. The blending of it with the thalami forms the structures of the tegmental hypothalamic regions, and the continuations of the extreme lateral portions, the bases pedunculi, enter into the internal capsules of the hemispheres. In the median line

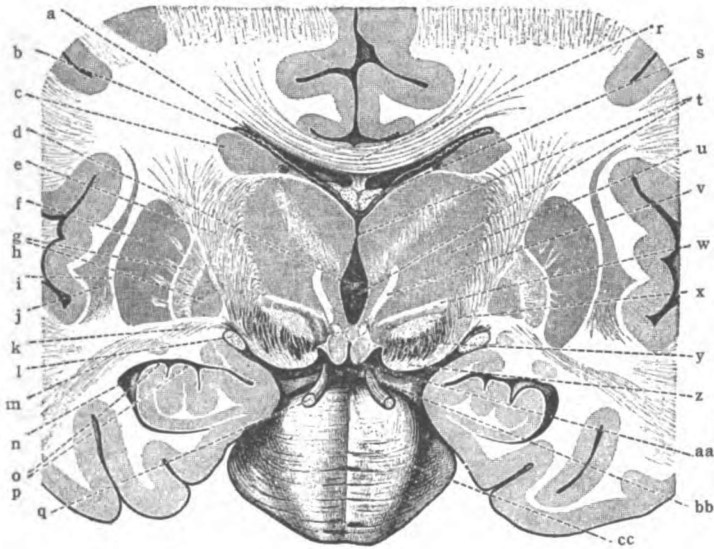


Fig. 42.—Transverse section of brain, cutting corpora mammillaria.
(After Toldt, *Morris's Anatomy*.)

a. Lateral ventricle (central portion). b. Chorioid plexus of lateral ventricle. c. Caudate nucleus. d. Massa intermedia. e. Internal capsule. Lenticular nucleus: f. Putamen; g, h. Zones, globus pallidus. i. External capsule. j. Claustrum. k. Ansa penduncularis. l. Optic tract. m. Inferior peduncle of thalamus. n. Inferior cornu of lateral ventricle. o. Hippocampus. p. Digitations. q. Oculomotor nerve. r. Corpus callosum. s. Fornix. t. Third ventricle. u. Thalamus. v. Thalamo-mammillary fasciculus. w. Ansa lenticularis. x. Hypothalamic nucleus (corpus Luysi). y. Substantia nigra. z. Basis of cerebral peduncle. aa. Corpus mammillare. bb. Interpeduncular fossa. cc. Pons (varolii.)

behind the third ventricle it is attached to the posterior commissure. The superior surface is an inch and a half broad.

The **inferior surface** joins the upper surface of the pons. It is a little narrower than the superior surface. It is about one inch and a quarter broad and measures an inch dorso-ventrally.

The **anterior surface (ventral)** of the mid-brain looks forward and downward (Figs. 45, 47 and 48). It is deeply grooved longit-

udinally by a median sulcus, the *fossa interpeduncularis*, and is slightly concave from above downward. It is separated on either side from the posterior surface by the *sulcus lateralis mesencephali*. Though partially concealed by the temporal lobes of the cerebrum, the anterior surface is unattached. It is formed by a prominent band, the *basis pedunculi* at either side; and by a median structure, the *posterior perforated substance* which is inclosed between the two bases. The posterior perforated substance forms the floor of the median sulcus. The inner border of the basis pedunculi is free and overhangs the perforated substance slightly. Thus is formed the *oculomotor groove* (*sulcus nervi oculomotorii*) between the basis and perforated substance whence the third cerebral nerve takes its apparent origin. The fourth nerve courses forward over the anterior surface, but is not attached to it.

The **posterior surface (dorsal)** of the mid-brain (Fig. 44), though free, is entirely concealed by the cerebellar and cerebral hemispheres. It forms part of the floor of the transverse fissure of the cerebrum and is covered by pia mater. The *lateral sulcus* bounds it on each side. From the sulcus lateralis it elevates abruptly toward the median line, where it presents a longitudinal groove. This produces two ridges which are subdivided by a transverse groove into the four eminences, the *colliculi* of the *corpora quadrigemina*. On either side, anterior and a little external to the quadrigeminal bodies, is the medial *geniculate body*, joined to the inferior quadrigeminal colliculus by an oblique ridge, called the *brachium inferius*. The nearly parallel longitudinal ridges below the corpora quadrigemina are formed by the *brachia conjunctiva of the cerebellum*. The bottom of the groove between them is formed by the *superior medullary velum* (of Vieussens); whence the *trochlear nerve* (fourth) is seen issuing.

Mid-brain	{	I. Corpora quadrigemina and Brachia.
	{	II. Pedunculi {
		1. Tegmenta
		2. Substantia nigra
		3. Bases pedunculi.

The four colliculi of the corpora quadrigemina and the four brachia connecting them with the geniculate bodies constitute

the *quadrigeminal lamina*, which forms the greater part of the posterior surface of the mid-brain (Fig. 44). This lamina rests upon the dorsum of the *pedunculi cerebri*. The pedunculi cerebri are made up of three great divisions, as shown above; named from before backward, they are: (1) The bases pedunculi, comprising the anterior part; (2) the substantia nigra, which is the middle part; and (3) the tegmenta, which are united by a median raphe

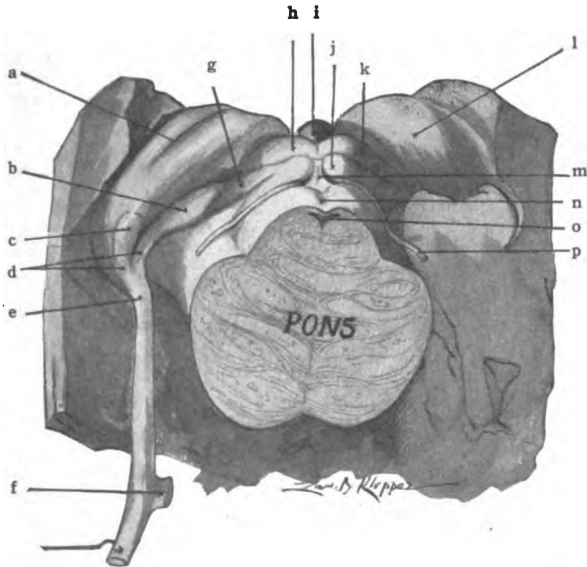


Fig. 43.—The region of the mid-brain showing pulvinar of the thalamus, the geniculate bodies, the corpora quadrigemina and brachia, the pineal body, the optic tract and the fourth nerve. (*Original.*)

a. Choroid groove. b. Medial geniculate body. c. Lateral geniculate body. d. Medial and lateral roots of optic tract. e. Optic tract. f. Optic chiasma. g. Brachium inferius. h. Superior colliculus of corpora quad. i. Pineal body. j. Inferior colliculus of corpora quad. k. Brach. superius. l. Thalamus. m. Frænulum veli. n. Superior medullary velum. o. Fourth ventricle. p. Trochlear nerve.

and lie in the posterior region next the quadrigeminal lamina. In the median plane between the quadrigeminal lamina and the tegmenta runs the *cerebral aqueduct*.

The **bases pedunculi** (Figs. 45, 46, 47 and 48) are two rounded bands of medullated fibers, limited by the interpeduncular fossa and lateral sulcus of the mid-brain. Each basis pedunculi is a half-inch broad and is distinctly striated longitudinally. It

issues from the under surface of the fore-brain at the junction of the hemisphere with the thalamus and, trending toward the median line, descends to the pons. At its superior end it is continuous with the motor tracts of the internal capsule. Four motor tracts make up the basis pedunculi, viz., the intermediate, the temporo-pontal, the pyramidal, and the fronto-pontal.

The **deep portion** of each basis pedunculi (Fig. 47) is occupied by the *intermediate bundle*, whose fibers rise in the corpus striatum and terminate in the nucleus pontis (Flechsig). The **superficial portion** should be studied in three parts.

(1) The *outer fifth* of each basis contains the **temporo-pontal tract** (*tractus cerebro-cortico-pontalis temporalis*). It is composed of efferent fibers which rise in the temporal cortex, in the superior, middle and inferior gyri (Dejerine); and, perhaps, in portions of the occipital lobe (Zacher) and the parietal lobe (Sioli). Proceeding through the inferior lamina and the occipital part of the superior lamina of the internal capsule, and through the lateral part of the basis pedunculi, they terminate chiefly in the nucleus of the pons; a few end in the motor nuclei of cerebral nerves (Spitzka). The fibers are probably interrupted and relayed in the thalamus or lentiform nucleus. They form a segment of the indirect motor path. These fibers are medullated later than the pyramidal tract (Flechsig).

(2) The *middle three-fifths* of the basis pedunculi (Figs. 47 and 48) is occupied by the **pyramidal tract** (*fasciculus longitudinalis pyramidalis*). Its fibers rise in the anterior central gyrus of the cerebral cortex; they run through the genu and anterior two-thirds of the occipital part of the internal capsule, form the middle three-fifths of the basis, a part of the anterior longitudinal fibers of the pons, and the pyramid of the medulla. Below the medulla they are continued in the anterior and lateral pyramidal tracts of the spinal cord. Those fibers of the pyramidal tract which innervate the *muscles of speech* and of the *face* run through the genu of the internal capsule and constitute the medial portion of the tract in the mid-brain and the accessory lemniscus (of Bechterew). Immediately behind the face fibers, in the capsula interna, and external to them, in the basis pedunculi, are fibers

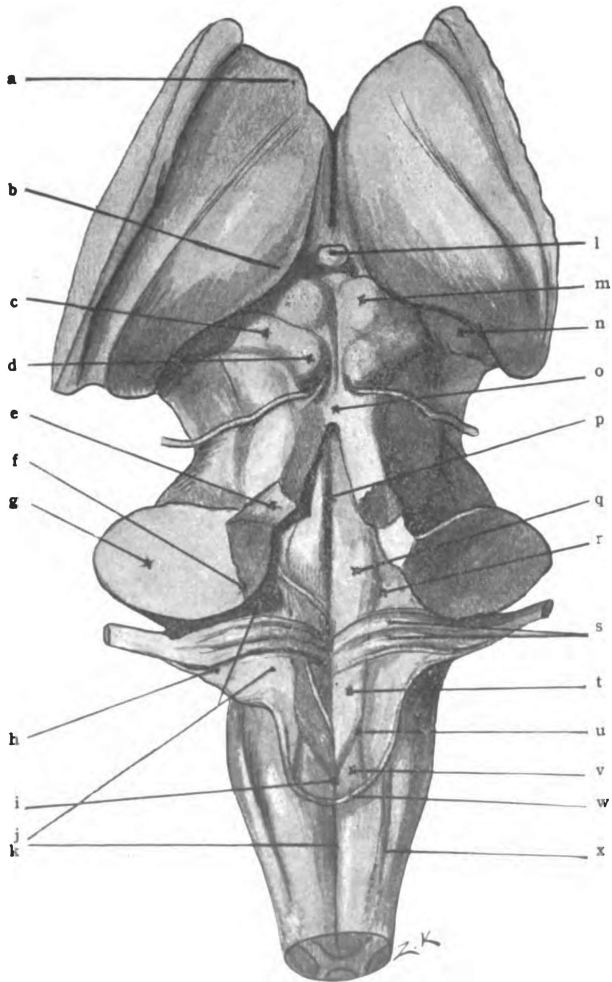


Fig. 44.—The dorsal or posterior aspect of the inter-brain, the mid-brain, the pons and the medulla. (*Original.*)

a. Anterior tubercle of thalamus. b. Pulvinar of thalamus. c. Brachium inferius. d. Inferior colliculus of corpora quad. e. Brachium conjunctivum. f. Corpus restiforme. g. Brachium pontis. h. Tuberculum acusticum. i. Calamus scriptorius. j. Area acustica. k. Posterior median fissure. l. Stalk of pineal body. m. Colliculus superior of corpora quad. n. Medial geniculate body. o. Superior medullary velum. p. Median groove. q. Colliculus facialis. r. Fovea superior. s. Medullary striae. t. Trigonum n. hypoglossi. u. Fovea inferior. v. Ala cinerea. w. Tænia ventriculi quarti. x. Posterior lateral sulcus.

which innervate the *muscles of the arm*. Still behind these, in the internal capsule, and external to them, in the pyramidal tract of the basis pedunculi, are fibers for the innervation of the *trunk and leg muscles*.

(3) The *inner fifth* of the basis pedunculi is composed of the **fronto-pontal tract** (*tractus cerebro-cortico-pontalis frontalis*) (Figs. 47 and 48). The origin of the latter is probably in the prefrontal cortex. It is motor. This motor tract is contained in the frontal part of the upper lamina of the internal capsule. According to Hoche, it is interrupted and relayed either in the thalamus or striated body (Barker). Its termination is in the nucleus of the pons and in the motor nuclei of cerebral nerves (Flehsig). It constitutes a stage of an indirect motor path, like the fibers of the outer fifth of the basis pedunculi, and the indirect path is continued to the opposite half of the cerebellum by neurones whose cell-bodies are in the nucleus pontis (Flehsig).

The Substantia Nigra (Figs. 46, 47 and 48).—The central part of the crura cerebri is a sheet of pigmented gray matter. The substantia nigra is visible at the base of the brain between the bases pedunculi, where it is called the *posterior perforated substance* (*substantia perforata posterior*), and its margin comes to the surface in each lateral sulcus of the mid-brain. It extends from the pons upward to the corpora mammillaria and nucleus hypothalamicus (Luysi). Dorsal to it are the tegmenta. Transversely, the substantia nigra is convex forward, but it is slightly concave longitudinally. The third nerve pierces it and comes out through the oculomotor groove. It contains small pigmented multipolar cell-bodies, some of which constitute a relay for certain fibers of the medial fillet (Barker). There is a median aggregation of these cells located just in front of the pons, the *interpeduncular ganglion* (*ganglion interpedunculare*). According to Forel, this ganglion is connected by a bundle of fibers, the fasciculus retroflexus, with the nucleus habenulæ of the thalamus. The superior portion of the substantia nigra lies ventral to the *nucleus hypothalamicus* (Luysi) on either side. The nucleus hypothalamicus lies ventro-lateral to the red nucleus, and is separated from it by the zona incerta.

The Tegmenta (Figs. 46, 47 and 48).—The posterior divisions of the pedunculi cerebri, which cover the other divisions, are in consequence called the tegmenta (tegmentum—a cover). They are united by a median raphe and fit ventrally into the concavity of the substantia nigra. They are bounded by the lateral sulcus of the mid-brain on the free side, where each tegmentum presents a *triangle*, bounded by the sulcus lateralis, in front; by the brachium inferius, above; and, inferiorly, by the lateral fillet. Dorsally, the tegmenta fuse with the quadrigeminal lamina except along the median line, where the *cerebral aqueduct* separates them. Each tegmentum at the superior end blends with the thalamus, and helps to form the tegmental hypothalamic structures. Imbedded in that superior portion is the red nucleus (n. ruber) of the tegmentum. (See tegmental hypothalamic region.) Inferiorly, the tegmenta are continued into the reticular formation of the pons.

The Cerebral Aqueduct (Aqueductus Cerebri, Sylvii, Figs. 17, 27 and 47).—The aqueduct is a very slender canal connecting the third and fourth ventricles. So it is the “iter a tertia ad quartum ventriculum.” It is situated in the median line under the quadrigeminal lamina and produces a slight beveling of the dorso-medial borders of the tegmenta. It is a half-inch long. In shape it is v-like, above; elliptical, in the middle, with a vertical major axis; and T-form, below, where it joins the fourth ventricle. Its height varies between a sixteenth and an eighth of an inch. Like other ventricles, it is lined with ependyma. A layer of gray matter, thickest on the sides and floor, surrounds the aqueduct of the cerebrum. This is the *stratum griseum centrale*, which gives rise to some of the fibers of the posterior commissure. The stratum griseum centrale is continuous with the gray matter of the fourth ventricle. In the ventral part of it are the nuclei of the oculomotor (third), the trochlear (fourth) and the trigeminal (fifth) cerebral nerves.

Nuclei of the Oculomotor and Trochlear Nerves (Figs. 47 and 48).—Both nuclei together extend the entire length of the aqueduct, and the oculomotor is prolonged into the wall of the third ventricle, where it receives a bundle of fibers from the opposite

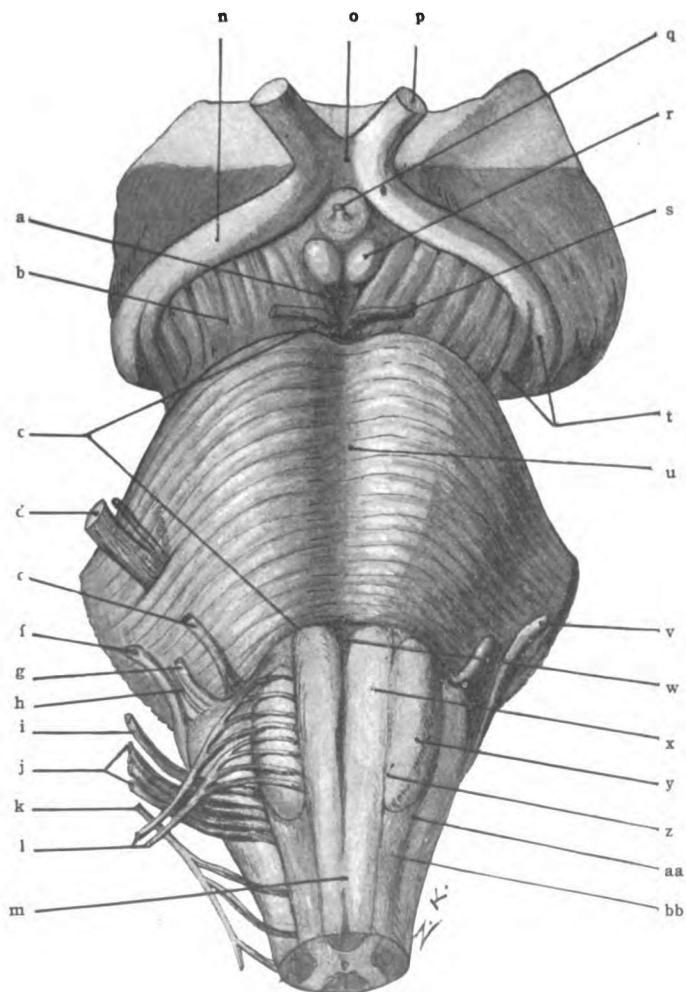


Fig. 45.—Anterior aspect of the mid-brain, pons and medulla. (Original).

a. Interpeduncular fossa. b. Basis pedunculi. c. Pons. d. Trigeminal nerve. e. Abducent nerve. f. Acoustic nerve. g. Facial nerve. h. Intermediate nerve. i. Glossopharyngeal nerve. j. Vagus nerve. k. Accessory nerve. l. Hypoglossal nerve. m. Anterior median fissure. n. Optic tract. o. Optic chiasma. p. Optic nerve. q. Stalk of infundibulum. r. Corpus mammillare. s. Oculomotor nerve. t. Medial and lateral roots of optic tract. u. Sulcus basilaris. v. Acoustic nerve. w. Foramen cæcum (Vicq d'Azyri). x. Pyramid. y. Olive. z. Anterior lateral sulcus. aa. Posterior lateral sulcus. bb. Funiculus lateralis.

optic radiation and optic tract. The **nucleus of the third nerve** (*n. oculomotorius*), according to Perlia, is composed of seven distinct cell-groups, scattered from the posterior part of the lateral wall of the third ventricle down to the level of the transverse groove between the superior and inferior quadrigeminal colliculi. From these seven cell-groups the axones proceed forward into the nerve of the same side; but there is, in addition, one median group of cell-bodies which sends axones into both nerves. The nuclei are also associated by decussating dendrites. The root fibers run forward through the red nucleus and substantia nigra and issue from the oculomotor groove. The **nucleus of the fourth nerve** (*n. trochlearis*) is a single oval mass of cell-bodies situated ventral to the inferior colliculus of the corpora quadrigemina. The root fibers of the fourth nerve, trochlear, proceed dorsally and caudalward from the nucleus. They decussate with the fibers from the opposite nucleus in the superior medullary velum, from which they emerge on either side of the frenulum. They then continue in the opposite nerve around the side and over the anterior surface of the mid-brain. This is the only nerve that decussates en masse between the genetic nucleus and the apparent origin.

The nucleus of the mesencephalic root of the trigeminal nerve is composed of large cell-bodies scattered in the extreme ventrolateral part of the stratum griseum centrale, from the highest level of the mid-brain down to the pons. There is no break between this nucleus and the chief motor nucleus of the fifth nerve formed by the substantia ferruginea under the locus cæruleus. The axones of these large cell-bodies run downward through the nucleus, accumulating gradually until they form a distinct crescentic strand, which joins the chief motor root of the same side.

The opposite pyramidal tracts and, probably, the three homolateral cerebro-pontal tracts (fronto-pontal, temporo-pontal and intermediate tracts) bring these nuclei into relation with the cerebral cortex; and the anterior and the medial longitudinal bundles establish their reflex relation.

Formatio Reticularis (Fig. 47).—Through the greater por-

tion of the tecta there are many oblique fibers interwoven with tracts of longitudinal fibers so as to produce a reticulum or net. Imbedded in the reticular formation ventral to each superior quadrigeminal colliculus is a mass of large cell-bodies constituting the *nucleus lateralis superior*. This is the first of the reticular nuclei and the only one in the mid-brain. Many of the oblique fibers of the formatio reticularis pass through the median raphe into the opposite tectum; they produce the *tegmental decussations*, which are situated at three successive levels, viz., the superior colliculus, the inferior colliculus and the isthmus rhombencephali.

The **tegmental decussations at the level of the superior quadrigeminal colliculus** (the fountain decussations) are: (1) The **dorsal tegmental decussation** (Meynerti) through which the anterior longitudinal bundle crosses. It is situated between the red nuclei but dorsal to them. (2) The **middle**—the decussation of the fasciculus pedunculo-mammillaris. (3) The **ventral tegmental decussation** (Foreli) in which the tract from the red nucleus, the rubro-spinal tract, crosses to the opposite side (Fig. 47).

At the level of the inferior colliculus (Fig. 48) is the decussation of the brachium conjunctivum (decussatio brachii conjunctivi). It crosses with its mate to reach the opposite red nucleus.

At the level of the isthmus is located the vestibular commissure, composed of fibers which connect the vestibular nuclei of the auditory nerve. Intermingled with the above bundles of crossing fibers there are many other fibers of the formatio reticularis.

Tracts of Fibers in the Tegmentum (Figs. 46, 47 and 48).—In the reticulum of the tectum there are eight distinct bundles of longitudinal fibers, viz., the anterior and the medial longitudinal bundles, the fillet, the spino-thalamic tract, the brachium conjunctivum (superior cerebellar peduncle), the rubro-spinal tract, the olivary bundle, and the descending root of the trigeminal nerve.

The **medial (or posterior) longitudinal bundle** (*fasciculus longitudinalis medialis*, Fig. 47) is a compact strand of fibers

running along the median raphe just ventral to the central gray substance. In Weigert-Pal sections it shows clearly as a dark triangle nearly one-sixteenth of an inch on a side. The tract will be found in the same relative position in the pons and medulla oblongata. In addition to several very small strands of fibers which will be explained later, the medial longitudinal bundle is

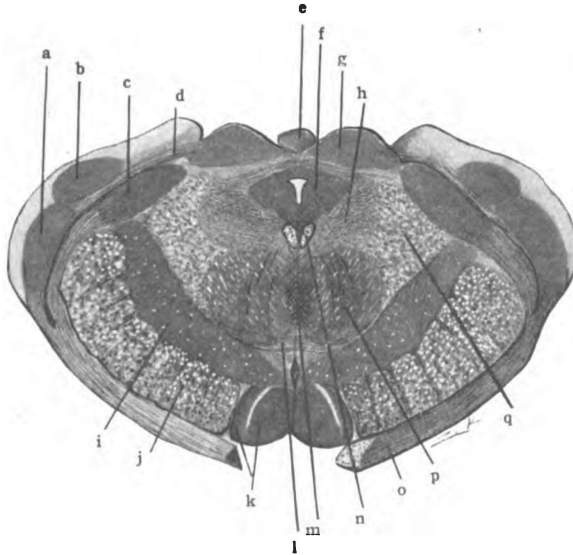


Fig. 46.—Transverse section through the corpora mammillaria and the superior colliculi of the corpora quadrigemina. (*Original.*)

a. Lateral geniculate body. b. Thalamus. c. Medial geniculate body. d. Brachium superius. e. Pineal body. f. Stratum griseum centrale. g. Superior colliculus of corpora quad. h. Formatio reticularis. i. Substantia nigra. j. Basis pedunculi. k. Medial and lateral nuclei of corpus mammillare. l. Ventral tegmental decussation (Foreli). m. Dorsal tegmental decussation (Meynerti). n. Medial longitudinal bundle. o. Optic tract. p. Red nucleus. q. Medial fillet.

functionally composed of two tracts: (1) An ascending bundle; and (2) a descending bundle.

(1) *The ascending part of the medial longitudinal bundle* is composed of fibers derived from the gray matter of the spinal cord and from the terminal nuclei of sensory cerebral nerves. It is the continuation of the long ascending fibers of the anterior fasciculus proprius. Possibly a small portion of the tract runs through the posterior commissure to the thalamus and is common sensory in function; but the major part of it decussates in several

successive strands which end in the opposite motor nuclei of the cerebral nerves. The function of this latter part is reflex.

(2) *The descending part of the medial longitudinal bundle* is composed chiefly of uncrossed axones from the large cell-bodies in the nuclei of the reticular formation. Beginning at the nucleus lateralis superior in the mid-brain, it receives fibers from each reticular nucleus down to the nucleus lateralis inferior of the medulla. It receives the largest accession of fibers in the pons, where the nucleus lateralis medius and the three nuclei centrales are located. On this account James S. Collier suggests that it be called the *medial ponto-spinal tract*. It has been traced through the anterior fasciculus proprius to the lower part of the spinal cord. Its size is gradually reduced by the ending of a few fibers in the gray substance corresponding to each segment of the cord.

In the mid-brain the medial longitudinal bundle also contains fibers derived—(1) from the oculomotor nucleus, which descend to the pons, and enter into facial nerve through which they supply the muscles of expression above the eye; and (2) from the nucleus of the abducent nerve. Running upward and decussating, the latter strand of fibers terminates in the opposite nucleus of the oculomotor nerve, and thus innervates the internal rectus of that eye. This strand accounts for the conjugate action of the two eyes in both health and disease.

The **anterior longitudinal bundle** forms a distinct strand situated in the formatio reticularis ventro-lateral to the medial longitudinal bundle (Figs. 47 and 48). It degenerates downward and is a descending tract. It takes its origin in the superior colliculus of the corpora quadrigemina, whence it decussates at once through the dorsal tegmental decussation (Meynerti) and descends through the reticular formation of the pons and medulla; and, then, through the fissural side of the anterior column of the spinal cord until it fades away in the lumbar region. Only by its degeneration has it been located. Its fibers end in the gray matter of the cord on both sides and in the genetic nuclei of cerebral nerves; but, chiefly, in the nuclei of the oculomotor, trochlear and abducent nerves and in the cilio-spinal center of the spinal

cord. In function the anterior longitudinal bundle is reflex; it is connected with all *ocular reflexes* which are excited by impulses from the retinae, such as, accommodation for distance, pupillary contraction and dilatation.

The **Fillet or Lemniscus** (Figs. 46, 47 and 48).—Near the upper end of the pons, in the ventral part of the formatio reticularis, the fillet, or lemniscus, forms a very broad band of fibers

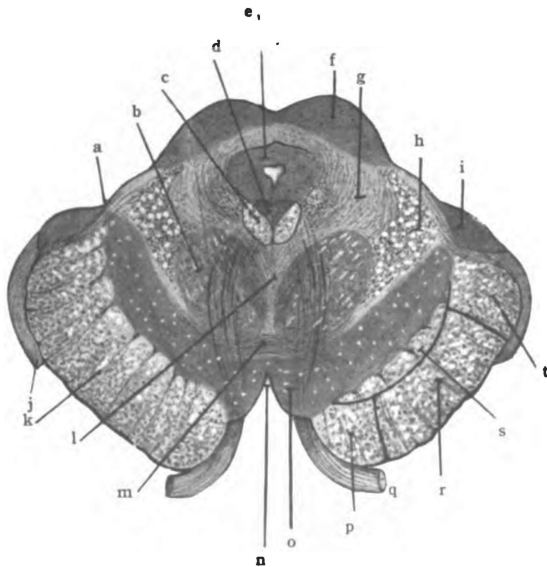


Fig. 47.—Section of the mid-brain through superior colliculi and the apparent origin of the oculomotor nerve. (*Original.*)

a. Sulcus lateralis of mid-brain. b. Red nucleus. c. Medial longitudinal bundle. d. Oculomotor nucleus. e. Stratum griseum centrale. f. Colliculus superior of corpora quadrigemina. g. Formatio reticularis. h. Medial fillet. i. Medial geniculate body. j. Optic tract. k. Basis pedunculi. l. Dorsal tegmental decussation (Meynerti). m. Ventral tegmental decussation (Foreli). n. Fossa interpeduncularis. o. Substantia nigra. p. Fronto-pontal tract. q. 3d. N. r. Pyramidal tract. s. Intermediate tract. t. Temporo-pontal tract.

on either side of the median raphe. The fillet is equal in width to half the transverse diameter of the mid-brain. It continues into the ventral portion of the tegmentum, but immediately divides into two fasciculi, viz., the *medial fillet*, and the *lateral fillet*. Farther forward a small bundle leaves the lateral part of the medial fillet and runs up to the superior quadrigeminal colliculus. That bundle is called the *superior fillet*.

Function.—The fillet forms a segment in the direct sensory tract. It carries spinal and cerebral impulses of the tactile and muscular senses to the corpora quadrigemina and thalamus, and auditory impulses to the inferior quadrigeminal colliculus.

Lemniscus { L. Medialis } L. Superior.
 { L. Lateralis }

Medial Fillet. (*Lemniscus medialis*, Figs. 47 and 48).—The fibers composing the medial fillet rise chiefly in the nucleus funiculi gracilis and nucleus funiculi cuneati of the opposite side of the medulla oblongata. They cross over in the fillet decussation of the medulla; and, excepting a small bundle, terminate in the lateral nucleus of the thalamus. Fibers are added from the terminal nuclei of sensory cerebral nerves which cross the median plane and enter the opposite fillet. Thus connected with all common sensory nerves, and with the vestibular nerve, it enters the mid-brain and divides into two parts. A small bundle of fibers separating from the lateral part and running to the superior quadrigeminal colliculus, forms the **superior fillet**. It associates ocular movements with sensations from cerebral and spinal nerves. The medial fillet continues to the lateral nucleus of the thalamus, bearing impressions of the tactile and the muscular sense. From the thalamus the impulses are carried by the *cortical fillet* to the somæsthetic area of the cortex.

The **lateral fillet** (*lemniscus lateralis*) forms an oblique ridge on the lateral border of the tegmentum (Fig. 44). It trends upward and inward over the brachium conjunctivum to the inferior quadrigeminal colliculus where some of its fibers terminate. A few fibers continue to the superior colliculus. Its *function is auditory conduction*. It rises chiefly from the ventral and lateral parts of the cochlear nucleus (principally the opposite one) and ends in the inferior quadrigeminal colliculus. The greater number of its fibers cross through the trapezoid body and medullary striæ, some are uncrossed. It undergoes partial relay in the nucleus of the superior olive and nucleus of the trapezoid body on both sides and the nucleus of the lateral fillet on the same side.

The lateral fillet is only partially relayed in the inferior col-

liculus of the corpora quadrigemina, being continued directly into the brachium inferius. Auditory conduction therefore proceeds from the inferior colliculus through the brachium inferius to the medial geniculate body and then through the acoustic radiation to the temporal cortex. Thus the lateral fillet forms the

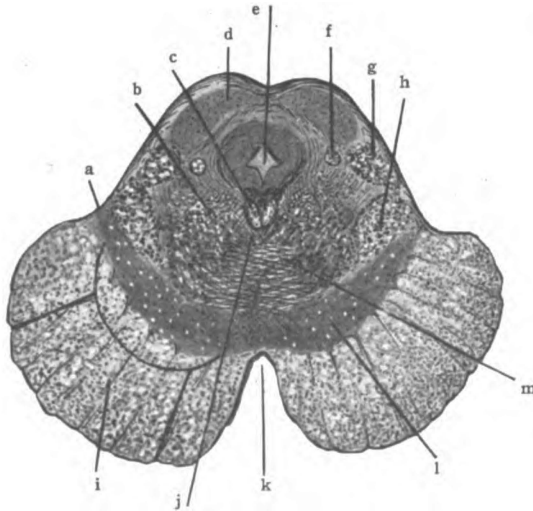


Fig. 48.—Section of the mid-brain cutting the inferior colliculi of the corpora quadrigemina. (Original)

a. Sulcus lateralis. b. Formatio reticularis. c. Medial longitudinal bundle. d. Nucleus of colliculus inferior. e. Aqueductus cerebri. f. Rubro-spinal tract. g. Lateral fillet. h. Medial fillet. i. Basis pedunculi. j. Location of anterior longitudinal bundle. k. Interpeduncular fossa. l. Substantia nigra. m. Decussation of brachia conjunctiva.

second stage in the auditory conduction path. The acoustic nerve constitutes the first stage, the lateral fillet the second stage, the brachium inferius the third, and the acoustic radiation the fourth stage. The last stage ends in the cortex of the superior and the transverse temporal gyri.

The **spino-thalamic tract** (Figs. 47 and 48) is located in the region of the nucleus lateralis superior. It is a loose strand of fibers not isolated from surrounding structures; and, probably, has many relays in its course. The spino-thalamic tract rises in the gray substance of the spinal cord and in the terminal nuclei of the common sensory cerebral nerves. Though it sends some

fibers to the quadrigeminal bodies, the substantia nigra and the lentiform nucleus, its chief termination is in the lateral nucleus of the thalamus. It is sensory. It conducts tactile, pain and temperature impressions.

Brachium Conjunctivum. (*Superior cerebellar peduncle*).—The brachium conjunctivum forms a ridge on the surface near the median line of the isthmus, which ends above at the inferior quadrigeminal colliculus (Fig. 44). The lateral fillet winds inward over its upper extremity. It is joined to its fellow by a sheet of white matter, the superior medullary velum. The fibers of the brachia conjunctiva bend ventrally beneath the inferior colliculus of the corpora quadrigemina and, for the most part, decussate anterior to the cerebral aqueduct, through the median raphe (Fig. 48). These crossed fibers with the few uncrossed run forward toward the inferior surface of the thalamus, where they inclose the red nucleus, and help to form the stratum dorsale of the hypothalamic region (Forel). Many of the fibers terminate in the red nucleus and from it others rise and proceed forward to the thalamus. Though most of the brachium conjunctivum rises in the cerebellum and forms a segment of an indirect sensory tract, it also contains efferent fibers which rise in the red nucleus.

Rubro-spinal tract (Crossed Descending Tract of the Red Nucleus).—Formed by axones of the red nucleus, it immediately crosses through the ventral tegmental decussation (foreli) and proceeds lateralward to the lateral fillet (Fig. 47). In the lower part of the mid-brain, it is imbedded in the medial part of that fillet. The rubro-spinal tract runs through the medulla and descends in the spinal cord to the lumbar region, where it ends in the center of the gray crescent.

Olivary Fasciculus.—The olivary bundle is a loose strand of fibers traversing the reticular formation lateral to the medial longitudinal bundle, in the upper part of the mid-brain; in the lower region of the mid-brain, it runs closer to the median line and is mingled with the fibers of the brachium conjunctivum as they are about to enter the decussation. The olivary bundle probably rises in the lentiform nucleus and ends in the olivary nucleus of the medulla.

The **descending root of the trigeminal nerve** (Fig. 48) rises in the ventro-lateral part of the central gray matter in the mid-brain and is, therefore, called the mesencephalic root. It is a motor root. It occupies a thin crescentic area, just at the lateral border of the stratum griseum centrale, which thickens as it proceeds downward toward the pons. This root extends the entire length of the mid-brain; but it is made up of very few fibers in the upper part and only assumes a distinct shape and outline when the level of the inferior quadrigeminal colliculus is reached. It is continued to the middle of the pons in the same lateral relation to the gray substance; and medial to the brachium conjunctivum cerebelli it joins the main part of the motor root and bends forward toward the anterior surface.

The Quadrigeminal Lamina (*Lamina quadrigemina*).—The quadrigeminal lamina forms the fourth great division of the mid-brain. It rests upon the dorsum of the tegmenta, entering into a large part of the posterior surface of the mesencephalon. A crucial groove shapes its surface into four eminences, called *colliculi* (*colliculi superiores* and *inferiores*) (Fig. 44).

The **colliculus superior**, of either side, is larger than the inferior colliculus and is circular in outline. It has resting upon its medial half the pineal body. It is joined to the lateral geniculate body by a band of fibers almost entirely concealed by the pulvinar of the thalamus. That band is the *brachium superius*. The superior colliculus is made up of gray substance for the most part (Figs. 46 and 47). It is composed of a superficial white layer, the *stratum zonale*, and a thick laminated gray layer, the *stratum griseum*. Within the stratum griseum many fibers end; a few from the *lateral fillet*, all of the *superior fillet*, and nearly all of the *brachium superius*. The stratum griseum gives origin to the *anterior longitudinal bundle* and, probably, to a few fibers that run through the brachium superius into the optic nerve. It constitutes an *optic-reflex center*.

The **colliculus inferior** of the corpora quadrigemina is elongated transversely (Fig. 44). It is joined to the medial geniculate body by an oblique ridge, called the *brachium inferius*, and it forms the termination of two ridges that approach it from below,

due to the lateral fillet, and the brachium conjunctivum of the cerebellum. Its surface is made up of medullated fibers continuous with the lateral fillet and brachium inferius, which forms the stratum zonale; gray substance, called the *nucleus of the inferior colliculus*, constitutes its deep portion. This nucleus receives a part of the lateral fillet and gives rise to a portion of the brachium inferius; it forms a partial relay in the acoustic path.

Brachium Superius (Figs. 43 and 44).—It connects the lateral geniculate body with the superior quadrigeminal colliculus; but, excepting its extreme posterior end, it is buried in the substance of the thalamus. Its course is anterior and internal to the medial geniculate body. The brachium superius is composed chiefly of efferent fibers from the optic radiation, a tract partially relayed in the lateral geniculate body; it probably contains, also, a few optic fibers from the lateral root of the optic tract and a few from the stratum griseum of the superior quadrigeminal colliculus. Optic reflex impulses are conducted by the brachium superius.

Brachium Inferius (Figs. 43 and 44).—The inferior arm, connecting the inferior quadrigeminal colliculus and the medial geniculate body, is visible through its whole length. It forms the superior boundary of the *triangle of the lateral fillet*; the lateral fillet and the sulcus lateralis of the mid-brain form the other two sides. Two sets of fibers make up the brachium inferius, viz., the lateral fillet fibers and the axones from the nucleus colliculi inferioris. They all terminate in the medial geniculate body. The brachium inferius forms the third segment of the acoustic path.

CEREBRUM.

SECTION III. THE STRUCTURE OF THE CEREBRUM. ITS GRAY AND WHITE MATTER.

We have noticed in the mid-brain that the basis pedunculi and much of the tegmentum are white matter, while the substantia nigra and quadrigeminal colliculi are composed chiefly of gray substance. Gray matter forms nearly all of the inter-brain. The deep part of the cerebral hemisphere is white substance, imbedded

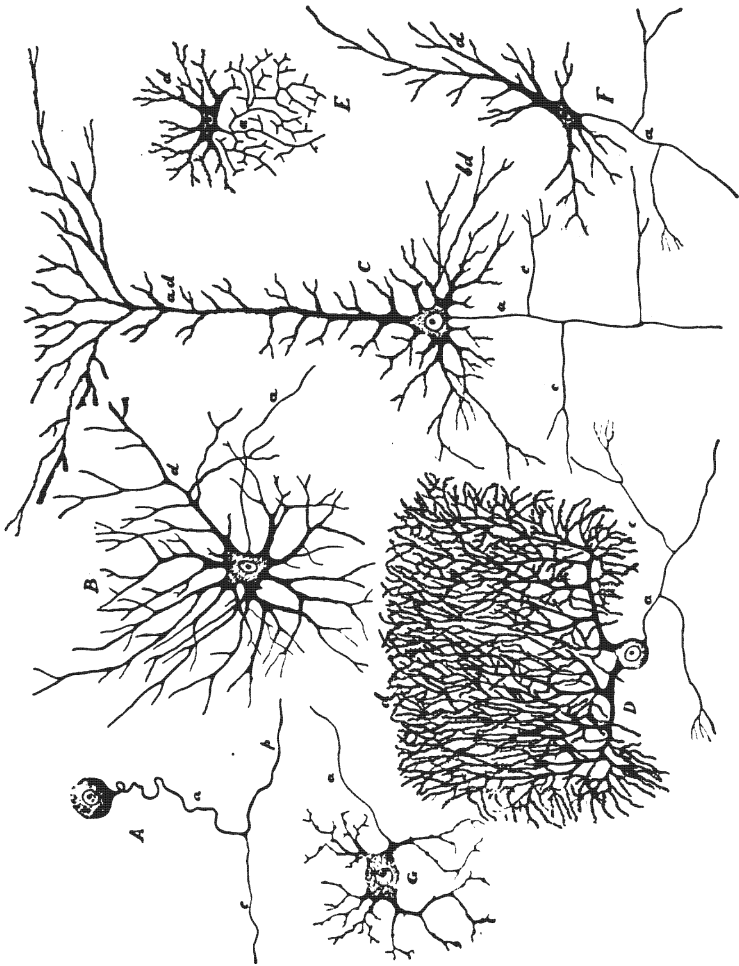


Fig. 49.—Varieties of neurones in the human nervous system.
(After *Morris's Anatomy.*)

A. From spinal ganglion. B. From ventral horn of spinal cord. C. Pyramidal cell from cerebral cortex. D. Purkinje cell from cerebellar cortex. E. Golgi cell of type II from spinal cord. F. Fusiform cell from cerebral cortex. G. Sympathetic. a, axone; d, dendrites; c, collateral branches; ad, apical dendrites; bd, basal dendrites; cc, central process; p, peripheral process, the dendrite.

in which is the gray corpus striatum. A thin envelope of gray substance, called the cortex, forms the surface of the hemisphere. The entire cerebral substance, both the white and the gray, is composed of *neurones* and *sustentacular tissue*, the latter being made up of neuroglia, ependyma and mesoblastic connective tissue. Of necessity the cerebrum possesses a rich blood supply.

The Neurone (Fig. 49).—The essential element in the nervous system is the neurone. The neurone comprises the cell-body, its processes and end-organs. The **cell-body**, *perikaryon*, or *neurone center*, is a granular reticulated mass of protoplasm of variable form. It ranges in man between four microns and one hundred and thirty-five microns in diameter. The size of the cell-body is usually proportionate to the length of the processes. Its shape, which is spherical, fusiform, pyramidal, stellate or polygonal, is dependent upon the number and mode of origin of its processes. The cell-body has a large *vesicular nucleus* in which there are one or more *nucleoli*. It also possesses a *centrosome* in spinal and sympathetic ganglia. Its reticulated appearance is due to a *net-work of fine fibrillæ* which form a close net about the nucleus. These fibrillæ may be seen in all parts of the cell-body and they are continued into the processes given off from it. Masses of deeply staining material, called *tigroid bodies* or Nissl bodies, produce the granulated aspect of the perikaryon. The tigroid bodies are found in the receptive side of the neurone, viz., in the dendrites and throughout the cell-body, except in the *axone-hillock* (Fig. 50).

The **processes** of the neurone are from one to eight or a dozen in number and are of *two kinds*, namely, the dendrites and the axones. **Dendrites**, like the cell-body, are protoplasmic in composition and of irregular contour, except in sensory nerves, where they are smooth, like axones. In all cases they contain fibrillæ prolonged from the cell-body. They branch richly and end in *beaded points*. The terminal branches are called *telodendria*. Dendrites may form synapses with axones of other neurones, may terminate in special end-organs, or end free among the cells of any tissue. They are developed later than the axones and are not always present. An active cell usually has several den-

drites. If long they become *medullated*. Their *conduction* is toward the cell-body, cellulipetal, or afferent. **Axones**, neuraxones or axis-cylinders (Fig. 50) are smooth and fibrillar in character. One (occasionally two or more) is given off from the axone-hillock of the cell-body. It may break up into branches at once, constituting a *dendraxone*; but usually it runs a considerable distance and sends out side branches, called *collaterals*. When long, as a rule, it *becomes medullated* as its function develops, and the medullary sheath presents segmental divisions separated by constrictions, called the *nodes* of Ranvier, at which points the collaterals are given off. Both the parent axone and all its collaterals end by multiple division in the form of an *end-brush*, or *tassel*. This tassel lies in contact with the dendrites or body of another neurone, with a secreting cell, or with a muscle fiber. In the last instance the fibers of the tassel spread out into disc-like platelets, called *motorial end-plates* (Fig. 50). *Axone conduction* is from the cell-body, cellulifugal, or efferent.

The **myelin sheath** of axones and dendrites, which is developed as the neurone begins to functionate, is imbedded in neuroglia within the optic nerve and tracts, and in the brain and spinal cord; but, elsewhere, is surrounded by the *neurolemma* (Schwann) and the *fibrous sheath* of Henle. The fibers of the olfactory nerve and most sympathetic fibers are not medullated, but they possess the fibrous sheath. Near the cell-body and near the end-tuft the processes are naked, having neither the fibrous nor the medullary sheath.

Types of Neurones.—1. The first type has a long axone, which preserves its identity, though it may give off many collaterals. Found in brain and spinal cord (Deiters).

2. The second type has a short axone, breaking at once into branches of apparently equal importance, the dendraxone. Found in cerebrum and cerebellum (Golgi).

3. The third type has two or more axones—diaxon, triaxon, polyaxon—as in the first layer of the cerebral cortex (Cajal).

Orders of Neuroñes.—1. The first order has distal process in relation with the periphery, as spinal-ganglion and anterior columna neurones, and conducts from the periphery or to it.

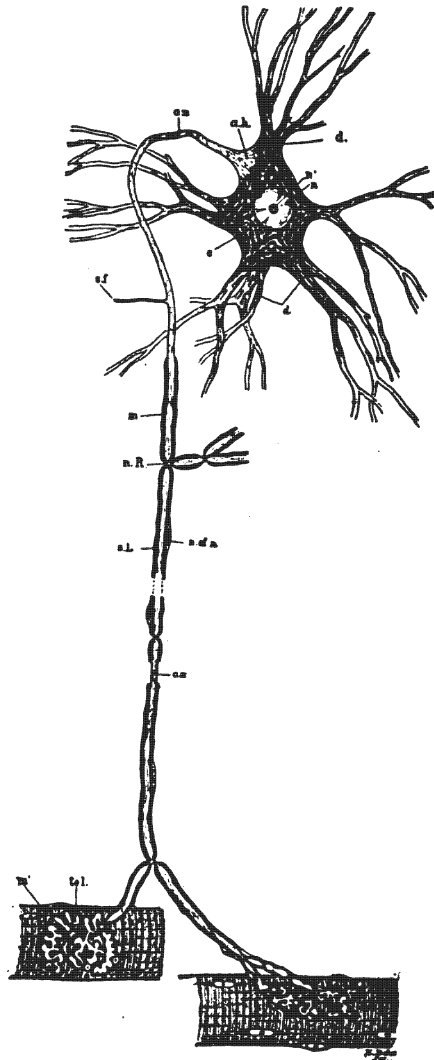


Fig. 50.—Motor neurone. (After Barker.)

a.h. Axone-hillock devoid of Nissl bodies, and showing fibrillation. ax. Axis cylinder or axone; this process near the cell-body, becomes surrounded by myelin. m., and a cellular sheath, the neurilemma, the latter not being an integral part of the neurone. c. Cytoplasm showing Nissl bodies and lighter ground substance. d. Protoplasmic processes (dendrites) containing Nissl bodies. n. Nucleus. n'. Nucleolus. n.R. Node of Ranvier. s.f. Side fibrils, collaterals. n. of n. Nucleus of neurilemma sheath. tel. Motor end plate or telodendrion. m. Striped muscle fiber. s.L. Segmentation of Lantermann.

2. The second order has cell-body or distal process in relation with neurone of first order. It conducts to a neurone of the first order or conducts centrally from it. In like manner there are neurones of the third, fourth, fifth order, etc.

Functions of Neurones.—1. Afferent. 2. Associative. 3. Efferent.

A neurone is afferent in function when its dendrites are directed toward the periphery; if its axone is peripherally directed, its

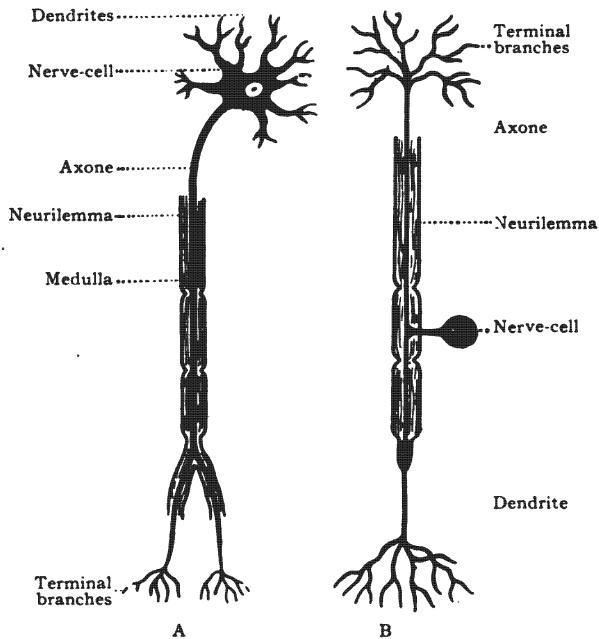


Fig. 51.—An efferent neurone and an afferent neurone. (After Brubaker.)

A. Efferent neurone. B. Afferent neurone.

function is efferent (Fig. 51). An association neurone connects other neurones together.

Degeneration.—If a neurone is prevented from functioning, it undergoes a slow atrophic change, called *degeneration of Nissl*. Rapid *Wallerian degeneration* occurs in an axone or dendrite which is completely cut off from all other parts of the neurone. In all probability neurones differ in chemical constitution and in electric

status, hence chemicals, electricity and diseases appear to exercise a selective power and affect certain neurones without influencing others.

Development (Figs. 52 and 128).—Every neurone is the derivative of an epiblastic cell, called the *germinal cell* of His, which is located in the neural tube or crest. This germinal cell, *in the neural tube*, sends out a process from what was originally its deep end, and becomes a neuroblast. This process forms the axone and, later, dendrites are produced. During development

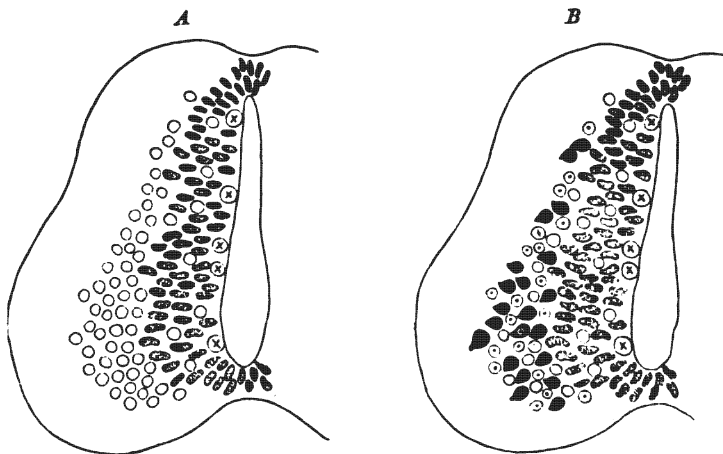


Fig. 52.—Diagram showing development of neurones in the spinal cord.
(McMurrich after Schäfer.)

The circles, indifferent cells; circles with dots, neuroglia cells; shaded cells, germinal cells; circles with cross, germinal cells in mitosis; black cells, nerve-cells.

the cell-body wanders more or less from its original position, and thus reaches its adult location. The neurones are in this manner aggregated into *nuclei* and *cortex*. The *germinal cells of the neural crest* form bipolar neuroblasts, which send out a process from each extremity. The axone appears first, the dendrite later, as in the neural tube. The resulting neurones make up the cerebral, spinal and sympathetic ganglia. In the spinal ganglia and in the common sensory cerebral ganglia, the neurones become converted into the *unipolar form* by the lateral growth of the cell-body and the fusion, for a short distance, of the two processes

into one common stem (Figs. 115 and 128). They remain bipolar in the olfactory and acoustic ganglia, but form multipolar cells in the sympathetic ganglia.

Sustentacular Tissue (Fig. 53).—In the brain and spinal cord and in the optic nerves two forms of sustentacular tissue are

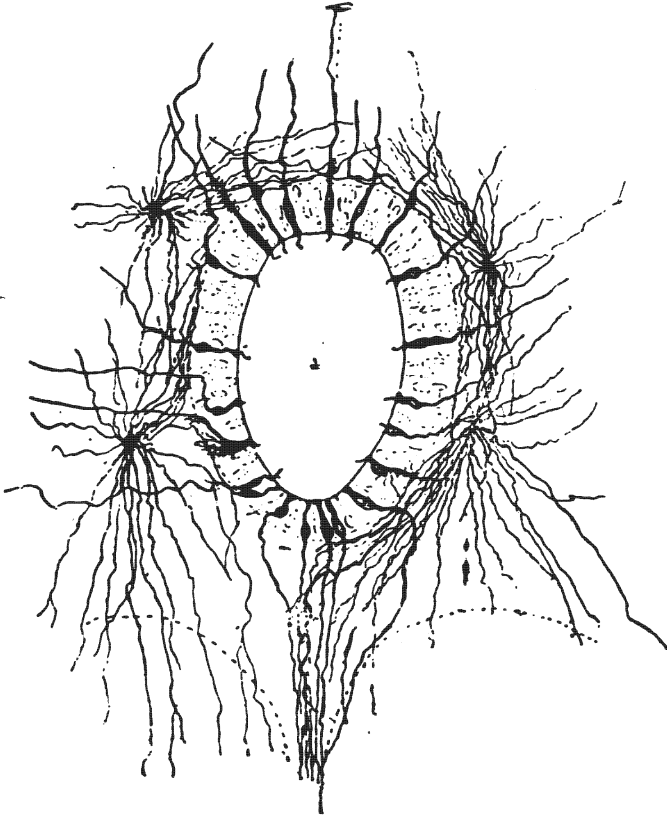


Fig. 53.—A section through the spinal cord of a human fetus, 23 cm. in length. Showing the central canal with its substantia gelatinosa centralis, neuroglia cells and ependyma cells. (After Lenhossek. *Gordinier's Nervous System.*)

found supporting the neurones, viz.: (1) *The epiblastic tissue*, comprising the neuroglia and the ependyma: (A) *Neuroglia* is most abundant in gray matter. It is made up of richly branched nucleated cells whose processes form a fine reticulation in the

larger meshes of the connective tissue network. There are three varieties of neuroglia cells, viz., (a) the *short rayed cells*, found in the cortex of cerebellum and cerebrum, the processes of which are strong and richly branched; (b) the *long rayed cells*, located chiefly in the white substance, whose processes are long and fine and but little branched; and (c) the *arborescent cells*, which lie near the surface in the cortex. Upon reaching the surface the tree-like branches form a limiting membrane of neuroglia.

(B) The columnar ciliated *ependymal cells* which line the ventricles are also epiblastic in origin and should be classed with the neuroglia cells. They form the only sustentacular tissue present in the neural tube when it is first formed, at which time they extend from the ventricular to the exterior surface of the tube and, in the peripheral zone, form a rich supporting network. They appear to be of little importance in the adult condition.

(2) *Connective Tissue Network*.—That is of mesoblastic origin and is formed by branching processes from the inner surface of the pia mater. It transmits the blood-vessels into the nervous substance.

The *neurones* constitute 53 per cent. of the brain and cord (cell-bodies, 6 per cent.) and the *sustentacular tissue* 47 per cent. (Donaldson).

The *white matter* of the cerebro-spinal axis is made up chiefly of bundles of medullated axones imbedded in neuroglia and supported by connective tissue. The fibers possess no neurilemma.

The *gray matter* of the central nervous system is composed of cell-bodies and dendrites, chiefly, but also contains axones. These nerve elements are supported by connective tissue and blood-vessels and are imbedded in a great abundance of neuroglia. The nerve fibers in the gray matter are to a large extent non-medullated and naked.

The **cerebral gray substance** (*substantia grisea cerebri*) is conveniently divided into three groups or classes:

- I. Cortical.
- II. Ganglionar.
- III. Central, or ventricular.

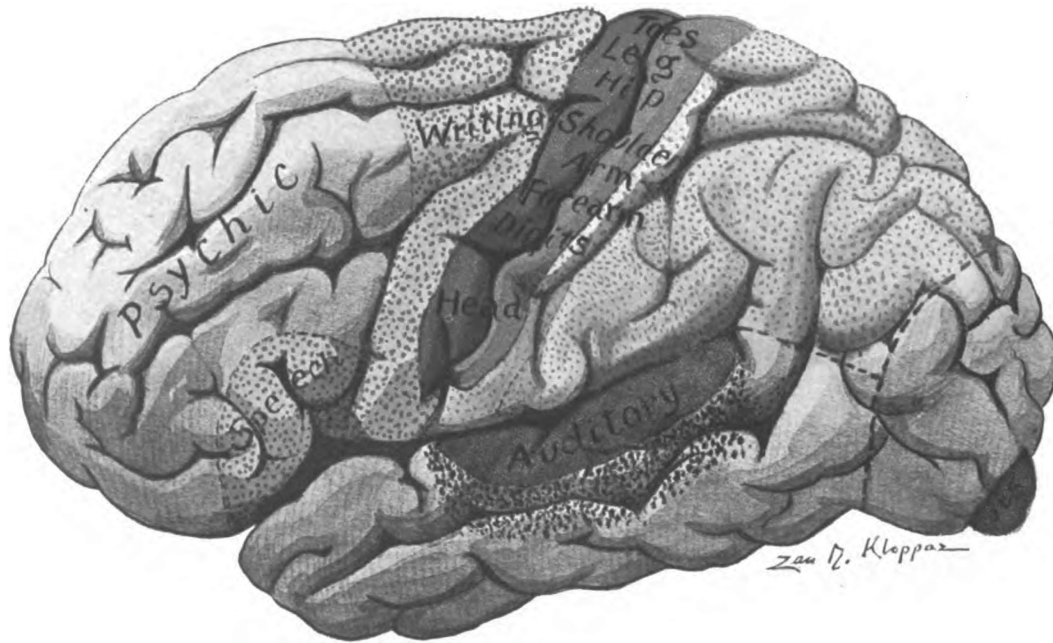


Fig. 54.—Cortical areas on convex surface of cerebral hemisphere. (Original.)

Plain red represents the emissive motor centers.
 Dotted red represents the psychic motor centers.
 Plain blue represents the receptive common sensory centers.
 Dotted blue represents the psychic common sensory centers.
 Plain purple represents the receptive centers of special sense.
 Dotted purple represents the psychic centers of special sense.

I. THE CORTICAL GRAY MATTER.

The *substantia corticalis* consists of a thin envelope, the cortex (or bark), which forms the surface of the hemispheres and incloses the white medulla, the *centrum semiovale*. The cortex varies in thickness from a line to a quarter of an inch. Thickest on the surface of the gyrus, it grows thinner to the bottom of the sulci. It is of a reddish, or yellowish-gray color depending on the richness of the blood supply. By repeated observation of the symptoms produced by definite brain lesions and by the anatomical and physiological study of human and lower animal brains, both in the embryonic and adult condition, the cortex has been mapped out into certain definite *functional areas* (Figs. 54 and 55). Psychic function undoubtedly is dependent upon the associated activity of a number of cortical areas; but motor, common sensory and special sensory regions have been outlined with considerable exactness.

Cortical or Cerebral Localization (Figs. 54 and 55).—In the following study of the cerebral cortex I shall use very extensively the recent work of Dr. Alfred W. Campbell, entitled, "Histological Studies on the Localization of Cerebral Function," Cambridge, England. In this epoch-making work we are shown that certain cortical areas have a characteristic histological structure that distinguishes them from all other areas. This will be referred to later under "cell and fiber lamination of the cortex," but to appreciate this histological evidence of localization one should thoroughly study the above work.

Motor Area (Figs. 54, 55, 56 and 57).—The **emissive motor area** is situated in the anterior wall of the central sulcus, in the posterior one-half of the gyrus centralis anterior and in that part of the paracentral lobule immediately continuous with it. This is the center for ordinary voluntary motion on the opposite side of the body. Axones from this area descend to the nuclei of all motor nerves. In lateral sclerosis there is degeneration and disappearance of the giant pyramidal cells limited to this motor area (Campbell). It is divided into four segments: *the head and neck*, the arm, the trunk, and the leg, named from below upward. The first extends to the inferior knee of the sulcus centralis

(Rolandi), though eye movements appear to be represented in the posterior end of the middle frontal gyrus; the *arm area* comprises the region between the genu inferius and the genu superius, the thumb, fingers, wrist, fore-arm, arm and shoulder movements being represented in this ascending order; just above the shoulder area, at the genu superius, is the *trunk area*; and above that, in the anterior central gyrus and in the paracentral lobule, in front of the sulcus centralis, is the *center for leg* movements, The representation in the leg center is inverted, the ascending order being hip, thigh, leg, ankle, toes and great toe.

The *psychic motor areas*, or *areas for educated movements* are located just anterior to the above motor areas, in the anterior central gyrus and in the contiguous ends of the superior, middle and inferior frontal gyri (Figs. 54 and 55). These areas are believed to send their axones to the emissive motor centers in the cortex. The psychic motor center for the *lower extremity* is probably located just in front of its emissive motor center in the anterior central and superior frontal gyri. In the posterior end of the middle frontal gyrus is the psychic motor *center for the arm*, the *writing center* of Gordinier; and in the inferior frontal gyrus the center for the organs of voice and speech, hence the *motor speech center*. In right handed people these centers are developed only in the left cerebral hemisphere.

Common Sensory Area (Figs. 54 and 55).—According to Dr. Alfred W. Campbell the receptive area of common sensation is limited to the posterior wall of the sulcus centralis, including the anterior one-half of the posterior central gyrus and that part of the paracentral lobule which is continuous with it. This area undergoes exclusive Nissl degeneration in locomotor ataxia (Campbell). It is probably divided into segments similar to those of the motor area (Spiller).

Psychic Sensory Area (Figs. 54, 55, 56 and 57).—A large portion of the remainder of the parietal cortex probably constitutes a number of centers for the interpretation of common sensory impulses, hence the term, psychic sensory area. Impressions of the *muscular sense* are believed to be interpreted in the supra-marginal gyrus and the *center of stereognosis* is said to be located

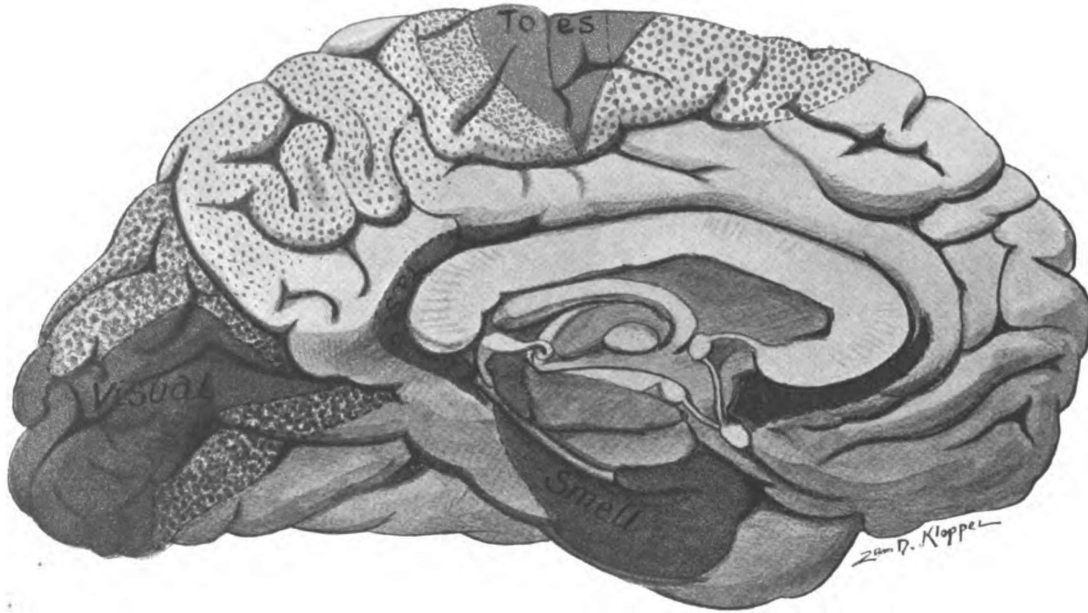


Fig. 55.—Cortical areas on the medial and tentorial surface of the cerebral hemisphere. (Original.)

Plain red represents the emissive motor centers.
Dotted red represents the psychic motor centers.
Plain blue represents the receptive common sensory centers.
Dotted blue represents the psychic common sensory centers.
Plain purple represents the receptive centers of special sense.
Dotted purple represents the psychic centers of special sense.

in the superior parietal lobule and præcuneus. Perhaps other parts interpret tactile, pain and temperature impulses. The whole receptive and psychic area of common sensation has been called the *somæsthetic area* (Barker), though the application of this term might better be limited to the *receptive area*.

Acoustic Center (Figs. 54 and 56).—The *receptive acoustic center* is located in the transverse temporal gyri and in that part of the superior temporal gyrus which is continuous with them. In the adjacent part of the superior and middle temporal gyri, in the left hemisphere, is the *psychic acoustic center*.

Optic Center (Figs. 54 and 55).—In the cuneus and lingual gyrus is located the *receptive optic center* for the temporal half of the same retina and the nasal half of the opposite one; perhaps, also, for the macula lutea of both sides. The remainder of the occipital lobe and, according to Mills and others, the angular gyrus, also, form the *psychic optic center*. This latter center is probably unilateral and developed only in the left hemisphere of right handed people.

Olfactory and Gustatory Centers (Figs. 55 and 57).—The uncus hippocampi forms the chief cortical *center of smell*, close to which in the fusiform gyrus is probably the *gustatory center* (Mills). Paul Flechsig in his recent studies of the human brain locates *taste in the gyrus cinguli* contiguous to the splenium of the corpus callosum (Fig. 55). The olfactory, auditory, visual, common sensory and motor areas are all distinguished by a definite characteristic histological structure peculiar to each region (Campbell). Medullation of the fibers in these cortical areas occurs at different times; and, according to Flechsig, in the following order: olfactory, tactile and muscular sense, visual, auditory, and gustatory.

In the temporal lobe Mills locates four other centers which include the pole, the inferior temporal gyrus and a part of the middle temporal gyrus (Fig. 56). These are from before backward: the *center of intonation* at the pole, the *naming center*, the *center of equilibration*, and the *center of orientation*.

All the above motor, somæsthetic and special sense areas are provided with projection fibers which connect them with definite muscle groups and surface regions and with the organs of

special sense. Large parts of the cerebral cortex possess no projection fibers; they are believed to be associative in function.

Association Centers of Flechsig.—Flechsig describes *three association centers*, the anterior, middle, and posterior. *Anterior Association Center* (Fig. 54).—According to Flechsig, that part of the frontal cortex which is anterior to the motor region determines the temperament and individuality of the person; and as Mills declares, is the center of inhibition, self control, attention, concentration, volition. It is the center of “the abstract concept”

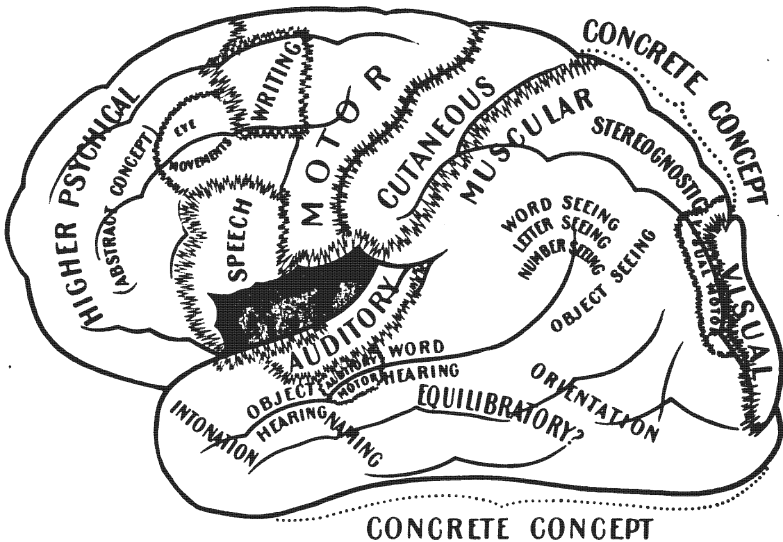


Fig. 56.—Cortical areas after C. K. Mills. Convex surface of cerebral hemisphere. (*Brubaker's Physiology.*)

(Fig. 56). J. S. Bolton says of this association center that “it is the last part of the cerebrum to be developed, and is the first to undergo dissolution; it is under-developed in amentia of all grades and atrophied in dementia, according to its degree.” “It possesses the highest (mental) function” (*Brain*, Vol. 29). *The posterior association center*, composed of those portions of cortex situated between the sensory region of the equatorial zone, in front, and the visual cortex of the occipital lobe, behind, deter-

mines the intellectuality of the individual (Fig. 54). To acquire knowledge of the external world is thus the function of the posterior association center. Mills calls it the *center of "the concrete concept"* (Fig. 56). It includes three psychic areas, the common sensory, auditory and visual. Flechsig regards the island (of Reil) as the *middle association center* (Figs. 25 and 56). Lesions in it are associated with paraphasia.

Destructive lesions of parts of the motor or sensory cortex cause merely loss of certain motions and sensations represented

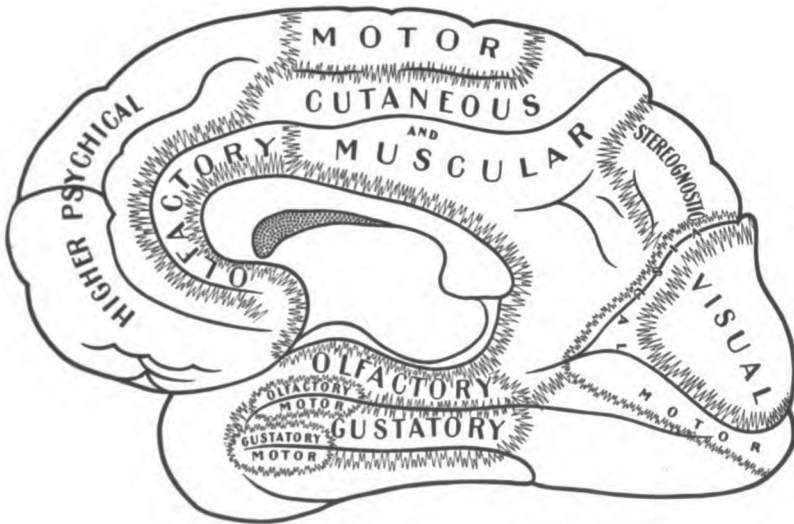


Fig. 57.—Cortical areas after C. K. Mills. Medial and tentorial surface of cerebral hemisphere. (*Brubaker's Physiology*.)

by those parts, but ablation of association centers disconnects the sensory, the psychic and the motor regions and causes aphasia, agraphia, change of temperament, impairment of the so-called moral and intellectual faculties, etc. Ablation of the visual psychic center or auditory psychic center produces mind-blindness in the former and in the latter mind-deafness.

Cell and Fiber Lamination of the Cerebral Cortex.—There is a *type* of cerebral cortex which, with small but definite variations, prevails throughout the cerebrum, excepting in the visual

and olfactory regions (Fig. 58). Though Dr. Campbell's division of the cortex into seven layers of cells is complicated, it is similar to Cajal's description and I think it entirely worthy of general adoption and shall follow it in this work. It is to be regretted that the fiber and the cell layers have not been more satisfactorily correlated, as this would assist in determining function. Dr. Arthur W. Campbell gives the layers as follows:

First, the layers of cells:—

1. The plexiform or molecular layer.
2. The layer of small pyramids.
3. The layer of medium-sized pyramids.
4. The external layer of large pyramids.
5. The layer of stellate or polymorphous cells.
6. The internal layer of large pyramids.
7. The layer of fusiform cells.

Second, the fiber zones:—

1. The fiberless layer, or neuroglia zone.
2. The zonal layer, stratum zonale.
3. The supraradiary zone.
4. The baillargic zone, line of baillarger.
5. The radiary zone.
6. The felt-work of Kaes.

1. *The plexiform layer* has next the surface a fiberless *zone of neuroglia*, on account of which it is often called the neuroglia-layer. Underneath the neuroglia is a more or less dense plexus of nerve fibers, constituting the *stratum zonale*; and then an area of sparsely scattered fibers that belongs to the *supraradiary zone*. Scattered here and there in the zonal and supraradiary regions of the plexiform layer are *small stellate cell-bodies*, four or six microns in diameter, belonging to the types of Golgi and Cajal, whose dendrites and whose double or triple axones ramify in the stratum zonale, some near the cell-body and others at a considerable distance from it. The *stratum zonale* also contains dendritic processes from subjacent laminæ, the T-branched axones of Martinotti's cells, and, perhaps, the end-tufts of incoming fibers

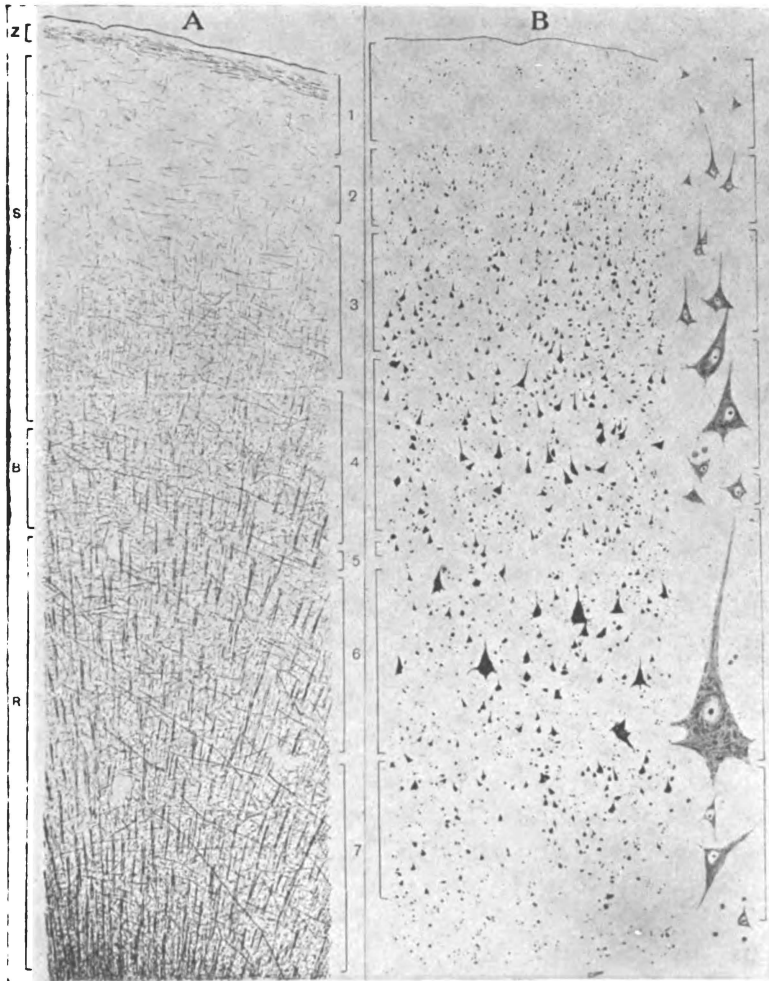


Fig. 58.—Cell and fiber lamination in the posterior half of the anterior central gyrus. The MOTOR AREA. (After *A. W. Campbell's "Histological Studies on the Localization of Cerebral Function."* Published by the Syndics of the Cambridge University Press.)

A. Stained to show only fibers. **B.** Stained to show only cell-bodies. **z.** Stratum zonale. **s.** Supraradiary zone. **B.** Line of Baillarger. **R.** Radiary zone in the deep part of which is the felt-work of Kaes. **1.** Plexiform layer. **2.** Layer of small pyramids. **3.** Layer of medium-sized pyramids. **4.** External layer of large pyramids. **5.** Stellate or polymorphous cells. **6.** Internal layer of large pyramids. **7.** Layer of fusiform cells.

from the commissural, the associative and the projection systems. It is very well marked in the motor area (Fig. 58), not so well in the common sensory area (Fig. 59). In the uncus it is very distinct (Fig. 61) and is so thick and dense in the gyrus hippocampi (the subiculum) as to be visible to the naked eye (Fig. 62). The zonal layer of fibers is faint in the visuo-sensory and audito-sensory cortex. The stratum zonale appears to grow richer with the education of the individual. The function of the plexiform layer is commonly thought to be association.

2. *The layer of small pyramids* (Figs. 58 and 59), as well as the third layer, is situated in the *supraradiary zone*. It is composed chiefly of *small closely packed cell-bodies, pyramidal* in shape. They measure eight or ten microns in diameter. Their apices point toward the surface. From the apices, surfaces and lateral angles, *dendrites* are given off which ramify in the stratum zonale of the first layer. The *axone* issues from the base of the pyramid and runs down through the subjacent layers. Among the small pyramids are a few ploymorphous cells.

3. *The layer of medium-sized pyramids* (Fig. 58) is a nearly pure layer; and, like the overlying layer, is nearly uniform throughout the cerebral cortex. In arrangement of cell-bodies and processes it is like the second layer. The pyramids get farther apart and become larger in size as the layer is descended. They measure ten to fifteen microns in their vertical diameter. In the anterior central gyrus these cells are motor. Layers "two" and "three" might be combined in one as was formerly the custom.

4. *External Layer of Large Pyramids* (Figs. 58 and 59).—This layer coincides in position with the *line of Baillarger*. The *pyramids* are larger and farther apart than in the above layer, and show a considerable accession of Nissl bodies as compared with the smaller pyramids. They measure 15μ to 20μ by 25μ to 30μ , and form "one of the most important criteria in dividing the brain surface into different histological territories" (Campbell). As these cells, in the anterior central gyrus, degenerate in amyotrophic lateral sclerosis, they are considered motor in function. The *apical processes* appear to reach the first layer and ramify in the stratum zonale; the *lateral and basal dendrites* arborize

within the line of Baillarger; the *axone* runs inward to the white substance. The external large pyramids are found in nearly all parts of the cortex. They are replaced by a layer of large stellate cells in the receptive visual cortex along the calcarine fissure. The line of Baillarger in the calcarine cortex is so thick and dense that Gennari and, later, Vicq d'Azyr described it from its naked eye appearance (Fig. 60). In the motor and common sensory area the line can scarcely be made out; while in the superior parietal gyrus there are *two Baillargic lines*, the deep line coinciding in position with the internal large pyramids. There are some peculiar Golgi cells among these pyramids, whose axones run horizontally and give off collaterals that form pericellular baskets around the pyramids (Johnston). They are associative in function.

5. *The layer of stellate or polymorphous cells* presents great variation in different regions and is a valuable guide for cortical localization. It is best marked in the calcarine area (Fig. 60) where it and the fourth layer are associated with the greatly thickened *Baillargic line* (Gennari), though elsewhere it is situated in the *radiary zone* of fibers. It is well marked in the auditory cortex. In the motor area it is hardly distinguishable, but it appears suddenly at the bottom of the central sulcus and forms a distinct feature in the common sensory region of the posterior central gyrus (Fig. 59). The cell-bodies of the stellate layer measure five to eight microns in diameter and are of many shapes, some being pyramidal. They are richly branched. The dendrites arborize at once near the cell-body. The axones of a considerable number of cells extend horizontally within the layer, helping to form the line of Baillarger; while others run toward the surface and end in the overlying laminae.

6. *Internal Layer of Large Pyramids* (Fig. 59).—This is the most important layer of the cortex for localization. It lies in the *radiary zone* of fibers and is present in almost every part of the cerebral cortex, though distinguished by definite variations in the different regions (Figs. 59, 60 and 61). Its great pyramids are intermingled with irregular cell-bodies of the Golgi type and with Martinotti cells. The *giant pyramids* (Betz), or *ganglionic*

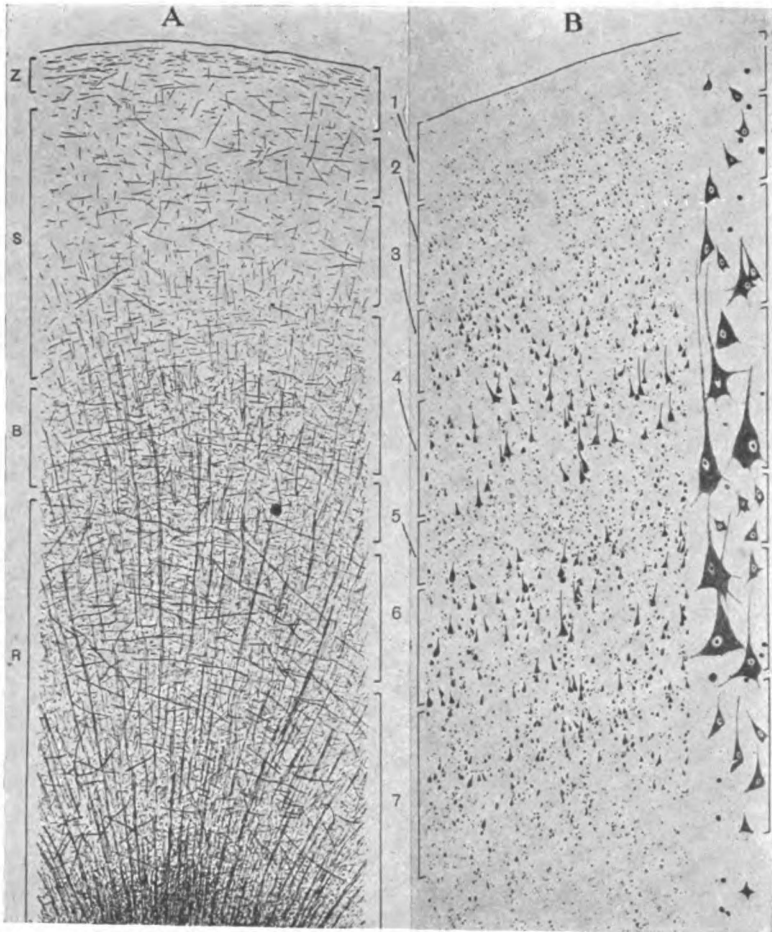


Fig. 59.—Cell and fiber lamination in the anterior half of the posterior central gyrus. The COMMON SENSORY AREA. (After *A. W. Campbell's* "Histological Studies on the Localization of Cerebral Function." Published by the Syndics of the Cambridge University Press.)

A. Stained to show fibers. B. Showing only cell-bodies. z. Stratum zonale. s. Supra-radiary zone. B. Line of Baillarger. r. Radiary zone. 1. Plexiform layer. 2. Layer of small pyramids. 3. Layer of medium-sized pyramids. 4. External layer of large pyramids. 5. Layer of stellate cells. 6. Internal layer of large pyramids. 7. Layer of fusiform cells.

cells (Bevin Lewis), are "pyraform" in shape. They are loaded with *Nissl bodies* and give off one axone and many dendrites. The *lateral and basal dendrites* ramify in the radiary zone; the *dendrite of the summit* runs straight out toward the surface and like the same process from other pyramids, arborizes in the stratum zonale of the plexiform layer; the *axone* enters the medullary substance and becomes a projection, association or commissural fiber. The giant pyramids characterize the motor cortex. No where else are they so large. Neither do they have in any other region the "pyraform" shape or the definite nest-like grouping seen in the anterior central gyrus. *They measure* twenty-five by sixty microns in the leg area of that gyrus; twenty by forty-five microns in the arm area; and, in the head area, seventeen by thirty-five microns (Bevin Lewis). In cases of amyotrophic lateral sclerosis studied by Campbell, 87.5 per cent. of these cells in the affected area were entirely destroyed and those remaining showed signs of degeneration. Both the internal and external large pyramids were thus affected in the anterior central gyrus, so they are motor in that gyrus; but they were not degenerated in any other part of the cortex.

7. *The fusiform layer* (Figs. 58, 59, 60 and 61) is found every where in the cerebral cortex. It presents very little topographical variation. Its spindle-shaped cell-bodies lie in the deep part of the *radiary zone* and in the *felt-work of Kaes*. The long axes of the spindles are perpendicular to the surface in the crown of a gyrus but are parallel with it in the fissural walls and floor. From these cell-bodies one *axone* and *several dendrites* are given off. The function of the spindle cell is probably association. The *felt-work of Kaes* is a rich plexus of fibers in which the white and gray substance meet. It is produced by the intermingling of the association, commissural and projection fibers. Scattered here and there through all the layers of the cortex are two atypical neurones, viz., the *dendraxonnes of Golgi*, which arborize very richly and are associative in function; and, second, the *inverted pyramids of Martinotti*. Of the latter the dendrites terminate near the cell-body; but the axone runs out to the first layer and, branching T-like, ramifies in the stratum zonale.

Martinotti's cells, like those of Golgi, are probably associative in function.

The Radiations of Meynert (Figs. 58, 59, 60 and 61).—The six fiber zones above enumerated have been as fully indicated in speaking of the cell lamination as the limits of this work will allow, but certain fibers, called the **fibers of Meynert**, need to be mentioned. The *radiations of Meynert* are strands of fibers, clearly visible in the radiary zone of the cortex, composed of corticifugal and corticipetal fibers. The corticifugal fibers are very largely axones from the pyramids; the incoming fibers of Meynert's radiations rise in other parts of the cortex or in gray matter situated at a lower level. The radiating fibers belong to the following systems, the projection, the association and the commissural. The radiations are distinct as far out as the external layer of large pyramids and the *line of Baillarger*, hence the name *radiary zone*; but in certain regions they are much longer and in some parts of the temporal lobe they extend to the stratum zonale of the first layer. In such regions the line of Baillarger divides the radiary zone into two parts and there is no proper supraradiary zone.

Association Fibers of Meynert.—This name is applied to arcuate fibers of large diameter located in the radiary, the Baillargic and the deep part of the supraradiary zone. Owing to condensation they form a distinct layer in the fissural walls and floor, but are sparsely scattered in the crown of the gyrus (Campbell). They arch over the medullary projection, crossing Meynert's radiations at right angles. The deeper ones appear to be continuous with certain fibers in the radiations and are probably corticipetal in direction (Kaes and Campbell). Meynert's association fibers are said by Vulpius not to be developed before the seventeenth year; and, according to Kaes, are most abundant in the highly developed parts of the brain.

Atypical Cortex.—The decided variations from the typical cortex are found in the visual and olfactory areas.

Visual Receptive Center (Fig. 60).—The cortex in the cuneus and gyrus lingualis presents *three marked variations* from typical cortex: 1. The greatly accentuated line of Baillarger, which

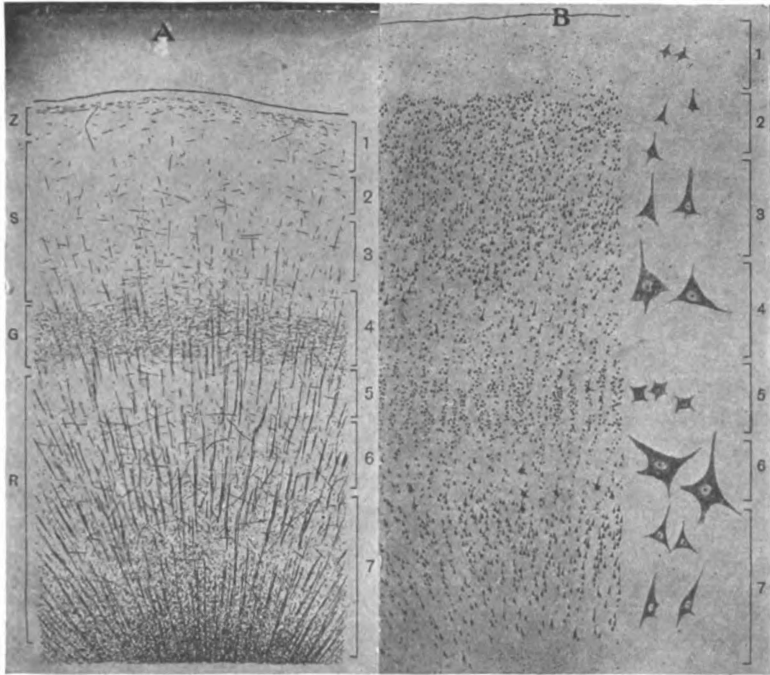


Fig. 60.—Cell and fiber lamination in the calcarine region. RECEPTIVE VISUAL AREA. (After *A. W. Campbell's* "Histological Studies on the Localization of Cerebral Function." Published by the Syndics of the Cambridge University Press.)

A. Shows fibers of occipital cortex. B. Cells of same. z. Stratum zonale. s. Supra-radiary zone. G. Line of Baillarger or Genari. R. Radiary zone. 1. Plexiform layer. 2. Layer of small pyramids. 3. Layer of medium-sized pyramids. 4. External layer of large stellate cells. 5. Small stellate cells. 6. Layer of giant pyramidal or stellate cells with some small pyramids. 7. Layer of fusiform cells with some medium-sized pyramids.

may be seen dividing the cortex into two gray layers. This line was first seen and described in the visual area by Gennari and, ten years later, by Vicq d'Azyr. 2. The external layer of large pyramids is replaced by a layer of stellate cells 25μ in diameter. These stellate cells give off three or four strong processes which appear to arborize in the line of Baillarger. They are found in the receptive and psychic visual areas but not elsewhere in the cerebral cortex. 3. The internal layer of large pyramids is replaced by a conglomerate made up of three varieties of pyramids. From without inward there are: First, small inverted pyramids, cells of Martinotti, which extend their axones out toward the surface. Second, the scattered giant pyramids, $25-30\mu$ in diameter, arranged in a single row and called the *solitary cells* of Meynert. The axones of the giant pyramids probably pass into the optic radiation. Third, a layer of medium-sized pyramids.

Olfactory Cortex.—All the divisions of the rhinencephalon are here mentioned, though only a part of them need be described: the olfactory bulb, triangle, parolfactory area, anterior perforated substance, gyrus subcallosus, septum pellucidum, gyrus supracallosus (longitudinal striæ), fasciola cinerea, fascia dentata, hippocampus, subiculum and uncus. The posterior inferior part of the hippocampal gyrus and the gyrus cinguli are ordinarily included in the rhinencephalon; but, according to Elliot Smith, they belong to the neopallium (Figs. 26, 28 and 62).

The cortex of the olfactory bulb (Fig. 63) is divided into five layers as pictured by Barker. These five layers are as follows, named from the surface toward the center: (1) The *stratum nervosum*, composed of the T-branched fibers from the olfactory nerve and their collaterals. These fibers run nearly parallel with the surface for some distance, then bend centrally and break up into their end-tufts in the second layer. (2) The *stratum glomerulosum* is made up of round bodies, called *glomeruli*, which are composed of the end-tufts of olfactory nerve fibers and of brush-like dendrites from the spindle and mitral cells of the third and fourth layers. The glomeruli constitute the synapses between the first and second olfactory neurones. (3) The *stratum reticulare*. This is a network of mitral dendrites interwoven with

arborizing processes from the granules in the fifth layer and the branches of a few endogenous spindle cells, called the brush cells. The mitral dendrites are on their way to the glomeruli in the second layer. The spindle cells likewise, both large and small, throw their dendritic processes down into the stratum glomerulosum, where they end in rich tufts or brushes; and their axones penetrate the fourth and fifth layers, enter into the white sheath of the bulb and thence are continued into the olfactory tract. (4) The *stratum cellulare*, or *layer of mitral cell-bodies*. The mitral cells have large pyramidal bodies with one axone and rich dendritic processes. The latter arborize through the reticular layer to the glomeruli of the second layer, where they terminate in the form of end-brushes. The axones of the mitral cells run centrally through the granular layer, to which they give off collaterals, and then turn backward in the white sheath and ultimately constitute the olfactory tract. The white sheath incloses a mass of cells derived from the ependymal lining of the ventricle in the embryo. (5) The *stratum granulosum* is composed of a thick layer of small cell-bodies, "granules," whose processes arborize richly in the granular, cellular and reticular layers. Imbedded in the granular layer are the medullated axones coursing toward the white sheath and the olfactory tract. The function of the granular layer is not understood. The mitral and spindle cells of the olfactory bulb, it should be carefully noted, form the *terminal nucleus* of the *olfactory nerves*: the points of contact between them are established in the *glomeruli*; and the axones of the nucleus constitute the *olfactory tract* and its *striae*, which join the bulb to the cerebral hemisphere (Fig. 63). The lateral stria of the olfactory tract runs directly to the uncus, hence we shall study that region next.

The uncus and crown of the hippocampal gyrus (Figs. 55, 61 and 62) probably represent the greater part of the lobus pyramiformis of osmatic mammals. It constitutes the chief cortical center of smell. However it is probable that the subiculum, hippocampus, fascia dentata, and anterior end of the gyrus cinguli belong in the cortical area of smell, as all showed arrested development in two cases of congenital absence of the olfactory bulbs




Fig. 61.—Cell and fiber lamination in the uncus hippocampi (lobus pyraformis). The AREA OF SMELL. (After A. W. Campbell's "Histological Studies on the Localization of Cerebral Function. Published by the Syndics of the Cambridge University Press.)

A. Showing fibers. B. Showing cell-bodies. z. Stratum zonale, external medullary lamina. s. Supraradiary zone containing radiating fibers. B. Line of Baillarger. R. Radiary zone. 1. Plexiform layer. 2. Layer of stellate cells showing cell-nests. 3. Represents third and fourth layers of typical cortex, medium-sized pyramids obliquely placed and stellate cells; with Golgi's silver method shows tassel-cells. 4. Fusiform or triangular cells. 5. Medium-pyramids. 6. Fusiform cells.

(Zuckerkan dl). The fascia dentata is of first importance according to Alexander Hill. He calls attention to the fact that the Narwhal, which has no sense of smell, possesses every part of the hippocampal region excepting the dentate fascia (Campbell). The uncus comprises the whole anterior part of the gyrus hippocampi. In structure the crown of the hippocampal gyrus and the uncus are nearly identical. They have only *five layers of cells*. (1) As already pointed out the plexiform layer is thick and possesses a dense *stratum zonale*, only second to that of the subiculum. (2) The place of the small pyramids is usurped by the "*olfactory islets*" (Calleja) which are curious nests of large stellate cells (28μ) interspersed with small nests of very minute pyramidal cells. (3) The *tassel-cells of Cajal*. Peculiar pyramidal cells, with such rich dendritic arborizations hanging from the bases as to resemble tassels, are seen in the place of the medium-sized pyramids. At the line of Baillarger there are no cells; the fourth layer of typical cortex is entirely wanting. (4) The stellate layer and internal layer of large pyramids are replaced by a layer of intermixed fusiform and triangular cells heavy with Nissl bodies. (5) The fusiform-cell layer is nearly typical.

Nucleus Amygdalæ (Fig. 32).—In the anterior wall of the inferior horn of the lateral ventricle, near the temporal pole and dorsal to the uncus hippocampi, is the amygdala, a nucleus of doubtful classification. The amygdala is in part continuous with the corpus striatum and, according to Campbell, appears on the surface of the uncus as the gyrus semilunaris.

Cortex of the Lower Wall and Lip of the Hippocampal Fissure (Fig. 62).—This is known as the *subiculum*. It is especially distinguished for its remarkable *stratum zonale*, which is visible to the naked eye, and for its *long radiations*, which reach the zonal layer and give the cortex a striated appearance. (1) The plexiform layer is almost wholly occupied by the *stratum zonale*, called here the *external medullary lamina*. (2) The layer of *olfactory islets*. The islets are closely packed nests of minute triangular cells, 5μ in diameter, resembling those in the uncus. (3) The *stratum radiatum* occupies about three-fourths of the depth of this cortex. In its deep part (the stratum lucidum)

there are several layers of medium-sized pyramids, arranged in columns. The prominent apical processes of these pyramids collect in bundles and proceed outward to the stratum zonale, separating the columns of pyramids and producing the striations above mentioned. As the apical dendrites approach the olfactory islets they branch richly. The axones of the pyramids run straight to the white core of the gyrus or into the alveus. The pyramids continue without interruption through the hippocampus into the nucleus of the dentate fascia. The *alveus*, which forms the ventricular surface of the hippocampus, is made up largely of the axones of these pyramids; from the alveus they proceed into the crus of the fornix. (4) A few fusiform or stellate cells lie next the alveus. They belong to the type of Golgi, the axone being wonderfully branched. In function they are associative. It is in the region of these associative neurones that the axones of the pyramids bend and adjust themselves so as to enter the alveus nearly parallel with its surface, hence the name stratum oriens applied to it by Edinger.

The fascia dentata (Fig. 62) is a free lip of cortex folded inward anterior to the hippocampal fissure. It presents a type of structure, which is continued, forward, through the band of Giacomini into the reflected part of the uncus; and which extends backward through the fasciola cinerea into the gyrus supracallosus (longitudinal striæ of the corpus callosum). It is similar in structure to the subiculum, the first and the third layers only present a marked variation. The stratum zonale is not so prominent as in the subiculum; and the stratum radiatum is entirely replaced by the nucleus fasciæ dentatæ. The nucleus is composed of pyramids, of polymorphous and fusiform cells and their branches. Their dendrites radiate toward the stratum zonale, their axones proceed into the crus of the fornix. The dentate fascia is absent in anosmatic animals (A. Hill).

Trigonum Olfactorium, Area Parolfactoria (Broca), Gyrus Subcallosus and *Septum Pellucidum*, and *Substantia Perforata Anterior* (Figs. 26 and 28).—These are the parts into which run most of the fibers of the medial and intermediate striæ of the olfactory tract. They are more conspicuous in the embryo than

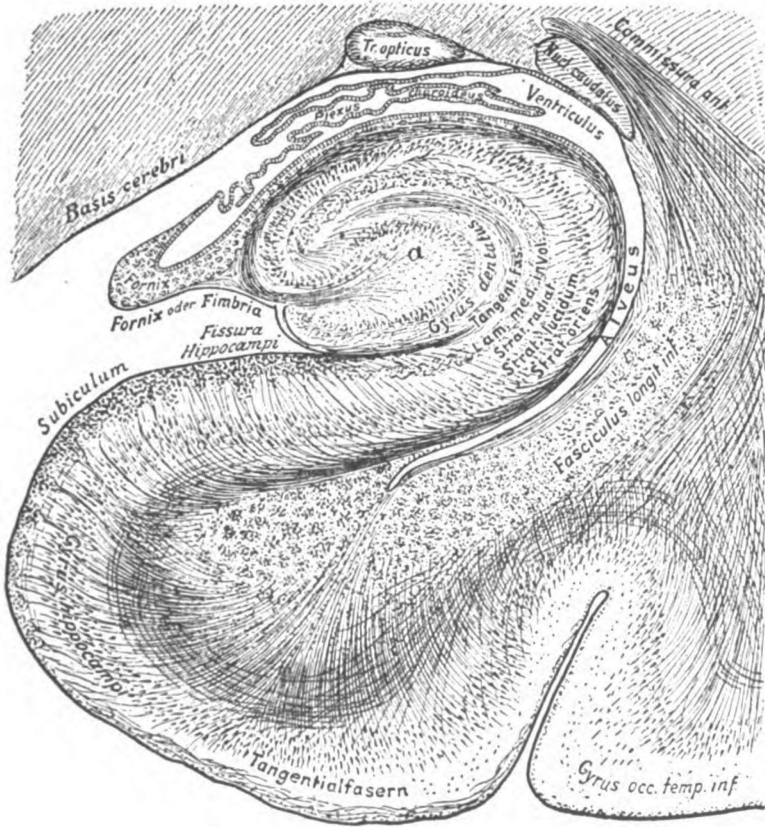


Fig. 62.—Transverse section of the hippocampal region. (After Edinger.)

a. Nucleus of fascia dentata.

in the adult human brain. The cortex of this whole region is so rudimentary or vestigial as to require but brief description. The plexiform layer may be identified. The whole gray substance beneath that is occupied by scattered pyramids of medium size, separated by strands of fibers belonging to the olfactory tract and, perhaps, to the cingulum.

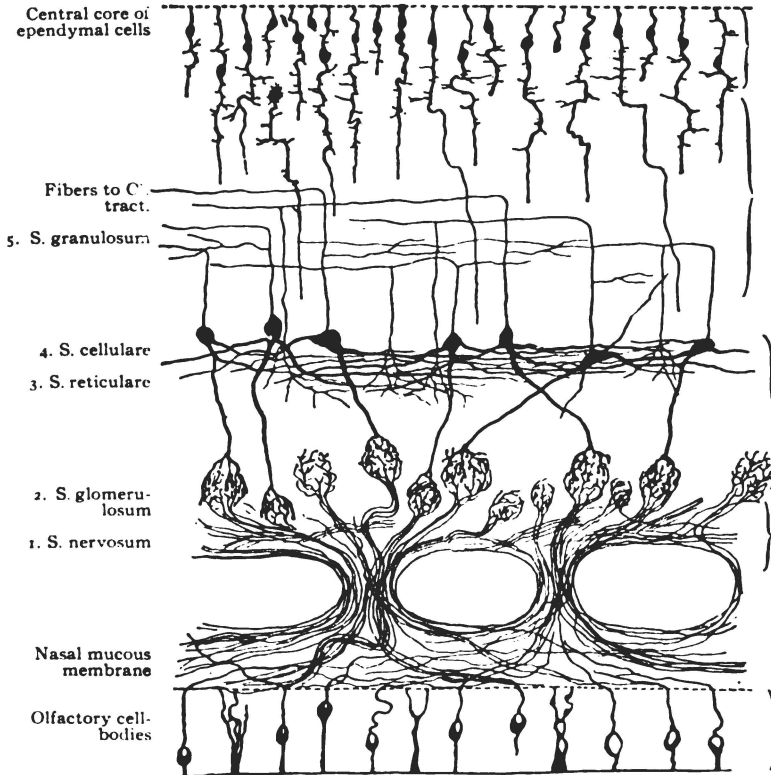


Fig. 63.—Chief elements of the olfactory bulb. (Gordinier after Van Gehuchten.)

The cortex of the gyrus cinguli (Fig. 28) is characterized by an entire absence of large fibers and large cells, by an oblique and irregular direction of the pyramids and by a most remarkable color affinity possessed by the deep cells. There are only *four cell layers*. (1) The plexiform presents a faint stratum zonale, but nothing characteristic. (2) The layer of small pyramids

is ill defined. (3) A layer of medium-sized pyramids placed at various angles occupies the place of the third, fourth, fifth and sixth layers of typical cortex. (4) The layer of spindle cells. In the spindle-cell layer are found the remarkable *chromophilous cells*. They are triangular or pyramidal in shape and have greater affinity for stains than the cells of any other part of the cerebral cortex.

The claustrum (Figs. 31 and 42) is a sheet of peculiar gray substance which, according to Meynert, may be classed as cortical. In structure it resembles the seventh layer of typical cortex, being made up of fusiform cell-bodies. The claustrum is a vertical antero-posterior sheet placed medial to the island, and lateral to the external capsule. The surface in contact with the external capsule is smooth, but the external surface is convoluted to coincide with the gyri insulæ. At its lower border it joins the lentiform nucleus.

II. GANGLIONAR GRAY MATTER.

The *substantia grisea ganglionaris* is found in the great ganglia which, in their situation and relations, have already been considered. They should be re-studied in this connection. They are as follows:

1. In the hemisphere:

The corpus striatum, composed of the caudate and the lentiform nucleus.

2. In the inter-brain:

The thalamus, lateral and medial geniculate bodies, nucleus hypothalamicus (Luysi) and red nucleus.

3. In the mid-brain:

The superior and inferior quadrigeminal colliculi, the substantia nigra, and the nucleus lateralis superior in the tegmentum.

The corpus striatum (Figs. 64, 31 and 66) is an ovoid mass of reddish-gray matter containing pigmented multipolar cell-bodies of various sizes, those of large size being more numerous in the nucleus lentiformis than in the nucleus caudatus. The

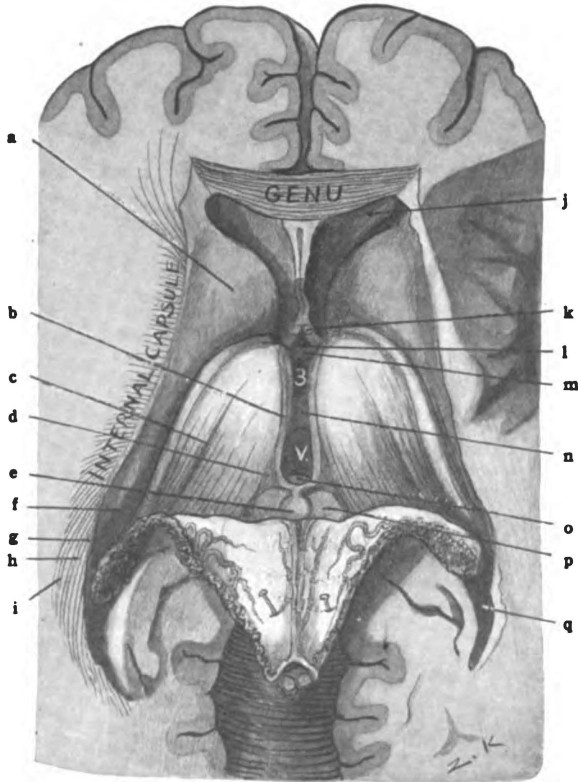


Fig. 64.—Horizontal section of cerebrum through genu and below splenium of corpus callosum. Fornix and chorioid tela turned back, to show inter-brain and third ventricle. (*Original.*)

a. Head of caudate nucleus. b. Stria medullaris thalami (or pineal stria.) c. Chorioid groove. d. Trigonum habenulae. e. Pineal body. f. Tail of caudate nucleus. g. Tapetum. h. Occipito-thalamic radiation. i. Inferior longitudinal fasciculus. j. Anterior horn of lateral ventricle. k. Columna of fornix. l. Recessus triangularis. m. Anterior commissure. n. Massa intermedia (or middle commissure). o. Posterior commissure. p. Superior, quadrigeminal colliculus. q. Posterior horn of lateral ventricle.

axones of those cell-bodies run both toward the pons and toward the cerebral cortex. The corpus striatum, therefore, forms a relay-station in an efferent conduction tract and, perhaps a less important one, in an afferent tract.

Of the **centrifugal fibers** note the following three groups:

(1) *The cortico-striate radiation* made up of corticifugal and

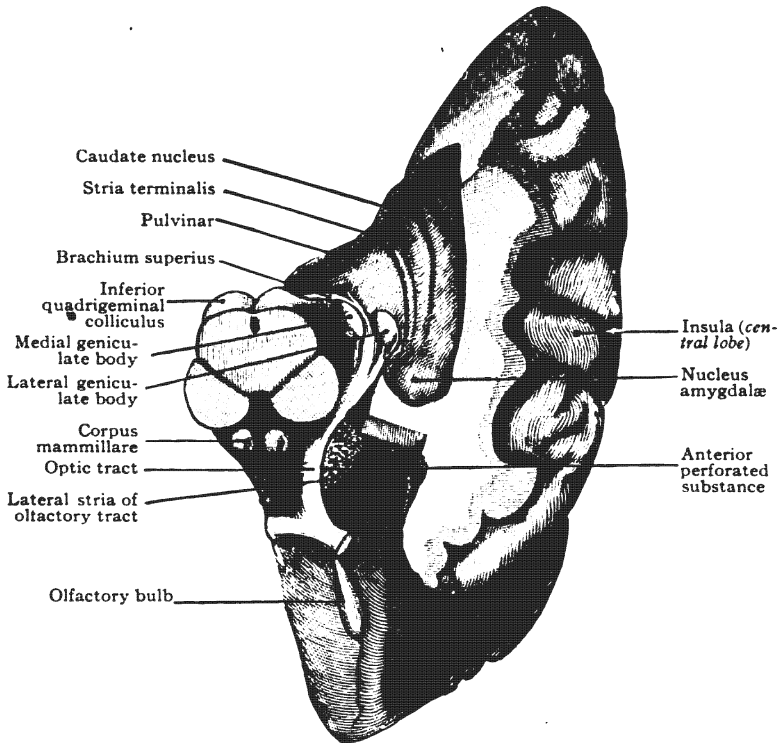


Fig. 65.—Dissection of brain to show geniculate bodies, optic tract, nucleus amygdalæ, etc. (After *Morris's Anatomy*.)

corticopetal fibers running from and to the equatorial zone of the hemisphere. (2) *The striato-thalamic fibers*, which are in part crossed fibers, pass through the inferior lamina of the internal capsule and terminate in many nuclei of the inter-brain, mid-brain and pons; some of them pierce the superior lamina of the capsule. They run to the thalamus, hypothalamus and

hypothalamic nucleus of both sides, the crossing fibers forming the *superior commissure* (Meynert's) in the tuber cinereum; to the nucleus ruber and quadrigeminal colliculi; and, through the deep part of the basis pedunculi, to the substantia nigra and nucleus pontis (Fig. 70). The last tract is the *stratum intermedium*, or the intermediate bundle of the basis pedunculi (Fig. 68). (3) *The olivary bundle* (fasciculus olivaris) probably rises in the globus pallidus (or thalamus) and descends to the nucleus of the olive in the medulla. In addition to the above, it is probable that the fronto-pontal and temporo-pontal tracts are relayed in the corpus striatum or thalamus.

The **centripetal fibers** connected with the corpus striatum are also numerous. (1) *The thalamo-striate fibers*, which belong to the common sensory path, rise partly in the thalamus and partly from nuclei lower down. They run through the frontal stalk and the ventral stalk of the thalamus and, perhaps, through the parietal stalk, and include uninterrupted fibers of the medial fillet and spino-thalamic tract (Fig. 70). (2) *Fibers from the globus pallidus* to the posterior central cortex in the cortico-striate radiation (the alpha and gamma bundles of Flechsig). These enter the parietal stalk high up in the superior lamina of the capsule.

Lesions of the corpus striatum affect the internal capsule, which impales it; and may cause, if extensive, hemiplegia and hemianesthesia of the opposite side of the body, partial deafness chiefly in the opposite ear and hemianopia due to cortical isolation of the corresponding halves of both retinae.

The **thalamus** (Figs. 64, 66 and 31) is made up chiefly of gray matter containing multipolar and fusiform cell-bodies. The white matter consists of the *stratum zonale* on its free surface and of the *internal medullary lamina*. The latter divides the gray substance into **nuclei**, of which Nissl has described about twenty. They may be grouped as follows: The medial, lateral, anterior, nucleus of the pulvinar and nucleus habenulae.

(1) The *medial nucleus* is joined to the opposite medial nucleus by the massa intermedia and is continuous with the hypothalamic gray matter in the wall and floor of the third ventricle; but the

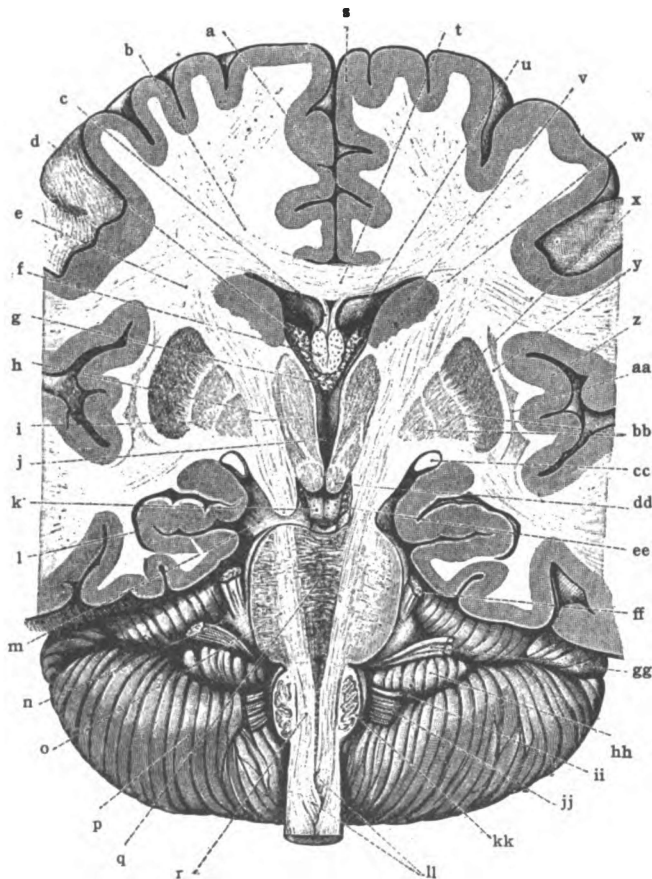


Fig. 66.—Transverse section of the brain in the line of the pyramidal tracts, showing basal ganglia, internal capsules, corpus callosum, lateral and third ventricles, etc. Viewed from front. (*Morris's Anatomy after Toldt.*)

a. Longitudinal fissure. b. Radiation of corpus callosum. c. Septum pellucidum. d. Chorioid plexus of lateral ventricle. e. Corona radiata. f. Column of fornix. g. Chorioid plexus of third ventricle. h. Internal capsule. i. Thalamus. j. Third ventricle. k. Interpeduncular fossa. l. Inferior horn of lateral ventricle. m. Cerebral peduncle. n. Brachium pontis. o. Longitudinal pyramidal fasciculi of pons. p. Cerebellum. q. Deep fibers of pons. r. Pyramid. s. Superior frontal gyrus. t. Body of corpus callosum. u. Anterior horn of lateral ventricle. v. Head of caudate nucleus. w. Radiation of corpus striatum. x. Putamen. y. External capsule. z. Insula. aa. Claustrum. bb. Globus pallidus. cc. Optic tract. dd. Corpus mammillare. ee. Oculo-motor nerve. ff. Trigeminal nerve. gg. Facial and acoustic nerves. hh. Flocculus. ii. Glossopharyngeal nerve. jj. Vagus nerve. kk. Inferior olivary nucleus. ll. Decussation of pyramids.

internal medullary lamina separates it from the other nuclei of the same thalamus. It gives origin to a part of the ventral stalk of the thalamus. According to Bechterew it probably gives rise to some descending fibers that run down the cord. (Jas. S. Collier has traced thalamo-spinal fibers in the cat down the lateral column of the cord.)

(2) The *lateral nucleus* is the largest. It extends from superior to inferior surface the entire length of the thalamus, and includes the *center median* (Luysi) and the *arcuate nucleus*, both of which fuse with it posteriorly. It also fuses with the nucleus of the pulvinar. It forms the terminal nucleus for the larger part of the tegmental fibers, especially of the medial fillet, the spino-thalamic tract, a part of the medial longitudinal bundle and the brachium conjunctivum of the cerebellum; and it constitutes the nucleus of origin for most of the fibers of the cortical fillet. Destruction of this nucleus interrupts the common sensory path, and causes anesthesia and ataxia of the opposite side.

(3) The *nucleus of the anterior tubercle* (Fig. 44) receives the fasciculus thalamo-mammillaris (Vicq d'Azyri) from the corpus mammillare and is thus connected with the columna of the fornix (Fig. 66).

(4) The *nucleus of the pulvinar* (Fig. 44) is an important one. It receives about twenty per cent. of the optic fibers and gives rise to a corresponding number of the corticopetal fibers in the optic, or occipito-thalamic radiation; hence, a lesion of the pulvinar impairs vision. It is continuous with the lateral nucleus.

(5) The *nucleus of the habenula* belongs to the *epithalamus* (Fig. 64). It lies beneath the trigonum habenulæ. It receives fibers from the rhinencephalon through the medullary stria of the thalamus, and originates a bundle of fibers, the fasciculus retroflexus (Meynerti), which may be traced back through the tegmentum to the interpeduncular ganglion in the substantia nigra. Beyond this, connections are probably established with the motor nuclei of cerebral nerves.

The **white matter** of the thalamus includes, first, the stratum zonale of the superior surface, which is derived from the occipito-thalamic radiation and the lateral root of the optic tract; and,

second, the interior fibers, a part of which form the internal medullary lamina. Into the thalamus enter the medial fillet, the spinothalamic tract, a small part of the medial longitudinal bundle, the brachium conjunctivum cerebelli and perhaps some other tegmental fibers, all carrying common sensory impulses; they end chiefly in the lateral nucleus, whence the cortical fillet proceeds to the sensory area of the cerebral cortex. The thalamus also receives fibers from the special sense paths, from the optic, auditory, olfactory, and probably the gustatory (?), and gives rise to fibers that continue in those paths to the special sense areas of the cortex or as, in the case of the olfactory, to reflex centers. It is also known that the thalamus is entered by a considerable number of corticifugal fibers, especially through the occipitothalamic and temporothalamic radiations. The several bundles of thalamic fibers are as follows:

(1) The *columna of the fornix*, having pierced the thalamus, descends to the corpus mammillare and terminates in its medial nucleus, whence the bundle of Vicq d'Azyr, the thalamo-mammillary bundle, rises and ascends to the thalamus. It ends in the anterior nucleus.

(2) The *stria medullaris thalami* (Fig. 64) from the hippocampus and from the region of the olfactory triangle, terminates in the nucleus habenulæ and from this nucleus the fasciculus retroflexus originates and descends to the interpeduncular ganglion. Both "one" and "two" belong to the olfactory paths.

(3) From the lateral surface of the thalamus issue two groups of fibers which rise chiefly in the lateral nucleus. They are common sensory in function: (a) The inferior one is the *ventral stalk* (ansa peduncularis) (Fig. 70), which rises from the medial and lateral nuclei and is in part relayed in the lentiform nucleus under which it passes toward its destination. It proceeds through the inferior lamina of the internal capsule and contributes fibers to both the medullary laminæ of the lentiform nucleus and to the external capsule. Underneath the lentiform nucleus the ventral stalk is divided into two horizontal laminæ by a thin sheet of gray substance. The upper lamina, the *ansa lenticularis*, is intermingled with the striatothalamic fibers and enters into the lenti-

form nucleus, where it probably terminates; but the conduction path to which it belongs is continued to the upper third of the posterior central and the paracentral gyri by the alpha and gamma bundles of Flechsig. The lower lamina of the ventral stalk, the inferior peduncle, runs principally into the external capsule medial to the claustrum, but a part of it dips under the claustrum. It terminates in the temporal lobe and the island. (b) The superior

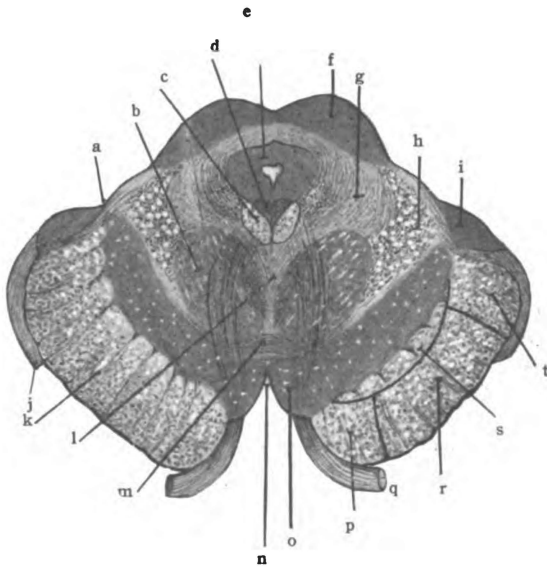


Fig. 68.—Section of the mid-brain through superior colliculi and the apparent origin of the oculomotor nerve. (Original.)

a. Sulcus lateralis of mid-brain. b. Red nucleus. c. Medial longitudinal bundle. d. Oculomotor nucleus. e. Stratum griseum centrale. f. Colliculus superior of corpora quadrigemina. g. Formatio reticularis. h. Medial fillet. i. Medial geniculate body. j. Optic tract. k. Basis pedunculi. l. Dorsal tegmental decussation (Meynerti). m. Ventral tegmental decussation (Foreli). n. Fossa interpeduncularis. o. Substantia nigra. p. Fronto-pontal tract. q. 3d. N. r. Pyramidal tract. s. Intermediate tract. t. Temporo-pontal tract.

group of fibers that issues from the lateral surface of the thalamus is the *parietal stalk* (Fig. 70). It rises from the lateral nucleus and traverses the superior lamina of the internal capsule. To a slight extent it is probably relayed in the lentiform nucleus. It terminates in the posterior central gyrus and in the paracentral lobule. This parietal stalk, in the upper limits of the internal capsule, contains nearly all of the common sensory fibers going

to the cortex. Flechsig has found that in development it is built up of six distinct strands of fibers, which receive their medullary sheaths one after the other; and he names the bundles, according to the order of their medullation, after the first six letters of the Greek alphabet (see page 232).

(4) The *frontal stalk* (Fig. 70) streams from the anterior end of the lateral nucleus via the frontal part of the internal capsule. Its fibers end in the corpus striatum and the frontal cortex. In

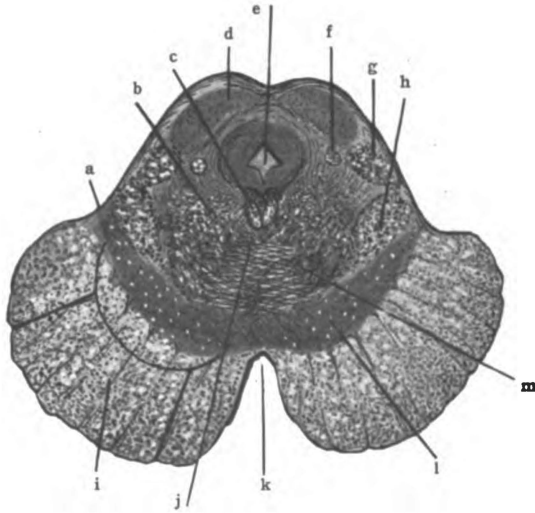


Fig. 69.—Section of the mid-brain cutting the inferior colliculi of the corpora quadrigemina. (Original.)

a. Sulcus lateralis. b. Formatio reticularis. c. Medial longitudinal bundle. d. Nucleus of colliculus inferior. e. Aqueductus cerebri. f. Rubro-spinal tract. g. Lateral fillet. h. Medial fillet. i. Basis pedunculi. j. Location of anterior longitudinal bundle. k. Interpeduncular fossa. l. Substantia nigra. m. Decussation of brachia conjunctiva.

the globus pallidus they are probably relayed to the somæsthetic cortex.

The ventral, parietal and frontal stalks of the thalamus constitute the *cortical fillet*; the *parietal stalk*, high up, contains nearly all the common sensory corticopetal fibers and, alone, is often called cortical fillet. The cortical fillet carries common sensations received from the medial fillet, the spino-thalamic tract, the medial longitudinal bundle and the brachium conjunctivum

cerebelli, up to the somæsthetic area (Fig. 54). Interruption of the cortical fillet stops all common sensory impulses—tactile, pain and temperature impulses, and impulses of the muscular sense.

(5) *Radiatio Occipito-thalamica* (Gratioleti).—A large pencil of fibers, the *optic*, or *occipito-thalamic radiation* (Fig. 70) passes from the lateral geniculate body and the pulvinar through the internal capsule to the visual centers in the occipital lobe. A number of fibers in the occipito-thalamic radiation are corticifugal and end in the superior quadrigeminal colliculus, though many are probably relayed in the thalamus and lateral geniculate body. Destructive lesion of the occipito-thalamic radiation of either side produces hemianopia and atrophy of the same side of both retinae.

(6) *Acustic Radiation or Radiatio Temporo-thalamica* (Fig. 70).—Another pencil of fibers radiates from the region of the medial geniculate body through the internal capsule to the auditory area in the temporal lobe. It constitutes the temporo-thalamic radiation. Its fibers are also in part corticifugal in direction. If the temporo-thalamic radiation be destroyed the result is partial deafness affecting chiefly the opposite ear.

According to von Bechterew certain lesions in the thalamus have been accompanied by loss of facial movements expressing emotion.

The **red nucleus** (*nucleus ruber*) of the tegmentum is situated beneath the thalamus (Figs. 42 and 46). It is a relay-station in the indirect sensory tract, receiving the opposite brachium conjunctivum cerebelli and, by its axones, continuing the tract to the thalamus and somæsthetic cortex. It also receives efferent axones from the cerebral cortex (Beever and Horsley) and gives origin to two bundles: (a) One centrifugal bundle of axones, (the rubro-spinal tract), after crossing over in the ventral decussation of the tegmentum (Forel's) descends, first, with the medial portion of the lateral fillet; second, through the lateral area of the medulla, and, third, through the lateral part of the spinal cord. Gradually diminishing, it disappears at the first lumbar segment. It ends in the lateral column and center of the gray crescent of the spinal cord. (b) The red nucleus also sends a bundle of axones through the opposite brachium conjunctivum of the cerebellum to the nucleus dentatus.

The **nucleus hypothalamicus** (Luysi) (Figs. 30 and 42) is a pigmented bi-convex mass of gray matter placed ventro-lateral to the red nucleus, and between it and the basis pedunculi. It is separated from the red nucleus by the *zona incerta*. It constitutes an important relay for certain corticopetal fibers of the tegmentum and gives origin to others belonging to the cortical fillet. Certain descending fibers from the striate body terminate in this nucleus. The latter run through the *tuber cinereum*, just above the posterior border of the optic chiasma, and form the *commissura superior* (Meynerti), Gudden's commissure being called the *commissura inferior*.

Metathalamus.—The metathalamus is made up of two ganglia at the posterior end of the thalamus, called the geniculate bodies (Fig. 65). The **lateral geniculate body** (*corpus geniculatum laterale*) contains pigmented multipolar cells, which receive 80 per cent. of the optic fibers in the corresponding tract and give origin to a like per cent. of the corticopetal fibers in the occipitohalamic radiation; and, also, receive corticifugal fibers from the same radiation and originate a part of the *brachium superius*. The latter are reflex in function. As the dark cell-bodies are arranged in layers separated by laminæ of fibers, the body has a stratified appearance. The **medial geniculate body** (*corpus geniculatum mediale*) is gray in color. Placed at the end of the medial root of the optic tract, it would at first appear to be concerned in vision; but it is not visual in function. Moreover, it is a very important station in the auditory path. The medial optic root is merely Gudden's commissure, the fibers of which are supposed to rise in the medial geniculate body. This body contains chiefly fusiform cell-bodies which, in addition to their connection with the inferior commissure (of Gudden), receive the end-tufts of fibers in the *brachium inferius* and send their axones through the acoustic, or temporo-thalamic radiation to the auditory cortex; the cells also receive corticifugal fibers through the temporo-thalamic radiation and, probably, shoot some of their axones backward through the *brachium inferius* to the *corpora quadrigemina*. The latter are reflex in function.

Ablation of the lateral geniculate body interrupts the visual

path, destruction of the medial geniculate breaks the auditory path.

The **superior colliculi of the corpora quadrigemina** (Figs. 65 and 68) represent the optic lobes of birds, fishes and reptiles. They contain the center of optic reflexes. In being stratified, they bear some resemblance to the lateral geniculate bodies. They possess three white and two gray layers: (1) The *stratum zonale* (*stratum album superficiale*) is a layer of white matter on the surface. This invests the *laminated stratum griseum*, which forms the deep part of the colliculus and comprises two gray and two white layers: (2) The *stratum griseum superficiale* is composed of small multipolar cells. (3) The *stratum album medium* is a layer of fibers separating the small from the large multipolar cells. (4) The large cells make up the *stratum griseum profundum*, underneath which is another layer of fibers. (5) *The stratum album profundum*. The **fibers** of the superficial, middle and deep strata comprise, *first*, those that enter the colliculus through the optic tract and radiation, through the superior and a part of the lateral fillet, the striato-thalamic tract and the spino-thalamic tract; and, *second*, those that take origin in the colliculus and leave it through the brachium superius or the anterior longitudinal bundle. Of the fibers originating in the superior colliculus and running through the brachium superius it is supposed that some go as far as the retina; probably others enter the cortical fillet.

The *anterior longitudinal bundle* is made up of efferent axones of the cell-bodies in the superior colliculus. It crosses at once through the dorsal tegmental decussation (Fig. 68) and descends ventro-lateral to the opposite medial longitudinal bundle, to the anterior column of gray matter in the spinal cord. Its fibers end largely in the nuclei of the third, fourth and sixth cerebral nerves and in the cervical enlargement of the spinal cord; but perhaps others enter the remaining nuclei of motor cerebral nerves, and a few fibers of the tract have been traced as low as the lumbar region. This bundle is the *great optic reflex tract*. The fibers to the nuclei of the third, fourth and sixth cerebral nerves bring about the reflex movements of the eyeball, contraction

of the pupil and accommodation to distance; while those fibers which end in the gray substance of the lower part of the cervical enlargement of the spinal cord, called the cilio-spinal center, through the white rami communicantes and cervical sympathetic, produce dilatation of the pupil. The latter constitute the *pupillo-dilator tract*.

Destructive lesions affecting the superior quadrigeminal colliculi produce loss of reflex movement of the eyeballs, loss of pupillary reflex and loss of accommodation.

The **inferior colliculi of the corpora quadrigemina** form a relay in the auditory path (Figs. 65 and 69). They are made up of a white *stratum zonale*, whose fibers are continuous chiefly with the lateral fillet and brachium inferius, and of a deep gray mass, the *nucleus colliculi inferioris*, which is composed of small multipolar cell-bodies in a network of fibers. The nuclei of the two eminences fuse in the median plane. In the nuclei end a considerable number of fibers belonging to both lateral fillets, but most of them belong to that of the same side; and from them proceed axones of the auditory paths through the brachia inferiora to the medial geniculate bodies. A few fibers of the spino-thalamic tract also end in the inferior colliculus. Again this colliculus receives a small bundle of the striato-thalamic fibers and, probably, corticifugal fibers of the temporo-thalamic radiation.

Though the greater part of the lateral fillet passes by the inferior colliculus without relay, a lesion in this body is apt to involve the entire bundle and cause almost complete deafness in the opposite ear.

Nucleus Lateralis Superior (Fig. 68).—In the reticular formation of the tegmentum at the level of the superior quadrigeminal colliculus is the nucleus lateralis superior. It contains large multipolar cell-bodies. The nucleus forms a relay both for ascending and descending fibers of the formatio reticularis. According to Tschermak, a small fasciculus runs from this nucleus into the medial longitudinal bundle where it divides T-like; and its descending fibers run down through the anterior fasciculus proprius of the cord (Barker). The spino-thalamic tract probably undergoes a partial relay in the superior lateral nucleus.

Substantia Nigra (Figs. 66, 67, 68 and 69).—The small pigmented multipolar cell-bodies which make up the substantia nigra form, *first*, a terminal nucleus for certain fibers of the medial fillet and a nucleus of origin for other fibers which continue in that tract (Barker); and, *second*, a terminal station for the fasciculus retroflexus (Meynerti) and a relay for the intermediate tract from the corpus striatum. Beyond this terminal station the efferent tracts are probably continued, but with the exception of the intermediate tract they have not been traced. The intermediate tract is relayed to the nucleus pontis.

III. CENTRAL, OR VENTRICULAR GRAY MATTER.

It is located (1) in the floor and walls of the third ventricle, the *hypothalamus*; (2) in the middle commissure of that ventricle, the *massa intermedia*; and (3) around the cerebral aqueduct, the *stratum griseum centrale*.

(1) **The Hypothalamus, Pars Optica.**—The *lamina cinerea terminalis* and the *tuber cinereum* (Figs. 21 and 27) form a sheet of gray substance that connects the inferior and medial surfaces of the cerebral hemispheres and may be called their inferior gray commissure. The optic chiasma is white matter, and the hypophysis is not composed of nerve tissue at all and, therefore, neither one need be described in this place. From the floor of the third ventricle the gray matter extends laterally beneath the thalamus, and is continuous with the anterior perforated substance. The gray matter of the floor also extends up to the sulcus hypothalamicus on the medial surface of the thalamus. The inferior gray commissure receives efferent fibers from the corpus striatum of both sides. Some of these fibers form a commissure just above that of Gudden; hence, it is called the *commissura superior* (Meynerti) to distinguish it from the *commissura inferior* (Guddeni) in the optic chiasma. The fibers of Meynert's commissure cross through the tuber cinereum.

Hypothalamus, Pars Mammillaris (Figs. 26 and 46).—The corpora mammillaria (*albicantia*), though composed of fornix fibers on the surface, contain in the interior **two nuclei**, the medial and lateral. The *medial nucleus* is the larger of the two. It

receives the end-tufts of the fibers in the columna of the fornix and gives origin to the fasciculus mammillaris princeps. The latter bifurcates, sending one branch, the thalamo-mammillary bundle (of Vicq d'Azyr), up to the anterior nucleus of the thalamus and the other branch, the fasciculus pedunculo-mammillaris, backward into the tegmentum. The fasciculus thalamo-mammillaris (Vicq d'Azyri) connects the fornix with the thalamus. The tegmental part of the pedunculo-mammillary bundle has been traced, in the mouse by Cajal, downward to the lower part of the pons, running anterior to the medial longitudinal bundle (Barker). The small *lateral nucleus* of the corpus mammillare gives origin to the basilar part of the pedunculo-mammillary bundle, which according to Flechsig ends in the substantia grisea centrale of the mid-brain and is thence connected with the motor nerve-nuclei and the automatic centers of the medulla (Barker). Through the fornix, the stria medullaris thalami and the fasciculus retroflexus, and through the fornix and the pedunculo-mammillary bundles the reflex connections of the olfactory nerve are in part established.

(2) **The massa intermedia** (*the middle commissure*, Figs. 27 and 64) joins the medial nuclei of the thalami. It is formed, when present, by the approximation and fusion of the thalami in the second month of embryonic life. It is occasionally absent. In the massa intermedia are cell-bodies and transverse fibers. The latter appear to be loops which reach only to the median line; at least many of the fibers do not cross to the opposite side. It is not a commissure in the ordinary sense of that term.

(3) **The stratum griseum centrale of the mid-brain** (Figs. 46, 68 and 69) surrounds the cerebral aqueduct (Sylvii). This gray matter begins in the lateral wall of the third ventricle. It extends through the mid-brain and is continuous with the gray substance in the floor of the fourth ventricle. Besides the nuclei of the third, fourth and a part of the fifth cerebral nerves, it contains scattered cell-bodies of variable size and shape which give origin to the true commissural fibers of the posterior commissure. According to Flechsig this central gray substance receives the basilar part of the pedunculo-mammillary bundles and probably

gives origin to fibers that descend to the motor nuclei of the pons and the medulla.

Oculomotor Nucleus (Figs. 45 and 68).—The nucleus of the third cerebral nerve (nucleus nervi oculomotorii) is an elongated mass of gray substance in the ventral part of the stratum griseum centrale, which extends from the lateral wall of the third ventricle down to the level of the transverse groove between the quadrigeminal colliculi. The nuclei are placed somewhat obliquely; at the lower end they fuse in the median plane. According to Perlia, seven distinct cell-nests are found in each nucleus; and nest fifteen occupies the area of fusion and is common to both nerves. The greater number of axones of this nucleus run *forward* into the nerve of the same side; but those from the median nest go into both nerves, and a small bundle from each nucleus descends with the medial longitudinal bundle to the colliculus facialis, where it joins the facial nerve and through that nerve supplies the muscles of facial expression above the orbit.

Trochlear Nucleus (Fig. 69).—The nucleus nervi trochlearis is a small oval mass of cell-bodies situated anterior to the inferior colliculus of the corpora quadrigemina. It is in the ventral part of the stratum griseum centrale like the oculomotor nucleus. Unlike the third, the axones from the nucleus of the fourth cerebral nerve run *backward* and issue from the posterior surface of the mid-brain at the isthmus; they are peculiar also, in that the axones decussate before their emergence (Fig. 65).

The nuclei of the oculomotor and trochlear nerves receive *fibers from the cerebral cortex* through the pyramidal tract and other motor tracts of the internal capsule and thus obtain their voluntary motor and inhibitory impulses. It is probable also that the third nucleus receives fibers, through the medial longitudinal bundle, from the opposite abducent nucleus, and that the part of the nucleus which receives these fibers supplies the internal rectus muscle of the eye. For the *purpose of reflex* both the oculomotor and trochlear nuclei receive fibers from the anterior and medial longitudinal bundles, from the pedunculo-mammillary bundles (?) and, perhaps, from the cerebellum through the brachia conjunctiva.

Trigeminal nucleus of the mid-brain is a very small nucleus situated in the extreme lateral part of the central gray matter. It is continuous with the pontine nucleus of the fifth, located under the locus cæruleus, and is merely the superior end of the motor nucleus of the trigeminal. It gives origin to the descending root of the fifth nerve, which descends to the pons and there joins the main motor root. In its course downward the mesencephalic root runs between the central gray matter and the brachium conjunctivum cerebelli.

Lesions of these cerebral nerve nuclei are apt to involve the tegmentum. If so, the result is paralysis of the nerves on the same side and hemianæsthesia, hemiataxia, loss of taste (?) and deafness on the opposite side.

The **white matter of the cerebrum** is composed, in the adult condition, of medullated fibers; the medullation begins in the ninth month, in utero, and is continued for a considerable time after birth (Flechsig). Within the cortical substance the myelin sheaths continue to be laid down until late in life (Kaes, McMurrich). The cerebral fibers form three definite systems:

1. Projection, or peduncular fibers.
2. Transverse, or commissural fibers.
3. Association fibers.

I. PROJECTION FIBERS.

The projection fibers are connected only with the motor and sensory areas of the cerebral cortex and are, therefore, motor and sensory in function (Figs. 54 and 55). Where they are present they are continuous with Meynert's radiations. They are composed, *first*, of the medullated axones of the pyramids and the polymorphous neurones; these descend from the cerebral cortex, are motor in function, or corticifugal, and constitute the upper motor segment; and, *second*, they comprise the medullated axones of neurones whose cell-bodies are situated in gray matter below the cerebral cortex; these axones ascend to the cortex and are sensory in function, or corticipetal. The projection fibers run from cerebral cortex through the corona radiata, the internal

capsule and the mid-brain, and vice versa (Figs. 30 and 42). They connect the cortex, directly or indirectly, with all parts of the body, throwing or projecting a picture of every part and organ upon the cerebral cortex. Many of the fibers are interrupted in the basal ganglia, especially of the corticopetal fibers. Within the hemisphere all projection fibers run through one great sheet, the internal capsule, with the exception of the olfactory; but in the mid-brain, they are separated into two great groups—the basis pedunculi and the tegmentum, the substantia nigra intervening.

CORTICIFUGAL, OR MOTOR PROJECTION FIBERS.

The most important tracts of corticifugal or motor projection fibers are the following, namely, the intermediate tract, the fronto-pontal tract, the pyramidal tract and the temporo-pontal tract.

The **intermediate tract** (*stratum intermedium pedunculi*, Figs. 70, 69 and 87) extends from the corpus striatum through the inferior lamina of the capsule and the deep part of the basis pedunculi to the motor cerebral nuclei and to the nucleus pontis, though it is probably relayed in the substantia nigra. From the nucleus pontis axones run by way of the brachium pontis to the cortex of the opposite hemisphere of the cerebellum. The intermediate tract thus forms a segment of an indirect (through the cerebellum) efferent, or motor path.

The **fronto-pontal tract** (*tractus cerebro-cortico-pontalis frontalis*, Figs. 70, 71, 69 and 87) rises from the cortex of the frontal lobe anterior to the precentral sulci. It tranverses the centrum semiovale, corona radiata, frontal part of the internal capsule and medial one-fifth of the basis pedunculi to the ventral area of the pons, where it terminates in the nucleus pontis (chiefly) and in the nuclei of motor cerebral nerves (Flechsig). It is probably relayed in the thalamus (Beevor and Horsley).

According to Dejerine, the **temporo-pontal tract** (*tractus cerebro-cortico-pontalis temporalis*, Figs. 70, 71, 69 and 87) extends from the temporal lobe through the inferior lamina (and posterior part of the superior lamina) of the internal capsule and lateral one-fifth of the basis pedunculi to the substantia nigra and the

nucleus pontis; but according to Spitzka some of its fibers end in the nuclei of motor cerebral nerves. Thus it should be noted that, with the exception of those fibers to motor nuclei of the cerebral nerves, each of the three tracts above mentioned, viz., the intermediate, fronto-pontal and temporo-pontal, constitutes a segment of an indirect efferent path which is interrupted in the nucleus pontis and then continued by the axones of that nucleus through the brachium pontis of the cerebellum. It is probable, though not surely established, that the fronto-pontal and tempo-

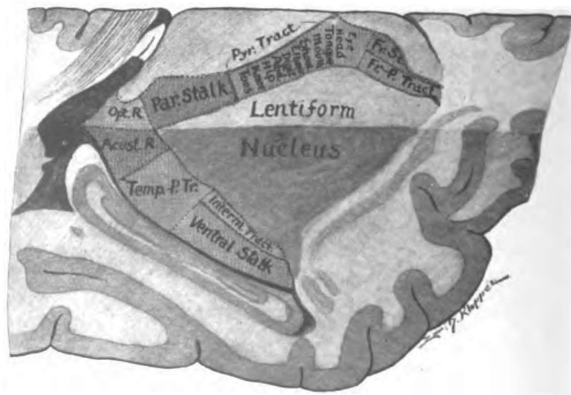


Fig. 70.—Horizontal and sagittal section through internal capsule, much enlarged. (Original.)

BLUE, Common sensory tracts: Fr. St., Frontal stalk; Par. Stalk, Parietal stalk; Ventral stalk. RED, Motor tracts: Fr.-P. Tract, Fronto-pontal tract; Pyr. Tract, Pyramidal tract; Temp.-P. Tr., Temporo-pontal tract; Interm. Tract, Intermediate tract. PURPLE, Special sense tracts: Opt. R., Occipito-thalamic radiation; Acust. R., Temporo-thalamic radiation.

rontal tracts are relayed in the corpus striatum or thalamus, as they have been found undegenerated in the base of the peduncle when their cortical origins were destroyed by extensive lesions.

The **pyramidal tract** (*tractus cerebro-spinalis pyramidalis*) (Figs. 70 and 71) rises in the anterior central gyrus and the pre-central part of the paracentral lobule. It is composed of axones from the giant pyramids and large polymorphous cells of that region. Descending through the corona radiata, genu and anterior two-thirds of the occipital part of the internal capsule, the pyramidal tract comprises the middle three-fifths of the basis pedunculii, enters into the anterior longitudinal fibers of the pons,

forms the pyramid of the medulla and the anterior and lateral pyramidal tracts of the spinal cord (Figs. 71, 69, 87, 93 and 102). The fibers of the pyramidal tract, with a few exceptions, cross over to the opposite side; they end in connection with the motor nuclei of cerebral and spinal nerves. Fibers enter the nucleus of the trochlear (or fourth) nerve chiefly on the same side, and a few descend to the motor nuclei of other cerebral nerves and to the gray matter in the spinal cord without decussation; all other pyramidal fibers terminate on the side opposite to their origin. The fibers from the lower one-fourth of the anterior central gyrus, which go to the motor nuclei of the cerebral nerves, to a large extent

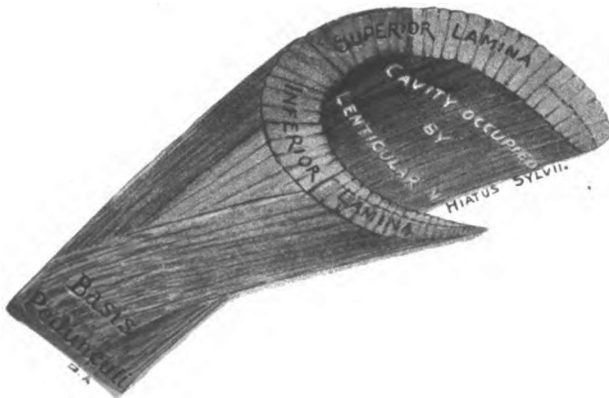


Fig. 71.—Diagram of internal capsule in colors. (*Original.*)
RED, motor; BLUE, common sensory; PURPLE, special sensory.

leave the pyramidal tract high up in the peduncle and run for some distance through the medial portion of the fillet; they constitute Bechterew's *accessory lemniscus*. This accessory fillet has been recently traced by Flechsig.

Head and Neck Fibers (Figs. 70, 105 and 106).—Those fibers of the pyramidal tract which end in the nuclei of the cerebral and the upper four cervical nerves rise in the lower segment of the motor area, including that part of the anterior central gyrus below the genu inferius of the central sulcus. They run through the genu of the internal capsule to the peduncle and, then, both through

the accessory fillet and the inner portion of the middle three-fifths of the basis pedunculi. *Upper Extremity Fibers* (Figs. 70 and 105).—The fibers of the pyramidal tract that end in the cervical part of the spinal cord, and through it innervate the muscles of the upper extremity, take their origin from that part of the anterior central gyrus adjacent to the foot of the middle frontal gyrus: their origin lies between meridians which intersect the central sulcus at the genu inferius and the genu superius, respectively. These fibers run through the pars occipitalis of the internal capsule just behind the genu, and through the basis pedunculi immediately lateral to the head and neck fibers. Those fibers which innervate the muscles of the thumb, fingers and hand, rise lowest down in the arm area of the cortex and occupy the posterior part of the arm bundle in the internal capsule and the lateral part of it in the peduncle. The fibers which control the shoulder muscles rise in the upper part of the cortical area and form the anterior and medial part of the arm bundle in the capsula interna and basis pedunculi, respectively; while the wrist, forearm, elbow and arm are innervated by means of fibers which are intermediate in both origin and course. *Trunk Fibers*.—The trunk fibers of the pyramidal tract rise in that projection of the anterior central gyrus which is situated just above the genu superius of the central sulcus. In the internal capsule, the trunk fibers run just behind those to the fingers and just lateral to them in the basis pedunculi. *Lower Extremity Fibers* (Figs. 70 and 105).—A large number of the pyramidal fibers terminate in the lumbar enlargement of the spinal cord and carry impulses to the nerves of the lower extremity. They originate in the upper fourth of the anterior central gyrus and in the paracentral lobule. The hip fibers rise farthest downward and the toe fibers farthest upward, immediately in front of the sulcus centralis. The fibers have the same relative position in the internal capsule; in the base of

Description to Fig. 72.

a, a. Motor cells of cerebral cortex. b, b. End-tufts of sensory fibers in cortex. c. Nucleus of funiculus cuneatus, showing end-tufts of fibers from the cord. d. Nucleus of funiculus gracilis, containing end-tufts of fibers from cord. e. Section of medulla at fillet decussation. f. Section of medulla at pyramidal decussation. g, g. Motorial end-plates. h. Section of cervical cord, showing terminations of fibers of anterior and lateral pyramidal tract. i, i. Spinal ganglia. j, k. Short sensory fibers. l. Long sensory fibers. m, m, m. Sensory end-organs. n. Section of lumbar cord.

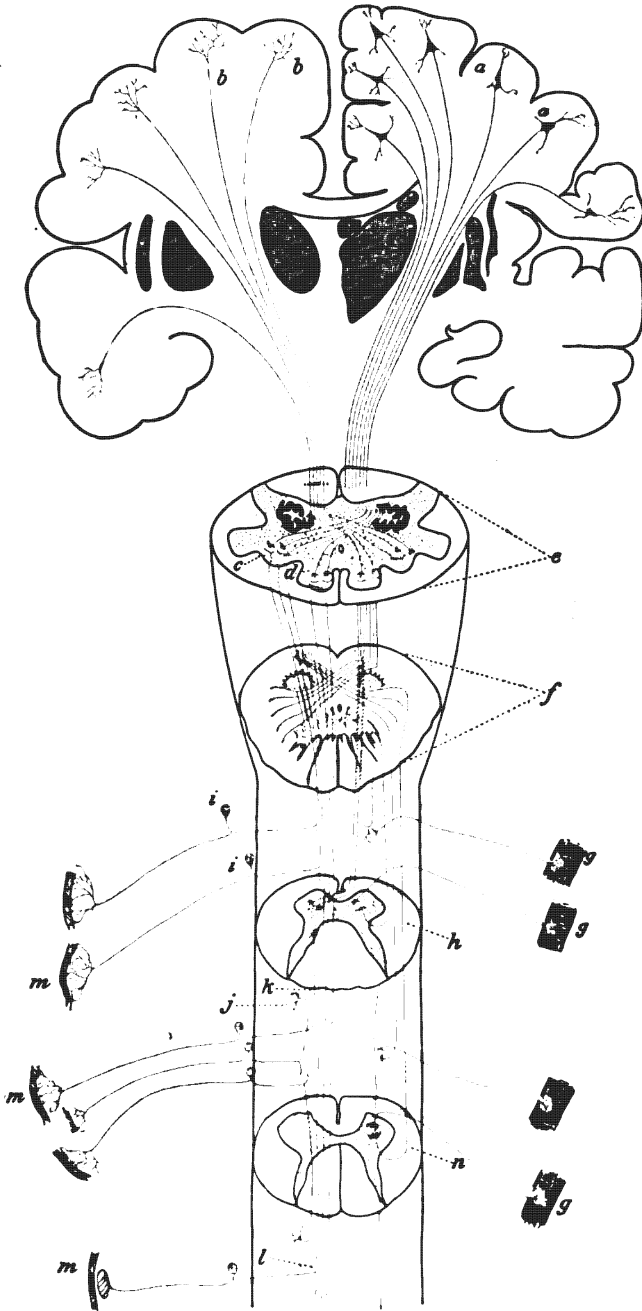


Fig. 72.—A diagram showing motor and sensory paths; motor red, sensory blue.
(After Gordinier.)

the peduncle the hip fibers are medial and the toe fibers lateral. Fibers which innervate the muscles of the thigh, leg and small toes have this same relative position and order between the hip and great toe fibers both in their cortical origin and in their course through the internal capsule and basis pedunculi.

There are *other corticifugal fibers* in the internal capsule, viz., some within the occipito-thalamic and temporo-thalamic radiations (Figs. 70 and 71) and others running from the special and common sensory areas of the cortex; but these fibers are probably reflex in function and do not properly belong to the projection group.

Several bundles of descending fibers are found in the tegmentum, namely, the anterior longitudinal bundle, which is reflex in function, the rubro-spinal tract from the red nucleus, a small part of the brachium conjunctivum of the cerebellum, the descending root of the trigeminal nerve, the olivary bundle, and certain other fibers in the formatio reticularis. With these exceptions the tegmentum is ascending in direction and sensory in function.

Destruction by clot or tumor, or otherwise, of any of the above divisions of the pyramidal tract causes upper segment paralysis of the particular muscles innervated through that tract, the muscles being spastic and the reflexes increased.

SENSORY OR CORTICIPETAL PROJECTION FIBERS.

The sensory or corticipetal projection fibers of the tegmentum comprise the medial, superior and lateral fillets; the spino-thalamic tract; the brachium conjunctivum of the cerebellum; a part of the medial longitudinal bundle; and certain other ascending fibers of the formatio reticularis. Excepting a small number of fibers, all these bundles terminate in the basal ganglia; but the paths of conduction are continued through the internal capsule. The *medial fillet* carries impressions of the tactile and the muscular senses; the *spino-thalamic tract* conducts tactile, pain and temperature impulses; while all varieties of common sensory impulses are carried by the *brachium conjunctivum cerebelli*. Chiefly through these three tracts, common sensory impressions

arrive in the lateral nucleus of the thalamus. In the capsula interna the corticopetal projection fibers constitute the *cortical fillet* and the *optic* and *acoustic* (and *gustatory?*) *radiations*. The former end in the somæsthetic area of the cerebral cortex, the latter in the visual, auditory and gustatory cortex.

The *olfactory projection fibers* are contained neither in the tegmentum nor in the internal capsule. They proceed from the olfactory bulb, through the olfactory tract and its striæ, directly to the cerebral cortex.

The exact origin of the **cortical fillet** (Figs. 70 and 71) has not been entirely determined, but it is known to rise, chiefly, in the lateral nucleus of the thalamus. The *ventral stalk of the thalamus* (Fig. 70) runs through the internal capsule, in the inferior lamina. It is relayed largely in the globus pallidus. Its fibers enter the medullary laminæ of the nucleus lentiformis and the external capsule; ultimately they terminate in the upper one-third of the posterior central gyrus and in the temporal and insular lobes (see p. 212). From the anterior end of the thalamus streams a great pencil of fibers, called the *frontal stalk* (Fig. 70). It mingles to a small extent with the fibers of the pyramidal tract, but runs chiefly through the frontal part of the internal capsule. Its termination is largely in the corpus striatum; some of its fibers reach the frontal cortex.

The *parietal stalk* issues from the lateral surface of the thalamus higher up than the ventral stalk and mingles with the pyramidal fibers in the superior lamina of the internal capsule. Its location is principally in the posterior third of the occipital part of the capsule (Figs. 70 and 71). It terminates in the paracentral lobule and the posterior central gyrus. According to Flechsig some fibers also end in the upper extremity of the anterior central, the superior frontal gyri and in the underlying part of the gyrus cinguli. The *parietal stalk*, if we may apply this name to all the common sensory fibers in the occipital part of the capsule, ultimately comprises all the corticopetal fibers to the somæsthetic area. Flechsig gives their origin and termination, in the order of their medullation, as follows:

- a. The alpha bundle, a small one, runs from the globus pal-

lidus to the upper third of the central gyri, chiefly to the anterior central. Origin is in doubt.

β . A large bundle from the posterior inferior part of the lateral nucleus to the upper third of the central gyri, chiefly to posterior central gyrus and adjacent part of the paracentral lobule.

γ . The gamma bundle is large. It runs from the globus pallidus to same area as beta bundle. Origin is in doubt.

δ . Runs from the lateral nucleus of thalamus (from the central of Luys and the arcuate nuclei) to the middle third of the central gyri, principally to the posterior central.

ϵ . A bundle from the antero-inferior part of the lateral nucleus to the lower third of the posterior central gyrus.

ζ . The zeta bundle is last to be medullated. It rises in the superior part of the lateral nucleus and terminates in the foot (posterior end) of the superior frontal gyrus and in that part of the gyrus cinguli which underlies the foot of the first frontal.

The *cortical fillet* conveys common sensory impulses to the somæsthetic area of the cerebral cortex. If the cortical fillet be severed, all common sensory impulses to that hemisphere are interrupted; and complete loss of common sensation on the opposite side of the body and hemiataxia result.

Just where the fibers conducting *taste* impulses are located in the tegmentum is unknown. *Auditory* impulses run through the lateral fillet and the brachium inferius to the medial geniculate body; while *optic impulses* run directly to the lateral geniculate body and the pulvinar without passing through the mid-brain at all. Within the internal capsule the gustatory tract cannot at present be located; but the acoustic and visual paths are well known.

The *acoustic, or temporo-thalamic radiation* (Figs. 70 and 54) continues the auditory path from the medial geniculate body through the retrolentiform part of the internal capsule, to the transverse temporal gyri and the third and fourth fifths of the superior temporal gyrus (Barker). Interruption of these fibers produces deafness in the opposite ear, which is not complete because the acoustic path is not wholly crossed. There are some

corticifugal fibers in the temporo-thalamic radiation; they are probably reflex in function.

The optic, or occipito-thalamic radiation (Figs. 70, 38, 45 and 55) rises in the lateral geniculate body and in the pulvinar of the thalamus. It continues the visual conduction path through the retrolentiform region of the internal capsule to the cortex of the lingual and cuneate gyri. Half-blindness in the same side of both retinae results from section of the optic radiation. The corticifugal fibers in the occipito-thalamic radiation are believed by Campbell to be axones of the solitary giant cells (Meynert's) in the occipital cortex. They run through the lateral geniculate body and brachium superius to the superior colliculus of the corpora quadrigemina, where they end in contact with the neurones of the anterior longitudinal bundle. Their function is reflex.

II. COMMISSURAL FIBERS.

They connect opposite sides of the cerebrum and, like the projection fibers, are continuous with the radiations of Meynert. They are contained chiefly in the corpus callosum, the anterior commissure, and the commissura hippocampi; but are also found in the posterior commissure, commissura hebenularum, inferior (Gudden's) and superior (Meynert's) commissures.

The **corpus callosum**, as already described, is the great link between the cerebral hemispheres (Figs. 34, 27 and 73). Its fibers connect both similar and dissimilar parts of the cortices; within the hemisphere, they form a prominent radiation, called the *radiatio corporis callosi*. The corpus callosum is made up almost wholly of cortical axones, a few of them being projection fibers; of a small number of afferent projection fibers, and of collaterals from the association and projection fibers. All callosal fibers, except the few efferent projection fibers, end on the opposite side in arborizations within the cortex. It is the corpus callosum, chiefly, that makes it possible for the two hemispheres of the cerebrum to act together as one organ. Phylogenetically, it is of recent development, since it is not found below mammals.

The **anterior commissure** (Figs. 73, 40 and 30) joins the

opposite temporal and occipital lobes together (*pars occipilo-temporalis*), the limbic lobes with the contra-lateral olfactory tracts, and the olfactory tracts with each other (*pars olfactoria*). It is supplementary to the corpus callosum and associates regions not joined by the great commissure, especially the cortex of the tentorial areas of the cerebral hemispheres. In size it varies

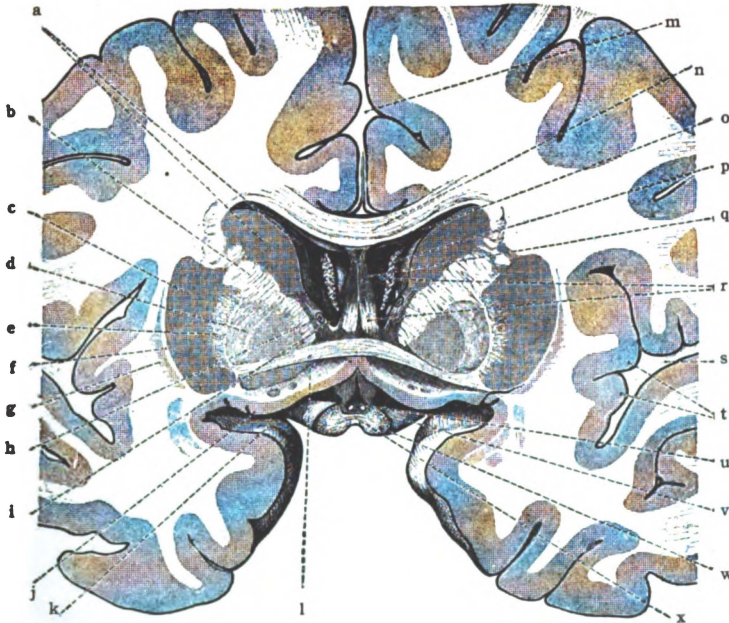


Fig. 73.—Transverse section of cerebrum, cutting corpus callosum, anterior commissure and optic chiasma. Viewed from front. Commissural fibers. (*Morris's Anatomy after Toldt.*)

a. Caudate nucleus (head). b. Internal capsule (frontal portion). Lentiform nucleus: c. Putamen, d. Globus pallidus. e. Medullary lamina. f. External capsule. g. Claustrum. h. Vena terminalis. i. Interventricular foramen (Monroi). j. Anterior perforated substance. k. Uncus. l. Anterior commissure. m. Longitudinal fissure. n. Corpus callosum. o. Anterior horn of lateral ventricle. p. Chorioid plexus of lateral ventricle. q. Septum pellucidum. r. Columns of fornix. s. Lateral fissure (Sylvii). t. Gyri of insula. u. Optic recess. v. Optic tract. w. Optic chiasma. x. Inferior commissure (Guddeni).

inversely as the corpus callosum. Its importance diminishes with the appearance of the corpus callosum in the lower mammalia and it continues to decrease as the higher forms are approached. Below mammals it is said to be the most important connecting link between the hemispheres and is phylogenetically very old.

The **commissura hippocampi**, the *lyre* (Fig. 36), unites the hippocampal gyrus, dentate fascia, and the hippocampus with their fellows of the opposite side. This is the commissure of the pyriform lobes, the cortical areas of smell.

III. ASSOCIATION FIBERS.

These fibers remain on the same side and connect parts of the same hemisphere. They are situated within or beneath the cortex, the various parts of which they serve to unite. Association fibers become medullated and actively functional only as mental effort and education gradually develop them. So far as the brain is concerned education consists, *first*, in the development of the functional centers of the brain; and, *second*, in the establishment of lines of rapid communication between them.

The **short association fibers** are the more numerous and are very important. They unite contiguous parts of the same gyrus and associate together adjacent gyri. They are intralobar. In direction they comprise *arcuate* and *tangential* fibers; and they are *intracortical* and *subcortical*, in position. Every zone of the cerebral cortex contains association fibers, from the felt-work of Kaes to the stratum zonale. But they are found chiefly (1) in the radiary zone and adjacent part of the supraradiary zone, *along the line of Baillarger* (Fig. 60); and (2) in the *zonal layer* (Figs. 58 and 61). (1) Those sparsely scattered large fibers whose location is indicated by the line of Baillarger are called *Meynert's association fibers*. The deeper of these fibers are continuous with the radiations of Meynert and probably do not belong to the short association fibers, if associative at all (they are corticopetal fibers); the more superficial, intersect the radiations at right angles and are truly associative in function. The associative fibers of Meynert are compacted together by pressure in the walls and floor of the sulci. In the crown of a gyrus they are scattered. Their exact origins are not yet worked out; but they are probably the horizontal processes of cells in the second to sixth layers. (2) The association fibers of the plexiform layer of the cortex, which constitute the *stratum zonale* (Fig. 61), are quite short when compared with those of Meynert; they join together immediately

contiguous parts within circumscribed areas. The richness of the zonal layer of fibers, as already pointed out in describing the plexiform layer of the cortex, varies greatly in different regions, being best developed in the subiculum. The *fibers comprising the zonal layer* have four sources of origin: (a) The axones and dendrites of the cells of Cajal in the plexiform layer. (b) The apical dendrites of the subjacent pyramids. (c) The T-branched

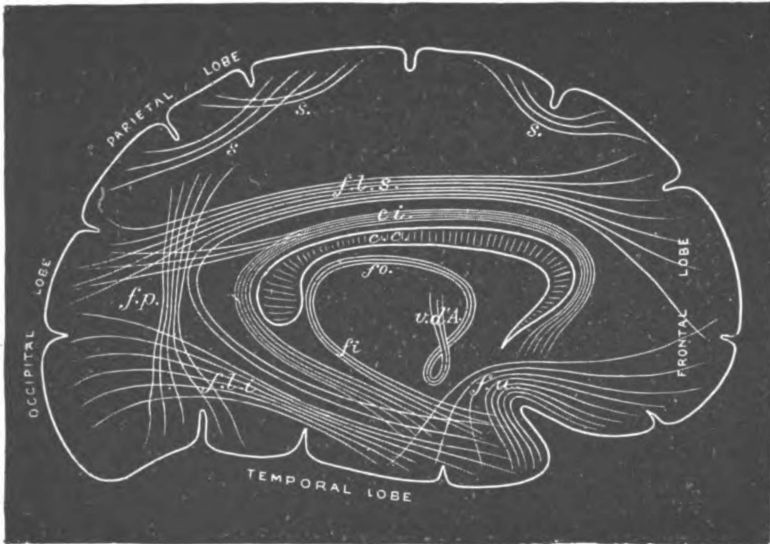


Fig. 74.—Diagram of association fibers in the cerebral hemisphere.
(Gordinier and Quain after Meynert.)

s. Short association fibers, connecting adjacent gyri. f.l.s. Fasciculus longitudinalis superior. c.i. Cingulum. f.p. Fasciculus perpendicularis. f.l.i. Fasciculus longitudinalis inferior. f.u. Fasciculus uncinatus. fo. Fornix. fr. Crus fornicis. v.d.A. Thalamo-mammillary bundle of Vicq d'Azyr.

axones of Martinotti's cells. (d) The corticopetal axones which terminate in the superficial layer of the cortex.

The short association fibers are *almost infinite in their connections*. They connect the receptive and psychic sensory areas, and their interruption on the left side causes inability to interpret the sensations, called mind-blindness, mind-deafness, stereognosis, etc. Again, those short fibers also associate the psychic with the psychic-motor, and the psychic-motor with the emissive-

motor centers. In this manner the writing center is connected with the motor center for the upper extremity, and the speech center with the motor centers for the lips, tongue, etc.: breaking of the former connection on the left side destroys ability to write, *agraphia*; and *aphasia* results, if the latter connection is broken. Besides these and many other connections of associated centers, the short fibers join together the various parts of each cortical area.

The **long association fibers** (Figs. 74 and 75) are collected into bundles. They rise from the pyramidal, the polymorphous and the fusiform layers of the cerebral cortex (Cajal), and are axones. Proceeding out of the lobe in which they rise, being interlobar, they dip down into the centrum semiovale and arborize about neurones in more or less distant parts of the cortex. Among the best known are the following bundles:

(1) *The cingulum* of the gyrus fornicatus (Fig. 74) is a bundle of fibers in that gyrus which almost entirely encircles the corpus callosum. It extends from the anterior perforated substance through the gyrus cinguli and hippocampal gyrus, to the uncus and temporal pole. The fibers, which form several systems, have been divided into three groups by Beevor, namely: (a) *The anterior*, which joins the region of the anterior perforated substance to the fore part of the frontal lobe. (b) *The horizontal*, which unites the frontal lobe and the gyrus fornicatus. (c) *The posterior fasciculus*, which associates the lingual and fusiform gyri with the hippocampal gyrus and the pole of the temporal lobe. Like the two following bundles it establishes associations for the sense of smell.

(2) *The Fornix* (Fig. 74).—In each lateral half of the fornix is a bundle of association fibers as well as of projection and commissural fibers. The *projection fibers* rise in the olfactory bulb and in the region of the olfactory triangle and, running up through septum pellucidum to the fornix, continue through it to their destination in the hippocampus and uncus. The *commissural fibers of the fornix* rise in the uncus, the fascia dentata and gyrus hippocampi and run through the alveus of the hippocampus into the crus fornicis, whence they cross through the commissura hip-

pocampi to the opposite side (Fig. 36). They terminate in the dentate fascia and hippocampal gyrus, including the uncus. The *associative group of fibers in the fornix* has the same origin as the commissural group. It enters crus fornicis and continues through the body of the fornix (corpus fornicis) into the columna, where

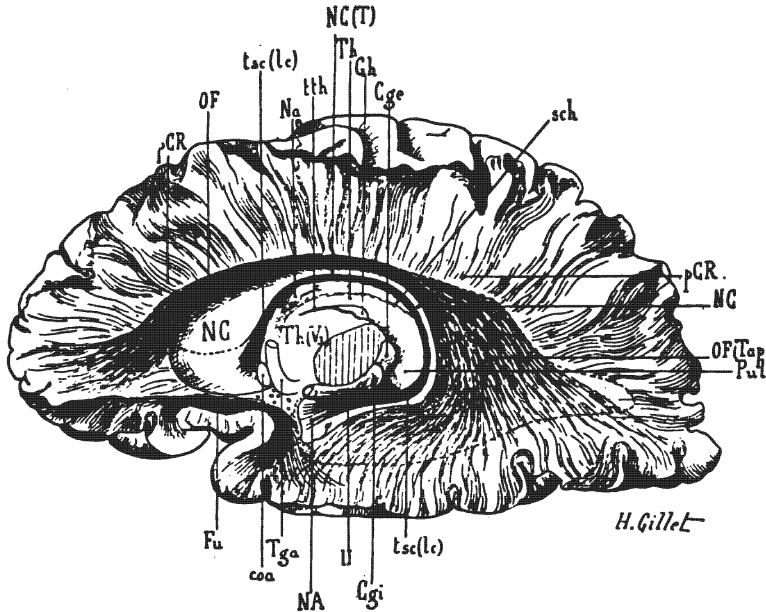


Fig. 75.—Fasciculus occipito-frontalis. Stria terminalis and fasciculus uncinatus. (Gordinier after Dejerine.)

Cge. Lat. geniculate body. Cgi. Med. geniculate body. coa. Anterior commissure. Fu. Fasciculus uncinatus. Gh. Ganglion of the habenula. NA. Amygdaloid nucleus. Na. Anterior nucleus of thalamus. NC. Head of caudate nucleus. NC(T). Tail of caudate nucleus. OF. Fasciculus occipito-frontalis. OF(Tap). Part of the fasciculus occipito-frontalis forming the tapetum. pCR. Foot of corona radiata. Pul. Pulvinar. sch. Choroidal fissure. Tga. Columna of fornix. Th and Th(V₃). Thalamus. tsc(1c). Stria terminalis. tth. Stria medullaris thalami. II. Optic tract.

it divides into two unequal bundles: The smaller is the *stria medullaris thalami* (pineal stria) (Fig. 40), which bends backward and runs along the supero-medial border of the thalamus to the nucleus habenulæ; in part it decussates in the commissura habenularum. By the fasciculus retroflexus of Meynert, it is connected with the inter-peduncular ganglion of the mid-brain. The larger bundle continues as *columna fornicis* (Fig. 74). As already

indicated, it terminates in the medial nucleus of the corpus mammillare, partly on the opposite side. Its termination is associated first, with the anterior nucleus of the thalamus by the thalamo-mammillary bundle (of Vicq d'Azyr) and, second, with the mid-brain and pons by the pedunculo-mammillary bundles.

(3) *The uncinat fasciculus (fasciculus uncinatus, Fig. 74)* is a bundle, with some sharply curved fibers, which arches over the main stem of the fissura cerebri lateralis, and connects the uncus and the anterior temporal region with the orbital gyri and the pole of the frontal lobe. It is situated near the basal surface. Its fibers spread out at both ends in the cortex, and they especially join the medial and posterior orbital and the inferior frontal gyri with the limbic lobe (Barker). Like the cingulum and fornix, it is connected with the rhinencephalon. Lesion in any one of these three bundles causes disturbance of smell.

(4) *The superior longitudinal fasciculus (fasciculus longitudinalis superior, Fig. 74)* is a sagittal bundle located beneath the convex surface of the hemisphere, just above the posterior ramus of the lateral fissure of the cerebrum. According to Cunningham, it runs just above and behind the putamen of the lenticular nucleus, external to the base of the corona radiata. Its fibers diverge at the posterior end of the lateral fissure and radiate into the parietal, occipital and temporal cortex: some of them, arching around that fissure, run as far forward as the temporal pole. The superior longitudinal bundle joins the frontal cortex with the parietal, occipital and the external temporal. It thus associates the psychic auditory and visual centers with the motor speech center; hence *motor aphasia* is the result of its interruption.

(5) *The inferior longitudinal fasciculus (fasciculus longitudinalis inferior, Fig. 74)* is about on a level with the lateral ventricle. It passes near the outer wall of the inferior and posterior horns of that ventricle, being separated from them by the occipito-thalamic radiation and the tapetum. It connects the temporal lobe to the occipital. In the temporal lobe its fibers cross at right angles those of the inferior lamina of the internal capsule. This fasciculus unites the auditory and visual psychic centers, and

thus associates the concepts of things seen with those of things heard. Breaking of this connection produces intercortical *sensory aphasia*. So, an object seen is recognized, but fails to suggest its name; and the spoken word is heard and understood, but does not recall the visual picture of the object or person it represents. According to Ferrier and Turner the inferior longitudinal bundle is not found in the Macaque monkey, but is present in the chimpanzee and the orang.

(6) *The Fasciculus Occipito-frontalis* (Foreli).—This is a large bundle of fibers formerly regarded as a part of the corpus callosum (Fig. 75). It is situated below the corpus callosum and, in equatorial sections of the brain, is found in the angle formed between the callosum and the internal capsule, just external to the lateral ventricle. It extends from the cortex of every part of the frontal lobe to the cortex of the convex surface and lateral border of the occipital lobe. Posteriorly, the fibers diverge to form a fan-like sheet in which there is an intermingling of fibers from the corpus callosum (Cunningham); and that sheet enters into the external boundary of the inferior horn of the lateral ventricle and into the floor, lateral wall and roof of the posterior horn, hence the synonym, *tapetum*. The tapetum is lined by the ventricular ependyma and is separated from the inferior longitudinal bundle by the occipito-thalamic radiation. Its particular function is unknown.

(7) *The Perpendicular Fasciculus* (*Fasciculus Perpendicularis*, Fig. 74).—This is a very broad vertical bundle located just in front of the occipital pole. It extends from the inferior parietal and superior occipital gyri, above, down to the middle and inferior temporal, the inferior occipital and the fusiform gyri. It is often classed with the short association fibers. Its function is doubtful.

CHAPTER IV.

THE RHOMBENCEPHALON.

SECTION I. THE CEREBELLUM.

The rhombencephalon is composed of the *cerebellum*, the *pons* and the *medulla oblongata* (Figs. 20, 21 and 27). It is the lozenge-shaped brain. The cerebellum is the dorsal and largest portion of it, and is developed in the roof-plate and dorsal zones of the metencephalon. Together with the pons it forms the hind-brain. Its weight is about five ounces, slightly more than one-tenth of the whole brain. It is situated in the posterior fossa of the skull, under the tentorium cerebelli and dorsal to the pons and medulla oblongata. Between it and the last two structures is enclosed the *fourth ventricle*. The cerebellum is distinguished from the cerebrum by its stratification. Its surface is composed of gray substance, the *cortex (substantia corticalis)*; its interior is white and is called the *medullary body (corpus medullare, Figs. 79 and 81)*.

Function.—The cerebellum is an important relay in the indirect motor and indirect sensory paths. In response to impulses received from skin, muscles, tendons, joints and viscera, it is also believed to originate impulses which co-ordinate muscles and maintain equilibrium. Moreover, according to Russel, each cerebellar hemisphere exercises an important inhibitory function, through the brachia conjunctiva, upon the opposite side of the cerebrum.

Divisions.—The cerebellum is made up of two lateral parts, the *hemispheres*, and a central part, uniting the hemispheres together, called the *vermis cerebelli*, or *worm* (Figs. 76, 77, and 80). In the early embryo the cerebellum is a transverse ridge in the roof of the fourth ventricle, partially divided for a time by a median groove on its ventricular surface; and it remains undifferentiated into medial and lateral parts in many lower animals (Edinger).

The **cerebellar hemispheres** (*hemispheria cerebelli*) measure

two inches from before backward and about the same in thickness, antero-medially; but they taper rapidly toward the lateral borders (Figs. 76 and 77). They are joined together by the worm, or vermis, which forms the central and most elevated part of the cerebellum.

The **vermis cerebelli**, or **worm**, is a small elongated lobe,

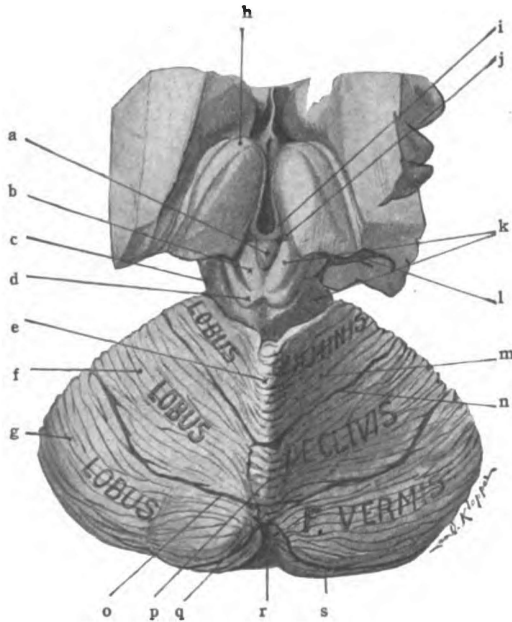


Fig. 76.—Dorsal view of inter-brain, mid-brain and cerebellum. Superior surface of cerebellum. (*Original.*)

a. Pineal body. b. Colliculus superior of corp. quad. c. Lateral sulcus. d. Colliculus inferior of corp. quad. e. Culmen monticuli. f. Pars posterior of quadrangular lobule. g. Superior semilunar lobule. h. Anterior tubercle of thalamus. i. Stria medullaris thalami. j. Trigonum habenule. k. Mid-brain. l. Inferior horn of lateral ventricle. m. Pars anterior of quadrangular lobule. n. Predeclivul sulcus. o. Postdeclivul sulcus. p. Declivul sulcus. q. Folium vermis. r. Posterior cerebellar notch. s. Horizontal sulcus.

shorter and much thinner than the hemisphere (Figs. 76 and 80). In animals lower than mammals, it is not differentiated from the hemispheres and appears to be the only part of the cerebellum present, being very large in birds and swimming reptiles (Edinger). Its transverse ridges give it a worm-like appearance. It unites the upper half of the medial aspect of the two hemispheres, their

lower halves being separated by an antero-posterior groove, called the valley or *vallecula cerebelli*. The upper surface of the vermis is called the superior worm, or *vermis superior*; and the lower surface, the inferior worm, or *vermis inferior*. The superior and inferior surfaces are separated from one another at the posterior end of the worm by the great horizontal sulcus; anteriorly, the medullary body of the cerebellum separates them. At either end of the worm is a notch bounded by the vermis and the hemispheres, the *anterior* and *posterior cerebellar notches*.

The **posterior cerebellar notch**, *incisura cerebelli posterior* (Fig. 76), bounded by the posterior end of the worm and the postero-medial border of the hemispheres, is occupied by the falx cerebelli. A prolongation of the medullary body of the cerebellum fills up the *incisura cerebelli anterior*, or **anterior cerebellar notch**, which is situated between the antero-medial borders of the hemispheres in front of the vermis cerebelli.

The **medullary body** (*corpus medullare*) which is the white center of the cerebellum splits, in its median part, into *two laminae*: a *superior*, which forms the superior medullary velum and three pairs of connecting bands (peduncles), and an *inferior*, which is the inferior medullary velum (Figs. 79 and 78). Separating at an acute angle, the two laminae form the tent of the fourth ventricle.

The *inferior medullary velum* (*velum medullare inferius*, Figs. 79 and 91) is the inferior lamina of the medullary body. It is a short plate of white matter, not more than a quarter of an inch long and is separated from the superior lamina by the angle, called the *fastigium*. It ends in a concave border from which a sheet of epithelium continues down over the fourth ventricle; and together they form the inferior half of the roof of that cavity. Laterally, the inferior velum extends to the flocculus of the hemisphere. Of the worm it covers the nodulus, antero-superiorly. It bounds, dorsally, the lateral recesses of the fourth ventricle.

In the BNA the cerebellar vela are called "velum medullare anterius" and "v. m. posterius;" but there is no more reason for those embryological terms in this place than there is elsewhere throughout the central nervous system. and I have used "superius" and "inferius" which properly indicate their positions in adult anatomy.

The **superior lamina of the medullary body** joins the cerebellum immediately to the pons. The superior lamina is made up of three pairs of connecting bands (cerebellar peduncles) and the superior medullary velum. It constitutes all the prolongations of the corpus medullare of the cerebellum, except the inferior velum (Fig. 91).

The **brachia conjunctiva** (superior peduncles, Figs. 78 and 86) converge as they pass forward and upward to the inferior

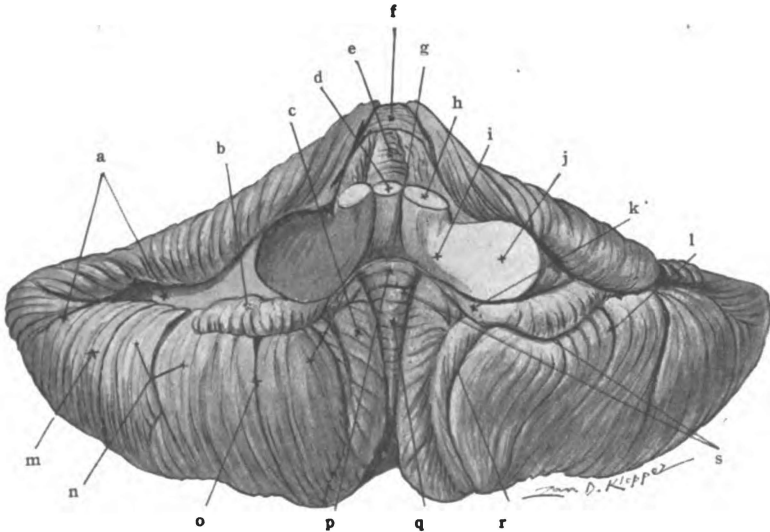


Fig. 77.—Anterior aspect of cerebellum. (Original.)

a. Horizontal sulcus. b. Flocculus. c. Tonsil. d. Superior medullary velum. e. Lobulus centralis. f. Culmen monticuli. g. Inferior medullary velum. h. Brachium conjunctivum. i. Restiform body. j. Brachium pontis. k. Peduncle of flocculus. l. Division in biventral lobule. m. Lobulus gracilis. n. Lobulus biventer. o. Prepyramidal sulcus. p. Nodule. q. Uvula. r. Depression in tonsil. s. Postnodular sulcus.

quadrigeminal colliculi, where they disappear. They are joined to one another by a thin plate of white matter, the *superior medullary velum* (*velum medullare superius*). With the velum, they form the roof and lateral boundaries of the superior half of the fourth ventricle. They gradually bury themselves in the pons as they proceed upward toward the corpora quadrigemina. Beneath the corpora quadrigemina and the cerebral aqueduct, the brachia conjunctiva cerebelli decussate, and pass into the

hypothalamic region of the opposite side. They end chiefly in the red nuclei, which their fibers surround. Near the corpora quadrigemina each brachium conjunctivum is obliquely crossed by the lateral fillet in its course to the inferior quadrigeminal colliculus.

The **superior medullary velum** (*valve of Vieussens*, Figs. 86, 87 and 92), is a trapezoidal sheet of white substance, wider where it fuses with the corpus medullare of the cerebellum than at the mesencephalic end. It forms the floor of the groove between the brachia conjunctiva cerebelli and the superior half of the

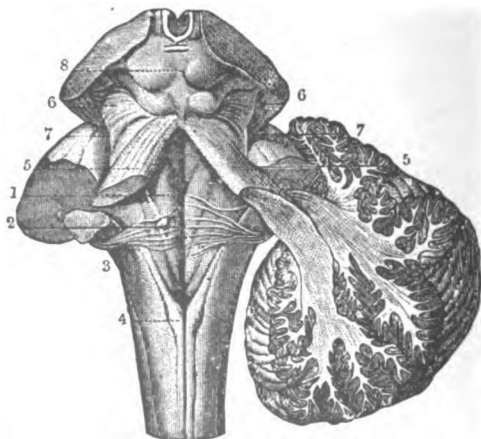


Fig. 78.—Dissection of rhombencephalon to show brachium conjunctivum, brachium pontis and corpus restiforme. (*Gordinier, Sappey after Hirschfeld and Leveille.*)

On left side the cerebellar brachia and restiform body have been cut short; the right hemisphere is cut obliquely to show connection with brachium conjunctivum and corpus restiforme. 1. Median groove of fourth ventricle. 2. Medullary striæ. 3. Restiform body. 4. Clava in funiculus gracilis. 5,5. Brachium conjunctivum. 6. Lateral fillet. 7,7. Lateral sulcus of mid-brain. 8. Corpora quadrigemina.

roof of the fourth ventricle. Its lateral borders fuse with and unite the brachia conjunctiva, hence their name. In the median line its posterior surface presents a slight ridge, the *frænulum veli*, from either side of which emerges the trochlear nerve.

The **corpora restiformia** (inferior peduncles of the cerebellum) issue from the cerebellum between the brachium conjunctivum and the brachium pontis (Figs. 78 and 86). They first run forward to the posterior surface of the pons, near the inferior border; and then, bending downward and backward (a flexion

of more than 90 degrees), they converge in the posterior areas of the medulla toward the calamus scriptorius. They help to form the floor and to bound laterally the inferior half of the fourth ventricle.

The **brachia pontis** (middle peduncles) join the cerebellum to the lateral borders of the pons (Figs. 78, 85 and 91). They are continuous with the transverse fibers in the ventral area of

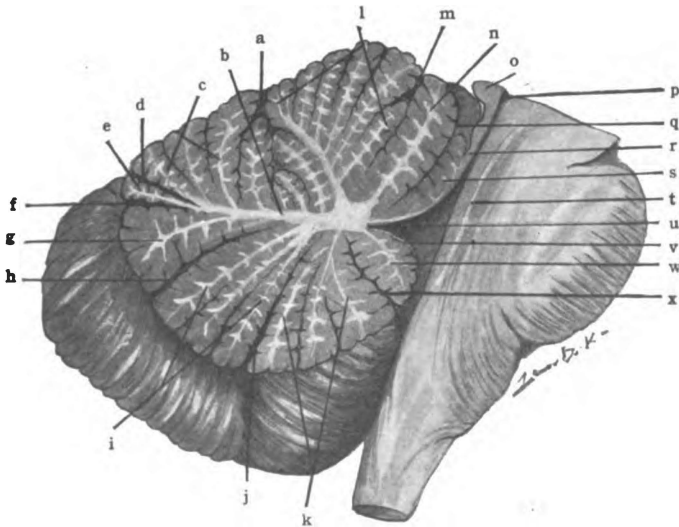


Fig. 79.—Median section of cerebellum, pons and medulla. (Original.)

a. Predeclivil sulcus. b. Arbor vitæ. c. Declive monticuli. d. Postdeclivil sulcus. e. Folium vermis. f. Horizontal sulcus. g. Tuber vermis. h. Postpyramidal sulcus. i. Pyramid. j. Prepyramidal sulcus. k. Uvula. l. Culmen monticuli. m. Postcentral sulcus. n. Central lobule. o. Inferior colliculus of corp. quad. p. Cerebral aqueduct. q. Precentral sulcus. r. Superior medullary velum. s. Lingula. t. Medial longitudinal bundle. u. Fastigium. v. Inferior medullary velum. w. Nodule. x. Postnodular sulcus.

the pons. The brachia pontis in the anterior cerebellar notch are placed external to the brachia conjunctiva and the restiform bodies, and are opposite the widest part of the fourth ventricle.

Horizontal Sulcus of Cerebellum (Figs. 76, 79 and 80).—The cerebellum has one great sulcus which divides it into upper and lower surface. The *sulcus horizontalis cerebelli* is irregularly circular in shape; anteriorly its lips are separated by the prolongation of the medullary body from which the sulcus runs backward,

dividing the border of each hemisphere and the posterior end of the worm. Rarely the two halves are not continuous through the posterior extremity of the worm. In the horizontal sulcus the remaining important sulci of the cerebellum terminate. They are nearly parallel with one another; hence, the cerebellum is laminated, not convoluted like the cerebrum. Though the horizontal sulcus is an important landmark in the adult cerebellum, it does not form a primary embryonic division of the cerebellum but appears late in foetal life (Cunningham).

SUPERIOR SURFACE OF THE CEREBELLUM.

The superior surface of the cerebellum (*facies cerebelli superior*) is bounded by the horizontal sulcus and the superior lamina of the medullary body (Figs. 76 and 79). The posterior and larger part of this surface is covered by the tentorium cerebelli, the *tentorial area*; the small anterior part of it bounds the anterior cerebellar notch. The superior surface is divided into five continuous lobes by four crescentic sulci, called interlobular sulci.

Sulci of Upper Surface.—The interlobular sulci (*sulci interlobulares*) divide the worm and both hemispheres into *lobules*; and each *lobe* is composed of a central and two lateral lobules. These sulci are best seen in a median section of the vermis and are named in accordance with their relations to the lobules in the worm, viz.:

(1) The **precentral sulcus** (*s. præcentralis*), which is located in the anterior cerebellar notch just above the superior velum (Fig. 79). It is between the lingula and lobulus centralis, in the worm; between the vinculum and ala, in the hemisphere. It terminates in the horizontal sulcus. When the vinculum is wanting the precentral sulcus is present only in the vermis.

(2) The **postcentral sulcus** (*s. postcentralis*), in the worm, separates the lobulus centralis from the culmen; and, in the hemisphere, the ala from the anterior part of the quadrangular lobule (Figs. 77 and 79). The sulcus is situated at the upper border of the anterior cerebellar notch and runs just under the anterior border of the tentorial surface of the cerebellar hemi-

phere. Both central sulci terminate on the dorsum of the superior medullary lamina in the horizontal sulcus.

(3) **Predeclivil Sulcus.** (*S. prædeclivis, s. primarius*) (Figs. 76 and 79).—Behind the culmen and anterior part of the quadrangular lobule, a half inch from the anterior border of the tentorial surface, there is the predeclivil sulcus. It bounds the declive and posterior part of the quadrangular lobule in front. It ends at the junction of the anterior and middle thirds of the antero-lateral border of the hemisphere in the horizontal sulcus. Embryologically it is second to appear; it is the deepest sulcus of the cerebellum, hence the name, sulcus primarius, given it by Kuithan. Its development begins near the end of the third month in utero (Cunningham).

(4) The **postdeclivil sulcus** (*s. postdeclivis*) (Figs. 76 and 79) is located in the posterior cerebellar notch, from which it curves outward and forward in the superior surface of the hemispheres. It separates the declivil lobe from the folium vermis, in the worm, and from the superior semilunar lobules in the hemispheres. It ends in the horizontal sulcus at the junction of the posterior and middle thirds of the antero-lateral border. Being behind the crescentic gyri of the quadrangular lobule, this sulcus may be called the sulcus postlunatus. It appears a month later than the predeclivil sulcus.

Sulci and lobules of the upper surface of the cerebellum from before backward:

Hemisphere.	Worm.	Hemisphere.
Vinculum	Lingula	Vinculum
Ala	<i>Precentral sulcus</i> Lobulus Centralis <i>Postcentral sulcus</i>	Ala
Lobulus quadrangularis. pars anterior.	Culmen Monticuli <i>Predeclivil sulcus</i>	Lobulus quadrangularis. pars anterior.
Lobulus quadrangularis. pars posterior	Declive Monticuli <i>Postdeclivil sulcus</i>	Lobulus quadrangularis. pars posterior
Semilunaris superior	Folium Vermis <i>Horizontal sulcus</i>	Semilunaris superior

Lobes of Superior Surface (Figs. 76, 77 and 79).—The lobes of the superior surface of the cerebellum should be studied first in a median section, where the branches of the medullary body (*laminae medullares*) will guide the student and where the sulci are most easily identified. These lobes include the divisions of the worm and of the hemispheres, and are five in number.

Lingula and Vincula, Lobus Lingulæ.—The lingula is a very small lobule of the vermis entirely concealed in the anterior cerebellar notch by the overhanging central lobule. It is a tongue-shaped group of four or five rudimentary transverse gyri. It rests upon the superior medullary velum, with which its white center is continuous. Laterally, the lingula tapers off and is sometimes represented in the hemisphere by a very thin gyrus called the *vinculum lingulæ*. The *vinculum* is bounded by the *brachium conjunctivum cerebelli* in front, and by the precentral sulcus behind. The precentral sulcus separates the lobe of the lingula from the central lobe.

Central Lobule and Alæ, Lobus Centralis (Figs. 77 and 79).—The lobulus centralis is situated between the precentral and postcentral sulci, in the anterior cerebellar notch. It covers the lingula and in turn is overhung by the culmen. Four or five small transverse gyri make it up. On sagittal section, it is seen to form a single branch of the *corpus medullare* (*arbor vitæ*). The gyri of the central lobule, continuing along the anterior cerebellar notch into either hemisphere, form a triangular or wing-like lobule, the *ala* (*ala lobuli centralis*).

Culmen and Anterior Part of Quadrangular Lobules, Lobus Culminis (Figs. 76 and 79).—In the culmen monticuli the surface of the cerebellum reaches its highest elevation. It is a large lobule and occupies half of the tentorial surface of the worm. It is made up of three or four prominent gyri, which extend laterally into the hemispheres; and, in each, forms the *anterior part of the quadrangular lobule*. The *pars anterior lobuli quadrangularis* occupies about one-third of the tentorial surface of the hemisphere. The predeclivil sulcus separates the culmen and the *pars anterior* of either side (the lobe of the culmen) from the declivil lobe.

Declive and Posterior Parts of Quadrangular Lobules, Lobus Declivis (Figs. 76 and 79).—The *declive monticuli* forms the posterior slope, as the culmen forms the summit, of the monticulus cerebelli. The declive has about half the extent of the culmen. Its gyri are continued into either hemisphere, where they form a large crescentic lobule, the *pars posterior lobuli quadrangularis*. The increased size of the lobe in the hemisphere is due to the expansion of the secondary gyri found in the worm. The anterior and posterior parts of the quadrangular lobule constitute the *lobulus quadrangularis*, which forms the anterior two-thirds of the tentorial surface of the hemisphere. The declive and its hemispherical extensions are inclosed between the predeclivil and postdeclivil sulci.

The **folium vermis and superior semilunar lobules, lobus folii vermis** (Figs. 76 and 79), lies behind the postdeclivil and above the horizontal sulcus. The *folium vermis* is the terminal lobule in the superior worm, and occupies the posterior cerebellar notch. It appears near birth in the bottom of a transverse groove common to the postdeclivil and horizontal sulci (Cunningham). Rarely it is absent. It contains a single medullary lamina beset with rudimentary gyri, which are largely developed in the hemispheres. The *superior semilunar lobule* is, therefore, very large in comparison with the folium vermis. It expands lateralward to the postero-lateral border of the hemisphere, which it forms. It comprises the posterior third of the hemisphere's tentorial surface, and forms one of the remarkable features of the human cerebellum.

INFERIOR SURFACE OF THE CEREBELLUM.

The inferior surface of the cerebellum (*facies cerebelli inferior*) is prominent laterally and depressed centrally (as the organ is viewed inverted), the *hemispheres* being separated by the antero-posterior groove, called the *vallecula cerebelli* (Figs. 77 and 80). The vallecula (little valley) is occupied by the *inferior worm* and is bounded on either side by a small cleft, between the worm and the overhanging hemisphere, called the *sulcus valleculæ*. The

inferior cerebellar surface is limited by the horizontal sulcus and is separated from the medulla by the transverse fissure of the cerebellum. It is more complex than the superior surface; and its sulci are more sharply curved forward as they pass from the worm into the hemispheres.

Sulci of Lower Surface (Fig. 8o).—The interlobular sulci of this surface are very deep. They are three in number, namely:

(1) The **postnodular sulcus** (*s. postnodularis*) (Figs. 77, 79 and 8o) is in the anterior end of the worm between the nodule

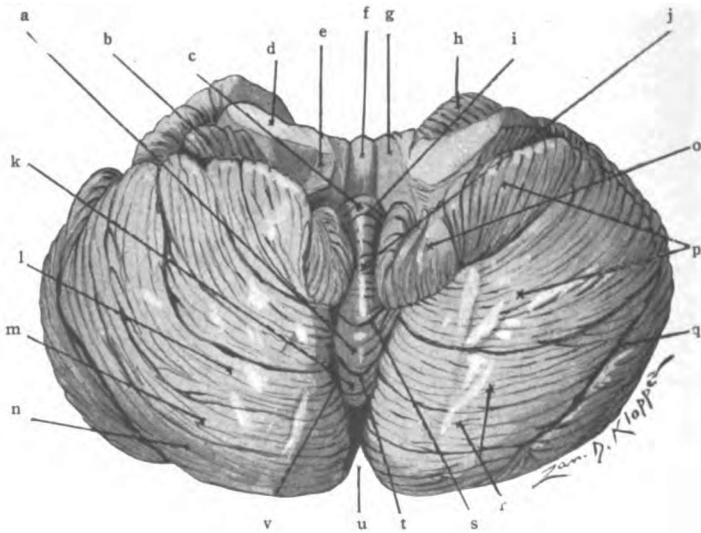


Fig. 8o.—Inferior surface of cerebellum. (Original.)

a. Pyramid. b. Flocculus. c. Nodule. d. Brachium pontis. e. Restiform body. f. Superior medullary velum. g. Brachium conjunctivum. h. Quadrangular lobule. i. Post-nodular sulcus. j. Uvula. k. Tuber vermis. l. Ant. and m. Post. Slender lobules. n. Inferior semilunar lobule. o. Tonsil. p. Biventral lobule. q. Horizontal sulcus. r. Lobulus gracilis. s. Prepyramidal sulcus. t. Postpyramidal sulcus. u. Post. cerebellar notch. v. Sulcus vallicularis.

and uvula. In the hemisphere it winds forward and outward between the inferior medullary velum and the tonsil, and then continues lateralward between flocculus and biventral lobule to the horizontal sulcus. It is the first cerebellar sulcus to be developed (Cunningham).

(2) The **prepyramidal sulcus** (*s. præpyramidalis*) (Figs. 79 and 8o), situated between the uvula and pyramid, is very con-

cave in the hemispheres. It curves outward and forward around the tonsil, separating it from the biventral lobule. It terminates behind the flocculus in the postnodular sulcus.

(3) The **postpyramidal sulcus** (*s. postpyramidalis*) (Figs 79 and 80), between the pyramid and tuber vermis, is near the posterior end of the worm. It forms an oblique groove in either sulcus valliculæ, from which three concentric sulci extend into the hemisphere. The anterior of the three (the pregracile), usually considered the postpyramidal sulcus in the hemisphere, separates the biventral lobule from the slender lobule (*l. gracilis*); the remaining two (midgracile and postgracile) subdivide the slender lobule into anterior and posterior slender, and separate the lobulus gracilis from the inferior semilunar lobule. The last is bounded behind by the horizontal sulcus.

Sulci and lobules of the lower surface of the cerebellum, from before backward:

Hemisphere.	Worm.	Hemisphere.
Flocculus.	Nodule. <i>Postnodular sulcus.</i>	Flocculus.
Tonsil.	Uvula. <i>Prepyramidal sulcus.</i>	Tonsil.
Biventral lobule.	Pyramid. <i>Postpyramidal sulcus.</i>	Biventral lobule.
Slender lobule and inferior semilunar lobule.	Tuber vermis. <i>Horizontal sulcus.</i>	Slender lobule and inferior semilunar lobule.

Lobes of Lower Surface.—They are not continuous from the worm to the hemisphere as on the upper surface (Figs. 76 and 80). Excepting in the posterior lobe, only a small ridge beneath the sulcus valliculæ joins the central and lateral lobules together. The inferior lobes are four in number. Each is composed of a central and two lateral lobules as on the upper surface. The lobule in the worm gives its name to the lobe.

Nodules and Flocculi, Lobus Noduli (Figs. 79 and 80).—The *nodule* (nodulus vermis) is a small lobule at the anterior end of the inferior worm. It is composed of three or four gyri, which project from the middle of the dorsal surface of the inferior medullary velum. It comprises a single branch of the arbor vitæ.

Though larger it is the counterpart of the lingula on the superior velum. It is bounded by the sulcus valliculæ on either side. The inferior medullary velum extends laterally from the nodule, and in part blends with the brachium pontis of the cerebellum. In front of the tonsil, a layer of gray matter (*pedunculus flocculi*) appears on the velum. That gray matter enlarges more externally to a small tufted mass, called the *flocculus*, in which the velum ends. Embryologically, the flocculus is the oldest lobule of the human cerebellum, as is the floccular sulcus (postnodular sulcus) which bounds it, the first one formed. The flocculus is very small and rudimentary in man. It is divided into an anterior and a posterior part, the latter being called the secondary flocculus. The flocculus is separated from the tonsil and the biventral lobule by the postnodular sulcus. The whole line of structures, namely, the nodule, velum, peduncle and flocculus, form the lobe of the nodule.

Uvula and Tonsils, Lobus Uvulæ (Figs. 79 and 80).—The *uvula* (uvula vermis) comprises a considerable part of the vermis inferior behind the nodule. It broadens backward and is widest next the pyramid. Bounded on either side by the sulcus valliculæ, it projects into the valley like the uvula into the isthmus of the fauces. It comprises one large branch of the arbor vitæ which bifurcates near its origin into two laminæ and presents at the surface six or eight small gyri. A slight ridge, the furrowed band, joins it to the *tonsil* (tonsilla cerebelli) in the hemisphere. From the furrowed band the tonsil expands downward and backward, forming a lobule of nearly a dozen sagittal gyri. The tonsil overhangs the side of the uvula and conceals the furrowed band, medially; and, behind, it conceals the connecting ridge between the pyramid and biventral lobule. Its large size makes it a prominent feature of the human cerebellum. The fossa containing the tonsil is the bird's nest (*nidus avis*). Behind the uvular lobe, composed of the above three lobules, is the prepyramidal sulcus.

Pyramid and Biventral Lobules, Lobus Pyramidis (Figs. 79 and 80).—As seen from the surface, three or four distinct gyri make up the *pyramid* (*pyramis vermis*); in reality, it covers

one strong lamina of the arbor vitæ, which divides into two near the surface. It forms the most prominent lobule of the inferior worm. A low connecting ridge joins the pyramid to the biventral lobule in the hemisphere. The *biventral lobule* (lobulus biventer) is triangular in outline. Its base looks toward the flocculus and is bounded by the postnodular and the horizontal sulcus; its apex is continuous with the connecting ridge joining

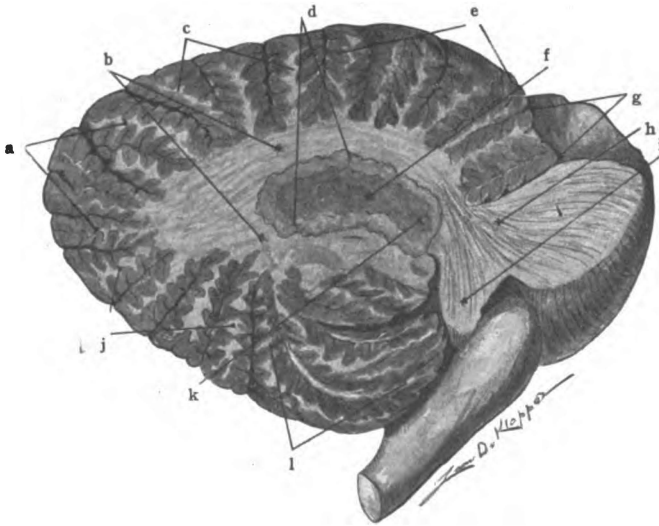


Fig. 81.—Sagittal section of cerebellum, cutting nucleus dentatus. (*Original.*)

a. Sup. semilunar lobule. b. Corpus medullare. c. Post. part quadrangular lobule. d. Nucleus dentatus. e. Ant. part of quadrangular lobule. f. Interior of dentate nuc. g. Central sulci. h. Brachium pontis. i. Restiform body. j. Inf. semilunar and slender lobules. k. Hilus of nuc. dent. l. Biventral lobule.

it to the pyramid. The gyri composing it radiate from the apex toward the base, and are divided into two groups by a very deep intralobular sulcus. Its lateral extension is a little beyond the flocculus. The postpyramidal sulcus bounds it postero-externally, and separates it from the slender lobule.

Tuber Vermis, Slender and Inferior Semilunar Lobules, Lobus Tuberis (Figs. 79 and 80).—The tuber vermis forms the posterior end of the inferior worm. It resembles the lobules of the vermis superior, because some of its half dozen tertiary gyri

are continued into the hemispheres, the sulcus valleculæ not cutting them off. A bifurcated lamina of the arbor vitæ enters into the tuber. The horizontal sulcus separates it from the folium vermis of the superior worm. The *slender* and *inferior semilunar lobules* comprise the posterior two-thirds of the inferior surface of each hemisphere, extending from the biventral lobule to the postero-lateral border. Twelve to fifteen gyri compose the lobules. The gyri are divided into three groups by the midgracile and postgracile sulci; the anterior and middle groups are named the *anterior slender* and *posterior slender lobules*, they constitute the *lobulus gracilis*. The posterior is the inferior semilunar lobule. The inferior semilunar lobule, only, is continuous with the gyri of the vermis. The great size of the inferior and superior semilunar lobules is the most characteristic feature of the human cerebellum.

The **gray matter of the cerebellum** is composed of cortex which covers the cerebellar laminæ and of ganglia imbedded in the medullary body (Figs. 81 and 84).

I. CORTICAL GRAY MATTER.

The *cortex* of the cerebellum (*substantia corticalis cerebelli*) is made up of two thick layers visible to the naked eye, viz., (1) a superficial layer, and (2) a deep, granular layer. At the junction of these two layers is a single row of large pitcher-shaped cell-bodies, which are characteristic of the cerebellar cortex and are often visible to the unaided eye. They are the bodies of Purkinje's cells, and are considered in the deep part of the first macroscopic layer, where they form the *stratum gangliosum*. Under the microscope three layers are easily seen, viz., (1) the gray layer (*stratum cinereum*); (2) the ganglion cell layer (*stratum gangliosum*); and (3) the granular layer (*stratum granulosum*).

(1) **Superficial Layer** (Figs. 82 and 83).—Thickest on the laminæ and thinnest beneath the fissures, this layer contains small and large stellate cell-bodies with their processes, which constitute the *stratum cinereum* proper; and the large Purkinje cell-bodies with their dendrites and recurrent axones, together

with many corticopetal fibers. The Purkinje cells form the *stratum gangliosum*.

Cells.—The bodies of **Purkinje's cells** (Figs. 82 and 83) are located near the deep surface of the superficial layer in the *stratum gangliosum*. They measure from 100μ to 135μ in their longest axis. Each has one *axone* which, after piercing the deep layer, becomes a fiber of the medullary body. It gives off, in the deep layer, several *recurrent collaterals*, which form contact relations with other cells in both layers. From the outer end of each cell-body antler-like processes, the *dendrites*, are given off; they ramify toward the surface in a *wide plane* at right angles to the free border of the gyrus. The edge of the plane only is seen in a longitudinal section of the gyrus and the arborization is very narrow and tall. The **stellate cell-bodies**, an outer and inner layer, together form the *stratum cinereum*. They increase in size toward the Purkinje cells. They have rich dendritic processes and one axis-cylinder each. Their processes ramify throughout the stratum cinereum and stratum gangliosum. The *inner layer* of the stratum cinereum contains the larger cells; they are called the "basket cells." Their axis-cylinder processes run parallel with the surface and at right angles to the border of the gyrus; they give off vertical branches, which descend to Purkinje's corpuscles and inclose them in a basket work of filaments. In the *outer layer* of the stratum cinereum the stellate cell-bodies are smaller than in the inner layer. They branch freely and terminate in claw-like end-tufts in contact with other stellate cells.

The **fibers of the superficial layer** (Figs. 82 and 83) have three sources: (a) The processes of neurones within the layer, which include the dendrites and axones of the stellate cells and the dendritic planes and recurrent collaterals of Purkinje's cells. (b) The processes of cell-bodies in the deep layer, whose T-branched axones pierce the dendritic planes of Purkinje in the first layer; and, the processes of the large granules whose dendrites ramify toward the surface. (c) The fibers of the medullary projection rise or end largely in the cellular layer. The axones of Purkinje's neurones compose all of the corticofugal fibers. They end in the cerebellar and vestibular nuclei of the cat (Clark

and Horsley) and probably have these endings in the human brain, with the possible addition of the inferior olivary nucleus. The corticopetal fibers, which rise either in other parts of the brain or in the spinal cord and ganglia, terminate in varicose fibrils chiefly in the superficial layer. These fibrils entwine about the "primary and secondary stems of the Purkinje dendrites" (Cunningham).

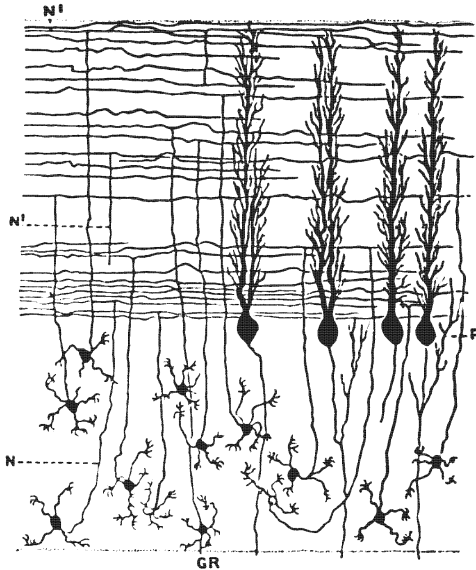


Fig. 82.—Section of cerebellar gyrus made parallel with its free border. Diagrammatic. (After *Kolliker* from *Cunningham*.)

GR. Small granules with claw-shaped dendrites and long axones that run out into the gray layer and divide T-like. N. Axone of small granule. P. Purkinje cells seen in profile, showing border of dendritic planes in gray layer.

(2) The **deep, granular layer** (*stratum granulosum*, Figs. 82 and 83) is of uniform thickness. It blends centrally with the medullary projection. It contains a few superficial granules which are comparatively *large* in size and many *small granules* in which the nucleus occupies nearly the whole cell-body.

Cells of the Granular Layer.—The granules are small, round, or stellate cell-bodies, largest near Purkinje's cells, closely packed externally, but scattered among the projection fibers centrally.

Each **small granule** has three to five short *dendrites*, which soon break up into claw-like tufts in contact with adjacent granules, and one long *axone*. The axone runs out into the superficial layer, branches T-like, and, piercing the dendritic planes of Pur-

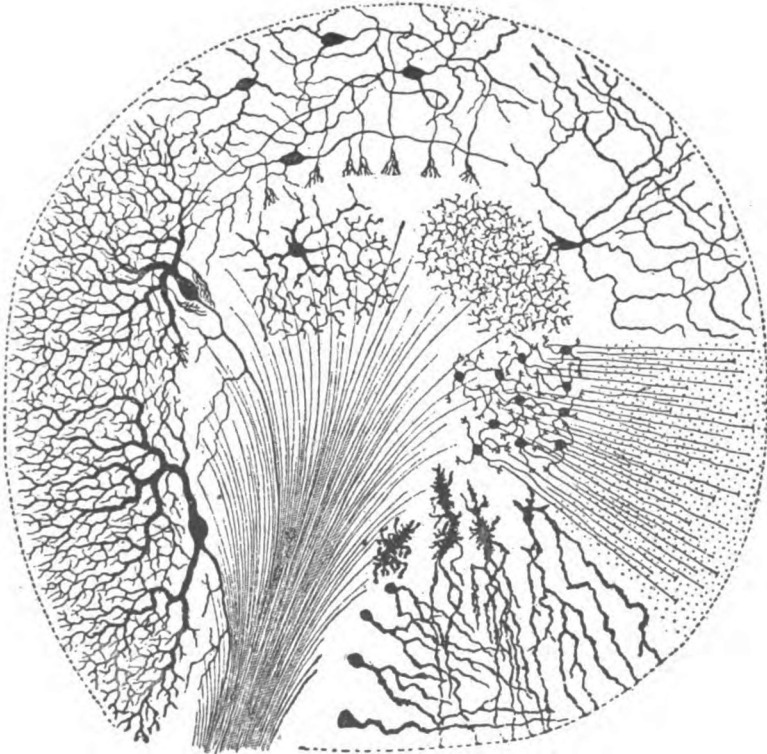


Fig. 83.—Section across a cerebellar gyrus at a right angle to the free border. Diagrammatic. (*Gordinier after Van Gehuchten.*)

Showing large stellate cells of first layer with their basket-work endings; the cells of Purkinje, their dendritic planes in the gray layer and their axones running through the granular layer to the medullary lamina of the gyrus; two large granules of Golgi type; the small granules whose T-branches run parallel with the border of the gyrus; moss-like endings of Cajal, etc.

kinje, gives off collaterals to them until exhausted by multiple division. The **large granules** are dendraxones, the type of Golgi. The axones form remarkable arborizations toward the medullary projection, touching and associating many granules. The dendrites, branching freely, ramify in the superficial layer.

Fibers of the Granular Layer (Figs. 82 and 83).—The nerve fibers of the granular layer are as follows: (a) The processes of the granules, (b) the axones of Purkinje's cells running down into the medullary projection, together with their recurrent collaterals, and (c) corticopetal fibers, most of which run through the granular layer, without branching, to end in the first layer; the remainder terminate in the deep layer in the *moss-like appendages* of Cajal.

The **functions** of the stellate cells, the "basket cells" and the granule cells are probably receptive and associative; they receive impulses through the projection fibers and transfer those impulses to the dendrites or bodies of Purkinje's cells. Purkinje's cells originate impulses for the coordination of muscular action (Gordinier), and for the inhibition of nervous activity in the opposite cerebral hemisphere (Russel). Lesions in the cerebellum produce incoordination, chorea, athetosis and, rarely, convulsions.

The **neuroglia of the cerebellum** is similar to that in the cerebrum. The *short-rayed cells* are scattered throughout the gray substance, while the *long-rayed* are located near, or within, the white substance. In the region of Purkinje's cells, near the surface of the deep layer, are the bodies of the *arborescent cells*, whose processes form a fine interlacement about the cell-bodies of Purkinje and then extend in parallel lines out to the surface. They form a *neuroglia felt-work* just beneath the pia mater (lamina basalis).

II. GANGLIONAR GRAY MATTER.

The ganglia of the cerebellum are the nucleus dentatus, nucleus emboliformis, nucleus globosus and nucleus fastigii (Figs. 81 and 84). All these nuclei are made up of stellate cell-bodies, which vary in size from six to forty microns. *They form relay stations in the paths going out of the cerebellum.* In them terminate axones of Purkinje's cells.

The **nucleus dentatus** (corpus dentatum) is a wavy, sinuous pouch of yellowish-brown gray matter imbedded in the medullary body of each hemisphere. The nucleus dentatus measures a half inch in length and a quarter of an inch in width (Fig. 81).

It is filled with white fibers, which issue from its open anterior end, called the *hilus*, and form the greater part of the brachium conjunctivum cerebelli. It also receives many axones from Purkinje's cells and, thus, forms a relay in the common sensory path.

The **small ganglia** are just visible to the naked eye under favorable conditions (Fig. 84). One of these, a club-shaped mass,

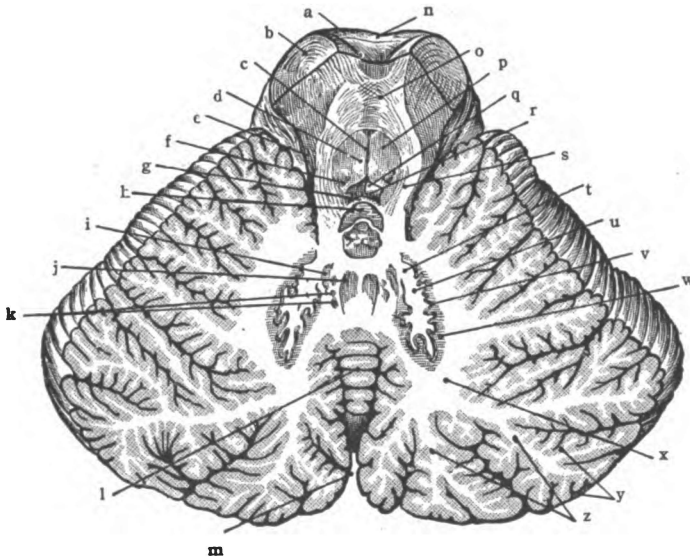


Fig. 84.—Horizontal section of cerebellum cutting nuclei and brachia conjunctiva. (Morris's Anatomy after Toldt.)

a. Interpeduncular fossa. b. Cerebral peduncle. c. Raphe of medulla oblongata. d. Medial longitudinal fasciculus. e. Lateral lemniscus. f. Substantia ferruginea. g. Superior medullary velum. h. Lingula cerebelli. i. Nucleus emboliformis. j. Nucleus fastigii. k. Nucleus globosus. l. Vermis (superior). m. Posterior cerebellar notch. n. Pons (varolii). o. Decussation of brachium conjunctivum. p. Stratum nucleare. q. Fossa rhomboidea (pars superior). r. Fourth ventricle. s. Brachium conjunctivum. t. Hilus of dentate nucleus. u. Core of the dentate nucleus. v. Dentate nucleus. w. Capsule of dentate nucleus. x. Corpus medullare. y. Cortical substance. z. Medullary lamina.

the cork-like *nucleus emboliformis*, partly closes the hilus of the dentate nucleus. Medial to that is an elongated antero-posterior ganglion, bulbous behind, called the *nucleus globosus*. The third nucleus is in the anterior end of the worm, just above the fastigium of the fourth ventricle. It is called the nucleus of the highest

point of the roof, *nucleus fastigii* (Stillingi). In the last two the stellate cell-bodies are larger than in the nucleus emboliformis or dentatus; but, otherwise, they are alike in structure. The nucleus fastigii and nucleus globosus form a part of the origin of the acustico-cerebellar tract, which descends to the nucleus of Deiters in the medulla; probably axones of Purkinje's cells also enter into the acustico-cerebellar tract in man, as they do in the cat (Clarke and Horsley). Perhaps the nucleus emboliformis and nucleus dentatus have a less important connection with the same tract. The small cerebellar ganglia, and especially the nucleus fastigii and nucleus globosus, constitute a relay in the arc of equilibrium.

The White Substance of the Cerebellum (Figs. 79 and 81).

—The **corpus medullare** contains all the white matter of the cerebellum. It is a strong body measuring a third of an inch in thickness vertically in the middle of the hemisphere, but in the worm it is a thin sheet and is very slender as seen in median section. Its branches to the cerebellar gyri are called the *medullary laminae* (*laminae medullares*). Viewed in a sagittal section of the hemisphere, the medullary laminae are short and stubby branches of a very thick trunk; but the tree-like appearance of the medullary body and laminae in the vermis is perfect, hence the name, *arbor vitæ*, which is applied to them there. In the anterior cerebellar notch the medullary body divides into a thick superior lamina and a thin inferior lamina which are separated by a transverse furrow, the bottom of which constitutes the peak, or fastigium, of the fourth ventricle. The inferior lamina is the *inferior medullary velum*, already described; this, with the continuation of its endymal epithelium, forms the roof of the inferior half of the fourth ventricle. The superior lamina of the corpus medullare forms the *three pairs of connecting bands* (peduncles) and the *superior medullary velum*. Medullated axones make up the entire corpus medullare and its divisions. We study these axones in three systems like those of the cerebrum:

- I. Projection, or peduncular fibers.
- II. Commissural fibers.
- III. Association fibers.

I. PROJECTION FIBERS.

All fibers that leave the cerebellum, or enter it, do so through the brachia, the restiform bodies and the superior medullary velum, hence these are composed of projection fibers. At a higher level the projection fibers are contained in the corpus medullare.

Brachium Conjunctivum (Figs. 44, 77 and 78).—The brachium conjunctivum (superior peduncle) is the innermost of the three, at its origin in the anterior cerebellar notch; external to it, in the notch, are the restiform body and the brachium pontis; and, in the angle between the brachium conjunctivum and the restiform body, is the vestibular nucleus of Bechterew (the upper part of Deiters's nucleus). The brachium conjunctivum is joined to its fellow of the opposite side by the **superior medullary velum** (*velum medullare superius*). Two bundles of fibers run throughout the brachium conjunctivum. They are afferent and efferent. *First*, the fibers to the cerebrum, which comprise nearly the whole brachium, are axones of cell-bodies situated in the nucleus dentatus. This group of fibers partially buries itself in the dorsal area of the pons, then penetrates the mid-brain and decussates ventral to the inferior quadrigeminal colliculi. It ends largely in the opposite red nucleus, but partly in the thalamus. It constitutes one segment of the indirect sensory path. In the red nucleus this path is relayed to the thalamus and to the cortical fillet, or the relay is directly into the cortical fillet. It is probable that a few fibers of this brachium terminate in the nuclei of the third and fourth, and perhaps the sixth cerebral nerves. The *second group* of fibers rises in the opposite red nucleus, pursues a reverse course and ends in the nucleus dentatus. A few fibers from Bechterew's nucleus are found in the cerebellar end of the brachium conjunctivum and the fila lateralia pontis traverses the same part of it. Although the greater number of these fibers in the conjoined brachia decussate in the tegmentum, a few run to the red nucleus and thalamus of the same side; while the fila lateralia cross in the pons from the opposite pontine nucleus and the commissural fibers between Bechterew's vestibular nuclei leave the brachium and cross through the superior velum in the isthmus. The **superior medullary velum** (Fig. 65) arches over

the fourth ventricle between the brachia conjunctiva. It is composed of longitudinal and transverse fibers. One distinct bundle, derived from the spinal cord, passes through it to the worm. This is the anterior ascending cerebello-spinal tract (Hoche). The decussating root-fibers of the fourth nerve (trochlear) course transversely through it and also the commissural fibers between Bechterew's nuclei.

Brachium Pontis (Middle Peduncle, Figs. 44, 78, 81 and 91).—The brachium pontis comes from the pons, of which it forms the anterior and middle transverse fibers. It enters into the medullary body of the cerebellum lateral to both the brachium conjunctivum and the restiform body. According to Klimoff fibers running to the cerebellum make up the entire brachium pontis. These are axones of the nucleus pontis, chiefly the opposite one. Most of them run to the cortex of the cerebellar hemisphere; a small number runs to the vermis cerebelli. They form a segment in the indirect motor path contained, above the pons, in the medial and lateral fifths and the intermediate bundle of the basis pedunculi. In the cerebellar end of the brachium pontis we may include the *acustico-cerebellar tract*. The latter is largely a descending tract but may contain some ascending vestibular fibers. It rises in the cerebellar nuclei, and probably in the ganglionic layer of the cortex; it terminates in the nucleus of Deiters. The principle origin of the acustico-cerebellar tract is in the opposite nucleus fastigii and nucleus globosus. It forms a part of the descending limb of the arc of equilibrium. By far the greater number of fibers in the brachium pontis, whether efferent or afferent, are crossed fibers.

Possibly there are in the brachium pontis axones of Purkinje's cells which terminate in the nuclei pontis on both sides and in the nuclei of the reticular formation.

The **corpus restiforme** (inferior peduncle) (Figs. 44, 78, 81 and 91) can be traced both to and from the upper part of the hemisphere and worm. Inferiorly, it is the restiform body of the medulla oblongata. The bundles of component fibers are very numerous: (1) The *posterior cerebello-spinal fasciculus* (direct cerebellar tract), whose origin is in the dorsal nucleus of the cord

and termination in the superior worm, forms its central part. (2) The *external arcuate fibers* of the medulla (posterior and anterior) form its free surface. They rise in the nucleus funiculi gracilis and nucleus funiculi cuneati and end in the vermis superior, the posterior on the same and the anterior on the opposite side. (3) A *bundle from the lateral nucleus of the medulla* to the cerebellar cortex on the same side. (4) The internal arcuate fibers to the opposite lower olive, the *cerebello-olivary tract*. These constitute a large part of the deep area of the restiform body and, with the acustico-cerebellar tract, make up all, or the greater part, of the indirect motor path from the cerebellum to the medulla. According to Cunningham the cerebello-olivary are ascending fibers.

There are probably a few axones of Purkinje's cells that run down through the corpus restiforme and are continued without interruption into the anterior descending cerebello-spinal tract of the spinal cord; but surely the greater part of that tract is relayed in the medulla and pons, chiefly in the nucleus of Deiters and in the inferior olivary nucleus.(?)

It should be noticed that the (posterior) cerebello-spinal fasciculus, the external arcuate fibers and the anterior ascending cerebello-spinal tract, with the tract from the lateral nucleus, are the incoming parts of the indirect sensory path, and that the brachium conjunctivum is the out-going continuation of that path up to the red nucleus and thalamus; and again, that the brachium pontis, the acustico-cerebellar tract and the descending fibers of the restiform body constitute segments of the indirect motor path and have to do with coordination and equilibrium.

II. COMMISSURAL FIBERS.

The cerebellar hemispheres are joined by transverse fibers, of which there are two sets, namely: One near the anterior end of the worm beneath the central lobe, and the other at the posterior end of the worm.

III. ASSOCIATION FIBERS.

Limited areas of cerebellar cortex are richly associated together as pointed out in the description of the cortical gray substance;

but there appears to be nothing analogous to the long association fibers found in the cerebrum.

RHOMBENCEPHALON.

SECTION II. THE PONS (VAROLII).

The pons and medulla form the ventral part of the rhombencephalon, the cerebellum being its dorsal portion. By a transverse indentation of its roof, the posterior brain-vesicle is partially divided into an upper vesicle, the *metencephalon*, and a lower vesicle, the *myelencephalon*; the latter is the embryonic medulla, the former gives rise to the cerebellum and the pons. The pons is developed from the floor of the metencephalon (Fig. 79). It is so named because it forms the connecting link, or *bridge*, between the mid-brain, above, and the cerebellum and medulla oblongata, below; between the medulla and cerebellum, and between the two cerebellar hemispheres (Fig. 85).

In shape the pons is roughly cylindrical. It has a broad basal or ventral part, the *pars basilaris pontis*, and a narrower dorsal portion, the *pars dorsalis pontis* (Fig. 87).

Size.—The pons is about one inch long. It is a little broader than long, and measures an inch, dorso-ventrally.

Position.—It rests in the anterior end of the groove which extends from the foramen magnum to the dorsum sellæ, and lies between and ventral to the hemispheres of the cerebellum. Superiorly, it joins the mid-brain; and, below, it is continuous with the medulla oblongata.

Surfaces of the Pons.—The pons has four surfaces, viz., superior (attached); inferior (attached); anterior (free), and posterior (partially free); and two borders, namely, right and left lateral, continuous with the brachium pontis of the cerebellum.

The superior and inferior surfaces are made by section, and are directly continuous with mid-brain above and the medulla below.

Anterior Surface (Tuber annulare).—The anterior surface of the pons (Fig. 85) looks forward and slightly downward and rests on the sphenoid bone behind the sella turcica. It is divided

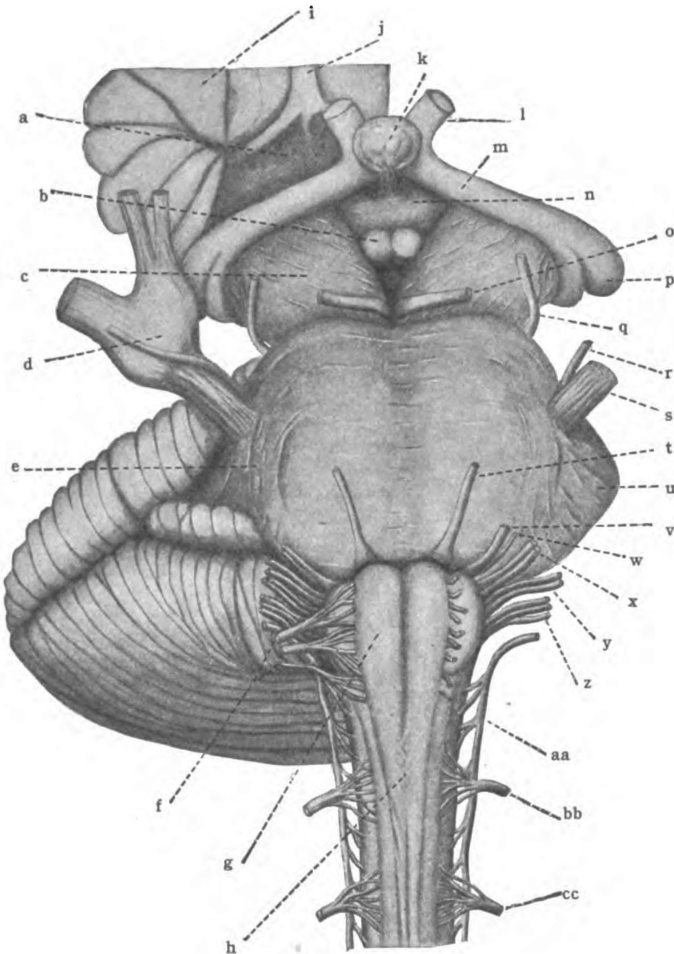


Fig. 85.—Anterior aspect of mid-brain, pons and medulla. (After *Morris's Anatomy*.)

a. Anterior perforated substance. b. Corpus mammillare. c. Cerebral peduncle. d. Ganglion semilunare (gasseri). e. Oblique fasciculus. f. N. hypoglossus (XII). g. Pyramid. h. Decussation of pyramids. i. Insula. j. Olfactory tract. k. Hypophysis. l. N. opticus (II). m. Optic tract. n. Tuber cinereum. o. N. oculomotorius (III). p. Lateral geniculate body. q. N. trochlearis (IV). r. N. trigeminus (M. P.). s. N. trigeminus (V). t. N. abducens (VI). u. Brachium pontis. v. N. facialis (VII). w. N. intermedius. x. N. acusticus (VIII). y. N. glossopharyngeus (IX). z. N. vagus (X). aa. N. accessorius (XI) (spinal accessory). bb. Cervical I. cc. Cervica II.

into lateral halves by the sulcus basilaris, containing the basilar artery; and is bounded laterally by a sagittal plane cutting the root of the trigeminal nerve. Vertically the surface is slightly convex, and is markedly so from side to side. It shows transverse striations, which converge laterally, due to the fibers that form it and enter the brachia pontis of the cerebellum. The fibers of the anterior surface are not exactly transverse in direction. Those at the superior end of the pons bend downward (*fasciculus obliquus*) and form a rounded margin, which covers the lower part of the bases pedunculi of the mid-brain; at the inferior extremity of the pons, the fibers are convex downward and partially conceal the pyramids of the medulla oblongata. The two roots of the fifth nerve (trigeminal) are attached to the lateral border (Henle) of this surface, a little above the middle.

The *posterior surface* of the pons is concealed by the cerebellum (Fig. 88). It is free in its middle part, where it forms the floor of the superior half of the fourth ventricle (Fig. 86). The **ventricular area** of the posterior surface is completely concealed by the superior medullary velum. If examined, it is found to be divided into lateral halves by a median longitudinal groove. Each half presents in its posterior part a rounded eminence, the *colliculus facialis*, which flanks the median furrow and is in turn bounded, laterally, by a linear valley, the *sulcus limitans*, lying near the brachium conjunctivum cerebelli and parallel with it. The inferior end of the valley is called the *fovea superior*; its upper part has a bluish tint, due to underlying pigmented cells, and is called the *locus ceruleus*. **Attached Area.**—Lateral to this ventricular area, the posterior surface of the pons is attached to the restiform body and the conjoined arms of the cerebellum. The restiform bodies enter the surface near the lower end of the pons and then bend downward into the medulla oblongata; while the brachia conjunctiva, in their course up to the cerebrum, partly imbed themselves in the lateral part of the posterior surface and form the walls of the fourth ventricle. The lateral fillet issues from this surface just external to the brachium conjunctivum. It runs obliquely across the upper end of the brachium to the inferior colliculus of the corpora quadrigemina, and pro-

duces a flat striated ridge, which may be seen easily in a well hardened specimen.

Structure of the Pons.—The pons is composed of transverse and longitudinal white fibers and of gray matter. The trans-

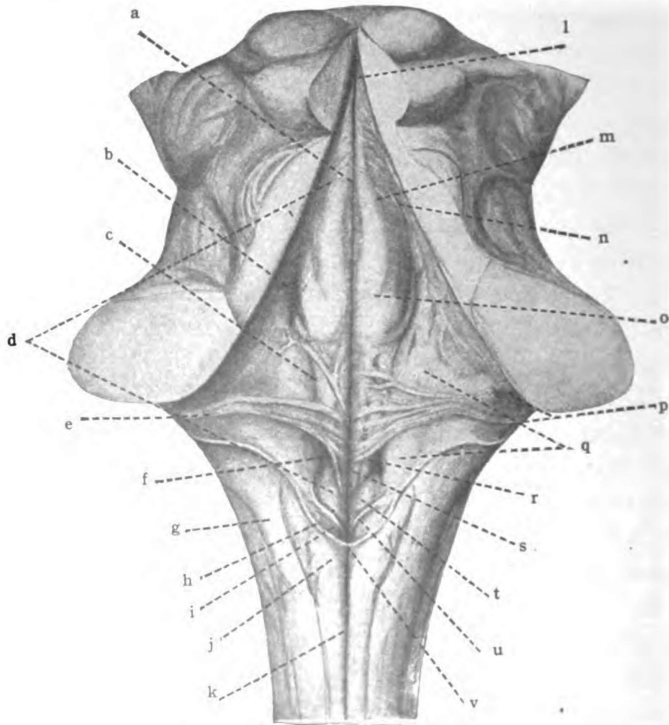


Fig. 86.—Dorsal surface of pons and medulla. (*Morris's Anatomy modified from Spalteholz.*)

a. Median sulcus. b. Superior fovea. c. Limiting sulcus. d. Medial eminence. e. Striæ medullares. f. Inferior fovea. g. Nucleus funiculi cuneati. h. Tænia of fourth ventricle. i. Area postrema. j. Nucleus funiculi gracilis (clava). k. Posterior median fissure. l. Aquæductus cerebri. m. Nucleus incertus. n. Locus cæruleus. o. Colliculus facialis et nucleus abducentis. p. Nucleus N. cochlearis (tuberculum acusticum). q. Area acustica (nucleus vestibularis). r. Nucleus intercalatus. s. Trigonum N. hypoglossi. t. Ala cinerea. u. Funiculus separans. v. Obex.

verse fibers are found chiefly in the basilar portion of the pons; the longitudinal, in both the basilar and the dorsal part. The anterior longitudinal intersect the deep transverse fibers of the pars basilaris.

TRANSVERSE FIBERS OF PONS.

The transverse fibers form *three consecutive layers in the pons*, viz., the anterior, the middle, and the posterior layer. They lie one upon another. The two former are situated in the basilar area of the pons, the latter in the dorsal area (Figs. 87 and 88).

The **superficial transverse fibers** are anterior in position and form a thin compact layer constituting the anterior surface of the pons (Fig. 87). They are not intersected by longitudinal fibers; but, otherwise, are like the deeper transverse fibers of the *pars basilaris pontis*.

Deep Transverse Fibers of Pars Basilaris.—These form a thick lamina posterior to the superficial transverse fibers and in contact with the superficial lamina. They are intermingled with longitudinal fibers from the bases pedunculi, viz., the pyramidal, fronto-pontal, temporo-pontal and intermediate tracts (Figs. 87 and 88). In the meshes between the intersecting fibers is a large mass of gray matter, on either side, called the *nucleus pontis*. The deep and superficial transverse fibers of the *pars basilaris pontis* form the *brachia pontis cerebelli*. Their origin is found in the opposite nucleus pontis (Klimoff). They continue the indirect motor path from the termination of the fronto-pontal, temporo-pontal and intermediate tracts in the nucleus pontis to the cerebellar cortex of the opposite side.

In connection with the superficial and deep transverse fibers in the basilar part of the pons there should be mentioned an independent strand, the **fila lateralia pontis**, which is situated at the upper border of the pons and buried more or less in the isthmian furrow between the pons and mid-brain. It is called by Henle the *tænia pontis*. According to Sir Victor Horsley, it rises from the nucleus pontis just ventral to the interpeduncular ganglion, and, winding round the isthmus, enters the cerebellum through the *brachium conjunctivum*. Its destination is probably the nucleus dentatus and nucleus fastigii (Brain, Vol. 29, No. 113).

The **transverse fibers of the pars dorsalis pontis** (Fig. 88) compose a thin layer on the dorsum of the middle transverse fibers, separating them from the *formatio reticularis*. This

transverse lamina is present only in the inferior part of the pons. It is called the *corpus trapezoideum*.

The *trapezoid body* (*corpus trapezoideum*) lies in the dorsal area of the pons, next the boundary between the *pars basilaris* and the *pars dorsalis pontis*. Its fibers rise chiefly from the nuclei of the cochlear nerve and, after decussating in the raphe, are continued up in the lateral fillet to the inferior quadrigeminal colliculus. A few fibers join the tract directly from the cochlear nerve. The *nuclei* of the trapezoid body and of the superior olive form relays for a number of its fibers. The *corpus trapezoideum* with the medullary striæ, and the lateral fillet, which is the continuation of both, form the second stage in the auditory conduction path; and the auditory impulses are continued (a) through the *brachium quadrigeminum inferius* and (b) the temporo-thalamic radiation to the temporal cortex (Fig. 89).

LONGITUDINAL FIBERS OF PONS.

. The longitudinal fibers of the pons are arranged in two distinct groups, viz., the ventral or anterior and the dorsal or posterior (Figs. 87 and 88). The groups are separated by the trapezoid body.

The **ventral longitudinal fibers** are situated in the *pars basilaris pontis* (Figs. 87 and 88). Four fasciculi make them up. They are the four motor tracts of the basis pedunculi. The fronto-pontal, temporo-pontal and intermediate tracts terminate in the nucleus pontis. The pyramidal fibers run from the middle three-fifths of each basis pedunculi down through the middle transverse layer of the pons to the pyramids of the medulla oblongata. Together with the above cerebro-pontal tracts they form a thick bundle on either side of the median line, which presses down the superficial transverse fibers and produces the *sulcus basilaris*. The *nucleus pontis*, one on either side, is situated among the pyramidal fibers. The pyramidal tracts diminish in size during their descent, because of the fibers which leave them to decussate and end in the nuclei of motor cerebral nerves.

The Dorsal Longitudinal Fibers.—These are contained in

the *pars dorsalis pontis* in the *formatio reticularis* (Figs. 87 and 88). They are dorsal to the corpus trapezoideum, and lie in the floor of the fourth ventricle, where they are intermingled with the ventricular gray substance. They do not form a compact layer, but are collected into a number of distinct strands, of which the larger are visible to the naked eye in Weigert-Pal sections. The dorsal longitudinal fibers are mingled with many transverse and oblique fibers; and, thus, there is produced the netlike arrangement suggesting the name, *formatio reticularis*. The *formatio reticularis* of the pons is continued down from the tegmentum of the mid-brain and comprises the tegmental region of the pons. The gray matter in the meshes of this network, which is the stratum nucleare continued up from the medulla, contains the nuclei of the fifth, sixth and seventh cerebral nerves and a part of the nucleus of the eighth nerve, and also the nuclei of the *formatio reticularis*, viz., the nucleus centralis superior, medius and inferior, and the nucleus lateralis medius. In the *formatio reticularis* are the nine bundles or tracts of fibers that constitute the dorsal longitudinal fibers of the pons. These tracts are as follows: The anterior ascending cerebello-spinal tract, the spinothalamic tract, the medial fillet, the lateral fillet, the medial (posterior) and anterior longitudinal bundles, the rubro-spinal tract, the olivary fasciculus, and the descending root of the fifth cerebral nerve, besides unidentified fibers of the *formatio reticularis* which are probably both ascending and descending in conduction. The anterior ascending cerebello-spinal tract and the descending root of the trigeminal (or fifth) nerve are the only tracts not already considered in our study of the tegmental region of the mid-brain, page 156.

(1) The **medial fillet** (*lemniscus medialis*, Figs. 87 and 88) is a large bundle of fibers that runs through the pons next the median plane. In the lower part of the pons it lies dorsal to the trapezoid body, though some of the trapezoidal fibers pierce it. Its origin is found on the opposite side in the nucleus funiculi gracilis and nucleus funiculi cuneati and in the terminal nuclei of common sensory cerebral nerves (Fig. 94). It conducts impulses of the tactile and muscular senses. In the mid-brain it

gives off the *superior fillet* (*lemniscus superior*) which terminates in the superior quadrigeminal colliculus. The medial fillet ends in the lateral nucleus of the thalamus (Fig. 47). Interruption of the medial lemniscus causes ataxia on the opposite side.

(2) **Lateral Fillet.** (*Lemniscus lateralis*).—The lateral fillet forms a link in the special sense, auditory path (Fig. 89). As stated on page 160 it is but the longitudinal continuation of the corpus trapezoideum and the medullary striæ. It takes form near the middle of the pons, where the fibers of the trapezoid body bend upward to a longitudinal direction; and it runs just lateral to the medial fillet (Figs. 86 and 87). Very soon it becomes separated from the medial fillet by the brachium conjunctivum of the cerebellum. It runs dorso-medially over the conjoined brachium to the inferior colliculus of the corpora quadrigemina, where a few of its fibers end; but the greater number are continued through the brachium inferius to the medial geniculate body. The chief origin of the lateral fillet is found in the opposite cochlear nuclei, though some of its fibers rise in the nucleus of the corpus trapezoideum, the superior olivary nucleus, and the nucleus of the lateral fillet, which constitute partial relays in the auditory path. It is also true that a few fibers enter the lateral fillet from the cochlear nuclei and nerve of the same side; they are supposed to decussate near or in the quadrigeminal bodies and terminate in the opposite inferior colliculus. Destruction of the lateral fillet causes deafness, almost complete, in the opposite ear.

(3) The **spino-thalamic tract** occupies the lateral part of the formatio reticularis where it is intermingled with the anterior ascending cerebello-spinal tract (Figs. 87 and 88). As already stated, it rises in the spinal cord from the basal gray substance of the anterior column and from the terminal nuclei of common sensory cerebral nerves in the medulla and pons. The spino-thalamic tract ends in the lateral nucleus of the thalamus. It conducts impulses of the tactile, pain and temperature senses.

(4) The **anterior ascending cerebello-spinal tract** has the same spinal origin and function as the spino-thalamic tract and the same course up to the isthmus rhombencephali (Figs. 87 and 88). There, it bends backward, medial to the brachium con-

junction, and, through the superior medullary velum, enters the superior worm of the cerebellum. It thus belongs to the indirect sensory path (through the cerebellum). From the cerebellar cortex the path is continued by the axones of Purkinje's cells to the nucleus dentatus, whence the brachium conjunctivum completes it up to the opposite red nucleus and thalamus. The anterior ascending cerebello-spinal and the spino-thalamic tracts

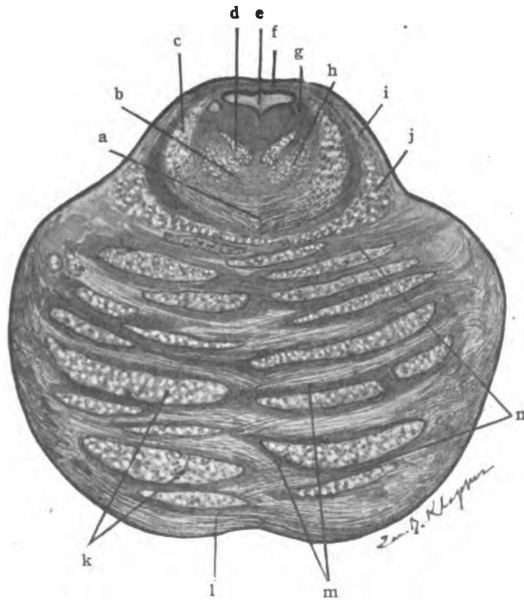


Fig. 87.—Superior section of the pons. (Original.)

a. Beginning of decussation of brachium conjunctivum. b. Formatio reticularis. c. Brachium conjunctivum. d. Medial longitudinal bundle. e. Fourth ventricle. f. Superior medullary velum. g. Descending root of 5th n. h. Spino-thalamic tract. i. Lateral fillet. j. Medial fillet. k. Long. fibers from basis pedunculi. l. Superficial transverse fibers. m. Nucleus pontis. n. Deep transverse fibers of pars basilaris pontis.

are the chief bundles of a spino-encephalic system of fibers which terminates very largely in the cerebellum and thalamus, but also sends fibers to the nucleus lateralis inferior and other reticular nuclei, to the substantia nigra, to the inferior and superior colliculi of the corpora quadrigemina, to the nucleus ruber, the nucleus hypothalamicus, and the corpus striatum. In this spino-encephalic system there are two important paths—the *direct*

path (No. 3) and the *indirect path* (No. 4)—for *tactile, pain and temperature impulses*. It is called *Gowers's tract*.

(5) The **medial (posterior) longitudinal bundle** (*fasciculus longitudinalis medialis*) (Figs. 87 and 88) runs next the median plane and just under the ventricular gray matter in a position similar to the one it occupies in the mid-brain (Figs. 47 and 48), see page 156. It is in the pontine portion of this bundle that the fibers from the oculomotor nucleus pass to the genu of the facial nerve, ultimately to innervate the frontalis, corrugator and orbicularis oculi; it is in the pons, that fibers from the abducent nucleus join this bundle, and run upward through it to the oculomotor nucleus of the opposite side and make possible the conjugate movements of the eyeballs; it is also here, that fibers, which rise in the hypoglossal nucleus, leave the longitudinal bundle and enter the facial nerve at the genu to be distributed by way of the facial to the orbicularis oris. As in the mid-brain, the longitudinal bundle includes the two functional tracts, the descending strand and the ascending strand.

(6) **Anterior Longitudinal Bundle.**—This ocular-reflex bundle is continued from the mid-brain down through the pons in nearly the same relative position. Diverging a little from the medial longitudinal bundle as it descends through the pons, it is located in the formatio reticularis a short distance ventro-lateral from it. The anterior longitudinal bundle can be recognized in normal adult tissue only in the dorsal tegmental decussation (Meynerti) of the mid-brain: lower down it can be distinguished from the surrounding tissues by degeneration and medullation but in no other way (Fig. 87). Having given fibers to the oculomotor and trochlear nuclei above, it sends fibers to the nucleus of the abducent nerve at this level, and perhaps to other pontine nuclei (see Mid-brain, page 158).

(7) **Rubro-spinal Tract.**—In the mid-brain, we have traced this tract from the red nucleus, through the ventral tegmental decussation (Foreli), to the opposite side, where it mingles with the lateral fillet down near the isthmus (Figs. 47 and 48). It occupies the same position in the upper half of the pons; it is close to the posterior surface of the corpus trapezoideum in the lower

part of the pons (Figs. 87 and 88). In the center of the gray crescent of the spinal cord the rubro-spinal tract ends. Its function is unknown, perhaps it has to do with locomotion (Horshy).

(8) The **olivary bundle** (*fasciculus olivaris*) is regarded by many as an ascending tract, but the weight of evidence at present is in favor of a descending course. Rising in the lentiform nucleus and descending through the mid-brain, it enters the center of the

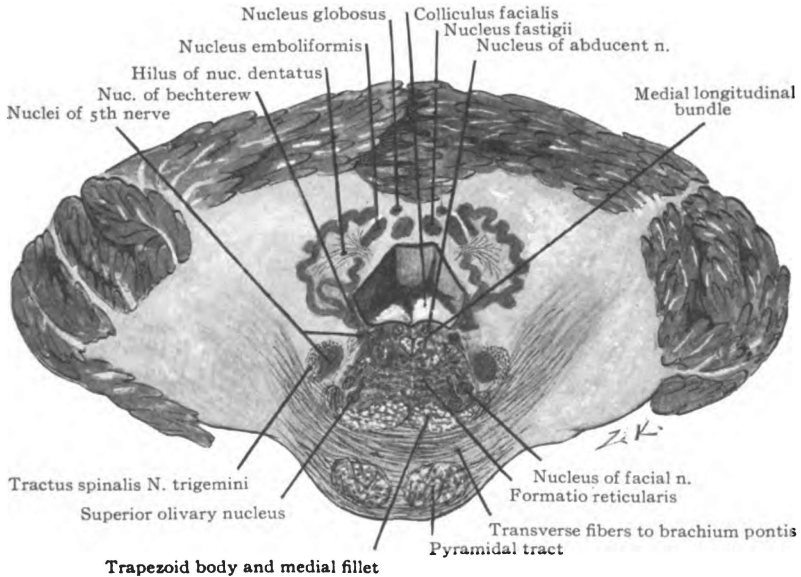


Fig. 88.—Inferior section of the pons together with the cerebellum. (Original.)

reticular formation of the pons, hence the name, *central tegmental tract* (Fig. 88). It runs dorsal to the medial fillet and the corpus trapezoideum in the lower part of the pons, just medial to the superior olivary nucleus. It terminates in the inferior olive.

(9) The **descending root of the trigeminal nerve** (Fig. 87) is crescentic in section and runs between the ventricular gray substance and the brachium conjunctivum of the cerebellum down to the middle of the pons, where it joins the principle motor root. It passes lateral to the motor nucleus situated under the locus

cæruleus, and runs between it and the superior end of the terminal or sensory nucleus.

In the lowest part of the pons there is seen the **spinal tract of the fifth nerve** (*tracus spinalis nervi trigemini*). This is a part of its sensory root and is composed of the descending limbs of T-branched axones from the semilunar ganglion (Gasseri). The spinal tract of the trigeminal nerve runs lateral to the gray substance, between the substantia gelatinosa (Rolandi), on the inner side, and the vestibular root of the acoustic nerve and the restiform body on the outer side.

GRAY MATTER OF THE PONS.

In the pons gray matter is found in two situations: (1) In the interstices between the deep transverse fibers of the pars basilaris pontis and the ventral longitudinal fibers, the *nuclei pontis*; and (2) in the formatio reticularis, just under the fourth ventricle where it forms the *stratum nucleare*.

The **nucleus pontis** is a mass of gray matter, on either side the raphe, containing the bodies of large multipolar nerve cells whose axones run through the brachium pontis of the cerebellum to the cortex on the opposite side. It extends vertically throughout the pons and is continuous with the arcuate nucleus of the medulla. The nucleus pontis receives the terminals of the descending tracts which form the inner and outer fifths of the basis pedunculi and the intermediate bundle of the same, and thus connects these tracts with the cerebellum. It forms a relay in the indirect motor path.

The **gray matter of the stratum nucleare** includes (1) *the olivary group* of nuclei, viz., the superior olivary nucleus, the nucleus of the corpus trapezoideum, the preolivary nucleus and the semilunar nucleus; (2) *the nuclei of the formatio reticularis*, viz., the nucleus centralis superior, medius and inferior, and the nucleus lateralis medius; and (3) *the nuclei of cerebral nerves*—the fifth, sixth and seventh, and a part of the vestibular nucleus of the eighth nerve.

(1) **Olivary Group.**—The *superior olivary nucleus* (n. olivaris

superior) is situated in the lateral part of the formatio reticularis in the dorsal portion of the corpus trapezoideum (Fig. 88). It lies just ventral to the nucleus of the facial nerve and ventrolateral to the olivary bundle of fibers. The nucleus contains small bodied nerve cells; and, in this respect, resembles the olive of the medulla. Its outline is crescentic, convex toward the median line. In size it is microscopic. According to Bruce and Cunningham it is continuous with the nucleus of the lateral fillet. The superior olive constitutes a subordinate relay in the auditory path, receiving fibers from the cochlear nuclei of both sides and contributing fibers to both lateral fillets (Fig. 89).

The *superior olivary nucleus* gives off a small strand of fibers, called the *olivary pedicle*, which runs dorso-medially, between the recurrent and emergent parts of the root of the facial nerve, to the nucleus of the abducent nerve; there some of its fibers end, the remainder join the medial longitudinal bundle and run to the trochlear and oculomotor nuclei. The pedicle forms part of an auditory-ocular reflex arc.

A small accessory nucleus, called the nucleus *præolivaris*, is situated just a little ventral to the superior olivary nucleus; and a second one embraces the convexity of the nucleus olivaris superior, lying on the medial side of it. The latter is the *nucleus semilunaris*.

Nucleus of the Trapezoid Body (N. Corporis Trapezoidei).— This nucleus is deeply imbedded in the trapezoid body ventromedial to the superior olivary nucleus (Fig. 88). Its cell-bodies are scattered and, like the other nuclei of the olivary group, it forms a partial relay for the auditory path. This nucleus is peculiar; the fibers it receives terminate in the form of cup-shaped discs, *acoustic cups*, which are in direct contact with its cell-bodies (Held).

(2) The **nuclei of the reticular formation** contained in the pons are the *n. centralis superior*, *n. centralis medius*, *n. centralis inferior* and *n. lateralis medius*. All are microscopic. They are made up of large scattered cell-bodies whose axones, dividing T-like, are both ascending and descending in direction (Tschermak). We may divide these axones into *two groups*, a crossed and an uncrossed. The *crossed fibers* pierce the median plane and become

longitudinal in the formatio reticularis near the ventricular gray matter and medial to the root of the abducent nerve. At that point they bifurcate and one branch runs upward and the other downward. The descending branches of the crossed fibers (lateral ponto-spinal tract) pass through the substantia reticularis grisea of the medulla and the lateral area of the spinal cord throughout its length; they end in the center of the gray crescent in successive segments until exhausted near the end of the cord (Tschermak,

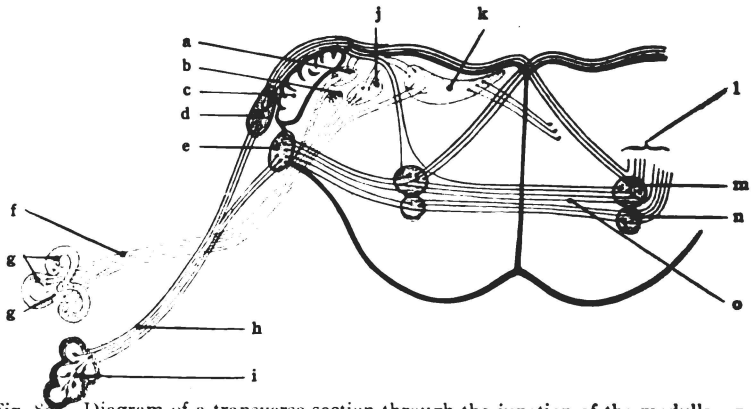


Fig. 80.—Diagram of a transverse section through the junction of the medulla and pons showing the roots and nuclei of the eighth cranial nerve and the auditory paths in the pons. (After *Morris's Anatomy*.)

a. Bechterew's nucleus. b. Nuc. of descending root. c. Restiform body. d. Lat. cochlear nucleus. e. Ventral nucleus. f. Vestibular nerve. g. Semicircular canals. h. Cochlear nerve. i. Cochlea. j. Dorso-lateral nucleus (Deitersi). k. Dorso-medial nucleus. l. Lateral fillet. m. Superior olivary nucleus. n. Nucleus of trapezoid body. o. Trapezoid body.

Barker). The *uncrossed fibers* from the reticular nuclei enter the medial longitudinal bundle of the same side and there branch T-like. The descending branches (anterior ponto-spinal tract) run with this bundle into the anterior column of the spinal cord, through which some of them continue to the end. They occupy the outer side of the anterior funiculus and end in succession in the anterior column of gray matter (Tschermak and Barker). Just what is the destination of the ascending branches of either group of fibers has not been determined. J. S. Collier suggests that these tracts from the reticular nuclei should be called the *crossed and uncrossed ponto-spinal tracts* (Brain, Vol. 24, 1901).

(3) **Nerve Nuclei.**—The *nuclei of the trigeminal nerve* (*nuclei nervi trigemini*) are two in number. The *genetic* or motor *nucleus* of the fifth nerve (*n. motorius*) in the pons is a continuation of the mesencephalic nucleus. It is rather close to the fourth ventricle in the extreme lateral part of its floor, underneath the locus cæruleus (Fig. 86). It extends as far down as the middle of the pons, where the whole group of axones passes forward into the motor root of the nerve. *Cortical Connection.*—The nucleus receives motor fibers from the opposite pyramidal tract and perhaps from the cerebro-pontal tracts of the same side; and sensory fibers terminate in it from the sensory root of the fifth nerve, and from the terminal nuclei of other common sensory nerves, through the medial longitudinal bundle and establish its *reflex connections*.

The *terminal or sensory nucleus* (*n. terminalis or sensibilis*) of the trigeminal nerve begins at the middle of the pons and extends to the second segment of the spinal cord. At its superior end it is ventro-lateral to the motor nucleus and under cover of the brachium conjunctivum of the cerebellum (Figs. 86 and 87). Near the medulla it lies ventro-medial to the restiform body and the vestibular root of the acoustic nerve. This part of it is almost in contact with the nucleus of the facial nerve, and its distance from the ventricle is greater than it is higher up. The nucleus is gelatinous in character and is continuous with the same substance in the posterior column of the spinal cord. It receives the whole sensory root of the trigeminal nerve. Just lateral to it runs the spinal tract of the fifth nerve, the fibers of which gradually bend into the nucleus and terminate in rich arborizations. Axones from the nucleus pursue several different courses: (a) *Reflex fibers* go directly to the motor nucleus of the fifth and through the medial longitudinal bundle to other motor nuclei. (b) *Tactile, pain and temperature fibers* are supposed to enter the opposite spino-thalamic tract through which they reach the thalamus; perhaps, some run through the anterior cerebello-spinal tract to the cerebellum. (c) *Tactile and muscular sense fibers* proceed to the thalamus, probably through the medial fillet on the opposite side.

Nucleus of the Abducent Nerve (*N. Nervi Abducentis*).—This

motor nucleus is close to the median plane and is separated from the ependyma of the ventricular floor only by the fibers of the seventh or facial nerve. It is situated in the colliculus facialis (Figs. 86 and 88). The root-fibers of the facial nerve run lateral to the sixth nucleus, describe a loop on its dorsal surface and then return lateral to it. *Cortical Connection.*—The abducent nucleus receives the end-tufts of motor fibers from the opposite pyramidal tract and from the cerebro-pontal tracts. It receives *reflex impulses* through the anterior and medial longitudinal bundles and the pedicle of the superior olivary nucleus; and perhaps, also, through the brachium conjunctivum from the cerebellum. The axones of the cell-bodies in the abducent nucleus run in two directions: The greater number run ventro-lateralward and emerge at the lower part of the pons, as abducent nerve; a small bundle of axones runs to the oculomotor nucleus on the opposite side by way of the medial longitudinal bundle. The former innervates the external rectus muscle of the eye on the same side as the nucleus; the latter, through the third nerve, innervates the internal rectus of the opposite eye, though that muscle receives independent fibers from the third, also.

The nucleus of the facial or seventh nerve (n. nervi facialis) is *genetic* or motor (Fig. 88). It is situated deep in the pons, in the lateral part of the formatio reticularis, beneath the superior fovea. Immediately ventral to it is the superior olivary nucleus, and the substantia gelatinosa (Rolandi) lies dorso-lateral to it. The nucleus is placed midway between the spinal tract of the fifth nerve and the olivary fasciculus. *Cortical Connections.*—It receives voluntary motor impulses from the cerebral cortex of the opposite hemisphere via the pyramidal tract; and, probably, fibers of the cerebro-pontal tracts terminate in it. These establish its motor connections. The *reflex connections* of the facial nucleus are established by fibers from the spinal tract of the trigeminal nerve, from the trapezoid body (Cunningham), and from the medial longitudinal bundle. The axones of the cell-bodies in the nucleus facialis all enter the root of the facial nerve. By its direction this root is divided into three parts, viz., two distinct parallel parts, joined by a very short ascending portion.

(1) The recurrent part, the *pars prima*, runs dorso-medialward to the colliculus facialis, passing lateral and then dorsal to the lower end of the abducent nucleus; (2) it then ascends about one-fifth of an inch (Cunningham) between the ventricular ependyma, dorsally, and the abducent nucleus and medial longitudinal bundle, ventrally, and this part is called the *genu internum*; and (3) the *pars secunda*, bending sharply outward over the nucleus of the sixth nerve, then plunges ventrally through the pons; this emergent part of the root runs between the nuclei of the facial and trigeminal nerves. The root of the facial nerve is joined at the *genu internum* by fibers from the medial longitudinal bundle which rise in the oculomotor and hypoglossal nuclei and supply the facial muscles above the orbit and the orbicularis oris respectively.

Just dorsal to the facial nucleus is a small group of cell-bodies which is said to constitute a *salivary nucleus* (Cunningham). Its axones run to their destination through the *nervus intermedius* and its *chorda tympani* branch, and form the efferent root of the *nervus interdemedius*. They are secretory and vasodilator fibers to the submaxillary and sublingual glands.

Vestibular Nucleus of the Auditory Nerve (N. Nervi Vestibularis) (Fig. 88).—This nucleus is made up of three parts: (1) The *chief nucleus* (Schwalbe); (2) the *nucleus of the descending root*, and (3) the *nucleus of Deiters*, which is lateral in position. The superior parts of Schwalbe's and of Deiters's nuclei extend into the pons just medial to the restiform body, and the nucleus of Deiters is prolonged dorsally along that body toward the cerebellum. This dorsal extension of Deiters's nucleus is called Flechsig's or Bechterew's nucleus. We shall recur to the vestibular nucleus in the medulla where the greater part of it is located.

Lesions in the pons are usually attended by crossed paralysis. The paralysis and anæsthesia of parts supplied by spinal and by bulbar cerebral nerves are on the opposite side, but the fifth, sixth and seventh cerebral nerves of the same side as the lesion are apt to be involved. If the spino-thalamic and anterior ascending cerebello-spinal tracts are involved and not the medial fillet, the pain and temperature sense is lost, but there is no ataxia; if

the medial fillet be destroyed and not the spino-thalamic and anterior ascending cerebello-spinal tracts, then the pain and temperature sense is intact, but the muscular sense is lost on the opposite side of the body. The tactile sense is impaired in both cases. A lesion of the trapezoid body produces almost total deafness; of the lateral fillet, slightly impaired hearing on the same side and nearly complete deafness in the opposite ear. Conjugate deviation occurs when the nucleus of the sixth nerve is affected; and strabismus when the root fibers, but not the nucleus, are involved. The strabismus is external if the lesion be irritative and internal if the root fibers are destroyed. Destructive lesion in the nucleus of the seventh nerve causes inferior paralysis of the face, the frontalis, corrugator, orbicularis oculi and orbicularis oris not being affected. Complete facial paralysis occurs if the root-fibers of the facial nerve be destroyed in the pars secunda or in the genu internum.

RHOMBENCEPHALON.

SECTION III. THE MEDULLA OBLONGATA. (MYELENCEPHALON.)

Situation.—The medulla oblongata is the distal, or caudal part of the brain (Figs. 21 and 27). It may be regarded as the expanded intra-cranial portion of the spinal cord, hence the synonym, *spinal bulb*. It occupies the basilar groove of the occipital bone, posterior to the pons; and is continuous with the spinal cord below the foramen magnum. Dorsally, it is in part concealed in the valley of the cerebellum. The vertebral arteries wind forward around it, and form the basilar at its junction with the pons.

Size.—The medulla is about an inch long, and dorso-ventrally, is a half-inch thick. Its width at the lower end is a half-inch, also. At the upper extremity it measures from three-quarters of an inch to one inch in width (Figs. 85 and 86).

Its **shape** resembles an inverted frustum of a cone flattened dorso-ventrally at the base. The truncated apex of the frustum, which is nearly circular in outline, is continuous with the spinal

cord; and the flattened base joins the pons. On the anterior surface, a transverse groove marks the boundary between the medulla and pons. The medulla is a bilateral organ composed of symmetrical halves (Figs. 85 and 86). In the interior, the two halves are united by both gray and white matter in the raphe, but on the surface they are partially separated by the anterior and the posterior median fissures (fissura mediana anterior and f. m. posterior). These fissures are continued through the spinal cord, but neither extends the whole length of the medulla. The anterior median fissure is interrupted in the lower part of the medulla by the crossing of two large tracts of fibers, forming the

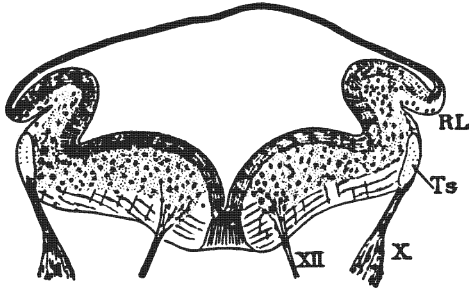


Fig. 90.—Section of embryonic medulla. Length of back, 9.1 mm.
(Gordinier and Minot after His.)

RL. Rhomboid lip. Ts. Tractus solitarius. X. Vagus nerve. XII. Hypoglossal nerve.

decussation of the pyramids; while only through the lower half of the medulla does the posterior median fissure extend.

Origin.—The medulla oblongata is developed from the myelencephalon of the embryo (Figs. 90 and 118). The myelencephalic floor and walls thicken and form the greater part of the medulla. Inferiorly, the roof undergoes some thickening; but it stretches out into a single layer of epithelium, superiorly, which is continuous at its upper end with the inferior medullary velum of the cerebellum.

Ventricle.—The common cavity of the posterior brain vesicle persists in the mature brain as the fourth ventricle (Figs. 118, 90 and 86). The fourth is, therefore, the ventricle of the adult rhombencephalon (see page 313).

SURFACES.

The medulla oblongata presents four surfaces: The *anterior*, *posterior* and *two lateral*, separated by the anterior lateral and posterior lateral grooves. In the upper medulla, the surfaces are clearly defined; but they become less distinct as they descend to the inferior and nearly circular extremity (Figs. 81, 85 and 86).

The **anterior lateral sulcus** (*s. lateralis anterior*) separates the anterior from the lateral surface, and is in line with the exits of the anterior roots of the spinal nerves. No corresponding groove exists in the cord. From the anterior lateral groove issue the roots of the hypoglossal nerve and the anterior root of the first cervical nerve. The abducent (or sixth) nerve rises nearly in line with it from the transverse groove between the pons and the medulla (Fig. 86).

Posterior Lateral Sulcus. (*S. lateralis posterior*).—The posterior lateral sulcus of the medulla separates the lateral from the posterior surface (Figs. 86 and 87). It descends between the olive and the restiform body and is continued through the spinal cord. Through this sulcus into the cord run the posterior roots of the spinal nerves, and, likewise, the sensory roots of the vagus and glossopharyngeal nerves run through it into the medulla; while the motor roots of the ninth and tenth and the cerebral root of the eleventh nerve emerge from the medulla through the posterior lateral sulcus. The roots of the seventh, eighth and intermediate nerves are found at the superior end of the sulcus in the transverse groove between the medulla and pons. The posterior lateral sulcus is not parallel with the axis of the medulla, but bends outward and forward as it ascends. Inferiorly, it is obliterated for a short distance by the crossing of the fasciculus cerebello-spinalis (direct cerebellar tract) from the lateral to the posterior surface.

The **anterior surface** (*facies anterior*) of the medulla, bounded on either side by the anterior lateral sulcus, extends from the transverse sulcus below the pons down to the spinal cord (Fig. 85). It is made up of symmetrical halves united, below, by the decussation of the lateral (crossed) pyramidal tracts; but separated, above, by the anterior median fissure, which terminates at the

inferior end of the pons in a blind foramen (foramen cæcum of Vicq d'Azyr). On either side of the median fissure, the anterior surface presents a fusiform eminence, most prominent near the pons, called the **pyramid**. The pyramidal tract, which we have already traced through the internal capsule, basis pedunculi and pons, forms the pyramid of the medulla. In the lower part of the medulla the pyramid divides into two tracts, viz., the *lateral* (or crossed) *pyramidal tract* and the *anterior* (or direct) *pyramidal tract*, the former comprising about the medial four-fifths and the anterior pyramidal tract the lateral one-fifth of the pyramid. Transverse fibers, called the *anterior external arcuate*, are also seen crossing the pyramid from within outward. They form a more or less continuous sheet of fibers, which emerges from the anterior median fissure and winds around the medulla to the posterior surface, where its fibers enter the restiform body. The anterior surface is identical with the surface of the two anterior areas of the medulla.

Lateral Surface. (*Facies lateralis*, Figs. 81 and 85).—There are two lateral surfaces, a right and a left. Each is bounded by the anterior lateral and the posterior lateral sulcus; and is inclosed between the roots of the hypoglossal nerve, ventrally, and those of the ninth, tenth and the cerebral portion of the eleventh, dorsally. Lateral surface is synonymous with the surface of the lateral area. The lateral surface is formed, above, by the *olive*, below, by the *lateral column* and, winding backward over both, are the anterior external arcuate fibers.

The **olive** (*oliva*) is an elongated eminence, a half inch in length, situated just below the pons (Fig. 85). It is produced by the inferior olivary nucleus in the lateral area of the medulla; and, superficially, is composed of fibers continuous with the fasciculus proprius of the lateral column in the spinal cord (Fig. 93).

Lateral Column. (*Funiculus lateralis*, Fig. 85).—It is made up of three great bundles of fibers (Figs. 93, 94 and 95): The *lateral fasciculus proprius*, which, splitting into a superficial and a deep lamina, incloses the inferior olivary nucleus; the *anterior descending cerebello-spinal tract*, running down the anterior lateral sulcus; and the *anterior ascending cerebello-spinal* and *spino-*

thalamic tract, which runs up the posterior lateral groove. At the junction of the medulla with the spinal cord the cerebello-spinal fasciculus (direct cerebellar tract) passes from the lateral to the posterior surface. The anterior external arcuate fibers, running from the anterior surface backward to the restiform body, may be so numerous as to conceal the lateral column and lower part of the olive.

The **posterior surface** (*facies posterior*) of the medulla comprises all the surface inclosed between the diverging posterior lateral sulci (Fig. 86). It embraces the surfaces of the two posterior areas of the medulla.

Inferiorly, it is divided into lateral halves by the posterior median fissure, and presents four bundles of fibers in each half (Figs. 91, 94 and 96). From the fissure outward they are as follows: The *junculus gracilis*, *junculus cuneatus*, *tractus spinalis n. trigemini*, and the *cerebello-spinal fasciculus*. The funiculus gracilis (Fig. 96) is a continuation of the medial tract of the posterior column of the spinal cord, and the funiculus cuneatus is in direct continuity with the lateral tract in the same column of the cord. These two bundles leave the surface and end in the nuclei of these columns in the medulla. The spinal tract of the trigeminal nerve is here situated on the surface; its fibers end in the under-lying gelatinous substance. The fasciculus cerebello-spinalis (direct cerebellar tract) is continued up from the lateral column of the spinal cord. Remaining on the surface it runs up to the cerebellum through the restiform body.

Superiorly, the posterior surface, on either side, is formed by a large rounded band of fibers, the restiform body (Figs. 91 and 96). The **restiform body** (*corpus restiforme*) is continued upward to the pons and then bends backward into the corpus medullare of the cerebellum in connection with which it has already been studied. Of the superficial fibers in the medulla, the cerebello-spinal fasciculus, and the anterior and posterior external arcuate fibers are continued into the restiform body; and, as we have already learned, the restiform body contains, in addition to the above three tracts, the tract from the lateral nucleus and the cerebello-olivary tract. A single layer of flattened epithelial cells

stretches between the two restiform bodies, and roofs over the inferior part of the fourth ventricle. That is the *roof epithelium*. It is continuous with the surface layer of the ependyma lining the fourth ventricle. By it the posterior surface is completed.

The **roof epithelium** (Figs. 90 and 91), seen in the mid-dorsal surface of the medulla, is of triangular shape; its base is attached to the inferior medullary velum of the cerebellum; its apex, which is directed downward, terminates at the obex and covers the

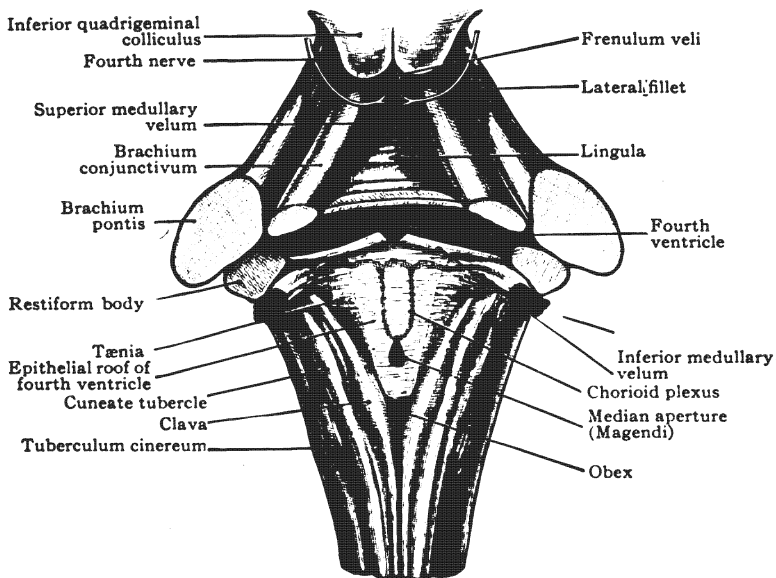


Fig. 91.—Roof and lateral walls of fourth ventricle, and its chorioid plexuses.
(After *Morris's Anatomy*.)

inferior angle of the fourth ventricle; and, laterally, it is attached to the clava, the cuneate funiculus and the restiform body. The line of attachment to the restiform body runs, first, obliquely upward and outward; and then, transversely outward, inferior to the *lateral recess*. The borders of the epithelial lamina become thickened by the addition of neuroglia, and are in continuity with the ependyma of the ventricle. The thickened apex of the epithelial lamina is called the *obex*. With the pia mater investing

it, termed the chorioid tela of the fourth ventricle, this roof epithelium is perforated in the median line near the obex by a foramen, the *median aperture* (*apertura mediana ventriculi quarti*, Magendi) and over each lateral recess by the *lateral aperture* (*apertura lateralis ventriculi quarti*, Key and Retzii). These foramina establish communication between the subarachnoid space and the ventricle. On either side of the median line there is a longitudinal invagination of the epithelial lamina into the ventricle and a similar transverse one just below the inferior medullary velum, both of which are occupied by a vascular fold of pia mater. This fold constitutes the *chorioid plexus of the fourth ventricle* (*plexus chorioideus ventriculi quarti*). If the roof epithelium be torn away, as it usually is with the pia, a rough line of separation is seen winding over the restiform body. That line is the *tania of the fourth ventricle*. Two layers of endyma form it.

When the roof epithelium is thus removed, the lower triangle of the **floor of the fourth ventricle** is brought into view (Figs. 86 and 96). Notice the median longitudinal furrow bounded by the *eminentiæ mediales*, which form the calamus scriptorius; then the little fossa in the *sulcus limitans*, called the *fovea inferior*, situated lateral to the middle of the pen, and the *ala cinerea* (*trigonum vagi*), whose superior angle is formed by the fovea inferior; and, last, the large lateral area, located above the ala cinerea external to the eminentia medialis, and crossed by the nearly transverse *medullary striæ*. This region is called the *area acustica*.

WHITE MATTER OF MEDULLA.

The medulla is made up of white and gray matter, which together bound ventrally and laterally the inferior part of the fourth ventricle, and surround the upper extremity of the sixth ventricle (Figs. 92 and 95).

For the most part the white matter of the medulla is continuous with the longitudinal fibers of the pons and restiform bodies, above, and with the spinal cord, below; the bulbar roots of the eighth to the twelfth cerebral nerves, and many decussating or

commissural fibers of the reticular substance are also included in the white substance.

Substantia Reticularis.—Superficially, the white matter is collected into great bundles of fibers, such as the pyramids, lateral column and restiform body; but, in the deep parts of the medulla, the white matter enters into a great network called the substantia reticularis, which has gray matter in its meshes (Figs. 92 and 94). It is continuous, above, with the reticular formation of the pons, and, below, with the fasciculi proprii of the spinal cord. The substantia reticularis contains many scattered fibers, processes of its intrinsic neurones, which form a frequently interrupted and, for the most part, a crossed ascending and descending tract. Transverse and oblique fibers are, likewise, numerous in the reticular substance. They are chiefly the *arcuate fibers*. The distinct tracts of longitudinal fibers contained in it will be noticed later (page 293). The gray substance of the substantia reticularis is composed of the *nucleus lateralis inferior*, the *eighth to the twelfth cerebral nerve nuclei* and the *olivary nuclei*.

Raphe (Figs. 92 and 94).—The raphe is, primarily, a sagittal lamina of neuroglia derived from the floor-plate of the myelencephalon. It lies in the median plane and joins the lateral halves of the medulla together. It is very distinct in the superior part of the medulla. Below the level of the olive, it is entirely obliterated by the fillet and pyramidal decussations. The raphe is pierced transversely by decussating and commissural fibers and is traversed dorso-ventralward by the anterior external arcuate fibers.

The **white matter of the medulla** is divided by the direction of its fibers into three classes or systems: (1) Transverse fibers; (2) dorso-ventral fibers; and (3) longitudinal fibers.

(1) The **transverse fibers** of the medulla are really more or less oblique in direction and most of them are arched. They include the fibers of the following: (a) The pyramidal decussation (*decussatio pyramidum*), (b) the medial fillet in the *decussatio lemniscorum*, (c) the anterior external arcuate fibers on the surface and, also, in the *decussatio lemniscorum*, and (d) the cerebello-olivary fibers. The *pyramidal decussation* (Fig. 95) is lo-

cated in the lower half of the medulla. About four-fifths of the pyramid crosses over through it, and becomes the lateral pyramidal tract of the spinal cord. The lower level of the pyramidal decussation marks the boundary between medulla and cord. The *medial fillet*, the *anterior* and the *posterior external arcuate fibers* all rise in the nucleus funiculi gracilis and nucleus funiculi cuneati. The two former run forward and cross over in the middle of the medulla, forming the *fillet decussation* (*decussatio lemniscorum*), after which they separate (Fig. 94). The medial fillet bends upward and ascends between the inferior olives, hence its name in the medulla, *stratum interolivare lemnisci*. The anterior external arcuate fibers, continuing their ventral direction, issue from the anterior median fissure and anterior surface of the medulla (Fig. 93), then arch backward around the medulla to the restiform body, through which they enter the cerebellum. The posterior external arcuate fibers run through the restiform body to the cerebellum without decussating. The external arcuate fibers, like the medial fillet, conduct impulses of the tactile and muscular senses. The *cerebello-olivary tract* is a large one (Fig. 92). It comprises most of the internal arcuate fibers of the medulla. Its origin is in the cerebellar cortex, and perhaps in the cerebellar ganglia; it terminates in the opposite inferior olivary nucleus. This tract probably belongs to the indirect motor path, though Cunningham believes it to be ascending in direction.

(2) The **dorso-ventral fibers** of the medulla are found in five situations: (a) In the median raphe, (b) in either half of the medulla between the anterior and lateral areas, running in a linear series of ten or twelve fascicles toward the anterior lateral sulcus, and (c) in several bundles not exactly in linear series, which run inward or outward through the posterior lateral sulcus between the lateral and posterior areas of each side.

(a) The dorso-ventral fibers of the raphe are the *anterior external arcuate fibers* (Fig. 92). These can be traced to the cortex of the cerebellum through the restiform body. Their origin is in the nuclei funiculi gracilis and funiculi cuneati (Fig. 94). Some of them seem to be interrupted in the arcuate nucleus on the anterior surface of the pyramid.

The root-bundles of the eighth to the twelfth cerebral nerves constitute the remaining groups of dorso-ventral fibers. By them the medulla is divided into areas.

(b) The *root-bundles of the hypoglossal nerve* (Fig. 93) run from the ventricular gray matter, near the median line, ventro-lateralward to the anterior lateral sulcus, where they emerge. Inclosing between them and the raphe, the *anterior area*, they also separate it from the *lateral area*. The anterior and lateral areas are bounded dorsally by the thick sheet of gray matter in the floor of the fourth ventricle.

(c) The *vestibular root* of the auditory nerve, the *roots of the glosso-pharyngeal* and *vagus* and the *cerebral root of the accessory nerve* form the third group of dorso-ventral fibers (Fig. 93).

The motor fibers of the ninth, tenth and cerebral part of the eleventh nerves take their origin in nuclei of the medulla and emerge from the posterior lateral sulcus; while the sensory fibers of the vagus, glossopharyngeal and vestibular nerves enter that sulcus from without and run through the medulla to their terminal nuclei in the ventricular gray matter. These nuclei, both genetic and terminal, are located lateral to the hypoglossal nucleus. The nerve roots rising or terminating in them separate the *lateral* from the *posterior area*. The posterior area comprises everything dorsal to the above roots of the eighth to eleventh cerebral nerves. It thus includes the gray matter in the floor of the fourth ventricle, called the *stratum nucleare*.

(3) **Longitudinal Fibers.**—In the medulla, the longitudinal fibers, are chiefly continuations of the same in the pons and the restiform bodies; they are also continuous with the tracts of the spinal cord. They can be best located by reference to the three areas bounded by the above dorso-ventral fibers, namely, *anterior*, *lateral* and *posterior areas*, which are distinctly outlined in the upper half of the medulla (Figs. 92 and 93).

Longitudinal Fibers of the Anterior Area.—The anterior area of the medulla lies between the raphe and the roots of the hypoglossal nerve, and between the anterior surface and the gray matter in the floor of the fourth ventricle (Figs. 92 and 93). It contains the pyramid, the medial fillet, the medial and anterior

longitudinal bundles, the *substantia reticularis alba* and two nuclei, the arcuate nucleus and the medial accessory olivary nucleus. Excepting that part forming the lateral pyramidal tract and the medial fillet, the anterior area is continued in the anterior column of the spinal cord. It is naturally divided into a ventral and a dorsal part, or the region of the pyramid and the region of the *substantia reticularis alba*.

The pyramid (*pyramis*) with the arcuate nucleus imbedded in it and the arcuate fibers winding over it, occupies the ventral portion of the anterior area (Figs. 92 and 94). It is the continuation of the pyramidal tract and is composed of the axones of cortical cells in the anterior central gyrus of the cerebrum. The pyramidal tract diminishes in size as it descends through the pons and medulla, because some of its fibers terminate in ramifications about the cells of cerebral nerve nuclei. In the lower part of the medulla, the pyramid breaks up into the *anterior* (direct) *pyramidal tract* (10 per cent. of the pyramid), which descends along the anterior median fissure in the same side of the spinal cord; and the *lateral* (crossed) *pyramidal tract* (80 per cent. of the pyramid), which, after decussating with its fellow through the anterior median fissure, runs down in the lateral column of the opposite side of the cord (Fig. 95). The fibers of the anterior tract cross in succession to the opposite side of the cord, through the white anterior commissure; and there, with the fibers of the lateral pyramidal tract, terminate in fibrillar end-tufts about the cell-bodies in the gray matter. Thus the pyramid forms a crossed cerebral tract for motor cerebral and spinal nerves. A small number of pyramidal fibers (10 per cent.) diverge lateralward from the pyramid in the medulla and descend in the lateral funiculus of the cord without decussation. They account for the weakness on the well side, and for slight motion on the paralyzed side, which are commonly observed in hemiplegia. If, as E. A. Schäfer claims, the fibers of the pyramidal tracts end in the posterior column of gray matter, then at least one neurone intervenes between them and the motor neurones of the spinal nerves; but without doubt, they enter into either direct or indirect relations with those neurones.

The dorsal part of the anterior area is occupied by the *substantia reticularis alba* (Figs. 92 and 93). It contains the bodies of very few nerve cells and is of a light color. The *medial accessory olivary nucleus* is imbedded in it near the pyramid and among the fibers of the fillet; and three definite bundles of longitudinal

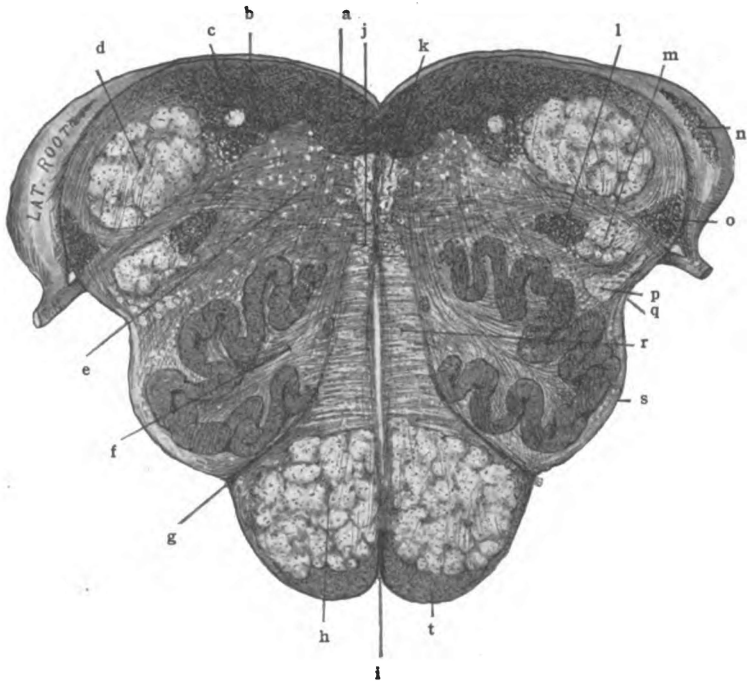


Fig. 92.—Section of medulla oblongata near the pons. (Original.)

a. Hypoglossal nucleus. b. Vestibular nucleus. c. Tractus solitarius. d. Restiform body. e. Substantia reticularis. f. Hilus of olivary nucleus containing cerebello-olivary fibers. g. Anterior lateral sulcus. h. Pyramid. i. Anterior median fissure. j. Anterior longitudinal bundle. k. Medial longitudinal bundle. l. Nuc. tractus spinalis n. trigemini. m. Tractus spinalis n. trigemini. n. Lateral cochlear nucleus. o. Ventral cochlear nucleus. p. Ascending anterior cerebello-spinal, spino-thalamic, and rubro-spinal tracts. q. Posterior lateral sulcus. r. Medial fillet, interolivary stratum. s. Anterior external arcuate fibers. t. Arcuate nucleus.

fibers have been demonstrated in it, namely, the medial fillet and the medial and anterior longitudinal bundles.

Medial Fillet (Lemniscus Medialis).—Just dorsal to the pyramid in the anterior area of the medulla at the level of the olives, is a large bundle of fibers called the interolivary stratum of the fillet

(Figs. 92 and 94). Situated between the inferior olivary nuclei, it is on that account so named. Superiorly, it is continued as the medial fillet. The medial fillet rises from the nucleus funiculi gracilis and nucleus funiculi cuneati of the medulla and crosses through the median raphe in the fillet decussation. As the fillet runs brain-ward, it receives fibers from the terminal nuclei of common sensory cerebral nerves and from the vestibular nuclei. Along its lateral border, it is accompanied for a short distance in the pons by the lateral fillet. The medial fillet is composed of ascending axones which constitute a "cerebral" tract for the sensory fibers of spinal and cerebral nerves. It carries ordinary sensations (tactile and muscular) to the superior quadrigeminal colliculus by the *superior fillet*, and to the thalamus by the greater part of the medial fillet.

The medial longitudinal bundle (fasciculus longitudinalis medialis) (Figs. 92 and 95) which we have studied in the mid-brain and pons, constitutes a very distinct strand in the superior half of the medulla; but below the level of the olive it can be identified in the anterior fasciculus proprius only by a study of its medullation or of its degeneration. It is continuous with the anterior fasciculus proprius of the spinal cord. Its location is next the median raphe and the ventricular gray substance, immediately anterior to the hypoglossal nucleus, in the upper medulla. The same position is occupied by it in the mid-brain and pons. It is here in the medulla that the hypoglossal fibers are supposed to enter it and run up to the colliculus facialis, where they join the facial nerve at the internal genu. At the middle of the medulla the decussation of the fillet pushes this bundle forward and somewhat away from the median plane, so that it runs between the fillet decussation and the medial accessory olivary nucleus. Below the level of the fillet decussation it runs between the decussatio pyramidum and the isolated head of the anterior column of gray substance. Rising primarily in the gray matter of the cord, the *ascending part* of the medial longitudinal bundle is augmented in the medulla and pons by fibers from the terminal nuclei of sensory cerebral nerves. Most of its ascending fibers cross the median line and terminate in the motor cerebral nuclei on the

opposite side; these form the middle links in many reflex arcs; a few decussate in the posterior commissure and end in the thalamus. The latter are sensory conduction fibers. The *descending*

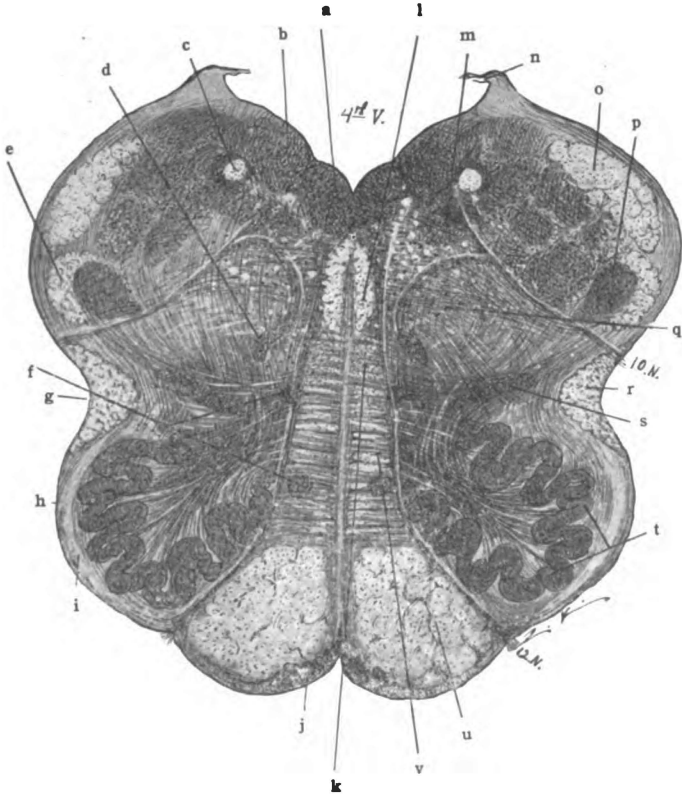


Fig. 93.—Section of the medulla oblongata at the middle of olive. (Original.)

a. Nucleus of 12th n. b. Vestibular nucleus. c. Tractus solitarius. d. Nucleus ambiguus. e. Tractus spinalis n. trigemini. f. Medial accessory olivary nuclei. g. Posterior lateral sulcus. h. Ant. external arcuate fibers. i. Fasciculus proprius. j. Arcuate nucleus. k. Anterior longitudinal bundle in substantia reticularis alba. l. Medial longitudinal bundle. m. Nucleus alae cinerea. n. Tænia of 4th ventricle. o. Restiform body. p. Gelatinous substance. q. Substantia reticularis grisea nucleus lateralis inferior. r. Ascending ant. cerebello-spinal, spino-thalamic, and rubro-spinal tracts. s. Dorsal accessory olivary nucleus. t. Inferior olivary nucleus. u. Pyramid. v. Medial fillet, interolivary stratum.

part of the medial longitudinal bundle is the medial ponto-spinal tract of Collier (see pages 280, 360 and 373).

The *anterior longitudinal bundle* (Figs. 92 and 95) descends as a distinct strand, from the opposite superior colliculus of the

corpora quadrigemina, to the lower part of the medulla; there it approaches the medial longitudinal bundle and is continued along the fissural surface of the anterior column in the cord. Its termination is in the central gray substance, chiefly the *cilio-spinal centers*. It forms the middle link in the visual reflex arc. Its bulbar and spinal portions constitute, chiefly, the *pupillo-dilator tract* (see pages 158, 276 and 355).

Longitudinal Fibers of the Lateral Area.—The contents of the lateral area (Figs. 92 and 93) are as follows: Superficially, the lateral fasciculus proprius, the anterior descending, and the anterior ascending cerebello-spinal tracts and the spino-thalamic tract. Deeply, lies the substantia reticularis grisea. Imbedded in the substantia reticularis are the nucleus ambiguus, the nucleus lateralis inferior and the accessory olivary nuclei, and in the fasciculus proprius is the main inferior olivary nucleus. The gray matter of the substantia reticularis grisea is a part of the disintegrated anterior column of the cord and, unlike that of the anterior area, it contains the bodies of many large nerve cells.

Lateral Fasciculus Proprius (Fasciculus Lateralis Proprius, Figs. 93 and 94).—The whole lateral column of the spinal cord, except the lateral pyramidal and cerebello-spinal tracts, is continued into the lateral area of the medulla. Composed of ascending and descending axones which are commissural and associative for different segments of the spinal cord, the lateral fasciculus proprius ascends into the lateral area of the medulla, and runs in part beneath and in part superficial to the inferior olivary nucleus; beyond the olive, it is continued in the substantia reticularis grisea of the medulla and reticular formation of pons and mid-brain. Among the fibers of the lateral fasciculus proprius, ventral to the olive, is the *triangular tract* of Helwig and, dorsal to the olive, the *olivary bundle*. The former is believed to rise in the olive of the medulla and the latter to end in it. They are made up of descending axones and, according to Bechterew, form a functionally continuous tract.

The **anterior descending cerebello-spinal tract** (*fasciculus descendens cerebello-spinalis anterior*) rises in the cerebellar ganglia

and cortex. Between the cerebellum and the medulla it comprises the acustico-cerebellar tract and, possibly, the cerebello-olivary tract; and, therefore, is almost completely relayed in the vestibular nuclei, the nuclei of the reticular formation, and, possibly, in the inferior olivary nucleus (Figs. 94 and 95). It forms part of the brachium pontis and restiform body through which it reaches the medulla. In the lateral area, it descends along the anterior lateral sulcus, to the corresponding area of the cord. It ends (?) in the anterior column of gray matter. It was once regarded as a part of the anterior pyramidal tract. The anterior descending cerebello-spinal tract forms a segment of the indirect motor path, and the motor arm of the reflex arc of coordination and equilibrium.

Anterior Ascending Cerebello-spinal and Spino-thalamic Tract. (*Fasciculus ascendens cerebello-spinalis anterior*) (Figs. 92 and 95).—These two tracts are combined into one throughout the cord, medulla and pons. Near the isthmus the former turns backward through the superior medullary velum and ends in the cortex of the superior vermis cerebelli; while the spino-thalamic tract continues in the original direction, to the lateral nucleus of the thalamus. The common spino-encephalic tract made up of these two bundles takes its origin from the base of the anterior column and center of the crescent of gray matter, chiefly on the opposite side of the spinal cord; and, crossing through the white anterior commissure, it ascends, mingled somewhat with the fibers of the above descending cerebello-spinal tract, along the lateral surface of the cord (Barker). It runs beneath the posterior lateral groove of the medulla and through the formatio reticularis of the pons, to the point of division near the isthmus rhombencephali, whence the two divisions proceed to their cerebellar and thalamic terminations, as above stated. The tract is probably reinforced in the medulla and pons by the addition of axones from the opposite terminal nuclei of common sensory cerebral nerves; and, rising primarily in relation with the posterior roots of spinal nerves, it thus forms a crossed path for common sensations, spinal and cerebral. It conducts tactile, pain and temperature impulses (see pages 161 and 356).

The **rubro-spinal tract** is the *crossed descending tract of the red nucleus* (Figs. 92 and 95). Running dorsal to the inferior olive in the medulla it mingles with the fibers of the anterior ascending cerebello-spinal tract. It is continued down the cord, in the lateral column, to the lateral column and center of the gray crescent as far as the first lumbar segment (see pages 162, 276 and 358).

Longitudinal Fibers of the Posterior Area.—The longitudinal fibers of the posterior area form many bundles; and the bundles are different in upper and lower medulla. The substantia reticularis is small. The ventricular gray substance belongs to this area.

The **lower medulla** contains: The funiculus gracilis, funiculus cuneatus, tractus spinalis nervi trigemini and cerebello-spinal tract, named from the posterior median fissure outward (Figs. 94 and 96). In the **upper medulla** are: The restiform body and the spinal tract of the fifth cerebral nerve at the surface; and the tractus solitarius in the interior (Figs. 92, 93 and 96).

The **funiculus gracilis** is the superior end of the ascending postero-medial column (Goll's column) of the spinal cord. Near its extremity it expands and forms the *clava*, and then tapers off and disappears along the side of the fourth ventricle. The clava is due to the nucleus funiculi gracilis, in which the fibers of the column end. The funiculus gracilis is composed of ascending branches of the posterior roots of the spinal nerves, which enter the cord below the seventh or eighth thoracic segment.

Funiculus Cuneatus (Figs. 94 and 96).—It is separated from the posterior median fissure by the gracile bundle; and is the continuation of the ascending postero-lateral column (Burdach's column) of the spinal cord. It ends about the cells of the nucleus funiculi cuneati and accessory nucleus funiculi cuneati, which form the cuneate tubercle seen on the surface. The fibers of the funiculus cuneatus are ascending branches of the posterior roots of the spinal nerves. The nerves contributing to this column are the cervical and the six or eight upper thoracic. The funiculi gracilis and cuneatus carry to the nuclei of these columns common sensations belonging to the tactile and muscular senses. Interference with these tracts produces ataxia.

Spinal Tract of the Trigeminal Nerve. (*Tractus spinalis nervi trigemini*, Figs. 92 and 96).—It forms a narrow strip of the posterior surface of the medulla, which is broadest near the restiform body and tapers downward toward the spinal cord. It is composed of the descending fibers from the sensory root of the trigeminal nerve: the sensory fibers of this nerve on entering the pons divide T-like, into an ascending and a descending branch, and the descending branches form the spinal tract of the nerve, which for a short distance is visible on the surface of the medulla. This tract is continued through two segments in the spinal cord. The nucleus of the spinal tract of the trigeminal nerve, over which it runs and in which it terminates, is but the continuation of the gelatinous substance of the posterior column of gray matter in the cord; in the upper medulla it is situated ventro-medial to the restiform body. The nucleus produces a slight eminence below the level of the clava, called the tuberculum cinereum.

The **cerebello-spinal tract** (*fasciculus cerebello-spinalis*, Figs. 94 and 96) in the lower medulla crosses the posterior lateral groove and the spinal tract of the fifth nerve, going from the lateral column of the cord to the posterior area of the medulla; it then ascends to form a considerable part of the restiform body. It takes its origin from the nucleus dorsalis (Clarki) in the spinal cord. It ends, very largely on the opposite side, in the cortex of the superior cerebellar worm. The cerebello-spinal tract (direct cerebellar tract) probably conducts common sensory impulses received from viscera. They should be classed largely under the muscular sense, as they seem to concern equilibrium and orientation. They are sympathetic sensory.

Restiform Body. (*Corpus restiforme*).—In the upper medulla, forming the lateral part of each posterior area, is a large rounded bundle of fibers, called the restiform body (Figs. 92, 93 and 96). It is the largest bundle in the medulla, and joins it to the cerebellum. It is made up of the following: Ascending tracts—(1) the cerebello-spinal tract; (2) the external arcuate fibers, anterior and posterior; and (3) the tract from the lateral nucleus of the medulla to the cortex of the cerebellum. Descending tracts—(4) the cerebello-olivary fibers; and (5) a few axones of Purkin-

je's cells which enter into the descending cerebellar tract (?) (see cerebellum, page 264).

The restiform body is inclosed between the *vestibular* and *cochlear roots* of the auditory nerve (eighth) (Fig. 89). Ventral to it and between the roots, is the *ventral part* of the **cochlear nucleus**; on its lateral surface and among the fibers of the lateral root, is the dorsal, or *lateral part* of the same nucleus. The **vestibular nuclei**—the *chief dorso-medial nucleus* (Schwalbe), the *dorsolateral* (Deiters), the *superior* (Flechsig and Bechterew) and the *nucleus of the descending root* are situated dorsal and medial to the restiform body.

Tractus Solitarius (Figs. 92 and 94).—The solitary tract is a small, round bundle imbedded in the middle of the ventricular gray matter of the posterior area. In Weigert-Pal sections of the upper medulla it is clearly visible to the naked eye. It is formed by the sensory roots of the nervus intermedius and the ninth and tenth cerebral nerves. It descends through the *nucleus tractus solitarii* lateral to the nucleus of the ala cinerea, and along the medial aspect of the posterior column of gray matter in the cord. It ends on both sides of the median line in gelatinous gray matter, called the nucleus of the solitary tract, which surrounds it. The nuclei of these tracts converge downward; according to Cajal, they are united near their inferior extremities by a central mass, called the nucleus commissuralis (Barker). The solitary tract may be traced from the upper part of the medulla down to the spinal cord (Kölliker). It is believed to associate the nuclei of the nerves controlling respiration, hence the synonym, respiratory bundle.

GRAY MATTER OF MEDULLA.

The gray matter of the medulla is composed (1) of that continuous with the nucleus pontis, called the *arcuate nucleus*; (2) of the ventricular gray substance, the *stratum nucleare*, and that of the *substantia reticularis*, also continued downward from the pons; and (3) of the *special nuclei* of the medulla, which are not represented in the pons or in the spinal cord.

(1) **Nucleus of the External Arcuate Fibers** (Figs. 92 and

93).—This is the *nucleus arcuatus*. It forms a large crescentic mass on the ventral and medial surface of the pyramid. Running over and through it there are the anterior external arcuate fibers, for certain of which it constitutes a relay. The arcuate nucleus is continuous above with the nucleus pontis. It is brought to the surface at the lower border of the pons by the disappearance of most of the transverse fibers.

(2) The **gray substance in the substantia reticularis and in the immediate floor of the fourth ventricle** (Figs. 92 and 93) is continuous with the same in the pons and mid-brain, above; and is represented in the spinal cord by the H-shaped column of gray matter. By the posterior and lateral expansion of the neural canal, in the upper half of the medulla and in the pons, which forms the fourth ventricle, the posterior columnæ of the H-shaped column of gray matter are pushed outward to a transverse direction; and the entire bases of the anterior columnæ are brought into the floor of the ventricle. The expansion of the canal, together with the decussation of the lateral pyramidal tracts through the anterior columnæ and of the medial fillets through the posterior and anterior columnæ, disposes the H-shaped column as follows:

Anterior Columna.—From the base of the anterior columna is derived a column of cells, the *hypoglossal nucleus* (Figs. 92 and 93), which is two-thirds of an inch in length and extends along the median raphe in the upper medulla, beneath the eminentia medialis. It is continued into the lower medulla as far as the pyramidal decussation. By commissural fibers it is joined to the nucleus of the opposite side according to Kölliker. The nucleus gives origin to the hypoglossal nerve proper; and probably to a small fasciculus which by way of the medial longitudinal bundle joins the facial nerve and supplies the orbicularis oris. The hypoglossal axones run in linear series forward through the medulla to the anterior lateral sulcus, whence they emerge between the pyramid and the olive (Fig. 85). They separate the anterior from the lateral area. The main body of the anterior columna is broken up into the *nucleus lateralis inferior*, the *nucleus ambiguus* and the *motor part of the nucleus of the ala cinerea*.

The *nucleus lateralis inferior* (Figs. 92 and 94) is situated in the reticular substance of the lateral area. Though it is made up of large cell-bodies, they are so scattered among the fibers of this region that the nucleus is invisible to the naked eye. It probably gives origin to descending fibers which are continued both in the anterior and lateral column of the spinal cord (Tschermak). It is known to receive fibers from the anterior ascending cerebello-spinal tract and from the nuclei funiculi gracilis and funiculi cuneati, and it gives rise to the ascending tract already traced to the cerebellum, which probably transmits tactile, muscular, pain and temperature impressions to the cerebellar cortex.

The *nucleus ambiguus* (Fig. 93) forms an irregular sheet of gray substance, pear-shaped in section, which extends longitudinally through two-thirds of the medulla. It is prolonged from near the ventricle ventro-lateralward into the substantia reticularis. It is not visible to the naked eye. Its axones form the cerebral root of the eleventh nerve and probably a part of the motor roots of the tenth and ninth nerves. The root fibers of the accessory nerve run out through the posterior lateral sulcus below the level of the olive.

The *nucleus of the ala cinerea* (Fig. 93) is in part derived from the base of the anterior columna; this part is motor in function and its neurones resemble those of the anterior columna in the cord. It belongs to the ninth and tenth nerves. It is situated, above, close to the floor-ependyma of the fourth ventricle under the ala cinerea; and it extends, inferiorly, into the closed medulla nearly as far as the hypoglossal nucleus. It is immediately lateral to the nucleus of the hypoglossal. Its axones run in a curve, convex toward the median plane, between the restiform body and the olive. They are joined medially by those axones of the nucleus ambiguus which enter the roots of the ninth and tenth nerves. By this nucleus and the nucleus ambiguus, many distinct fascicles are formed, belonging to the roots of the ninth, tenth and the cerebral part of the eleventh nerves. They run in slightly different planes, but all of them emerge in the region of the posterior lateral sulcus of the medulla (Fig. 85). Intermingled with the motor cells of the nucleus alæ cinereæ, there are the small spindle

cells of the terminal nucleus of the vagus nerve, which represent neurones of the posterior column of gray matter. They receive the end-tufts of the sensory root fibers of the vagus nerve and possibly of a small number from the glossopharyngeal nerve.

The hypoglossal nucleus, the motor part of the nucleus of the *ala cinerea* and the nucleus ambiguus receive many fibers from the opposite pyramidal tract, and probably from the cerebro-pontal tracts, which bring to them voluntary motor and inhibitory im-

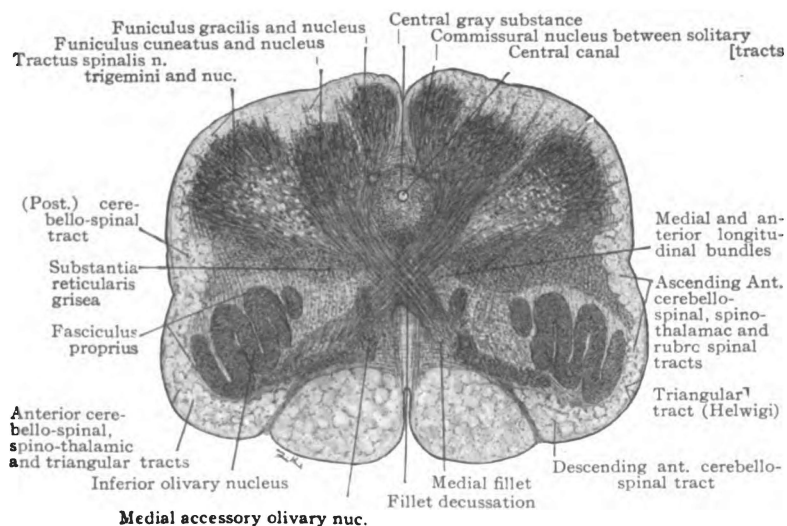


Fig. 94.—Section of the medulla oblongata at the fillet decussation. (*Original.*)

pulses from the *cerebral cortex*; and their *reflex connection* is established by fibers of the medial longitudinal bundle which rise in sensory nuclei.

The *posterior column* is decapitated by the fillet. It is represented in the medulla (1) by the following terminal nuclei, viz., the sensory part of the nucleus *alæ cineræ* of the vagus and glossopharyngeal nerves, the vestibular and cochlear nuclei of the auditory nerve, the nucleus tractus solitarii and the nucleus of the spinal tract of the trigeminal nerve; and (2) by the gray matter of the reticular substance of the posterior area.

The *nucleus alæ cinereæ of the vagus and glossopharyngeal nerves* (Fig. 93) contains in its lateral part a group of small fusiform cell-bodies like those in the posterior column. These fusiform cells constitute the terminal nucleus of the sensory fibers of the vagus, and it is probable that a few glossopharyngeal fibers also arborize and end in the nucleus. *Cortical Connection.*—Axones of this nucleus probably enter into the medial fillet, the spino-thalamic tract and the medial longitudinal bundle. The two former conduct tactile, muscular, pain and temperature impulses to the thalamus, whence the cortical fillet carries them to the cortex; the latter establishes its *reflex connection* with motor nerves.

Nucleus Tractus Solitarii (Figs. 92 and 94).—The nucleus of the solitary tract surrounds the tractus solitarius with which it coincides in extent. It is gelatinous in appearance and is situated just lateral to the nucleus of the ala cinerea. In its descent it trends dorsally and toward the median line. It is joined to the opposite nucleus, at its spinal end, by the *nucleus commissuralis* (Cajal). The nucleus of the solitary tract is the terminal nucleus of the afferent fibers of the intermediate and glossopharyngeal nerves and, probably, receives a few fibers from the vagus. It is thus the nucleus of the nerves of taste and forms the first relay station in the gustatory path. The axones of the cell-bodies in the nucleus tractus solitarii establish reflex connections with efferent nuclei and continue the taste path toward the thalamus, but their exact course has not been worked out.

Nucleus Tractus Spinalis Nervi Trigemini (Figs. 92 and 95).—The nucleus of the spinal tract of the trigeminal nerve is gelatinous in character. It is continuous with the sensory pontine nucleus of the trigeminal nerve, above; and, below, is continued in the gelatinous substance of the posterior column of the spinal cord. As low down as the second cervical segment it receives fibers from the trigeminal nerve, so the terminal nucleus of this nerve extends from the middle of the pons to the second cervical nerve. The nucleus of the trigeminal is embraced between the emergent part of the facial nerve, medially, and the vestibular nerve, laterally, in the lower portion of the pons; in the upper medulla, the

nucleus lies along the ventro-medial surface of the restiform body; it enlarges in bulk and approaches the surface near the middle of the medulla, where it produces the tuberculum cinereum; and it is then continued down into the cord as a cap of the posterior column of gray substance. In the lower part of the medulla the nucleus underlies the visible part of the tractus spinalis nervi trigemini.

The *sensory root* of the trigeminal nerve (fifth) enters the pons on its ventral surface, in line with the roots of the seventh, eighth, ninth, tenth and accessory nerves (Fig. 85). The root fibers divide T-like; the short ascending branches end in the pontine nucleus of the fifth nerve and the long descending branches, forming the spinal tract, terminate in the nucleus of that tract. A certain few of these root-fibers go directly to the motor nucleus of the trigeminal nerve and perhaps to other motor nuclei; these are reflex in function.

From the trigeminal nucleus axones establishing *reflex* and *cortical relations* run: (a) To motor nuclei by way of the medial longitudinal bundle and directly without entering that bundle, forming the middle link of reflex arcs, and (b) by way of two paths they run toward the cerebral cortex as far as the thalamus. The latter cross the median raphe and probably enter the medial fillet and the spino-thalamic tract. The axones bearing impulses of the muscular sense enter the medial fillet and are continued through it to the lateral nucleus of the thalamus; those fibers which conduct pain and temperature impressions run through the spino-thalamic tract to the same nucleus. Both sets of fibers conduct tactile impulses. From the thalamus the cortical fillet completes the path to the somæsthetic cortex of the cerebrum.

Vestibular Nuclei (*Nn. Nervi Vestibularis*, Figs. 92 and 93).—These are located partly in the pons as already pointed out, and extend as low as the mid-medulla. Their function is equilibrium. The *principal nucleus* (Schwalbe's) is dorso-medial in position and lies beneath the acoustic area of the ventricular floor, crossed by the medullary striæ. It extends transversely from near the eminentia medialis almost to the restiform body. It appears to receive nearly all the fibers of the vestibular nerve, which arbor-

ize and terminate about its cells. Lateral to the principal nucleus are the *nucleus of Deiters* and the *nucleus of the descending root*. Deiters's nucleus is spread along the medial surface of the restiform body, chiefly in the pons. It becomes a distinct nucleus as the lower border of the pons is approached and grows larger for some distance above that point. In the pons it is bent backward with the restiform body toward the cerebellum. Its upper end is thus placed in the lateral wall of the fourth ventricle between the restiform body and the brachium conjunctivum. This portion is called the *superior nucleus* (of Bechterew or Flechsig). Deiters's nucleus is made up of cell-bodies which are large in comparison with those of the principal nucleus. It receives the descending fibers of the acustico-cerebellar tract from cerebellar ganglia and cortex and originates axones that proceed down the cord in the anterior descending cerebello-spinal tract, thus forming a relay in the cerebello-spinal path; and this is its chief function. It is only a subordinate terminal nucleus of the vestibular nerve. The nucleus of the descending root is, in all probability, a relay station in the conduction path from the vestibular nerve, but not a terminal nucleus of that nerve. It is composed of cell-bodies scattered through a strand of fibers, called the descending root, which extends from the level of the principal nucleus down to the nucleus funiculi cuneati (Bruce). It is placed somewhat under cover of the medial border of the restiform body and, with the enveloping descending root, separates this body from the principal nucleus. Certain fibers of the descending root terminate in the nucleus of the same name.

Cortical Connections.—Axones of the terminal nuclei of the vestibular nerve enter the opposite medial fillet and, by way of the descending root, also the nucleus funiculi cuneati. The medial fillet continues the direct path to the thalamus and the cortical fillet completes it up to the *temporal cortex*. The descending root and the arcuate fibers from the nucleus funiculi cuneati constitute the connecting link between the vestibular nuclei and the cortex of the cerebellum. The *reflex connections* of the vestibular nerve are established, *first*, with cerebral nerves, by fibers which join the medial longitudinal bundle and terminate

in the nuclei of motor nerves; *second*, with spinal nerves by the axones of Purkinje's cells to the nucleus fastigii and nucleus globosus; from the cerebellar ganglia by the acustico-cerebellar tract to the nucleus of Deiters, and then by way of the anterior descending cerebello-spinal tract to the motor nuclei of the spinal nerves in the anterior columna.

Cochlear Nuclei (Nn. Nervi Cochlearis, Fig. 92).—There are two cochlear nuclei, the *ventral* and the *lateral*. They concern hearing proper. The *ventral cochlear nucleus* appears in section as a triangular mass of cell-bodies imbedded in the medulla at the upper end of the posterior lateral sulcus. It lies between the restiform body and the olive; the vestibular root of the auditory nerve separates it from the olive. It receives the greater number of fibers in the cochlear nerve and gives rise to those of the *trapezoid body* and, through that, to a large part of the lateral fillet of the opposite side; a few of its fibers enter the fillet of the same side. In the corpus trapezoidicum, the cochlear tract is largely relayed by the neurones forming the nuclei of the superior olivary group. The *lateral cochlear nucleus* embraces the outer surface of the restiform body. It is situated both lateral and dorsal to the ventral nucleus and, stretching around the posterior surface of the restiform body, it produces the ventricular eminence in the lateral part of the acustic area, called the *tuberculum acusticum*. The lateral nucleus receives that part of the cochlear root which does not end in the ventral nucleus, and the fibers arborize about its cells. The axones of the lateral nucleus form the medullary striæ; a few of them enter the trapezoid body (Figs. 86, 89 and 92). The medullary striæ run somewhat obliquely across the ventricular floor to the median groove, plunge forward to the superior olivary nuclei of the opposite side where they are partially relayed and then, bending upward, are continued in the lateral fillet. At the superior olivary nuclei of the opposite side the fibers from the lateral and ventral nuclei become intermingled, hence the trapezoid body and medullary striæ combine in the formation of the *lateral fillet*. The lateral fillet suffers a partial relay in its own nucleus, after which it separates into two parts; the principal part runs to the internal geniculate body, by way of the

brachium inferius; the smaller part ends in the quadrigeminal colliculi, chiefly in the inferior colliculus on the same side. From the medial geniculate body to the transverse and superior temporal gyri, the acoustic path is formed by the *temporo-thalamic (acoustic) radiation*. This completes the *cortical connection* of the cochlear nuclei. Their *reflex connections* are established, *first*, by the olivary pedicle and medial longitudinal bundle and, *second*, by that part of the lateral fillet which ends in the colliculi of the corpora quadrigemina (see pages 160 and 161).

(3) **There are Certain Special Nuclei of the Medulla.**—These are not represented either in the pons, above, or the spinal cord, below. They are the nucleus funiculi gracilis, the nucleus funiculi cuneati and the nucleus olivaris inferior.

Nucleus Funiculi Gracilis and Nucleus Funiculi Cuneati (Figs. 94 and 95).—The nucleus funiculi gracilis and nucleus funiculi cuneati are large nuclei, extending from the level of the olive to the lower end of the medulla. They are situated near the posterior surface beneath the gracile and cuneate funiculi, whose fibers terminate in them; they give origin to the medial fillet, and the anterior and posterior external arcuate fibers, and they produce, respectively, the *clava* and *cuneate tubercle* on the posterior surface of the medulla. In successive sections from below upward, the **nucleus funiculi gracilis** is first seen as an isolated mass of gray substance imbedded in the funiculus gracilis at the level of the pyramidal decussation. It enlarges dorso-ventrally and transversely toward its upper end, as is shown in consecutive sections, and reaches its greatest size at the clava, where it receives the terminal end-tufts of the funiculus gracilis. At the level of the clava the ventral border of the nucleus funiculi gracilis fuses with the gray matter about the central canal. The axones of this nucleus form about one-half of the medial fillet and the external arcuate fibers. The **nucleus funiculi cuneati** (Fig. 95) appears at the same inferior level as the nucleus funiculi gracilis. It is from the first and throughout its length continuous with the central gray substance on which it appears as a bud-like outgrowth in the lower medulla. It gradually broadens and elongates dorsalward when traced upward (Fig. 94). Beneath the *cuneate tubercle*



it reaches its full stature and gathers into itself the fibers of the funiculus cuneatus and the descending root of the vestibular nerve; thence it sends its own axones upward in the medial fillet and the external arcuate fibers. Near the lower end of the medulla there is a small lateral bud of gray matter connected with the nucleus funiculi cuneati, to which it is accessory and, like it, is imbedded in the funiculus cuneatus. It occupies the position of the dorsal nucleus (Clarki) in the spinal cord, and is called the *accessory nucleus funiculi cuneati*.

The nuclei funiculi gracilis et cuneati form the first relay station in the *spino-cerebral path* for impressions of the muscular and

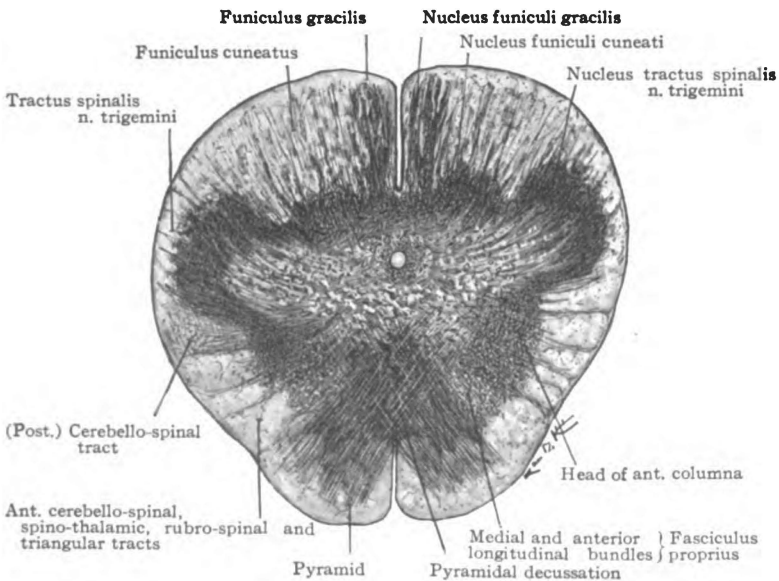


Fig. 95.—Section of the medulla oblongata at the pyramidal decussation. (Original.)

tactile senses, and lesions in them cause ataxia. They also lie at the dividing of the ways; the direct path continuing through the fillet decussation and the medial fillet to the thalamus, and the indirect path running through the arcuate fibers to the cerebellar cortex. From the cerebellar cortex the impulses proceed cerebralward through Purkinje's neurones to the dentate nucleus

and, thence, through the dentate neurones by way of the brachium conjunctivum cerebelli to the opposite red nucleus and thalamus. The cortical fillet conducts all common sensory impulses from the thalamus to the cerebral cortex.

The *nucleus olivaris inferior*, the olivary nucleus of the medulla (Figs. 92 and 94), is a sinuous, pouch-like collection of gray matter resembling the nucleus dentatus of the cerebellum. It is situated near the lateral surface of the medulla and is invested superficially and deeply by fibers from the lateral fasciculus proprius. Its open *hilus* looks medially and is filled with fibers, the *cerebello-olivary fibers*, which join it to the opposite hemisphere of the cerebellum. On either side of the olivary nucleus is an accessory nucleus—the *medial accessory*, in the anterior area among the fibers of the interolivary part of the medial fillet, and the *dorsal accessory* in the lateral area. The olivary nucleus, covered by fibers of the lateral fasciculus proprius, forms the olive (*oliva*). The olive shows the longitudinal extent of the nucleus and on section it is seen to measure a quarter of an inch in depth. The olivary nucleus is said to be a modern structure; it is found well developed only in the higher mammals and does not appear in the human brain until the sixth month. It probably contains both ascending and descending neurones. Axones enter it from the nucleus funiculi gracilis and nucleus funiculi cuneati and probably some of the cerebello-olivary fibers are ascending in direction. It receives two groups of descending fibers, viz.: (a) The descending cerebello-olivary fibers pass down from the cortex of the cerebellum through the restiform body to the medulla, decussate and, entering the hilus of the opposite nucleus, arborize and end about its cell-bodies; and (b) the olivary fasciculus (central tract of the tegmentum), having descended from the lentiform nucleus through the mid-brain and pons, fades away just dorsal to the olive and probably ends in it. Axones of the olivary nuclei of the medulla have been traced by Kölliker and others down the lateral column of the spinal cord. The *triangular tract* of Helwig is probably composed of such fibers. It descends along the surface of the cord lateral to the anterior roots of the spinal nerves and ends in the gray matter of the cord.

Lesions in the medulla are very fatal and death usually occurs before any sensory or motor phenomena can be observed; but rarely the pyramidal tracts alone have been involved or the pyramidal tracts together with one or more of the roots of the ninth to the twelfth cerebral nerves. In the last case, crossed paralysis is produced, as in the pons, affecting the cerebral nerves on the same side and the opposite spinal nerves. In progressive bulbar paralysis the motor nuclei of the medulla are involved as a preliminary to the degeneration of the anterior gray column in the spinal cord.

RHOMBENCEPHALON.

SECTION IV. THE FOURTH VENTRICLE.

The common cavity of the rhombencephalon is the fourth ventricle (*ventriculus quartus*) (Fig. 118). The fourth ventricle is contained chiefly in the pons and medulla, and is ventral to the cerebellum (Fig. 79). It is broadest at the junction of the pons and medulla (Figs. 86 and 91). Above and below that junction, it gradually contracts to the size of the cerebral aqueduct and central canal of the spinal cord, with which it is continuous. Inferiorly it communicates through its roof with the subarachnoid space via three apertures, a median and two lateral. The fourth ventricle is a *gable-roofed* chamber with a *diamond-shaped floor*. The gables (Fig. 79) are directed lateralward and are prolonged in tunnel-like extensions around the restiform body. The long axis of the ventricular floor (Figs. 86 and 96) is parallel with the spinal cord, and extends from the superior extremity of the pons to the middle of the medulla. The transverse axis coincides with the junction of the pons and medulla. Thus the superior triangle of the floor is formed by the pons; the inferior, by the medulla oblongata. The fourth ventricle is lined with ependyma, which is complete throughout, except in the roof of the inferior part, where below the inferior medullary velum only the epithelial layer is present.

Boundaries.—The **floor** is formed by the pons and medulla.

The **lateral wall** (superior triangle) is formed by the brachium conjunctivum of the cerebellum; and (inferior triangle) by the tænia of the fourth ventricle winding across the restiform body, funiculus cuneatus and funiculus gracilis to the *obex*. The **roof** is formed by the superior medullary velum (valve of Vieussens) superiorly; and by the inferior medullary velum and roof epithelium, inferiorly (Fig. 91). The superior and inferior halves of the roof meet at an acute angle, the *fastigium*, and form the tent of the fourth ventricle (Fig. 79). On either side, the gable is pushed out over the restiform body and thus is formed the *lateral recess*. The lateral recess is a tunnel-like extension of the ventricular cavity, reaching almost to the posterior lateral sulcus. The recess is bounded, superiorly and ventrally, by the restiform body; dorsally, by the inferior medullary velum; and inferiorly, by the roof epithelium. The *chorioid plexuses of the fourth ventricle* invaginate the roof epithelium and hang from the roof into the lateral recesses and the inferior part of the cavity (Fig. 91).

Floor of the Fourth Ventricle. (*Fossa rhomboidea*).—Because it contains the nuclei of one or more roots of the posterior eight (fifth to twelfth) cerebral nerves, the floor of the fourth ventricle is a very important area (Figs. 86 and 96). A median groove bounded by the eminentiæ mediales forms the long axis of the diamond-shaped floor and divides it into two lateral halves; the lateral halves are bisected transversely by a number of lines, the medullary striæ (*striæ medullares*). The striæ are produced by bundles of fibers which rise from the cochlear nucleus of the auditory nerve. Diverging somewhat and plunging into the medulla at the median groove, the fibers of the striæ enter the opposite trapezoid body and lateral fillet. The medullary striæ divide each lateral half of the floor into a superior and an inferior triangle.

Description to Fig. 96.

a. Nucleus of olfactory nerves. b. Nucleus of oculomotor nerve. c. Nucleus of trochlear nerve. d. Nucleus of descending root of trigeminus. e. Chief motor nucleus of trigeminus. f. Nucleus of facial. g. Nucleus of abducens. h. Nucleus ambiguus (*vagus* and *glossopharyngeus*). i. Nucleus of hypoglossus. j. Nucleus of accessory nerve. Nuclei of optic nerve: k. Pulvinar of thalamus, l. Lateral geniculate body, m. Nucleus of superior colliculus. n. Sensory nucleus of trigeminus. o. Nucleus of vestibular nerve. p. Ventral nucleus of cochlear nerve. q. Lateral nucleus of cochlear nerve. r. Nucleus *alæ cineræ* (*vagus* and *glossopharyngeus*). s. Solitary tract (*vagus* and *glossopharyngeus*). t. Nucleus of spinal tract of trigeminus.

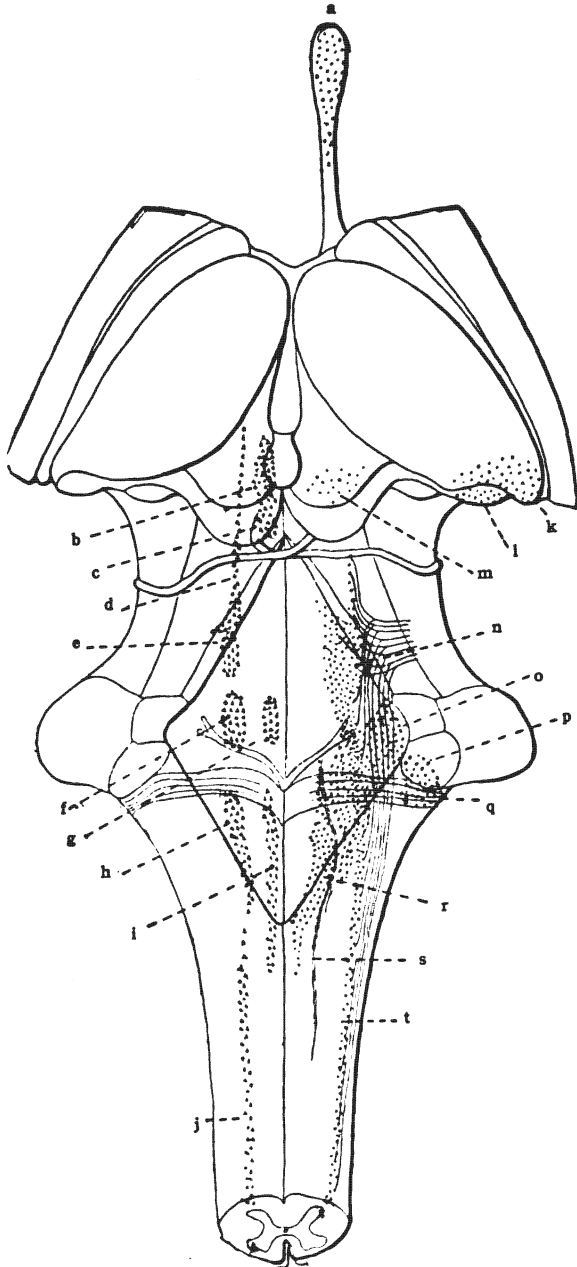


Fig. 96.—Nuclei of the cerebral nerves in the medulla, pons, mid-brain, inter-brain and olfactory bulb. Motor (or genetic) nuclei, red; terminal (or sensory) nuclei, blue. (After *Morris's Anatomy*.)

The **superior triangle of the floor** presents the colliculus facialis, superior fovea, locus cæruleus and a part of the acoustic area.

The colliculus facialis (Fig. 86), the superior extremity of the eminentia medialis, is located next the median groove. It is produced largely by the genu of the facial nerve. Beneath it is the nucleus of the abducent (sixth) nerve (Fig. 96). External to it and in front of the striæ medullares is a small fossa, the fovea superior.

Fovea Superior (Fig. 86).—The fovea superior is near the lateral wall of the ventricle and marks the location of the facial nucleus (seventh) and the salivary nucleus of the intermediate nerve, which are deeply seated in the pons. Running upward along the wall of the ventricle from the superior fovea, is the sulcus limitans. It is a blue-floored groove in the pons, called locus cæruleus.

The locus cæruleus (Fig. 86) continues to the superior angle of the ventricle. The blue color is due to the substantia ferruginea, a pigmented layer of cell-bodies underlying the ependyma. The principle motor nucleus of the trigeminal nerve (fifth) lies beneath the superior part of the locus cæruleus (Fig. 96).

Inferior Triangle of the Ventricular Floor.—It presents: The trigonum hypoglossi, fovea inferior, ala cinerea and eminentia cinerea, and most of the area acustica (Fig. 86).

The hypoglossal triangle (Fig. 86) is produced by the inferior half of the eminentia medialis. Its apex is in the inferior angle of the ventricle, and forms one nib of the *calamus scriptorius*; its base looks upward and is situated under the medullary striæ. The twelfth nerve rises from the column of cells whose upper one-half is covered by it (Fig. 96). External to the trigonum hypoglossi and inferior to the striæ medullares is the inferior fovea, which forms the apex of the ala cinerea.

Ala Cinerea (Trigonum Vagi, Fig. 86).—The vagus triangle is of a darker color than the ventricular floor around it, hence the name, ala cinerea. The *inferior fovea* forms the depressed and superiorly directed apex of the ala; its floor rises inferiorly to the base, *eminentia cinerea*, which is directed toward the clava. The

nucleus alæ cinereæ, the nucleus tractus solitarii and the nucleus ambiguus, three nearly parallel columns of cell-bodies a half-inch in length, are in part covered by the ala cinerea (Fig. 96).

The superior and inferior foveæ and the sulcus limitans fossæ rhomboideæ in which they are located represent the lateral sulcus, which in the embryo separates the ventral from the dorsal zone of the rhombencephalon.

Area Postrema.—Below the ala cinerea and between it and the tænia ventriculi quarti, there is a small fusiform strip of the ventricular floor which Retzius has called the area postrema. An oblique stria separates it from the base of the ala cinerea.

The area acustica occupies the lateral angle of the ventricular floor (Fig. 86). It is partly in the superior triangle, but chiefly in the inferior. Inclosed between the ala cinerea and the tænia, its apex points downward, and its base looks upward and is crossed by the medullary striæ. A slight eminence, the tuberculum acusticum, makes the lateral angle of the acustic area most prominent. Beneath the acustic area are the vestibular nuclei of the auditory nerve; also the lateral part of the cochlear nucleus, which is found in the acustic tubercle (Fig. 96).

ORIGIN OF CEREBRAL NERVES.

According to Sömmering, there are twelve pairs of cerebral nerves (nervi cerebrales), but to this must be added the nervus intermedius (pars intermedia) which, though associated with the facial nerve in the facial canal, is of itself a true mixed nerve. The first, second and eighth cerebral nerves are purely sensory; six of them, the third, fourth, sixth, seventh, eleventh and twelfth, are purely motor; while the fifth, the intermediate, the ninth and tenth are mixed nerves and contain both efferent and afferent fibers.

Cerebral Nerves, Nervi Cerebrales (Figs. 86 and 96).—

1. Olfactory (nn. olfactorii)—special sense of smell.
2. Optic (n. opticus)—special sense of sight.
3. Oculomotor (n. oculomotorius)—motor.
4. Trochlear (n. trochlearis)—motor.

5. Trigeminal (n. trigeminus)—motor and common sensory.
6. Abducent (n. abducens)—motor.
7. Facial (n. facialis)—motor.
Intermediate (n. intermedius)—special sense of taste, secretory and trophic.
8. Acoustic (n. acusticus)—special senses of hearing and equilibrium.
9. Glossopharyngeal (n. glossopharyngeus)—Special sense of taste, common sensory, secretory, trophic and motor.
10. Vagus (n. vagus)—motor, vaso-motor, viscero-motor, inhibitory, secretory, trophic and common sensory.
11. Accessory (n. accessorius)—motor.
12. Hypoglossal (n. hypoglossus)—motor.

All cerebral nerves are connected with the brain and, when their functions were not understood, these points of connection were indiscriminately called origins; but with our present knowledge of the functions and development of the pure sensory and the mixed nerves such use of the term "origin" is not admissible. Pure sensory nerves and the sensory roots of mixed nerves take their origins from ganglia situated wholly outside the brain. From those ganglia the dendrites grow outward to the peripheral distribution of the respective nerves; the axones grow centrally into the brain, where they arborize and end in groups of cell-bodies forming nuclei. Such nerves conduct impulses from the periphery to these nuclei, hence the name applied to them is *terminal nuclei (nuclei terminales)*. See the blue nuclei, Fig. 96. The motor nerves and the motor roots of mixed nerves take their origins inside the brain from groups of cell-bodies also called nuclei. The axones grow outward from these latter nuclei toward the periphery; they conduct impulses from the nuclei to the muscles or to the secreting cells in their respective areas of distribution, hence the nuclei of motor nerves and motor roots are *genetic nuclei (nuclei origines)*. See the red nuclei, Fig. 96. Thus it is seen that the brain connection of a motor nerve is its true origin, while this connection is the real termination of a sensory nerve.

TABLE II.
SENSORY NERVES AND SENSORY ROOTS.

Ganglion of Origin.	Entrance Into Brain.	Terminal Nucleus.
	<i>1. Olfactory (Smell).</i>	
Olfactory cells in nasal mucous membrane.	Under surface of olfactory bulb.	Mitral and brush cells of bulb (a part of cerebral hemisphere).
	<i>2. Optic (Sight).</i>	
Ganglionic layer of the retina.	Surface of lateral geniculate body, pulvinar of thalamus and superior quadrigeminal colliculus.	Nuclei of same in inter-brain and mid-brain.
	<i>5. Trigeminal (Sensory Root).</i>	
Semilunar ganglion.	Anterior surface of the pons.	Nucleus tractus spinalis n. trigemini reaching from mid-pons to second cervical nerve.
	<i>Intermediate Nerve (Sensory Root) (Taste).</i>	
Geniculate ganglion.	Groove between pons and medulla, between seventh and eighth nerves.	Nucleus tractus solitarii beneath inferior fovea in medulla.
	<i>8. Acoustic (Hearing and Equilibrium).</i>	
<i>Cochlear Root.</i> —Spiral ganglion (of Corti).	Groove between pons and medulla.	<i>Cochlear Nuclei.</i> —Ventral and lateral, placed ventral and lateral to restiform body in medulla.
<i>Vestibular Root.</i> —Vestibular ganglion.		<i>Vestibular Nuclei.</i> —Principal, Deiters's and nucleus of descending root, in floor of fourth ventricle in medulla.
	<i>9. Glossopharyngeal (Sensory Root) (Taste, etc.).</i>	
Superior and petrosal ganglia in jugular foramen.	Posterior lateral sulcus of medulla.	Nucleus tractus solitarii and nucleus alæ cineræ in medulla.

10. *Vagus (Sensory Root).*

Jugular and nodular ganglia in jugular foramen and below it.	Posterior lateral sulcus of medulla.	Nucleus alæ cineræ, and perhaps nucleus tractus solitarii, in medulla.
--	--------------------------------------	--

TABLE III.

MOTOR NERVES AND MOTOR ROOTS.

Genetic Nucleus.	Apparent Origin (Exit from Brain).
<i>3. Oculomotor (Motor Nerve).</i>	
Nucleus in floor of cerebral aqueduct in mid-brain under superior colliculus.	Interpeduncular fossa of mid-brain.
<i>4. Trochlear (Motor Nerve).</i>	
Nucleus in floor of cerebral aqueduct in mid-brain under inferior colliculus.	Superior medullary velum in isthmus rhombencephali.
<i>5. Trigeminal (Motor Root).</i>	
Nucleus in floor of cerebral aqueduct in mid-brain and under locus cæruleus of pons.	Anterior surface of pons.
<i>6. Abducent (Motor Nerve).</i>	
Nucleus under colliculus facialis in pons.	Groove between pons and medulla.
<i>7. Facial (Motor Nerve).</i>	
Nucleus under fovea superior in pons.	Groove between pons and medulla.
<i>Intermediate (Efferent Part, Secretory).</i>	
Dorsal part of facial nucleus in pons.	Groove between pons and medulla.
<i>9. Glossopharyngeal (Motor Root).</i>	
Nucleus alæ cineræ and nucleus ambiguus in the medulla.	Posterior lateral sulcus of medulla, upper end.
<i>10. Vagus (Motor Root).</i>	
Same as ninth, but chiefly nucleus ambiguus.	Posterior lateral sulcus below ninth, and between olive and restiform body.

11. *Accessory (Motor Nerve).*

<i>Cerebral Root.</i> —Nucleus ambiguus in closed medulla.	Posterior lateral sulcus of medulla below level of olive.
<i>Spinal Root.</i> —Nucleus in lateral part of base of anterior column—upper five segments of cord.	Lateral surface of cord between ligamentum denticulatum and posterior roots of spinal nerves.

12. *Hypoglossal (Motor Nerve).*

Nucleus under trigonum hypoglossi, floor of fourth ventricle, and in closed medulla.	Anterior lateral sulcus of medulla between pyramid and olive.
--	---

Terminal Nuclei.—The terminal nuclei of the first and second cerebral nerves are peculiar and cannot as yet be classified with the nuclei of other sensory nerves and sensory roots (Figs. 26, 43 and 63). The terminal nuclei of the fifth, the intermediate, the eighth, ninth and tenth nerves may be called the *posterior columna series*; because they are formed by masses of cell-bodies representing the upward prolongation of the posterior columna of gray substance in the spinal cord. Terminal nuclei are common sensory and special sensory.

Common Sensory Nuclei (Fig. 96).—Of the posterior columna series of nuclei, the terminal nucleus of the fifth and of the tenth nerves and a part of the terminal nucleus of the ninth nerve receive common sensory impulses, and *transmit them to the opposite thalamus by two routes*, viz., through the *medial fillet* and through the *spino-thalamic tract*. Impulses of the muscular sense travel over the former route; those of the pain and temperature senses, over the latter; and tactile impressions are believed to traverse both routes alike. From the thalamus these impulses are carried to the cortex of the posterior central gyrus. Thus is the *cortical connection* of these nuclei established; and each is brought into *reflex connection* with motor nuclei by axones of the terminal nuclei which run chiefly through the medial longitudinal bundle and terminate in the motor nuclei.

Special Sense Nuclei.—The *cortical connection* of the *nucleus tractus solitarii*, which receives *taste* impulses from the glosso-pharyngeal and intermediate nerves, has not been definitely traced; but it is probably relayed in the thalamus and is established by

fibers of the *formatio reticularis*, in the pons and mid-brain, and, in the hemisphere, by certain fibers of the internal capsule which end in the fusiform gyrus (?). The *cochlear nuclei* (ventral and lateral) receive true impulses of *hearing* and conduct them on toward the cerebral cortex by way of their axones, which form the trapezoid body and medullary striæ and then unite in forming the lateral fillet (Fig. 89). The remaining links of the cortical connection are formed by the brachium inferius and the acoustic radiation (*radiatio temporothalamica*). The *reflex connection* of these nuclei is somewhat indirect. It is established in part by certain fibers of the lateral fillet which end in the quadrigeminal colliculi, together with the anterior longitudinal bundle; but is chiefly brought about by the olivary pedicle and the medial longitudinal bundle. The *vestibular nuclei*—the principal (Schwalbe's), Deiters's and the nucleus of the descending root—concern *equilibrium*. They receive impulses from the vestibule and semicircular canals of the internal ear. They have a *cerebral* and a *cerebellar cortical connection*. The former is established as far as the thalamus, by the opposite medial fillet, and completed by the cortical fillet; and the latter is formed by the descending root, which ends in the nucleus funiculi cuneati, and the external arcuate fibers. With the *cerebral motor nerves*, these nuclei are brought into *reflex connection*, *first*, by axones entering the medial longitudinal bundle and terminating in the motor nuclei; and, *second*, probably by fibers of the brachium conjunctivum which become connected with the nuclei of the third, fourth and sixth cerebral nerves. The reflex connection with *spinal nerves* is formed by the anterior descending cerebello-spinal tract, viz., by axones of Purkinje's cells, the acustico-cerebellar tract, the cerebello-olivary fibers and descending fibers from Deiters's and the inferior olivary nuclei.

The terminal nuclei of the *optic nerve* are situated in the lateral geniculate body, the pulvinar of the thalamus and the superior colliculus of the corpora quadrigemina (Fig. 43). Like the terminal nucleus of the olfactory nerve, these cannot at present be included in the posterior column series, because the ventral and dorsal zones of the embryonic fore-brain have not been sufficiently

elucidated. If the sulcus hypothalamicus really separate ventral from dorsal zone in the inter-brain, as is claimed by many, it would seem that both the optic and olfactory terminal nuclei might be included in the posterior series; but there is need of further investigation, as this places the whole cerebral hemisphere in the dorsal zone.

The *cortical connection* of the terminal nuclei of the optic nerve (Fig. 67) is established by fibers of the optic radiation (radiatio occipito-thalamica) which rise in the lateral geniculate body and in the pulvinar of the thalamus and terminate in the cortex of the calcarine region of the occipital lobe. From this cortical center, corticofugal fibers run through the occipito-thalamic radiation and brachium superius to the superior quadrigeminal colliculus. This colliculus also receives a few fibers directly from the outer root of the optic tract; it thus becomes the *center of optic reflexes*; and axones of the superior colliculus form the anterior longitudinal bundle, which completes the connection with opposite motor nuclei.

The *terminal nucleus* of the *olfactory nerve* is situated in the olfactory bulb (Figs. 26 and 63). The axones of this nucleus establish direct *cortical connection*, *first*, with the uncinata region and anterior perforated substance by way of the lateral olfactory stria and, probably, by way of the intermediate stria; and, *second*, with the parolfactory area, the olfactory triangle, the gyrus subcallosus and the gyrus cinguli through the fibers of the medial stria of the olfactory tract. The *reflex connection* of the olfactory nerve is but little understood. The following probabilities may be stated: *First*, the fornix, stria medullaris thalami, fasciculus retroflexus and axones of interpeduncular ganglion; *second*, the fornix, thalamo-mammillary bundle and descending axones of the thalamus; and, *third*, the fornix and the pedunculo-mammillary bundles running into mid-brain, pons and medulla.

Genetic Nuclei (Nn. Origines) (Fig. 96).—The nuclei of the oculomotor, trochlear, abducent, facial, accessory and hypoglossal nerves and the nuclei of the motor roots of the trigeminal, glossopharyngeal and vagus nerves represent the anterior column of gray matter in the cord and constitute the *anterior columna series*. These nuclei are *connected with the cerebral cortex* on both

sides, but chiefly with that of the opposite hemisphere. The connection is established *first and principally* by the pyramidal tracts, some of the fibers running directly from the tract to the nucleus, and others, leaving the tract high up, run through the *accessory fillet* (Bechterewi) to a point near the respective nuclei which they are about to enter; and, *second*, the fronto-pontal, temporo-pontal and intermediate tracts are believed to send some fibers to the genetic nuclei of the same side. The *reflex connection* of these genetic nuclei is established for all of them by the medial longitudinal bundle; by the anterior longitudinal bundle and by the olivary pedicle (for the third, fourth, and sixth), by the trapezoid body (for the seventh) and by the spinal tract of the trigeminal nerve (for the fifth, seventh, and twelfth).

CHAPTER V.

MEMBRANES OF THE SPINAL CORD.

(MENINGES SPINALIS.)

Dura Mater.—Through the foramen magnum the membranes of the brain are continuous with those of the cord with which they are very similar in structure. The *dura mater spinalis* is attached to the margin of the great foramen and to the bodies of the first two or three cervical vertebræ; elsewhere, though joined to the vertebræ by fibrous bands, its surface is free from immediate bony attachment and it does not possess the periosteal layer. Thus suspended, it hangs as an open sack, or sheath (Fig. 100) and reaches down to the third sacral vertebra, where it is constricted to a fibrous cord which blends with the periosteum on the posterior surface of the coccyx. The arachnoid and pia, and the spinal cord and cauda equina are contained in the dural sack (Figs. 97, 98 and 100). Externally, the surface of the dura is separated from the wall of the spinal canal by the internal vertebral plexus of veins, areolar tissue and fat. The *outer surface* is composed of flat polygonal cells, like the inner surface. Its *internal, serous surface* is bathed with a small amount of cerebro-spinal fluid which separates it from the arachnoid. For every segment of the spinal cord, the dura presents, on either side, a pair of foramina, through which run the anterior and posterior roots of the spinal nerves (Fig. 97). Those nerve roots are invested by a sheath of dura prolonged from the margins of the foramina. The dura mater of the cord does not separate into two layers, and forms neither sinuses nor processes. It performs no periosteal function and possesses no arachnoid granulations (pacchionian bodies). Its two surfaces are formed by endothelium.

Arachnoid.—The arachnoid of the spinal cord (*arachnoidea spinalis*) forms a sack of the same length as the dural sheath, with which it is externally in contact (Figs. 97, 98 and 100). It

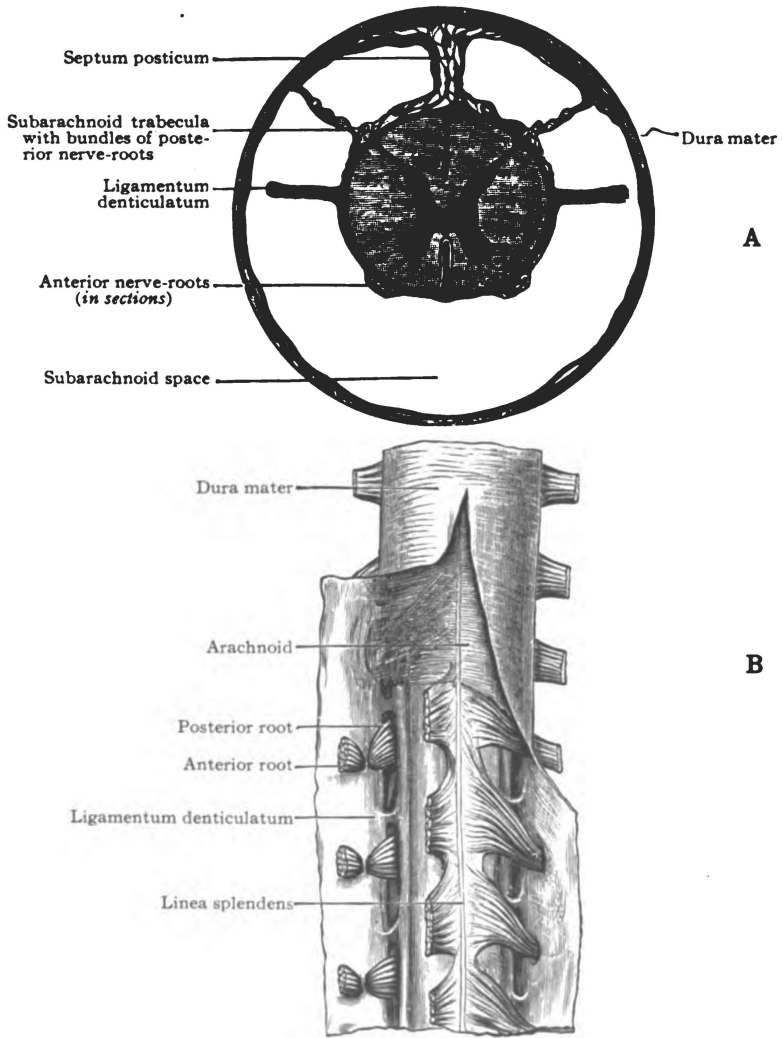


Fig. 197.—Meninges of the spinal cord. A. Transverse section. (After Key and Retzius.) B. Anterior view. (After Ellis. *Morris's Anatomy*.)

presents two serous surfaces. Internally, bands of fibro-elastic tissue attach it to the pia mater along the posterior median line of the cord and form the *subarachnoid septum* (Fig. 97). The external spinal veins and a considerable space separate the arachnoid from the pia mater. That subarachnoid space is filled with fluid. By the *ligamenta denticulata* it is divided into the *anterior* and *posterior subarachnoid spaces*, which, through the foramen magnum, are continuous with the same spaces in the cranial cavity (Figs. 97 and 6).

Pia Mater.—The pia of the cord (*pia mater spinalis*) is much stronger than that of the brain (Figs. 97 and 98). It has *two*

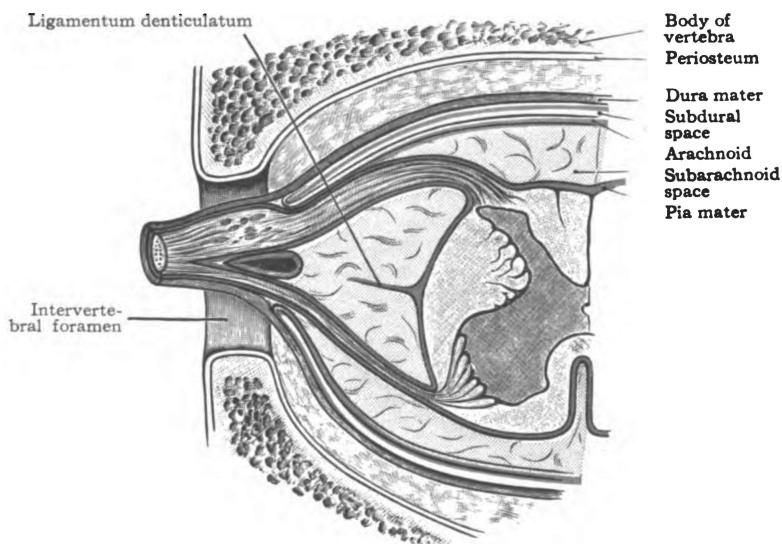


Fig. 98.—Diagrammatic section of the spinal meninges and spinal cord.
(After *Morris's Anatomy*.)

distinct layers, the inner of which is continuous with the brain pia and forms an epineurium for the cord and roots of the spinal nerves. The outer is the more vascular layer. Both layers dip into the anterior median fissure; they form the anterior septum which contains the anterior spinal artery. The inner layer is attached to the septum in the posterior median fissure. The outer layer forms the *linea splendens* along the front of the cord, and the

ligamentum denticulatum on either side. The denticulate ligament is a longitudinal band whose smooth medial border is continuous with the pia along the middle of the lateral surface of the cord; its lateral border is notched and its twenty teeth, invested with arachnoid, are attached to the dura opposite the first twenty vertebræ. The two ligaments subdivide the space between the pia and arachnoid into anterior and posterior subarachnoid spaces. A filamentous extension of the pia below the cord proper helps to form the *filum terminale internum*. It descends in the arachnoidal sheath with the roots of the lumbar and sacral nerves, and all together constitute the *cauda equina* (Fig. 100). For some distance, about half its length, the *filum terminale internum* contains gray matter and rudimentary fibers continuous with the spinal cord. The filum unites with the arachnoid and dura at the third sacral vertebra in forming the *filum terminale externum* which forms a sort of ligament for the spinal cord. That ligament is inserted into the coccyx. The pia mater of the cord contains the trunks and large branches of the anterior and the two posterior spinal arteries, and the tributaries of the external spinal veins.

Nerve Supply.—The membranes of the spinal cord are supplied by recurrent branches of the spinal nerves and by the sympathetic. The recurrent branches are sensory in function.

BLOOD SUPPLY OF THE SPINAL CORD.

The vessels supplying the cord are the anterior spinal artery and the two posterior spinal arteries, which rise at the foramen magnum from the vertebral arteries, and are reinforced by cervical, intercostal and lumbar arteries. The **anterior spinal artery** (*a. spinalis anterior*) descends along the entrance to the anterior median fissure (Fig. 99); it is formed by the union of two vessels, one from each vertebral. The **posterior spinal artery** (*a. spinalis posterior*) of either side, is in reality a pair of vessels which freely communicate, and are so placed as to embrace the posterior nerve roots. The larger vessel of the pair is anterior to the nerve roots, while the smaller is between them and the posterior median fissure

(Fig. 100). The spinal arteries give origin to two sets of **branches**, namely, the *fissural or centrifugal*, and, the *centripetal arteries*. Both sets are end-arteries and form rich longitudinal plexuses, which overlap each other but do not anastomose.

The **fissural or centrifugal arteries** rise, *first and chiefly*, from the anterior spinal artery (Fig. 100). These enter the anterior median fissure and, running lateralward, supply the

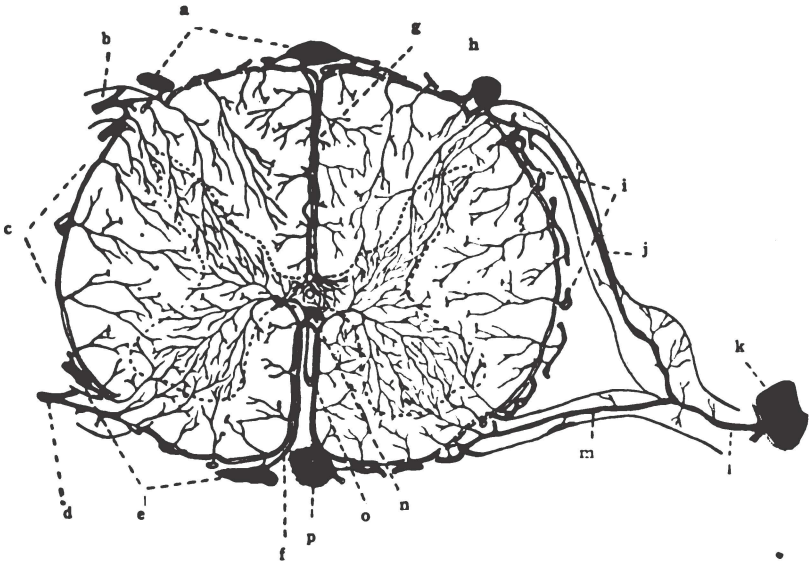


Fig. 99.—The arteries and veins in the spinal cord. Diagrammatic.
(After *Morris's Anatomy*.)

a. Dorsal external spinal veins. b. Posterior radicular vein. c. Peripheral venous plexus. d. Anterior radicular vein. e. Ventral external spinal veins. f. Anterior central vein. g. Posterior central artery and vein. h. Posterior spinal artery. i. Peripheral arterial plexus. j. Posterior radicular artery. k. Intercostal artery. l. Spinal ramus. m. Anterior radicular artery. n. Interior spinal vein. o. Anterior central artery. p. Anterior spinal artery.

greater part of the gray matter. *Second*, a few centrifugal arteries rise from the posterior spinal arteries. Running into the posterior fissure, they are distributed to the posterior white columns, the posterior commissure and to the nucleus dorsalis (Clarki).

The **centripetal arteries** rise from both the anterior and posterior spinal arteries (Fig. 100). They enter the cord at right angles to the surface, and supply the white matter and the periph-

eral parts of the gray substance, including the tips of the columnæ. Those branches to the columnæ accompany the root-fibers.

Veins.—The veins that carry the blood from the interior of the cord, the **venæ spinales internæ**, are the *fissural veins*, which issue from the fissures, the *root-veins*, which accompany the anterior and posterior root-fibers to the surface of the cord, and a small number of veins that issue from other parts of the surface of the spinal cord. All unite in forming the external spinal plexus (**venæ spinalis externæ**) spread over the entire surface of the cord beneath the arachnoid membrane. According to Cunningham, the plexus includes six longitudinal veins—anterior and posterior median and, on either side, an antero-lateral and a postero-lateral vein placed just behind the respective nerve roots. In the upper cervical region, the plexus forms two or three small veins which empty into the vertebral or inferior cerebellar veins; elsewhere, by a branch along each spinal nerve, the plexus communicates with the internal vertebral plexus (**plexus venosi vertebrales interni**) outside the dura mater, and is drained into the vertebral, intercostal, lumbar and sacral veins. No valves are found in the spinal veins.

Lymphatics.—Perivascular and perineural spaces carry the lymph from the spinal cord. There are no lymphatic vessels in the cord.

CHAPTER VI.
THE SPINAL CORD.

The spinal cord (*medulla spinalis*) is developed from the posterior part of the neural tube, and forms the corresponding portion of the central axis of the nervous system.

Extent.—It is continuous with the medulla oblongata, above; and, in the adult, reaches to the lower border of the first lumbar vertebra (Fig. 100). Its length is seventeen to eighteen inches. In a very slender process, the *filum terminale internum*, the cord is continued beyond the first lumbar vertebra. That process and the lower spinal nerves form the *cauda equina*, which is inclosed in a sheath composed of the arachnoid and dura mater. The *filum terminale internum* for about three inches contains a prolongation of the central gray matter and ventricle of the cord; and, also, a few fibers, which suggest the coccygeal nerves of lower animals.

In the fœtus before the third month, the cord and spinal canal are of equal length. At birth the cord reaches the third lumbar vertebra, and it continues to recede with the rapid growth of the vertebræ to adult life.

Diameters (Fig. 101).—The spinal cord is shaped like a cylinder, slightly flattened from before backward (dorso-ventrally). Its longest diameter is transverse and measures less than half an inch, except in the cervical and lumbar enlargements of the cord. In the latter, it equals a half-inch; and, in the former, it slightly exceeds it. The thoracic portion of the cord is small and nearly cylindrical in shape. Divested of its meninges and nerves the spinal cord weighs about one ounce and a half, avoirdupois.

The *cervical enlargement* (*intumescentia cervicalis*) extends from the medulla oblongata to the second thoracic vertebra (Figs. 100 and 101). Its greatest diameter is on a level with the fifth intervertebral disk. It gives origin to the motor fibers and

receives the sensory fibers of the nerves which form the cervical and brachial plexuses.

The *lumbar enlargement* (*intumescentia lumbalis*) begins at the tenth thoracic vertebra and increases to the twelfth (Figs. 100 and 101). Opposite the first lumbar vertebra, it tapers off

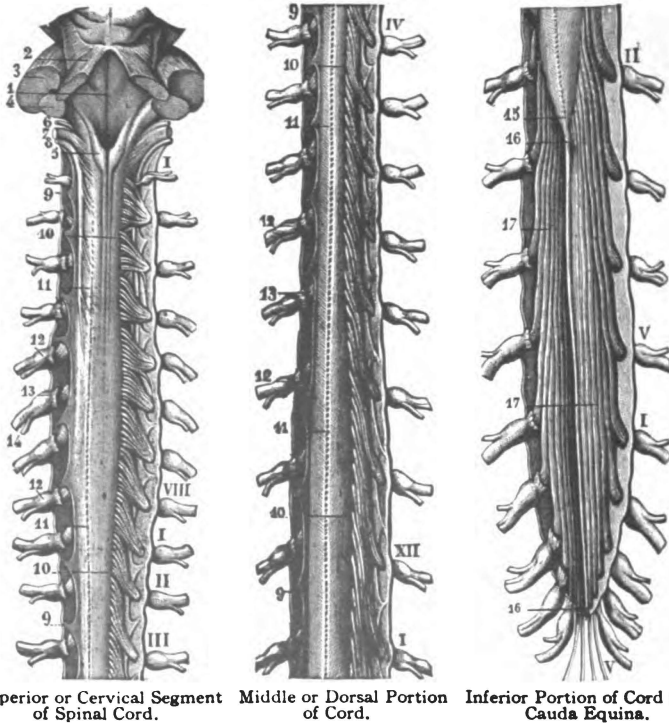


Fig. 100.—Posterior view of the spinal cord, the dura mater and the arachnoid being laid open and turned aside. (*Brubaker after Sappey.*)

1. Floor of fourth ventricle. 2. Brachium conjunctivum. 3. Brachium pontis. 4. Restiform body. 5. Clava. 6. Glossopharyngeal nerve. 7. Vagus. 8. Accessory nerve. 9, 9, 9, 9. Ligamentum denticulatum. 10, 10, 10, 10. Posterior roots of spinal nerves. 11, 11, 11, 11. Posterior lateral sulcus. 12, 12, 12, 12. Spinal ganglia. 13, 13. Anterior roots of spinal nerves. 14. Anterior and posterior divisions of spinal nerve. 15. Conus medullaris. 16, 16. Filum terminale internum. 17, 17. Cauda equina. I-VIII. Cervical nerves. I-XII. Thoracic nerves. I-V. Lumbar nerves. I-V. Sacral nerves.!

almost to a point, the *conus medullaris*; but a very small process continues in the *filum terminale internum*. From the lumbar enlargement rise the motor fibers of the nerves contained in the lumbar and sacral plexuses, and into it enter the sensory fibers of the same plexuses.

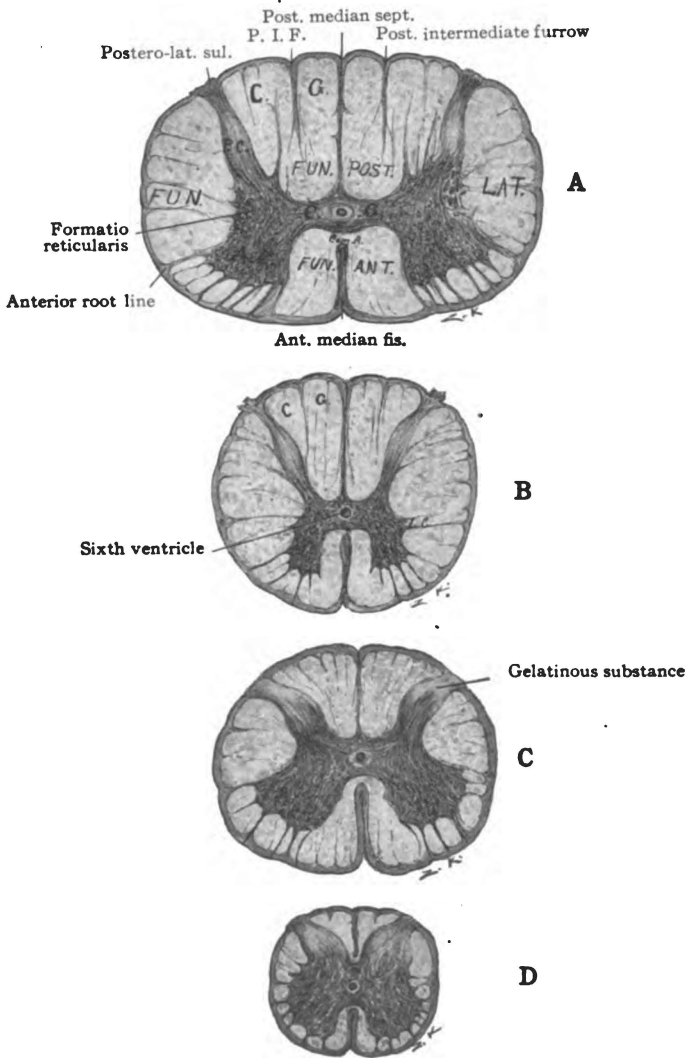


Fig. 101.—Sections of the spinal cord; A. The cervical, B. The thoracic, C. The lumbar, and D. The sacral. (*Original.*)

A. Section of cervical cord. A. C. Anterior column, P. C. Posterior column, C. G. Gray commissure, anterior gray and posterior. Com. A. White anterior commissure. Fun. Ant. Funiculus anterior, Fun Lat. Funiculus lateralis. Fun. Post. Funiculus posterior. G. Fasciculus gracilis, C. Fasciculus cuneatus. B. Section of thoracic cord. L. C. Lateral column. C. Section lumbar cord. D. Section of lower sacral cord.

Sixth Ventricle (Fig. 101, B).—The central canal of the spinal cord (*canalis centralis spinalis*) is the representative of the cavity of the neural tube. It is just visible to the naked eye; but it extends throughout the cord and expands above into the fourth ventricle. In the filum terminale internum it is also dilated, forming the *ventriculus terminalis* (Krausei). It is lined with columnar ciliated cells which stand on a thick lamina of *substantia gelatinosa*.

Fissures of the Spinal Cord (Fig. 101).—The spinal cord is incompletely divided into symmetrical lateral halves by the anterior and the posterior median fissure.

The **anterior median fissure** (*fissura mediana anterior*) is the broader and shallower of the two (Fig. 101). It extends in length from the inferior end of the ventral surface of the pons (foramen cæcum of Vicq d'Azyr) down the anterior median line of the medulla and cord. As to depth, it equals one-third of the cord's axis. Its floor is formed by the white anterior commissure. Both layers of pia mater dip down into it and inclose the anterior spinal artery and its branches. The anterior median fissure is interrupted at the junction of the cord and medulla by the decussation of the pyramids. In the lumbar enlargement it gradually disappears.

The **posterior median fissure** (*fissura mediana posterior*) is narrow and deep (Fig. 101). It extends, longitudinally, down the posterior median line of the cord from the middle of the posterior surface of the medulla. It divides the cord, dorso-ventrally, beyond its middle. The floor of the fissure is formed by the posterior commissure, which, with the gray and white anterior commissures, separates the posterior from the anterior median fissure. The posterior median fissure is not an open fissure; it is occupied by a lamina of connective tissue, the *posterior septum*, which is attached to the deep layer of the pia mater. In the posterior septum ramify branches of the two posterior spinal arteries and tributaries of the external spinal veins.

Posterior Lateral Sulcus. (*S. lateralis posterior*).—Each lateral half of the spinal cord is partially divided, near the junction of the posterior fourth with the anterior three-fourths of its semi-

circumference, by the posterior lateral sulcus (Fig. 101). The sulcus is situated opposite the posterior column of gray matter, to which it transmits the posterior roots of the spinal nerves. It is continuous above with the posterior lateral sulcus of the medulla. It separates the posterior surface and the antero-lateral surface from each other.

Anterior Root-line. (*S. lateralis anterior*).—As a landmark, it is convenient to call the longitudinal line through which issue the most lateral fibers of the anterior roots of the spinal nerves, the anterior root-line of the spinal cord (Fig. 101). There is no groove on the surface of the cord along this line and it is misleading to call it a sulcus, as has been the custom. It is situated opposite the anterior column of gray matter and in line with the anterior-lateral groove of the medulla oblongata. Through it and through the surface, just medial to it, emerge the anterior roots of the spinal nerves. It subdivides the antero-lateral surface into anterior and lateral surfaces.

The **posterior intermediate sulcus** (*s. intermedius posterior*) is a slight longitudinal groove in the cord which subdivides the upper three-fourths of the posterior surface into postero-medial surface and postero-lateral surface (Fig. 101). From it a connective tissue septum extends into the cord and separates the fasciculus gracilis and fasciculus cuneatus from each other. The posterior intermediate furrow is found only in the cervical and in the upper eight thoracic segments of the cord.

I. GRAY MATTER OF THE CORD.

The spinal cord is composed of (1) gray matter (*substantia grisea spinalis*), in the central part; and (2) white matter (*substantia alba spinalis*) in the peripheral area. It is like the medulla and pons in having the white matter on the surface (Fig. 101).

A column of gray matter (Fig. 101), crescentic in section, extends through the center of each lateral half of the spinal cord. The crescent is convex medially; and is joined to its fellow, a little in front of the middle, by a vertical transverse lamina of gray matter, called the *gray commissure* (*commissura grisea*).

It is joined to the white matter of the opposite side by the white anterior commissure. The points of the crescent are directed forward and backward, respectively, and form the *anterior* and *posterior* columnæ. A lateral projection from the center of the crescent, visible only in the thoracic region, is called the lateral columna; it fuses with the anterior columna in the cervical and lumbar enlargements. Together, the two crescents and the gray commissure form an H-shaped column of gray matter. The H-shaped column is well marked in the cervical and thoracic regions; but, toward the lower end of the cord, the crescents become short and thick, and the gray column is almost cylindrical.

The **H-shaped column** is composed of *two kinds of gray substance*, viz.: (1) The *substantia gelatinosa* (Rolandi), which forms (a) a cap for the head of the posterior columna and (b) an envelope for the central canal, or ventricle, of the cord. (2) The *substantia spongiosa*. The latter forms all the H-shaped column except the tips of the posterior columnæ and the thick sheath of the central canal. Imbedded in the neuroglia, there is a network of medullated nerve fibers; and these, with the common stains, give rise to a spongy appearance under the microscope.

Gray Crescent (Fig. 101).—It is made up of (1) *the anterior columna*; (2) *the center*, which is joined to its fellow of the opposite side by the gray commissure and which forms the lateral projection, called the *lateral columna*; and, (3) *the posterior columna*. The lateral border of the crescent is not everywhere clear cut and definite, especially in the cervical region, but is intermingled for a short distance with the white matter, forming the *formatio reticularis*. The *formatio reticularis* is found in the cervical region, elsewhere it is very feebly developed.

(1) The **anterior columna** (*columna anterior*) (Fig. 101) as seen in sections is short and thick compared with the posterior columna. It is thickest in the cervical and lumbar enlargements, where it swells out sharply toward the lateral surface of the cord; in the mid-thoracic region it is more slender. It does not reach the surface of the cord as does the posterior columna. It ends in a bulbous, serrated head, which points toward the anterior root-line, and is joined to the center of the crescent by the cervix

or base. From it the anterior roots of the spinal nerves rise; and, together with the anterior root-fibers, it separates from each other the anterior and lateral white columns of the cord.

Cells of the Anterior Columna (Figs. 102 and 103).—The gray matter of the spinal cord contains *multipolar neurones* of the Golgi and Deiters types. The **Golgi cells** ramify richly in the gray matter about the cell-bodies, and, both their axones and dendrites terminate in relation with other neurones in the adjacent gray substance. The long axones of the **Deiters cells** either enter into the anterior roots (*radices anterior*), and the neurones are called *radicular cells*, or they enter into a longitudinal tract or strand of fibers, and the neurones are named *strand-cells* (Cunningham). The dendrites of the Deiters cells arborize in both the gray and white substance. The cell-bodies in the anterior columna are large and vesicular in character. They are motor or efferent in function, and their axones form, in great part, the anterior roots of the spinal nerves. Together with the neurones of the genetic nuclei of cerebral nerves, these of the anterior columna constitute the lower segment motor neurones.

Two chief columns of cell-bodies are located in the anterior columna, the **medial column** and the **lateral column** (Figs. 102 and 103). The former is continuous throughout the cord with the exception of the fifth lumbar and the first sacral segments (Bruce-Cunningham); while the lateral column is found only in the cervical and lumbar enlargements. The *medial column* of cells shows a double group in sections of the lower three cervical, all the thoracic and the first lumbar segments of the cord. These subgroups are called the *ventro-medial* and the *dorso-medial cells*. Only the ventro-medial group is present above the sixth cervical segment and below the first lumbar segment. The dendrites of the cell-bodies in the medial column arborize in the gray substance of the same columna, in the adjacent white matter of the anterior column of the cord and, to some extent, in the opposite anterior columna, having passed through the white anterior commissure; the axones of these medial cell-bodies enter very largely into the anterior roots of the spinal nerves on the same side; but a certain number probably run through the white

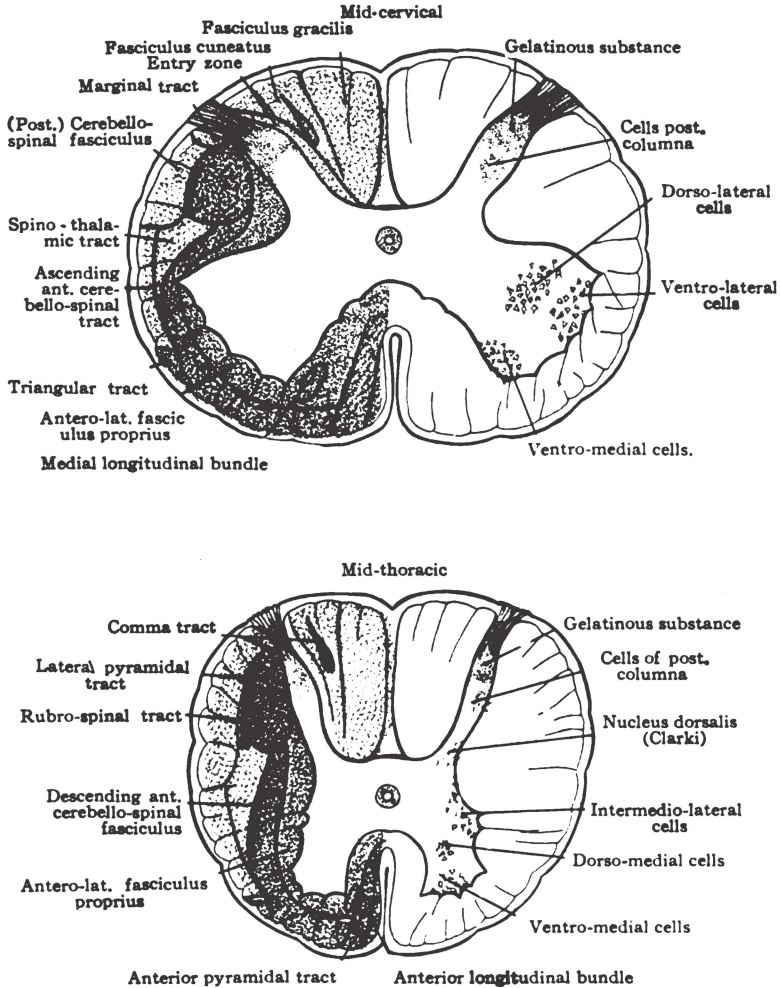


Fig. 102.—Tracts of fibers and columns of cells, in the cervical and thoracic regions of the cord. Diagrammatic. (In part after *Bruce and Cunningham.*)

anterior commissure into the anterior nerve-roots of the opposite side, and others enter into the fasciculi proprii of the cord.

The *lateral column of cells* in the anterior column is a large one (Figs. 102 and 103). It is found only in the regions which innervate the extremities, that is, in the cervical and lumbar enlargements. It is everywhere divided into a *ventro-lateral* and a *dorso-lateral cell-group*, and in most of the segments of the lumbar enlargement there are two other cell-groups, according to Alexander Bruce. One of them is located behind the dorso-lateral cells and is called the *post-dorso-lateral group*; and the other, which occupies the angle between the ventro-lateral and the dorso-lateral cells, lying medial to both, is called the *central group* (Cunningham). The dendrites of the cell-bodies in the lateral column arborize and end both in the gray matter of the anterior column and in the white matter adjacent to its lateral surface; the axones proceed largely into the anterior roots of the spinal nerves but partly into the longitudinal white columns of the cord. Probably the medial column innervates the trunk muscles; the lateral column, the muscles of the extremities. *Cortical Connection.*—These cell-columns are brought into relation with the anterior (direct) pyramidal fibers and the lateral (crossed) pyramidal fibers by means of intermediate neurones. In this manner motor and inhibitory impulses descend to them from the cerebral cortex, coming from the opposite hemisphere, chiefly, but also from the same side. They also are in relation with the end-tufts of posterior root-fibers and with axones whose cell-bodies are located in the center and posterior column of the gray crescent. The latter neurones form contact relations with fibers of the posterior roots of the spinal nerves on both sides. Thus both by immediate contact between anterior and posterior root-neurones and by the intervention of an intrinsic spinal neurone the *simple reflex mechanism* of the spinal cord is formed. It has been the belief that the end-tufts of the fibers in the anterior and lateral pyramidal tracts are in direct contact with the dendrites or cell-bodies of the neurones in the anterior column; but the investigations of Schäfer, Collier and others, indicate that this connection between the neurones of the anterior column and the lateral pyramidal fibers,

at least, is established by intervening neurones whose cell-bodies are located near the base of the posterior column in the region of the nucleus dorsalis (Clark's column). The evidence of such termination of the anterior pyramidal tract is not conclusive.

Lesions.—Paralysis due to lesions of the anterior column and of the genetic nuclei of cerebral nerves is often called *lower segment paralysis*. The cells in the anterior column are the seat of hemorrhagic inflammation and rapidly degenerate in acute anterior poliomyelitis. In progressive muscular atrophy and in amyotrophic lateral sclerosis they degenerate slowly. As a result of the first, sudden flaccid paralysis occurs. The muscles waste away in the second and third because the nerves controlling the muscles and their blood supply are gradually destroyed. In the last, the muscles are also spastic, because the involvement of the pyramidal tracts cuts off cerebral inhibition.

(2) **Center of Crescent and Columna Lateralis** (Fig. 101).—In the center of the crescent there are many small, closely packed cell-bodies, which are probably sympathetic in function. This part of the crescent appears to contain the automatic spinal centers, such as, the cilio-spinal, cardiac-accelerator, vaso-motor, secretory, trophic, inhibito-secretory, visceromotor, visceroinhibitory, etc. That the cell-bodies in the center of the crescent are of *sympathetic junction* is suggested by two facts; *first*, the cell-bodies are small, which indicates that the axones run but a short distance from the neurone center, as is the case with spinal sympathetic neurones; and, *second*, the distribution of these central neurones is limited to those regions of the spinal cord whence the efferent sympathetic fibers rise.

The *intermedio-lateral column of cell-bodies* (Fig. 102, B) is the only one found in the center of the crescent. In the thoracic segments of the cord, where the lateral column is visible, this column is contained in the lateral column and in the white matter immediately adjacent to it; so far as it is found in the cervical and lumbar enlargements it is situated in the base of the anterior column near its lateral surface. The intermedio-lateral column is found in the last cervical, all the thoracic and the first and second lumbar segments, in a nearly continuous column; it is also found

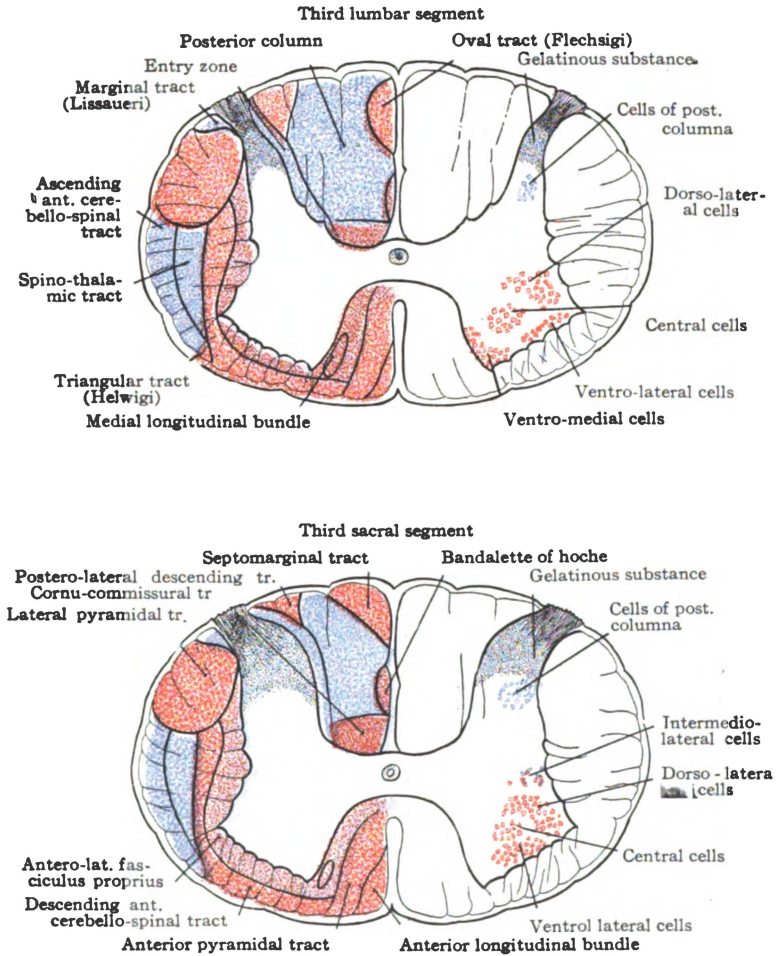


Fig. 103.—Tracts of fibers and columns of cells in the lumbar and sacral regions of the cord. Diagrammatic. (In part after *Bruce and Cunningham.*)

in the third and fourth sacral segments of the cord and in the first three cervical (Cunningham). The *first region* (from last cervical to second lumbar segment) corresponds in position and extent to the origins of the white rami communicantes; the *second region* is at the level of origin of the pelvic splanchnics; and the cell-groups representing this column in the *upper cervical segments* probably contribute sympathetic fibers to the accessory and phrenic nerves.

The cells of the intermedio-lateral column are largely of the radicular variety, their slender axones enter into the anterior roots of the spinal nerves. Whether any belong to the strand-variety is not known. They are in contact relation with posterior root-fibers and are also connected with the posterior roots by intervening neurones. Their cerebral connection has not been traced.

(3) The **posterior columna** (*columna posterior*) except in the lower cord, is slender (Fig. 101). It is longer than the anterior columna and reaches the surface in the posterior lateral sulcus, where it receives the posterior roots of the spinal nerves. The posterior columna presents a slight enlargement near its extremity, called the *caput columnæ*, which tapers off to the *apex columnæ*. The head is joined to the base by a constricted part, the *cervix*. The head of the posterior columna is capped by a V-shaped mass of *substantia gelatinosa*. Spongy substance makes up the remainder of it. The posterior columna separates the posterior from the lateral column of the cord (Figs. 102 and 103).

The cells of the *posterior columna* are numerous. In the head of the posterior columna they have smaller bodies than the cells of the columna anterior. They are less definitely grouped and are fusiform in shape throughout the *caput columnæ*; but in the base of the horn, near its medial surface, they have large vesicular bodies and form one of the most definite cell-columns in the spinal cord. The posterior columna neurones are afferent or sensory in function.

The neurones of the head of the *posterior columna* (Figs. 102 and 103) belong largely to the *type of Golgi*, as the processes of the greater number of them neither enter into the anterior roots

of the spinal nerves, nor help to form the longitudinal fiber-tracts of the cord. Their axones arborize and end in the gray substance of both crescents. Those axones of the Golgi cells which cross over through the posterior commissure to the opposite crescent help to constitute the "immediate decussation" of the pain and temperature path. There are also *Deiters cells* in the head of the posterior column; their axones enter into the posterior fasciculus proprius of the cord, hence they belong to the strand-variety. They appear to form the ventral field of the posterior column (Hoche) called the cornu-commissural tract, and at least a part of the comma, oval and septo-marginal tract. The neurones in the caput of the posterior column receive posterior root-fibers which carry excito-reflex impulses and impulses of the tactile, pain and temperature senses. The former are transmitted forward largely in the same crescent to the center and anterior column; the latter, to a considerable extent, are carried through the posterior commissure to the anterior column of the opposite crescent.

Nucleus Dorsalis (Stillingi and Clarki).—This column, which was discovered by Stilling, is composed of cell-bodies measuring from 40μ to 90μ in diameter (Figs. 102 and 104). It forms a most striking feature of the gray crescent throughout the thoracic region. It is situated near the medial surface of the base of the posterior column, bounded laterally by a curved strand of posterior root-fibers; and forms a continuous column from the seventh cervical segment to the second lumbar segment. The column is largest in the lower two thoracic segments, where it bulges out the medial surface of the posterior column. It is represented by separated groups of cell-bodies in the third and fourth sacral and first three or four cervical segments of the cord and in the accessory nucleus of the cuneate column in the medulla oblongata. The limitation of the dorsal nucleus, as an unbroken column, to the region of the white rami communicantes has suggested its connection with the sympathetic system; and it is the terminal nucleus of *afferent sympathetic fibers*, but it gives rise to no efferent fibers of that system. All the axones of the dorsal nucleus appear to run toward the lateral surface of the cord and enter into the cere-

belo-spinal tract of the same side. The several dendrites of each neurone ramify richly in the vicinity of the cell-body. Together with the cell-bodies, the dendrites are in contact relation with fibers of the posterior roots of the spinal nerves. The nucleus dorsalis probably has to do with muscular tonicity and equilibrium, chiefly. It is supposed to receive afferent sympathetic impulses from the internal organs.

Concerning the relation of the gray crescent to the spinal nerves (Fig. 104), it may be remarked, here, that in the anterior columna

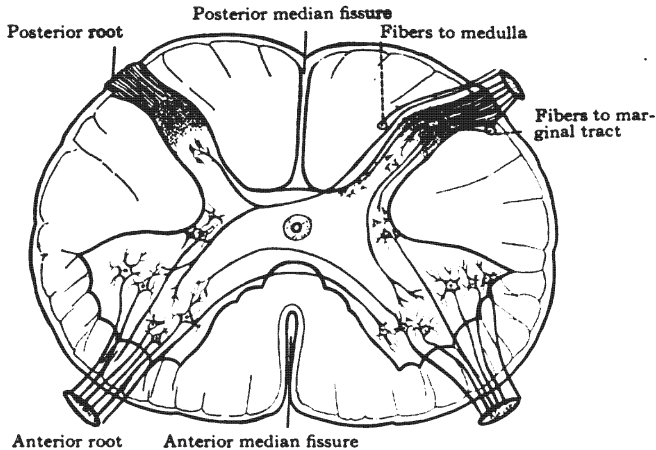


Fig. 104.—The roots of the spinal nerves. Diagrammatic. (Original.)

Anterior root rises from medial, lateral and intermedio-lateral cells of same crescent and from medial cells of opposite crescent: it is also connected with the opposite side by certain dendrites.

Posterior root terminates in gelatinous substance, in the center and base of the posterior columna, in the intermedio-lateral column, and in the anterior columna of the same crescent; in the anterior and posterior columna of the opposite side (?); and in the nucleus funiculi gracilis or nucleus funiculi cuneati of the medulla oblongata.

and center of the crescent are located the *genetic nuclei* of the motor or efferent fibers (anterior roots) of the spinal nerves; and that the *terminal nuclei* of the sensory fibers (posterior roots) of the spinal nerves are located chiefly in the posterior columna, but also in the center and anterior columna of the crescent in the cord, and in the nucleus funiculi gracilis and nucleus funiculi cuneati in the medulla oblongata.

The **gray commissure of the spinal cord** (the *gray anterior*, and the *posterior commissure*) is the vertical, transverse sheet of gray substance connecting the two crescents together (Fig. 101). This commissure (*commissura grisea*) completes the gray matter of the cord. It unites the gray crescents together a little in front of their center, except in the lumbar region where it joins their centers. It forms the floor of the posterior median fissure; and, in front, is in relation with the white anterior commissure. It is pierced longitudinally by the central canal of the spinal cord, which is surrounded by a thick envelope of *substantia gelatinosa*. This canal, the sixth ventricle, divides the commissure into two parts. That part of the commissure in front of the canal is the *gray anterior commissure* (*commissura anterior grisea*) and that behind it is the *posterior commissure* (*commissura posterior*, Fig. 101). The gray commissure, comprising both these divisions, is composed of spongy and gelatinous substance in which there are imbedded the bodies of many nerve cells and a large number of medullated fibers. The medullated fibers are derived from the posterior roots of the spinal nerves, and from intrinsic neurones of the cord, whose centers are situated chiefly in the commissure and in the posterior column. The *posterior commissure* is said to contain a long *sensory tract*, between the ventricle and dorsal surface (Ciaglinski). This long sensory tract is found in the thoracic portion of the cord and the discoverer believes it to be made up of ascending root-fibers which conduct pain and temperature impulses. It is in need of further investigation (Barker).

Lesions of the gray substance, as in syringomyelia, completely abolish the pain and temperature senses at the level of the lesion, while the muscular and tactile senses are preserved. The dissociation of sensations is most complete and bilateral when the lesion destroys the posterior commissure; if the lesion be limited to one crescent, the pain and temperature senses are affected on the side opposite to the lesion. These facts show that the pain and temperature paths to the cerebral cortex run through the gray substance of the cord and that they decussate through it immediately upon entering the cord. It also shows that muscular and

tactile impressions may reach the cerebrum without passing through the gray substance in the spinal cord; but it does not exclude the possibility of a part of the impulses of the muscular and tactile senses being transferred from a lower to a higher neurone in the spinal gray substance.

2. WHITE MATTER OF THE CORD.

The white matter (Fig. 101) of the spinal cord (*substantia alba spinalis*) is disposed in its peripheral area and in the white anterior commissure. It is composed of medullated nerve fibers (axones and collaterals) imbedded in a small amount of neuroglia, and supported by a connective tissue network derived from the pia mater. Like the gray matter, it is richly supplied with blood-vessels. The fibers of the spinal cord run transversely, dorso-ventrally and longitudinally.

The **transverse fibers**, which are usually somewhat oblique in direction, comprise (1) those running from the longitudinal tracts into the gray matter or out of the gray matter into such tracts; (2) the axones of intrinsic neurones which connect the two crescents at nearly the same level; and (3) posterior root-fibers running through the posterior commissure to the opposite crescent.

The *white anterior commissure* of the spinal cord (*commissura anterior alba*) is the only definite lamina of transverse fibers in the cord (Fig. 101). It connects the anterior and lateral white columns of the cord with the opposite gray crescent and the two crescents with each other. It is located in front of the gray anterior commissure, forming the floor of the anterior median fissure. It is composed of medullated fibers belonging to (a) the anterior pyramidal tract, (b) the anterior fasciculus proprius, (c) the ascending anterior cerebelló-spinal and spino-thalamic tracts; (d) it comprises the crossed fibers to the anterior roots of the spinal nerves, and (e) the decussating dendrites between the anterior columnæ.

The **dorso-ventral fibers** of the spinal cord (Fig. 104) are (a) those of the anterior roots of the spinal nerves, in their course from the gray matter to the surface of the cord; (b) those of the

posterior roots, running from the posterior-lateral sulcus to their destination in the gray matter, and (c) axones of intrinsic neurones connecting posterior with anterior parts of the crescent.

The **longitudinal fibers** comprise most of the white matter in the cord, forming the *funiculus anterior*, *funiculus lateralis* and *funiculus posterior* (Fig. 101). These three great columns occupy the anterior, lateral and posterior areas of the cord. They are disposed around the gray crescent in bundles or tracts. The tracts which make up the funiculi are not visible to the naked eye, nor under the microscope in a healthy adult cord; they have been located by embryological, experimental and pathological investigations. The longitudinal fibers rise in the brain, in the spinal cord and in the spinal ganglia; some run upward and others downward, constituting the tracts of the cord. Thus the tracts are characterized as ascending, descending and mixed tracts.

Ascending Tracts: (1) Ascending anterior cerebello-spinal and spino-thalamic tract. (2) Cerebello-spinal tract (direct cerebellar) with the spino-vestibular tract. (3) Marginal tract (of Lissauer). (4) Fasciculus cuneatus. (5) Fasciculus gracilis. (6) Ciaglinski's long sensory tract, in the posterior commissure.

Descending Tracts: (1) Anterior (direct) pyramidal tract, including the anterior longitudinal bundle. (2) Lateral (crossed) pyramidal tract. (3) Descending anterior cerebello-spinal tract, including Helwig's tract. (4) Rubro-spinal tract (Pawlow). (5) Descending postero-medial tract, called at different levels the comma, oval, and septo-marginal tract. (6) Descending postero-lateral tract.

Mixed, Ascending and Descending Tracts: (1) The anterior fasciculus proprius, including the medial longitudinal bundle. (2) Lateral fasciculus proprius. (3) The posterior fasciculus proprius, composed of the cornu-commissural tract, the septal bandalette of Hoche, and possibly a part of the comma, oval, septo-marginal and the descending postero-lateral tract (Cunningham).

The methods of locating tracts of fibers may be summarized briefly, as follows:

The **embryological method** was first employed successfully

by Flechsig. He found that nerve fibers when first laid down are naked axones without any insulating white substance of Schwann ensheathing them. That the medullary sheaths are developed at different times and that the medullation is nearly coincident with the beginning of function. Thus the fibers of motor and sensory nerves are *first* to become medullated, since life cannot be sustained without the automatic mechanism. *Second*, the fasciculi proprii of the cord are medullated and, *third*, the cerebellar tracts. At this stage the simple automatic and coordinating mechanisms are complete. *Fourth*, the voluntary motor mechanism is established by the medullation of the tracts connecting the lower neurones with the cerebral cortex, the fibers of the pyramidal tracts being the last to receive their medullary sheaths. This last occurs just before birth. *Fibers of the cerebrum concerned with the higher psychic functions* of the brain become medullated gradually, year after year, keeping pace with the mental development; and the process of medullation there is not completed until late in life (Kaes).

The **pathological and experimental methods** depend upon the fact that a nerve fiber when severed from the cell-body undergoes degeneration in accordance with the *law of Waller*. If the severed fiber be above the cell-body, the degeneration occurs above the lesion and is called ascending degeneration; but, if the degeneration extends from the lesion down the nerve fiber, the cell-body being above, then the condition is called descending degeneration, though all parts of the severed fibers really degenerate simultaneously. Thus by studying the paths of degeneration, above and below a destructive lesion in the human cerebro-spinal axis, the various tracts of fibers have been discovered and many of them charted and traced from origin to termination. These investigations have been greatly aided by the study of degenerations in the brain and cord of lower animals. These degenerations are the results of definite experimental lesions, as cutting of certain posterior nerve roots, partial section, hemisection or complete section of the spinal cord, etc. The pathological and experimental methods are commonly called the *physiological method*.

TRACTS OF THE SPINAL CORD.

The **antero-lateral fasciculus proprius** (*fasciculus antero-lateralis proprius*) occupies the deep part of the anterior and lateral columns (Figs. 102 and 103). It embraces the anterior column of gray matter and covers the outer surface of the center of the crescent and the base of the posterior column. By the most lateral anterior root-fibers it is subdivided into *anterior* and *lateral fasciculi*. It approaches, but does not quite reach, the surface of the cord. Notice that it is separated from the anterior median fissure by the anterior pyramidal tract, and that the anterior cerebello-spinal and spino-thalamic tracts run between it and the surface of the cord. Behind, it is in relation with the lateral pyramidal tract. The antero-lateral fasciculus proprius is composed of ascending and descending fibers which are the T-branches of axones from the gray crescent. It is largely a short fiber tract, *associative and commissural in junction*. That part situated in the anterior column, the *anterior fasciculus proprius*, is largely commissural, between the anterior columnæ; while the *lateral fasciculus proprius* is chiefly associative, and connects different segments of the cord on the same side. The antero-lateral fasciculus proprius is continued in the substantia reticularis of the medulla, and the reticular formation of pons and mid-brain, constituting a short fiber tract which extends from the lower part of the cord to the basal ganglia of the cerebrum. In the anterior fasciculus proprius there is a strand of long fibers called the medial longitudinal bundle (*fasciculus longitudinalis medialis*).

The *medial (posterior) longitudinal bundle* is composed of an *ascending* and a *descending strand* of fibers (Figs. 102 and 103). The **ascending strand** rises from the anterior column in each segment of the spinal cord and runs upward to the motor nuclei of cerebral nerves and terminates in them. Perhaps a few fibers reach the thalamus. It ascends just ventro-medial to the anterior column in the cord; in the medulla, it runs between the head of the anterior column and the pyramidal decussation, then just lateral to the fillet decussation, after which, it takes its dorso-medial position along the raphe. Its *junction is reflex*. The **descending**

strand is the *medial ponto-spinal tract* (Collieri). It rises from all the nuclei of the reticular formation but chiefly from the nuclei centrales and the nucleus lateralis medius in the pons. Forming a part of the medial longitudinal bundle of the same side, its fibers end in the center of the crescent as it descends the cord. Within the *lateral fasciculus proprius*, descends the *lateral ponto-spinal tract* (Collieri). This tract has the same origin and termination as the medial ponto-spinal tract except that it decussates. It crosses near its origin right through the medial longitudinal bundles. Both ponto-spinal tracts extend to the lower part of the cord.

The **anterior pyramidal tract** (*fasciculus cerebro-spinalis anterior*), occupies a thin area next the anterior median fissure (Figs. 102 and 103). It is the *direct* continuation of about 10 per cent. of the pyramidal tract in the medulla. Its fibers are axones of cortical cells whose bodies are situated in the anterior central gyrus of the cerebrum. As the tract descends in the cord, the fibers decussate through the white anterior commissure, and terminate in relation with the cells of the opposite gray crescent, probably, in the posterior column. It reaches to the fifth sacral segment (Collier). Imbedded in the anterior pyramidal tract is a small strand first described by Held, the anterior longitudinal bundle.

Anterior Longitudinal Bundle (Figs. 102 and 103).—Held called it the *fasciculus longitudinalis ventralis*. It occupies a very narrow strip in the anterior column just beside the entrance of the anterior median fissure. The anterior longitudinal bundle has already been traced from its origin in the superior quadrigeminal colliculus, through the dorsal tegmented decussation (Meynerti) to a position in the mid-brain ventro-lateral from the medial longitudinal bundle. It descends in that relative position through the pons and half the medulla; near the pyramidal decussation the anterior and medial longitudinal bundles are brought together and lie between that decussation and the isolated head of the anterior column; they diverge upon entering the cord and remain separate to the end. The anterior longitudinal bundle ends in both anterior columnæ (Collier). It forms the *middle link in the ocular and pupillary reflex arcs*.

The **descending anterior cerebello-spinal tract** (*fasciculus descendens cerebello-spinalis anterior*—Marchi's, Tschermak's and Loewenthal's column) together with the ascending anterior cerebello-spinal tract, occupies a thin peripheral area, broadest posteriorly, which extends from the anterior pyramidal tract outward and backward, over the antero-lateral fasciculus proprius, to the middle of the lateral surface of the cord (Figs. 102 and 103). Its posterior border is in relation with the (posterior) cerebello-spinal tract and the lateral pyramidal tract. The fibers of the two anterior cerebello-spinal tracts are mingled together; but the descending fibers are found, chiefly, in the anterior and postero-medial part of the common area and the ascending in the postero-lateral part. The tract is almost completely relayed in the medulla. The descending fibers, in the first stage, are axones from the cortical cells of Purkinje in the cerebellum and from the nucleus fastigii and perhaps the other cerebellar ganglia. They descend to the nucleus of Deiters through the brachium pontis cerebelli. There the greater number end and new fibers rise which continue the tract down the cord. In all probability the cerebello-olivary fibers in the restiform body, and the olivo-spinal fibers, forming the tract of Helwig in the cord, should be included in the descending cerebellar tract. It terminates in the gray substance of the spinal cord and directly or by the intervention of intrinsic spinal neurones is connected with the motor cells of the anterior column. The descending cerebello-spinal tract forms one segment of an *indirect motor path*; and, together with the intrinsic and anterior column neurones, it forms the efferent limb of a *reflex arc of muscular tonicity, coordination and equilibrium*. Scattered among the vestibulo-spinal fibers in the posterior part of the anterior descending cerebello-spinal tract are descending fibers from the thalamus and quadrigeminal colliculi which end in the gray crescent.

Ascending Anterior Cerebello-spinal and Spino-thalamic Tract. (*Fasciculus ascendens cerebello-spinalis anterior*, Gowersi).—These form a single tract in the cord which is found chiefly in the postero-lateral part of the area common to it and the descending anterior cerebello-spinal tract (Figs. 102 and 103). It is composed

of axonic processes of cells whose bodies are situated in the center of the crescent and base of the anterior column, chiefly on the opposite side of the cord (v. Lenhossek). Most of the fibers of the ascending anterior cerebello-spinal and spino-thalamic tract cross near their origin through the white anterior commissure of the cord. In the medulla, the tract ascends through the dorsal part of the lateral area, sending collaterals to the inferior lateral nucleus; it then continues, through the *formatio reticularis* of the pons, to a point near the inferior quadrigeminal colliculus, where the *cerebellar part* is bent backward under the *brachium conjunctivum*, and enters the *vermis cerebelli superior* through the superior medullary velum (Hoche). The *spino-thalamic portion* continues to the thalamus, sending some fibers to the quadrigeminal colliculi (Mott) and others to the substantia nigra and lentiform nucleus (Rossolimo). The anterior ascending cerebello-spinal and spino-thalamic tract carries tactile, pain, and temperature impulses. The *triangular tract of Helwig* (*fasciculus olivaris*) is found on the surface near the middle of the area common to the anterior cerebello-spinal tracts (Figs. 102 and 103). It descends just lateral to the anterior nerve roots and may be traced to the lumbar region, where its longest fibers end. It probably rises in the olive of the medulla oblongata and is *efferent in conduction*.

The (posterior) **cerebello-spinal tract** (*direct cerebellar*) (*fasciculus cerebello-spinalis [posterior]*) runs posterior to the other cerebello-spinal tracts (Fig. 102). It is superficially located, and in section extends from the middle of the lateral surface of the cord back to the posterior lateral sulcus as far down as the lumbar cord. Below the second lumbar segment its absence allows the lateral pyramidal tract to come to the surface. The (posterior) cerebello-spinal tract runs from the dorsal nucleus (Clarki) of the cord to the superior worm of the cerebellum. Its fibers are axones of vesicular cells in that nucleus. In the medulla, it forms a part of the restiform body. It conveys impulses of the muscular sense, received, especially, from the viscera (?). In the dorso-lateral part of the cerebello-spinal tract is a small strand of fibers discovered by Horsley and Thiele in 1901, called the *spino-vestibular tract*. It rises in the lumbo-sacral region

of the cord and, ascending along the surface of the cerebello-spinal tract to the medulla, it winds inward dorsal to the restiform body and terminates in the nucleus of the descending root of the vestibular nerve.

The **lateral pyramidal tract** (*fasciculus cerebro-spinalis lateralis*) forms a considerable part of the lateral column of the spinal cord (Figs. 102 and 103). It is covered, superficially, by the cerebello-spinal tracts in the cervical and thoracic cord; but in the lumbar and sacral cord it forms part of the surface. Its deep surface is in relation with the posterior column of gray matter, the lateral fasciculus proprius and the marginal bundle. The fibers composing it are axones of cell-bodies in the anterior central gyrus of the cerebral cortex. They rise with those of the anterior pyramidal tract, and the two run as one tract down through the genu and anterior two-thirds of the occipital part of the internal capsule, the middle three-fifths of the basis pedunculi, the anterior longitudinal fibers of the pons and the pyramid of the medulla. In the medulla the two tracts separate. The *lateral tract*, comprising four-fifths of the pyramid, decussates with its fellow through the anterior median fissure, pierces the anterior gray column and descends with some uncrossed fibers in the lateral column of the cord. It terminates in relation with the cell-bodies within the posterior column, according to Schäfer, Collier and others. The *anterior tract* follows the anterior median fissure as already described. Both end chiefly in the gray crescent opposite to their cortical origin. According to Marchi, ten or twenty per cent. of the fibers remain uncrossed. The pyramidal tracts are the cerebral *motor tracts*. By them *motor and inhibitory impulses* are carried to the cord. In the outer part of the lateral pyramidal area is found the crossed descending tract of the red nucleus, the rubro-spinal tract (Pawlow).

The Rubro-spinal Tract (Fig. 102).—It extends as far as the first lumbar segment and ends in the center of the gray crescent. Its origin in the nucleus ruber, its crossing through the ventral tegmental decussation (Foreli) and its course down the brain stem have been described. The rubro-spinal tract is descending *in direction*.

Lesions.—The pyramidal tracts (especially the lateral) are involved in lateral sclerosis and in amyotrophic lateral sclerosis; and, as a consequence of it, both voluntary and inhibitory impulses from the brain are interfered with, hence the spastic paralysis and exaggerated reflexes. The pyramidal tract may be more or less involved in insular sclerosis and in bulbar paralysis, and the symptoms vary with the amount of sclerosis. Gliosis of the pyramidal, cerebello-spinal and posterior tracts (Dejerine and Letulle) has been demonstrated in Friedreich's hereditary ataxia, and the involvement of the pyramidal tracts explains the spastic paralysis which affects both arms and legs. In ataxic paraplegia (Gowersi) there is diffuse sclerosis of the lateral and posterior columns of the cord. It is the degeneration in the pyramidal tracts that causes the spastic gait, incoordinated arm movements and early increase of the reflexes, observed in that affection.

The **marginal tract** (*fasciculus marginalis*, Lissaueri) is a small tract composed of the ascending branches from the outer set of fibers in the posterior roots of the spinal nerves (Figs. 102 and 103). It is situated in the lateral column on the outer surface and apex of the posterior column. Its fibers are of small caliber and, after ascending a short distance, end about the cell-bodies of the substantia gelatinosa.

Tracts of the Posterior Column of the Cord (Fig. 101).—In the posterior column of the spinal cord, there are, *first*, two ascending and two descending tracts, derived from posterior nerve roots; *second*, the posterior fasciculus proprius, which is much scattered and is little understood; and, *third*, the entry zone occupied by the incoming fibers of the posterior roots.

Entry Zone (Figs. 102 and 103).—Over the apex and along the medial surface of the posterior column of gray substance the posterior roots of the spinal nerves enter the cord and divide T-like into ascending and descending branches. The name entry zone is well applied to this region. The presence of horizontal fibers distinguishes the entry zone from the longitudinal tracts. The root-fibers of small caliber and many collaterals very soon enter the gray substance. The large fibers, in part, enter the dorsal nucleus, but the greater number form the longit-

udinal tracts of the posterior column. The *ascending fibers* begin their upward course in the entry zone. As they ascend they are crowded toward the median septum by the entrance of new root-fibers in the succeeding upper segments. So the fibers near the septum are those which enter low down in the cord and those close to the posterior column are of recent entrance into the cord. The *descending T-branches* and collaterals of the posterior roots begin their descent also in the entry zone. Some of them run a long course, even from the sixth cervical to the sacral segments (Collier). The greater number are much shorter. From above downward they are crowded in a dorso-medial direction, like the ascending fibers; and, after a considerable downward course, they plunge forward through the white column to end in the posterior column. These ascending and descending fibers, whose origin is in the spinal ganglia on the posterior roots of the spinal nerves, together with the fibers of the posterior fasciculus proprius which rise in the posterior column, constitute the longitudinal tracts of the posterior column of the spinal cord. That posterior column is undivided by any sulcus below the eighth thoracic segment, where the posterior intermediate furrow and septum fade away; but, above that level, it is subdivided into two distinct ascending tracts, a postero-medial, the fasciculus gracilis, and a postero-lateral, the fasciculus cuneatus (Fig. 102). These two tracts are alike in constitution. They have the same *junction*, carrying impressions of the muscular and tactile senses. They differ only in length; the fibers of the fasciculus gracilis come from the spinal nerves below the eighth thoracic, while those of the fasciculus cuneatus come entirely from thoracic and cervical nerves.

Fasciculus Gracilis (Ascending Postero-medial Tract, Goll's Column).—This tract may be said to begin at the entrance of the posterior root of the coccygeal nerve (Figs. 102 and 103). It ascends along the posterior median septum to the nucleus funiculi gracilis of the medulla. Up to the lower thoracic nerves it gradually enlarges, due to the acquisition of successive posterior root-fibers; and in this region, excepting only the entry zone and the descending branches of the posterior roots, it comprises the whole

extrinsic part of the posterior column. Its size is uniform in the upper three-fourths of the cord, where the posterior intermediate furrow separates it from the fasciculus cuneatus. In depth it reaches to the posterior commissure. Its fibers are the ascending branches of the spinal ganglia cells. Arriving at the clava, all the fibers of the fasciculus gracilis arborize and end in the nucleus funiculi gracilis.

Fasciculus Cuneatus (Ascending Postero-lateral Tract, Burdach's Column).—Beginning in the lower thoracic segments (Fig. 102) the fasciculus cuneatus ascends between the entry zone and the fasciculus gracilis to the nucleus funiculi cuneati of the medulla. It acquires new fibers from every spinal nerve above its origin and grows stronger up to the first cervical nerve. In section it is wedge-shaped, being broadest at the surface; the edge of the wedge touches the junction of the posterior column and posterior commissure. Its fibers are ascending, and are branches of the axones of spinal ganglia cells, like the fasciculus gracilis. In the nucleus funiculi cuneati all its fibers arborize and terminate (Collier).

Descending Tracts Derived from Posterior Roots.—The descending fibers from the posterior roots of the spinal nerves arrange themselves somewhat roughly into two tracts, a postero-lateral and a postero-medial (Figs. 102 and 103). These descending radicular tracts greatly expand and multiply the terminal relations of the posterior root-fibers. Mingled with them, there are many fibers of the posterior fasciculus proprius.

The **descending postero-medial tract** (Figs. 102 and 103) has received various names at different levels. In the cervical and upper nine thoracic segments, it is the **comma tract** (of Schultze), situated in the fasciculus cuneatus. Its ventral part disappears in the posterior column above the tenth segment, but the remainder continues down the cord. Shifting its position in a dorso-medial direction, it takes its place beside the median septum and gradually approaches the cord's posterior surface. It continues in that situation to the end of the cord, and is called, in succession, the **oval tract** (of Flechsig), the **septo-marginal tract** (of Bruce and Muir), and the **median triangular tract**

(of Gambault and Phillippe). Fibers from the spinal nerves enter this postero-medial descending tract in the cervical, thoracic, and, at least, the upper lumbar segments. After a variable course within the tract, the fibers plunge forward into the posterior columna of gray substance where they terminate.

The **descending postero-lateral tract** (Fig. 103), situated at the posterior surface of the cord medial to the entry zone, in the lumbo-sacral region, appears to have been first described by Thiele and Horsley. It is very largely endogenous, but contains a number of root-fibers (Collier). In section it is triangular. Its fibers terminate in the posterior columna of gray substance. Both the descending radicular tracts are intermingled with endogenous fibers that belong to the fasciculus proprius.

Posterior Fasciculus Proprius. (*Fasciculus posterior proprius*).—This is made up of association fibers that connect different segments of the cord. It is not a compact strand. Its fibers are scattered throughout the posterior column, but they are especially numerous in the descending radicular tracts, in the region along the ventral one-third of the septum (the *bandelette* of Hoche) and in the cornu commissural field of Marie (Figs. 102 and 103).

The **cornu commissural tract** (Fig. 103) is placed between the posterior column (cornu), the posterior commissure and the posterior septum. It extends up to the eleventh thoracic segment and downward to the end of the cord. It contains both ascending and descending fibers as do other parts of the fasciculus proprius.

Lesions in the posterior columns cause disturbances of the muscular and tactile senses, and ataxia and incoordination result. If the entry zone is involved there is disturbance of all kinds of common sensation, at the level of the lesion. These columns are usually involved, by extension from the posterior roots, in locomotor ataxia (posterior sclerosis), hence the *paræsthesia*, crises, loss of reflexes, disturbed equilibrium and ataxic gait.

ROOTS OF THE SPINAL NERVES.

Thirty-one pairs of spinal nerves connect the cord with the periphery. Each nerve is joined to the cord by two roots: an *ante-*

rior, efferent or motor root and a *posterior, afferent or sensory root* (Figs. 100 and 104). These roots descend more or less from their cord attachment to the inter-vertebral foramen in which they unite to form the spinal nerve. The roots of the first cervical nerve are horizontal; those of the first thoracic nerve descend the width of two vertebræ, and those of the twelfth thoracic, the width of four vertebræ; while the roots of the coccygeal nerve extend from the first lumbar vertebra to the second piece of the coccyx, through ten vertebræ.

Anterior Root.—In all spinal nerves, except the first, the anterior root (*radix anterior*) is smaller than the posterior. It is composed of from four to six fasciculi, which soon combine into two bundles. After piercing the dura mater, the anterior root unites with the posterior, beyond the latter's ganglion, and forms a spinal nerve. The anterior root is *efferent, or motor, in junction*.

Apparent Origin (Fig. 104).—The anterior root is composed of medullated axones which issue from the narrow longitudinal area at the junction of the anterior one-fourth with the posterior three-fourths of the cord's surface. This area is bounded laterally by the anterior root-line, commonly called the anterior lateral sulcus.

Real Origin (Fig. 104).—These medullated axones rise from the medial, lateral, and intermedio-lateral columns of cell-bodies on the same side of the cord and from the medial column of the opposite side. These cell-bodies of the anterior columnæ and the intermedio-lateral column constitute the *genetic nuclei (nuclei origines)* of the spinal nerves. The fibers of large caliber in the anterior roots rise from the cell-bodies in the anterior columnæ. They are *voluntary motor fibers*. In the intermedio-lateral column, the small fibers of the anterior roots take their origin. They are probably *sympathetic in junction*, that is, involuntary motor, vaso-motor, visceromotor, inhibitory, secretory, trophic, inhibito-secretory, and inhibito-trophic.

Lesions.—The lower motor neurones (spinal and cerebral) are probably in a state of toxic irritation in laryngismus stridulus, tetanus, acute ascending paralysis (Landry), strychnine poisoning,

etc., hence the twitchings, spasms and convulsions. Their destruction causes flaccid paralysis (lower segment paralysis). In spinal meningitis both the anterior and posterior roots are affected.

The **posterior root** (*radix posterior*) is the sensory, or afferent root (Figs. 100 and 104). It is larger than the anterior root, except in the case of the first cervical nerve; and is composed of from six to eight fasciculi, which also combine at once into two bundles. The posterior root pierces the dura mater separately from the anterior root. It unites with the anterior root in the intervertebral foramen. Near the outer end, it presents a swelling which contains large vesicular *unipolar cell-bodies* and is called a *spinal ganglion* (*ganglion spinale*). The ganglion (Figs. 100 and 128) and posterior root are occasionally absent on the first nerve. The posterior root, external to the ganglion, is made up of the dendritic processes (Cajal) of the ganglion cells. These dendrites, which in appearance are axones, extend to the most distant parts of the body; they are the sensory fibers of the spinal nerves. On the proximal side of the ganglion, the posterior root is composed of axones, which rise from the ganglion cells. Both the axonic and dendritic processes are medullated.

Apparent Central Termination (Fig. 104).—The posterior roots of the spinal nerves enter the posterior-lateral sulcus; and, at once, divide into an outer set of small fibers and an inner set of large fibers with some small ones interspersed. The fibers of each set bifurcate into a large ascending and a smaller descending branch. Collaterals rise from the parent axone and from both branches.

Real Central Termination, Terminal Nuclei (Fig. 104).—The ascending divisions of the outer set of fibers run a short distance along the external surface of the posterior column, and end in ramifications about the cell bodies of the substantia gelatinosa. They form the *marginal tract* (of Lissauer). Probably their descending branches have the same ending. The T-branches and collaterals of the inner set of fibers from the posterior root run: (1) **To the gray matter of the cord, viz.:** To all parts of the posterior column, to the center of the crescent, and to the anterior column on the same side, and, through the posterior commis-

sure, to the center and columnæ of the opposite crescent. These fibers end in relation with the dendrites or cell-bodies situated in those several regions of the crescent at various levels: (a) At the same level as the nerve, (b) at a lower level than the nerve, through the descending radicular tracts, and (c) at a higher level, through the collaterals given off by the ascending tracts. (2) The large ascending T-branches of the inner set of fibers run **to the medulla oblongata**. They form the fasciculus gracilis and fasciculus cuneatus and ascend to the nuclei of those columns in the medulla oblongata. They terminate in the nuclei funiculi gracilis and cuneati. Hence the *terminal nuclei* (*nn. terminales*) of any spinal nerve are composed of the *gray crescents* of the cord, chiefly at the same level, and of the *nucleus funiculi gracilis* or the *nucleus funiculi cuneati* in the medulla.

Physiologically, we may divide the fibers of the posterior roots of the spinal nerves into *four groups*, viz.: 1. Excito-reflex fibers which terminate in all parts of both crescents. 2. Fibers bearing impulses of the muscular and tactile senses from muscles, tendons, joints and skin, through the posterior column, to the nucleus funiculi gracilis and nucleus funiculi cuneati. 3. Fibers carrying impulses of the muscular sense from the viscera to the dorsal nucleus. 4. Fibers transmitting pain, temperature and tactile impulses to that part of the same and opposite crescent whence the spino-thalamic and ascending anterior cerebello-spinal tracts take their origin.

Lesions.—The posterior roots of the spinal nerves and the spinal ganglia are affected in locomotor ataxia, and the lesion extends to the marginal tract (of Lissauer) and the posterior column of the cord. Excepting the fasciculus proprius, the whole posterior column becomes involved.

CHAPTER VII.

TRACING OF IMPULSES.

Having studied the grouping and chaining together of neurones, let us now make the knowledge practical by tracing impulses through the better known paths formed by these various neurone groups. The paths thus formed are of three kinds, namely: I. Efferent, or motor. II. Afferent, or sensory—general and special sense. III. Reflex.

I. EFFERENT, OR MOTOR PATHS.

The **CEREBRO-SPINAL OR PYRAMIDAL PATHS** (Fig. 105) are direct, as they do not pass through the cerebellum. Their impulses ultimately run either through the spinal or the cerebral nerves, and are both motor and inhibitory. Hence the increased reflexes and spastic contractions of lateral sclerosis in which these tracts are diseased.

1. **Through the Spinal Nerves** (Fig. 105).—Starting in the upper three-fourths of the gyrus centralis anterior of the cerebral cortex, motor and inhibitory impulses run down through the corona radiata, the anterior two-thirds of the occipital part of the internal capsule, the middle three-fifths of the basis pedunculi, the anterior longitudinal fibers of the pons, and the pyramid of the medulla oblongata, whence they proceed by the *lateral and anterior pyramidal tracts* to the gray crescent, partly in the same side but chiefly in the opposite side of the spinal cord. By the former route, the impulses cross over in the medulla, through the decussation of the pyramids, and descend in the lateral column of the spinal cord to the gray substance in the vicinity of the nucleus dorsalis (Clark), where the path is relayed, and intrinsic neurones carry the impulses forward into the anterior column; but by the anterior route, they descend in the anterior column of the cord and decussate, in succession, through the white anterior com-

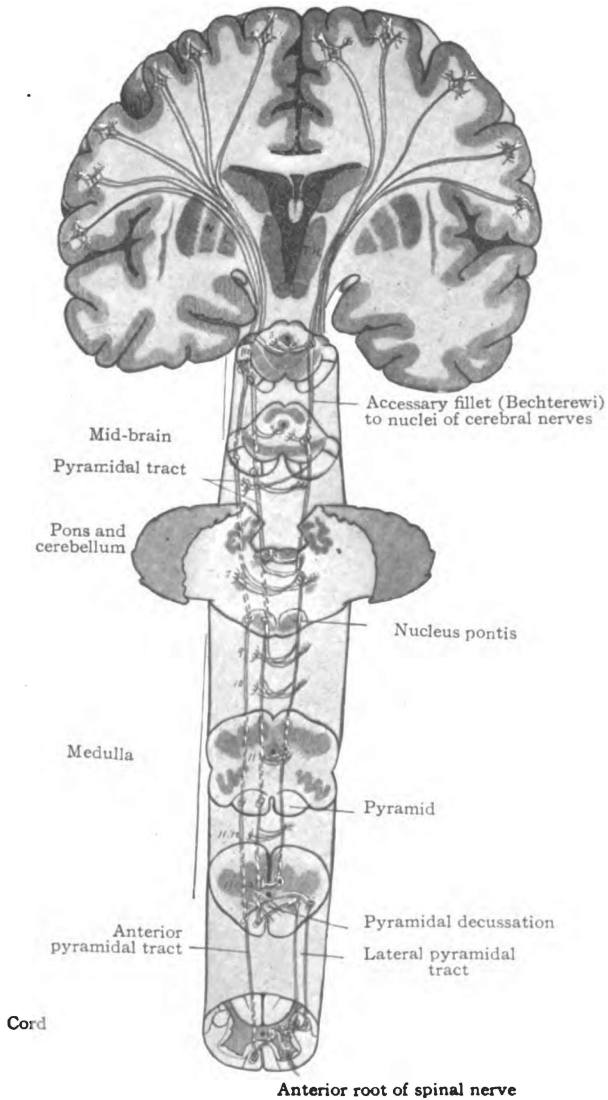


Fig. 105.—Direct motor paths from cerebral cortex, to cerebral and spinal nerves. Diagrammatic. (Original.)

Motor paths extending from the cortex of the anterior central gyrus to the nuclei of the motor cerebral nerves and of the anterior roots of the spinal nerves; ⊙ represents point where the section is pierced by a longitudinal fiber; 3, 4, 5, 6, 7, 9, 10, 11, and 12, nuclei of cerebral nerves.

missure. Impulses by either route finally reach the anterior gray columna of the spinal cord and, with the exception of a small per cent. of them, they reach the columna opposite to their cortical origin. The few undecussated fibers in the lateral pyramidal tract conduct uncrossed impulses to the anterior columna of the same side. Thus are explained two symptoms of hemiplegia due to cerebral lesion, viz., weakness on the well side and slight motion on the paralyzed side. From the anterior gray columna of the spinal cord the nerve commotions are conducted by the efferent, or motor fibers of the spinal nerves to the muscles.

2. **Through the Cerebral Nerves** (Fig. 105).—Impulses destined to the cerebral nerves run chiefly from the lower two-fourths of the anterior central gyrus through corona radiata, genu of internal capsule and on, by the same path as the impulses to spinal nerves, down to the point where they leave the pyramidal tract to enter the nuclei of the cerebral nerves, which some of them do in the vicinity of the several nuclei. According to Bechterew they run, at least in part, through pyramidal fibers which constitute the *accessory lemniscus*. These fibers leave the pyramidal tract near the internal capsule, and descend through the medial portion of the fillet to points near the respective nuclei in which they end by multiple division. From either hemisphere impulses proceed to the nuclei of both sides. But the greater number enter the nucleus of the fourth nerve on the same side, and the nuclei of the third, fifth, sixth, seventh, ninth, tenth, eleventh and twelfth cerebral nerves of the opposite side. By the above nine nerves innervation is conducted to the muscles of the orbit; the muscles of mastication, and expression; the muscles of the tongue, palate and ear; the digastric and styloid muscles; the muscles of the larynx, trachea and bronchi, and of the pharynx, esophagus, stomach, and the intestines down to the descending colon. And inhibitory impulses are carried to the heart; also vasodilator, secretory, trophic and inhibito-secretory impulses to alimentary glands, etc.

THE CEREBRO-PONTAL PATHS, FRONTAL, TEMPORAL AND INTERMEDIATE.—These paths are indirect, for spinal nerves, since they run through the cerebellum.

Fronto-pontal (Fig. 106).—The impulses originate in the frontal region (?), and descend through corona radiata, the frontal part of the internal capsule, and the medial fifth of the basis pedunculi to the nucleus pontis. **Temporo-pontal**.—They rise in the temporal cortex and run through corona radiata, the occipital part and inferior lamina of the internal capsule, and the lateral fifth of the basis pedunculi to the nucleus pontis. Both the fronto-pontal and the temporo-pontal paths are probably relayed in the corpus striatum or the thalamus. **Intermediate Bundle**.—Cortical impulses of unknown origin are received by the corpus striatum and conveyed, by a bundle of centrifugal axones which form the deep portion of the basis pedunculi, to the substantia nigra and then to the nucleus pontis, chiefly of the same side. The impulses thus traverse the internal capsule and a broad but thin area in the basis pedunculi just ventral to the substantia nigra and dorsal to the pyramidal tract. In all three of these paths the impulses run to the nucleus pontis of the same side and to motor nuclei of the cerebral nerves. Whence they proceed from nucleus pontis: (1) *To Spinal Nerves*. They run through the brachium pontis to the cerebellar cortex and, thence, continue down the anterior descending cerebello-spinal tract to the anterior gray column of the spinal cord. Their course from the cerebellar cortex is through the acustico-cerebellar tract and the restiform body, the lateral area of the medulla and the antero-lateral column of the cord. From the gray matter of the spinal cord the impulses are conveyed by the motor fibers of the spinal nerves to the muscles which they supply. (2) *To Cerebral Nerves*. The impulses run from the synapses formed in the cerebral nuclei, by the fibers of the cerebro-pontal tracts, through the motor fibers of these nerves to their distribution.

PATHS THROUGH THE RED NUCLEUS (Fig. 106).—There are two, a direct and an indirect. Impulses run from some part of the cerebral cortex to the thalamus and red nucleus or to the corpus striatum and red nucleus. From the red nucleus they pursue either a direct or indirect route.

(1) **Direct Route, The Rubro-spinal Path**.—By the direct route, impulses run through the crossed descending tract of the

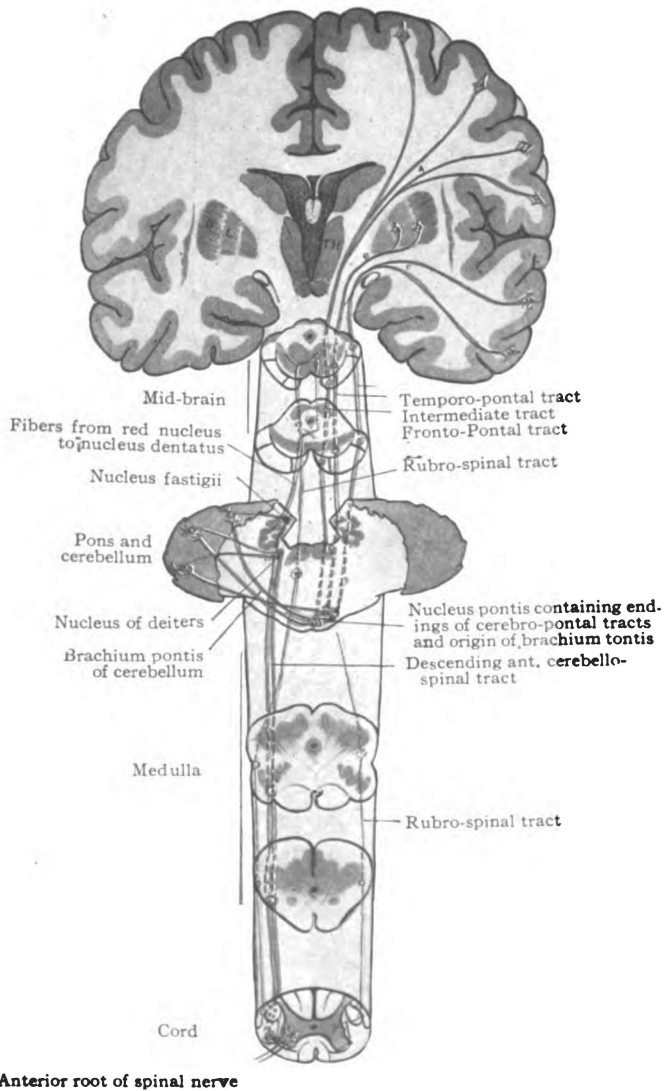


Fig. 106.—Indirect motor paths to the spinal nerves. Diagrammatic. (Original.)

Motor paths from cerebral cortex through the cerebellum to spinal nerves. A. Fronto-pontal tract rising in frontal lobe. B. Intermediate tract rising in lentiform nucleus. C. Temporo-pontal tract rising in middle and inferior temporal gyri. Also rubro-spinal tract. © © represent points of perforation in the sections.

red nucleus to the center of the gray crescent in the opposite side of the spinal cord. Crossing the median raphe at once, in the hypothalamic region through the ventral tegmental decussation, (Foreli), the impulses descend by way of the rubro-spinal tract, through the ventral part of the formatio reticularis of the mid-brain and pons, in the medial part of the lateral fillet, then through the lateral area of the medulla, among the fibers of the anterior ascending cerebello-spinal tract, and finally down the spinal cord, through the ventral portion of the lateral pyramidal area, to their destination in the gray matter. From the center of the gray crescent they proceed with or without transferring to the roots of the spinal nerves, and are conducted to the muscles.

(2) **Indirect Route.**—Impulses from the red nucleus may also run through the brachium conjunctivum, chiefly the opposite one, to the nucleus dentatus; and thence, by axones from that nucleus, down the anterior descending cerebello-spinal tract, which continues their path to the column anterior of the cord.

PONTO-SPINAL PATHS.—The ponto-spinal tract is the name suggested by Collier for the tracts originating in the nuclei of the reticular formation, chiefly in the pons, and descending to the gray matter of the spinal cord. There are two of them on either side. The **medial ponto-spinal tract** accompanies the medial longitudinal bundle down the anterior ground bundle of the cord without decussating, unless the crossing occurs near the termination. The **lateral ponto-spinal tract**, which is crossed, decussates in the brain stem near its origins and descends in the lateral column of the spinal cord. Just how the impulses reach the nuclei centrales and nuclei laterales of the formatio reticularis, in which the ponto-spinal tracts take their origins, cannot be definitely stated; but, having arrived in them, they descend to both crescents of the spinal cord and apparently enter into all its segments. The anterior nerve roots complete the paths.

Short Fiber Paths.—Those are paths in the formatio reticularis chiefly. (1) Impulses having reached the great ganglia of the cerebrum and mid-brain may run through many relays down the formatio reticularis of mid-brain, pons and medulla and the antero-lateral fasciculus proprius of the spinal cord, to the gray

crescent of the same, and continue through the anterior root-fibers to their destination. On the other hand, the impulses, leaving *formatio reticularis* in mid-brain, pons or medulla, may enter the nuclei of motor cerebral nerves and be conducted by them to the muscles and glands supplied by cerebral nerves. (2) The impulses may leave the *formatio reticularis* in the pons, and run to the cerebellar cortex through the *brachium pontis*. From the cerebellum they may follow the ordinary course through the anterior descending cerebello-spinal tract, by way of the nucleus of Deiters, to the anterior gray column of the cord. (3) Impulses having arrived at the cerebellar cortex by way of the *brachia conjunctiva* and *brachia pontis*, may descend through the cerebello-olivary tract, in the restiform body, to the opposite inferior olive, and be carried on through descending axones of the olive, in the lateral column, to the gray matter of the cord (Kölliker). (4) Impulses descend from the nucleus of the third cerebral nerve by way of certain fibers in the medial longitudinal bundle to the seventh nerve, where it enters into the *colliculus facialis*, and through the facial nerve innervate the following muscles—the *frontalis*, *procerus*, *corrugator* and *orbicularis oculi*. Hence these muscles are not paralyzed in nuclear facial paralysis. But if the lesion be in the *colliculus facialis* or distal to it, then facial paralysis is complete. (5) At the same eminence, impulses pass into the facial nerve from the hypoglossal nucleus via a small strand of axones which rises in the hypoglossal nucleus and runs through the medial longitudinal bundle into the facial at the genu (?). These impulses innervate the *orbicularis oris*. (6) Through certain short fibers in the medial longitudinal bundle which rise in the nucleus of the sixth cerebral nerve and cross to the opposite nucleus of the motor oculi, impulses run from the nucleus of the abducent through the opposite third nerve to the internal rectus oculi. They explain the conjugate action of the eyes in health, and also the conjugate deviation observed in lesions affecting the nucleus of the sixth nerve. In nuclear lesions of the abducent nerve the external rectus of the same eye and the internal rectus of the other eye are paralyzed if the nucleus is destroyed and stimulated if the nucleus is only irritated.

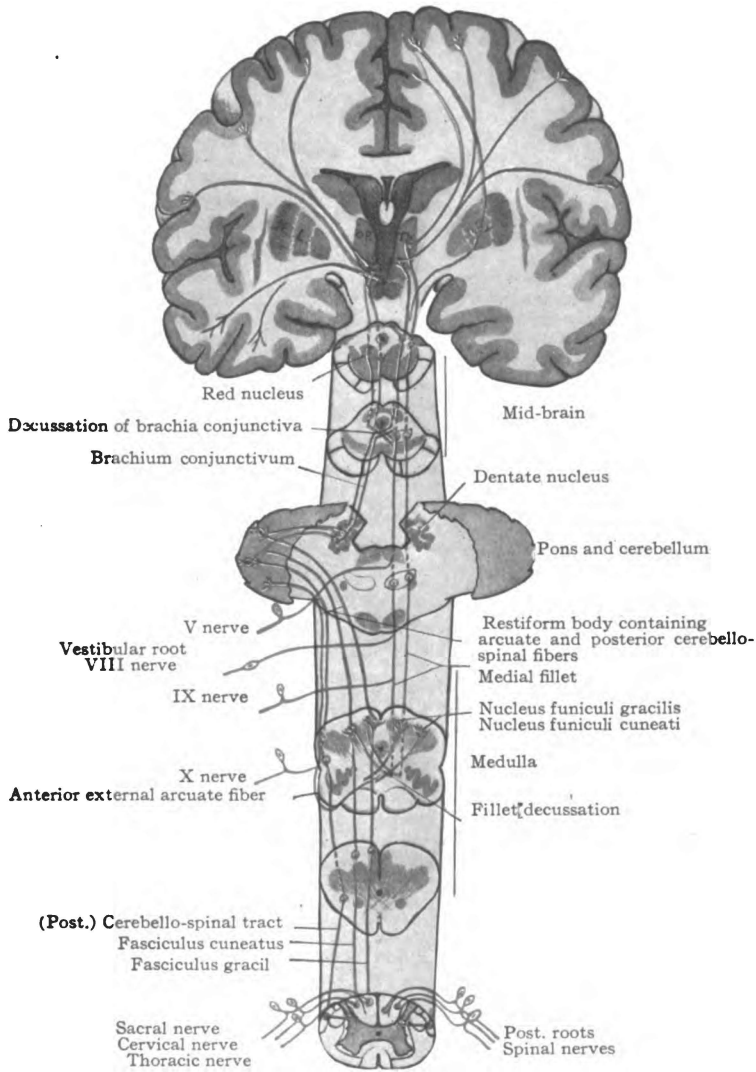


Fig. 107.—Common sensory paths, muscular and tactile, by way of the posterior column and (posterior) cerebello-spinal tract. Diagrammatic. (Original.)

These paths terminate in the posterior central gyrus and in the middle and inferior temporal gyri.

II. AFFERENT, OR SENSORY PATHS.

The sensory paths conduct two varieties of impulses, viz., general and special. The impulses originate in the end-organs of the cerebral and spinal nerves, and by those nerves are conveyed to the cerebro-spinal axis, through which they reach the proper cortical area in the cerebrum.

I. General Sensations.

General sensation is the function of the **sense of touch**. This sense has *four important subdivisions*—the tactile sense, muscular sense, pain sense, and temperature sense. *Stereognosis* is only an associated interpretation of all the impulses of the sense of touch and not a subdivision of it. *Tactile sensations* appear to be most elemental and, according to Spiller and Mills, may be conducted by all common sensory nerve fibers. Other common sensations seem to require some specialization, as yet not understood, in their conducting media; and *pain* and *temperature impulses* pursue a path entirely distinct from that followed by impressions of the *muscular sense*. In giving the common sensory tracings, the following classification will be adhered to, though conclusive evidence of certain points in it is still lacking.

I. Paths conducting impulses of the muscular and tactile senses, chiefly, from muscles, tendons, joint surfaces, and the skin. Spinal and cerebral (Fig. 107).

II. Paths carrying impulses of the muscular and tactile senses, chiefly from viscera (?) (Fig. 107).

III. Paths conveying pain, temperature, and tactile impulses. Spinal and cerebral (Fig. 108).

I. PATHS TRANSMITTING IMPULSES OF THE MUSCULAR AND TACTILE SENSES, chiefly, from muscles, tendons, ligaments, joint surfaces and the skin.

Through Posterior Column and Fasciculi Gracilis et Cuneatus (Fig. 107).—Impulses originating in the end-organs of the spinal nerves traverse the dendrites of the spinal ganglion neurones (Cajal), the cell-bodies in the ganglia, and then the axones of the same. They enter the cord through the posterior roots of the

spinal nerves, and ascend through the posterior column as far as the eighth thoracic segment and then through the fasciculus gracilis, or, entering above the eighth thoracic segment, they ascend through the fasciculus cuneatus. In either case they arrive in one of the nuclei of the posterior column, namely, the nucleus funiculi gracilis or the nucleus funiculi cuneati. Thence the impulses may proceed either by a direct or by an indirect route.

(1) *The direct route* carries the impulses by way of the medial fillet through the sensory decussation of the medulla, the formatio reticularis of pons and mid-brain, to the lateral nucleus of the thalamus, from which they are conducted by the cortical fillet to the somæsthetic area of the cerebral cortex. In their last stage the impulses run from the thalamus through the internal capsule and corona radiata to the posterior central gyrus in the equatorial zone of the hemisphere.

(2) *Indirect Route.*—By that route impulses from the nucleus funiculi gracilis and nucleus funiculi cuneati run to the cortex of the vermis cerebelli superior through the external arcuate fibers; then on, through the brachium conjunctivum, to the red nucleus and thalamus. They traverse the restiform body of the same side, by way of the posterior external arcuate fibers; or, by way of the anterior external arcuate fibers, they traverse the fillet decussation of the medulla and the opposite restiform body to reach the vermis cerebelli superior. From the cerebellar cortex, the impulses continue through cortical axones to the nucleus dentatus, whose axones conduct them to the red nucleus and thalamus of the opposite side. The greater number, therefore, cross over in the tegmentum of the mid-brain. Their course from the red nucleus and thalamus is through the cortical fillet to the cortex.

These impulses from the spinal nerves go to the upper two-thirds of the posterior central gyrus, those from the lower extremity to the upper third and those from the arms to the middle third (Spiller).

Through Cerebral Nerves and Medial Fillet (Fig. 107).—As crossed fibers from the terminal nuclei of the trigeminal, the vestibular, the glossopharyngeal and the vagus nerves join the

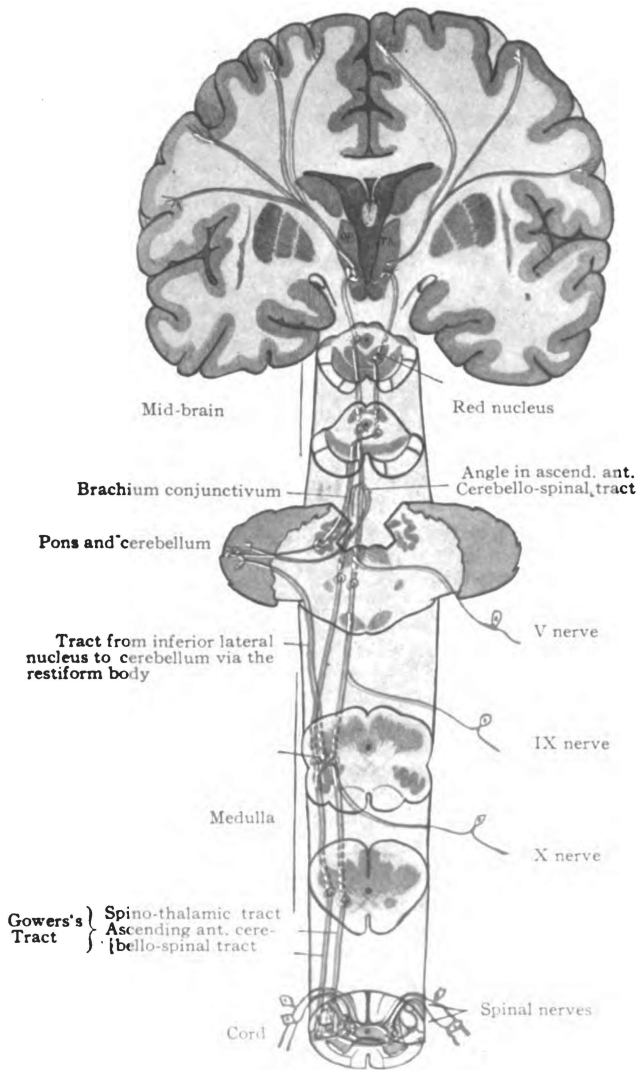


Fig. 108.—Common sensory paths, pain, temperature and touch, by way of ascending anterior cerebello-spinal and spino-thalamic tracts. Diagrammatic. (*Original.*)

Posterior root-fibers connected with this path end in the center of the crescent and in the base of the anterior column of both sides; and the ascending fibers rise partly on the same and partly on the opposite side; the crossed fibers run through the white anterior commissure.

medial fillet and run to the thalamus, so muscular and tactile sensations transmitted by those cerebral nerves to their nuclei in the medulla and pons, are carried by the medial fillet to the lateral nucleus of the thalamus on the opposite side. The cortical fillet conducts them to the lower portion of the posterior central gyrus in the somæsthetic area.

II. PATHS CARRYING IMPULSES OF THE MUSCULAR AND TACTILE SENSES, CHIEFLY FROM VISCERA (?).

Through (Posterior) Cerebello-spinal Tract (Direct Cerebellar) (Fig. 107).—The column of cell-bodies, forming the nucleus dorsalis (Clark), receives impulses concerning equilibrium (?) from the posterior roots of the spinal nerves and transmits them at once to the (posterior) cerebello-spinal tract, through which they ascend along the dorso-lateral surface of the cord, along the posterior surface and through the restiform body of the medulla to the cortex of the superior worm of the cerebellum. To a small extent they cross in the worm to the opposite side. These impulses probably excite, within the cerebellar cortex, impulses of coordination and equilibrium which traverse the descending anterior cerebello-spinal tract to the gray crescent of the cord, and are transmitted to the motor neurones of the anterior column. The motor neurones conduct the impulses to the muscles. From the cerebellar cortex the journey to the cerebrum is completed in four stages, as already described, namely: Nucleus dentatus, opposite red nucleus, thalamus and some part of the cerebral cortex, probably the middle and inferior temporal gyri.

Probably the *vagus nerve* conducts impulses of similar nature from the viscera to its terminal nucleus; but, if so, their path from the terminal nucleus is not certainly known.

PATHS CONVEYING PAIN, TEMPERATURE AND TACTILE IMPRESSIONS. SPINAL AND CEREBRAL.

Through Spino-thalamic and Ascending Anterior Cerebello-spinal Tract (Fig. 108).—In the spinal cord, medulla and pons these constitute one tract, commonly called Gowers's tract. They separate just below the isthmus, whence the spino-thalamic tract continues to the thalamus and the other turns back to the cerebellum. They appear to form the only paths for pain and

temperature impulses. These impulses enter the gray crescent of the cord, on both sides, through the posterior nerve roots. A large number decussate via the posterior nerve roots in the gray commissure; the rest decussate in the first stage of the ascending tracts, crossing in the white anterior commissure, and run upward through the spino-thalamic and ascending anterior cerebello-spinal tracts of the opposite side; they run to the thalamus and to the cortex of the superior worm of the cerebellum. In the cord they ascend along the lateral surface. They run dorsal to the olive in the lateral area of the medulla oblongata, and through the lateral part of the formatio reticularis of the pons to the angle in Gowers's tract situated near the isthmus. From the angle, just below the quadrigeminal bodies, the cerebellar impulses run backward with the tract through the superior medullary velum to the cortex of the vermis cerebelli superior; the remainder run upward to the thalamus, and from that to the posterior central cortex. The common course of sensory impulses from the cerebellar to the cerebral cortex is, as already described, through nucleus dentatus and brachium conjunctivum to opposite red nucleus and thalamus. Having arrived in the thalamus, they proceed thence by the cortical fillet to the somæsthetic cortex.

Certain fibers of the ascending anterior cerebello-spinal tract diverge from the others, in the medulla oblongata, and terminate in the inferior lateral nucleus. Impulses of pain and temperature, following the same course, enter the lateral nucleus, and are carried on through the restiform body to the cerebellum by the tract from the lateral nucleus to the cerebellar cortex, thence to the somæsthetic area as previously given.

Through Cerebral Nerves and the Spino-thalamic Tract (Fig. 108).—Pain and temperature impulses are transmitted by certain fibers of the vagus, glossopharyngeal and trigeminal nerves to their terminal nuclei. From those nuclei they are conducted by axones which *probably* enter into the spino-thalamic tract, and, perhaps, into the ascending anterior cerebello-spinal tract, to the thalamus and to the cerebellar cortex. The path from either point to the posterior central gyrus is now familiar.

The Short Fiber Paths.—What special varieties of common



sensation are conducted through these paths is unknown. Under certain conditions, perhaps, they may carry all varieties. (1) The antero-lateral fasciculus proprius and formatio reticularis contain ascending axones which may convey sensory impulses from the gray matter of the cord, received from the posterior roots of the spinal nerves, and from terminal nuclei in medulla and pons which receive the common sensory fibers of cerebral nerves, upward to the thalamus of the opposite side. The course from the thalamus is by way of the cortical fillet. (2) Again, impulses may leave the formatio reticularis in the pons and run through the brachium pontis cerebelli, by way of axones from the nuclei pontis, to the cortex of the cerebellum; and then continue by the ordinary course through the brachium conjunctivum to the red nucleus and thalamus.

Destruction of any of the above sensory paths causes diminution or loss of the especial variety of impulse which travels that path. Destruction of the posterior white columns produces loss of muscular sensations and gives rise to ataxia. Interruption of Gowers's tract (spino-thalamic and ascending anterior cerebello-spinal tracts) abolishes pain and temperature sensations while touch is not much affected.

2. Special Sensations.

Impulses producing the sensations of smell, sight, hearing and taste are carried from the respective organs of sense to the brain by the following nerves: The olfactory; the optic; the auditory; and the glossopharyngeal and intermediate nerves.

Olfactory Path (Figs. 109 and 21).—Impulses of smell originate in the upper third of the nasal mucous membrane. They run through the olfactory nerves to the second layer in the bulb, where they are transferred to the dendrites of the mitral and brush cells. By the axones of these cells they are carried backward through the olfactory tract and striæ to the cerebral hemisphere. The *medial stria* conducts them to the parolfactory area (Brocae), the triangle, the gyrus subcallosus and anterior end of the gyrus cinguli, whence, through the cingulum, the fornix and uncinata fasciculus they may reach the cortical area of smell in the uncus

hippocampi. By the *intermediate olfactory stria* the impulses enter the triangle and anterior perforated substance, and complete their journey either in the same manner as given above or via the anterior commissure. The *lateral stria* of the olfactory tract conducts the impulses directly to the uncus of the hippocam-

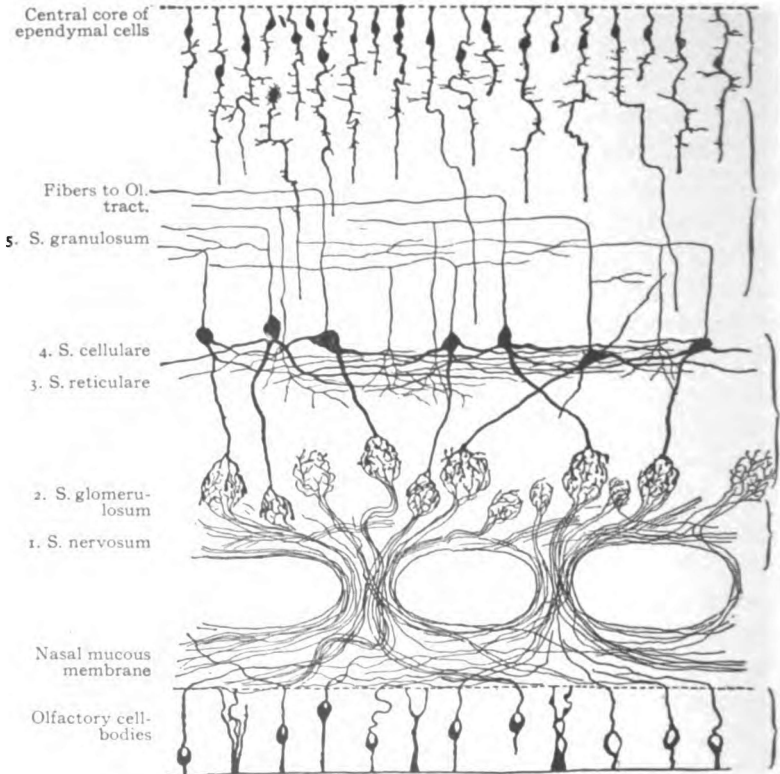


Fig. 109.—Chief elements of the olfactory bulb. (Gordinier after Van Gehuchten.)

pal gyrus. Note that olfactory impulses are chiefly, if not entirely, uncrossed.

Optic Path (Figs. 110 and 111).—Impulses of sight originate in the rods and cones of the retina and traverse three or more series of neurones to the terminal nuclei of the optic tracts; namely, the rod and cone, the bipolar, and the ganglionar neurones. The axones of the last form the optic nerves and the visual part

of the optic tracts. From the right halves of both retinae and from the left halves of both, impulses run through the corresponding tract to the lateral geniculate body and the pulvinar of the thalamus; also to the superior quadrigeminal colliculus. The latter produces ocular and pupillary reflexes. From the lateral geniculate body and pulvinar the occipito-thalamic radiation carries the impulses through the pars occipitalis of the internal capsule to the half-visual center in the cuneus, gyrus lingualis and the pole of the occipital lobe. Impulses from the nasal halves of the retinae decussate in the optic commissure; those from the

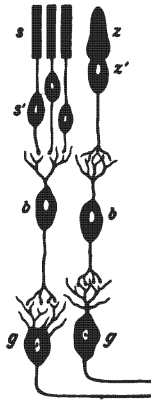


Fig. 110.—The chief retinal elements. (After Brubaker.)

Cells. *s' s'*. Visual cells with their peripheral terminations. *s*. Rods. *z*. Cones. *b*. Bipolar cells. *g*. Ganglion cells from which arise the axones of the optic nerve.

temporal halves, for the most part at least, remain on the same side, but a few may cross through the quadrigeminal colliculi and brachia superiora. Impulses from the nasal half and from the temporal half of the macula lutea are conducted equally by both optic tracts. Hence destruction of one tract causes hemianopsia, preserving the vision in the corresponding half of each visual field, and also diminishes the acuteness of macular vision in both eyes.

Auditory Paths.—There are two auditory paths, cochlear and the vestibular. The former is concerned with *hearing* and the latter with *equilibrium*.

1. *The Cochlear Path* (Figs. 89, 70 and 54).—Impulses of hearing originate in the organ of Corti. They are transmitted by the rods and hair cells of Corti to the dendrites of the spiral ganglion. Traversing the dendrites and cell-bodies of that ganglion, they enter the axones, which form the cochlear nerve, and run backward to the terminal nucleus of that nerve in the medulla. Both the ventral and the lateral portions of the cochlear nucleus receive the impulses of hearing. From the cochlear nucleus they run either lateral and dorsal to the restiform body and cross to the opposite side through the medullary striæ and trapezoid body, or they run medial to the restiform body and enter at once into the trapezoid body. By either course they reach the lateral fillet, and chiefly the opposite one. The lateral fillets conduct the impulses to the inferior quadrigeminal colliculi; the brachia inferiora to the medial geniculate bodies, and the temporo-thalamic radiations to the third and fourth fifths of the superior temporal and to the transverse temporal gyri of the cerebrum. Through the lateral fillet, impulses producing reflex reach the quadrigeminal colliculi and, thence, by the anterior longitudinal bundle, pass to motor nuclei; and, also, through the olivary pedicle and medial longitudinal bundle, they reach the nuclei of the sixth, fourth and third cerebral nerves.

2. *Vestibular Path*.—The extent of the vestibular conduction path is from the acoustic areas of the utricle, saccule and semi-circular canals to the vestibular nuclei in the floor of the fourth ventricle; and, thence, to the cerebellum, and to the cortical area of equilibrium, according to Mills, in the temporal cortex. It is the path of space sense. Through the vestibular nerve the impulses reach the dorso-medial, the dorso-lateral and superior nucleus, and the nucleus of the descending root in the floor of the fourth ventricle.

The impulses may pursue, from the terminal nuclei in the ventricular floor, either a direct or an indirect course to the cerebral cortex.

(1) *By the direct course* they run through the opposite medial fillet and certain fibers in the cortical fillet, perhaps the ventral stalk of the thalamus, to the middle and inferior temporal gyri.

(2) The impulses run to the cerebellum, *by the indirect course*, through the descending root, and the external arcuate fibers in the restiform body. They thus reach the cerebellar cortex. They may excite in the cerebellum impulses of equilibrium and then continue upward. From the cerebellum the course of the impulses is, presumably, through the brachium conjunctivum to the red nucleus and thalamus of both sides and thence to the cortex.

Impulses, believed to be concerned with reflexes, run from the vestibular nuclei in the floor of the fourth ventricle, (a) to the opposite nuclei of motor cerebral nerves via the medial longitudinal bundle; (b) to the quadrigeminal colliculi through the superior fillet; (c) to the cerebellum by way of the descending root and arcuate fibers, whence they reach the spinal nerves through the descending anterior cerebello-spinal tract; (d) to the spinal cord and nerves through the axones of Deiters's nucleus; and, perhaps, less directly through the vestibulo-olivary and olivo-spinal fibers of Kölliker.

The Gustatory Paths.—They extend from the tongue to the nucleus tractus solitarii in the medulla and thence, probably, through the opposite formatio reticularis and internal capsule to the taste area in the gyrus fusiformis (Mills) or gyrus cinguli (Flechsig). There are *two paths* from the tongue to the nucleus of the solitary tract. Those impulses from the base of the tongue and the palate run through the *ninth nerve* and those from the anterior two-thirds of the tongue through the *chorda tympani and intermediate nerve* to the medulla (A. F. Dixon, Keen and Spiller, H. Cushing, etc.). Possibly, gustatory impulses originating in the palate may traverse the descending branches of Meckel's ganglion and the great superficial petrosal nerve to reach the geniculate ganglion on the facial; and, then, continue through the intermediate nerve to the solitary tract. All impulses arriving at this nucleus of the solitary tract probably complete their journey in two stages: *First*, through the formatio reticularis to the opposite thalamus; and, *second*, through internal capsule to the cortex.

Destruction of the olfactory conduction path on one side causes anosmia on the same side; of the optic tract or radiation, atrophy and destruction in the corresponding halves of both retinae;

of the auditory path above the pons, deafness chiefly on the opposite side; and interruption of the gustatory path above the medulla oblongata abolishes taste on the opposite (?) side.

III. REFLEX PATHS.

There is no visible limit to the number of reflex paths. Hence no attempt will be made to give them completely, but a few examples of various kinds will be given which may assist the student to trace others and be suggestive of their great multiplicity and importance. Under certain conditions, unquestionably, the sensory and motor paths that have been traced are but the afferent and efferent limbs of reflex arcs.

Reflex arcs are formed (1) by the sensory and motor fibers of spinal nerves, associated in the gray matter of the cord; (2) by the sensory and motor fibers of cerebral nerves, which are connected in the brain; (3) by afferent spinal fibers connected by the ascending fibers of the medial longitudinal bundle, with efferent cerebral fibers; and (4) by afferent cerebral and efferent spinal nerve fibers, the two being associated by the anterior longitudinal bundle, the ponto-spinal tracts, the fasciculi proprii, the spinal tract of the fifth nerve, the vestibulo-spinal tract, the solitary tract, etc.

(1) **Spinal Reflexes** (Figs. 112 and 113).—In the *simplest* spinal reflexes, the afferent fibers of the arc arborize about the cell-bodies whose axones constitute the efferent fibers; the afferent and efferent fibers are connected by one set of intervening neurones in the *next grade of reflex arc*. Among these are the skin and muscle reflexes, such as the plantar, the patellar, the gluteal and the cremaster reflexes, the involuntary withdrawing of a part from a source of irritation, etc.

Coordinating and equilibrating reflex impulses traverse much longer arcs. They are composed of the spinal ganglion neurones, the external arcuate fibers (and probably the [posterior] cerebello-spinal tract) in the afferent limb, and the descending anterior cerebello-spinal tract and the anterior root neurones in the efferent limb of the reflex arc.

More complicated spinal reflexes are those of defecation, micturition, parturition, vasomotor reflexes, cardio-accelerator reflexes, etc. The impulses traverse at least three neurones in these reflexes; because all efferent white rami communicantes terminate in some ganglion proximal to the organ supplied. As an example, trace a defecation reflex.

Defecation Reflex.—The rectum is supplied by the third and fourth sacral nerves and by branches of the inferior mesenteric and hypogastric plexuses. Irritation of the sensory endings in the mucous membrane is caused, normally, by the presence of feces. The impulses caused thereby run to the special defecation center in the lumbar enlargement of the spinal cord, either by

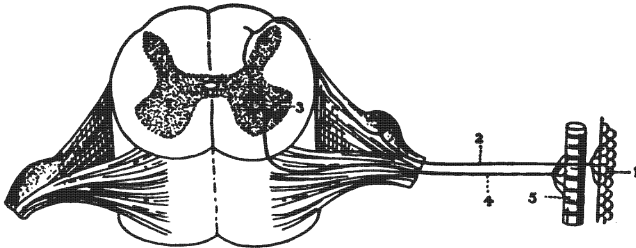


Fig. 112.—Diagram of a simple reflex arc. (After Brubaker.)

1. Sentient surface. 2. Afferent nerve. 3. Emissive or motor cell. 4. Efferent nerve.
5. Muscle.

way of the sacral nerves or through the sympathetic plexuses, the ganglionated cord, and the rami communicantes to the lumbar nerves, through the posterior roots of which they reach the center in the cord. From the defecation center the impulses pursue two courses: (a) They descend through the third and fourth sacral nerves and cause inhibition in the circular fibers of the rectum and contraction of the longitudinal muscle. (b) This action is immediately followed by impulses which pursue the sympathetic course, through the anterior roots of the lumbar nerves, the rami communicantes, the ganglionated cord, and the inferior mesenteric and hypogastric plexuses, to the rectum. They cause, in succession from above downward, contraction of the circular muscle of the rectum. The two series of impulses

thus open a way for the passage of fecal matter; and, then, force it through the opening unless prevented by the voluntary contraction of the external sphincter.

(2) **Cerebral Reflexes.**—The simplest of these reflexes are such as spasm of the muscles of mastication caused by a bad tooth, in which both limbs of the arc are formed by the trigeminal nerve. Again, the facial expression of pain due to the same cause. In this the impulses traverse the trigeminal nerve and

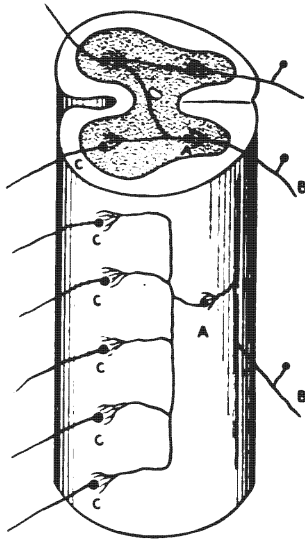


Fig. 113.—A more complicated spinal reflex arc, involving the fasciculi proprii. (Brubaker after Kölliker.)

Diagram showing the relation of the third neurone *a*, to the afferent neurone *b*, and to the efferent neurones *c*, *c*, *c*.

by the collaterals of its root-fibers reach the nucleus of the facial. Through the facial they cause contraction of certain muscles of expression. Facial spasm in tic douloureux is due to the same reflex. The involuntary expansion of the nostrils upon the detection of a faint odor is due to an olfactory-facial reflex. The connection of the terminal nucleus and cortical center of the olfactory nerve with the genetic nucleus of the facial nerve is very much

in doubt; it may be established in part (1) by the fornix, the thalamo-mammillary bundle and thalamo-spinal fibers, (2) by the fornix, medullary stria, fasciculus retroflexus and descending fibers of the interpeduncular ganglion, and, (3) by the fornix and the pedunculo-mammillary bundles. *Squinting*, due to bright light, is produced by an arc composed of the visual path, the corticifugal part of the occipito-thalamic radiation, the anterior longitudinal bundle and the facial nerve. Substitute the oculomotor nerve for the facial and we have the arc for *pupillary contraction* under the same conditions.

Salivary reflexes, in which the sight of a fine dinner or the smell of it causes the flow of saliva; coughing, sneezing, vomiting reflexes and deglutition reflexes are complicated, but, knowing the nerve supply of the parts involved, the student should try to trace the impulses.

(3) **Spino-cerebral Reflexes.**—Impulses received by the spinal cord through the afferent fibers of its nerves are transmitted by the medial longitudinal bundle, the fasciculi proprii and formatio reticularis to the nuclei of motor cerebral nerves. Thus is brought about the movement of the head and eyes toward the source of impulse, a change of facial expression to agree with the painful or pleasing character of the impulses, etc.

(4) **Cerebro-spinal Reflexes.**—Of these there are many. Let us notice three.

Respiratory Reflex.—Any obstruction or irritation in the larynx or trachea sends an impulse through the vagus nerve to its sensory nucleus and, through its descending branches, in the solitary tract, to the nucleus ambiguus and nucleus of the phrenic nerve in the cervical cord, causing increased respiratory efforts, coughing, spasm of muscles closing glottis, etc.

Equilibrium Reflex (Vestibulo-spinal Reflex).—The simplest arc of equilibrium between the eighth cerebral nerve and the spinal nerves is formed by the neurones of the vestibular ganglia (Scarpa's), the vestibulo-spinal part of the descending anterior cerebello-spinal tract and the motor neurones of the anterior column of the spinal cord. A more complicated arc includes the descending root of the vestibular nerve, the external arcuate

fibers from the nucleus funiculi cuneati and the descending anterior cerebello-spinal tract.

Pupillary Reflexes.—*Pupillary dilatation* belongs to the cerebro-spinal group of reflexes. The cilio-spinal center is in the cervical enlargement of the spinal cord. It receives optic impulses through the anterior longitudinal bundle from the corpora quadrigemina. The superior quadrigeminal colliculi receive those impulses by two routes: First, directly, through the fibers of the lateral root of the optic tract, and, second, indirectly, through corticifugal fibers in the occipito-thalamic radiation, and the brachium superius. By the latter route, the optic impulses which have reached the visual area of the occipital lobe, by way of the intrinsic retinal neurones and the optic nerves, tracts and radiation, are returned to the lateral geniculate and superior quadrigeminal bodies. Thence, reaching the cilio-spinal center through the anterior longitudinal bundle, the impulses take the following course: They leave the spinal cord through the anterior roots of the upper thoracic nerves and run, in succession, through the rami communicantes, the cervical cord of the sympathetic, the cavernous plexus, the ciliary ganglion and the short ciliary nerves to the radiating fibers of the iris, causing dilatation of the pupil.

For *pupillary constriction*, the impulses run directly from the superior quadrigeminal colliculus to the oculomotor nucleus, traversing the anterior longitudinal bundle only through the dorsal tegmental decussation (Meynerti). Then, through the third and short ciliary nerves, they reach the sphincter pupillæ muscle.

CHAPTER VIII.

EMBRYOLOGY OF THE BRAIN AND SPINAL CORD.

The brain and spinal cord are developed from the neural tube; the spinal and sympathetic ganglia and the ganglia of sensory cerebral nerves are derivatives of the neural crest (Figs. 16 and 114).

Very soon after conception there appears along the median line, in the back of the embryo, a plate of epiblast, called the *medullary plate*. That plate soon presents two longitudinal elevations, the *medullary ridges*, separated by a median furrow, the *neural groove* (Fig. 16). At first the medullary plate is formed of a single layer of columnar cells; but those cells undergo rapid mitosis, as the medullary ridges are developed, and arrange themselves in several layers which thus bound the neural groove (Fig. 114). The infolding of the medullary ridges, together with their rapid growth, roofs over and closes in the neural groove and produces the *neural tube* (Fig. 16). The tube is first formed in the cervical region, whence the fusion of the medullary ridges extends in both directions. By the approximation of the medullary ridges a slight paramedian crest is produced on either side, called the *neural crest*. The neural tube and the neural crest are nearly complete by the fifteenth day after conception, the groove is open only at the position of the future median aperture of Magendie. Both ends of the tube are open for a short time, the anterior closing first. The mesoblast which later grows around the neural tube is developed into the meninges and the surrounding bones, which inclose the cerebro-spinal axis.

The Neural Tube (Figs. 16 and 114).—It is well formed at the fifteenth day. The cephalic end of the tube is much larger than the caudal end, and presents at this time two constrictions that separate the **primary brain vesicles** from one another—the *anterior*, the *middle*, and the *posterior*. Behind the posterior

primary vesicle, the neural tube remains small and of nearly uniform size; that part forms the spinal cord, in which the general plan of development may be observed in its simplest form.

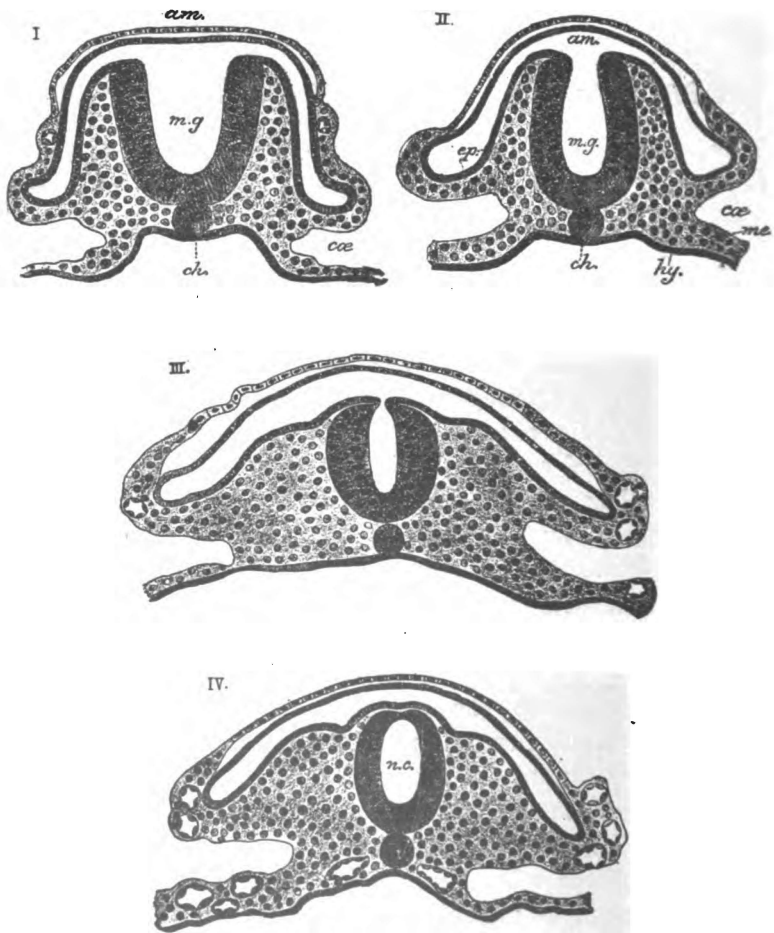


Fig. 114.—Sections showing stages in the conversion of the medullary groove into the neural canal. From the tail end of an embryo of the cat. (Gordinier after E. A. Schäfer.)

ep, me, hy. Epiblast, mesoblast, and hypoblast. *m.g.* Medullary groove. *n.c.* (in IV). Neural canal. *ch.* Notochord. *ca.* Celom. *am.* Tail-fold of the amnion.

In the very early stages of development two varieties of cells make up the neural tube (Fig. 115). Certain very long cells, during the karyokinetic growth, arrange themselves at right angles

to the axis of the tube. They are the *ependymal cells*, which form a supporting framework for the more important elements. They reach from the lumen of the tube to its peripheral surface and possess nuclei which are situated largely in the central half of the cell. The peripheral parts of the ependymal cells, by irregular branching and vacuolation, form a protoplasmic network destitute of nuclei, called the *marginal velum*. This marginal velum forms a peripheral zone which comprises the outer one-

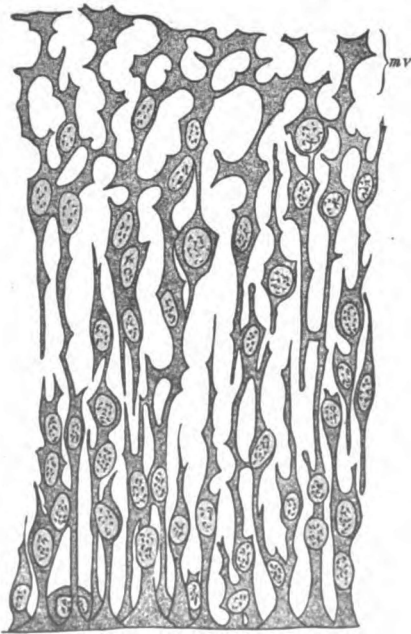


Fig. 115.—Two histologic layers in the embryonic spinal cord, embryo 4.25 mm. long. (McMurrich after His.)

mv. Marginal velum formed by peripheral ends of ependymal cells, indifferent cells among their bases.

sixth of the neural tube. The inner three-fourths or five-sixths of the tube constitutes a thick central zone in which are the bodies of the ependymal cells and, among their bases, a variety of cells possessing large nuclei and small protoplasmic bodies (Fig. 115). The destination of the latter cells cannot yet be determined, so they are named the *indifferent cells* (Fig. 116). In the nuclei

of the indifferent cells all forms of karyokinetic figures may be seen. This fact shows that they are rapidly multiplying.

In a somewhat later stage of development the indifferent cells wander outward toward the marginal velum and arrange themselves into a definite layer, known as the *mantle layer* (Figs. 116 and 127). Three concentric zones are clearly visible at this time in a cross section of the neural tube; the *marginal velum*, the *mantle layer*, and the *ependymal layer* formed by the bases of the ependymal cells. As the indifferent cells multiply in the mantle layer they become specialized into two types, the *neuroblasts* and the

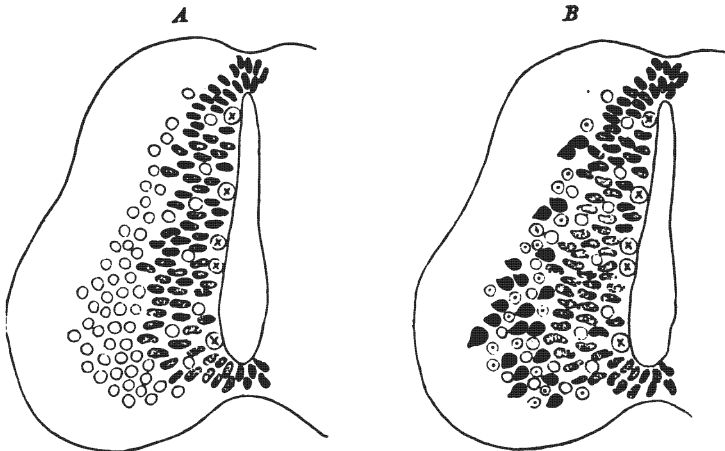


Fig. 116.—Diagram showing development of neurons in the spinal cord.
(McMurrich after Schäfer.)

The circles, indifferent cells; circles with dots, neuroglia cells; shaded cells, germinal cells; circles with cross, germinal cells in mitosis; black cells, nerve-cells.

spongioblasts. The **neuroblasts** are the larger. They are the embryonic neurones. Each neuroblast throws out a protoplasmic process which develops into an *axone* and grows outward into the marginal velum. Within the marginal velum the axone either runs some distance and returns to the mantle layer, or it passes outward through the marginal velum and becomes an efferent or motor root-fiber. *Collaterals* are given off from the axones, the *end-tufts* are formed and the medullary sheath is laid down as development proceeds and function begins. While these events

are occurring in the efferent part of the neuroblast, other processes, called *dendrites*, are given off by the cell-body. They belong to the afferent side of the cell. There are usually several dendrites. They branch richly close to the cell-body and terminate, as a rule, within the mantle layer. The **spongioblasts** are the smaller of the indifferent cells. They are primitive neuroglia cells (Fig. 53). The spongioblasts develop many very slender and richly branched processes of ray-like or arborescent form, which by their interlacement constitute a delicate supporting reticulum. The neurones are held in the meshes of this reticulum, and both the neurones and neuroglia cells are still further supported by a coarse mesoblastic framework produced by the ingrowth of blood vessels.

Zones (Figs. 117 and 127).—While the neurones and neuroglia cells are forming, there occurs in each lateral wall of the neural

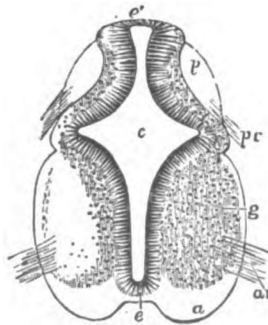


Fig. 117.—Transverse section of the cervical part of the spinal cord of a human embryo of six weeks. (Gordinier after Kölliker, from Quain.)

c. Central canal. *e.* Its epithelial lining. *e.* (Superiorly) The original place of closure of the canal. *a.* The white substance of the anterior columns. *g.* Gray substance of anterior column. *p.* Posterior column. *ar.* Anterior roots. *pr.* Posterior roots.

canal a longitudinal evagination. This evagination produces a *longitudinal groove* on the ventricular surface of the neural tube, which divides it into a ventral and a dorsal zone. The *ventral zone* is largely efferent in function, hence from it issue the outgoing tracts (Figs. 127 and 128). It is composed of a median floor plate and, on either side, of a basal, or ventral lamina. The *dorsal zone* is made of up two alar, or dorsal laminae joined by

the median roof-plate. The dorsal zone is afferent in function and in connection with it the sensory nerves terminate. The *roof-plate* and the *floor-plate* take little or no part in forming neurones; they lack the mantle layer, and are composed of neuroglia and ependymal cells.

The Neural Crest (Figs. 16 and 114).—(1) *The cephalic portion of the neural crest* becomes broken into five pairs of ganglia, which, during development, shift their positions to the ventral side of the brain. Those ganglia are called the vagus, glossopharyngeal, geniculate, auditory and semilunar (Gasseri). Later, the auditory ganglia lie between the geniculate and glossopharyngeal ganglia. These five ganglia give origin to the sensory parts of the *vagus*, *glossopharyngeal*, *intermediate* and *trigeminal nerves*; and to all of the *acoustic nerve*. In all the ganglia except the auditory, the cells develop into *unipolar neurones*; they remain *bipolar* in the auditory ganglia. The unipolar condition is produced by the growth of the cell-body toward the surface of the ganglion and the shifting of both processes to the same side of the cell-body, together with the elongation of the common point of attachment. The single processes of the unipolar neurones immediately divide, T-like, into peripheral and central fibers, which in appearance are axones. The peripheral fibers form the sensory part of the respective nerves and conduct impulses toward the cell-body, hence they may be considered dendrites (Cajal); the central fibers, the axones proper, form that part of the nerve which extends from the ganglion into the dorsal zone of the embryonic brain. All the central axones of the several ganglia divide, T-like, upon entering the brain, and collaterals rise from the undivided fibers and from both branches of them. These axones and collaterals arborize, chiefly, in the terminal nuclei of the respective nerves; but certain of them, the excito-reflex fibers, terminate in nuclei of motor nerves.

The development of peripheral common sensory neurones, both cerebral and spinal, has been observed in certain lower vertebrates. In the *amblystoma punctatum* the following phases have been observed: 1. The elongation of the cells in the neural crest to a spindle-form. 2. The projection of a slender central process, *the axone*, which grows into the neural tube. 3. A thick

irregular process, *the dendrite*, is thrown out from the peripheral end of the cell; later it becomes smooth and fibrillar in character. This *bipolar condition* persists in very low forms, such as the amphioxus and cyclostomes. 4. In bony fishes some of the neurones become *unipolar*. The greater number become unipolar in higher vertebrates (*J. B. Johnston's Nervous System of Vertebrates*).

(2) *The spinal portion of the neural crest* forms the *thirty-one pairs of spinal ganglia* situated on the posterior nerve roots; and, also, the *vertebral, prevertebral and terminal ganglia* of the sympathetic system. The sympathetic ganglia wander widely. In them the epiblastic cells develop into *multipolar neurones*, the nonmedullated processes of which constitute the larger number of gray fibers in the sympathetic system. The cells of the spinal ganglia form *unipolar neurones*, like those of the vagus, glossopharyngeal, geniculate and semilunar ganglia. Like them, also, the single processes divide, T-like, the peripheral arms of the T-branches forming the sensory part of each spinal nerve and the central arms (the axones) the posterior roots of those nerves. The latter enter the cord at the posterior lateral sulcus and, before and after dividing T-like into an ascending and a descending branch, give off collaterals. The *descending fibers*, long and short, arborize and end in the gray matter of the posterior column, the center of the crescent and the anterior column, the long fibers forming the postero-medial and postero-lateral descending radicular tracts; the *ascending axones* and collaterals terminate in the gray substance of the spinal cord and in the nuclei of its posterior columns, namely, the nucleus funiculi gracilis and nucleus funiculi cuneati of the medulla. The long ascending fibers form the postero-medial tract (Goll's) and, the postero-lateral tract (Burdach's); and, the shorter ones, those reaching but a few segments, make up the marginal tract of Lissauer. The greater number of posterior root-fibers terminate in the gray substance at or near their level of entrance into the cord.

THE BRAIN.

The primary brain vesicles grow rapidly. By the end of the fourth week a constriction is visible in the anterior primary vesicle

and another in the posterior primary vesicle, dividing each into two and making in all *five secondary brain vesicles*, which freely communicate with one another and are numbered from before backward. They are:

1. Telencephalon.
2. Diencephalon.
3. Mesencephalon.
4. Metencephalon.
5. Myelencephalon.

These vesicles form the brain, their cavities becoming the ventricles (Figs. 118, 120 and 17). The neuroblasts of the mantle layer produce the neurones, whose cell-bodies and dendrites are found in the cortex and ganglia, and whose medullated axones form the white substance.

Flexures (Fig. 118).—The cephalic portion of the neural tube is the seat of three flexures, two ventral and one dorsal. (1) *The mesencephalic flexure* (ventral) begins very early and amounts to nearly 180 degrees by the twenty-eighth day. It bends ventrally the diencephalon until it almost touches the metencephalon. Thus the inter-brain and pons are approximated and the mid-brain almost concealed. (2) *The cervical flexure* is also a ventral one. It is located at the junction of the fifth vesicle with the spinal cord, and corresponds to the bending of the head upon the body of the embryo. This flexion begins about the twenty-first day. By the end of the fourth week, it is completed and amounts to 90 degrees. (3) The dorsal flexure is beginning to form at the same time (fourth week). It occurs between the fourth and fifth brain vesicles, and is often called the *metencephalic flexure*. It reaches 180 degrees by the eighth week, when the dorsal part of the metencephalon (the cerebellum) rests upon the medulla oblongata. The convexity is formed by the pons, hence the synonym, *pontine flexure*. The cervical and metencephalic flexures almost entirely disappear, but the mesencephalic flexure is permanent.

TABLE IV.

BRAIN VESICLES, THEIR DERIVATIVES AND VENTRICLES

(Figs. 17, 118 and 120).

Primary Vesicles.	Secondary Vesicles.	Derivatives.
Anterior—the Pro-encephalon or Fore-brain.	Telencephalon, Lateral ventricle and Aula of third ventricle.	Cerebrum.
	Diencephalon, and Third ventricle, except the aula.	
Middle—the Mes-encephalon, or Mid-brain.	Mesencephalon, and aqueductus cerebri.	
Posterior—the Rhombencephalon.	Isthmus rhombencephali	Rhombencephalon and Fourth ventricle.
	Metencephalon	
	Myelencephalon.	

TABLE V.

SECONDARY BRAIN VESICLES AND THEIR DERIVATIVES.

Telencephalon (End-brain)	Cerebral hemisphere.	Neopallium
		Rhinencephalon
	Pars optica hypothalami.	Corpus striatum.
Diencephalon (Inter-brain)	Thalamencephalon.	Chiasma opticum
		Lamina terminalis
	Pars mammillaris hypothalami.	Tuber cinereum
		Hypophysis.
	Thalamus	
	Metathalamus	Corpora Geniculata
	Epithalamus	Epiphysis, and Nuc. habenulæ
		Corpora mammillaria.

Mesencephalon (Mid-brain)	{ Pedunculi cerebri. Lamina quadrigemina.	{ Bases pedunculi Substantia nigra Tegmenta.
		{ Corpora quadrigemina— Colliculi superiores Colliculi inferiores Brachia— Brachia superiora Brachia inferiora.
Metencephalon	{ Isthmus rhomben- cephalii (in which are) Cerebellum. Pons Varolii.	{ Pedunculi cerebri Brachia conjunctiva Velum medullare superius.
		{ Cortex Corpus medullare Ganglia (Pedunculi cerebelli) Vela medullaria.
Myelencephalon	{ Medulla oblongata.	

In the following resume of the formation of the central nervous system, I have drawn so largely from Prof. McMurrich's "Development of the Human Body" that I wish at this point, to make grateful acknowledgment of my indebtedness to him.

TELENCEPHALON.

TABLE VI.

DERIVATIVES OF TELENCEPHALON.

(Modified from McMurrich's Embryology.)

	In Median Structures.	In Hemisphere.
Roof-plate	{ Roof epithelium of the aula Lamina terminalis (in part).	{ Floor of chorioidal fissure
Dorsal Lamina	{ Lamina terminalis (in part) Optic vesicle.	{ Neopallium Rhinencephalon Corpus striatum.

Ventral Zone	{	Anterior part of hypothalamic region Tuber cinereum Infundibulum.	
Surrounding Mesoblast	{	Falx cerebri Part of chorioid tela of third ventricle.	} Meninges.

The telencephalon is at first a single vesicle forming the fore part of the anterior primary vesicle, and for a time is open in front at the *neuropore* (Fig. 118, VI). The median portion of its anterior wall, *lamina terminalis*, remains almost stationary; laterally, it is the seat of rapid growth.

Optic Vesicle.—Almost before the telencephalon is differentiated from diencephalon, a club-shaped diverticulum, called the optic vesicle, is thrown out from the ventral part of its dorsal zone. It grows outward and forward, separates from the telencephalon and, becoming indented, forms the *optic cup*, from which the retina is developed. The point of origin of the optic vesicle is indicated in the adult by a slight pit, termed the *optic recess*. The optic recess is situated between the lamina terminalis and the columna fornicis at the anterior end of the *sulcus hypothalamicus* (Monroi). This sulcus, in the anterior primary vesicle, separates the ventral from the dorsal zone.

Hemisphere of Cerebrum (Figs. 17, 118 and 120).—Soon after the appearance of the optic vesicle, a large bulging occurs on either side in the dorsal zone of the telencephalon. That bulging produces a hollow diverticulum, whose cavity is the primitive *lateral ventricle* and whose walls form the substance of the hemisphere. The outgrowth is called the *hemisphere vesicle*. Its constricted stalk contains the primitive *interventricular foramen* (Monroi, Fig. 17). The vesicles grow forward and outward at first, separated from one another by mesoblast which forms the falx. Later, growth occurs in succession, upward, backward and downward, until by the seventh month the hemisphere overhangs every other part of the brain. The hemisphere vesicle is formed almost wholly by the dorsal lamina of the telencephalon which grows and develops wonderfully and will be considered further

on. It also contains a narrow prolongation of the roof-plate. This prolongation of the roof-plate undergoes very little development. At first it is placed in the roof of the hemisphere vesicle; but the upward growth of the hemisphere shifts it to the medial surface and, later, the backward and downward extension of the hemisphere carries the roof-plate through a horse-shoe curve down toward the pole of the temporal lobe. No thickening occurs in this prolongation. Becoming indented longitudinally it forms the floor of the *chorioid fissure* in which is developed, from

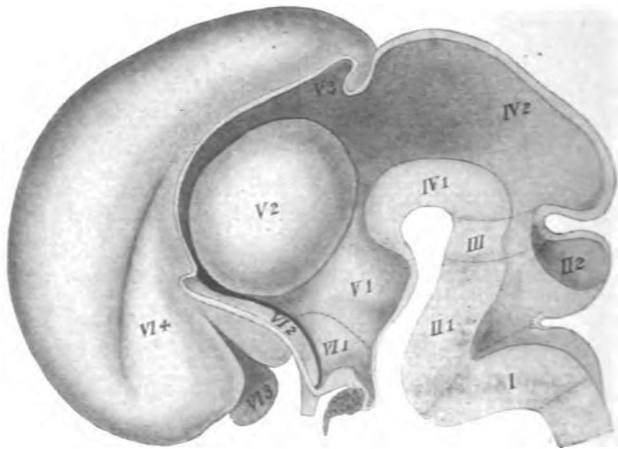


Fig. 118.—Median section of embryonic brain of the third month.
(McMurrich after His.)

I. Myelencephalon. II. Metencephalon: 1, Pons, 2, Cerebellum. III. Isthmus rhombencephali. IV. Mesencephalon: 1, Pedunculi, 2, Corpora quadrigemina. V. Diencephalon: 1, Pars mammillaris hypothalami, 2, Thalamus, 3, Epithalamus. VI. Telencephalon: 1, Pars optica hypothalami, 2, Corpus striatum, 3, Rhinencephalon, 4, Neopallium.

ingrowing mesoblast, the *chorioid plexus* of the lateral ventricle (Fig. 119).

Rhinencephalon (Figs. 17, 118 and 120).—In the fifth week a hollow diverticulum grows out from the antero-inferior wall of the hemisphere vesicle and forms a prominent lobe. It preserves a lobular form in the horse, and in some other animals; but in man it soon becomes constricted by the sulcus parolfactorius posterior into an *anterior* and a *posterior part*, and loses its ventricular cavity. The anterior part develops the olfactory bulb,

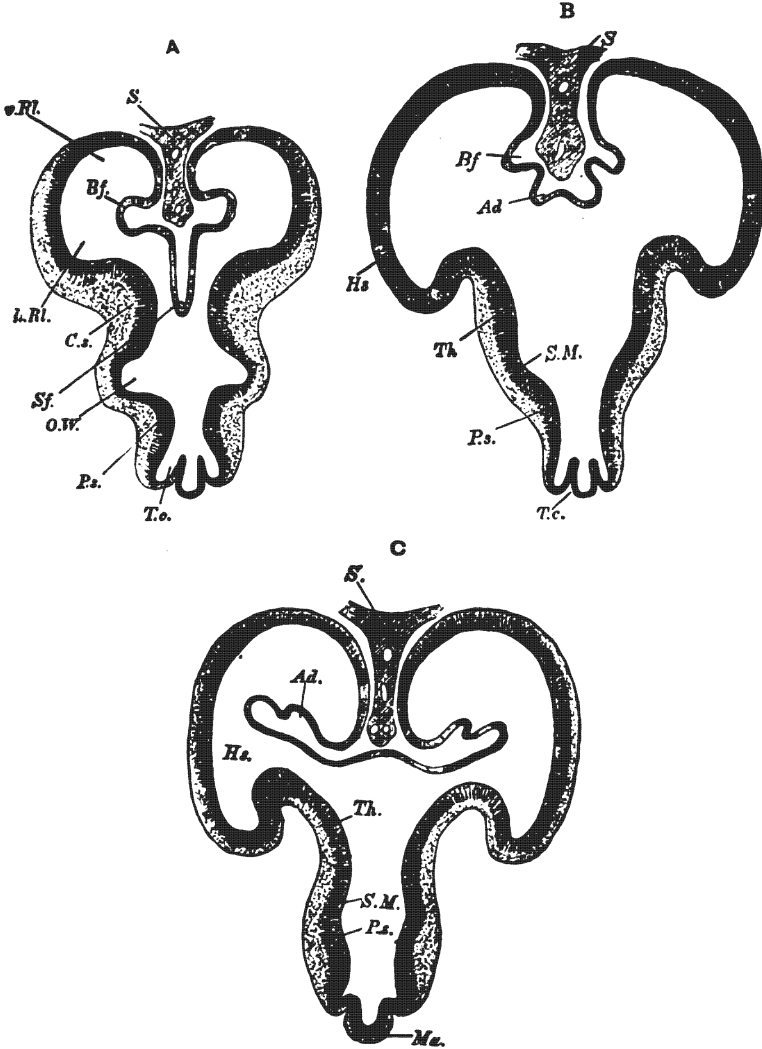


Fig. 119.—Transverse sections through the fore-brain of a four and one-half weeks embryo. (Gordinier and Quain after His.)

A. Through the lower anterior part of the fore-brain. *S.* Falx. *Sf.* Fold of roof passing below falx toward the third ventricle. *Bf.* Fold forming the fissura hippocampi. *v. Rl.*, *h. Rl.* Anterior and posterior parts of olfactory lobe. *C.s.* Corpus striatum. *O.W.* Groove continuous with optic stalk. *Ps.* Hypothalamus. *T.c.* Tuber cinereum.

B. Section a little farther back. *Sf.* is replaced by a less prominent but broader fold of the roof, *Ad.*, which subsequently receives the chorioid vessels, and is, therefore, the chorioid fold. *Hs.* Hemisphere vesicle. *Th.* Thalamus. *S.M.* Sulcus hypothalamicus (Monroi), below and behind the thalamus.

C. Still farther back. *Ad.* Chorioid fold here projecting into lateral ventricles, but still free from mesoblast and blood-vessels. *Ma.* Mammillary tubercle. The other lettering as before.

tract, triangle, and the parolfactory area (Brocæ), the posterior portion forms the anterior perforated substance, etc.

Primary Fissures (Figs. 121 and 122).—The vesicle walls are of uniform thinness up to the second month. During their rapid growth in the second and third months they become thrown into folds which encroach upon the cavity and present on the surface of the vesicle (or hemisphere) the primary fissures. The cause of the infoldings is, perhaps, the resistance of the slower growing cranium. The primary fissures are best developed in the third month. They consist of the chorioidal fissure, already mentioned, the hippocampal fissure which, surrounding it, is concentric with

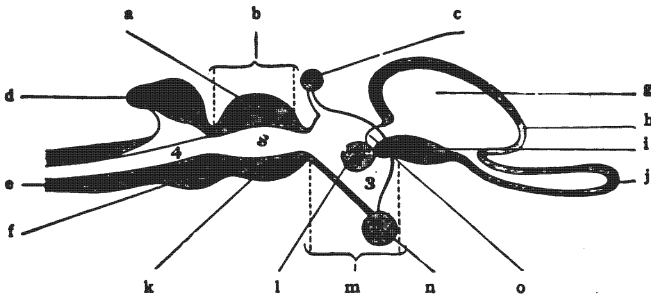


Fig. 120.—Diagrammatic sagittal section of vertebrate brain.
(*Morris's Anatomy after Huxley.*)

a. Corpora quadrigemina. b. Mid-brain. c. Pineal body. d. Cerebellum (hind-brain). e. Medulla oblongata (after-brain). f. Pons Varolii (hind-brain). g. Lateral ventricle. h. Cerebral hemisphere. i. Corpus striatum. j. Olfactory diverticulum. k. Pedunculi cerebri. l. Thalamus. m. Inter-brain. n. Hypophysis. o. Interventricular foramen. 4. Fourth ventricle. s. Aqueduct of cerebellum. 3. Third ventricle.

it, and the fossa lateralis cerebri (Sylvii). The **hippocampal fissure** (Fig. 121) begins near the frontal pole on the medial surface of the hemisphere vesicle and extends backward, downward and, lastly, forward toward the temporal pole. It divides the medial surface into a broad marginal gyrus and the dentate gyrus, the latter is between it and the chorioidal fissure. In its whole course it is parallel with the chorioidal fissure (Figs. 119 and 121). The ventricular eminence caused by the hippocampal fissure is called the *hippocampus*. The hippocampal fissure gives off two branches at its most posterior part, which represent the *occipitoparietal* and the *calcarine fissures* (Fig. 121). Both branches produce ventricular eminences, but only that of the calcarine per-

sists, in the *calcar avis*. The primary occipito-parietal fissure entirely disappears. The whole superior part of the hippocampal fissure is represented in the adult, as to position, by the *callosal fissure*. The **lateral cerebral fossa** (Fig. 122) is a deep bay in the ventral border of the hemisphere vesicle. It is due to the relatively limited growth of the corpus striatum in comparison with the more rapid and greater growth of the surrounding parts. The thickened floor of the fossa cerebri lateralis develops, internally, the *corpus striatum* and, externally, forms the *insula* (Reili). The lateral fossa and the four fissures mentioned above are well formed by the third month, but the lateral cerebral fossa is not converted into a fissure until the end of the fifth month. Even then only the *posterior ramus* of the fissura cerebri lateralis (Sylvii) is formed, and this is brought about by the meeting of the temporal and the fronto-parietal parts of the operculum. It is during the first year after birth that the development of the orbital and frontal parts of the operculum produces the *anterior horizontal ramus* and the *anterior vertical ramus* of this fissure.

Secondary Sulci and Secondary Fissure (Fig. 123).—The secondary sulci are linear indentations of the surface only; they cause no ventricular eminences. About the middle of the fifth month the first secondary sulcus makes its appearance. It is the *sulcus cinguli* of the medial surface, which separates the superior frontal gyrus and paracentral lobule from the gyrus cinguli of the adult brain (Fig. 27). Its development in two or three pieces explains its irregularity and occasional want of continuity. In the sixth month the subparietal and occipito-parietal sulci are present. There is no sign of the latter sulcus in the early part of the fifth month and the permanent sulcus does not produce a ventricular eminence, hence the occipito-parietal indentation is a sulcus and not a fissure (see Cunningham Memoirs). Early in the sixth month the most important of the remaining sulci are formed, such as, the *central sulcus* (Rolandi), the *precentral*, the *postcentral*, the *superior temporal sulcus* and the remaining larger sulci of the frontal, parietal, occipital and temporal lobes (Figs. 23 and 123). The only secondary fissure, the *collateral fissure* appears in the same month. It is developed on the tentorial sur-

face of the hemisphere, at first, in three separate parts, an *anterior* and a *posterior temporal* and an *occipital part*. Its middle part is a total fissure, so is its anterior part sometimes. When both are total they produce a long eminence in the inferior horn of the lateral ventricle, external to the hippocampus and parallel with it, hence its name, the *eminencia collateralis*.

There are many *tertiary sulci* which do not appear until near birth, some of them one or two years after birth.

Transverse Fissure of the Cerebrum.—Only the anterior part

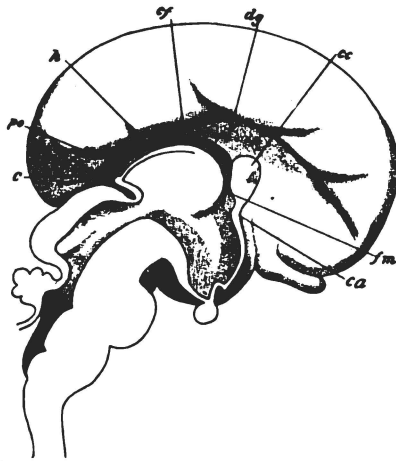


Fig. 121.—Medial sagittal section through the brain of an embryo of three months, showing the primitive fissures on the medial surface of the cerebral hemisphere. (McMurrich after Mihalkovicz.)

c. Calcarine fissure. *ca.* Anterior commissure. *cc.* Corpus callosum. *cf.* Chorioidal fissure. *dg.* Dentate gyrus. *fm.* Foramen interventriculare (Monroi). *h.* Hippocampal fissure. *po.* Occipito-parietal fissure.

of this fissure, which is between the fornix and the inter-brain, belongs wholly to the cerebrum; the posterior part separates cerebrum from cerebellum. The anterior part of the transverse fissure is produced by the backward growth of the united cerebral hemispheres over the free dorsal surface of the diencephalon, the inter-brain. It is continuous laterally with the chorioidal fissure in each hemisphere and contains the chorioid tela of the third ventricle.

Cerebral Cortex and Medulla.—As the gyri of the cerebrum

are acquiring their adult forms and producing the various fissures and sulci, the walls of the hemisphere vesicle thicken rapidly and give rise to the corpus striatum, the cortex and the medullary substance; but the order of development is not yet understood. The development of the gray and the white substance contracts the cavity of the hemisphere vesicle to the size of the *lateral ventricle*; and the *cornua* of the ventricle are produced by the forward, backward, and downward growth of the vesicle in the successive formative stages. Little is known of the time at which the cortical neurones are formed; but it would seem that they continue to undergo medullation and to become functional up to a late period of life, and the investigations of Kaes support this inference.

Fornix.—A ridge appears, about the fourth month, on the medial surface of the hemisphere vesicle, along the convexity of the chorioidal fissure. That ridge reaches from the lower end of the hippocampus to the roof of the interventricular foramen. It becomes converted into a bundle of fibers which is continued into the lamina terminalis and then through the lateral wall and floor of the diencephalon to the corpus mammillare. It forms a lateral half of the fornix. The union of the two halves in the lamina terminalis forms the primitive *body*, or *corpus fornicis*. The body is extended by the upward and backward growth of the lamina terminalis and by the crossing over of certain fibers from one crus fornicis to the other, which results in the formation of the *commissura hippocampi*.

Another ridge, a slight one, appears about the same time on the opposite lip of the chorioidal fissure. It represents the **stria terminalis**. This latter ridge and the fornix ridge bound the roof-plate as represented in the hemisphere. This roof-plate extension undergoes no development. It forms the *chorioid epithelial lamina* of the lateral ventricle, which loosely joins the fornix and the stria terminalis, being folded over the *chorioid plexus* of that ventricle (Fig. 119).

Internal Capsule.—It is formed largely along the line of fusion between the medial surface of the hemisphere vesicle and the lateral surface of the diencephalon. Motor fibers grow downward through the corpus striatum from the cerebral cortex, and

sensory fibers ascend through the striated body to the cortex from the thalamus and other ganglia. All these motor and sensory fibers together constitute the internal capsule. Its bell-shape in the hemisphere is due to the rotary growth of the hemisphere, upward, backward, downward and forward, around the corpus striatum (Figs. 32 and 33).

Anterior Commissure (Fig. 121).—The *lamina terminalis* at the fourth week is a thin median plate bounding the aulla anteriorly and joining the hemisphere vesicles together just in front of the foramina interventricularia (Monroi) (Fig. 17). Its ventral portion remains thin; but its dorsal part thickens greatly and,

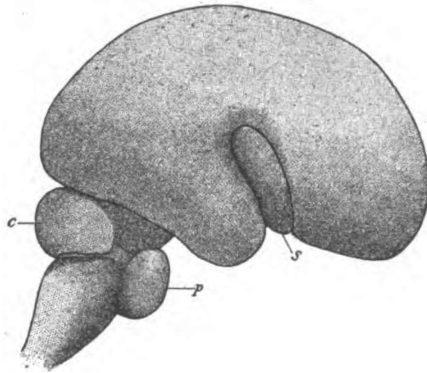


Fig. 122.—The fossa lateralis cerebri, in embryonic brain of the fourth month. (After McMurrich.)

c. Cerebellum. p. Pons. s. Fossa lateralis cerebri.

with the upward and backward growth of the hemisphere, it is extended in a crescent, dorsal to the interventricular foramen, as far backward as the splenium of the corpus callosum. Within this thickened crescentic part of the lamina terminalis are formed the *anterior commissure*, the *body of the fornix*, the *corpus callosum* and the *septum pellucidum*. The anterior commissure is first formed. Through the ventral angle of the thickened portion grow, transversely, the commissural and the decussating fibers of the rhinencephalon and the commissural fibers connecting the occipito-temporal cortices. These fibers make up the anterior commissure. The *fornix fibers* grow for the most part

longitudinally through the zone next the ventral surface of the crescentic lamina and, on reaching the anterior commissure, bend backward into the lateral wall of the aula and third ventricle; a certain number of fornix fibers cross over in the posterior border of the lamina terminalis and produce the *commissura hippocampi*. The corpus callosum is formed in the dorsal zone of the crescentic lamina terminalis.

The corpus callosum (Fig. 121) is produced by fibers that grow from one cerebral hemisphere to the other through the fronto-

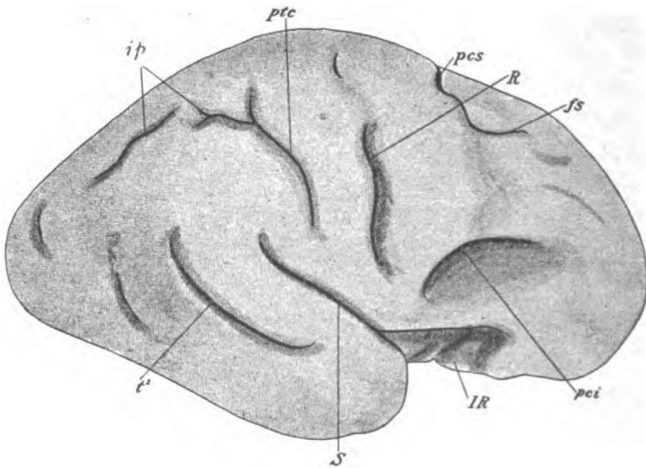


Fig. 123.—Permanent fissures and sulci on the convex surface of the cerebrum as seen in a seven months embryo. (McMurrich after Cunningham.)

fs. Superior frontal fissure. ip. Interparietal. IR. Island (Reili). pci. Inferior pre-central. pcs. Superior pre-central. ptc. Post-central. R. Central (Rolandi). S. Lateral (Sylvii). t. First temporal.

dorsal zone of the lamina terminalis. The different parts of the corpus callosum are formed in regular order—rostrum, genu, truncus, splenium—and this order coincides with the lines of growth in successive stages of cerebral development. The fibers of the corpus callosum pierce the dentate gyrus of the hemisphere vesicle. In so doing, they completely obliterate the superior part of the *hippocampus* and leave but *rudiments of the dentate gyrus*, namely, the gyrus supracallosus and gyrus subcallosus (longitudinal striæ and peduncle of the corpus callosum), the fasciola

cinerea and the small dentate fascia of the adult are the rudimentary remains.

Septum Pellucidum.—That part of the lamina terminalis which is included between the corpus callosum and the body of the fornix persists as the septum pellucidum. It develops a lymph space in the median plane, called the *fifth ventricle* (*cavum septi pellucidi*) and becomes so thin as to be translucent.

The above description, giving the origin of the septum pellucidum, corpus callosum and anterior commissure from lamina terminalis, is the one commonly accepted; but it is not their origin in the rabbit (Marshall) or in the rat (Zuckermandl), and there is still room for doubt concerning their origin in the human brain. It is possible that all or a part of them are developed in a crescentic area of fusion between the cerebral hemispheres, as in lower animals.

The **pars optica hypothalami** (Fig. 118) is developed in the ventral zones of the telencephalon. The tuber cinereum and the *infundibulum* are true derivatives of these telencephalic zones, but the *optic chiasma* is not. It is produced by the ingrowth of fibers from the retinae and the medial geniculate bodies.

DIENCEPHALON.

This is the posterior division of the anterior primary vesicle. It forms the **inter-brain** and contains the greater part of the **third ventricle** (Figs. 17, 118, V, and 119). Its lateral walls present on each side a distinct ventricular sulcus, the *sulcus hypothalamicus* (Monroi) (Fig. 119, B and C) which separates the ventral zone from the dorsal zone (?).

TABLE VII.

DERIVATIVES OF THE DIENCEPHALON.

	Derivatives.
Roof-plate	{ Roof epithelium of third ventricle.
	{ Corpus pineale (epiphysis).
Dorsal Lamina	{ Thalamus
	{ Corpora geniculata.
	{ Pars mammillaris hypothalami
Ventral Zone	{ Corpus mammillare
	{ A small part of tuber cinereum.
Surrounding Mesoblast	{ Chorioid tela and plexus of third ventricle.

The **roof-plate** of the diencephalon stretches out and becomes very thin, except at its posterior extremity (Figs. 118, V3, and 120). Its major portion forms the epithelium covering the third ventricle. Posteriorly, fibers grow through it from opposite sides and form a transverse white band, the *posterior commissure*. Immediately in front of this commissure, a diverticulum of the roof-plate appears which is the primitive *pineal body*. The pineal body soon becomes solid and is joined to the diencephalon by a

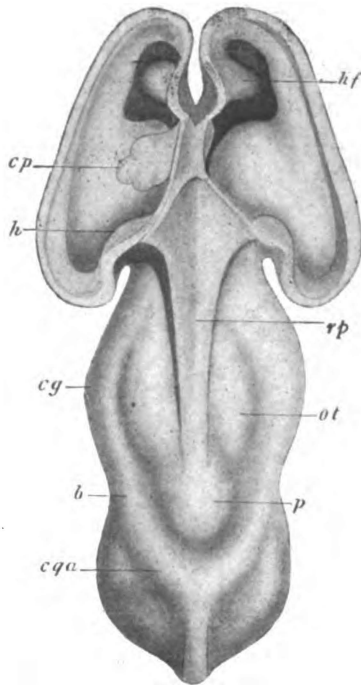


Fig. 124.—Dorsal view of an embryonic brain, the roof of the lateral ventricles having been cut away. Embryo of 12.6 mm. (McMurrich after His.)

b. Brachium superius. cg. Corpus geniculatum laterale. cp. Choroid plexus of lateral ventricle. cqa. Colliculus superior of corpora quadrigemina. h. Hippocampus. hf. Hippocampus and fissure. ot. Thalamus. p. Pineal body. rp. Roof-plate.

constricted *stalk* in which there is a conical prolongation of the ventricular cavity, called the *pineal recess* (Fig. 120). Anterior to the pineal body, two longitudinal folds of the roof-plate dip down into the ventricular cavity. These are followed by two

like downward projecting folds from the inferior lamina of the chorioid tela, which constitute the *chorioid plexuses* of the third ventricle.

The **dorsal lamina** of the diencephalon thickens greatly and so encroaches upon the ventricle as to convert it into a narrow median slit. Externally, the dorsal lamina fuses with the cerebral hemisphere, as a result of the formation of the *internal capsule*; and the fusion at one point of the medial surfaces of the two dorsal laminae gives rise to the *massa intermedia* (middle commissure). The development of the thickened dorsal lamina of the diencephalon produces the *thalamus* with its *pulvinar* and the *geniculate bodies* (Fig. 124).

The **ventral lamina and floor-plate** of the diencephalon constitute the *pars mammillaris hypothalami*, which embraces some gray and white matter beneath the thalamus, and the *corpora mammillaria* (Fig. 118, VI). A single oval eminence situated in the median line, represents the mammillary bodies up to the third month; but, during the third month, that eminence is divided into the two white bodies (*corpora albicantia*) of the adult. The gray substance immediately in front of the corpora mammillaria also belongs to this region, hence a part of the tuber cinereum is included among the derivatives of the diencephalon.

MESENCEPHALON.

This is the **mid-brain** (Figs. 17, 118, IV, and 120). It is the third of the secondary vesicles. The elbow of the mesencephalic flexure of 180 degrees is formed by it; and that flexure almost brings the diencephalon and metencephalon in contact with one another beneath it. The mesencephalon remains small, but its walls thicken greatly. As a result of the thickening, its cavity is reduced to a slender canal, the *cerebral aqueduct* (Fig. 120).

TABLE VIII.

DERIVATIVES OF MESENCEPHALON.

Dorsal Zones	{	Lamina quadrigemina Colliculi Brachia (in part) Red nuclei.
--------------	---	--

Ventral Zones	}	Stratum griseum centrale (in part)
		Nuclei of third, fourth and part of fifth nerve
		Nuclei laterales superiores
		Tegmenta (above isthmus)
		Substantia nigra (above isthmus).

Little is known about the development of the mid-brain. The origin of the derivatives tabulated above is largely inferred from their position and function. The formation of the *corpora quadrigemina* has been observed (Figs. 120 and 124). In the dorsal part of the mesencephalon, an elongated eminence on either side of median line is present at the beginning of the third month. Those two eminences resemble the corpora bigemina of birds, fishes and reptiles. Two months later a transverse groove divides each eminence into the *superior colliculus* and the *inferior colliculus*. By the growth of fibers through the marginal velum between the colliculi and the corpora geniculata the *brachium superius* and the *brachium inferius* are produced (Fig. 43). The *bases pedunculi* are produced, likewise, by the down-growth of fibers from the fore-brain, which traverse the marginal velum in the ventral region and, when medullated, form the prominent strands of the adult.

METENCEPHALON.

The metencephalon is the fourth of the secondary brain vesicles. From it are derived the **isthmus**, the **cerebellum** and the **pons** (Figs. 17, 118, III, and IV, and 120). Its dorsal wall, which forms the cerebellum, presents a transverse indentation, the metencephalic angle; and, as a result of that angle the opposite wall is bulged forward. The ventral wall of the metencephalon forms the pons. The cavity of this vesicle forms the *upper half of the fourth ventricle*. Superiorly, this cavity contracts to the size of the cerebral aqueduct; it expands inferiorly and is broadest at the junction of the pons with the medulla oblongata. The ventricular surface presents on each lateral wall a *longitudinal furrow* which divides the metencephalon into a ventral and a dorsal zone. In the adult the location of that furrow is indicated by the *sulcus*

limitans of the rhomboid fossa, containing the *jovea superior* and the *locus cæruleus*, hence, the pons comprises the greater portion of the metencephalon, including the entire ventral zone and a part of the dorsal zone.

TABLE IX.

DERIVATIVES OF METENCEPHALON (McMurrich, modified).

	Metencephalon Proper	Isthmus
Roof-plate	{ *Inferior velum { Cerebellar vermis	{ Superior velum, or valve of { Vieussens— contains de- { cussation of trochlear { nerves.
Dorsal Zones	{ Lobes of cerebellum { Terminal nuclei, of sensory { nerves (part of fifth and { eighth) { Ganglia of cerebellum (?) { Nucleus pontis (?)	{ Brachium conjunctivum of { cerebellum grows through { it.
Ventral Zones	{ Genetic nuclei of motor { nerves (fifth, sixth, sev- { enth) { Nuclei centrales and nucleus { lateralis medius of the re- { ticular formation	{ Inferior part of tegmen- { tum and of substantia { nigra. { The basis pedunculi grows { down through it.
Floor-plate	{ Median raphe	{ Median raphe.

Cerebellum.—It forms the roof of the upper part of the fourth ventricle, that is as far down as the transverse fold of invaginated roof-plate, called the *plica chorioidea*, produced by the metencephalic flexure (Fig. 118, between II and I). Above the plica chorioidea the dorsal laminæ of the metencephalon thicken rapidly and form a prominent transverse ridge on either side of the median line. The two thickenings are partially separated from each other in the median line by a deep ventricular sulcus but joined dorsally by a thin bridge of tissue, the metencephalic roof-plate. At this early stage there is no representative of the **vermis cerebelli**, the ridges represent the **hemispheres**. But very soon, cells from the dorsal laminæ invade and thicken the

roof-plate to the extent of obliterating the median ventricular sulcus and completely uniting the two dorsal laminae. The cerebellum is now represented by *one continuous transverse ridge* arching over the fourth ventricle. It develops slowly in comparison with the cerebrum. The lateral parts develop more rapidly than the median portion after the third month. Thus the hemispheres are differentiated from the vermis. The *flocculus* is the first lobule to be formed and it reaches a high development in the third month; other lobules of the hemisphere which are more characteristic of the human cerebellum, the *tonsil*, the *quadrangular lobe*, the *superior semilunar* and the *inferior semilunar lobules*, are not fully formed until near birth. The *jolium vermis* of the worm is developed after birth (Figs. 76 and 80).

Sulci (Fig. 79).—The chief sulci of the worm appear in the third month; with two exceptions, those of the hemisphere develop later. The lateral part of the *postnodular sulcus* is first manifest. In the second month it cuts off a strip of the cerebellar ridge, just above the chorioidal plica, which is the primitive flocculus. A little later the sulcus extends across the median line and forms the posterior boundary of the nodule. The next sulcus to develop is the *predeclivil sulcus* (Fig. 79). It cuts very deeply into the vermis between the culmen and the declive. From the vermis it extends into the hemispheres, where it separates the anterior and the posterior parts of the quadrangular lobe. The *prepyramidal* and the *postpyramidal sulci* are formed near the end of the third month (Fig. 79). In the fourth month the hemispherical part of the *postdeclivil sulcus* is first visible behind the quadrangular lobule (Fig. 76). Soon it becomes continuous through the vermis with that of the opposite hemisphere. It is the beginning of the fifth month before the prepyramidal sulcus is extended into the hemisphere between the tonsil and biventral lobule (Fig. 80). At about the same time the lateral extension of the postpyramidal sulcus establishes the posterior boundary of the biventral lobule. According to O. C. Bradley's study of the rabbit's cerebellum, the *postcentral sulcus* and the *precentral sulcus* appear at about the same time as the postdeclivil. The last important sulcus to appear is the *horizontal sulcus* (Figs. 76

and 80). It is not well formed until near birth and is produced almost wholly by the enormous growth of the superior and the inferior semilunar lobules which are so characteristic of the human cerebellum (Cunningham).

The cerebellar lobules are subdivided into gyri by *intralobular sulci* which develop in the later months of pregnancy and the early months of extrauterine life. There are two, called the *midgracile* and *postgracile sulci*, which Bradley says are found only in man and the anthropoid apes.

Cortex and Ganglia.—Little is known of the particular order and manner of development in either the cortex or ganglia of the cerebellum. As to the cortex, it consists in general, (1) of the multiplication and development of the cells in the mantle layer, some of whose processes descend to the cerebellar ganglia and Deiters's nucleus, and, (2) of the formation of contacts with in-growing fibers from pons, medulla and spinal cord.

Corpus Restiforme of Cerebellum.—Fibers from the cerebellar cortex descending to the medulla, and ascending fibers from the cord and medulla in their course to the cerebellar cortex, give rise to the *corpus restiforme* in the third month. Fibers from the nucleus pontis and nucleus fastigii form the *brachium pontis* a month later and in the fifth month the *brachium conjunctivum* is produced by fibers from the nucleus dentatus.

Pons (Figs. 118, II, I, 121 and 122).—The pons develops simultaneously with the cerebellum. The **ventral zone** of the metencephalon thickens greatly. The neuroblasts formed therein constitute the *nuclei of the pons* (?) and of the *reticular formation*, and the *motor nuclei* for the *fifth, sixth and seventh* pairs of cerebral nerves; the **dorsal lamina** in the lateral wall of the metencephalon, produces the neuroblasts which form the superior *olivary nucleus* and the superior part of the *terminal nucleus* of the *trigeminal* and of the *acoustic nerve*. From the nucleus pontis axones ascend through the lateral walls of the metencephalon to the cerebellum. They form most of the brachia pontis. At the same time, about the fourth month, the motor tracts composing the basis pedunculi grow downward into the ventral portion of the pons and the *fronto-pontal, temporo-pontal* and *intermediate tracts*

end in the nuclei pontis. The *pyramidal fibers* to motor nuclei of spinal nerves grow down through the pons, intersecting its transverse fibers.

MYELENCEPHALON.

The myelencephalon forms the **medulla oblongata** (Figs. 118, I, and 122). It is constricted off from the metencephalon at the twenty-eighth day; but, later, that constriction largely disappears and the common cavity of the two vesicles, broad in the middle

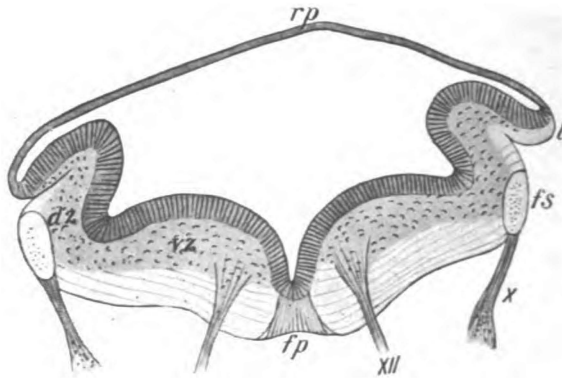


Fig. 125.—Transverse section of medulla from an embryo of 91. mm. (*McMurrich after His.*)

ds. Dorsal zone. fp. Floor-plate. fs. Tractus solitarius. l. Lip. rp. Roof-plate. vs. Ventral zone. X and XII. Tenth and twelfth nerves.

and contracted to a slender canal at each end, persists as the *fourth ventricle* of the mature brain. Like the metencephalon, the fifth brain vesicle is divided at the third week into a *ventral* and a *dorsal zone* by a deep furrow on the ventricular surface of each lateral wall (Figs. 125 and 126). That lateral furrow actually persists in the *sulcus limitans and inferior fovea* of the fourth ventricle. The *roof-plate* of the superior half of the myelencephalon stretches out widely and remains a single layer of epithelial cells. It forms no nerve tissue. Other portions of the myelencephalon develop quite uniformly. But by the expansion of the roof, just mentioned, the dorsal extremities of the lateral walls are pushed outward and

forward almost to the plane of the floor, and a transverse section of the vesicle in that region presents the form of a very broad capital V with the roof epithelium stretching between the two arms and converting the letter into a triangle. Transverse section through the lower half of the myelencephalon at the third or fourth week shows an elongated ellipse with a dorso-ventral major axis.

Internal Surface (Fig. 125).—The lateral wall, in both upper and lower regions, presents the longitudinal groove which separates the ventral and dorsal zones. The median ventral groove persists throughout and the lateral grooves are represented by the

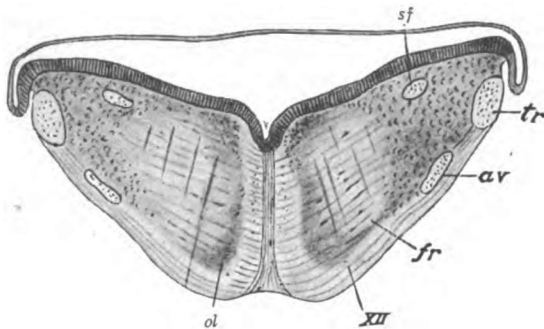


Fig. 126.—Transverse section of the medulla from an embryo of eight weeks.
(McMurrich after His.)

av. Spinal tract of the trigeminal nerve. fr. Substantia reticularis. Ol. Olivary nucleus of medulla. sf. Tractus solitarius. tr. Restiform body. XII. Hypoglossal nerve.

sulcus limitans and inferior fovea of the fourth ventricle (Fig. 96). The low eminence situated between the median and each lateral groove becomes the *eminencia medialis*.

External Surface (Figs. 125 and 126).—On the exterior surface of the myelencephalon, along the ventral border of the dorsal zone, there appears very early an oval bundle of descending fibers, called the *solitary tract*. It is composed of axones from the geniculate, glossopharyngeal and vagus ganglia, and constitutes the root-fibers of the intermediate, the ninth and tenth pairs of nerves. At about the same time axones from the semilunar ganglion form a bundle of descending

fibers on the lateral surface ventral to the solitary tract. They constitute the *spinal tract of the trigeminal nerve*. Soon after the appearance of the solitary tract and the spinal tract of the fifth nerve, the posterior margin of the dorsal lamina is folded outward and forward until it rests upon the external surface. That fold, which is called the *rhombic lip*, covers both the above bundles of fibers and places them in the position they occupy in the mature brain. Between the rhombic lips the roof epithelium stretches across the ventricle and pushes a transverse fold into it. The mesoblast which dips into that fold develops the *chorioid plexus of the fourth ventricle* (Fig. 91).

TABLE X.

DERIVATIVES OF MYELENCEPHALON.

(Modified from McMurrich.)

Roof-plate	}	Roof epithelium
		Nuclei funiculi—gracilis, and cuneati, and nucleus tractus spinalis n. trigemini.
Dorsal Zone	}	Olivary nuclei (inferior)
		Arcuate nuclei
		Terminal nuclei of sensory roots of cerebral nerves (intermediate, eighth, ninth and tenth)
		Sensory tracts grow up through it.
Ventral Zone	}	Nucleus lateralis inferior
		Genetic nuclei of motor roots and nerves, ninth, tenth and eleventh (its bulbar root) and twelfth
		Motor tract (pyramid) grows down through it.
Surrounding Mesoblast	}	Meninges—
		Chorioid plexus of fourth ventricle.

The **substance of the myelencephalon**, like other divisions of the neural tube, presents under the microscope *three distinct layers* at the fourth week of embryonic life (Fig. 125). The

outer layer, the *marginal velum*, is composed of neuroglia; the middle, or *mantle layer*, of neuroblasts; and the inner, or *ependymal layer* is made up of columnar epithelial cells.

The cells of the *inner layer* become ciliated and form the lining of the ventricle.

The *mantle, or middle layer* undergoes most development. Its neuroblasts form the substantia reticularis and the cerebral nerve nuclei and other nuclei of the medulla oblongata. In the **dorsal zone** the neuroblasts form the *terminal nuclei* for the eighth, ninth and tenth cerebral nerves and the nucleus funiculi gracilis, nucleus funiculi cuneati and nucleus of the spinal tract of the trigeminal nerve. As early as the fourth week axones may be traced from the nucleus funiculi gracilis and nucleus funiculi cuneati, ventro-medially, toward the point where they very soon form the *fillet decussation*. Neuroblasts which have wandered from the dorsal zone form the *arcuate, the olivary and accessory olivary nuclei*. The olivary nuclei are developed quite late in the intrauterine life (sixth month). The nucleus of the cuneate funiculus, the nucleus of the spinal tract of the n. trigeminus, the olivary and arcuate nuclei are all products of the rhombic lip (Cunningham). From the neuroblasts of the **ventral zone** are developed the gray matter and fibers of the substantia reticularis alba et grisea, and the *motor nuclei* of the twelfth, eleventh (cerebral part), tenth and ninth pairs of cerebral nerves.

The *neuroglia layer, or marginal velum*, forms the supporting matrix for the tracts of fibers in the medulla. By the third month the funiculus gracilis and funiculus cuneatus, extensions of the same fasciculi in the cord, have grown up to their terminal nuclei in the medulla. The restiform body is at that time well developed, and the tracts of the lateral area of the medulla are visible. The medial longitudinal bundles appear near the median raphe in the ventral zone at about the same time; and, ventral to them, fibers from the fillet decussation insinuate themselves and form the interolivary stratum of the medial fillets. The great motor tracts from the anterior central gyrus of the cortex reach the medulla at the fourth month. Growing downward in the neuroglia layer, on either side of the median line, they conceal the

medial fillets and form the pyramids of the medulla oblongata. The form of the medulla is completed two months later (the sixth month) by the appearance of the olivary bodies (Fig. 93).

SPINAL CORD.

That portion of the neural tube which is situated behind the metencephalon is the embryonic spinal cord (Figs. 16 and 118). It is of nearly uniform size from cephalic to caudal end. The lumen of the neural tube in this region is at first large and elliptical in shape. Later, at the sixth week, it has a diamond shape, the acute angles of the diamond being formed by the roof-plate and floor-plate of the canal; it is lined with columnar ciliated cells (Fig. 117). As the walls thicken the canal is contracted more and more until it reaches the capillary size of the adult cord. The canal is continuous with the fourth ventricle above and dilates to form the *ventriculus terminalis* in the filum terminale internum (Fig. 110). The spinal part of the neural tube forms the whole substance of the spinal cord, with the exception of the great motor tracts that grow into it from the brain, and the sensory tracts and fibers that enter it from the spinal ganglia. At the sixth week of embryonic life the anterior and posterior roots of the spinal nerves are clearly seen; they are horizontal in direction. The cord extends to the fourth mesoblastic somite of the coccyx, when the somites are first laid down; but, as no neuroblasts are developed by the three lower segments of the human cord, they form a connective tissue strand, the primitive *filum terminale* (McMurrich). The cord occupies the entire length of the spinal canal until the third month, when the caudal end begins to recede and the filum terminale to lengthen. It reaches only to the third lumbar vertebra at birth and, in the adult, but to the lower border of the first lumbar vertebra. With the rapid growth of the spinal column, the roots of the lumbar, sacral and coccygeal nerves and the filum terminale become greatly elongated and form the *cauda equina*.

Meninges.—The investing mesoblast of the neural tube develops the meninges of the spinal cord.

Zones (Figs. 117 and 127A).—By the sixth week of intrauterine

life the neural tube, in the spinal region, is divided into a *ventral* and a *dorsal zone* by a lateral groove on either side, continuous with that formed in the rhombencephalon two weeks earlier. The tube presents externally, opposite to each lateral groove, a furrow in the mantle layer representing the concavity of the gray crescent and called the *central fissure*; it is occupied later by the lateral pyramidal and other tracts. The whole of the spinal cord ventral to the bases of the posterior columnæ of gray matter is represented by the ventral zones. From them grow out the

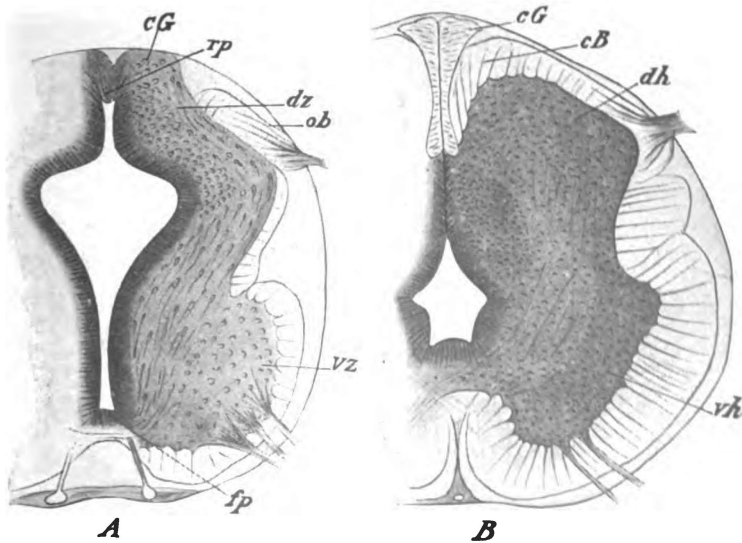


Fig. 127.—Transverse sections through the spinal cords of embryos of (A) about four and a half weeks and (B) about three months. (*McMurrich after His.*)

cB. Fasciculus cuneatus (Burdachi). *cG.* Fasciculus gracilis (Goll). *dh.* Posterior columnæ. *dz.* Dorsal zone. *fp.* Floor-plate. *ob.* Oval bundle (His). *rp.* Roof-plate. *vh.* Anterior columnæ. *vz.* Ventral zone.

anterior roots of the spinal nerves. In the dorsal zones the posterior columnæ and the posterior columns of fibers are developed. They receive the *posterior roots* of the spinal nerves (Figs. 117, 127 and 128).

Three Histologic Layers (Figs. 116 and 127A).—At a time somewhat earlier than the division into ventral and dorsal zones, even at the fourth or fifth week, the spinal part of the neural tube

presents three microscopic layers, like those seen earlier in the brain vesicles.

The *outer layer, or marginal velum*, composed of neuroglia, is very thin except in the central fissure and in the floor and roof of the tube on either side of the median line. In those situations are formed the lateral, the anterior and the posterior funiculi of the cord.

The *mantle layer* is gray matter. It contains the neuroblasts. At the fourth or sixth week it is very thick, comprising nearly all of the neural tube. The *H-shaped column* of gray sub-

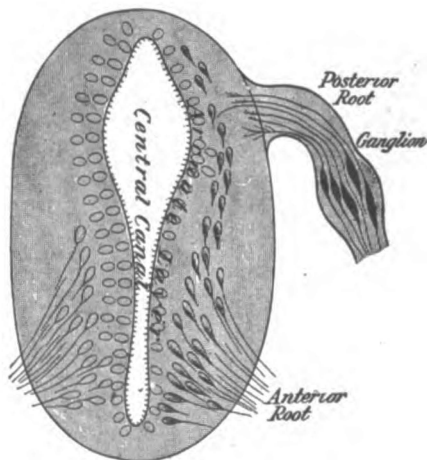


Fig. 128.—Mode of origin of anterior and posterior roots of spinal nerves. Diagrammatic. (Brubaker and Edinger after His.)

stance is derived from this layer. In the **ventral zone** the neuroblasts develop earliest. They collect near the floor of the tube and form a large column on either side of the median line, the *anterior column*. The axones of the more ventrally located neuroblasts grow centrifugally out of the antero-lateral surface of the neural tube. They form the *anterior roots* of the spinal nerves. The more dorsally located neuroblasts develop axones also; but on account of meeting resistance, according to His, they become longitudinal and form the fasciculi proprii of the cord and, perhaps, the ascending anterior cerebello-spinal and the spino-thala-

mic tracts. The gray matter in the **dorsal zone** develops later. It becomes transformed into the *posterior column*; its neuroblasts form largely intrinsic neurones, their processes remaining in the spinal cord, others give rise to the posterior cerebello-spinal tract which ascends through the marginal velum to the vermis superior of the cerebellum. Axones from the spinal ganglia, forming the *posterior roots* of the spinal nerves, grow into the dorsal zone; and each axone divides T-like into a descending and an ascending branch, and also gives off many collaterals both before and after division. The ascending fibers for a time form the *oval bundle of His* on the surface of the tube; later, they constitute the marginal tract (Lissaueri) and the fasciculus cuneatus (Burdachi) and fasciculus gracilis (Golli).

The *third, or ependymal layer*, lines the ventricle. It is composed of neuroglia covered internally by columnar ciliated cells, which appear about the fifth week.

The Longitudinal Tracts (Figs. 101, 102 and 103).—The white columns of the spinal cord are formed in the superficial, or neuroglia layer. At first they are composed of nonmedullated fibers, and it is a remarkable fact that the various tracts receive their myelin sheaths at definite periods between the fifth and ninth months of intrauterine life (Flechsig). The anterior nerve-roots and the anterior and lateral fasciculi proprii, and the posterior nerve-roots and the oval bundles of His are first to make their appearance. The axones of these nerves-roots and tracts may be seen at the sixth week. The ascending cerebello-spinal tracts follow, and the descending cerebello-spinal and the pyramidal tracts are last to appear; they are not developed before the fourth or fifth month. According to Kahler, as quoted by Cunningham, the tracts of the spinal cord are medullated as follows:

1. Fibers of the fasciculus cuneatus with the posterior nerve-roots, preceded by the medullation of the anterior nerve-roots (fifth month).
2. Fibers of anterior and lateral fasciculi proprii (fifth and sixth months).
3. Fibers of fasciculus gracilis (sixth month).
4. Posterior cerebello-spinal tract (seventh month).

5. Ascending anterior cerebello-spinal and spino-thalamic tracts (?) (eighth month).
6. Pyramidal tracts (ninth month).

Fissures (Fig. 101).—The so-called *posterior median fissure* is in reality a septum of neuroglia. At no time is it a true fissure. Its mode of formation is still in doubt. It appears to be produced by thickening in the roof-plate due to the elongation of ependymal cells. From the sixth week this neuroglia septum extends ventrally until it reaches the center of the cord.

The *posterior lateral sulcus* is the groove between the lateral border of the posterior column and the dorsal border of the lateral column. It is the development of the posterior and lateral columns that produces the fissure. The embryonic central fissure is obliterated and the postero-lateral surface of the cord rendered prominent by the formation of the lateral fasciculus proprius, the cerebello-spinal and the pyramidal tracts.

Anterior Median Fissure.—That is a true fissure. It begins to be formed at the sixth week, when the anterior columnæ and the earliest fibers of the anterior fasciculus proprius are developing. It deepens with the growth of the gray columnæ and of the anterior fasciculus proprius and its walls are further heightened, in the fourth or fifth month, by the descent of the anterior pyramidal tracts. In this manner there is produced a bulging of the anterior surface on either side of the median line, which increases with the medullation of the longitudinal tracts up to the ninth month. The ridges thus produced, failing to fuse completely, become the walls of the anterior median fissure. The partial fusion which does occur between the two ridges is due to the formation of the white anterior commissure of the cord.

ADDENDA.

According to Head, Rivers and Sherren (Brain, 1905) three distinct mechanisms operate in the production of common sensation, one concerned with deep sensibility and two with superficial sensibility. The *mechanism of deep sensibility* includes the nerves supplying muscles, tendons, joints and ligaments. Though it may be affected by environment, it is chiefly acted upon by stimuli originating within the organism, such as pressure (resulting from weight and inertia) and tension. It may give rise to painful sensations, but its principal concern is with muscular tonicity and equilibrium. The nerves of the deep mechanism constitute the "proprio-ceptors" of Sherrington. They are so named because their stimuli are furnished chiefly by the organism itself (Brain, 1906). The mechanisms of *superficial (cutaneous) sensibility* are called by Head, Rivers and Sherren the Protopathic and the Epicritic. The *protopathic mechanism* responds to painful cutaneous stimuli and to extremes of heat and cold. It may set up reflexes without arousing consciousness. Cutaneous localization is no part of its function. The *mechanism of epicritic sensibility* is adapted to mild stimuli, to light touch, to warmth, to coolness. By it the localization of cutaneous stimuli is accomplished and its activity usually involves consciousness. It may also produce reflexes through the efferent nerves. Sherrington speaks of these two mechanisms as the "extero-ceptors" and gives the name "intero-ceptors" to the nerves of the interior surfaces, those of the alimentary tract, etc. The "intero-ceptors" are especially adapted to chemical stimuli and give rise to digestive reflexes; but they may also produce pain and temperature sensations, and may respond to stimuli occasioned by tension and pressure. See pages 365 and 377.

INDEX.

- Abducent nerve, 45, **153**, 321
- Accessory lemniscus, 227
 nerve, 5, 49, **153**, 293, 322
 nucleus funiculi cuneati, 311
- Acoustic center, 181
 nerve, 46, **153**, 209, 320
 radiation, 100, 104, 217, 226,
 232, 233, 310
- Acustico-cerebellar tract, 264
- Afferent neurone, 171
 paths, 377
 root, 303
 sympathetic fibers, 348
- After-brain, 33
- Ala cinerea, **149**, 270, 290, 317
- Alveus, 200, 201
- Amygdala, 123, 124
- Angular gyrus, 43, 61, 63, 67
- Ansa lenticularis, 100, **145**
 peduncularis, **145**, 212
- Anterior area of medulla, 293
 association center, 182
 brain vesicle, 30
 calcarine fissure, 89
 central gyrus, 39, 59, 60, 61
 central artery, 331
 cerebral artery, 4, 6, **15**, 16, 25
 vein, 23
 chorioidal artery, **15**, 18, 19
 communicating artery, 14, **15**, 16
 commissure of cerebrum, 30, **95**,
 109, 131, 136, **137**, 234, 235,
 411, 413
 column, **335**, 339, 399, 427,
 428
 neurones, 165, 340
 external arcuate fibers, 292, **295**,
 297
 fasciculus proprius, 354
 horn of lateral ventricle, 120, **137**,
 209, 235
 inferior cerebellar artery, **15**, 27,
 29
 internal frontal arteries, 16
- Anterior lateral sulcus of cord, **335**,
 338
 lateral sulcus of medulla, 41, **153**,
 295
 longitudinal bundle, 158, 161,
 163, 219, 276, 295, 297, 305,
341, **345**, 355
 median fissure of cord, **335**, 337,
 349, 430
 median fissure of medulla, 41,
 285, 286, 295, 337
 median vein of medulla, 24
 orbital gyrus, 74
 parolfactory sulcus, 86
 perforated substance, 38, 47, 79,
 207, 235, 267
 pyramidal tract, 289, 294, **341**,
 345, 353
 radicular artery, 331
 root-line, **335**, 338
 root of spinal nerve, 327, 334,
 349, 363, 399, 427, 428
 slender lobule, 252, 253, 256
 spinal artery, 5, **15**, 24, 27, 330,
 331
 subarachnoid space, 8, 327, 329
 surface of medulla, 267, 286
 of mid-brain, 267
 of pons, 266, 267
 temporal artery, 19
 tubercle of thalamus, 140, **149**,
 243
- Antero-lateral ganglionic arteries, **15**,
 18, 19, 22
 fasciculus proprius, 354
 median ganglionic arteries, 18,
 19
- Apertura mediana ventriculi quarti
 (Magendi), 9, 290
 lateralis ventriculi quarti (Key
 and Retzii), 9, 290
- Aqueduct of cerebrum, 37
 Aqueductus cerebri, **37**, **75**, 152, 161,
 270

- Arachnoid granulations, 5, 6, 65
 of brain, 8, 9
 of cord, 326, 327, 329
 Arachnoid of brain and cord com-
 pared, 9
 Arachnoidea encephali, 8
 spinalis, 326
 Arbor vitæ, 247, 262
 Archipallium, 98
 Arcuate fibers, 291
 nucleus of medulla, 295, 297,
 302
 nucleus of thalamus, 211
 Arcus occipito-parietalis, 64, 69
 Area acustica, 149, 270, 290, 318
 parolfactoria (Brocæ), 47, 75,
 91, 94, 200
 postrema, 270, 318
 for educated movements of cere-
 brum, 178
 Arteria basilaris, 14
 carotis interna, 14, 25
 cerebelli inferior anterior, 27, 29
 inferior posterior, 27, 29
 superior, 27
 cerebri anterior, 16, 25
 media, 16
 posterior, 17, 25
 chorioidea anterior, 18
 communicans anterior, 14, 25
 posterior, 14, 25
 meningeæ media, 6, 7
 spinalis anterior, 24, 27, 330
 posterior, 24, 27, 330
 vertebralis, 14, 27
 Arteriæ chorioideæ posteriores, 17
 pontales, 24
 Arterial circle, 14
 Arteries of dura, 6
 of pia mater, 10
 of spinal cord, 330, 331
 Artery of cerebral hemorrhage (Char-
 cot), 18
 Ascending anterior cerebello-spinal
 tract, 287, 295, 297, 298,
 305, 311, 341, 345, 356
 anterior ramus of lateral fissure
 of cerebrum, 57
 frontal arteries, 16, 19, 22
 parietal arteries, 17, 19, 22
 part of medial longitudinal
 bundle, 157
 postero-medial tract, 360
 Ascending postero-lateral tract, 361
 tracts of spinal cord, 352
 Association fibers of cerebellum, 262,
 265
 fibers of cerebrum, 224, 236
 Meynert, 192
 Associative centers of Flechsig, 182
 Atypical cortex, 192
 neurones, 191
 Auditory artery, 5
 center, 70, 71
 conduction path, 160
 paths, 280, 385
 Auditory and facial nerve, 5
 Aula of third ventricle, 30, 137,
 141
 Axones, 168, 169, 398, 400
 Axone hillock, 167, 169
 Axis cylinders, 168, 169
 Baillargic line (Gennari), 188
 zone of cerebral cortex, 184
 Bandalette of Hoche, 345, 362
 Base of brain, 36
 of cerebral hemisphere, 73, 75
 of fore-brain, 52, 73, 75
 Basilar artery, 5, 14, 15
 plexus, 4, 5
 vein, 23
 Basis pedunculi, 4, 30, 38, 47, 75,
 115, 145, 146, 147, 153,
 157, 159, 161, 418
 Basket cells of cerebellar cortex, 257,
 259
 Bechterew's accessory lemniscus, 227
 superior nucleus, 277, 280, 308
 Betz, giant pyramids of, 188
 Bipolar neurones, 400, 401
 Biventral lobules, 252, 254, 255
 Blood supply of brain, 14
 of cerebellum, 27
 of cerebrum, 14
 of medulla oblongata, 24
 of pons varolii, 24
 of spinal cord, 330
 Body of fornix, 101, 109
 Boundaries of fourth ventricle, 313,
 Brachia of corpora quadrigemina, 30,
 146, 164
 Brachium conjunctivum cerebelli (or
 brachia conjunctiva), 13,
 146, 149, 162, 231, 245, 246,
 252, 261, 263, 275, 289

- Brachium inferius of corpora quadrigemina**, 146, 147, 149, 163, 164, 418
pontis, 13, 41, 149, 209, 245, 246, 247, 252, 255, 264, 267, 289
superius of corpora quadrigemina, 147, 157, 163, 164, 207, 416, 418
Brain, 31
 general considerations, 34
 vesicles, 30, 34, 395, 402, 403
Bruce and Muir's septo-marginal tract, 361
Bulb of posterior horn of lateral ventricle, 123, 131
Bulbus olfactorius, 77
Burdach's column, 300, 361
Buried gyrus, 64

Cajal's moss-like appendages, 260, 259
 tassel cells, 199
Calamus scriptorius, 149, 317
Calcar avis, 123, 125, 131, 133, 410
Calcarine artery, 17
 fissure, 43, 75, 86, 89, 91, 95, 121, 409, 411
Calleja's olfactory islets, 199
Callosal sulcus, 80, 86, 91, 95, 101, 410
Calloso-marginal sulcus, 86
Canalis centralis spinalis, 337
Capsula interna, 99
Cauda equina, 333, 334
Caudate nucleus, 101, 105, 109, 115, 116, 123, 125, 137, 145, 204, 207, 209, 235
Cava subarachnoidea, 8
Cavernous sinus, 3, 5
Cavum septi pellucidi, 111, 415
Cell-body of neurone, 167, 169
Cell-columns of cord, 340, 341, 344, 345, 347
Cells of anterior columna, 340
 of granular layer of cerebellum, 258
 of posterior columna, 347
 of Purkinje, 257, 258, 259
Cell and fiber lamination of cerebral cortex, 183, 185, 189, 193, 197

Cellulifugal conduction, 168
Cellulipetal conduction, 168
Center median (Luysi) of thalamus, 211
 of abstract concept, 182, 182
 of concrete concept, 182, 183
 of crescent, 344
 of equilibrium, 71, 181
 of intonation, 71, 181
 of macular vision, 67
 of muscular sense, 178
 of optic reflexes, 324
 of orientation, 71, 181
 of smell, 82, 94, 181
 of stereognosis, 178
 of taste, 94, 98, 181
 of visual memories, 67, 69
Central canal of cord, 399, 428
 of lower medulla, 305
 cells of anterior columna, 343, 345
 gray substance of medulla, 305
 lobule, 247, 250
 part of lateral ventricle, 112
 sulcus (Rolandi), 56, 57, 410, 414
 sulcus of island, 72
 tegmental tract, 277
 or ventricular gray matter, 221
Centrifugal arteries, 331
 fibers of corpus striatum, 207
Centripetal arteries, 331
 fibers of corpus striatum, 208
Centrosome, 167
Centrum semiovale, 177
Cerebellar hemispheres, 242
 notches, 244
 vermis or worm, 243
Cerebello-olivary fibers, 265, 292, 295, 312
Cerebello-spinal fasciculus (posterior), 288, 301
Cerebellum, 31, 33, 35, 36, 37, 38, 43, 53, 209, 242, 418, 419
 blood supply of, 27, 29, 30
 veins of, 29, 30
Cerebral aqueduct (Sylvii), 4, 30, 34, 87, 132, 147, 152, 247, 417
 cortex and medulla, 177, 411
 gray substance, 174
 hemispheres, 30, 35, 37, 51, 98
 localization, 177
 nerves, 47, 318
 peduncle, 209, 267
 reflexes, 392

- Cerebro-pontal paths, frontal, temporal and intermediate, 369
- Cerebro-spinal paths, 366
reflexes, 393
- Cerebrum, 30, 31, 33, 50
- Cervical enlargement of spinal cord, 333, 334, 335
flexures, 402
- Charcot's artery of cerebral hemorrhage, 18
- Chiasma opticum, 38, 82, 83
- Chief nucleus of vestibular nerve (Schwalbe), 283
- Choroid epithelial lamina of lateral ventricle, 124, 412
plexus of fourth ventricle, 13, 290, 314, 424
of lateral ventricle, 10, 80, 90, 120, 124, 125, 127, 136, 145, 209, 235, 289, 406, 412, 416
of third ventricle, 10, 129, 132, 209, 417
tela of fourth ventricle, 10
of third ventricle, 10, 11, 90, 95, 131, 132, 135
- Choroidal fissure, 80, 86, 90, 95, 101, 124, 127, 133, 406, 407, 409, 411
groove of thalamus, 137, 140, 147
vein, 11, 21, 129
- Chromophilous cells, 204
- Ciaglinski's sensory tract, 350
- Cilio-spinal centers, 298
- Cingulum, 237, 238
- Circular sinus, 4, 5
sulcus, 70
- Circulation of cerebrum, 14
of rhombencephalon, 14, 24
- Circulus arteriosus (Willisi), 14
- Cisterna cerebello-medullaris, 9
interpeduncularis, 9
pontis, 9
- Claustrium, 101, 145, 204, 209, 235
- Clava, 13, 246, 289, 300, 310
- Cochlear nerve, 280
nucleus, 280, 302, 305, 309, 323
path, 386
- Cohnheim's end arteries, 18
- Collaterals, 168, 169, 398
- Collateral fissure, 75, 80, 81, 86, 90, 91, 95, 101, 410
- Colliculi of corpora quadrigemina, 147, 149, 163, 243, 246
- Colliculus facialis, 149, 209, 270, 277, 317
inferior of corpora quadrigemina, 149, 163, 220
superior of corpora quadrigemina, 149, 159, 163, 219, 243, 416
- Columna anterior, 339
fornicis, 105, 110, 131, 239
lateralis, 335, 341, 344
posterior, 347
- Columnæ of fornix, 110, 131, 132, 137, 139, 209, 212, 235
- Comma tract of Schultze, 341, 361
- Commissura anterior alba, 351
anterior cerebri, 31, 136, 201
anterior grisea, 350
grisea of spinal cord, 338, 350
habenularum, 111, 135
hippocampi (Fornix), 51, 110, 125, 131, 236, 412, 414
inferior (Guddeni), 218, 221
posterior cerebri, 132
posterior of cord, 350
superior (Meynerti), 218, 221
- Commissural fibers of cerebellum, 262, 265
of cerebrum, 224, 234
nucleus, 305, 306
- Common sensory area of cerebrum, 178
nuclei of cerebral nerves, 322
paths 375, 377, 379
- Confluens sinuum, 2
- Conus medullaris, 31, 334
- Co-ordinating and equilibrating reflex, 390
- Convex surface of fore-brain, 52
- Corona radiata, 209
- Cornu anterius ventriculi lateralis, 120
commissural tract, 345, 362
inferius ventriculi lateralis, 123, 133
posterius ventriculi lateralis, 123, 133
- Corpora albicantia (see corpus mammilla), 85, 221
geniculata, 30
quadrigemina, 28, 30, 37, 109, 146, 163, 219, 418
mammillaria (see corpus mammillare)

- Corpus callosum, 6, 25, 30, 51, 87, 91, 101, 104, 109, 117, 112, 145, 209, 234, 235, 411, 413, 414
 dentatum, 260
 geniculatum mediale, 143, 147, 149, 218, 221
 geniculatum laterale, 143, 147, 218, 416
 Luysi, 143, 145
 mammillare (or corpora mammillaria), 30, 38, 47, 75, 82, 85, 87, 95, 131, 145, 153, 207, 209, 221, 267, 417
 medullare cerebelli, 242, 244, 247, 255, 261, 262
 pineale, 30, 75, 132, 137, 243
 restiforme, 149, 246, 264, 288, 301, 421
 striatum, 28, 36, 37, 98, 115, 204, 410
 trapezoideum, 272
 Cortex of cerebellum, 242, 256, 258, 259
 and ganglia of cerebellum, 421
 Cortical areas of convex surface of cerebrum, 175, 182
 of medial surface of cerebrum, 179, 183
 of smell, 82, 94, 181
 gray matter of cerebrum, 177
 connection of abducent nucleus, 282
 of anterior column, 343
 of cochlear nuclei, 310
 of facial nucleus, 282
 of genetic nuclei of cerebral nerves, 324
 of motor nuclei in medulla, 305
 of nucleus *alæ cineræ*, 306
 of oculomotor and trochlear nuclei, 223
 of olfactory nucleus, 324
 of terminal nuclei of optic nerve, 324
 of trigeminal nucleus, 281, 307
 of vestibular nuclei, 308, 323
 fillet, 104, 160, 216, 232, 233
 localization, 177
 system of arteries, 15
 Corticifugal fibers of cerebrum, 225
 Corticopetal projection fibers, 231
 Cortico-striate radiation, 207
 Crista galli, 4
 Crossed descending tract of red nucleus (see rubro-spinal tract)
 ponto-spinal tract, 280
 pyramidal tract, 287
 Crown of hippocampal gyrus, 196
 Crus fornicis, 95, 101, 105, 110, 124, 131, 133, 237
 Culmen monticuli, 87, 243, 245, 247, 250
 Cuneate gyrus (see cuneus)
 tubercle, 13, 289, 310
 Cuneus, 25, 97
 Declive monticuli, 87, 243, 247, 251
 Decussatio lemniscorum, 291, 292
 pyramidum, 41, 291
 Decussation of brachia conjunctiva, 156, 161, 245, 261, 263, 275
 of pyramids, 209, 267, 291, 294
 Deep transverse fibers of pars basilaris pontis, 271, 275
 veins of pons, 27
 vena cerebri media, 23
 Defecation reflex, 391
 Degeneration of neurones, 171
 of Nissl, 171
 of Waller, 171
 Deiter's cells, 340, 348
 dorso-lateral vestibular nucleus, 280, 308
 Dendraxone, 168
 Dendraxones of Golgi, 191
 Dendrites, 165, 167, 169, 399, 401
 Dentate fascia, 82, 101, 124, 127, 415
 gyrus, 411, 414
 nucleus, 255, 260, 277
 Derivatives and ventricles of brain vesicles, 403
 of diencephalon, 415
 of mesencephalon, 417
 of metencephalon, 419
 of myelencephalon, 424
 of telencephalon, 404
 Descending anterior cerebello-spinal tract, 287, 298, 305, 311, 341, 345, 352, 356
 part of medial longitudinal bundle, 158
 postero-medial tract, 361
 postero-lateral tract, 362

- Descending root of trigeminal nerve, 163, 275, 277
 tracts of spinal cord, 352
 Destruction of special sense paths, 389
 Destructive lesions of cerebral cortex, 183
 Development of brain, 401
 of neurones, 172
 of peripheral common sensory neurones, 400
 Diameters of spinal cord, 333, 334, 335
 Diagram of brain ventricles, 141
 Diaphragma sellæ, 5, 84
 Diencephalon, 28, 30, 127, 402, 415,
 Digitations of hippocampus, 124
 Direct cerebellar tract (see posterior cerebello-spinal tract), 264, 301, 357
 motor paths, 367
 pyramidal tract (see anterior pyramidal tract)
 Dorsal accessory olivary nucleus, 297, 312
 longitudinal fibers of pons, 272
 tegmental decussation (Meynerti), 156, 157, 159
 view of brain ventricles, 141
 zone, 422, 427
 Dorso-medial cells of cord, 340, 341
 vestibular nucleus (of Schwalbe), 280, 307
 Dorso-lateral cell-group, 341, 343, 345
 vestibular nucleus (Deitersi), 280, 308
 Dorso-ventral fibers of medulla, 292
 of spinal cord, 351
 Dura mater encephali, 1
 of brain, 1, 6
 of cord, 326, 327, 329
 spinalis, 326
 of brain and cord compared, 7
 Ectorhinal sulcus, 80, 86, 90, 95
 Efferent neurone, 169, 171
 paths, 366
 root, 363
 sympathetic fibers, 344
 Elements of olfactory bulb, 196, 203
 Embryologic divisions of the brain-table, 30
 Embryological method of locating tracts, 352
 Embryology of brain and spinal cord, 395
 Embryonic neurones of spinal cord, 172
 Eminentia cinerea, 317
 collateralis, 93, 124, 131, 133, 411
 medialis, 290, 423
 Emissive motor area of cerebrum, 63, 177
 Encephalon, 31
 general considerations, 34
 End arteries of Cohnheim, 18
 End-brain, 30, 33, 50, 51, 73
 End-brush of axones, 168
 Entry zone, 341, 345, 359
 Ependymal cells, 173, 174, 397
 layer of embryo, 398, 425, 429
 Epiblast, 395, 396
 Epiblastic sustentacular tissue, 173
 Epiphysis, 135
 Epithalamus, 28
 Equilibrium reflex, 393
 Experimental methods of locating tracts, 353
 Exterior surface of fore-brain, 51
 External arcuate fibers, 265, 292
 capsule, 101, 105, 113, 145, 209, 235
 layer of large pyramids of cerebrum, 184, 187
 perpendicular sulcus, 67, 69
 spinal veins, 331, 332
 surface of temporal lobe, 70
 veins of cerebrum, 22
 Facial nerve, 45, 153, 209, 321
 Facies anterior of medulla, 286
 cerebelli inferior, 251
 superior, 248
 convexa cerebri, 52
 lateralis of medulla, 287
 posterior of medulla, 288
 Falx cerebelli, 2, 3
 cerebri, 1, 2, 3, 4, 6, 407
 Fascia dentata, 90, 97, 131, 200, 201
 Fasciculus antero-lateralis proprius, 297, 305, 311, 341, 345, 354
 ascendens cerebello-spinalis anterior, 298, 356

- Fasciculus cerebello-spinalis posterior**, 301, 357
 cerebro-spinalis anterior, 355
 lateralis, 358
 cuneatus, 335, 341, 361, 427
 descendens cerebello-spinalis anterior, 298, 356
 gracilis, 335, 341, 360, 427
 lateralis proprius, 298
 longitudinalis inferior, 131, 201, 237, 240
 medialis, 156, 276, 296, 354
 pyramidalis, 148
 superior, 237, 240
 ventralis (see anterior longitudinal bundle)
 mammillaris princeps, 110, 222
 marginalis (Lissaueri), 341, 345, 359
 occipito-frontalis (Foreli), 239, 241
 olivaris, 208, 277
 pedunculo-mammillaris, 85, 110, 222
 perpendicularis, 237, 241
 posterior proprius, 362
 thalamo-mammillaris (Vicq d' Azyri), 85, 110, 237
 uncinatus, 237, 239, 240
- Fasciola cinerea**, 82, 97, 414
Fastigium, 244, 247
Felt-work of Kaes, 184, 191
Fiber zones, 184
Fibers of granular layer of cerebellar cortex, 260
 of Meynert, 192
 of superficial layer of cerebral cortex, 257
Fibrillæ of neurones, 167
Fibrous sheath of Henle, 168
Fifth nerve, 3
 ventricle, 111, 121, 415
Fila lateralia pontis, 271
Fillet, 159
 decussation, 292, 305, 425
Filum terminale externum, 330
 terminale internum, 330, 333, 334, 334
Fimbria hippocampi, 124
First cerebral vesicle, 35
Fissura calcarina, 25, 86, 89
 cerebri lateralis, 53, 55, 57, 61, 63, 91
 chorioidea, 80, 86, 90, 95, 411
 collateralis, 75, 80, 81, 86, 90, 131
 hippocampi, 80, 86, 90, 95, 131, 201
 longitudinalis cerebri 35, 39, 43, 52, 53
 mediana anterior, 337
 posterior, 337
 occipito-parietalis, 409
 rhinalis, 93
 transversa cerebelli, 36
 cerebri, 35, 55
Fissural arteries, 331
Fissure, 52
Fissures of convex surface of cerebrum, 52
 of medial and tentorial surface, 85
 of spinal cord, 335, 337, 430
Flechsig's oval tract, 361
 sensory bundles of internal capsule, 232
 superior nucleus, 308
Flexures, 402
Flocculus, i. of cerebellum, 209, 245, 252, 253, 420
Floor of fourth ventricle, 246, 270, 290, 314, 334
Floor-plate of neural tube, 400, 422, 427
Folium vermis, 87, 243, 247, 251
Foramen cæcum (Vicq d'Azyri), 153
 interventriculare (foramina inter-ventricularia) (Monroi), 30, 87, 112, 132, 141, 411
Forceps major of corpus callosum, 108, 123
 minor of corpus callosum, 108, 120
Foreli's ventral tegmental decussation, 156, 157, 159
Fore-brain, 30, 31, 35, 50, 51, 407
Formatio reticularis of cord, 335
 of mid-brain, 155, 157, 159, 161, 273, 339
 of pons, 273, 275, 277
Fornix, 11, 30, 87, 91, 95, 97, 101, 109, 121, 129, 131, 145, 237, 238, 412, 413
Fossa cerebri lateralis, 413
 interpeduncularis, 146, 153, 159
 rhomboidea, 314

- Fourth nerve, 3, 5, 13, 289
 ventricle, 9, 13, 33, 37, 147, 242, 275, 285, 289, 313, 422
- Fovea inferior, 149, 290, 317
 superior, 149, 269, 317
- Foveolæ granulares, 6
- Frænulum veli, 13, 147, 246
- Frenulum of Giacomini, 94
- Frontal lobe of cerebrum, 37, 53, 59, 73, 75, 87, 91, 98
 part of internal capsule, 103
 pole of cerebrum, 50, 53
 stalk of thalamus, 103, 216, 226, 232
- Fronto-marginal sulcus, 60
- Fronto-pontal tract, 103, 151, 159, 225, 226
- Function of cerebellum, 242
 of neurones, 171
 of posterior root, 364, 365
- Functional areas of cerebrum, 175, 177, 179, 182, 183
- Funiculus anterior, 335, 352
 cuneatus, 288, 300, 305, 311
 gracilis, 288, 300, 305, 311
 lateralis, 335, 352
 of medulla, 153, 287
 posterior, 335, 352
 separans, 270
- Fusiform gyrus, 79, 81, 95
 layer, 191
- Galen's great cerebral vein, 136
 internal cerebral veins, 129
- Gambault and Philippe's median triangular tract, 361
- Ganglia, 400, 401
 of cerebral nerves, 400
- Ganglion interpedunculare, 151
 jugulare, 49
 nodosum, 49
 semilunare (Gasser), 45, 267
 spinale, 364
- Ganglionic gray matter of cerebellum, 260
 of cerebrum, 204
- Ganglionic cells (Bevin Lewis), 191
 system of arteries, 18
- Gelatinous substance (Rolandi), 339, 341
- Genetic nucleus, i., 42, 319, 363
- Genetic nuclei of anterior roots of spinal nerves, 349, 363
 of cerebral nerves, 319, 324
 nucleus oculomotor nerve, 45, 152, 223
 trochlear nerve, 45, 152, 223
- Geniculate bodies (metathalamus), 51, 204, 207, 417
- Gennari's or Baillargic line, 188
- Genu capsulæ internæ, 103, 113
 inferius of central sulcus, 56
 internum of facial nerve, 283
 superius of central sulcus, 56
 of corpus callosum, 11, 95, 108, 109, 120, 121
- Germinal area, 35
 cells of neural crest, 172
 of His in neural tube, 172
- Giant pyramids (Betz), 188
- Globus pallidus of lentiform nucleus, 116, 145, 209, 235
- Glomus chorioideum, 11, 120, 125, 129
- Glossopharyngeal nerve, 5, 46, 153, 209, 293, 320, 321
- Golgi cells, 165
 of spinal cord, 165, 340, 347
 dendroxones, 191
- Goll's column, 300, 360
- Gordinier's writing center, 175, 178, 182
- Gowers's tract, 276, 356
- Granulationes arachnoideales, 5
- Granular layer of cerebellar cortex, 258
- Granule cells of cerebellum, 258, 259
- Gray anterior commissure, 335, 350
 commissure of cord, 335, 338, 350
 crescent of spinal cord, 339
 matter of cerebellum, 256
 of cerebrum, 164
 of medulla, 302
 of pons, 278
 of spinal cord, 338
 of stratum nucleare, 278, 302
- Gratiolet's radiatio occipito-thalamica, 217
- Great anastomotic vein (of Trolard), 23
 cerebral vein (Galen), 3, 10, 21, 136
 middle meningeal artery, 6, 7

- Gudden's inferior commissure, 218, 221, 235
- Gustatory center, 179, 181, 183
 paths, 389
 radiations, 232
- Gyri breves insulæ, 65, 72
 insulæ, 65, 72, 235
 occipitales laterales, 68
 superiores, 68
 temporales transversi, 70
 transitivity, 64
 of convex surface of cerebrum, 59
 of medial and tentorial surface, 93
- Gyrus angularis, 61, 63, 67
 centralis anterior, 59, 60, 61
 posterior, 61, 63, 64
 cinguli, 93, 95, 97, 203
 cortex, of 203
 circumambians, 82, 94
 cunei, 89
 cuneo-lingualis, 90
 fornicatus, 93, 95, 97
 frontalis inferior, 59, 61
 medius, 59, 61
 superior, 59, 61, 95, 97
 fusiformis, 75, 81, 97
 hippocampi, 79, 81, 93, 94, 95, 97
 lingualis, 81, 95, 97
 longus (furcalis) insulæ, 65, 72
 marginalis, 97
 orbitalis anterior, 74, 75
 lateralis, 74
 medialis, 74, 75
 posterior, 74, 75
 profundus transitivus, 64
 rectus, 74, 75, 95, 97
 semilunaris, 82, 94
 subcallosus, 75, 87, 91, 97, 107, 200, 414
 supracallosus, 107, 414
 supramarginalis, 61, 63, 67
 temporalis inferior, 61, 70, 71, 75
 medius, 61, 70, 71
 superior, 61, 70, 71
 transversus insulæ (of Eberstaller), 72
- H-shaped column, 339
- Helwig's triangular tract, 298, 305, 312, 357
- Hemisphere vesicle, 405, 409
 of cerebellum, 41, 242, 245, 252, 419
 of cerebrum, 35, 39, 43, 47, 53, 405
- Hemispheria cerebelli, 242, 245, 252
- Hiatus (Sylvii), 99, 115
- Hind-brain, 31, 33
- Hippocampal fissure, 80, 86, 90, 91, 95, 101, 201, 409, 411, 416
 gyrus, 81, 94, 95
 region, 201
- Hippocampus, 80, 90, 101, 113, 124, 131, 133, 145, 409, 414, 416
 minor (see calcar avis), 125, 133
- His (germinal cell in neural tube), 172
- Histologic layers of neural tube, 427
 of spinal cord, 397
- Hoche's bandalette, 362, 345
- Horizontal anterior ramus of lateral fissure, 57.
 part of interparietal sulcus, 57
 sulcus of cerebellum, 243, 245, 247, 420
- Hypoblast, 396
- Hypoglossal nerve, 5, 49, 153, 293, 322
 nucleus, 295, 303
 triangle, 317
- Hypophyseal region, 37
- Hypophysis cerebri, 37, 38, 47, 82, 84, 267
- Hypothalamic nucleus, 143, 145
- Hypothalamus, 82, 143, 221
- Impressio petrosa, 53
- Incissura præoccipitalis, 61,
 temporalis, 80
 tentorii, 2
- Indifferent cells, 397
- Indirect motor paths, 371
- Inferior cerebral veins, 13, 23
 colliculi of corpora quadrigemina, 147, 149, 163, 220, 418
 commissure (Guddeni), 218, 221, 235
 efferent veins of pons, 27
 external cerebellar veins, 29
 frontal artery, 19, 22
 fovea, 270, 290, 317

- Inferior frontal gyrus, 39, 59, 60, 61
 sulcus, 39, 57, 59
 gray commissure of fore-brain, 84
 horn of lateral ventricle, 101, 105, 123, 133, 141, 145
 internal frontal artery, 19
 lamina of internal capsule, 99, 113, 115, 123
 lateral occipital gyrus, 61
 longitudinal fasciculus, 137, 237, 240
 medullary velum, 13, 244, 245, 247, 262
 olivary nucleus, 209, 297, 305, 312, 425
 parietal lobule, 61, 63, 64
 peduncles of cerebellum, 246, 264
 of thalamus, 100, 145
 petrosal sinus, 3, 3, 4, 5
 postcentral sulcus, 57, 63
 precentral sulcus, 39, 57, 59, 414
 quadrigeminal colliculus, 13, 147, 149, 163, 204, 207, 220, 418
 sagittal sinus, 2, 3
 semilunar lobule, 252, 255, 255, 420
 surface of cerebellum, 251, 252
 of island, 74
 striate veins, 23
 temporal gyrus, 61, 70, 71, 79
 sulcus, 70, 80, 81, 86, 93
 Inero-lateral border, 52
 Infundibulum, 4, 9, 47, 75, 82, 84, 109, 131
 Insula (Reili), 71, 74, 75, 105, 125, 207, 209, 267, 410
 Inter-brain, 30, 33, 37, 50, 51, 73, 127, 415
 Interior surface of fore-brain, 98
 Interlobar boundaries, 55
 Intermediate nerve, 45, 153, 320
 olfactory stria, 77, 78
 tract 100, 148, 159, 225, 226
 Intermedio-lateral column of cell-bodies, 341, 344
 Internal capsule, 99, 101, 105, 109, 113, 115, 145, 209, 226, 412, 417
 carotid artery, 3, 4, 5, 14, 15, 19
 cerebellar veins, 29
 Internal layer large pyramids of cerebral cortex, 184, 188
 medullary lamina of thalamus, 208
 orbital artery, 16
 spinal veins, 331, 332
 veins of cerebrum, 21
 Interparietal sulcus, 39, 43, 57, 63, 414
 Interpeduncular fossa, 145, 146, 153, 159, 161, 209
 ganglion, 151
 space, 38
 Interventricular foramen (of Monro), 36, 37, 95, 112, 128, 235, 405
 Intumescencia cervicalis, 333, 334, 335
 lumbalis, 334, 335
 Inverted pyramids of Martinotti, 191
 Island (of Reil), 71, 74, 75, 98, 105, 414
 Isthmus gyri fornicati, 94
 rhombencephali, 28, 33, 418, 419
 Jugular ganglion, 49
 Kaes, medullation late in life, 412
 Key and Retzii, apertura lateralis ventriculi quarti, 9, 290
 Lamina affixa, 119
 chorioidea epithelialis, 115, 119, 124
 cinerea terminalis, 30, 36, 38, 82, 83, 87, 91, 95, 109, 131, 139, 221, 413
 quadrigemina, 30, 163
 rostralis of corpus callosum, 108
 Laminae medullares, 262
 Lateral apertures (Key and Retzii), 9, 10, 290
 area of medulla, 293, 298
 cerebral fossa, 410, 413
 cochlear nucleus, 309
 column of cell-bodies, 340, 341, 345
 column of medulla, 287
 columna of cord, 335, 344
 fasciculus proprius, 287, 298, 354
 fillet, 13, 159, 160, 161, 246, 274, 275, 309

- Lateral fissure of cerebrum (Sylvii),** 53, 55, 57, 61, 63, 91, 414
 geniculate body, 140, 143, 157, 204, 207, 218
 longitudinal stria (see longitudinal stria)
 nucleus of thalamus, 211
 occipital gyri, 43, 68, 69
 sulci, 57, 68
 olfactory stria, 75, 78, 207
 orbital arteries, 16
 gyrus, 74
 ponto-spinal tract (Collieri), 355, 373
 pyramidal tract, 287, 294, 341, 345, 358
 recess of fourth ventricle, 289
 sulcus of mid-brain, 159, 243
 surface of medulla, 287
 ventricles, 30, 34, 36, 37, 111, 112, 145, 405, 412
 view of brain ventricles, 141
- Layers of cells of cerebral cortex, 184**
 Layer of fusiform cells of cerebral cortex, 184
 of large pyramids, external, 184, 187
 of large pyramids, internal, 184, 188
 of medium sized pyramids of cerebral cortex, 184, 187
 of small pyramids of cerebral cortex, 184, 187
 of stellate and polymorphous cells of cerebral cortex, 184, 188
- Law of Waller, 353**
- Lemniscus, 159**
 lateralis, 160, 274
 medialis, 160, 273, 295
 superior, 274
- Lenticulo-striate artery, 18**
- Lentiform nucleus, 101, 105, 113, 116, 145, 204, 226, 235**
- Lesions of anterior column, 344**
 of corpus striatum, 208
 of gray substance in cord, 350
 of special sense paths, 389
 in medulla, 313
 in posterior columns, 362
- Ligamentum denticulatum, 3, 327, 329, 330**
- Limbic lobe, 73, 81, 87, 91, 93, 97, 98**
- Limen insulæ, 72, 77, 79**
- Line of Baillarger, 184, 188, 213**
- Linea splendens, 327, 329**
- Lingual gyrus, 95, 97**
- Lingula cerebelli, 13, 87, 247, 250**
- Lissauer's fasciculus marginalis, 341, 345, 359**
- Lobes of convex surface of cerebrum, 59**
 of lower surface of cerebellum, 253
 of medial and tentorial surface of cerebrum, 93
 of superior surface of cerebellum, 250
- Lobules of cerebellar vermis, 247, 249, 253**
- Lobulus biventer, 245, 254**
 centralis, 87, 245, 250
 gracilis, 245, 256
 paracentralis, 64, 97
 parietalis inferior, 63, 64
 superior, 63, 64
- Lobus centralis cerebelli, 250**
 culminis cerebelli, 243, 250
 declivis cerebelli, 243, 250
 folii vermis, 243, 251
 frontalis, 59
 limbus, 81
 lingulæ cerebelli, 250
 noduli, 253
 occipitalis, 67
 parietalis, 63
 pyraformis, 97
 pyramidis, 254
 temporalis, 69
 tubercis, 255
 uvulæ, 254
- Localization of cerebral function, 177**
- Locus cæruleus, 269, 270, 317**
- Long association fibers of cerebrum, 238**
- Longitudinal fibers of medulla, 293**
 of lateral area of medulla, 298
 of pons, 272, 275
 of posterior area of medulla, 300
 of spinal cord, 352
 fissure of cerebrum, 35, 39, 43, 52, 53, 209, 235
 striae, medial and lateral, 97, 107, 117
- Lower segment paralysis, 344**
 surface of cerebellum, 253

- Lumbar enlargement of spinal cord, 334, 335
- Luis, center median of thalamus, 211
nucleus hypothalamicus of, 143, 151, 218
- Lymph spaces of cerebellum, 30
of cerebrum, 23
of medulla, 24
of spinal cord, 332
- Magendi, apertura mediana ventriculi quarti, 290
- Mammillary bodies, 38, 51, 75, 85
- Mantle layer, 398, 425, 428
- Marginal gyrus, 95, 97
sinus, 5
tract, Lissauer's, 341, 345, 359
velum, 397, 397, 398, 425, 428
- Margo-infero-lateralis, 52, 75
- Margo occipitalis lateralis, 52, 75
medialis, 52, 75
orbitalis medialis, 52, 75
superciliaris, 39, 52, 75
supero-medialis, 39, 52
- Martinotti's inverted pyramids, 191
- Massa intermedia, 95, 137, 139, 145, 221, 222, 417
- Medial accessory olivary nucleus, 295, 297, 305, 312
cerebral veins, 22
column of cell-bodies, 340
fillet, 157, 159, 160, 161, 231, 273, 275, 277, 292, 295, 295, 297, 305
geniculate body, 140, 143, 146, 147, 149, 157, 159, 204, 207, 218
longitudinal bundle, 156, 157, 159, 161, 275, 276, 277, 295, 296, 297, 305, 311, 341, 345, 354
stria (see longitudinal stria),
nucleus of thalamus, 208
occipital border, 52, 75
olfactory stria, 75, 77, 78
orbital border, 52, 75
gyrus, 74, 75
ponto-spinal tract, Collieri, 158, 297, 355, 373
surface of fore-brain, 92, 95
and lateral olfactory striæ, 47, 75, 77, 78
- Median aperture (Magendi), 9, 9, 10, 13, 289, 290
triangular tract (of Gambault and Phillipe), 361
- Medulla oblongata, 24, 31, 33, 35, 36, 37, 38, 87, 242, 284, 422
spinalis, 31, 333, 334, 335
- Medullary body of cerebellum, 242, 244
groove, 396
laminæ, 262
plate, 395
ridges, 395
striae, 149, 270, 290, 309
- Medullation, 168, 169, 129
- Membranes, of brain, 1
of spinal cord, 326, 327, 329
- Meninges encephali, 1
spinalis, 326, 327, 329
of brain, 1
of spinal cord, 426, 327
- Mesencephalic flexure, 402
- Mesencephalon, 28, 30, 31, 144, 402, 417
- Mesoblast, 396
- Mesoblastic sustentacular tissue, 174
- Metathalamus, 140, 143, 218
- Metencephalic flexure, 402
- Metencephalon, 28, 31, 33, 36, 266, 402, 418
- Methods of locating tracts of fibers, 352
- Meynert's association fibers, 192, 236
commissura superior, 208, 218, 221
dorsal tegmental decussation, 156, 157, 159
solitary cells, 195
- Mid-brain, 30, 31, 33, 36, 37, 50, 87, 144, 243, 417
- Middle association center, 183
brain vesicle, 30
cerebral artery, 4, 15, 16
commissure, 137, 222
frontal gyrus, 39, 59, 61
sulcus, 57, 60
internal frontal arteries, 16
meningeal artery, 3, 5, 6, 7
or lateral occipital gyrus, 61
peduncles of cerebellum, 247, 264
temporal gyrus, 61, 70, 71
sulcus, 63, 70

- Midgracile sulcus, 421
 Mixed ascending and descending tracts, 352
 Monro, interventricular foramen of, 95, 112, 128, 141, 405
 sulcus hypothalamicus of, 91, 95, 415
 Moss-like appendages of Cajal, 259, 260
 Motor area of cerebrum, 177
 center for foot, 98, 178
 cerebral nerves, 321
 fibers of cerebrum 225,
 of internal capsule, 100, 103
 memory center 67,
 neurone, 169
 paths, 229, 366, 367, 371
 roots of cerebral nerves, 321
 root of spinal nerve, 363
 speech center, 178
 Motorial end-plates, 168, 169
 Myelencephalon, 28, 31, 33, 266,
 284, 402, 422
 Myelin sheath of axones and den-
 drites, 168
 Myelination, 412, 429
 Naming center, 71, 181
 Neopallium, 28, 98
 Nerves of arachnoid, 9
 of dura mater, 7
 of pia mater, 13
 Nervi cerebrales, 318, 421, 425
 olfactorii, 42, 320
 Nervus abducens, 45, 267, 321
 accessorius, 49, 267, 322
 acusticus, 46, 267, 320
 facialis, 45, 267, 321
 glossopharyngeus, 46, 267, 320,
 321
 hypoglossus, 49, 267, 322
 intermedius, 45, 267, 320
 oculomotorius, 42, 267, 321
 opticus, 25, 42, 83, 267, 320
 trigeminus, 45, 267, 320, 321
 trochlearis, 45, 267, 321
 vagus, 46, 267, 321
 Neural canal, 396
 crest, 35, 172, 395, 400
 groove, 35, 395
 tube, 35, 172, 395
 Neuraxones, 168
 Neuroblasts, 398
 Neuroglia, 172, 399
 cells, 173
 zone, 184
 of cerebellum, 260
 Neurolemma (Schwann), 168, 169
 Neurone 165, 167, 169, 171, 398
 center, 157
 Neurones of head of posterior col-
 umna, 347
 Neuropore, 405
 Nuclei of cerebellum, 260, 261
 of cerebral nerve, 278, 281, 303
 of reticular formation, 156, 278,
 279, 304
 of thalamus, 208
 Nucleolus of neurone, 169
 Nucleus alæ cinereæ, 297, 303, 304,
 305, 306, 315
 ambiguus, 297, 303, 304, 315
 amygdalæ, 113, 119, 199, 207,
 239
 arcuatus, 303
 caudatus, 116
 centralis inferior, 278, 279
 medius, 278, 279
 superior, 278, 279
 commissuralis, 305, 306
 corporis trapezoidei, 279
 dentatus, 255, 260, 261, 277
 dorsalis (Stillingi and Clarki),
 348
 dorso-lateralis (of Dieters), 283,
 303
 emboliformis, 260, 261, 277
 fastigii, 261, 277, 260, 262
 funiculi cuneati, 270, 305, 311,
 310
 gracilis, 270, 305, 311, 310
 globosus, 260, 261, 277
 habenulæ, 140, 211
 hypothalamicus Luysi, 143, 151,
 204, 218
 incertus, 270
 intercalatus, 270
 lateralis inferior, 297, 303, 304
 medius, 278, 279
 superior, 156, 220
 lentiformis, 101, 105, 116, 209
 n. abducentis, 281
 cochlearis, 270, 315, 309
 facialis, 282
 oculomotorii, 45, 155, 315
 trochlearis, 45, 155, 315

- Nucleus vestibularis, 270, 283, 305, 307, 315
 olivaris inferior, 312
 originis, 42, 319, 324, 363
 pontis, 272, 278, 421
 ruber, 217
 terminalis, 42, 319, 365
 tractus solitarii, 302, 305, 306
 spinalis n. trigemini, 295, 305, 311, 314, 306
 of anterior tubercle, 211
 of abducent nerve, 277, 281, 315
 of accessory nerve, 304, 315
 of Bechterew, 277, 308
 of colliculus inferior, 161, 164, 220
 of corpus mammillare, 85, 157
 of descending root of trigeminal nerve, 155
 of descending root of vestibular nerve, 280, 283, 308
 of external arcuate fibers, 302
 of facial nerve, 277, 282, 315
 of fascia dentata, 201
 of fourth nerve, 155, 315
 of hypoglossal nerve, 303, 315
 of neurone, 167, 169
 of oculomotor nerve, 152, 315
 of optic nerve, 315
 of pulvinar, 208
 of third nerve, 152, 315
 of trapezoid body, 272, 278, 279, 280
 of trigeminal nerve, 277, 281, 315
 of trochlear nerve, 152, 223, 315
 Ninth, tenth and eleventh nerves, 3
 Nissl bodies, 167, 169
 degeneration, 171
 Nodes of Ranvier, 168, 169
 Nodular ganglion, 49
 Nodule of cerebellum, 245, 247, 252, 253
 Nodus cerebelli, 87, 253
 Notochord, 396
 Obex, 13, 270
 Oblique fasciculus of pons, 267, 269
 Occipital lobe, 53, 67, 75, 87, 91, 98
 part of internal capsule, 103
 pole, 50, 53, 68
 sinus, 2, 5
 Occipito-parietal fissure, 409, 411
 sulcus, 17, 43, 53, 56, 57, 86, 89, 91, 95
 Occipito-thalamic radiation, 137, 213, 217, 226, 234
 Ocular reflex arcs, 355
 Oculomotor nerve, 42, 145, 153, 209, 321
 sulcus, 146, 159
 Olfactory bulb, 37, 47, 75, 77, 195, 203, 207
 center, 97
 cortex, 195
 diverticulum, 36, 37
 islets (Calleja), 199
 lobe, 73, 77, 98
 nerves, 42, 320
 path, 383
 projection fibers, 232
 sulcus, 74
 striae, 75, 78
 tract, 47, 75, 77, 78, 267
 triangle, 75, 77, 79
 Oliva, 287
 Olivary fasciculus, 162, 208, 277, 298
 nucleus, inferior, 295, 297, 312, 423, 425
 pedicle, 279
 Olive, 31, 41, 153, 287
 Operculum, 64, 70, 410
 Ophthalmic division of fifth nerve, 5
 Optic center, 181
 chiasma, 30, 38, 47, 75, 83, 95, 147, 153, 213, 235, 415
 commissure (see optic chiasma), 131
 cup, 405
 nerve, 4, 38, 42, 83, 153, 213, 320
 path, 213, 384
 radiation, 104, 213, 217, 226, 232, 234
 recess, 91, 139, 235, 405
 reflex center, 163, 324
 tract, 219, 355
 tract, 4, 38, 47, 75, 83, 145, 147, 153, 157, 159, 209, 235, 267
 vesicle, 35, 405
 Orbital lobe, 73
 Orders of neurones, 168
 Origin of anterior root of spinal nerve, 363

- Origin of posterior root of spinal nerve, 364
- Oval bundle of His, 427, 429
tract (Flechsigi), 345, 361
- Pachionian bodies, 5
- Paracentral lobule, 64
- Paramedial sulcus, 39, 57, 59, 60
- Parietal lobe, 53, 63, 87, 91, 98
stalk of thalamus, 103, 104, 226
- Parieto-temporal artery, 17, 22
- Parolfactory area (of Broca), 79, 86
- Pars anterior rhinencephali, 77
basilaris pontis, 266
dorsalis pontis, 266, 273
frontalis capsulæ internæ, 103, 113
mammillaris hypothalami, 28, 82, 221, 417
occipitalis capsulæ internæ, 103, 113
optica hypothalami, 28, 82, 221, 415
posterior rhinencephali, 77
- Pathological method of locating tracts, 353
- Path carrying visceral, muscular and tactile impulses, 381
for tactile and muscular sense, 375, 377
for tactile, pain and temperature impulses, 276, 379, 381
through red nucleus, 370, 371
- Peduncle of corpus callosum (see gyrus subcallosus)
- of flocculus, 245, 254
- Peduncular fibers of cerebellum, 262
of cerebrum, 224
- Pedunculi cerebri, 28, 30, 37, 146, 147
- Pedunculus flocculi, 254
- Perikaryon, 167
- Permanent fissures and sulci of cerebrum, 409, 414
- Perpendicular fasciculus, 237, 241
- Petrosal glossopharyngeal ganglion, 46
- Petro-squamosal sinus, 5
- Physiological method of locating tracts, 353
- Pia mater encephali, 9
spinalis, 329
of brain, 9
- Pia mater of spinal cord, 329, 329
of brain and cord compared, 13
- Pineal body, 36, 37, 51, 91, 95, 109, 131, 132, 137, 147, 157, 243, 416, 416
recess, 132, 416
stria, 135, 137, 239 (see stria medullaris thalami)
- Pituitary body, 84 (see hypophysis)
- Plexiform layer of cerebral cortex, 184
- Plexus basilaris, 4
chorioideus ventriculi lateralis, 120, 201
chorioideus ventriculi quarti, 290
venosi vertebrales interni, 332
- Plica chorioidea of fourth ventricle, 419
- Pole of island, 71
- Polus insulæ, 71
- Pons (varolii), 24, 28, 31, 33, 37, 38, 87, 101, 145, 153, 242, 266, 418, 421
- Pontal arteries, 24
- Pontine flexure, 402
- Ponto-spinal tracts, 280, 373
- Postcentral lobule, 72
sulcus of cerebellum, 247, 248, 420
of cerebrum, 63, 410
- Postdeclivul sulcus, 243, 247, 249, 420
- Post-dorso-lateral cells, 343 (see intermedio-lateral)
- Postgracile sulcus, 421
- Postnodular sulcus, 247, 252, 252, 420
- Postparietal gyrus, 63, 67
- Postpyramidal sulcus, 245, 247, 252, 253, 420
- Posterior anastomotic vein, 23
area of medulla, 293, 300
association center, 182
brain vesicle, 33, 35
calcarine fissure, 89
central gyrus, 39, 61, 63, 64
cerebellar notch, 36, 243, 244, 252
cerebello-spinal fasciculus, 264, 305, 311, 288, 341, 357
cerebral artery, 15, 17, 25
chorioidal artery, 15, 17, 19
columna, 335, 339, 347, 427, 429

- Posterior commissure of cerebrum, 95, 109, 131, 132, 137, 416
of cord, 335, 350
communicating artery, 4, 14, 15
fasciculus proprius, 362
horn of lateral ventricle, 123, 131, 133, 137, 141
inferior cerebellar artery, 15, 24, 27, 29
intermediate sulcus of cord, 335, 338
internal frontal arteries, 16, 25
lateral sulcus of cord, 335, 337, 430
lateral sulcus of medulla, 41, 149, 153, 286, 295, 297
longitudinal bundle (see medial longitudinal bundle)
median fissure of cord, 335, 337, 349, 430
median fissure of medulla, 285
median vein, 24
orbital gyrus, 74, 75
parolfactory sulcus, 86
perforated substance, 38, 47, 109, 132, 146, 151
pillar of fornix, 133 (see crus fornicis)
radicular artery, 331
vein, 331
ramus of lateral fissure of cerebrum, 57
root of spinal nerve, 327, 334, 349, 363, 364, 399, 427, 428, 429
slender lobule, 252, 255
spinal artery, 24, 27, 331
subarachnoid space, 8, 329
surface of medulla, 270, 288
of pons, 269, 270
white column of cord, 345, 399
- Postero-lateral column (Burdachi), 300
descending tract, 345, 362
ganglionic arteries, 19, 21
- Postero-medial column (Gollis), 300
- Postero-medial ganglionic arteries, 15, 18, 20
- Precentral lobule of island, 72
sulcus of cerebellum, 247, 248, 420
of cerebrum, 59, 410, 414
- Precuneate gyrus (see precuneus)
- Precuneus, 95, 97
- Predeclivul sulcus, 243, 247, 249, 420
- Preolivary nucleus, 278, 279
- Prepyramidal sulcus, 245, 247, 252, 252, 420
- Prevertebral ganglia, 401
- Primary brain vesicles, 30, 35, 395
fissures of cerebrum, 409, 411, 413
- Primitive streak, 35
- Principle or chief vestibular nucleus (Schwalbe's), 307
- Processes of dura mater, 1
of neurone, 167, 169
- Processus duræ matris, 1
- Projection fibers of cerebellum, 262, 263
of cerebrum, 224
- Prosencephalon, 30, 31, 51
- Protoplasmic processes of neurones, 169
- Psychic acoustic center, 71, 181
center of abstract concept, 60, 182, 183
center of concrete concept, 182, 183
motor area, 178
optic center, 181
sensory area, 178, 67
- Pulvinar of thalamus, 140, 149, 207, 211, 315
- Pupillary constriction, 394
dilation, 394
reflexes, 394
- Pupillo-dilator tract, 220, 298, 355
- Purkinje's cells, 257, 258, 259, 265
- Putamen of lentiform nucleus, 116, 145, 209, 235
- Pyramid of cerebellum, 247, 252, 254
of medulla, 41, 153, 209, 267, 295, 297, 311, 293, 294
- Pyramidal cells of cerebral cortex, 165
decussation, 291, 311
motor paths, 366
tract, 103, 148, 159, 226, 272, 277, 294, 355, 358
- Pyramis cerebelli, 87, 254
medullæ oblongatæ, 294
vermis, 254

- Quadrangular lobule 243, 250 251,
 255, 420
 Quadrigeminal bodies, 4, 146, 147,
 163
 colliculus, i., 75, 87, 163
 lamina, 146, 147, 163
 Radiatio occipito-thalamica (optic),
 104, 131, 217
 corporis callosi, 234
 temporo-thalamica (acoustic), 104,
 217
 Radiations of corpus callosum, 209,
 234
 of corpus striatum, 207, 209
 of Meynert, 192
 Radiary zone of cerebral cortex, 184
 Radicular cells, 340
 veins of medulla 24
 Radix anterior of spinal nerve, 349,
 363
 posterior of spinal nerve, 349,
 364
 Ranvier's nodes, 168, 169
 Receptive auditory center, 70, 71, 181
 olfactory center, 82, 94, 97, 179,
 183
 visual center, 81, 98, 181
 Recessus triangularis, 128, 136, 137
 Red nucleus, 101, 157, 159, 204, 217
 Reflex arcs, 390, 391, 392
 connections of abducent nucleus,
 282
 of cochlear nucleus, 310, 323
 of facial nucleus, 282
 of geniculate nuclei, 325
 of motor nuclei in medulla, 305
 of nucleus *alae cinereae*, 306
 of olfactory nucleus, 324
 of trigeminal nuclei, 281, 307
 of vestibular nuclei, 308, 323,
 389
 mechanism of cord, 343
 paths, 390
 Regio tegmentalis hypothalami, 143
 Relations of arachnoid, 8, 326, 327,
 329
 of dura mater, 1, 326, 329
 of pia mater, 9, 327, 329
 Respiratory reflex, 393
 Restiform body, 13, 41, 246, 252,
 255, 280, 288, 295, 297,
 301, 423
 Rhinencephalon, 28, 77, 97, 98, 406
 Rhombencephalon, 31, 33, 38, 242,
 266, 284
 Rhomboid lip, 285, 422, 423
 Rolandic angle, 56
 Rolando, central sulcus of, 56, 57,
 61, 410
 gelatinous substance of, 339, 341
 345
 Roof epithelium of fourth ventricle,
 13, 289, 314
 of third ventricle, 132
 of fourth ventricle, 289, 289,
 314
 Roof-plate, 400, 416, 422, 422, 427
 Roots of optic tract, 83, 147, 153
 of spinal nerves, 349, 362
 of twelve cerebral nerves, 42
 Rostrum of corpus callosum, 95, 108,
 120
 Rubro-spinal path, 370, 371
 tract, 161, 162, 276, 295, 297,
 300, 305, 311, 341, 358,
 370, 371
 Salivary nucleus, 283
 Schultze, comma tract of, 341, 361
 Schwalbe's dorso-medial vestibular
 nucleus, 280, 307
 Schwann's sheath, 168
 Second cerebral vesicle, 35
 cervical nerve, 3
 Secondary brain vesicles, 402, 403
 sulci and fissure, 410, 411, 414
 Sections of fore-brain, 407
 of spinal cord, 335
 Semilunar ganglion (*Gasseri*), 45
 nucleus, 278
 Sense of touch, 377
 Sensory aphasia, 241
 cerebral nerves, 320
 conduction paths, 377
 paths, 229, 377
 projection fibers, 231
 roots of cerebral nerves, 320
 of spinal nerve, 349, 363, 364
 root of trigeminal nerve, 307
 tract Ciagliński, 350
 Septo-marginal tract, 345, 361
 Septum pellucidum, 30, 87, 95, 97,
 111, 115, 121, 123, 209,
 235, 413, 415
 Seventh and eighth nerves, 3

- Short association fibers of cerebrum, 236, 237
 fiber motor paths, 373
 sensory paths, 382
- Simple reflex arc, 391
- Sinus *alæ parvæ*, 3
cavernosus, 3
circularis, 4
duræ matris, 2
intercavernosus anterior, 3
 posterior, 3
occipitalis, 2
petrosus inferior, 3
 superior, 3
rectus, 2
sagittalis inferior, 2
 superior, 2
transversi, 2
- Sixth nerve, 3
 ventricle, 335, 337
- Slender lobules, 255, 255
- Smelling brain, 77
- Solitary cells of Meynert, 195
 tract, 295, 297, 302, 305, 423
- Somæsthetic area, 64, 98, 181
- Special nuclei of medulla, 302, 310
 sensations, 383
 sense fibers of internal capsule, 104, 115, 226
 nuclei, 322
- Speech center, 60, 175, 178, 182
- Spheno-parietal sinus, 3, 4
- Spinal bulb, 284
 cord, 31, 333, 334, 335, 341, 426
 ganglion, 334, 364, 401, 428
 neurones, 165, 400, 401
 reflexes, 390
 tract of trigeminal nerve, 278, 301, 423, 424
- Spino-cerebral reflexes, 393
- Spino-thalamic tract, 161, 231, 275, 274, 287, 295, 297, 299, 305, 311, 341, 345, 356
- Spino-vestibular tract, 357
- Splenium of corpus callosum, 75, 95, 105, 108, 113, 109, 121, 131
- Spongioblasts, 398, 399
- Stalk of pineal body, 87, 140
- Stellate cells of cerebellum, 257, 259
- Stem of fissura cerebri lateralis, 57
- Stereognosis, 377
- Stereognostic center, 64, 98, 182, 183
- Stilling's nuclei, 262
- Stilling and Clark (nucleus of), 348
- Straight gyrus, 74, 75
 sinus, 2, 3, 4
- Strand cells, 340
- Stratum cinereum, 256
gangliosum, 256, 257
granulosum, 256, 258
griseum centrale, 152, 157, 159, 221, 222
 of superior colliculus, 163, 219
intermedium, 208, 225
interolivare lemnisci, 292
nucleare, 278, 293, 302, 303
 zonale of cerebral cortex, 184
 of corpora quadrigemina, 163, 219
 of thalamus, 140, 208
- Stria intermedia, 77, 78, 267
lateralis, 78, 267
medialis, 77, 78, 267
medullaris thalami, 87, 91, 95, 135, 137, 212, 239, 239
terminalis, 101, 109, 115, 119, 124, 125, 207, 239, 412
- Striæ medullares, 149, 270, 290, 309
olfactoriæ, 78, 267
- Striato-thalamic fibers, 207
- Structure of arachnoid, 8,
 of cerebrum, 164
 and relations of dura mater, 1
 and relations of pia mater, 9
- Subarachnoid rivulets, 8
 septum, 327, 329
 space, 6, 8, 9, 329
- Subcallosal gyrus, 97, 107, 414
- Subdural space, 329
- Subiculum, 199, 201
- Subparietal point, 55
 sulcus, 86, 91, 95
- Substantia alba spinalis, 351
corticalis cerebelli, 242, 256
cerebri, 177
gelatinosa centralis, 173, 339
 (Rolandi), 339, 345, 347
nigra, 30, 101, 145, 146, 151, 157, 159, 161, 221
perforata anterior, 38, 75, 79, 200
 posterior, 38, 75, 151
reticularis, 291, 295, 297, 302, 303, 305, 423
spongiosa, 339

- Sulci, 52
 occipitales laterales, 61, 68
 of cerebellum, 247, 248, 252, 420
 of convex surface of cerebrum, 52
 of lower surface of cerebellum, 252, 253
 of lower surface of cerebrum, 73
 of medial surface of cerebrum, 85
 of upper surface of cerebellum, 248, 249
- Sulcus basilaris, 153, 272
 centralis (Rolandi), 39, 53, 56, 57, 61, 410
 insulæ, 65, 72
 cinguli, 25, 86, 91, 95, 410
 circularis insulæ, 70, 71, 75, 125
 corporis callosi, 86, 91
 ectorhinalis, 80, 86, 90
 frontalis inferior, 59, 61
 medius, 59, 60, 61
 superior, 59, 61
 horizontalis cerebelli, 247
 hypothalamicus, 91, 139, 405, 415
 intermedius posterior, 335, 338
 interparietalis, 61, 63
 lateralis anterior, 41, 286, 338
 mesencephali, 146, 159, 161
 posterior, 41, 286, 337
 limitans, 269, 270, 290, 418
 nervi oculomotorii, 146
 occipitalis transversus, 61, 68
 occipito-parietalis, 58, 61, 86
 orbitalis, 74, 75
 paramedialis, 59, 61
 parolfactorius anterior, 47, 75, 79
 posterior, 75, 77, 79, 95
 præcentralis cerebelli, 248
 inferior, 59, 61
 superior, 59, 61
 prædeclivis cerebelli, 249
 præpyramidalis cerebelli, 252
 postcentralis cerebelli, 248
 inferior, 61, 63
 superior, 61, 63
 postdeclivis cerebelli, 249
 postnodularis cerebelli, 252
 postpyramidalis cerebelli, 253
 rhinalis, 80
 subparietalis, 86, 91
- Sulcus temporalis inferior, 70, 80, 86
 medius, 61, 63, 70
 superior, 61, 63, 70
 valleculæ, 251, 252
- Superciliary border, 39, 52
 Superficial annectant gyrus, 64
 layer of cerebellar cortex, 256
 middle cerebral vein, 23
 transverse fibers of pons, 271, 275
- Superior cerebellar artery, 15, 27
 peduncle (see brachium conjunctivum)
- cerebral veins, 22
 colliculus of corpora quadrigemina, 157, 219
 commissure (Meynerti), 208, 218, 221
 efferent veins of pons, 27
 external cerebellar veins, 29
 fillet, 159, 160, 274, 296
 fovea, 270
 frontal gyrus, 39, 59, 60, 61, 209
 sulcus, 39, 57, 59, 414
 glossopharyngeal ganglion, 46
 lamina of internal capsule, 100, 113, 115, 226
 longitudinal fasciculus, 240
 medullary velum, 13, 87, 146, 147, 149, 245, 246, 247, 252, 262, 263, 275
 nucleus of Bechterew and Flechsig, 308
 occipital gyrus, 43, 61, 68, 69
 olivary nucleus, 277, 278, 279, 280
 parietal lobule, 43, 61, 63, 64
 peduncle of cerebellum, 245
 petrosal sinus, 3, 4, 5
 postcentral sulcus, 57, 63
 precentral sulcus, 39, 57, 59, 410, 414
 quadrigeminal colliculus, 137, 204, 219, 418
 sagittal sinus, 2, 3, 5, 6
 semilunar lobule, 243, 251, 255, 420
 surface of cerebellum, 243, 248
 of temporal lobe, 70
 temporal gyrus, 61, 70, 71
 sulcus, 57, 63, 70, 410
- Supero-medial border, 39, 52

- Supracallosal gyrus, 97, 107, 414
 Supramarginal gyrus, 43, 61, 63, 67
 Supraradiary zone of cerebral cortex, 184
 Surface of cerebellum, 248
 of cerebrum, 34, 51
 Surfaces of medulla oblongata, 286
 of mid-brain, 144
 of pons, 266
 of spinal cord, 337
 of thalamus, 140
 Sustentacular tissue, 167, 173
 Sylvian point, 55
 Tænia semicircularis, 115, 119, 125
 (sec stria terminalis)
 terminalis, 119
 ventriculi quarti, 149, 270, 297
 Tapetum, 123, 124, 131, 137, 239
 Tassel neurones, 199
 Tegmental decussations, 156
 hypothalamic region, 143
 Tegmentum, a, of mid-brain, 30, 75, 109, 132, 146, 152
 Tela chorioidea ventriculi quarti, 10
 tertii, 10
 Telencephalon, 28, 30, 402, 403, 404
 Telodendria, 167, 169
 Temporal artery, 17
 lobe of cerebrum, 37, 53, 69, 75, 91, 98
 pole, 53, 70
 Temporo-occipital gyrus, 81, 97
 sulcus, 81
 Temporo-parietal artery, 19
 Temporo-pontal tract, 100, 148, 159, 225, 226
 Temporo-thalamic radiation, 100, 226, 233, 310
 Tentorial area of cerebellum, 248
 of cerebrum, 79
 notch, 2, 4
 Tentorium cerebelli, 2, 3, 4
 Terminal ganglia, 401
 nuclei of optic nerve, 315, 323
 nucleus, 42, 310, 322, 340, 364, 365
 of olfactory nerves, 42, 196
 Tertiary sulci, 411
 Thalamus, i., 28, 30, 37, 51, 101, 105, 110, 125, 130, 145, 147, 157, 208, 209, 416, 417
 Thalamo-mammillary fasciculus (of Vicq d'Azyr), 145, 222, 237
 Thalamo-striate fibers, 208
 Third cerebral vesicle, 35
 nerve, 3, 4, 5, 42
 ventricle, 9, 30, 34, 37, 101, 111, 127, 137, 145, 209
 Threshold of island, 72, 77
 Tigroid bodies, 167
 Tonsil of cerebellum, 245, 252, 254, 420
 Torcular herophili, 2
 Tracing of impulses, 366
 Tracts of fibers in tegmentum, 156
 of spinal cord, 341, 345, 354, 429
 Tractus cerebro-cortico-pontalis frontalis, 103, 151, 225
 temporalis, 100, 148, 225
 cerebro-spinalis pyramidalis, 226
 intermedius, 100, 148, 225
 olfactorius, 77, 78
 optici, 83
 solitarius, 285, 295, 297, 302, 422, 423
 spinalis n. trigemini, 277, 278, 288, 295, 297, 301, 305, 311
 Transverse fibers of medulla, 291
 of pons, 271
 of spinal cord, 351
 fissure of cerebellum, 36
 of cerebrum, 35, 43, 53, 55, 109, 411
 occipital sulcus, 43, 57, 68, 69
 sinuses, 2, 3, 4, 5
 temporal gyri, 70, 105, 121, 125
 sulci, 70
 Trapezoid body, 271, 272, 277, 280
 Triangle of habenula, 140
 of lateral fillet, 152, 164
 Triangular tract of Hclwig, 298, 305, 311, 312, 341, 345, 357
 Trigeminal nerve, 41, 45, 153, 209, 320, 321
 nucleus, 224
 Trigonum vagi, 290, 317. (see *ala cinerea*)
 collaterale, 123, 124
 habenule, 140, 137, 243
 n. hypoglossi, 149, 270
 olfactorium, 47, 75, 77, 79, 200
 Trochlear nerve, 45, 146, 147, 321
 nucleus, 223

- Trolard's great anastomotic vein, 23
 Truncus of corpus callosum, 95, 108
 Tuber annulare, 266
 cinereum, 30, 38, 47, 75, 82, 84, 87, 221, 267, 415
 vermis, 87, 247, 252, 255
 Tuberculum anterior thalami, 140
 acusticum, 149, 309
 cinereum, 13, 289, 301
 Twelfth nerve, 3, 49, 322
 Types of neurones. 168
- Uncinate fasciculus, 237, 239, 240
 Uncrossed ponto-spinal tract, 280, 373
 Uncus hippocampi, 82, 94, 196, 235
 Unipolar neurones, 400, 401
 Uvula vermis cerebelli, 87, 245, 247, 252, 254
- Vagus nerve, 5, 46, 153, 209, 293, 321
 Vallecule cerebelli, 36, 244, 251
 Valve of Vieussens, 246
 Veins of cerebellum, 29
 of cerebrum, 21
 of medulla, 24
 of pia mater, 13
 of spinal cord, 331, 332
 Velum interpositum, 135 (see chorioid tela of third ventricle)
 medullare inferius, 244
 superius, 245, 263
 Vena basilaris, 23
 cerebri interna, 21
 magna, 21
 media, 23
 terminalis, 235
 Venæ cerebelli inferiores, 29
 cerebri, 21
 externæ, 22
 inferiores, 23
 mediales, 22
 superiores, 22
 spinales externæ, 332
 internæ, 332
 Ventral cochlear nucleus, 309
 longitudinal fibers of pons, 272
 stalk of thalamus, 100, 212, 226, 232
 Ventral tegmental decussation, 156, 157, 159
 zone, 399, 422, 427
 Ventro-lateral cells of cord, 341, 345, 343
 Ventro-medial cells of cord, 341, 345, 340
 Ventricle of corpus callosum, 89
 Ventricular gray matter of cerebrum, 221
 Ventriculus lateralis, 112
 quartus, 313
 terminalis, 337, 426
 tertius, 127
 Vermis cerebelli, 242, 243, 419
 inferior, 244
 superior, 244
 Vertebral artery, 3, 5, 14, 15, 27
 ganglia, 401
 Vessels of arachnoid, 9
 Vestibular nerve, 280, 293, 320, 386
 nucleus, 295, 297, 283, 302, 307
 path, 386
 Vestibulo-spinal reflex, 393
 Vicq d'Azyr (foramen of), 153
 Vicq d'Azyr's fasciculus thalamo-mammillaris, 85, 110, 222, 237
 Vieussens's medullary velum, 146
 valve, 246
 Vinculum, a, cerebelli, 250
 Vision, center for macular, 67
 Visual center (receptive), 81, 98, 192
 memory center, 67, 69
- Wallerian degeneration, 171
 White anterior commissure, 335, 351
 matter of cerebellum, 262
 of cerebrum, 224
 of medulla, 290
 of pons, 270
 of spinal cord, 351
 of thalamus, 208
 Worm of cerebellum, 243
 Writing center of Gordinier, 175, 178, 182
- Zonal layer of cerebral cortex, 184
 Zones of embryo, ventral and dorsal, 399

E451

S23

1907

Santee, H.E.

Anatomy of the brain
and spinal cord.

54339

NAME

A. S. Hadland

DATE DUE

OCT 22 1969

