



3 1761 06704915 5

F 20

SOME POINTS
IN THE
SURGERY OF THE BRAIN AND ITS
MEMBRANES



MACMILLAN AND CO., LIMITED
LONDON · BOMBAY · CALCUTTA
MELBOURNE

THE MACMILLAN COMPANY
NEW YORK · BOSTON · CHICAGO
ATLANTA · SAN FRANCISCO

THE MACMILLAN CO. OF CANADA, LTD.
TORONTO

MN
B

SOME POINTS
IN THE
SURGERY OF THE BRAIN
AND ITS MEMBRANES

BY

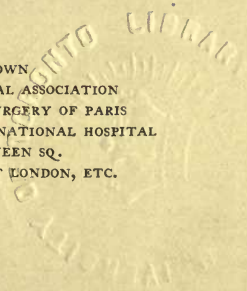

(Sir) CHARLES A. BALLANCE
M.V.O., M.S., F.R.C.S.

ROYAL PRUSSIAN ORDER OF THE CROWN
HONORARY FELLOW OF THE AMERICAN SURGICAL ASSOCIATION
CORRESPONDING MEMBER OF THE SOCIETY OF SURGERY OF PARIS
SURGEON TO ST. THOMAS'S HOSPITAL AND TO THE NATIONAL HOSPITAL
FOR THE PARALYSED AND EPILEPTIC, QUEEN SQ.
EXAMINER IN SURGERY IN THE UNIVERSITY OF LONDON, ETC.

WITH ILLUSTRATIONS

MACMILLAN AND CO., LIMITED
ST. MARTIN'S STREET, LONDON

1908



409791
15.7.42



First Edition February 1907
Second Edition February 1908

PREFACE

THIS little book contains the material prepared for the Lettsomian Lectures of the Medical Society of London for 1906. The short time devoted to a lecture, and the large amount of material available for each one, made me decide to give the Lectures as lantern demonstrations.

Previous to 1906 the Lettsomian Lectures have been delivered for fifty-five years. It is interesting to note that the subject chosen by me had never before been selected by a Lettsomian lecturer.

I heartily thank the many friends who have been willing to let me have the use of their illustrations. I thank Dr. Charles Green for looking up many cases for me, and my brother, Hamilton Ballance, for the illustrations and notes of specimens in the Norwich Museum.

Since the Lectures were delivered some cases have been brought up to date, and a few have been added.

Fresh from a visit to the great hospitals and laboratories of Philadelphia and Baltimore, I am

ILLUSTRATIONS

FIG.	PAGE
1. John Coakley Lettson, M.D., LL.D., F.R.S.	2
2. John Fothergill, M.D., F.R.S.	4
3. Garden view of Dr. Lettson's house at Camberwell	7
4. Destitute family relieved as a result of one of Dr. Lettson's morning walks in the Metropolis	8
5. Anterior part of cisterna magna distended by artificial injection	13
6. Anterior part of cisterna magna distended with pus	13
7. Posterior basal meningitis	13
8. The brain stem	16
9. Portion of aorta of turtle (<i>Chelonia Mydas</i>) showing capacious lymphatic sheath surrounding the artery	19
10. Dissection of head of turtle, with brain stem exposed	20
11. The brain stem in the embryo	20
12. Diagram of subdural hæmatocele	22
13. Photograph of the outer surface of the tumour	22
14-16. Intracranial hæmorrhage of the new-born	31
17. Sketch of operation for arachnoid cyst	32
18, 19. Simple fracture of skull in infants	33, 34
20. Traumatic meningocele	34
21. Fracture of right frontal bone in a new-born infant, fracture extending into orbit	37
22. 1. Traumatic meningocele before operation. 2. Same case after operation	37
23. Diagram of fracture of skull in Dr. Bastian's case of traumatic encephalocele	38

X SURGERY OF THE BRAIN

FIG.	PAGE
24. Sub-arachnoid space between the convolutions	45
25. Sketch of complete mastoid operation	48
26, 27. Lumbar puncture	57
28. Arrangement of membranes around spinal cord	58
29. Arrangement of arachnoid in the region of the cauda equina	58
30. The relation of the frontal sinuses to the frontal lobes	64
31. The relation of the accessory sinuses to the base of the skull ; viewed from the cranial cavity	64
32. Radiogram of large frontal sinuses	65
33. Radiogram of suppurative disease (granulation, polypi, and pus) in the left frontal sinus	66
34. Result six weeks after the Killian operation for frontal sinus suppuration	67
35. Miliary tuberculosis of pia covering the convexity of the brain	72
36. General suppurative meningitis	74
37. Posterior basal meningitis	77
38. Diagram of subdural drainage by an angular metal tube	78
39. Congenital hydrocephalus in an infant of 6 months	81
40. Congenital hydrocephalus treated by ligation of both common carotid arteries	81
40a. Sketch of arachnoid hæmatocele in cerebellar fossa	88
41. Traumatic meningo-cortical abscess of brain	89
42. Spreading septic softening of the right frontal lobe	103
43. Encysted abscess of left frontal lobe	104
44. Abscess of the right temporo-sphenoidal lobe	108
45, 46. The cortical centre for hearing	111
47, 48. The cortical centres for taste and smell	112
49. Diagram of the position in the cerebral cortex of the centres concerned in the mechanism of speech	115
50. Tumour of the 3rd temporal convolution, indicating the position of the naming-centre	115
51. Case illustrating site of supposed naming centre	116
51a. Scheme of the connection of the various centres concerned in speech	116

ILLUSTRATIONS

xi

FIG.	PAGE
52. Tumour of the right temporo-sphenoidal lobe bearing on the localisation of the sense of smell	125
53. Abscess in the temporal and frontal lobes	128
54. Two abscesses in the brain	136
55-57. Illustrating case of two abscesses in the cerebellum	146
58. Frontal lobe abscess secondary to frontal sinus disease	147
59. Abscess of cerebellum occupying the anterior and inner part of the left hemisphere	148
60. Drawing to show the direction in which the complete mastoid operation should be extended in order to drain a cerebellar abscess through its stalk	149
61. Coronal section of left cerebral hemisphere, with small temporo-sphenoidal abscess	151
62. Glioma of frontal lobe	164
63. Cholesteatoma vera of cerebellum	165
64. Endothelioma of meninges of temporal lobe	166
65. Carcinomatous deposit in centrum ovale, secondary to growth in œsophagus	166
66. Carcinomatous deposit in the skull, secondary to Scirrhus mammae	167
67. Sarcoma of brain (multiple growths), secondary to sarcoma of lung	168
68, 69. Simple cyst of cerebellar hemisphere	169, 170
70. Hydatid of right frontal lobe	171
71. Hydatid of right lateral ventricle removed through post-Rolandic region	171
72. Aneurism of the intra-cranial portion of the left internal carotid artery	172
73-76. The establishment of a cerebral hernia as a decompressive measure for inaccessible brain tumours	176
77. Exposure of cerebellum (R. hemisphere) by the usual method	177
78. Tumour of the brain with a long history and with few symptoms	183
79. Photograph of psammoma (angioliathic sarcoma) of occipital lobe	185
80. Microscopical section of tumour	185

xii SURGERY OF THE BRAIN

FIG.	PAGE
81. Patient fourteen months after operation for cerebellar tumour	196
82, 83. Back and side views of head, two years and nine months after operation for cerebellar tumour	203, 204
84, 85. Healed fracture, outer and inner surfaces of skull, over gliomatous tumour in occipital lobe	206
86. Cystic glioma of occipital lobe under healed fracture of skull	206
87. Photograph of supposed meningo-cortical abscess	210
88. Tumour of frontal lobe following punctured fracture of skull	210
89-95. Illustrating the histology of the tumour	211-215
96, 97. Parosteal round-celled sarcoma of the squama	227
98. Periosteal sarcoma of squama	227
99. Cavernous angioma (without sarcoma cells) of os frontis projecting backwards into skull cavity and compressing frontal lobe	228
100. Sarcoma of orbital part of os frontis displacing dura and brain	228
101. Sarcoma of outer aspect of dura mater compressing left frontal lobe	229
102. Sarcoma of outer aspect of dura	229
103. Fibrosarcoma of cerebellar meninges	230
104. Tumour (? endothelioma) of meninges in frontal region	231
105, 106. Endothelioma of meninges in frontal region	232
107. Sarcoma ossis frontalis before and after operation	233
108. Destruction of skull by malignant disease	233
109. Epithelioma of frontal region	234
110. Carcinoma of frontal region	234
111. Photograph of a child, aged 5 years, showing position of head assumed in a lesion of the right lateral lobe of the cerebellum	239
112. Child with right cerebellar tumour (solitary tubercle)	240
113. Skew deviation of the eyes	252
A, B, C, D, illustrating Dr. Hughlings Jackson's classical papers on tetanus-like seizures and paralysis, with rigidity in tumour of the middle lobe of the cerebellum	254, 255

ILLUSTRATIONS

xiii

FIG.		PAGE
114.	Bulging right occipital fossa in a child $3\frac{1}{2}$ years	257
115.	Simple cyst of left cerebellar hemisphere	259
116.	Photograph of cast of back of head, showing bulging left occipital fossa	262
117.	Illustration of solitary tubercle removed from left occipital fossa with success	262
118, 119.	The patient fifteen months after operation	264
120.	Hæmorrhage tearing up left cerebral hemisphere	268
121.	Fibro-plastic tumour of Lebert	270
122.	Fibro-plastic tumour of cerebellar meninges	270
123.	Fibro-sarcoma of cerebellar meninges	271
124.	Tuberculous tumour of the cerebello-pontine angle	271
125.	Upper surface of cerebellum, showing a solitary tubercle in each hemisphere	272
126.	Endothelioma of cerebellum	272
127.	Solitary tubercle of cerebellum	273
128.	Simple cyst of cerebellum	273
129.	Spindle-celled sarcoma of the auditory nerve	274
130.	Tumour of left auditory nerve	275
131.	Endothelioma of cerebellar meninges	276
132.	Glioma filling fourth ventricle	277
133.	Fibroma growing from the left acoustic nerve	278
134.	A tumour the size of a bantam's egg, of a firm fibrous consistence, in the left cerebello-pontine space	279
135.	Neurofibroma of the right acoustic nerve	280
136.	Encapsulated sarcoma of the cerebellar meninges com- pressing upper surface of vermis	281
137.	Fibro-sarcoma of left cerebellar hemisphere	282
138-144.	Case of fibro-sarcoma of cerebellar meninges	284-288
145-148.	A case of compound comminuted fracture of the skull and laceration of the brain	289-292
149.	Operation for simultaneous exposure of both cerebellar hemispheres, necessitating ligation of the occipital sinus	293
150.	Structures in relation to the anterior aspect of the cere- bellar hemisphere and the posterior surface of the petrous	293

xiv SURGERY OF THE BRAIN

FIG.	PAGE
151. The reindeer of the cave of Thayngen, near Schaffhausen	295
152. Perforated antler discovered in the cave of La Madelaine	296
153. Right cerebral hemisphere from a human fœtus in the latter half of the 6th month of development	296
154. Sarcomatous solid tumour of (?) optic thalamus	299
155. Spreading œdema of the centrum semi-ovale, from a small nodule in the right prefrontal cortex, secondary to a renal carcinoma	300
156. Areas and centres of the lateral aspect of the human hemicerebrum	302
157. Areas and centres of the mesial aspect of the human hemicerebrum	302
158. Horizontal section of the occipital lobe, showing the optic radiation	308
159. Glioma of occipital lobe	310
160, 161. Symmetrical atrophy and degeneration of the occipital lobes	313
162. The distribution of the middle meningeal artery	315
163. Fibro-plastic tumour of cerebral meninges	315
164. The motor area and its subdivisions on the lateral aspect of the hemicerebrum of the chimpanzee	317
165. The motor areas and centres on the mesial aspect of the hemicerebrum of the chimpanzee	317
166. Glioma of frontal lobe, microscopical section	322
167. Glioma of frontal lobe	327
168-170. Large glio-sarcoma of frontal lobe successfully removed	328
171-174. Illustrating a case of subcortical tumour	329
175-182. Illustrating a case of malignant growth of frontal lobe perforating dura and skull	331-336
183, 184. Symmetrical cortical lesions causing hallucinations of hearing, word deafness, and sensory aphasia	357
185. Sketch of operation for subcortical tumour (sarcoma), growing in the centrum ovale beneath the cortex of the upper part of the precentral convolution and the superior parietal lobule	359

ILLUSTRATIONS

XV

FIG.	PAGE
186-189. Illustrating the usual method of making the scalp flap, and the drainage of a malignant "cyst"	360
190. Diagram of site of tuberculous tumour behind the central fissure	362
191. Large sarcoma of cerebral meninges	374
192. Large tumour of left parietal region	377
193. Radiogram of the tumour	377
194-198. Tumour of frontal lobe without optic neuritis	388-392
199. Microscopical section of growth found between dura of posterior fossa and temporal bone	394
200-201. Microscopical appearances of frontal lobe tumour described under Figs. 175-182	395, 396
202-206. Large sarcoma of outer surface of dura mater	399-403
207. Horizontal section of brain, showing the hernia and the extension of the tumour across the middle line	405
208. Microscopic section of tumour, showing gliomatous tissue with giant cells	406
209. Expansion of right internal auditory meatus by fibroma of auditory nerve	407
210. Chronic hydrocephalus of ventricles	412
211. Three views of transverse sections of the cerebellum	413
212. Section of a cerebellar glioma	414
213. Choroid flexus of fourth ventricle with tumour cells adherent	415
214. Posterior aspect of cerebellum, showing the expanded right cerebellar hemisphere and the pressure cone around the medulla	417
215. Lateral view of right cerebellar hemisphere and medulla, showing pressure cone	418
216. Under surface of cerebellum and medulla, showing flattening of medulla, bulging of right cerebellar hemisphere and left vertebral artery lying in a groove on the surface of the medulla	419
217. Section through pons and cerebellum, showing cyst in right hemisphere	420
218. Area of brain exposed by right occipital decompressive operation	422

xvi SURGERY OF THE BRAIN

FIG.	PAGE
219. Localised meningo-cortical lesion of left ascending parietal convolution—drawing of brain as exposed during the operation	425
220. Section showing tumour in right hemisphere	429
221. Section through ventricles showing destruction of basal ganglia and extension of the tumour into the lateral ventricle	430
222. Histological section of tumour	431
223. Meningeal sarcoma	434
224. Tuberculous tumour of post-central convolution	438
225. Glio-sarcoma in cerebello-pontine angle	440

LECTURE I

REMINISCENCES OF DR. LETTSOM—SOME POINTS IN THE SURGERY OF THE CEREBRAL MEMBRANES

Anatomical, physiological, and physical considerations—The subdural and sub-arachnoid spaces—The cerebro-spinal fluid—Subdural hæmorrhage in adults and infants—Traumatic encephalocele—Pathology of meningeal infections—Subdural and sub-arachnoid suppuration—Varieties of meningitis—Symptoms and diagnosis—Surgical treatment of tubercular and suppurative meningitis and of hydrocephalus interna.

It is my duty, as it is my pleasure, to acknowledge gratefully the honour which the Council of the Medical Society of London has conferred upon me by inviting me to deliver the Lettsomian lectures.

Reminiscences of Dr. Lettsom.

These lectures were founded to commemorate a great physician who, a century ago, was a leader of medical practice in London. It therefore seems only right briefly to recall something of his life and work before entering upon the subject matter of the lectures.

John Coakley Lettsom came of a Quaker family. He was born in 1744 in the West Indies, and died in London in 1815.

Sent at an early age to England to be educated, he chose medicine as his profession, and, in accordance with the custom of the time, was apprenticed, the master selected for him being




FIG. 1.—John Coakley Lettsom, M.D., LL.D., F.R.S.

a Mr. Sutcliff then practising at Settle in Yorkshire. After his apprenticeship he attended St. Thomas's Hospital, where he was most diligent in his observation of the patients, of whose cases he made notes, a custom not then usual.

His first practice was in the West Indies. He had returned to the place of his birth to claim the residue of a property left to him by

his father. It consisted of a portion of land and some fifty slaves ; these latter he promptly emancipated, slavery being altogether repugnant to his nature.

He thus found himself dependent upon his profession for support, and commenced practice in Tortola. It is recorded that "in five months he amassed two thousand pounds," a financial success attending the early efforts of very few. He gave half this sum to his mother, and with the remainder returned to England in September 1768.

He spent several months visiting the Universities of Edinburgh, Paris, and other centres of learning, and took the degree of M.D. at the University of Leyden.

Soon after graduating he returned to London, and commenced practice in the City under the patronage of Dr. John Fothergill. His success was early and complete, and it is stated that for a number of years he enjoyed the largest practice in the City of London.

Of this Society he was one of the original Fellows. The memoirs of the Society bear witness to the prominent part he took in its discussions, while the freehold property from which we still derive a revenue attests the generosity of his benefactions.

He was no less celebrated for liberality of mind and benevolence than for his skill as a physician.

The following is one of the more extraordinary instances of his generosity. He was attacked and robbed by a highwayman, but far from bearing any resentment, he gave the man



FIG. 2.—John Fothergill, M.D., F.R.S.

his address, and offered him further assistance. The robber responded to this invitation, and Lettsom succeeded in obtaining for him from His Majesty a commission in the army, and he served the country with distinction.

Lettsom was a voluminous writer, and did not confine himself to medical subjects. His non-medical writings were chiefly upon matters of public utility or on philanthropy, such as the properties of the tea-plant, the cultivation of the

mangel-wurzel, the abolition of slavery, and the relief of the poor.

He was not learned in the highest acceptation of the term, yet he was the friend and the patron of learning. Wherever his influence extended—and it was not narrowly circumscribed—science and useful literature flourished.

He was particularly keen on exposing quacks. On one occasion he insisted on a post-mortem examination as a “urine caster” had asserted that the disease which had caused death was in the kidneys, whereas Lettsom maintained that the symptoms—headache, vomiting, slow pulse, and vertigo—were due to disease of the brain. The autopsy showed healthy kidneys, and inflammation within the skull, probably the result of a former injury.

His correspondence was extensive, and many remarkable letters have been preserved, which show the variety of subjects in which he took interest, and afford many evidences of his kindly and sympathetic nature.

The amenities of medical life appear to have somewhat differed, in their forms of expression at least, from those of the present day. It is recorded that Lettsom was much angered by the discourtesy of Mr. Baker, one of the surgeons of the hospital. Mr. Baker had a son who suffered

from epilepsy, which somewhat impaired his understanding. His medical colleague Dr. Akenside inquired to what study he proposed to place him ; Mr. Baker replied, "I find he is not capable of making a surgeon, so I have sent him to Edinburgh to make a physician of him."

Another instance of the manners of the times is afforded by the well-known ungenerous epigram written of Lettsom—

When patients come to I,
I purges, bleeds, and sweats 'em.
If after that they choose to die,
What's that to I,
I lets 'em.

Lettsom undoubtedly earned a handsome professional income, but the extent to which his private fortune must have been injured by his generosity to others may be gathered from one of his letters, dated 18th February 1783. Replying to an intimate friend who had upbraided him for neglecting to take any adequate relaxation, he says, "I have a weakness which I cannot overcome. I hope and believe it does not result from ambition or from vanity ; but so it is, however, that if I hear of want, I often distress myself to obviate that want. In looking over my expenses since January last, I find I have

expended above six hundred pounds in donations; and, like a necessitarian, I have no power to control this extravagance. Thus with an income of £5000 per annum I am always involved; and what is still more alarming, my pensioners increase daily. I mention my extravagance as an excuse for my perpetual application to busi-




FIG. 3.—Garden view of Dr. Lettsom's house at Camberwell.

ness; for since the year 1769, when I first settled in London, I have not taken one half-day's relaxation, and I cannot get to Grove Hill above once a fortnight."

Though there were no death duties in his time, he distributed his wealth during his life—a form of charity much more real than that commonly practised of distributing after death what can no longer be retained.

The story of the rescue of a starving family as the result of an early morning walk is typical

of Lettsom's life. This family was saved from starvation, and with the co-operation of the churchwarden of Little Greenwich in Bishopsgate Street was given a new start in life.

Lettsom writes "that he has experienced how

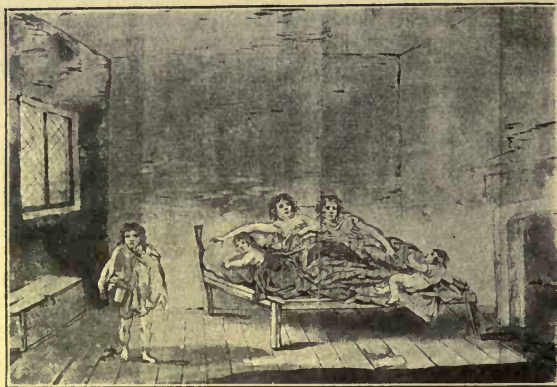

FIG. 4.—Destitute family relieved as a result of one of Dr. Lettsom's morning walks in the Metropolis.

greatly the sight of real misery exceeds the description of it," and again

To pity human woe,
Is what the happy to the unhappy owe.

Physician, student of nature, and philanthropist, Lettsom passed into the silent world, leaving behind him a host of friends and a name ever to be associated with boundless private charity and numerous projects for the public weal.

Of Lettsom it may be truly said—

To live in hearts we leave behind is not to die ;
and,

The souls of the righteous are in the hand of God.

In this lecture I propose to consider the position of surgical intervention in the disease, or rather group of diseases, having for anatomical basis a lesion of the meninges.

*Anatomical, Physiological, and Physical Observations.
The Subdural and Sub-Arachnoid Spaces.*

We are all familiar with the three-fold membranous investiture of the central nervous system, but the special importance of certain anatomical details is less well understood.

Axel Key and Gustav Retzius in 1875 published the result of several years' research in a beautiful monograph, which, as Charpy says, has remained the classical work on this subject, though their results have not been confirmed (or corrected) by subsequent workers.

Key and Retzius showed :—

1. That there is no gross communication between the subdural and the sub-arachnoid spaces.

2. That the sub-arachnoid and the subdural spaces of the brain can be completely injected from the corresponding spinal spaces.

3. That fluids injected separately into each of these spaces mix in the subdural space of the Pacchionian bodies, then pass on into the venous sinuses, and even reach the veins of the scalp.

4. That injection of the sub-arachnoid space, after death or during life, at a low pressure shows that at the base of the brain it is broken up into certain definite spaces of considerable capacity, and that over the cerebral hemispheres the sub-arachnoideal mesh-work is more abundant in the sulci than over the tops of the convolutions, so that these latter, as another writer has aptly expressed it, stand out from the general injection mass like the hedges of a flooded land.

5. That the blood-pressure in the cerebral sinuses, though diminishing during inspiration, is always positive, and that the pressure of the cerebro-spinal fluid in the sub-arachnoid space always exceeds by a few mm. of Hg. the cerebral venous pressure, and that therefore the flow of fluid is from the sub-arachnoid space into the venous system. As the specific gravity of the cerebro-spinal fluid is less than that of the blood, any flow determined by osmosis would be, in the main, in the same direction.

As the result of his own researches, Leonard Hill maintains that the sub-arachnoid space is "chiefly a potential rather than an actual space, except in those few places where inequalities of the brain surface are rounded off by small collections of fluid beneath this membrane," and that "the living brain with its circulating blood almost entirely fills the cranium, and the fluid that moistens its surfaces is little more in amount than the synovial fluid in a joint."

This latter statement is certainly true of the subdural cavity, but is less clearly applicable to the sub-arachnoid space; and when it is stated that "the plates in Key and Retzius' monograph, which are copied into most anatomical works of to-day, give an entirely erroneous idea of the contents of the cranium in the living animal"; it seems desirable to point out that these authors made their injections shortly after death, and do not suggest that the spaces are normally distended to the same degree during life, and that they controlled their results obtained from injections on the cadaver by experiments on living animals. It must not be forgotten that however little fluid there may be in the sub-arachnoid cavities at a particular moment during life, yet a considerable amount is present in the ventricles with which the

sub-arachnoid cavities are in direct communication.

The well-known figure of Key and Retzius, showing the sub-arachnoid spaces fully injected as they appear in a vertical median section of the head, was expressly intended to represent the relationship "of the various parts of the brain when the ventricles and the sub-arachnoid space were distended with fluid." The blood-pressure being nil, the injection would displace most of the blood from the vessels of the pia, driving it at least as far as the venous sinuses, and the sub-arachnoid spaces would therefore appear exaggerated. Artificial distension by injection is a usual and well-known method of anatomical demonstration. For example, it would scarcely be contended that Sappey's illustrations of the lymphatics, as demonstrated by injection with mercury, were intended to represent their normal state of distension during life.

Whatever the normal condition of the sub-arachnoid spaces may be, they certainly become distended during life with blood or purulent effusions; of this any one who has attentively made a few post-mortem examinations must be convinced.

In the illustration of posterior basal meningitis published by Dr. Lees and Sir Thomas

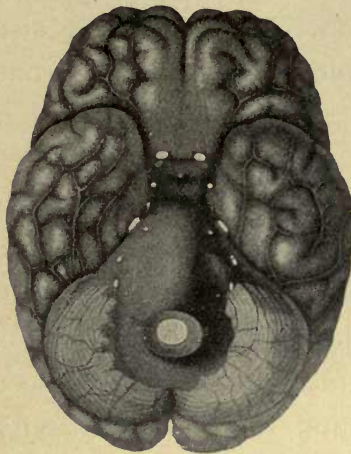


FIG. 5.—Anterior part of cisterna magna distended by artificial injection.
(Key and Retzius.)

The injection was made into the sub-arachnoid space of the spinal theca. The injection has penetrated everywhere beneath the arachnoid, in the interpeduncular space, and in the sulci between the convolutions.

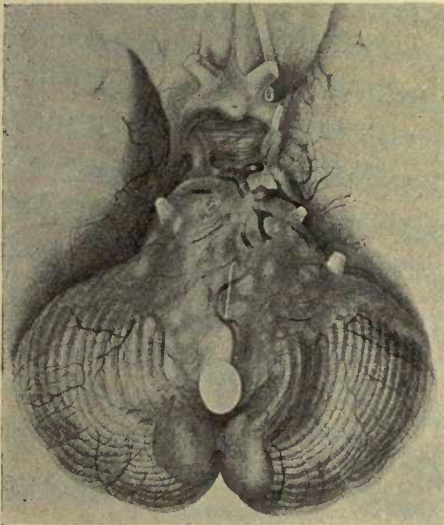


FIG. 6.—Anterior part of cisterna magna distended with pus. (Lebert, 1861.)

From a case of suppurative meningitis in a soldier aged 24 years. Death on the fourth day. The onset was sudden, and the symptoms were fever, shivering, severe occipital pain, prostration, delirium, and finally coma.

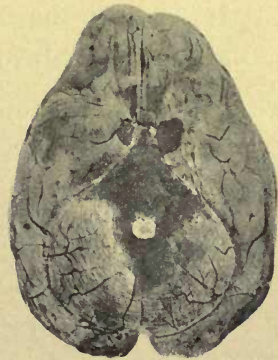

FIG. 7.—Posterior basal meningitis. (Lees and Barlow.)

Child aged 5 months. Duration of illness 11 days.

The dark shading indicates the sites of pus collection under the arachnoid. The anterior part of the cisterna magna was distended, and pus was also present over the tips of the temporo-sphenoidal lobes.

Barlow, the anterior part of the cisterna magna is seen distended with pus, just as one of Key and Retzius' figures shows it distended artificially by injection.

It is a common surgical experience—for example, in operating to relieve optic neuritis—that it is easy to obtain a flow of fluid from the sub-arachnoid space of the base of the brain while it is almost impossible to do so from the vertex—opening the subdural cavity is for such a purpose a useless measure.

The only place at which, from the figures of Key and Retzius, it would be reasonable to infer that a considerable flow of cerebro-spinal fluid would be obtained is below the cerebellum. It is just here that the surgeon most easily obtains a rush of cerebro-spinal fluid and is able to establish drainage.

Imbert, in 1884, wrote: "The principle of Archimedes, in conjunction with that of Pascal, explains the manner in which certain fluids of the animal economy afford protection to the organs immersed therein. The brain, for example, loses 98 per cent of its weight when immersed in cerebro-spinal fluid, for the difference in specific gravity between the brain and the fluid is only 0.02. A brain which would weigh 1500 grammes in air would only weigh

30 grammes in the cerebro-spinal fluid: it is this weight, then, of 30 grammes which represents the whole pressure of the brain on the base of the skull. So feeble a pressure, scarcely amounting to 1 decigramme per square centimetre, would neither damage the extremely delicate texture of the nervous centres nor offer the least resistance to the circulation of the blood in the interior of the brain. Further, fluid interposed between the brain substance and the cranium lessens the effect of blows and external shocks by spreading compression produced at any one point over the whole surface of the brain, in accordance with the law that pressure is equally distributed in all directions."

Though it cannot be admitted that the physical conditions are anything like so simple as Imbert's description would lead us to believe, yet the almost constant escape of the brain stem in injuries of the head points conclusively to the existence of some special protective mechanism.

The sub-arachnoid cisternæ, partitioned off as they are so that fluid only slowly escapes from one into another, are well fitted to act as a kind of hydraulic buffer, and notwithstanding the view that the sub-arachnoid space is a potential space only, it would appear that the cisternæ are

of importance in protecting the isthmus cerebri from injury.

The weight of the brain is not wholly, or even to any considerable extent, supported by hydrostatic pressure ; its anterior and posterior

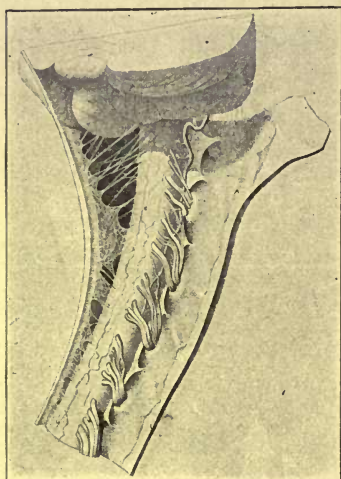


FIG. 8.—The brain stem.
(Key and Retzius.)

Note the sub-arachnoid trabeculae which prevent movement of the brain stem against the foramen magnum.

extremities rest upon planes inclined in opposite directions, viz. the orbital plate of the frontal bone and the tentorium cerebelli ; the middle lobe fits with great accuracy into the middle fossa, and the falx cerebri prevents any side-to-side movement of the hemispheres ; a very thin layer of fluid would in ordinary

circumstances prevent any injurious shock from impact of the brain substance against the resisting bone.

From the mass of the hemispheres the isthmus cerebri passes almost vertically downwards, its lateral displacement is prevented by the sheaths of the nerves issuing from it and by bands of sub-arachnoid connective tissue, and

the amount of fluid by which it is surrounded is sufficient to give material mechanical support.

It is to the parts below the tentorium that Imbert's purely physical statement of the conditions present more closely applies.

Hill's experiments led him to conclude that though the amount of blood in the arteries or veins of the brain may and does vary considerably, the absolute amount of blood within the cranium does not vary to any great extent, the observed circulatory variations being variations in the distribution of blood and not in its total amount, and the atmospheric pressure being the chief factor in maintaining these conditions.

Sir Thomas Watson in the fifth edition of his *Practice of Physic* observed that he formerly taught this view, and mentioned some experiments by Munro and Kelly which led him, though with some hesitation, to accept it; the experiments of Burrows, however, convinced him that it was erroneous.

It would certainly be thought that if the atmospheric pressure exercised so considerable an influence on the cerebral circulation this would be profoundly modified when the dura or even the skull was opened; surgeons do not, however, observe any profound change in

c

the condition of the patient at the moment of opening the skull.

No more marked disturbance of the circulation is observed on opening the skull than on opening the peritoneum; when the surgeon incises the dura mater there are no phenomena comparable to those occurring when the normal parietal pleura is incised.

The Cerebro-Spinal Fluid

The cerebro-spinal fluid is a secretion and not an exudation. Mott has recently laid stress on this point. He writes: "It is comparable to the amniotic fluid and the sweat for true albumin and fibrinogen are absent. (It may be noted here that one function of the amniotic fluid is protection.) At each cardiac systole it is driven from the cranium into the spinal canal. (This may in part explain the presence of blood and pus in the spinal theca when purulent and hæmorrhagic effusions occur within the cranium.) A layer of arachnoid like a sieve follows the pial vessels as they dip into the brain, and thus forms a perivascular canalicular system. The vessels are therefore always surrounded by a constant fluid pressure." The cerebro-spinal fluid is of course not lymph, but these arachnoid

sheaths play a part in the brain that is elsewhere the sole function of the lymph sheaths. In this manner oxygen, which is necessary for the biochemical changes of nervous tissue, is probably carried by the cerebrospinal fluid to all parts of the central nervous system.

On examining the great lymph sheath around the aorta of the turtle in the Royal College of Surgeons Museum, it occurred to me that it would be interesting to examine the membranes around this creature's brain. It will be noticed that the cranial subdural cavity of the turtle is not a potential but an actual space, and that delicate connective tissue bands cross it, as in the sub-arachnoid space of man, to prevent displacement of the brain stem (Figs. 9, 10, and 11).



FIG. 9.—Portion of aorta of turtle (*Chelonia Mydas*) showing capacious lymphatic sheath surrounding the artery.—(R. C. S. Museum, *Physiological Series*, No. 863 c.)

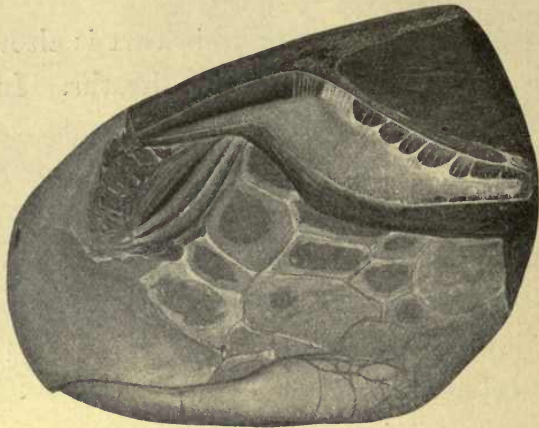


FIG. 10.—Dissection of head of turtle, with brain stem exposed.

Note the trabeculae of areolar tissue crossing the wide subdural space to prevent displacement against the surrounding rigid brain case.

The turtle heads were kindly supplied by Messrs. Buszard of Oxford Street.

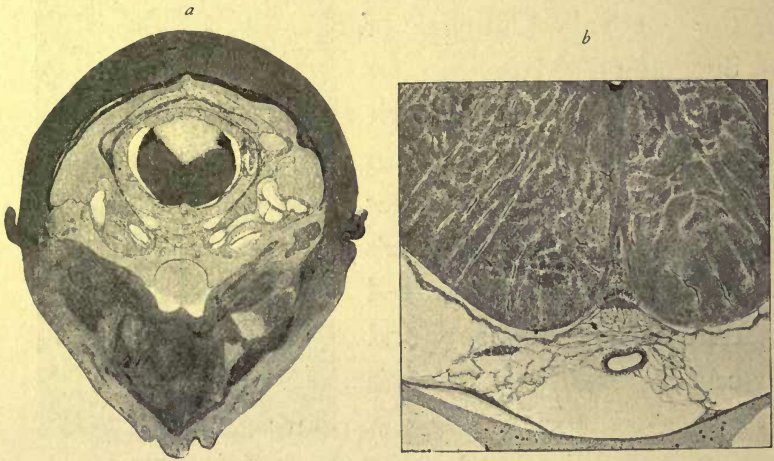


FIG. 11.—The brain stem in the embryo.

FIG. 11 *a*.—Drawing of section of head of human embryo (about four months). ($\times 2$). A large space is seen between the brain stem and the skull. In this space the basilar artery can be recognised lying nearer the brain stem than the skull. The space is crossed by delicate bands of embryonic connective tissue.

FIG. 11 *b* represents a portion of the same specimen as seen under a one-inch objective. The basilar artery and the connective-tissue bands are more plainly shown, and fine vessels can be seen penetrating deeply into the brain substance.

The specimen was prepared by Dr. Charles Green, who kindly allowed me to use it.

Hæmatocele of the Subdural Cavity in Adults and Infants. Traumatic Cephalhydrocele and Encephalocele.

It has already been pointed out that the subdural and sub-arachnoid cavities are often defined and distended by effusion of blood following injury. Time will not allow a full discussion of this subject, but reference may briefly be made to cases in which a blow on the head or a fall is followed at some distance of time by obscure cerebral symptoms, among which mental disturbance and transitory paralysis are prominent; in some such instances a considerable hæmorrhage has taken place into the arachnoid cavity, the blood has become encysted, and like a blood collection in the tunica vaginalis, has continued to increase in size, causing slow pressure on the brain.

I successfully removed such a cyst, which measured seven inches in its long diameter, four and a half in its short, and one and a half in thickness, from a man aged thirty-four years, a patient of Dr. James Taylor, who had narrowly escaped being consigned to a lunatic asylum, where he might possibly have been labelled

“general paralysis” and died without relief (Figs. 12 and 13).

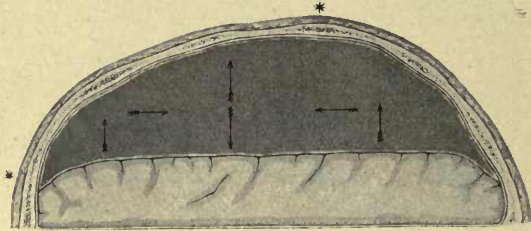


FIG. 12.—Diagram of subdural hæmatocele. (Taylor and Ballance.)

Horizontal section showing the position of the “cyst” and the compression of the cerebral hemisphere, and explaining the occurrence of *expansile pulsation in the tumour*. The marks ** show the extent of the opening in the skull. The tumour being fluid, the pulsations of the brain were transmitted in every direction; hence when the finger and thumb grasped the centre of the tumour (see arrows in the centre of the cyst) they were separated by an expansile pulsation comparable to that which obtains in aneurysm.

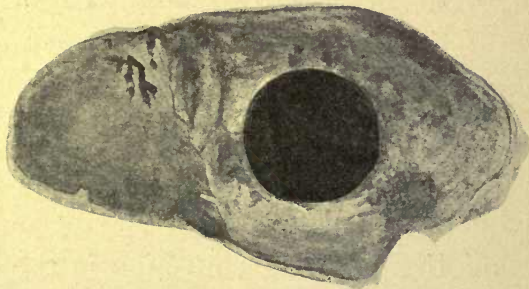


FIG. 13.—Photograph of the outer surface of the tumour. (Taylor and Ballance.)
(R. C. S. Museum, No. 3837 A.)

An opening has been made in the cyst wall, which exposes in the specimen a deep red clot.

The following two cases of operation for subdural hæmorrhage I have not previously published :—

C. K., female, aged twenty-six years. Admitted December 21, 1904, into the National Hospital under Dr. Ferrier.

History (obtained from husband).—No neurosis in family. Married eighteen months. Now five months pregnant. No history of injury. A month ago her husband was leaving home in the morning for his work when he heard a cry, and on going back found his wife shrieking and in a demented condition. She was violent, and tossed herself about. Next day condition much the same, but some weakness of right arm was noticed. She continued screaming, with intervals, during which she would repeat meaningless combinations of words, or point to things seen by herself apparently of a terrifying description. She remained in this state for a month. Recently paresis of right leg had been noticed.

On admission.—Patient lies on her back continually crying out and waving her left arm. She does not seem to recognise objects presented to her. On being moved she utters loud cries. When not crying she lies in an exhausted semi-comatose condition. She has double optic neuritis, but is able to see. Pupils normal. Marked weakness of right side of face; complete flaccid paralysis of right arm, and nearly complete paralysis of right leg. Left arm moves well. Abdominal reflexes absent on right side. Knee-jerk brisk, and ankle clonus present on right side. Urine retained; fæces passed unconsciously.

Operation, December 24, 1904.—The patient has been kept quiet under morphia; she is more exhausted and her pulse is weaker. The left motor area was exposed. A subdural hæmatocele compressing the Rolandic area was found. It extended forwards to the frontal pole and downwards towards the base, and was half an inch thick. It was removed without difficulty. Patient was much better after the operation, and all went well for

24 SOME POINTS IN THE SURGERY

ten days. On January 7 pneumonia supervened, and the patient died on January 10. There had been a little blood noticed on the dressings for a few days. This had come from cortical vessels, possibly those which had furnished the blood of the hæmatocele.

W. M., male, aged forty-eight years. Admitted on March 28, 1906, into the National Hospital under Dr. Ormerod.

The family history was good ; no epilepsy nor other neurosis could be traced in it. The patient denied having had venereal disease, but admitted having incurred the risk of contracting it. He had worked hard and had had recent mental worries. Much head work, but no manual labour. In May 1905 he was struck hard on the right side of the head by the falling lid of a flush tank ; he did not lose consciousness. Since then he has suffered from headache on waking in the morning. In February 1906 he had an illness thought to be influenza, and was sick once or twice without obvious cause. Since then he has had headache, occipital and retro-ocular. When he gets out of bed his sight becomes temporarily blurred ; he has diplopia occasionally. No definite giddiness. Has vomited six times since the "influenza." Sight has been worse during the last four weeks. The symptoms have varied. A week before admission he was thought to be better.

On admission.—Is slightly emotional ; cerebration slow ; takes some time to answer even simple questions. No alteration of smell, taste, or hearing. Sight much impaired ; reads one inch letters at four feet. No hemianopsia ; fields not contracted. (Rough test only).
Optic Discs. (Mr. Gunn.) *Right:* Intense fungiform

papillitis with numerous hæmorrhages. Highest point seen with +9 D. *Left*: Same as right. Highest point seen with +9.5 D. Pupils normal.

Tongue when protruded deviated slightly to left. Complains of dull, constant headache, occipital, retro-ocular, and frontal. No weakness of face or arms. Cremasteric reflex difficult to obtain on left side. Patellar and ankle reflex more brisk on left than on right side. Ankle clonus well marked on left, slight on right side. Gait feeble and slightly unsteady. No tenderness of cranium.

Operation in two stages. Bone removed over right frontal lobe. On opening the dura a thin layer of clot enclosed in a membrane found over the whole convex surface of the right hemisphere, from frontal to occipital region. This was removed. A cortical vein in the frontal area bled a good deal; apparently it was attached to the clot capsule, and may have been the cause of the subdural hæmorrhage. The clot was thicker (about quarter inch) over the anterior part of the frontal lobe and over part of the Rolandic area; elsewhere it was very thin. Patient left hospital convalescent on May 16, 1906.¹

This matter did not escape the astute observation of Richard Bright, who in 1831 wrote: "There is a species of partial accumulation of fluid in the brain which must not be passed over without notice: I mean serous cysts forming in connection with the arachnoid, and apparently lying between its layers, or attached

¹ See another case of successful operation for Subdural Hæmorrhage on page 87.

by thin adventitious membranes. These are occasionally discovered on dissection, and have either produced no symptoms or have been quite unsuspected till after death. These cysts vary in size from the size of a pea to that of a large orange, and may be considerably larger. They appear to be of the most chronic character, and probably never enlarge after their first formation. The brain is completely impressed by them, so that when the fluid is let out a permanent cavity remains, and even the bone of the skull is moulded to their form."

Two cases are illustrated in Bright's work.

The post-mortem appearances in one of these are thus described: "On sawing through the skull-cap a sudden gush of limpid fluid attracted attention, and examining whence this fluid escaped, a considerable oblong depression was found in the middle lobe of the right hemisphere. On minute inspection the fluid, which amounted to at least twelve ounces, had been contained in a cyst formed by the splitting of the arachnoid membrane, which had pressed on the middle lobe of the brain, and thus produced a corresponding depression. The membranes and substance of the brain (with the exception stated) did not exhibit any morbid appearances. The thoracic viscera were quite healthy. The abdo-

minal viscera showed no traces of disease, except extensive ulceration of the ileum and cæcum." The preparation is deposited in the Museum of the Royal College of Surgeons. The patient, a male aged eighteen years, had probably died from enteric fever. No history of injury is given.

In 1897 Biroula showed at a meeting of the St. Petersburg Anatomical Society a specimen very similar to that of Bright. The patient, a soldier aged twenty-four years, died from enteric fever. A large meningeal cyst was found over the first and part of the second frontal convolution on the left side. The brain was indented by the cyst. The cyst walls were formed by the meninges, and no trace of any parasite was found. There was a projection over the corresponding part of the skull. Shortly before death some rigidity of the right arm had been observed ; with this exception no symptoms referable to the cyst had been noticed.

Prescott Hewitt, in 1845, contributed a paper to the Royal Medical and Chirurgical Society, in which he discussed the subject with great acumen, and related several cases. In accordance with the views then prevalent, he held that the thin investing membranes were derived from the fibrin of the blood, and he made the interesting observation that he had seen similar

membranes enclosing blood collections in the pleura. Curiously enough, though he referred to cases in Abercrombie's work, he made no mention of Bright's cases.

Prescott Hewitt also discussed the subject in his article on "Injuries of the Head" in Holmes's *System of Surgery*. Good illustrations of these cysts are there given and reference made to a particularly striking case published in full in *The Lancet*, 1846, vol. i. p. 416. A boy aged eight years received a blow on the head from a cricket ball and shortly afterwards showed symptoms of insanity. He had recurrent attacks of insanity with intervals of health until his death, fifteen years after the injury. The symptoms in the last attack were headache, vomiting, and drowsiness. At the autopsy a large arachnoid cyst was found.

Bearing in mind that in almost all serious head injuries blood is extravasated into the arachnoid cavity, it may well be that in certain cases of intermittent headache, intermittent paralysis, or intermittent insanity subsequent to head injury the pathological lesion present is arachnoid hæmatocele; a condition certainly remediable by operation.

As I have mentioned successful cases of removal of large arachnoid hæmatocele, I must

record one on which I did not operate and death ensued. It is noteworthy that in these cases of arachnoid hæmorrhage there is a rise of temperature.

W. W., male, æt. 56, groom. Typhoid fever three years ago. No history of syphilis. Was kicked by a horse over the left eyebrow three months ago. Wound sutured by Dr. Halsted, who stated that there was no fracture of skull. Was said to be quite well until six weeks ago, when it was noticed that his left arm was weak and that he dragged his left leg when walking. Complete paralysis of left arm and leg four days before admission, followed in twenty-four hours by frequent vomiting and unconsciousness. Temperature 101° on morning of admission. On examination reaction to external stimuli delayed, but would answer to his name if frequently called. Speech slow and slurred. Paralysis of left arm and leg. Occasional clonic contractions of right arm. In the intervals the limb was held stiff; hand-grip feeble. Right leg unaffected. Knee-jerks brisk on both sides. Ankle clonus on right side. Well-marked Babinski's sign on both sides. Pupils dilated, equal and active; no ophthalmoscopic changes detected. No trace of albumen or sugar in urine. Constipation of four days' duration and incontinence of urine. Scar over left eyebrow; no apparent injury to bone beneath. Temperature 99° ; pulse 60. Condition remained unchanged. Alternating drowsiness and lucid intervals. Troublesome constipation relieved by calomel and house mixture. Temperature ranged between 98.2° and 100° ; pulse rate gradually increased, reaching 120 on sixth day. Seventh day, temperature 104.4° ; coma and death.

P.M.—Bones of skull uninjured. Large arachnoid blood-cyst found flattening all convolutions of right hemisphere. This was definitely encapsuled and the sac could be demonstrated apart from the dura. Contents dark and fluid. Right lateral ventricle compressed; left distended, its posterior horn was about the size of a golf ball. Œdema of lungs. Chronic nephritis.

During the life of the patient in St. Thomas' the symptoms did not appear to justify operation. The man was fifty-six years of age and looked at least ten years older. He was accustomed to take a good deal of alcohol. Learning more of the history of the case after death and reading the P.M. notes, it is easy to be wise after the event. It is noteworthy that the scalp wound was on the side opposite to the arachnoid hæmorrhage. I may say that I could not be sure before the autopsy was performed that the case was not one of ordinary vascular lesion, though the alternating drowsiness and lucid interval were suggestive of subdural hæmorrhage.

Cushing has recently drawn attention to surgical intervention for the intracranial hæmorrhages of the new-born. Cerebral palsies, epilepsy, and other nervous disorders, which may be a permanent life disablement, are often due to these hæmorrhages arising from trauma during birth. The unsupported venules passing from the brain of the infant to the longitudinal sinus and Pacchionian bodies are easily broken, and thus large blood extravasations occur in the subdural and sub-arachnoid spaces. Cushing

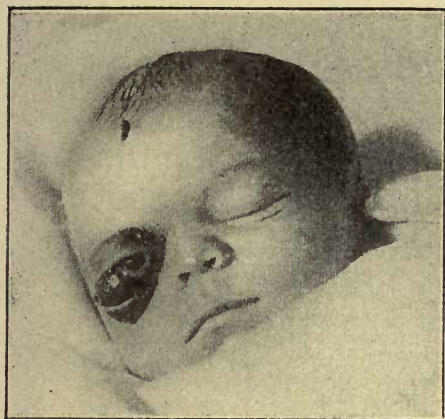

Fig. 14.

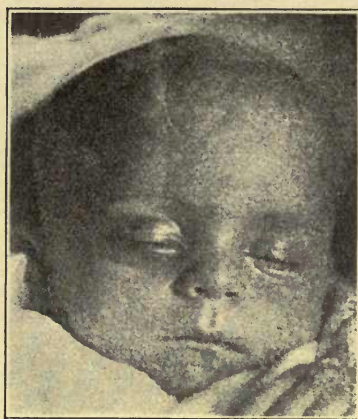

Fig. 16.

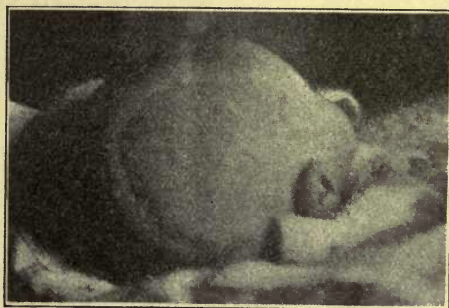

Fig. 15.

FIGS. 14, 15, 16.—Intracranial hæmorrhage of the new-born. (Cushing.)

FIG. 14.—Photograph of 9-day old comatose female infant. *Note* extreme degree of ocular proptosis and subconjunctival hæmorrhage and œdema. Forceps delivery; inability to suck; tense fontanelle; Cheyne-Stokes respiration, and gradual onset of coma.

FIG. 15.—Lateral view to show size and position of one of the symmetrically-placed osteoplastic flaps. Operation on right side; much blood-clot irrigated away, dura stitched under tension. To relieve tension same operation performed on left side with removal of further clot and relief of tension, as shown by recession of fontanelle.

FIG. 16.—Same patient. Photograph during sleep two months after operation. Complete retrocession of the exophthalmos.

says these extravasations are usually unilateral, and that they give rise to post-natal asphyxiation, a bulging fontanelle without pulsation, convulsions, unilateral palsy, a stable pupil on the side of the hæmorrhage, irregular respiration, slowing of the pulse, a rise of temperature, inability to take nourishment, and death.

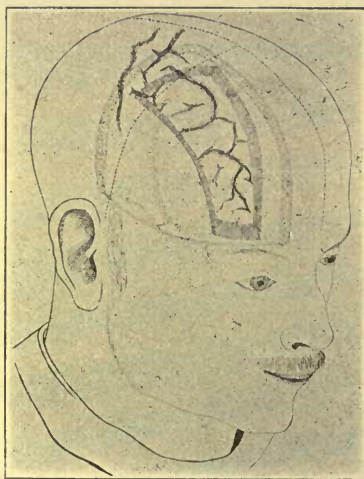


FIG. 17.—Sketch of operation for arachnoid cyst at St. Thomas's Hospital.

Cushing gives the details of four cases on which he operated ; two were successful. I have not had the opportunity of operating on such cases, but Cushing's paper will, I believe, be a stimulant to much good work in this direction in the future.

Besides the large collections of blood in the subdural cavity which run a somewhat acute course, surgeons are familiar with the localised

collections of clear fluid found years after an injury in this situation, and which produce mental disturbances, convulsions, and headache. The following is an illustrative case :—A man aged twenty-five was struck some years before admission to St. Thomas' Hospital on the right frontal region. Since the injury he had suffered from headache, irritable temper, and convulsions. On exploring the frontal region, a cyst of the arachnoid was discovered, containing clear but slightly yellow fluid. The headache was cured by the operation, but months after the operation he had a fit, and the epileptic condition has occasionally recurred.

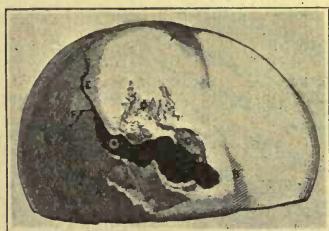

FIG. 18.—Simple fracture of skull in an infant. (Godlee, 1884.)

Male, æt. 5 months. Fell 8 feet on to head. Large, soft hæmatoma right side. Slow increase in size, with impulse on coughing. Twitching of left face, arm, and leg. Vomiting. Much improvement in 2 months. Child left hospital with tumour protected by gutta-percha shield. Soon became ill, and was admitted into St. Bartholomew's with meningitis. Death 24 hours later.

Mr. Godlee read a most instructive paper at the Pathological Society in 1885, "On simple fracture of the skull in infants followed by the development of pulsating subcutaneous tumours."

D

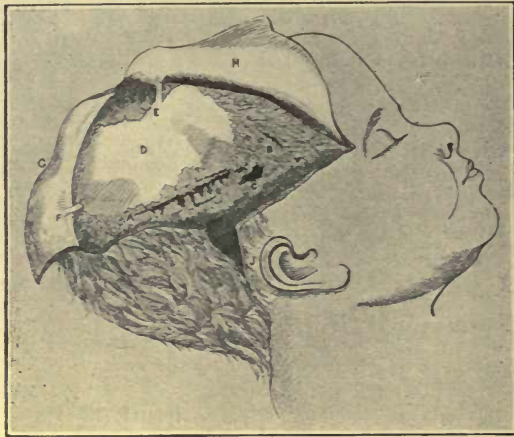


FIG. 19.—Simple fracture of skull in an infant. (Godlee, 1884.)

Female, æt. 8 months. Fell 14 feet on to head. Large hæmatoma right parietal region. Temp. 101° . Pulse 140. Left hemiplegia. Twitching movements of right limbs. Tumour at first diminished, but then began to increase in size. Pulsation noticed 10th day. Occipital bed-sore formed: sepsis, death. *Autopsy*.—The tumour communicated through damaged dura and cortex with ventricle.

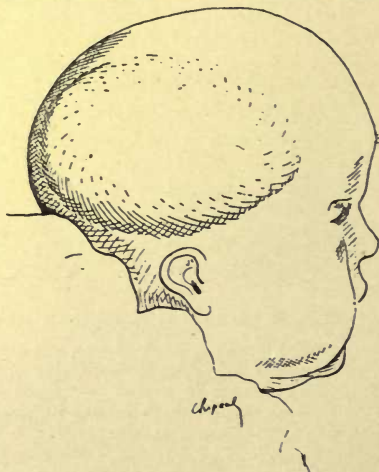


FIG. 20.—Traumatic meningocele. (Golding Bird, *Guy's Hosp. Reports*, 1889.)

Female, aged 7 months. Fell on floor 6 days before being brought to Hospital. A small swelling appeared in right parietal region immediately after injury. On admission there was a large, tense, pulsatory swelling over right side of head. The swelling was aspirated, blood and cerebro-spinal fluid being removed. It completely disappeared in 3 weeks.

For other cases see Lucas, *Guy's Hosp. Reports*, 1876, 1878, 1881, 1884, and Silcock, *Chem. Soc. Trans.* vol. xxi.

Similar cases have been reported by Sir Thomas Smith, Mr. Golding Bird, and others. The pulsating mass may consist of blood and cerebrospinal fluid with or without brain matter. Mr. Godlee's cases were aged five months and eight months. One of them had been also under the care of Sir Thomas Smith. Both died of septic infection. In both cases the injury was caused by a fall out of window, in one of eight, and in the other of fourteen feet. In one of the cases the brain cortex had been ruptured so as to open the ventricles.

Mr. Godlee writes: "When a young child receives a blow on the head the mischief is almost all spent upon the part struck and that lying immediately beneath it. The process extends little, if at all, beyond a single bone; indeed no one of the common fractures of the skull as we meet with them in an adult can take place in its typical form in an infant, but, on the other hand, there are forms of fracture special to the young skull. There are fractures of the infant's skull, formerly described by Mr. Syme, which would have been undetected (the bone after breaking the adjacent dura and severely lacerating the brain having sprung back in place) had not actual brain matter been found in the wound, beneath the scalp, or in the

pus (as I saw in one case) evacuated from the suppurating hæmatoma, which formed over it."

The following case, which was under the care of Dr. Bastian in 1902, is an example of a large traumatic encephalocele occurring later in childhood, and illustrates a method of treating hernia cerebri. A boy aged four years fell twenty-two feet out of window. In falling it was thought he struck the left side of the head against a projecting window ledge. He was unconscious for four days. A large non-pulsating tumour formed over the left parietal region. Some three and a half weeks after he had received the injury he was brought to London and I saw him with Dr. Bastian. He had right hemiplegia, complete aphasia, and some paresis of the left third nerve. The tumour was slowly increasing in size. Operation was decided on. A large scalp flap was thrown downwards, exposing a mass of brain substance, which was protruding through a fracture of the parietal bone. The break of the parietal bone extended downwards and forwards obliquely from near the middle of the sagittal suture. The edges were so clean that they might have been cut with a knife, and were separated about one-third of an inch. The fragment of parietal bone in front of the fracture

was removed by disarticulation at the sagittal and coronal sutures. A corresponding piece of

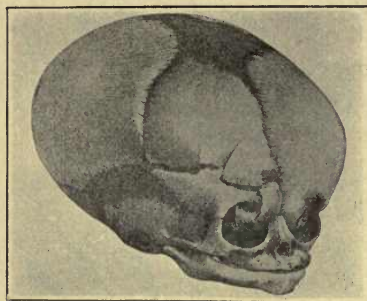


FIG. 21.—Fracture of right frontal bone in a new-born infant, fracture extending into orbit. (Von Bergmann, after Bruns.)

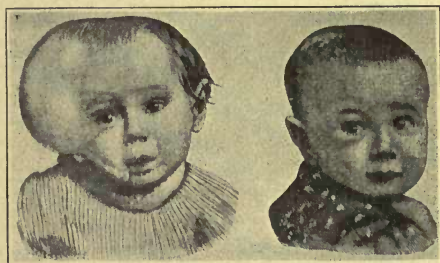

FIG. 22.—1. Traumatic meningocele before operation. (Dembowski, *Sawicki's Essay in Chirpault*.) 2. Same case after operation.

Male, aged 16 months. Three months before being seen fell on head. Tumour appeared and grew rapidly, so as to occupy right half of skull. *Operation.*—Part of frontal and most of parietal bone depressed and almost detached. The posterior part of parietal displaced backwards and outwards. Through the gap in the parietal bone the hernia cerebri protruded. Bone replaced. Gap closed by periosteal flap. Patient recovered.

bone behind the fracture was removed. It was then seen that the hernial mass of cerebral tissue protruded between the sharp edges of a rent in

38 SOME POINTS IN THE SURGERY

the dura corresponding in position and extent to the fracture in the bone. The opening in the dura was enlarged by incisions made at right angles to the tear, to the size of the aperture made in the skull. Pulsation in the extra-cranial mass at once recommenced. No further

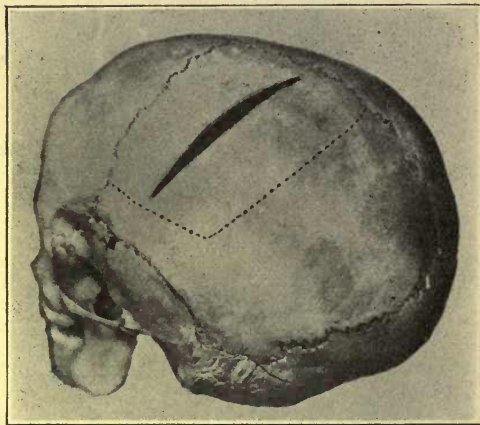


FIG. 23.—Diagram of fracture of skull in Dr. Bastian's case of traumatic encephalocele.

The bone enclosed by the dotted lines and by the frontal and sagittal sutures was removed at the operation.

nipping of the junction of brain and hernia could then take place. The brain had been damaged to the depth of an inch along the line of fracture. The scalp flap was replaced. The patient made a good recovery; the hernia soon disappeared. Two years later Dr. Saunders of Pembroke Dock wrote to Dr. Bastian: "Speech gradually improved and now almost perfect except for some

slurring when excited. Power over left leg almost completely restored, of arm only partially—no use of hand.”

*Lumbar Puncture in Injury to Brain and in
Apoplexy.*

This seems a fitting place to point out the great value of lumbar puncture in traumatic lacerations of the cerebral substance when the patient passes into the stage of cerebral irritation. A jockey, twenty-one years of age, was thrown from a horse. There was no fracture of the skull, but he was unconscious for ten days. The right arm was paralysed, and there was left ophthalmoplegia. I saw the patient with Dr. Ferrier. From unconsciousness he passed into a state of restlessness, irritability, and sleeplessness. By lumbar puncture $2\frac{1}{2}$ to 3 oz. of red-stained cerebro-spinal fluid was drawn off; on each occasion quiet sleep was obtained afterwards for four hours. The man made a good recovery. The question arises whether in some cases of ordinary apoplexy the pressure of the clot and serum on the nervous centres might not be relieved with advantage by lumbar puncture. In extra-dural hæmorrhage, from injury to the meningeal artery or a venous sinus,

the fluid withdrawn by lumbar puncture is clear, while in cerebral laceration or subdural hæmorrhage it is blood-stained.

Pathology of Infection.

Infective processes may extend from a focus of disease outside the skull to the interior of the skull by—

1. The disease affecting the bone and a visible track of bone disease forming a way of communication.

2. Extending through a pre-formed channel, such as a foramen or canal for the passage of vessel or nerve.

3. Making its way through a congenital defect in the ossification of the bone.

4. Extending along one of the processes of dura mater, which in certain situations dip into the bone.

5. Entering the circulation.

In some injuries infective material is introduced directly by the injury into the interior of the skull, a "stab culture" being in fact made, and the natural resistance to penetration being directly and abruptly broken down. This is the sole difference in the pathology of the intra-cranial complications of injury and disease.

The infective process more or less rapidly spreads within the skull from the spot where the dura has been brought into contact with infective material.

Extra-Dural Suppuration.

At the spot where it has come into contact with the pus the dura becomes inflamed and extra-dural suppuration occurs.

This is the first stage of intra-cranial infection. The resistance of the dura mater to the further progress of the infection may be great and prolonged. The effects are then limited to the formation of a more or less considerable localised extra-dural abscess. Or, the dura may be softened and perforated forthwith, and only a few drops of pus may collect external to it.

The following case well illustrates the resistance of the dura :—

A man was admitted to hospital on February 2nd with ear disease, which had already extended beyond the limits of the temporal bone. This was clearly shown by the fact that, on irrigation of the ear until it was quite free from pus, the pus rapidly re-filled the entire auditory canal and overflowed into the concha. The mastoid operation was done on March 12th.

The following day a fistulous track was noticed. This was enlarged with a sharp spoon. Recurrence of symptoms took place. On April 11th a free opening was made by chiselling away sufficient bone, thus freely opening the extradural abscess. From that time recovery was uninterrupted (Bergmann). Pus must have been in contact with the dura for at least nine weeks (probably longer), but no perforation of the dura took place.

At the post-mortem examination of a man who had died from acute meningitis within forty-eight hours of the onset of illness, the temporal bones, while the dura was still in place, looked normal, but on removing the dura the roof of the left tympanum looked a little darker than that of the right. It was not perforated nor carious, but a tiny thrombosed vein was seen to issue from it. On breaking through the tegmen the tympanum was seen to be filled with a solid mass of granulation tissue, which could be picked out all in one piece with forceps. The long process of the incus was necrotic. The tympanic membrane appeared as if about to slough. There had been no otorrhœa during life.

It is easy to understand how vascular infection could follow from such a condition.

When the arachnoid is traversed the infection reaches the sub-arachnoid and the pia, and either a localised or a diffused inflammation results. Why the inflammation should in one case be limited to a small or even a minute area and in another should spread rapidly over the whole surface is not difficult to understand. The answer is that it depends on the nature and virulence of the infection, just as a local infection of the hand may end in a local abscess or start a cellulitis which spreads in twenty-four hours over the whole limb. The sub-arachnoid tissue may then, like the areolar tissue of the arm, be involved in either a local infection or in a rapidly spreading cellulitis.

Infection of Arachnoid and Pia Mater.

It has long been known that effusion of serum is one of the first effects of infective irritation of the pleura, the peritoneum, the joints, and the cellular tissue, but until the publication of Quincke's papers on lumbar puncture in 1891, and on meningitis serosa in 1893, it was scarcely appreciated that the phenomena within the skull were just the same, and the term meningitis was not considered applicable to any case in which purulent

44 SOME POINTS IN THE SURGERY

or at least sero-purulent effusion was not obviously present within the meninges.

Quite early, even before meningeal were distinguished from cerebral lesions, cases had been observed and recorded in which no gross intra-cranial lesion was found after death, though the symptoms had seemed to point conclusively to its presence. That great pioneer of cerebral pathology, Thomas Willis, 1645, in relating such a case, wrote: "Wherefore in this case no other explanation seems possible but that the vital spirits within the brain were put to flight, or, so to speak, extinguished by particles of a malignant or narcotic or otherwise noxious nature, so that the movement of the heart, like the main-spring of a clock, being arrested, all other functions, deprived of their source of energy, immediately and absolutely ceased."

Even now suppurative meningitis is looked upon as a mortal disease, and some special explanation has been sought of the recovery of some patients presenting apparently unequivocal evidence of this lesion, and of the absence of any appreciable lesion after death in other cases with quite similar symptoms; after the vague terms pseudo-meningitis and meningism had been used to designate such cases,

meningitis serosa was welcomed as a new fact in morbid anatomy affording an explanation of these clinical phenomena.

Even while still without the dura a focus of infection may determine an excess of fluid

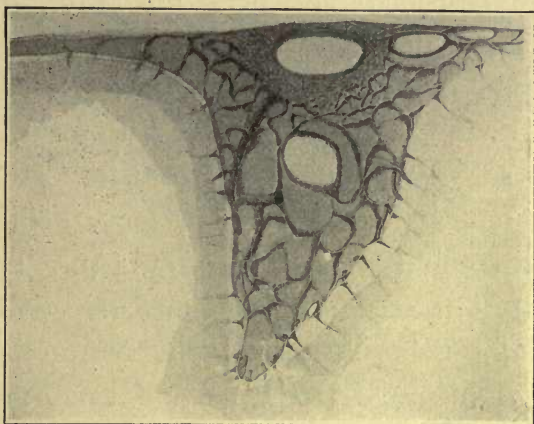


FIG. 24.—Sub-arachnoid space between the convolutions. (Key and Retzius.)

The sub-arachnoid space is here broken up into a number of channels, through which the cerebro-spinal fluid finds its way. At each systole the fluid in the ventricles is pumped into the spinal theca and into the great cisterns at the base of the brain. It escapes from the spinal theca along the sheaths of the nerves, and from the cisterna it passes upwards in the sub-arachnoid rivulets between the convolutions to reach the Pacchionian bodies and the superior longitudinal sinus.

within the skull, just as disease of a rib may excite serous effusion in the pleura, or disease of the tibia may bring about an effusion in the knee-joint.

I have had many opportunities of observing that clear fluid collects in the subdural cavity when the dura becomes inflamed by the presence external to it of pus. This is what we should

expect. Elsewhere, *e.g.* in the areolar tissue of a limb, an inflammatory focus is always surrounded by a zone of tissue tense and sodden with serum, and, indeed, before the pus becomes visible the site of the coming abscess is the site of serous effusion or œdema. The same sequence of events occurs in the cerebral meninges. In the subdural space, which is not divided into compartments, a pond of fluid will form, while in the sub-arachnoid space of the cortex the tissue, under normal circumstances being traversed by countless rivulets of fluid (like marshy ground), will become œdematous and swollen.

The following cases show the symptoms produced by meningeal effusion and the beneficial effect of lumbar puncture. Probably in some cases the removal of fluid under pressure from the intra-dural spaces will prevent the occurrence of suppurative meningitis :—

Case 1.—J. C., æt. 19, female.—Admitted with R. chronic otorrhœa and large mass of breaking-down glands on the right side of the neck.

The radical mastoid operation was done, and all the affected glands in the neck were removed. The glandular disease was tubercular.

The temperature for a few days was normal and the pulse quick. The condition of the patient then changed. The temperature rose, the pulse became slower, sickness occurred, and she lay in bed in an apathetic state, with eyes closed and mouth open.

Lumbar puncture was done, and with the withdrawal of 2 oz. of fluid all the symptoms disappeared. A few days later the whole group of serious symptoms returned, and were again relieved by lumbar puncture. In another week she was again in a serious condition, and, in addition to the other signs, there was now loss of the sense of smell and commencing optic neuritis. She was given chloroform, and an incision was made in the dura over the tegmen tympani, which had been removed at the first operation. This incision gave exit to pus and gas from a localised abscess in the arachnoid cavity. The patient made a good recovery.

Case 2.—A boy, aged twelve, at school, had a cold on a certain Friday; on Saturday and Sunday he complained of pain in both ears. On Monday evening I saw him. He was drowsy, temperature 104° , there was œdema over the left mastoid, both tympanic membranes were bulging. There was no discharge from either side.

The same evening the right drum was incised, and the operation for acute mastoid suppuration was done on the left side. The lateral sinus was exposed in this operation for 1 inch, part of which was of a pink colour and inflamed.

The next morning patient was little if at all better, and during the afternoon he was drowsy, complained of headache, was restless and was sick. The temperature was 102° , the pulse came down to 80, the pupils were somewhat dilated and reacted slowly, tenderness was manifest over the right mastoid, and the optic discs were pinker than normal. The same evening an operation was performed on the right mastoid of an exactly similar character to that which had been carried out on the left side; every cell of the pneumatic mastoid was full of pus, and the dura over the lateral

sinus and beyond was red. Lumbar puncture was now done, and 2 oz. of fluid under pressure were withdrawn. The next morning there was no headache, no sickness, no drowsiness, and the pupils reacted well. Convalescence was rapid, and on both sides practically perfect hearing was regained.

Effusion in the pleura or peritoneum gives

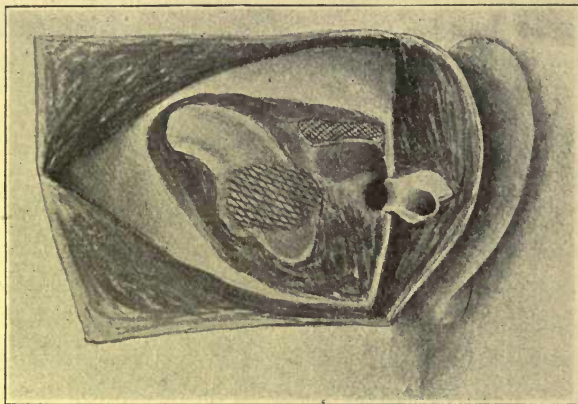


FIG. 25.—Sketch of complete mastoid operation.

In some acute cases the dura when exposed is found of a bright red colour. In the figure the shaded areas over the antrum and attic, and over the sigmoid sinus, indicate the usual sites of inflammation of the dura. (The complete mastoid operation is only very rarely required in acute cases; the figure of the complete mastoid operation is used because it shows clearly the region of the tegmen.) Meningitis serosa may be induced by the inflamed dura, and can be relieved by lumbar puncture.

rise to physical signs by which its presence can be detected quite independently of any symptoms it may cause. Within the skull we are almost entirely dependent upon symptoms for our diagnosis, and it may be helpful to consider what was accomplished and what was missed when the diagnosis of diseases of the chest was unassisted

OF THE CEREBRAL MEMBRANES

by the means of physical agents available.

Of late years our diagnosis of the brain and meninges has been much aided by the practice of lumbar puncture, which affords certain and valuable information regarding the nature of the fluid in the meningeal cavity. It does not afford equally certain evidence as to its amount and distribution. It must not be forgotten that there is no direct communication between the subdural and the arachnoid space; the fluid obtained by lumbar puncture may be derived from the subarachnoid space or from the other; and we cannot tell from which source it comes.

In the skull, as elsewhere, the disease may be arrested in the serous stage, or cerebral lesions may arise.

Inflammation of the pia mater is clinically nor anatomically distinguished from inflammation of the arachnoid, but it is usually subdural or the sub-arachnoid space is the exclusive or the chief seat of the inflammatory exudation, a fact not without importance in the treatment.

Diffuse suppuration in the subdural space is uncommon except as the result of disease of the brain by injury, but I have seen it occur in the absence of any cerebral lesion.

Certain varieties of meningitis have been described

Contains the material prepared for the Lettsomian Lectures of the Medical Society of London for 1906. Bellence (1856-1936) acquired Great merit in experimental and neurological surgery, especially in his operations of the brain

HALLAM, GEORGE A. Some Points in the Surgery of the Brain and Its Membranes. 8vo, orig. cloth. London, 1908. Illus.

by the means of physical examination now available.

Of late years our diagnosis of diseases of the brain and meninges has been much assisted by the practice of lumbar puncture. This gives us certain and valuable information respecting the nature of the fluid in the meningeal spaces, but does not afford equally certain evidence as to its amount and distribution. It should not be forgotten that there is no direct gross communication between the subdural and the sub-arachnoid space; the fluid obtained by lumbar puncture may be derived from the one or from the other, and we cannot tell from which.

In the skull, as elsewhere, the disease may be arrested in the serous stage, or other inflammatory lesions may arise.

Inflammation of the pia mater is neither clinically nor anatomically distinguishable from inflammation of the arachnoid, but either the subdural or the sub-arachnoid space may be the exclusive or the chief seat of the inflammatory exudation, a fact not without significance in the treatment.

Diffuse suppuration in the subdural cavity is uncommon except as the result of direct infection by injury, but I have seen it occur in influenza.

Certain varieties of pus seem to have but

E

little tendency to perforate serous membranes (such as the arachnoid or peritoneum) and but little irritant effect upon them. The pus may be spread out in a sheet of greater or less thickness over a certain limited area of the visceral arachnoid, though there may be no visible adhesions present which have checked its spread.

In a woman, age forty-nine years, the subject of chronic otorrhœa, who died after three weeks' acute illness, a thick layer of yellow pus covered the visceral arachnoid exactly over the left frontal and parietal lobes.

This is quite comparable to what not unfrequently occurs in the peritoneum and pleura. It sometimes happens that in peritonitis the exudation is apparently limited to a certain area, though there are no adhesions present, and that when the pus is wiped off the membrane underneath it looks unaltered.

The same appearance is sometimes noticed in pleurisy with pneumonia.

When pus slowly makes its way to a serous membrane adhesion of the two layers takes place, and if the infection proceeds further it traverses both layers without causing general infection of the cavity. In the pleura and peritoneum the serous surfaces are kept in constant lateral movement, and infective material is

rubbed over a considerable area before adhesions can take place.

In the arachnoid the mechanical conditions are different, there being no appreciable lateral movement. The two layers therefore can, and commonly do, become adherent before any considerable area is affected, hence any collection of pus between dura and pia is commonly quite small in amount.

When the infection has traversed both layers of the arachnoid the sub-arachnoid space and the pia are reached; either a localised or a diffused inflammation may result here, or, forming a mere track through the pia, the infection may pass on into the cerebral substance.

Varieties of Meningitis.

All intra-cranial affections, accompanied by delirium, were formerly confounded together under the name "phrenitis or phrenzy," and we doubtless now include under the term meningitis many affections which though attended in their terminal stages by inflammation of the meninges will, as our knowledge of cerebral surgery and pathology advances, nevertheless be shown to be quite distinct diseases, exactly as abdominal surgery has shown us that diffuse suppurative peritonitis is but a terminal stage in several distinct affec-

tions, most of which can be recognised and arrested before that dangerous stage is reached.

For the present the surgeon classifies meningitis as tubercular and non-tubercular; and recognises that in each variety the pathological effusion may be serous or suppurative, localised or diffused.

The anatomical distinction between tubercular and non-tubercular meningitis is quite clear, and the diagnosis can, moreover, be usually made clinically. The various forms of non-tubercular meningeal affection cannot be distinguished without bacteriological examination, though some points of difference both in the symptoms observed and in the lesions found have been noticed. Epidemic cerebro-spinal meningitis and the posterior basal meningitis of children, which are possibly the same disease, are the two forms best differentiated.

Symptoms and Diagnosis.

There is no one pathognomonic symptom of meningitis. The symptoms which arise are not the direct result of the meningeal lesion, but are largely due to the influence exercised by the inflamed meninges on the brain-substance beneath, the symptomatology being, as the French writers express it, a borrowed symptomatology.

Until quite recently we had to depend for

diagnosis upon symptoms alone, but within the last few years the practice of lumbar puncture has given us a valuable though indirect means of physical examination.

Though most, if not all, of the symptoms met with in cases of meningitis are also met with under other conditions, yet clinical experience has taught us that a particular grouping of certain symptoms is usually associated with manifest meningeal lesions.

In seeking to define the relation of symptoms to lesions, and to apportion to each symptom its exact diagnostic significance, we meet, as an initial difficulty, with the fact that on the one hand the symptoms are sometimes met with without demonstrable meningeal lesion, and on the other hand that gross meningeal lesions are sometimes found post-mortem which had been quite unsuspected during life.

Our present knowledge seems to show that the symptoms most directly referable to the meningeal inflammation are the three symptoms, headache, vomiting, and constipation.

These are regarded as the cardinal symptoms of meningitis; the headache is severe and persistent, the vomiting apparently purposeless and not accompanied by nausea, and the constipation obstinate, resisting purgatives, and neither

accompanied by abdominal distension nor associated with abdominal pain.

These three symptoms appear to depend mainly upon intra-cranial effusion, whereby the pressure relations are altered and the normal power of adjustment of the intra-cranial tension impaired, but in some degree also upon absorption of toxins.

Tension of fibrous tissues gives rise to pain. Incision of the dura is painful. The headache of meningitis is comparable to the eyeache of glaucoma; both are due to tension of a fibrous envelope enclosing a nervous tissue.

With these three cardinal symptoms are associated two other groups of symptoms:—

A. Symptoms, such as fever and impaired nutrition, resulting from general infection, and depending more upon the variety of the infection than upon the distribution or degree of the meningeal lesions.

B. Symptoms which are the clinical expression, not of the meningeal lesions, but of the irritation of the subjacent cortex. These vary with the nature, degree, and distribution of the meningeal lesions, and with the cortical irritability of the individual.

Most of the symptoms met with in cases of meningitis belong to this group. They are—

1. *Psychic symptoms.* — Irritability. Change of disposition.

2. *Motor symptoms.* — Convulsions. Kernig's sign. Exaggeration of reflexes.

3. *Sensory symptoms.*—Photophobia. Hyperæsthesia.

4. *Sympathetic vaso-motor disturbances.*—Tache cérébrale.

5. Finally symptoms due to *exhaustion and death of nerve cells.*—Paralyses. Anæsthesia. Coma.

This group of symptoms being, as I have already said, the clinical expression of irritation of the cerebral cortex, it is easy to understand that meningitis is by no means the only condition capable of so affecting the cerebral cortex as to give rise to them.

An actual lesion of the brain substance, the absorption of toxic substances circulating in the blood, and that still unexplained disturbance of innervation known as hysteria, may all give rise to symptoms more or less closely resembling those associated with meningitis. An absent knee-jerk, a Babinski reflex, or early changes in the optic disc would be pathognomonic of an intra-cranial inflammation in a case in which the delirium and fever might have led to the suspicion of typhoid fever.

The diagnosis between these various conditions

is sometimes difficult, and occasionally baffles even an attentive and experienced observer.

Examination of the cerebro-spinal fluid obtained by lumbar puncture affords information as to—

1. The intra-dural pressure.
2. The chemical composition of the fluid.
3. Certain physical properties, such as the freezing point.
4. The cells contained therein.
5. The bacteriology.
6. The permeability of the meninges to chemical substances introduced into the blood.

Of these the cytological examination is, at present at all events, the most important.¹

Normally, the cerebro-spinal fluid contains few or no cellular elements, but in inflammation of the meninges the cellular elements are abundant; either leucocytes or poly-nuclear plasma cells may predominate. The general indications are that leucocytosis points to a slow or subsiding inflammatory process, and abundance of poly-

¹ The ordinary method of counting the cells in the centrifuge deposit from the fluid can give at the best only an approximate idea. Dr. Purves Stewart has recently drawn attention to this, and has urged the value of Fuchs and Rosenthal's special counting-chamber, in which the uncentrifuged fluid is mixed with a portion of a staining reagent, and the number of cells per cubic millimetre is accurately counted. Dr. Purves Stewart believes that the absence of lymphocytosis excludes syphilis, tuberculosis, and other inflammatory conditions of the meninges: the converse, however, is not necessarily true. In neoplasms a lymphocytosis is exceedingly rare.

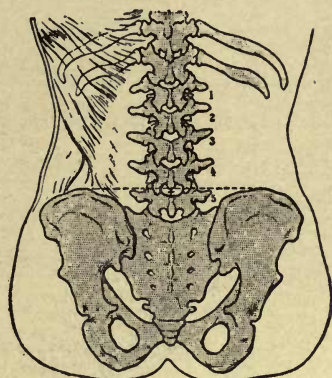


FIG. 26.—Lumbar puncture in the adult. (Tuffier.)

A line joining the highest part of the iliac crests bisects the space between the 4th and 5th lumbar vertebræ. This is the best guide in lumbar puncture. A fine hollow needle, 7 c.m. long, is required.

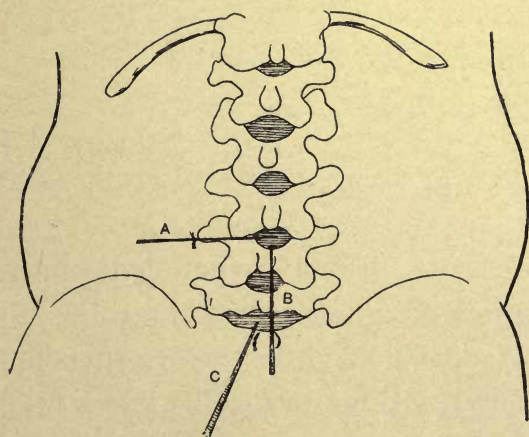


FIG. 27.—Lumbar puncture in the child. (Chipault.)

A. Method of Quincke. B. Method of Marfan. C. Method of Chipault.

The simplest plan seems to be to puncture between the 4th and 5th lumbar vertebræ. The space between these vertebræ corresponds to the highest part of the iliac crests. Chipault, however, maintains that the lumbo-sacral space is preferable since it is the largest, is surrounded by good landmarks, and is opposite the terminal enlargement of the dural sheath.

nuclear cells to an acute, active, and intense inflammation.

Systematic examination of the cerebro-spinal fluid obtained by lumbar puncture in a series of

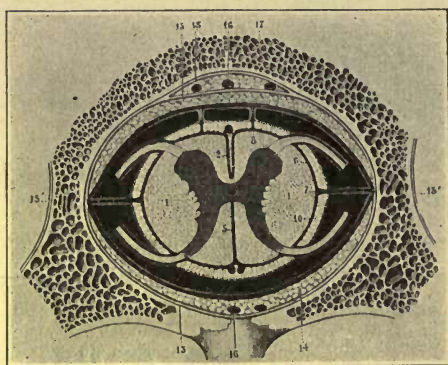


Fig. 28.

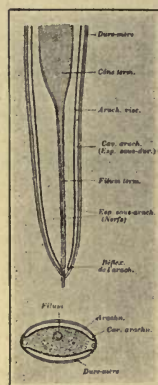


Fig. 29.

FIG. 28.—Arrangement of membranes around spinal cord. (Testut.)

The wide dark area is the subdural space. The light area around the cord is the sub-arachnoid space. In the spinal canal the subdural is normally an actual space; in the cranial cavity it is a potential space.

FIG. 29.—Arrangement of arachnoid in the region of the cauda equina. (Charpy.)

In lumbar puncture the sub-arachnoid cavity is usually tapped. The fluid, however, in meningitis serosa may occupy the subdural space. The arachnoid will then recede from the dura, these membranes being separated by an interval wider than normal. Thus in some cases fluid may be withdrawn by the needle from the subdural space.

cases of acute diseases, whether symptoms of meningitis were present or not, has shown that—

1. Modifications of the cerebro-spinal fluid and symptoms of meningitis may be present together.
2. There may be symptoms of meningitis without modification of the cerebro-spinal fluid; and
3. There may be modification of the cerebro-spinal fluid without symptoms of meningitis.

Therefore it seems that there is no necessary

and constant correlation between the symptoms commonly accepted as indicating meningitis, the lesions present, and the condition of the cerebro-spinal fluid.

Our knowledge of the pathological physiology of the symptoms is not yet sufficiently complete to enable us to satisfactorily explain these apparent discrepancies.

The diagnosis is then in most instances still a matter of ordinary clinical observation and judgment; we have to determine whether the patient's symptoms are due to meningitis or to some other condition, and if we decide upon meningitis, what is its variety and extent.

The conditions most frequently giving rise to symptoms closely resembling meningitis are hysteria, organic disease of the brain, and the meningeal irritation occurring in the course of certain acute specific diseases, notably pneumonia and enteric fever.

Hysteria sometimes finds expression in symptoms having some resemblance to those of meningitis, but a shrewd observer is not often deceived thereby; the disease indeed assumes the mask of meningitis, but it is a mask at once incomplete and exaggerated, some symptoms being wanting, others caricatured. Other signs of hysteria are present, and the general condition

of the patient does not correspond to the gravity of the symptoms.

It must never be forgotten that the neurotic temperament affords no protection against organic disease, and that the two conditions may co-exist.

The question of diagnosis between meningitis and organic disease of the brain itself chiefly arises when localisation symptoms are present. Though bearing a general resemblance to those of brain disease, these symptoms when due to meningitis are usually to be distinguished by being transient, irregular, and variable in their onset, by the outlined rather than complete, the less pure and more diffused character of their clinical expression, and by their acute or sub-acute evolution.

The meningeal symptoms due to acute specific diseases very closely resemble those of suppurative meningitis, but attention to the history and the evolution of the disease usually soon enables the diagnosis to be made. In such cases the suggestion has been made, and seems probable, that the symptoms are due to irritation of the brain by the specific toxins of the disease.

We are usually able to diagnose clinically (1) tuberculous meningitis, (2) non-tuberculous acute meningitis, (3) the posterior basal meningitis of infants.

In tuberculous meningitis the onset is in-

sidious, and the evolution sub-acute rather than acute ; a period of apparent remission divides the disease into the three stages so well described long years ago by Robert Whytt.

Non-tuberculous general suppurative meningitis has an acute onset and rapid course.

The posterior basal meningitis of infants begins as an acute disease, but is less rapid in its course than general suppurative meningitis, and retraction of the head is a very prominent sign.

Posterior basal meningitis is a disease of the first year of life. Tubercular meningitis is most common from the second to the seventh year (Méry and Armand Délille, 1905). While optic neuritis depends in some measure upon the site of the primary meningeal lesions, it may be affirmed to be, as a rule, a late sign in tuberculous meningitis and an early one in suppurative meningitis.¹ Tubercle of the choroid when seen is pathognomonic of tuberculous meningitis.

All forms of meningitis, if unrelieved by art, tend to cause death.

Recovery is, however, undoubtedly possible ; it has been inferred (1) from post-mortem evidence after death from other causes, (2) from

¹ Sir Thomas Barlow, in his article on tuberculous meningitis in Allbutt's *System of Medicine*, vol. vii., says: "With regard to optic neuritis, its indications in the early stage of the disease are often ambiguous ; but late in the disease it can be generally detected on both sides, though unequal in amount."

the fact of recovery after clinical symptoms of meningitis, and, lastly, from the recovery of patients with a local suppurative disease and marked symptoms of meningitis after an operation limited to the local disease.

We are, therefore, justified in saying that the meninges are not destitute of recuperative power, but, like the peritoneum, are quite capable of dealing with a certain amount of infective material, if the further supply is cut off.

Treatment.

Paracelsus (circa 1490-1541) held that "Nature was sufficient for the cure of most diseases; art had only to interfere when the internal physician, the man himself, was tired or incapable. Then some remedy had to be introduced which should be antagonistic, not to the disease in a physical sense, but to the spiritual seed of the disease." These remedies were termed "arcana."

Antitoxins, and substances that appear to raise the resisting power of the individual to certain infective processes, are remedies fulfilling in some degree the ideal of Paracelsus; but such remedies have, for most diseases, still to be found.

By removing a focus of disease, or by giving free exit to infective products, surgery—though

essentially a remedy "opposed to disease in a physical sense"—has afforded us the means of arresting many infective diseases which otherwise must destroy life; and we must now consider whether surgical intervention can help us in treating meningitis, for we have no other remedy.

From this point of view we may divide cases of meningitis into two great groups—(1) those due to extension of a local infective process, and (2) those due to a general infection carried by the blood stream.

In the first group it may at once be said that the main surgical indication is the removal of the local disease, and this surely should have been carried out before the meningitis had arisen.

The importance of effectively dealing with temporal bone suppuration is now fairly well known, and the operation for its relief has slowly become appreciated, though retrograde papers on the subject continue to appear; but in this country the radical treatment of frontal and ethmoidal suppurative disease is not always thoroughly carried out. Even acute cases are sometimes left till the patient has developed meningitis, while in chronic cases the danger of the disease is not recognised, and it is therefore apt to be left unremoved.

Chronic suppuration in the accessory cavities

64 SOME POINTS IN THE SURGERY

of the nose is exactly comparable to temporal bone suppuration, and like it should be treated

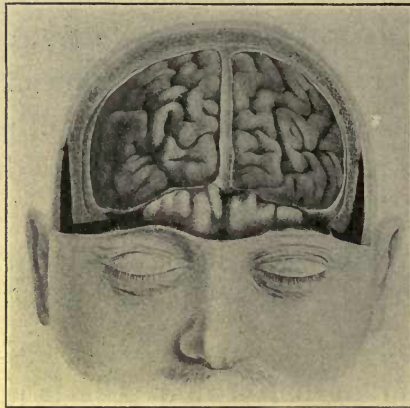


FIG. 30.—The relation of the frontal sinuses to the frontal lobes. (Killian.)

The frontal sinus is opposite the base of the corresponding first or upper frontal convolution. In a large sinus the temporal recess may extend as far as the second or middle frontal convolution. An abscess of the brain arising from disease of the frontal sinuses is, as a rule, located in the anterior inferior part of the superior frontal gyrus.

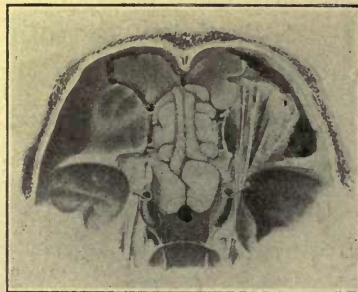


FIG. 31.—The relation of the accessory sinuses to the base of the skull ; viewed from the cranial cavity. (Killian.)

The frontal, ethmoidal, and sphenoidal sinuses are exposed. With the exception of the posterior two-thirds of the sphenoidal sinuses, all the accessory sinuses abutting on the cranial cavity lie in the region of the anterior cranial fossæ.

strictly in accordance with the ordinary surgical principles applicable to the treatment of

diseased bone wherever situated—namely, complete ablation.

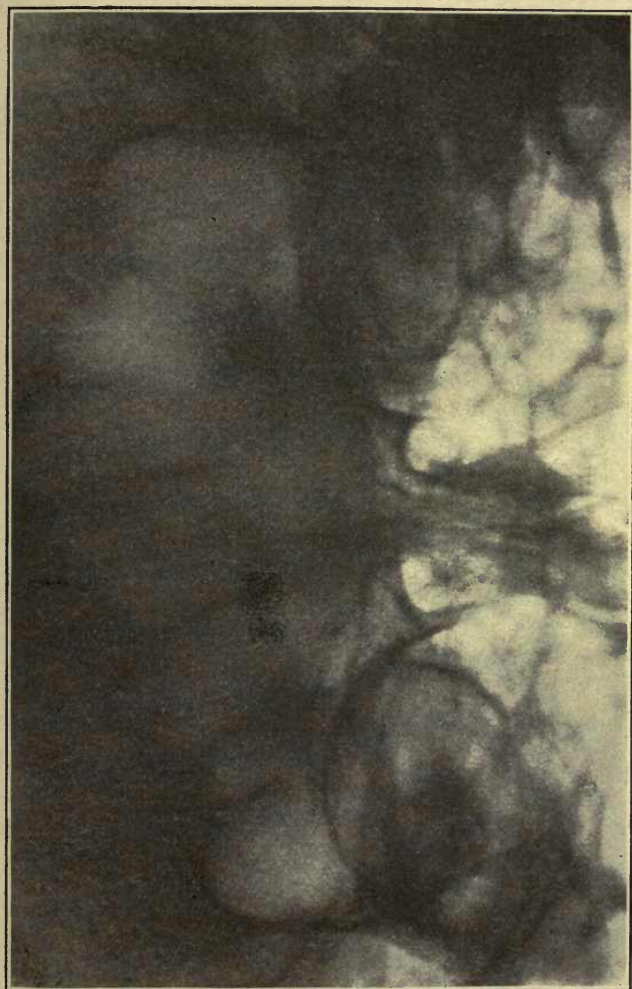


FIG. 32.—Radiogram of large frontal sinuses. (Prof. Goldmann of Freiburg.)
By this method the surgeon before operating is able to learn the extent and outline of the frontal sinuses.

Acute frontal sinus suppuration, and especially acute necrosis of the frontal bone, is, if possible,

F

66 SOME POINTS IN THE SURGERY

even more dangerous to life than acute temporal bone suppuration ; urgent symptoms rapidly

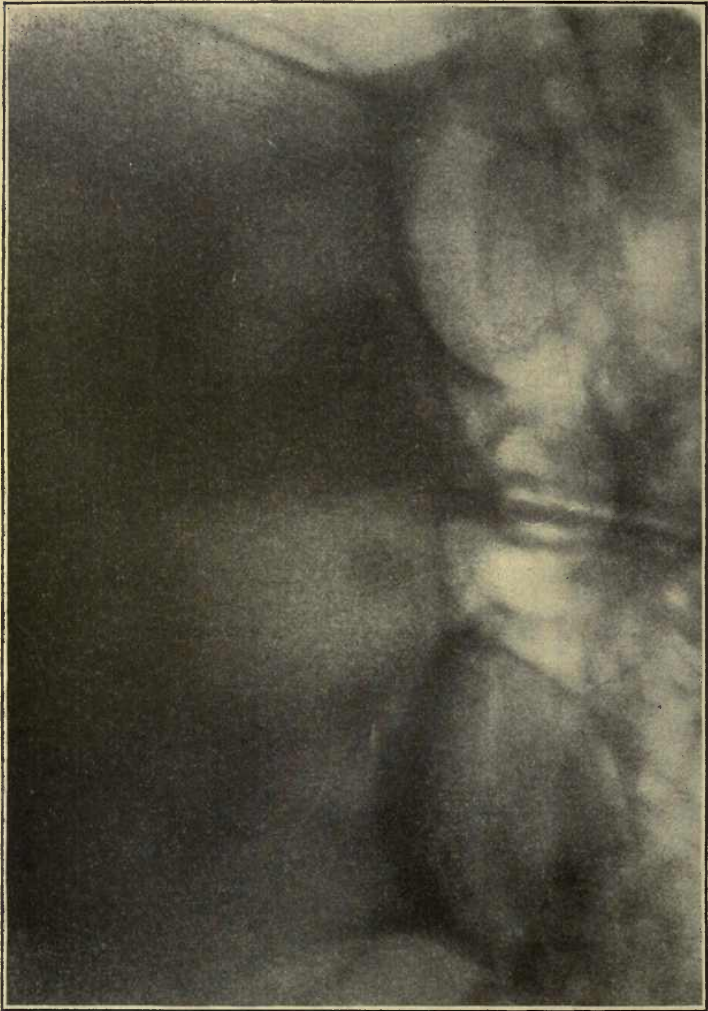


FIG. 33.—Radiogram of suppurative disease (granulation, polypi, and pus) in the left frontal sinus.
(Prof. Goldmann of Freiburg.)

develop, and operation is imperative. I was recently called in consultation to such a case, in

OF THE CEREBRAL MEMBRANES 67

which the patient's life was saved by immediate operation.

The intra-meatal aural specialist of a past

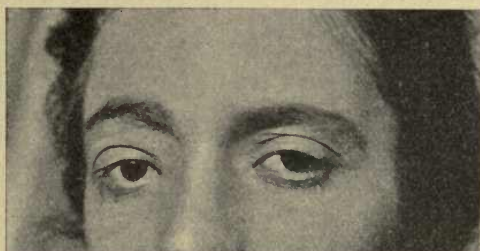

FIG. 34.—Result six weeks after the Killian operation for frontal sinus suppuration.

Miss D., age 27 years. When seen the right frontal sinus was obviously enlarged; it extended upwards on the forehead for some distance and outwards, with diminishing vertical extent, as far as the external angular process. A streak of pus could be seen in the middle meatus. The antrum of Highmore was translucent, but the right frontal sinus was absolutely opaque to transmitted light.

Three years previously she had been struck in the right frontal region, and for two years had had constant aching in that situation and discharge, usually watery and without odour, from the right nostril.

Operation.—The usual vertical incision was made, with another running along the orbital margin of the eyebrow instead of along the line of the hair, where it subsequently causes an unsightly mark. The outer table of the skull was raised up with the forehead flap (Durante's osteoplastic flap). The sinus was full of granulation polypi and pus, and on displacing the tendon of the superior oblique and removing the roof of the orbit, the same condition was found in the ethmoidal cells and in the sphenoidal sinus. The disease was entirely ablated, and the various cavities were thrown into one by removing the bony partitions between them; this was swabbed out with chloride of zinc solution (40 grs. to 1 oz.). The middle turbinated bone was removed. The skin edges were then accurately sutured, and drainage provided for through the right nostril. Convalescence was rapid and complete. The patient complained of diplopia for two weeks.

Even at Freiburg patients do not escape without a slight depression in the forehead after the Killian operation by the master himself. To obviate this I made use of Durante's osteoplastic flap. This, of course, cannot be employed unless the operator can ensure complete eradication of the disease. Making the horizontal incision below, instead of through the hair of the eyebrow is, I think, also a great improvement. The œdema of the right upper eyelid had not quite subsided when the photograph was taken. The vertical incision can just be seen in the full-sized photograph. There is *no* flattening over the operated sinus.

generation was content to flit helplessly about his chosen canal in the manifest presence of lethal complications. Is it or is it not true that the intra-nasal specialist of the present day, with

some brilliant exceptions, may at times be unduly influenced by the traditions of his otological kinsmen instead of following the teaching of Killian and facing the operation for the complete removal of the disease ?

Operation for the cure of frontal and ethmoidal suppuration is now regarded in this country much in the same way as was the mastoid operation twenty years ago ; hence the fatal frontal sinus cases so surprisingly frankly reported from time to time in our medical journals, as if the disease was inevitably mortal, and as if the lesson that danger attends delay and imperfect operation had yet to be learnt.

When the opportunity for a preventive operation has gone by, and meningitis has resulted from a local cranial lesion, the chances of recovery are naturally much lessened, but even then surgery is not helpless. Many cases are recorded in which recovery has followed the removal of the local disease by an operation not opening the dura, even though symptoms of meningitis were already present.

The following is an instance of such a case:—

In April 1901 I saw with Mr. Tyrrell a boy, aged nine years, who had just returned from Paris.

There was a clear history of tubercle in his family.

Three years previously tubercular glands had been removed from both sides of his neck. A slight watery discharge from the right ear had been noticed a year before the operation on the neck, and had continued without intermission.

Six weeks before I saw the patient he had complained of pain in the head on running. During the two preceding weeks he had had severe pain in the head at intervals, with vomiting. Squint of the right eye had been noticed for a week.

When seen he complained of constant pain in the head with exacerbations. The temperature was 99° F.; the tongue was furred. There was a slight watery discharge from the right tympanum coming through a large perforation in the anterior part of the membrane. The right external rectus was paralysed. No optic neuritis.

Complete mastoid operation forthwith. The dura covering the tegmen and a considerable area of the dura of the posterior fossa, including the sinus wall, was granulating. The mastoid, except the outer shell, was destroyed by granulation tissue, which was found by Mr. Shattock to be tubercular. The

granulating dura was painted with absolute phenol.

The patient made a complete recovery. In a week the headache had ceased, and in three and a half months the sixth nerve had recovered its functional activity.

This case also illustrates the futility of removing tubercular glands of the neck and leaving mastoid disease untouched.

In such cases there must always be some doubt whether anything more than serous effusion had occurred within the dura.

When cerebral symptoms persist after the removal of local disease of the cranium the dura should be opened by an extension of the local operation, and further procedure guided by the condition found.

We have now to consider what should be done when meningitis has occurred otherwise than as a complication of some local cranial lesion.

Tuberculous Meningitis.

So fatal is this disease that even the bare possibility of recovery without permanent damage to the brain has been doubted.

It is true that certain cases have been reported as recoveries, but of these some may well have

been localised cerebral tubercle, and in others the observer may have been deceived by a toxæmic meningitis.

The results of opening the abdomen in tuberculous peritonitis have led to the hope that something would be accomplished by opening the skull in cases of tuberculous meningitis, but the few efforts that have been made in that direction have afforded but little encouragement.

Must we accept the results hitherto obtained as final, and conclude that no benefit is to be derived from intervention in these cases? Before accepting defeat we should consider whether the measures hitherto adopted are those most likely to prove successful.

In operating for tuberculous peritonitis we neither remove the disease nor the source of infection, and it is by no means clear in what way the modification in the evolution of the disease is brought about, but it certainly seems that exposure of the disease and drainage of the inflammatory exudation must be the main factors. The operation is simple and easy of execution.

A problem of much greater complexity confronts the surgeon who seeks to deal with tuberculous meningitis in the same way. To obtain direct access to the disease and to drain the morbid exudation it would be necessary to

72 SOME POINTS IN THE SURGERY

expose and open the Sylvian lake, and also to tap the ventricles, for the tubercular disease lies in the sub-arachnoid space, mostly in the Sylvian fissure, and in the choroid plexus of the ventricles. Irrigation of the ventricles and sub-arachnoid space would be equally necessary, and these cavities cannot be irrigated the one from the other.

Chipault in 1895 suggested that instead of

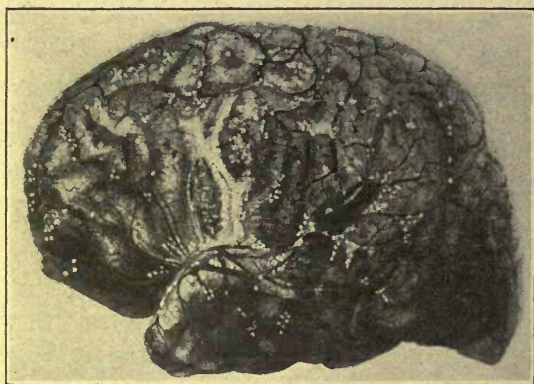


FIG. 35.—Miliary tuberculosis of pia covering the convexity of the brain. (Lebert.)

merely opening the arachnoid, the Sylvian lake on each side should be opened. Writing again in 1904 he says that though several surgeons have accepted his views there is as yet no practical confirmation of the value of the suggestion.

Some of the operations hitherto performed have, however, been limited to opening the subdural space; consequently direct access to the disease and direct drainage have not been obtained;

the sub-arachnoid space, where the disease lies, being left untouched. This procedure is merely opening a neighbouring cavity: opening the pleura could have little influence on disease in the pericardium.

Until more complete operations have been performed in an earlier stage of the disease we cannot say whether tuberculous meningitis is likely to be modified in the same favourable manner by operation as is tuberculous peritonitis.

General Suppurative Meningitis.

The indications for treatment are to suppress the source of infection, to give free exit to the suppurative exudation and to combat the disease with the appropriate anti-toxin.

Some remarkable and encouraging results of surgical intervention in this desperate disease have been already published. Kümmel relates the following case:—

A man, aged thirty-three years, fell, striking his occiput; for two days he felt pretty well, then had gradually increasing headache, especially occipital, and vertigo, together with tinnitus and deafness in the right ear. There had been a watery discharge from the nose the day after the accident. On the sixth day he was admitted to hospital as the symptoms had increased in severity. He was then still able to walk; he complained of frontal and occipital headache. No paralysis nor

74 SOME POINTS IN THE SURGERY

eye-changes were observed. There was right-sided deafness, but no visible lesion of tympanic membrane. Cerebro-spinal fluid was discharged through the nose. On the third day after admission he became torpid, and his temperature rose to 104; next day there was complete unconsciousness, with marked rigidity of neck and squint. Lumbar puncture let out 20 cc. of purulent

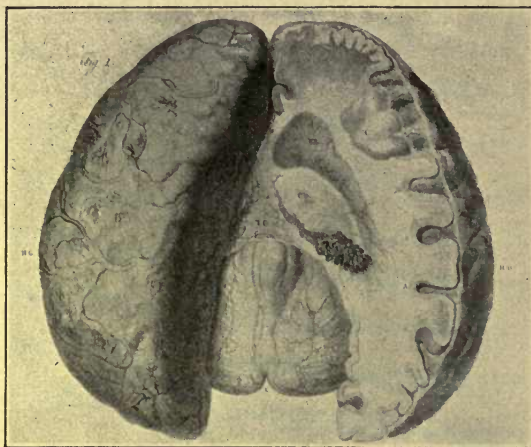


FIG. 36.—General suppurative meningitis. (Cruveilhier.)

In the original beautiful drawing greenish pus is seen everywhere beneath the arachnoid; in the sulci, and over the middle part of the upper surface of the cerebellum.

The stream of fluid passing upwards from the cisternæ at the base through the sulci of the convexity to the Pacchionian bodies explains the rapidity with which pus spreads over the convexity in cases of fulminating meningitis. To relieve this condition drainage of the sub-arachnoid space is necessary.

fluid under pressure of 235 mm. Hg. Profoundly unconscious all the day, the lumbar puncture gave no relief; urine passed under him. Following day (fifth after admission) apparently moribund.

Operation as a forlorn hope. Opening made in the bone as large as a five-shilling piece on each side of the middle line low down in occipital region. Dura under pressure. Dura excised over whole extent of

bone opening. Arachnoid deeply congested, only a small quantity of sero-purulent fluid escaped. Large plugs of gauze inserted in openings as deeply as possible into the posterior fossa, skin flap sutured, after providing for drainage. The patient gradually improved, and in six weeks was discharged well.

Hinsberg refers to this and other cases in a paper published last year. It is probable that in this case the sub-arachnoid space was opened, but it is not clear from the description given that this was done as a deliberate measure. Hinsberg says that up to the present at least ten cases of recovery from meningitis after drainage of the sub-arachnoid space are known, and five in which marked improvement occurred.

Suppurative meningitis may, as we have seen, chiefly or wholly affect either the subdural or the sub-arachnoid cavity. When on opening the subdural space we meet with a sheet of pus we have no ready means of ascertaining how far it extends, and it is difficult or impossible to remove the pus by irrigating from one opening to another.

Continuous irrigation is conceivable, but cleansing by wiping is impossible, unless bone is removed to the full extent of the pus sheet.

In general suppurative meningitis the operation affording the best chance of success is one

which provides a free bi-lateral opening, and allows the escape of pus from the sub-arachnoid space. It has been moreover rightly suggested that the spinal theca should be opened in the lumbar region so as to permit irrigation from the cranial to the spinal cavity.

Posterior Basal Meningitis of Infants.

The main surgical indication is the relief of the internal hydrocephalus, which is apt early to arise from the effusion blocking the foramina through which the cerebro-spinal fluid escapes from the ventricles.

We have various methods for the surgical treatment of hydrocephalus, and of these I have had considerable experience at the Hospital for Sick Children, Great Ormond Street.

1. *The Parkin operation* I carried out many years ago in several cases under the care of Dr. Lees and Sir Thomas Barlow. In this operation an opening is made in the occipital bone, and through it the pia-matral expansion over the back of the fourth ventricle is broken through. We found it a very severe operation in infants, and it moreover fails if the Sylvian aqueduct is blocked. These operations mostly occurred in the Winter, and we kept the infants alive

after operation by placing them in an incubator. In only one case was the child cured, and in this one the ventricles were tapped also

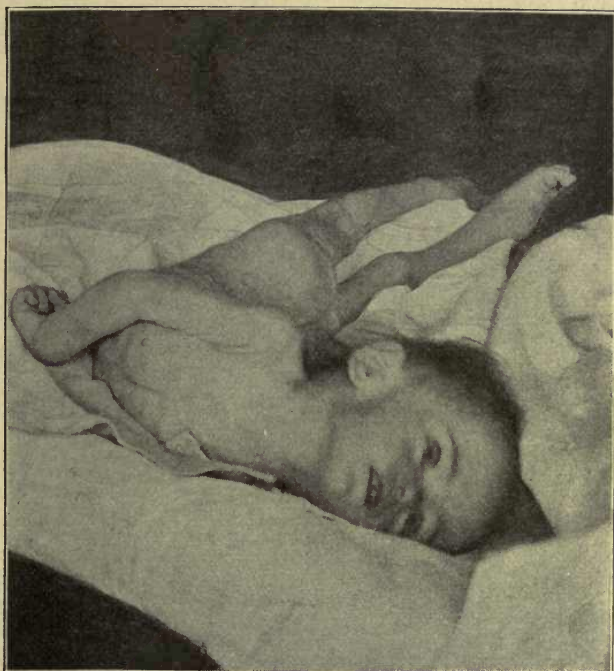


FIG. 37.—Posterior basal meningitis. (Lees and Barlow.)

Head retraction, marked opisthotonus, rigid extension of limbs. In some cases there is no opisthotonus, and there is flexor spasm of limbs. The head retraction is the characteristic sign. It is seldom so marked in tuberculous meningitis.

Child's age at onset, 16 months. Ill 13 weeks. The 4th ventricle was dilated. The iter and the foramen of Monro were obliterated. The hydrostatic system of the brain and cord was partitioned by adhesions into four sections: the right lateral ventricle, left lateral ventricle, 3rd ventricle, and 4th ventricle, and sub-arachnoid space of cord.

The left ear contained semipurulent fluid.

through the anterior fontanelle. Unfortunately, a few months afterwards the child was re-admitted to the hospital with diphtheria and died.

78 SOME POINTS IN THE SURGERY

2. *Successive tappings* of the ventricles may give some relief.
3. *Lumbar puncture* often fails to drain the

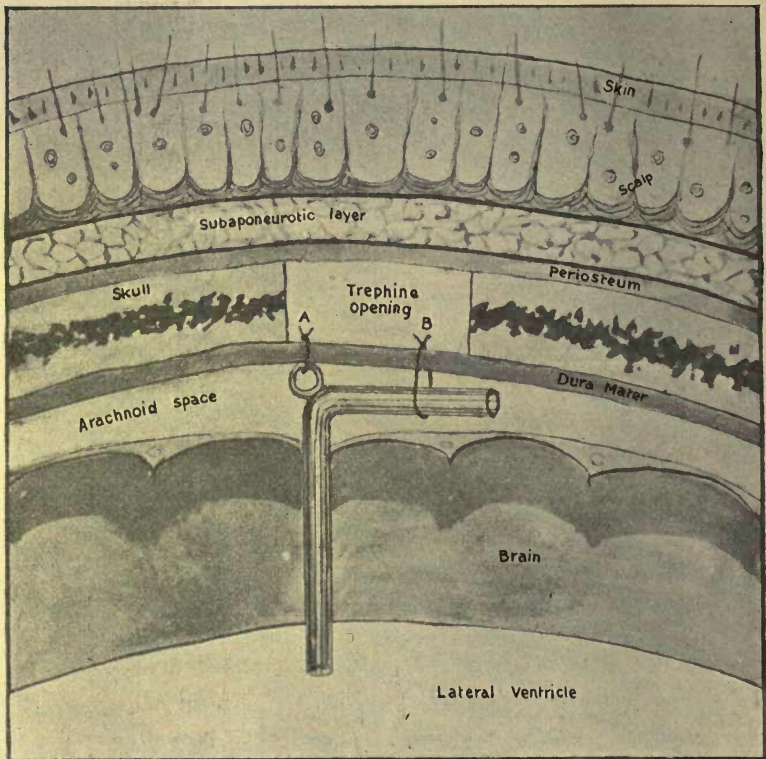


FIG. 38.—Diagram of subdural drainage by an angular metal tube.

The tube is sutured to the dura. The second loose suture prevents the displacement of the tube if the cortex sinks away from the dura. Occasionally the amount of fluid will be in excess of that which can be absorbed by the Pacchionian bodies. The internal hydrocephalus then becomes an external hydrocephalus, and the head may continue to enlarge.

The tube employed is much smaller than that shown in the figure.

ventricles of hydrocephalic infants, as the foramina of Majendie and Luschka may be congenitally absent or blocked by antenatal

meningitis or adhesion of the cerebellum to the medulla : the Sylvian aqueduct may also be blocked.

4. *Intra-dural drainage*, suggested by Cheyne and Sutherland, succeeds if the fluid is not too rapidly secreted to be drained off by the Pacchionian bodies, otherwise it only converts an internal into an external hydrocephalus ; a fact which I have several times observed. The plan of drainage can be carried out through the lateral angle of the anterior fontanelle, or the descending cornu of the lateral ventricle on the right side may be opened by the ingenious method of Keen. A fine tube bent at a right angle, made of gold and iridium, or of platinum, should be used.

Cases of successful treatment of hydrocephalus interna by intra-dural drainage :—

(a) *Posterior Basal Meningitis and Hydrocephalus.*

Male, aged three and a half, acute illness with pyrexia, head retraction, and right otorrhœa, followed by a stage of irritability, vomiting, rigidity of limbs, and emaciation.

Six weeks after admission to Great Ormond Street, intra-dural drainage was carried out by passing a number of silk threads through a fine opening in the cortex. Ten days later silk threads were replaced by a fine india-

rubber tube. A fortnight after second operation child knew his mother and spoke to her. The tube was left *in situ* for two months and then removed. The child left the hospital well but quite deaf. *Seven years later* (at age of ten and a half) child happy and healthy at a deaf and dumb school, making progress at the lip language. Like other children, but perhaps more tendency to fall when running about.

(b) *Congenital Hydrocephalus.*

Child, aged ten months, admitted to Great Ormond Street in December 1903. The head had been increasing in size for three or four months. The circumferential measurement is 23 inches. The eyeballs are depressed, and there is some lateral nystagmus and occasional vomiting. The child is emaciated.

January 1904.—A fine angular platinum tube was passed through the cortex into the descending cornu of the lateral ventricle on the right side.

June 1904.—Quite well; beginning to talk. Mind, sight, hearing, and speech normal.

January 1906.—Child quite well. Head looks large; measures 21 inches in circumference. It is so heavy that the infant has much difficulty in moving it.

5. The secretion of fluid may be lessened by ligature of one or both common carotid arteries. This can be safely done in hydrocephalic children, in whom the blood-supply to the brain

stem is of much more relative importance than that to the cerebral substance and the choroid plexus.

Congenital hydrocephalus treated by ligation of both common carotid arteries :—

George C., aged eleven months, was admitted to my ward in the Hospital for Sick Children, Great Ormond

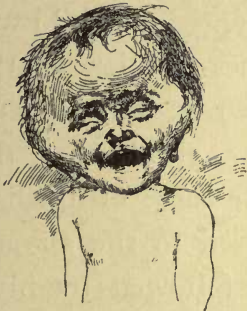

FIG. 39.—Congenital hydrocephalus in an infant of 6 months. (D. Schwartz, *Cackovic's article in Chipault.*)

Child aged 16 months. A litre and a half of cerebro-spinal fluid was withdrawn through the anterior fontanelle. Head reduced in size, and eyes more freely moved. Ultimate result not known.

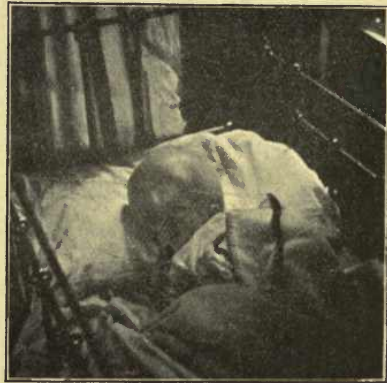

FIG. 40.—Congenital hydrocephalus treated by ligation of both common carotid arteries.

Street, on October 21st, 1905. The head had been enlarging since the age of three months. Circumference now $23\frac{3}{4}$ inches, intermeatal measurement 17 inches. Eyeballs depressed, lateral nystagmus, temperature 90° to 100° , occasional vomiting, emaciation. Anterior fontanelle very prominent and tense.

October 28th.—Right common carotid tied. One ounce of cerebro-spinal fluid drawn off through the lateral angle of the anterior fontanelle by a fine-trocar and cannula to relieve tension.

G

November 4th.—Left common carotid tied. The pulse became very weak, but the respiration continued. The child gradually recovered, but I thought it well to withdraw a little cerebro-spinal fluid from the anterior fontanelle early in December. About the middle of January the child left the hospital apparently quite well, and with no abnormal pressure of the fontanelle.

I have treated another case of congenital hydrocephalus in the same way. The child was under the care of Dr. James Collier of the National Hospital, Queen Square. This patient, however, died, but I do not think that the ligation of the carotids was the cause of death—one of the wounds was exposed to the air and became septic and this was followed by high temperatures.

Dr. Hildesheim has recently published an admirable paper on posterior basal meningitis. He refers to the occurrence of the disease after the first and second years of life, and points out that many cases of apparently acute hydrocephalus in adults and older children are really exacerbations of a chronic condition.

About fifteen years ago a man, twenty-six years of age, came to see me from Yorkshire. Both nostrils were full of mucous polypi. A mass of these growths projected from the posterior nares on to the soft palate. The patient answered

my questions clearly, but the father, a farmer, said that his son was not mentally capable of supervising any work on the farm. The polypi were removed by Banks' method. The operation was easy—one application of the forceps on each side brought away the polypus mass. The bleeding was not excessive. All went well till the third day, when the temperature rose to 103° F.; vomiting and delirium set in, and three days later death ensued. With some difficulty an autopsy was obtained. All that we found was chronic hydrocephalus. The foramina in the roof of the fourth ventricle were blocked by old basal meningitis. There was no recent meningitis and no injury to the roof of the nasal cavity. I then saw the parents and asked them if they could recollect any illness their son had during the first year of life. To my surprise and interest they told me that their son had had a severe illness before he was a year old, lasting some months. The head increased in size, and was retracted so as to touch the back—vomiting was frequent and his life was despaired of. Gradually the symptoms had abated, but had left considerable impairment of mental power during school time and after-life.

Conclusion.

Our predecessors, in dealing with acute head infections, applied vigorously those measures which they believed to be of service in treating similar affections in other parts of the body.

We have abandoned the venesection and severe purgation employed by our forefathers as remedies for acute infective disease. In parts of the body other than the cranium we have replaced them by appropriate surgical measures, but in the treatment of intra-cranial infections we have replaced the vigorous if inappropriate measures of our predecessors by an equally inappropriate inertia.

Hinsberg, in the concluding paragraph of his paper on the subject, says:—"It can no longer be doubted that in some cases of suppurative meningitis recovery may be brought about by active intervention. We are as yet quite unable to say how large a fraction this may prove to be. Personally I am not sanguine that it will be a large one, for the difficulties I have mentioned as attending the diagnosis and localisation and the dangers of the after-treatment are still so great that a quite special concatenation of favourable circumstances is necessary for them all to be overcome."

Twenty-five years ago acute abdominal in-

fections from the appendix, the bile ducts, and the Fallopian tubes, ruptured tubal gestation, and intestinal obstruction were almost as fatal as the acute infections of the meninges; to-day these abdominal affections are treated surgically with considerable success, not only by those of exceptional ability and opportunities, but as a matter of ordinary practice.

I am convinced that our treatment of intracranial infection has been too long encrusted in conventionality, and that "we are no longer justified in regarding such cases as hopelessly lost, and in remaining with folded hands, the rather must we attempt to save them by doing the utmost within our power."

REFERENCES. LECTURE I.

- LETTSON. Biographical notes, chiefly obtained from Life and Letters of Dr. Lettson, by T. J. Pettigrew.
- KEY and RETZIUS. Studien in der Anatomie des Nerven-Systems und des Bindegewebes. Stockholm, 1875.
- CHARPY. *Traité d'Anatomie Humaine*. Poirier and Charpy.
- LEONARD HILL. The Physiology and Pathology of the Cerebral Circulation. London, 1896.
- LEES and BARLOW. Simple Meningitis of Children. In Allbutt's System of Medicine, vol. vii.
- IMBERT. In *Traité élémentaire de Physique médicale*. Wundt-Monoyer. Second French edition.
- SIR THOS. WATSON. Lectures on the Principles and Practice of Physic. London, 1871.
- MOTT. British Medical Journal, 1904.
- AORTA OF TURTLE. Specimen No. 863c, Physiological Series, Royal College of Surgeons' Museum.

86 SOME POINTS IN THE SURGERY

- TAYLOR and BALLANCE. Removal of Arachnoid Cyst. *Lancet*, August 29th, 1903.
- RICHARD BRIGHT. Reports of Medical Cases.
- BIROULA. Société de Psychiatrie de S. Petersburg. Reported in *Revue Neurologique*, 1897, p. 206.
- PRESCOTT HEWITT. In *Holmes' System of Surgery*, vol. i., third edition, 1893, and *Med.-Chir. Trans.* vol. xxviii.
- ABERCROMBIE. *Pathological and Practical Researches on Diseases of the Brain and Spinal Cord*, 1828.
- CUSHING. *American Journal of Medical Sciences*, October 1905.
- GODLEE. *Pathological Society's Transactions*, vol. xxxvi. 1885.
- SIR THOS. SMITH. *St. Bartholomew's Hospital Reports*, 1884.
- GOLDING BIRD. *Guy's Hospital Reports*, 1889.
- BALLANCE. In *Chipault. L'État actuel de la Chirurgie Nerveuse*, vol. ii. 1903.
- BERGMANN. *Die Chirurgische Behandlung von Hirnkrankheiten*.
- QUINCKE. *Verhand. des X^{te} Congress für innere Medizin*, 1891, p. 322, and *Volkman's Klinische Vorträge. Neue Folge*, No. 67.
- THOS. WILLIS. *De Anima Brutorum. Part 2*, p. 276.
- ERNEST DUPRÉ. In *Traité des Maladies de l'Enfance. Grancher-Comby (symptoms of meningitis)*.
- GEORGES GUINON. In *Traité de Médecine. Charcot-Bouchard-Brissaud (for information afforded by lumbar puncture)*.
- ROBERT WHYTT. *Observations on the Dropsy of the Brain*, 1768.
- MÉRY and ARMAND DÉLILLE. In *Traité des Maladies de l'Enfance. Grancher-Comby*.
- PARACELsus. Quoted from Dr. Payne's Article on the History of Medicine in *Encyclopædia Britannica*.
- CHIPAULT. *Traité de Chirurgie opératoire du Système Nerveux and l'État Actuel de la Chirurgie Nerveuse*.
- KÜMMEL. *Archiv. für klinische Chirurgie*, vol. lxxvii. p. 930.
- HINSBERG. *Zeitschrift für Ohrenheilkunde*, vol. xxxviii. p. 126, and vol. l. p. 261.
- PARKIN. *The Lancet*, 1893.
- CHEYNE and SUTHERLAND. *Clinical Society's Transactions*, 1898.
- KEEN. *Medical News*, 1888.
- HILDESHEIM. *Dissertation of the Degree of M.D., Oxon. See also Practitioner*, 1905.
- PURVES STEWART. *The Clinical Significance of the Cerebro-Spinal Fluid. Edin. Med. Journal*, 1906.

*Case of Subdural Hæmorrhage in Cerebellar Fossa treated
by Operation.*

Miss C., age 50 years, single, art mistress. Seen in September 1906 by Dr. Charles Green and Dr. Purves Stewart. Twenty years previously she had a severe shock accompanied by grave physical injury, owing to the collapse of a wall beside which she was standing. The neck of the left femur was fractured, and she certainly sustained some superficial injuries to the head, but it is not clear from the history whether she had a fractured skull or not.

She made a good recovery from the accident, but with considerable shortening of the limb and some general nervous disturbance. For about a twelvemonth before she came under my observation she had felt giddy from time to time, and also had had pain in the back of the head, extending down the neck. Both the vertigo and the pain were increasing in severity. There was some tenderness on deep pressure in the left occipital region, but no deformity of skull. The hearing was slightly impaired on the left side. With this exception, there was no affection of any cranial nerve. There was no ear disease. The edges of both discs were indistinct, but no swelling nor hæmorrhages could be seen. Sensation normal, no loss of power in any limb; gait normal, except in so far as it was embarrassed by the deformity of the left lower limb. Left patellar reflex rather more brisk than right. Patient was of fair complexion, thin, and in poor general health. She was sent to a seaside nursing home for a month, took iodide of potassium with bromide, and was massaged daily. Her general con-

88 SOME POINTS IN THE SURGERY

dition improved a little, but the symptoms were in no way relieved. When she returned there was decided optic neuritis, with a swelling measuring 2 D. No other fresh symptoms were detected.

Localised tenderness, persistent pain, vertigo, and increasing optic neuritis led me to advise operation.

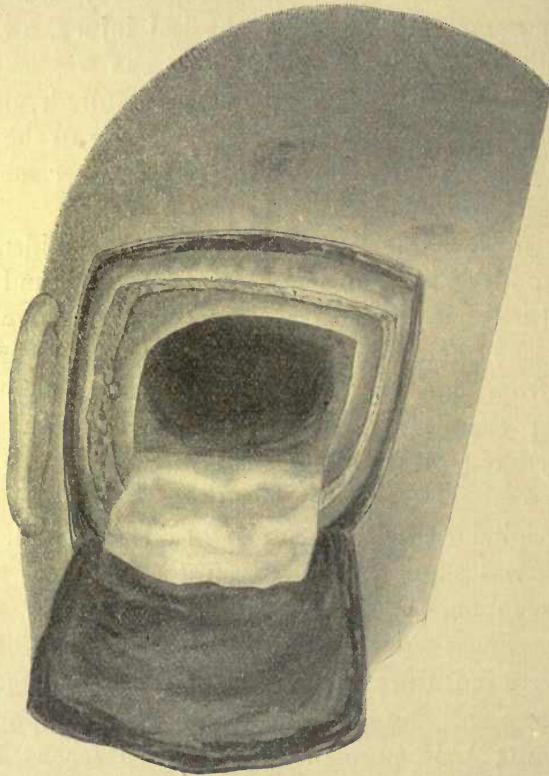


FIG. 40a.—Sketch of arachnoid hæmatocele in cerebellar fossa. Case of Miss C.

On November 11, 1906, the bone was removed from the left cerebellar region. It was thick and dense, but no evidence of fracture was observed. The dura was under moderate tension. A flap was

cut and thrown down forthwith, exposing the surface of the cerebellum, on which was seen a soft brown mass, apparently the remains of old blood extravasation and false membranes. This was picked off with forceps. No other tumour was discovered outside or inside the cerebellum. An incision was made into the cerebellar hemisphere, but nothing abnormal was detected thereby. The shock attending the operation was severe, but the patient soon rallied, and the wound healed readily, except the upper posterior angle, through which cerebro-spinal fluid discharged in considerable quantity for several weeks. The patient continued to suffer from headache after the operation, and had neuralgia of the fifth nerve on the homo-lateral side, but the vertigo was immediately relieved and did not recur. Convalescence was slow, and was interrupted by a somewhat protracted period of mental disturbance with sleeplessness and delusions. It was not until March 1907, four months after the operation, that the mental state became normal. The flap, after healing of the wound, remained convex and was at times very tense, but the wound was not reopened.

In April she was sufficiently recovered to be sent to the seaside, where she remained until August. On her return she was in excellent general health, had gained considerably in weight, had no pain or giddiness, and slept well at nights. There was no optic neuritis. The scalp flap was but slightly convex. She is now quite well, and has (September 1907) resumed her duties.

LECTURE II

SOME POINTS IN THE SURGERY OF ABSCESS OF THE BRAIN

Etiology—Morbid anatomy and pathology—Infection of brain substance—Manner of development, form, and situation—Clinical evolution—Symptoms and diagnosis—Complications—Operative treatment of the varieties of abscess—Recent improvements in details—Concluding remarks.

IT is now almost universally accepted that suppuration does not occur without the intervention of microbes¹; various species of microorganisms have been found associated with suppuration within the brain, and each of them might be spoken of as a cause of cerebral suppuration.

To the practising surgeon, however, the general or local disease of which the cerebral suppuration is a complication is the dominant etiological factor. Not because the bacterio-

¹ Sterile liver abscess is said to be due to the presence of bacterial toxin. Certain chemical substances determine sterile suppuration. Multiple sterile suppuration is deliberately induced by Poncet of Lyons by the subcutaneous injection of terebene for the cure of puerperal sepsis.

logical diagnosis is not of importance in treatment, but because it is not usually available until the clinical diagnosis has been put to the proof.

With what diseases, then, is brain abscess associated ?

1. Injuries to the head.
2. Local cranial suppurations.
3. Certain general infections.
4. Certain local diseases other than those of the head.

Abscess of the brain complicating injuries to the head is too well known to need any exposition in this place ; I will only remark that, except when the instrument causing the injury has penetrated deeply into the brain substance, the abscess is in most cases really a local meningeal suppuration with participation of the adjacent brain cortex, a meningo-cortical abscess rather than a brain abscess proper.

Less frequently injury leads to local chronic disease of bone, from which a brain abscess may subsequently arise. I have elsewhere spoken of brain abscess secondary to local cranial suppuration.

The general infective diseases most liable to be complicated with abscess of the brain are (*a*) pyæmia ; (*b*) tubercle ; (*c*) certain specific fevers, such as influenza, enteric fever, or variola.

Little need be said of brain abscess secondary to general pyæmia. The brain is one of the less common localisations of pyæmic abscess, and general pyæmia is happily a disease well on its way towards becoming extinct.

It is of great interest that cases have been met with of abscess of brain, apart from any other macroscopic intra-cranial tubercular lesion, which have yielded pure cultures of the tubercle bacillus.



FIG. 41.—Traumatic meningo-cortical abscess of brain. (Starr.)

The abscess was in the inferior parietal region, and was secondary to fracture of the skull. The thick capsule of the abscess can be seen. The patient was an infant. The injury was followed in two weeks by hemiplegia and hemianopsia.

In 22 cases of brain abscess observed at the Presbyterian Hospital, New York, 12 were due to trauma. Starr also relates 3 cases which recovered.

Cases of brain abscess following, and apparently caused by, the acute specific fevers, without any evidence of disease of the cranial bones or anything to suggest pyæmia have been from time to time reported ; for example, Dr. Bristowe in 1891 published two such cases (to which I shall have again occasion to refer) following influenza. These cases rarely come under a surgeon's observation ; they present great diffi-

culties in diagnosis, and even when brain abscess has been suspected there has usually been little or nothing to show in which region or even on which side of the brain the abscess has developed.

The local disease elsewhere than in the head which is most liable to be complicated with brain abscess is putrid inflammation or gangrene of the lung. Brain abscess supervening upon this condition has been observed and recorded for at least fifty years. Though it is clear enough that the infection is carried in the blood-stream, no adequate explanation is as yet forthcoming why it should be localised in the brain.

In 1901 Claytor collected reports of 58 cases of brain abscess secondary to disease of the lungs, most of which occurred on the left side of the brain. The particular form of lung disease was in 20 cases bronchiectasis, in 10 empyema, in 9 purulent bronchitis, in 7 gangrene of lung, in 5 tuberculous disease, in 3 abscess of lung, in 2 pneumonia, and in 2 gunshot wound of lung.

Stoll reports a case of abscess in left frontal lobe, and a cavity in the apex of the right lung $2\frac{1}{2}$ cm. in diameter. A similar case to that of Stoll is reported in the *Lyon Médicale*, 1904.

Blöttche found pulmonary pigment in the pus of certain brain abscesses.

Examples of Brain Abscess following Pulmonary Disease.

Case 1 (Cayley).—Male, aged nineteen years.—Severe attack of pleurisy lasting eight weeks. Hæmoptysis during the attack and, in small quantities, at intervals subsequently.

Three years afterwards. Headache, vomiting, temporary loss of power in left arm and leg. Renewed hæmoptysis. Complained of some confusion of thought but answered questions rationally though slowly. Constipation. Dulness at left base with bronchial breathing and bubbling crepitation. Five days after commencement of head symptoms he had a fit with clonic spasms affecting first the left leg, then the trunk, and then the left arm; there was no loss of consciousness, and he attempted to control the movements with right arm. Vomiting and headache increased. Pulse 44, temperature 96.6°. Edges of disc blurred. Died five days later. At the autopsy two abscesses were found in the brain. One in the centrum ovale of the right hemisphere as large as an unshelled walnut. "It gave off from its upper part a prolongation or loculus which reached the surface in front of the superior parietal lobule at the top of the ascending frontal convolution, the grey matter of which was partly destroyed by it. Though in this region quite superficial the abscess had not burst on to the surface of the brain. This upper loculus communicated with the principal cavity by an aperture the size of a crow-quill." Bronchiectasis of left lung and enlarged bronchial glands without evidence of tubercle. The diagnosis during life had been tubercular tumour.

Case 2 (Pye-Smith).—Male, aged nineteen years.—Empyæma treated by simple incision, August 16,

1876. Irrigated with weak iodine solution. Wound had healed and lung expanded by October 5. On October 6, vomiting, headache, and delirium. Temperature 101.8. Left hemiplegia. Died three days later. Autopsy. Residual abscess between lobes of lung. Purulent meningitis, pus beneath arachnoid. Two abscesses in right cerebral hemisphere each as large as a marble, the one involving the gyrus fornicatus, and the back of the optic thalamus, and the other situated in front of the corpus striatum. Both abscesses had burst into the ventricles.

Case 3 (Rudolph Meyer, 1864).—Male, aged thirty-six years.—Cough and stinking expectoration three years. Temporary paresis of right hand. Four days later, shivering, right hemiplegia, aphasia. Constipation and involuntary micturition. Intense frontal headache. No vomiting; pulse 52, temperature 98.6°. Rigidity of left arm. Died comatose. Multiple abscesses in brain. One in right occipital lobe, and two in the left hemisphere, one of which was close to the cortex.

Infection of Brain Substance.

In speaking of meningitis I have already indicated how infection reaches the interior of the skull; and how the meninges react towards it. I have now to speak of the effects of infection of the brain substance.

Like meningitis, brain abscess may be caused by infection reaching the brain by direct continuity from an infective lesion in the head, or conveyed indirectly by blood-vessel or lymphatic

from a local lesion in the head or elsewhere, or may occur as part of a general infection of the blood.

The oft-quoted statistics of Newton Pitt show that nearly one half of all brain abscesses are secondary to local disease of the cranial bones, while only a small proportion of meningitis cases have a similar origin. To reach the brain by direct continuity from extension of a local infective cranial lesion infection must first traverse the meninges. In a rapidly extending infective process diffuse meningitis would be the most probable result ; in the more slowly spreading infection resulting from chronic disease the meningeal infection would be localised by adhesions and time given for extension of disease to the brain.

The same point is illustrated by the fact that abscess of the brain or sinus infection is a more common complication of chronic ear disease than is acute suppurative meningitis, whereas meningitis has been the most usual result in those cases, now happily rarely met with, in which attempts to extract a foreign body from the ear have been so unskillfully made that intra-cranial infection has followed. Here the meninges are directly infected, as in accidental injury.

In most cases of slowly spreading infection from chronic disease adhesions occur obliterating the cavity of the arachnoid at the site of infection and binding together dura, arachnoid, pia, and cortex. The lymphatic sheaths of the numerous small blood-vessels which traverse the cortex at right angles to its surface are in direct communication with the sub-arachnoid space, and through these, as through a number of capillary tubes, infective matter easily traverses the cortex and reaches the white substance within.

The cortex is very vascular, and its connective tissue element, reinforced by numerous prolongations from the pia mater, is abundantly supplied with connective tissue corpuscles. Hence it is able to offer a strenuous resistance to the bacterial attack, and does not ordinarily undergo any extensive destruction. Where it is traversed by the infective material a barrier of fibrous tissue is thrown out, limiting the destructive process to the formation of a narrow track.

The white substance is much less resistant, and it would seem that the greater the distance from the cortex the more easily does bacterial action cause dissolution of brain substance.

Thus the abscess comes to assume a mushroom-like shape, with the narrow portion or stem attached to the dura at the original site

H

of infection from the bone. Preysing's figures admirably illustrate this important fact.

When the dura has been separated from the bone over a more or less considerable area adhesion of the meninges takes place to a much greater extent.

In a case successfully operated upon by Salzer, an area of the dura over the temporo-sphenoidal lobe measuring several square centimetres was in a sloughy condition. The diseased portion was excised, and the meninges were found fused into one layer, the inner portion of which, corresponding to the pia, was not necrotic. There was no abscess of brain.

In a similar case, reported by Manasse, the infection had proceeded a stage further and there was an abscess of brain, the outer wall of which was, over a considerable area, formed by fused meninges and brain cortex.

The more recent the abscess the nearer will it lie to the spot where the infection traversed the dura, and the more evident will be the stalk or its remains. The older the abscess the greater is the apparent recession from the dura and the less evident the remains of the stalk.

Such is the ordinary course of the formation of brain abscess when, as is usual, the infection gradually spreads into the brain substance by

slow extension in direct continuity from the spot where the disease in the bone reached the interior of the skull ; but, as has already been stated, the infective particles may, in the brain, as in other parts of the body, be carried by the circulation to a spot remote from the site of infection.

An abscess may thus arise in the substance of the brain without having any visible connection with the bone disease to which it really owes its origin. Just as an abscess in the axilla may arise from infection in the finger tip without visible intermediate lesion.

The stalked form of brain abscess is quite comparable, as to its mode of formation, to a superficial cervical abscess connected by a narrow track to a focus of disease beneath the deep fascia, and the isolated variety of brain abscess has its parallel in an abscess of liver arising from disease in the intestine.

No difficulty need therefore arise in explaining the pathology of a case reported by Swain, in which purulent infection of the choroid plexus in the descending cornu of the lateral ventricle occurred as a result of caries of the tegmen tympani of the same side, the intervening brain substance being unaffected.

The abscess may more or less rapidly increase

in size and ultimately leak, either into the ventricles or on to the surface of the brain.

Or it may run an entirely chronic course, with more or less complete latency so far as symptoms are concerned.

In these circumstances the abscess may or may not become encapsuled. Encapsulation of abscess appears to be relatively more frequent in the brain than in other parts of the body.

This is due, not to any difference in the pathological process, but to the peculiar liquid texture of the brain, allowing a sharper differentiation between the sclerotic tissue forming the abscess wall and the surrounding unaltered brain substance.

The statement that only acutely developing brain abscesses are free from encapsulation is too absolute, and a history of long-continued cerebral symptoms in a case of brain abscess does not necessarily point to the presence of a capsule ; for in a case of cerebellar abscess with symptoms pointing to a duration of at least eight months no capsule was found, but the whole cerebellar hemisphere was nothing but a shell of softened grey matter.

An abscess completely latent as regards symptoms for any length of time will usually be encapsuled. An abscess in the brain, as in

other parts of the body, may tend slowly to extend, causing great local destruction of tissue. Such abscesses give rise to slight symptoms extending over a considerable period, and are not encapsuled.

A slowly growing abscess may be thought of as displacing or pushing aside fibres passing from the cortex to the internal capsule rather than causing their actual destruction, and this view is somewhat supported by the fact that recovery from paralysis takes place after successful drainage of the abscess. It must, however, be pointed out that cortical impulses may sometimes find new paths.

When an abscess is drained through the point of attachment to the dura, as in the case of a temporo-sphenoidal abscess opened through the tegmen tympani, though the abscess may be large, there may be but little actual damage to the cortex.

The formation of even a thick capsule does not prevent the abscess from extending; nor even from leaking into the ventricles. Acute inflammatory softening or even suppuration has been known to arise around an encapsuled abscess. Abscesses surrounded with a thick capsule and which can be shelled out whole have run a chronic course. Complete encapsulation of an

abscess arising by extension of infection by direct continuity from bone may and does occur, the narrow track of communication being obliterated by scar tissue, just as in an aneurism, in process of cure, the narrow orifice of communication with the lumen of the artery becomes obliterated. In these cases we should find adhesion of the abscess wall to the bone.

When an abscess is found in the brain completely isolated and at some distance from the meninges, the infective organisms have been carried by the blood or lymph stream, and have first multiplied at a spot in the brain some distance from the point of infection.

Many of the cases published have resulted from injury, not from bone disease, a considerable number having followed gunshot wounds. In these, at least, it is conceivable that infective particles have been driven directly into the substance of the brain, in fact that a "stab-culture" has been made.

The following is a good instance of encapsuled abscess (Bergmann) :—

A youth, aged sixteen years, received a pistol-shot wound in the right frontal region. Four months afterwards the right frontal lobe was explored for abscess, several punctures being made with a needle. No pus was reached. Three days later the abscess burst. The

opening was enlarged with a scalpel. So thick and firm was the capsule that it was dragged out whole. Three days later the symptoms recurred. A second encapsuled abscess was opened and the capsule likewise dragged out. On the death of the patient, six weeks

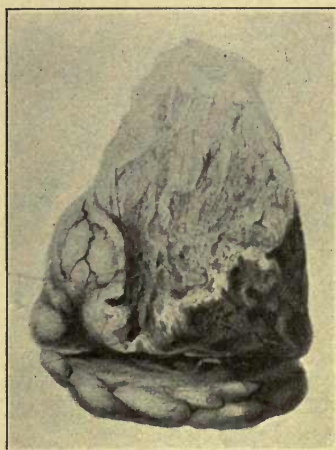

FIG. 42.—Spreading septic softening of the right frontal lobe. (Hooper, 1826.)

Lebert gives a good illustration of the same condition in the cerebellar hemisphere. I think that this particular result of septic infection occurs more readily and is more dangerous in the cerebellum than in the cerebrum. The brain, just like any other soft tissue of the body, may be affected by localised or by spreading suppuration.

later, from pyelitis, the wound in the brain was found to be healing well.

Spontaneous Recovery in certain Tubercular Cases.

Inspissation and even calcification of brain abscess has been observed, but only in tubercular cases, the occasional spontaneous cure of which cannot be denied.

Cases are relatively common in early life which, although the symptoms are apparently only explicable by the presence of a cerebral tumour or of meningitis, either get well or run

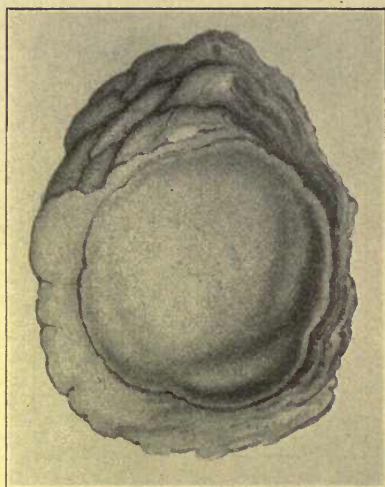


FIG. 43.—Encysted abscess of left frontal lobe. (Hooper, 1826.)

The cyst-wall was as thick as the pericardium. The cyst contained between 2 and 3 oz. of pus. Von Bergmann's case is a good example of encysted abscesses of the frontal lobe. I have known an abscess of the frontal lobe to have so thick a wall that it could be rolled about the floor like a billiard ball.

a chronic course extending over many years, and then die from distension of ventricles.

In some at least of these cases it seems probable that there was a localised tubercular mass in the brain which has been recovered from.

In one such case, some four years after a diagnosis of cerebral tumour had been made, the autopsy showed great distension of ventricles.

There was no visible tumour and no evident trace of tubercle in the brain, but in the mesentery there was a large calcareous mass.

Two girls, under twenty years of age, both suffered from headache, vertigo, nystagmus, and repeated purposeless vomiting; both had double optic neuritis, unsteady gait, and absence of the patellar reflex. The diagnosis in both cases was some affection below the tentorium, probably cerebellar tumour. Both made good recoveries, but in one some impairment of sight remained.

Multiple Brain Abscess (apart from General Pyæmia).

Multiple brain abscess does not commonly occur as a result of injury, indeed the abscess which follows an injury is usually a meningo-cortical abscess.

A second abscess in the temporo-sphenoidal lobe is rare. Probably in some at least of the published cases the second abscess was nothing but a pocket of the original abscess. In Kümmel's case, however, the autopsy showed a second abscess separated by a thick capsule from the first. In Roncali's case a temporo-sphenoidal abscess extended into the frontal lobe. In a

case of my own a temporo-sphenoidal abscess had extended into the occipital lobe.

A second or even a third abscess in the cerebellum is by no means uncommon. The first abscess is usually situated in the anterior and outer part of the lateral hemisphere. A second abscess may be situated internal to the first and separate from it; or posterior to it, in which latter case it has probably been originally connected with it, so that the apparently double abscess is really a single dumb-bell shaped cavity.

Another type of second abscess met with in the cerebellum is the oyster-shaped abscess. This forms beneath the grey matter of the upper surface. It occupies an extensive area laterally and antero-posteriorly, but in depth is very shallow.

When a second or third abscess has not arisen by infection from, or extension of, the first, it has a separate point of attachment to the dura at the site of infection.

I have elsewhere pointed out that the statistics of St. Thomas' and Great Ormond Street Hospitals show that abscess of aural origin is more frequent in the cerebellum than in the temporo-sphenoidal lobe.¹ The following

¹ Körner on the contrary states that temporo-sphenoidal abscess is the more common.

suggestions may be offered as an explanation of this, and of the fact that abscess resulting from disease of the temporal bone is more frequently multiple in the cerebellum than in the temporo-sphenoidal lobe.

In the middle fossa the site of infection is practically limited to the roof of the tympanum and antrum, while in the posterior fossa infection may occur anywhere along the whole posterior surface of the petrous or the groove of the sinus.

Not only is there a larger bone area where infection can enter, but there is a larger surface from which septic absorption can take place, for if both were spread out, the superficial area of the folia of the cerebellum, in relation to the posterior surface of the petrous, would greatly exceed that of the convolutions of the temporo-sphenoidal lobe in relation to the tegmen.

Again, since the pia mater runs to the bottom of every fissure between the folia, and also lines the deeper fissures between the lobes, it, when infected, carries septic material deeply into the cerebellum, hence the opportunity for the branching of the track of infection or the formation of two distinct tracks.

Abscess has been met with at the same time,

both in the temporo-sphenoidal lobe and in the cerebellum.

The great morbid anatomists of the last generation—Auvart, Cruveilhier, Lebert, Bright,

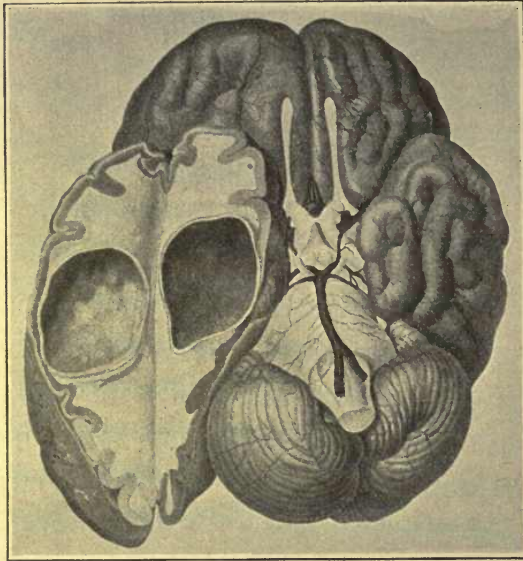


FIG. 44.—Abscess of the right temporo-sphenoidal lobe. (Cruveilhier, 1830.)

Male, aged 32 years. Pain and discharge from right ear for 20 years. *April 18, 1829.*—Taken ill with violent headache and fever. *April 29.*—Seen by Cruveilhier. No affection of sensation movement or intelligence. Died suddenly *May 11.*

Cruveilhier states that the grasp of the two hands the day before death was equal, so there could not have been any gross hemiplegia.

Autopsy.—The ventricles were full of pus, but the encysted abscess had no connection with the ventricles. The last illness was probably meningitis and acute infection of the ependyma of the ventricles—a new infection—from the petrosal disease. The encysted abscess, as we often find, was not the immediate cause of death.

Hooper, and Carswell—all contribute beautiful illustrations of abscess of the brain. How splendid were their labours, and how much we are indebted to them! On the sure foundation

laid by such patient pathological investigations the more perfect clinical diagnosis of the present day has been built up, and the recent advances of surgery have in great measure been made possible.

The Symptoms of Brain Abscess.

If we appreciate the march of the symptoms arising when abscess occurs anywhere we shall have the key to the understanding of the symptoms of abscess when situated in the brain. The symptoms of abscess in any region, as, for example, in the axilla, can naturally be grouped in three divisions :—

1. Those due to the infective process itself.
2. Those common to infective lesions of the anatomical region involved, and
3. Those due to specific functional disturbances caused by the local lesion or its influence on the surrounding tissues.

We may then classify the symptoms of brain abscess as follows :—

1. Those due to the mere presence in the body of deep-seated pus independent of its locality. Such as the febrile state, with perhaps shivering and vomiting.
2. Those due to increase of tension within the closed cavity of the skull.

Such as purposeless vomiting, slow pulse, torpor.

3. Those due to irritation or suppression of function of particular parts of the central nervous system.

Such as epilepsy, anæsthesia, paralysis, and perversion or loss of one or other of the special senses.

Symptoms of Extra-Dural Suppuration.

Suppuration between the bone and dura gives rise to no specific symptoms, and the first indication of the presence of an extra-dural abscess is often the discovery of the pus during the course of an operation for disease of the bone.

When the pus happens to be under tension there is much local pain and fever, possibly there may be tenderness on percussion over the site of the abscess, and there is often rigidity of neck when the suppuration is in the posterior fossa. Sometimes symptoms arise from compression of the brain, but there is then nothing to distinguish extra-dural from intra-dural suppuration. When the infection is virulent enough to make its way rapidly through the dura, the pus not being under tension, the extra-dural stage of the progress of the case is not commonly marked by any recognisable symptoms.

The symptoms of brain abscess are sometimes pathognomonic as to its situation, in others they are in this respect indefinite, and the diagnosis of the seat of the abscess, if possible at all, has to be made from the attending circumstances rather

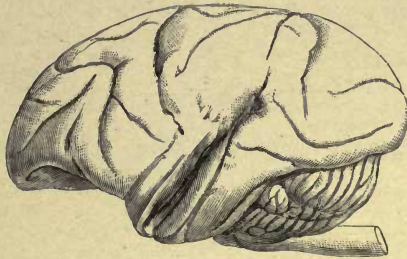

FIG. 45.

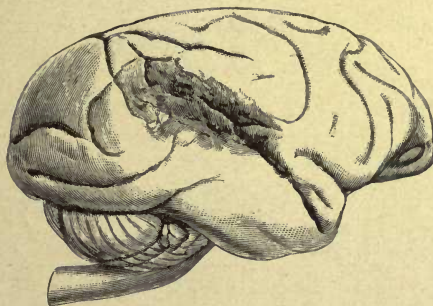


FIG. 46.

Figs. 45, 46.—The cortical centre for hearing. (Ferrier.)

The superior temporo-sphenoidal convolution was destroyed in both sides in the monkey, causing complete deafness. The animal was allowed to survive for more than a year, during which time it enjoyed perfect health and the full enjoyment of all its faculties, with the single exception of hearing.

than from the direct effects of the abscess on the brain.

I shall not have time to deal with the localising symptoms of brain abscess, and this is the more unnecessary as I have elsewhere done so in

some detail, and the subject has moreover been fully discussed by many other observers. I propose only to illustrate the application of localising

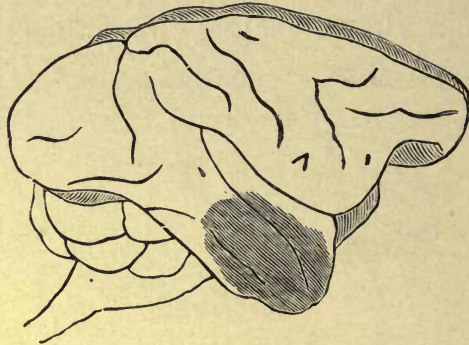


FIG. 47.

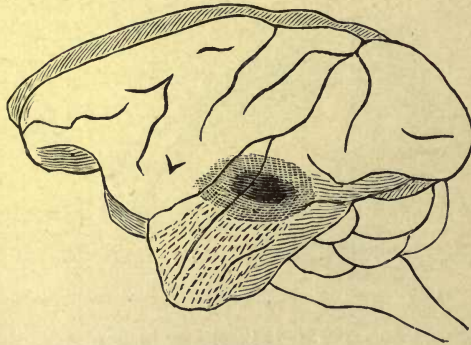


FIG. 48.

FIGS. 47, 48.—The cortical centres for taste and smell. (Ferrier.)

Lesions of right and left hemisphere, causing in the monkey loss of taste and smell. In the right hemisphere the shading indicates the extent of destruction of the grey matter. In the left hemisphere the dark shading indicates the superficial extent of the wound, and the dotted lines the extent of internal destruction of the lower portion of the temporo-sphenoidal lobe.

symptoms to diagnosis by discussing those produced by abscess or tumour of the temporo-sphenoidal lobe either by disturbance of cortical

centres or by pressure on adjacent parts of the brain.

1. The cortical centre for hearing may be in part or wholly involved, causing tinnitus, hyperacusia, or absolute deafness of the opposite (healthy) ear, all of which symptoms I have observed.

2. The cortical centres for taste and smell may be affected. Alteration or suppression of the sense of smell may occur in abscess, involving the anterior extremity of the temporo-sphenoidal lobe. Some cases illustrating the cortical localisation of the sense of smell are given farther on. Jackson and Beevor published, in 1887, a remarkable case of tumour of the tip of the right temporo-sphenoidal lobe, confirming clinically Ferrier's classical experiments. Their patient suffered from fits, associated with the dreamy state (commonly called intellectual aura), and a crude sensation of smell. I have observed the dream state in several cases of temporo-sphenoidal abscess.

3. Sensory aphasia often occurs in abscess of the left temporo-sphenoidal lobe in consequence of the cortical centres for the mechanism of speech being on the left side of the brain. The auditory word centre and the visual word centre are the ones involved in temporo-sphenoidal

abscess. A temporo-sphenoidal abscess on the left side is therefore commonly more easy to recognise than one on the right.

4. Paralysis of the opposite side of the body may be of cortical or internal capsule type. The march of the paralysis is different in the two cases. This paralysis is a frequent occurrence from pressure on the posterior end of the internal capsule, and may be associated, as might be expected, with hemi-anæsthesia.

5. Paralysis of the third nerve on the side of the abscess. This is important. The paralysis is rarely complete. A stabile pupil on the side of the suspected abscess clinches the diagnosis.

6. Paralysis of the "naming centre."

Certain clinical and pathological observations point to the conclusion that the nervous mechanism by which the ideas of objects are correlated with their names, is located in the left temporo-sphenoidal lobe.

The formation of an idea of an external object is the combination of the evidence respecting it received through all the senses; and for the employment of this idea in intellectual operations it must be associated with and symbolised by a name. Broadbent and Charcot thought a naming centre necessary for the

receipt and combination of the sensory impulses involved. Ross and Bastian do not think so.¹

Cases Suggestive of Site of Supposed Naming Centre.²

1. A woman, aged forty years, became in a high degree word blind after a cerebral seizure, though not letter

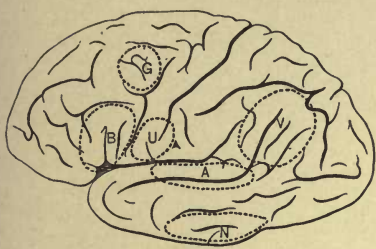

FIG. 49.

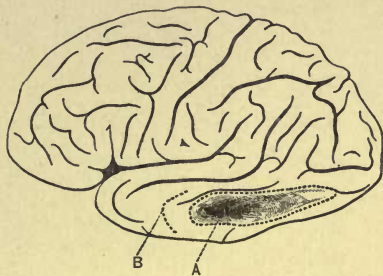

FIG. 50.

FIG. 49.—Diagram of the position in the cerebral cortex of the centres concerned in the mechanism of speech. (Mills.)

A, Auditory centre (centre for word hearing); V, visual centre (centre for word-seeing); N, naming centre (centre where percepts are given a name); B, motor-speech centre (in Broca's convolution); G, graphic centre; U, utterance centre.

FIG. 50.—Tumour of the 3rd temporal convolution, indicating the position of the naming-centre. (Mills.)

A, Densest, and probably oldest portion of the growth (the cortical limit of the lesion is indicated by the dotted lines); B, anterior limit of the lesion beneath the cortex.

blind. She could not name objects she recognised by sight and by touch. On one occasion she called the scissors "what I sew with," and the purse "what I buy with." At the autopsy a tumour was found involving the third left temporal convolution (Mills).

2. Captain M., aged forty-four years, suffered six weeks before I saw him with an inflamed throat, pain in

¹ Byrom Bramwell, Wyllie and Beevor deny the existence of a naming centre, while Marie goes so far as to deny the existence of special speech centres altogether.

² See page 158 for another case of anomia, and see page 159 for a case of left temporo-sphenoidal abscess without aphasia and without anomia.

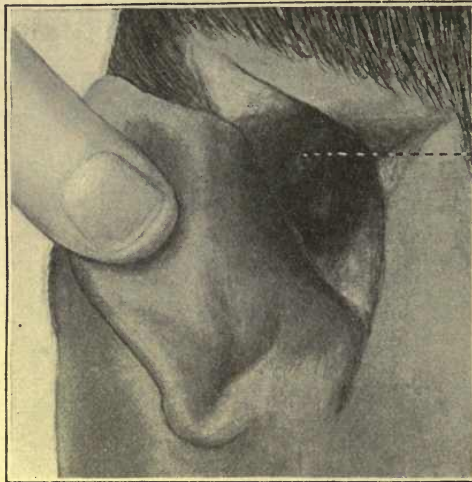


FIG. 51.—Capt. M. Case illustrating site of supposed naming centre.

a, Granulating cerebral cortex seen through opening in dura covering region of tegmen tympani three weeks after operation. (From a photograph by A. C. Ballance.)

To discover the "stalk" and evacuate the contents of a temporo-sphenoidal abscess the operator removes the tegmen tympani.

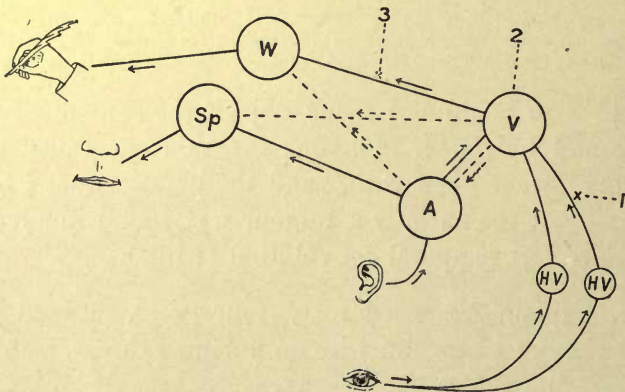


FIG. 51a.—Scheme of the connection of the various centres concerned in speech. (From Purves Stewart, after Bramwell.)

A. Auditory word centre. V. Visual word centre. Sp. Motor vocal word centre. W. Motor centre for writing. HV. Half-vision centre.

the left ear, and left otitis media. For ten days he had had pains in the head and vertigo. Pus could be seen oozing from a perforation in the lower part of the drum. For a fortnight hot fomentations and antiseptic irrigation were employed, and at the end of that time the patient returned without headache, but still with otorrhœa and vertigo. The complete mastoid operation was then done. As the tegmen was carious it was removed. The dura over the tegmen was inflamed and not pulsating normally. For a fortnight all went well. The patient was out daily and appeared to be convalescing. The temperature then rose to 101° , and the patient was sick. Next morning he was irritable, temperature 99° , general headache, and feeling of nausea. Suddenly he was much perturbed by being unable to name any object or person, though still able to converse in a somewhat confused manner. This condition, in its worst form, lasted about two hours. In the evening the exposed dura was bulging, headache and nausea continued, vomiting was repeated, and both discs were congested. An anæsthetic was given, and the bulging dura incised. The membranes and cerebral cortex were fused together, and on passing the little finger through the dura a cavity in the cerebral cortex was entered about the size and shape of a thimble. No actual pus was seen. The brain around the cavity was soft, and incisions were made in it. Lumbar puncture was done, the fluid contained polynuclear leucocytes in abundance, and it was feared that meningitis had set in. The cavity probably occupied the temporo-occipital convolution and the adjoining part of the third temporal convolution, so interfering with Mills' "naming centre." The patient made a rapid and complete recovery.

Preysing has published a somewhat similar case.

3. A woman, aged thirty years, had had chronic supuration in the left ear for twenty-four years. Three days before Preysing saw her the discharge ceased suddenly, and from that time there had been severe pain behind the ear and in the temporal region. The meatus was somewhat narrowed by inflammatory swelling, and a small amount of fetid pus was found in it. Complete mastoid operation next day. A week later the middle fossa was opened by removing the tegmen tympani and antri. Dura granulating and perforated, some pus escaped from the temporo-sphenoidal lobe. Next day fever and headache persisted, the wound was explored, and a further extension of the abscess opened up with forceps. Some difficulty was experienced in establishing satisfactory drainage. In the evening the fever had subsided and the patient felt well, but was astonished by finding that she was unable to give her address, she could only say "It is in the narrow street close by the church." She could not even recognise the name of the street when it was told her, but answered, "No, that is not the street." On investigation it was found that she was unable to name any countries, towns, or streets; though she could describe those with which she was familiar. She did not always recognise the names when she heard them. Ordinary objects were, with few exceptions, correctly named. This partial loss of the power of naming persisted for about a week. For about another fortnight she was unable, after reading a short paragraph, to say what it was about; the meaning of the lines being forgotten almost as soon as they were read. In three months from the time of the first operation recovery was complete.

Brissaud and Souques, in their interesting and lucid exposition of language defects resulting from brain disease, say :—"Complete inability to utter any vocal sound, articulate or inarticulate, is quite exceptional. Complete loss of articulate speech, with ability to make use of guttural sounds of low or high pitch, is often enough observed."

"Some aphasics are only able to pronounce isolated vowels or consonants, such as A, O, R, S, or, as is most usual, only meaningless syllables or grotesque words, which they keep on repeating.¹ Others, again, retain nothing of their native tongue but oaths and expressions of the most objectionable nature. Some have saved from the wreck a few castaways, fragments of words, generally the first syllables ; and sometimes this partial aphemia is limited to substantives. Such was the case, related by Trousseau, of the eminent lawyer who said "Give me my um—um—um—damnation !" "Your umbrella ?" "Ah, yes, just so, my umbrella."

Aphemia limited to one particular part of speech, the substantive, the verb, etc., is by no means rare. Most commonly it is the noun,

¹ As illustrations of such syllables and words the authors give "*af, far, wat, cousisi, akoko, monomentif, iquifofdiqui*"; these with, of course, the French pronounciation aptly represent the mumblings of certain aphasics.

“the substance of discourse,” that is the most completely lost. The Abbé Périér,¹ wishing to ask for his hat, could only say, “Give me my . . . what is hanging on the . . .” Loss of memory of verbs is not common, the speech then becomes a sort of “nigger language,” or pidgin English. A patient of Voisin lost all the personal pronouns, which he replaced by “one”; speaking of himself, he would say, “One would like something to eat,” “One is not feeling well.” Aphemia generally obeys the law of progressive loss of memory, going from the particular to the general; proper nouns are first lost, then concrete and abstract nouns, adjectives, and adverbs. Some observations (Bouillaud, Winslow, Voisin) form exceptions to this rule.

“One of Charcot’s patients was completely aphasic for Italian and Spanish, which she spoke quite fluently before her illness, but retained the power of speaking French, which was not her native language. That is, however, an exception; the native language is usually the last

¹ Piorry, who published this case in 1838, thus described loss of memory of names as a particular form of speech defect sometimes met with in cerebral hæmorrhage:—“Some patients who have had cerebral hæmorrhage recollect incidents perfectly well, have an exact memory of places, things, sounds, etc., but if asked to give the name of a person whom they know very well are unable to recollect or to pronounce the name. In a more advanced stage of the affection they cannot even assign to anything the noun used to designate it.”

to be lost. There is likewise an aphemia for figures and numbers, for musical notes, etc., sometimes these various varieties co-exist, sometimes they occur independently. A very interesting form of motor aphasia results from the fact that the words of a familiar song become so closely associated with the corresponding musical notes that words and music come to form one complete whole ; so that, for example, an aphasic quite unable to recite the words of the Marseillaise, would sing them without fault on hearing the music. The centre of ideation common to the words and the musical sounds being able to set in action the motor impulses for phonation."

Brissaud and Souques do not appear to recognise the existence of a separate naming centre. They quote Pitres to the following effect :—
" Patients affected with amnesic aphasia have not absolutely lost the power of speech, often enough they speak a great deal. They can read both mentally and aloud. They understand what is said to them. They give accurate replies to questions. But from time to time the words they desire to employ to express their thoughts escape their memory, and they are obliged to stop or make use of a paraphrase. It is quite natural that the lesions giving rise to amnesic

aphasia should be sought in the immediate vicinity of the sensory word centres, but they have no absolutely fixed localisation. Indeed the symptoms seem to be caused, not by destruction of a highly specialised centre exclusively devoted to the recall of words, but by interruption of some or other of the commissural fibres uniting the special centres for verbal images with those parts of the cortex concerned in the higher psychic functions."

"Ballet thinks that amnesic aphasia is due to diminished functional activity of centres specially differentiated for the preservation and reproduction of word images.

"Déjerine does not consider it a special form of aphasia, but merely an attenuated form of motor or sensory aphasia into which it passes by insensible gradations."

Thus it is evident that though partial defects of speech in incomplete forms of aphasia are explained by some as consequent on lesions of definite centres, yet this view remains unproved, and is not accepted by other prominent neurologists.

Centres for intonation, equilibration, and orientation have been located in the temporo-sphenoidal lobe. Time will not permit me to discuss them now.

Other cases illustrating the localising symptoms of temporo-sphenoidal disease :—

1. Man, aged thirty-eight years. Operation for left petro-mastoid disease. Three days later he complained that everything given or shown to him had a bad smell. One day he asked the Sister to boil a sixpence (he had previously been in the habit of giving his wife sixpence to buy eggs). The day after this he had aphasia agraphia, alexia ; he had vomited, and there was weakness of face and arm with exaggeration of the knee-jerk on the contra-lateral side. At the operation the whole of the left temporo-sphenoidal lobe was found occupied by an abscess. (Case under treatment ten years ago.)

2. A woman, aged twenty, was quite unconscious of having been removed to the hospital, and repeated exactly the same words as when she was in bed at home. She lay quietly on her side with the limbs flexed, occasionally moaning, and taking no notice of anything around her. She could be roused with difficulty, and she then sat up in bed with a vacant expression of countenance, the eyes staring straight in front of her, and being apparently unconscious of her surroundings she said slowly, "Am I dying?" "Where am I?" Then she sank back on the pillow till again roused, when the same result followed, and the same words were repeated. The abscess was in the left temporo-sphenoidal lobe. This case illustrates the condition known as the *dream state*.

3. A man, aged forty-eight, was admitted to St. Thomas's some years ago with chronic otorrhœa on the right side. He had lost a son the year before from cerebellar abscess. The patient was a gardener, and said

that for three weeks he had had slight headache and had once vomited. His main complaint, however, was that he had lost the sense of smell, being unable to distinguish in this way between roses and violets. On examination the right pupil was found to be stabile and the right disc blurred. Operation forthwith. A large abscess was drained through the stalk, which was adherent to the diseased tegmen tympani. Rapid convalescence. No hernia cerebri. Recovery of sense of smell.

4. A man, aged thirty-eight, was seen six years ago. He was of considerable intellectual attainments and a good pianist. He had had left chronic otorrhœa since early childhood. Ten days previously a polypus had been removed from the ear by an otologist. Shortly afterwards he began to suffer from headache and vomiting. When seen by me pus was pouring from the left meatus in such quantity that it was obviously coming from a large cavity. He had also aphasia, agraphia, alexia, and amusia. The left pupil was stabile and the right face weak. Operation forthwith. Large abscess evacuated. Complete recovery, with the exception that the loss of the appreciation of musical sounds remained permanent.

5. Tumour of the right temporo-sphenoidal lobe (Beever and Jackson). Female, aged fifty-three years. For thirteen months before her admission to hospital she had had epileptic fits. The patient, who was a cook, had peculiar seizures in which she saw a little black woman who seemed to be always very actively engaged in cooking. She had also the subjective sensation of a horrible smell. She would stand with her eyes fixed and directed forwards (dream state) and then say, "Oh, what a horrible smell!" There was some drooping of the left side of the face, and the tongue when protruded deviated to the left.

Autopsy.—The whole of the anterior end of the hippocampal lobule on the right side was occupied by a tumour. It involved the amygdaloid nucleus and the central white matter, but did not affect the grey cortex of the hippocampal convolution or of the first temporo-sphenoidal convolution. The nucleus lenticularis and

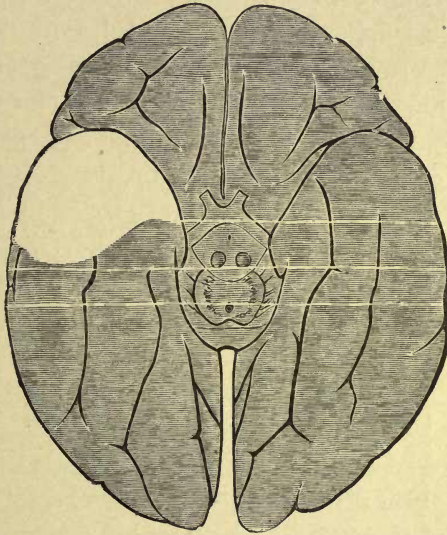


FIG. 52.—Tumour of the right temporo-sphenoidal lobe bearing on the localisation of the sense of smell. (Jackson and Beevor.)

M'Lane Hamilton (*New York Medical Journal*, 1882) published a case of cortical sensory discharging lesion, in which disease involved the tip of the temporo-sphenoidal lobe. Before being convulsed, the patient, a woman *æt.* 40, had a peculiar aura: she suddenly perceived a fetid odour.

the anterior end of the internal capsule were compressed. Hence the weakness of the opposite side of the face and the deviation of the tongue to the left. The left arm and leg became paralysed shortly before death.

The extreme anterior end of the temporo-sphenoidal lobe is the hippocampal lobule, which is highly developed in macrosomatic animals and rudimentary in microsomatic animals like the dolphin.

6. *Roncali's case*.—A man, aged thirty-eight years, had severe pain in the right mastoid region following an attack of facial erysipelas. The tympanic membrane was incised. The patient had had two previous attacks of erysipelas, but gave no history of having formerly had ear disease.

Ten days after the incision of the tympanic membrane a severe epileptic fit occurred, leaving the patient prostrate for several days. A week or so after the fit there was high fever, and an abscess formed over the right mastoid region which soon burst externally, giving exit to a considerable quantity of pus. For a short time the occipital and frontal headache of which the patient complained was much relieved, but soon recurred with increased severity. The man then entered an hospital, where the mastoid operation was done; this, of course, gave no relief, since the disease was in the brain, and when the wound had cicatrised the patient was worse than ever. The headache became more severe and vomiting occurred several times daily; the least noise or the ordinary daylight caused intense distress, and the general health steadily deteriorated.

In this state he was sent to an aural specialist in Rome, who diagnosed brain abscess, and at once proceeded to try to open it through the mastoid; after several attempts he succeeded in finding, at the lower level of the middle fossa, a fistulous opening in the squama through which pus came. This he enlarged to the size of a sixpence and incised the dura. One hundred c.c. of pus came away. A plug of gauze was inserted into the abscess cavity through the fistula. The temperature kept high for a few days. On the third day, when the dressing was removed and the plug pulled out, 50 c.c. of pus came away. After this the patient improved,

and a fortnight later he left the hospital and became an out-patient. The mastoid wound healed up very quickly. The fistulous track became partly blocked by granulations but did not close, and at every dressing a considerable quantity of pus escaped through it.

If it was not at first obvious that the opening in the skull was insufficient to drain the abscess, this was soon rendered evident by the subsequent course of the case. The discharge continued without diminution, and symptoms of local brain lesion were added. Vertigo, violent headache extending all over the right side of the head, epileptic fits beginning with movement of the toes on the left side and preceded by hallucinations of smell, were prominent symptoms. In spite of all this no attempt was made for twenty months to open up the skull and evacuate the brain abscess. Six "operations" limited to curetting the wound and irritating the fistulous opening with the cautery were performed. Irrigation was attempted through a tiny silver tube inserted through the little opening in the skull.

After this lamentable waste of time and opportunity the patient, then in a very feeble state, came under the care of Roncali, who came to the conclusion that there must be a large abscess in the frontal lobe extending backwards to the Rolandic area. Making a free opening in the skull, he found and opened the upper abscess shown in the figure. Ninety c.c. of pus were let out. The cavity was explored with the finger and seemed as large as an egg; it was irrigated through the fistula and through the wound until no more pus escaped from the fistula.

For two days all went well. On the third day there was fever, followed by drowsiness. Wound dressed; no pus came from the abscess cavity, but some was

seen trickling through the old fistula. Another fit occurred that day, preceded by olfactory aura. Next day more bone removed. A knife was inserted into the fistula and brought out through the already open abscess cavity. All intervening structures were divided; the track was very dense and offered great resistance to the knife. On washing the track thus laid open the dilatation of the sphenoidal stalk shown in the figure was seen. Two small orifices through which pus trickled opened into the upper part of the dilatation,

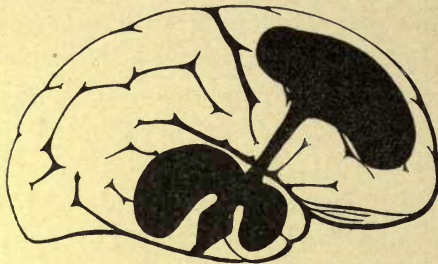

FIG. 53.—Abscess in the temporal and frontal lobes.
(Roncali, in *Chippault*, vol. iii.)

The sphenoidal stalk, which was irrigated daily for so long, is seen. By this treatment, no doubt, at last pus was squirted into the frontal lobe.

a probe-pointed bistoury was inserted through each into the cavity beyond and an incision made downwards. Eighty c.c. of fetid pus were let out. Improvement for three days, then rise of temperature and death on the seventh day, probably from suppurative meningitis.

This case illustrates: some symptoms of temporo-sphenoidal abscess, namely, hyperacusia, and fits preceded by an olfactory aura; the uselessness of operation limited to a cranial bone when the brain is suppurating; the pernicious effect of syringing a brain abscess through a small tube whereby in this patient the pus was driven from the temporal into the frontal lobe; and the fatal

result necessarily attending a case of brain abscess when dealt with in a manner contrary to the principles governing the treatment of abscess in other parts of the body. When the case came under Roncali's care it was too late to save life, but the measures he adopted were conceived in the true spirit of surgery.

Clinical Evolution and Diagnosis.

The evolution of abscess wherever situated varies greatly. The initial local infection may be quickly subdued and a small local abscess alone result, well isolated, and giving the patient little more inconvenience than an encysted sterile foreign body ; or the abscess may slowly extend and burst, with favourable or unfavourable results according to the seat of rupture ; or the abscess may extend acutely from the first with severe or even fatal general infection ; the symptoms—both those due to the abscess as such, and those due to the local lesion—necessarily vary in these different eventualities.

So in cerebral suppuration the complexity of the symptoms is not due to any peculiarity in the pathology of suppuration in the brain, but to the complex functions of the organ involved.

As abscess of the brain is a secondary and not a primary disease, the problem of diagnosis is often rendered the more difficult owing to

K

the presence of symptoms which are, or may be, due to the primary disease, or to some of its complications. Suppuration in the brain, like suppuration elsewhere, varies within wide limits in its virulence and local destructive effects; there will from this cause be wide differences in the clinical course of cases. The moment when infection reaches the brain is not commonly marked by any recognisable local symptom.

We may adopt the five types of clinical evolution so well described by Brissaud and Souques.

1. *A sub-acute evolution* more or less distinctly divided into three stages: the *initial* febrile stage, the symptoms in which are those of septic or febrile infection; headache, vomiting, and fever. Similar symptoms occur in the initial stage of specific fevers, and the distinction may at first prove difficult. This stage lasts a variable number of days and corresponds to the acute stage of the suppuration.

It is succeeded by the *second stage*, the stage of remission. Sometimes suddenly, more often gradually, the symptoms abate and give place to a period of calm, which is the more deceptive as it is sometimes prolonged. During this period, though few or no symptoms are manifest, there

is, especially, as insisted on by Okada, when the abscess is in the cerebellum, emaciation and impairment of general health; moreover, a thorough examination would in most cases raise the suspicion that gross brain disease was present or unmask some pathognomonic localising sign.¹

The *third* or paralytic stage supervenes in most cases suddenly as an "ictus" with or without convulsion; the apoplectiform condition may pass at once into profound coma terminating fatally in a few hours, or recovery from the seizure may take place with symptoms indicating a local brain lesion.

With the onset of the third stage there is generally renewed fever. The more rapidly fatal cases are associated with rupture of the abscess, the others with more or less rapid extension of the suppuration.

The above-described evolution of a brain abscess in three stages is quite comparable to the evolution of appendicular suppuration in three stages not unfrequently observed in cases not operated on in the initial stage. First there are transient symptoms of onset, then a period of quiet during which there is localised suppuration, and finally renewal of symptoms due to extension or rupture of the abscess.

¹ A blood count would probably show leucocytosis.

2. *The evolution with severe general infection.*—These are rapidly fatal cases—the symptoms of brain abscess are merged in those of grave general infection; high fever and acute delirious mania are prominent symptoms. Sometimes the history or the manifest presence of one of the known causes of brain abscess will arouse a suspicion of the existence of that complication; more often the diagnosis is made of a malignant form of some specific fever or the disease known as acute delirious mania.

3. *Evolution with complete latency* until the final attack of coma.—The patient dies suddenly or in a few hours, and a brain abscess, evidently having existed for a considerable time, is found at the autopsy. In some such cases death is absolutely sudden. According to Brissaud and Souques the abscess will then be found in the centre of the frontal lobe or in the postero-external region of the occipital lobe. I should like to point out that the right temporo-sphenoidal lobe is a much more frequent and equally “silent” site of abscess.

The term “latent” must not be misused in connection with these cases; symptoms not noticed and symptoms not present are not synonymous terms; some of the manifestations of gross disease of the brain cause the patient

but little inconvenience and are only elicited by an attentive clinical examination. In but few of the recorded cases of "complete latency" is there any evidence that such examination has been made, and in fewer still have the patients been under skilled observation for a period of several days during which pulse and temperature have been regularly taken.

We all know that an examination of the optic discs, the field of vision, and the actions of the muscles of the eye, has revealed the gravity of an illness which from the patient's complaints alone might well have been considered trivial. And, on the other hand, that the omission of such an examination has often led to an error in diagnosis. No one would call an axillary abscess latent because there was no pressure on the brachial plexus. Is it not possible that in at least some of the latent cerebral cases the latency has been in the faculties of the observer, not in the clinical reactions of the patient?

4. *In the fourth type the clinical evolution is just like that of brain tumour.*—The infection is of low virulence and the abscess produces just those symptoms which a tumour growing in the same region and at the same rate would cause.

5. *The fifth type of evolution is the remittent type.*—“Here the clinical evolution is in two acts,

separated by an entr'acte of greater or less duration. The first act is marked sometimes by headache and fever, sometimes by an attack of mania, sometimes by acute delirium. Then all quiets down and the patient seems cured. But after a few weeks, a few months, or even a year, follows the second act, which is commonly quickly fatal."

Bristowe's influenza cases previously referred to are examples of this type of evolution.

Case 1.—A man, aged twenty-four years, was admitted to hospital with right hemiplegia and paralysis of the left third nerve. There was incontinence of urine. Optic neuritis was present on both sides. The patient was apathetic and did not speak or attempt to speak. He died three days after admission. About two months before admission he had an acute illness with shivering, severe headache, and convulsions. At the autopsy there was found in the upper part of the left frontoparietal region an encapsuled abscess as large as a Tangerine orange, containing thick greenish pus. There was no disease of the cranium.

Case 2.—A girl, aged fourteen, had, one month before admission to hospital, an acute illness with shivering, vomiting, and severe headache. From this she apparently recovered in the course of a few days but she did not quite lose her headache. Two months later headache increased in severity and she had vomiting from time to time. When admitted to hospital, agonising pain in the head, rigidity of neck, left pupil larger than right, no optic neuritis, no paralysis,

nor anæsthesia. At the autopsy an abscess as large as a Tangerine orange was found in the right occipitospheoidal region, containing thick greenish pus. There was a small communication between the abscess and the descending cornu of the lateral ventricle which contained about a drachm of pus. No cranial disease.

Another example was a case I saw with Dr. James Taylor.

A man, aged forty years, was admitted to hospital on Sept. 14th, 1895, with severe occipital pain, vomiting, and slow cerebation. He had paralysis of the right sixth nerve and double optic neuritis. He lay on his right side in bed. There were forced movements to the right with rotation to the right in walking. With the eyes shut he fell backwards and to the right. In the beginning of May in the same year he had a severe illness with shivering, sweating, and rigor, said to have been of influenzal origin. This had been followed by slight loss of power on the left side, from which he had recovered. About ten days before admission the headache and other symptoms returned. On the day following admission (September 15th) a rigor commenced at 5.30 P.M.; at 6.30 coma was complete; at 7.30 artificial respiration was necessary and was continued until I arrived. I was told that the case was thought to be one of cerebellar tumour. Considering it almost impracticable to remove a cerebellar tumour during the performance of artificial respiration, and thinking that the history of left-sided paresis might indicate a lesion of the right cerebral hemisphere, I removed a large area of bone in the right parietal region. The brain bulged under great pressure, but

natural respiration did not return. A trocar and cannula was plunged in up to the hilt and impinged upon a hard mass, into which it would not penetrate. As this was thought to be a solid basal tumour which could not be removed, the operation was abandoned. The necropsy revealed an encapsulated abscess containing an ounce of thick greenish pus, replacing the right optic thalamus. The capsule was very firm and about one-fourth of an inch thick. At the present day such an abscess or tumour coming under my observation would be enucleated.

Abscess may, apart from pyæmia, occur in

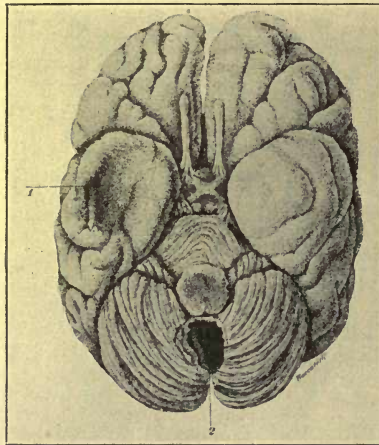


FIG. 54.—Two abscesses in the brain. (Durante, in *Chipault*, vol. iii.)

Patient, æt. 7 years, suffered from fracture of the right parietal bone. This was followed by abscess in the temporal lobe, which was drained.

Death was caused by abscess of the middle lobe of the cerebellum, and purulent infection of the ventricles.

more than one situation in the brain at the same time. Thus it has been found simultaneously in the cerebellum and the temporo-sphenoidal

lobe, in the occipital and the temporo-sphenoidal lobes, and also in the frontal and temporal lobes. The simultaneous development of abscess in more than one situation must confuse the symptoms and will probably render an exact diagnosis impossible. Unless the abscesses formed one after the other, and the case was most carefully observed from day to day, successful treatment would be well nigh hopeless.

Diagnosis of Brain Abscess with Complications.

1. *Abscess with meningitis.*—The symptoms of abscess will be modified or controlled by those of meningitis, according as the abscess or the meningitis is the more prominent disease. In abscess complicated with meningitis the temperature is relatively high, the pulse quick, delirium, convulsions, and optic neuritis occur early, pain in the head is severe, and retraction of the head may be present, together with vomiting, squint, and irregular respiration.

2. *Abscess complicated by pyæmia.*—The lateral sinus is often involved in cases of cerebellar abscess, the abscess in the cerebellum being secondary to sloughing of the wall of the sinus. The symptoms therefore are first those of pyæmia and secondly those of abscess. As

the abscess increases, the mental state becomes impaired, and the lower temperature and slower pulse of abscess replace the oscillating temperature and rapid pulse of pyæmia.

3. *Abscess complicated with acute hydrocephalus.*
—Acute hydrocephalus is no uncommon complication of cerebellar abscess. If an abscess burst or leak into one of the ventricles, general purulent infection of the ependyma occurs.

In one such case a cerebellar abscess was opened and all went well for seven days. On the tenth day after opening the abscess the following symptoms were observed : temperature 96°, pulse 50, apathy, screaming fits from pain in the head, dilated and stabile pupils. Acute hydrocephalus was diagnosed, Keen's tapping of lateral ventricle carried out, fluid escaped under pressure, next day remission of all symptoms. Five days later without warning the following symptoms appeared : temperature 105, pulse 140, wild delirium, unconsciousness, squint. Acute purulent infection of the ventricles diagnosed. Diagnosis confirmed by the escape of bubbles of gas and purulent cerebro-spinal fluid on withdrawing the tiny tube that had been left in the descending cornu. Irrigation of ventricles with saline solution. The pus of the original brain abscess had yielded a pure culture of pneumococcus,

therefore antipneumococcic serum was given. In 36 hours the ventricles contained nothing but cerebro-spinal fluid. The wounds assumed the pink colour characteristic of successful anti-toxin injection and ceased to discharge pus. Pulse temperature and general condition greatly improved and consciousness returned. Six days later patient again became unconscious and died. At the autopsy a second cerebellar abscess was found which had not been opened.

Rupture of abscess into the ventricles causes drowsiness, rapidly deepening into coma, high fever, and speedy death.

Diagnosis between Brain Abscess and certain other conditions.

(a) Tuberculous meningitis and tuberculous tumour.

—The symptoms and duration of tuberculous meningitis vary so greatly that diagnosis is often difficult, especially in childhood. When associated with chronic purulent otorrhœa the disease has been mistaken for brain abscess, and operative treatment undertaken which, of course, failed in its object. It is important to remember how often otitis in children is tuberculous, and that symptoms of intra-cranial disease, simulat-

ing brain abscess, may arise from the presence of a tuberculous mass or masses in the brain or from tuberculous meningitis. The writer has many times experienced this difficulty in diagnosis. The cases of tuberculous meningitis in which suspicion of brain abscess is likely to arise are those of ear disease with palsy. The salient features in which a case of tuberculous meningitis differs from one of brain abscess are: the temperature is above normal, the pulse is 100 or more rapid, optic neuritis is absent or is a late symptom; except in certain acute cases, vomiting is neither so urgent nor so frequent as in abscess, and the child is apathetic from the onset of illness, or even before illness is suspected is dull or irritable.

The predominance of certain localising symptoms in cases of tuberculous meningitis, especially of hemiplegia, has long been well known, and before the treatment of brain abscess by operation as a systematic procedure came into practice, these symptoms were often considered in relation to the diagnosis of meningitis from tumour. Several years ago I operated upon a case in which right hemiplegia was associated with left purulent otorrhœa, under the notion that a temporo-sphenoidal abscess was present, but the case

proved to have been one of tuberculous meningitis.¹

(b) *Marantic thrombosis of sinuses*.—In young children intra-cranial thrombosis as a complication of marasmus is not uncommon. It not unfrequently causes paralysis, and is sometimes associated with ear disease.

The main facts which distinguish these cases from abscess are: (1) The temperature above normal; (2) the pulse more rapid; (3) the slight degree of ear disease, and (4) the alternating paralysis of the eyes and face.

(c) *Embolism, hæmorrhage, and thrombosis*.—When an elderly patient who happens to have a discharge from the ear presents symptoms of brain lesion we naturally inquire whether the cerebral condition arose from the ear disease.

In the aged the temporal bones are sclerosed, and if tympanic disease arise it cannot produce an infection of the brain until sufficient time (months or years) has elapsed for the inflammatory process to pass through the dense boundaries of the tympanum; the comparatively rapid intracranial infection seen in young children with unclosed sutures and soft bone cannot occur.

¹ Leucocytosis might be detected in the cerebro-spinal fluid in cases of meningitis and in the blood in cases of abscess.

Again, in abscess of the brain due to ear disease the onset of the brain symptoms is gradual, and they may not reach their acme for two or three weeks, while in vascular lesions of the brain the symptoms may be fully developed in a few hours or, at most, days. In embolism the onset is usually instantaneous, and prolonged unconsciousness is rare. In hæmorrhage the patient may be a sufferer from chronic heart or renal disease; the onset is usually rapid and arterial pressure is in excess. In thrombosis the manifestation of the symptoms is more gradual and may extend over a few hours or days.

Treatment.

1. *General considerations.*—An abscess in the brain should be dealt with surgically on the same principles as an abscess elsewhere in the body, viz. by incision so planned as to evacuate its contents and to provide for free and spontaneous drainage, or, in the event of the abscess being encapsuled, by its complete enucleation.

In operating for brain abscess, however, the surgeon has to find out as he goes on the size and exact situation of the abscess, the acuteness or otherwise of the suppurative process, and even whether he has to deal with circumscribed or

diffused inflammation or with both, facts which are readily enough ascertainable by physical examination with regard to an abscess in an accessible situation. A case of acute cerebellar abscess which was opened with relief to the symptoms, died, and at the necropsy an old encapsulated abscess was found internal to that which had been opened.

When the abscess is found and opened, the brain tissue, which is of liquid texture and enclosed in an inextensible bony capsule, at once flows together in obedience to the laws of hydrostatics, and may shut off a portion of the abscess cavity from communication with the incision. There is thus a difficulty in maintaining free drainage. The integrity of certain parts of the brain is essential to the continuance of life, and in certain directions a limit is therefore placed on surgical interference.

These general considerations, though they in no way modify the principles of treatment of brain abscess, have an important bearing upon the details of operation.

2. *Operation for brain abscess following local cranial disease.*—It has been already said that in brain abscess, following frontal or temporal bone disease, the suppurative process has extended by direct continuity from the disease in the bone to

the white substance of the brain. The operation for the evacuation of the abscess should therefore be a direct continuation of the operation for the removal of the disease of the bone.

Every endeavour must be made to discover, follow out, and remove the pathway traversed by the infective process through the bone into the interior of the skull. If, for example, in the course of a mastoid operation this is not discovered, and the symptoms point clearly to the abscess being in the cerebellum or in the temporo-sphenoidal lobe, the surgeon should work his way in the one case from the inner or posterior wall of the antrum to the posterior surface of the petrous, and in the other he should enter the middle fossa by removing the roof of the tympanum and attic. So much of the petrous or squama must be removed as is necessary to expose thoroughly the extra-dural abscess or the diseased portion of the dura representing the point of attachment of the abscess to the meninges. Thus by the adoption of this route for the evacuation of the abscess, we recognise that the abscess is, in most cases, not an isolated globe within the white substance, but has a narrow portion or stalk passing through the cortex and adherent to the dura at the original site of infection.

This stalk is the track through which the infection entered. Its lumen presents a ready-made channel, with fibrous walls through which drainage can be effected and the infective material made to leave the brain. This natural tube is not liable to be obstructed by the flowing together of the liquid substance of the brain by which the efficiency of all forms of artificial drainage tube is so much impaired. If, then, the abscess can be tapped through the stalk itself without the knife passing through healthy cortex and meninges, there would be efficient drainage without risk of suppurative meningitis or hernia cerebri.

In a cerebellar abscess the point of attachment of the abscess to the dura is over the sinus groove, over the aqueductus vestibuli, or over the internal auditory meatus. In temporo-sphenoidal abscess the point of attachment is over the anterior surface of the petrous, and most commonly to the dura covering the tegmen. In frontal lobe abscess the point of attachment is usually on the cranial wall of the sinus. In deep abscess following injury the point of attachment of the stalk is in the region of the fracture.

Drainage through the stalk would, if successfully accomplished, remove all urgent

L

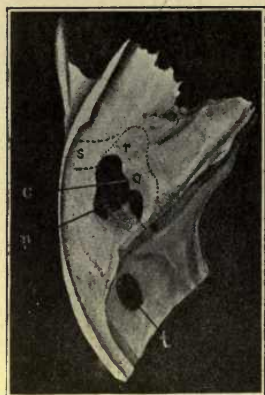


FIG. 55.

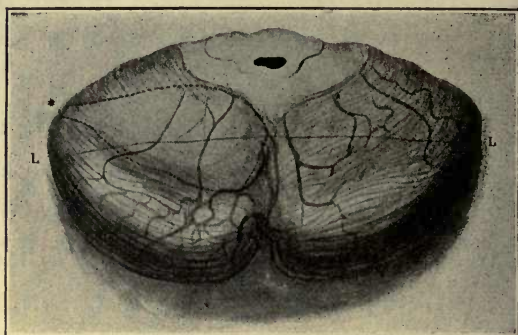


FIG. 56.

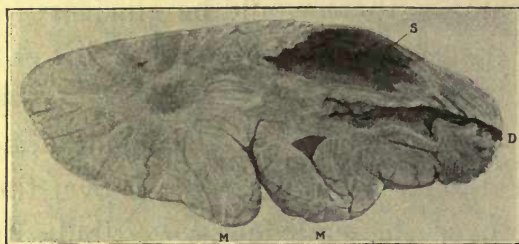


FIG. 57.

FIG. 55.—View from above of portions of the left middle and posterior fossæ, G, eroded edge of tegmen antri; *n*, site of tegmen antri destroyed by disease; *t*, trephine opening through which cerebellar abscess (D in Fig. 57) was drained; *r*, tegmen tympani; Q, remains of tegmen antri. The tympanum and antrum are enlarged by erosion. A black style projects through the opening, which leads from the antrum into the posterior fossa. S. Site of external auditory meatus.

FIG. 56.—Sketch of upper surface of cerebellum, showing by a dotted line the extent of the undrained abscess. * marks the place where the stalk of the undrained abscess was adherent to dura at site of carious erosion on posterior surface of petrous. LL, line of section shown in Fig. 57.

FIG. 57.—Drawing of transverse section of cerebellum, corresponding to line LL in Fig. 56. The drawing represents the posterior part of the specimen seen from in front. D, track along which one cerebellar abscess was drained through the trephine opening (*t* in Fig. 55); MM, amygdalæ; S, undrained abscess. This abscess measured (see Fig. 56) 53 mm. from side to side, 28 mm. in the antero-posterior direction, and about 14 mm. from above downwards. After hardening the depth of the abscess appeared greater than when the specimen was fresh. The abscess was close to the upper surface of the cerebellum.

symptoms and obviate the tendency to death. In some cases, no doubt, such an opening would not be sufficient to effect a cure, and the surgeon would be obliged to make a counter-opening, as he would in other parts of the body. To do

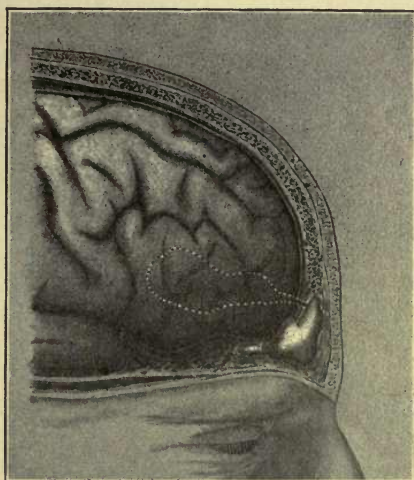


FIG. 58.—Frontal lobe abscess secondary to frontal sinus disease.
(Modified from Killian.)

Note the stalk of the abscess springing from the cranial wall of the frontal sinus. Such an abscess is commonly situated in the white matter of the basal part of the first frontal convolution. As it extends backwards it tends to involve the corona radiata and anterior end of the internal capsule, causing paresis of face, tongue, arm, and leg in the order named on the contralateral side. Killian says, "In a very instructive case, in which recovery took place, I was able to observe motor disturbances arise and completely disappear after the operation."

this it is desirable to remove a considerable area of bone, and then to open the dura and pack the wound with gauze, so as to get the area of the brain through which an incision is to be made isolated by adhesions, on the principle so long rendered familiar by colotomy

and similar operations. By doing the operation in this way a new point of attachment of the

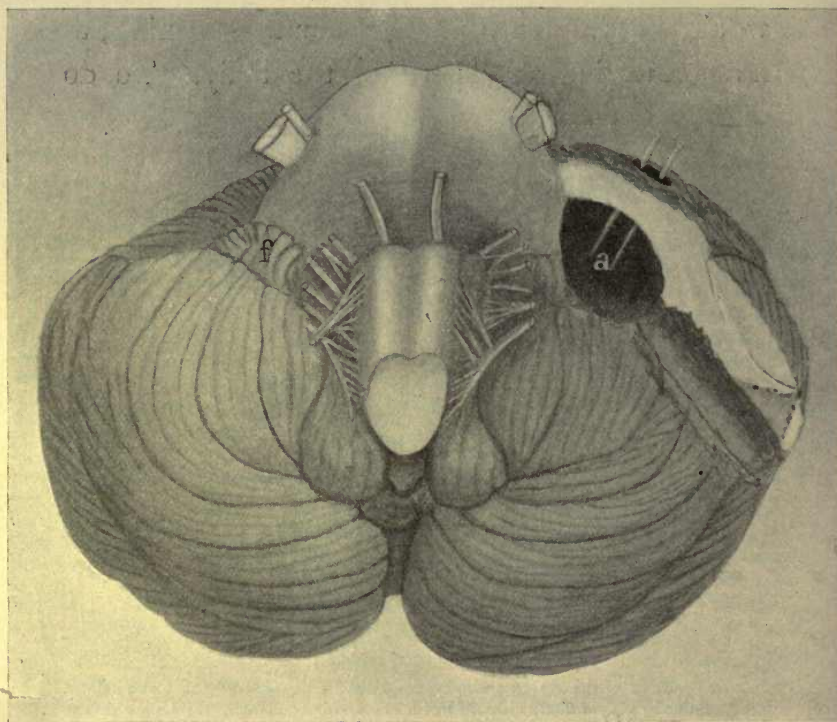


FIG. 59.—Abscess of cerebellum occupying the anterior and inner part of the left hemisphere.

a, abscess; *f*, flocculus. The track through which abscess was opened is visible. Two bristles pass into the abscess through an opening in the cerebellar cortex opposite the internal auditory meatus. The day following opening of abscess patient died.

Autopsy.—Pus in labyrinth and internal auditory meatus. Dura adherent, softened, and perforated opposite internal auditory meatus.

The illustration shows how a cerebellar abscess should not be opened. The direct route to open the stalk was through the petrous.

abscess to the dura is formed, and the danger of diffuse encephalitis avoided. The area of bone to be removed will be determined by the position

and size of the abscess, as ascertained by a probe passed through the open stalk.

In some cases when, for example, respiration has ceased, the condition of the patient is so bad that there is no time to follow a possibly tortuous route through which the disease found entrance to the brain. At all costs the abscess

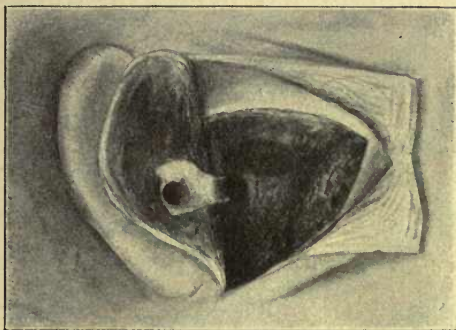


FIG. 60.—Drawing to show the direction in which the complete mastoid operation should be extended in order to drain a cerebellar abscess through its stalk.

The oval marked by a black line indicates the region between the sigmoid sinus behind and the facial canal in front, where bone may be safely removed. Working cautiously inwards with burr or gouge, the operator will come upon the stalk of a cerebellar abscess attached to the dura, on the inner side of the sinus, or anywhere on the posterior surface of the petrous as far inwards as the internal auditory meatus. The operation is easier when there is a visible carious track.

must be evacuated quickly. The abscess must then be reached by the most direct route and by the most rapid method. Just as in some cases of intestinal obstruction the bowel must be emptied without reference to the cause of obstruction, so in certain cases of brain abscess the abscess must be evacuated before dealing with the local bone disease.

On two occasions in my experience it has happened that with the first few inhalations of chloroform respiration ceased, and the operation had to be completed during the performance of artificial respiration. In another, artificial respiration had been in progress two hours before I arrived. Neither morphia nor strychnia should be administered before the dura has been opened.

3. *Discovery and incision of the abscess.*—The abscess may burst as the dura is opened. When there is a sufficient opening in the bone and dura it may be possible to determine by palpation that the abscess is immediately sub-cortical. An incision should then at once be made through the intervening portion of brain substance into the abscess cavity, care being taken to avoid wounding the vessels, as in other parts of the body. The use of a trocar and cannula, pus-seeker, or other special instrument is unnecessary. If the site of the abscess is not obvious it must be sought for by exploratory puncture, and in so doing it should be remembered that the site of the abscess is almost certainly close to the bone disease which gave rise to it. The best instrument to use is a sharp-pointed, long, and narrow knife. Our brains are not like Satan's—

Entrails, heart or head, liver or reins—

which Milton tells us could

Not in their liquid texture mortal wound
Receive, no more than can the fluid air ;

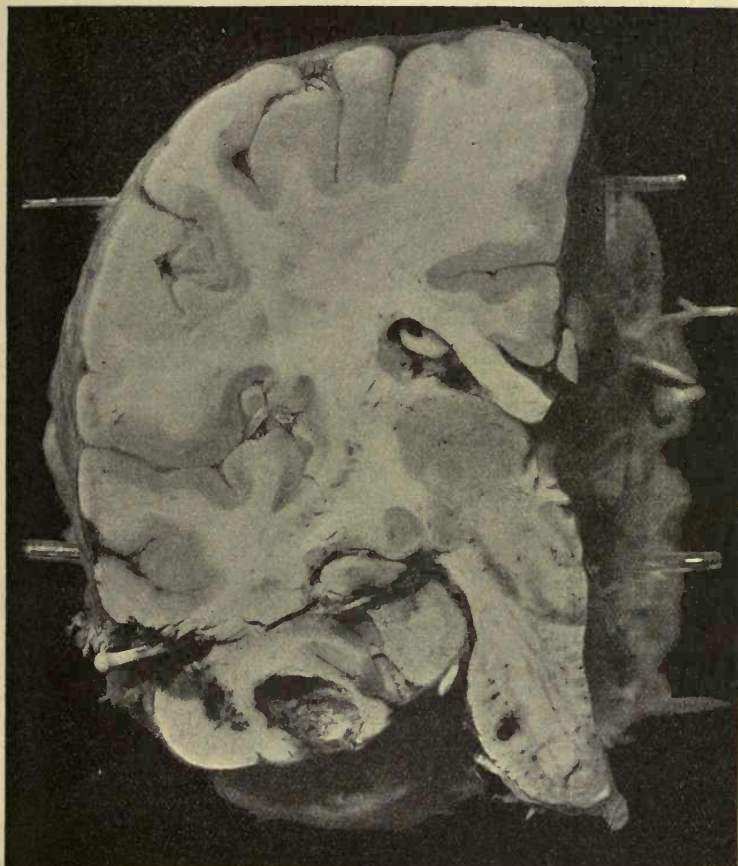


FIG. 61.—Coronal section of left cerebral hemisphere from a man, aged 29, displaying a small temporo-sphenoidal abscess 1 cm. in diameter, situated just above the tegmen tympani. The abscess was secondary to chronic otitis media. The rod lodged in the brain above the abscess shows the track made by the trocar at the operation performed for the relief of the disease. This track just misses the abscess cavity. The patient died of meningitis. (Norwich Hospital Museum.)

Remarks.—Compare with Fig. 59. The illustration shows how a temporo-sphenoidal abscess should not be opened. The direct route to open the stalk (attached to the tegmen) is through the tegmen.

and a wound made by the surgeon's knife will not heal quite so readily as that inflicted by the sword of Michael; yet in the brain, as elsewhere, clean cut wounds heal more readily than any others, and there is certainly less risk of missing an abscess with the knife than with any other instrument.

There have been cases in which the trocar and cannula has—1. Missed the abscess. 2. Passed through it without tapping it. 3. Struck the capsule but failed to penetrate it.

The use of the knife for the evacuation of an abscess of the brain is not a new operation, but was taught and practised more than a century ago. Dupuytren in one of his lectures says:—

“In certain cases of deeply-seated fluid collections we must incise the dura mater, the arachnoid, the brain itself, if the focus is at the surface of this organ, and by this bold proceeding patients have been saved.”

And a little further on in the same lecture he continues:—

“Relying also on the success of J. L. Petit, Boyer concurs in the advice of Quesnay, and does not fear to plunge the bistoury quite deeply (*assez profondément*) into the very substance of the brain in order to evacuate traumatic

effusions which may have formed there, and it has fallen to my lot to do so several times with success." Like many another step in the advance of knowledge, this advice, though justified by some brilliant successes, remained for a considerable time a dead letter, for we find a great English surgeon writing nearly half a century later: "There are few surgeons who would have the hardihood of Dupuytren, who plunged a bistoury into the substance of the brain and thus luckily relieved the patient of an abscess in this situation." Dupuytren, in his account of this historical case, says simply: "I incised the dura mater, nothing came out; I thrust a bistoury cautiously" (? so as to avoid the vessels of the cortex) "into the brain and there welled up immediately a flood of pus. That very night all the symptoms disappeared and the patient recovered."

If careful exploratory puncture with the knife fail to find the abscess, the finger inserted into the brain substance will almost infallibly detect the presence of a tense, abnormal swelling, and however deep the abscess is it may be safely opened by the knife guarded by the finger. Mistakes, however, may still be made, as in two cases I treated many years ago. In one of these one cerebellar abscess and in the

other two had been opened, yet both patients died from an unopened abscess, oyster-like in shape, lying immediately beneath the cortex of the upper surface of the cerebellar hemisphere. The examining finger felt the sensation of resistance, but this was attributed to the tentorium.

The stalks of these abscesses would probably have been found and their contents evacuated had they been approached by way of the disease in the temporal bone.

Progress of the Case.

The course of brain abscess is, as I have shown, very variable.

The earlier the operation is carried out the greater the chance of success, hence the condition having once been diagnosed action should never be delayed.

I have known of cases where operation has been arranged for the following morning, but the patient died in the night.

Unless the patient is actually moribund the operation should be done. Even cessation of respiration is no bar to success in cases of brain abscess, for the operation has been carried out during the performance of artificial respiration and the patient has recovered.

After the operation the patient may rapidly convalesce or may present symptoms which will tax to the utmost the resources of the surgeon. A voracious appetite is a favourable sign.

Just as symptoms may arise after an operation for appendicitis which give rise to anxiety lest the infective process should still be in progress, but which are merely due to temporary paralysis of the gut or to some other manifestation of the functional disturbance of the abdominal contents caused by the disease or the operation ; so after an operation for the relief of an intra-cranial infection, symptoms such as vomiting, fever, and delirium may continue or newly arise during convalescence and give rise to similar anxiety, but may nevertheless be likewise due merely to disturbance of cerebral function and not call for operation. Apart from this, however, it is by no means uncommon to have definite recurrence of symptoms a few days after the evacuation of an abscess of the brain, due either to the re-filling of the abscess cavity from faulty drainage or to the formation of a new abscess in another part of the same lobe. The new symptoms are much modified by the skull being opened, and may suggest conditions, such as meningitis or acute distension of the ventricles, which are not present. The surgeon must not suffer himself

to be led astray by idle speculations as to the explanation of the symptoms, but must concentrate his attention on the region where he has already found abscess, and whatever the symptoms may be must explore the same region of the brain.

During apparent convalescence some cases of brain abscess begin to retrograde without evident reason, and finally end fatally. A similar event occurs occasionally after the removal of large brain tumours, and depends on a general nutritional failure. In these cases large areas of brain are involved, and the healing process exhausts the vitality of the patient.

In my surgical life the evolution of the operation for brain abscess has advanced a good stage towards perfection. Not many years ago but few surgeons had even made any attempt to operate for brain abscess; but at the present time in every surgical clinic such operations have been performed.

Although we are at present only on the threshold of a perfect understanding of the surgical treatment of abscess of the brain, yet the labour of many workers during the last twenty years has not been in vain, and the future is bright with promise.

REFERENCES.

- BRISTOWE. *British Medical Journal*, 1891.
- CLAYTOR. *Philadelphia Medical Journal*, March 2, 1901.
- STOLL. *American Journal of the Medical Sciences*, Feb. 1906.
- BLÖTTCHE. Quoted from Stoll.
- CAYLEY. *Pathological Society's Transactions*, vol. xxxv. (1883), p. 12.
- PYE-SMITH. *Pathological Society's Transactions*, vol. xxviii. (1876), p. 4.
- RUDOLPH MEYER. *Zur Pathologie des Hirnabscess*, 1867.
- NEWTON PITT. *British Medical Journal*, 1890.
- PREYSING. *Zeitschrift für Ohrenheilkunde*, vol. xxxv. p. 108, and vol. xxxvii. p. 208.
- SALZER. *Wiener klinische Wochenschrift*. Band iii. No. 34.
- MANASSE. *Zeits. f. Ohrenheilk.*, vol. xxxi. p. 226.
- SWAIN. *Zeits. f. Ohrenheilk.*, vol. xxxi. p. 351.
- BERGMANN. *Die Chirurgische Behandlung von Hirnkrankheiten*. Third edition.
- KUMMEL. *Zeits. f. Ohrenheilk.*, vol. xxviii. p. 259.
- RONCALI. In *Chipault. État actuel de la Chirurgie nerveuse*, vol. iii.
- JACKSON and BEEVOR. *Brain*, 1887.
- FERRIER. *The Functions of the Brain*.
- MILLS. Article in *Dercum's Text-Book of Nervous Diseases and other papers*. Broadbent, Charcot, Ross, Bastian, quoted from Mills.
- PREYSING. *Archiv f. Ohrenheilk.*, vol. li. p. 266.
- BRISSAUD and SOUQUES. In *Traité de Médecine*, Charcot-Brissaud. Second edition, vol. ix.
- PIORRY. *Traité de Diagnostic* (1838), vol. iii. p. 294.
- BEEVOR and JACKSON. *Loc. cit.*
- RONCALI. *Loc. cit.*
- BRISSAUD and SOUQUES. *Opus cit.*
- OKADA. *Diagnose und Chirurgie des Otogenen Kleinhirnabscess*.
- PARADISE LOST. *Book vi.*, line 346.
- DUPUYTREN. *Leçons Orales*. Second edition, vol. vi. pp. 183-84.

158 SOME POINTS IN THE SURGERY

ERICHSEN. The Science and Art of Surgery. Seventh edition, (1887), vol. i.

STEPHEN PAGET. Clin. Soc. Trans., vol. xxx., "On Cases of voracious Hunger and Thirst from Injury or Disease of the Brain." The suggestion is made that there are special centres in the brain for the perception of hunger and thirst, situated near the olfactory centres.

Note to page 115.

I have recently had another case illustrating anomia.

J. B., aged thirty-four, was admitted to the National Hospital under Dr. Beevor. He had had discharge from the left ear ever since he could remember. Last January a mastoid operation was done at a throat hospital in London, but the otorrhœa was not arrested.

On admission to National Hospital in August there was discharge of thin pus from the left ear, double optic neuritis, and occasional pain in left mastoid and temporal regions.

Operation.—Tegmen carious. This was removed, and the dura above it was then seen to be inflamed.

A few days later dura gave way, and a hernia cerebri formed. I then discovered that the patient could not name any object such as a watch, scissors, or pencil, though fully understanding what they were. Two days later patient became drowsy, and a small abscess of thin pus was evacuated by passing a knife up through the opening in the dura through which the hernia protruded. A few days later the patient died.

Autopsy.—Spreading septic softening without boundary wall involving second and third temporo-sphenoidal convolutions, and adjoining temporo-occipital convolution. The tip of the temporo-sphenoidal lobe and the first temporo-sphenoidal convolution were not

involved. There was also meningitis diffused over the base of the brain, not over the vertex.

Remarks.—Patient probably entered the hospital with commencing infection of the temporal lobe. It would have been perhaps better if I had incised the dura in the first instance, but spreading septic cerebritis is always a very fatal disease.

*Case of left Temporo-Sphenoidal Abscess without Anomia
or other Speech Defect.*

B. H., a man aged twenty-seven years, was admitted to St. Thomas's Hospital in July 1907. In childhood he had an attack of measles followed by discharge from both ears. On the right side the discharge soon ceased, but on the left it persisted in greater or less amount. Six days before admission he was seized, while at work, with headache and was obliged to return home, he vomited once at the commencement of the attack but the vomiting had not been repeated and the headache subsided. On admission there was an abundant foul-smelling purulent discharge from the left ear and slight œdema over the mastoid. Temperature 100, pulse 60. The right drum was scarred from old disease, watch heard on that side at four inches. The mental condition seemed slightly dull but was difficult to estimate on account of the bi-lateral deafness. Fine rapid nystagmus in all directions. No oculo-motor paralysis. No optic neuritis. No complaint of headache. Tongue furred. No facial weakness. Could name all objects and speech was normal. Right knee-jerk more brisk than left. Plantar reflex flexor on both sides. No loss of power in limbs. The blood count did not show leucocytosis. Vomiting, pressure symptoms, and

leucocytosis were absent probably owing to the partial drainage of the abscess through the stalk, the opening in the dura and tegmen allowing the pus to discharge into the tympano-antral cavity.

Complete mastoid operation. Tegmen carious and pus coming through a small opening in it. Tegmen removed. Small extra-dural abscess, an aperture seen in the dura mater from which pus was welling out. This aperture was slightly stretched and two tubes were introduced through it into the temporo-sphenoidal lobe giving exit to quite $1\frac{1}{2}$ oz. of pus. One tube was removed at the end of a week and the other a week later. The wound, but not the abscess cavity, was irrigated daily with hydrogen peroxide. No hernia formed. Cultures made from the pus yielded streptococcus pyogenes and staphylococcus albus. Five weeks after the operation, the patient being apparently well, and about to leave the Hospital for a Convalescent Home, he was seized with sudden severe pain in the head, became comatose, and died in a few hours. I was absent from London at the time. No post-mortem examination was allowed.

LECTURE III

SOME POINTS IN THE SURGERY OF TUMOUR OF THE BRAIN

Diagnosis—Difficulty of localisation—Symptom-complex—Absence of all symptoms—Localisation symptoms—Relation of injury to tumour growth—Tumours of the cranium, the meninges, and the brain—Tubercular and syphilitic tumours—Endothelioma—Fibro-sarcoma—Glioma, solid and cystic—Sarcoma—Psammoma—Cysts—Secondary tumours—Treatment without operation—Operations, curative and palliative—Pioneer work of the past, the present position, and future outlook.

I APPEAR before the Society this evening to speak of the surgery of tumours of the brain not as an apologist but as a modest exponent of a splendid and established department of general surgery. It would be impossible in the course of a single hour to give any adequate account of so vast a subject as that of intra-cranial tumours. I shall attempt no such task, but shall only endeavour, in a somewhat elementary manner, to draw your attention to the resources which surgery offers for the relief or cure of these terrible cases. Not many years ago very few felt any enthusiasm for the surgery of the central nervous system, and our early efforts were received by the majority with, at best, friendly scepticism.

Even now the advance made in this department of surgery has received less recognition than it deserves, and one reason that influenced me in choosing this subject was that it would enable me to review my personal experience and perhaps to arouse in others an interest as yet latent.

In a monograph on the subject published last year the results of 400 operations for brain tumour are discussed. In a large proportion notable improvement or cure resulted, and in some instances even recurrent growth was successfully dealt with. Still more recently an American surgeon has analysed the results of 116 operations for tumour of the cerebellum alone.

Some twelve years ago, in conjunction with my friend and colleague Dr. Bevor, I brought before this Society a successful case of operation for brain tumour. We expressed the conviction that in a few cases of brain tumour the growth could be extirpated and the patient definitively cured, in others partial removal would give material relief and prolong life, and in yet others, though the tumour itself had to be left untouched, the relief of intra-cranial pressure by opening the dura would so modify the symptoms as to restore the patient to comparative comfort.

I shall not discuss the ætiology or the morbid anatomy of brain tumours. I have elsewhere

expressed my opinion as to the ætiology of tumours in general, and that of brain tumours does not differ therefrom. Certain histological varieties of tumour are peculiar to the brain, otherwise the morbid anatomy of brain tumours is that of tumours elsewhere.

In this connection I use the word tumour in a wide sense as including cysts, and the products of the infective granulomata as well as neoplasms proper, inasmuch as clinically and surgically they are all "tumours."

The following is a list of cerebral tumours the majority of which are of surgical importance :—

Intra-Cranial Tumours.

I. *Epiblastic tumours*—

- A. Cerebroma.¹
- B. Glioma, glio-sarcoma, angio-glioma.
- C. Epithelioma. Developed from the epithelium of the ependyma, the choroid plexus, the pineal gland, or the pituitary body.
- D. Cholesteatoma vera.

II. *Mesoblastic tumours*—

- A. Sarcoma ;² of skull, of meninges, of brain

¹ Localised hypertrophy of the brain of developmental origin not sharply defined from the rest of the brain substance, but sometimes in more or less defined nodules. This form of tumour is described and figured by Ziegler (11th Edition, 1906) as neuro-glioma ganglionare.

² Osteoma and lipoma occur in the brain : see references in paper by Parkes Weber and Paul Daser, *Path. Soc. Trans.* 1907. Max Borst, vol. i.

- substance (probably arising from the walls of the intracerebral vessels), of the pineal gland, of the pituitary body.
- B. Endothelioma; meningeal. (The fibroplastic tumour of Lebert.)
- C. Fibroma. Fibro-sarcoma.
- D. Psammoma. Angio-lithic sarcoma.
- III. *Secondary tumours*: metastases from carcinoma or sarcoma of other regions.
- IV. *Cysts*.—Simple cysts. Hæmorrhagic cysts. Parasitic cysts. Intra- and extra-dural dermoids.
- V. *Tuberculous tumours*.
- VI. *Gummata*.
- VII. *Vascular tumours*.—Aneurism.



FIG. 62.—Glioma of frontal lobe. (R. C. S. Museum, 3782, A.)

A section through the right hemisphere, showing a large rounded glioma, 3 inches in diameter, which occupies the whole of the frontal lobe. Anteriorly and above, the tumour projects upon the free surface; below, it is bounded by a thin band of brain substance. Its margin is well defined; its section is homogeneous and in parts flocculent. From a man, aged 25, who had been for a long time under treatment with double optic neuritis, occasional convulsions, and paresis on one side. An attempt was made, but failed, to get at the tumour to enucleate it. (Presented by Dr. Goodhart, 1885.)

p. 167, mentions bony tumours having been found in the cerebral hemisphere, the basal ganglia, the cerebellum, and the meninges. These bony tumours have no connection with the bones of the skull (discontinuierlichen osteome) and are comparable to similar tumours sometimes found in the lung and in muscle.



FIG. 63.—Cholesteatoma vera of cerebellum. (R. C. S. Museum, 3779 B. Presented by Miss Knowles.)

A cerebellum, between the lateral hemispheres of which there projects a large cholesteatoma, which has grown from the situation of the fourth ventricle. The tumour has an extreme diameter of about two inches, is of irregularly spheroidal form, in places mammillated, and presents throughout the pearly lustre characteristic of this class of new growth.

The patient, a well-developed woman of 30, complained of pains in the back of the head "like knives"; a feeling of weight on the top of the head; of a sensation of "pins and needles" in the hands and feet; and of inability to walk. She had enjoyed good health until two years ago, when she was noticed to stagger in walking; the difficulty in locomotion increased steadily, and of late she had been constantly falling. The pains in the head and the other subjective sensations were of only three weeks' duration. No history of syphilis, otitis, injury to the head, or alcoholism could be obtained. On admission she was a well-nourished woman, of medium height and sallow complexion; her mental state was dull, and she was slow in answering questions, but did so correctly. Speech was thick and indistinct, resembling that of a general paralytic. The tongue was protruded in the middle line, and was distinctly tremulous. The breath was offensive. The gait was a staggering one with the feet wide apart, and the arms extended to preserve the balance. There was a constant tendency to fall to the left, and Romberg's symptom was well marked. The muscular power in both lower limbs was good; no tenderness on pressure, no rigidity, muscular wasting, or anæsthesia could be detected. The knee-jerks were present on both sides, but exaggerated; ankle clonus was not obtained. In the upper limbs the only thing noted amiss was a slight impediment of muscular sense. As regards the head, there was slight but distinct tenderness to percussion and pressure over the whole of the occipital region, but it was not more marked on one side than on the other; there was no facial or ocular paralysis, and no nystagmus. Pupils equal, moderately dilated, reacting readily to light and accommodation.

The bladder acted normally; the bowels were obstinately constipated. The patient lay quietly in bed and slept well at night; she complained of moderately severe occipital headache; there was no vomiting; the appetite was good, and the temperature varied between 97°.4 and 99°.2. Pulse normal. On September 24, five days after admission, she became restless, attempting to get out of bed: at intervals she would lie quietly curled up on the left side. Towards evening the pulse became very rapid, respiration failed rather suddenly, and she died, remaining conscious almost to the last.

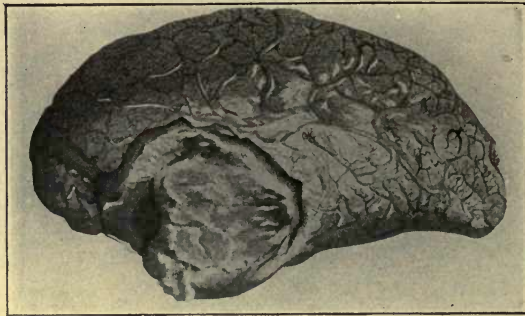

FIG. 64.—Endothelioma of meninges of temporal lobe. (Dupré and Devaux.)

Male, aged 34 years. History extending over 2½ years.

The symptoms observed were headache, vomiting, vertigo, troubles of memory, mental dulness, progressive blindness from optic neuritis and atrophy; then epilepsy, slight local paresis, dementia, coma, and death. Large circumscribed, spheroidal tumour, size of an orange at the base of the left hemisphere, compressing the orbital lobe, the insula, and the tip of the temporo-sphenoidal lobe. An endothelioma of the arachnoid.

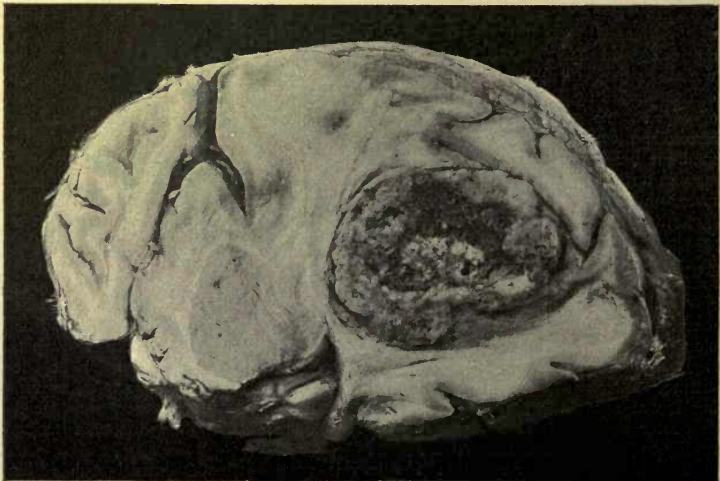

FIG. 65.—Carcinomatous deposit in centrum ovale, secondary to growth in œsophagus. (Norfolk and Norwich Hospital Museum, No. 170.)

P. L., aged 50. Male.

Admitted September 8, 1900, complaining of loss of power in left arm, which came on after two recent fits, one three weeks ago, and the other two weeks ago.

OF TUMOUR OF THE BRAIN 167

When admitted he had complete paralysis of left arm, none in leg. Hard, irregular tumour in epigastrium.

October 9.—Convulsions of left arm, double optic neuritis, proptosis of left eyeball.

„ 18.—Another fit of same character to-day, with no loss of consciousness. The fits continued up to October 30, when he died; the left arm gradually became contracted and rigid, and some contraction also developed in the left leg.

P.M.—Hard, carcinomatous growth, size of a fist, at the lower end of the œsophagus. Many growths throughout lungs and in liver.

Large tumour under Rolandic area and right half of brain, extending almost from the frontal to the occipital lobe.

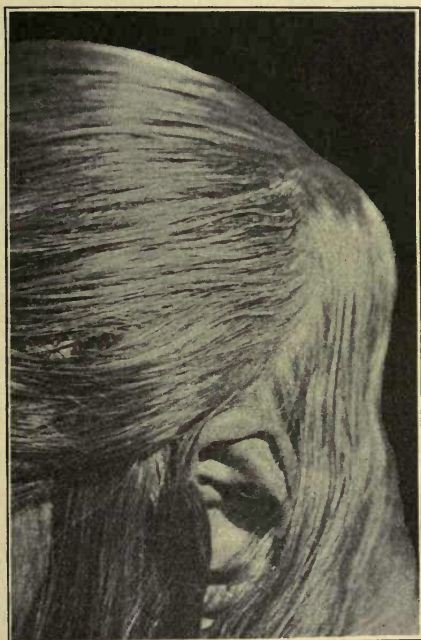

FIG. 66.—Carcinomatous deposit in the skull secondary to Scirrhus mammae.

E. A. S., aged 70 years.

April 1904.—Removal of left mamma and axilla by Halsted's method for spheroidal celled carcinoma.

August 1906.—Above photograph taken. Tumour had been noticed three months before. There was no pain, no tenderness on pressure, and no cerebral symptoms. Patient otherwise well; region of primary operation healthy.

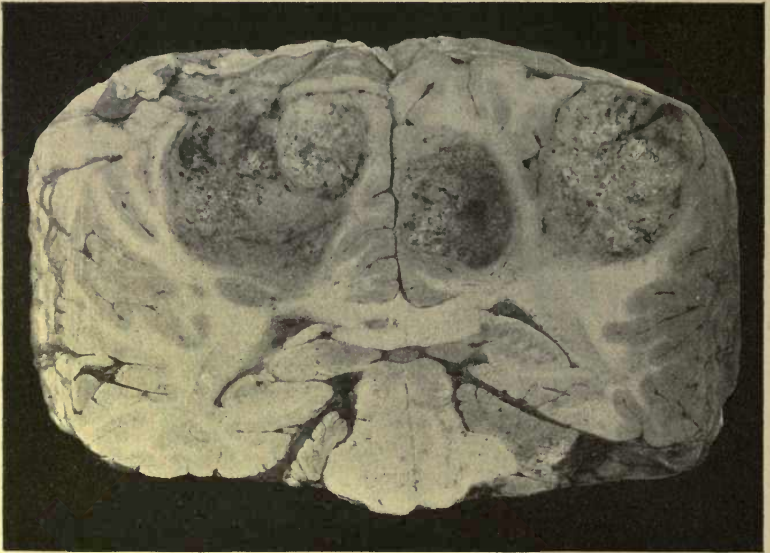


FIG. 67.—Sarcoma of brain (multiple growths), secondary to sarcoma of lung. (Norfolk and Norwich Hospital Museum, No. 166, A.)

S. M., aged 24. Male.

Admitted August 7, 1902.

Quite well on August 3. Cough and expectoration began on August 4.

August 9.—Three fits, beginning in right arm. Fits occurred almost every day for two months, sometimes five or six in one day; often confined to right hand. At the end of the two months patient had distinct hemiparesis, but could walk about, dragging right foot.

November 13.—The fits have continued in lessening number since last note; purulent expectoration, double optic neuritis.

November 25.—Left motor area exposed, and soft, non-encapsulated growth scooped out.

December 8.—Much purulent expectoration; power in right arm increased considerably as result of operation.

December 13.—Fits recommenced.

January to March 1903.—Much vomiting and headache; large hernia cerebri. Died March 8, 1903.

P.M.—Large new growth in lung. Multiple secondary growths in brain.

The microscopical section shows the cells arranged in groups around the blood-vessels. The cells are mostly round; some are oval and spindle-shaped.

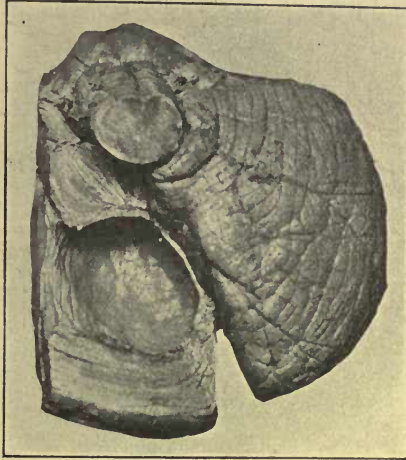

FIG. 68.—Simple cyst of right cerebellar hemisphere.
(St. Thomas's Hospital Museum, Path. Series, Part iii. 2013.)

From a girl, aged 14, admitted under the care of Dr. Bristowe, November 4, 1887. Three months before her admission her sight began to fail, strabismus and double vision being observed; in a few weeks vomiting and headache came on, but during all the time there had been no giddiness and no fits.

On admission there was severe double optic neuritis, and sight was much impaired, the left eye having no perception of light; convergent strabismus of the left eyeball. Hearing was impaired on the left side. There was no paralysis or staggering, and no loss of sensation. During the five months she was under observation in the hospital there were frequent attacks of headache and vomiting. Six weeks after admission she was blind, and the optic discs were becoming atrophied. During the last three months there were rather frequent fits, during which consciousness was lost, the head thrown back, the eyes fixed, and the extremities rigid. (Dr. Hadden, *Path. Soc. Trans.*, vol. xli. p. 17.)

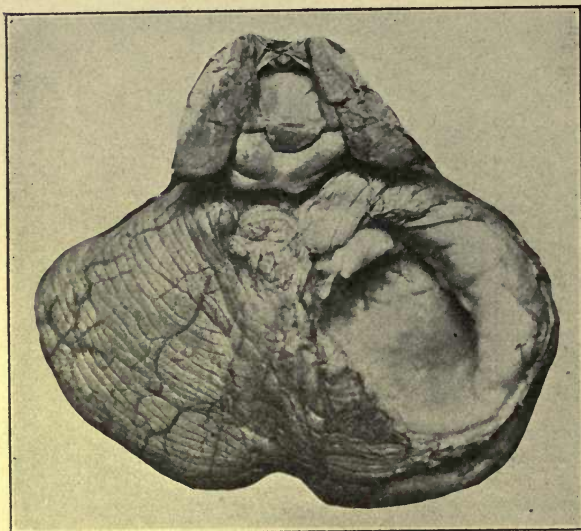


FIG. 69.—Simple cyst of right cerebellar hemisphere.
(St. Thomas's Hospital Museum, Path. Series, Part iii, 2012.)

J. T., aged 22, admitted under Dr. Stone, October 15, 1878. From the age of twelve years he had been frequently attacked with severe headache, not localised to any particular region. For the three or four past years he had noticed some loss of power in the right upper and lower extremities. About four months before admission the patient was struck on the back of the head by two heavy shutters, and since then he has not been free from headache; about a week or two later vomiting became a pretty frequent occurrence, and did not seem to have any relation to taking food; his sight became dim, and shortly before entering the hospital he had some kind of convulsive attack. Marked optic neuritis was found by Mr. Nettleship. On November 4 he had a fit of fainting, with severe headache and rigor, vomiting and retching. On November 5 the report states that he had had many severe rigors, unaccompanied with rise in temperature. He was suddenly attacked with stertorous breathing, became comatose, and died in ten minutes.

Autopsy.—Except for the cyst of the cerebellum shown, the rest of the brain appeared normal, and there was no important disease of any of the other organs. Microscopic examination showed no cyst wall apart from the condensed tissue of the cerebellum. There was no evidence anywhere of hæmatoidin crystals or granules.

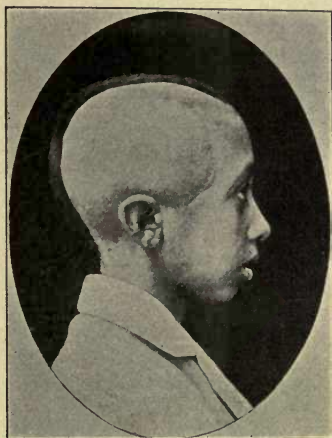

FIG. 70.—Hydatid of right frontal lobe. (Herrera Vegas, *Chipault*, iii.)

Boy, aged 14 years. Operation. Recovery.
Recurrence one year later. Operation. Death.

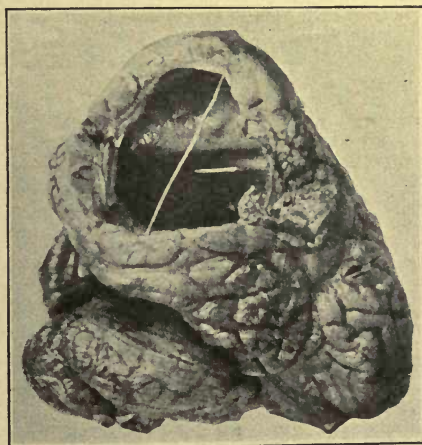


FIG. 71.—Hydatid of right lateral ventricle removed through post-Rolandic region. (Herrera Vegas, *Chipault*, iii.)

Boy, aged 8 years. Headache; vomiting; left hemiplegia.
Operation. Cyst size of fetal head enucleated.
Death on third day.

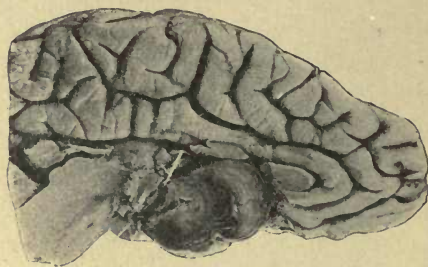


FIG. 72.—Aneurism of the intra-cranial portion of the left internal carotid artery. (R. C. S. Museum, 3795 D. Presented by C. F. Beadles.)

The anterior portion of the left hemisphere of a brain. In connection with the left internal carotid artery, immediately on its entry within the cranial cavity, there has formed a somewhat bilobed aneurism about an inch and a half in chief diameter; the sac is mostly filled with firm laminated clot, but through the centre of this is a narrow cleft which held recent coagulum and fluid blood. A piece of glass has been passed from the divided end of the internal carotid artery (which is cut across close to the sac) into the aneurism, between the wall and the clot. Another rod of glass has been passed from the same divided end of the artery, behind the sac, along the anterior cerebral, and out by the anterior communicating, which vessels lie on the superior aspect of the aneurism. The aneurism is imbedded chiefly in the under part of the left frontal lobe, but it also compressed the frontal lobe of the right side; posteriorly it extends over the infundibular space; the roots of the olfactory and optic nerves were seriously damaged. Blood was found extravasated into the pia-arachnoid, between the frontal lobes and the sac; the source of this blood, which has been removed, was apparently the left anterior cerebral artery. The other cerebral arteries appeared healthy. The kidneys were reduced in size and granular.

From a female, aged 48, who died August 13, 1902. She was the subject of aural hallucinations, optical delusions, and delusions of electrical annoyance, and had been violent towards her relatives. She was melancholic.

On February 19, 1897, she is said to have complained of "a hissing noise in her head, which she thinks due to electricity"; she complained of a voice continually annoying her. Outward divergence of the right eyeball was present, and there was a very slight tendency to paresis of the right side of the face.

On April 2, 1898, she was in a depressed mental state. She complained that "when she sneezes under the bedclothes she sees the bronze flash from her eyes; says she is being bronzed, and that electricity is applied to her." The condition of the eye was much the same, but the facial paresis had slightly advanced. For two years or more there was little change in her condition. The aural hallucinations and optical delusions persisted; she heard men under the floor, who applied electricity to her; she saw "spirits flying about," which gave her great annoyance, and which occasionally made her excited. She would suddenly stamp on the floor and throw things at the spectre, but generally she was inclined to be melancholic. Her hearing remained good, and there was never any indication of defect of sight; she did needlework almost up to the last. During the last year of life the right eyeball became more markedly turned outwards. There was never any form of fit or seizure. Speech was unaffected, and she was always fairly coherent. There was occasional vomiting, unassociated with food, during the last few months. She never complained of pain in the head, and there was never any attack of giddiness. She gradually lost flesh, and although looking ill, never spoke of feeling so.

On August 9, 1902, she had a sudden apoplectic seizure, and remained in a comatose state for four days, and then died.

Operations.

I propose to bring before you examples of the various operations that may with advantage be performed and thereby to attempt an answer to the question, "What do patients suffering from tumour of the brain gain from surgery?"

1. In the first place a well-defined and accessible tumour such as fibroma or endothelioma of the meninges can, and should, be completely removed. No time need be spent in arguing the value of such an operation.

2. Local solitary manifestations of tubercle and sometimes of syphilis should be removed. An excellent example of removal of a syphilitic tumour is published by Bardesco. The patient was a man thirty-six years of age and had hemiplegia, from which he completely recovered. A successful case of removal of a gumma of the left cerebellar hemisphere by Horsley is published in *Brain*, vol. cviii.

3. Infiltrating growths, such as glioma and sarcoma of the brain, can but seldom be completely removed, chiefly because in the living brain there is often no visible and obvious line of demarcation between the brain and the tumour tissue. The gain after partial removal is that the tumour grows more slowly. The

partial removal of a malignant tumour of another part of the body, say the mamma, is followed by continued or even more rapid growth, but the partial removal of a malignant tumour of the brain appears in some instances to have a contrary effect. This probably results from the profoundly altered physical conditions being less favourable to the local absorption of toxin and to the growth of the essential elements of the tumour. An operation which would deprive the patient of the power of speech is not justifiable.

4. Cysts, simple, hydatid, or malignant, should be dealt with by drainage or by ablation, according to circumstances. Herrera Vegas of Buenos Ayres has operated successfully for hydatid cysts, and MacHill of Melbourne has collected thirteen cases of operation for hydatid of brain performed in the Australian colonies, in six of which complete cure resulted. The same author refers to five cases in which operation had been decided upon but the patient died before the date that had been fixed for it. In hydatid of the brain, as in abscess, sudden aggravation of symptoms is liable to occur, and no delay is permissible when once the diagnosis has been made.

Many cases of operation for hydatid of the brain have died from early hyperpyrexia. Bird of Melbourne states that this is due to hæmor-

rhage into the cavity left by the operation, and to prevent this result he has successfully practised filling the cavity left by the operation with gauze and allowing this to remain in place for six days.

I have never operated for hydatid of the brain, but I have successfully done so for hydatids of the spinal canal causing paraplegia.

5. When the tumour cannot be localised, or is too deeply placed for removal, the skull and dura should be opened so as to relieve the intracranial tension. No patient should be allowed to become blind from optic neuritis.

A woman, aged forty-one years, was admitted to the National Hospital, under Dr. Buzzard, with symptoms pointing to tumour pressing on the internal capsule: hemianæsthesia, hemiplegia, severe headache, and failing sight from optic neuritis. She became comatose after a paroxysm of pain. I opened the skull and dura. Consciousness returned, and the headache, optic neuritis, and vomiting were completely relieved. There was even, a month later, some return of power and sensation in the paralysed limbs.

Again, a man of forty was admitted to the National Hospital, under Dr. Buzzard, with agonising headache, vomiting, and intense optic neuritis. For certain reasons the tumour was located in the left cerebellar hemisphere. I removed the bone and dura over this region, but found no tumour. The man recovered and returned to work. He died eighteen months later, when a large tumour was found in the right frontal region.



FIG. 73.




FIG. 74.

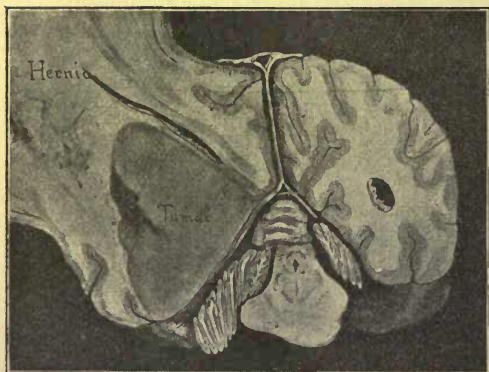


FIG. 75.

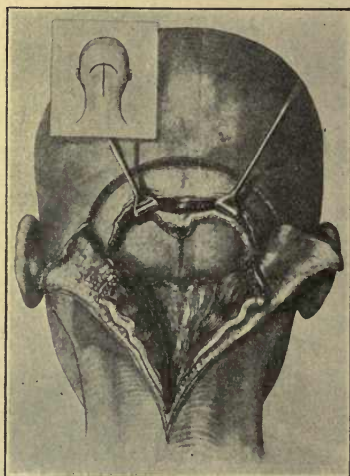


FIG. 76.

FIGS. 73, 74, 75, and 76.—The establishment of a cerebral hernia as a decompressive measure for inaccessible brain tumours. (Harvey Cushing.)

FIG. 73.—Male, aged 32, one month after decompressive operation over left occipital lobe.

FIG. 74.—Size and condition of hernia one year after the first operation.

FIG. 75.—Drawing of section of brain which passed nearly through the centre of the tumour, which was a glioma. Note the deflection of the ventricle toward the hernia. The tumour occupied in large part the entire site of the occipital lobe.

FIG. 76.—Sketch of the field of operation before opening the dura, in the sub-occipital procedure. Note the high transverse cut of the "crossbow" incision.

OF TUMOUR OF THE BRAIN 177

The patient (Figs. 73, 74, 75) had suffered from headache for two years. On admission to hospital the headache was very severe, with mental dulness, intense double optic neuritis, projectile vomiting, tenderness over left occipital region, and some weakness of right face and arm. There was also complete right homonymous hemianopsia. The operation was not done by the intermuscular method, hence the large size of the hernia. "An intermuscular operation would probably have left the patient without his disabling astereognosis, and so capable of working, and at the same time able to amuse himself with reading, a resource from which he was entirely cut off." It is not clear why an attempt was not made to remove this occipital tumour. Cushing gives an admirable example of an intermuscular decompressive operation in a case of sarcoma of the optic thalamus. It was from the desire to control these formidable herniæ that he hit on the plan of making the bone defect under the temporal muscle. He has carried out the same plan with success in the cerebellar region by making a "crossbow" incision: the transverse cut is high above the attachment of the muscles of the neck, which are subsequently sutured in layers. Cushing, in this paper, relates cases in which Nature carried out the decompressive operation in early life by separation of the cranial sutures. "There is a curious reluctance on the part of many surgeons to leave bone defects in the skull. Emphasis must be laid on the fact that in cases of brain tumour the defect is desirable. Owing to the inelasticity of the dura the removal of bone alone does not answer as a palliative measure. The hernia should be established over as 'silent' an area of the cortex as possible." There is no doubt in my mind that the dura must be reflected or removed in decompressive operations. The removal of even a large area of bone alters very little the volume of the intradural space. In an experiment performed with Prof. Sherrington many years ago, it was found (in the case of a recently-killed large dog) that only 0.54 ccm. of fluid entered the dural cavity in consequence of the removal of half the vault of the skull.

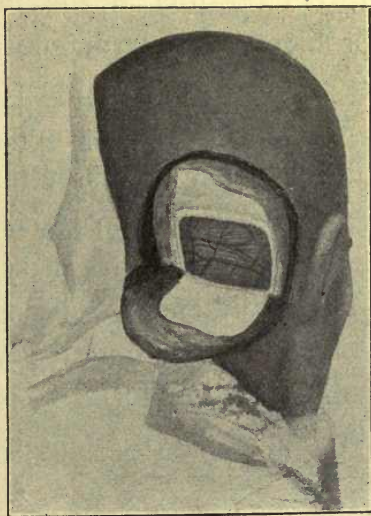


FIG. 77.—Exposure of cerebellum (R. hemisphere) by the usual method.
(From a drawing of an operation by the author.)

The opening is made behind the vertical and below the horizontal parts of the sigmoid sinus.

Contrast with Harvey Cushing's "intermuscular method."

N

Symptoms and Diagnosis.

The problem presented to the surgeon when asked to see a case of suspected cerebral tumour is three-fold.

1. Is there an intra-cranial tumour ?
2. If so, where is it ?
3. What is its nature ?

To the first question an answer can often with confidence be given, to the second much less frequently, and to the third rarely. In other words, we may usually be sure that a tumour is present, but its exact localisation often presents a perplexing, and possibly at the present time insolvable problem. The diagnosis depends mainly upon a correct interpretation of the symptoms presented; radiography, lumbar puncture, and percussion and auscultation of the cranium in some cases afford material assistance.

A complete exposition of the symptoms of cerebral tumour would entail a discussion of all that is known of cerebral function and its disturbance by disease. Only the general outline of the interpretation of symptoms can be given on this occasion.

In the first place we find that intra-cranial tumours give rise to a group of general cerebral symptoms, which are quite independent of the

seat or nature of the growth or of any particular lesion of the brain ; these symptoms are produced by—

- (a) Alteration of the intra-cranial tension.
- (b) Œdema, inflammation, or irritation.
- (c) Toxin absorption.

Headache, vomiting, and optic neuritis are the three main symptoms of this group ; “fits,” slow cerebation, vertigo, alterations of pulse and respiration are symptoms frequently associated with them. These symptoms may occur singly or in various combinations and in varying degrees of intensity, and may be regarded as the clinical expression of the influence exerted upon the brain as a whole by the intra-cranial growth.

In the second place, symptoms are produced which depend upon irritation or suppression of function of nervous centres, or interruption of commissural fibres connecting various centres with each other or with organs of sensation or motion.

These symptoms may be classified in ten groups :—

1. Mental phenomena.
2. Motor phenomena.
3. Oculo-motor phenomena.
4. Disturbances of associated movements.
5. Disturbances of equilibrium.
6. Speech affections.
7. Abnormal sensory phenomena.
8. Alteration of reflexes.
9. Special sense affections.
10. Modifications of

the general functions : circulation, respiration, secretion.

Guthrie, in 1841, in the opening paragraph of his well-known lectures, said, "It may even be said that there is no one symptom which is presumed to demonstrate a particular lesion of the brain, which has not been shown to have taken place in another of a different kind. Examination after death has often proved the existence of a most serious injury which had not been suspected ; and death has not infrequently ensued immediately, or shortly, after the most marked and alarming symptoms without any adequate cause for the event being discovered on dissection. Such are the deficiencies in our knowledge of the complicated functions of the brain, that although we can occasionally point out where the derangement of structure will be found, which has given rise to a particular symptom during life, the very next case may possibly show an apparently sound structure with the same derangement of function."

What Guthrie said of injury is, despite the advance made since his time, still true of cerebral tumour. The most eminent neurologists will occasionally differ as to the localisation of a brain tumour. In the fable men differed as to the colour of the chameleon, and all proved to be

right ; but in the localisation of a brain tumour, if observers differ, only one can be right and all may be wrong, and further, as I shall point out later on, there may be no brain tumour revealed either at operation or autopsy.

Are there, then, any symptoms which definitely indicate the position or even the existence of a tumour ? No one symptom alone will give us this information, but the association of certain symptoms do afford us, if not the certainty, at least a strong probability of the existence of this particular lesion. Neither headache, vomiting, optic neuritis, fits, vertigo, nor hemianopsia alone warrant the diagnosis of cerebral tumour ; but two or more of these symptoms in combination do constitute evidence of the existence of a brain tumour.

For example :—

1. Optic neuritis and headache : in the absence of anæmia and albuminuria.
2. Fits followed by paralysis or fits commencing with an aura and involving successively the various segments of one or both limbs in a regular order corresponding to the topography of the motor cortex.
3. Optic neuritis and unsteady gait.
4. Hemianopsia and optic neuritis.

It is impossible to exaggerate the importance of the presence of optic neuritis. The absence of this sign may make diagnosis

impossible, while its presence may clinch the diagnosis. The time and manner of evolution of symptoms are of equally great diagnostic importance, as also the absence of certain symptoms.

The clinical evolution of cerebral tumour varies greatly : there may be complete latency of all symptoms, and the tumour remain unsuspected until the autopsy, the patient either dying suddenly apparently from the tumour, or from some other affection during the course of which no symptoms suggestive of brain tumour are observed. In one such case the patient, himself a distinguished physician, died ten days after the operation of lateral lithotomy, no complication having occurred. At the post-mortem an encysted tumour as large as an egg was found in the right parietal region, containing a blackish pulpy material and masses of cholesterin¹ (*B.M.J.* 1875, ii. 453). In other cases one of the symptoms pointing to cerebral tumour, such as headache or vertigo, may be present, but a considerable time, even years, may elapse before other symptoms occur which warrant a definite diagnosis of cerebral tumour. In a case which occurred many years ago, under the care of Beevor and Horsley, the patient had occasional

¹ Oppenheim (*Diagnostik und Therapie der Geschwülste des Zentralen Nervensystems*, 1907, p. 45) relates a successful case of removal of a cholesteatoma vera from the cerebellar region.

fits with unconsciousness, beginning in the corner of the mouth six years before other symptoms arose which justified operation, and then the tumour was found so situated that it could not be removed without producing aphasia.

A man, aged twenty-three years, died in St. Thomas's Hospital, under the late Dr. Hadden, after

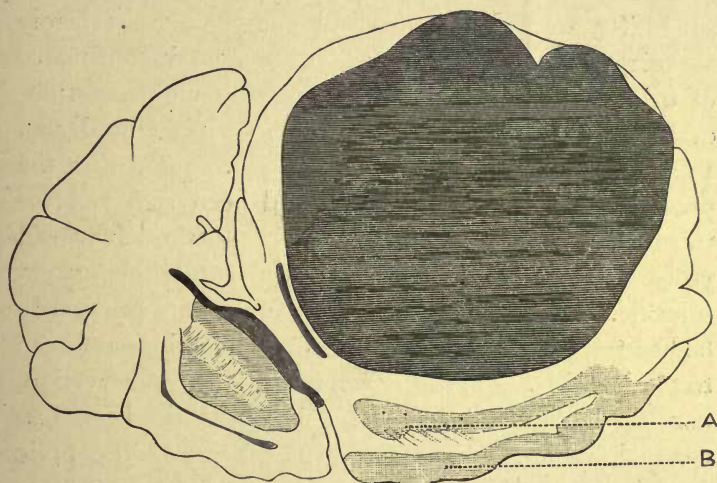


FIG. 78.—A case of tumour of the brain with a long history and with few symptoms. (Hadden.)

A, B, caudate and lenticular nuclei displaced and flattened out, with the internal capsule between them.

The tumour had destroyed the whole of the right frontal lobe, and had perforated the skull by pressure atrophy. The dura was firmly adherent to it for $2\frac{1}{2}$ inches. The tumour was probably of meningeal origin; it was composed of spindle cells.

having been comatose for fifteen hours. At the autopsy a large tumour was found that involved the whole frontal lobe and part of the brain behind, and had caused pressure atrophy of the frontal bone in more than one place. Twelve years previously he had received a severe blow over the right eye at football.

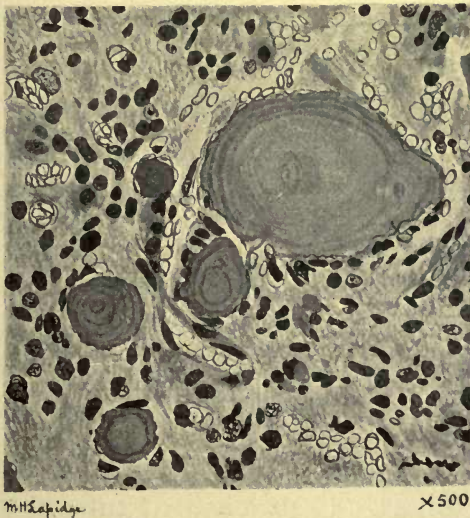
He had been in the hospital six years before his death, when he had fits, and again three years before his death with mental aberration, from which he recovered in ten days. He was a well-educated man, good at arithmetic and geometry, and an excellent draughtsman. The gravity of the case was not suspected till the onset of the final coma.

In February 1904 I saw, with Dr. Ferrier, a man, aged fifty-four years, who had complete right hemianopsia, double optic neuritis, occasional incontinence of urine, slight paresis, both of motion and sensation, of limbs on left side, and occasional occipital headache. In spite of his hemianopsia he had been a good shot the previous winter. Both testicles had been removed for tubercular disease, the right twenty, and the left fifteen years previously. There was no family history of tubercle. No history of syphilis. Five years previously he had "Catherine wheel" visual hallucinations referred to the left side. He had never had a "fit," nor vertigo, nor had he vomited. The hemianopsia had been discovered by Dr. Ferrier some months, and the optic neuritis some six weeks before I saw him. For some time he had noticed diminution in his power of walking. On 3rd March 1904 bone was removed over the right occipital lobe, and a few days later a dural flap thrown down. A very vascular tumour was found occupying the cuneus, and the outer aspect of the first and second occipital convolutions. The tumour, together with a tail-like prolongation which reached the descending cornu of the lateral ventricle, was enucleated from the centrum ovale without serious hæmorrhage. A recurrence subsequently took place and was removed, but the patient died two days after the operation.

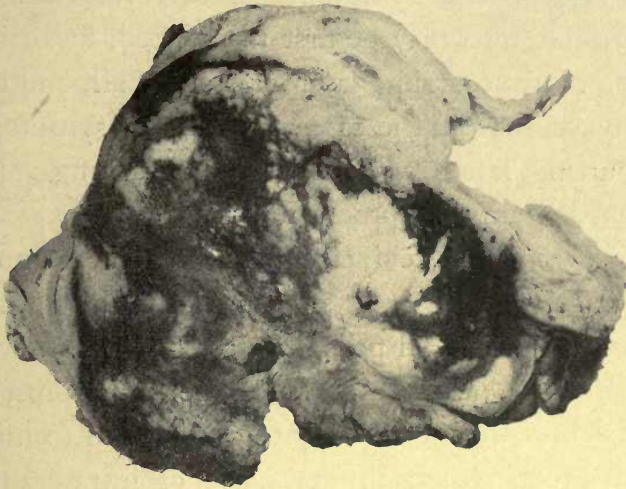

FIG. 79.—Photograph of psammoma (angioliathic sarcoma) of occipital lobe.
(Dr. Ferrier's case.)

Note the long process, above and to the right, foreshortened in the photograph, which reached to the middle corner of the lateral ventricle.



M.H. Lepidge

x 500

FIG. 80.—Microscopical section of tumour.

The general symptoms of cerebral tumour, the syndrome, may be first manifested, localising symptoms occurring later or not at all, and the converse may be the case. Localising symptoms occurring late have less definite localising value than the same symptoms occurring early.

We have no evidence that a brain tumour once developed ever spontaneously disappears, except gumma and perhaps tubercle.

In some instances though the symptoms, so far as our present experience goes, seem to indicate pretty clearly the presence of intra-cranial tumour, the course of events shows that this diagnosis is in error, and yet a critical review of the history and symptoms does not show why the diagnosis went astray. In this category may be included cases where the symptoms subside, and the patient remains well for years; fatal cases in which no tumour of brain is found; and cases that recover after an operation at which no tumour is found.

No error is fully confuted until we not only know that it is an error but how it became one, and until we are in a position fully to explain such cases, similar errors must continue to occur. Some may no doubt be explained by the spontaneous recovery from localised tubercle, or even syphilis, but all cannot in this way be accounted

for. In some of the cases in which operation is done there is distinct evidence of increased intracranial pressure, but none as to its cause. It seems that the symptoms we take as indicative of tumour are the clinical expression of a slowly increasing morbid process in the brain of which tumour is not the only possible cause. Nonne has drawn attention to these cases. Some instances given by him recovered after a course of anti-syphilitic treatment. It is true their recovery was delayed, but this does not exclude syphilis. It is doubtful whether such cases can fairly be claimed as examples of syndrome symptoms without tumour.

Sänger has pointed out that in some of these cases there are microscopic metastases in the brain from malignant growths elsewhere. Nonne makes some apt remarks on the difficulty or indeed impossibility of diagnosing some cases of chronic hydrocephalus from tumour of the posterior fossa.

I relate several cases with syndrome symptoms in which no tumour was found, and, by way of contrast, Dr. Hadden's case of tumour with no observed symptoms may be referred to (page 183).

The two following cases are taken from Nonne's paper :—

1. A man, aged twenty-six years, had without

evident cause, particularly without any reason to suspect syphilis, hemiparesis on the left side. This was accompanied by headache, occasional vomiting, and abnormal sensations on the left side of the body. A year and a half later he was admitted to hospital; besides the hemiparesis he then had exaggeration of deep, and diminution of superficial, reflexes, variable diminution in frequency of pulse, and slight optic neuritis on both sides. No impairment of sensation. The skull was not tender on percussion; the pupil reactions and speech were normal. Except for a slight central facial paresis on left side there was no affection of the cranial nerves. Consciousness and mental condition not altered. No improvement followed mercurial inunction. He went out after four weeks without noticeable change in his symptoms. He was readmitted six months later; the hemiparesis had become more intense, and the abnormal sensations on the left side had become more troublesome. He also at that time complained of double vision, and the left external rectus was paralysed. There were no convulsive movements and no fever. Urine and internal organs normal. No nose nor ear affection. Anti-syphilitic treatment renewed. Patient discharged in six weeks; no improvement. Five months later the patient presented himself well. No treatment had been adopted in the meantime. The "cerebral" condition of the reflexes was no longer present, and the fundus oculi was normal.

2. A man, aged thirty years, was taken ill without evident cause with headache, vomiting, and partial loss of consciousness; the symptoms gradually increased in severity, and there were abnormal sensations in the left arm and leg. On admission to hospital there was marked left hemiparesis and hemianæsthesia (for all

kinds of sensation). The hemiparesis was of cerebral type. Optic papillæ normal. Intra-dural pressure somewhat increased (250 mm. water). Torpor and headache at first only got worse under iodide and mercury, and the left external rectus became paralysed. After fourteen days improvement began, and in a month recovery was complete. Patient when last seen had continued regularly at work for eleven months, the only abnormality to be detected was that the left knee-jerk was more marked than the right, though not showing a pathological degree of increase.

Nonne also refers to a case in which there were marked symptoms of organic disease of the left motor cortex. An operation was performed, but the patient died as a result of injury to the superior longitudinal sinus. No tumour was evident to the naked eye, but microscopical examination demonstrated an infiltrating glioma unusually poor in cells.

I saw, in 1898, with Dr. Hawkins, Mr. A., aged thirty-two years. When seen he had paralysis of the left third, fourth, and sixth nerves, and anæsthesia of the second division of the fifth nerve, and slight prominence of the eye-ball on the left side. On the right side there was some weakness of the third nerve. There was no affection of any limb. Intense papillitis was present on both sides. Sixteen years previously he had had a severe fall over the handles of a bicycle. His illness commenced in 1897 with a fit; this occurred while he was walking in the street, but he quickly recovered consciousness and got up and

walked home. Two months later he began to suffer from giddiness. Six months after the first "fit" he had severe pain in the head, vomiting, and the subjective sensation of a disagreeable taste. He felt better after food. Not long afterwards he began to complain of diplopia. Optic neuritis was first observed eight months after the first fit. The anæsthesia of the second division of the left fifth nerve had been preceded by severe neuralgia. He improved considerably under potassium iodide. Later on his sight steadily deteriorated, headache and vomiting were renewed, fits and neuralgia of second division of fifth recurred and protrusion of the left eyeball was added to the symptoms. The first stage of operation was carried out on August 28th, 1898, and the dura opened on September 2nd. The fronto-sphenoidal region on the right side was examined. The brain bulged under great pressure, but no tumour was found. A few days after the operation the patient died. No tumour was found at the autopsy. Microscopical preparations were made by Dr. Purves Stewart from various portions of the brain, but no histological changes were detected.

Dr. James Taylor recently published a remarkable case:—The patient was in the hospital fifteen years ago; the history of the case is extremely interesting, as is also the sequel. He came first of all on account of severe headache and vomiting. He also had intense optic neuritis and right-sided weakness, affecting both the arm and the leg. In addition there was very great difficulty with speech. He became rapidly worse, the impairment of power in the limbs became much greater, and the weakness spread so as to affect the opposite side. In course of time he became completely para-

lysed in all four limbs. At this time he was also unconscious, taking no notice of anything which was said to him, and only swallowing, and that automatically, when anything was put on the back of his tongue. The surgeon's opinion was that it was not the kind of case in which operation could be reasonably expected to do good. The patient remained unconscious for about two months, completely blind and deaf. Then he began gradually to recover, and in some months he attained his present condition. The only disability with which he is left—a most unfortunate one—is a very grave defect in vision on account of the intensity of the optic neuritis, which had proceeded to atrophy. During fifteen years he has remained quite well except for that one defect. He is a man of considerable intellectual ability.

The case illustrates the fact that, however hopeless the condition of a patient may appear to be, it is possible for him to recover from a very severe degree of paralysis without impairment of mental functions. And it is also an instance of the permanent and grave impairment of vision which is the great danger in cases that recover. The question of the nature of such a tumour is one of very great interest, and in this case I think there was some reason for supposing that the tumour was probably tuberculous in character.

The following three cases are examples from my own experience of recovery after operation at which no tumour was found :—

1. A man, aged forty-three, under the care of Sir W. Gowers in the National Hospital. (Notes by Dr. Singer.) Father and two brothers died of phthisis. No previous illness except influenza in 1894 or 1895. No venereal disease. Began in May 1900 with head-

ache, which recurred daily, mostly in the evening, and was associated with nausea and on one occasion vomiting. Headache rather more severe on right side of forehead and vertex. Sight began to fail one month later, and he had diplopia. Soon after began to be deaf in right ear, and in August 1900 also in left. At that time he had lost 16 lbs. in weight in less than one year. *On admission*, August 24th, 1900, he was very slow and heavy, paused for some time before answering even a simple question, and spoke slowly, though without definite abnormality. No bulging or localised tenderness in the skull. Smell and taste normal. Vision, right, $\frac{6}{12}$; left, $\frac{6}{18}$. No contraction of visual fields to rough test. Well-marked optic neuritis, swelling on both sides, 2 D. Watch heard on right side at 4 feet, on left at 1 foot. Diplopia in all directions, but no obvious strabismus or weakness of ocular muscles. Right pupil larger than left, but both act well. No affection of motion or sensation. *September 7th.*—More drowsy, pain in head constant. O.D.'s much more swollen, being 6 D. on both sides. The left K.J. is now greater than the right, and the left plantar reflex is now of extensor type. No ankle clonus. *September 12th.*—A tender spot was found on the skull about the middle of the right half of the coronal suture.

Operation, September 12th.—Bone removed over right frontal region; bone very dense and thick and bled freely. Dura very dense and bulging. *Second Stage, September 20th.*—Dura opened and about 1 ounce of fluid escaped. Bulging of brain. No tumour seen or felt.

October 8th.—Free from pain since last operation.

Note.—The following abbreviations are sometimes used:—

O.D. = optic disc. K.J. = knee jerk.

A.J. = Achilles jerk. S.J. = supinator jerk.

Swelling of O.D.'s, right, 6 D. ; left, 6.5 D. ; one or two hæmorrhages in left disc. *November 9th.*—Leaving hospital to-day. Mental condition improved, but still dull. No pain, but is giddy when walking. Optic neuritis as before. Still has well-marked plantar extensor response on the left side.

After discharge was away in the country and steadily improved, lost his giddiness and could walk ten miles easily. No headache. *December 21st.*—Vision, right, $1\frac{6}{12}$; left, $\frac{6}{24}$. Right disc, no swelling; left, 1.5 D. Visual fields normal.

Patient remained quite well, getting gradually on to full work until *Easter* 1903, when he had some return of headache and giddiness, with mental obscuration and loss of appetite, lasting several weeks but finally passing off quite suddenly. A second similar attack came on about two weeks later, and he was admitted to St. Thomas's. He then presented a good deal of mental slowness, and had some frontal headache, not nearly as severe as before his operation. There was no fresh optic neuritis, and his vision was practically perfect. He still had an increased knee-jerk on the left side, with an extensor plantar reflex on that side, but no fresh signs. He left the hospital practically well, and when last heard of was quite well.

2. Mrs. B., aged thirty-two (patient of Drs. Ferrier and Purves Stewart).—Never robust; subject to anæmia. Married eleven years, three children, aged 10, 6, and 1 year. No injury or accident. No ear trouble. No scarlet fever. In September 1904, six or seven weeks after the birth of last child, began to have attacks of diffuse headache and violent nausea. Was lactating at the time, and continued to nurse child until it was three

months old. After, for two or three weeks, she had acute attacks every few days. The pain then subsided to an ordinary (retro-ocular) headache, such as she had been subject to since the age of sixteen. Headaches gradually became more frequent and more acute. At the end of April 1905 headache became associated with retching and with mistiness of vision, and with numbness in legs and inability to walk with comfort. Also felt faint when standing up suddenly or when walking up or down stairs.

July 18th, 1905.—Complains of headache, chiefly occipital and pain down back of neck, worse in the early morning. Headache reaches its maximum in about ten minutes, and is associated with intense nausea (no vomiting) and with mistiness of vision coming on in "waves." Occasional slight diplopia, no giddiness. Legs feel clumsy and wooden, especially the left. Intelligence, speech, and articulation normal. Patient left-handed. Intense double optic neuritis. Visual fields normal. Vision, right, $\frac{6}{24}$; left, $\frac{6}{18}$. Pupils, 2.5 mm. Left not quite circular externally. Ocular movements normal. Smell and taste acute on both sides. Hears watch at 6 inches in right ear, at 9 inches in left. Tuning-fork on vertex heard equally in both ears. Face pallid. Tongue normal. Sensory functions normal. No motor paralysis of limbs. Rapid rotatory movements of pronation and supination performed somewhat faster on left side. Movements of lower limbs not energetic, but none impossible. No ataxy of lower limbs. Gait feeble and uncertain. No spasticity. Can stand on either leg alone, but slightly more steadily on the left leg. Reflexes normal. Diffuse tenderness all over back of head. Lumbar puncture withdrew fluid under excessive pressure, in which a moderate number of lymphocytes were found. Heart,

OF TUMOUR OF THE BRAIN 195

lungs, and abdomen normal. Urine 1010, no albumen. Mr. Gunn reported 1 D hypermetropia in both eyes, 2 dioptries swelling in right disc, 3 dioptries swelling in left.

July 21st—First Stage of Operation.—Flap turned down in left occipital region. Large area of bone 3" × 2" removed. Dura tense and with little pulsation.

July 24th—Second Stage of Operation.—Dura opened and left occipital fossa thoroughly explored. No tumour found. Scalp wound closed. Dura not stitched.

August 1st.—For the first two or three days after operation patient felt as if she were sinking downwards through the bed. This passed off. Pupils equal and normal. Visual fields normal. No squinting. No diplopia. No nystagmus. Cranial nerves normal. No anæsthesia of face, trunk, or limbs. No motor weakness, or inco-ordination of upper or lower limbs as patient lies in bed. Reflexes normal and equal. Cerebro-spinal fluid still escaping from outer angle of wound. Wound otherwise healed. No headache.

August 10th.—All stitches removed several days ago. Temperature normal. No headache or vomiting. Discs examined to-day. Swellings rather less: about 1.5 D. in right eye, a little more in left.

August 30th.—Leaking of cerebro-spinal fluid continued until yesterday, when it ceased. Discs seen to-day by Mr. Gunn. Edge of right disc now clear except on inner side. Edge of left disc still blurred. Swelling less than 1 D. in each eye. No pallor. No contraction of fields.

September 13th.—Discs pink, but no measurable swelling. Rapid rotatory movements of forearms are less quickly performed on left side than on right, also slight unsteadiness in pointing to small objects with left foot. K.J.'s brisk and equal. Plantars flexor.

April 2nd, 1906.—Has been at Littlehampton for

six months. Still feels unsteady in going up or down stairs. Likes to be near surrounding objects, but does not reel. Some giddiness on stooping. No spontaneous giddiness. Goes downstairs always right foot first, comes up left foot first. Occasional neuralgic pain

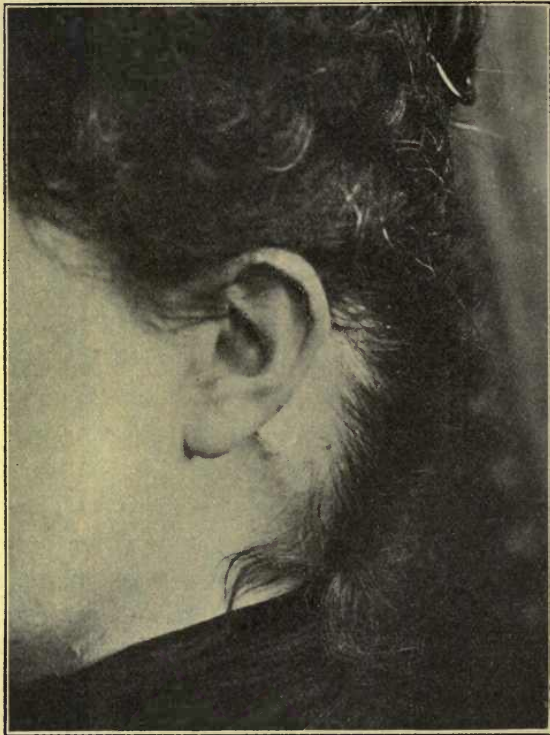

FIG. 81.—Mrs. B., patient of Dr. Ferrier, fourteen months after operation.
The flap still bulges considerably.

behind eyes if tired. Once or twice had nausea, but no vomiting. No diplopia. No unsteadiness in hands on sewing or crocheting. Marked bulge in left suboccipital region. Pupils and external ocular movements normal. No diplopia, no nystagmus. Face, palate, tongue normal. Hearing acute both sides. No anæsthesia.

OF TUMOUR OF THE BRAIN 197

Discs good colour, no swelling. K.J.'s and A.J.'s brisk and equal. Plantars flexor. No diadokokinesis. Slight tremor of left lower limb on pointing to objects. Stands alone on one leg, better on right leg than on left. Gait still slightly unsteady.

July 3rd, 1906.—No giddiness now, but still likes to be near surrounding objects. Still same method of going up and down stairs as before. No headache or vomiting. Left disc a little less clearly defined than right. Pupils and cranial nerves normal. No unsteadiness in pointing to nose with either hand. S.J.'s, K.J.'s, A.J.'s normal and equal.

Remarks.—In this case the symptoms seemed to point conclusively to the existence of gross disease in the occipital fossa, but were inconclusive as to the site of the disease. The greater relative prominence, tenderness, and dulness of the left cerebellar region, and the greater intensity of the optic neuritis in the left eye, led me to operate on that side.¹

3. F. T., male, aged twenty.—Sent to me by Dr. Bernard of Londonderry in September 1903. Paternal grandfather died of malignant disease in abdomen. Paternal aunt died of phthisis. No nervous or mental disease in any relation. Patient complains of recurrent attacks of vomiting. The first attack fifteen months ago, in June 1902. He had headaches for a couple of weeks at that time and had sudden vomiting lasting two days. At that time he used to knock his right shoulder against the wall of a white-washed corridor at home. During the next two months he had three or four more

¹ *July 1907.*—There is still some bulging of the flap, but the patient is much better than a year ago, is able in great part to lead an ordinary life, but the question of the presence of a tumour must be considered (*see* next case) as still undecided.

attacks of vomiting. He then remained perfectly well for three or four months, able to hunt, etc. Last Xmas went to Berlin and thinks he caught cold on his way back to Ireland. Gradually occipital headaches recurred and almost daily vomiting. In March was so ill with vomiting that he was fed for a week by enemata. Another relapse in May and again in June lasting a week. Since then has had two days' sickness, one in July and the last a week ago. Attacks consist of sudden vomiting, usually bilious. No known exciting cause, dietetic or otherwise. Never lost consciousness during attacks. No ear trouble. Has astigmatism, for which he wears glasses. Bowels tend to be confined. In July last had diplopia for a couple of days, the images appeared not on the same level, also a certain amount of photophobia. Reading tires him. Occasional giddiness when stepping off a tram-car. No weakness of arms or legs.

Condition, September 26th, 1903. — Intelligent, well developed, speech and articulation normal. Discs show deep physiological pits. No neuritis or atrophy. Visual fields normal. Pupils, face, palate, and tongue normal. No squint or diplopia. Marked coarse nystagmus on looking to the right, slighter on looking to the left. No anæsthesia of face, trunk, or limbs. No weakness or ataxia of arms or legs. Gait normal. S.J.'s left greater than right. K.J.'s left greater than right. A.J.'s left present, right absent. Plantars flexor. No cranial tenderness. Heart, lungs, abdomen, normal. Urine, no albumen, no sugar. *October 1st.* — Sir Anderson Critchett agrees as to the nystagmus, and says it was not present when he saw the patient eight months ago. The nasal sides of both discs are suspicious; not quite clearly defined, but with a

little swelling not amounting to actual papillitis.

October 16th.—Well-marked diplopia to the right. The false image seen by left eye is displaced downwards below the true, but is practically parallel with it. The nystagmus as before. No weakness of face or limbs. Hearing acute on both sides. S.J.'s and K.J.'s left greater than right. A.J.'s left present, right absent. Reels slightly when walking, but keeps in a straight line.

October 30th.—A small hæmorrhage is now present in the left disc at its inner margin. Two days ago had sudden flushing of the face for a couple of minutes with slight headache; no giddiness. Only one slight attack of vomiting since last night. Diplopia less troublesome. Reeling as before. Diplopia occurs on looking to extreme right, the false image with the left eye being below the true, and with its upper end leaning away from the true, *i.e.* to the right. K.J.'s left greater than right. A.J.'s left present, right absent.

November 5th.—Patient's mother writes that he is more unsteady in picking up small objects, and when cutting his food misplaces his knife.

November 21st.—Hæmorrhage in left disc is as before. Swelling of left disc greater than right. Diplopia to extreme right as before. Nystagmus almost gone, still present on looking to the right. Reflexes as before. Difficulty in cutting food with right hand some four or five days ago. No headache.

December 17th.—Has had three bad attacks of headache, and vomiting at intervals of seven days. Seems to feel particularly well before each attack. One of these attacks lasted three days. Headache commences as steady aching pain in right eye, gradually diffusing all over the head, and with paroxysms of agonising pain in the back of the neck mesially, especially when bowels move. Has noticed aggravation of diplopia after each

attack. Hæmorrhage of left disc almost gone. The inner edge of the disc is swollen much more than before. The right disc is now moderately swollen as well, especially on its inner edge. The diplopia to the right less marked. Images not definitely separated as before. Coarse horizontal nystagmus to the right. Pupils equal, moderately dilated, reactions normal. Face, hearing, tongue, palate, normal. Reflexes as before. Very slight reeling on turning rapidly. No difference in rapidity of alternate pronation-supination movements on two sides. No abnormal static rigidity of either lower limb. No cranial irregularity or tenderness. *December 18th.*—Lumbar puncture. Four drachms of clear fluid under abnormal pressure, containing a few mononuclear cells. *December 31st.*—No nystagmus, no diplopia, headache less. No unsteadiness in walking, but knocks right foot against curb on regaining the path. Reflexes as before. Discs *in statu quo*.

January 14th, 1904.—Felt particularly well until the 9th, when he had a recurrence of severe headache and vomiting. Diplopia and nystagmus reappeared with greater intensity. I saw him during the attack and noted distinct local tenderness in right occipital region. Optic neuritis has increased and now measures up to $2\frac{1}{2}$ dioptries in both eyes, the right more than the left (measured by Mr. W. T. Lister yesterday). Slight reeling when turning. Reflexes as before. Dr. Ferrier, Dr. Pye-Smith, Dr. Purves Stewart, and Sir Victor Horsley all concurred in advising operation in right cerebellar region.

January 16th.—Operation. Bone over right cerebellar region was removed. Dura was tense and bulging. Lumbar puncture was then performed, and about half an ounce of clear fluid was withdrawn under considerable pressure. Removal of this fluid reduced

the cerebellar dura to a flaccid, non-bulging condition. *January 23rd.*—Dura opened; lumbar puncture having previously been done, and about $1\frac{1}{2}$ ounces of cerebro-spinal fluid withdrawn under excessive pressure. No tumour was detected by the finger in the right cerebellar fossa external to the cerebellum, and none was found after horizontal section of the cerebellar hemisphere.

January 28th.—Patient languid and restless. No actual paralysis of cranial nerves or of limbs, but he seems to have difficulty in moving himself in bed. Intelligence perfect. Copious escape of cerebro-spinal fluid from angle of wound. *February 7th.*—No headache, no vertigo, no vomiting. Articulation much better but not normal. Fluid still leaking. Still marked diplopia to the right. Coarse nystagmus to the right, fine to the left. Marked unsteadiness of right upper limb. Cannot feed himself with the right hand. No difference between lower limbs in pointing to small objects. S.J.'s and K.J.'s left greater than right; A.J.'s left present, right absent. *February 17th.*—Mr. Lister examined discs again to-day. Swelling reduced to half a dioptré in both discs. Marked unsteadiness of gait, and right hand in reaching very unsteady. Fluid escaping copiously.

March 14th.—Wound hardly leaking at all. No unsteadiness on walking. Slight diplopia to the right. Coarse nystagmus to the right. Some bulging of flap. Discs, left practically normal; right, a little indistinct at edges but no measurable swelling. *March 22nd.*—In the right disc veins are a little tortuous. No measurable swelling, moderate nystagmus on extreme lateral division, right greater than left; none on vertical rotation. Face, tongue, palate, normal. Occasional diplopia to the right, not constant. Sensory functions normal. No unsteadiness of upper or lower extremities

on pointing to small objects. Gait normal. S.J.'s, K.J.'s, A.J.'s, left greater than right. Plantars flexor.

May 1st.—Patient remained well until two days ago, when he vomited all day long and had pain in the right eye. Ten days ago had similar pain without vomiting. Now feels well. Moderate bulging of flap; discs practically normal (Lister). Very slight weakness of right face. No deafness. Articulation normal. Slight nystagmus to the right and slight diplopia to the right. No anæsthesia, no weakness or unsteadiness of arm or leg. S.J.'s and K.J.'s, left greater than right. A.J.'s, left present, right not elicited.

September 26th, 1904.—Feels well except for occasional giddiness at the moment of waking in the morning. Still diplopia to the right. Hearing acute on both sides. Cranial nerves normal. No unsteadiness of limbs. S.J.'s, K.J.'s, A.J.'s, normal and equal. Gait normal. Scar in right occipital region bulges moderately. Gentle pulsation.

December 14th.—Since last note has been to various places in England and feels very well. Has occasional sudden feelings of giddiness the first thing in the morning. Still diplopia to the right. Coarse nystagmus as before to both sides, especially to right. Right palpebral fissure slightly wider than left. Cranial nerves otherwise normal. Gait normal. Reflexes normal and equal on two sides. Discs practically normal.

January 23rd, 1906.—Patient is quite well. Can play two rounds of golf without fatigue. Occipital operation flap now concave.

Remarks.—All who saw the patient agreed that the symptoms pointed to tumour occupying the right cerebellar fossa. The symptoms suggesting a right-sided lesion were the slight inco-ordination of the right hand, the greater swelling of the right optic disc, the

absent right A.J., the diminished right K.J., and S.J., the coarse nystagmus on looking to the right, and the history that in walking down a passage he tended to

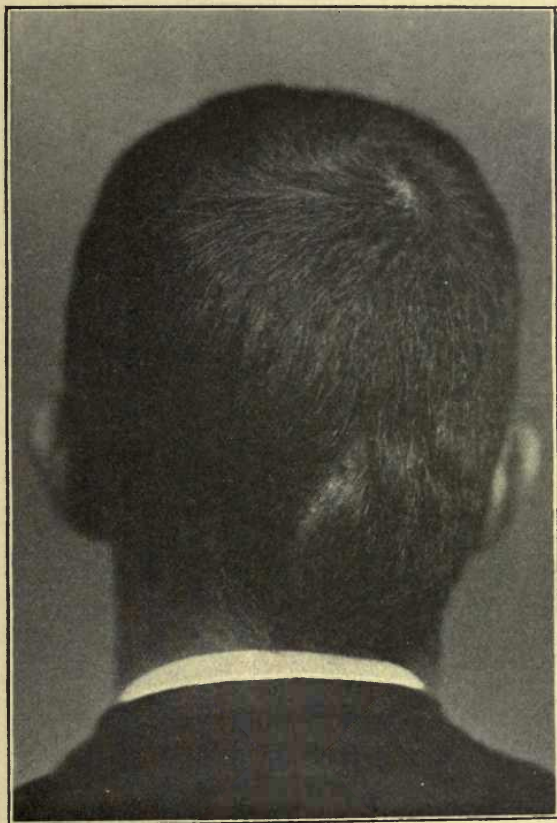


FIG. 82. See Fig. 83.

deviate to the right, and in crossing the road he knocked the right foot against the curb.¹

As a practical operation detail I wish to draw attention to the value of lumbar puncture before opening

¹ During my illness in the spring of this year (1907) Mr. T. came to London. There was more bulging of the flap and slight return of swelling of the right optic disc: otherwise patient was in *statu quo*. Sir Victor Horsley kindly operated, and found a cystic swelling within the dura,

the dura when there is much intra-cranial pressure. This procedure facilitates exploration and saves the brain tissue from damage.

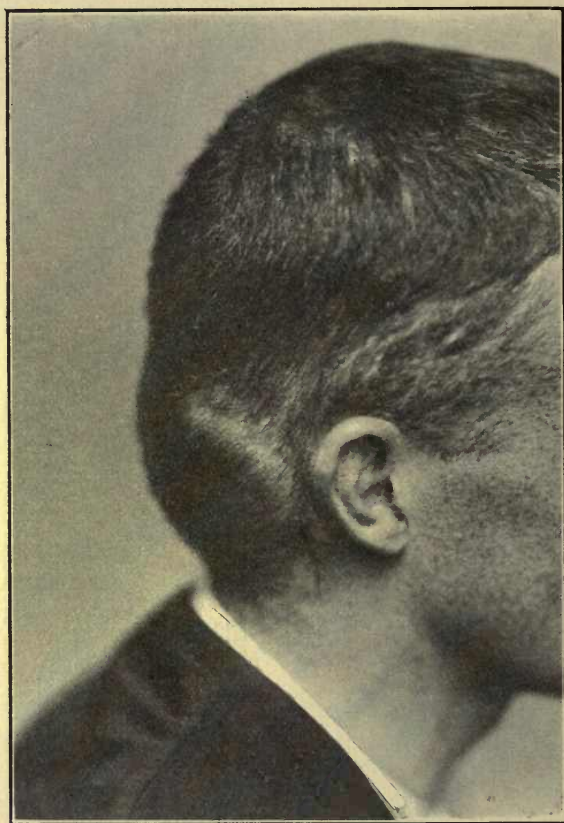


FIG. 83.

FIGS. 82, 83.—Back and side views of head of Mr. T. (Sept. 1906), two years and nine months after operation.

The bulge is considerable, and is now more marked than it was a year ago. For the last six months his golf has been poor owing to double vision, and six weeks ago he had a severe attack of pain in right eye and vomiting.

having a small hard nodule at its anterior and inner extremity. The nodule and part of the cyst were in the substance of the cerebellum. The patient died a few hours later. Oppenheim (*opus cit.*) relates a similar experience, a tumour being found three years after the first operation. An account of Oppenheim's case is given at the end of this book.

Relation of Injury to Tumour Growth.

Malignant growths have in some instances a purely local origin, in the same way that tubercular infection may arise from direct inoculation and remain a local though a spreading disease. Local irritation or injury often precedes the actual presence of tubercular or malignant disease. Against the view that local irritation or injury is associated with the outbreak of these diseases, the main argument adduced is that a large proportion of those exposed to local irritation or injury should become the subjects of these diseases. But the efficient cause lies beyond the mechanical irritation, which is but the partial cause of the disease, and the question resolves itself into this : Why are some persons infected in such circumstances whilst others escape ? It is beyond the scope of my present purpose to attempt an answer to this question, but as in other parts of the body, so in the head, injury is sometimes followed by malignant disease.

Many such cases might be cited of which the following are good examples :—

1. A boy, ten years old, had a blow on the head and afterwards suffered continuously from headache and vertigo ; nine years later he began to suffer from cerebellar ataxy, the general symptoms of brain tumour gradually showed themselves, and death took place

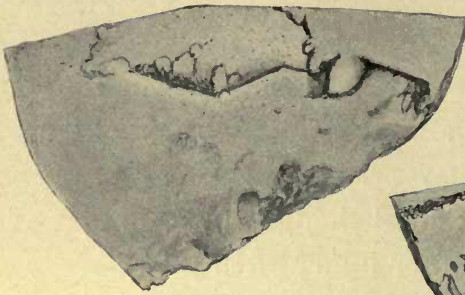

FIG. 84.




FIG. 85.

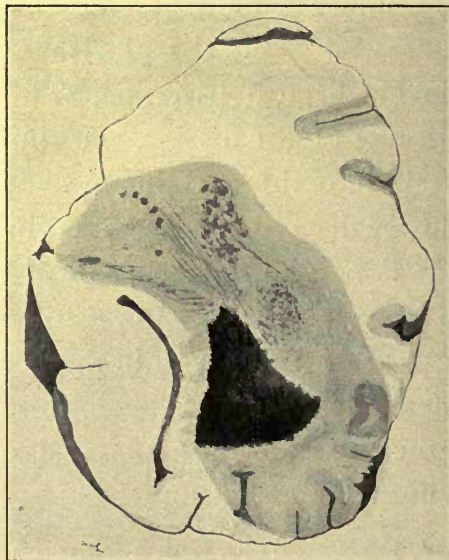

FIG. 86.

FIGS. 84 and 85.—Healed fracture, outer and inner surfaces of skull, over gliomatous tumour in occipital lobe.

FIG. 86.—Cystic glioma of occipital lobe under healed fracture of skull. The cavity in the tumour appears black; the extent of tumour is shaded a grey tint.

suddenly. A sarcoma was found in the middle lobe of the cerebellum. (Duret, p. 40.)

2. In 1895 I operated for brain tumour on a coachman, aged thirty-one years, whom I saw in consultation with Mr. Lunn and Dr. Beevor. He had suffered from headache for a year, and his sight had been failing for nine months. A history was obtained of hemianopsia having been observed in another hospital. On admission he had severe headache and vomiting. He was almost totally blind, and hearing was much impaired on both sides. Both discs atrophic from optic neuritis. Mental state tending to torpor. No paralysis of motion or sensation, but tendency to fall towards the left side. He denied having met with any injury to the head. At the operation a healed fracture was found in the right occipital region, and it was afterwards ascertained that twenty years previously he had been kicked by a horse, and had remained unconscious for some hours afterwards. Beneath the healed fracture was a cystic glioma of the occipital lobe.

3. *Case by Dr. Dudley.*—A male adult was struck on the right side of the head with a stick, he was unconscious for twelve hours after the injury, on recovery he had slight headache. Three days later he had a fit. The wound healed in two months. The fits continued for eleven months. He was trephined six months after the accident on the right side, and for a time was much improved. A year after the injury he was admitted to hospital with weakness of the right leg. There was a cicatrix on the right side of the head and tenderness over the opposite parietal region. The fits recurred and tactile sensibility on right side was gradually lost. He died three months later. A soft glioma was found in the posterior part of the left frontal lobe

as large as a Tangerine orange. The tumour was apparently the direct result of the injury.

4. F. C., female, aged twenty-one years, was admitted to St. Thomas's Hospital under my care on March 27th. In the previous August she fell, striking the left frontal region against an iron spike. There was a wound which bled freely, and the patient was unconscious for twenty-four hours. She was admitted into Grantham Hospital under Dr. Shipman. From the time she recovered consciousness until her admission to St. Thomas's seven months later the only symptoms observed were occasional attacks of headache and repeated bleeding from the wound, which did not heal. It was for this repeated hæmorrhage that the patient was sent to me.

On admission to St. Thomas's there was a wound in the upper left frontal region about the size of a shilling, surrounded by scar tissue, which led into a cavity within the skull. There was no optic neuritis, and careful examination failed to detect any focal symptoms.

Operation.—An oval scalp flap was thrown down including the wound; this exposed a hole in the bone as large as a shilling, many bleeding points were seen in the bone surrounding this opening, a condition which I have previously met with during removal of angio-sarcoma of brain. A considerable area of bone was removed. This revealed an opening in the dura corresponding to that previously found in the bone; through this opening the finger passed for two inches into a cavity with thick walls. A dural flap was then made, the supposed meningo-cortical abscess was enucleated entire, and the operation completed in the usual way with drainage. At the bottom of the abscess cavity was a particle of hard material which gave the chemical reactions for iron.

The patient did fairly well for some days, except that

there were repeated small hæmorrhages from the wound, on which the local application of adrenalin and turpentine, and the internal administration of calcium chloride, had no effect. On the twenty-second day a severe hæmorrhage suddenly occurred and the patient became comatose, with subnormal temperature, slow pulse, and slow respiration. The unconsciousness was due to a mass of clot which had collected in the cavity left at the first operation, and torn up the surrounding brain substance. When the clot was removed there was immediate improvement. Several vessels in the brain were ligated. Some days later, as slight hæmorrhages repeatedly recurred, the left carotid was ligated. A week later the patient died; the temperature rose to 107° immediately before death.

Repeated microscopical examinations during the life of the patient failed to reveal the presence of malignant disease, but when the brain was examined after death many discrete nodules of new growth could be seen with the unaided eye in the neighbourhood of the injury, some of which involved the pia. Some had hæmorrhages around them, others were distinguished only by their whiter colour. On microscopical examination these masses proved to be angeio-sarcoma, containing numerous vessels with thin and undeveloped walls from which blood had obviously escaped in many places. Clotting had taken place in the internal carotid and its middle cerebral branch. A ligature was found on one of larger branches of the middle cerebral.

Remarks.—This patient's brain must have been inoculated in many places with the virus of malignant disease as surely as a tube of culture medium is inoculated by plunging into it a platinum point deliberately charged with infective material.

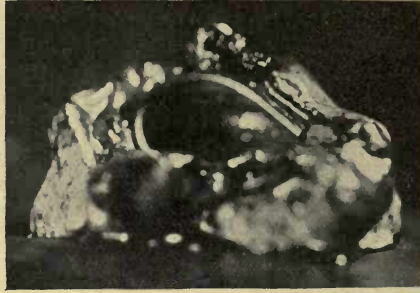

FIG. 87.—Photograph of supposed meningo-cortical abscess removed at the first operation on Dr. Shipman's case.

Note.—The external opening is seen, and the thickness of the wall of the abscess.

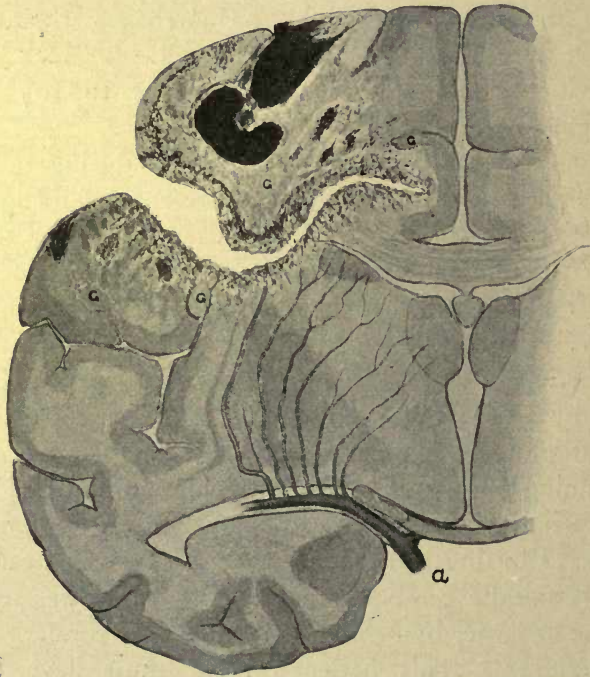


FIG. 88.—Tumour of frontal lobe following punctured fracture of skull.
(Dr. Shipman's case.)

Coronal section (partly diagrammatic) just behind the chiasma. A portion of the cavity in the brain at the time of death is represented. The dark parts are hæmorrhages; *G, G, G*, discrete nodules of growth, grey in colour, without hæmorrhages; *a*, internal carotid artery and its middle cerebral branch, the latter with its striate branches.

OF TUMOUR OF THE BRAIN 211

FIGS. 89 to 95 illustrating the Histology of the Tumour—
Dr. Shipman's Case.

The obviously diseased area was made up of growth and degenerated and inflamed brain substance with much extravasation of blood. Sections taken from just beyond this area showed discrete nodules of sarcoma in the pia, many visible to the naked eye in the stained sections. The pia, where affected, was thickened, highly vascular, and infiltrated with round cells; the walls of many of the vessels were infiltrated with sarcoma. The processes of pia extending into the smaller sulci were in many cases clearly infiltrated with growth, and the vessels entering the brain substance carried sarcoma cells with them. The brain cortex was œdematous, and its perivascular spaces were dilated. Some of what appeared to be outlying nodules of new growth surrounded by a zone of hæmorrhage were really islets of more or less degenerated brain substance completely enclosed by processes of the pia infiltrated with growth. Others were definite nodules of sarcoma. The spread of the growth along blood-vessels could be clearly demonstrated, and in sections stained by the orcein and thionin method, introduced to my notice by Professor Goldmann of Freiburg, examples of vessels destroyed by the growth were well shown. In sections taken from the deeper part considerable areas of sarcoma could be seen, in which were many vessels of new formation with thin and undeveloped walls. Hæmorrhages had occurred both from old and new vessels. Streaks of comparatively unaltered brain tissue were in places to be seen between masses of extravasated blood. I am indebted to Dr. Charles Green for the preparation of the microscopical specimens.

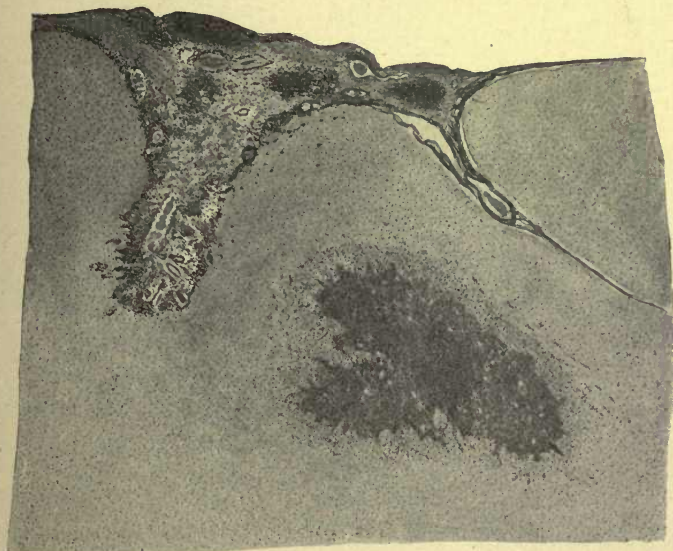


FIG. 89.—A drawing made of section from the brain cortex just beyond the obviously diseased area.

Several darkly-stained areas, which are nodules of sarcoma, are seen in the pia. Two processes of pia are seen, one fairly normal, the other much thickened and

infiltrated with sarcoma cells. In the brain substance a large nodule of sarcoma without definite limits is seen. The specimen was stained with logwood.

The appearances in this section seem to resemble the microscopical appearances found in the case reported by Sanger, in which the pia only was affected (referred to on page 182), which, in the brief account to which I had access, are thus described :—“The pia over the convexity was much infiltrated by fairly large cells with large nuclei ; some of the cells were round, some oblong, and some caudate ; in many places the cells formed close agglomerations, in others small areas of pia were free, except for small groups of carcinoma cells.”

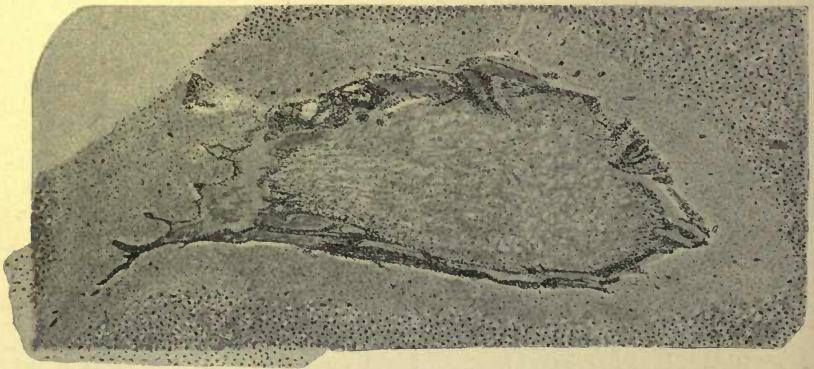


FIG. 90.—Reproduction of a drawing made from a section through what appeared to the naked eye as a nodule of new growth surrounded by a ring of hæmorrhage.

It is an islet of brain substance enclosed in a ring of pia infiltrated with new growth. In the enclosed portion of brain tissue the noble elements have to some extent perished, and immediately without the ring of pia is a zone of degenerated brain substance.

The specimen was stained with orcein and thionin blue, and the drawing made under a one-inch objective.

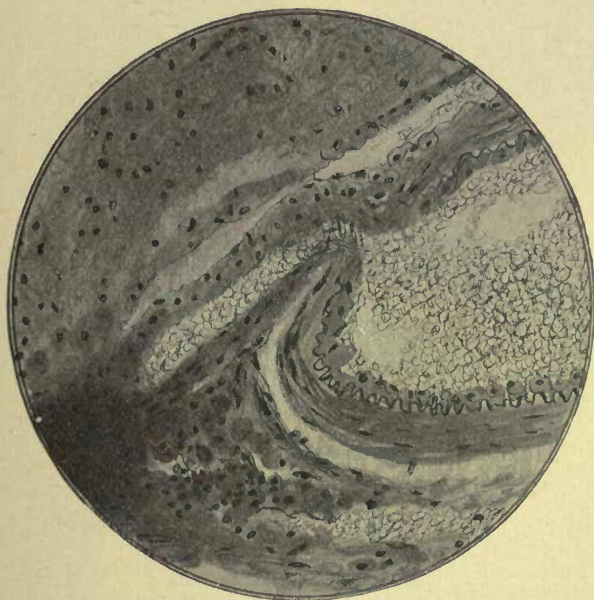


FIG. 91.—Reproduction of a drawing made of a portion of a vessel in the pia as seen under a high power.

The vessel happens to be cut at a point where a tiny branch is given off. A group of rather large sarcoma cells can be seen almost at the angle of junction of the branch with the main vessel. The elastic tissue of the main vessel is well shown.

In other sections the walls of the branch were seen to be infected with sarcoma for a considerable distance.

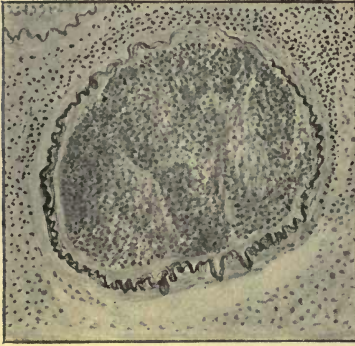


FIG. 92.

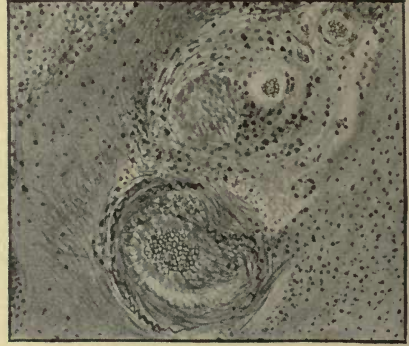


FIG. 93.

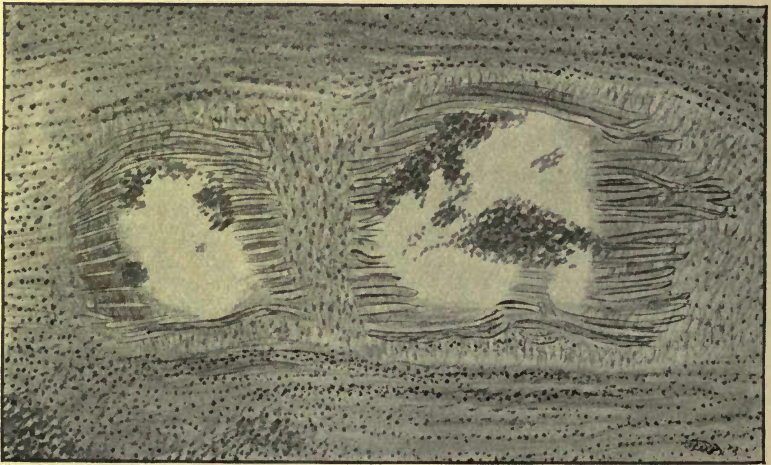


FIG. 94.

FIGS. 92, 93, 94.—Reproduction of drawings of degenerated vessels as seen under a high power.

FIG. 92.—The general outline of the vessel is clearly shown by its elastic lamina, which has taken the characteristic stain, but at one point it is almost completely destroyed. The other tissues of the vessel wall are almost completely destroyed.

FIG. 93.—Two small vessels in which the degeneration is more advanced. Only fragments of the elastic laminae are recognisable.

FIG. 94.—A small vessel cut obliquely. Remnants of the elastic laminae are clearly seen, but the wall of the vessel is almost entirely replaced by sarcoma tissue.

The vessels represented in these three figures were all in the same section taken from the obviously diseased area, and quite close to the operation cavity.

The section was stained with orcein and thionin blue.



FIG. 95.—Reproduction of a drawing of part of the wall of an artery.

The adventitia is infected with sarcoma cells, the tunica media has degenerated, and the elastic membrane is bulged at one point where the vessel seems about to give way.

The section was taken from the obviously diseased area, and quite close to the operation cavity. The particular vessel was easily visible to the naked eye. The specimen was stained with picro-indigo-carminé.

Tumours of the Cranium and Meninges.

Brain symptoms may arise from tumour of the cranial bones or of the meninges as well as from tumours of the brain itself. The tumours of the cranial bones which are of chief importance in this relation are sarcoma and carcinoma, though other varieties of tumour, such as angioma, enchondroma, or osteoma may also cause brain symptoms. Sarcoma of a cranial bone may grow outwards and not involve the brain. The destruction of the cranium is in some cases wide-spread and terrible.

Carcinoma of the skull or its contents is rare, and when it occurs it is generally secondary to carcinoma of the breast. It may develop secondarily in the skull, as it often does in other bones, or it may infect the meninges, causing a tumour which may irritate or compress the surface of the brain. Carcinoma has also been known to occur in the scalp, and to perforate the skull and meninges, as in the cases cited from Mikulicz and Braun.

Sarcoma of the dura mater may grow from its outer aspect, destroying the bone, but not perforating the dura, as in Auvert's case. Indeed the dura seems to offer considerable resistance to

perforation by sarcoma, whether from within or from without.

Tumours of the meninges of common occurrence within the dura are fibroma, fibrosarcoma, endothelioma, and solitary tubercle. These tumours either compress the brain, making a depression in which they are found, or seem at first sight to occupy the substance of the brain, but then on careful examination an attachment to the meninges is found showing their real origin.

The following cases illustrate some of these remarks :—

1. *Parosteal Sarcoma*.—A female child, eighteen months old, was under my care in the Great Ormond Street Hospital. A tumour had been noticed on the left side of the head some three months. The growth was removed; it was limited externally by a delicate capsule, and grew from the outer layer of the periosteum over the squama. The bone was not involved. Three months later the growth recurred, but no further operation was attempted. The growth ulcerated and the child died in about two months from cachexia induced by the discharge and hæmorrhage. (Figs. 96 and 97.)

2. *Periosteal Sarcoma of the Squama*.—Male, aged ten years, was admitted to St. Thomas's Hospital in 1898. One year before admission a tumour, the size of a small nut, was noticed above the right ear. Nine months later it was excised at the Staines Cottage Hospital. Rapid recurrence took place, and on

admission to St. Thomas's Hospital the photograph reproduced was taken. The direction of the eyes is a photographic effect, and not due to any intra-cranial complication. (Fig. 98.)

Operation.—A skin flap of the whole temporal region, including the pinna, was turned downwards, the cartilaginous meatus being divided. The bone was exposed above, behind, and in front of the limits of the tumour. The skull was divided in the same direction, the incision in the bone being horse-shoe in shape, with the convexity upwards. Patient then became very faint, was infused, and put back to bed. Two days later the boy was again anæsthetised. The wire of a Gigli's saw was passed between the extremities of the horse-shoe cut in the skull, coming out in front near the anterior part of the zygoma and behind near the mastoid process. The saw was then worked vertically downwards, so dividing the squama and most of the mastoid from the petrous. Though the tumour occupied the whole of the temporal fossa it was attached only to the squama, and was subperiosteal in origin. It was white on section, and microscopically was a small, round-celled sarcoma.

Patient left the theatre in fair condition, but shock was considerable, and though twice infused, death occurred thirty hours later.

3. *Cavernous Angeioma (without Sarcoma Cells) of Os Frontis projecting backwards into the Skull Cavity and compressing the Frontal Lobe.* (Zajaczkowski of Poland. From Sawicki's article in *Chipault*, vol. ii.)—The patient was a woman aged thirty-eight years. When seen there was a tumour as large as a hen's egg above the right orbit. Twelve years previously a hard, fixed swelling had appeared above the orbit, which in

six years grew to the size of a hen's egg, and was then removed with the gouge. The bone wound bled very freely. Recurrence began a year after this operation, and in five years the growth was as big as ever. The edges were indurated, the centre soft and pulsatile, and the overlying skin thin and cyanosed. No effect was produced by compression of the tumour or of the vessels. The patient complained of headache and vertigo, and had mental depression alternating with periods of excitement. Zajaczkowski removed the growth, together with a portion of the dura to which it was adherent. There was a considerable depression in the frontal lobe. The wound in the dura was sutured, part of the anterior wall of the frontal sinus which was involved was removed, and the gap then covered with a skin flap. The patient recovered, the headache and vertigo disappeared, but some mental dulness persisted. (Fig. 99.)

4. *Sarcoma of Orbital part of Os Frontis displacing Dura and Brain.* (Preindlsberger, of Serajevo, in *Bosnia. Chipault*, vol. ii.)—The patient, a man aged twenty-four years, was admitted to hospital with a tumour as large as the egg of a goose, presenting at the supero-external angle of the right orbit. He could give no account of the tumour, and only applied for treatment because it was rapidly increasing in size. The growth was enucleated together with the eyeball. A considerable part of the orbital wall had been destroyed, but the dura mater appeared unaltered. The day following the operation there was slowness of pulse lasting twenty-four hours. The wound united by first intention. The growth was sarcoma. (Fig. 100.)

5. *Recurrent Sarcoma of Outer Aspect of Dura Mater compressing left Frontal Lobe.* (Durante. Roncali in

Chipault, vol. iii.)—The patient was a woman, aged thirty-five years. For about a year before the first operation she had had loss of smell and impairment of memory, and had become melancholic and taciturn. The left eye was displaced outwards and downwards. The skull was opened by Durante's tangential osteo-plastic flap, made by incising soft parts down to the bone, and then, instead of elevating periosteum, chiselling off the external table of the bone so as to raise the periosteum with the external table attached to it in fragments of about one square centimetre. A tumour was found which had perforated the dura mater at the level of the anterior part of the left frontal lobe. The growth was removed with some difficulty and the wound closed.

The patient recovered and remained perfectly well for six months; at the end of that time she had an epileptic fit with unconsciousness lasting forty-eight hours. A year later a second attack occurred, and subsequently attacks were repeated with increasing frequency. Sense of smell abolished in left nostril and much diminished in right. Second operation twelve years after the first. Skull opened by making a flap in the same way through the old scar. So perfectly had the bone been reproduced that it was impossible to determine the limits of the new bone. The bone was very thick and adherent to the meninges; a tumour as large round as a crown piece was found incorporated with the dura mater—it extended on to the falx. The dura was divided all round the tumour with the thermo-cautery and the mass removed. The patient made an excellent recovery, and seven years after the second operation was known to be alive. (Fig. 101.)

6. *Sarcoma of Outer Aspect of Dura*. (Avert, 1851.)—The patient was a Russian peasant woman, thirty-five

years old at the time of her death. Eight years previously she had a severe blow on the right side of the head. No immediate symptoms of any severity were observed, and she followed her occupation for a considerable time without inconvenience. Subsequently she suffered from headache, increasing in frequency and severity, the pain being referred to the site of injury. The attacks terminated with vomiting, which gave some relief. A soft pulsating tumour appeared at the painful spot, and increased in four years from the size of a hazel-nut to that of an orange. The pain became almost continuous. The patient at this stage consulted a surgeon, who diagnosed sebaceous cyst, and made an incision into the tumour; instead of the pulraceous matter he expected, blood came out in a full stream, and the hæmorrhage was with difficulty arrested. The wound did not cicatrise, but rather became larger, and a bloody, fœtid discharge continued to exude from it.

When seen by Auvert the tumour was as large as an adult head, and its surface was extensively ulcerated. The patient died six weeks after admission to hospital. The pia, arachnoid, and dura were intimately adherent beneath the tumour, and separated it from the cerebral cortex. The pressure of the growth had to a great extent obliterated the convolutions of the hemisphere. (Fig. 102.)

7. *Fibro-Sarcoma of Cerebellar Meninges.* (Cruveilhier, 1830.)—The patient was twenty-six years old at the time of her death; she had had good health until the age of nineteen years, when she began to suffer from severe pain in the head at intervals, and gradually became deaf in the left ear. A twelvemonth later partial loss of sight was noticed, and after another year spasm of left side of face. From this time

there was further progressive diminution of sight, so that three weeks after the first facial spasm the patient could no longer see her way about. In a few months there was complete blindness. For two years her condition remained stationary, the headache was less and occurred at longer intervals, appetite was good, and general health satisfactory. The condition then became worse, the headache increased, and alternated with severe pain in the left thigh. Rigidity of the limbs occurred, most marked on the left side, as well as convulsive movements of the left face. Smell was now gradually lost. Three months before death there was complete blindness, and complete loss of taste and smell, deafness was incomplete. Patient was able to get up until the last month of life. Vomiting did not occur until fifteen days before death.

At the autopsy a hard tumour was found springing from the posterior surface of the left petrous, to which it was attached by a stalk which occupied an irregular cavity in the bone uniting the internal auditory meatus with the foramen lacerum posticum and with the carotid canal. "The stalk could be easily separated from the cavity in which it lay, so that the tumour appeared to have arisen from the process of dura mater extending into the internal auditory meatus rather than from the bone itself." The base of the skull was thinned and eroded in several places in situations remote from the tumour, and the brain substance was pressed into these erosions. The growth had compressed the left half of the pons and of the bulb and the corresponding cerebellar peduncles. The sensory root of the fifth nerve was stretched out into a broad ribbon, and the facial and auditory nerves were compressed between the brain and

the tumour. The sixth nerve was pushed aside without damage. The vagus, glosso-pharyngeal, and spinal accessory nerves were pushed in front of the tumour. The hypoglossal presented no abnormality. (Fig. 103.)

8. *Tumour (? Endothelioma) of Inner Aspect of Dura.* (Cruveilhier, 1830.)—The patient was a woman, aged forty-five years, a school-mistress, who was seen by Cruveilhier on 3rd September 1829. The symptoms observed were frontal headache, inability to walk, weakness of left leg, slow speech, mental enfeeblement, and involuntary micturition. She died on 3rd October. Cruveilhier had diagnosed tumour of the frontal lobe, and had the satisfaction of demonstrating to his class the tumour in the situation in which he had predicted that it would be found. (Fig. 104.)

9. *Endothelioma of Meninges in Frontal Region.* (Beadles.)—The patient was a woman, aged sixty-nine years, who had been in an asylum for nineteen years. She was admitted to the asylum with melancholia, and subsequently suffered from right facial palsy and severe hemicrania. (Figs. 105 and 106.)

An interesting fact in relation to tumours of the brain is their presence undiagnosed in the insane. It is, of course, to be expected that tumours may produce mental symptoms, and also that tumours of the brain may arise within the cranium of patients insane from other causes. Mr. Cecil Beadles has collected a considerable number of brain tumours from autopsies on insane persons. These cases will shortly be published.¹

10. *Epithelioma of Frontal Region.* (Braun of Königsberg, 1892.)—A girl aged fourteen years was admitted to

¹ Two per cent of insane patients who die in asylums, and on whom autopsies are made, have tumour of the brain. Of these tumours one-half are syphilitic. (Mott.)

hospital with an ulcerating carcinoma on the right side of the forehead ; it extended from the margin of the orbit to the hairy scalp, and from 1 centimetre to the left of the middle line to the tip of the right pinna. The overhanging lower edge concealed, but did not involve, the eyelids. No enlarged glands were observed. Brain pulsation was readily perceptible over the central area of the growth. Twelve years previously she had been severely scalded in the situation of the tumour, and two years previously she received a blow from a slipper in the scar ; an ulcer formed which had never healed. An attempt (in another hospital) had been made to cure the ulcer by excision and transplantation of skin, but this failed, and only resulted in extension of the ulcer.

The growth was removed in three stages.

(1) In order to minimise the risk of meningeal infection, the peripheral portions of the growth were curetted down to the bone, and the growth cut off where it perforated the bone ; the aperture in the bone was as large as a shilling. The surface was dressed with sublimate lotion, and, a week later, (2) an incision was made all round the growth down to the bone ; the superficial portion of the bone was removed to within about $\frac{1}{2}$ cm. of the aperture through which the growth passed ; here the whole thickness of the bone was removed. The wound in the soft parts measured $11\frac{1}{2}$ cm. from above downwards, and $10\frac{1}{2}$ cm. from right to left. Smart bleeding from the middle meningeal artery, in its bony canal, led to the operation being interrupted at this stage. (3) Twelve days later the opening in the bone was enlarged, the lateral aspect of the superior longitudinal sinus was wounded, but the bleeding was easily controlled. Bone was removed until the dura was exposed over an area of $6\frac{1}{2}$ cm. square ; round the margin

of this area the dura was incised, the cut edges raised up and turned over the growth. The growth was firmly adherent to, and apparently incorporated with, the brain. The vessels in the pia were ligatured all round the growth, and the growth cut away with a part of the frontal lobe $\frac{1}{2}$ cm. thick, $3\frac{1}{2}$ cm. from above downwards, and 4 cm. from right to left. Wound left open and dressed with iodoform gauze. Violent anæsthetic vomiting was the only immediate after-symptom. Hernia cerebri four days later. This attained a considerable size, and did not begin to diminish for a month. Six weeks after the removal of the tumour some induration was noticed about the granulations at the spot where the middle meningeal hæmorrhage had taken place, bone was cut away, and the indurated tissue removed by the thermo-cautery, together with the underlying dura and a layer of brain substance. Microscopical examination confirmed the diagnosis of recurrence.

Two months afterwards another portion, in which recurrence was suspected, was excised, but histological examination showed no evidence of growth.

When there had been nothing to lead to the suspicion of recurrence for a whole month, the wound was partially closed by a plastic operation, after the site of the hernia cerebri had been freshened with the thermo-cautery, and the closure completed subsequently by skin grafting.

Eleven months after the first operation healing was complete. No cerebral symptoms. (Fig. 109.)

11. *Epithelioma of Frontal Region.* (von Mikulicz.)
—A married woman, aged fifty years, was admitted to hospital with a large, malignant ulcer over the right half of the frontal bone. The surface bled easily and

Q

was partly covered with crusts. It was made up of a number of separate, rounded, warty masses, which in places had a glistening surface. In the centre of many of the masses was an easily removed epidermis plug. The greater part of the upper eyelid was destroyed by the ulcer. There was no optic neuritis, nor any affection of cranial nerves. No enlarged glands were seen.

Five years previously a small ulcer had been noticed, which never healed, but increased in size, very slowly at first, but rapidly during the six months before admission.

At the operation the growth was found to have perforated the frontal bone and involved the dura. The growth was removed, together with a piece of the frontal bone as large as a five-shilling piece, and a considerable portion of the zygoma. The eyelid was so extensively involved that it was thought better to sacrifice the eyeball. There were no meningeal adhesions, the exposed pia looked normal. The whole area of the bone defect and the greater part of the skin wound was covered in by a flap which included the outer table of the skull, cut from the forehead and hairy scalp. The flap was so planned that its attached base was downwards. The raw surface of the bone in the flap rested against the pia. The flap was held in place by a few silver sutures, and the surface left in raising it allowed to granulate and afterwards grafted. The flap united readily. A small recurrence took place on the cheek three months later. When the paper was read (eight months after the first operation) only the outer angle of the wound was still granulating. (Fig. 110.)

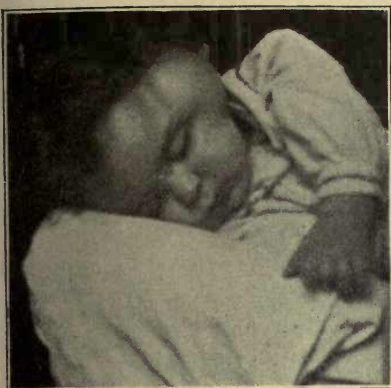

FIG. 96.

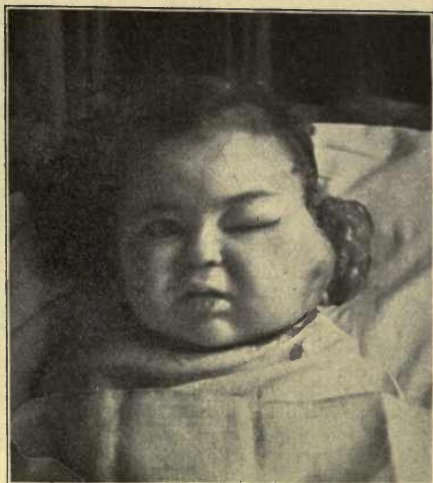

FIG. 97.

FIGS. 96 and 97.—Parosteal round-celled sarcoma of the squama.

FIG. 96.—Before operation.

FIG. 97.—Recurrence five months after operation.

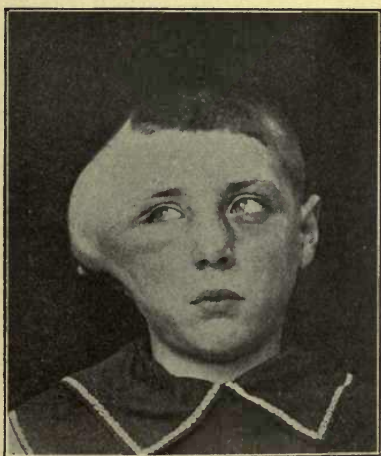

FIG. 98.—Periosteal sarcoma of squama.

The deviation of the eyes is not due to disease.

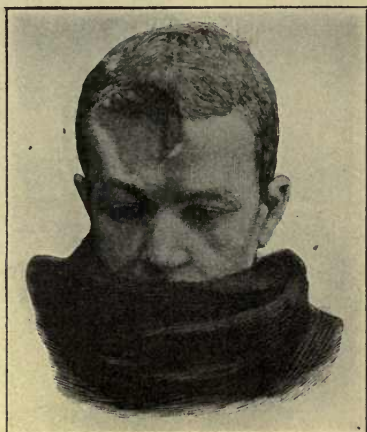

FIG. 99.—Cavernous angeioma (without sarcoma cells) of os frontis projecting backwards into skull cavity and compressing frontal lobe. (Zajaczkowski of Poland. From Sawicki's article in *Chipault*, ii.)

The figure is taken from a photograph after operation.

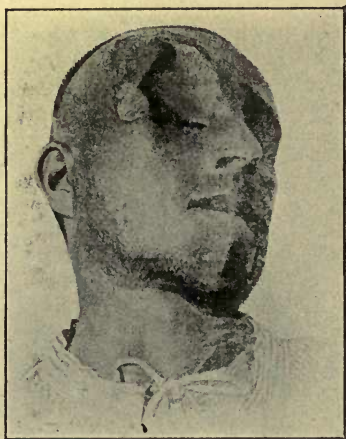

FIG. 100.—Sarcoma of orbital part of os frontis displacing dura and brain. (Preindlsberger of Serajevo in Bosnia. *Chipault*, ii.)

The figure is taken from a photograph after operation.



FIG. 101.—Sarcoma of outer aspect of dura mater compressing left frontal lobe.
(Durante. Roncali's article in *Chipault*, iii.)

The figures represent the parts removed at the second operation—

- (a) the growth still attached to the bone ;
- (b) the bone with the growth removed, to show how perfectly it had been reproduced.

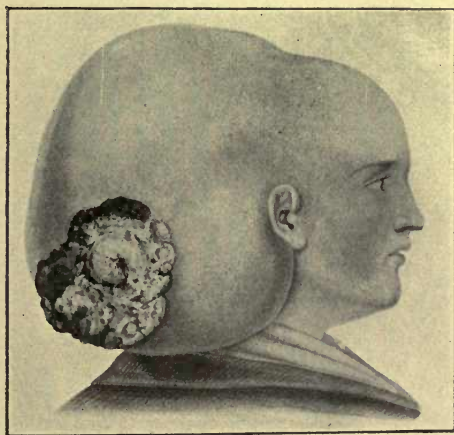


FIG. 102.—Sarcoma of outer aspect of dura. (Auvert.)

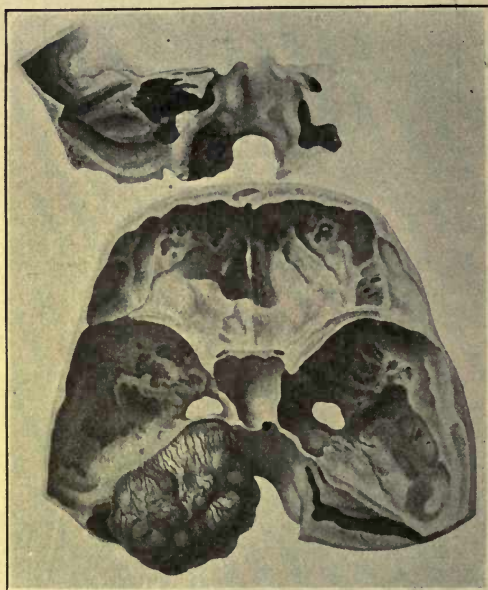


FIG. 103.—Fibrosarcoma of cerebellar meninges. (Cruveilhier.)

The upper figure represents the cavity in the petrous, in which the stalk of the growth was lodged. The lower figure shows the growth attached to the petrous and some erosions in other parts of the base of the skull.

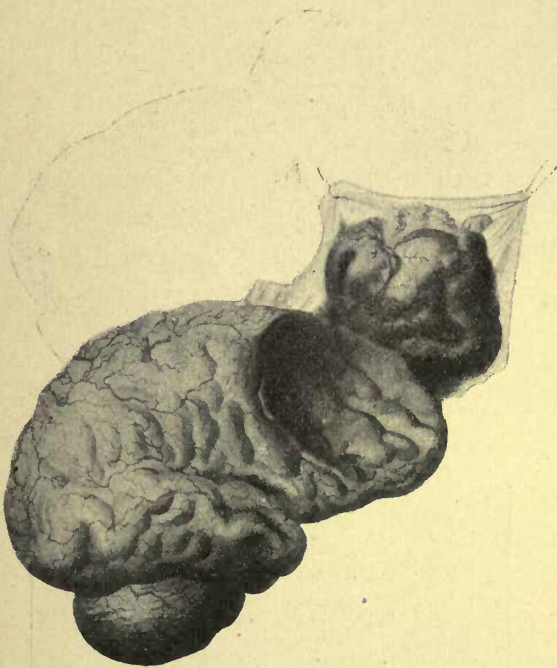

FIG. 104.—Tumour (? endothelioma) of meninges in frontal region. (Cruveilhier.)

The figure shows the tumour adherent to the inner aspect of the dura, and the depression in the frontal lobe in which it was lodged.

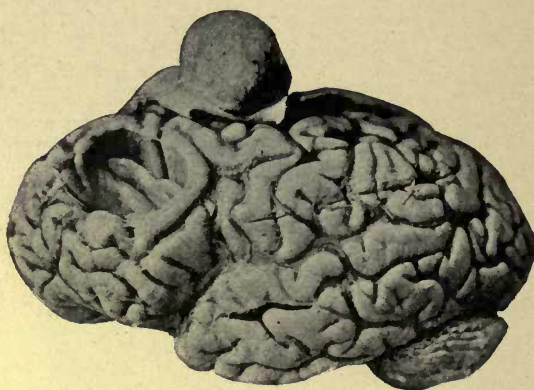


FIG. 105.

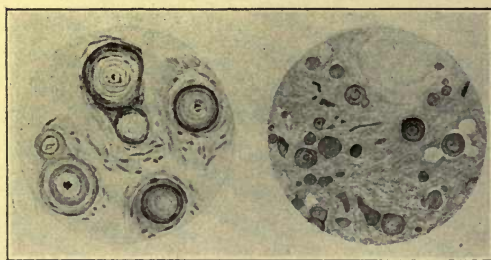


FIG. 106.

FIGS. 105 and 106.—Endothelioma of meninges in frontal region. (Beadles.)

FIG. 105.—Photograph of tumour and depression in frontal lobe in which it was lodged.

FIG. 106.—Microscopical section of tumour.



FIG. 107.—Sarcoma ossis frontalis before and after operation. (From von Bergmann's article in the *German System of Practical Surgery*, American Edition.)

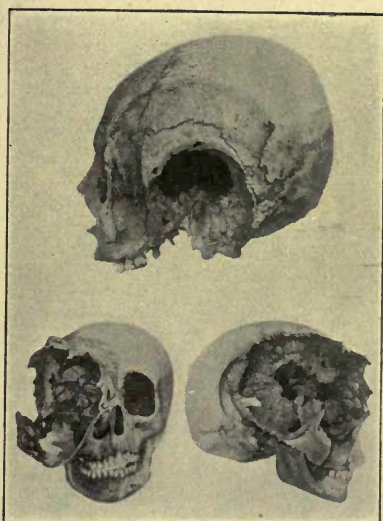

FIG. 108.—Destruction of skull by malignant disease. (Lebert, 1859.)

The upper figure represents the skull of a case which was observed in 1764. The patient was a man 21 years of age. When admitted to hospital he had a tumour the size of his head projecting from the left side of the skull. In four months death occurred. The growth was a sarcoma of the dura mater. The temporal bone was destroyed.

The lower figures represent a skull which is in the Musée Dupuytren. Lebert does not give the history of the case.

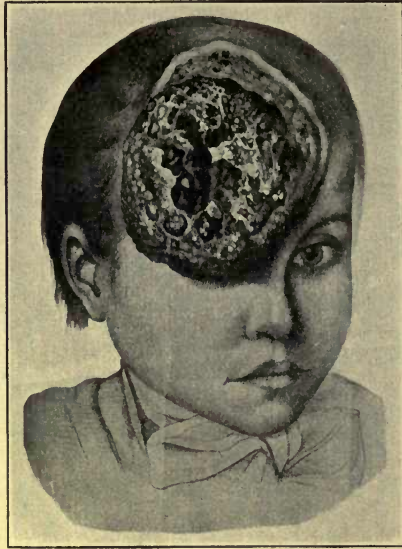

FIG. 109.—Epithelioma of frontal region. (Braun of Königsberg.)

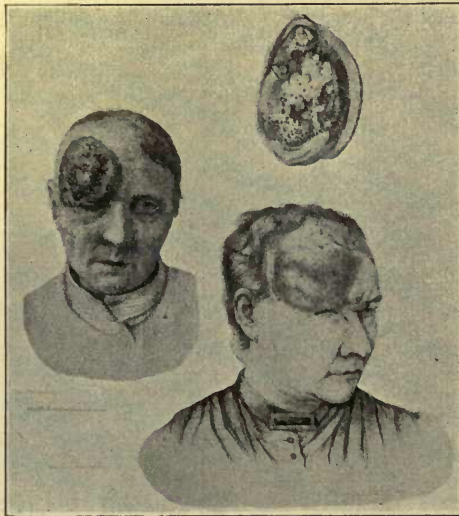


FIG. 110.—Carcinoma of frontal region. (von Mikulicz, reported by Tietze.)

The figures show the appearance of patient before and after operation, and the mass removed.

Tumours of the Cerebellum.

As I referred at some length in the second lecture to cases illustrating the symptoms of the temporo-sphenoidal lobe, I propose in this lecture to illustrate the application of localising symptoms to diagnosis by discussing the signs of cerebellar disease and relating some illustrative cases. Tumours which are capable of enucleation are more frequently met with below than above the tentorium. Tumours in the occipital fossa are of various kinds. The common varieties are fibroma, myxo-fibroma, fibro-sarcoma, endothelioma, sarcoma, glioma, simple cyst, and solitary tubercle. The great morbid anatomists of the first half of the nineteenth century were familiar with meningeal tumours, which they described under the name "fibro-plastic tumour," and they also figure what we now know as the solitary tubercular tumour.

Diagnostic Symptoms of Cerebellar Tumour.—Most observers agree on the main facts, but there is a conflict of opinion on the localising significance of some symptoms, such as the side to which the patient tends to fall. This conflict of opinion may be explained in some cases by the symptoms caused by a tumour

differing according to whether it is intra- or extra-cerebellar, or whether its effects are irritative or destructive. Some of the signs and symptoms are of general while others are of regional significance. It may at once be said that certain signs, when present, make the regional diagnosis easy, when such signs are absent the problem of localisation may be insolvable. The patient commonly complains of headache, vomiting, vertigo, unsteadiness of movement, and dimness of vision. The *headache* is most often occipital, but is sometimes frontal, and occasionally, though rarely, limited to the contra-lateral frontal side. It is severe, may be insupportable, and the paroxysms are often associated with severe *vomiting*. *Vertigo* is an early sign, comes on with change of position, is associated with a feeling of utter faintness, and causes a tendency to fall independently of titubation. Recently I saw with Dr. Charles Green a woman, aged thirty years, who had some signs of left cerebellar tumour, she became intensely giddy on suddenly being rotated towards the left. The direction of the subjective sensation of movement differs according to whether the tumour is intra- or extra-cerebellar. In extra-cerebellar tumour the subjective rotation of self is to the side of the

lesion, in intra-cerebellar tumour of the lateral hemisphere it is away from the lesion. Louis Tollemer concludes his remarks on cerebellar vertigo by saying that its chief characteristics are constancy and intensity. Attacks of vertigo often occur suddenly, like epileptic fits. Disturbances of equilibrium are not always accompanied by the subjective sensation of giddiness. Duret points out that the vertigo of Menière's disease can be usually distinguished without difficulty from that caused by tumours in the occipital fossa, or tumours involving any part of the vestibular tract, by the presence in the latter of other signs of tumour, and by certain peculiarities in the seizures. The *mental state* is normal or only affected later as a consecutive phenomenon. *Sensation* is intact. In children the *occipital region may bulge*. *Tenderness on percussion* over the occipital region is rare and is suggestive of a superficial lesion; in an individual case it may be present sometimes, but not at others.

A woman, aged twenty-seven years, under the care of Dr. Ferrier, had weakness of left external rectus, slight weakness of left side of face, inco-ordination of movement of left limbs, and slow and deliberate nystagmus, more marked towards the left than towards the right. When her

feet were placed close together she fell backwards and to the left. There was tenderness on percussion over the whole occipital region, but especially on the left side. I removed a large glioma from the left cerebellar hemisphere.

The deep reflexes may either be diminished or exaggerated; in either event the modification is on the side of the lesion in lateral cerebellar tumour. In a tumour of the cerebello-pontine angle the exaggeration is likely to be due to pressure on the crus, and will then be on the contra-lateral side. *The attitude of the head* is in some cases characteristic. Batten writes:—“When standing or sitting, the head is held with the ear approximated to the shoulder on the side opposite to the tumour. The face is turned to the side of the lesion and the chin elevated.” In experimental ablation of the lateral lobe the opposite position is assumed. This position would naturally be adopted to relax the wound. Also the head may be retracted or the chin depressed on the chest; the anterior or the posterior part of the vermis is then probably involved. The dimness of vision is due to *optic neuritis*, which is an early sign, is very pronounced, and is most intense on the side of the lesion. Failure of sight is sometimes very rapid.

Certain remarkable *disturbances of equilibrium* and of movement may be observed. On stand-

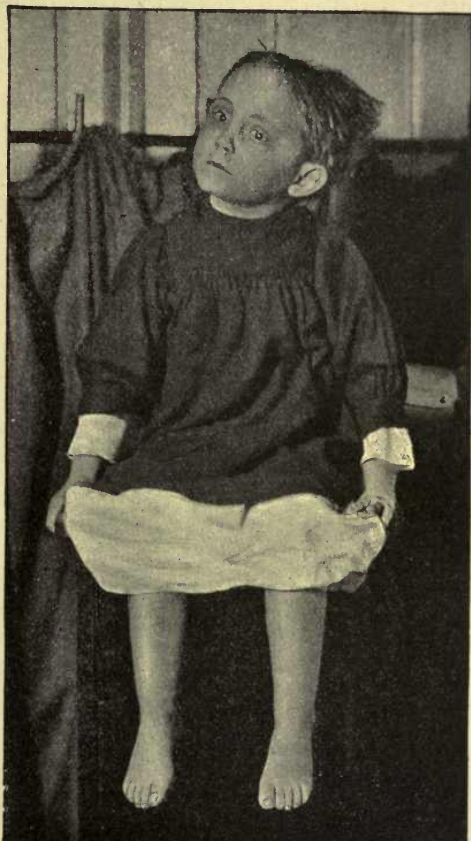

FIG. 111.—Photograph of a child, aged 5 years, showing position of head assumed in a lesion of the right lateral lobe of the cerebellum. (Batten.)

“When standing or sitting she held her head to one side, so that her left ear was approximated to the left shoulder; her face was turned to the right, and the chin was slightly elevated; there was a slight spinal curve, with the concavity to the left.”

ing the feet are widely separated, the abduction being greatest on the homo-lateral side. Un-

steadiness may be so great as to prevent standing. Romberg's sign may or may not be present. When present the tendency to *fall is to the side of the lesion* when this is in the lateral lobe, and backwards when in the vermis. When walking

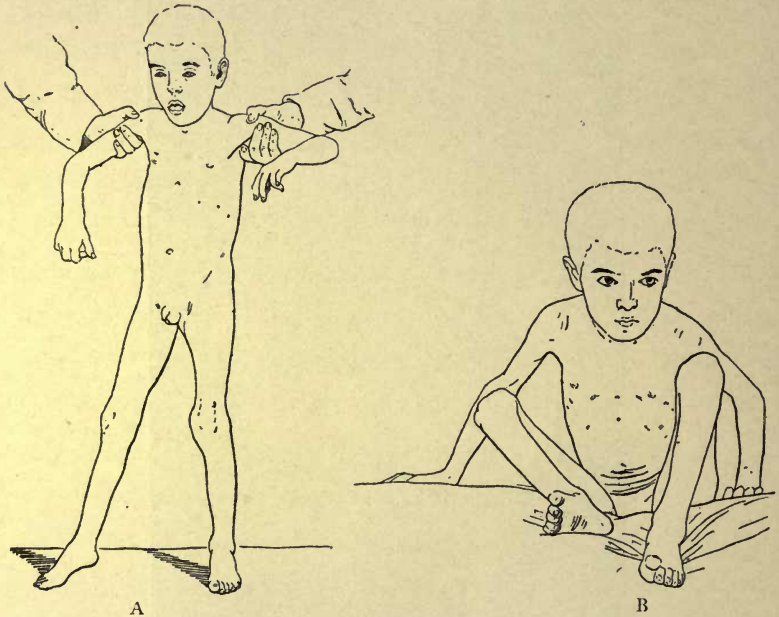


FIG. 112.—Child with right cerebellar tumour (solitary tubercle). (Louis Tollemer.)

A, position when standing, right thigh abducted; B, position when sitting, right thigh abducted.

the patient keeps the feet wide apart, staggers, and, instead of progressing forward in a straight line, follows a zig-zag course; the deviation from the straight line is more marked towards the side of the lesion. The patient is unable to turn sharply. The gait has been compared to

that of a child when first learning to walk. *Ataxy of the limbs* is manifested by want of steadiness and precision on executing voluntary movements, particularly in rapid succession. For example, alternate movements of pronation and supination, which the normal individual can execute with great rapidity, are less rapidly and less precisely performed by the subjects of cerebellar disease. The power of repeating movements in rapid succession has been termed by Babinsky *diadocokinesis*. Again, if the thigh be flexed on the abdomen and the leg on the thigh, and the patient be then asked to extend the limb, the movement will not, as in the normal individual, be performed as a whole, but the two segments of the limb will be extended separately. This want of correspondence in time and energy of the movements of groups of muscles which should act together is termed *asynergia*. These phenomena are most marked in the homo-lateral limbs, but occur on both sides, particularly when the vermis is involved.

In a male child, aged six years, under the care of Dr. Risien Russell, who was found to have a tumour in the vermis, it was noted that the muscles were well developed but deficient in tone. The strength was fair and about equal on the two sides. Co-ordination was impaired

R

on both sides, rather more on the left. There was no tremor when at rest. He stood with considerable lordosis from weakness of spinal muscles, and kept his feet wide apart. He reeled and staggered to both sides, but more frequently to the left. When his feet were placed together he tended to fall backwards and to the left. There was weakness of both external recti. In bed the head was retracted. The left occipital region bulged. The tumour in this case was a glioma; it occupied the central portion of the vermis, and measured $3\frac{1}{2}$ cm. across. I operated, but failed to remove the tumour.

Bruce says :—“Lesions situated in the lateral lobes may produce no disturbance of equilibrium provided they are situated entirely external to the intra-cerebellar paths of the upper and lower peduncles and of the nucleus dentatus (area of possible latency). If, however, these structures are interfered with, either by pressure or by direct involvement, then the characteristic symptoms of cerebellar disease will be produced, and will depend in their character and amount on the nature and extent of this interference. If the cerebello-vestibular tract or Deiter's nucleus be injured, then the usual stimuli will not pass either to the anterior cornua of the cord or to

the sixth or third nucleus. Hence may result the weakness of the same side, the tendency to fall to that side, the tendency of both eyes to be directed to the opposite side, and the lateral nystagmus which occurs, especially when the eyes are directed towards the same."

Titubation and disturbance of orientation may be observed in lesions of the vestibular nerve anywhere between the peripheral termination and the cortical representation in the posterior two-thirds of the temporal lobe. These symptoms, therefore, are not diagnostic of cerebellar lesion. Horsley, for example, reports a case diagnosed as one of injury to the middle peduncle of the cerebellum, the crus, the optic tract, and the temporal lobe, in which there were forced movements, vertigo, auditory amnesia, and hemianopsia. As the cortical terminations of the vestibular nerve are in the temporal lobe, it is easy to understand that in tumour or injury involving these fibres near their cortical distribution there may be, in addition to titubation and disturbance of orientation, hemianopsia, forced movements, and disturbance of the senses of hearing, smell, and taste. *Forced rotation* only occurs in lesions of nervous tissue proximal to the internal ear, not in internal or middle ear disease. Forced movements in cerebellar

tumour seem more common after operation than before.

One of the most striking signs in some cases of tumour involving the cerebellar hemisphere is *weakness and loss of tone of the muscles of the homo-lateral limbs*. An early view of Luciani was that this atonia was due to the cutting off of the reinforcing influence of the lateral lobe of the cerebellum from the opposite cerebral hemisphere. The absence of this reinforcing influence would make itself felt *via* the pyramidal tracts, hence the weakness of the homo-lateral upper limb, and of both lower limbs, and the conjugate deviation of the eyes to the opposite side. Pagano's experiments are of great interest. He used the excitation method; his chief conclusions are :—1. Stimulation of one lateral lobe of the cerebellum produces motor phenomena, varying in intensity from simple contraction of groups of muscles in a limb, causing it to assume fixed attitudes, up to violent convulsions. The muscles affected are the homo-lateral ones, and there are definite cerebellar zones corresponding to groups of muscles. There is also rotation of the body on its longitudinal axis, which occurs constantly from the side of excitation towards the other side. 2. Movements produced by cerebellar excitations are

accomplished by intermediation of the cerebral cortex, because extirpation of the contra-lateral motor area abolishes the localised muscular contractions of the limbs on the same side, and the rotation of the body occurs in the contrary direction, showing that the action of the cerebellum, though preponderating on the homo-lateral, acts also on the contra-lateral muscles through the corresponding motor cortex. Complete extirpation of both motor cerebral areas abolishes completely the motor phenomena. 3. Stimulation of the anterior part of the vermis causes the head to look upwards and induces an irresistible tendency to fall backwards. 4. Stimulation of the posterior part of the vermis causes an irresistible tendency to fall forward—the head being drawn strongly downwards on the chest. Pagano says that the cerebellum has an energising action on the cerebro-spinal centres, that no organ is innervated directly from the cerebellum, and that the asthenia of the homo-lateral limbs produced by the ablation experiments of Luciani by no means contradicts, but confirms his results.

We may accept the results of Pagano's experiments, but need not adopt the theoretical conclusions based thereon. What, then, is the function of the cerebellum? Louis Tollemer

writes "that the cerebellar hemisphere regulates, suppresses, or excites at the appropriate time the nervous impulses which give rise to muscular contraction." In my view it neither reinforces nor energises the cerebral cortex. Its energy, obtained from the common source of supply, the blood, is required for the exercise of its own functions. The cerebellum is the reflex centre of the sensori-motor system concerned in equilibration, co-ordination of muscular movement, and the sense of orientation. It receives impressions from the vestibular apparatus, the eyes, and (through the spinal cord) the muscles, and probably the skin. From these impressions it elaborates efferent impulses, which reach the central nuclei and the cerebral cortex, and through them the muscular apparatus. Static equilibrium is maintained unconsciously, or at least subconsciously. The reflex arc passes through the cerebellum, the red nucleus, the corpora quadrigemina, the nucleus of Deiters, the nucleus of Bechterew, and the nuclei in the pons. "In all movements and attitudes the influence of the cerebellum is manifested by variations in muscular tonus regulating the extent and the force (and the time) of these movements. Thus, when an animal, a dog, raises its front paw, not only must the cortical

motor centres come into action in order to command and bring about the movement by way of the pyramidal tract, but a particular state of tonicity in the neighbouring muscles, and, indeed, in the whole trunk, is essential during the whole time that the movement is continued in order to assure its smoothness and precision. The cerebral cortex sends impulses by way of the crus, the pons, and the middle cerebellar peduncle to the cerebellar cortex simultaneously with those that it sends to the cord. The cerebellar cortex, through its efferent fibres and its central ganglia, supplies the tonus necessary to the corresponding muscular apparatus and to the trunk itself. The brain is kept informed of all the modifications of the muscular apparatus by the efferent cerebellar fibres which pass to the red nucleus and the optic thalamus by way of the cerebellar superior peduncles, and thus at every moment, at every period of the movement, equilibrium is maintained. But let there be an unilateral lesion of the cerebellum, the muscular tonus furnished by this side of the cerebellum will be wanting from the homolateral muscles, while the contra-lateral muscles will remain abundantly provided for; hence incurvation of the trunk, loss of equilibrium, oscillation, and fall towards the side of the

lesion" (Duret). The conductor of an orchestra does not play any instrument nor energise any performer, but it is through his influence that the work of each individual performer is exactly adapted to that of every other. Without such guidance, though all the parts might be played correctly as parts, there would be "asynergia," and the effect on the audience would differ from that intended by the composer. Muscular movement is in some such way co-ordinated through the cerebellum.

Operations on man and ablation experiments on brutes show that weakness occurs in the homo-lateral upper extremity on removal of the cerebellar hemisphere. In a case of mine, already referred to, no tumour was found, but the intracranial pressure was so great that the healthy lobe of the cerebellum was pushed through the dural opening and much of it was lost by sloughing. The patient recovered, was completely relieved of his headache and vomiting, but for some months his left arm was so weak as to be quite useless. Masnata relates the following case:—A man, aged thirty-eight years, whose sight was much impaired from old standing corneal disease, fell backwards and was brought home unconscious; in the left occipital region were two scalp wounds and a large

hæmatoma. The symptoms of cerebral commotion subsided, but there was bi-lateral facial paralysis and complete immobility of the eye-balls, with squint, clonic spasm of the right limbs, high temperature, and feeble pulse. The patient was drowsy, with intervals of agitation; voluntary movements were slowly and hesitatingly performed; there was some rigidity of muscles of neck. Operation on the eighth day; fracture of occipital bone with a large splinter. On removing the splinter a black pultaceous mass escaped; the removal of this slough, which involved a great part of the left cerebellar hemisphere, was completed with the curette. Immediately after the operation the pulse improved, the temperature fell, and the facial paralysis disappeared. The patient recovered, but for many months was quite unable to stand without support owing to weakness of the limbs on the side of the lesion; he tended to fall backwards and towards the side of the lesion. Durante, in removing a growth involving the antero-superior part of the right cerebellar hemisphere, was constrained to destroy the whole of the corresponding lobe. In the thirteen hours which preceded the patient's death he observed very pronounced asthenia and atonia of the muscles of the homo-lateral limbs,

a high temperature, rapid pulse, exaggeration of the patellar reflexes, and a strong tendency to turn in bed so as to lie on the side of the lesion. Roncali remarks that the cases hitherto observed of surgical removal of one cerebellar hemisphere confirm the experimental observation that the affection of the limbs is on the side of the lesion, but that in cases of tumour the limbs on both sides are almost always affected; this he attributes to compression, a view confirmed by some experiments conducted by him in order to elucidate the effect of compression as distinct from ablation of one cerebellar hemisphere.

The asthenia is often marked in the muscles of the trunk, especially the spinal muscles, and this is probably most obvious when the vermis is involved. Holmes and Grainger Stewart write: "The character of the weakness, the absence of any organic rigidity, and the normal state of the superficial reflexes, are strongly against any interference with the pyramidal tracts."

In addition to asthenia or weakness there is *loss of tone* of the muscles of the homo-lateral limbs, causing them to be flaccid and the limbs to assume unusual positions. *Spasticity* of the limbs may be present, and is an indication, as Mills points out, of an irritative, not a destructive lesion. *Astasia* may also be present. "A dog

from whom half the cerebellum has been removed, when lying on the ground differs from a normal dog only by a slight uninterrupted trembling of the head, which in the circumstances is the only part of the body not supported. If the dog stands up the trembling extends to the trunk, which wobbles slightly either transversely or obliquely. When it walks slowly, writes Luciani, the same phenomenon becomes exaggerated in the muscles of the homo-lateral side, especially those of the limbs and of the spinal column. We notice, indeed, that the movements of the limbs of the operated side are wanting in smoothness and continuity, and that the vertebral column shows a characteristic want of firmness and rigidity which certainly depends upon the fact that muscular contractions are irregularly performed, as always happens when the perfect harmony of the elementary contractions upon which muscular action depends is disturbed. And it is to this absence of the proper blending of muscular movements that clinicians have given the name of titubation or uncertainty of voluntary movements, because the observer gets the impression that the subject hesitates to come to a decision, or experiences delay in transmitting the requisite impulses to his muscles. This hesitation or uncertainty of movements,

manifest enough when the animal walks slowly, disappears when it spontaneously or under compulsion quickens its pace" (Roncali). Quite similar phenomena have been observed in man.

Optic neuritis has already been mentioned. As failure of sight from this cause is so frequent

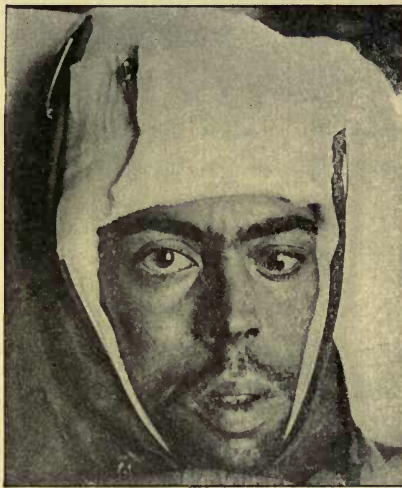

FIG. 113.—Skew deviation of the eyes taken a few weeks after removal of tumour from the left lateral lobe of the cerebellum. (Grainger Stewart and Gordon Holmes.)

The patient was a man, aged 27, and the tumour was a gumma which Sir Victor Horsley removed. The skew deviation occurred immediately after the operation, the left eye being directed downwards and inwards, and the right outwards and slightly upwards; it persisted for two months.

and occurs so early, it should be included in the syndrome of cerebellar tumour. The ocular symptoms are of importance. There may be conjugate deviation of eyes to the opposite side, or skew deviation (Majendie, Russell) especially after operation. Lateral nystagmus is common,

the jerks being towards the side of the lesion. Mills says, "We have not been able as yet to make any inference of localising value from a study of cerebellar nystagmus, although it would seem probable that in a case of destructive lesion affecting the cerebello-vestibular tract, the nystagmus would be greater when the eyes were directed toward the side of the tumour." *Other cranial nerves* may be involved, especially in tumours of the cerebello-pontine angle. Sixth nerve paralysis, deafness and tinnitus, paresis of face, trigeminal neuralgia, and anæsthesia, weakness of the palate, difficulty in swallowing, and deviation of the tongue, have all been met with. In lesions of the vermis, as seen in Pagano's experiments, *rotation* occurs around a horizontal axis: in lesions of the lateral lobe around a vertical axis. In some instances both of abscess and tumour of the hemisphere, as in Russell's experimental ablations, the patient *lies on the healthy side*, so that the side of the face corresponding to the side of the lesion is uppermost. In a case of mine, minutely described by Holmes and Grainger Stewart, *fits* were observed after operation with rotation of the body towards the healthy side. Dr. Jackson has described tonic fits in tumours of the vermis, and Dana last year published a paper "On the Syndrome

(Cerebellar Fits) characteristic of Cerebellar Tumours"; these were associated with tinnitus, vertigo, forced movements, loss of consciousness, and in some cases tonic spasms.

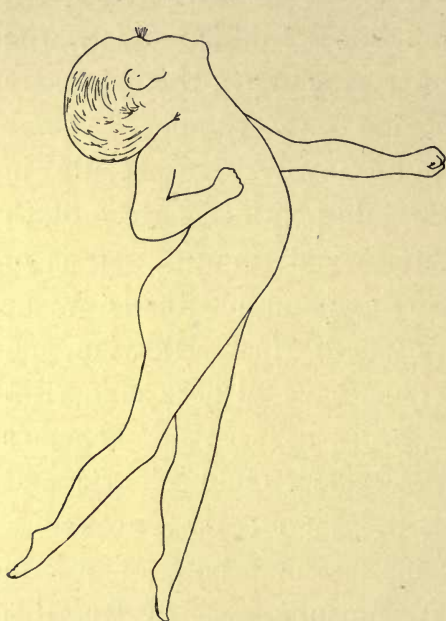

FIG. A.

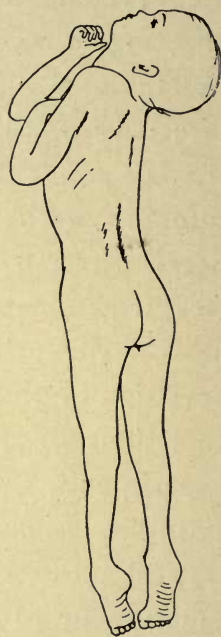


FIG. B.

FIGS. A, B, C, D, illustrating Dr. Hughlings Jackson's classical papers on tetanus-like seizures and paralysis, with rigidity in tumour of the middle lobe of the cerebellum. The papers were published in the *British Medical Journal*, 1871 and 1872. (See *Brain*, 1906.)

FIGS. A and B.—Sketches of the boy during tetanus-like seizure.

FIG. C.—Cerebellar paralysis with persisting rigidity.

FIG. D.—Cerebellar paralysis with rigidity in another case of tumour of the middle lobe of the cerebellum.

Dr. Jackson remarks that rigidity of groups of muscles and tetanic-like paroxysms form important localising symptoms in cerebellar disease. Such attacks in one of Dr. Hughlings Jackson's patients (Figs. A, B, C), a case of tuberculous tumour of

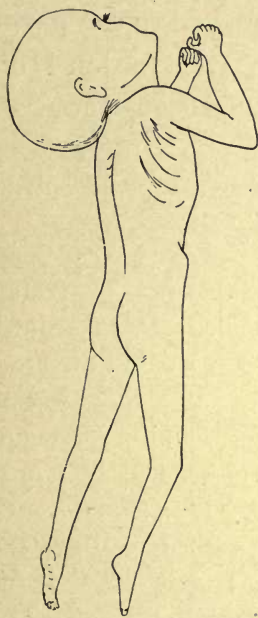


FIG. C.

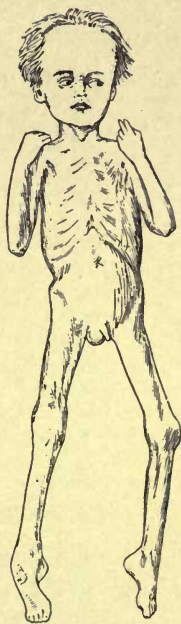

FIG. D.

the vermis, are thus described: "Sometimes, but not always, the seizure was preceded by a loud cry. There was no marked twitching of the face, nor any special deviation of the eyeballs. His hands were clenched; his forearms were flexed on the upper arms, which were generally kept to the sides. The head was drawn back and the back was curved. His legs were always extended to the fullest possible degree, the feet being arched backwards. Sometimes he passed fæces and urine in an attack. The seizures generally lasted about three or four minutes, and when passing off they returned if he were moved about. He was not unconscious. There was no clonic spasm. In one attack the two eyes were turned to the left, and the head to the right, the head not backwards as usual." Dr. Jackson compared the attitude depicted in the sketch of the boy as he appeared during one of these seizures to "a caricature, with gross exaggeration in some particulars, of the attitude depicted in a snapshot of a man or a child running very fast."

I cannot close this short account without referring to my indebtedness to the admirable symposium on cerebellar tumours in the *New York Medical Journal*, 1905, by various distinguished American authors, and to the paper by two of my junior colleagues, Dr. Gordon Holmes and Dr. Grainger Stewart, in *Brain*, 1904.

The following cases illustrate the observations about symptoms :—

Case 1.—A feeble male child, aged $3\frac{1}{2}$ years, was admitted in September 1899, under Dr. Lees, into the Hospital for Sick Children, Great Ormond Street. He had been ailing about six weeks. For three weeks the symptoms had been headache, vomiting, staggering gait, and lateral nystagmus. There had been no fits. The headache was occipital. *On admission.*—Pupils equal ; double optic neuritis ; slight lateral nystagmus. Right cerebellar fossa bulging ; gait ataxic ; mental action slow. No paralysis. Speech natural. *October 5th.*—Frequent vomiting ; slight twitching movements of right arm and hand. Reflexes have varied from time to time. *October 6th.*—Bone over right occipital fossa removed. *October 9th.*—Encapsuled tumour enucleated from the middle of the right cerebellar hemisphere. It weighed 507 grains. Patient never really rallied from the operation, and died on October 15th. No autopsy allowed.

Note.—The bulging occipital fossa clinched the diagnosis.

Case 2.—Male, aged $6\frac{1}{2}$. Admitted May 26th, 1905, into the Great Ormond Street Hospital under my care. In October 1904 he received a blow behind the left ear from which resulted headache that kept him awake all that night. After Christmas he began to have headache and vomiting at intervals. The vomiting occurred

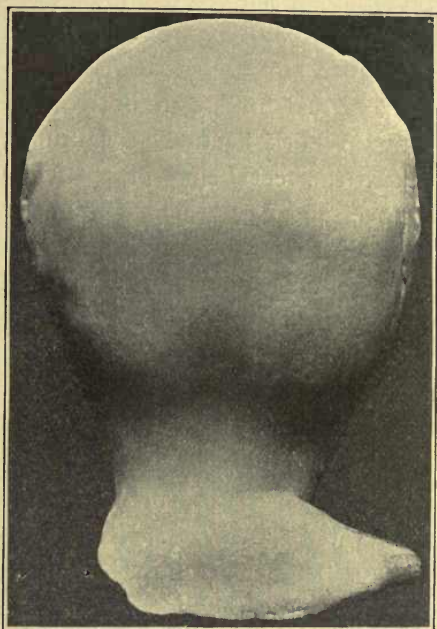


FIG. 114.—Bulging right occipital fossa in a child $3\frac{1}{2}$ years. (Lees and Ballance.)

The illustration is a photograph of a cast.

in the night or early morning, and did not seem to have any relation to taking food. About the same time the left eye was noticed to squint. Six weeks before admission the child had a bad fall, and was unconscious. Since then he has been giddy, unable to walk without staggering, and his pupils have become dilated.

Family history.—Both parents are well; they have

five other living children ; one died at the age of nine months from "water on the brain and convulsions." The mother has had no miscarriage, and there is nothing to suggest tubercle or syphilis. *Previous history*.—Satisfactory. *On admission*.—A well-nourished boy, with a large head and bulging forehead. The cerebellar region seems more prominent on the right side. No tenderness on pressure or on percussion of either cerebellar region. Sensation normal. Inco-ordination to an equal extent in both arms. Marked inco-ordination in both legs when walking. The gait is very unsteady, the feet being placed wide apart, and moved with uncertainty. While standing with the feet close together he tends to fall indifferently to either side. The muscles are not flabby, and their power does not seem diminished. Though he can only stand with great difficulty, he can walk quickly or run, but always tends, whether walking or running, to deviate to the right. The attitude of the head reminded me of Batten's paper ; the right ear was approximated to the right shoulder ; the face was turned towards the left, and the chin elevated. *Reflexes*.—Knee-jerks increased and equal ; no patellar clonus. Plantar reflex is extensor on left side. Tendon reflexes in arms not increased. *Eyes*.—Well marked left internal squint. No nystagmus. Both pupils widely dilated, but equal. They react equally, sluggishly, and incompletely to strong light, but not to accommodation. Optic neuritis on both sides ; more marked on left. Vision so much impaired that he cannot count fingers at three feet. *Ears*.—Normal. Hearing good. *Voice* rather drawling. Other systems normal.

Operation—First Stage, June 15th.—The bone over the right occipital region was removed ; it was very

thin. The dura bulged strongly, but appeared healthy. *Second Stage, June 24th.*—The dura was incised, and the right half of the cerebellum was examined; nothing abnormal was found. The child bore the operation

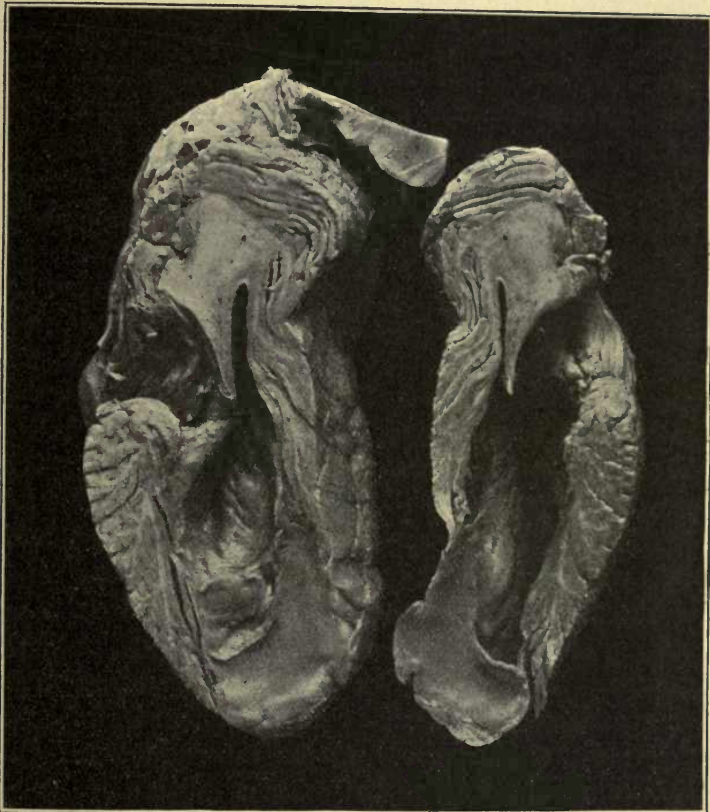


FIG. 115.—Simple cyst of left cerebellar hemisphere.
Boy, aged $6\frac{1}{2}$ years. Patient did not survive second operation.

well, and was only slightly sick afterwards. *Progress.*—On July 5th the child vomited again. The flap bulged considerably. The squint had disappeared, but there was marked nystagmus. Inco-ordination was worse; the voice was more drawling than before, and all sense

of tune was lost. *Second Operation—First Stage, July 6th.*—Bone removed over left cerebellar region, leaving a bridge in the middle line. The dura looked healthy. *Progress.*—On July 8th vomiting began, and continued till the next day, when the child died.¹ The second stage of the operation was not performed. *Autopsy.*—Large simple cyst found in left lobe of cerebellum.

Remarks.—Captain Mahan, the eminent naval historian, explains Sir Robert Calder's failure to bring Villeneuve's squadron to decisive action by his having made to himself a "picture," and allowed the impression produced by it to blind his mind to the facts of the situation—an error against which Napoleon used to caution his generals. I painted a mental picture in this case of a tumour beneath a bulging occipital fossa, and allowed it to blind me to the true interpretation of the other symptoms. Many striking examples of similar errors are to be found in surgical records. On examining the case the slight enlargement of the right occipital region made an undue impression on my mind. This was increased by the recollection of Case 1, and by the fact that there was another child with marked bulging of the occipital fossa (Case 3) in the ward at the time. In mitigation of the mistake I may say that all my friends who examined the case rather inclined to the view that the tumour was on the right side. On reflection it is clear that the mistake might have been avoided. The points in favour of a left-sided tumour were—(1) Site of injury, (2) the attitude of the head,

¹ Oppenheim (p. 55) relates a somewhat similar fatality. A boy, aged 7 years, had a tumour of the right cerebellar hemisphere, which it was intended to remove in two stages. On removing the bone the dura was found tense and without pulsation. The child died some hours afterwards, the dura not having been opened. This case lends support to the view that complete operation at one time is often advisable.

(3) the greater intensity of the optic neuritis on the left side, (4) the paralysis of left sixth nerve, (5) ankle clonus and Babinski reflex present on the left side only.

Case 3.—A male child, aged four years and ten months, was admitted into the Hospital for Sick Children, Great Ormond Street, under the care of Dr. Colman, on May 4th, 1905. Three months previously the child began to suffer from pains in the head, chiefly at the back, accompanied by vomiting. The child slept day and night in the intervals between the attacks of pain. The head was held over to the left side. *Family history.*—Both parents are living and well. They have two other children living—an older, who is healthy, and a younger, who has an aural discharge. One child died from injuries received during forceps delivery. The mother had two miscarriages—one at the third, and the other at the fourth month—prior to the birth of her first child. *Previous health.*—Full time; difficult instrumental labour. Breast-fed for seven months. Had whooping-cough at nine months, and has not seemed quite the same since. Three years ago he had pains in the head, but no vomiting. There have been slight pains in the head ever since, for which he has been attending the Out-Patient Department. When eighteen months old the mother thought he was weak in the left arm. Never known to have had a rash or snuffles. *On admission.*—Child anæmic and flabby. The cerebellar region seems to bulge unduly on both sides, but is much more prominent on the left. No tenderness on pressure or on percussion. There is a scar on the right arm. Sensation normal. The left upper limb is weaker than the right. No difference in the lower limbs. There is manifest inco-ordination in

the movements of the left arm, slight inco-ordination in those of the right, but none in moving the legs. The gait is unsteady, the feet being placed wide apart, and the arms kept in constant motion to maintain equilibrium. He falls to either side indifferently. Epigastric reflex increased on the right side. Cremas-

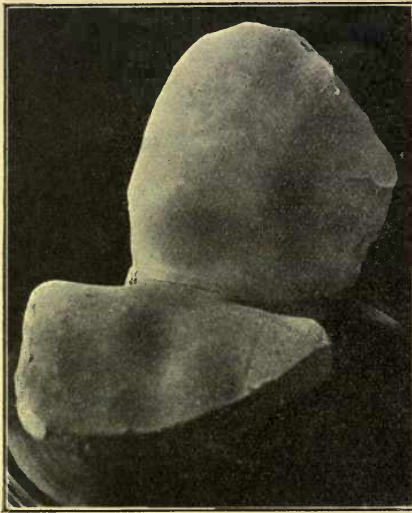

FIG. 116.

FIG. 116.—Photograph of cast of back of head, showing bulging left occipital fossa. (Colman and Ballance.)



FIG. 117.

FIG. 117.—Illustration of solitary tubercle removed from left occipital fossa with success. x Site of attachment to tentorium.

The patient was 4 years and 10 months old. The tumour measured $1.82 \times 1.73 \times 2.2$ inches, and weighed $1\frac{3}{4}$ oz.

teric marked, and equal. Knee-jerks equal, and not increased. Ankle clonus not present. Plantar reflex normal on the right side, slightly extensor on the left. Slight internal squint on left side; very slight nystagmus on looking to the right. Pupils rather dilated; react both to light and accommodation. No optic neuritis. Ears and voice normal. Other systems normal. Since

the time of admission he has been treated with pot. iod. without improvement.

Operation—First Stage, June 22nd.—Bone removed over the left cerebellar region. The bone was deficient at one spot, and was so thin that the lateral sinus could be seen through it. The bone was removed as high as the horizontal and as far forward as the vertical portion of the sigmoid sinus. Through the thin bulging dura the cerebellar convolutions could be plainly seen. At one place below the sinus the convolutions were replaced by a more uniform appearance. *Second Stage, June 24th.*—The flap of soft tissues was thrown down; no convolutions were seen through the dura; the exposed area had now a clear, transparent appearance. A flap was cut in the dura, and clear œdematous brain tissue bulged into the wound. A tumour was felt, and slowly enucleated. It was a solitary tubercle, occupying almost the whole of the interior of the left lobe of the cerebellum, extending as far as the middle line and as deeply as the pons, and was attached to the under surface of the tentorium just internal to the lateral sinus. The child stood the operation well.

Progress—July 20th.—There has been occasional vomiting and rise of temperature since operation. Wound now soundly healed. The voice, which was rather drawling after the operation, has now much improved. *August 4th.*—Inco-ordination is still manifest in both arms; nystagmus, which was worse just after the operation, is now better, but still present. Left plantar reflex no longer extensor. *September 8th.*—Is much brighter and stronger; has learned to walk. The nystagmus and inco-ordination are both improved. *November 5th.*—Has been at a convalescent home

since last note ; is now much stronger. The inco-ordination of the right arm has improved ; that of the left is the same. He walks with a stiff gait. *September 1906.*—Child quite well.

Case 4.—Female, aged seven years and ten months. Admitted to the Hospital for Sick Children under

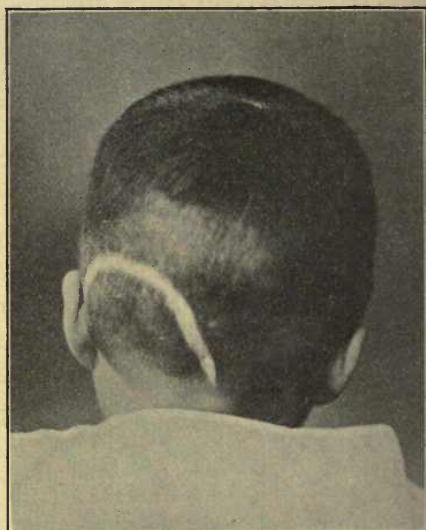
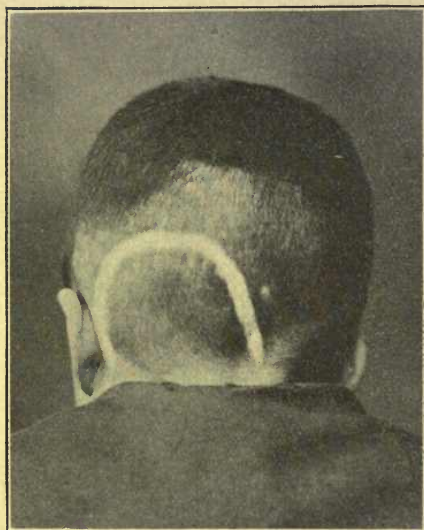


FIG. 118.

FIG. 119.

FIGS. 118, 119.—Case 3. Dr. Colman's case fifteen months after operation.

The scalp flap is concave.

Dr. Garrod, May 29th, 1905. Her illness commenced in the preceding January with vomiting, which at first occurred every morning, and has been repeated at intervals ever since. All the time she has had attacks of pain in the back of her head so severe as to cause her to cry out. She would sometimes grasp her throat and say she felt as if she were being strangled. She walks with a stiff gait and has wasted a good deal.

Her father and mother are well ; she is the third

of five children, one of whom has had post-diphtheritic paralysis. No history of tubercle in family.

On admission.—Well-nourished child; complains of pain at the back of the head. No tenderness of scalp. No signs of rickets or syphilis. No fixed attitude of head. The skull is asymmetrical, but the cerebellar regions seem equal. Sensation normal. No loss of power in the limbs. Muscles in good condition. No inco-ordination. Superficial reflexes normal. Knee-jerks present and equal. Both plantar reflexes are flexor. The gait is very slightly stiff, but there is no tendency to fall to either side. Optic neuritis in both eyes, more marked in the right. Hearing is not quite so good on the right side. No paralysis of face, eye, or speech muscles. Other systems normal.

June 17th.—The optic neuritis has increased in both eyes; there is a small retinal hæmorrhage on both sides. Attacks of headache and vomiting have been frequent.

Operation—First Stage, June 19th.—A scalp flap was thrown down over the right cerebellar region. The bone, which was very thin, was removed, as in the three previous cases. The cerebellum could be seen through the thin dura, and looked healthy. There was considerable intra-cranial tension. The flap was replaced. The child had very little pain subsequently. *Second Stage, June 24th.*—A flap was cut in the dura, when the brain at once protruded. No tumour was found on exploring the interior of the cerebellar lobe. The brain bulged so much that the dura could not be stitched in place, and only the scalp flap was replaced.

June 26th.—The child stood the operation very well, but was sick this morning, and continued so all day. *July 1st.*—Most of the stitches removed; the

flap is beginning to bulge. Fluid allowed to escape from behind ear. *July 7th.*—Wound is quite healed. Eyes examined; the optic neuritis has improved considerably in both. The flap is bulging more. *July 19th.*—Child gets up and walks about; the gait is rather stiff. Reflexes normal. *August 3rd.*—The flap is bulging more than ever. The pupils are dilated; no nystagmus.

August 14th—Second Operation.—The bone was removed from the left cerebellar fossa. A tumour was seen through the dura. A flap of dura was turned down. A large tubercular tumour, which extended down to the foramen magnum and occupied nearly the whole cerebellar fossa, was removed. It was firmly adherent to the under surface of the tentorium behind. The flap was then replaced, a drain of gauze being left in the middle line. The tumour in this case was larger than in Case 3. In the evening the temperature rose to $101^{\circ}.6$; a great deal of cerebro-spinal fluid escaped. The child vomited several times.

July 15th.—Vomiting continued, profuse discharge of cerebro-spinal fluid. *July 16th.*—Vomiting continues; the child very restless, tossing about. The pulse is very poor, the child apparently dying. 2 P.M.—Three-quarters of a pint of saline, with 4 minims of liq. morph. (1 in 40), infused into a vein in the arm. Child went to sleep immediately; colour returned; pulse improved, and vomiting ceased. 5.45 P.M.—Infused with $\frac{1}{2}$ pint with min. 2 liq. morph. *July 17th.*—Had a quiet night; can now take fluids by the mouth. Temperature above 105° . At 9 A.M. was infused with $\frac{1}{2}$ pint with min. 3 liq. morph. *July 18th.*—Sick twice in night and once at mid-day; infused $\frac{1}{2}$ pint with liq. morph. min. 2. Takes plenty of milk by mouth. Wound dressed

OF TUMOUR OF THE BRAIN 267

every day ; looks well. *July 23rd.*—The flap on left side has begun to bulge. *July 24th.*—Headache ; sick once to-day. *July 25th.*—Headache present. The wounds bulge, but are completely healed. A probe was put through the wound, and a considerable amount of cerebro-spinal fluid escaped under pressure. *July 30th.*—When the wound bulges and no leak occurs there is headache, and *vice versa*. The temperature, which has always been from 100° to 102° since the operation, has now come down to normal. The child is well enough to sit up and knit. *September 2nd.*—A leak had again to be allowed on account of bulging and headache ; this relieves both conditions at once. *September 4th.*—The scar is firmly healed everywhere, except the small hole behind the ear where the leak is allowed. Vomited several times to-day. *September 5th.*—Vomiting continues ; child looks ill ; food by mouth stopped. *September 6th.*—Vomiting continues ; pulse very feeble ; condition very restless. Was infused twice with 1 pint of saline with 3 mins. of liq. morph. After the first infusion the vomiting ceased, and the temperature, which was 103°, fell to 99°, and she was able to take fluid by the mouth to assuage thirst. *September 7th.*—Infused once after being sick. No leak of cerebro-spinal fluid. *September 8th.*—Vomited eight times to-day. *September 9th.*—Vomited four times. The optic neuritis is not better. No leakage. *September 10th.*—The bulging of the flaps was so great that some cerebro-spinal fluid was allowed to escape ; vomited only once. *September 11th.*—Considerable leakage has occurred, and the bulging has subsided ; no more vomiting. *September 13th.*—Child has been better and brighter in every way. No more vomiting ; takes her food by the

mouth; the leak is stopping and the bulge recurring. *September 14th.*—Seemed very well in the morning, but about 11.30 A.M. she had a fit, which affected at first her face only, and very shortly afterwards her whole body was convulsed for a few moments. The face, floor of the mouth, and the tongue remained twitching till about 1 P.M., when some cerebro-spinal fluid was let out and the twitching ceased; but the

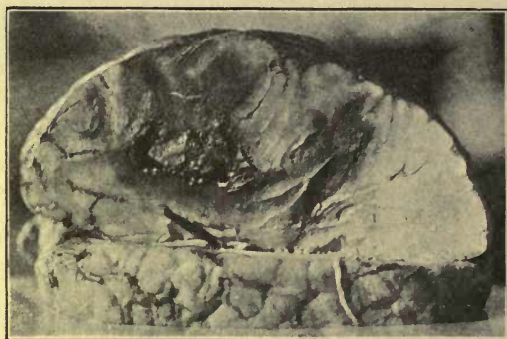

FIG. 120.—Hæmorrhage tearing up left cerebral hemisphere.
(Garrod and Ballance.)

Large tubercular tumour removed three months before from left cerebellar fossa. The patient was a girl 7 years and 10 months old.

child remained unconscious, with the arms rigid and the left pupil widely dilated; the pulse was 70. This condition was unchanged till 5.30, when the respiration suddenly stopped. As the heart continued to beat, artificial respiration was kept up for sixty-five minutes. Then as the whole course of the symptoms was thought, possibly, to be due to recurrence of the tumour, it was decided to explore the cerebellum. The child was taken to the theatre, and artificial respiration being continued, the left side of the cerebellum was exposed. No tumour was found. The brain bulged strongly, and was discoloured with blood; a good deal of clot

was removed from the surface. The breathing, which was resumed after the flap had been thrown down and the pressure relieved, now stopped again. As the heart could not be heard after the injection of ether, the child was thought to be dead, and beyond sewing up the wound nothing was done. The parents were interviewed, and about a quarter of an hour later they left the child. The apparent death took place at 7.10. At 7.45 the Sister of the ward thought she detected a slight movement. On watching carefully shallow respirations were observed at the rate of two per minute. These gradually increased till the rate was five per minute. On listening carefully to the heart it was found to be faintly beating 54-56 per minute. Hot cloths were applied and stimulants injected. There was no other sign of life; the sphincters were relaxed, and no effort at swallowing made. The eyes were examined, but the corneæ were opaque, and prevented the retina being seen. The heart and respirations stopped gradually at 8.30.

Post-Mortem Examination.—No tumour was found. The left side of the brain was discoloured with blood, the veins being engorged with blood over the vortex. The longitudinal sinus was solid with ante-mortem clot. On section the left half of the cerebrum was found to be ploughed up with a large hæmorrhage, which had spread upwards apparently from the lower and back part of the hemisphere. There was no blood in the ventricle, and the cause of the hæmorrhage was not found.

Remarks.—This case is a good example of one in which a regional diagnosis was impossible. It is well known that scurvy in children is not an infrequent cause of hæmorrhage, and I am inclined to think that the long illness of this child had induced a scorbutic condition of the blood.

For the notes of Cases 2, 3, and 4, and for unremitting and skilful care of these three children, I am indebted to Dr. FitzWilliams, the extremely able House Surgeon of the Hospital for Sick Children.

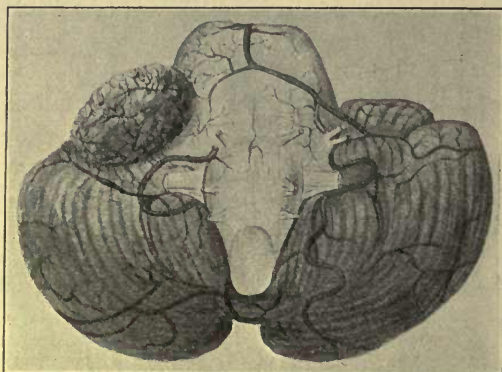


FIG. 121.—Fibro-plastic tumour of Lebert, 1851.

The specimen was shown by M. Broca at the Anatomical Society of Paris. The tumour was growing from the pia mater, the vessels of this membrane ramifying on both surfaces. The cerebellum and pons were hollowed out to receive it, but the substance of the brain was not invaded by the growth. The external surface was of a reddish grey colour. On section the surface was of an ashy grey colour, with vascular streaks and black patches of hæmorrhage. The consistence of the tumour was firmer than that of the brain, and, microscopically, cells and fibro-plastic tissue were seen. There are no clinical details, the tumour having been found accidentally in a woman who died of peritonitis.

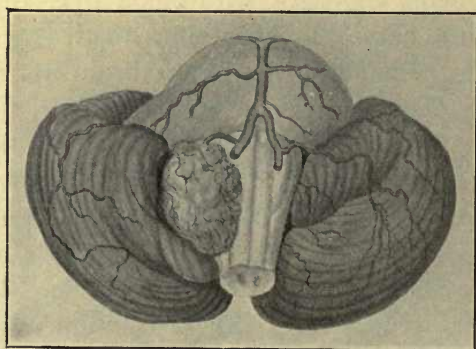


FIG. 122.—Fibro-plastic tumour of cerebellar meninges. (Cruveilhier, 1830.)

The medulla was pressed on by the tumour, so that a shallow depression was formed in which the tumour lay. The medulla was in no way invaded by the growth. No clinical history is given.

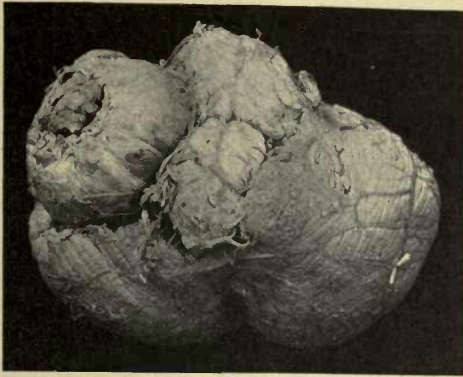


FIG. 123.—Fibro-sarcoma of cerebellar meninges. (R. C. S. Museum, 3787.)

The specimen came from the museum of G. Langstaff to the College of Surgeons in 1835.

The tumour is spheroidal, and presses on the nerves emerging from the right side of the pons and medulla. It is encapsuled, hard in consistence, and, microscopically, is a fibro-sarcoma. (Shattock.)

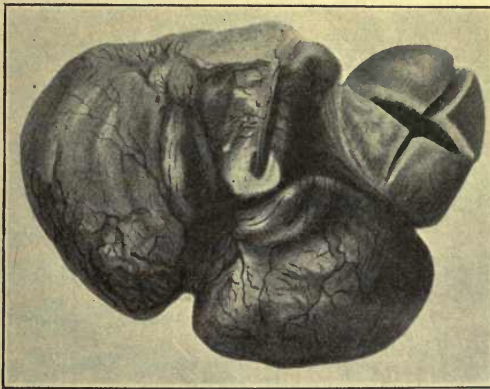


FIG. 124.—Tuberculous tumour of the cerebello-pontine angle. (Auvart.)

Male, aged 30. Severe blow on head three years before admission to hospital. When seen, apathetic, emaciated, nearly blind, all four limbs paralysed, partial loss of sensation on right side of body, and severe left hemicrania. Death three weeks later from convulsions followed by coma.

The paralysis of the homolateral limbs can now be explained, and that of the contra-lateral limbs was due to pressure on the pyramidal tract above the decussation.

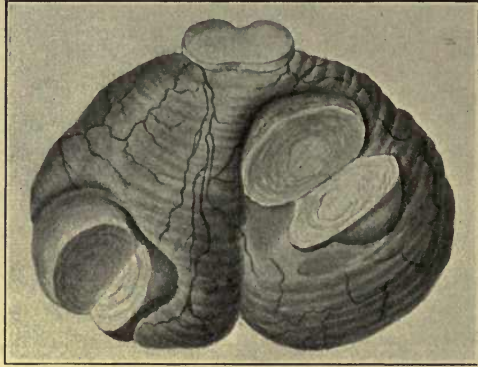


FIG. 125.—Upper surface of cerebellum, showing a solitary tubercle in each hemisphere. (Cruveilhier.)

From a child 9 years of age.

The failure of operation for solitary tubercle may be due to the presence of other tubercular tumours unsuspected during life. This is especially true of the disease in childhood.



FIG. 126.—Endothelioma of cerebellum. (R. C. S. Museum, 3863, A.)

Occupying the posterior surface of the left lobe is a rounded firm tumour. The surface is covered by the membranes, and it lies in a deep indentation of the cerebellum.

From a patient who suffered from osteitis deformans.




FIG. 127.—Solitary tubercle of cerebellum. (R. C. S. Museum, 3786.)

The tumour is firm, oval in shape, and measures 2 in. and $1\frac{1}{2}$ in. in its chief diameters. It is deeply imbedded in the upper part of the cerebellum. It lies directly beneath the pia, and is loosely connected with it and the other adjacent parts.

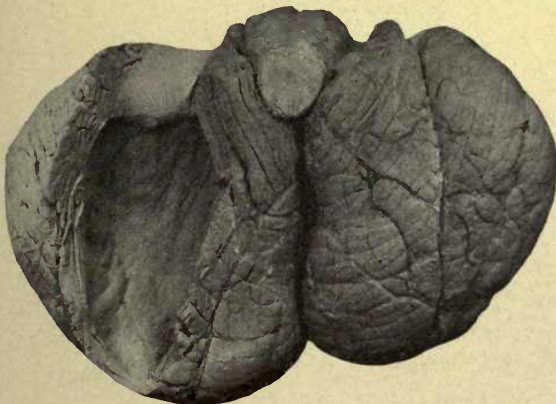


FIG. 128.—Simple cyst of cerebellum. (R. C. S. Museum, 3778 C.)

The right lobe of the cerebellum is occupied by an oval cyst measuring 2 inches in its longest diameter. The wall is formed by a delicate smooth membrane.

From a man, aged 36, who presented symptoms of cerebral disease a few weeks before death. Presented by Dr. Gulliver, 1891.

T

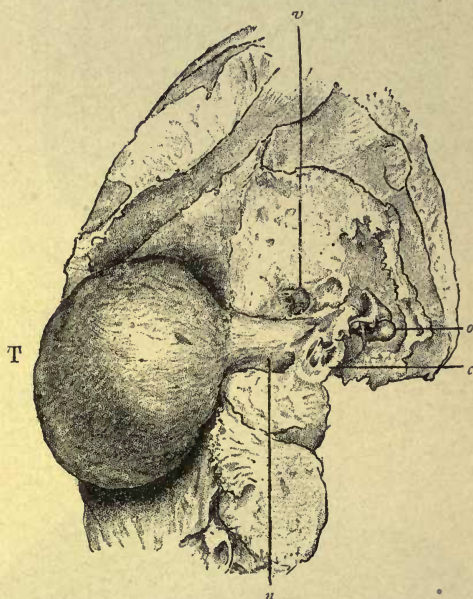


FIG. 129.—Spindle-celled sarcoma of the auditory nerve, the size of a walnut, growing into the internal auditory meatus. (Politzer.)

o, Tympanic cavity with malleus and incus; *v*, vestibule; *c*, cochlea; *T*, sarcoma of auditory nerve; *n*, the new growth extending into the internal meatus.

History of Case.—Patient a woman. Total deafness for ten years. Three months before death double optic neuritis, soon followed by left-sided facial palsy and dementia.

Autopsy.—The facial and auditory nerves were involved in the tumour. No changes had taken place in the tympanum, vestibule, or cochlea.

The specimen was obtained by Dr. von Millingen, of Constantinople, and sent by him to Prof. Politzer.

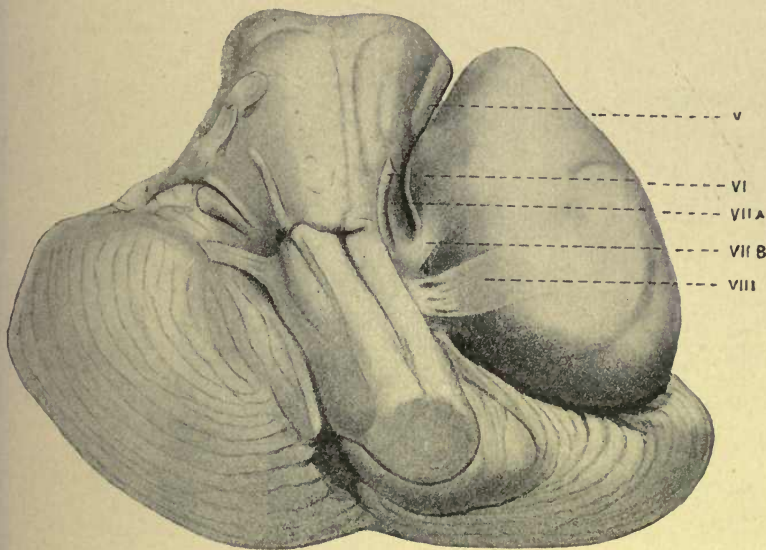


FIG. 130.—Tumour of left auditory nerve. (Sharkey.)

V, fifth nerve ; VI, sixth nerve ; VIIA, facial nerve ; VII B, auditory nerve ; VIII, vagus nerve.

R. G., aged 41, was admitted to St. Thomas's Hospital in 1887.

Present Illness.—Gradual onset for many months. Pain in the head, attacks of vertigo, left ear tinnitus and deafness, some loss of sight, and loss of flesh and strength. Has never vomited.

State on Admission.—Total deafness left ear. Double optic neuritis. No paralytic symptoms. Headache, giddiness, tinnitus, and attacks of unconsciousness.

Six months later the vision was more impaired, hallucinations of vision and fits occurred, and there was left facial paralysis.

Nine months after he was first seen patient died.

Autopsy.—The tumour occupied the cerebello-pontine fossa. It lay in a deep cup-shaped cavity in the left lobe of the cerebellum, and had flattened the left side of the pons and medulla. A portion of the tumour had expanded the internal auditory meatus, and had evidently arisen as a growth from the auditory nerve. Microscopically the tumour was a mass of spindle cells.

Remarks.—Some years ago I observed a somewhat similar case in a woman. At the present day such a tumour would be removed.

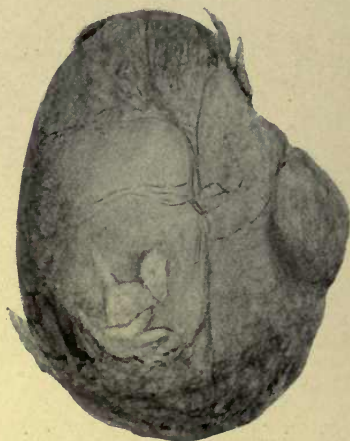


FIG. 131.—Endothelioma of cerebellar meninges. (R. C. S. Museum, 3779, C.)

F. F., aged 26, admitted into St. Thomas's Hospital under care of Dr. Sharkey, June 1902. Three months previously the patient began to suffer from frontal headache and vertigo; the sight was beginning to fail, and there were occasional attacks of vomiting. The headache increased, and was often severe at the back of the head. Two months ago double vision was noticed, with ataxy and difficulty in walking, and deafness of the right ear. On admission the gait was cerebellar. There was no paralysis of limbs and no anæsthesia; double optic neuritis, lateral nystagmus, and slight skew deviation of eyeballs; deafness of the right ear; occasional vomiting. Headache in right occipital region, increased by mental exertion; inco-ordination of right hand; right-sided hemiataxia; tendency to fall to the right and rotate to the left; head depressed towards the right shoulder.

Operation in Two Stages.—August 12, 1902.—I removed the bone over the right lateral lobe of the cerebellum. August 16.—The dura was opened and the tumour removed; the latter was firmly attached to the dura mater on the posterior surface of the petrous bone.

On removing the growth two spurts of blood occurred; the hæmorrhage was quickly controlled by pressure. Death took place twenty-four hours later, although bleeding did not recur. At the autopsy the tumour was found to have been adherent to the dura mater over the lateral and superior petrosal sinuses; this portion of the dura was softened, and the hæmorrhage had taken place from the lateral and superior petrosal sinuses.

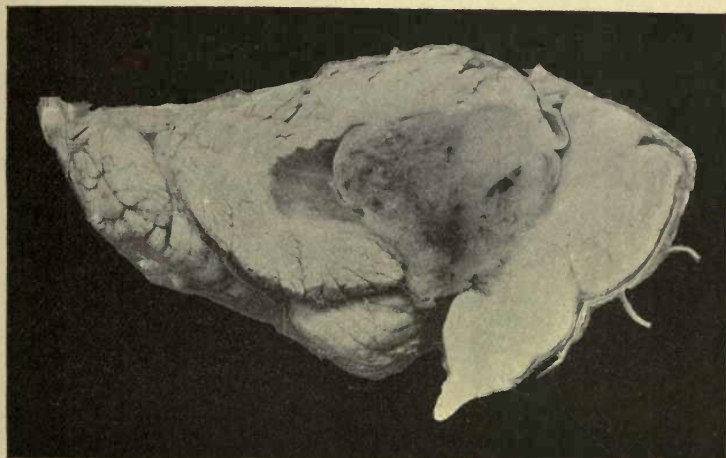

FIG. 132.—Glioma filling fourth ventricle.
(Norfolk and Norwich Hospital Museum, No. 144.)

E. L., aged 11. Female.

Admitted into hospital, August 11, 1900, and died the same day.

Pain in head and back of neck for last eight months; much worse last six weeks, vomiting, staggering gait, and failing eyesight; unable to walk alone for last three weeks. Two generalised fits five days previously, the first lasting quarter of an hour, the second half an hour.

Came into hospital in maniacal condition, shouting and throwing limbs about; resented being interfered with in any way. If quiet at all, assumed position of general flexion; pupils widely dilated, hardly reacted to light at all.

Died suddenly in the afternoon in a condition of asphyxia.

P.M.—Tumour in cerebellum over fourth ventricle. No other tumour in brain. Great excess of cerebro-spinal fluid.

Other organs healthy.

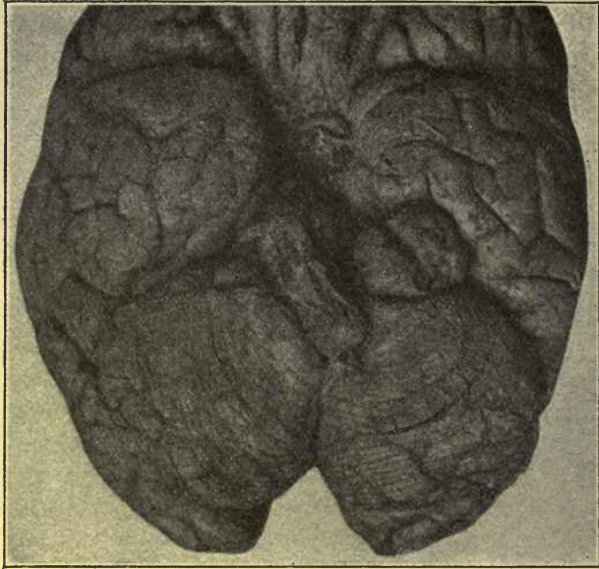


FIG. 133.—Fibroma growing from the left acoustic nerve, compressing the left lateral lobe of the cerebellum and the lower surface of the left temporal lobe. (Weisenburg.)

The tumour was 3 cm. wide and $2\frac{1}{2}$ cm. in the sagittal direction.

The record of this case is given by Dr. Mills in full. It shows how clinically such a growth can be overlooked. At the necropsy the tumour was found together with internal hydrocephalus. For the relief of the syndrome symptoms an operation was performed by Dr. Frazier, the prefrontal region being selected.

"Fibromata are rare, but are relatively more frequent in the cerebellum than in the cerebrum. The majority of these tumours are on the left side. They may undergo cystic, fatty, or myxomatous degeneration. Most writers persist in calling these tumours neurofibromata. The best example of a true neurofibroma is the amputation neuroma, therefore fibroma would be a better term for these growths. Because of the slow growth and the nature of the tumour, clinical symptoms may not appear at all. There may be no symptoms of such a growth, the tumour, unsuspected before, being found at the necropsy."

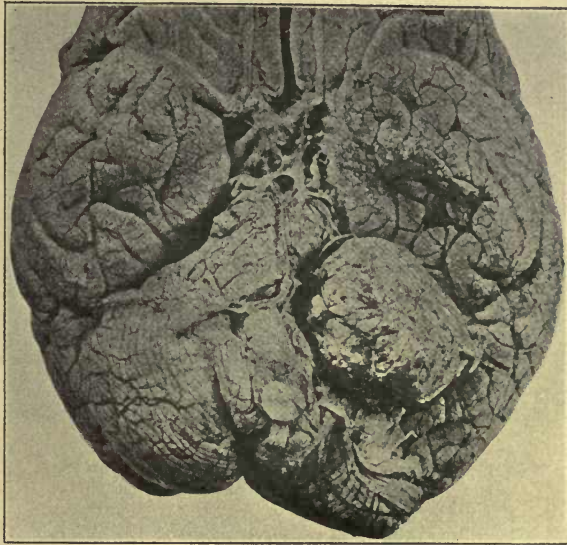


FIG. 134.—A tumour the size of a bantam's egg, of a firm fibrous consistence, in the left cerebello-pontine space. (Fraenkel and Hunt.)

Married woman, aged 51 years. Mental state defective. For $1\frac{1}{2}$ years had weakness of left leg, arm, and face. Hearing impaired, left side. Illness said to have begun six years before. Initial symptoms, headache and vomiting. Vision defective from neuritis, worse on left side. Paralysis of left external rectus. Ataxic walk with tendency to fall to left side.

Fraenkel and Hunt report five cases, two of the left acoustic nerve, one of the right, one case of bilateral tumour of the acoustic, and one of tumour of the right trigeminus.

"In this group of tumours there is an *early appearance* of symptoms referable to involvement of a single cranial nerve. The 8th, 5th, and 7th nerves may be involved; hence occur tinnitus, vertigo, deafness, facial neuralgia, and facial palsy."

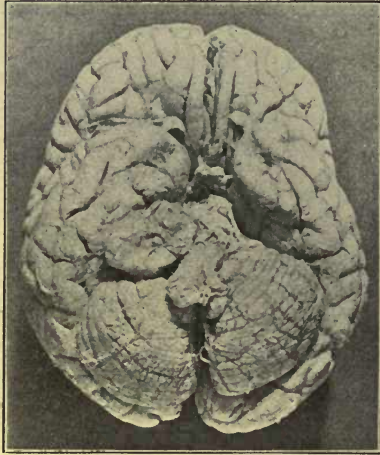


FIG. 135.—Neurofibroma of the right acoustic nerve.
(Fraenkel, Hunt, Woolsey, and Elsberg.)

Male, aged 48. Five years before being seen, diminution of hearing right side. Three years ago, cerebellar gait. Two years ago, impairment of vision.

On examination:—Ataxic gait; falls to *left* side; mental apathy; double optic neuritis; right facial paralysis last four months; right extremities ataxic, left spastic; headache not generally severe; conjunctival and corneal reflexes absent; tenderness right occipital region. Patient died forty-eight hours after first stage operation.

The authors describe another case in a man aged 42, also fatal after operation. In this patient, as in the one described, the 5th, 7th, and 8th cranial nerves on the side of the tumour were involved.

At the end of the paper a *résumé* of six other cases previously published is given.

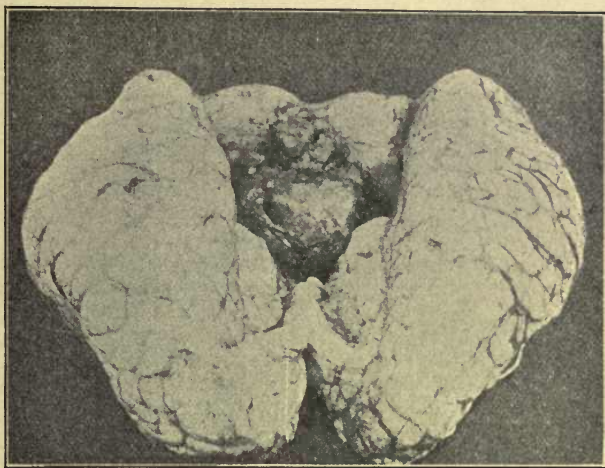

FIG. 136.—Encapsulated sarcoma of the cerebellar meninges compressing upper surface of vermis. (Hendrie Lloyd and Perceval Gerson.)

F. E., male, aged 21.

Discharged in 1894 from nautical school ship for stupidity and insubordination. Subsequently became irritable, melancholy, and suffered frequent headache.

No history of trauma.

Present illness.—In August 1897 intense headache, dull mentally. Failure of sight and hearing.

On and after Admission to Hospital, February 1898.—Semi-stuporous condition. Limbs flexed. Head held by hands. Complains of pain in head. Can scarcely stand, and if assisted to do so has tendency to pitch forward. Total deafness. Double optic neuritis. Patellar jerks change in intensity—normal, minus, or plus. Several attacks of vomiting. Study of various forms of sensation impracticable. Patient became gradually weaker, respirations assumed Cheyne-Stokes type, and patient died April 3, 1898.

Autopsy.—A large encapsulated nodular tumour was found lying upon the vermiform process beneath the tentorium. It had grown from the meninges. It was not adherent to the brain, but had compressed the vermis and quadrigeminal bodies. The tumour was 6 cm. wide and 6.5 cm. long. The tumour was vascular and was a sarcoma. The aqueduct of Sylvius was pervious. The ventricles were much distended.

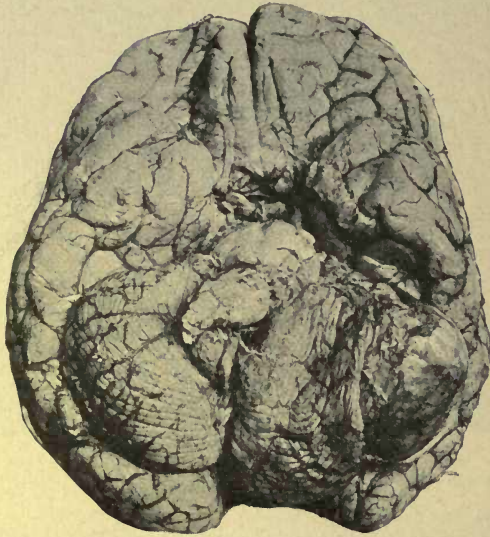

FIG. 137.—Fibro-sarcoma of left cerebellar hemisphere. (Chance and Spiller.)

Male, aged 26. Severe occipital headache, Easter 1904. In July vomiting occurred. In November paralysis of left external rectus, dimness of vision, and photophobia. In December slight left facial palsy and double optic neuritis. Patient gradually deteriorated, and developed a tendency to fall towards the left side. He died suddenly on April 7, 1905.

Remarks.—The tumour was situated upon the outer portion of the left lobe of the cerebellum, to which it was only loosely attached. It was very favourably situated from the point of view of operation. It measured $4 \times 5.5 \times 5$ cm., was hard in texture, and had deeply indented the cerebellar hemisphere. The third and lateral ventricles were somewhat dilated.

Fibro-sarcoma of Cerebellar Meninges.

Figs. 138 to 144.

To prove that operation for cerebellar tumour in the adult may be completely successful, I may mention that in 1894 I removed an encapsuled fibro-sarcoma from the right cerebellar fossa of a woman aged forty-nine years, and that she is alive and well now. The following is an account of the case :—

Female, aged forty-nine. Seen with Mr. Lunn and Dr. Beevor.

Family History.—One brother and one sister died of phthisis. *Present Illness.*—Twelve months ago began to suffer from vertigo and pains in head, chiefly in frontal region, and mental dulness. During last six months eyesight has been failing and the right ear became deaf. During the last three months pain in the back of the head has become more marked, and she has had several attacks of severe vertigo and right ear tinnitus; she has never lost consciousness. Has lost flesh and strength lately. No history of injury.

Present Symptoms (November 14, 1894).—Headache, vomiting, double optic neuritis: right disc more swollen. Right grasp less than left. Right knee-jerk more brisk than left. Is giddy when walking, and tends to fall towards the left. Lateral and vertical nystagmus: former more marked on looking to left. Scars of old suppurative otitis on right drum. No tenderness on percussion of cranium anywhere. Watch heard at half inch on right side; left ear hearing normal. No anæsthesia anywhere or loss of muscular sense. No inco-ordination of upper limbs.

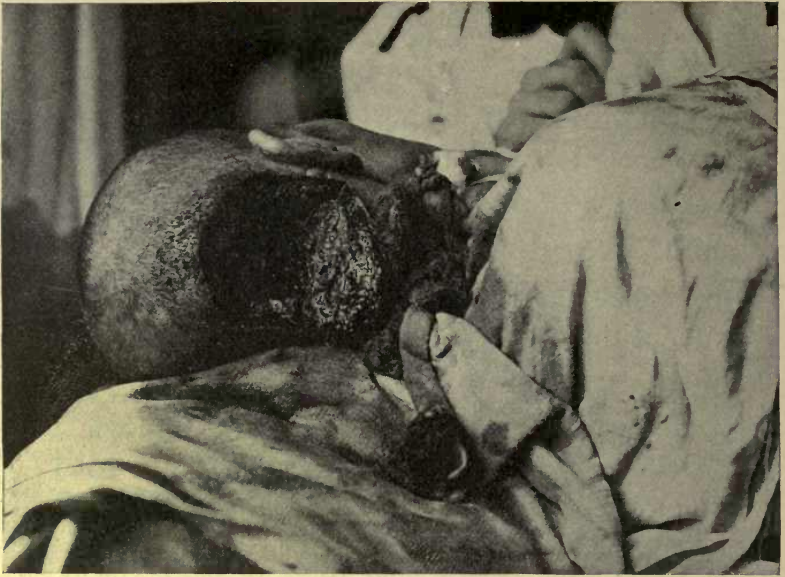

FIG. 138.—Photograph taken during operation.

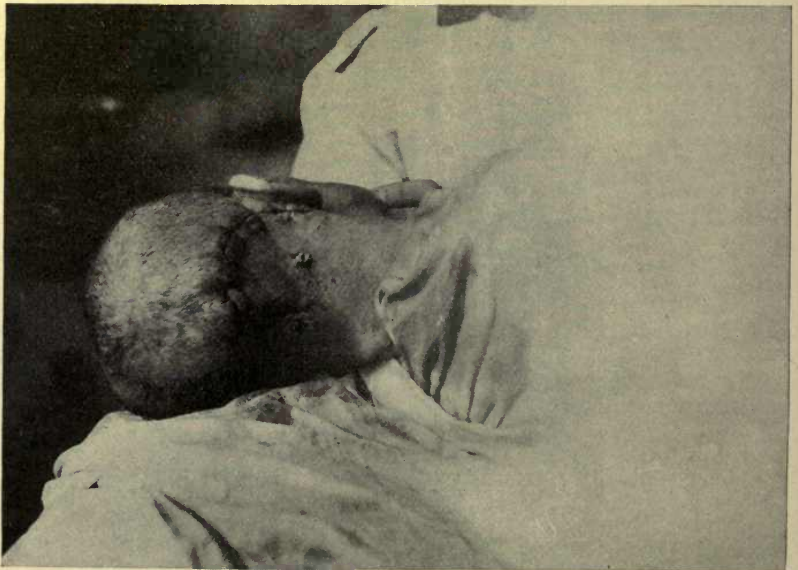


FIG. 139.—Photograph taken at completion of operation.

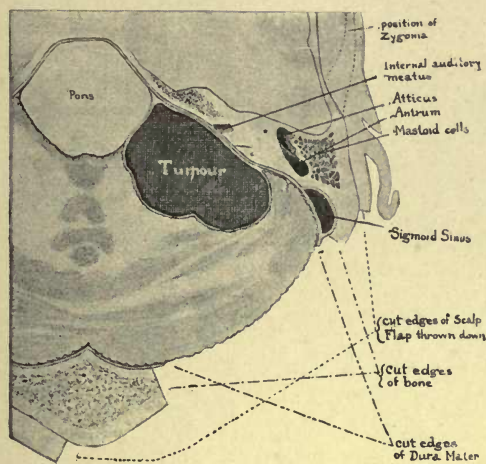


FIG. 140.—The diagram represents a nearly horizontal section passing through the petrous. It was drawn the day after the removal of the tumour. It shows the extent of the opening in the bone and dura, and the position of the tumour before its successful removal.

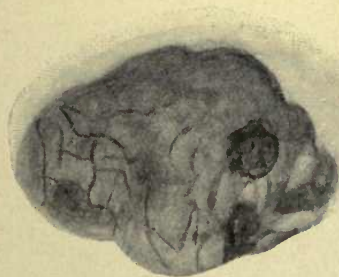

FIG. 141.—Photograph of tumour immediately after removal.

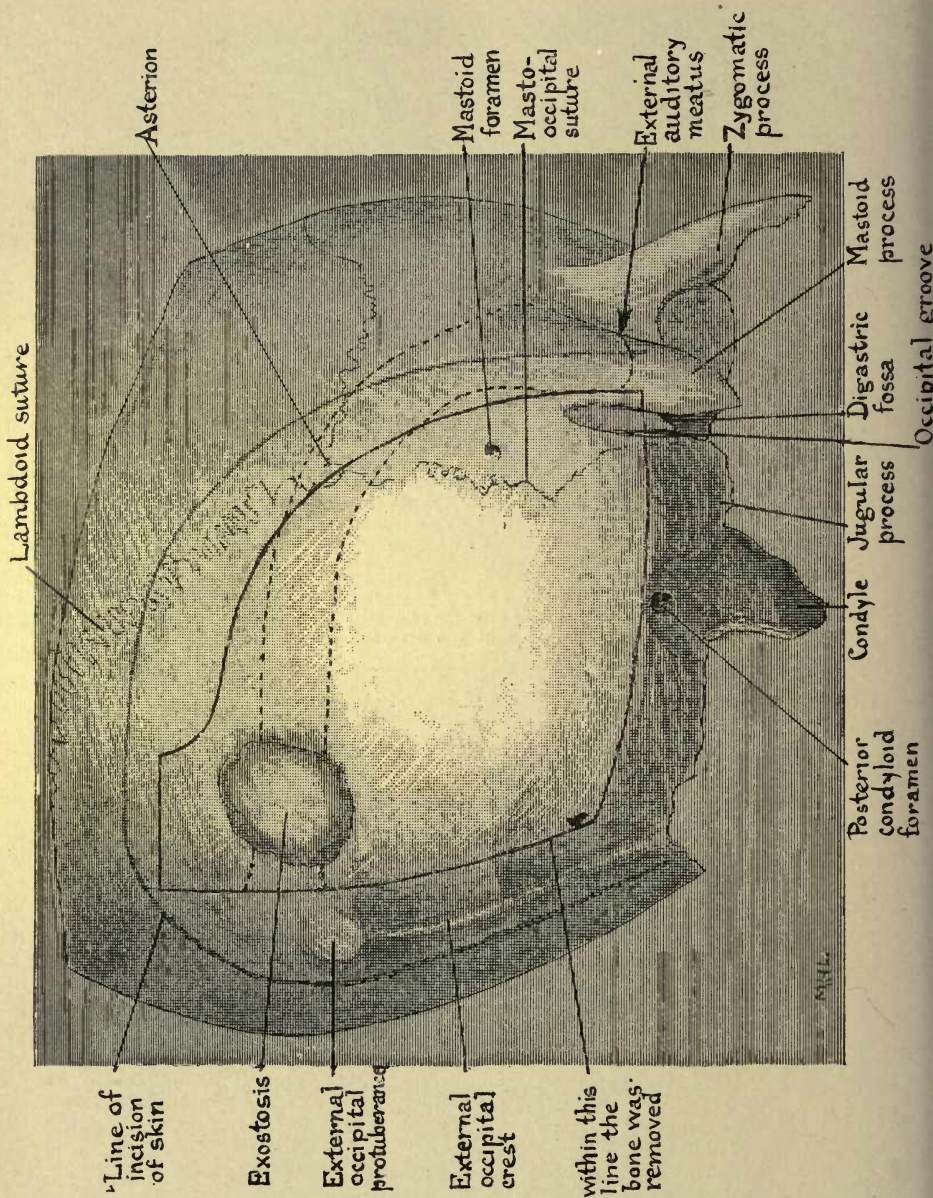


FIG. 142.—Drawing of right occipital region of skull, showing the outline of the scalp flap, the portion of bone removed, the course of the sigmoid sinus, and the site of the exostosis.

Operation, November 19, 1894.—Scalp flap thrown down in right occipital region and bone removed. Towards the external occipital protuberance an exostosis was discovered and removed. The exostosis presented towards the dura as well as externally. The inward projection had occluded the lateral sinus. When, therefore, the exostosis was removed the sinus filled up, causing a considerable alteration in the venous circula-

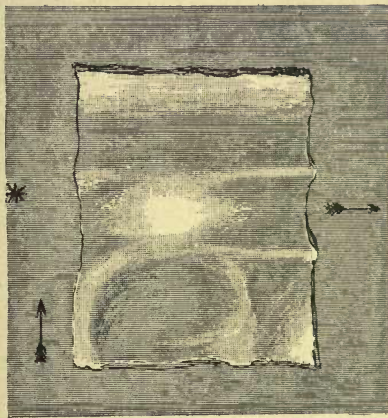


FIG. 143.—Inner aspect of bony groove for lateral sinus in the region of the exostosis. Note that the exostosis projected inwards, and thus obliterated the groove.

tion. The result was the patient collapsed, and respiration ceased. Patient was revived with much difficulty.

Operation, November 26, 1894.—Flap thrown down, and then dural flap thrown down. Solid tumour found attached to dura over inner part of posterior surface of petrous. Somewhat firmly fixed, and the finger had to be insinuated between pons and tumour to get it away.

Patient, after a somewhat protracted convalescence,

recovered. The fifth and seventh nerves were injured at the operation, and the right eye ulcerated and had to be removed. The optic neuritis in the left eye



FIG. 144.—Patient twelve years after operation for cerebellar tumour.
(Mr. Lunn's case.)

The scalp flap is concave. The ala nasi has been destroyed by trophic ulceration, the result of injury to the fifth nerve.

cleared up with recovery of good eyesight. Some trophic ulceration occurred at the angle of the mouth and at the right ala nasi; this ultimately healed.

September 1906.—Patient is alive and well, but has right facial palsy and anæsthesia corresponding to the right fifth nerve.

FIGS. 145 to 148, *illustrating a case of Compound Comminuted Fracture of the Skull and Laceration of the Brain which was under my care twenty years ago.*

The case is introduced so that a comparison may be made between Fig. 145 and Figs. 81, 82, 83, 118, 119, 144, 171, and 172. After the comminuted fragments of a fracture of the skull are removed, and the patient recovers, the scalp falls in, forming a concave depression. The same is true after removal of a brain tumour so soon as the conditions within the cranium become normal. Recurrence or regrowth of tumour, or conditions which make for a continuance of abnormal intra-cranial tension, cause the scalp depression to disappear. The scalp over the cranial defect will then be on the same level as the rest of the scalp, or it will bulge. Concavity of the scalp flap will thus point to complete recovery, and convexity to a persistence of abnormal intra-cranial conditions.

Figs. 81, 82, 83, and 172 show bulging of the flap. In the cases represented in Figs. 81, 82, and 83 no tumour was removed: the cause which produced the symptoms of tumour persists though the urgent symptoms are relieved. In Fig. 122 the scalp previously concave after removal of the tumour again became convex as the growth recurred.

The patient, a man aged 26, was brought to the West London Hospital in an unconscious state. He had been kicked a short time previously in the stable on the right side of the head by a horse of which he had charge. A very severe comminuted "saucer" fracture had occurred, sharp hæmorrhage was taking place from the middle meningeal artery, and there was considerable laceration of the anterior region of the frontal lobe.

The surgical treatment need not be described. The man made an excellent recovery, and eight months after the injury was driving a pair of horses about London all day.



FIG. 145.—Portrait of patient eight months after injury (August 1886). The hair, which had grown freely over the depressed scalp, was cut off for the purposes of this sketch. The slight appearance of squint is incorrect.

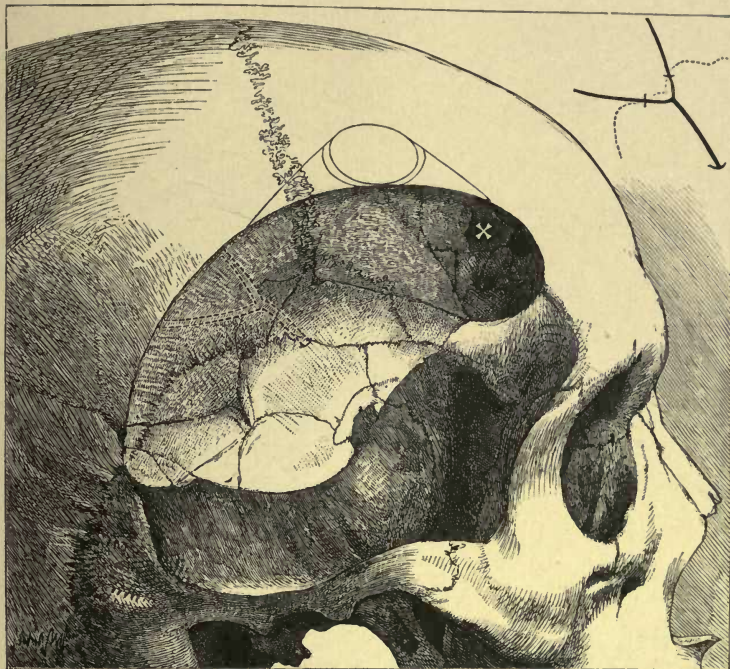


FIG. 146.—Diagram two-thirds natural size, showing the extent of the depression in the temporal region. The normal sutures, the lines of fracture, and the position of the middle meningeal artery are marked. The artery below the point where it is indicated by a dotted line entered a canal in the bone. The small diagram in the upper right-hand corner is to make clear the points of breakage and ligation of the two main branches of this vessel. *x* indicates about the point where the calkin or heel of the horseshoe drove a portion of skull into the brain. The semicircular line of fracture behind this point was evidently caused by the semicircular edge of the horseshoe. The bone along this line was so cleanly fractured that it looked as if it had been cut with a knife.

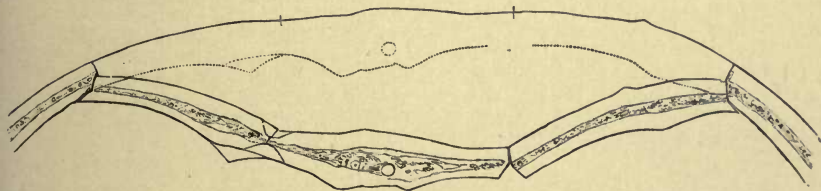

FIG. 147.—Diagram (natural size, and taken from the pieces of bone which were removed after they had been fitted together). The breaking away of the inner table to a greater extent than the outer, and the close and even fitting of the fragments at the lines of fracture is represented. The depression partly caused the locking of the fragments, as it was not abrupt, and any attempt at elevation only jammed them more tightly together, hence the resort to the trephine. The foramen is for the middle meningeal artery.

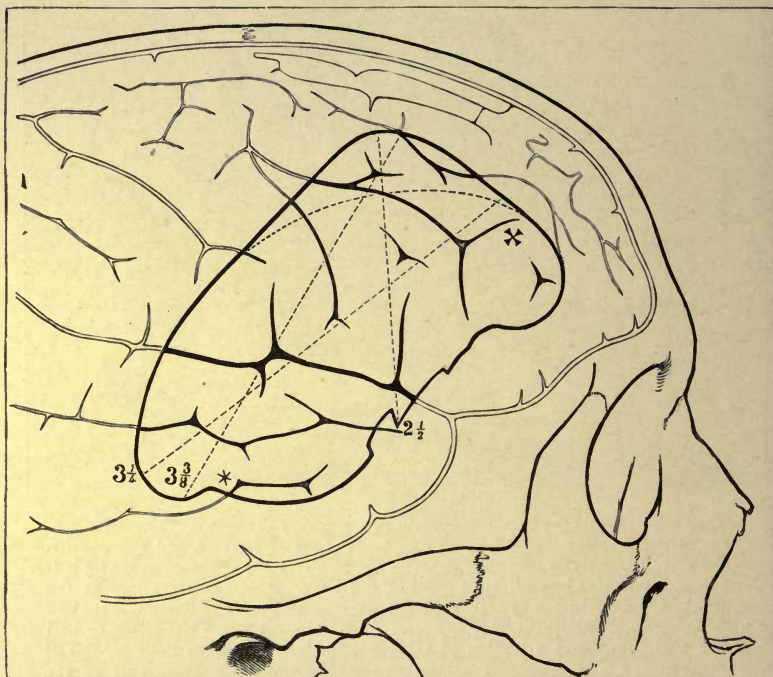


FIG. 148.—Diagram (two-thirds natural size) to show the extent of brain, which can now be felt pulsating underneath the scalp. Part of the Sylvian fissure, and convolutions and sulci of the frontal, parietal, and temporo-sphenoidal lobes are exposed. The figures against the straight dotted lines indicate in inches the size of the opening. The curved dotted line separates the bone depressed by the horse-kick from that removed with the trephine. \times shows about the spot where the calkin or heel of the horseshoe drove a portion of skull into the brain; * indicates the place where a counter-opening was made in the dura mater and a catgut drain inserted.

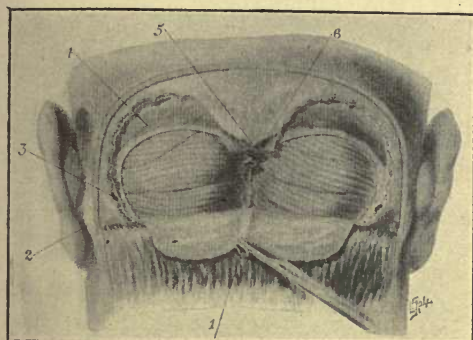


FIG. 149.

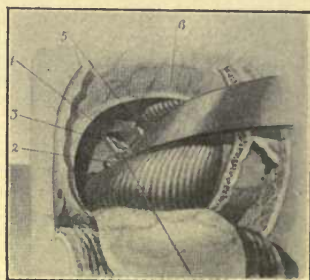


FIG. 150.

FIG. 149.—Operation for simultaneous exposure of both cerebellar hemispheres, necessitating ligation of the occipital sinus. (Charles Frazier.)

1. Occipital sinus which has been ligated and reflected with the dura. 2. Mastoid process. 3. A tributary of the lateral sinus. 4. Lateral sinus. 5. Occipital protuberance. 6. Occipital sinus.

FIG. 150.—Structures in relation to the anterior aspect of the cerebellar hemisphere and the posterior surface of the petrous. Note the position of the 5th, 7th, and 8th cranial nerves. 2. 9th, 10th, and 11th cranial nerves. 3. Auditory nerve drawn to one side. 4. The facial nerve is seen on its inner side. 5. Root of trigeminus as it enters the groove on the apex of the petrous.

Frazier urges early operation. He writes: As the exploratory operation is recognised as the surest, safest, and most reliable diagnostic measure in tumours of the stomach, it should be considered of equal value and importance in tumours of the brain. It is unnecessary to preserve the overlying bone, therefore the osteoplastic flap which has done so much to revolutionise the surgery of tumours of the cerebrum is not to be employed in tumours of the cerebellum. Puncture of the ventricles and lumbar puncture is attended by danger owing to the sudden disturbance of pressure, as illustrated by many fatalities. Frazier recommends the removal of one-third or one-half of the cerebellar hemisphere in order to explore a tumour before removal, and thus avoid traumatism by the finger and undue pressure or traction on the pons or medulla. He says the percentage of tumours found is yearly growing larger, the percentage of partial or complete recoveries is larger, and the mortality has fallen from 70 to 38 per cent.

Tumours of the Cerebrum.

Time will allow only a few remarks on the localising symptoms of tumours of the cerebrum. In man the left cerebral hemisphere controls the highly specialised movements of the right hand, is the seat of the sensori-motor nervous mechanism of speech and writing, and it appears also that the left prefrontal region is more concerned with the higher psychic functions than the right. The leading half of the cerebrum is therefore the left, or, as Professor Cunningham puts it, man is left-brained and right-handed. He writes: "It is easy to prove that the characteristic right-handedness is one of vast antiquity. Of this there is the clearest evidence, not only in historical records and pictorial representations, but also in ancient mythology and in the structure of almost all languages. It appears probable that right-handedness assumed form as a characteristic at a very early period of man's evolution, and most likely before he became endowed with the power of articulate speech. The ape is ambidextrous. There is a much higher percentage than in the normal individual of microcephalic idiots who are ambidextrous,

and consequently a great reduction in the percentage of those who are right-handed. No sooner did man assume an upright gait than the work of the right hand grew in importance, the

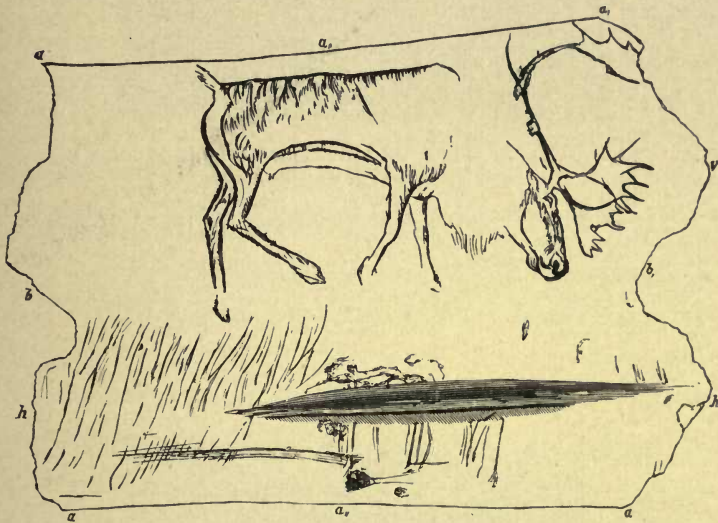


FIG. 151.—The reindeer of the cave of Thayngen, near Schaffhausen.
(From *Early Man in Britain*, by Prof. Boyd Dawkins.)

“Referring to the fact that in these sketches the animals depicted sometimes look to the left and sometimes to the right, Sir Daniel Wilson remarks: ‘This is a nearly unerring test of right or left handedness. The skilled artist can, no doubt, execute a right or left profile at his will. But an unpremeditated profile drawing by a right-handed draughtsman will be represented looking to the left.’ In the majority of palæolithic drawings within my reach the animals depicted look to the left, which in some small degree suggests the idea of right-handedness on the part of the artist. With regard to those in which the profile looks to the right, absolutely no proof can be obtained either in one way or the other, and it is absurd to put them down to the work of left-handed artists. The impression that one receives from the engraving of the grazing reindeer is that it was undoubtedly depicted from life, and that the animal happened to be facing to the right at the time the artist was engaged in his work.” (Quoted from Cunningham.)

functional superiority of the left hemisphere became pre-eminent, since all the movements which require the higher guidance of the brain



FIG. 152.—Perforated antler discovered in the cave of La Madelaine.
(M. Gabriel de Mortillet.)

A human form is seen between two horses' heads. From the attitude of the figure and the position of the right upper limb, which holds a baton or stick, right-handedness is strongly suggested.

"It is most unfortunate that so few of the artistic efforts of the palæolithic cave-dwellers have been directed to the delineation of man. By such representations alone would it be possible to judge the point at issue." (Cunningham.)

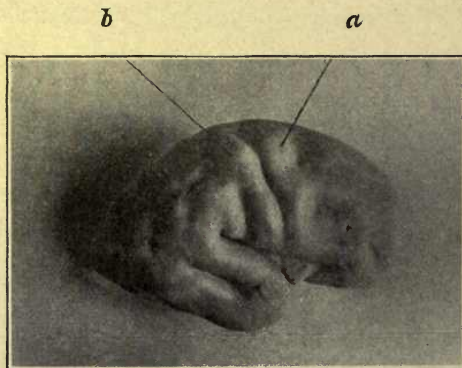


FIG. 153.—Right cerebral hemisphere from a human fœtus in the latter half of the 6th month of development. (Cunningham.)

a, Elevation which corresponds to the motor area of the arm; *b*, corresponding elevation behind the central fissure.

"These cortical elevations are undoubtedly connected with the development of function in localised areas, and represent the arm centre of the cortex. Possibly the bulging behind the central fissure is the receptive centre to which sensory impressions travelling from the upper limb are conveyed." Cunningham was unable to discover in the developing brain any material difference between the arm centres of the left and right hemispheres.

are performed by the right hand. Further, the active speech centre is situated in the left cerebral hemisphere, and the greater part, if not the whole, of the motor incitations which lead to articulate speech go out from the speech centre which resides in the left cerebral hemisphere. There are probably no series of motor acts which require a greater refinement of adjustment than those that result in articulate speech. It is indeed remarkable that it should have fallen to the lot of one cerebral hemisphere to preside over the movements accompanying speech in the same way as it presides over the movements of the skilful right hand. If the ape is truly ambidextrous, it is reasonable to conclude that in the evolution of man right-handedness did not assert itself until the upper limb had been set absolutely free from the office of locomotion, and had assumed the higher duties which are now assigned to it."

Tumours involving certain regions of the left cerebral hemisphere are liable to cause derangements in the expression or in the recognition of the visual or auditory symbols by which ideas are communicated (the *facultas signatrix*), and are therefore more easily recognised clinically than tumours of corresponding parts of the right hemisphere; for example, the right temporo-

sphenoidal lobe is often described as a "silent" region of the brain.

A brain tumour may begin in the meninges and invade or displace the cortex secondarily, or it may begin in the subcortical tissue and then grow towards the cortex or towards the deeper parts, such as the internal capsule. The history of the case and the march of the symptoms may decide this point. A meningeal tumour, or one invading the cortex, may be the cause of local tenderness, or pain on pressure or percussion. Abducens palsy is not a localising symptom. Tumours growing in the deeper parts of the brain, such as the optic thalamus, the corpus striatum, or the pituitary body, are at present spoken of as "inoperable." This is incorrect, for much may now be done for these cases by decompressive operations, and it is by no means improbable that in the near future they will be successfully removed. A fit is, as we all know, an occurrence common to irritations arising in all parts of the cerebral cortex. Its localising value depends on the recognition of the site of the initial local spasm, or the clear description by the patient of a psychic or sensory aura preceding the fit. The persistence of a local paralysis after the conclusion of a fit is evidence of a gross lesion. A sensory aura—olfactory, auditory, or

OF TUMOUR OF THE BRAIN 299

J. M., aged 40, admitted to the National Hospital under the care of Dr. Ferrier. He was afterwards under the care of Dr. James Taylor, who asked me to operate.

The patient is a left-handed man with right hemiplegia. He used to bowl with the left hand, but writes and feeds himself with the right hand.

One year ago he commenced to have difficulty in writing with the right hand. Five months ago in India he had several "fainting attacks" and lameness of right leg. He then came to England, and shortly afterwards was admitted to hospital. There was right hemiplegia most complete in arm. Speech slow, difficulty in completing a sentence, sometimes used wrong words, easily confused, and emotional. The left superior parietal region was tender to firm pressure. The right side was incompletely hemianæsthetic and hemianalgesic; the loss of sensation did not affect the face, and was most marked in the right hand and foot. The sphincters were unaffected. Headache was severe, and double optic neuritis was present. Antisyphilitic treatment did not have any effect on patient's condition.

The patient gradually became worse; the optic neuritis increased, the headache was very severe, the mental dulness and difficulty in speaking increased, and operation was decided on.

Operation.—The bone was removed over the left parietal region, and over the posterior part of the left upper frontal region. On opening the dura, which was under considerable tension, the convolutions were found to be flattened, but no tumour could be felt by palpation through the cortex. An incision sufficient to admit the finger was made through the caudal extremity of the first frontal convolution. On introducing the finger through the cortex into the centrum ovale for $1\frac{1}{2}$ inches in a direction downwards and backwards, a hard, rounded tumour was felt, and slowly enucleated with the finger. There was no material hæmorrhage and no shock. The wound was closed in the ordinary way.

The tumour was about the size of a golf ball. It measured $1\frac{1}{8} \times 1\frac{1}{2} \times 1\frac{1}{4}$ inches, and weighed just 2 oz. The removal of the tumour was effected without opening the ventricle. As the tip of the finger reached the deepest surface of the tumour the whole finger was enclosed within the brain. The tumour must have occupied a subependymal position, and was at the site of or close by the optic thalamus. On making a brain section and measuring the distance from caudal extremity of the first frontal convolution to the optic thalamus, it was found to be $2\frac{1}{2}$ to $2\frac{1}{2}$ inches. On microscopical section the central part of the tumour was found to be degenerating.

After the operation the headache disappeared, the wound rapidly healed, but for a few days the aphasia was almost complete. Four weeks after operation there was no headache, the optic neuritis had subsided, and speech was much improved; the arm was still paralysed, but the right hip and knee movements were strongly performed. The hemianæsthesia was much less than before operation. Mentally, patient was bright, but was easily fatigued by conversation.

Patient had only two months respite from distressing symptoms, the scalp flap then began to bulge and he was readmitted, a little over three months from the first operation, comatose and with the flap greatly bulging and very tense. Operation was immediately carried out and a tumour mass 6 oz. in weight removed. For two weeks afterwards he was sensible and able to indicate simple wants, but a fungating mass again protruded through the cranial opening from which several hæmorrhages took place. Death occurred four weeks from the second operation. The second tumour was more cellular and more vascular than the one first removed.



FIG. 154.—Sarcomatous solid tumour of (?) optic thalamus.

visual—localises the tumour behind the motor region. Idiopathic epilepsy, hæmorrhage, dementia, and melancholia must be recognised apart from brain tumour. Among the sources of error in localisation may be mentioned multiple tumours and œdema spreading widely

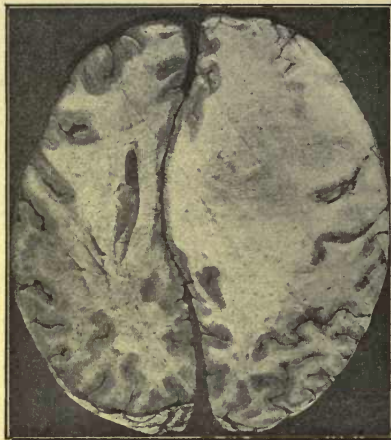

FIG. 155.—Spreading œdema of the centrum semi-ovale, from a small nodule in the right prefrontal cortex, secondary to a renal carcinoma. (James Collier.)

The cerebral symptoms were very urgent, and death occurred in fourteen days after their appearance. There were no localising signs during the first seven days. The white matter of the right hemisphere was enormously swollen, softer than normal, and somewhat jelly-like in appearance.

from a tumour—a condition described by James Collier. It is often difficult to determine whether tumour is present or not when the symptoms are not typical, and it is to be borne in mind that large, slowly-growing tumours may be present without any symptoms which are unequivocal. For example, epileptic fits

and headache may lead to the suspicion of the presence of tumour years before other symptoms arise which justify operation. It was formerly thought that occasional fits beginning locally, followed by loss of consciousness, though attended by persistent local headache, would not justify an operation unless optic neuritis was present. It is now known that optic neuritis may not be manifest till shortly before death ; and it is no longer thought necessary, but rather disastrous, to await the completion of the syndrome before operating : the importance of opening the skull before the tumour has attained a large size being fully recognised. Surgical intervention is, unhappily, still our only remedy for certain classes of brain tumours, but only too generally the same apathy prevails in adopting this remedy as was prevalent twenty-five years ago in operating for analogous disease in the abdomen. It has been already pointed out that the difficulty of making a precise diagnosis at an early stage of the disease is prominent among the obstacles to successful operation. Not many years ago the nature of many abdominal diseases was not ascertained until the abdomen had been opened. In the early Listerian days the condition found on opening the abdomen often differed widely from that expected. This is

much less frequently the case now. The diagnosis of intra-cranial disease is, speaking generally, a far more complex problem than that

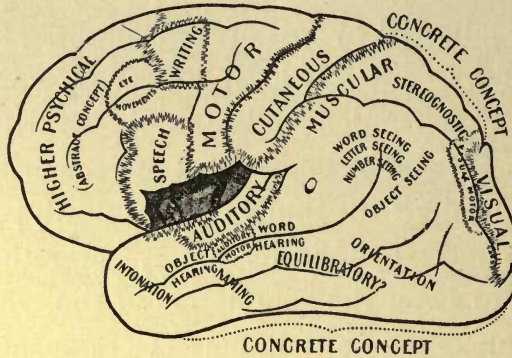


FIG. 156.—Areas and centres of the lateral aspect of the human hemisphere. (Mills.)

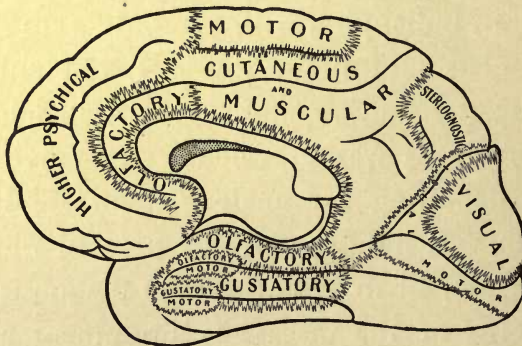


FIG. 157.—Areas and centres of the mesial aspect of the human hemisphere. (Mills.)

of intra - abdominal disease ; and, moreover, within the skull an exploratory operation cannot be conducted in the same rapid and complete manner and with so little serious risk as in the

abdomen. The maxim that diagnosis must precede operation is only true of those diseases, the signs, symptoms, and course of which are fully comprehended. When the early clinical manifestations of a disease are ill understood, and when danger attends delay, the surgeon is content to act upon a provisional diagnosis. Many lives are thus saved, and diagnosis becomes perfected.

The signs and symptoms of tumour of the occipital, frontal, and parietal regions will now be briefly referred to, and some cases related which illustrate the statements made. The functions of the cortical regions of the cerebrum are illustrated by the diagrams of Mills. The convexity of the hemisphere is the region of most interest to the surgeon, since it is the surface which is exposed in all procedures for the operative removal of brain tumours. The other surfaces and the deeper parts are not so directly accessible, and will only be incidentally referred to in this lecture.

Tumour of the Occipital Lobe.

In the cortex of the occipital lobe and of the adjoining parts of the parietal and temporo-sphenoidal lobes are situated the visual centres. Various authors agree in stating that the retina is represented on each side of the calcarine fissure. The primary visual cortical centres are on the mesial part of the occipital lobe. Here objects are *seen*, while in the higher visual centres they are *recognised*. These higher visual centres lie in the cortex of the outer aspect of the occipital lobe, and extend on to that of the adjacent lobes. Possibly the centres for colour recognition lie in the cortex of the convolutions (temporo-occipital) of the tentorial aspect of the occipital lobe.

Henschen of Stockholm has met with a remarkable series of cases illustrating the cortical localisation of the sense of vision as distinct from the higher centres for the recognition of things seen. When the grey matter of the calcarine fissure, or the fibres of the optic radiation leading thereto, are destroyed, the patient does not see objects on the contra-lateral side of the median line (homonymous lateral hemianopsia). When the higher centres on the external aspect of the cortex are destroyed, the patient has, not hemi-

anopsia, but mind-blindness, word-blindness, and other defects of appreciation of the objects seen,—seeing, he sees but does not perceive. These higher visual centres attain a higher degree of evolution in the cortex of the left hemisphere. Not only does a total lesion of the calcarine visual centre produce complete hemianopsia, but a partial lesion of the grey matter of the calcarine fissure (or of the optic radiation) produces an absolute scotoma of constant nature. A lesion limited to the upper lip of the calcarine fissure determines a scotoma involving the upper part of the contra-lateral half of the visual field, a lesion limited to the inferior lip of the calcarine fissure determines a scotoma involving the lower part of the contra-lateral half of the visual field, lesions of the bottom of the calcarine fissure determine a scotoma involving the middle portion of the contra-lateral half of the visual field. Henschen gives several charts of visual fields from cases illustrating his views. He also relates the following remarkable case of bilateral lesion :— In the left hemisphere the cortex of the calcarine fissure was destroyed, the lesion only involving the white matter quite close to the occipital pole, so that the optic radiation was in no way affected. Besides this, nature had made a re-

markable control experiment ; the lateral surface of the other (right) hemisphere was to a great extent destroyed, but this second lesion did not give rise to hemianopsia, which was present only on the right side of the field of vision. He also relates a case in which there was hemianopsia and scotoma due to the presence of a bullet which had lodged in the calcarine fissure, and which was successfully removed.

Touche of Brevannes considers that there is a special centre for "topographical memory," which he defines as the faculty of recollecting, not the objects themselves, but their relative positions in space. He instances a patient who could describe perfectly Notre Dame, the Hôtel Dieu, and the Palais de Justice, but could not describe their relative positions to one another and to the Seine, though he had lived for many years in that part of Paris. His conclusions are—1. That topographical memory may be affected independently of its constituent elements. 2. That a lesion of the left hemisphere only will determine its loss. 3. That the centre for topographical memory is on the inferior surface of the temporo-occipital lobe. 4. That complete destruction of what is ordinarily termed the visual area (the cuneus, the lingual and fusiform lobules) on the left side is compatible with the

persistence of the memory of contours and colours. 5. That even a partial destruction of the fusiform lobule (middle third) on the left side causes loss of topographical memory. He relates cases which appear to show that when this particular area is uninjured the patient, though he may have hemianopsia, is able to find his way about ; when it is destroyed, the faculty of orientation may be lost, though there is no hemianopsia.

The one striking symptom of tumour of the occipital lobe is some form of defect in visual innervation, the most common being hemianopsia, the objects on the opposite side of the median line not being seen. Hemianopsia is almost always present, and its localising value is especially great when it is first in date among the symptoms of tumour. Visual hallucinations or spectra may precede the hemianopsia, as in the case of angiolithic sarcoma recorded in the early part of this lecture. In a case of tumour of occipital lobe described many years ago by Gowers, the hallucination took the form of a flickering of light like a golden serpent moving very fast in all directions.¹

¹ In one of Oppenheim's cases of tumour of the occipital region the man before operation had hemianopsia, and after operation for a time described his hands as looking like coloured plush.

The Wernicke hemianopic reaction of the pupil is a means of determining whether the lesion lies between the optic chiasma and corpora quadrigemina, or farther back in the visual

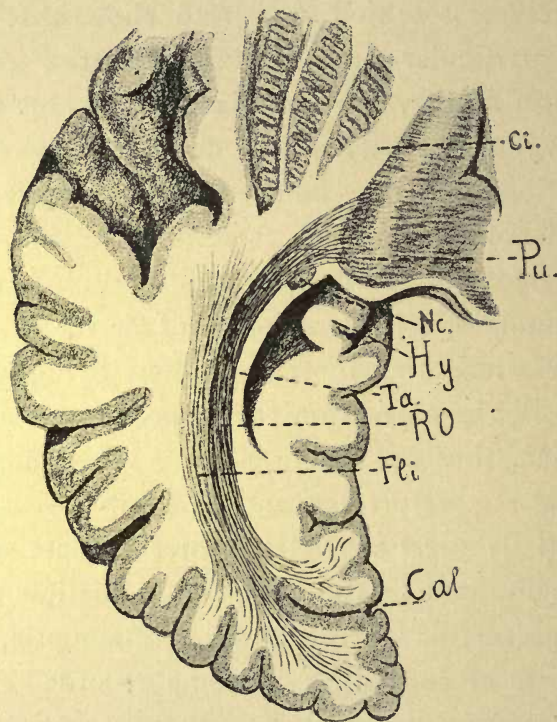


FIG. 158.—Horizontal section of the occipital lobe, showing the optic radiation (after Raymond).

Ci, internal capsule; *Pu*, pulvinar; *Nc*, nucleus caudatus; *Hy*, hippocampus; *Ta*, tapetum; *RO*, optic radiation; *Fli*, inferior longitudinal fasciculus; *Cal*, calcarine fissure.

pathway. If the beam of light falling upon the blind side of the retina causes no contraction of the pupil, it is assumed that the lesion is in that portion of the sensori-motor arc of the pupillary

reflex included between the chiasma and the corpora quadrigemina ; if there is reaction of the pupil the lesion is in the optic radiation or the visual cortex. A fit resulting from an occipital tumour may be preceded by a visual aura. As the tumour extends forwards motor and sensory phenomena are likely to arise on the contralateral side, and in tumour of the left occipital lobe language defects from involvement of the angular gyrus and the caudal extremity of the superior temporo-sphenoidal convolution. In some cases cerebellar symptoms are observed, such as staggering gait, Romberg's sign, etc. The visual signs prove that the tumour is not in the cerebellum. The cerebellar signs indicate increased pressure in the cerebellar fossa. The tumour does not exercise direct pressure through the tentorium, which is much too strong a membrane to be displaced, but blocks the aqueduct of Sylvius or otherwise interferes with the secretion or flow of cerebro-spinal fluid.

ILLUSTRATIVE CASES.

I. A lady aged forty, a patient of Dr. Wilfrid

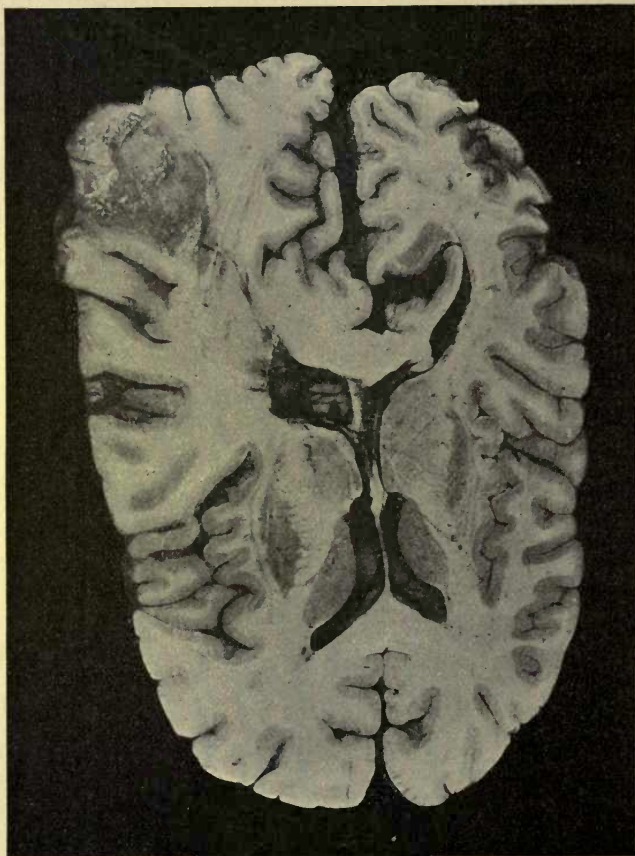


FIG. 159.—Glioma of occipital lobe. (Dr. Risien Russell's case.)

The section is at a low level, where the tumour is solid. It shows the involvement of the optic radiations. At a higher level the tumour occupied the outer aspect of the occipital lobe (except the tip) and was cystic.

Dawson, was confined in August. Nine days afterwards she had a fit, but seemed to recover com-

pletely. The following Easter she complained of headache, which gradually grew more severe. Three weeks before I saw her Dr. Risien Russell examined her and could find no evidence of gross intra-cranial disease, but two days previously he discovered early optic neuritis, most marked in the right eye, and right abducens palsy. When seen by me (in July) the headache was very severe, vomiting had occurred off and on for six weeks, and besides the signs mentioned above there were staggering gait, Romberg's sign, left Babinski reflex, complete left hemianopsia, and Wernicke's pupillary reaction. The conditions were confirmed next day by Dr. Russell and Mr. Gunn.

Operation.—First stage. Bone removed over right occipital region. Great intradural pressure relieved by withdrawing two ounces of cerebro-spinal fluid by lumbar puncture. Twenty hours later patient died in a fit before the dura was opened. It had been arranged to do the second stage of the operation forty-eight hours after the completion of the first stage.

Autopsy.—Convolutions much flattened. Large cystic glioma of right occipital lobe. This tumour appeared on the outer surface of the lobe, and there was a line of demarcation between it and healthy cortex. It could apparently have been enucleated.

Remarks.—The case illustrates the danger of sudden death in cases of brain tumour, especially in relation to operation in two stages. In this case the removal of the bone over the occipital lobe was not accompanied by any appreciable loss of blood, fall in blood pressure, or shock. A two-stage operation is advisable when there is loss of blood and shock, but it is not advisable (and this case is an instance in point) when the patient is in good condition at the conclusion of the first stage

of the operative procedure. The fact that the tumour was cystic explains the rapid increase in pressure, the rapid onset of symptoms, and the sudden death by arrest of respiration.

II. A case of brain tumour in which hemianopsia was the dominant symptom is related by Souques. A soldier, aged twenty-three years, was taken ill one day in April 1890 with buzzing in the ears, vertigo, mental confusion, and aphasia ; the attack proved transitory, and he returned to duty the next day. During the next twelve months he had attacks at intervals, with transitory aphasia, and became unable to read or write, so that he was compelled to ask a comrade to read his letters to him and to write those he wished to send. He had no difficulty in understanding what was said to him, and his difficulty in speaking was only transitory. In April 1891 he was admitted to hospital under Souques, the diagnosis of the military medical authorities not having proceeded beyond epilepsy and hysteria. He then had optic neuritis, right hemianopsia, and agraphia ; the agraphia was not quite complete, for he could write his own name, and he could write figures. He could identify any letter, whether in scrip or print, but could not read a syllable, so that he was word blind, but not letter blind. He could add and subtract correctly, and write and read figures, so that the case lends support to the view that there is a centre for numbers distinct from that for letters and words. The patient became gradually worse and died in August 1891. At the autopsy a large glioma was found in the left hemisphere, occupying the white matter of the occipito-parietal region ; it came to the surface on the external aspect at the angular gyrus, which it had destroyed, and on

the internal aspect at the lower part of the quadrilateral lobule. It had evidently destroyed the optic radiation.

III. Marchand relates an interesting case of blindness

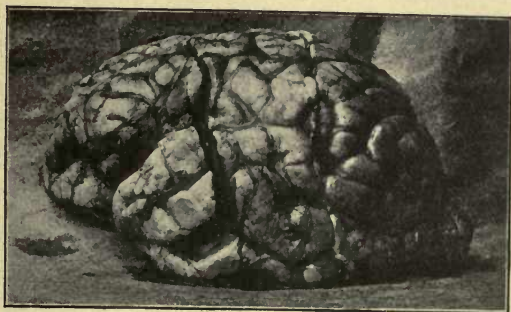

FIG. 160.

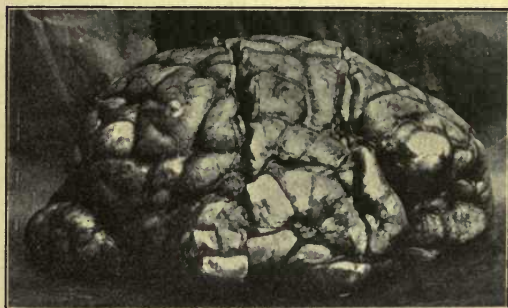

FIG. 161.

FIGS. 160 and 161.—Symmetrical atrophy and degeneration of the occipital lobes. (Marchand, 1903.)

FIG. 160.—Left hemisphere.

FIG. 161.—Right hemisphere.

from a bilateral cortical lesion. The patient, a female then nineteen years old, was admitted to an asylum on October 1, 1880, with the diagnosis "epilepsy with criminal tendencies." At the age of one year she had had meningitis. Fits had commenced a year before her

admission. Fits occurred at intervals without noticeable change for seventeen years, and then became more frequent. With the increasing frequency of the fits failure of sight was noticed, and speech became difficult. Sight failed slowly and progressively, and in five years she was, except for bare perception of light in the central portion of both fields, totally blind. The right side of the field of vision was first lost. Towards the last she also lost the faculty of direction, so that she could not find her way about the wing of the asylum of which she had been an inmate for twenty-two years. She died on July 14, 1902. The skull was very thick. There was considerable excess of cerebro-spinal fluid. The frontal, parietal, and temporal lobes were normal. Over both the external and internal aspects of the occipital lobes the pia mater was thickened, adherent, and very vascular; the surface was covered with false membranes forming bands, which in places appeared to penetrate into the cortex. The convolutions of the external aspect were small, puckered, and atrophied; their original shape was lost, and they were penetrated by false membranes. The appearances of the convolutions on the internal aspect of both lobes were the same. Fluctuation could be clearly felt on palpation of the surface; the thickness of brain substance between the surface and the ventricular fluid was only 2 mm.

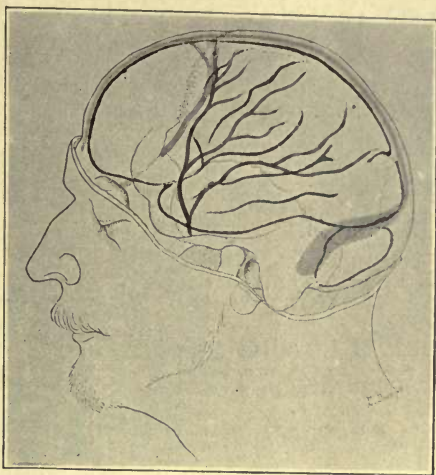

FIG. 162.—The distribution of the middle meningeal artery. (After Chipault.)

When the occipital lobe is exposed the scalp flap is turned downwards; but the dural flap must have its base forwards, for otherwise its blood-supply will be cut off.

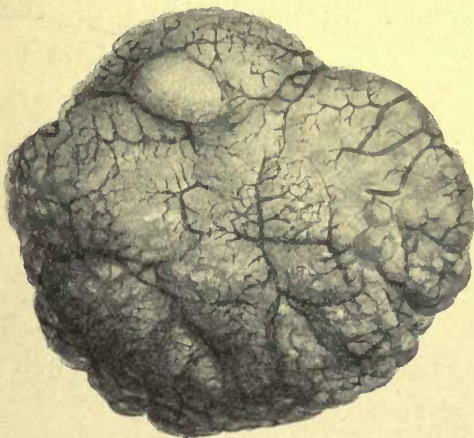


FIG. 163.—Fibro-plastic tumour of cerebral meninges. (Lebert, 1851.)

From a woman, aged 71, who was admitted to the Salpêtrière on May 4, 1850, with hemiplegia and blindness. She died suddenly and unexpectedly on Dec. 12, 1850.

Autopsy.—The tumour was intimately adherent to the dura over the right occipital lobe. A depression, the size of a hen's egg, was present on the surface of the occipital lobe, and in this depression the tumour lay. In structure the tumour was fibrous. It had probably produced blindness from optic atrophy following neuritis, and hemiplegia of the opposite side.

Lebert describes these cases as chronic, with disturbances of motion, sensation, special sense, and intelligence.

Tumour of the Frontal Lobe.

The outer surface of the frontal lobe is bounded posteriorly by the fissure of Rolando. This is true not only from the point of view of the anatomist, but also from that of the physiologist, since recent experiments on the brains of the chimpanzee and gorilla, and actual electrical stimulation of the brain of man, show that the motor cortex does not extend behind the Rolandic fissure, for in the grey matter of the precentral convolution are represented the movements of the chief groups of muscles on the contralateral side of the body. The following brief remarks refer chiefly to the left or dominant frontal lobe. The cortex of the frontal lobe can be conveniently divided into a posterior part, which, when appropriately stimulated, gives rise to muscular movements, and an anterior part, or anterior pole, which is "silent" when treated in a like manner.

The *posterior-frontal* region is limited to the ascending frontal convolution and a portion of the cortex of the caudal extremities of the 2nd and 3rd frontal convolutions, in which are represented the movements of the head and eyes. The movements produced by stimulation of the

ascending frontal convolution are so well known through the splendid labours of many experi-

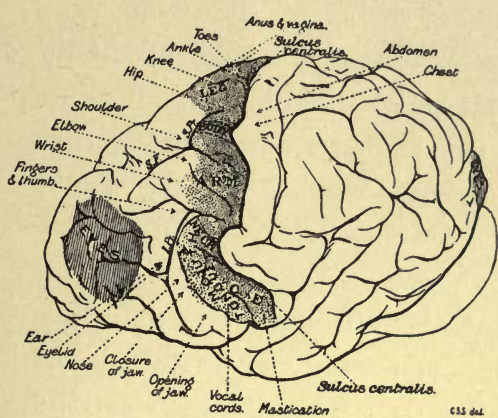


FIG. 164.—The motor area and its subdivisions on the lateral aspect of the hemispheric of the chimpanzee. (Grunbaum and Sherrington.)

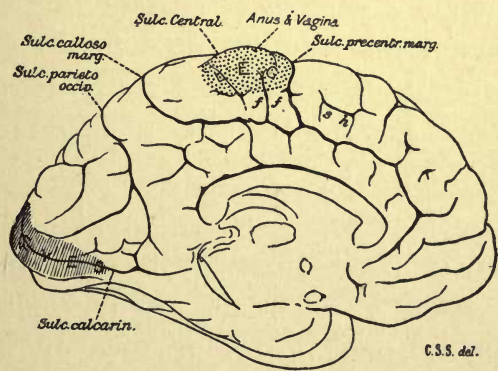


FIG. 165.—The motor areas and centres on the mesial aspect of the hemispheric of the chimpanzee. (Grunbaum and Sherrington.)

menters and pathologists that they need not here be further alluded to. Many tumours originate in, or subsequently involve the motor region of the frontal lobe, and their focal diagnosis does

not often present much difficulty. The initial local spasm of a fit or a local paresis is pathognomonic of the site of the lesion.

The *mid-frontal* region of Mills contains Charcot's motor graphic centre at the posterior end of the second frontal convolution, and the motor speech centre (Broca, 1870) at the posterior end of the left third frontal convolution. Between and in advance of these centres are those concerned with the movements of the head and eyes. The movements of the head are represented on a higher level than those of the eyes. Mills says "that the symptom complex of this region is motor agraphia, motor aphasia, fits with movements of the head and eyes as the salient feature of the local spasm, and psychic symptoms of a special sort, such as transient affection of memory."

The true *anterior-frontal* region is concerned with the highest psychic functions, and this is especially true of the left prefrontal lobe. Destructive lesions in this situation give rise to loss of the highest functions of the brain, such as ideation, memory, control, attention, and judgment.¹

¹ Polimanti gives a résumé of the results of experimental removal of the anterior pole of the frontal lobe on one or both sides in his work *Contributi alla Fisiologia ed all' Anatomia dei Lobi Frontali*. Bianchi's observations are very striking (*Congress of Rome*, 1894).

ILLUSTRATIVE CASE.

Convulsions followed by Motor Agraphia.

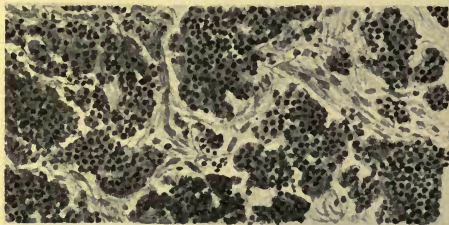
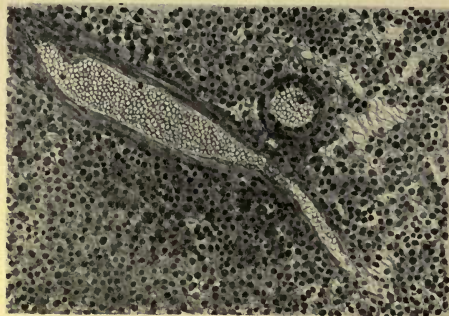
Man, aged twenty-eight years. When eight years old fell, striking the occiput, but no symptoms known to have ensued. In February 1899 he had a convulsion after a hearty meal; a year later a second convulsion occurred, and a third and a fourth in the course of the succeeding six months. In June 1901 he had a series of minor attacks; occasionally while talking he would look queer, appear dazed for a few seconds, and then proceed with the business in hand as if nothing had happened. On May 1, 1904, he had a convulsion without loss of consciousness, the right side of the face being the part affected. The attack was repeated; on one occasion he had twelve such attacks within two hours. About this time he became unable to write; there was slight paresis of right side of face, but none of limbs. There was no ataxia. Speech was thick, and he paused unduly between his words; he had no difficulty in reading or in naming objects shown to him. In attempting to write he could only make meaningless strokes, though he held the pencil correctly, and there was no want of precision in the movements of the hand. His wife stated that his mental condition had undergone gradual change since the commencement of his illness; he had become irritable, and seemed less able to understand. On May 21, 1904, the posterior part of the left frontal region of the brain was exposed and a tumour removed. "It lay across the foot of the second frontal convolution, encroaching somewhat on the lower half of the first and slightly upon the upper posterior

portion of the third frontal convolution, and on the anterior edge of the precentral convolution. After the operation there was paresis of the face and of the right hand, as well as agraphia. But these soon cleared up, and on June 12, 1904, the patient was able to write a letter. (J. W. MacConnell.)

When there is evidence of psychic dissolution preceding the onset of motor phenomena, the presumption is strongly in favour of the tumour being in the frontal lobe. Head and eye movements, and motor speech and writing defects, are also special symptoms of frontal lobe lesions. Motor agraphia and motor aphasia are associated with the loss of all kinds of skilled movements of the arm and leg (Mills), such as painting and dancing. There is no loss of common sensation on the opposite side of the body, but there is loss of the power of localising light touches and of muscular sense when the motor cortex is involved, as was long ago pointed out by Horsley. This can best be explained at the present time by the tumour not only involving the precentral convolution, but also extending behind the fissure of Rolando, so as to involve corresponding areas of the sensory cortex. There seems some doubt whether a specific form of ataxia is determined by lesions of the frontal lobe. Bruns attaches importance

to this symptom, which in one case enabled him to diagnose the site of the tumour; he operated, and the patient recovered. In another case, on the other hand, it led Hitzig into error, for he believed the tumour was in the cerebellum, because of the ataxic phenomena, and opened the skull in the occipital region, but the tumour was in the frontal lobe. Frontal ataxia is manifested when the patient stands or attempts to walk. When stood up he sways to right and to left, and would fall if not supported, but in walking does not describe zigzags, and does not stagger like a patient with a cerebellar lesion. Some authors, for example Bruns, look upon the condition as due to paresis of muscles of the trunk and neck. Mills describes a case in which the ataxia of the fore limb might be considered as due to loss of the power of attention, the patient being unable to convey food to the mouth with any certainty. Grainger Stewart has recently pointed out that a fine vibratory tremor may occur in the extended homolateral upper limb, and that the epigastric and abdominal reflexes may be absent on the contralateral side. The headache in a frontal lobe tumour may in some part of the course of the case be occipital in site. Some frontal tumours fulminate with fearful headache: in one case

seen by me the man, groaning in pain, sat up continually in bed holding his forehead with both hands, and with the body bowed forwards till the head touched the bedclothes. The per-



M.H. Holmes
1906

X185

FIG. 166.—Glioma of frontal lobe.

Microscopic section by Dr. Gordon Holmes.

The upper figure shows the highly cellular nature of the growth and the well-formed blood-vessels. At one part of the tumour (see lower figure) some intercellular tuberculae were found, but these did not stain red with the van Gieson stain. The well-formed walls of the blood-vessels and the non-staining property of the intercellular substance prove the tumour to be a glioma, not a sarcoma.

sistent headache of tumour is quite unlike the transient headache sometimes associated with idiopathic epilepsy. It may again be noted that epilepsy may occur from irritation arising in any part of the cortex, and not simply from irritation

of the motor area; that it occurs in hysteria and idiopathic epilepsy, and in many gross lesions other than tumour. When tumour involves the orbital surface of the frontal lobe, symptoms referable to pressure on or invasion of the olfactory lobe or optic tract may be present.

The following case of glioma of the frontal lobe illustrates a point of practical interest, namely, that a highly cellular tumour of the brain is not necessarily very malignant. This is true, not of brain tumours only, but of tumours of other parts of the body: thus a large cellular carcinoma mammæ may prove less malignant than a small atrophic scirrhous with few cellular elements.

In 1903 a man, aged thirty-two, was admitted into the National Hospital under the care of Sir William Gowers. Three years previously he commenced to have peculiar attacks without loss of consciousness, in which a choking sensation was experienced. Four months previously he had his first Jacksonian fit, which commenced with shaking of the right arm. On admission he had incomplete right hemiplegia, the arm being most affected, severe headache, slow speech, loss of memory, mental dulness, impairment of sensation in right hand and forearm, and in right foot and leg, and early double optic neuritis. The condition of patient rapidly deteriorated, vomiting occurred, and the optic neuritis increased. I drained a large gliomatous cyst in the left frontal lobe with complete relief of symptoms.

Two years later the symptoms recurred, and I then removed a large mass of tumour from the same region. The patient left hospital well and proposed to resume his work. The tumour was a highly cellular glioma. (Fig. 166.)

ILLUSTRATIVE CASES.

1. *Brissaud and De Massary's Case. Fits and persistent Headache.*

Male, aged twenty-eight years. On July 10, 1894, had an epileptic fit without any apparent cause; the four following days he went to work as usual. The fits were afterwards repeated, and besides the complete attacks, in which the convulsions were generalised and consciousness was lost, he had at intervals abortive attacks, the facial muscles twitched, the countenance was distorted by a forced grin, and the patient, though conscious and understanding what was said to him, could make no reply. He improved, but in January 1895 the complete attacks recommenced. The movements were greater on the left side than on the right. In the intervals between the attacks the patient complained of headache and throbbing referred both to the frontal and the occipital region. There were no visual troubles, and there was no optic neuritis. Bromide was given, and the attacks became less frequent; in May 1895, renewed frequency of attacks with rise of temperature. Similar treatment with the addition of antipyrin; the patient again improved and returned to work. In January 1896 he had a relapse, followed shortly by death. At the autopsy a sarcoma of the pia mater was found, 6 by 3 cm., involving the first and part of the second frontal convolutions on the right side. The

tumour was adherent to the dura mater, and had sprouted through several little rents in that membrane.

Brissaud and de Massary, in commenting on the case, observe that headache sometimes occurs as a more or less persistent symptom in aged epileptics with atheromatous arteries, but that as a rule a diagnosis of essential epilepsy should exclude persistent headache. Persistent headache, even though diffused, should be considered a formal indication for operation, particularly if it becomes aggravated when the fits occur. Even though no tumour may be found, a decompressive operation will prevent the occurrence of a fatal status epilepticus.

II. Knecht's Case. Fits and Emprosthotonos.

Male, aged twenty-seven years. In 1876 began to increase in weight, and in October of that year began to suffer from convulsions, preceded by headache and pain in the back of the neck.

The attacks began suddenly by the head being bent forwards, urine was passed, and vomiting occurred during the attacks, and the trunk was bent strongly forwards. Consciousness was not entirely lost. A somnolent condition followed the attacks. In March, during two attacks, the muscles bending the head and trunk forwards remained strongly contracted. The patient complained of pain in the muscles of the neck and in the frontal region. In April and May similar attacks. On May 19, paresis of left external rectus observed, and the tongue and the uvula deviated to the left. On May 23 he had frequent attacks and could not see; when he got out of the room he could not find it again; the next day he died. Rigor mortis occurred a few minutes after death. The dura over

the left hemisphere was very tense. Over the frontal region it was adherent to the pia. A glioma as large as a pigeon's egg was found at the tip of the left frontal lobe, involving the first and second frontal convolutions. The whole left hemisphere was hyperæmic.

III. Cestan and Lejonne's Case. Fits, Paralysis, Mental Symptoms, and partial Aphasia.

A woman, aged thirty-three years, was admitted to hospital with right hemiplegia, complete blindness, mental disturbance, headache, vomiting, fits, optic neuritis, and partial aphasia.

The symptoms of increased intra-cranial tension, headache, optic neuritis, and vomiting almost completely subsided, and as this took place a peculiar defect in the mental condition became manifest; the patient had no delusions, nor was she demented, but she seemed to have lost the power of associating ideas and of attention. She knew and recognised her relatives, the professors, and those who attended on her; but she could not be induced to remember the names of any of the staff or attendants, even of those who saw her daily. She would make simple additions, but would not multiply. She had almost complete loss of memory for recent events.

Fits continued at intervals, and always began at the right angle of the mouth; the reflexes were brisk. Stereognosis and sensation were, so far as the defective mental condition would allow them to be tested, normal.

The patient died, and a sarcoma of the meninges as large as an orange, and surrounded by a zone of softening, was found in the left frontal region. The tumour involved the posterior two-thirds of the 1st and 2nd,

and the posterior extremity of the 3rd frontal convolutions, and it also compressed and covered over the ascending frontal convolution.

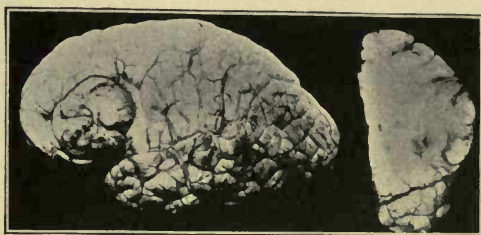

FIG. 167.—Glioma of frontal lobe. (Ballet and Delille, 1902.)

A man, aged 53 years, poor and overworked, was admitted to the Salpêtrière on October 8, 1900. He had had migraine and neuralgia for a long time, and for six months he had suffered from a sensation of emptiness in the head which was most troublesome. On September 20 he had incontinence of urine, and on October 1 right hemiparesis, with some difficulty in articulation. He was a painter, and confused the names of his pictures and of the parties to whom he had sold them. His disposition, normally violent, had become more gentle. On October 7 he had incontinence of fæces for the first time. At this time he was mentally weak, inclined to melancholy, and easily became tired. Sight normal. Paresis of limbs and lower half of face on the right side. The patellar reflexes were exaggerated. Mental condition rapidly deteriorated. On November 11 he became comatose, and died the following day. The temperature rose to 116°.7 immediately before death.

At the autopsy a large glioma, which was not encapsuled, but incorporated with the substance of the hemisphere, was found occupying the left frontal lobe. The tumour measured $5\frac{1}{2} \times 6 \times 3$ cm.

Remarks.—Note that though the tumour is apparently discontinuous with the brain on the surface, the section shows that there is no line of demarcation between normal brain and tumour tissue. This is a most important point to bear in mind at operations.

Ballet and Delille describe another interesting case of frontal lobe tumour:—

Male, aged 19 years. Was struck a severe blow with a stick in the left temporal region. The next day he had headache, and at the end of a week he had ptosis on both sides, diplopia, amblyopia. Three days later all symptoms subsided except ptosis on the left side and headache. These persisted, and two months later he was admitted to hospital. It was then found that the sense of smell was somewhat impaired on the left side. He had epileptic fits the day after admission. The deep reflexes were exaggerated. Operation was advised, but refused. Five months later he was readmitted with torpor and right-hand paresis. A diffuse glioma was found on the inner aspect of the anterior part of the left frontal lobe.

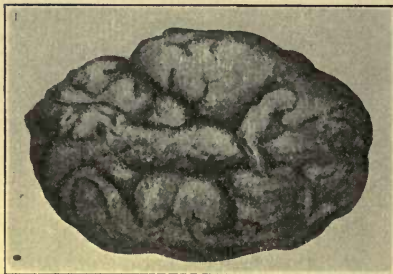


FIG. 168.

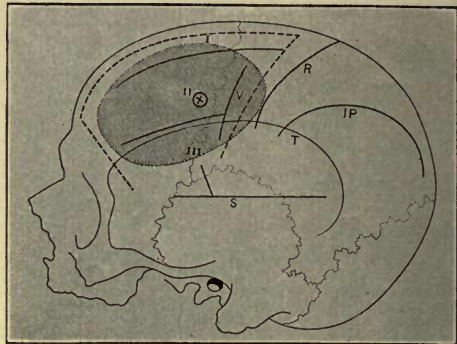


FIG. 169.

Figs. 168-170.—Large glio-sarcoma of frontal lobe successfully removed. (Keen and Thomas.)

FIG. 168.—The tumour. It was 7.5 cm. long, 5.5 cm. broad, and 4 cm. deep, and was well defined. It weighed $2\frac{3}{4}$ oz.

FIG. 169.—Diagram to show approximately the relations of the tumour, which is represented by the shaded area. The interrupted line represents the osteoplastic flap. I., II., III., are the three frontal convolutions. ⊕ represents the place where the tumour had broken through the cortex; R, fissure of Rolando; V, precentral sulcus; IP, intraparietal sulcus; S, fissure of Sylvius; T, temporal ridge.

FIG. 170.—Diagram to show the depth and relation of the tumour to the convolutions and the ventricle. The shaded portion represents the tumour.

Patient a male, aged 17 years. History of injury left frontal region. Headache, vomiting, and dim vision from optic neuritis. Slight weakness right face. Left eyeball prominent. Mental dulness. No fits, hence probably subcortical tumour. Later some weakness of right hand and thickness of speech. The tumour was shelled out without difficulty. The anterior part of the ventricle was packed to prevent blood passing into it.

Keen refers to seven other tumours larger than the one above described, which have been removed from the brain. His first case, operated on in 1887, was published in the *American Journal of the Medical Sciences* for 1888. The operation was successful. The tumour was a fibroma occupying the left frontal region. It weighed 3 oz. and 49 grains.

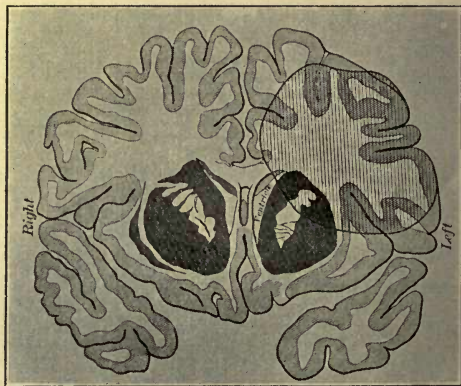


FIG. 170.



FIG. 171.



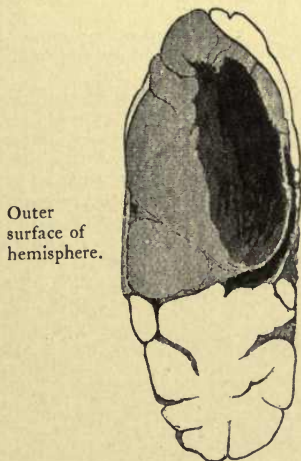
FIG. 172.



Front.

Outer surface.

FIG. 173.



Outer
surface of
hemisphere.

FIG. 174.

FIGS. 171-174.—*Figures illustrating a case of Subcortical Tumour (Cystic Angio-Sarcoma) which commenced to grow in the Centrum Ovale beneath the lower part of the Motor Cortex.*

The patient was a boy aged 11 years. One year before admission to hospital under Sir William Gowers he was stunned by a blow on the left side of the head; this was followed by irritable temper. The other salient facts of the case were as follow:—

1. Fits commencing with twitching of the right angle of the mouth, and followed by paralysis of the lower part of the right face.
2. Gradual extension of the paralysis to the right upper and lower extremities. No hemianæsthesia.
3. Slow speech. No tender spot on cranium.
4. Severe frontal headache, vomiting, and double optic neuritis.

First Operation.—A drainage tube was inserted into the cyst, with the result that all the symptoms were relieved. The cyst lay under the lower part of the ascending parietal and frontal convolutions, and extended forwards beyond the ascending frontal convolution for about 1 inch. On looking into the cyst the wall appeared like normal brain tissue; there was no true cyst wall. The drainage of the "cyst" was sometimes good and sometimes obstructed. The fluid being plasma, blocked the tube on cooling; hence repeated difficulties in drainage were encountered. When drainage was good the symptoms disappeared, and *vice versa*. Three years and three months from the first operation the child grew worse, and the—

Second Operation was done, a cystic tumour 3 oz. in weight being removed. Fig. 171 is a photograph 3½ months after the removal of the tumour. During the five months preceding the operation the boy was detected on many occasions stealing from other patients in the ward with much cunning. After the removal of the tumour this moral deterioration disappeared.

Five months after removal of the tumour, patient was admitted with a large cerebral hernia (Fig. 172) coming through the cranial opening and bulging the scalp flap.

Third Operation.—The bulging mass was found to be a large tumour. The bone around the cranial opening bled from every pore, and all efforts to stop this capillary hæmorrhage from the infected bone failed. The child died a few hours later.

Figs. 173 and 174 are horizontal and coronal sections of the left hemisphere. The enormous extent of the tumour is very remarkable; it commenced in the left frontal lobe, and grew gradually backwards, pushing before it the pyramidal fibres in the corona radiata. Before the last operation the right hemiplegia was only partial.

Remarks.—This case occurred some fifteen years ago. The treatment should have been enucleation of the tumour at the first operation.

FIGS. 175-182.—*Malignant Growth of Frontal Lobe perforating Dura and Skull.*

F. S., male, under the care of Dr. Acland in St. Thomas's Hospital.

Previous History.—Never had syphilis, does not take alcohol, no history of injury to skull.

Present Illness.—Seven years ago noticed swelling in right frontal region, which has very slowly increased in size. About this time patient had a fit. Four years ago he had another fit, and again two years ago. During the last eighteen months he has had a good deal of headache, has occasionally done odd things, has not been able to walk far, and has had occasional incontinence of urine.

Patient now complains of severe aching pain in right frontal region—which, however, is not continuous—and some loss of sight, especially in right eye.

State on Admission.—Smooth, hard swelling right frontal region, extending over middle line, and involving right frontal, right parietal, right squamous, and left parietal bones. The edge of the tumour is definite. The scalp is free over the tumour, and there is no tenderness on pressure.

Mental state dull, speech slow, lack of power of attention, incontinence of urine at night. No alteration of reflexes, no paralysis of limbs. No optic neuritis: diplopia on looking to the extreme right or left. Headache absent as a rule in morning, but comes on when he gets out of bed; often severe in latter part of day in frontal region.

Patient became rapidly worse in hospital—the mental torpor increased, and sometimes he was difficult to rouse; the power of attention failed, answers to questions were not completed, and he spilled his food over the bed. Ten days after admission operation for the removal of the bone tumour was performed.

Operation.—The bone around the tumour was cut through, as described under Fig. 179. The capillary bleeding from the bone was in some places considerable, which made me think I had to do with a sarcoma of bone. When the bone section was completed it was found that the mass could not be raised from the dura, as the central part of its under surface was attached to a growth coming through the dura. This isthmus of tumour was torn through, and the finger being inserted through the dural opening, discovered the anterior part of the frontal lobe replaced by new growth.

The patient's condition now became suddenly very bad; the scalp wound was rapidly sewn up, and infusion and other restoratives applied. Patient did not rally, and death took place the next morning.

Remarks.—The operation was undertaken with the idea that the tumour was a slow-growing sarcoma of bone, or that the bone tumour was of a nature allied to leontiasis ossea. It was supposed that the tumour had encroached on the intra-cranial cavity and compressed the frontal lobe, which would account for the mental symptoms, the headache, and the incontinence of urine. Dr. Beevor has drawn attention to the early occurrence of incontinence of urine in frontal lobe tumours.

Microscopical Appearances.—The mass of the growth was vascular and highly cellular. In parts there were numerous whorls or groups of cells arranged concentrically. The greyish processes which extended between the brain and the frontal bone were composed of longitudinally arranged blood channels without definite walls around which the cells of the tumour ranged themselves. It is probable that the growth commenced as a hæmangio-endothelioma in the frontal lobe, and later a transition occurred into a more common form of sarcoma.

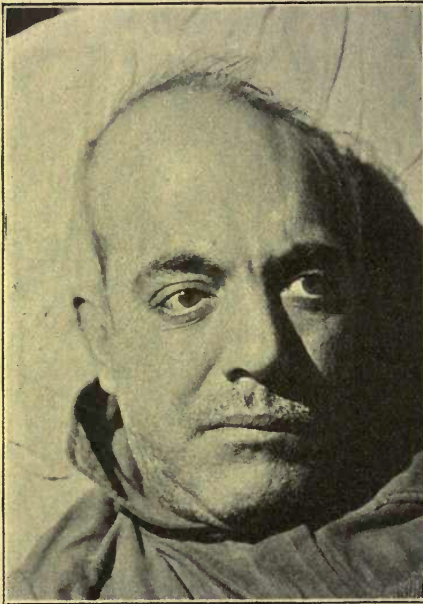


FIG. 175.




FIG. 176.

FIGS. 175 and 176.—Sarcoma of frontal lobe perforating dura and frontal bone.

Photographs of patient before operation.

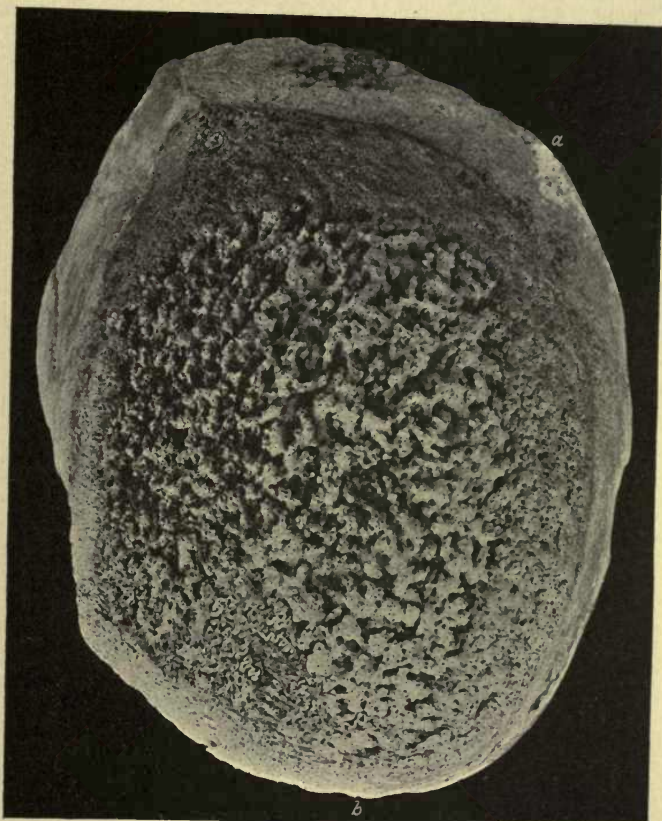

FIG. 177.—Photograph of external surface of the portion of skull, after maceration, removed at the operation.

a, b, median line.

The measurements were 6 inches from before backwards, and 5 inches from side to side; but when the tape was laid on the curve, the measurements were $7\frac{3}{4}$ inches and 8 inches. Measured by callipers the thickness of bone in the centre was $1\frac{1}{4}$ inches.

Note the coral-like appearance of the bone, due to infiltration with new growth.

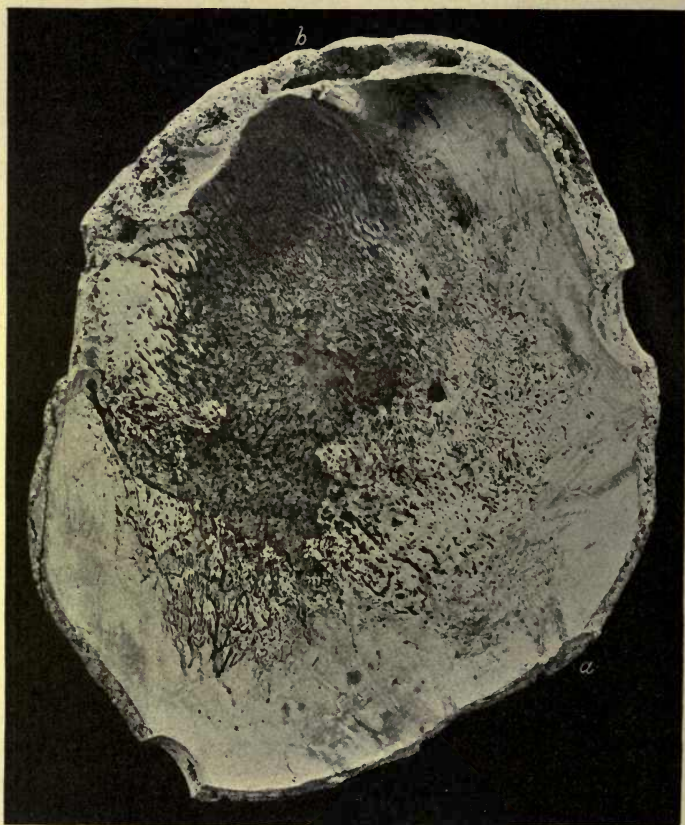


FIG. 178.—Photograph of internal aspect of the portion of skull, after maceration, removed at the operation.

a, b, median line.

Extending from the opening in the dura to the central portion of the bone which appears dark in colour, were long, string-like, grey-coloured processes of new growth.



FIG. 179.—Photograph of the portion of skull, after maceration, removed at the operation, viewed from the left side.

The trephine opening was made in the left parietal bone, and the remainder of the skull section was made by powerful forceps of the de Vibiss pattern.



FIG. 180.—Photograph of anterior part of brain enclosed in dural capsule, showing sarcoma of right frontal lobe sprouting through the dura.

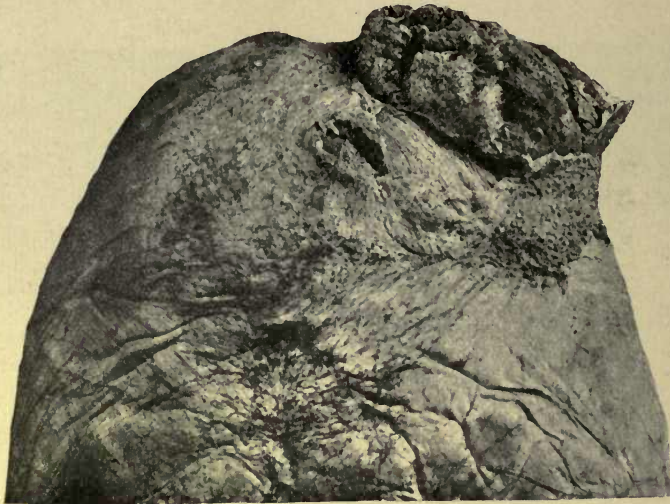

FIG. 181.—Photograph of brain enclosed in dural sheath, showing (from above) the sarcoma of right frontal lobe sprouting through the opening in the dura.

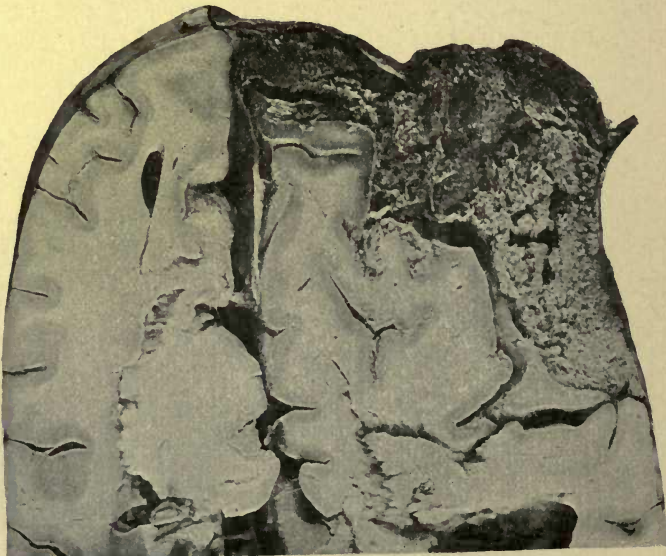

FIG. 182.—Photograph of horizontal section of brain through the lower part of the opening in the dura.

The brain, unfortunately, was not properly preserved.

It was impossible to photograph the sections made at a higher level, the brain tissue being diffuent.

Tumour of the Parietal Lobe.

The intra-parietal sulcus arches through the parietal lobe. Its horizontal portion divides the parietal lobe into two parts—the superior and inferior parietal lobules. Its vertical portion (post-centralis inferior) separates the post-central from the supra-marginal convolution. The superior parietal lobule is continuous on the mesial surface of the hemisphere with the quadrate lobule or precuneus. The inferior parietal lobule is embraced within the curve of the intra-parietal sulcus. It presents three arching convolutions—the supra-marginal, angular, and post-parietal convolutions. With regard to the ascending parietal convolution and the superior parietal lobule Mills writes:—

“Physiologically this part of the cortex can be divided into areas of cutaneous and muscular sensibility and of stereognostic perception. Muscular sensibility has its representation in the anterior part of the superior parietal lobe and the anterior part of the inferior parietal lobe (supra-marginal convolution). Cortical sensory representation is probably divided into segments for different cutaneous areas of the body, and these have topographical relations with centres and sub-areas of the motor region. Stereognosis

is a conceptual process. The ability to recognise objects by touching and handling them so as to obtain an idea of their form is brought about by the recalling of memorial images obtained in the first place through such senses as contact, pain, temperature, spacing, location, and position ; but although thus obtained, the process of recognising objects in this way becomes an independent one. The cutaneous and muscular processes are primary ; stereognosis is secondary and higher." In one of Dr. Beevor's cases, in which pachymeningitis involved the right cortex over an area including the lower half of the ascending parietal gyrus and the whole of the supra-marginal convolution, the patient, a man aged forty-two years, suffered from diminution of common sensation, loss of the power of localising light touches, and loss of muscular sense in the left upper limb.¹

The growth of a tumour is so seldom restricted to the part of the parietal area in front of and above the intra-parietal sulcus, that besides the symptoms due to the loss of the cortical representation of the various forms of common sensation, including the localisation of tactile impressions, muscular sense, and stereognostic

¹ A case of my own illustrating the cortical localisation of the stereognostic sense is given at the end of this chapter.

perception, other symptoms, such as follow lesions of the motor region, are usually present.

The angular gyrus and the post-parietal gyrus form part of the higher visual field, and on the left side are concerned in the higher nervous mechanism of language. Tumour involving the angular convolution gives rise to inability to comprehend the visual symbols of ideas, such as words, letters, numbers, musical notes, gestures, etc. If the tumour involves the post-parietal convolution, objects though seen will not be recognised ; this symptom is spoken of as object or mind blindness. If the tumour also involves the posterior end of the superior temporo-sphenoidal convolution, in the grey matter of which are the cortical centres for hearing, cortical deafness or auditory amnesia in its various varieties are present also.

Duret insists upon the connection of the superior parietal lobule and its mesial annexe, the quadrate lobe, with the representation of superficial and deep sensation and stereognosis, and that the inferior parietal lobule plays an important part in the faculty of language, particularly in word-seeing, and consequently in reading and writing. Hence lesions of this region on the left side give rise to sensory agraphia, alexia, and amusia.

A particular motor defect, which has been termed "apraxia," has been met with in lesions of one or other parietal lobule. Duret terms it a psychic paralysis, but Liepmann, who described the condition, considers that it is quite distinct from psychic paralysis, and that it bears the same relation to the muscles of the limbs that motor aphasia does to the muscles of the organs concerned in speech. The patient knows perfectly well what he desires to do, but is unable to make the appropriate systematised movements; though the limb affected (say the arm) is not paralysed and not ataxic, he either makes no movement at all, or makes the movement appropriate to an entirely different purpose; thus an apraxic wishing to smoke a cigar made the movements appropriate to the use of the tooth-brush, just as an aphasic, though well aware what he wishes to say, employs a word of quite a different meaning.

Liepmann's explanation of the meaning of apraxia is as follows:—

A lesion interfering with the transmission of the centripetal impulses that arise from the position of the joints, the degree of tension of muscles, tendons, and fascial bands, and certain impressions from the skin, which together make up the so-called muscular sense, or damage to the cortical sensory centres where such impulses are received, gives rise to ataxia. The patient

is no longer able, as normally, to control his movements through the sensation of the position and of the movement of the limbs; coarse movements are performed, though clumsily; but more delicate movements, such as fastening a collar button, are impossible. The desired act cannot be performed owing to failure of co-ordination of the elementary muscular movements, the limb moving in jerks or being carried wide of the mark. In apraxia the combination of co-ordinated movements for a definite purpose fails, an effect quite different from the one desired being brought about, though the movements themselves are perfectly co-ordinated; for example, an ataxic would use a comb clumsily enough, but always as a comb—not, as did an apraxic, like a pen or a Jew's harp.

Liepmann considers that the phenomenon of apraxia is explained by the existence of a lesion or lesions which cut off the cortical sensori-motor nervous mechanism from the higher special sense centres, especially the optic and auditory perception centres, through which most of the movements we are accustomed to perform are initiated, directed, and controlled. By the habitual performance of a certain act the sensori-motor nervous mechanism in the cortex becomes so adjusted that the sensory impressions resulting from the position of the muscles and joints concerned in each phase of the act are able to call forth the motor impulses for the succeeding phase, the current of energy being, so to

speak, short-circuited at the sensori-motor cortical area, so that the act once started is continued sub-consciously, though not sub-cortically; for the initiation and the proper control of any act, not only must the cortical sensori-motor mechanism be intact, but its connections with the higher perception centres must be maintained.

Just as interruptions of the normal communications between the highly specialised portion of the sensori-motor nervous mechanism of the cortex and those portions of the perception centres concerned in language gives rise to aphasia in various forms, so interruption of the normal nervous connections between the larger sensori-motor cortical area and the higher perception centres causes disorder in the performance of definite purposeful acts. Apraxia like aphasia may be more or less complete, and affect certain acts only: no trace of any purposeful action may be evident in the movements executed, or certain definite elementary phases of a purposeful act may be manifest, or the movement may be definitely purposeful though not adapted to the particular act it is desired to perform; just as an aphasic may utter sounds bearing no resemblance to articulate speech, or definite syllables may be recognisable though not combined to form

words, or definite words may be uttered, but not meaning what was intended.

Tumours of the parietal region, extending inwards, reach the posterior end of the internal capsule ; and thus other symptoms arise, such as hemianopsia, hemianæsthesia, and hemiplegia.

ILLUSTRATIVE CASES.

I. Bruns' Case. Sensory Symptoms from Tumour involving Superior Parietal Lobule.

A man, aged fifty-five years, began to fail in health. In October 1896 he had slight vertigo, mental fatigue, and irritability. In November he had a fall on the right side. In February 1897 optic neuritis and commencing right hemianopsia were observed, together with sensory disturbances on the right side of the body, especially in the arm. The symptoms increased in severity ; the sense of stereognostic perception was first lost, then that of position of the limb, and, lastly, sense of pain and of contact. In consequence the movements of the right upper limb, especially of the hand, were very unsteady when the eyes were shut. Neuralgic pains preceded the loss of sensation. The right hemianopsia became complete by the end of November 1897. There were slight and variable language defects, the hemianopsia interfered somewhat with reading, but there was no true alexia. Of the general symptoms of tumour, vertigo was first noticed, then optic neuritis ; for a long time there was neither headache nor vomiting ; headache was not complained of until January 1898, and was chiefly occipital, while vomiting only

occurred shortly before death, and then on but few occasions. The patient never had convulsions, but had apoplectic attacks, sometimes accompanied by temporary total blindness, and on one occasion there was temporary right ptosis lasting twelve hours. The patient died on May 4, 1898.

At the autopsy a hard encapsuled meningeal tumour was found, measuring 6 by 4.5 by 4 cm. It was quite sharply differentiated from the brain substance, but had hollowed out and compressed the left superior parietal lobule. It protruded through an aperture in the dura 4 cm. in diameter, and was only adherent to the dura at the edges of this opening. The pia mater ceased at the edge of the hollow in the brain in which the tumour lay. Microscopical examination showed that the grey matter beneath the tumour was destroyed by atrophy and softening. The growth was a sarcoma which Bruns considered had sprung from the inner surface of the dura.

The account of this case by Bruns, and his observations thereon, are instructive. His localisation of the growth was exact, but he was of opinion that it was in the white matter of the brain, whereas the autopsy showed that, like the growth shown in Fig. 104, it was meningeal, and could have been removed by operation. He inferred that the growth was deeply seated, because (1) headache was absent in the initial stages; (2) there was no tenderness on percussion of the skull; and (3) that hemianalgesia was present, which he thought rare from a purely cortical lesion, though astereognosis points especially to involvement of the cortex. The temporary blindness he attributed to sudden increase of intra-cranial tension leading to pressure on the optic chiasma. The fall mentioned in the history of this

case was due to the tumour, not the tumour to the fall. Many observations have been made during the eight years that have elapsed since the publication of this case, tending to increase our appreciation of the localising value of cortical sensory affections, and it seems clear that the rule should be that any patient presenting symptoms of such definite localising value should have the chance afforded by an exploratory operation.

II. Raymond's Case. Loss of Sensation: no Loss of Motor Power till Late in the Illness.

A man, aged forty-seven years, employed in the post office. The illness began with a feeling of numbness and heaviness in the left hand, and he soon became unable to oppose the thumb to the fingers, and consequently had great difficulty in sorting letters. He was unable to take up and adjust the dynamometer, but when it was placed in his hand he was able to grasp it with a force equal to that of the other hand. Sensation, particularly deep sensation, became more and more impaired in the left upper limb; finally, the hand lost all sensation of weight, of position, and of temperature, so that it was hypoæsthetic and ataxic. The left supinator jerk was increased. The general signs of brain tumour gradually manifested themselves; headache, at first general, became localised on the right side. The diagnosis was large glioma not definitely limited, which could not be removed. The patient left the clinic soon after Prof. Raymond's lecture, and the ultimate result is not known.

In his comment on this case Prof. Raymond remarks that loss of sensation from cortical lesion is (1) rarely total; (2) especially affects the muscular

sense, the sense of temperature, and the different varieties of deep sensation which go to form stereognostic perception; (3) rarely extends to the whole of one side of the body, and still more rarely is uniformly intense over the whole area affected. It is a hypæsthesia rather than an anæsthesia, and is often limited to one limb, or even to a segment of a limb. Also that while in some cases Jacksonian epilepsy is the dominant symptom, in others the convulsions are abortive, and are but a fragment of the symptoms present, and apt to be lost sight of and as it were smothered in the other manifestations. Such abortive attacks of Jacksonian epilepsy may, nevertheless, if carefully observed, be an important guide to the seat of the lesion. The convulsive attacks were in this case abortive, hence Raymond thought it probable that the lesion did not directly affect the cortical motor centres, but only the fibres of conduction leading therefrom. Cortical ataxia does not occur without loss of deep sensation. Co-ordination depends on the exact correlation of the activity of the sensory and motor centres, and is not the function of a special part of the cortex. Raymond further insists that great improvement under anti-syphilitic treatment does not necessarily indicate that the lesion is syphilitic. It may be due to the resolvent effect of iodide of potassium and mercury on the inflammation around a malignant tumour.

*III. Lemos's Case. Localisation determined by
Sensori-motor Aura.*

A man, aged twenty-four years, all of whose family showed signs of an irritable, nervous system, suffered at frequent intervals from generalised convulsions with

loss of consciousness. The fits were preceded by a peculiar aura ; the patient felt pain in the head, with a feeling of irritability and depression, accompanied by a sensation of stiffness or contraction gradually creeping up the left leg. He had no loss of power, but complained of pain in that limb, and later on had frequent hallucinations as to its position and shape. On several occasions he told his doctor he had twisted it, and asked him to reduce the deformity. Muscular sense was quite lost, so that if the eyes were closed and the limb moved passively, the patient had no sense of its position. He died in the "status epilepticus," and at the autopsy a solitary tubercle no larger than a pea was found in the right superior parietal lobule close to its junction with the ascending parietal convolution.

IV. Starr and M'Cosh's Case. Loss of Muscular Sense and Astereognosis without Motor Symptoms.

"The muscular sense, or sense of position of limbs, as derived from sensations arising in the surface, joints, and muscles, which serve as a guide to movement" (S. and M.).

Male, aged twenty-one years, had a fall on the head at five years, and a second at sixteen years of age ; was unconscious on both occasions. He complained of pain in the left side of the head, referred to a spot where there was a small scar between the parietal eminence and the middle line of the vertex. The pain was continuous with exacerbations. The patient was subject to maniacal attacks, with, at times, loss of consciousness, which had prevented him from having regular education or following any employment. He was trephined in the region of the scar ; a linear depression was found

in the bone on its outer surface, but no fracture of the inner table. On opening the dura no evidence of meningitis was seen. There was a vascular mass consisting exclusively of veins immediately beneath the trephine opening. The opening in the skull was enlarged, and the mass removed after ligation of the vessels leading into it. The cortical grey matter was slightly injured in placing the ligatures. After removal of the mass the cortex was explored with a needle, but no fluid was found. Immediately after the operation the boy had a peculiar awkwardness of the right arm and hand. There was pronounced ataxia, and when the eyes were shut and the right arm moved passively the patient was unable to place the left arm in the corresponding position. The actual power of the right hand was greater than that of the left. This condition lasted unaltered for about three weeks, and then gradually subsided; the ultimate recovery was complete. The lesion was considered to involve the cortex above and below the intra-parietal sulcus.

V. Spiller's Case. Sensation and Stereognostic Perception-impaired in one Limb without other Symptoms.

Male, aged thirty-eight years, a teacher. Was well until July 21, 1904, when he had a blow over the right parietal region which rendered him unconscious for two hours. He was unable to use the fingers of the left hand for two weeks after the blow, and since the injury had paræsthesia of the left hand. There was no affection of the face or of the lower limb. The sense of position and stereognostic perception were much impaired in the left hand, and the answers to sensory tests of that region were less accurate than to corresponding

tests on the opposite side. The ultimate result is not stated.

VI. Korteweg's Case. Alexia, Agraphia, Aphasia, diffuse infiltrating Tumour of Inferior Parietal Lobule.

Man, aged twenty-six years. In February 1899 began to suffer from headache, and at times used words incorrectly while speaking. Admitted to hospital the following May; he then had violent headache, optic neuritis on both sides without loss of vision, paresis of right fourth nerve, and slight right hemiparesis with paræsthesia, particularly in the fingers. Light touches on the right arm and right foot were incorrectly localised, sense of position of the right fingers lost, and passive movements not appreciated. Patient heard names and words, but understood the latter imperfectly. Particularly when tired he would reply to a question by repeating the answer he had given to a previous question. He saw and recognised objects; he could see letters and words, but could not read words, whether in scrip or print, particularly if they were a little long. He spoke a good deal, and had many words at his command, but occasionally made mistakes. He could not repeat long words or even simple sentences. He had a peculiar tendency to mingle words previously heard or said; thus, having said "red," "lottery ticket," he said "re-lot," and having said "red," "lead," "inkstand," he said "re-linked." He read aloud very badly, but could repeat letters, and even short words well enough, but could only get out the first words of a long phrase. Spontaneous writing was impossible to him, and in writing from dictation he only succeeded in writing the initial letters correctly; he could copy correctly, whether from scrip or from

print. *Diagnosis*: tumour of left parietal lobe involving the gyrus angularis. Operation; sarcoma found, which could be only partially removed. Made a good recovery from operation; headache and optic neuritis got better, but paresis of motion and sensation on right side worse than before. Aphasic symptoms much better, but no improvement in writing. Later symptoms aggravated, and flap bulged; more growth removed in September, headache again relieved, but soon returned. *November 26.*—Third operation; headache again relieved, but death eight days after. No autopsy. (Quoted from Chipault.)

VII. Liepmann's Case. Apraxia.

A man, aged 48 years, who had had syphilis nineteen years previously, began in the summer of 1899 to suffer from vertigo and attacks of faintness and pain in the occipital region. He soon became unable to attend to his official duties. (He held an administrative post.) When speaking he often came to a stop, lost the thread of what he was saying, and frequently contradicted himself. He also made mistakes in writing. He became forgetful, and lost his way in going about the streets. On December 2, 1899, he had a fit without loss of consciousness, after which he was aphasic and for a time unable to walk, though he had no paralysis of limbs.

He wrote, fed himself, and fought duels right-handed, but always played cards left-handed.

On December 7, 1899, he was admitted to hospital. He then seemed almost completely demented, passed urine and fæces in bed. There was left facial paresis. Power of speech and writing lost. Urine contained

1½ per cent sugar. In a month he improved considerably, but was still aphasic, could only say "ja" and "ach," and once got out "Donner-wetter." Sometimes seemed to recognise objects, at others not. On January 13, 1900, he was able to write his name with the omission of one or two letters, and had learned to write the word "knife"; for some time afterwards, whenever he attempted to write, this word came from his pen. On January 30 he ran away, and was found wandering in the streets; the next day he was taken home by his wife. Ten days later he was admitted to an asylum with the diagnosis, "Aphasia and dementia following apoplexy."

On February 17, 1900, seen by Liepmann for the first time.

The patient was asked to make certain movements with the hand, and to pick up a particular one of a number of familiar objects that were on the table before him. He invariably made the attempt with the right hand, but was always wrong, and the way in which he handled the objects was altogether absurd.

At first sight it seemed that the patient was word deaf and perhaps also object blind. When asked to execute a movement in which the whole body was concerned, such as to stand up, to go to the window or the door, the patient did so without any hesitation or difficulty; the power of understanding speech was therefore not wholly lost. Liepmann then suspected that the errors made with the right hand depended on a purely motor defect and not on any want of comprehension. He then held the right hand of the patient firmly, and asked him to hand up one of the objects lying on the table; he at once did so, and made no mistake so long as he was compelled to use the left

hand. He, however, always made mistakes when allowed to use the right. The right leg was similarly affected; the patient could imitate any movement with the left leg, but none with the right. It was at once clear that the patient was neither word deaf nor object blind.

Liepmann during the next few weeks made a careful study of the patient's condition, for a full account of which the original paper must be consulted; only a short summary can here be given.

The patient had almost complete motor aphasia; he could only say a few monosyllables, and did not use those appropriately. His right-sided apraxia gave him the appearance of being unable to understand writing; but as he could execute correctly a written request when he was compelled to use the left hand, it was clear that he could understand writing. Short written requests were equally well understood, whether written in German or in French, but long written sentences were not understood. It was found that he had lost the power of expression by gesture as well as by speech, so that a nod or shake of the head could not be depended upon for "yes" and "no." When asked to express "yes" by a plus sign and "no" by a minus sign made with the left hand, the answers were reliable, and so a way of communication was opened.

With the right hand he could neither write spontaneously nor copy, a few letters, "m" most often, and those misplaced were occasionally recognised in the scribble. He could not copy simple geometrical figures with the right hand.

With the left hand he wrote what at first sight seemed meaningless scribble; but on looking more closely it could be recognised as reversed writing, and though the letters were clumsy, with the aid of a

mirror the correct intention could always be traced. Simple geometrical figures were clumsily copied by the left hand, but in their general outline correctly.

Sensation was somewhat impaired in the right limbs; the power of localising needle-pricks was very imperfect, and the sensation of position of the right limbs almost wholly lost.

The most striking feature of the case was the apraxia of the right limbs; this was most carefully investigated by Liepmann. The patient could perform certain acts to which he was accustomed perfectly well, such as buttoning and unbuttoning his clothes with his right hand, whether with the eyes shut or open. If asked to button his coat, he had great hesitation and difficulty in finding the button and commencing; but when once he had got the button and buttonhole, the rest of the act followed smoothly enough.

He could smoke a cigar when once it was lighted for him (using his right hand), but sometimes put the wrong end in his mouth.

Given a comb and asked to use it, he took it in his right hand, made various movements, rubbed the back of it over his hair, and then stuck it behind his ear like a pen. Asked to comb himself with his left hand, he did so easily. It never seemed to occur to him to use his left hand; it was always necessary to ask him to do so, or to hold his right hand.

Given a pen and asked to take a dip of ink, he looked for the ink-pot, and when he had found it placed his hand on it and put the pen down; lifted up the ink-pot, then put it down, and took up the pen; then put the cover on the ink-pot, and said "ach ja." Asked to do it with his left hand, he did so immediately.

When asked to do anything requiring the use of

both hands, the most grotesque effects resulted from the irregular action of the right hand. For example : Asked to transmit a telephone message, he took the receiver with his left hand and placed it correctly to his ear ; but he moved the transmitter to and fro with his right hand, placed it to his forehead and made nodding and puffing movements, then he put it to his eye and looked into it, next he put it up to his mouth, and finally placed it behind his ear. Asked to take up a box of matches and strike a light, he took the box, and with some difficulty opened it with his right hand, took out a match with the left hand, and held it ready to strike ; but instead of holding the box firmly with the right hand, he moved it about, put it down, then took it up again, and finished by putting it up to his mouth. When the box was held for him, he struck the match promptly with his left hand. Asked to brush the professor's coat, he held the lappet of the coat correctly with his left hand, but moved the brush with his right hand up and down behind his ear. Asked to pour out a glass of water, he took the jug in the left hand and handled it correctly, but took up the empty glass with his right hand and put it to his mouth ; when the glass was held for him, he filled it without difficulty.

There was no affection of any special sense.

The muscles moving the head, face, and tongue were apraxic on both sides ; the patient was amimetic or paramimetic—that is, his facial expression underwent no change with emotion, or assumed the expression corresponding to a different emotion from that felt. In addition to this defect, which was part of the aphasia, there was definite apraxia, for he was unable to put out his tongue, though it moved perfectly in mastication, or to make a facial movement on request, whether the

request was to make a definite movement such as to wrinkle the forehead, or merely for a change of expression such as to make a wry face.

The patient was treated by mercurial inunction, and for several months improved considerably; the power of appreciating the position of the right limbs was regained, and the sensation returned almost to the normal, but the apraxia persisted, though in a somewhat less degree. The patient by making more use of his left hand became much less helpless.

In October he had an apoplectic attack, which left him with right hemiplegia and aphasia. Rapid improvement with inunction treatment. In December he was able to speak again, though very indistinctly. In January 1901 speech again lost. The arm had recovered power of movement, but was ataxic as well as apraxic; the leg remained paretic. At the end of 1901 the left hand became in some degree apraxic; in May 1902 the patient had three fits and complete left hemiplegia. He never properly rallied, and his death was hastened by pneumonia.

Autopsy.—Advanced arterio-sclerosis of the large arteries of the brain, especially the left Sylvian artery and the basilar. There was a trough-like depression of the left supra-marginal convolution and superior parietal lobule; the convolutions affected were atrophic, but quite distinct; beneath them was a large cyst, the posterior extremity of which reached the white substance of the gyrus angularis, but did not extend below it. The precentral convolution was quite intact, and the post-central convolution was apparently normal, except for a small patch of yellow softening and a tiny cyst. In the left insula was a small cyst. Broca's convolution was atrophic. In the white substance of the left frontal

lobe was a patch of degeneration. The corpus callosum was atrophic, and its anterior end contained a small cyst. In the right hemisphere there was a small symmetrical focus of disease in the gyrus angularis involving both white and grey matter, and a patch of softening as large as a pea in the internal capsule, which had probably caused the left hemiplegia.

Remarks.—The large lesion in the left hemisphere was in the region diagnosed as diseased by Liepmann in an early stage of the case. The multiple lesions found at the autopsy must have interfered considerably with many association fibres.

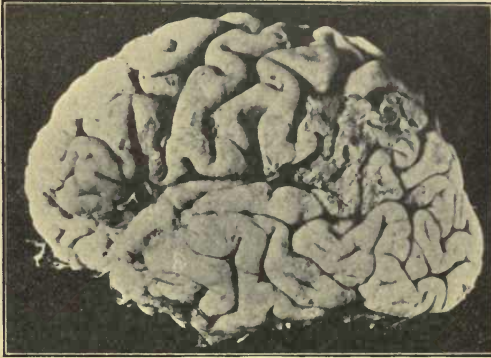

FIG. 183.—Left hemisphere.

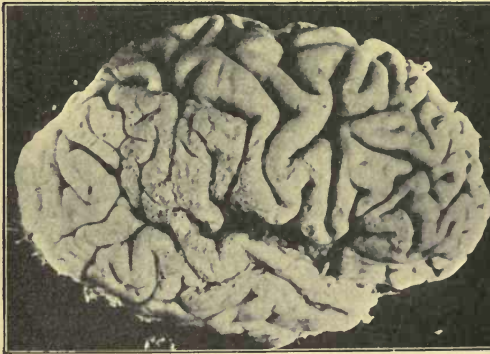

FIG. 184.—Right hemisphere.

FIGS. 183, 184.—*Symmetrical cortical lesions causing hallucinations of hearing, word deafness, and sensory aphasia. (Sérieux and Migot.)*

The patient was a man, aged 41 years, who had had syphilis at the age of 20 years. He was admitted to the asylum of Ville-Evrard on August 31, 1900. His general intelligence was not much enfeebled, but he had delusions of persecution and of grandeur which had become systematised under the influence of affections of special sense. On several occasions this systematised delirium, based upon hallucinations, was temporarily interrupted by epileptiform convulsions; these manifestations of abnormal excitation suddenly giving place to manifestations of reduced activity of the corresponding centres, cortical deafness, then word deafness. These symptoms lasted a few days and then gradually disappeared, and the hallucinations of hearing—an almost constant symptom in the case—resumed their former activity. In January and February 1901 he had a fresh series of convulsive attacks, and the hallucinations became worse. In April and May word deafness, paraphasia, jargonaphasia, word blindness, and paraphagia were observed. These symptoms, as in the preceding attacks, were of short duration; but the intelligence was by that time much enfeebled, and the hallucinations had become stereotyped. In June and in October fresh series of convulsive attacks. The patient became violent and agitated, and more and more demented; the nutrition failed, and he died on December 1, 1901.

Autopsy.—Only the brain was examined. The right hemisphere weighed 551 grammes; the left, 521 grammes. This difference was due to atrophy affecting the hemispheres unequally; the patient was not left-handed. The meninges at the base were slate-coloured. The pia was adherent to the cortex in places over both frontal lobes, but these adhesions were of no great depth or extent. In both temporal lobes there were scattered patches of slight ulceration, but in the left hemisphere in addition there was a focus of intense meningo-encephalitis affecting the posterior third of the first temporal convolution and the convolutions of the posterior inferior part of the parietal lobe behind the intra-parietal sulcus. In this situation the lesion extended in depth as far as the white substance; the whole thickness of the grey matter came away adherent to the pia. On the right side there was a symmetrically placed, but less intense lesion, not reaching the white matter.

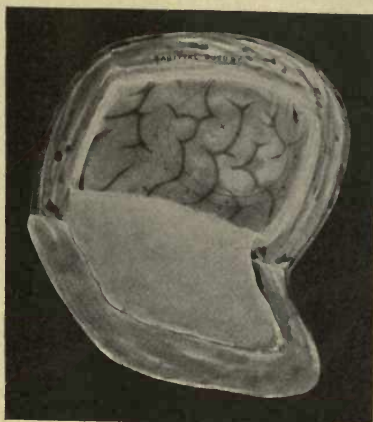

FIG. 185.—Sketch of operation for subcortical tumour (sarcoma), growing in the centrum ovale beneath the cortex of the upper part of the precentral convolution and the superior parietal lobule. (Beevor and Ballance.)

R, fissure of Rolando, + place where cortex was thinned and ruptured during palpation. The continuous line is the line of incision of cortex for removal of tumour; outside this the vessels have been ligated with fine silk.

Female, aged 30. Illness commenced twelve months before.

The salient points of the case were as follow :—

1. The gradual onset of the paralysis, involving successively ankle, knee, hip, hand, elbow, shoulder, speech.
2. The syndrome symptoms were present—headache, vomiting, and optic neuritis.
3. The mental condition deteriorated.
4. Partial loss of sensation in the right limbs.

Patient never had a fit, and there was no tenderness of cranium. Muscular sense was lost in the right upper extremity and in the right toes and ankle. Cutaneous sensation of all forms was affected, but not completely lost anywhere on the right limbs or right half of the body.

The localisation of the tumour was easy—the absence of fits and cranial tenderness pointed away from the cortex; the march of the paralysis corresponded to the arrangement of the representation of the different segments of the body in the internal capsule, and the absence of complete anæsthesia was against capsular destruction. On the mesial aspect of the hemisphere the tumour involved part of the marginal convolution and quadrate lobe. The opening made in the bone was $3\frac{1}{2} \times 2\frac{1}{2}$ inches. After the removal of the tumour a large cup-shaped cavity, the size of half an orange, was present in the brain, exposing a considerable area of the falx.

The patient was able for three years to perform her household duties. Recurrence then took place, and a tumour weighing over 3 oz. was removed. Three years later (six years from the first operation) recurrence again took place, but patient died shortly after 3rd operation, of capillary hæmorrhage from the bone which had become infected around the edges of the cranial opening.

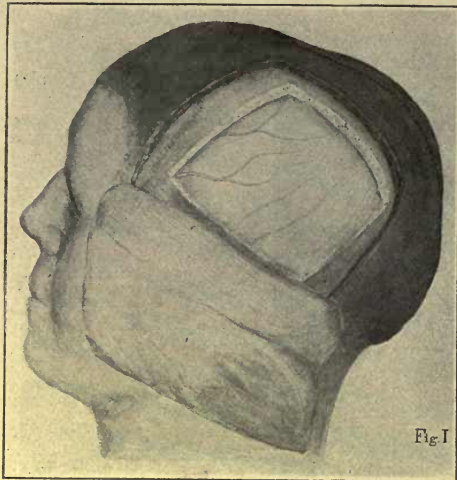


FIG. 186.

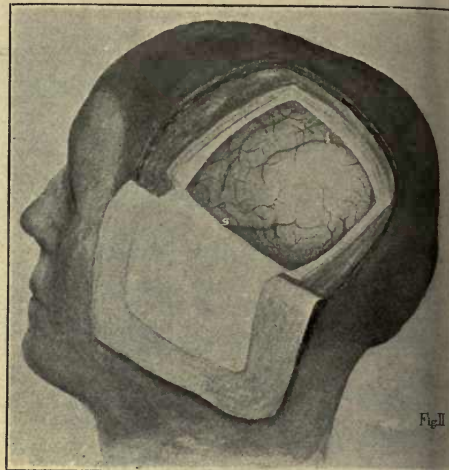


FIG. 187.

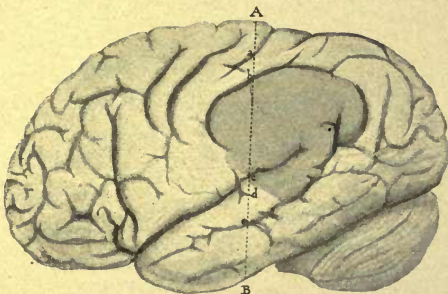


FIG. 188.

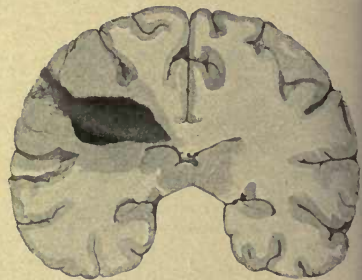


FIG. 189.

FIGS. 186-189 illustrate the usual method of making the scalp flap, and the drainage of a malignant "cyst." (Colman and Ballance.)

FIG. 186.—Scalp flap thrown down. A quadrilateral opening in the skull has been made. So great is the intra-cranial pressure that the meningeal arteries are empty. The dotted line on the scalp is over the sagittal suture.

FIG. 187.—Second stage of operation. Flap of dura has been turned down. I marks the intra-parietal sulcus, S the Sylvian fissure. The cortex of the inferior parietal lobule is thinned, almost translucent towards the centre, and forms the external boundary of the "cyst."

FIG. 188.—Lateral view of brain after hardening. The shaded cortex of the inferior parietal lobule and of the posterior part of superior temporo-sphenoidal convolution is infiltrated by the tumour.

FIG. 189.—Transverse section of brain through AB in Fig. 188. The section passes through the centre of the "cyst," and shows the path of drainage from the surface of the cortex. The extent of tumour infiltration is shown by the shading.

Mrs. G., aged 31. Ten months before being seen had a fit. Other symptoms were severe headache, occasional vomiting, optic neuritis, sensory aphasia, alexia, and agraphia, slight right hemiplegia, and hemianæsthesia. There was a remarkable recovery from all symptoms as the result of the operation, but two months afterwards patient died of pneumonia. The tumour proved to be an infiltrating glioma. The plasma filling a malignant cyst is difficult to drain, as it coagulates on cooling.

Tuberculosis of Cerebrum.

Tuberculosis of the brain, whether in the form of miliary tuberculosis, or in the form of a localised tumour or tumours, has its origin in the meninges. A tubercular tumour, even when found deeply imbedded in the brain substance, has commenced to develop in the sheaths of the vessels that penetrate the brain substance from the pia mater. A solitary tubercular mass is simply a conglomeration of miliary tubercles with degeneration of the intervening tissue. It may reach the dimensions of an egg. When several such localised masses are present, only one may cause the symptoms, the others being "latent"; this is especially true in children, who are more frequently the subjects of such tumours than adults. The difficulties of successful surgical intervention and the possible disappointments are obvious.

I will relate two recent cases of my own affecting the cerebrum, the one successful and the other fatal :—

I. A widow, aged fifty-six years, under the care of Dr. Ferrier and Dr. Purves Stewart. Seen July 6, 1905. Some three months previously, when feeling otherwise quite well, she felt a sudden sensation of weakness in the left hand. This soon passed off, but

similar attacks continued to occur, at first two or three times a day only, but soon increasing in frequency, until twenty or thirty occurred in the course of a single day. After a while clonic jerks of the whole upper limb from fingers to shoulder, apparently simultaneous at all joints, were added to the feeling of weakness. During the attacks there was no loss of consciousness. No twitchings of face or lower limb were observed.

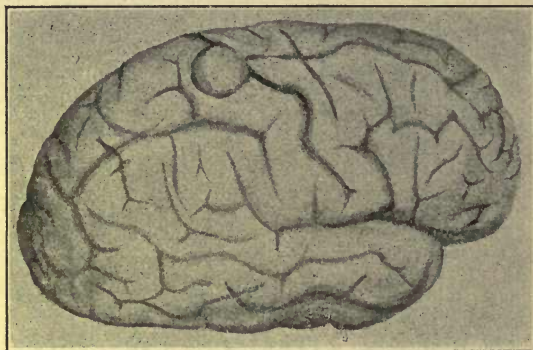


FIG. 190.—Diagram of site of tuberculous tumour behind the central fissure.
(Dr. Ferrier's case.)¹

During the last fortnight the attacks have again diminished in frequency to two or three a day. The left hand has, throughout, felt perfectly well in the intervals between attacks, but the left leg has become weak and drags a little in walking. There has been no headache nor vomiting, and no affection of sight.

When seen there was slight weakness of the left lower limb at all joints, with some exaltation of the deep reflexes on the same side. There was no affection of deep or superficial sensation. The optic discs were normal. There was no cranial tenderness. Fluid

¹ Compare Oppenheim's case of tuberculous abscess in same situation. See abstract at end of book.

removed by lumbar puncture showed moderate lymphocytosis. The intra-dural pressure was not excessive. The weakness of the left lower limb increased, the ankle and toes becoming completely paralysed. The left upper limb became distinctly weak, but all movements were possible. Twitchings of left arm and hand were observed at intervals, and slight twitchings of left toes sometimes accompanying, sometimes preceding, and sometimes following those of the left hand. Sensation, both deep and superficial, remained normal, as did also the optic discs, the pupils, and the cranial nerves. Supinator jerks increased, left greater than right, left knee-jerk much greater than right, ankle clonus present on left side. Left plantar reflex extensor, right flexor.

On July 24 I removed bone over the upper part of the right Rolandic area; the skull was abnormally thick.

July 27.—Yesterday slight twitching at left shoulder and in left lower limb, commencing at hip and spreading to toes. No increase in paralysis of limbs. Left face moves less than right on smiling. *July 28.*—Yesterday at 2.45 P.M. felt a sensation of weakness in the epigastrium, followed by twitchings in left lower limb from the thigh to the foot, simultaneously in the toes, duration $1\frac{1}{2}$ minutes. At 7.10 P.M. twitchings in left lower limb preceded by sensation of "needles and pins" in hallux. Patient felt the twitching first on the outer side of the knee, but the jerking was visible from thigh to foot, gradually increasing in severity. The foot did not change its position as a whole. With each spasm the hallux was sharply drawn up, the second toe slightly, the remaining toes being unaffected. 10.45 P.M.—Three attacks of

twitching, beginning in the left shoulder and spreading down the arm, also from the left hip to the ankle. No movements of toes. 3.15 A.M.—Jerking from left shoulder down to fingers; then from left thigh to foot. Hallux drawn up at each movement and foot inverted. 9 A.M.—Can feebly move left upper limb at all joints. Flaccid palsy of left lower limb, total at toes and ankle, severe, but not absolute at knee and hip. Cutaneous sensibility normal. Can localise light touches everywhere. Sense of position on passive movements lost at left toes and ankle, normal at knee and hip; also lost at left fingers and wrist; impaired at left elbow and shoulder. Reflexes as before.

On July 31 I reflected a flap of dura and exposed the upper part of the Rolandic area. The dura was hard and tough, and a small calcareous plate about as large as a sixpence adhered to its deep surface and to the pia mater. The corresponding portion of the cortex (post-central gyrus) was of a deeper shade of grey than the remaining healthy cortex. By means of a silver teaspoon this more deeply grey part was explored, and a yellow caseous nodule about the size of a thimble was dug out from the subjacent white matter; it had a narrow stalk connecting it with the thickened and adherent meninges. The whole area of disease was within one inch of the middle line.

August 1st.—During last night six or seven attacks of twitchings of left upper limb from elbow to hand. On one or two of these occasions the left face also twitched, and once the left foot. To-day, total flaccid paralysis of the left upper and lower limbs at all joints. Left face very slightly weaker than right. Tongue straight. No hemianopia. Anæsthesia to touch and pain of left upper and lower limbs, absolute in hand

and foot, decreasing in intensity towards proximal segments of limbs. No hemianæsthesia of trunk. 10 P.M.—Four or five attacks of twitching of left hand during the day. In one of these the march was upwards from fingers to shoulder, and then to head and left face. *August 2nd.*—Two attacks of twitching during last night, both in the face. The second one also in the left hand. *August 3rd.*—Three slight attacks of twitching of face in last twenty-four hours, and one attack of “pins and needles” in left hand. *August 4th.*—Two attacks of “pins and needles” in hand, and once slight twitching of hand and left eyelid. *August 5th.*—One slight attack last night in the hand; one attack this afternoon in left face. *August 6th.*—Slight twitching of left thumb and index at 9 A.M. At 7 P.M. “pins and needles” in the left foot. *August 10th.*—No more twitchings or tinglings since last night. All stitches now removed from wound. Can feel lightest touches everywhere on left side as acutely as on right. Still total flaccid paralysis of left upper and lower limbs. *September 22nd.*—Wound healed. Total paralysis of left upper limb at all joints. No movement of trapezius. Sterno-mastoid normal. Latissimus contracts on coughing. Face normal. Lower limb has fair movements at hip and knee; none at ankle or toes. With support can just stand and walk, dragging the left leg. No anæsthesia to lightest touches on arm or leg. Can localise sensations well. Astereognosis of left hand. S.J.’s, K.J.’s, A.J.’s, left much greater than right. Right patella clonus, and A.C. Plantars left extensor, right flexor.

Patient gradually improved, and when she left London had to a considerable extent regained power in the hemiplegic limbs, and was able to walk.

Remarks.—The spasm of the hallux and toes localised the tumour in the upper part of the Rolandic area, and the depth from which the disease was removed explains the increase of the paralysis and anæsthesia which took place after the operation. There was no optic neuritis throughout.

II. A man, aged twenty-five years, who had evident signs of phthisis, and had had syphilis, was admitted to hospital under Dr. Aldren Turner on June 21, 1905. In the preceding November he experienced a feeling of numbness in both hands, which became specially marked in the right. About Christmas time, one day when he was lying down quietly, he noticed for the first time a trembling in the right hand; after this he had tremors of the right hand lasting about an hour two or three times a day, but they have not increased in frequency or in severity. In March 1905 he had, for the first time, a fit. There was no warning beyond some increase in the tremor of the hand, which seemed to affect particularly the ring and the little finger; the fingers were drawn up, the arm stiffened, consciousness was lost, and the patient became convulsed. The right leg was not affected. Since then he has had several fits, usually of about three minutes' duration; after one of them he found that he had lost the use of his right little finger. About March he noticed some weakness of his right arm, but cannot say whether this commenced before or after the first fit.

Some three weeks before admission the right ankle became stiff. He has not had much headache, but has suffered a good deal from giddiness. He has only vomited when coughing.

On Admission.—Some paresis, with spasm of the right

OF TUMOUR OF THE BRAIN 367

hand. Flexion of the elbow is weak, extension fair; all movements of wrist weak. The hand goes into the position of ulnar flexion, the fourth and fifth fingers are flexed at the proximal phalanges and extended at the distal, and the hand seems drawn towards the ulnar side by clonic spasms which occur three or four times a day, each lasting about an hour. Left arm and both lower extremities normal. Temperature 100° , pulse 100. Slight optic neuritis, rather more marked on left side. No limitation of visual fields. No affection of other cranial nerves. Sensation normal. Reflexes normal. I *operated* on July 20 and 26. Skull dense and thick. A parallelogram of bone was cut away, and a dural flap made so as to expose the left Rolandic area from the longitudinal sinus to the Sylvian fissure. The cortex bulged slightly. Shock was so severe that the wound was closed without further exploration. The patient died six days later. The temperature rose to 108° shortly before death.

Autopsy.—Attached to the under surface of the dura near the falx there was a firm mass about the size of a cherry, which had depressed the cortex of the left paracentral lobule at its upper margin where the fissure of Rolando commences. The pia-arachnoid was thickened and milky, especially in the inter-peduncular space. The convolutions of the left Rolandic area were flattened, and beneath them a firm mass could be felt. Another mass could be felt beneath the caudal end of the second frontal convolution. The right hemisphere was apparently normal.

After hardening, besides the meningeal tumour above mentioned, there were found on section three other tumours; one about $1\frac{1}{2}$ cm. broad, and extending to a depth of $2\frac{1}{2}$ cm., which apparently originated in the

Rolandic fissure and extended beneath the cortex equally in front and behind it. It was hard and circumscribed, and involved the pia. The two others, both spherical, about $\frac{3}{4}$ cm. in diameter, were superficially placed, the one in the posterior part of the right first frontal convolution, and the other in the posterior end of the left second frontal convolution. Both were hard and circumscribed, resembled the cortex in colour, and adhered to the dura. Forebrain was cut in coronal sections, but no other tumours could be found, nor any evidence of disease. (Left arm centre minutely examined.) Membranes thickened and gelatinous (tubercle bacilli found in films) at the base of the pons and ventral surface of the cerebellum.

A small firm tumour, the size of a pea, was found in the substance of the posterior part of the ventral side of the left lobe of the cerebellum, quite superficial and attached to the pia. Nothing else in the pons, cerebellum, or midbrain. *Spinal Cord.*—Pia-arachnoid thickened and gelatinous, especially in the dorsal and lumbar regions. No tumour. *Microscopically.*—All the tumours are tubercular growths completely caseous, surrounded by a narrow ring of cellular tissue, in which tubercle bacilli were found. Brain tissue in which the tumours lay was not much disturbed, being only displaced. There was no degeneration in the spinal cord.

Remarks.—The case illustrates the condition of multiple tubercular masses involving several parts of the brain with focal symptoms apparently indicating localisation of the disease in one cortical centre, viz. that for the right arm. It also shows how little such patients are able to bear severe operative measures when the lungs are also affected.

It has been already pointed out that localising signs to be of much value must arise early in cerebral tumour. This fact has been specially emphasised by James Collier in his instructive paper on the false interpretation of the signs of intra-cranial tumour. Such signs led to an erroneous interpretation in 20 out of 161 cases analysed by him. The above case is an illustration of such error in localisation. Symptoms which may lead to a wrong diagnosis are fits, cranial nerve paralyses, and certain so-called "cerebellar signs." The pathological conditions which may cause error in localising a tumour include hydrocephalus, spreading œdema around the neoplasm, vascular lesions co-existing with the neoplasm, and metastases from the primary growth.

Tumours of Large Size.

Tumours, whether arising in the meninges or in the brain substance itself, may attain a large size, involving in their growth more than one anatomical region. As sarcomata in other parts of the body grow to a great size, so we meet with sarcomata of the brain which have become diffused throughout the hemicerebrum, the brain substance being almost entirely replaced by tumour tissue. Some of these cases have been described as glio-sarcoma; but this is somewhat begging the question of their nature, though it is by no means always easy to say definitely whether a given microscopical specimen represents a glioma or a sarcoma.

As germane to this point some observations of Max Borst are of interest:—A glioma of the brain being of epiblastic origin, while sarcoma is of mesoblastic origin, a tumour which is both a glioma and a sarcoma must have originated in two different tissues. Such a combination is conceivable, but he has not observed it. A glioma but rarely invades the meninges at all, and never oversteps the limits of the pia, and never gives rise to metastases in other organs;

while sarcoma, if not growing from the meninges, often invades them. The arrangement of tumour cells around the blood-vessels is characteristic of sarcoma. Some gliomata arising deeply in the brain exhibit epithelial inclusions, and may have arisen from the ependyma in diverticula of the original central nervous cavity.

A pure glioma does not form a solid tumour obviously distinct from the brain substance of such a size as does a sarcoma, and even when extensively diffused through the brain tissue does not alter the shape and appearance of the hemisphere to the same extent. Cystic degeneration is a common change in large gliomata. A very large tumour must have been of slow growth, since a rapidly growing tumour causes urgent pressure symptoms and speedy death. The slowly growing tumour in its early stages may give rise to no localising symptoms, while in its later stages the presence of signs indicating a lesion of the deeper regions of the brain often becomes manifest, and produces a curious reluctance on the part of the physician to advise operation. The syndrome symptoms may be absent in a slowly growing tumour. Duret observes: "In some cases the appearance of the syndrome symptoms is delayed for several years—five or even ten years—in benign or

slowly growing tumours. It should be remembered that the syndrome is really an epiphenomenon in the evolution of brain neoplasms, brought about by collateral lesions, particularly by increase of intra-cranial tension, which may be absent. . . . The diagnosis may be made in those cases of tumour of brain in which intellectual and psychic disturbances are the chief phenomena, by remembering that madness when accompanied by severe headache or localised paralytic phenomena ought to make us think of a gross lesion of the brain, and more particularly of a tumour." The syndrome symptoms are commonly wanting in tumours of the corpus callosum, of the pons, and of the medulla, and appear later in tumours of the motor region than in tumours of other regions of the cortex."

The symptoms so well described by Duret do not necessarily indicate the presence of a large tumour, but they point to the desirability of an exploratory operation which may end in the removal of the tumour or the relief of symptoms by decompression.

The following are a few illustrative cases of large tumours : many others might be cited :—

I. Bramann's Case.

A man, aged twenty-nine years, began in April 1891 to suffer from right-sided headache and from vertigo. The attacks were repeated at varying intervals and with varying intensity. In the summer of that year he had a blow on the right side of the head. In October, while sitting smoking a cigar, the cigar dropped out of his left hand and his face became distorted. Since then there has been gradually increasing weakness of the left hand. He had two further fits during the next eight weeks. In November 1891 the headache increased and the sight of the right eye began to fail rapidly, and some impairment of the power of attention was noticed. He also had double vision, but this was temporary. In March 1892 the sight of the right eye was reduced to perception of light, and failure of sight of left eye became noticeable; by the end of April he could only count fingers. There was slight vertigo, but no vomiting. On April 21, 1892, he was admitted to Bramann's clinic. The head was bowed forwards and inclined slightly towards the left. Pupils sluggish. Double optic neuritis most marked on right side. Sight very defective, and fields contracted. Left facial palsy; decided paresis of left arm, especially of fingers and hand; there was slight paresis of left leg, but right leg seemed weaker than normal. Reflexes exaggerated on both sides, especially on the left. There was œdema and tenderness of scalp in right fronto-parietal region where the patient localised his headache. On May 1 he had a fit with twitchings of left side of face, and a feeling of numbness in left hand and leg.

May 3.—Operation in right fronto-parietal region.

Bone very thin. About 8 cm. sq. of dura exposed. Dura very vascular. Hard tumour, evidently clearly marked off from brain, felt through dura; more bone cut away until limits of tumour felt, then dura incised about 2 cm. beyond growth. All vessels tied before division as operation proceeded. The tumour measured 8 cm. from before backwards, and 7 cm. from above downwards. It was enucleated step by step, the part over the ventricle being left to the last. The operator thought his finger went into the ventricle, but considered it imprudent to verify this. After the tumour was removed almost the whole of the longitudinal fissure could be seen, and most of the ethmoid. The patient made a good recovery. The growth weighed 280 grammes (9.875 oz.), and was a sarcoma with both spindle and round cells, and enclosed in a capsule of connective tissue.

II. Ballet and Delille's Case.

Male, aged fourteen years. Admitted September 20, 1900.

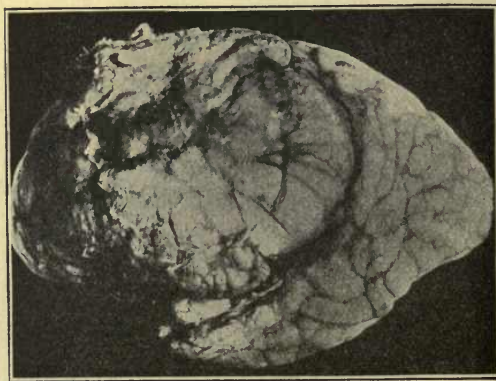

FIG. 191.—Large sarcoma of cerebral meninges. (Ballet and Delille.)

Four years previously had epileptic fits, which occurred at intervals during two years, and then ceased under potassium bromide, leaving, however, a slight right facial paresis. Nine months before admission he began to have vomiting and trophic lesions (alopecia) of scalp. When admitted he had been drowsy and dull for a month. There was alopecia of the left temporo-parietal region with œdema of the scalp. The left eye appeared deeper in the orbit than the right, and squinted downwards. There was right facial palsy and paresis of right arm. The patient complained of headache, and had optic neuritis. Fæces passed involuntarily. He could stand, but only with difficulty. No difference in power of legs. He had several fits, and died four months after admission.

Autopsy.—Old tubercle in both apices. A very large tumour involved the left frontal lobe. When the brain was removed the tumour was seen to project like the head of a mushroom, 5 cm. above the surface of the hemispheres. It measured 12 by 10 by 15 cm., and was attached by a comparatively small pedicle, the section of which measured 3 by $2\frac{1}{2}$ cm. The convolutions beneath the tumour were flattened. The posterior extremity of the left third frontal convolution was involved, but there was no aphasia. The growth was a sarcoma.

III. Dercum and Keen's Case. Brief Abstract of Symptoms, May to November 1902.

H. W., aged twenty-six years. Dull headache. Irritability of temper for previous four months. Slight loss of control of movements of right hand. Several attacks of vomiting. Bilateral optic neuritis, most advanced on left side. Paralysis of right external

rectus, slight weakness of right side of face. Astereognosis of right foot. Achilles clonus right side. Slight diminution of sensibility in right lower limb to pain, touch, and temperature. Tenderness in left post-parietal region sometimes present, but not always demonstrable. Later some numbness of left side of face.

November 1902.—Left temporal region explored; result negative.

March 1903.—Hemiplegia and hemianæsthesia of right side of gradual onset. The hemianæsthesia was most decided in the distal portion of the extremities. Right homonymous hemianopsia, without Wernicke's sign. No word-deafness, but characteristic word-blindness. Partial anosmia. Complete astereognosis.

Operation in three stages in left parietal region. The tumour, an encapsulated spindle-celled sarcoma, weighing 264 grammes (9.3 oz.) was removed. The parenchymatous hæmorrhage from the bone was difficult to arrest—a condition often found in bone infiltrated by sarcoma. The patient died soon after the operation.

Remarks.—The interest of this case lies in the presence of an enormous tumour with absence of striking localising symptoms until late in the case. "In reviewing the symptoms we are impressed with the fact of the insignificant value of paralysis of one abducens or of trifacial hypæsthesia. The case does demonstrate the localising value of astereognosis and slight muscular inco-ordination."

IV. Mills and Pfahler's Case.

A woman, aged thirty-two years, was admitted to hospital in October 1901. Some months before she began to lose power in the right leg, and the right arm

OF TUMOUR OF THE BRAIN 377

soon after became affected. She suffered from severe headache.

Symptoms on and after Admission.—Right hemiplegia

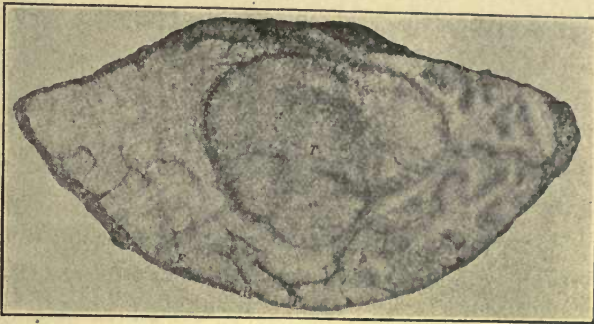

FIG. 192.

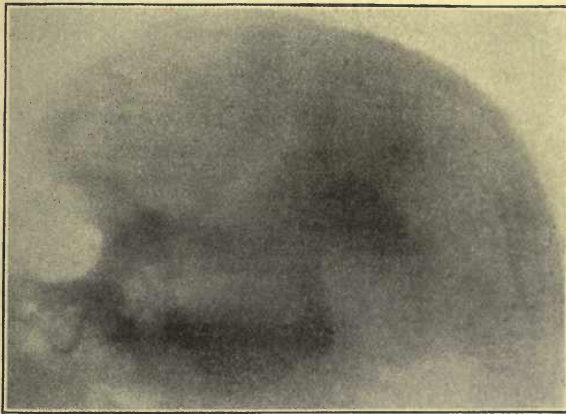


FIG. 193.

FIG. 192.—Horizontal section of left cerebral hemisphere, showing large fibrosarcomatous tumour of left parietal region. The tumour was chiefly subcortical. (Mills and Pfahler.)

FIG. 193.—Radiogram of this tumour of the brain in the living patient. Note the dark shadow in the lower parietal region. (Pfahler.)

most marked in arm. Sensation to touch and pain lost in right upper extremity, impaired in right lower extremity. Muscular sense and stereognostic percep-

tion also impaired. The loss of all forms of sensation became more decided as time went on. Marked bilateral optic neuritis. Right homonymous hemianopsia. All deep reflexes exaggerated on right side. Attacks of agonising headache. Mental state well preserved.

Diagnosis.—Large dense subcortical tumour. A distinct shadow was obtained on examination with the Röntgen rays, and the diagnosis was fully confirmed by operation and necropsy.

The severe pain in head made operation imperative, the diagnosis being large subcortical tumour in parietal region.

Operation by Drs. Hearn and da Costa.

The parietal region and ascending frontal convolution were exposed. A nodulated mass 1.8 inches in diameter coming through the cortex was removed. Death occurred two hours later.

Autopsy.—Tumour removed had been broken off from a large subcortical mass. The tumour reached the internal capsule and thalamus, but did not invade them.

Dr. Pfahler ably comments on the method to be employed to obtain Röntgen-ray photographs of brain tumours.

Remarks.—The tumour was large and for the most part subcortical. It reached the thalamus and occupied most of the parietal lobe. It was a fibro-sarcoma. The tumour was localised by clinical study and by the Röntgen rays. This is the second case in which the rays localised a brain tumour; the first case was published by Church (*Amer. Journal of the Med. Sci.*) in February 1899.

Conclusion.

I have now only to express the hope that in this lecture I have been able to show that the victims of tumour of the brain have, in surgical intervention, a means of relief, and sometimes of cure.

Starr quotes with approval the dictum of Keen, that "these operations are not to be rashly undertaken by the novice in Surgery"; but it may well be asked what operation should be rashly undertaken by the novice or by the master?

Cases of brain disease requiring surgical relief are numerous and widely distributed, but those who operate on these cases are few and far between. Not so long ago the same was true of acute abdominal diseases, but now the surgery of acute abdominal disease is successfully practised by the great body of surgeons. Until this stage in the history of brain tumours has been reached many remediable cases must go unrelieved. Up to the present, those of us who have worked in this field have been passing through a period of criticism, of opposition not

always friendly, of many disasters, and of some great achievements. Indeed, the history of operations for brain tumour, so far, may be compared to that of the early years of ovariotomy. Of those who have contributed to the slow but certain progress of this department of Medicine and Surgery some are known, but many are unknown to fame. Though in this, as in every other branch of science, each stage in the advance of knowledge is associated more particularly with one or several great names which are interwoven with its history, we ought never to forget what is due to those of less renown—the most obscure practitioner who has accurately observed and recorded an important fact, he also has added his stone to the building. And to such an one I would recall the words spoken on a memorable occasion by the late Sir James Paget, “No good work is ever wholly lost.”

I may fairly claim that, in the great achievements of the past, the strenuous and scientific labours of my colleagues at the National Hospital have had a large share.

As to the future we cannot—

“look into the seeds of time,
And say which grain will grow and which will not,”

but I am convinced that the dawn of a happier day for these terrible cases has come :—

“ And not by Eastern windows only,
 When daylight comes, comes in the light :
 In front the Sun climbs slow—how slowly ;
 But Westward look, the land is bright.”

REFERENCES.

- AUVERT, ALEXANDER. *Selecta Praxis Medico-Chirurgica*, 1851.
- BALLANCE, C. A. *Medico-Chirurgical Transactions*, vol. lxxix.
- BALLANCE and SHATTOCK. *Trans. of the Pathological Society of London*, 1887, and *Proceedings of the Royal Society*, 1890 and 1895.
- BALLET and DELILLE. *Nouvelle Iconographie de la Salpêtrière*, 1902.
- BARDESCO. *Revista di Chirurgica*, 1898, p. 35 and p. 404, quoted from Duret.
- BATTEN, F. E. *Brain*, vol. xxviii.
- BEADLES, CECIL F. Personal Communication.
- BEEVOR, C. E. Address on the Accurate Localisation of Intracranial Tumours. “*Brain*,” 1898 ; and “*Diseases of the Brain*,” 1898.
- BEEVOR and BALLANCE. *Transactions of the Medical Society of London*, vol. xviii. (1895).
- BEEVOR and HORSLEY. *British Medical Journal*, 1893.
- BERGMANN. Figure taken from the American edition of the Bruns-Mikulicz Handbook of Practical Surgery.
- BIRD. *Inter-colonial Medical Journal*, 1900, p. 281 and p. 329, quoted from MacHill.
- BORST, MAX. *Die Lehre von den Geschwülsten*, 1902, pp. 255-57.
- BRAMANN, Prof. von. Ueber Exstirpation von Hirntumoren. “*Verhandlungen der Deutschen Gesellschaft für Chirurgie*,” 1892, p. 532.
- BRAUN, H. *Verhand. d. Deut. Gesell. f. Chir.* 1892, pp. 439 *et seq.*
- BRISSAUD and MASSARY. *Nouvelle Iconographie de la Salpêtrière*, 1897, p. 73.
- BRUCE, ALEXANDER. *Trans. of Edinburgh Medico-Chirurgical Society*, 1899, vol. xviii. pp. 95 and 96.

382 SOME POINTS IN THE SURGERY

- BRUNS, L. (of Hanover). *Neurologisches Centralblatt*, 1898, pp. 783 *et seq.*, and pp. 848 *et seq.*
- CESTAN and LEJONNE. *Revue Neurologique*, 1901, p. 846.
- CHANCE and SPILLER. *American Medicine*, Jan. 1906.
- CHIPAULT, A. *Chirurgie opératoire du Système Nerveux*, vols. i. and ii., 1895; and *L'Etat actuel de la Chirurgie Nerveuse*, vols. i., ii., and iii., 1902 and 1903.
- CLOUGH. Say not the Struggle nought availeth.
- COLLIER, JAMES. *Brain*, vol. xxvi.
- COLMAN and BALLANCE. *Clinical Society's Transactions*, vol. xxix.
- CRUVEILHIER, JEAN. *Anatomie pathologique du Corps Humain*.
- CUNNINGHAM, Prof. D. J. Right-handedness and Left-brainedness. Huxley Lecture, 1902.
- CUSHING, HARVEY. The Establishment of Cerebral Hernia as a Decompressive Measure for Inaccessible Brain Tumours. "Surgery, Gynæcology, and Obstetrics," October 1905.
- DANA, CHARLES. *New York Medical Journal*, 1905, p. 270.
- DAWKINS, Prof. BOYD. Quoted from Cunningham.
- DERCUM and KEEN. *Journal of Nervous and Mental Disease*, Dec. 1903.
- DUDLEY, W. *Brain*, vol. xi. p. 503.
- DUPRÉ and DEVAUX. *Nouvelle Iconographie de la Salpêtrière*, 1901, p. 173.
- DURANTE, FRANCESCO. Quoted from Roncali.
- DURET, H. *Les Tumeurs de l'Encéphale*. Paris, 1905.
- FRAENKEL and HUNT. *Medical Record*, Dec. 26, 1903.
- FRAENKEL, HUNT, WOOLSEY, and ELSBERG. Neuro-fibromata of the Acoustic Nerve. "Annals of Surgery," Sept. 1904.
- FRAZIER, CHARLES. Remarks upon the Surgical Aspects of Tumour of the Cerebellum, "New York Medical Journal," 1905, p. 278; and the Surgical Aspects of Tumours of the Cerebrum, "Univ. of Penn. Med. Bull." 1906.
- GRUNBAUM and SHERRINGTON. *Proceedings of the Royal Society*, 1902 and 1903.
- GUTHRIE, G. J. On Injuries of the Head affecting the Brain.
- HADDEN, W. B. *Brain*, vol. xi.
- HENSCHEN, S. E. (of Stockholm). *La Semaine médicale*, 1903, p. 125.
- HITZIG, ED. (of Halle). Ueber hirnchirurgische Misserfolge. "Therap. Wochenschrift," 1896, Nos. 9 and 10.
- HOLMES, GORDON, and STEWART GRAINGER. Symptomatology of Cerebellar Tumours. *Brain*, 1904.

OF TUMOUR OF THE BRAIN 383

- HORSLEY. Trans. of Otological Society, vol. vi., and Brit. Medical Journal, Oct. 1886.
- JACKSON, J. HUGHLINGS. Lancet, 1880, i. p. 123.
- KEEN and THOMAS. American Journal of the Medical Sciences, Nov. 1896.
- KNECHT (of Waldheim). Archiv für Psychiatrie und Neurologie, vol. xii. p. 487.
- KORTEWEG. Quoted from Winkler and Rotgans' article in Chipault, vol. i.
- LEBERT, H. Traité d'anatomie pathologique, 1857-1861.
- LEMOS, M. Nouvelle Iconographie de la Salpêtrière, 1898, p. 20.
- LIEPMANN, H. Monatsschrift für Psychiatrie und Neurologie, 1900, and Archiv f. Psych. 1904.
- LLOYD, HENDRIE, and GERSON PERCEVAL. Philadelphia Medical Journal, Feb. 1902.
- LUCIANI, L. Il Cerveletto. Nuovi Studi di Fisiologia normale et pathologica. Firenze, 1891.
- MACDONNELL, J. W. Univ. of Pennsylvania Medical Bulletin, July and August 1905.
- MACHILL, W. In Chipault, vol. iii.
- MAHAN, Capt. The Influence of Sea Power.
- MAJENDIE. Journ. de Phys., 1824, vol. iv. p. 399.
- MARCHAND. Nouvelle Iconographie de la Salpêtrière, 1903, p. 85.
- MASNATA. Atti del XVI. Con. ital. di Chi., 1902, quoted from Roncali.
- MIKULICKZ, VON. Tietze's paper in Verhand. d. Deutsch. Gesell. f. Chi., 1892, pp. 450 *et seq.*
- MILLS, C. K. Diagnosis of Tumours of the Cerebellum, "New York Medical Journal," 1905; The Physiological Areas of the Cerebral Cortex, "Univ. of Penn. Medical Bulletin," 1904; Subdivisions of the Concrete Concept Area, "Med. News," Nov. 1904; On the Diagnosis of Operable Tumours of the Cerebrum, "Univ. of Penn. Med. Bull.," 1906.
- MILLS and PFAHLER. Philadelphia Medical Journal, Feb. 1902.
- MILLS and WEISENBURG. The Localisation of the Higher Psychic Functions, "Jour. of the Amer. Med. Assoc.," Feb. 1906.
- MORTILLET, GABRIEL DE. Quoted from Cunningham.
- NONNE (of Hamburg). Deutsche Zeitschrift für Nervenheilkunde, 1904, and Neurologisches Centralblatt, vol. xxiv. (1905), p. 1077.

- PAGANO, G. *Revista di Patologia nervosa e mentale*, 1902.
- PAGET, J. Address at International Medical Congress, 1881.
- POLITZER, ADAM. *Lehrbuch der Ohrenheilkunde*, 4th ed. p. 625.
- PREINDLSBERGER, J. Article in *Chipault*, vol. ii.
- RAYMOND, F. *Cliniques*, vols. iii. and v.
- RONCALI, Prof. D. B. Article in *Chipault*, vol. iii.
- RUSSELL, J. S. RISIEN. *The Functions of the Cerebellum*. "Phil. Trans. of the Royal Society," 1894.
- SÄNGER, ALF. *Ueber Hirnsymptome bei Carcinomatose*. "Neurol. Centralblatt," vol. xx. (1901), p. 1087.
- SAWICKI, BRONISLAS. Article in *Chipault*, vol. ii.
- SÉRIEUX ET MIGOT. *Nouvelle Iconographie de la Salpêtrière*, vol. xv.
- SHARKEY, S. J. *Brain*, vol. xi. 1889.
- SOUQUES, A. *De l'agraphie sensorielle*. "Rev. Neurol.," 1894, p. 65.
- STARR and MACCOSH. *Amer. Jour. of Med. Sci.*, vol. 108, p. 517.
- STEWART, T. GRAINGER. *The Diagnosis and Localisation of Tumours of the Frontal Regions of the Brain*. "Lancet," 1906, vol. ii. p. 1209.
- TAYLOR, JAMES. *Brit. Med. Jour.*, 1905, vol. ii. p. 1437.
- TOLLEMER, LOUIS. Article in *Traité de médecine*, Charcot-Bouchard-Brissaud, 2nd ed. vol. ix.
- TOUCHE, M. *La Presse médicale*, 1901, p. 306.
- VEGAS, HERRERA. Quoted from Llobet's article in *Chipault*, vol. iii.
- WEISENBERG, T. H. *The Pathology of Cerebellar Tumours*. "New York Medical Journal," 1905, p. 319.
- WERNICKE. *Archiv für Anat. und Phys.*, 1878.

Two sets of valuable papers which have been of much use to me, and which I recommend to others, have been recently contributed by the Philadelphia School. Those relating to the cerebellum appeared in the *New York Medical Journal* in 1905; and those relating to the cerebrum in the *University of Pennsylvania Medical Bulletin* in 1906. I append a list of these papers:—

- The Diagnosis of Tumours of the Cerebellum and the Cerebello-pontile Angle, especially with reference to their Surgical Removal. By Charles K. Mills.
- Remarks upon the Surgical Aspects of Tumours of the Cerebellum. By Charles H. Frazier.
- The Pathology of Cerebellar Tumours. By T. H. Weisenburg.
- The Diagnosis of Cerebellar Tumours. By Joseph Fraenkel.
- The Ocular Symptoms of Cerebellar Tumour. By G. E. de Schweinitz.

OF TUMOUR OF THE BRAIN 385

- The Functions of the Cerebellum. By Edward Lodholz.
Report of a Case of Cyst of the Cerebellum. By John M. Swan.
The Cerebellar Seizure (Cerebellar Fits); a Syndrome Characteristic of Cerebellar Tumours. By Charles L. Dana.
On the Diagnosis of Operable Tumours of the Cerebrum. By Charles K. Mills.
The Ocular Symptoms of Tumours of the Cerebrum. By G. E. de Schweinitz.
The Surgical Aspects of Tumours of the Cerebrum. By Chas. H. Frazier.

To these may be added a paper by Dr. P. C. Knapp, of Boston, "On the Results of Operation for the Removal of Cerebral Tumours," read at a meeting of the American Neurological Association held at Philadelphia in June 1905.

- Beiträge zur Diagnostik und Therapie du Geschwülste im bereich des zentralen Nervensystems. By Prof. Dr. H. Oppenheim.
Die Encephalitis. By Prof. Dr. H. Oppenheim and Dr. Cassirer.
Die Oitischen Erkrankungen des Hirns, der Hirnhäute, und der Blutleiter. By Prof. Dr. Otto Körner.
The Indications for Operation in Cases of Intracranial Tumour. By Dr. Risien Russell. "Brit. Med. Journal," Oct. 1907.
The Ophthalmoscopic Indications for Operation in Cases of Intracranial Tumour. By Mr. Marcus Gunn. "Brit. Med. Journal," Oct. 1907.
Die Geschwülste des Nervensystems. By Prof. Dr. Ludwig Bruns.
The Technique of Operations on the Central Nervous System. By Sir Victor Horsley. "Brit. Med. Journal," 1906.
The Lettsomian Lectures. By Dr. Charles Beevor. Medical Society's "Transactions," 1907.
The Treatment of Intracranial Gummata. By Dr. James Collier. Royal Society of Medicine, Dec. 1907.
On four Cases of Tumour of the 4th Ventricle. By Dr. Grainger Stewart. Royal Society of Medicine, Dec. 1907.
Lumbar Puncture with particular reference to the Diagnosis of Tuberculous Meningitis. By Dr. Bernstein. Mt. Sinai Hospital "Reports," vol. v.

Some additional Cases of interest, the fatal ones, as is usual, being especially instructive.

I. LARGE TUMOUR OF FRONTAL LOBE WITHOUT OPTIC NEURITIS (FIGS. 194-198).

Man aged 52 years. Under the care of Drs. Evans and Zieman. He was a total abstainer, but rather inclined to free indulgence in eating. He had had no previous illness, and there was no history of syphilis. He had been married twenty-five years; his wife had had two children, both healthy.

On March 29 he had a fit in his office, and was brought home in a cab; after the fit he vomited. He resumed his business the next day. On April 22 he had another fit, after which he also vomited. He went back to his work the next day (April 23), but had three fits the course of which was not observed. After this he rested for two weeks before resuming business. A few months later he went to Switzerland for three weeks with his family. His speech had become slower than normal, he would often miss his train, and became excited and emotional. In Switzerland his family had much trouble and anxiety about him. He returned home on August 8, and on that day had a fit. About this time he became very careless about his dress, and for a time had incontinence of urine. On August 16, weakness of left hand was observed, and on August 20, the left side of the face and the left leg were similarly affected. Since the commencement of the illness he had had severe headaches at intervals.

He was seen in September by Dr. Risien Russell, and

a few days later, on the 14th, by me. He then had left hemiplegia, the loss of power being most profound in the arm, with very slight hemi-anæsthesia, amounting to only slight dulness of sensation to light touches. Localisation was good. Ankle clonus was obtained on the left side. There was no optic neuritis. Mentally he was dull and slow. There had been no incontinence of urine since August.

On September 15 I removed bone over the right fronto-parietal region, and on the 24th opened the dura. The middle and upper part of the frontal lobe bulged, a large subcortical tumour was removed which occupied the first and second frontal convolutions, and the whole of the white matter beneath. It weighed over 2 oz.

The patient stood the operation remarkably well, the blood pressure only fell from 125 to 105 mm. of Hg. For a few days all went well, but the patient died on October 1, from acute spreading lobar pneumonia of the right lung, possibly of influenzal origin. The local operation conditions were normal—cerebro-spinal fluid was draining freely.

Dr. Zieman took X-ray photographs of the patient's head which demonstrated the position of the tumour. I could not make out distinctly the tumour from a study of the negatives, but on the bromide prints the outline of the tumour could clearly be seen by oblique illumination, indeed much more clearly than is expressed in the reproductions (Figs. 197 and 198). I ought to add that the skull was remarkably thin.

Dr. Zieman contributes the following facts:—The plates were imperial special rapids 10" × 8". The distance was 18 inches. The exposure in the side view was four minutes, and in the top view five minutes. The tube was very soft, having been lying by for eighteen months.

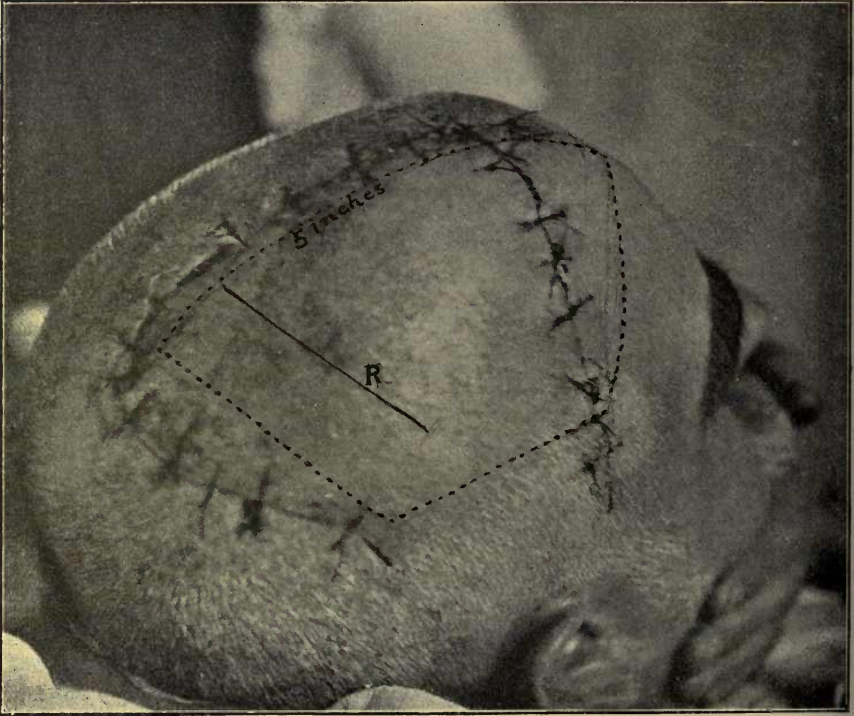

FIG. 194.—From a photograph. The dotted line shows the area of bone removed.

R, Site of furrow of Rolando.

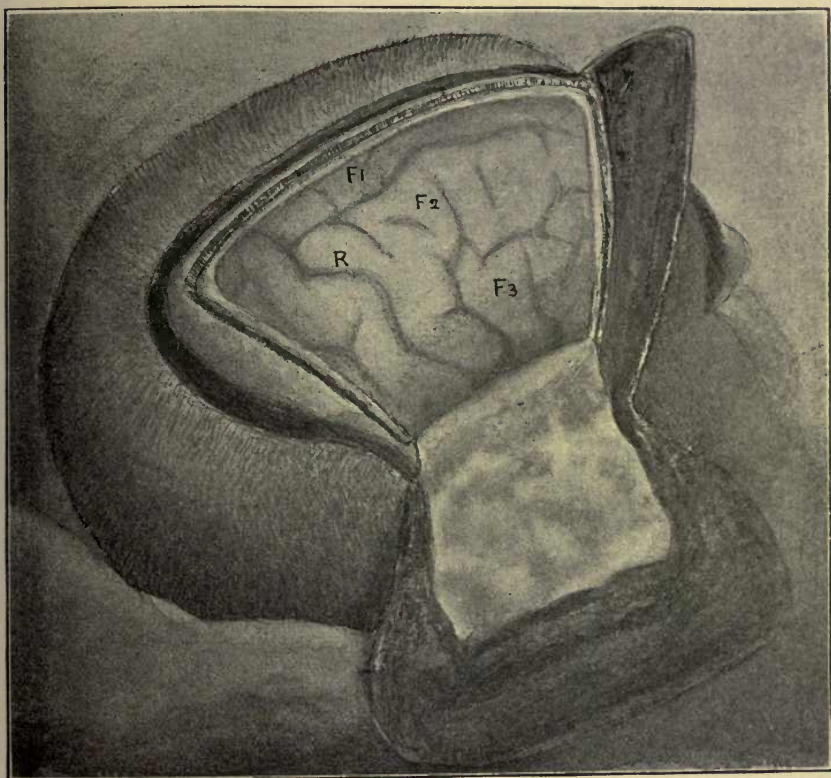


FIG. 195.—Sketch to show area of brain exposed.
R, Furrow of Rolando ; F¹, F², F³, frontal convolutions.

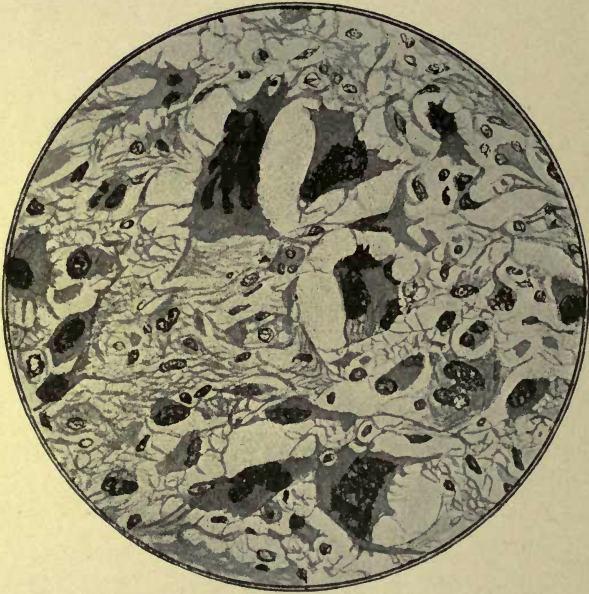

FIG. 196.—Microscopic section of frontal tumour.

The tumour is a glioma with giant cells.

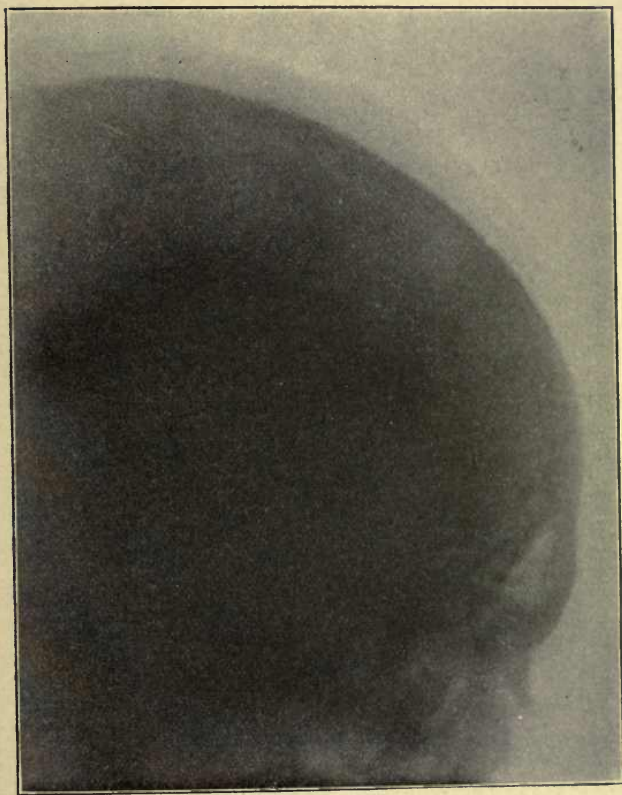


FIG. 197.—Radiogram by Dr. Zieman of frontal lobe tumour. (Side view.)

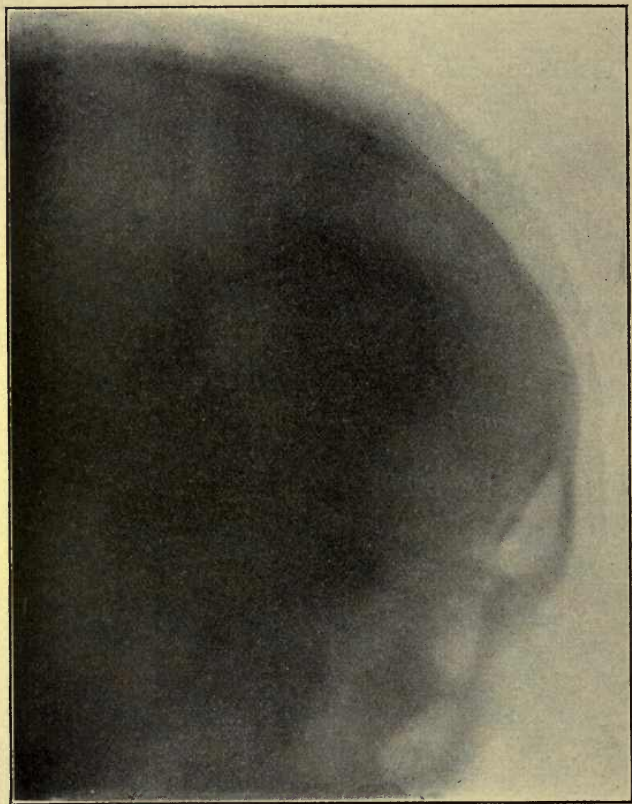


FIG. 198.—Radiogram by Dr. Zieman of frontal lobe tumour.
(View from above and in front.)

2. TUMOUR OF BASE OF SKULL WITH MENINGITIS SEROSA, MISTAKEN FOR INTRADURAL TUMOUR OF THE RIGHT CEREBELLAR FOSSA (FIG. 199).

On October 4th I was asked by Drs. Harold and Risien Russell to see a man aged 40 years. For about eight weeks he had had a vague feeling of general ill health, but without definite symptoms, until three weeks before the date of my visit. He then had pain in the right ear; this subsided after a day or two, but left him deaf in that ear and with weakness of the right side of the face. The right-sided deafness and facial palsy became absolute. He was semi-stuporous when I saw him, and for two or three days it had been observed that at times he was unable to name objects correctly and that he occasionally used wrong words. He had not had headache, vomiting, giddiness, or inco-ordination of limbs. The reflexes were brisker on the right side than on the left. The right upper limb was distinctly weak, and the grasp of the right hand feeble. Pulse 100; temperature 100°. He could be roused, and sometimes answered questions correctly. There was no decided optic neuritis, but it was thought that the retinal veins were fuller than they had been a few days previously. He had certainly had syphilis. The diagnosis was syphiloma or other tumour involving the anterior part of the right cerebellar hemisphere.

The next day the dura in the right cerebellar fossa was exposed. In working forwards towards the descending portion of the sigmoid sinus I encountered a mass of granuloma or new growth lying between the outer surface of the dura and the posterior aspect of the petrous and mastoid bones. In the hope that this was

a syphiloma the wound was closed. The dura was not abnormally tense. Next morning he was much worse, insensible, and with a slow pulse. The flap was hurriedly thrown down, and the dura, which had become very tense, opened. On insinuating the finger between the posterior surface of the petrous and the cerebellum much cerebro-spinal fluid escaped. There was no growth inside the dura. Patient did not rally, and died in twelve hours.

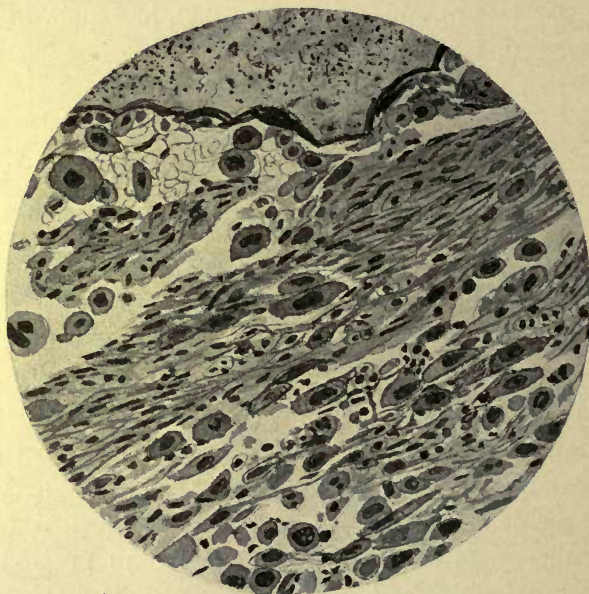


FIG. 199.—Microscopical section of growth found between dura of posterior fossa and temporal bone.

The growth was a sarcoma growing either from the outer surface of the dura or from the temporal bone. The upper portion of the drawing shows a portion of the mastoid bone which was superficially invaded by the tumour.

A radiogram of the head (side view) was taken by Dr. Zieman, but as the patient became rapidly worse was not seen before the operation. As in the last case the bromide print showed the site of the tumour; a

crested dark area about a quarter of an inch in width at its centre was visible by oblique illumination, marking the site of the tumour which separated the dura from the posterior surface of the petrous. An attempt was made to reproduce this effect, but was unsuccessful.

3. FIGS. 200 and 201.—*Microscopical Appearances of the Case of Frontal Lobe Tumour described under Figs. 175-182.*

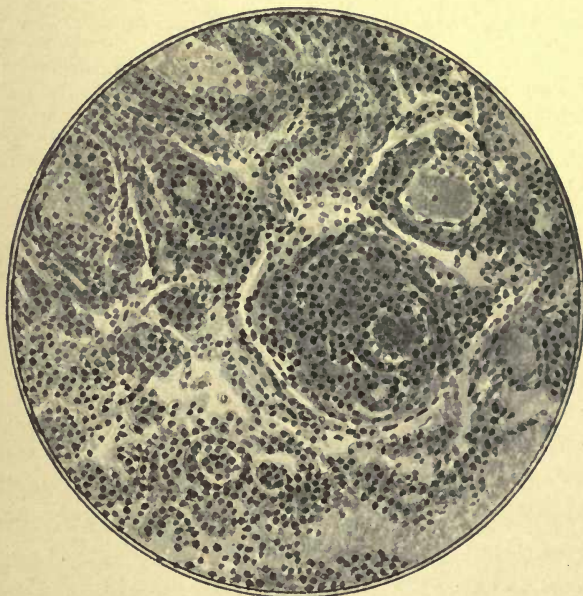


FIG. 200.—Portion of the tumour near the base of one of the greyish processes, which extended between the brain and the frontal bone ($\times 175$).
 Note the tendency to concentric arrangement of the cells so as to form whorls.

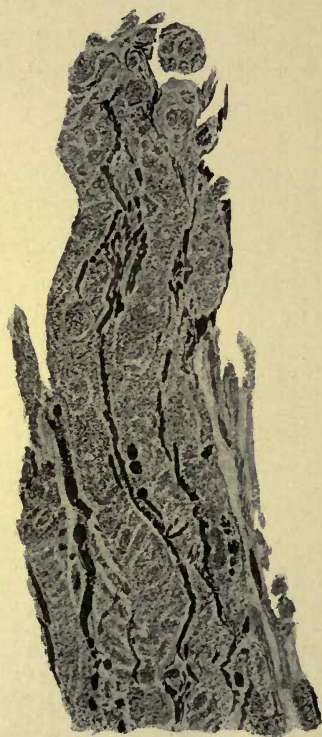

FIG. 201.—Section through a villous process showing the longitudinal arrangement of the vessels; see description, p. 331. ($\times 22$.)

4. *Figs. 202-206 illustrate a tumour of the outer surface of the dura mater kindly sent to me by Dr. Thomson of Scranton in Pennsylvania.* It reached me on 14th December 1906, when this work was already in print, but it is of such interest that, although I have no clinical history of the case, I decided to add it at the last moment.

The growth weighed (in the preserved state) 907 grammes, almost equalling the weight of the brain (in the preserved state), which was 915 grammes.

The growth measured 17 cm. from before backwards, 9.5 cm. from side to side, and 10 cm. from above downwards. It lay obliquely across the upper surface of the dura of the vertex. Its long axis was directed from in front and the left, obliquely backwards and to the right, and crossed the superior longitudinal sinus a little behind its middle at an angle of about 30° .

The growth was intimately adherent to the dura over a considerable area, and had perforated the cranium and scalp. It protruded through the skin as an oval fungating mass, measuring 9 by 8.4 centimetres.

Where not adherent to dura or scalp the limits of the growth were well defined, and its surface was in places smooth, in others nodular.

The brain had evidently suffered great compression, especially the posterior two-thirds of the left hemisphere, and was much distorted in shape. It was not infiltrated with the growth, the inner surface of the dura was intact. Histologically the growth was a spindle-celled fibro-sarcoma. The bulk of the growth was made up of long fusiform cells arranged in bundles mostly parallel to the long axis of the vessels. In places the cells appeared to be of different sizes and shapes, and to

be arranged in whorls, but this was due to bundles of long cells being cut obliquely.

Where adherent to the outer surface of the dura there was no sharp line of demarcation between growth and dura, but the long fusiform cells of the growth seemed to pass into the fibres of the dura; the dura itself was nowhere completely destroyed, but groups of sarcoma cells could in places be seen in its outer part. Near the dura were numerous pigment granules apparently derived from the blood.

In sections, including a portion of skin, the limit between skin and growth was in some places well defined, in others the growth had extended into and blended with the deep layer of the skin. Outlying groups of sarcoma cells could be seen in the thickness of the skin, and here and there groups of sarcoma cells blocked the vessels. Near the skin the bundles of long spindle cells were less compact and less regularly arranged than in the part of the growth near the dura. Near the skin, bundles of well-developed fibrous tissue were present. Where the fibrous bundles and spindle cells were cut transversely or obliquely the appearance resembled that of alveolar sarcoma.

The growth was only moderately vascular, the walls of the vessels were ill-developed.

An instance taken from Auvert's work of sarcoma of the outer aspect of the dura mater attaining great dimensions, and in some respects resembling Dr. Thomson's specimen, is described on pages 220 and 221, and figured on page 229.

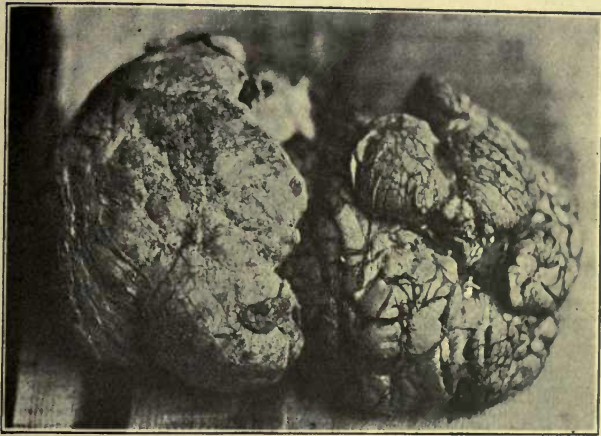

FIG. 202.—Photograph by Dr. C. E. Thomson of the tumour and the brain placed side by side to show their relative size.

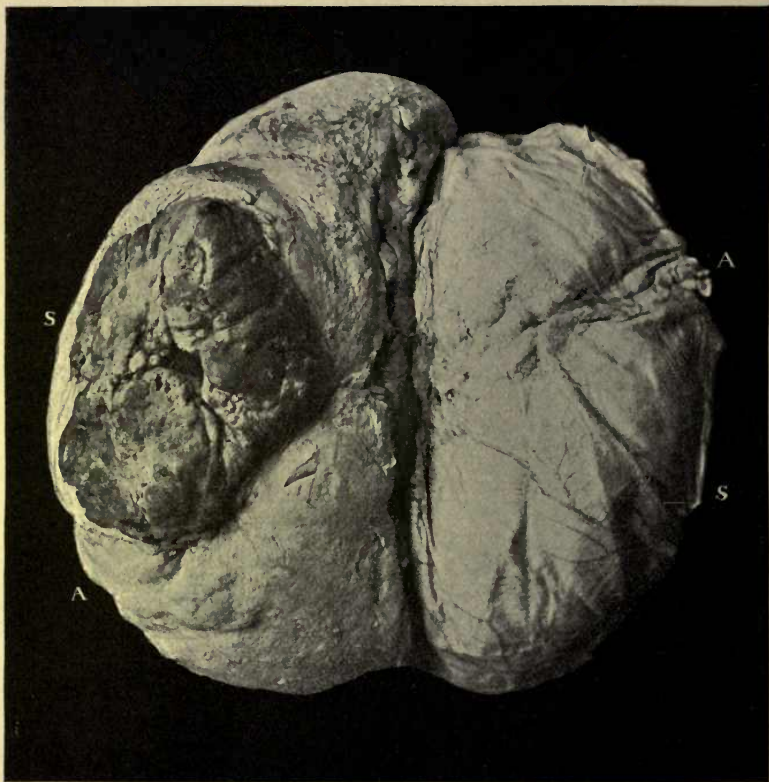

FIG. 203.—Photograph of the tumour and dura taken from above and somewhat from the right, showing the position of the tumour lying obliquely across the upper surface of the dura.

A, A, Line of longitudinal sinus ; S, S, line of section shown in next figure.

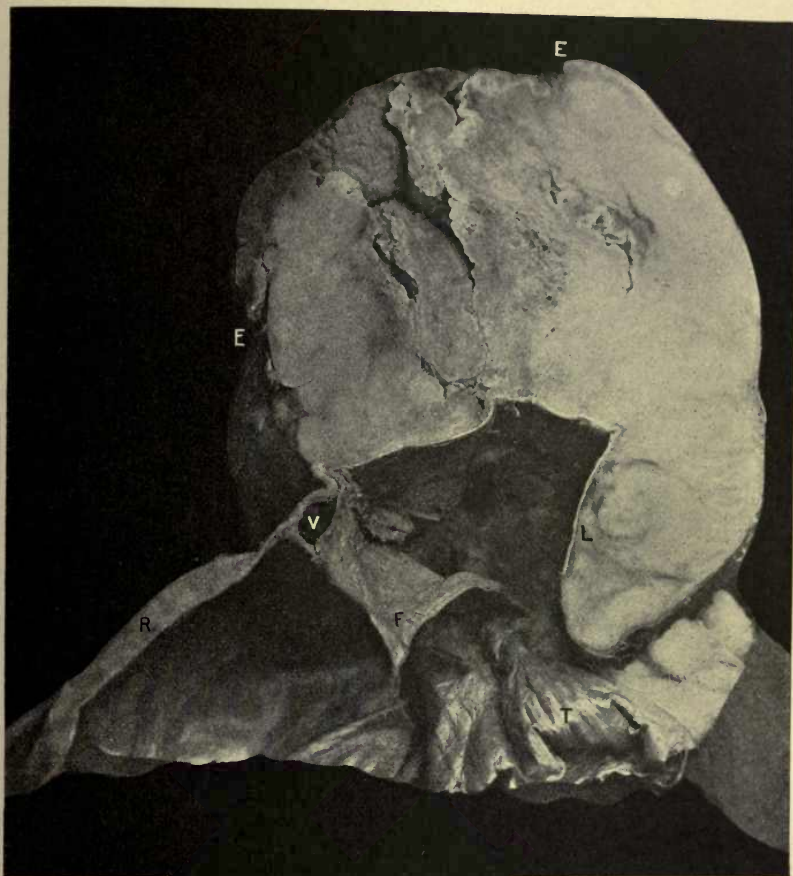


FIG. 204.—Photograph of section of tumour made in the direction indicated by the line S, S, in the preceding figure. The view is of the posterior half of the section from in front.

V, Superior longitudinal sinus seen in section; R, dura of right hemisphere; L, cut edge of dura of left hemisphere; F, falx cerebri; T, tentorium cerebelli; E, E, edge of ulcerated opening in scalp.

Note the ulceration of the tumour extends deeply, almost reaching the dura, and also that the inner aspect of the dura is intact.

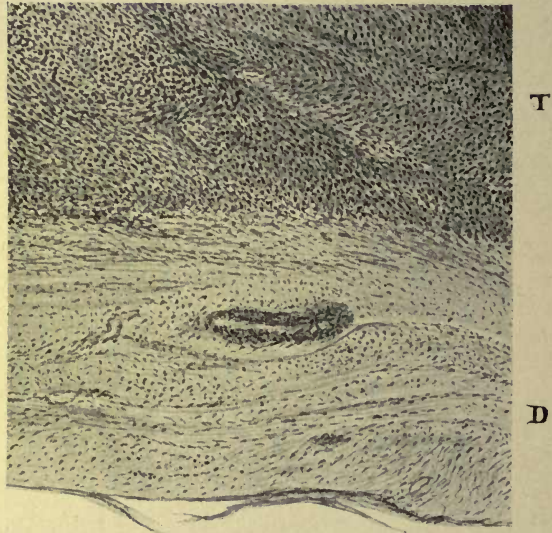
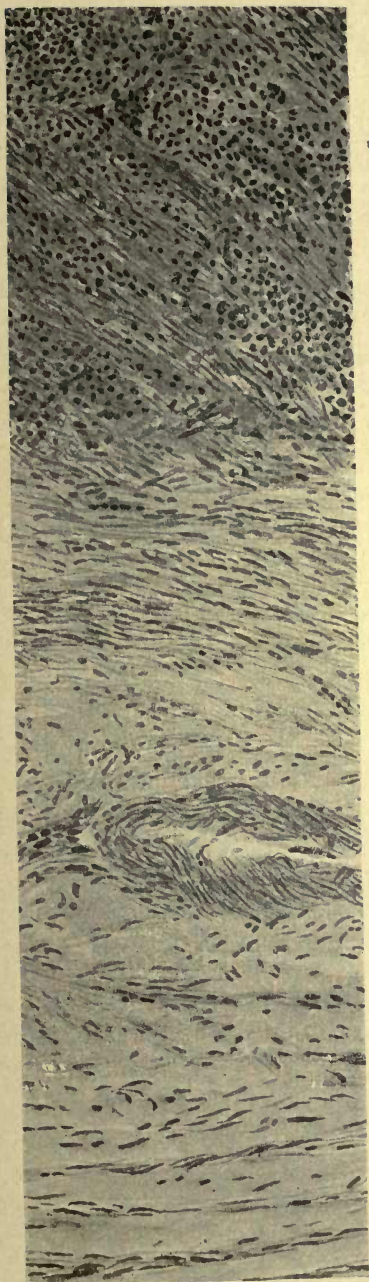

FIG. 205.—Microscopic section of the tumour where adherent to dura. ($\times 45$.)
T, Tumour ; D, dura.



T

FIG. 206.—Part of the section shown in the preceding figure. ($\times 150$.)

T, Tumour invading or growing from the outer layers of dura, which are separated by the tumour cells; D, inner layers of dura unaffected by the growth.

D

5. LARGE SUB-CORTICAL MALIGNANT CYST WITHOUT SYNDROME SYMPTOMS ; BUT WITH PROGRESSIVE LEFT HEMIPLEGIA AND JACKSONIAN EPILEPSY.

W. W., a postman, aged thirty-nine years, admitted to hospital in 1906, under the care of Sir William Gowers. There was no history of syphilis. In May 1906 he had a fit, commencing with a sudden difficulty in breathing, he felt that his left leg was slipping away, and in the course of the fit the left arm and hand and the left side of the face became convulsed, consciousness was lost and the tongue was bitten. He recovered quickly from the fit. In November of the same year he had a second fit, followed by temporary left hemiplegia, and had ten fits in all before he came into the hospital. The fits were preceded by a peculiar sensation felt deeply as starting from the left toes, travelling upwards, and seeming to pass out at the left shoulder. For some weeks prior to admission the left side had become gradually weaker. No headache, vomiting, or vertigo ; no optic neuritis ; no impairment of vision ; no astereognosis. The right pupil was larger than the left. The left plantar reflex was extensor. There was left hemiplegia without loss of sensation in the paralysed limbs.

Operation, July 29th, 1907, in one stage. Right fronto-parietal region exposed ; no great tension of dura. Veins over first and second frontal convolutions tied, and an incision then made into the brain through the middle of these convolutions. The incision opened a large malignant cyst which extended backwards in the centrum ovale as far as the finger could reach. No attempt was made to enucleate the tumour. The

paralysis was not immediately increased by the operation. There was no definite alteration of sensation of the limbs. A hernia cerebri formed which, in spite of attempts at drainage, became worse, and in the course of a month was as large as an orange. During the next few weeks it diminished in size, but the patient's

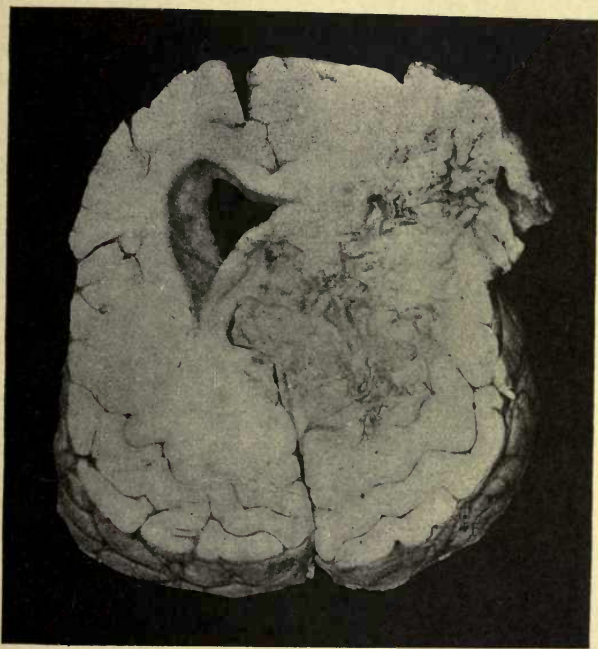


FIG. 207.—Horizontal section of brain showing the hernia and the extension of the tumour across the middle line.

condition underwent no improvement, and the hemiplegia became more profound. In October (ten weeks after the operation) he began to suffer from short fits, in which he had twitchings of the left leg, arm, and face, sometimes localised in the orbicularis or in the thigh. A month later twitchings on the right side commenced, indicating that the tumour had probably

crossed the corpus callosum. The wound unfortunately became septic, and this hastened the patient's death. The autopsy showed that the tumour had

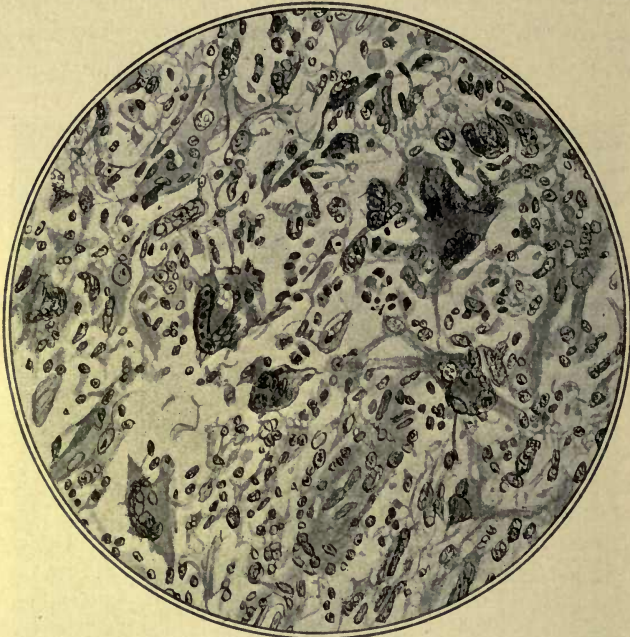

FIG. 208.—Microscopic section of tumour showing gliomatous tissue with giant cells.

crossed the middle line. Histologically the growth, which was extremely vascular, had in places the character of an angio-sarcoma ; in other parts the presence of stellate cells suggested glioma.

6. LARGE CELLULAR FIBROMA OF RIGHT AUDITORY NERVE. OPERATION. DEATH FROM HÆMORRHAGE.

W. H., male, aged forty-four years. Under the care of Dr. Aldren Turner. During the five years

OF TUMOUR OF THE BRAIN 407

prior to admission there had been deafness in the right ear, associated with "steaming" tinnitus, and the patient, by occupation an expert carpenter, had been unable to execute skilled work with the right hand. There had been no vomiting; for some nine months he had had occasional attacks of vertigo, and sometimes, in the early morning, occipital headache. He had been able to walk well, but felt the need of some support on the left side. When admitted he had nystagmus, coarse and slow when he looked to the right, but occurring

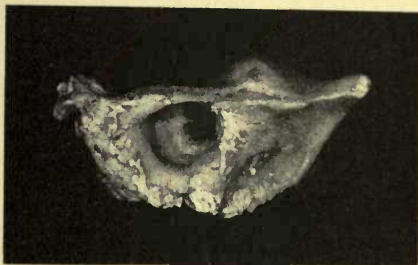

FIG. 209.—Expansion of right internal auditory meatus by fibroma of auditory nerve. (Dr. Aldren Turner's case.)

whatever the direction in which he looked. There was very slight paresis of the right seventh and of the sensory portion of the right fifth nerve. The right ear was absolutely deaf, and the patient complained of constant "steaming" tinnitus in it. There was no optic neuritis; the patient experienced some slight difficulty in swallowing, and some tenderness was elicited by pressure behind the right mastoid process. In walking he bore heavily on the heels. The right patellar reflex was more brisk than the left. Slight inco-ordination of the movements of the right hand. Movement of vocal cords normal. The giddiness induced by

rotation was more intense when the patient was turned from left to right than when the rotation was from right to left.

Operation in two stages. Severe shock at the end of the first stage so that intra-venous infusion was required. Four days later the second stage was carried out. The cerebellum bulged under great pressure, and the tumour was immediately found with the finger. The patient at once became so collapsed that rapid removal of the growth was considered imperative; this was easily accomplished, but considerable hæmorrhage followed. The patient never rallied, and died four hours after the operation. The tumour measured 5 cm. by 3 cm. and, as these chronic tumours so often do, had expanded the internal auditory meatus (see Fig. 209).

Remarks.—Operation on cases of this kind is attended by considerable mortality from hæmorrhage. The bleeding not only comes from ruptured veins but from the torn inferior cerebellar artery, and it does not seem possible at present to ligate this vessel before removing the tumour.

It is hard for the surgeon to refrain from removing a tumour when he can easily do so; the writer, however, cannot but think that, until we can be more sure of controlling the hæmorrhage, removal of the tumour, though presenting no difficulty, is not in all cases the best course to adopt, for it may kill the patient, while a simple decompressive operation will ameliorate his condition and prolong his life. Further, the after-result of cases that recover may be marred by injury to the fifth and seventh nerves, to which the tumour is often adherent.

The only other methods by which access could be

gained to tumour in this situation are (1) removing the petrous, and (2) lifting up the occipital lobe of the cerebrum and making a flap in the tentorium with its hinge at the superior petrosal sinus. The first method would not give sufficient access to a tumour of any considerable size, and is moreover objectionable for other obvious reasons; the second method would give ample access to the tumour, and might possibly allow the surgeon to pass an aneurism needle round the inferior cerebellar artery and to tie this vessel. The sudden alteration of intra-cranial pressure, which occurs when the dura is opened, allows parts which have been forced down by the increasing intra-cranial pressure through the foramen magnum to recede towards a more normal position. This change of position, together with the sudden loss of intra-cranial pressure, must inevitably produce a great alteration in the circulation through the pons and medulla. The disturbing effect of these changes on the respiratory and cardiac nuclei is another cause of the high mortality of these operations.

7. FIBROMA OF AUDITORY NERVE. DEATH FOLLOWING LUMBAR PUNCTURE.

Mrs. L., aged twenty-one years. Patient of Dr. Ferrier and Dr. Drake. She had, for many years, suffered from headache of some severity, and from attacks of vomiting. For some eight months before she came under observation the headache had been worse and recurred almost daily; she did not vomit more often than once in two weeks. For a year she had been treated (without benefit) for deafness and

whistling tinnitus on the right side. Her sight had been failing for a month. Condition found on examination:—Complete deafness of the right ear; horizontal nystagmus with wide excursions on looking to the right. Mr. Gunn reported intense fungiform papillitis on both sides, with 7 D. swelling. No hæmorrhages. She could walk well, but showed some tendency to fall towards the right side. No ataxia of limbs. Right knee-jerk very brisk; no sign of affection of seventh or fifth nerve; no dysphagia; no weakness of right sterno-mastoid. Movements of palate and of tongue normal.

Operation in two stages. At the first stage all the bone over the right cerebellar region was removed; both the horizontal and the descending limb of the sigmoid sinus were exposed. There was not much hæmorrhage, but, as is usual in cases of sub-tentorial tumour, the shock was considerable. The patient recovered well, was bright mentally, and neither had headache nor vomiting. Nine days later the second stage of the operation was undertaken; the scalp flap was thrown down; the thin dura was found to be extremely tense: in the hope of minimising the risk of injury to the cerebellum, lumbar puncture was carried out; before incising the dura a considerable amount of cerebro-spinal fluid, under great pressure, was thus withdrawn. The dura became quite slack, and I was about to incise it when I noticed that the patient was not breathing, and had changed colour. Artificial respiration was at once commenced. Oxygen was given; strychnine injected subcutaneously; brandy administered per rectum, and saline solution infused intravenously. I incised the dura while artificial respiration was continued; as there was no sign of return of natural

respiration, it was thought best to remove the tumour rapidly ; one movement of the finger sufficed to effect this. No relief was obtained, so, as it was now certain that the heart had ceased to beat, an incision was made in the abdominal wall and in the diaphragm, and the heart massaged, but no response was obtained. The tumour was attached to the auditory nerve; on throwing the light into the cavity from which the tumour came, the torn auditory nerve and the uninjured fifth and seventh nerves could clearly be seen. The sudden relief by lumbar puncture of high intra-cranial tension was the cause of the fatality in this case.

8. TUMOUR OF VERMIS EXTENDING INTO CEREBELLAR HEMISPHERES AND INTO AND BEYOND THE FOURTH VENTRICLE. OPERATION. DEATH.

P. E., male, aged fifteen years, admitted to hospital under Dr. Ferrier, September 2nd, 1907.

Three years previously he fell from a cart, striking the top of his head ; he lost consciousness for a time, but had no further symptoms for a fortnight. He then had, for the first time, an attack of headache and vomiting, and afterwards continued to have a similar attack twice or three times a week. The headache was chiefly occipital, but was also felt at the vertex and in the frontal region. The attacks began suddenly, lasted about twelve hours, and ended suddenly. Some nine months before admission he began to have fits of giddiness in which objects seemed to move rapidly round from left to right, and the patient felt that he also moved round in the same direction. About this time the movements of the limbs began to become unsteady, especially during the attacks

of giddiness, so that he was much embarrassed in walking and could not keep on the pavement.

On admission there was optic neuritis on both sides with commencing atrophy of discs, more advanced on

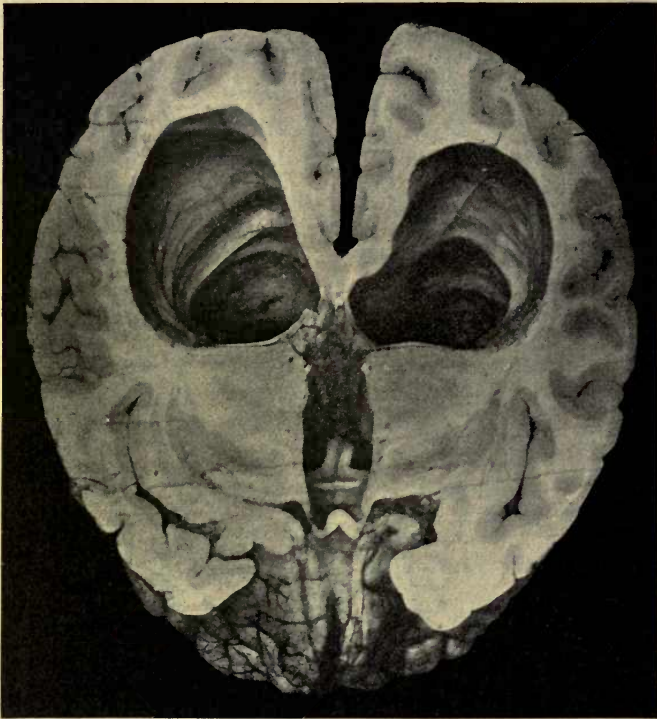


FIG. 210.—Chronic hydrocephalus of ventricles.

the right side. The range of outward movement of both eyes appeared somewhat lessened, and punctate jerkings of the eyes occurred when the patient looked to either side. No other cranial nerve was affected, and there was no loss of power or of sensation in the limbs. He could walk without assistance, but staggered and inclined to deviate to the left, and felt as if he

would fall towards the left. There was ataxia on both sides, more marked on the right side. The deep reflexes were exaggerated on both sides.¹

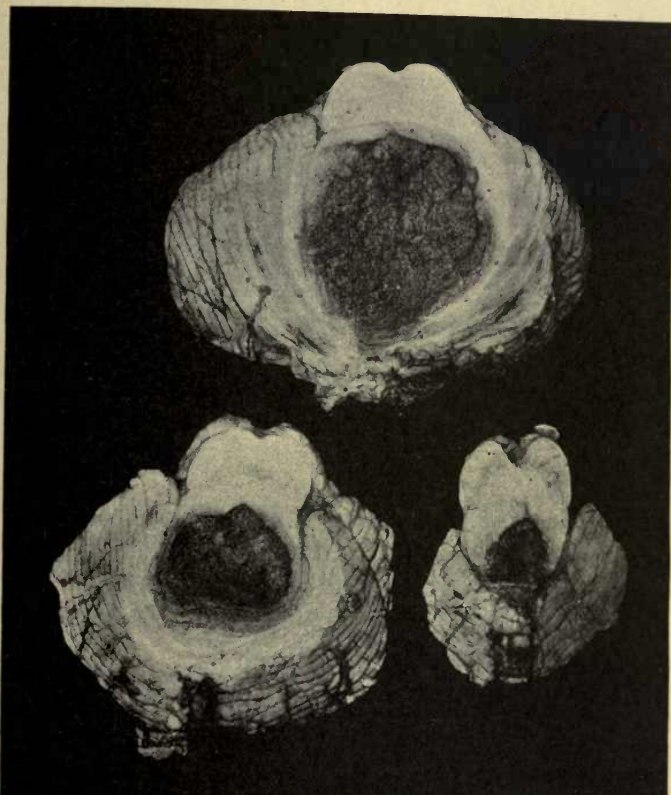


FIG. 211.—Three views of transverse sections of the cerebellum. The upper one shows the growth in the vermis and extending into the lateral lobes. The two lower show the continuity of the growth in the cerebellum and fourth ventricle.

Operation in three stages.—With the object of exposing the vermis, Cushing's cross-bow incision was made,

¹ Compare paper by Dr. Grainger Stewart on symptoms of fourth ventricle tumours. *Proc. R. S. M.* vol. i.

and flaps of the soft parts reflected, laying bare the bone over the whole cerebellar region. The patient's condition became so unsatisfactory that it was decided to do no more that day, and the scalp flaps were sutured.

Nine days later bone was removed over the cerebellar

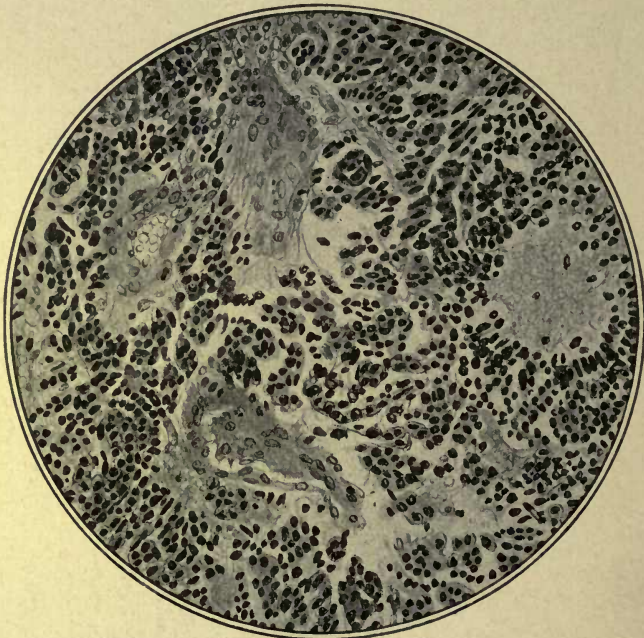


FIG. 212.—The tumour was a glioma with small cells—a form of growth frequent in the cerebellum. In some parts of the section, as shown in above drawing, the vessels are blocked by thrombi or fibrous tissue. Vascular occlusion offers an explanation of the apparently spontaneous arrest of growth in some cases.

region, the gap made extending from one mastoid process to the other. The scalp flaps were again replaced.

After another interval of nine days the third stage of the operation was carried out. The dura was under great tension. The occipital sinus was tied and a flap of the dura mater cut and thrown down so as to expose the vermis and both cerebellar hemispheres. A claret-

coloured diffuse growth, which it was obviously impossible to remove completely, was seen occupying the vermis. The operative shock was severe, but when I saw the patient next morning he appeared better and spoke to me; a few minutes later respiration ceased suddenly and could not be restored.

Autopsy.—The skull, as it often is in cases of chronic cerebellar tumour with hydrocephalus, was very thin in

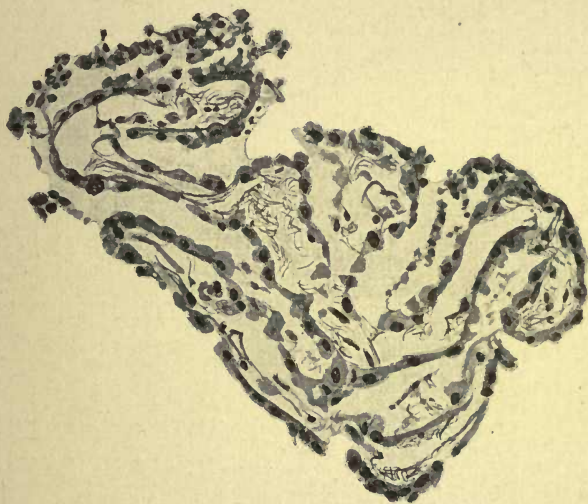

FIG. 213.—Choroid flexus of fourth ventricle with tumour cells adherent.

all parts. The medulla and pons were flattened, but the cerebellum was not forced down into the foramen magnum so as to form a "pressure cone." The folia of the cerebellum were somewhat flattened and the upper surface bulged upwards. The convolutions of the cerebrum were slightly flattened. The ventricles, especially the third, were dilated. The tumour occupied the vermis and extended into the lateral lobes of the cerebellum; it protruded from the cerebellar substance

between the pons and the medulla, the projecting portion being covered by the arachnoid. The growth had filled up the fourth ventricle, which was dilated, and spread along the dilated aqueduct of Sylvius as far as the corpora quadrigemina. It had probably commenced in the cerebellum and reached the fourth ventricle by growing through the ependyma.

Part of the tumour in the fourth ventricle had not the claret colour of the rest of the growth, but looked greyish white like an ordinary glioma.

Remarks.—The autopsy showed that the case was too far advanced for successful operation. The operation was undertaken in the hope of preventing, when the patient was no longer under observation, a relapse of the optic neuritis and the risk of sudden death which a new acute attack would have entailed. It is at present impossible to distinguish a case which may be benefited by operation from one that is irremediable.

9. LARGE CYSTIC TUMOUR OF RIGHT CEREBELLAR HEMISPHERE AND VERMIS, DISPLACING FOURTH VENTRICLE. OPERATION. DEATH.

W. I., male, aged twenty-four years. Admitted under Dr. Ferrier.

Three years prior to admission he had vomited, without any feeling of nausea, three times in the course of one week. Six months before admission he vomited one day on getting out of bed, and since then vomiting has continued at frequent intervals, sometimes on alternate days, sometimes several times a day. The vomiting has sometimes been accompanied by violent shooting pains referred to the frontal region. Some

three weeks before admission he began to complain of a gnawing pain in the left occipital region which has remained constant. Three months before admission he began to experience difficulty in maintaining equilibrium when walking, and found that he became very easily tired. A little later he began to see double. He

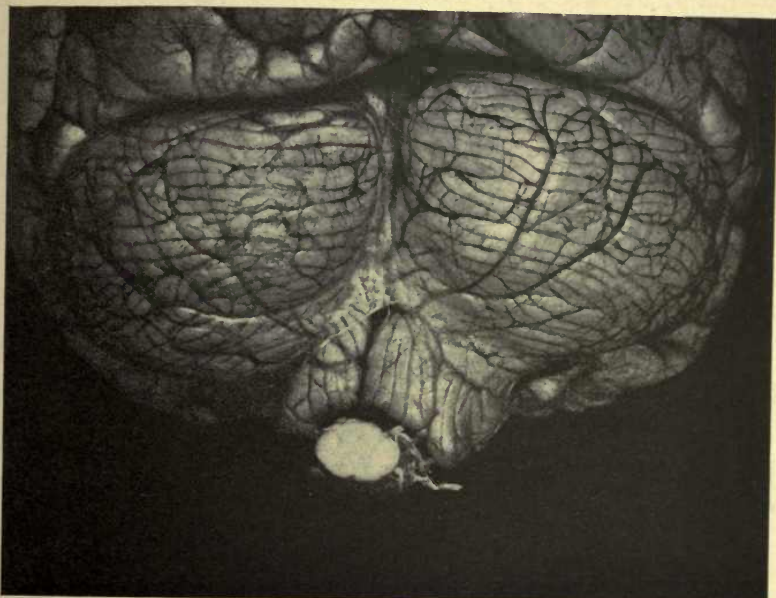


FIG. 214.—Posterior aspect of cerebellum showing the expanded right cerebellar hemisphere and the pressure cone around the medulla.

has had some occasional difficulty in swallowing. His memory is good ; there have been no sphincter troubles. Hearing and smell normal. For some two months a tendency to slur over words in speaking has been noticed.

When admitted he was scarcely able to stand alone and quite unable to walk unaided. There was intense optic neuritis. H. on each side 2 D. Swelling on right

2 E

8 D., on left 7 D. No hæmorrhages. Pupils acted both to light and to accommodation; both external recti weak, horizontal nystagmus on looking to either side. Diplopia from weakness of left superior oblique. Lower jaw deviated a little to the left, and mouth perhaps was a little drawn to right. The right side of the palate moved more than the left. Right knee-jerk

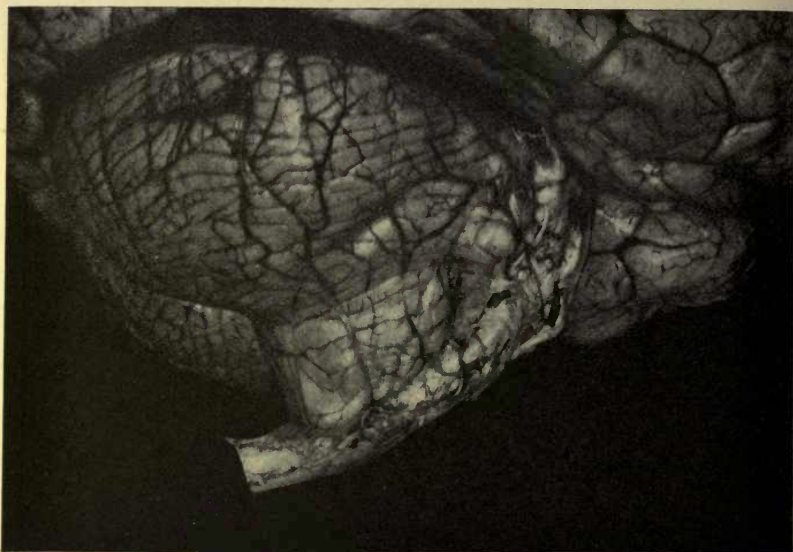


FIG. 215.—Lateral view of right cerebellar hemisphere and medulla, showing pressure cone.

greater than left. Muscles of limbs normal. Slight ataxia of right limbs, none of left. Slight staggering towards either side in walking. Romberg's sign not present. Naso-labial fold rather more marked on the left side than on the right, the tongue when protruded deviated very slightly to the left. There was perhaps slight hyperæsthesia in the distribution of the right fifth nerve.

Operation in two stages.—All the bone over the left cerebellar region was removed, but the dura, which was under great tension, was not then opened. As the scalp flap was being sutured the patient collapsed but revived well after intravenous infusion. The amount of blood lost was not excessive. Half an hour later he

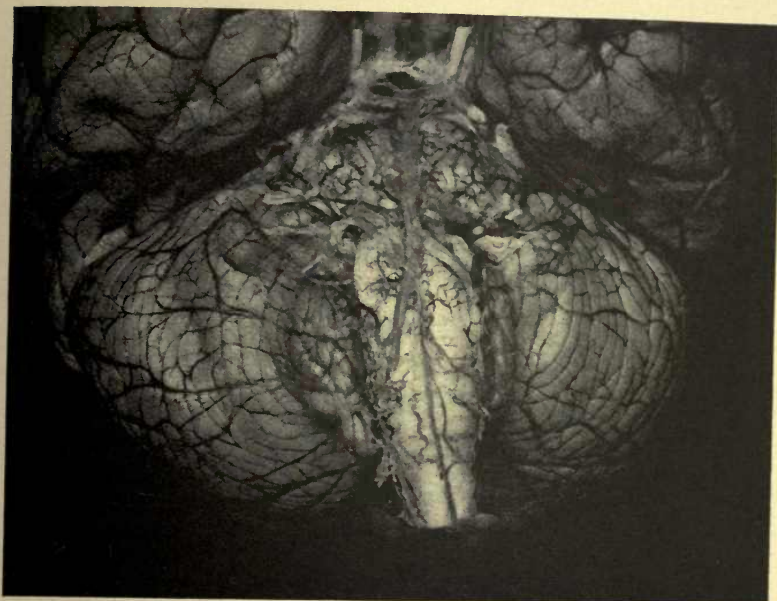


FIG. 216.—Under surface of cerebellum and medulla, showing flattening of medulla, bulging of right cerebellar hemisphere and left vertebral artery lying in a groove on the surface of the medulla.

regained consciousness and spoke, but then suddenly ceased breathing. The dura was opened and artificial respiration persisted in for an hour and a half, but in spite of stimulants and a second intravenous infusion the heart stopped.

Autopsy.—Large cystic tumour of right cerebellar hemisphere and vermis. The cyst wall was quite

definite, in some places 4 mm. in thickness. The contents of the cyst were orange red in colour and gelatinous. The cerebellum had been forced downwards into the foramen magnum showing a well-marked "pressure cone." The medulla was indented

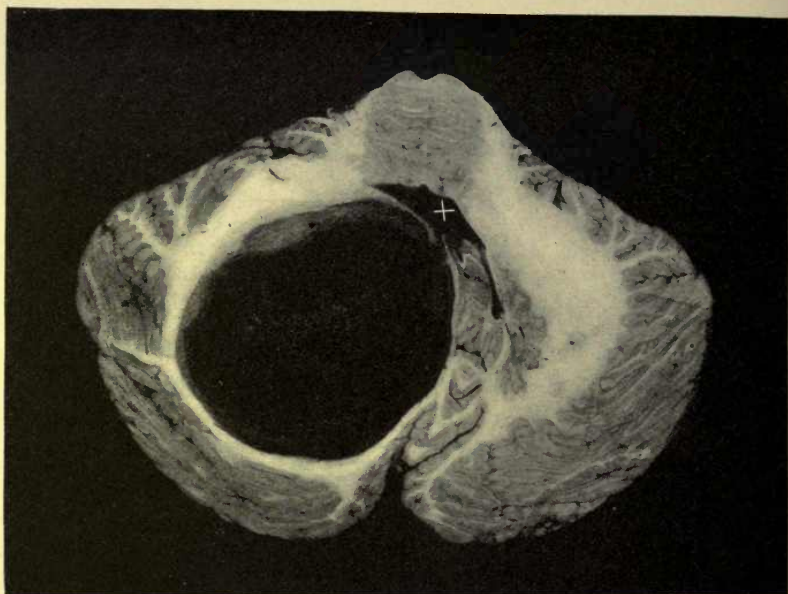


FIG. 217.—Section through pons and cerebellum, showing cyst in right hemisphere. The + indicates the fourth ventricle, which was displaced but not invaded. The ependyma in the specimen was unbroken—the gap in the figure is accidental. The photograph is of the under surface of the upper segment.

in front by a bony projection on the anterior border of the foramen magnum, and the vertebral arteries were lying in grooves on the surface of the medulla. The aqueduct of Sylvius was dilated. The fourth ventricle was obstructed and deformed but not invaded. The tumour was probably a glioma which had undergone cystic degeneration from the cutting off of its blood-supply, a method of apparent cure not infrequently

OF TUMOUR OF THE BRAIN 421

met with in glioma of the cerebellum. Neither the cyst wall nor the contents showed any definite histological structure.

10. CEREBRAL TUMOUR. SITE UNDIAGNOSED. FITS WITH HALLUCINATION OF SMELL OR TASTE PRECEDED BY AN INTELLECTUAL AURA. DECOMPRESSIVE OPERATION. IMPROVEMENT.

Mr. X., aged thirty-one years. Patient of Dr. Mott and Dr. Menzies.

Seen September 1907. For two years he had not felt quite clear in his head, and had been incapable of sustained mental application. He had had daily, or several times in a day, attacks, lasting two minutes or less, in which he had an ill-defined feeling of great dread or apprehension of impending calamity, and immediately afterwards a subjective sensation described as a metallic taste or an hallucination of smell. The only change in his appearance noticed by those with him when the fits occurred was pallor of the face. He had suffered from headache from time to time, but never severely, and not at all within the last two months. He had vomited occasionally without apparent cause during the preceding year. He had had tremor of both hands for several years; this was attributed to tobacco, and was not increasing. There was choked disc on both sides, with swelling of 4.5 D. On the left side the visual field was considerably contracted. During the time he was under observation this contraction increased, and some contraction of the right field also became apparent; there was no central scotoma. No paralysis of limbs, no alteration of

reflexes, and no loss of sensation were made out, but the right hand, although the patient was left-handed, was thought to be the stronger. There was no history of syphilis, but the patient had been given a long course of mercury and iodide of potassium.

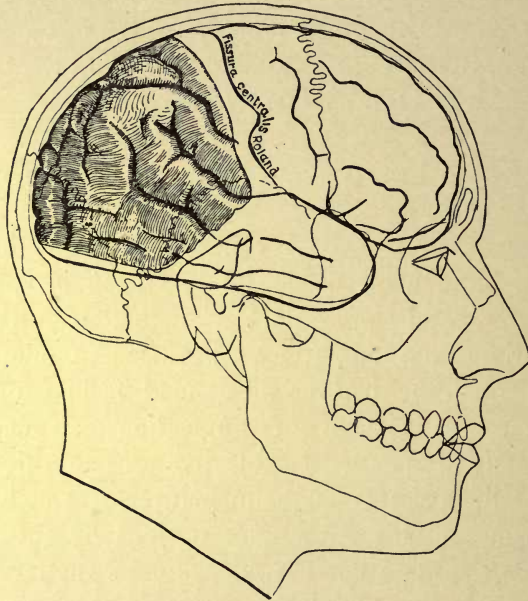


FIG. 218.—Area of brain exposed by right occipital decompressive operation. After Harvey Cushing.

Operation.—Decompressive operation over right occipital region. The dura mater was under moderate tension. No difficulty was encountered during the operation, but for some hours afterwards the patient was rather collapsed. For a few days after the operation there were no fits at all; subsequently they recurred, but only once a day in the early morning. They were very slight, and were no longer accompanied by an hallucination of taste or smell. On one occasion the

nurse noticed that the left angle of the mouth appeared drawn. Three weeks after the operation optic neuritis had totally subsided. The scalp flap was slightly bulging. The patient felt clearer in the head than he had done for years previously, and, with the exception of the very slight attacks, was quite well. The decompressive operation was done because it seemed impossible accurately to localise the tumour, which probably occupies the tip of the right temporo-sphenoidal lobe or the orbital surface of the right frontal lobe. Four months after the operation there was very slight bulging of the scalp flap, varying a little in degree from time to time. The eye signs remained unchanged, but the patient said he could see better. The head was described as feeling normal and clear, and there had been neither vomiting nor headache. There was no tremor of the hands, and the knee-jerks were normal and equal. As a rule an attack of petit mal occurred morning and evening, but as the face did not become pallid, the attacks were not evident to others. The patient states that he retains consciousness throughout the attacks, and that the sensation of fear which accompanies them is much less. The hallucination of smell sometimes occurs, but is much less intense and is never disagreeable. After exertion the patient experiences a sensation of tiredness in the head so that he now avoids walking more than about four miles. In every respect the patient's condition appears much improved.

II. LOCALISED MENINGO-CORTICAL LESION OF LEFT ASCENDING PARIETAL CONVOLUTION, CAUSING, AMONG OTHER SYMPTOMS, ASTEREOGNOSIS OF RIGHT HAND.

F. R. G., male, aged fifty years. Patient of Dr. Colcutt of Brighton and Dr. Purves Stewart. Seen September 7th, 1907.

Had had tinnitus and headache for ten to twelve years. Six years ago had intense paroxysmal pain in right hand, extending almost up to the elbow, for two or three weeks; none since. About three years ago headache became more intense; it was not always felt at the same spot. Two years ago had violent vomiting for two hours, repeated six months later, but not subsequently. When examined one and a half years ago had buzzing noise in right ear, but no abnormal physical signs were detected. Three months ago was frightened when rowing in a rough sea. Two weeks later he began to have a difficulty in finding his words, which has subsequently increased. About that time he also began to experience tingling sensations in the right index and middle fingers, with occasional localised pain in the left parietal region. His gait became unsteady and his memory failed. No vomiting, no diplopia, no fits. Noises in both ears, more in left than in right. When seen (September 7th, 1907), slight weakness of lower branch of right facial. Optic discs normal; no abnormality of visual fields. No sensory or motor abnormality in limbs, deep reflexes normal and equal, plantars not elicited. On October 3rd left parietal headache had become much worse, in spite of energetic treatment with potassium iodide and mercury. Aphasia

OF TUMOUR OF THE BRAIN 425

more pronounced, and weakness of right lower face persisted. The movements of the right upper limb were somewhat clumsy, with very slight muscular weakness. There was astereognosis of right hand. Deep reflexes equal. On October 16th he was decidedly worse; the headache was yet more severe, and the speech indistinct and monosyllabic. There was total flaccid paralysis of the right hand, with weakness

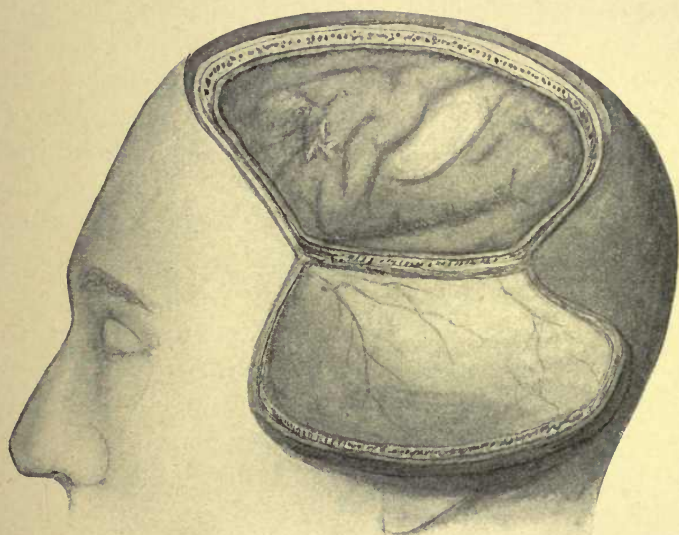


FIG. 219.—Drawing of brain as exposed during the operation. The disease of the ascending parietal convolution appears as a whitish area, while a puckered cicatrix lies just in front of the lower end of the ascending frontal convolution.

of the whole upper limb; the right leg was dragged slightly in walking. Supinator and patellar jerks increased on right side. Plantar reflexes not elicited. Trace of albumen in urine, no sugar, copious precipitate of urates. October 22nd, Mr. Lawford reported no optic neuritis or other abnormal conditions in eyes. October 22nd, 1907, osteo-plastic resection of skull in left

fronto-parietal region; dura opened a week later. No abnormal intra-cranial pressure. A whitish mass was seen showing through the arachnoid over the middle third and the upper part of the lower third of the post-central convolution. On reflecting the arachnoid this was seen to resemble inspissated pus, and it was carefully removed with the curette. The disease had destroyed the cortex superficially throughout the affected area, which was limited sharply in front by the Rolandic vein and behind by the intra-parietal sulcus. Over the posterior ends of the second and third frontal convolutions, in front of the lower part of the ascending frontal convolution, the arachnoid was scarred (see Fig. 219). This scarred portion of the arachnoid appeared to be an obsolete stage of the same process that was found over the ascending parietal convolution in a state of activity.

On November 5th, a week after the dura had been opened, speech had improved; there was no loss of power in the right leg; he could feel the lightest touch on face, arm, or leg, but there was some topoagnosis over the right hand, the stimulus being referred proximally. Painful sensations were accurately located. Joint sensation was lost in right arm and elbow, and there was very decided astereognosis in the right hand.

Patient left hospital on December 11th with considerable improvement in general condition, speech, and power of right arm, but without improvement in the stereognostic perception of the right hand.

Remarks.—Since the patient had neither vomiting, fits, nor optic neuritis, and no anæsthesia of the limbs, it seemed likely that the disease originated, and was growing, in the centrum ovale. The condition found at the operation came as a surprise. The case is a

OF TUMOUR OF THE BRAIN 427

contribution towards the localisation of the stereognostic sense.

12. A CASE OF EXTENSIVE INVASION OF LEFT CEREBRAL HEMISPHERE BY TUMOUR, WITH A SHORT HISTORY AND RAPID COURSE.

C. R., female, aged forty-nine years, admitted to hospital December 21st, 1906, under Sir William Gowers.

Her illness commenced with a fit, which occurred about eight months previously, in the early morning while she was in bed. There were no premonitory symptoms. Her husband, who was with her at the time, awoke and found the right side of her face drawn up, and the right arm and hand and the right side of face twitching. He did not notice any movement of the leg. She was unable to speak, though she did not appear to be unconscious. The fit lasted about half an hour. Neither urine nor fæces passed during the fit. The patient fell asleep again, and on waking was apparently well, and got up at her usual hour. There was neither headache nor vomiting.

The next day, about noon, a second fit occurred with similar movements affecting the arm and face, and in which the patient lost consciousness. This fit lasted about an hour. From this fit dated the hemiplegia and the aphasia. No fit of equal severity occurred subsequently. About three days after this second fit she had a fit lasting a minute or two, commencing with twitching in the right angle of the mouth and in the right side of the face, and a few seconds later affecting the right hand, which became flexed at the wrist and finger joints. No one digit was specially affected.

Consciousness was not lost during this fit. Similar fits have subsequently occurred about every second day, sometimes daily. Weakness, which has gradually increased, has been noticeable on the right side from the day of the second major fit. The power of voluntary movement of the right fingers, hand, and forearm has been almost totally lost for about six weeks, and asymmetry of the face has been noticeable during the same period. For about a month the right leg has dragged in walking. Since the date of the second major fit there has been aphasia, increasing in degree until only a few words were available, such as "yes," "no," and "oh dear." Speech was apparently well understood. There had been no vomiting throughout, nor any complaint of headache.

When admitted the patient had almost complete paralysis of the right arm, with paresis of the right leg and right side of the face. Speech was limited to a few monosyllables, but the patient apparently understood all that was said to her. The reflexes were more brisk on the right side than on the left. Ankle clonus was present on the right side, not on the left. There was no optic neuritis, and no affection of any cranial nerve except the facial. So far as could be judged, the mental condition was not materially deteriorated. The sensory and special sense functions could not be satisfactorily investigated owing to the almost complete motor aphasia. It was clear that complete hemianæsthesia was not present, as a pin prick was felt everywhere on the right side. The sphincters acted normally except for occasional incontinence of urine.

Twelve days after admission the inner margins of the optic discs had become obscured, and this led to the decision to operate immediately.

Operation, January 7th, 1907.—Skull opened in left fronto-parietal region. Dura very tense and somewhat dark. The dura was at once opened; a plum-coloured tumour the size of a shilling was seen coming through

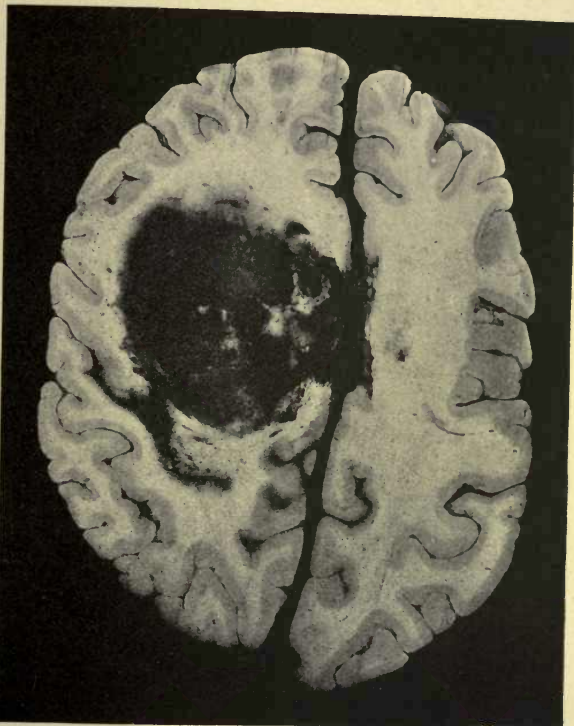

FIG. 220.—Section showing tumour in right hemisphere. *Note* right hemisphere expanded by tumour and larger than left.

the cortex of the posterior end of the second frontal convolution in front of the lower part of the arm centre. A portion of the tumour was removed, but the growth was infiltrating, and so extensive that extirpation was impracticable. Death took place the next day.

Autopsy.—Owing to the tumour the left hemisphere

was larger than the right. The growth lay in front of the fissure of Rolando and extended downwards below the level of the fissure of Sylvius, and across the middle

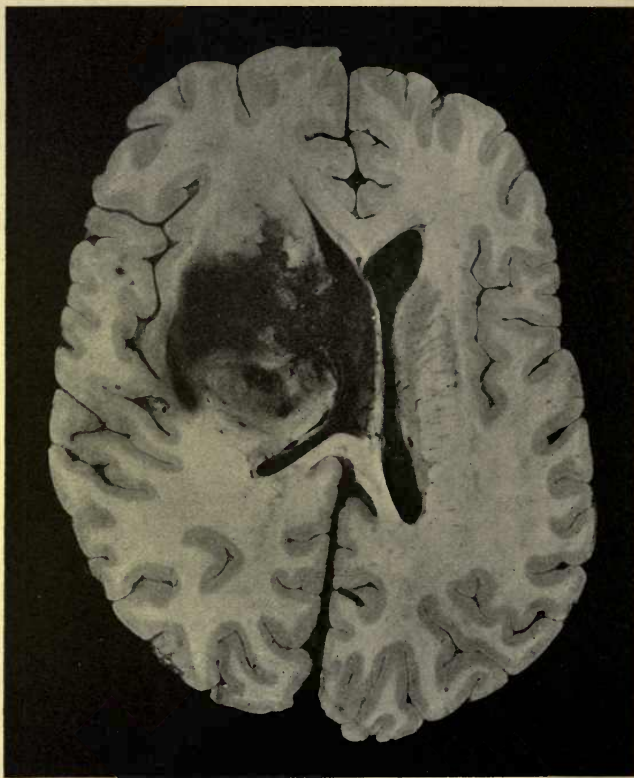

FIG. 221.—Section through ventricles showing destruction of basal ganglia and extension of the tumour into the lateral ventricle.

line at the level of the corpus callosum. The nearest part of the tumour to the frontal pole was distant 3.5 cm. A section below the level of the corpus callosum, passing through the lateral ventricle, showed that the growth involved the lenticular nucleus, the internal capsule, the caudate nucleus, and the optic thalamus,

and extended into the left lateral ventricle. Only the extreme anterior and posterior ends of the internal

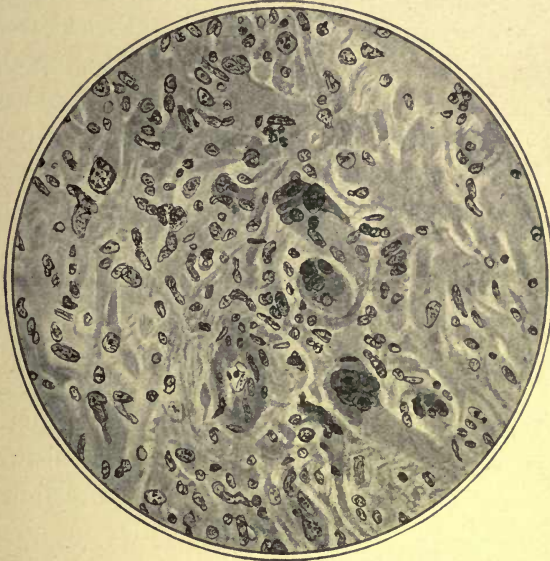

FIG. 222.—Histological section of tumour.

capsule escaped. Histologically the tumour was a glioma.

Professor Oppenheim's series of fourteen cases selected from his experience during the last three years is so instructive that I venture to append a short abstract of six of them. Of these six, three recovered.

Case I. Successful Case of Removal of Cholesteatoma Vera from the Cerebellar Region.

Man aged forty-six years. Seen January 10th, 1905.

A year previously he had fallen from a height of nine feet and injured the right side of the face. For two months he had complained of headache, of a feeling of stupor, and of vertigo ; for a week he had had frequent vomiting. He was very drowsy and could sleep all day. Headache referred to frontal and occipital regions. A few nystagmus-like jerks of the eyes in the extreme lateral position. No tinnitus. Left corneal reflex dull. Sometimes staggered in walking, tending to fall towards the left. Swayed a little when standing with the eyes shut, but became steady after a time. Left eyelids less firmly closed than right, but no difference in the action of the muscles supplied by the lower branch of the facial. Bi-lateral choked disc ; heard rather less distinctly on the left side. A slight push directed from his right towards his left side sufficed to disturb his equilibrium ; a push in the contrary direction well withstood. Left occipital region tender on pressure. Aggravation of symptoms during mercurial inunction. Operation April 4th, 1905, in left occipital region. After removal of the very thin bone a dirty brown tumour mass was exposed ; turbid brown fluid exuded from it. It seemed at first doubtful whether it was a degenerated sarcoma or a cholesteatoma. The tumour was so large that the bone wound had to be extended to the right of the middle line, forwards as far as the mastoid process and upwards above the superior curved line. Even then the limits of the tumour were not reached, so the mass was removed in fragments with the finger and a blunt curette. As the removal of the mass proceeded, glistening lamellæ were brought to light, which showed clearly that the tumour was a true cholesteatoma. After removal of the tumour it was seen that it had grown between the inner table of the

skull and the dura. The petrous and the mastoid were intact. The matrix, which was loosely attached to the dura, was removed with a blunt curette. The fragments weighed 90 grammes (3.19 oz. av.). The patient made a complete recovery.

Case II. Meningeal Sarcoma of Left Occipital Lobe.

Operation. Recovery.

The patient, a man aged thirty-five years, had for some years shown a general nervous irritability, attributed to stress of business: one of its manifestations was a peculiar dread experienced when sitting at an open window, travelling by train or by water. It sometimes happened that while transacting business he would fail to grasp the purport of what was said to him, but he was able by a strong mental effort to overcome this.

In March 1906 he began to suffer from intermittent headache, recurring every two or three days; in the intervals he was free from pain. The pain, when present, was referred to the occipital region, the neck, and the back; it did not predominate on either side. The pain increasing, Professor Oppenheim was consulted on April 25th, 1906. With the exception of slight enlargement of the spleen nothing abnormal was detected. Quinine was ordered, which seemed to give some relief to the pain. Ten days later a small retinal hæmorrhage was detected on the right side, and in the course of the next few days optic neuritis became definite on the right and showed signs of commencing on the left. During one of the paroxysms of headache, which now were of great severity, the pulse became decidedly slow.

During the month of May other symptoms were

added, rendering the clinical picture of cerebral tumour more complete. The symptoms then were headache, vomiting, giddiness on standing up, bi-lateral optic neuritis, with numerous hæmorrhages, right homonymous hemianopsia, with diminished acuity of vision in the central field. The hemianopsia was at first incomplete and only demonstrated with difficulty, but gradu-

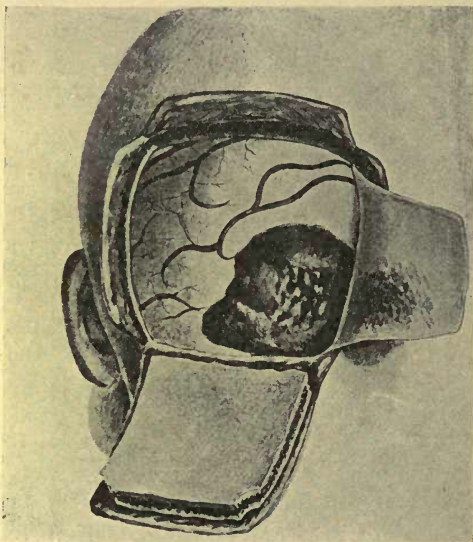


FIG. 223.—Meningeal sarcoma (left occipital region). (Oppenheim.)

ally became complete. There were defects in reading and writing partly due to failure of vision simply, but partly of the nature of alexia and agraphia. Visual hallucinations were seen on the blind side, and the sense of direction was impaired.

Mercurial inunction. Paroxysms of headache became less frequent but more intense. After a while slight loss of power and diminution of sensation on right side, tactile sensation, sense of position, and

stereognosis were all affected; there was also slight hemiataxia on right side. No spastic phenomena.

Diagnosis.—Tumour in left occipital region extending to white substance.

Operation, first stage, June 13th. Bone removed from left occipital region. Headache immediately relieved and subjective symptoms diminished. Second stage, June 25th. Dura adherent over posterior pole of occipital lobe, over tentorium and on median aspect; adhesions separated without cutting except at one small place. On separating the dura a tumour, easily distinguished by its form and colour, was seen lying on the surface of the occipital lobe and the cuneus. The growth was sharply defined; it was as large as a hen's egg and of firm consistence. It was easily shelled out with the finger, like an egg from its nest. Histological character, spindle-celled sarcoma.

During convalescence there were visual hallucinations on the blind side, but these and the hemianopsia disappeared, the patient made a perfect recovery and returned to business three months after the operation.

Case III. Sarcoma of Left Ascending Parietal Convolution. Absence of Pressure Symptoms until late. Operation. Recovery with defect.

A young man, of good physical development, had fits characterised by sensation perversions, which commenced in the right leg and gradually spread upwards over the whole right side of the body; after a while clonic twitchings, also beginning in the right leg and spreading to the right arm and right side of the face, were added to the sensation perversions. At first consciousness was either retained throughout the attack

or only lost during the course of it; later on, the attacks were no longer confined to the right side of the body, but became generalised, and were always associated with loss of consciousness.

There was weakness of the right arm, at first only noticeable immediately after the fits, but which later on became permanent. The symptoms of increased intracranial tension, headache, vertigo, and vomiting were absent. For a whole year the symptoms were those of a focal lesion, gradually increasing in extent and severity. When seen by Professor Oppenheim, the symptoms were:—1. Jacksonian epilepsy beginning on the right side. 2. Weakness of right upper limb, most pronounced in the fingers and hand, and particularly affecting the finer movements. 3. Ataxy of right arm. 4. Loss of sense of position of right arm and astereognosis, with but slight diminution of tactile sensation and no loss of sense of pain. All symptoms of cerebral pressure absent except slight vertigo.

Diagnosis.—Growth in upper posterior part of left post-central convolution. After five weeks mercurial inunction the symptoms of cerebral pressure were added, then operation.

Tumour found in expected situation and removed.

The growth was a sarcoma.

The patient recovered, but with some persistent motor and sensory defects in the right arm.

Case IV. Tubercular Abscess of Brain without Optic Neuritis. Operation. Death from Lung Disease.

Man aged twenty-eight years. At Easter 1905 a benign tumour, described as a papilloma, was removed from the right foot; the wound healed with difficulty.

OF TUMOUR OF THE BRAIN 437

In the summer of the same year a warty growth appeared on the palm of the left hand ; this was removed in April 1906 ; pus was found under it. The wound did not heal until Marmorek's serum was injected. No history of syphilis.

The nerve symptoms began in November 1905 with formication in the fingers of the right hand ; on the night of November 14th he had a fit of Jacksonian epilepsy, beginning in the right hand and spreading upwards, followed by loss of consciousness. Seen by Professor Oppenheim, November 28th, the patient then only complained of repeated attacks of twitchings and abnormal sensations, beginning in the fingers of the right hand and spreading over the whole upper limb and the face. Professor Oppenheim detected slight impairment of sensation in the right hand ; the sense of position was impaired, and objects placed in the right hand were not promptly recognised. There was slight ataxy of the movements of the right hand. The right abdominal reflex was less decided than the left. There was no optic neuritis, no headache, nor any other of the symptoms of increased intra-cranial tension.

Iodide and bromide were given. The fits ceased for a while, but began again in January 1906. Mercurial inunction was ordered ; aggravation of symptoms followed.

In March ataxia and anæsthesia in right arm were decided, stereognostic sensation and the sense of position were more impaired than was tactile sensation. Commencing ataxy in right leg. Ankle clonus on right side. Right patellar reflex more brisk than left. Right abdominal and cremasteric reflexes absent. Paresis of lower branch of right facial. No optic neuritis. No

hemianopsia. For a week or two left parietal headache. Tenderness on percussion in posterior part of left parietal region. Mental dulness and indications of commencing amnesia. Slight, if any, paresis of arm or leg.

Diagnosis.—New growth having its centre in the middle of the post-central convolution.

Operation in two stages. Dura opened, March

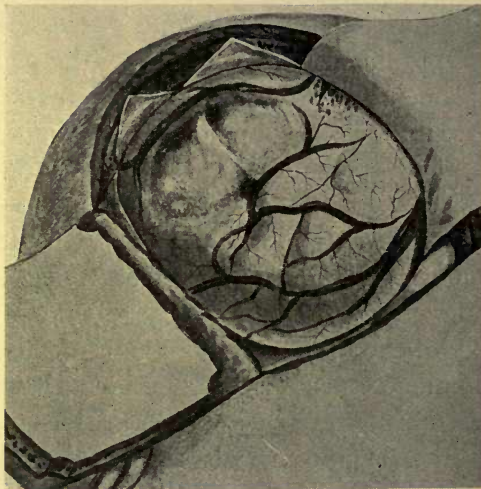


FIG. 224.—Tuberculous tumour of post-central convolution. (Oppenheim.)

30th. Brain bulged, dura adherent; on separating adhesions a yellowish grey-blue swelling, not looking like cerebral cortex, was apparent; its vertical extent was about $5\frac{1}{2}$ cm. It was divided by a band into a larger, lower, and a smaller upper and anterior part; so far as could be ascertained it occupied the upper middle portion of the ascending parietal convolution and the adjacent part of the parietal lobe. The tumour was tense and almost fluctuating; the edges felt harder than

the centre. Oppenheim wanted the mass extirpated as a whole, but the operator insisted upon making an incision; pus came out in a stream, and all except Oppenheim were convinced that it was only an abscess. Oppenheim felt sure it was a tuberculous mass, and had the pus immediately examined; abundant tubercle bacilli were found. The lower abscess cavity was then opened; it was as deep as the index finger of the operator was long; the two abscess cavities were now laid into one. Hernia cerebri, complete right hemiplegia and aphasia followed the operation.

The patient died on June 20th, 1906. Autopsy—advanced lung disease, but no trace of tubercle remained in the brain.

Case V. Left Extra- and Intra-Cerebellar Tumour (Glio-Sarcoma) with Extension to Pons and Medulla. Operation. Death.

C. H. Male aged fifteen years. Seen by Professor Oppenheim, April 1906. Two and a half years previously tinnitus and deafness on left side. Six months afterwards commencing unsteadiness of gait. This in another six months was so much worse that after slight bodily exertion the patient for a while could no longer walk alone. Mercury and iodide. At first got rapidly worse, then improved a little. In 1905 an attack of convulsions, involving all four limbs and accompanied by loss of consciousness. Head turned to left side. About ten attacks a month, another course of mercurial inunction; attacks became less frequent, but patient more apathetic.

When seen by Professor Oppenheim:—Nerve deafness left side. Paresis of left facial. Slight dysphagia,

with paralysis of the soft palate. Nystagmus especially on looking to left, and some weakness of the movement of eyes towards that side. Slight tachycardia. Bilateral optic neuritis. Spastic left hemiparesis, with ankle clonus and Babinski reflex. Tenderness in left occipital region.

Diagnosis.—New growth in left posterior fossa, pos-

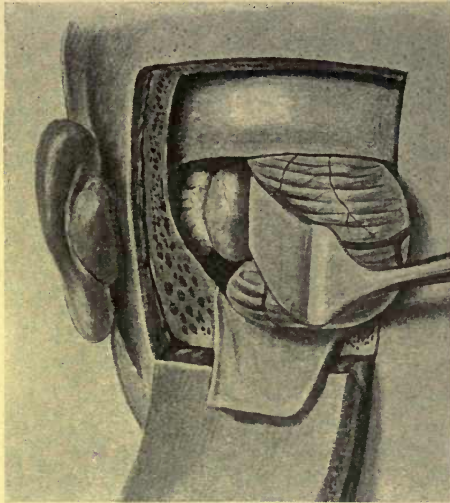


FIG. 225.—Gliosarcoma in cerebello-pontine angle. (Oppenheim.)

sibly beginning in auditory nerve, but in any case extending fairly deeply downwards and backwards.

Operation in two stages. May 2nd, bone removed over left cerebellar region. May 14th, dura opened, lateral sinus wounded and closed by suture. Cerebellum retracted towards median line; at a depth of 3 cm. a semi-fluctuating bluish tumour, with a vertical constriction, was seen. The finger was inserted between the cerebellum and the tumour, by which it was ascertained that the growth almost equalled the cerebellar

hemisphere in size, and was firmly attached to the petrous, and extended to a great depth medially and below.

An attempt was made to remove the tumour whole with a blunt spoon, but the capsule ruptured and part of the tumour came away. Pulse rapid (120) and small; two litres of saline solution infused.

Patient died the same evening. The growth was a richly cellular glio-sarcoma.

The autopsy showed that not only was there a large extra-cerebellar tumour, but that the growth had invaded the left cerebellar hemisphere, and spread from thence into the left half of the pons and the medulla.

Case VI. Cystic Sarcoma of Right Cerebellar Region found at a Second Operation two and a half years after the performance of a First Operation.

A man aged fifty-one years began in 1901 to suffer from pain in the right occipital region, especially at night and on lying down, and from nausea, eructations, and vomiting, gradually increasing in frequency and severity. He frequently had indistinct sensations of seeing double. Vertigo was often felt, and his gait and handling of objects gradually became more unsteady and uncertain. He had no affection of speech and no difficulty in swallowing. The hearing of the right ear was slightly impaired. Early in 1904 the headache subsided, but nausea, vomiting, and visual disturbances increased. The right cerebellar region was explored in April 1904, but no tumour was found. There was some improvement in the general symptoms and in the gait, but soon afterwards the right arm and leg became so weak and unsteady that the patient was unable to write,

and could not walk without support. After a time these symptoms slowly subsided, but later on again became prominent. Some four months after the operation there was considerable bulging of the flap. The swelling was punctured in the autumn of 1904 and again in the spring of 1905, but no important improvement resulted. In 1906 the bulging of the flap rapidly increased in size, and the patient came for the first time under the observation of Professor Oppenheim. He then had pronounced ataxia of all movements, but greatest in those of the right arm and leg. The deep reflexes on the right side were exaggerated. There was right facial paresis. Tongue protruded to right; decided weakness of right trapezius. Swelling as large as an apple in right occipital region. Bilateral choked disc. June 27th, 1906.—*Second Operation.* After 300 c.c. of clear fluid had been let out, a cyst as large as the fist with smooth walls was exposed. The anterior wall of the cyst penetrated like the stem of a mushroom into the cerebellum. The cyst wall was removed. The cerebellar hemisphere felt much harder than normal; it was firmly adherent to the tentorium and to the dura at the base. Smart bleeding on separation of the adhesions. Stertorous breathing and slow pulse on introducing the finger. The greater part of the apparently diffusely diseased cerebellar hemisphere was removed. Breathing remained stertorous; the patient never rallied; and died the same evening. The growth was a sarcoma.

INDEX

- Abscess of Brain—
 Clinical evolution of, 129-130; sub-acute, 130-131; with severe general infection, 132; with latency of symptoms, 132-133; simulating brain tumour, 133; remittent type, 133-134
 Cortical functions, effect on, 101
 Deep, point of attachment to dura, 145
 Diagnosis, 129 *et seq.*; of brain abscess with complications, 137-138; differential diagnosis, 139-142
 Direct infection, 95 *et seq.*
 Discovery and incision of, 150-154
 Diseases associated with, 91
 Encapsulation of, 100-103
 Gunshot wounds, due to, 102-103
 Indirect infection, due to, 99, 102
 Infective diseases, complicating, 91-92
 Instruments, use of, in operating for, 150-154
 Latency of, 100, 132-133
 Lung disease, secondary to, 93-95
 Mode of formation of, 97-99
 Multiple, 105-109
 Operation for, 143-150; advisability of early operation, 154; post-operative symptoms, 155-156
 Simultaneous development of, in different situations, 136-137
 Stalk of, drainage through, 144-145
 Symptoms, 109-110; of extra-dural abscess, 110
 Treatment of, 142 *et seq.*
 Tubercular, 436-439
 Tubercular, spontaneous recovery from, 103-105
 Acland, Dr., case of, *quoted*, 331
 Acute specific diseases simulating meningitis, 59, 60
 Agraphia, in parietal lobe tumour, 339, 349
 Alexia, in parietal lobe tumour, 339, 349
American Journal of Medical Sciences, *cited*, 328, 378
 Amnesia, auditory, 243, 339
 Amusia, 121, 124, 339
 Anæsthesia, 55; trigeminal, 253
 Angioma of cranial bones, 216, 218-219
 Angio-glioma, 163
 Angio-lithic sarcoma, 164
 Angio-sarcoma of brain following punctured fracture of skull, case *quoted*, 208-210; histology of case, 211-215
 Angular gyrus, tumour involving, 309, 339, 350, 355, 356
 Aphasia, 36, 113, 115-122, 349-350
 Aphemia, 119-120
 Apoplexy, lumbar puncture in, 39-40
 Apraxia, in lesions of parietal lobe, 340-343; in case of multiple brain lesions, 350-356
 Arachnoid membrane, 18; serous cysts of, 25-26; suppurative of, 43; inflammation of, 49
 Archimedes, principle of, in relation to brain protection by cerebro-spinal fluid, 14-15
 Arterio-sclerosis of brain arteries, 355
 Astasia, 250
 Astereognosis, 347-349; localising value of, 376; of right hand, 424
 Asthenia, 248-250
 Asynergia in cerebellar tumour, 241
 Ataxia—
 Cerebellar, 241
 Frontal, 320-321
 Atonia in cerebellar tumour, 244, 249-250
 Attitude in cerebellar tumour, 238
 Auditory nerve, tumour of, 273, 274, 278, 280, 406-411

- Auvert, *cited*, 108, 216, 220-221, 229, 271
- Babinski's sign, 29, 55
- Ballet, *cited*, 122
- Ballet and Delille, cases of, *quoted*, 327-374-375
- Bardesco, *cited*, 173
- Barlow, Sir Thomas and Dr. Lees, *cited*, 12-14; *quoted*, 61 *note*
- Bastian, Dr., *cited*, 36
- Batten, *quoted*, 238
- Beadles, C. F., cases of, 172, 223
- Bechterew's nucleus, 246
- Beever, Dr., *cited*, 115 *note*, 162, 331, 338
- Beever and Ballance, case of, *quoted*, 359
- Beever and Horsley, case of, *cited*, 182
- Beever and Jackson, case of, *quoted*, 124-125
- Beever and Lunn, case of, *quoted*, 207, 283
- v. Bergmann, cases of, *cited*, 104; *quoted*, 102-103
- Bernard, Dr., case of, *quoted*, 197-204
- Bird of Melbourne, *cited*, 174-175
- Biroula, *cited*, 27
- Blood pressure in cerebral sinuses, 10
- Blöttche, *cited*, 93
- Borst, Max, *cited*, 163 *note*, 370
- Bouillaud, *cited*, 120
- Brain—
- Abscess of. *See* Abscess of Brain
 - Lesion of substance of, simulating meningitis, 55, 59, 60
 - Protection of, by cerebro-spinal fluid, 14-15
 - Resistance of cortex to bacterial attacks, 97
 - Tumour of. *See* Tumour of Brain
 - Weight of, supported by hydrostatic pressure, 14-16
- Bramann, case of, *quoted*, 373-374
- Bramwell, Byrom, *cited*, 115 *note*
- Braun of Königsberg, case of, *cited*, 223-225
- Breast, carcinoma of skull secondary to that of, 216
- Bright, Richard, *cited*, 26, 27, 28, 108
- Brissaud and De Massary, case of, *quoted*, 324-325
- Brissaud and Souques, *cited*, 119, 121, 132
- Bristowe, Dr., cases of, *cited*, 92, 134-136
- Broadbent and Charcot, *cited*, 114
- Broca, M., *cited*, 270
- Bruce, *quoted*, 242
- Bruns, *cited*, 320-321; case of, *quoted*, 343-345
- Burrows, *cited*, 17
- Calcarine fissure, lesions of, 304, 305; bilateral, 305-306
- Carcinoma—
- Centrum ovale, in, 166-167
 - Cranium and meninges, of, 216
 - Secondary, in skull, 167
- Carotid arteries, ligature of, in congenital hydrocephalus, 80-82
- Carswell, *cited*, 108
- Cayley, case of, *quoted*, 94
- Centrum ovale—
- Carcinomatous deposit, secondary in, 166-167
 - Cystic angio-sarcoma of, 330
 - Sub-cortical sarcoma in, 359
- Cephalhydrocele, 21 *et seq.*, 33
- Cerebellum—
- Abscess in, 106-108, 131, 145; multiple, 106
 - Cholesteatoma vera of, 165
 - Cysts, simple, of right hemisphere, cases *quoted*, 169-170
 - Functions of, 245-248
 - Gumma of left hemisphere, removal of, 173
 - Sarcoma of, following injury, case *quoted*, 207
 - Spreading suppuration in, 103
 - Tumour of—
 - Cases *quoted*, 256-270
 - Diagnostic symptoms, 235 *et seq.*; diagnosis from occipital tumour with cerebellar signs, 309
 - Frontal ataxia distinguished from that of, 321
 - Operations for, 162; decompressive, 177
- Cerebellar fossa, tumour of, 197-204
- hemisphere, removal of, 248-252
 - superior peduncles, 247
 - tumour with hydrocephalus, 411-416
- Cerebello-pontine tumours, 271, 279
- Cerebral circulation, influence of atmospheric pressure on, 17-18
- hernia for inaccessible brain tumours, 176-177
 - irritation, lumbar puncture in, 39
 - meninges, fibro-plastic tumour of, 315
 - palsies, 30
 - suppuration, 90 *et seq.*
- Cerebro-spinal fluid—
- Cytological indications in meningitis, 56
 - Direction of flow of, 10, 18
 - Examination of, by lumbar puncture, 56-59
 - Origin and composition of, 18
 - Protective function of, 14-15

- Cerebroma, 163
 Cerebrum—
 Left hemisphere, functions of, 294-297
 Right and left hemispheres in developing brain, 296
 Tuberculosis of, 361-369
 Tumours of—
 Localising symptoms of, 297-303
 Surgical intervention in, 301-303
 Cestan and Lejonne, case of, *quoted*, 326-327
 Chance and Spiller, case of, *quoted*, 282
 Charcot, case of, *cited*, 120
 Charcot's motor graphic centre, 318
 Charpy, *cited*, 9
 Cheyne and Sutherland, *cited*, 79
 Chipault, *cited*, 72, 171, 218, 220, 229, 349-350
 Cholesteatoma vera, 163; of cerebellum, 165; successful case of removal of, 431-433
 Choroid plexus—
 Purulent infection of, 99
 Tubercle of, 61
 Church, *cited*, 378
 Cisterna magna, distension of anterior part, 12-14
 Claytor, *cited*, 93
 Colcutt, Dr., and Dr. Purves Stewart, case of, 424-427
 Collier, Dr. James, *cited*, 82, 300, 369
 Colman, Dr., case of, *quoted*, 261
 Colman and Ballance, 360
 Colour recognition, 304
 Coma, 55
 Conjugate deviation in cerebellar tumour, 252
 Consciousness, loss of, 254
 Constipation, 53
 Convulsions, 55
 Convulsions followed by motor agraphia, case *quoted*, 319-320
 Co-ordination, cerebellar control of, 246-248
 Corpora quadrigemina, 246
 Corpus callosum, lesions of, 356, 372
 Corpus striatum, tumours of, 298
 Cortex of cerebellum, functions of, 247
 Cortical lesions, symmetrical, 358
 Cranial bones, brain abscess from local disease of, 95 *et seq.*
 Cranial nerves, tumours involving, 274, 275, 278, 279, 280
 Cranium, tumours of, causing brain symptoms, 216-226
 Critchett, Sir Anderson, *cited*, 198
 Crus, 247
 Cruveilhier, *cited*, 108, 270, 272; cases of, *quoted*, 221-223, 230, 231
 Cunningham, Prof., *quoted*, 294-297
 Cushing, *cited*, 30; intermuscular decompressive operations of, 177
 Cutaneous sensibility, brain centres for, 337-338
 Cystic angio-sarcoma of centrum ovale, 330
 Cystic glioma of occipital lobe, 310-312
 Cystic sarcoma of right cerebellar region, 441-442
 Cystic tumour of right cerebellar hemisphere and vermis, 416-421
 Cysts of brain, 164
 Cerebellar, 273
 Malignant, 360, 404-406
 Operations for, 174
 Serous cysts of arachnoid, 25-26
 da Costa, Dr., 378
 Dana, *cited*, 253
 Dawkins, Prof. Boyd, *cited*, 295
 Dawson, Dr. Wilfrid, 310
 Deafness, 253
 Deep reflexes in subdural hematocoele, 22-25, 29; in cerebellar tumour, 238
 Deiters' nucleus, lesions of, 242-243
 Déjerine, *cited*, 122
 Delusions, 172, 358
 Dementia, 300
 Dercum and Keen, case of, *quoted*, 375-376
 Diadokokinesis in cerebellar tumour, 241
 Dimness of vision in cerebellar tumour, 236
 Dream state in temporo-sphenoidal abscess, 113, 123-125
 Dudley, Dr., case of, *quoted*, 207
 Dupré and Devaux, case of, *quoted*, 166
 Dupuytren, *quoted*, 152-153
 Dura mater, tumours of, 216-217, 219-221, 223, 397-403
 Durante, cases of, *cited*, 249-250; *quoted*, 219-220, 229
 Duret, *cited*, 207, 237, 339, 340; *quoted*, 246-248, 371-372
 Ear disease, brain symptoms with, 96, 141-142
 Embolism, brain abscess diagnosis from, 141-142
 Encephalocele, 10 *et seq.*, 36
 Enchondroma of cranial bones, 216
 Endothelioma, meningeal, 217; cerebellar, 272, 276; of frontal region, 223; of temporal lobe, 166
 Enteric fever, symptoms simulating those of meningitis in, 59

- Epileptic fits—
 Cerebral tumour, in, 300-301
 Cortical irritation, from, 322-323
 Jacksonian, 346
 Recurrent sarcoma of dura mater, following, 220
 Traumatic, 33
- Epiblastic tumours, 163
- Epithelioma, 163; of frontal region, 223-226
- Equilibrium—
 Disturbances of, in cerebellar tumour, 239-241
 Reflex arc for, 246-247
- Ethmoidal suppurative disease, operation in, 63-68
- Extra-dural suppuration, 41-42
- Falx cerebri, 16
- Ferrier, Dr., cases of, 184, 200, 237-238, 299, 411-416, 416-421
- Ferrier, Dr., and Dr. Drake, case of, 409-411
- Ferrier, Dr., and Dr. Purves Stewart, cases of, *quoted*, 193-197, 361-366
- Fibro-plastic tumours, 270
- Fibro-sarcoma—
 Cerebellar meninges, of, 221-223, 230, 271; successful operation on adult, 283-289
 Cerebellum, of, 282
 Large, of parietal lobe, 376-378
 Meninges, of, 217
- Fibroma of meninges, 217; of cerebellum, 278; of auditory nerve, cases of, 406, 411
- Fits—
 Cerebellar, 253-254
 Cerebral, 298, 300
 Diagnosis of brain tumour, in, 181
 Frontal lobe tumours, in, 318
 Occipital tumour, in, 309
 Sensori-motor aura of, in parietal lobe tumour, 346-347
- Fitzwilliams, Dr., notes of cases by, 270
- Forced movements in cerebellar tumours, 254
- Forced rotation, 243
- Fothergill, Dr. John, 3
- Fracture of skull in infants, 35-36
- Fraenkel and Hunt, case of, 279
- Fraenkel, Hunt, Woolsey, and Elsberg, case of, 280
- Frazier, Dr. Charles, *cited*, 278, 293
- Frontal bone—
 Cavernous angioma of, 218-219, 228
 Operation for brain abscess following disease of, 143-150
- Frontal bone, *continued*—
 Sarcoma of orbital part displacing dura and brain, 219, 228
- Frontal lobe—
 Abscess in, 104, 132; point of attachment to dura, 147
 Angio-sarcoma of, following punctured fracture of skull, case of, 208-210; histology of case, 211-215
 Encysted abscesses of, 104
 Glioma of, 164, 207-208
 Hydatid of, 171
 Motor areas and centres of, 316-318
 Tumours of—
 Cases *quoted*, 323-336, 355-356
 Localising symptoms of, 317-323
- Frontal region—
 Decompressive operation for tumour of, 175
 Endothelioma of meninges in, 223, 232
 Epithelioma of, 223-226, 234
- Frontal sinuses. *See* Sinuses
- Frontal sinus suppuration, treatment of, 63-68
- Fusiform lobule, lesions of, 307
- Gait—
 Cerebellar tumour, in, 240-241
 Cholesteatoma vera of cerebellum, in case of, 163
 Occipital tumour, cerebellar gait in, 309
- Garrod, Dr., case of, *quoted*, 264
- Glioma—
 Cerebellum, of, 238, 241-242
 Differentiated from sarcoma, 370-371
 Frontal lobe of, 164, 322-327; sections of, 322
 Fourth ventricle, filling, 277
 Occipito-parietal region of, 312-313
 Partial removal of, from brain, gain after, 173-174
- Glio-sarcoma, 163, 439-441; origin of, 370-371; of frontal lobe, 328
- Godlee, Mr., 33
- Goldmann, Prof., *cited*, 211
- Goodhart, Dr., case of, 164
- Gowers, Sir William, cases of, 191-193, 307, 323-324, 329-330, 404-406, 427-431
- Green, Dr. Charles, 211, 236
- Gulliver, Dr., case of, 273
- Gummata of brain, 164; spontaneous disappearance of, 186
- Gunn, Mr., 195, 311
- Guthrie, *quoted*, 180

- Hadden, Dr., case of, 183, 187
 Hæmorrhage—
 Cerebral hemisphere, tearing up, 268-269
 Diagnosed from brain abscess, 141;
 from brain tumour, 300
 Subdural, 21 *et seq.*
 Hallucinations of hearing, 172, 358
 — visual, 307
 Hamilton, M'Lane, *cited*, 125
 Hawkins, Dr., case of, 189-190
 Headache—
 Cerebellar tumour in, 236
 Cerebral tumour in, 179, 301
 Frontal lobe, tumour of, 321-322
 Intermittent, 28, 33
 Meningitis of, 53-54
 Persistent, 322, 325
 Hearn, Dr., 378
 Hematocele of subdural cavity, symptoms and cases, 21 *et seq.*
 Hemianæsthesia, 114, 343
 Hemianopsia—
 Complete, 305
 Diagnostic value of, 243, 307, 343
 Homonymous lateral, 304
 Hemiplegia, 36, 140, 343, 404
 Henschen of Stockholm, *cited*, 304-306
 Hernia cerebri, 36-38
 Hewitt, Prescott, *cited*, 27-28
 Hildesheim, Dr., *cited*, 82
 Hill, Leonard, *quoted*, 11
 Hinsberg, *cited*, 75; *quoted*, 84
 Hippocampal lobule, tumour of, 125
 Hitzig, *cited*, 321
 Holmes, Dr. Gordon, sections by, 322
 — and Dr. Grainger Stewart, *cited*, 253, 256; *quoted*, 250
 Hooper, *cited*, 108
 Horsley, Sir Victor, *cited*, 173, 200, 243, 320
 Hydatid of brain, 174-175; of spinal cord, 175
 Hydrocephalus—
 Brain abscess complicated with, 138-139
 Congenital, 80-82
 Intradural drainage for, 79-80
 Hyperacusia in temporo-sphenoidal abscess, 126-129
 Hyperæsthesia, 55
 Hyperpyrexia, 174-175
 Hysteria simulating meningitis, 55, 59-60
 Imbert, *quoted*, 14-15
 Inco-ordination, localising value of, 376
 Infection, intra-cranial—
 Pathology of, 41-51
 Process of, 95-99
 Inferior parietal lobule, lesions of, 339, 349-350
 Influenza—
 Brain abscess following, 92
 Suppuration in subdural cavity in, 49
 Injury to head—
 Abscess resulting from, 91, 105
 Tumour growth in relation to, 205-215
 Insane, the, brain tumours in, 223
 Insanity from cerebral injury, 28
 Intermuscular decompressive operations, 177
 Internal capsule:—
 Involved in tumours of parietal region, 343
 Lesion of, 356
 Pressure on: in temporo-sphenoidal abscess, 114; relief of, 175
 Internal carotid artery, aneurism of, 172
 Intra-cranial inflammation, diagnosis of, 55
 Intra-cranial tension:—
 Relief of, in inaccessible brain tumours, 175-177
 Symptoms of, alteration of, 179
 Intra-cranial tumours, symptoms leading to wrong diagnosis in, 369
 Intra-dural drainage in relief of internal hydrocephalus, 79-80
 Intra-parietal sulcus, 337
 Isthmus cerebri, protective mechanism for, 15-16
 Jackson, Dr., *cited*, 253-255
 Jackson and Beevor, case of, *cited*, 113
 Jacksonian epilepsy, 346, 404, 437
 Keen, *cited*, 79; cases of, *cited*, 328; *quoted*, 328, 379
 Kernig's sign, 55
 Key and Retzius, researches on subdural and sub-arachnoid spaces, 9-12
 Killian, *cited*, 68; Killian operation, 67
 Knecht, case of, *quoted*, 325-326
 Knee-jerk, absence of, 55
 Knowles, Miss, case of, 165
 Körner, *cited*, 106 *note*
 Korteweg, case of, 349-350
 Kummel, cases of, *cited*, 73-75, 105
 Langstaff, G., 271
 Lateral sinus, involved in cerebellar abscess, 137
 Lateral ventricle, hydatid of, 171
 Lebert, *cited*, 103, 108; cases of, 315; fibro-plastic tumour of, 164

- Lees, Dr., case of, 256
 —and Sir Thomas Barlow, *cited*, 12-14, 76
 Lemos, case of, 346-347
 Lettsom, John Coakley, reminiscences of, 1-9
 Liepmann, *quoted*, on apraxia, 340-341; case of, *quoted*, 350-356
 Lister, Mr. W. T., 200-201
 Lloyd and Gerson, case of, 281
 Luciani, *cited*, 244, 245, 251
 Lumbar puncture—
 Brain injury and apoplexy, in, 39 *et seq.*
 Diagnostic value of, 50, 53
 Examination of cerebro-spinal fluid by, 56-59
 Intra-cranial pressure, in relief of, 200-201, 204
 Meningitis, in, 46-48
 Lungs, brain abscess secondary to disease of, 93; cases *quoted*, 94-95
 Lunn, Mr., 207; case of, 283-289
 Lyon Médicale, 1904, *cited*, 93
 MacConnell, J. W., case of, 319-320
 MacHill, *cited*, 174
 Majendie, *cited*, 252
 Malignant tumour of brain, gain after partial removal, 173-174
 Manasse, *cited*, 98
 Marantic thrombosis of sinuses, diagnosed from brain abscess, 141
 Marchand, case of, 313-314
 Marie, *cited*, 115 *note*
 Masnata, case of, 248-249
 Mastoid suppuration, 47-48
 Mastoidectomy, 69-70
 Medulla, tumours of, 372
 Melancholia, 300
 Meninges—
 Adhesions of, 98
 Cerebellar, tumours of, 270, 271, 276, 281, 283-289
 Fibroma or endothelioma of, operation for, 173
 Tumours of, causing brain symptoms, 216 *et seq.*
 Meningitis—
 Acute, 42
 Brain abscess, complicating, 137-138
 Differential diagnosis, 55-60
 Diffuse, from direct infection, 96
 General suppurative, surgical intervention in, 73-76
 Non-tuberculous suppurative, 61
 Posterior basal, distension of cisterna magna with pus in, 12-14
 Meningitis, *continued*—
 Posterior basal, of infants, 60, 61; operations in relief of, 76, 83-85
 Recovery after, possibility of, 61-62
 Serosa, 45
 Suppurative, 44
 Surgical treatment of, 62-70
 Symptoms and diagnosis, 52-61
 Tuberculous, 60-61; diagnosis from brain abscess, 139; treatment of, 70-73
 Varieties of, 51-52
 Meningo-cortical abscess, 91, 92, 105
 Meningo-cortical lesion of left ascending parietal convolution, 424-427
 Menière's disease, vertigo of, 237
 Méry and Armand Delille, *cited*, 61
 Mesoblastic tumours, 163
 Meyer, R., case of, 95
 Middle cerebral peduncle, 247
 Mikulicz, case of, 225-226, 234
 Mikulicz and Braun, *cited*, 216
 v. Millingen, Dr., 274
 Mills, *cited*, 115, 302, 303, 318, 320, 321; *quoted*, 337-338; cases *quoted*, 278, 376-378
 Mind blindness, 339
 Mortillet, M. G. de, *cited*, 296
 Motor agraphia, diagnostic significance of, 318, 319-320
 Motor aphasia, 318, 320
 —centres of frontal lobe, 316-318
 Mott, *cited*, 18
 Mott, Dr., and Dr. Menzies, case of, 421-423
 Munro and Kelly, *cited*, 17
 Muscular sensibility—
 Brain centres for, 337-338
 Loss of, in parietal lobe tumour, 347-348
 Naming centre—
 Existence of, authorities *quoted* on, 121-122
 Paralysis of, 114
 Site of, cases suggesting, 115, 117, 158-159
 Nasal accessory cavities, treatment of chronic suppuration in, 63-68
 Nervous centres, symptoms of disturbances of, 179-180
 Neurofibroma, 278, 280
 New York Med. Journ., *cited*, 256
 Nonne, *cited*, 187, 189; cases of, 187-190
 Nucleus dentatus, lesions of, 242-243
 Numbers, brain centre for, 312
 Nystagmus, 237, 243; in cerebellar tumour, 252-253

- Occipital fossa—
 Bulging of, 257
 Case presenting symptoms of gross disease of, 193-197
 Tumours of, 235
- Occipital lobe—
 Cystic glioma of, 207
 Decompressive operation for glioma of, 176-177
 Localising symptoms of tumour of, 304-309
 Meningeal sarcoma of, 433-435
 Postero-external region, abscess in, 132
 Visual centres in, 304
 Tumour cases, *quoted*, 310-314
- Ocular palsy, 36, 39
- Okada, *cited*, 131
- Ophthalmoplegia, 39
- Oppenheim, Professor, *cited*, 182 *note*, 307 *note*; cases of, 431-442
- Optic neuritis—
 Cerebellar tumour, in, 238, 252
 Cerebral hematocoele, in, 23-25; cerebral tumour, in, 179, 301
 Diagnostic value of, 181-182
 Meningitis, in, 48, 61
- Optic radiation fibres, lesion of, 304, 305, 308-309
- Optic thalamus, tumours of, 177, 247, 298
- Orcein and thionin, sections stained by, 211, 212, 214
- Orientation sense—
 Cerebellar disease, in, 243
 Reflex centre for, 246, 307
- Osteoma of cranium, 216
- Otitis with palsy, 139
- Otorrhœa, purulent, associated with tuberculous meningitis, 139-140
- Pachionian bodies, 10
- Pagano's experiments, 244-245
- Paget, Sir James, *quoted*, 380
- Palæolithic drawings and right-handedness, 295, 296
- Palate, weakness of, 253
- Paracelsus, *quoted*, 62
- Paralysis—
 Arachnoid hæmorrhage, in, 29-30
 Cerebral, 28-30
 Face, of, 253
 Intermittent, 28
 Meningitis, in, 54
 Temporo-sphenoidal abscess, associated with, 114
- Parietal lobe:—
 Anatomical points, 337-338
 Tumours of, symptoms of, 338-343; cases *quoted*, 343-360; large tumours, 375-378
- Parkin operation in posterior basal meningitis, 76
- Peritonitis, suppurative, 51; tuberculous, 71
- Perivascular canalicular system, 18-19
- Pia mater—
 Inflammation of, 49
 Sarcomatous nodules in, 209, 211-212
 Suppuration of, 43
- Piorry, *quoted*, 120 *note*
- Pitres, *quoted*, 121
- Pitt, Newton, *cited*, 96
- Pituitary body, tumours of, 298
- Pneumonia simulating meningitis, 59
- Polimanti, *cited*, 318 *note*
- Politzer, Prof., 274
- Pons, 247; tumours of, 372
- Pontine nucleus, 246
- Post-parietal gyrus, tumour involving, 339
- Preindlsberger, case of, 219, 228
- Preysing, *cited*, 98; case of, *quoted*, 118
- Psammoma, 164
- Psychic functions, centre for, 318, 320
 — symptoms of meningitis, 55
- Pyæmia complicating brain abscess, 137
- Pyæmic abscess of brain, 92
- Pye-Smith, Dr., *cited*, 200; case of, *quoted*, 94-95
- Quincke, *cited*, 43
- Raymond, Professor, case of, *quoted*, 345-346
- Red nucleus, 246-247
- Reflexes, exaggeration of, 55
- Right-handedness, antiquity of, 294-297
- Rolando, fissure of, 316, 320; localising tumour symptoms in area of, 366
- Romberg's sign in cerebellar tumour, 240; in occipital tumour, 309
- Roncali, *cited*, 105, 219, 229, 250; *quoted*, 245-247; case of, *quoted*, 126-129
- Röntgen rays, brain tumour localised by, 378
- Ross and Bastian, *cited*, 115
- Rotation, in lesions—of lateral lobe, 244, 253;—of vermis, 245, 253
- Russell, Dr. Risien, *cited*, 241, 252, 253; case of, 310-312
- Salzer, case of, *cited*, 98
- Sänger, *cited*, 187, 212
- Sarcoma—
 Brain, secondary, 168; gain after partial removal of, 173-174
 Cerebellar meninges, of, 281
 Cranial bone, of, 216

Sarcoma, *continued*—

- Cystic, of right cerebellar region, 441-442
- Differentiated from glioma, 370-371
- Dura mater, of, 216-217, 219-221
- Frontal lobe, perforating dura and skull, 331-336; frontal meninges, 326-327
- Large-sized, in fronto-parietal region, 373-374; in cerebral meninges, 374-375; with absence of striking localising symptoms, 375-376
- Meningeal, of left occipital lobe, 433-435
- of left ascending parietal convolution, 435-436
- Sawicki, *cited*, 218
- Scalp—
 - Carcinoma of, 216
 - Concavity of, showing complete recovery, 264, 289, 290
 - Convexity of, showing persistence of abnormal conditions, 196, 204, 289, 329
 - Flap, method of making, 360
- Scurvy causing hæmorrhage, 269
- Sensation—
 - Cerebellar tumour, in, 237
 - Loss of, from cortical lesion, 345-346; from parietal lesion, 348
- Sensory cortical symptoms in parietal lobe tumour, case *quoted*, 343-345
- Serous cysts of arachnoid, 25-26
- Singer, Dr., notes of case by, 191-193
- Sinuses—
 - Accessory, relation to base of skull, 64
 - Frontal, suppuration of, 68; relation to frontal lobe, 64
- Sixth nerve paralysis, 253
- Sharkey, case of, 275, 276
- Shattock, Mr., *cited*, 69, 271
- Sherrington, Prof., 177
- Shipman, Dr., case of, 208-210; histology of, 211-215
- Skew deviation in cerebellar tumour, 252
- Skull, fractured, with laceration of brain, 289-292
- Smell, sense of, cortical localisation of, 123-129
- Smith, Sir Thomas, *cited*, 35
- Souques, case of, 312-313
- Spasticity of limbs, 250
- Specific fevers, brain abscess complicating, 91-93
- Speech, motor centre for, 318
- Spiller, V., case of, 348-349
- Squama, periosteal sarcoma of, 217-218, 227

- Starr, *cited*, 92; *quoted*, 379
- Starr and M^cCosh, case of, *quoted*, 347-348
- Stereognostic perception—
 - Brain centre for, 337-338, 427
 - Impairment of, in parietal lobe tumour, 347-349
- Stewart, Dr. Grainger, *cited*, 321
- Dr. Purves, *cited*, 56 n., 190, 200
- — and Dr. Ferrier, case of, 361-366
- Stoll, *cited*, 93
- Sub-arachnoid space—
 - Anatomical characters, 9-10
 - Capacity of, 11-12
 - Drainage of, in tuberculous and suppurative meningitis, 72, 73-75
 - Interchange of fluid between venous system and, 10
 - Protective function of, 15-16
 - Tuberculous disease in, 72
- Subdural cavity—
 - Anatomical characters, 9-10
 - Capacity of, 11
 - Hematocele of, symptoms and cases, 21 *et seq.*
- Subdural hæmorrhage in the new born, 30-31
- Superior parietal lobule, lesions of, 355-356
- Swain, case of, *cited*, 99
- Swallowing, difficulty in, 253
- Sylvian lake, 72
- Syme, Mr., *cited*, 35
- Syphilitic tumour of brain—
 - Removal of, 173
 - Spontaneous recovery of, 186
- Tache cérébrale, 55
- Taylor, Dr. James, cases of, 135, 190-191, 299
- Tegmen tympani, 42, 47, 99
- Temperature in subdural hæmorrhage, 29
- Temporal bone, abscess secondary to disease of, 107, 143-150; operation in suppuration of, 63-68
- Temporal lobe, tumours involving, 166, 243
- Temporo-sphenoidal lobe—
 - Abscess of—
 - Aural origin, of, 106-108
 - Drainage of, 101
 - Latency of symptoms in, 132
 - Localisation symptoms, 112-113; cases illustrating, 123-129
 - Multiple, 105-106
 - Point of attachment to dura, 145.
 - Centres in, 122

- Temporo-occipital lobe, topographical memory centre in, 306
- Tenderness on pressure or percussion, 237, 238, 298
- Tentorium cerebelli, 16, 17
- Third nerve paralysis, 114
- Thomson, Dr., case of, 397-403
- Thrombosis diagnosis from brain abscess, 141
- Tinnitus, 253, 254
- Titubation, 243, 251-252
- Tollemere, Louis, *cited*, 237; *quoted*, 246
- Tongue, deviation of, 253
- Tonic spasms, 254
- Topographical memory centre, 306-307
- Touche of Brevannes, *cited*, 306-307
- Toxins, absorption of, simulating meningitis, 55
- Trigeminal neuralgia and anæsthesia, 253
- Trousseau, *cited*, 119
- Tubercle of the choroid, 61
- Tuberculous abscess of brain, 92, 436-439
- Tuberculous tumours of brain—
Cerebellum, in, 271-273
Cerebrum, in, 361-369
Meninges, of, 217
Removal of, 173
Spontaneous disappearance of, 186, 191
- Tumour of Brain—
Clinical evolution of, 182-184
Cranial nerves, involving, 279, 280
Exploratory operations in, Frazier on, 293
Inaccessible, decompressive operations for, 175-177
Injury in relation to, 205-215
Insane persons, in, 223
Large size, of, 370-372; cases *quoted*, 373-378
Localisation of, 180-182
Malignancy of, 323
Morbid anatomy of, 163
Operations for, 173-177
Advisability of operation in two stages, 311-312
Prognosis in, 162-163
Results discussed, 162
Röntgen rays, localised by, 378
- Tumour of Brain, *continued*—
Scope of term, 163
Spontaneous disappearance of symptoms, 186-204
Symptoms and diagnosis, 178-182
General and localising, 180-182, 186
Latency of symptoms, 182-184
Syndrome symptoms without tumour, 186-187; cases *quoted*, 187-204
- Tumour of vermis extending into cerebellar hemispheres, 411-416
- Tunica vaginalis, 21
- Turner, Dr. Aldren, cases of, 366, 406-409
- Turtle, sub-arachnoid space in the, 20
- Tympanum, 42
- Unsteadiness of movement in cerebellar tumour, 236
"Urine caster," 5
- Urine, incontinence of, in frontal lobe tumours, 327, 331
- Vascular tumours, 164
- Vegas, Herrera, *quoted*, 171; *cited*, 174
- Vertigo, 236-237, 243, 254
- Vestibular nerve, lesions of, 243
- Visual centres, cortical localisation of, 304-307
- Voisin, *cited*, 120; case of, *quoted*, 120
- Vomiting, 28, 29, 53, 179, 236
- Watson, Sir Thomas, *cited*, 17
- Weisenburg, *cited*, 278
- Wernicke hemianopic pupillary reaction, diagnostic value of, 308-309
- White matter, resistance to bacterial action, 97
- Whytt, Robert, *cited*, 61
- Willis, Thomas, *quoted*, 44
- Wilson, Sir Daniel, *quoted*, 295
- Winslow, *cited*, 120
- Word blindness, 305
- Word deafness, 358
- Wyllie, *cited*, 115 *note*
- Zajaczkowski of Poland, case of, *quoted*, 218-219, 228
- Ziegler, *cited*, 163 *note*

THE END

Printed by R. & R. CLARK, LIMITED, Edinburgh.

18

MN
B

404741

Ballance, (Sir) Charles Alfred
Some points in the surgery of the brain.
[Ed.2]

University of Toronto
Library

DO NOT
REMOVE
THE
CARD
FROM
THIS
POCKET



