

An anatomical illustration of the human head and neck skeleton. The skull is shown in profile, with the jaw open, revealing the teeth. The cervical vertebrae of the neck are clearly visible, along with the ribs and the upper part of the thoracic cage. The illustration is rendered in a semi-transparent style, showing the underlying bone structure. The title 'HUMAN BODY I' is overlaid on the upper part of the skull.

# HUMAN BODY I

Britannica Illustrated Science Library



## **About the pagination of this eBook**

Due to the unique page numbering scheme of this book, the electronic pagination of the eBook does not match the pagination of the printed version. To navigate the text, please use the electronic Table of Contents that appears alongside the eBook or the Search function.

For citation purposes, use the page numbers that appear in the text.

# HUMAN BODY I



**Britannica Illustrated Science Library**

Encyclopædia Britannica, Inc.

Chicago ■ London ■ New Delhi ■ Paris ■ Seoul ■ Sydney ■ Taipei ■ Tokyo

# Britannica Illustrated Science Library

© 2008 Editorial Sol 90

All rights reserved.

**Idea and Concept of This Work:** Editorial Sol 90

**Project Management:** Fabián Cassan

**Photo Credits:** Corbis, ESA, Getty Images, Graphic News, NASA, National Geographic, Science Photo Library

**Illustrators:** Guido Arroyo, Pablo Aschei, Carlos Francisco Bulzomi, Gustavo J. Caironi, Hernán Cañellas, Leonardo César, José Luis Corsetti, Vanina Farías, Manrique Fernández Buente, Joana Garrido, Celina Hilbert, Inkspot, Jorge Ivanovich, Iván Longuini, Isidro López, Diego Martín, Jorge Martínez, Marco Menco, Marcelo Morán, Ala de Mosca, Diego Mourellos, Laura Mourellos, Pablo Palastro, Eduardo Pérez, Javier Pérez, Ariel Pirovansky, Fernando Ramallo, Ariel Roldán, Marcel Socias, Néstor Taylor, Trebol Animation, Juan Venegas, Constanza Vicco, Coralia Vignau, Gustavo Yamin, 3DN, 3DOM studio

**Composition and Pre-press Services:** Editorial Sol 90

**Translation Services and Index:** Publication Services, Inc.

**Portions © 2008 Encyclopædia Britannica, Inc.**

Encyclopædia Britannica, Britannica, and the thistle logo are registered trademarks of Encyclopædia Britannica, Inc.

## Britannica Illustrated Science Library Staff

### Editorial

Michael Levy, *Executive Editor, Core Editorial*

John Rafferty, *Associate Editor, Earth Sciences*

William L. Hosch, *Associate Editor, Mathematics and Computers*

Kara Rogers, *Associate Editor, Life Sciences*

Rob Curley, *Senior Editor, Science and Technology*

David Hayes, *Special Projects Editor*

### Art and Composition

Steven N. Kapusta, *Director*

Carol A. Gaines, *Composition Supervisor*

Christine McCabe, *Senior Illustrator*

### Media Acquisition

Kathy Nakamura, *Manager*

### Copy Department

Sylvia Wallace, *Director*

Julian Ronning, *Supervisor*

### Information Management and Retrieval

Sheila Vasich, *Information Architect*

### Production Control

Marilyn L. Barton

### Manufacturing

Kim Gerber, *Director*

## Encyclopædia Britannica, Inc.

Jacob E. Safra, *Chairman of the Board*

Jorge Aguilar-Cauz, *President*

Michael Ross, *Senior Vice President, Corporate Development*

Dale H. Hoiberg, *Senior Vice President and Editor*

Marsha Mackenzie, *Director of Production*

International Standard Book Number (set):

978-1-59339-797-5

International Standard Book Number (volume):

978-1-59339-809-5

Britannica Illustrated Science Library: Human Body I 2008

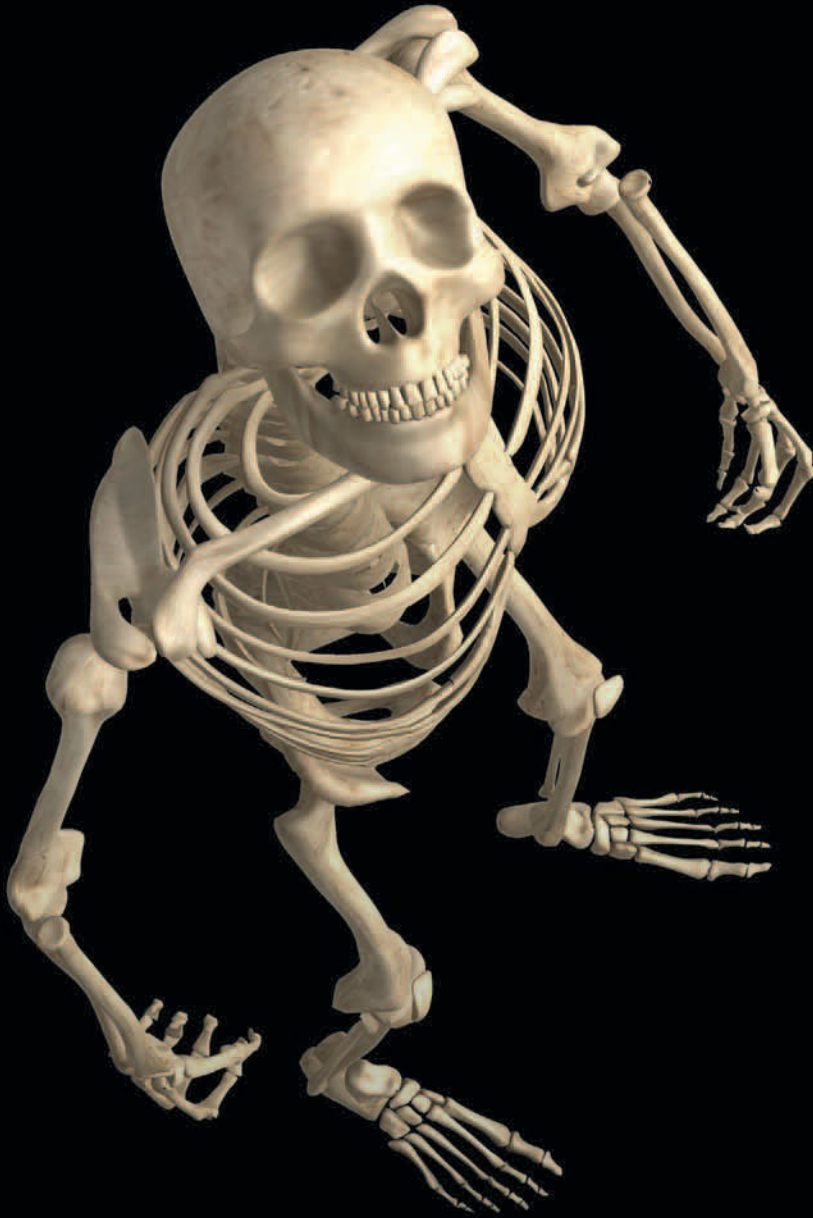Printed in China



www.britannica.com



# Human Body I

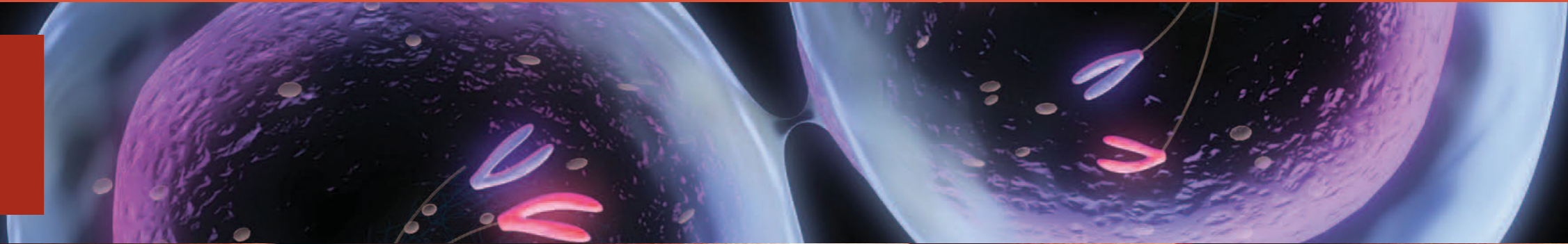




# Contents

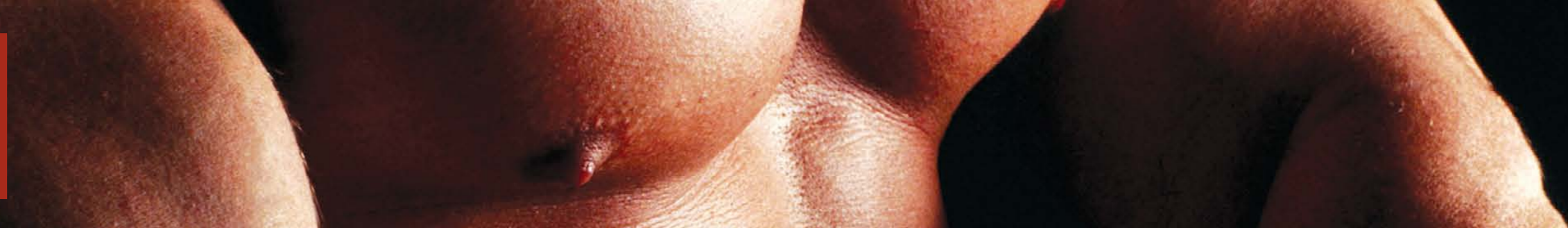## What Are We Made Of?

Page 6



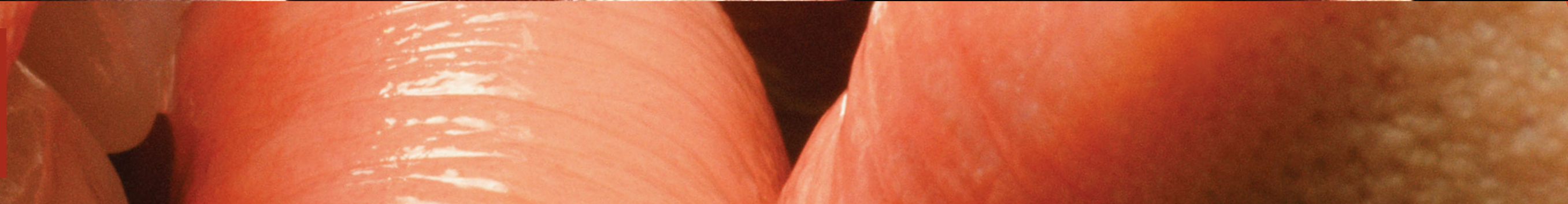## Bones and Muscles

Page 18



## Internal Systems and Organs

Page 34



## The Senses and Speech

Page 68



## Control Centers

Page 80





#### A LIVING STRUCTURE

The skeleton consists of 206 separate bones, which differ in form, size, and name. It supports and shapes the body, protects the internal organs, and—in the bone marrow of certain bones—manufactures various types of blood cells.

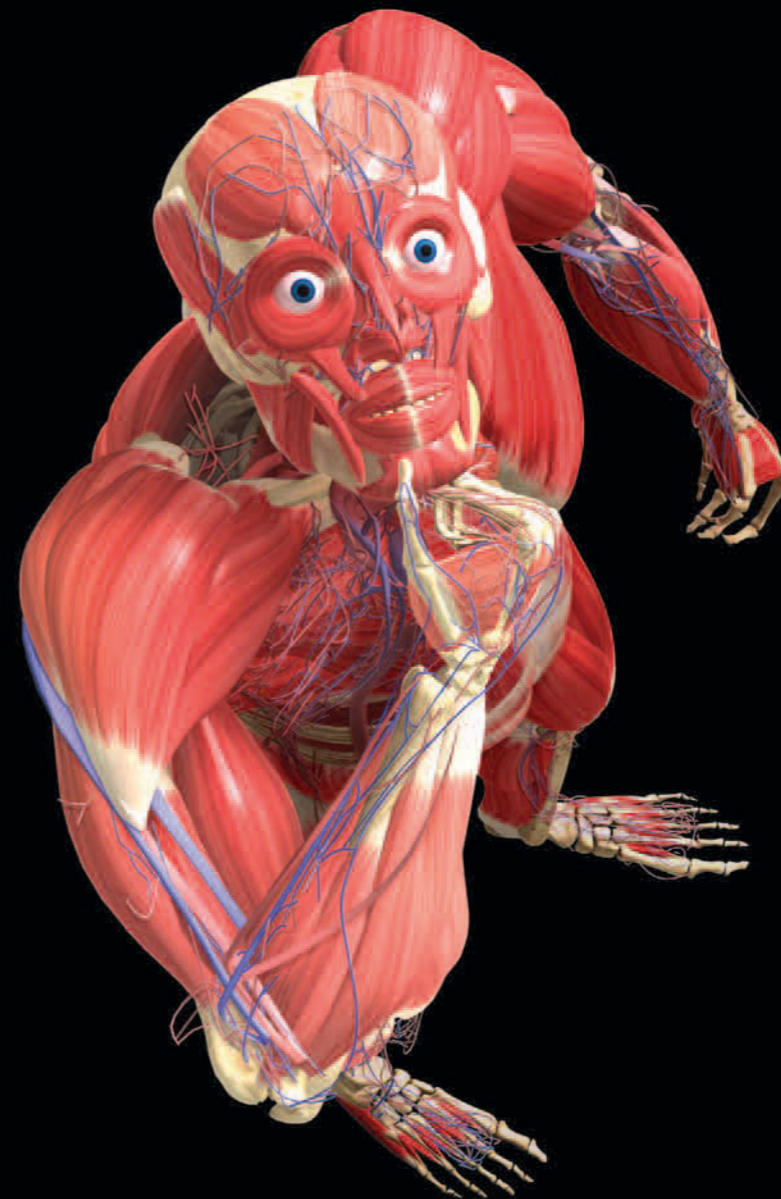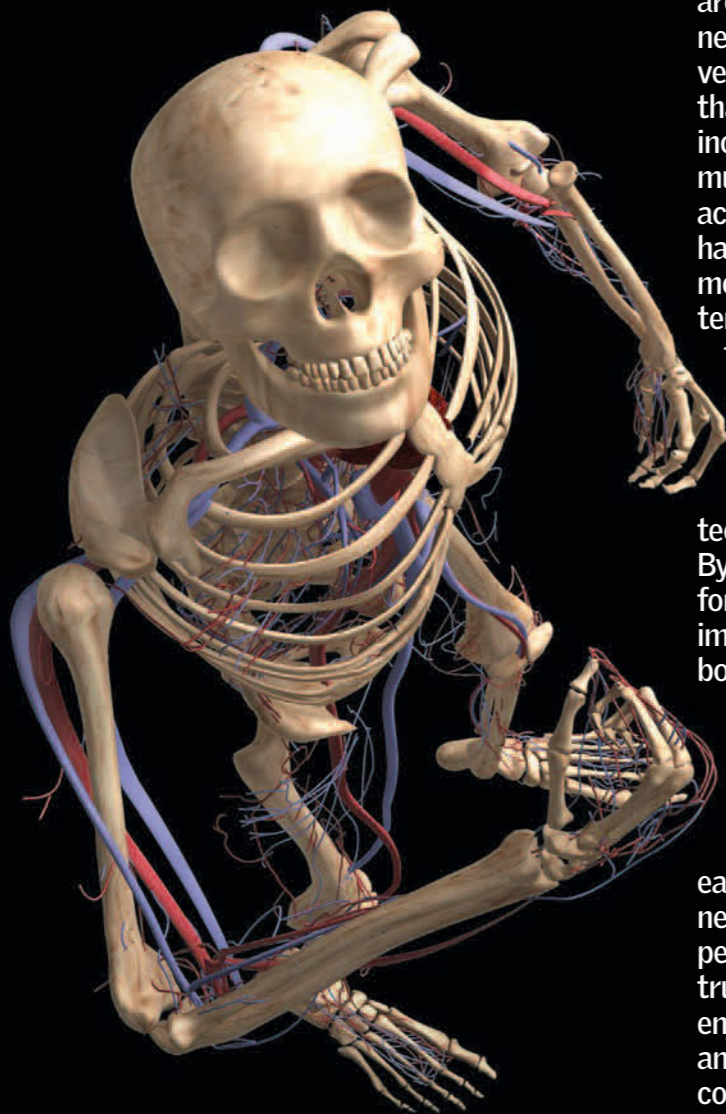
## A Perfect Machine

How can we understand what we are? What are we made of? Are we aware that all that we do—including reading this book—is the work of a marvelous machine? We know very little about how we are able to be conscious of our own actions; nevertheless, even though we are usually not very aware of it, this community of organs that is the body—an integrated system that includes the brain, heart, lungs, liver, kidneys, muscles, bones, skin, and endocrine glands—acts together in exquisitely regulated harmony. It is interesting that various mechanisms work together to keep the temperature of the body at 98.6° F (37° C); thanks to the dynamic structure of bones and cartilage, the body is maintained in perfect balance. The body also has a fantastic ability to transform the food it ingests into living tissues, bones, and teeth, all of which contribute to its growth. By this same process, we obtain the energy for working and playing. It is hard to imagine that not long ago the cells of the body of the person reading this book were autonomous and were duplicating themselves freely within the walls of a mother's uterus. Certainly no one reading this book could recognize herself or himself in those cells. Nevertheless, each cell carried within it the information necessary for the development of that person. Everything that happens inside us is truly fascinating. Therefore, we invite you to enjoy this book. It is full of incredible facts and illustrations that will show you the complex ways each part of the body works.

What are cells like, and how do they form tissue? What is blood, and why are proteins so important? The heart, usually thought of as the wellspring of love and the emotions, is actually the engine of the circulatory system. It is because of the heart that all the cells of the body receive a constant supply of nutrients, oxygen, and other essential substances. The heart is so powerful that it pumps about 10 pints (4.7 l) of blood per minute. The nervous system is the most intricate of all the body's systems. It works

every second of every day, gathering information about the organism and its surroundings and issuing instructions so that the organism can react. It is this computer that permits us to think and remember and that makes us who we are.

The nervous system is a complex network of sensory cells, originating in the brain and spinal cord, that transmits signals throughout the body, employing a caravan of chemical messengers to make sense of this marvelous complex that we catalogue as touch, taste, smell, hearing, and vision. In fact, at this precise moment, because of an extraordinary relationship between our eyes and our brain, we are able to see and understand what we are reading. Modern cameras are designed on the same basic principles as our eye, but they have never been able to equal the visual power of the eye. The focus and the automatic aperture of the human eye are perfect. Our ears share a similar complexity and allow us to have excellent hearing. The external ear operates by receiving sound waves in the air. Sound waves travel through the auditory canal and are transmitted by the bones of the intermediate ear toward the cochlea, which contains liquid and is spiraled like the shell of a small sea snail. The cochlea converts waves of air into vibrations of liquid, which are detected by special filaments in the ear that are of many lengths and that detect sound waves of different lengths. These filaments then transmit nerve impulses to the brain and provide us with our ability to interpret what we hear. This book will also tell you about the function of our skin, the largest organ of the body, which serves as an elastic barrier covering and protecting everything inside our bodies. Captivating images will show you how each of our extraordinary body systems function, and incredible facts will help you understand why the human body is so amazing. ●





# What Are We Made Of?

## MITOSIS

An enlarged view that shows the process of mitosis, the most common form of cellular division

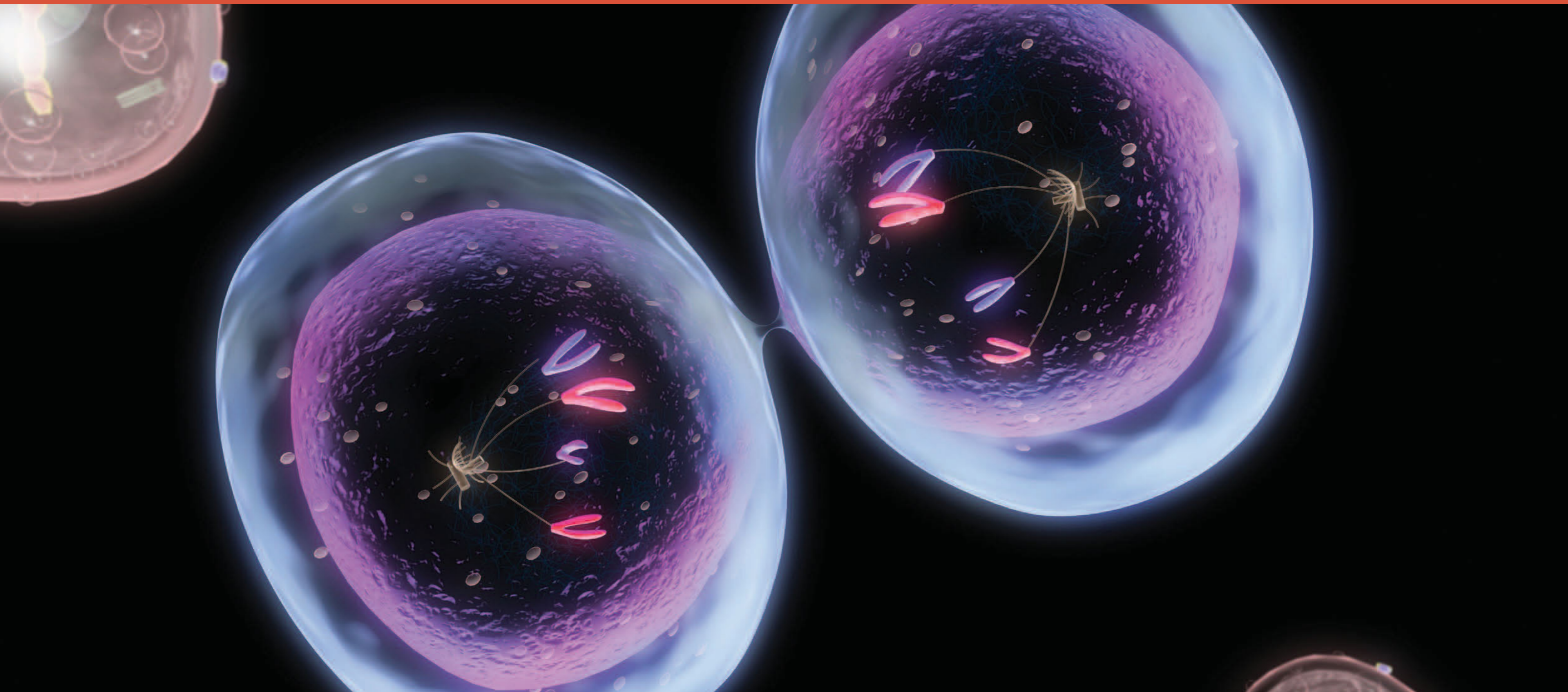
## UNDIVIDED ATTENTION 8-9

## WATER AND LIQUIDS 10-11

## THE CELL 12-13

## MITOSIS 14-15

## SYSTEMS OF THE BODY 16-17



To understand the truest and most elementary characteristics of life, we must begin with the cell—the tiny organizing structure of life in all its forms.

Most cells are too small to be observed with the naked eye, but they can be distinguished easily through an ordinary microscope. Human body tissues are groups of cells whose size

and shape depend on the specific tissue to which they belong. Did you know that an embryo is a mass of rapidly dividing cells that continue to develop during infancy? We invite you

to turn the page and discover many surprising things in this fascinating and complex world. ●



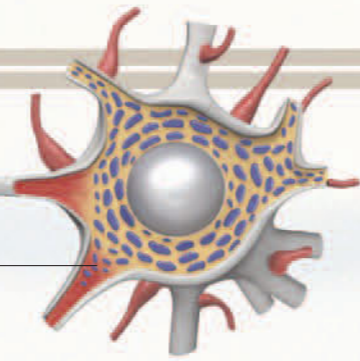
## Neurons

Each neuron in the brain can be connected with several thousand other neurons and is capable of receiving 100,000 signals per second. The signals travel through the nervous

system at a speed of 225 miles per hour (360 km/h). Thanks to this complex communication network, the brain is capable of remembering, calculating, deciding, and thinking.

### DENDRITES

They are the branches through which a neuron receives and sends messages. With this system each neuron can be stimulated by thousands of other neurons, which in turn can stimulate other neurons, and so forth.



## Undivided Attention

From birth the infant's brain cells develop rapidly, making connections that can shape all of life's experiences. The first three years are crucial. When neurons receive visual, auditory, or gustatory stimuli, they send messages that generate new physical connections with neighboring cells. The signals are sent through a gap called a synapse by means of a complex electrochemical process. What determines the formation of a person's synapses and neural networks? One key factor is believed to be the undivided attention and mental effort exerted by the person.

## Learning

Each child has his or her own intellectual filter; the quality of the filter depends on undivided attention and on how the child responds to a broad variety of stimuli.

225 miles  
per hour  
(360 km/h)

THE VELOCITY OF THE NERVOUS  
SYSTEM'S SIGNALS

## Brain

At birth the infant brain contains 100 billion neurons. That is about as many nerve cells as there are stars in the entire Milky Way Galaxy! Then as the infant receives messages from the senses, the cerebral cortex begins its dynamic development.

3 pounds  
(1.4 kg)

IS THE WEIGHT OF  
A HUMAN BRAIN.

## Respiration

Respiration is usually an involuntary, automatic action that allows us to take in the oxygen we need from the air and exhale carbon dioxide. These gases are exchanged in the pulmonary alveoli.

### A WORLD OF SENSATIONS

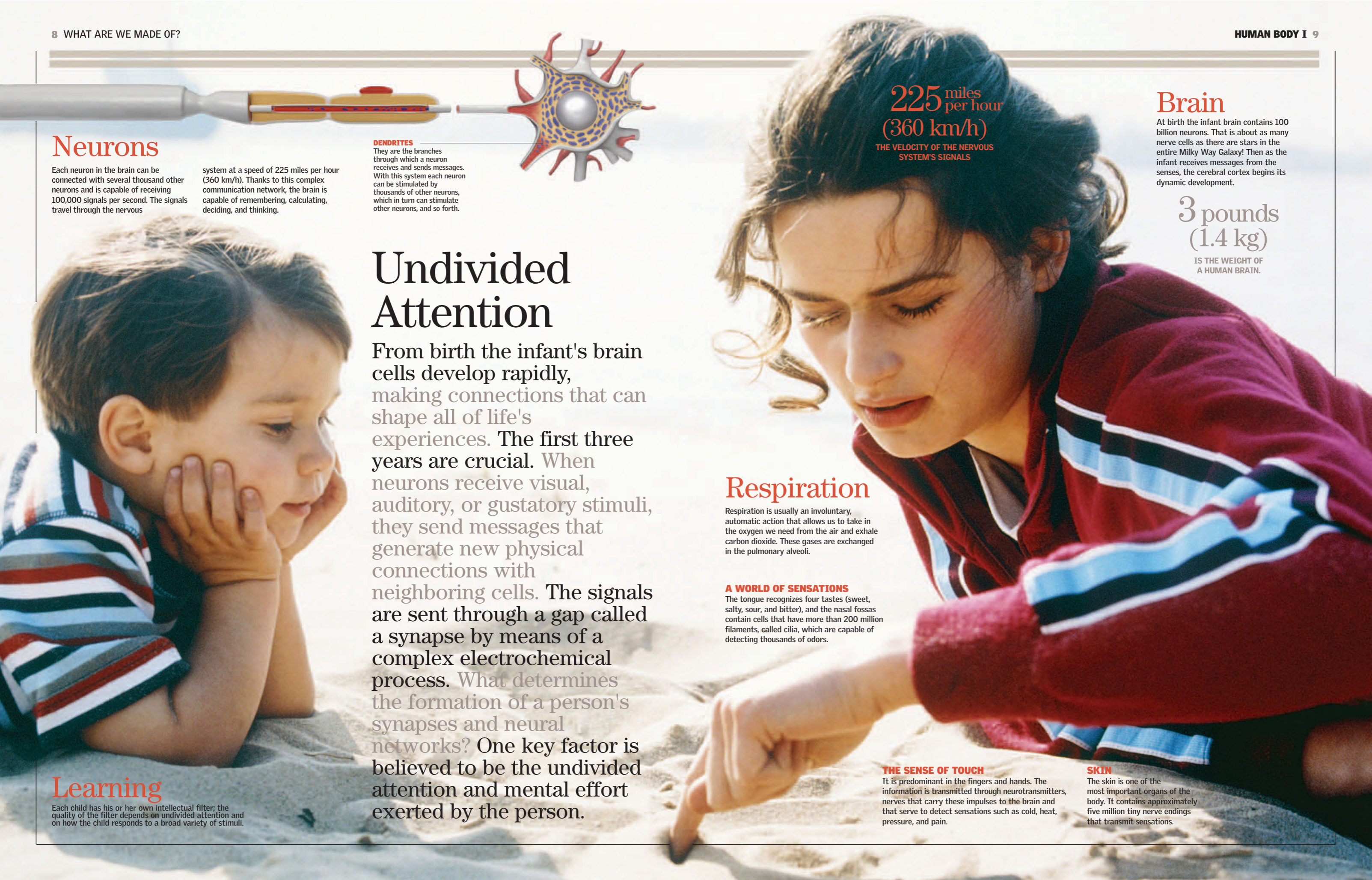The tongue recognizes four tastes (sweet, salty, sour, and bitter), and the nasal fossas contain cells that have more than 200 million filaments, called cilia, which are capable of detecting thousands of odors.

### THE SENSE OF TOUCH

It is predominant in the fingers and hands. The information is transmitted through neurotransmitters, nerves that carry these impulses to the brain and that serve to detect sensations such as cold, heat, pressure, and pain.

### SKIN

The skin is one of the most important organs of the body. It contains approximately five million tiny nerve endings that transmit sensations.





# Water and Fluids

Water is of such great importance that it makes up almost two thirds of the human body by weight. Water is present in all the tissues of the body. It plays a fundamental role in digestion and absorption and in the elimination of indigestible metabolic waste. Water also serves as the basis of the circulatory system, which uses blood to distribute nutrients to the entire body. Moreover, water helps maintain body temperature by expelling excess heat through the skin via perspiration and evaporation. Perspiration and evaporation of water account for most of the weight a person loses while exercising. ●

## Water Balance and Food

In its continuous process of taking in and eliminating water, one of the most important functions of the body is to maintain a continuous equilibrium between the water that enters and the water that leaves the body. Because the body does not have an organ or other place for storing water, quantities that are lost must be continuously replenished. The human body can survive for several weeks without taking in food, but going without water for the same length of time would have tragic consequences. The human being takes in about 2.5 to 3 quarts (2.5-3 l) of water per day. About half is taken in by drinking, and the rest comes from eating solid food. Some foods, such as fruits and vegetables, consist of 95 percent water. Eggs are 90 percent water, and red meat and fish are 60 to 70 percent water.

# 60%

THE PERCENTAGE OF A PERSON'S WEIGHT THAT IS DUE TO WATER. IN GENERAL, A 10 PERCENT LOSS OF WATER LEADS TO SERIOUS DISORDERS, AND A LOSS OF 20 PERCENT RESULTS IN DEATH.

### HOW THIRST IS CONTROLLED

Thirst is the sensation through which the nervous system informs its major organ, the brain, that the body needs water. The control center is the hypothalamus. If the concentration of plasma in the blood increases, it means the body is losing water. Dry mouth and a lack of saliva are also indications that the body needs water.

### HOW WATER IS ABSORBED

Water for the body is obtained primarily by drinking and ingesting food and through internal chemical reactions.



**50%** of the water comes from ingesting fluids.

**35%** of the water is obtained from food.

**15%** comes from metabolic activities.

### HOW WATER IS ELIMINATED

Water is expelled not only with urine but also with sweat, through the elimination of feces, and through evaporation from the lungs and skin.

**60%** is eliminated with urine.

**18%** is eliminated by sweating and through evaporation from the skin.

**14%** is eliminated during exhalation by the lungs.

**8%** is eliminated in excrement.

## Chemical Elements

The body contains many chemical elements. The most common are oxygen, hydrogen, carbon, and nitrogen, which are found mainly in proteins. Nine chemical elements are present in moderate amounts, and the rest (such as zinc) are present only in very small amounts, so they are called trace elements.



**MAGNESIUM 0.05%**  
Lungs, kidneys, liver, thyroid, brain, muscles, heart



**SODIUM 0.15%**  
Fluids and tissues, in the form of salt



**POTASSIUM 0.3%**  
Nerves and muscles; inside the cell



**SULFUR 0.3%**  
Contained in numerous proteins, especially in the contractile proteins



**CALCIUM 1.5%**  
Bones, lungs, kidneys, liver, thyroid, brain, muscles, heart



**CHLORINE 0.2%**  
maintains the equilibrium of water in the blood.



**PHOSPHORUS 1%**  
Urine, bones



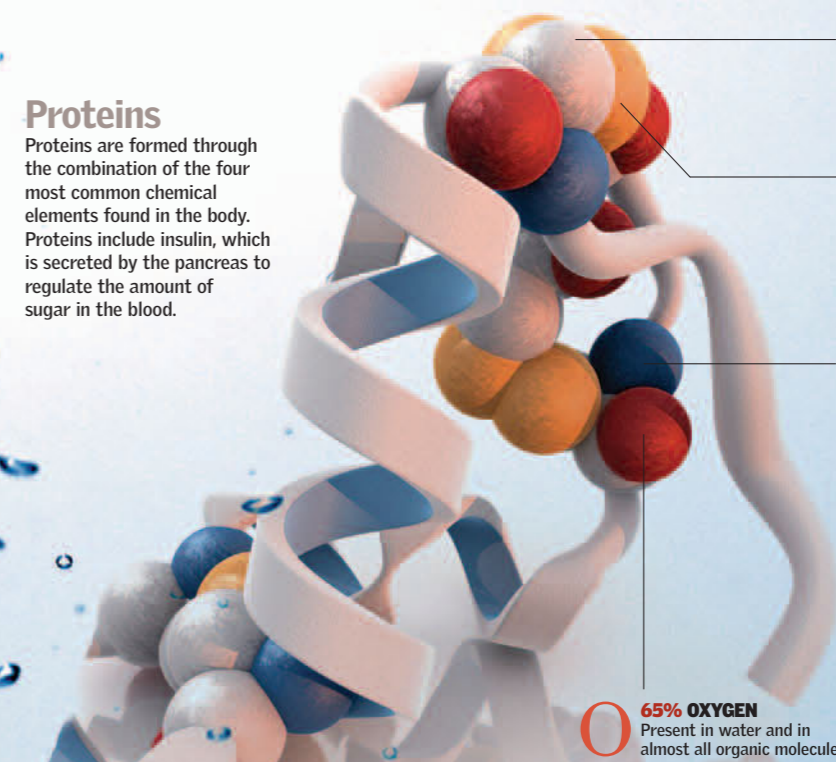
**0.004% IRON**  
Fluids and tissues, bones, proteins. An iron deficiency causes anemia, whose symptoms include fatigue and paleness. Iron is essential for the formation of hemoglobin in the blood.



**0.0004% IODINE**  
Urine, bones. When consumed, iodine passes into the blood and from there into the thyroid gland. Among its other functions, iodine is used by the thyroid to produce growth hormones for most of the organs and for brain development.

## Proteins

Proteins are formed through the combination of the four most common chemical elements found in the body. Proteins include insulin, which is secreted by the pancreas to regulate the amount of sugar in the blood.



**C 18% CARBON**  
Present in all organic molecules

**H 10% HYDROGEN**  
Present in water, nutrients, and organic molecules

**N 3% NITROGEN**  
Present in proteins and nucleic acids

**O 65% OXYGEN**  
Present in water and in almost all organic molecules



# The Cell

It is the smallest unit of the human body—and of all living organisms—able to function autonomously. It is so small that it can be seen only with a microscope. Its essential parts are the nucleus and cytoplasm, which are surrounded by a membrane. Each cell reproduces independently through a process called mitosis. The animal kingdom does have single-celled organisms, but in a body such as that of a human being millions of cells are organized into tissues and organs. The word "cell" comes from Latin; it is the diminutive of *cella*, which means "hollow." The science of studying cells is called cytology. ●

## Cell Theory

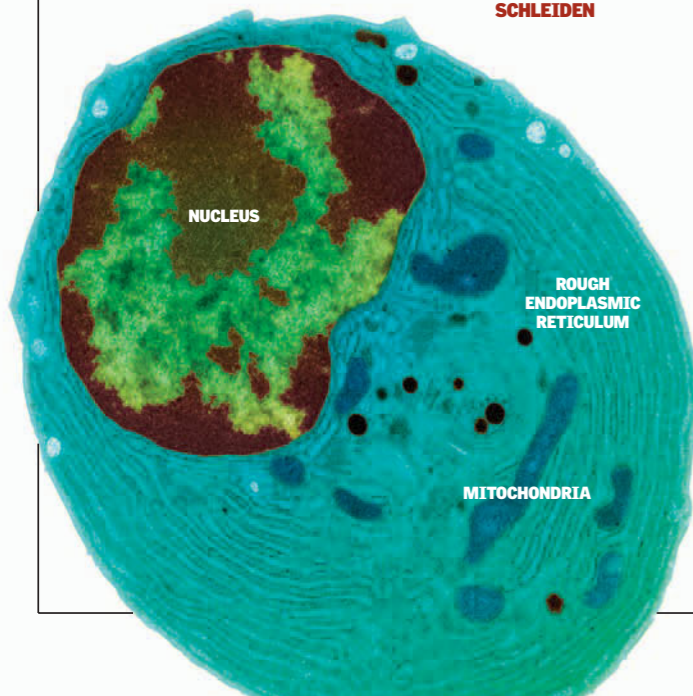
Before the invention of the microscope, it was impossible to see cells. Some biological theories were therefore based on logical speculations rather than on observation. People believed in "spontaneous generation" because it was inconceivable that cells would regenerate. The development of the microscope, including that of an electronic version in the 20th century, made detailed observation of the internal structure of the cell possible. Robert Hooke was the first to see dead cells in 1665. In 1838 Mathias Schleiden observed living cells, and in 1839, in collaboration with Theodor Schwann, he developed the first theory of cells: that all living organisms consist of cells.



**THEODOR SCHWANN**

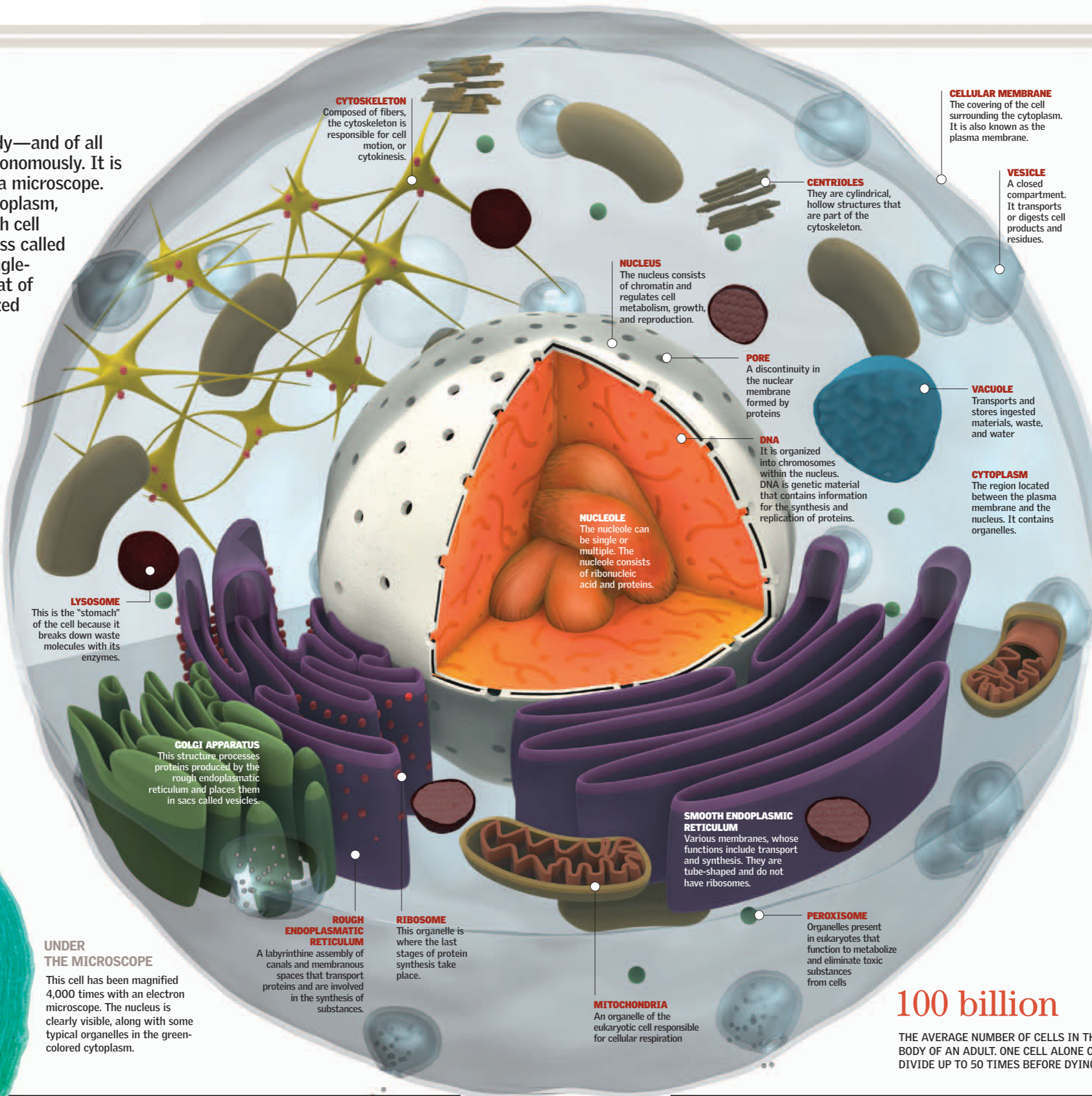


**MATHIAS SCHLEIDEN**



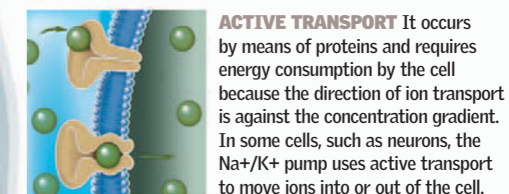
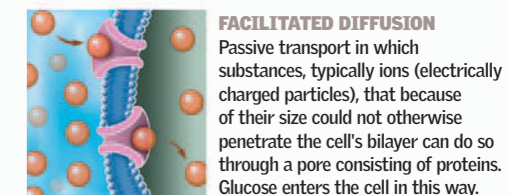
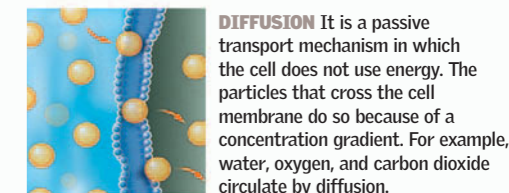
### UNDER THE MICROSCOPE

This cell has been magnified 4,000 times with an electron microscope. The nucleus is clearly visible, along with some typical organelles in the green-colored cytoplasm.



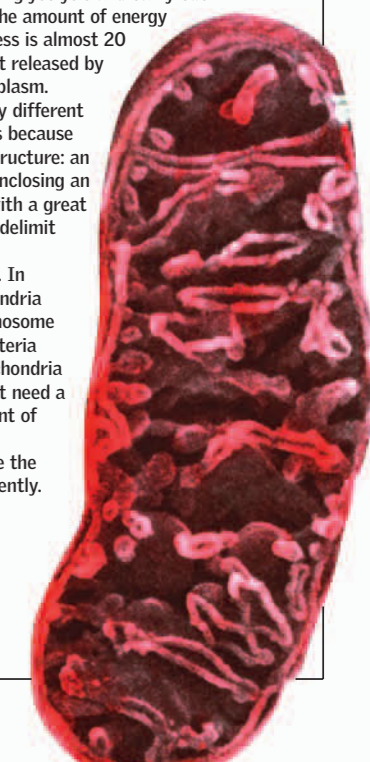
## TRANSPORT MECHANISMS

The cell membrane is a semipermeable barrier. The cell exchanges nutrients and waste between its cytoplasm and the extracellular medium via passive and active transport mechanisms.



## Mitochondria

The mitochondria provide large amounts of energy to the cell. They contain a variety of enzymes that, together with oxygen, degrade products derived from glycolysis and carry out cellular respiration. The amount of energy obtained in this process is almost 20 times as great as that released by glycolysis in the cytoplasm. Mitochondria are very different from other organelles because they have a unique structure: an external membrane enclosing an internal membrane with a great number of folds that delimit the internal area, or mitochondrial matrix. In addition, the mitochondria have a circular chromosome similar to that of bacteria that allows the mitochondria to replicate. Cells that need a relatively large amount of energy have many mitochondria because the cells reproduce frequently.




**100 billion**

THE AVERAGE NUMBER OF CELLS IN THE BODY OF AN ADULT. ONE CELL ALONE CAN DIVIDE UP TO 50 TIMES BEFORE DYING.

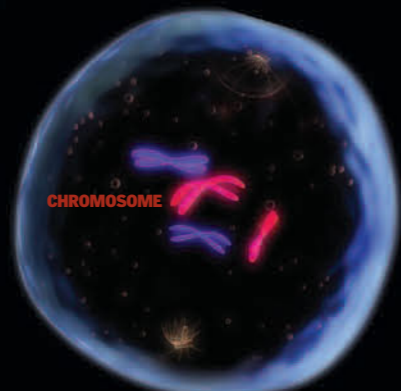

# Mitosis

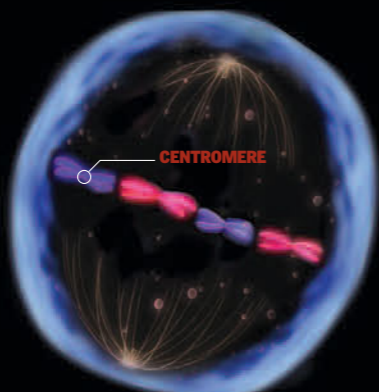
It is the cell-division process that results in the formation of cells that are genetically identical to the original (or mother) cell and to each other. The copies arise through replication and division of the chromosomes, or genetic material, in such a way that each of the daughter cells receives a similar inheritance of chromosomes. Mitosis is characteristic of eukaryotic cells. It ensures that the genetic information of the species and the individual is conserved. It also permits the multiplication of cells, which is necessary for the development, growth, and regeneration of the organism. The word "mitosis" comes from the Greek *mitos*, which means "thread," or "weave." ●



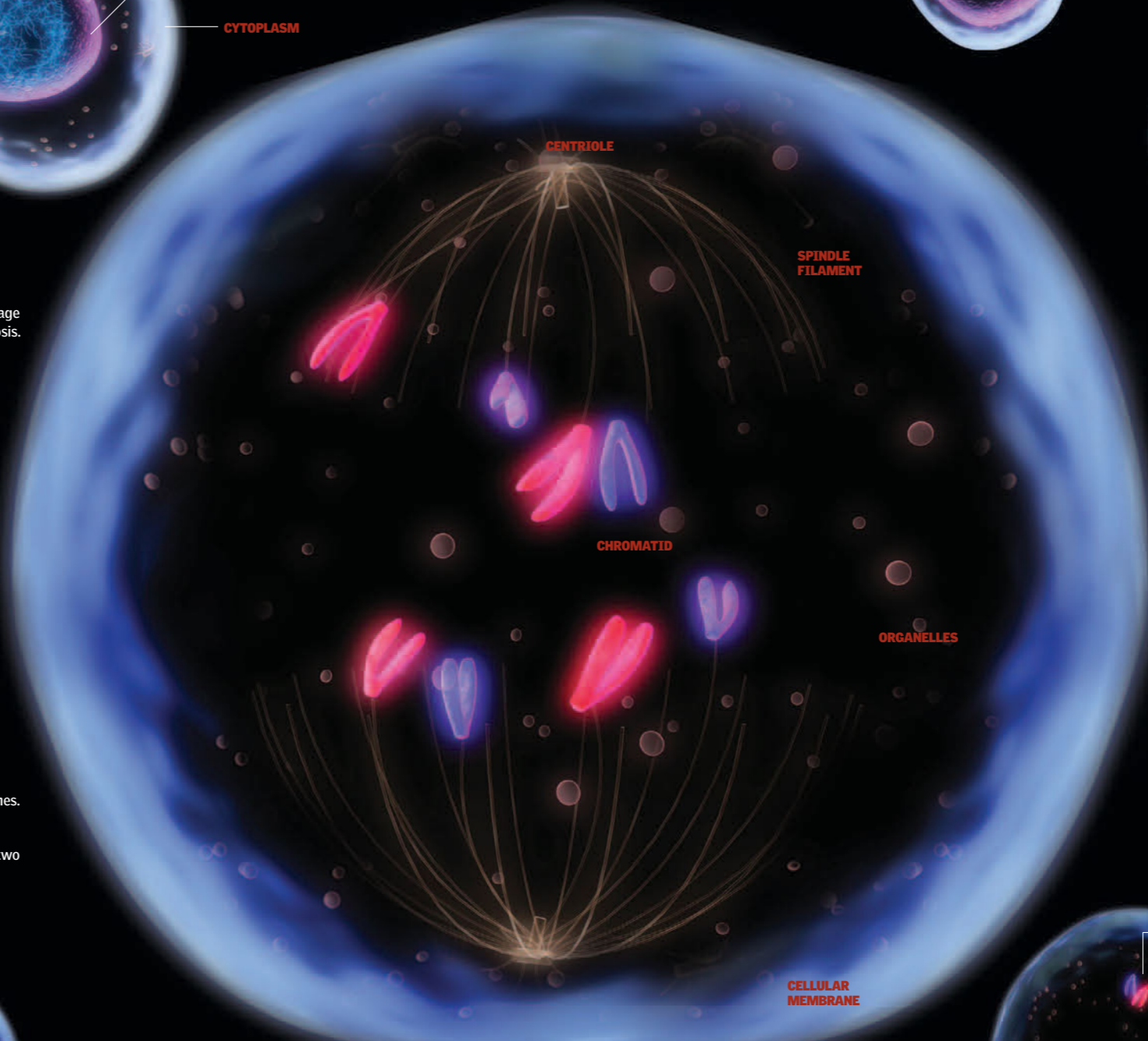
**1. INTERPHASE**  
An independent stage that precedes mitosis. The chromatin consists of DNA.



**2. PROPHASE**  
In prophase the chromatin condenses to form chromosomes. The karyotheca (nuclear envelope) begins to disappear. Chromosomes are formed by two chromatids that are joined together by a centromere.

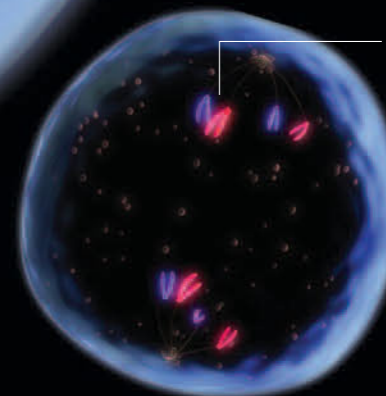


**3. METAPHASE**  
It is characterized by the appearance of the spindle. The centromere—the "center" of each chromosome—and the chromatids are joined together and align at the center of the spindle complex. The nuclear membrane disappears.



**4. ANAPHASE**  
In this crucial stage the copies of genetic information separate: the chromatids move apart and form sister chromosomes that migrate to opposite poles of the cell.

**5. TELOPHASE**  
The spindle disappears, and a new nuclear membrane begins to form around each new set of chromosomes. The membrane divides, resulting in two new cells that are identical daughters of the original cell.



**SISTER CHROMOSOMES**

## Antioxidants

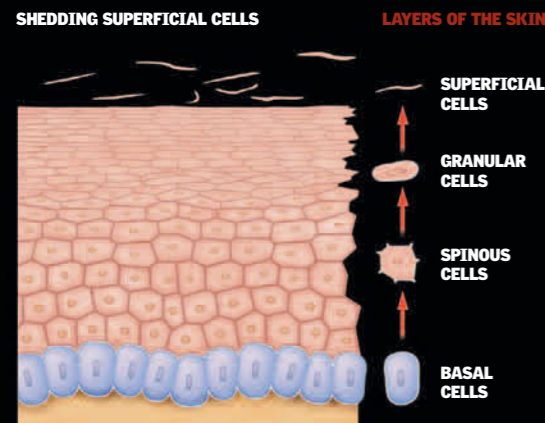
Antioxidants are various types of substances (vitamins, enzymes, minerals, etc.) that combat the pernicious effects of free radicals—molecules that are highly reactive and form as a result of oxidation (when an atom loses an electron), which is often caused by coming into contact with oxygen. A consequence of this oxidative action is the aging of the body. One action of antioxidants is the regulation of mitosis. Preventive geriatrics has focused on using antioxidants to prevent disease and to slow aging, in part because properly regulated mitosis is fundamental to these processes.

# 50,000

THE ESTIMATED NUMBER OF CELLS REPLACED EVERY SECOND IN THE HUMAN BODY THROUGH CELLULAR DIVISION

## The Ever-Changing Skin

Mitosis, or cellular division, occurs intensely within the skin, a fundamental organ of the sense of touch. The dead cells on the surface are continuously being replaced by new cells, which are produced by mitosis in the lowest, or basal, layer. From there the cells move upward until they reach the epidermis, the outer layer of the skin. A person typically sheds 30,000 dead skin cells every minute.



## Limit

50 MITOSES MARK THE LIFETIME OF A CELL AND ARE KNOWN AS THE "HAYFLICK LIMIT." THIS IDEA IS NAMED AFTER LEONARD HAYFLICK, WHO IN 1961 DISCOVERED THAT THE SECTION OF DNA CALLED THE TELOMERE INFLUENCES CELL LIFE SPAN.



# Systems of the Body

The body has various systems with different functions. These functions range from reproducing a cell to developing a new human being, from circulating the blood to capturing oxygen from the air, and from processing food through grinding and chemical transformations to absorbing nutrients and discarding waste. These functions act in harmony, and their interaction is surprisingly efficient. ●

## Circulatory System

This system carries blood to and from the heart and reaches the organs and cells in every part of the body. The supreme pump—the heart—drives the vital fluid—blood—through the arteries and collects it by means of the veins, with a continuous driving impulse that makes the heart the central engine of the body. **See page 36.**

## Skeletal System

The skeleton, or skeletal system, is a solid structure consisting of bones that are supported by ligaments and cartilage. The main functions of the system are to give the body form and to support it, to cover and protect the internal organs, and to allow motion to occur. The skeleton also generates red blood cells (called erythrocytes). **See page 20.**

## Nervous System

The central nervous system consists of the brain, which is the principal organ of the body, along with the spinal cord. The peripheral nervous system consists of the cranial and spinal nerves. Together they send external and internal sensations to the brain, where the sensations are processed and responded to whether the person is asleep or awake. **See page 82.**

## Reproductive System

### FEMALE

A woman's internal organs are the vagina, the uterus, the ovaries, and the fallopian tubes. The basic functions of these organs are the production of ova and the facilitation of fertilization of an ovum by a spermatozoon (a mature male sperm cell). When fertilization occurs, it sets a group of processes in motion that result in pregnancy. **See page 66.**

### MALE

The various male organs contribute one of the two cells needed to create a new human being. Two testicles (or gonads) and a penis are the principal organs of the system. The system is continuously active, producing millions of tiny cells called spermatozoa. **See page 64.**

## Respiratory System

Air from the external world enters the body through the upper airways. The central organs, the lungs, absorb oxygen and expel carbon dioxide. The lungs send oxygenated blood to all the cells via the circulatory system and in turn receive blood that requires purification. **See page 46.**

## Endocrine System

The endocrine system is formed by glands that are distributed throughout the body. Its primary function is to produce approximately 50 hormones, the body's chemical messengers. The endocrine system secretes the hormones into the bloodstream so that they can reach the organs they are designed to influence, excite, or stimulate for such activities as growth and metabolism. **See page 62.**

## Muscular System

Its function is to define the shape of the organism and protect it. The muscular system is essential for producing movement. It consists of muscles, organs made of fleshy tissue, and contractile cells. There are two types of muscles: striated and smooth. Striated muscles are attached to the bones and govern voluntary movement. Smooth muscles also obey the brain, but their movement is not under voluntary control. The myocardium, the muscle tissue of the heart, is unique and is in a class by itself. **See page 30.**

## Digestive System

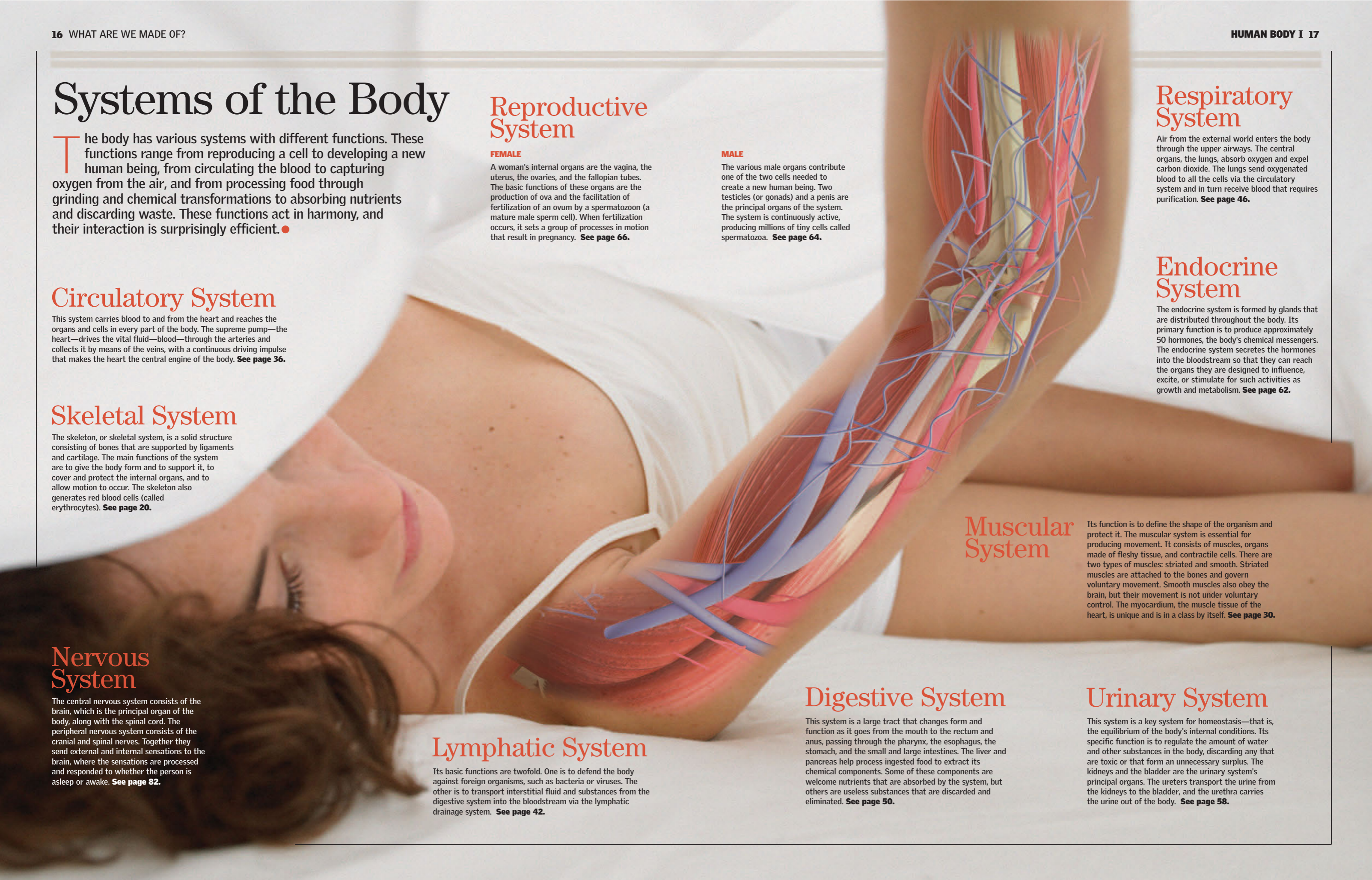This system is a large tract that changes form and function as it goes from the mouth to the rectum and anus, passing through the pharynx, the esophagus, the stomach, and the small and large intestines. The liver and pancreas help process ingested food to extract its chemical components. Some of these components are welcome nutrients that are absorbed by the system, but others are useless substances that are discarded and eliminated. **See page 50.**

## Urinary System

This system is a key system for homeostasis—that is, the equilibrium of the body's internal conditions. Its specific function is to regulate the amount of water and other substances in the body, discarding any that are toxic or that form an unnecessary surplus. The kidneys and the bladder are the urinary system's principal organs. The ureters transport the urine from the kidneys to the bladder, and the urethra carries the urine out of the body. **See page 58.**

## Lymphatic System

Its basic functions are twofold. One is to defend the body against foreign organisms, such as bacteria or viruses. The other is to transport interstitial fluid and substances from the digestive system into the bloodstream via the lymphatic drainage system. **See page 42.**





# Bones and Muscles

## MUSCLES OF THE THORAX

They play an important role in breathing by facilitating the contraction and expansion of the thoracic cavity.

## SKELETON 20-21

## BONE TISSUE 22-23

## CRANIUM AND FACE 24-25

## THE GREAT AXIS OF THE BODY 26-27

## JOINTS 28-29

## MUSCULAR SYSTEM 30-31

## MUSCLE FIBER 32-33



The musculoskeletal system consists of the skeletal system of bones, attached to each other by ligaments to form joints, and the skeletal muscles, which use

tendons to attach muscles to bone. The skeleton gives resistance and stability to the body and serves as a support structure for the muscles to work and produce movement. The bones also

serve as a shield to protect the internal organs. In this chapter you will see in detail—even down to the inside of a muscle fiber—how each part works. Did you know that bones are constantly

being regenerated and that, besides supporting the body, they are charged with producing red blood cells? In this chapter you will find incredible images, curiosities, and other information. ●



# Skeleton

The skeleton, or the skeletal system, is a strong, resistant structure made up of bones and their supporting ligaments and cartilage. The skeleton gives the body form and structure, covers and protects the internal organs, and makes movement possible. The bones store minerals and produce blood cells in the bone marrow.

## Well-Defined Form

The structure of the skeleton can be described as a vertical column of chained vertebrae with a pair of limbs at each end and topped off by the cranium. The upper limbs, or arms, are connected to the shoulder blades and clavicles in what is called the scapular belt, and the lower limbs, or legs, are connected at the hips, or pelvic belt. The joints reach such a level of perfection that modern engineering often uses them as a model in the study of levers when designing such objects as cranes or desk lamps. Although the bones that make up the skeleton are solid, they have a flexible structure and to a large degree consist of spongy tissue. Nevertheless, a small bone is capable of supporting up to 9 tons without breaking. A comparable weight would crush a block of concrete. For a long time anatomists thought that bones themselves were not alive and that their strength merely provided support for the other organs. Modern medicine recognizes that bones are actively living, furnished with nerves and supplied with blood.

## Types of Bones

Depending on their characteristics, such as size or shape, the bones of the human body are generally classified as follows:  
**SHORT BONES:** have a spherical or conical shape. The heel bone is a short bone.  
**LONG BONES:** have a central section that lies between two end points, or epiphyses. The femur is a long bone.  
**FLAT BONES:** form thin bony plates. Most bones of

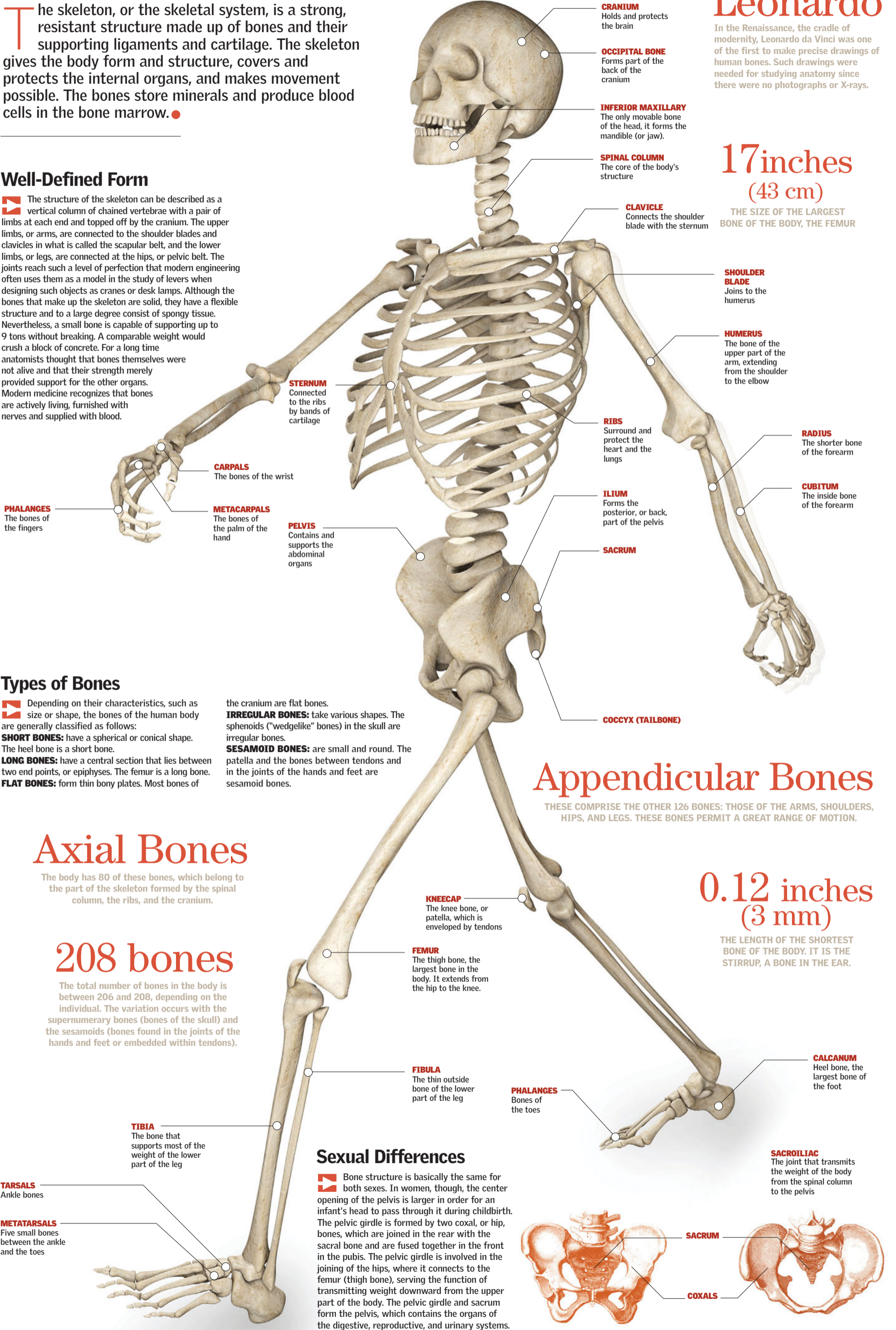
the cranium are flat bones.  
**IRREGULAR BONES:** take various shapes. The sphenoids ("wedgelike" bones) in the skull are irregular bones.  
**SESAMOID BONES:** are small and round. The patella and the bones between tendons and in the joints of the hands and feet are sesamoid bones.

## Leonardo

In the Renaissance, the cradle of modernity, Leonardo da Vinci was one of the first to make precise drawings of human bones. Such drawings were needed for studying anatomy since there were no photographs or X-rays.

17 inches  
(43 cm)

THE SIZE OF THE LARGEST BONE OF THE BODY, THE FEMUR



## Axial Bones

The body has 80 of these bones, which belong to the part of the skeleton formed by the spinal column, the ribs, and the cranium.

208 bones

The total number of bones in the body is between 206 and 208, depending on the individual. The variation occurs with the supernumerary bones (bones of the skull) and the sesamoids (bones found in the joints of the hands and feet or embedded within tendons).

## Appendicular Bones

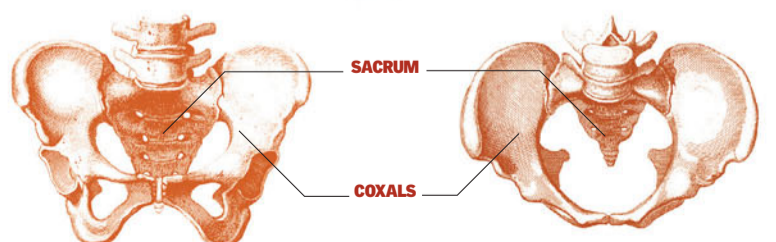
THESE COMPRISE THE OTHER 126 BONES: THOSE OF THE ARMS, SHOULDERS, HIPS, AND LEGS. THESE BONES PERMIT A GREAT RANGE OF MOTION.

0.12 inches  
(3 mm)

THE LENGTH OF THE SHORTEST BONE OF THE BODY. IT IS THE STIRRUP, A BONE IN THE EAR.

## Sexual Differences

Bone structure is basically the same for both sexes. In women, though, the center opening of the pelvis is larger in order for an infant's head to pass through it during childbirth. The pelvic girdle is formed by two coxal, or hip, bones, which are joined in the rear with the sacral bone and are fused together in the front in the pubis. The pelvic girdle is involved in the joining of the hips, where it connects to the femur (thigh bone), serving the function of transmitting weight downward from the upper part of the body. The pelvic girdle and sacrum form the pelvis, which contains the organs of the digestive, reproductive, and urinary systems.





# Bony Tissue

The primary mission of the bones is to protect the organs of the body. Bones are solid and resilient, which allows them to endure blows and prevent damage to the internal organs. The hard exterior is balanced by the internal spongy part. Over a person's lifetime bones are continuously regenerated; this process continues even after a person reaches maturity. Besides supporting the body and enabling movement, the bones are charged with producing red globules: thousands of millions of new cells are produced daily in the bone marrow, in a never-ending process of replacing old cells. ●

## Calcium and Marrow

All the hard parts that form the skeleton in vertebrates, such as the human being, are called bones. They may be hard, but they are nevertheless formed by a structure of living cells, nerves, and blood vessels, and they are capable of withstanding pressure of up to 1,000 pounds (450 kg). Because of their constitution and characteristics, they can mend themselves when fractured. A resistant exterior layer called the periosteum covers the outside of the compact bone. The endosteum, a thin layer of connective tissue lining the interior cavity of bone, contains the trabecular, or spongy mass, which is characterized by innumerable pores. The bone marrow, located in the center of the large bones, acts as a virtual red blood-cell factory and is also known as the medulla ossea. Minerals such as calcium go into making the bones. The fact that calcium is found in foods such as milk explains why healthy bones are usually associated with drinking a lot of milk. Calcium and phosphorous, among other chemical substances, give bones strength and rigidity. Proteins such as collagen provide flexibility and elasticity.



## Bone Marrow

A soft, fatty substance that fills the central cavities and produces red blood cells. Over time bone marrow in the large bones loses its ability to produce red blood cells.

**COMPACT BONE**  
Exterior covering, dense and heavy. It is one of the hardest materials in the body.

**PERIOSTEUM**  
A thin membrane that covers the exterior surface of the bone

**BLOOD VESSELS**  
carry blood to and from the bones to the rest of the body.

**ARTERY**  
**VEIN**

**DIAPHYSIS**  
contains the bone marrow, which produces red blood cells and has a network of blood vessels.

## Canals

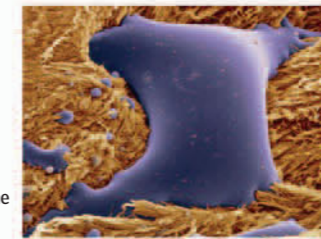
The structure of compact bone, showing concentric rings, or laminae, and canals called Havers conduits.

## Spongy Bone

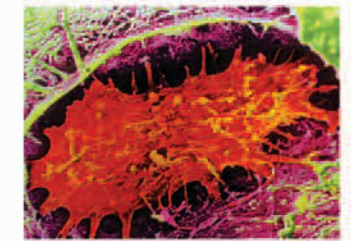
Internal layer of the bone. It is a network in the form of a honeycomb consisting of struts or rigid partitions called trabeculae, with spaces or cavities between them.

## TWO TYPES OF BONE CELLS

The osseous tissue consists of two types of cells, osteoblasts and osteoclasts. Both are produced by the bone marrow, and their interaction and equilibrium ensure the integrity and continuous renewal of the bone. An osteoclast reabsorbs bone tissue, leaving empty spaces, and an osteoblast fills them. The function of the osteocytes, a variant of the osteoblasts, is to maintain the shape of the bone.



**OSTEOBLAST**  
produces osseous, or bone, tissue, which maintains the strength of the bone.

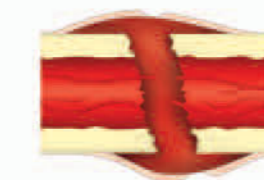


**OSTEOCLAST**  
breaks down the tissue so that it can be replaced with newer tissue.

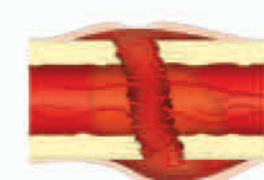## WHY FRACTURES HEAL

Bone has great regenerative capacity. Bone tissue has an extraordinary ability to repair itself after a fracture through processes that include the

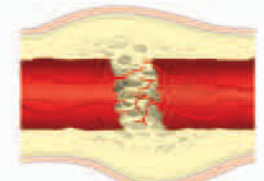
relatively rapid generation of cells. Medicine can guide these processes to cure other lesions, deformities, etc.



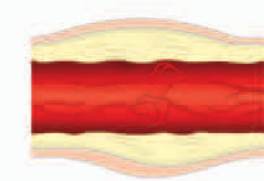
**A**  
A fracture occurs, and the blood cells coagulate to seal the broken blood vessels.



**C**  
Within one to two weeks new spongy bone develops on a base of fibrous tissue. The spaces created by the fracture are filled, and, finally, the ends are fused.



**B**  
Over a few days a fibrous mesh forms, which closes the ends of the bone and replaces the coagulate.

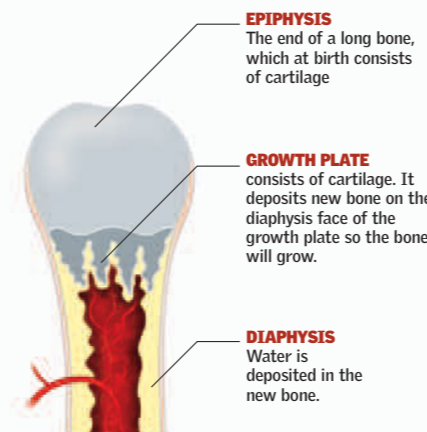


**D**  
Within two to three months, new blood vessels develop. Compact bone forms on the bony callous.

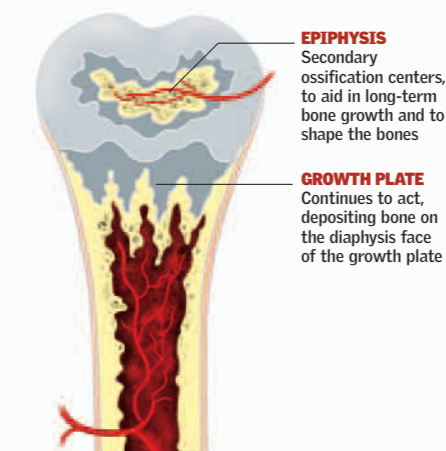
## Evolution of Bone

Bone development is completed at about 18 or 20 years of age in a process that begins with an infant's bones, which are largely cartilage, and continues with the ongoing generation of bone in the

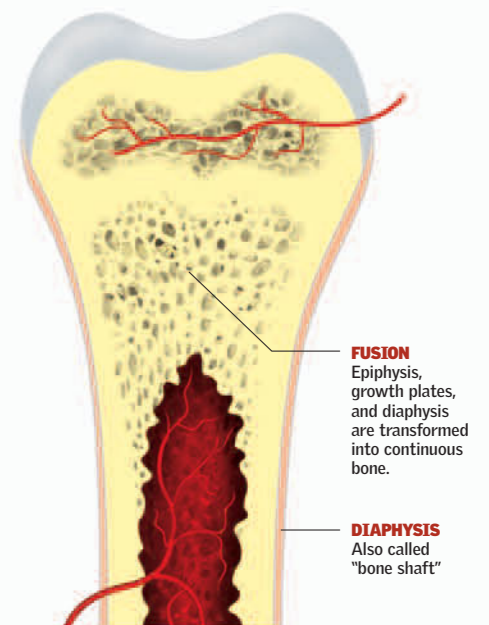
person as an adult. Calcium is an indispensable element for the healthy development of bones through this process. Until the age of six months, an intake of 0.007 ounce (210 mg) of calcium per day is recommended.



**1 IN AN INFANT**  
In a newborn infant the ends of the long bone (epiphyses) are made of cartilage. Between the bone shaft and an epiphysis, an area called a "growth plate" produces cartilage to lengthen the bone.



**2 IN A CHILD**  
In a child ossification continues to completion during epiphysis, generating long-term bone growth.



**3 IN AN ADULT**  
The process is complete when a person reaches about 18 years of age. The epiphysis, growth plates, and bone shaft fuse and become ossified into a continuous bone.

**FUSION**  
Epiphysis, growth plates, and diaphysis are transformed into continuous bone.

**DIAPHYSIS**  
Also called "bone shaft"



# Cranium and Face

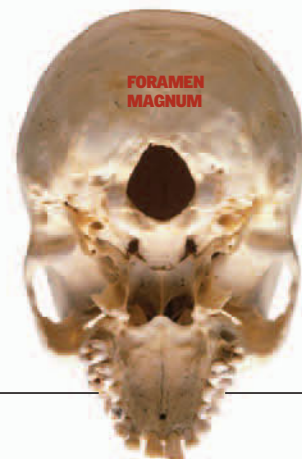The cranium surrounds and protects the brain, cerebellum, and cerebral trunk (sometimes called the encephalus). In an adult the cranium consists of eight bones that form the skull and the base of the cranium. The face is the anterior part of the skull. It consists of 14 bones, all of which are fixed except the lower maxillary, which makes up the mandible. The total number of bones in the head as a whole exceeds the total of the face and cranium (22) because it includes the little bones of the middle ear. ●

## Sutures and Fontanels

The cranium can be compared to a sphere, which consists of separate bones at birth and closes completely at maturity. The narrow separations between the bones, which appear as lines in the fetus for the first months of its life, are called sutures. Spaces called fontanels form where the sutures meet. Their separation has the functional purpose of allowing the brain to grow. Therefore, when brain growth is complete, the sphere closes tightly, because its function is to protect the brain.

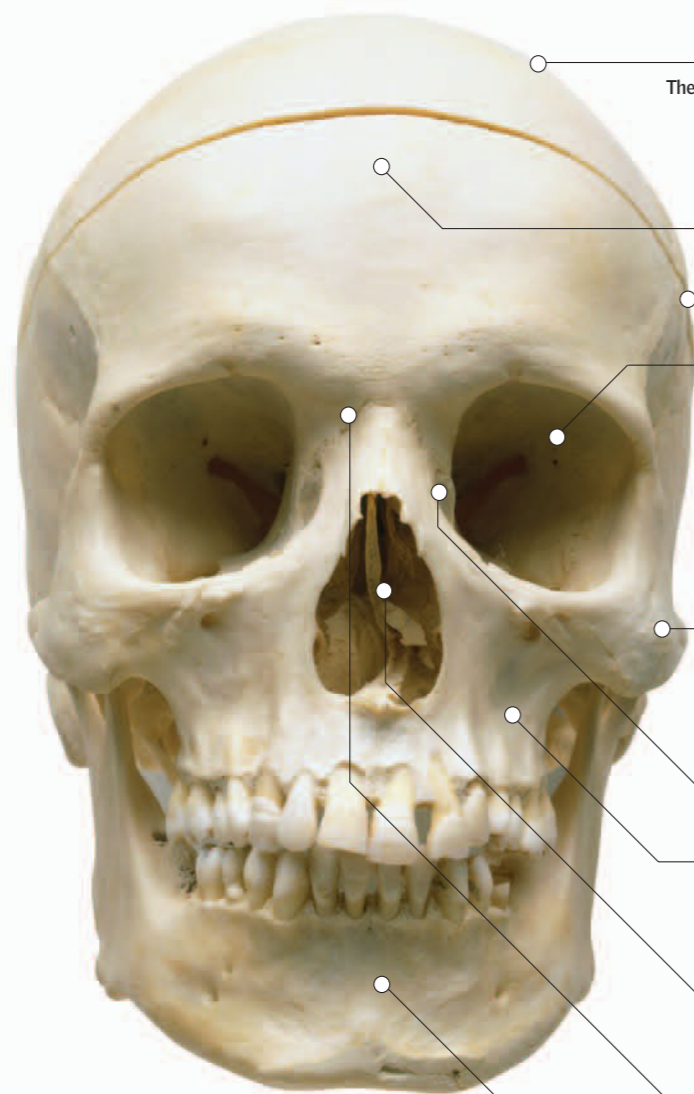## Vibration

When a person speaks, the bones of the cranium vibrate. In Japan a technology was developed based on this vibration. In 2006 the firefighters of the Madrid municipality in Spain adopted this technology. A helmet, furnished with a cranial contact microphone, amplifies the vibrations produced in the bones of the cranium during speech and sends them to radio equipment.



## Foramen Magnum

In Latin this term means "big hole." It is a circular opening, also called the occipital orifice, which is located at the base of the cranium. The foramen magnum allows for the passage of the spinal column, the medulla oblongata, the vertebral arteries, and the spinal nerve. The placement of the foramen magnum toward the bottom of the skull is associated with more highly evolved species.



### Cranial Bones (8)

**PARIETAL (2)**  
The superior and lateral parts of the cranium

**OCCIPITAL (1)**  
Together with the temporals, it forms the base of the cranium.

**FRONTAL (1)**  
It makes up the forehead.

**TEMPORAL (2)**  
The lateral part of the cranium

**SPHENOID (1)**  
The front part of the base of the cranium and part of the orbital bone (eye socket)

**ETHMOID (1)**  
Upper part of the nasal cavity

### Facial Bones (14)

**ZYGOMATIC (2)**  
The cheekbones

**PALATINES (2)**  
Internal bones that form the roof of the mouth

**LACHRYMAL BONES (2)**  
form the eye socket.

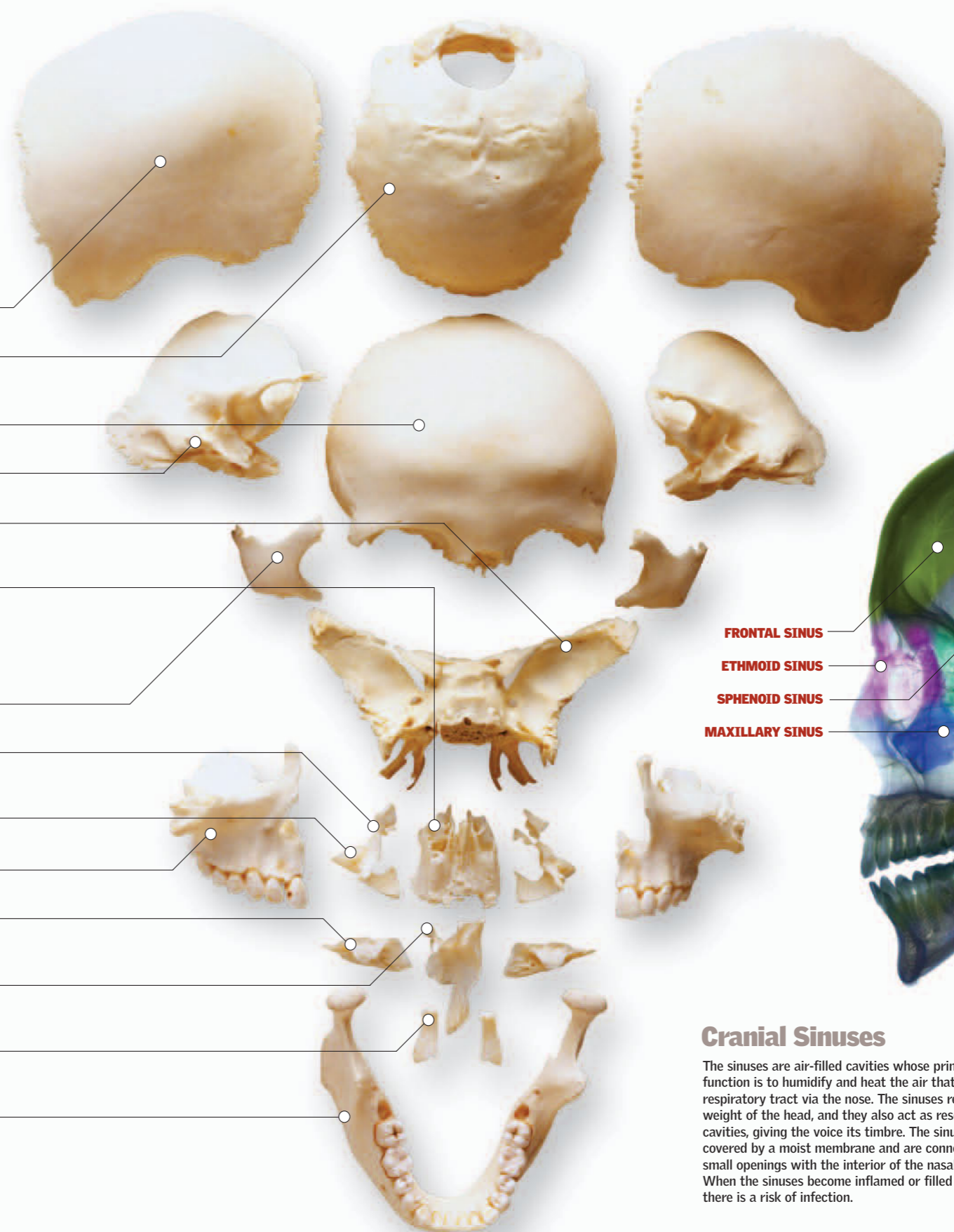
**SUPERIOR MAXILLARIES (2)**  
The upper mandible

**NASAL CONCHAS (2)**  
Independent of the ethmoid conchas

**VOMER (1)**  
divides the nasal cavity into two halves.

**NASAL BONE (2)**  
forms the bridge of the nose (the rest of the nose is cartilage).

**INFERIOR MAXILLARY (1)**  
constitutes the mandible and is the only facial bone that can move freely.

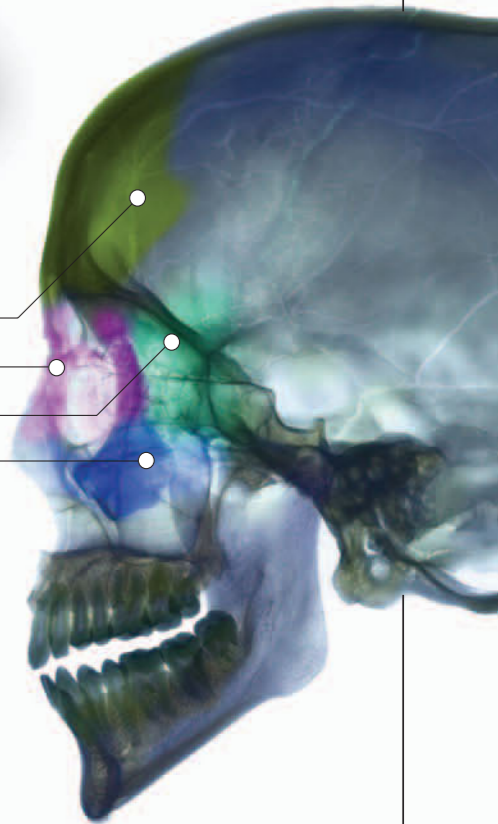


**22**  
THE TOTAL NUMBER OF BONES IN THE CRANIUM

**9 pounds (4 kg)**  
THE WEIGHT OF AN ADULT HUMAN HEAD

**83 cubic inches (1,360 cu cm)**  
THE TYPICAL VOLUME OF THE CRANIUM

**FRONTAL SINUS**  
**ETHMOID SINUS**  
**SPHENOID SINUS**  
**MAXILLARY SINUS**



## Cranial Sinuses

The sinuses are air-filled cavities whose principal known function is to humidify and heat the air that enters the respiratory tract via the nose. The sinuses reduce the weight of the head, and they also act as resonance cavities, giving the voice its timbre. The sinuses are covered by a moist membrane and are connected via small openings with the interior of the nasal cavity. When the sinuses become inflamed or filled with mucus, there is a risk of infection.



# The Great Axis of the Body

The vertebral, or spinal, column is the flexible axis that lends support to the body. It consists of a series of bones jointed together in a line, or chain, called the vertebrae. The spinal column forms a protective inner channel through which the spinal cord runs. The ribs perform a similar function, wrapping and shielding the vital internal organs, which include the heart and lungs. ●

## Stability and Motion

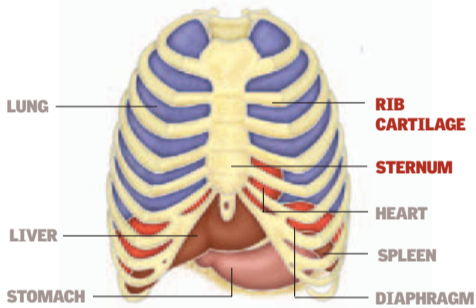
The vertebrae have a centrum that allows them to support the body's weight, each vertebra upon the next, as well as the weight of the rest of the body. The vertebrae also have extensions that allow them to articulate with other vertebrae or act as supports for the ligaments and the muscles. This system gives the axis of the body both strength and flexibility. In addition, most of the nerves of the peripheral system (that is, those responsible for

voluntary movement, for pain, and for the sense of touch) are connected to the spinal cord inside the spinal column. In the centrum the vertebrae are separated from each other by intervertebral disks that are made of cartilage and have a gelatinous interior. When an intervertebral disk is damaged, some of this material can escape and pinch a nerve. This condition, called a herniated disk, can be very painful.

## The Ribs and the Rib Cage

The 12 pairs of ribs, which also extend from the spinal column, protect the heart, lungs, major arteries, and liver. These bones are flat and curved. The seven upper pairs are called "true ribs," and they are connected to the sternum (a flat bone consisting of fused segments) by

cartilage. The next two or three pairs (called "false ribs") are connected indirectly. The remaining pairs ("floating ribs") are not attached to the sternum. The rib cage, formed by the ribs and its muscles, is flexible: it expands and contracts during breathing.



## 33 bones

OR VERTEBRAE, MAKE UP THE SPINAL COLUMN. DEPENDING ON THE INDIVIDUAL, SOMETIMES THERE ARE 34. THEY ARE CONNECTED BY DISKS OF CARTILAGE THAT ACT AS SHOCK ABSORBERS. THE SACRUM AND THE COCCYX ARE A RUDIMENTARY TAIL LOST DURING EVOLUTION.

### TARSUS (7)

1. MEDIAL CUNEIFORM
2. INTERMEDIATE CUNEIFORM
3. LATERAL CUNEIFORM
4. TALUS
5. TARSAL SCAPHOIDS
6. CALCANEUS
7. CUBOIDS

### PHALANGES (14)

### METATARSALS (5)

## Bones of the Hands and Feet

Each hand (see the drawing below) has 27 bones, and each foot (see above) has 26. The hand has great mobility, and each of its fingers (five in all) has three phalanges (distal, medial, and proximal), except for the thumb, which has two. The complex of carpal bones makes up the wrist and is connected to the forearm. The metacarpal bone sustains the medial part. The feet function in a similar manner; the toes have first, second, and third phalanges, except for the big toe.

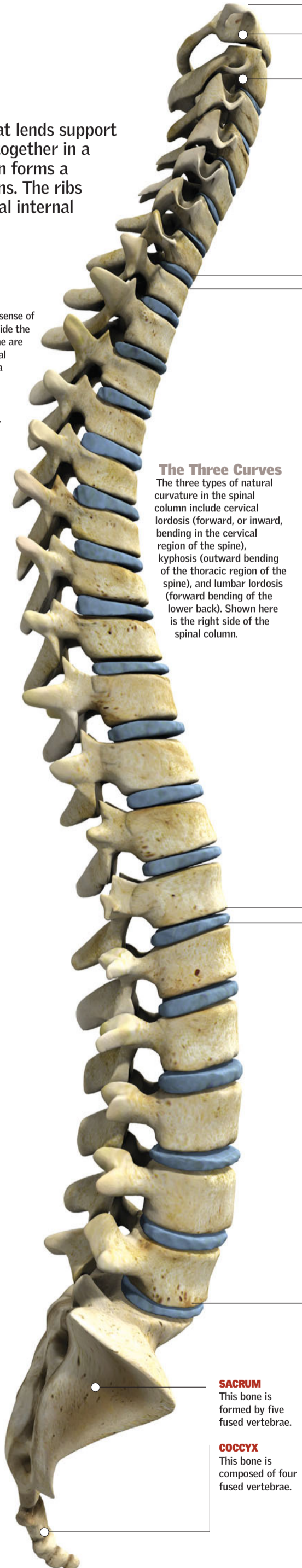
### CARPALS (8)

1. LUNATE
2. PISIFORM
3. TRIQUETRUM
4. TRAPEZIUM
5. TRAPEZOID
6. CAPITATE
7. SCAPHOID
8. HAMATE

### METACARPALS (5)

### CARPALS (8)

### PHALANGES (14)



**ATLAS**  
This bone is the first of the seven cervical bones; it unites the spinal column with the head.



**AXIS**  
The second cervical vertebra. Together with the atlas, it permits the movement of the head.



**CERVICAL**  
These seven vertebrae (including the atlas and the axis) support the head and the neck.



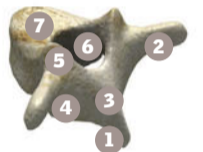### The Three Curves

The three types of natural curvature in the spinal column include cervical lordosis (forward, or inward, bending in the cervical region of the spine), kyphosis (outward bending of the thoracic region of the spine), and lumbar lordosis (forward bending of the lower back). Shown here is the right side of the spinal column.

**THORACIC, OR DORSAL, VERTEBRAE**  
There are 12, and they are joined to the ribs.

### PARTS OF THE VERTEBRAE

1. SPINAL APOPHYSIS
2. TRANSVERSE APOPHYSIS (2)
3. ARTICULAR APOPHYSIS (4) (2 SUPERIOR AND 2 INFERIOR)
4. LAMINAE (2)
5. PEDICULAE (2)
6. FORAMEN MAGNUM
7. BODY



### Downwards

All the vertebrae except the cervical axis and atlas have a cylindrical body, which gives them a particular characteristic: as they approach the pelvis they tend to be longer and stronger.

### LUMBAR VERTEBRAE

There are five of them, and they bear the weight of the upper part of the body.

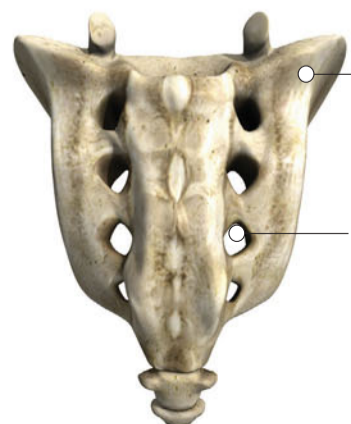

**SACRUM**  
This bone is formed by five fused vertebrae.

**COCCYX**  
This bone is composed of four fused vertebrae.

### BLADE

**SACRAL CANAL**  
Nerves pass through the sacral canal.





# Joints

They are the structures where two or more bones come together, either directly or by means of strong fibrous cords called ligaments. The skeleton has movement thanks to its joints. Most joints, like the knee, are synovial joints. They are characterized by mobility, versatility, and lubrication. The muscles that surround them contract to cause movement. When they work as a whole, the bones, muscles, and joints—together with the tendons, ligaments, and cartilage—constitute a grand system that governs the motor activity of the body and allows us to carry out our daily physical activities. ●

## Hypermobility

The versatility of the joints refers to their characteristic range of motion. Just as there are mobile, semimobile, and fixed joints, there is also a group of joints that are hypermobile. Such joints are less common but are easily recognizable, especially in children and adults who have not lost the flexibility of their joints. The elbows, wrists, fingers, and knees can at an early age and in certain individuals have a greater-than-normal range of motion. For people with hypermobile joints this extra range of motion can be accomplished without difficulty or risk of dislocation.

## Mobile

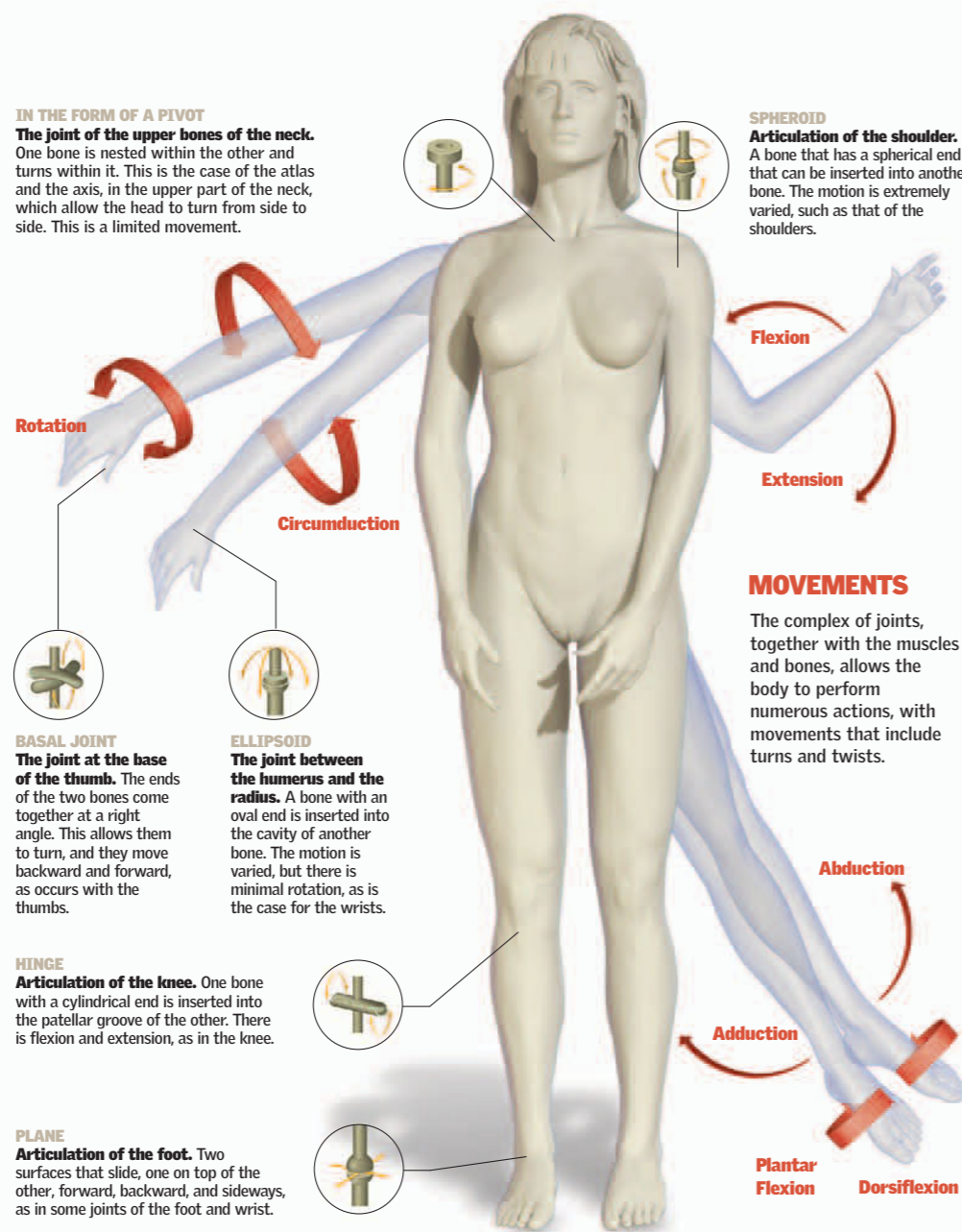
These are also called diarthroses; they are the joints with the greatest range of motion. The ends of the bones linked together are structured in various ways that facilitate their movement relative to each other, while ensuring the stability of the joint. Most joints in the body are of this type.

## Semimobile

Also known as amphiarthroses. The surfaces of the bone that make contact have cartilaginous tissue. One example is the vertebral joints: they have little individual movement, but as a whole they have ample flexion, extension, and rotation.

## Fixed

Also known as synarthroses. Most fixed joints are found in the cranium and have no need for motion because their primary function is to protect internal organs. They are connected by bone growth or fibrous cartilage and are extremely rigid and very tough.



**IN THE FORM OF A PIVOT**  
**The joint of the upper bones of the neck.** One bone is nested within the other and turns within it. This is the case of the atlas and the axis, in the upper part of the neck, which allow the head to turn from side to side. This is a limited movement.

**SPHEROID**  
**Articulation of the shoulder.** A bone that has a spherical end that can be inserted into another bone. The motion is extremely varied, such as that of the shoulders.

**BASAL JOINT**  
**The joint at the base of the thumb.** The ends of the two bones come together at a right angle. This allows them to turn, and they move backward and forward, as occurs with the thumbs.

**ELLIPSOID**  
**The joint between the humerus and the radius.** A bone with an oval end is inserted into the cavity of another bone. The motion is varied, but there is minimal rotation, as is the case for the wrists.

**HINGE**  
**Articulation of the knee.** One bone with a cylindrical end is inserted into the patellar groove of the other. There is flexion and extension, as in the knee.

**PLANE**  
**Articulation of the foot.** Two surfaces that slide, one on top of the other, forward, backward, and sideways, as in some joints of the foot and wrist.

**MOVEMENTS**  
 The complex of joints, together with the muscles and bones, allows the body to perform numerous actions, with movements that include turns and twists.

## 1918

**IN THIS YEAR PROFESSOR KENJI TAKAGI OF JAPAN USED A CYSTOSCOPE FOR THE FIRST INTERNAL OBSERVATION OF THE KNEE.** Technological advances now permit arthroscopy to make precise observations for diagnosis.

**ARTERY**  
 The femoral artery (artery of the femur) changes into the popliteal artery at the posterior face of the knee. Like all arteries it carries oxygenated blood from the heart.

## The Knee

The knee is the biggest joint of the body. It maintains its stability because it is constrained by four ligaments: the anterior and posterior cruciate and the internal and external lateral. The ligaments link the femur (the thigh bone) with the tibia (a bone of the leg). The knee is protected by the kneecap, a bony disk covered with cartilage that encases the anterior and superior part of the knee joint. Like the majority of the joints, it is synovial.

**EXTERNAL LIGAMENTS**  
 Stabilize the joint during movement. The knee also has internal ligaments.

**FIBULA**  
 The smallest bone of the lower leg

**FEMUR**  
 The thigh bone, which is the upper region of the lower limb

**MUSCLE**

**SYNOVIAL MEMBRANE**  
 produces the synovial liquid.

**KNEECAP**  
 Protective bony disk covered with cartilage

**PATELLAR LIGAMENT**  
 This ligament crosses over the kneecap and encases it.

**TIBIA**  
 The larger of the two bones of the lower leg

Where the patellar tendon connects to the bone

**MENISCUS**  
 Fibrous cartilage that helps the weight-supporting bones to absorb a blow

## Noise

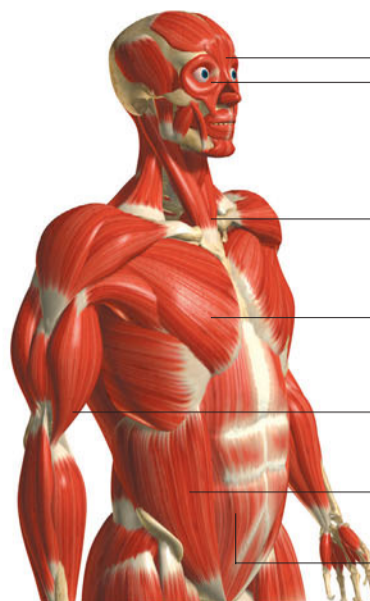
A CHARACTERISTIC OF THE JOINTS IS THAT THEY CAN MAKE A SOUND, SUCH AS THAT MADE WHEN SOMEONE CRACKS HER OR HIS KNUCKLES. THIS IS BECAUSE THERE IS AN EXPLOSIVE RELEASE OF GAS THAT PERMITS A SHOCK-ABSORBING FLUID TO FLOW IN THE JOINT.

**MUSCLE**



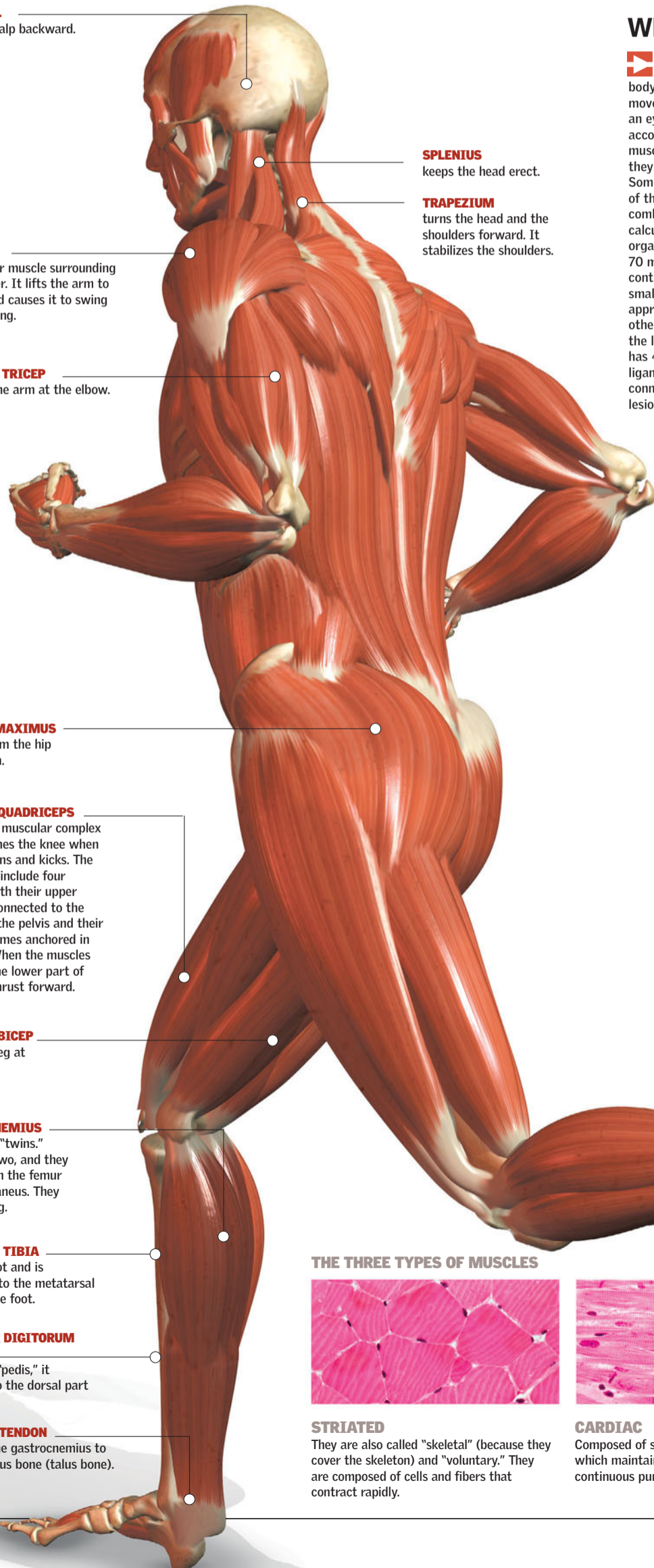
# Muscular System

The muscles are organs formed by fleshy tissue consisting of contractile cells. They are divided into striated, smooth, and, in a unique case, cardiac (the myocardium is the muscular tissue of the heart). Muscles shape and protect the organism. The muscles of the skeleton are attached to the bones to permit voluntary movement, which is consciously directed by the brain. The smooth muscles are also directed by the brain, but their motion is not voluntary, as in the case of digestion. These muscles get most of their energy from alimentary carbohydrates, which can be stored in the liver and muscles in the form of glycogen and can later pass into the blood and be used as glucose. When a person makes a physical effort, there is an increased demand for both oxygen and glucose, as well as an increase in blood circulation. A lack of glucose leads to fatigue. ●



- FRONTAL MUSCLE**  
wrinkles the forehead.
- ORBICULAR MUSCLE**  
allows blinking.
- STERNOCLEIDOMASTOID**  
allows the head to turn and move forward.
- PECTORALIS MAJOR**  
stretches the arm forward. It turns it and brings it close to the body.
- BRACHIAL BICEP**  
bends the arm at the elbow.
- EXTERNAL OBLIQUE**  
turns the trunk and bends it to both sides.
- RECTUS ABDOMINIS**  
bends the trunk forward.

**OCCIPITAL**  
pulls the scalp backward.



- SPLЕНИUS**  
keeps the head erect.
- TRAPEZIUM**  
turns the head and the shoulders forward. It stabilizes the shoulders.

**DELTOID**  
A triangular muscle surrounding the shoulder. It lifts the arm to the side and causes it to swing when walking.

**BRACHIAL TRICEP**  
stretches the arm at the elbow.

**GLUTEUS MAXIMUS**  
extends from the hip to the thigh.

**FEMORAL QUADRICEPS**  
A powerful muscular complex that stretches the knee when a person runs and kicks. The quadriceps include four muscles, with their upper extremes connected to the femur and the pelvis and their lower extremes anchored in the tibia. When the muscles contract, the lower part of the leg is thrust forward.

**FEMORAL BICEP**  
bends the leg at the knee.

**GASTROCNEMIUS**  
Also called "twins." There are two, and they extend from the femur to the calcaneus. They bend the leg.

**ANTERIOR TIBIA**  
lifts the foot and is connected to the metatarsal bones of the foot.

**EXTENSOR DIGITORUM LONGUS**  
Called the "pedis," it connects to the dorsal part of the foot.

**ACHILLES TENDON**  
connects the gastrocnemius to the calcaneus bone (talus bone).

## When the Skeleton Moves

The great number of muscles of voluntary action available to the human body makes possible thousands of distinct movements. Actions from the simple blink of an eyelid to the twisting of a belt are accomplished by muscular action. The eye muscles involve the most activity because they carry out 100,000 movements per day. Some 30 muscles control all the movements of the face and define an infinite possible combination of facial expressions. It is calculated that to pronounce one word, the organs for speech and respiration move some 70 muscles. The stirrup muscle, which controls the stirrup of the ear, is one of the smallest in the body. It measures approximately 0.05 inch (1.2 mm). There are other muscles that are very large, including the latissimus dorsi of the shoulder. The foot has 40 muscles and more than 200 ligaments. Because the muscles are connected by a great number of nerves, a lesion or blow causes the brain to react,

producing pain. Approximately 40 percent of the total weight of the body consists of the muscular system. When the organism reduces the quantity of calories it normally ingests (for example, when a person goes on a diet), the first thing the body loses is water, which is reflected in a rapid weight loss. Then the metabolism adapts to the diet, and the body resorts to using up muscle tissue before drawing on the fats stored for burning calories. For this reason, when the diet begins this second phase, the consequences can be lack of vigor and loss of muscle tone, which is recovered when the diet returns to normal.

**650 skeletal muscles**

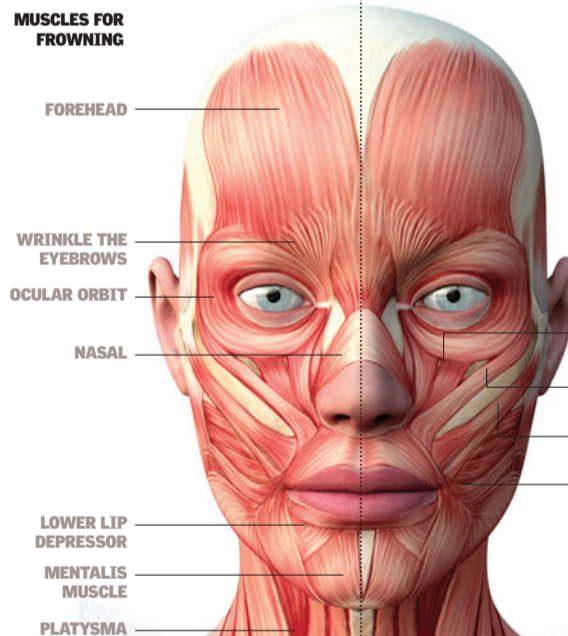
OR VOLUNTARY MUSCLES ARE IN THE TYPICAL HUMAN BODY.

### MUSCLES FOR FROWNING

- FOREHEAD
- WRINKLE THE EYEBROWS
- OCULAR ORBIT
- NASAL
- LOWER LIP DEPRESSOR
- MENTALIS MUSCLE
- PLATYSMA

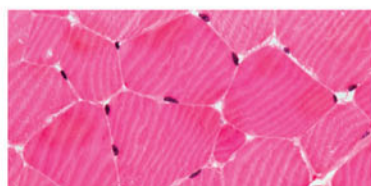
### MUSCLES FOR SMILING

- UPPER LIP ELEVATOR
- ZYGOMATIC MINOR
- ZYGOMATIC MAJOR
- RISORIOUS

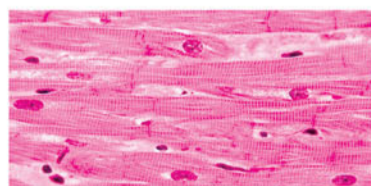


Clearly, a lot fewer muscles are needed to smile than to frown.

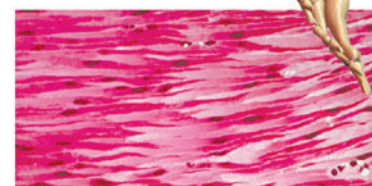## THE THREE TYPES OF MUSCLES



**STRIATED**  
They are also called "skeletal" (because they cover the skeleton) and "voluntary." They are composed of cells and fibers that contract rapidly.



**CARDIAC**  
Composed of small interconnected fibers, which maintain the rhythmic and continuous pumping of the heart.



**SMOOTH**  
Perform unconscious actions such as digestion. Their fibers contract slowly over an extended period of time.



# Muscular Fiber

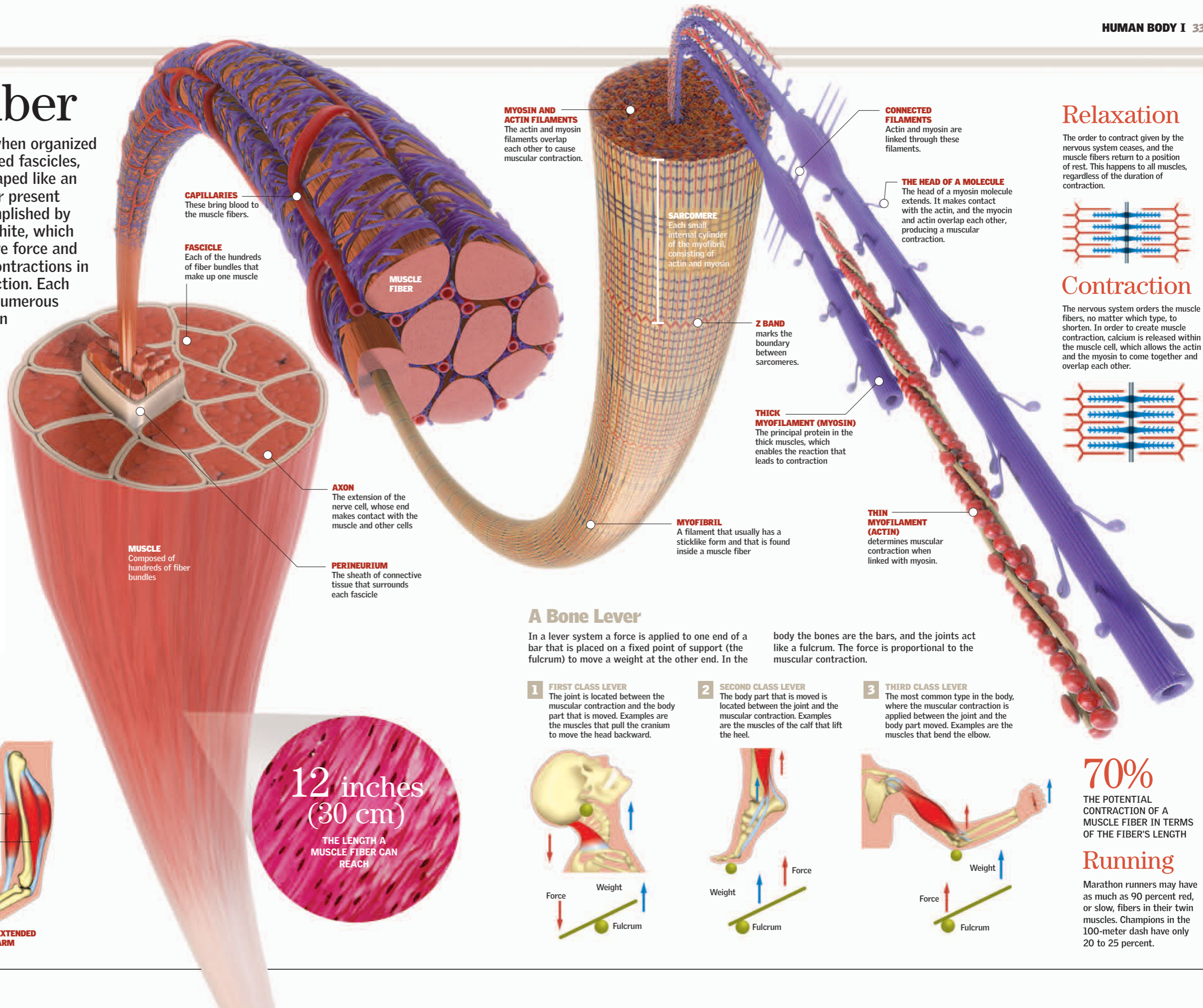
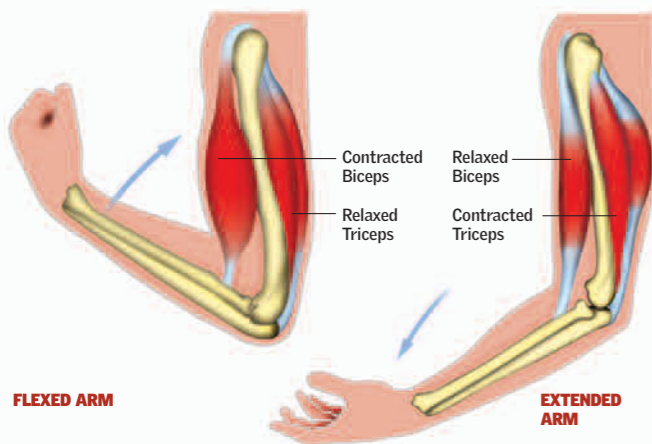
A fiber is the long, thin cell that, when organized by the hundreds into groups called fascicles, constitutes the muscles. It is shaped like an elongated cylinder. The amount of fiber present varies according to the function accomplished by each muscle. Fibers are classified as white, which contract readily for actions that require force and power, and red, which perform slow contractions in movements of force and sustained traction. Each muscle fiber contains in its structure numerous filaments called myofibers. Myofibers, in turn, have two classes of protein filaments: myosin, also called thick filaments, and actin, or thin filaments. Both kinds of fibers are arranged in tiny matrices called sarcomeres. ●

## Specialization

The quantity of muscle fiber varies according to the size and function of the muscle. Also, the same muscle can combine white fibers (rapid contracters) and red fibers (slow contracters). Even though their percentages differ from one person to the next, the composition of the muscles of the upper limbs tends to be the same as that of the lower in the same person. In other words, the relation between motor neurons and muscle fibers is inscribed in a person's genes. Depending on the type of neuron that stimulates them, the fibers are differentiated into slow fibers (when the neuron or motor neuron innervates between five and 180 fibers) and rapid fibers (when the neuron innervates between 200 and 800 fibers). The neurons and the fiber constitute what is called a motor unit.

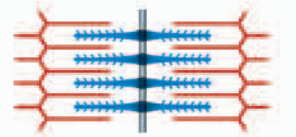
## Opposites

The muscles contract or relax according to the movement to be accomplished. To make the brain's directive take effect, the muscles involved carry out opposing actions.




## Relaxation

The order to contract given by the nervous system ceases, and the muscle fibers return to a position of rest. This happens to all muscles, regardless of the duration of contraction.



## Contraction

The nervous system orders the muscle fibers, no matter which type, to shorten. In order to create muscle contraction, calcium is released within the muscle cell, which allows the actin and the myosin to come together and overlap each other.



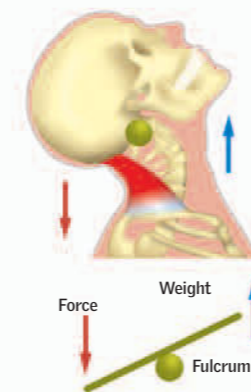
## A Bone Lever

In a lever system a force is applied to one end of a bar that is placed on a fixed point of support (the fulcrum) to move a weight at the other end. In the

body the bones are the bars, and the joints act like a fulcrum. The force is proportional to the muscular contraction.

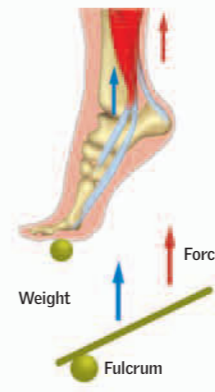
### 1 FIRST CLASS LEVER

The joint is located between the muscular contraction and the body part that is moved. Examples are the muscles that pull the cranium to move the head backward.



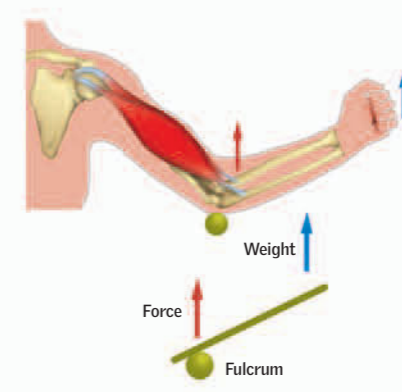
### 2 SECOND CLASS LEVER

The body part that is moved is located between the joint and the muscular contraction. Examples are the muscles of the calf that lift the heel.



### 3 THIRD CLASS LEVER

The most common type in the body, where the muscular contraction is applied between the joint and the body part moved. Examples are the muscles that bend the elbow.



**12 inches (30 cm)**  
THE LENGTH A MUSCLE FIBER CAN REACH

**70%**  
THE POTENTIAL CONTRACTION OF A MUSCLE FIBER IN TERMS OF THE FIBER'S LENGTH

## Running

Marathon runners may have as much as 90 percent red, or slow, fibers in their twin muscles. Champions in the 100-meter dash have only 20 to 25 percent.



# Internal Systems and Organs

## THE CHEMISTRY OF LOVE

Even a light kiss results in the release of adrenaline, causing a sensation of euphoria and joy.

## CIRCULATORY SYSTEM 36-37

ALL ABOUT THE HEART 38-39

COMPONENTS OF THE BLOOD 40-41

LYMPHATIC SYSTEM 42-43

GANGLIA 44-45

RESPIRATORY SYSTEM 46-47

## LUNGS 48-49

DIGESTIVE SYSTEM 50-51

STOMACH 52-53

LIVER, PANCREAS, BILE 54-55

LARGE AND SMALL INTESTINE 56-57

URINARY SYSTEM 58-59

## KIDNEYS 60-61

ENDOCRINE SYSTEM 62-63

MALE REPRODUCTIVE SYSTEM 64-65

FEMALE REPRODUCTIVE SYSTEM 66-67

**I**t is difficult to explain that the sexual attraction between a man and woman—something that appears to be so natural and intimate—is a chemical phenomenon. What is

certain is that when a couple feels they are in love, it is because hormones have gone into action. Without them, amorous thoughts and sexual fantasies would be drab and dull. We invite you to find out to

what extent hormones determine many of our actions and also to investigate in detail, one by one, how the body's systems function. You will learn to understand how various organs of the

body work as a team. Although each organ accomplishes specific tasks on its own, they all communicate with each other, and together they form a complete human being. ●



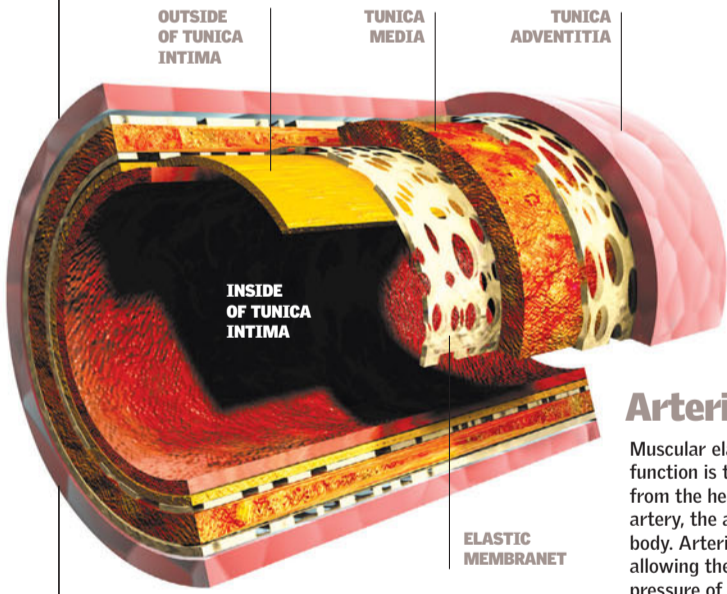
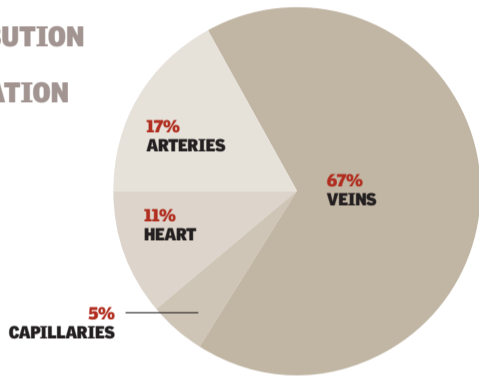
# Circulatory System

Its function is to carry blood to and from all the organs of the body. To drive the constant movement of the blood, the system uses the pumping of the heart, the organ that acts as the system's engine. The arteries bring oxygen-rich blood to all the cells, and the veins retrieve the blood so that it can be oxygenated once again and so that wastes can be removed. ●

## A System That Goes Around

The center of the system is the heart, which, together with a network of vessels, forms the cardiovascular machinery. This vital engine beats more than 30 million times a year—approximately 2 billion times in a person's lifetime. With each beat it pumps about 5 cubic inches (82 ml) of blood. This means that an adult heart could fill a 2,000-gallon (8,000-l) tank in just one day. Beginning at the heart, the circulatory system completes two circuits: the main, or systemic, circulation via the aortic artery and the minor, or pulmonary, circulation. The main circulation brings oxygenated blood to the capillary system, where the veins are formed; the minor circulation brings oxygen-poor blood through the pulmonary artery to be enriched with oxygen and to have carbon dioxide removed from it, a process called hematosis. Other secondary circuits are the hepatic portal system and the hypophyseal portal system.

### BLOOD DISTRIBUTION DURING CIRCULATION

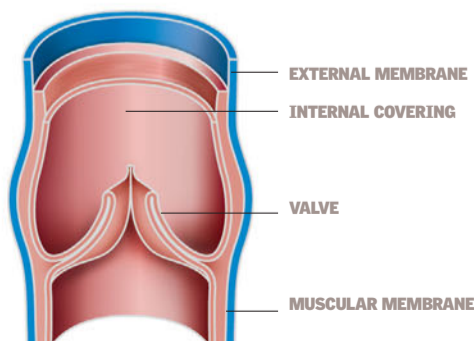


### Arteries

Muscular elastic blood vessels. Their function is to bring oxygenated blood from the heart (from the primary artery, the aorta) to all the cells of the body. Arteries have thick walls, allowing them to withstand the high pressure of the blood.

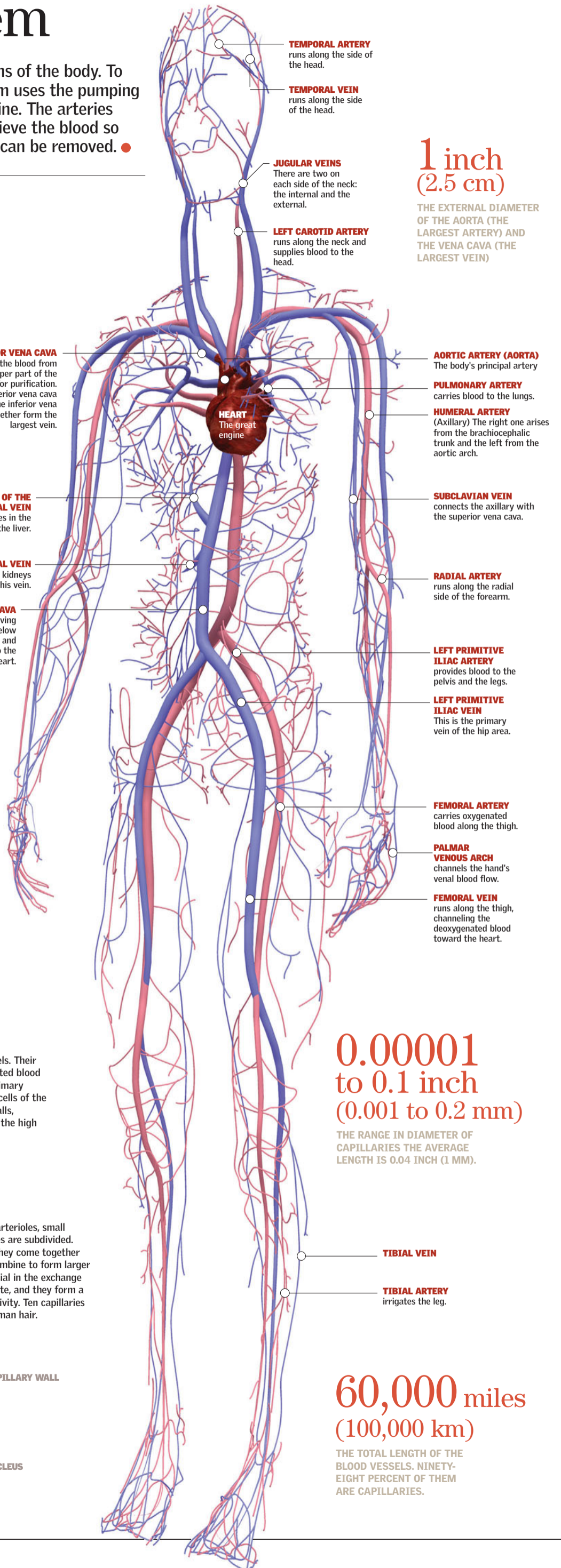
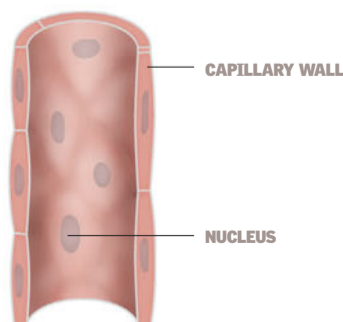
### Veins

The veins are the conduits that transport deoxygenated blood back toward the heart after it has traveled to different parts of the body. The veins have thin walls with less muscular fiber and less elasticity than the arteries. The principal veins have valves to prevent the reflux of blood, forcing it to travel in only one direction.



### Capillaries

These are branchings of the arterioles, small vessels into which the arteries are subdivided. The capillaries are tiny, and they come together to form small veins, which combine to form larger veins. The capillaries are crucial in the exchange of oxygen, nutrients, and waste, and they form a network to carry out this activity. Ten capillaries together are as thick as a human hair.



**1 inch (2.5 cm)**

THE EXTERNAL DIAMETER OF THE AORTA (THE LARGEST ARTERY) AND THE VENA CAVA (THE LARGEST VEIN)

**0.00001 to 0.1 inch (0.001 to 0.2 mm)**

THE RANGE IN DIAMETER OF CAPILLARIES THE AVERAGE LENGTH IS 0.04 INCH (1 MM).

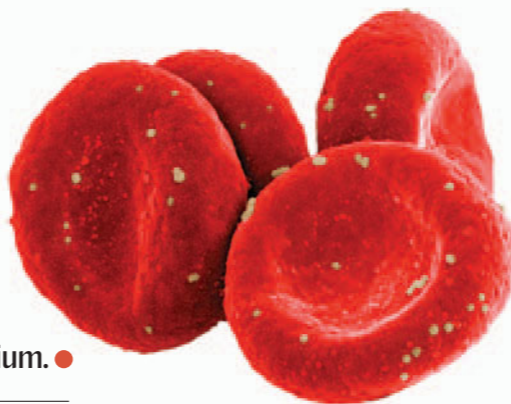**60,000 miles (100,000 km)**

THE TOTAL LENGTH OF THE BLOOD VESSELS. NINETY-EIGHT PERCENT OF THEM ARE CAPILLARIES.



# All About the Heart

The heart is the engine of the circulatory apparatus: it supplies 10 pints (4.7 l) of blood per minute. Its rhythmic pumping ensures that blood arrives in every part of the body. The heart beats between 60 and 100 times per minute in a person at rest and up to 200 times per minute during activity. The heart is a hollow organ, the size of a fist; it is enclosed in the thoracic cavity in the center of the chest above the diaphragm. The name of the stomach's entrance, or *cardias*, comes from the Greek word for heart, *kardia*. Histologically, one can distinguish three layers of tissue in the heart, starting from the inside out: the endocardium, the myocardium, and the pericardium. ●

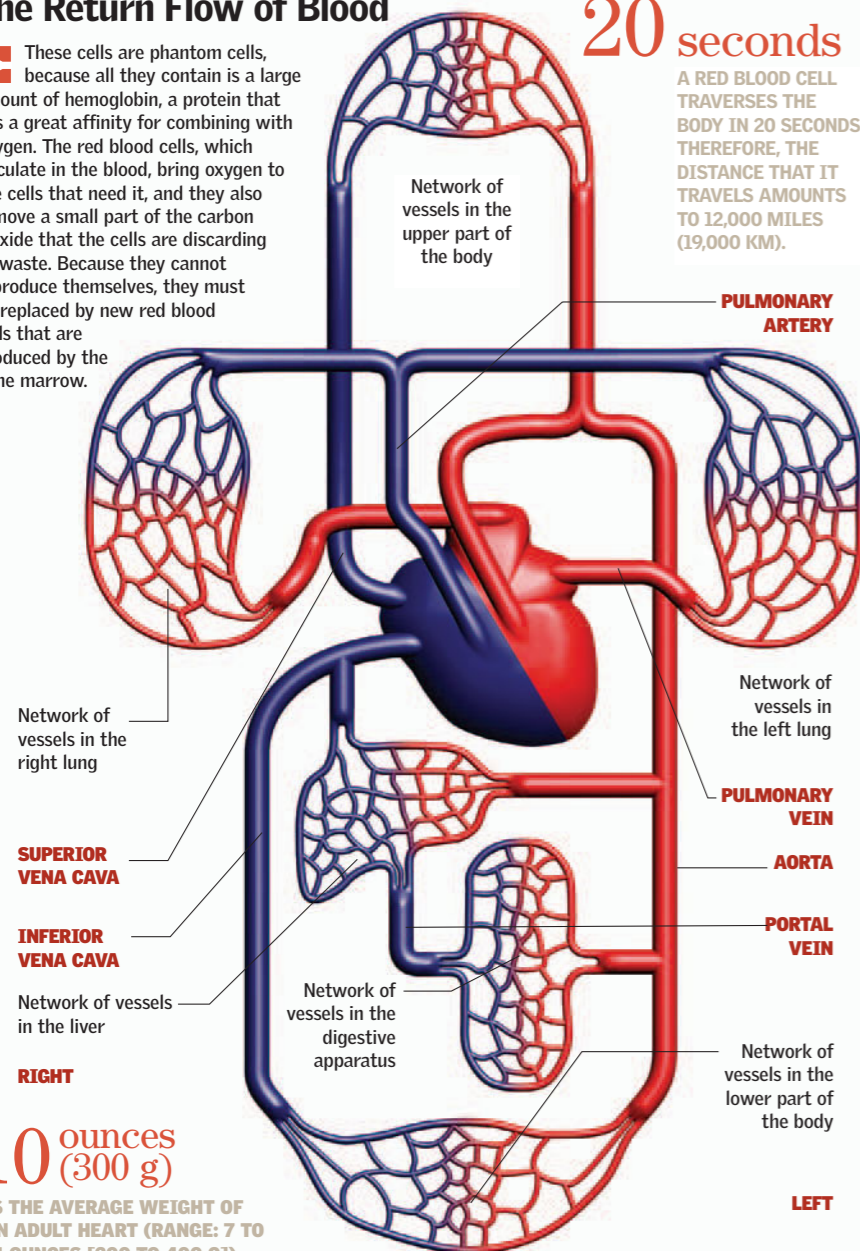


## The Return Flow of Blood

These cells are phantom cells, because all they contain is a large amount of hemoglobin, a protein that has a great affinity for combining with oxygen. The red blood cells, which circulate in the blood, bring oxygen to the cells that need it, and they also remove a small part of the carbon dioxide that the cells are discarding as waste. Because they cannot reproduce themselves, they must be replaced by new red blood cells that are produced by the bone marrow.

**20 seconds**

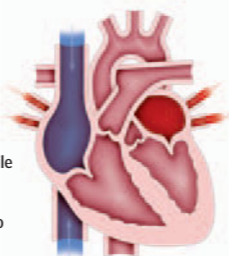
A RED BLOOD CELL TRAVERSES THE BODY IN 20 SECONDS. THEREFORE, THE DISTANCE THAT IT TRAVELS AMOUNTS TO 12,000 MILES (19,000 KM).



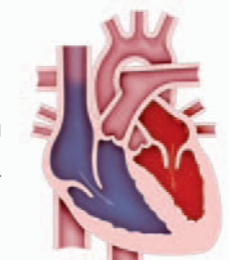
**10 ounces (300 g)**  
IS THE AVERAGE WEIGHT OF AN ADULT HEART (RANGE: 7 TO 14 OUNCES [200 TO 400 G]).

## THE SEQUENCE OF THE HEARTBEAT

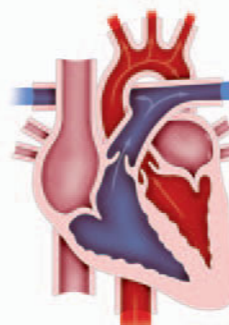
**1 DIASTOLIC**  
The atria and the ventricles are relaxed. The blood, supercharged with carbon dioxide, flows from all the corners of the body and enters the right atrium, while the blood that was oxygenated through the work of the lungs returns to the left part of the heart.



**2 ATRIAL SYSTOLE**  
The atria contract to push the blood down toward the ventricles. The right ventricle receives the blood that will have to be sent to the lungs to be oxygenated. The left ventricle receives blood coming from the lungs, which is already oxygenated and must be pumped toward the aorta.

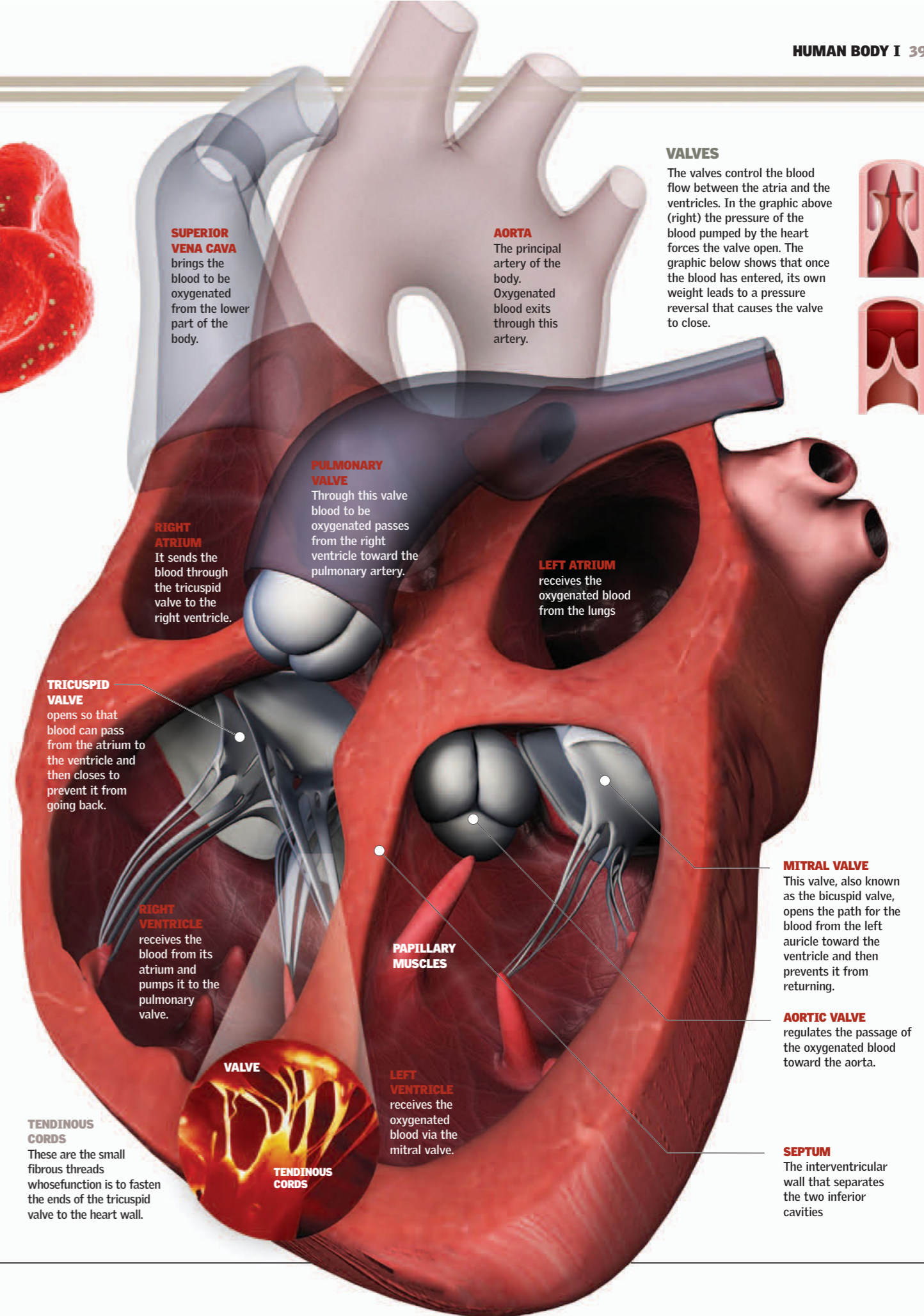


**3 VENTRICULAR SYSTOLE**  
The ventricles contract after a brief pause. The systole, or contraction, of the right ventricle sends impure blood to the lungs. The contraction of the left ventricle pumps the already oxygenated blood toward the aorta; it is ready for distribution throughout the body.



**70**

IS THE APPROXIMATE NUMBER OF TIMES THAT THE HEART BEATS PER MINUTE. IT PUMPS 2,000 GALLONS (8,000 L) OF BLOOD PER DAY.



## VALVES

The valves control the blood flow between the atria and the ventricles. In the graphic above (right) the pressure of the blood pumped by the heart forces the valve open. The graphic below shows that once the blood has entered, its own weight leads to a pressure reversal that causes the valve to close.





# Components of the Blood

The blood is a liquid tissue composed of water, dissolved substances, and blood cells. The blood circulates inside the blood vessels thanks to the impulse it receives from the contraction of the heart. A principal function of the blood is to distribute nutrients to all the cells of the body. For example, the red blood cells (erythrocytes) carry oxygen, which associates with the hemoglobin, a substance in the cell responsible for the blood's red color. The blood also contains white blood cells and platelets that protect the body in various ways. ●

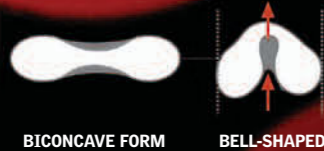
1

## Red Blood Cells

These cells are phantom cells, because all they contain is a large amount of hemoglobin, a protein that has a great affinity for combining with oxygen. The red blood cells, which circulate in the blood, bring oxygen to the cells that need it, and they also remove a small part of the carbon dioxide that the cells are discarding as waste. Because they cannot reproduce themselves, they must be replaced by new red blood cells that are produced by the bone marrow.

### FLEXIBILITY

Red blood cells are flexible and take on a bell shape in order to pass through the thinnest blood vessels.



BICONCAVE FORM

BELL-SHAPED

5 quarts (4.7 l)

THE APPROXIMATE VOLUME OF BLOOD PRESENT IN A HUMAN ADULT

0.0003 INCH (0.008 MM)

## The Blood Groups

Each person belongs to a blood group. Within the ABO system the groups are A, B, AB, and O. Each group is also identified with an antigen, or Rh factor, that is present in the red blood cells of 85 percent of the population. It is of

vital importance to know what blood group a person belongs to so as to give only the right type during a blood transfusion. The immune system, via antibodies and antigens, will accept the body's own blood type but will reject the wrong type.

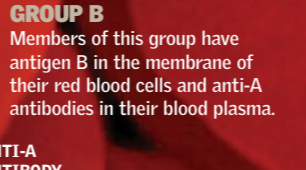
### GROUP A

An individual with red blood cells with antigen A in its membranes belongs to blood group A, and that person's plasma has antibodies against type B. These antibodies recognize red blood cells with antigen B in their membranes as foreign.



### GROUP B

Members of this group have antigen B in the membrane of their red blood cells and anti-A antibodies in their blood plasma.



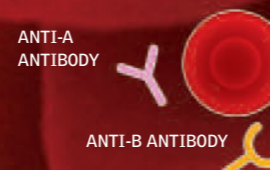### GROUP AB

Members of this group have antigen A and B in the membrane of their red blood cells and no antibodies in their blood plasma.



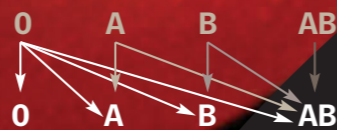
### GROUP O

Members of this group have no antigens in the membranes of their erythrocytes and anti-A and anti-B antibodies in their blood plasma.



### COMPATIBILITY

Donors of group O can give blood to any group, but group AB donors can give only to others with AB blood. The possibility of blood donation depends on the antibodies of the recipient.



0.0003 INCH (0.008 MM)

2

## White Blood Cells, or Leukocytes

This is what a leukocyte, or white blood cell, looks like swimming in blood plasma. They are called white because that is their color when viewed under a microscope.

7%

IS THE PORTION OF BODY WEIGHT REPRESENTED BY THE BLOOD.

### COMPOSITION

GRANULOCYTES	Neutrophils
	Eosinophils
	Basophils
AGRANULOCYTES	Lymphocytes
	Monocytes

## Blood Components

The blood is a tissue, and as such it is characterized by the same type of cells and intercellular substance as tissue. It is distinguished from the rest of the tissues in the human body by an abundance of intercellular material,

which consists primarily of water. The intercellular material, called plasma, is yellow, and it contains abundant nutrients and other substances, such as hormones and antibodies, that take part in various physiological processes.

### COMPONENTS OF THE BLOOD PER 0.00006 cubic inch (1 cu ml)

Red Blood Cells	4 to 6 million
White Blood Cells	4,500 to 11,000
Platelets	150,000 to 400,000
Normal pH	7.40

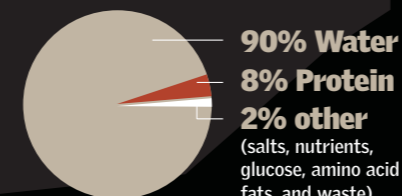
### DAILY PRODUCTION IN MILLIONS

Red Blood Cells	200,000
White Blood Cells	10,000
Platelets	400,000

4

## Plasma

Red and white blood cells and platelets (which contribute to coagulation) make up 45 percent of the blood. The remaining 55 percent is plasma, a fluid that is 90 percent water and the rest various nutrients.



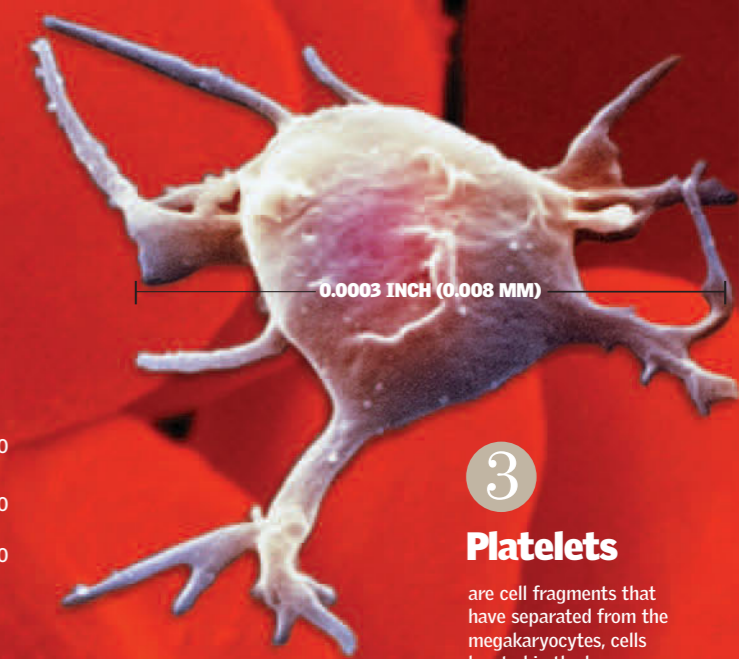
3

## Platelets

are cell fragments that have separated from the megakaryocytes, cells located in the bone marrow. They have a role in blood coagulation. Next to the red blood cells, the platelets are the most abundant component of the blood.

98.6° F (37° C)

THE BLOOD MAINTAINS THE BODY AT THIS AVERAGE TEMPERATURE.





# Lymphatic System

It accomplishes two basic functions: defense against foreign organisms (such as bacteria) and aid with transport of liquid and matter via the circulation of the lymph from the interstices of the tissue and from the digestive apparatus to the blood. About 3 to 4 quarts (2.8-3.7 l) of the liquid circulating in the system do not return. This liquid is known as lymph, and it is reabsorbed into the plasma only through the lymphatic vessels. The lymph contains cells called lymphocytes and macrophages, which are part of the immune system. ●

## Lymphatic Network

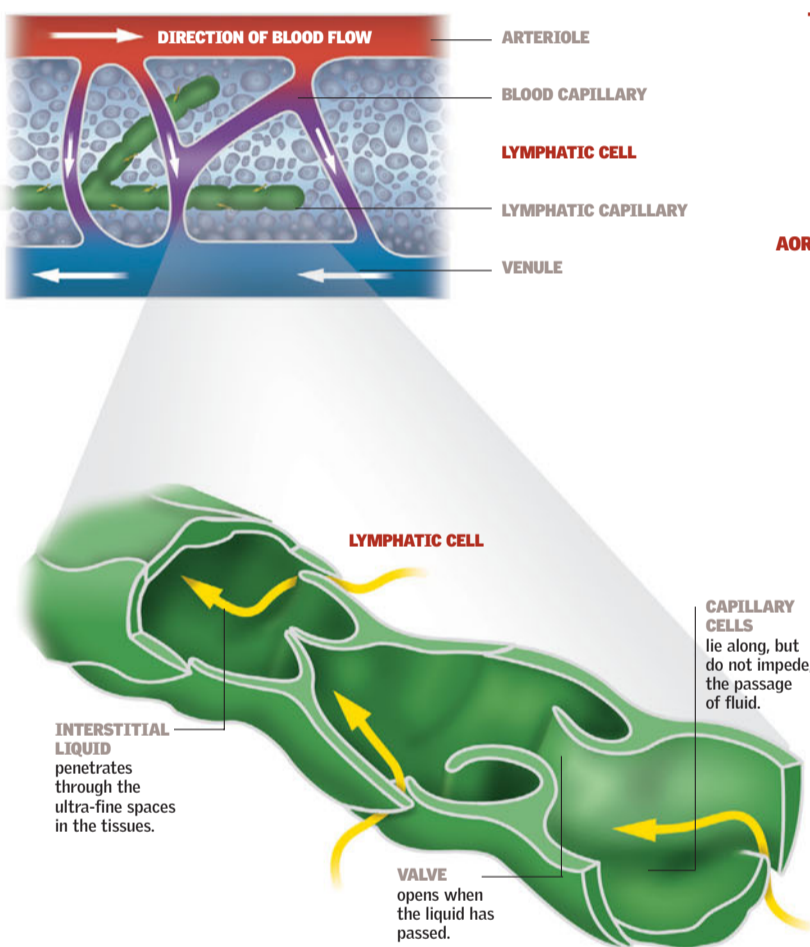
This network contains vessels that extend throughout the body and that filter the liquid that comes from the area surrounding the cells. The lymph circulates in only one direction and returns to the blood through the walls of small blood vessels. There are valves that prevent the lymph from

flowing in the opposite direction. The lymph nodes filter harmful microorganisms from the lymph, which returns via blood vessels to maintain the equilibrium of the body's fluids. Together with the white blood cells, the lymph nodes are in charge of maintaining the immune system.

## Lymphatic Tissue

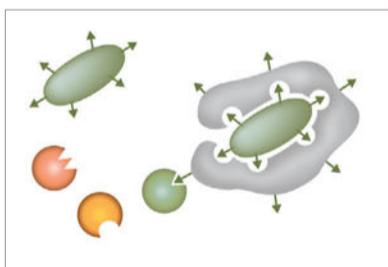
One part of the liquid that exits from blood flow and distributes itself in the body returns only through the action of

the lymphatic tissue, which reabsorbs it via the lymphatic capillaries and returns it to the blood via the lymphatic vessels.

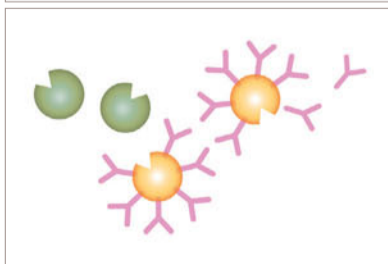


## Immune Response

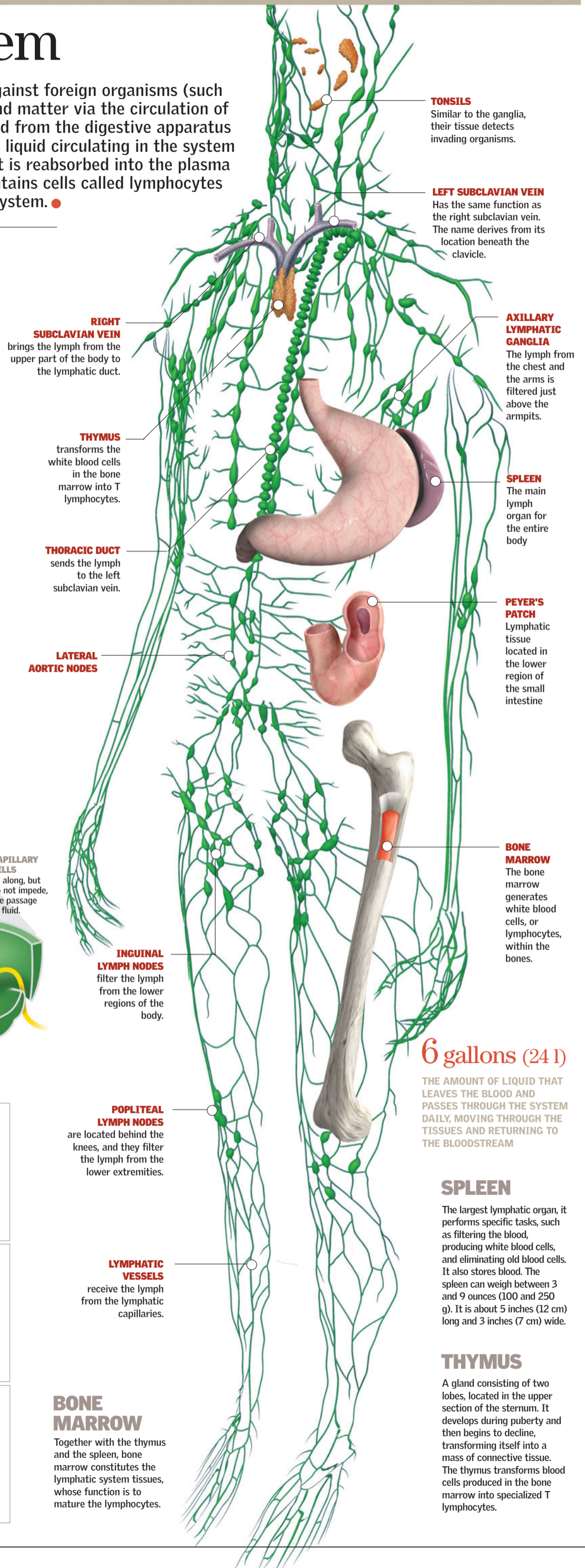
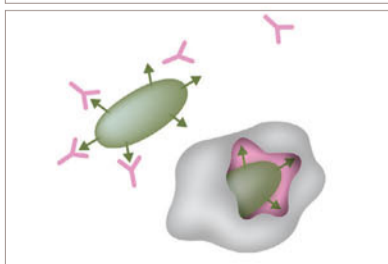
**1** The lymphatic system generates lymphocytes (also found in the blood and in other tissue) and macrophages. Together they constitute the immune system. Here invading bacteria are devoured by a macrophage, and the B lymphocytes take information from the surface of the bacteria that they need to "recognize" other similar bacteria.



**2** The B lymphocytes are activated and upon recognizing a pathogen divide themselves into plasmatic cells and memory cells. The plasmatic cells secrete thousands of antibody molecules per second, which are carried by the blood to the site of the infection. The memory cells retain the antigen information, and, when faced with a new invasion, will once again divide rapidly in order to deal with it.



**3** The antibodies, also called "immunoglobulin," are protein molecules in the form of a "Y," with arms unique to each specific type of antibody. It is this feature that attaches them to a specific antigen. Their function is to "mark" invaders, which can then be destroyed by the macrophages.



## SPLEEN

The largest lymphatic organ, it performs specific tasks, such as filtering the blood, producing white blood cells, and eliminating old blood cells. It also stores blood. The spleen can weigh between 3 and 9 ounces (100 and 250 g). It is about 5 inches (12 cm) long and 3 inches (7 cm) wide.

## THYMUS

A gland consisting of two lobes, located in the upper section of the sternum. It develops during puberty and then begins to decline, transforming itself into a mass of connective tissue. The thymus transforms blood cells produced in the bone marrow into specialized T lymphocytes.

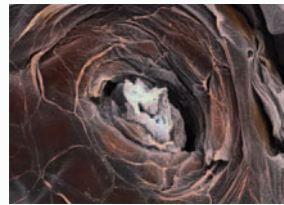


# Lymph Node

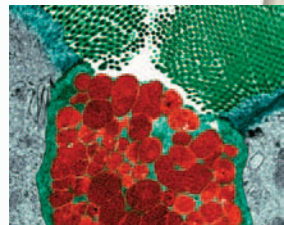
Also called a lymph gland, this node has a round shape and is about 0.4 inch (1 cm) in diameter. Lymph nodes are distributed throughout the body—in the neck, armpits, groin, and popliteal bone (behind the knees), as well as in the thorax and abdomen. The lymphatic vessels are the ducts for the lymph and the pathways for communication among the lymph nodes. The battle of the immune system against invading germs takes place within the nodes, which then enlarge because of inflammation. ●

## Natural Defenses

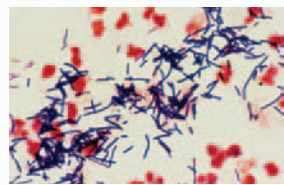
Besides the immune system, composed in part by the lymphatic system, the body has another group of resources called natural defenses, which people possess from birth. The body's first defensive barrier is the skin. If pathogenic agents succeed in passing through its filters, however, both the blood and the lymph possess specialized antimicrobial cells and chemical substances.



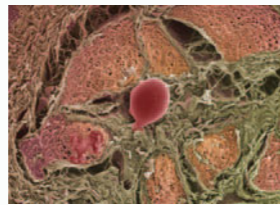
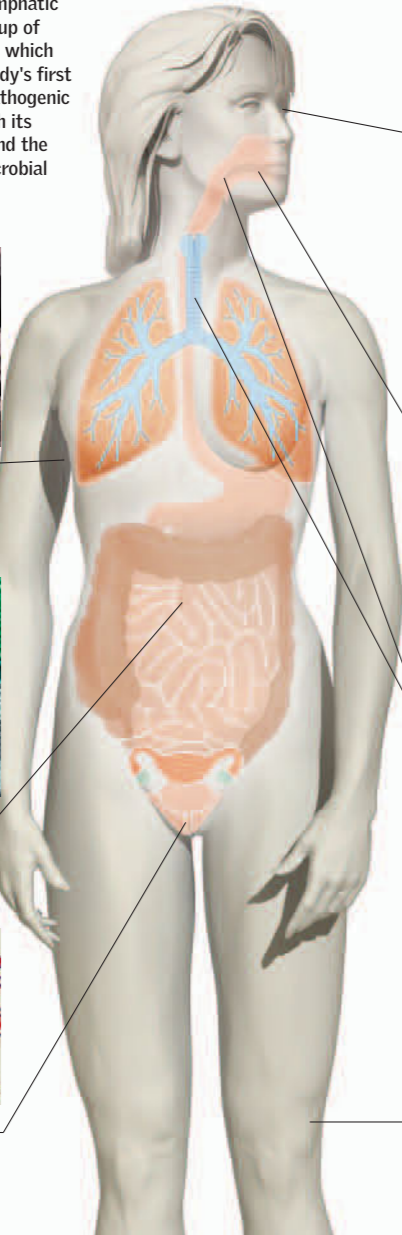
**SEBACEOUS GLAND**  
Located on the surface of the skin, this gland secretes a fatty substance called sebo.



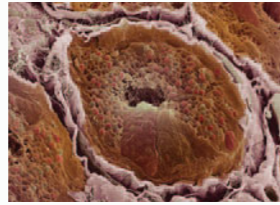
**INTESTINAL MUCOSA**  
The goblet cells in this membrane produce a defensive mucus.



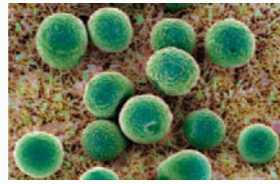
**VAGINAL BACTERIA**  
Under normal conditions, these are inoffensive, and they occupy areas that could be invaded by pathogenic bacteria.



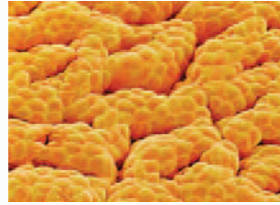
**LACRYMAL GLAND**  
Secretes tears that protect the eyes. Tears, like saliva and perspiration, kill bacteria.



**SALIVARY GLAND**  
produces saliva, which contains bactericidal lysozymes.



**MUCOUS SECRETIONS**  
These secretions, called mucus, form in the upper and lower respiratory tracts, where they capture bacteria and carry them to the throat to be spit out.



**SWEAT GLAND**  
secretes sweat, which helps to control body temperature, to eliminate toxins, and to protect the skin immunologically.

## A Defensive Filter

The glands are covered with a sheath of connective tissue, which in turn forms an interior network that consists of clusters filled with lymphocytes. Their immunological functions are to filter the fluid that arrives via both the sanguine and lymphatic afferent veins, which then goes toward the heart to be returned to circulation via the efferent vessels and to produce immune cells for attacking and removing bacteria and carcinogenic cells.

**100 square inches (600 sq cm)**

THE AREA OF THE SKIN COVERED BY SWEAT GLANDS, A PART OF THE NATURAL DEFENSES THAT COMPLEMENT THE WORK OF THE GANGLIA IN THE IMMUNE SYSTEM

### GERMINAL CENTER

The area that contains B lymphocytes. There are two types: B cells, which produce antibodies, and T cells.

### MACROPHAGES

Together with the lymphocytes, they are the basis of the immune system. They devour the invading bodies that are detected.

### AFFERENT LYMPHATIC VESSEL

The afferent vessels carry the lymphatic liquid from the blood to the ganglia, or lymphatic nodes.

**VALVE**  
regulates the passage of the lymph and prevents its reflux.

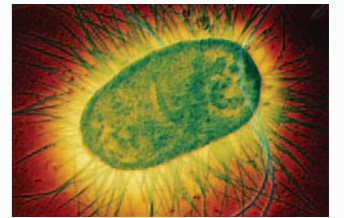**EFFERENT LYMPHATIC VESSEL**  
The conduit for the lymph that exits the ganglia and returns to the bloodstream

**VEIN**

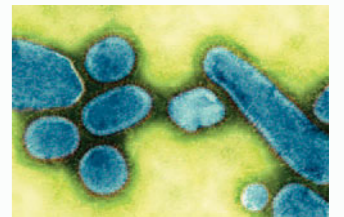
**ARTERY**

**RETICULAR FIBERS**  
The networks that support the lymph nodes

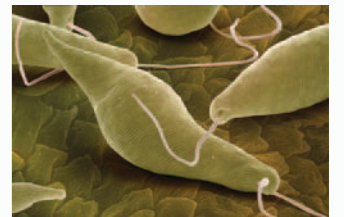**B LYMPHOCYTES**  
acquire their immunological capacity in the bone marrow and in the liver of the fetus.



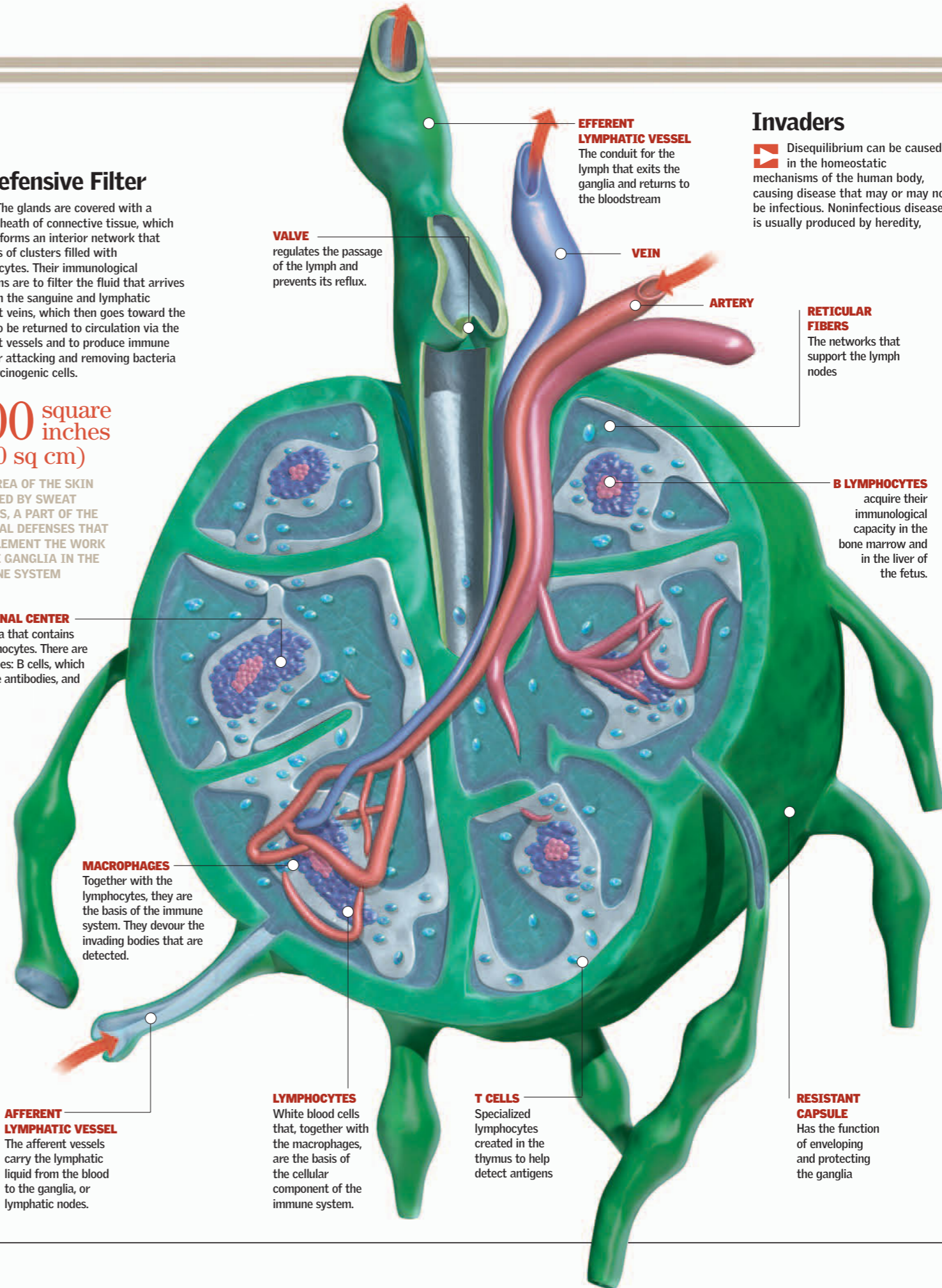
**A BACTERIA**  
are found by the billions in any medium. Not all of them are harmful. Bacteria known as germs are pathogenic and release poisonous substances called toxins.



**B VIRUSES**  
are not really living beings but chemical packages. They consist of genetic material. When they enter the body, they invade a cell, where they reproduce and then spread.



**C PROTOZOA**  
are organisms that typically live in water and in soil. There are about 30 pathogenic species, which can produce a range of diseases from sleeping sickness and severe diarrhea to malaria.



**LYMPHOCYTES**  
White blood cells that, together with the macrophages, are the basis of the cellular component of the immune system.

**T CELLS**  
Specialized lymphocytes created in the thymus to help detect antigens

**RESISTANT CAPSULE**  
Has the function of enveloping and protecting the ganglia

## Invaders

Disequilibrium can be caused in the homeostatic mechanisms of the human body, causing disease that may or may not be infectious. Noninfectious disease is usually produced by heredity,

external factors, or lifestyle. Infections are brought on by parasitic organisms, such as bacteria, viruses, fungi, and protozoa (single-celled organisms belonging to the protist kingdom).

## Red

THE COLOR OF INFLAMED SKIN WHEN BACTERIAL ACTION IN A WOUND CAUSES VASODILATION. THIS OCCURS BECAUSE THE BLOOD VESSELS EXPAND TO INCREASE BLOOD FLOW AS A MEANS OF DEFENSE.



# Respiratory System

The respiratory system organizes and activates respiration, a process by which the human body takes in air from the atmosphere, extracts the oxygen that the circulation will bring to all the cells, and returns to the air products it does not need, such as carbon dioxide. The basic steps are inhalation, through which air enters the nose and mouth, and exhalation, through which air is expelled. Both actions are usually involuntary and automatic. Respiration involves the airway that begins in the nose and continues through the pharynx, larynx, trachea, bronchi, bronchioles, and alveoli; however, respiration occurs primarily in the two lungs, which are essentially bellows whose job it is to collect oxygen from the air. The oxygen is then distributed to the entire body via the blood. ●

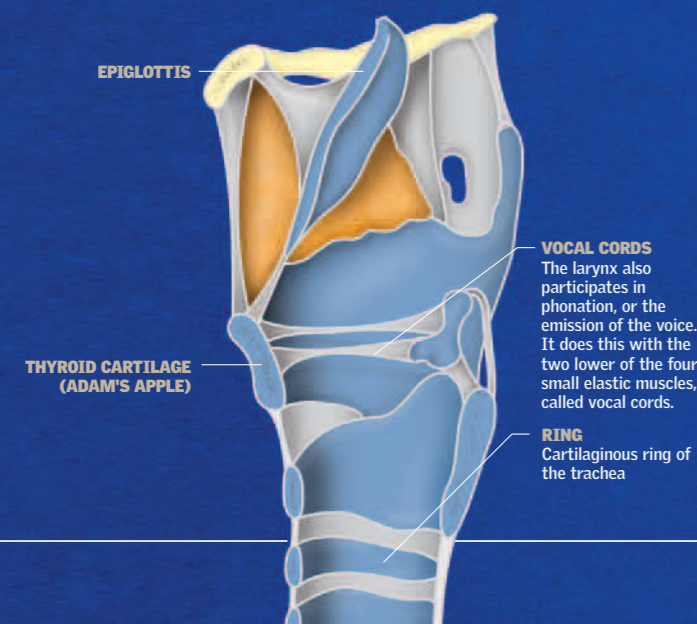
**6 quarts (5.5 l)**  
THE APPROXIMATE VOLUME OF AIR THAT ENTERS AND EXITS THE LUNGS DURING ONE MINUTE OF BREATHING

**15**  
WE NORMALLY BREATHE BETWEEN 15 AND 16 TIMES A MINUTE.

## Larynx

The resonance box that houses the vocal cords; it consists of various components of cartilaginous tissue. One of these components can be identified externally: it is the Adam's apple, or thyroid cartilage, located in the middle of the throat. The larynx is important

for respiration because it links the pharynx with the trachea and ensures the free passage of air entering and leaving the lungs. It closes the epiglottis like a door when the organism is ingesting food in order to prevent food from entering the airway.



## WHAT ENTERS AND WHAT EXITS

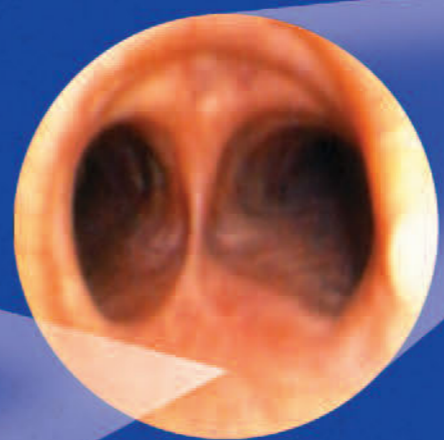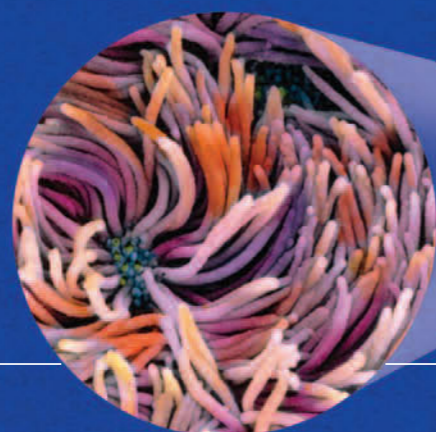
Component	Percentage in Inhaled Air	Percentage of Exhaled Air
Nitrogen	78.6	78.6
Oxygen	20.8	15.6
Carbon Dioxide	0.04	4
Water Vapor	0.56	1.8
<b>Total</b>	<b>100</b>	<b>100</b>

## Route

- 1 The air enters the nasal cavity, where it is heated, cleaned, and humidified (it also enters through the mouth).
- 2 The air passes through the pharynx, where the tonsils intercept and destroy harmful organisms.
- 3 The air passes through the larynx, whose upper part, the epiglottis, a cartilaginous section, prevents food from passing into the larynx when swallowing. From the larynx the air goes into the esophagus.
- 4 The air passes through the trachea, a tube lined with cilia and consisting of rings of cartilage that prevent its deformation. The trachea transports air to and from the lungs.
- 5 In the thoracic region the trachea branches into two bronchi, which are subdivided into smaller branches, the bronchioles, which in turn carry the air to the pulmonary alveoli, elastic structures shaped like sacs where gas exchange occurs.
- 6 From the alveoli the oxygen passes into the blood and then from the blood to the tissues of the body. The carbon dioxide exits the bloodstream and travels toward the alveoli to be subsequently exhaled. Exhaled air contains more carbon dioxide and less oxygen than inhaled air.

## HAIRS

The interior of the trachea is covered with hairs (cilia), which, like the hairs in the nose, capture dust or impurities carried by the air.



## RESPIRATORY PROCESS

1

2

3

4

5

6

**TRACHEA**  
The great respiratory pathway between the larynx and the bronchi

**LUNGS**  
Two organs that take oxygen from the air

**PHARYNX**  
The muscular tract in the neck. Food and air pass through it.

**LARYNX**  
A pharynx and trachea. It participates in phonation.

**TRACHEA**  
The great pathway for incoming air, which divides into the two smaller bronchial tubes going to the lungs

**BRONCHI**  
Two fibrous cartilaginous tubes, which begin in the trachea and terminate in the lungs

Legend  
**OXYGENATED BLOOD**  
**DEOXYGENATED BLOOD**

**DIAPHRAGM**  
Membrane primarily consisting of muscular fiber that separates the thoracic cavity from the abdominal cavity

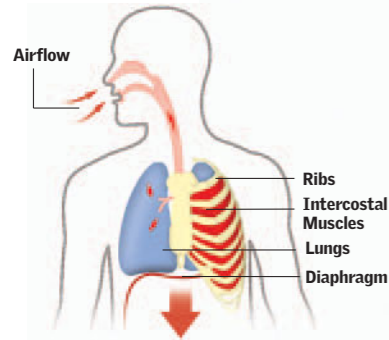


# Lungs

Their principal function is to exchange gases between the blood and the atmosphere. Inside the lungs, oxygen is taken from the air, and carbon dioxide is returned to the air. There are two lungs. The left lung has two lobes and one lingula, and it weighs approximately 30 ounces (800 g); the right lung has three lobes and weighs 35 ounces (1,000 g). Both lungs process the same amount of air. In men each lung has a capacity of 3 quarts (3.2 l), and in women, 2 quarts (2.1 l). The lungs fill most of the space in the thoracic cage surrounding the heart. Their major motions are inhalation (taking in air) and exhalation (expulsion). The pleural membranes, intercostal muscles, and diaphragm make this mobility possible. ●

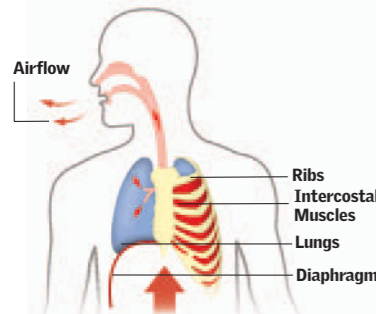
## Inhalation

The air enters. The diaphragm contracts and flattens. The external intercostal muscles contract, lifting the ribs upward. A space is created within the thorax into which the lungs expand. The air pressure in the lungs is less than that outside the body, and therefore air is inhaled.



## Exhalation

The diaphragm relaxes and becomes dome-shaped. The external intercostal muscles relax. The ribs move downward and inward. The space within the thorax decreases, and the lungs are compressed. The air pressure within the lungs is greater than that outside of the body, and therefore the air is exhaled.



## A Marvelous Pump

The respiratory system accomplishes its functions by combining a series of involuntary and automatic movements. The lungs, opening and closing like bellows, make inhalation possible by increasing their capacity to take in air, which is then exhaled when the bellows close. Inside the lungs the first stage of processing the gases that came in through the nose and the trachea is accomplished. Once the exchange of oxygen to be absorbed and carbon dioxide to be expelled occurs, the next stages can be accomplished: transport of the gases and delivery of oxygen to the cells and tissues.

**30,000**

THE NUMBER OF BRONCHIOLES, OR TINY BRANCHINGS OF THE BRONCHI, IN EACH LUNG

**350 million**

THE NUMBER OF ALVEOLI IN EACH LUNG (700 MILLION FOR BOTH TOGETHER)

**PLEURAL MEMBRANES** are primarily muscular and allow the lungs to move within the rib cage.

**TRACHEA**  
The trachea is reinforced with C-shaped pieces of cartilage.

**PULMONARY ARTERY**  
The only blue artery. The oxygen-poor blood goes from the right side of the heart to the lungs to pick up oxygen.

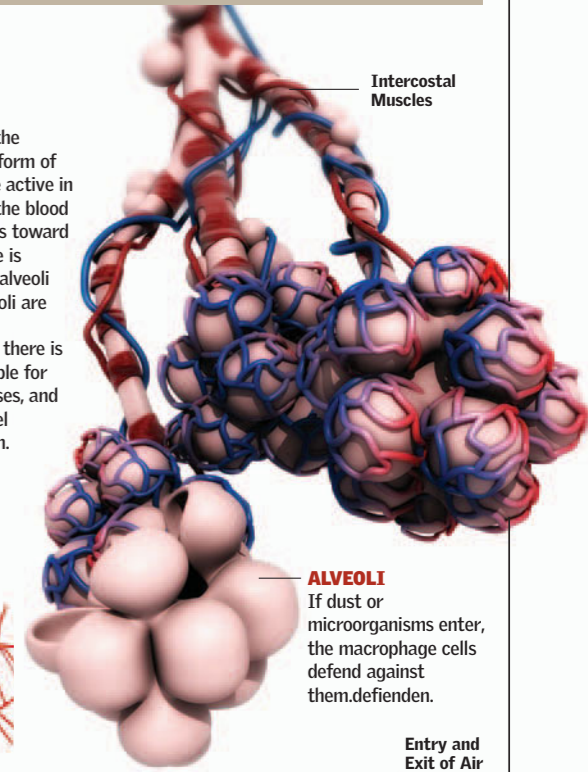
**AORTAL ARTERY**  
Recharged with oxygen from the lungs, the blood returns to the heart and then circulates through the entire body.

## BRONCHIAL TREE

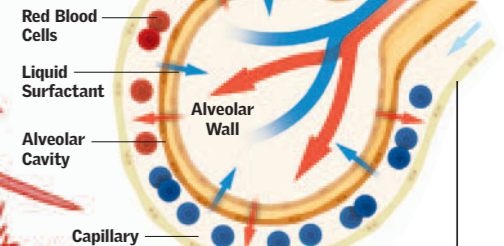
The complex of tubes that bring air to and from the lungs. They diminish in size from the trachea and subdivide into bronchioles and alveoli.

## Alveoli

Hollow structures that terminate in the bronchioles. They store air, have the form of a globe or cluster of bubbles, and are active in gas exchange. The oxygen comes to the blood via the alveolar walls and then passes toward the capillary network. Carbon dioxide is transferred from the blood to the alveoli and is then exhaled. If the alveoli are damaged as the result of a pulmonary disorder, then there is less surface area available for the interchange of gases, and the person might feel shortness of breath.



## HOW IT WORKS



- 1 The alveolar cavity fills with air. The red arrows indicate the direction the oxygen travels toward the red blood cells and then on toward the heart and the rest of the body.
- 2 The blue indicates the direction the carbon dioxide travels to the red blood cells and the plasma from the heart so that the alveolar can return it to the lungs.
- 3 The complete operation of exchange is hematosis. The carbon dioxide will be returned to the lungs by the venae cavae and exhaled.

**BRONCHI**  
One for each lung; the two great pathways into which the trachea is divided

**BRONCHIOLES** are thinner than a human hair. They secrete mucus.



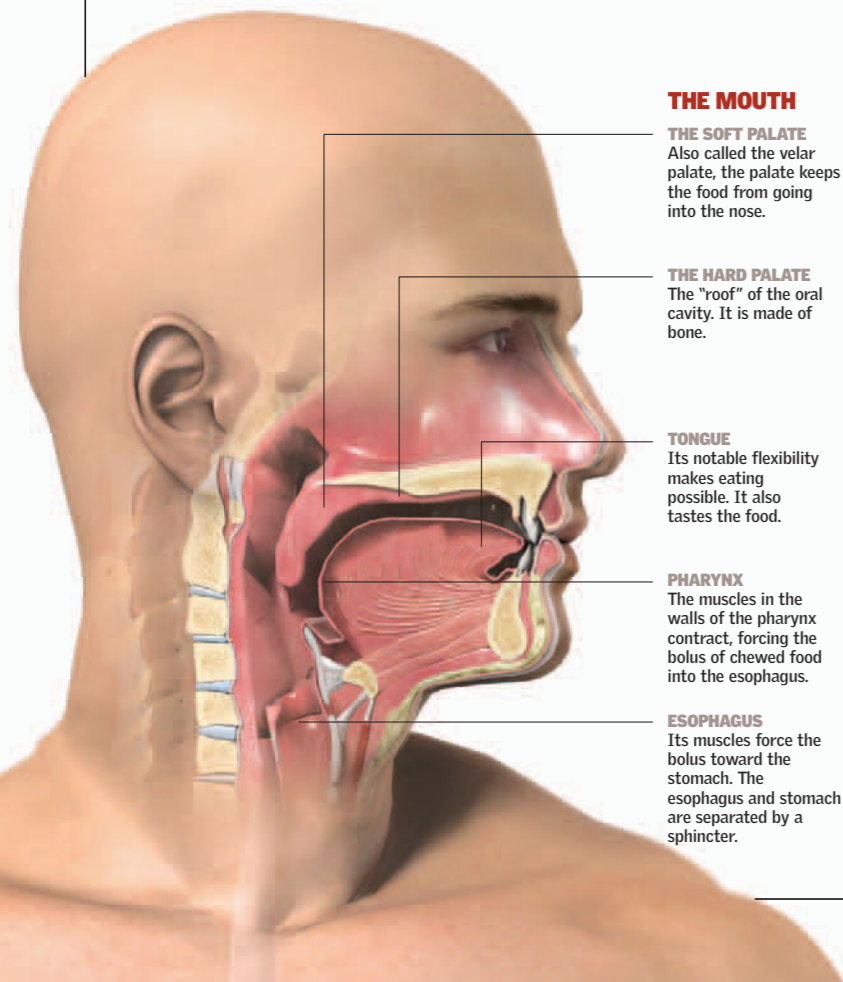
# Digestive System

The digestive system is the protagonist of a phenomenal operation that transforms food into fuel for the entire body. The process begins with ingestion through the mouth and esophagus and continues with digestion in the stomach, the small intestine, and the large intestine, from which the feces are evacuated by the rectum and anus. By then the task will have involved important chemical components, such as bile, produced by the liver, and other enzymes, produced by the pancreas, by which the food is converted into nutrients. Separating the useful from the useless requires the filtering of the kidneys, which discard the waste in urine. ●

## The First Step: Ingestion

The digestive process begins with the mouth, the entry point to the large tract that changes in form and function and ends at the rectum and anus. The tongue and teeth are the first specialists in the task. The tongue is in charge of tasting and positioning the food,

which is cut and ground by the teeth. This synchronized activity includes the maxillary bones, which are controlled by their corresponding muscles. The palate, in the upper part of the mouth, prevents food from passing into the nose. The natural route of the food is down the esophagus to the stomach.



### THE MOUTH

**THE SOFT PALATE**  
Also called the velar palate, the palate keeps the food from going into the nose.

**THE HARD PALATE**  
The "roof" of the oral cavity. It is made of bone.

**TONGUE**  
Its notable flexibility makes eating possible. It also tastes the food.

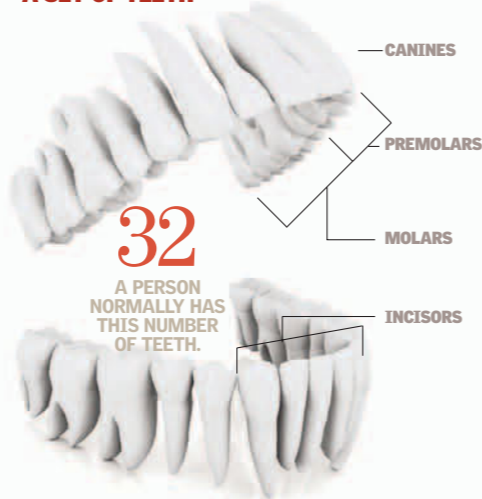
**PHARYNX**  
The muscles in the walls of the pharynx contract, forcing the bolus of chewed food into the esophagus.

**ESOPHAGUS**  
Its muscles force the bolus toward the stomach. The esophagus and stomach are separated by a sphincter.

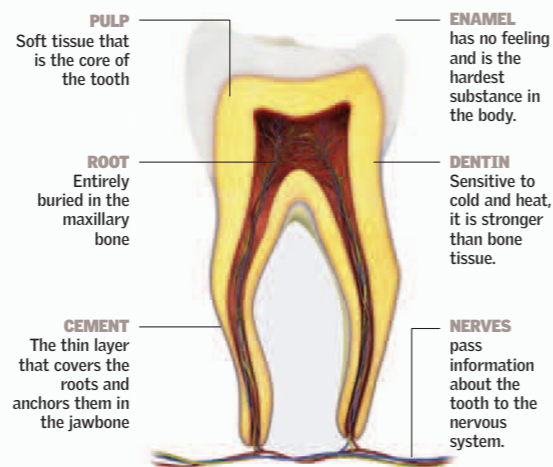
## Teeth

There are 32 teeth, and they are extremely hard, a condition necessary for chewing food. There are eight incisors, four canines, eight premolars, and 12 molars. Humans develop two sets of teeth, a provisional or temporary set (the baby teeth) and a permanent set (adult teeth). The first temporary teeth appear between six and 12 months of age. At 20 years of age the process of replacement that began at about age five or six is complete.

### A SET OF TEETH



### THE INSIDE OF A TOOTH



## Enzymes and Hormones

The complex chemical processes that transform food are essentially accomplished by enzymes and hormones. Both types of substances are secreted by various glands of the digestive system, such as the salivary glands. Enzymes are substances that act as catalysts. Hormones are substances that regulate processes such as growth metabolism, reproduction, and organ function.

## Digestion Chronology

The process that converts food into nutrients begins a few seconds after the food is raised to the mouth and chewing begins. The average digestion time is about 32 hours, though digestion can range from 20 to 44 hours.

### 1 00:00:00

The process begins when the food reaches the mouth. The entire organism is involved in the decision, but it is the digestive system that plays the main role. The first steps are taken by the teeth and the tongue, aided by the salivary glands, which provide saliva to moisten the alimentary bolus. The morsels are chewed so that they can pass through the esophagus.

### 2 00:00:10

About 10 seconds after chewing has begun, the food is transformed into a moist alimentary bolus that makes its way through the pharynx to the esophagus and then to the stomach, where other changes will take place.

### 3 03:00:00

Three hours after its arrival, the food leaves the stomach, which has accomplished its function. The first phase of digestion is over. The bolus now has a liquid and creamy consistency.

### 4 06:00:00

Three hours later, the food that has been digested in the stomach arrives at the midpoint of the small intestine. At this point it is ready to be absorbed.

### 5 08:00:00

Two hours later, the non-digested, watery residue arrives at the junction of the small and large intestines. The useless material rejected by the body's chemical selectors continues its course, and it is now prepared to be expelled from the organism in the form of feces.

### 20:00:00

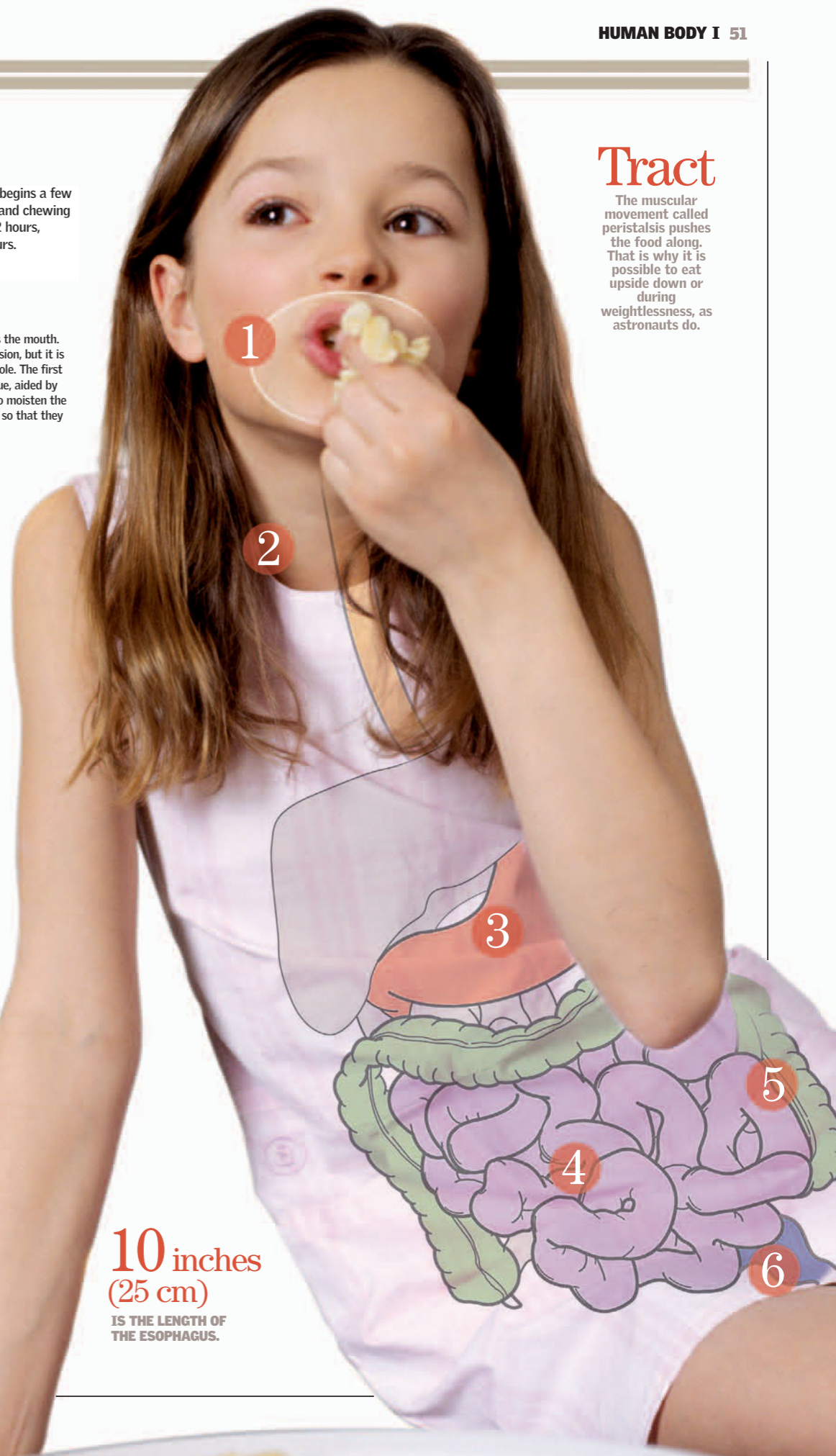The alimentary residue remains in the large intestine between 12 and 28 hours. In this part of the process the residue is converted into semisolid feces.

### 6 24:00

Between 20 and 44 hours after having entered the mouth as food, the residue that was converted into semisolid feces in the previous stage arrives at the rectum. The waste will be evacuated through the anus as excrement.

## Tract

The muscular movement called peristalsis pushes the food along. That is why it is possible to eat upside down or during weightlessness, as astronauts do.



**10 inches (25 cm)**  
IS THE LENGTH OF THE ESOPHAGUS.

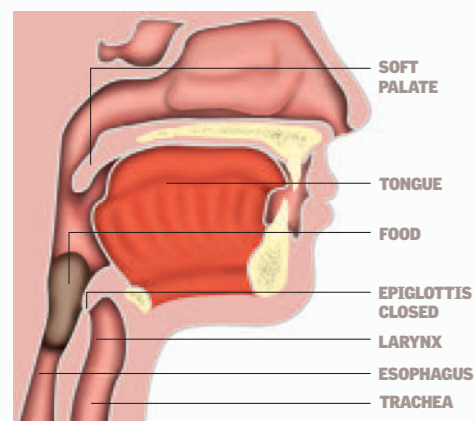
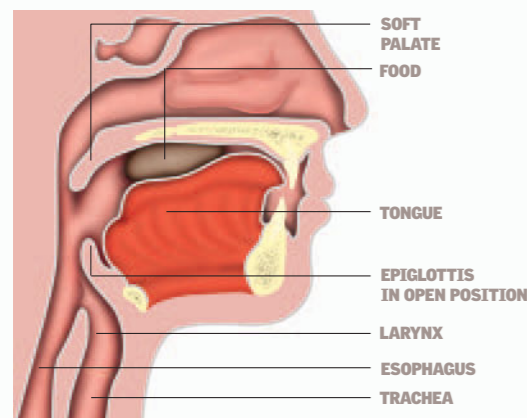


# Stomach

The part of the digestive tract that is a continuation of the esophagus. It is sometimes thought of as an expansion of the esophagus. It is the first section of the digestive system that is located in the abdomen. It has the shape of an empty bag that is curved somewhat like a bagpipe, the handle of an umbrella, or the letter "J." In the stomach, gastric juices and enzymes subject the swallowed food to intense chemical reactions while mixing it completely. The stomach connects with the duodenum through the pylorus. Peristalsis, or the muscular contractions of the alimentary canal, moves the food from the stomach to the duodenum, the next station in the progress of the alimentary bolus. ●

## How We Swallow

Although swallowing is a simple act, it does require the coordination of multiple parts. The soft palate moves backward when the alimentary bolus passes through the esophagus. The epiglottis moves downward to close the trachea and prevent the food from entering the respiratory pathways. The alimentary bolus is advanced by the muscular motions of peristalsis.



## X-ray of the Stomach

The stomach is the best known of the internal body organs, but it is also the most misunderstood. This J-shaped sac stretches to fill up with food, but it does not absorb any of the nutrients. Its work consists of starting the digestion process, storing semi-digested food, and releasing the food slowly and continuously. Internal gastric juices make it possible for the enzymes to decompose the proteins, while muscular contractions mix the food.

**PYLORUS**  
A muscular ring that opens and closes the pyloric sphincter to allow (or prevent) passage of liquefied food from the stomach on its way to the intestine

**STOMACH WALL**  
A covering of three muscular layers that contract in different directions to mash the food. It contains millions of microscopic glands that secrete gastric juices.

**WRINKLES OR FOLDS**  
are formed when the stomach is empty, but they stretch out as the stomach fills and increases its size.

**DUODENUM**  
The initial section of the small intestine

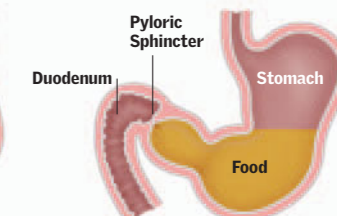
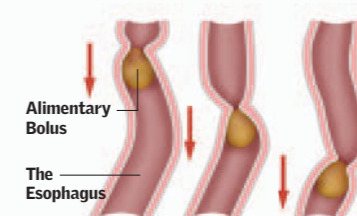
**ESOPHAGUS**  
carries chewed food to the stomach.

**INFERIOR ESOPHAGEAL SPHINCTER**  
closes the junction between the esophagus and the stomach to prevent reflux of the stomach contents.

## Peristalsis: Muscles in Action

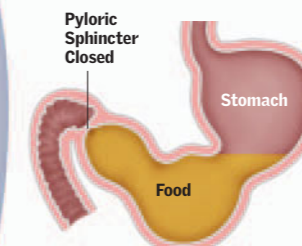
Peristalsis is the group of muscular actions that moves the food toward the stomach and, once the digestive stage has been completed, moves it on to the

small intestine. The sphincters are stationary, ring-shaped muscular structures whose opening and closing regulates the passage of the bolus.

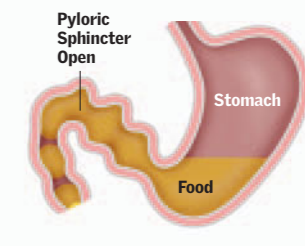


Food is sent toward the stomach, pumped by the muscular contractions of the esophageal walls. Gravity helps accomplish this downward journey.

Full stomach. Food enters. The pyloric sphincter remains closed. The gastric juices kill bacteria and are mixed with the food through muscular motions.



The stomach in full digestive action. The peristaltic muscles mix the food until it becomes a creamy, viscous liquid (chyme).



The stomach is being emptied. The pyloric sphincter relaxes, the muscles move the food, and small quantities of food exit toward the duodenum.

## Stomach Wall

The structure of the wall accounts for the two important functions of the stomach: the muscular layers and the activity of the gastric glands guarantee that digestion will run its course.

**GASTRIC MUCOSA**  
contains the gastric glands, which produce 3 quarts (2.8 l) of gastric juice per day.

**MUSCULAR LAYERS OF THE MUCOSA**  
Two fine layers of muscular fibers extend under the mucosa.

**GASTRIC WELLS**  
From three to seven glands open to form a groove.

**SUBMUCOSA**  
Tissue that connects the mucosa to the layers of muscle


**THREE LAYERS OF MUSCLE**  
They are the circular, the longitudinal, and the oblique.

**SUBSEROZA**  
Layer that connects the serosa to the muscles

**SEROSA**  
Layer that covers the outer surface

**GLÁNDULAS GÁSTRICAS**

**20 times**  
THE STOMACH INCREASES UP TO 20 TIMES ITS ORIGINAL SIZE AFTER A PERSON EATS.





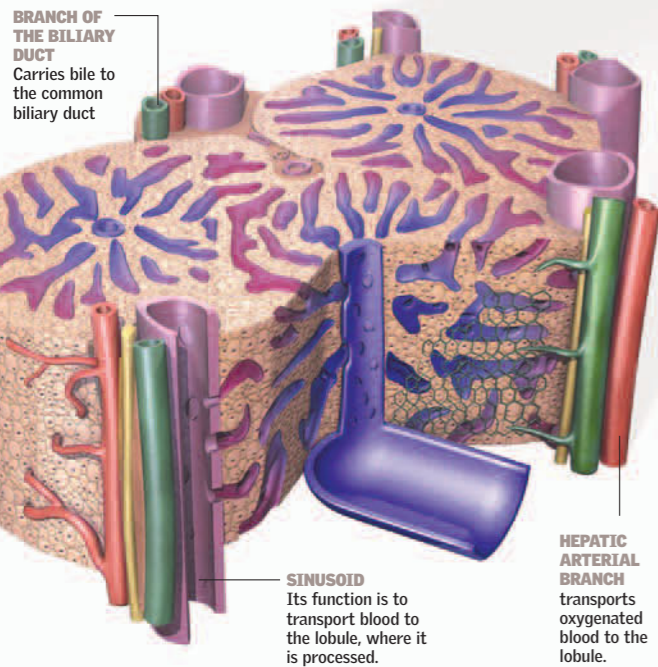
# Liver, Pancreas, Bile

The liver is the largest gland of the human body and the second largest organ (the skin is the largest). It has numerous functions, and a large part of the body's general equilibrium depends on it. The liver produces bile, a yellowish-green fluid that helps in the digestion of fats. The liver is the great regulator of the glucose level of the blood, which it stores in the form of glycogen. Glycogen can be released when the organism requires more sugar for activity. The liver regulates the metabolism of proteins. Proteins are the essential chemical compounds that make up the cells of animals and plants. The liver is also a large blood filter and a storage site for vitamins A, D, E, and K. The pancreas is a gland that assists in digestion, secreting pancreatic juice. ●

## Lobules

Among its other functions, the liver processes nutrients to maintain an adequate level of glucose in the blood. This task requires hundreds of chemical processes that are carried out by the hepatocytes, or liver cells. These are

arranged in columns, forming structures called lobules. They produce bile and a sterol (a solid steroid alcohol) called cholesterol. They also eliminate toxins that might be present in food.



## Vesicle and Bile

The biliary system stores bile that is produced by the hepatocytes in a specialized pouch called the gallbladder. The path the bile takes from the liver to the gallbladder leads through little canals, biliary ducts, and hepatic

ducts, whose diameter increases as the bile moves along. When the body ingests fat, the bile is sent from the gallbladder to the small intestine to accomplish its main function: emulsifying fats to help promote their later absorption.

## Liver

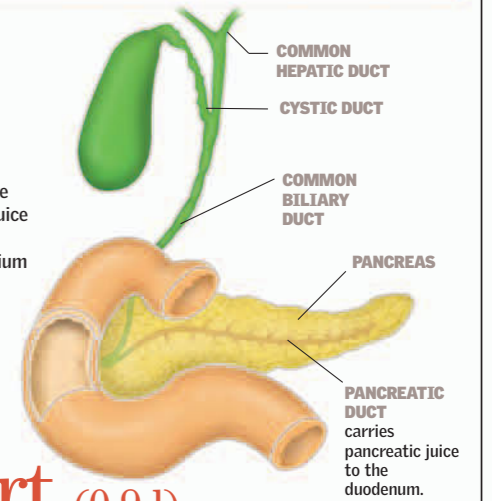
Among its numerous functions, the liver rids the blood of potentially harmful chemical substances, such as drugs and germs. It filters out toxins, starting in the small intestine, and it is involved in maintaining the equilibrium of proteins, glucose, fats, cholesterol, hormones, and vitamins. The liver also participates in coagulation.

**GALLBLADDER**  
stores bile produced by the liver.

**ESOPHAGUS**  
brings food to the stomach.

## Pancreas

The pancreas is a gland that accomplishes various functions. Its exocrine component secretes pancreatic juice into the duodenum to aid in digestion. This juice contains enzymes that break down fats, proteins, and carbohydrates. It contains sodium bicarbonate, which neutralizes the strong stomach acid. The pancreas also performs a function in the endocrine system: it secretes the hormone insulin into the blood, where it regulates glucose levels.



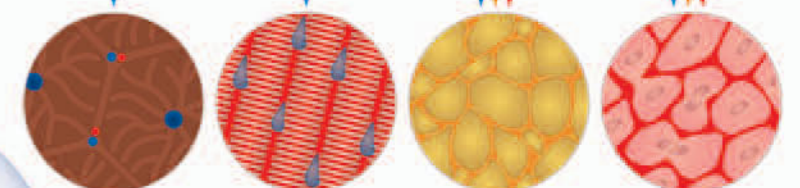
**1 quart (0.9 l)**

THE AMOUNT OF BILE THE LIVER CAN PRODUCE IN A DAY. THE LIVER IS THE HEAVIEST INTERNAL ORGAN OF THE BODY.

## Metabolism

The complex of chemical reactions that occur in the cells of living beings, transforming simple substances into complex substances and vice versa. When the nutrients are absorbed into the bloodstream and passed to the liver, the liver breaks down proteins into amino acids, fats into fatty acids and glycerol, and carbohydrates into smaller components. A normal diet includes carbohydrates, proteins, fats, vitamins, and minerals.

**ENERGY**  
The body's cells basically obtain their energy from the breakdown of glucose stored in the liver. When no glucose is available, the body turns to fatty acids for energy.



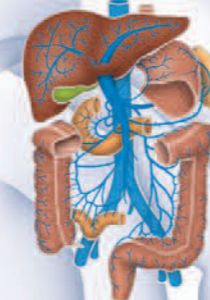
**HEPATIC TISSUE**  
Excess glucose in the organism is stored as glycogen in the cells of the liver.

**MUSCULAR FIBER**  
Muscle cells in the liver together with the hepatic cells store glycogen.

**ADIPOSE CELLS**  
are cells in which the organism stores excess fatty acids in the form of fat.

**CELLULAR GROWTH AND REPAIR**  
Amino acids are converted into proteins by a process called anabolism. Proteins are fundamental for mitosis, cellular regeneration, and enzyme production.

**THE CONNECTION**  
The esophagus, stomach, gallbladder, spleen, and small intestine are linked functionally and by their position in the body. They constitute the great crossroads of digestion.



**DUODENUM**  
The initial part of the small intestine

**SPLEEN**  
The spleen has a double function. It is part of the immune defense system, and it destroys defective red blood cells.

**PANCREAS**  
releases pancreatic juice, which contains digestive enzymes.

**PANCREATIC DUCT**

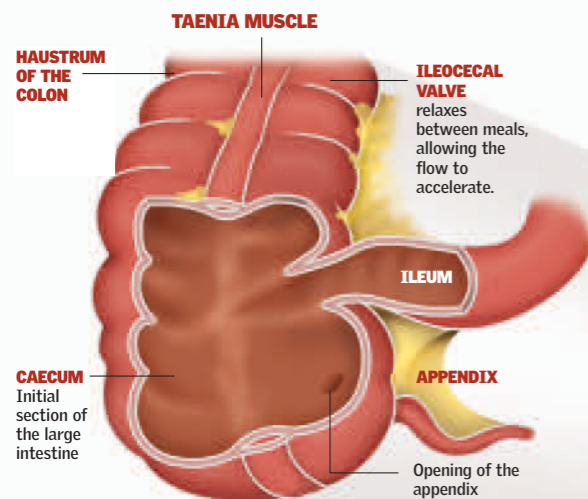


# Large and Small Intestine

The longest part of the digestive tract. It is about 26 to 30 feet (8 to 9 m) long and runs from the stomach to the anus. The small intestine receives the food from the stomach. Digestion continues through enzyme activity, which completes the chemical breakdown of the food. Then the definitive process of selection begins: the walls of the small intestine absorb the nutrients derived from the chemical transformation of the food. The nutrients then pass into the bloodstream. Waste substances, on the other hand, will go to the large intestine. There the final stage of the digestive process will occur: the formation of the feces to be excreted. ●

## The Union of Both

The small and large intestines join at the section called the ileum (which is the final section of the small intestine; the duodenum and jejunum come before the ileum). The ileac valve acts as a door between the small intestine and large intestine, or colon. The ileum terminates in the caecum (of the large intestine). The ileum measures approximately 13 feet (4 m) in length. Its primary function is the absorption of vitamin B12 and biliary salts. The primary function of the large intestine is the absorption of water and electrolytes that arrive from the ileum.



### WATER THAT ENTERS THE ALIMENTARY CANAL

In fluid ounces	
Saliva	34 (1 l)
Water from Drinking	77 (2.3 l)
Bile	34 (1 l)
Pancreatic Juice	68 (2 l)
Gastric Juice	68 (2 l)
Intestinal Juice	34 (1 l)
<b>Total</b>	<b>313 (9.3 l)</b>

### WATER REABSORBED BY THE ALIMENTARY CANAL

In fluid ounces	
Small Intestine	280 (8.3 l)
Large Intestine	30 (0.9 l)
Subtotal	310 (9.2 l)
Water Lost in the Feces	3 (0.1 l)
<b>Total</b>	<b>313 (9.3 l)</b>

**CAECUM** Initial section of the large intestine

**ASCENDING COLON** The water and mineral salts are absorbed along the length of the large intestine in a process that removes water from the digestive waste.

**DUODENUM** The initial section of the small intestine, to which the secretions of the pancreas and the liver are directed

**ILEUM** Final section of the small intestine, linked with the large intestine

**ANUS** Opening in the large intestine through which the feces exit

**RECTUM** The final point of the accumulation of the feces. Its storage capacity is small.

**SIGMOID COLON** contains a structure that permits the gases to pass without pushing the feces.

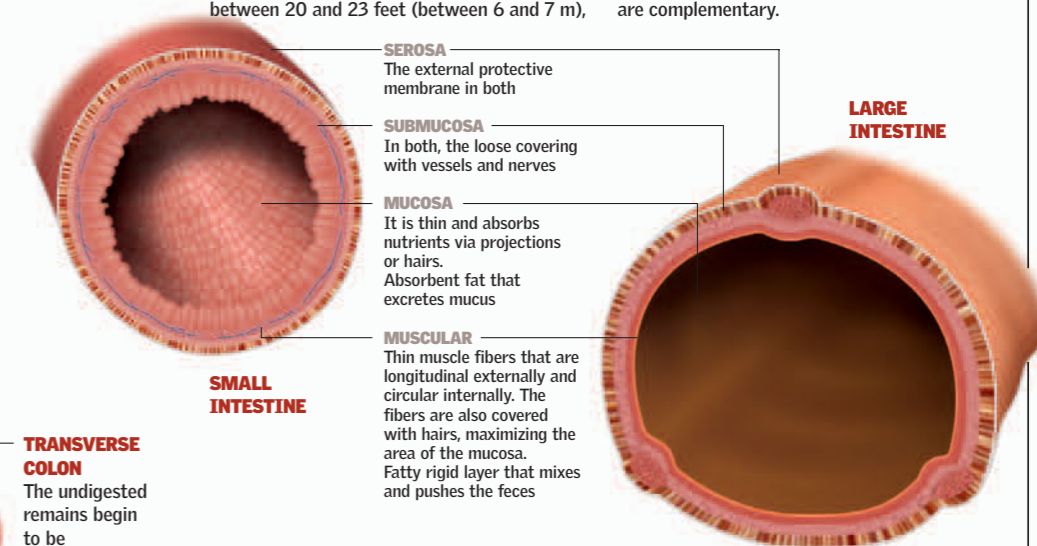
**JEJUNUM** The intermediate part of the small intestine, which links the duodenum with the ileum

**TRANSVERSE COLON** The undigested remains begin to be transformed into feces.

**DESCENDING COLON** The feces are solidified and accumulate before being expelled.

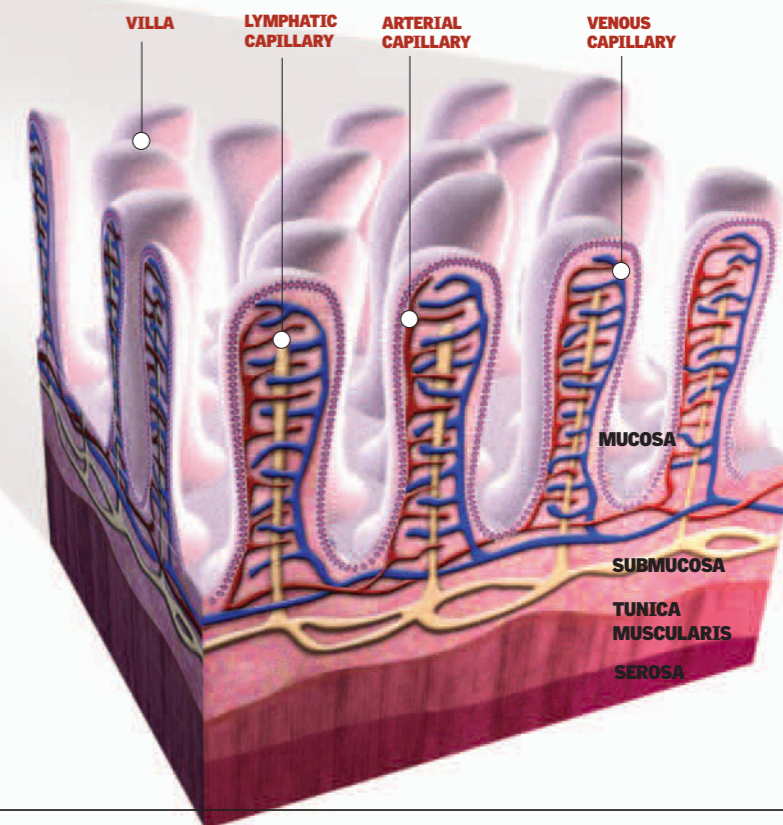
## Differences and Similarities

The small intestine is longer than the large intestine. The length of the small intestine is between 20 and 23 feet (between 6 and 7 m), and the large intestine averages 5 feet (1.5 m). Their respective composition and functions are complementary.



## Villa

The internal wall of the small intestine is covered with millions of hairlike structures called villi. Each one has a lymphatic vessel and a network of vessels that deliver nutrients to it. Each villus is covered by a cellular layer that absorbs nutrients. Together with epithelial cells, the villi function to increase the surface area of the intestine and optimize the absorption of nutrients.





# Urinary System

Its basic organs are the kidneys (2), the ureters (2), the bladder, and the urethra. Its function is to regulate homeostasis, maintaining the equilibrium between the water and the chemicals in the body. The first phase of this objective is accomplished when the kidneys produce and secrete urine, a liquid that is eliminated from the body. Urine is essentially harmless, only containing about 2 percent urea, and is sterile: it is composed primarily of water and salts, and it normally does not contain bacteria, viruses, or fungi. The ureters are channels that carry the urine through the body. The bladder is a sac that stores the urine until it is passed to the urethra, a duct through which it will be expelled from the body. ●

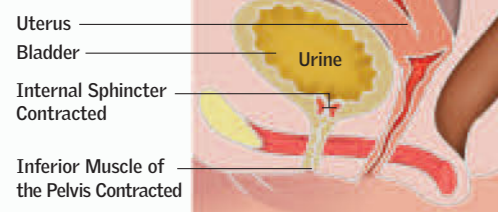
## The Urinary Tract

The glomerulus is a grouping of vessels located in the cortex of the kidneys. Most of the filtering that takes place in the nephron is performed in the glomerulus. Wide arterioles carry blood to the glomerulus. Other, thinner arterioles exit from the glomerulus, carrying away blood. So much pressure is generated inside the kidney that the fluid exits from the blood via the porous capillary walls.

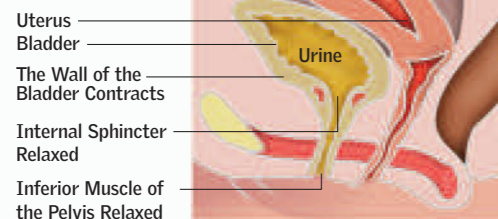
## The Bladder in Action

The bladder is continually filled with urine and then emptied periodically. When full, the bladder stretches to increase its capacity. When the muscle of the internal sphincter is relaxed, the muscles of the wall contract, and the urine exits through the urethra. In adults this occurs voluntarily in response to an order issued by the nervous system. In infants, on the other hand, this evacuation occurs spontaneously, as soon as the bladder is filled.

### FILLING



### EMPTYING



## Legend

### 1. BLOOD FILTERING

The blood enters the kidney via the renal artery.

### 2. TRANSFER

The artery carries the blood into the kidney, where it is filtered by the kidney's functional units, the nephrons.

### 3. STORAGE

A certain amount of urine is obtained from the filtrate in the nephrons, and that urine is sent to the renal pelvis.

### 4. ELIMINATION

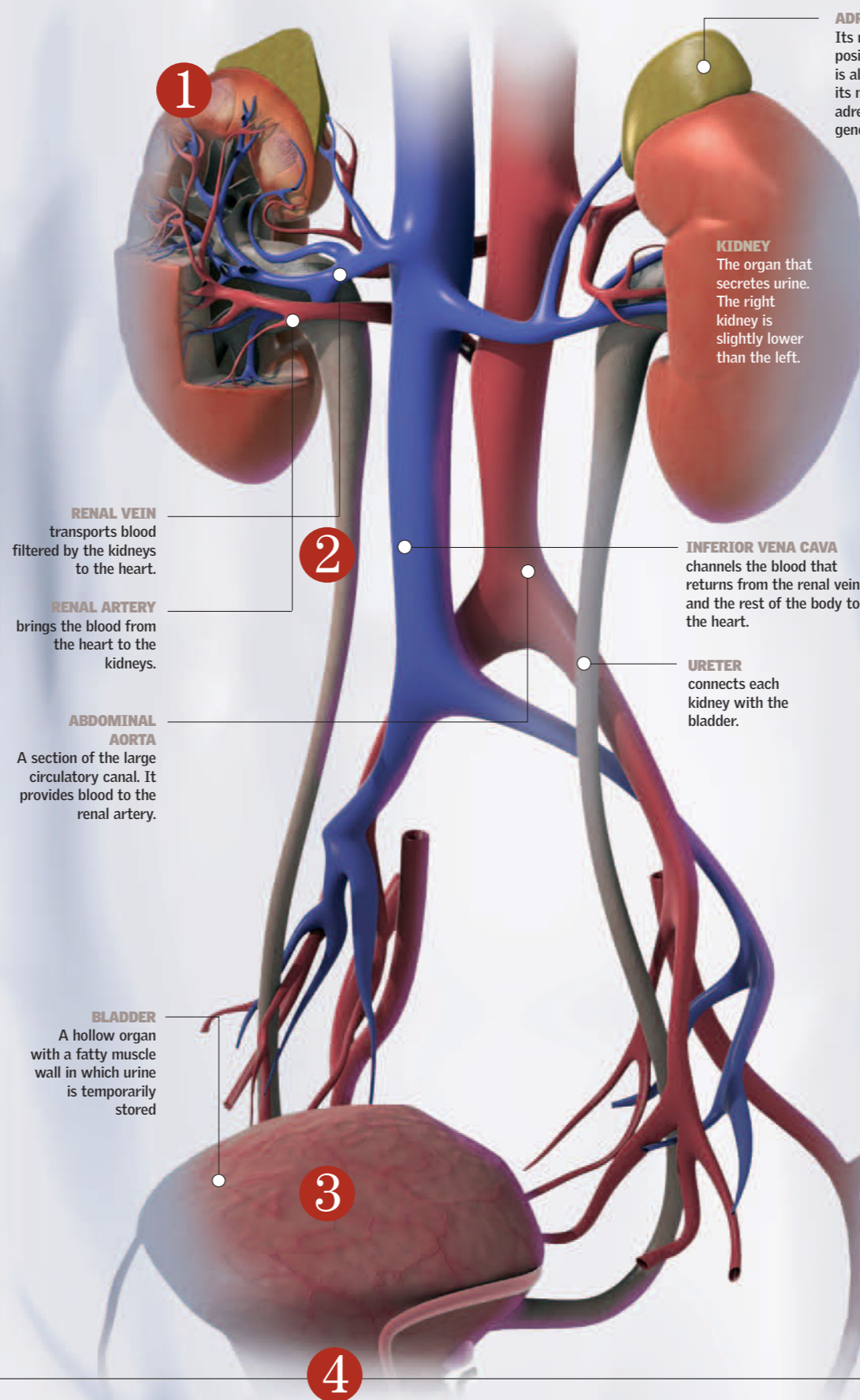
The urine passes from the renal pelvis to the ureter and then to the bladder, where it accumulates until it is eliminated through the tube-shaped urethra.

## 15 minutes

IT TAKES 15 MINUTES FOR LIQUIDS TO CIRCULATE THROUGH THE NEPHRONS.

## COMPONENTS OF URINE

<b>95%</b>	<b>Water</b>
<b>2%</b>	<b>Urea</b> , a toxic substance
<b>2%</b>	<b>Chloride salts</b> , sulfates, phosphates of potassium and magnesium
<b>1%</b>	<b>Uric acid</b>

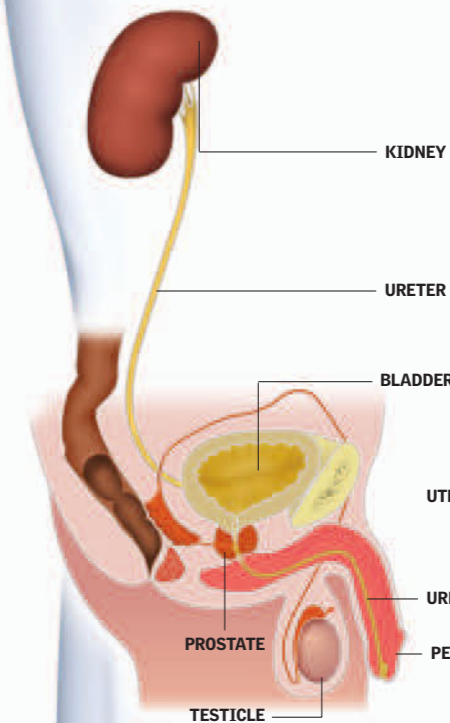


## Differences by Sex

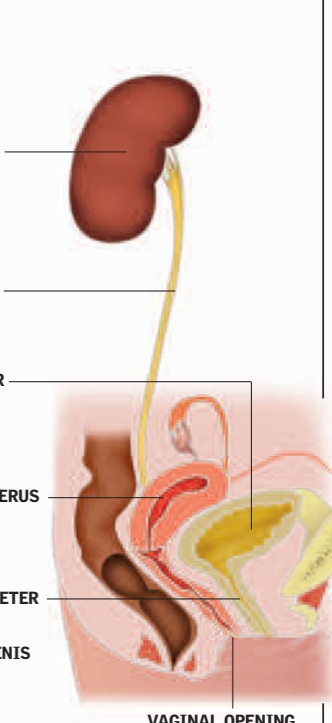
The urinary system has a double relationship to the reproductive system. The two systems are linked by their close physical proximity, but they are also linked functionally. For example, the ureter is a vehicle for secretions produced by the glands of both systems. The urinary systems in men and women are different. A

man's bladder is larger, and the male ureter is also larger than a woman's, because in a man the ureter extends to the end of the penis, for a total length of about 6 inches (20 cm); in a woman, on the other hand, the bladder is located at the front of the uterus, and the length of the ureter is approximately 1.5 inches (4 cm).

### IN A MAN



### IN A WOMAN



## Fluid Exchange

The volume of urine that a person expels every day is related to the person's consumption of liquids. Three quarts (2.5 l) a day would be excessive, but a significant decrease in the production of

urine can indicate a problem. The table details the relationship between the consumption of liquid and its expulsion by the different glands of the human body.

### CONSUMPTION OF WATER

<b>Drinking</b>	<b>60%</b>
50 fluid ounces (1,500 ml)	
<b>Food</b>	<b>30%</b>
25 fluid ounces (750 ml)	
<b>Metabolic water</b>	<b>10%</b>
16 fluid ounces (250 ml)	
<b>3 quarts (2,500 ml) TOTAL</b>	

### EXPULSIÓN DE AGUA

<b>Urine</b>	<b>60%</b>
50 fluid ounces (1,500 ml)	
<b>Losses through the lungs and the skin</b>	<b>28%</b>
25 fluid ounces (700 ml)	
<b>Sweat</b>	<b>8%</b>
16 fluid ounces (200 ml)	
<b>Feces</b>	<b>4%</b>
3 fluid ounces (100 ml)	
<b>3 quarts (2,500 ml) TOTAL</b>	



# Kidneys

Located on either side of the spinal column, the kidneys are the fundamental organs of the urinary system. They regulate the amount of water and minerals in the blood by producing urine that carries away the waste the kidneys discard. They keep the composition of the bodily fluids constant, regulate the pressure of the arteries, and produce important substances such as the precursor of vitamin D and erythropoietin. Every day they process 500 gallons (1,750 l) of blood and produce 2 quarts (1.5 l) of urine. The kidneys measure approximately 5 inches (12 cm) long and 3 inches (6 cm) wide. Their weight is only 1 percent of the total body weight, but they consume 25 percent of its energy. If one kidney ceases to function, the body is able to survive with the activity of the other. ●

## The Renal Circuit

Urine is produced in the nephrons in each kidney; there are thought to be a million nephrons in each kidney. From the nephrons the urine flows into the proximal convoluted tubule, where all the nutrients, such as glucose, amino acids, and most of the water and salts, are reabsorbed into the blood. After passing through the nephron the urine is filtered, and it arrives at the common collecting duct where only the residues and excess water are retained.

### 1. ENTRY OF BLOOD

The blood enters the kidney via the renal artery.

### 2. FILTRATION

The blood is filtered in the nephrons, the functional units of the kidneys.

### 3. URINE IS OBTAINED

A certain amount of urine is obtained from the filtrate in the nephrons, and it is sent to the renal pelvis. The filtered blood, free from waste, is sent to the renal vein and reenters the bloodstream.

### 4. URINE

The urine passes through the renal pelvis to the ureter and from there to the bladder, where it accumulates until it is eliminated through the tube-shaped urethra.

### 5. CLEAN BLOOD

The clean blood exits the kidney via the renal vein, which is connected to the vena cava. The blood then returns to the heart.

## 45 minutes

THE FRENCH PHYSIOLOGIST CLAUDE BERNARD (1813-78) WAS THE FIRST TO NOTE THE IMPORTANCE OF THE KIDNEYS.

At that time it was not known that the kidneys filter all the water content of the blood in the body every 45 minutes and that, even so, it is possible to survive with only one kidney (or none, in the case of dialysis).

**RENAL CAPSULE**  
Protective layer that covers each kidney. It consists of white fibrous tissue.

**1 million**

ONE KIDNEY HAS ABOUT ONE MILLION NEPHRONS.

**41 to 51**  
fluid ounces  
(1,200 to 1,500 cc)

IS THE AMOUNT OF URINE ELIMINATED EACH DAY BY AN ADULT.

### RENAL PYRAMID

A fluted structure in the form of a pyramid, located in the renal medulla

**RENAL PELVIS**  
transports the urine to the ureter.

### RENAL VEIN

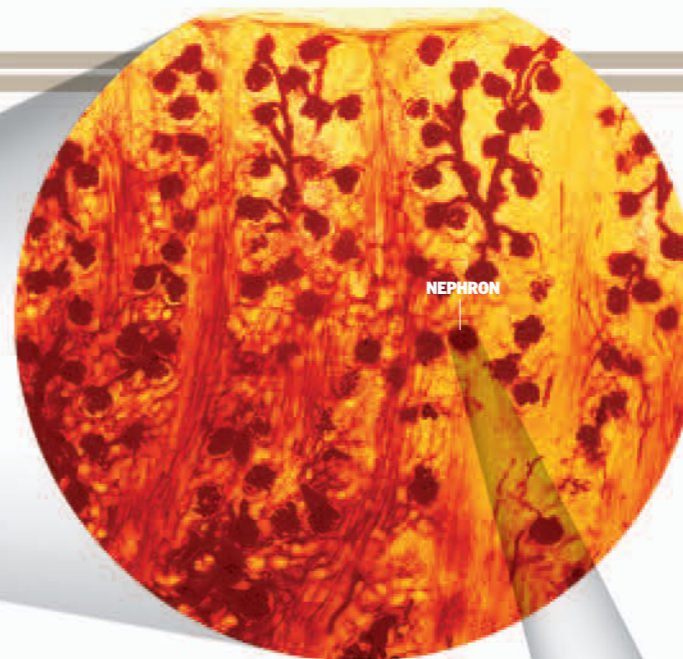
The blood flows out of the kidney through the renal vein toward the vena cava, one of the principal veins of the body.

### RENAL ARTERY

A branch of the aortic artery, which provides the kidney with blood

### URETER

The tube that transports the urine to the bladder

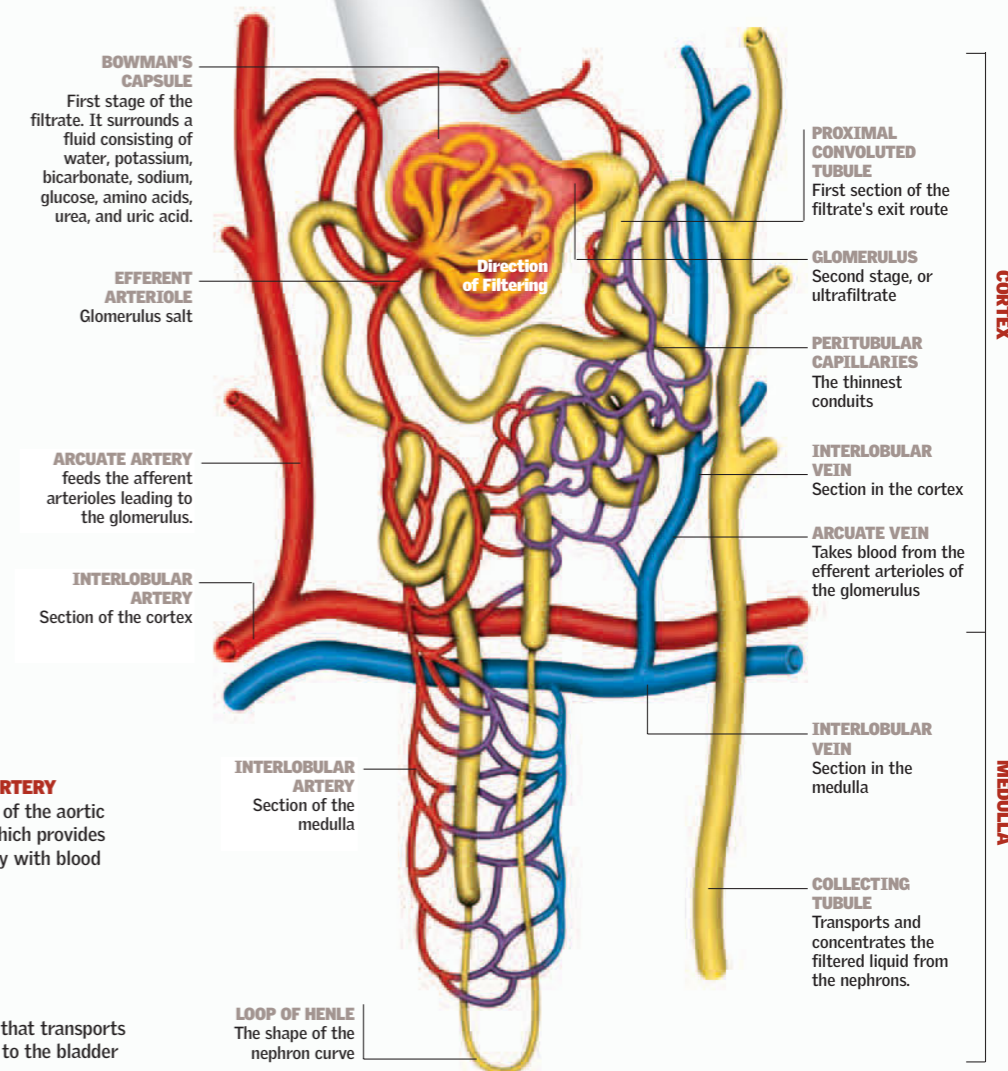


## Glomerulus

A grouping of vessels and capillaries in the kidney's cortex, or sheath. Most of the filtering done by the nephrons takes place there. The wide, afferent arterioles bring blood to the glomerulus. Other, narrower, efferent arterioles lead out of the glomerulus, transporting blood. Inside the glomerulus so much pressure is generated that substances in the blood pass out through the porous capillary walls.

## Nephrons

The functional units of the kidney that filter the blood and produce urine. The basic structure of the nephron consists of two parts: (1) the renal or Malpighian corpuscle, where filtration occurs, including the glomerulus and Bowman's capsule that envelops it; and (2) the renal tubule, a tube that collects the filtered liquid (urine) that is to be eliminated from the body.





# Endocrine System

Consists of the glands inside the body that secrete approximately 50 specific substances called hormones into the blood. The hormones activate or stimulate various organs and control reproduction, development, and metabolism. These chemicals control many of the body's processes and even meddle in our love lives. ●

## The Hormonal Message

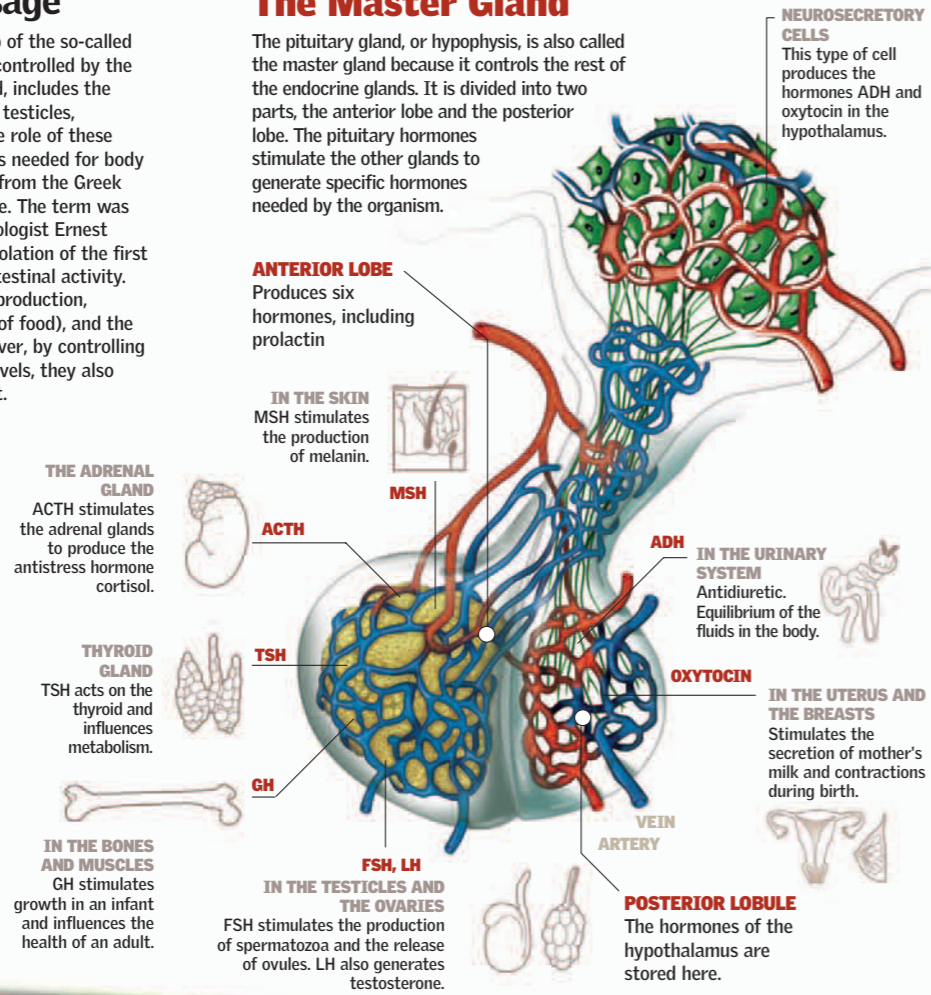
The endocrine system is made up of the so-called endocrine glands. This complex, controlled by the pituitary (hypophysis), or master, gland, includes the thyroid, parathyroid, pancreas, ovaries, testicles, adrenals, pineal, and hypothalamus. The role of these glands is to secrete the many hormones needed for body functions. The word "hormone" comes from the Greek *hormon*, which means to excite or incite. The term was suggested in 1905 by the British physiologist Ernest Starling, who in 1902 assisted in the isolation of the first hormone, secretin, which stimulates intestinal activity. Hormones control such functions as reproduction, metabolism (digestion and elimination of food), and the body's growth and development. However, by controlling an organism's energy and nutritional levels, they also affect its responses to the environment.

## Pituitary Hormones

- ACTH** Adrenocorticotropic hormone. It goes to the adrenal gland.
- TSH** A hormone that stimulates the thyroid to produce the thyroid hormones, which influence metabolism, energy, and the nervous system.
- GH** Growth hormone
- FSH** Follicle-stimulating hormone
- LH** Luteinizing hormone; testosterone and estrogen
- MSH** Hormone that stimulates the melanocyte of the skin.
- ADH** Antidiuretic hormone
- PRL** Prolactin; stimulates milk production by the mother.
- OXYTOCIN** Stimulates the release of milk by the mother, as well as the contractions needed during labor.

## The Master Gland

The pituitary gland, or hypophysis, is also called the master gland because it controls the rest of the endocrine glands. It is divided into two parts, the anterior lobe and the posterior lobe. The pituitary hormones stimulate the other glands to generate specific hormones needed by the organism.



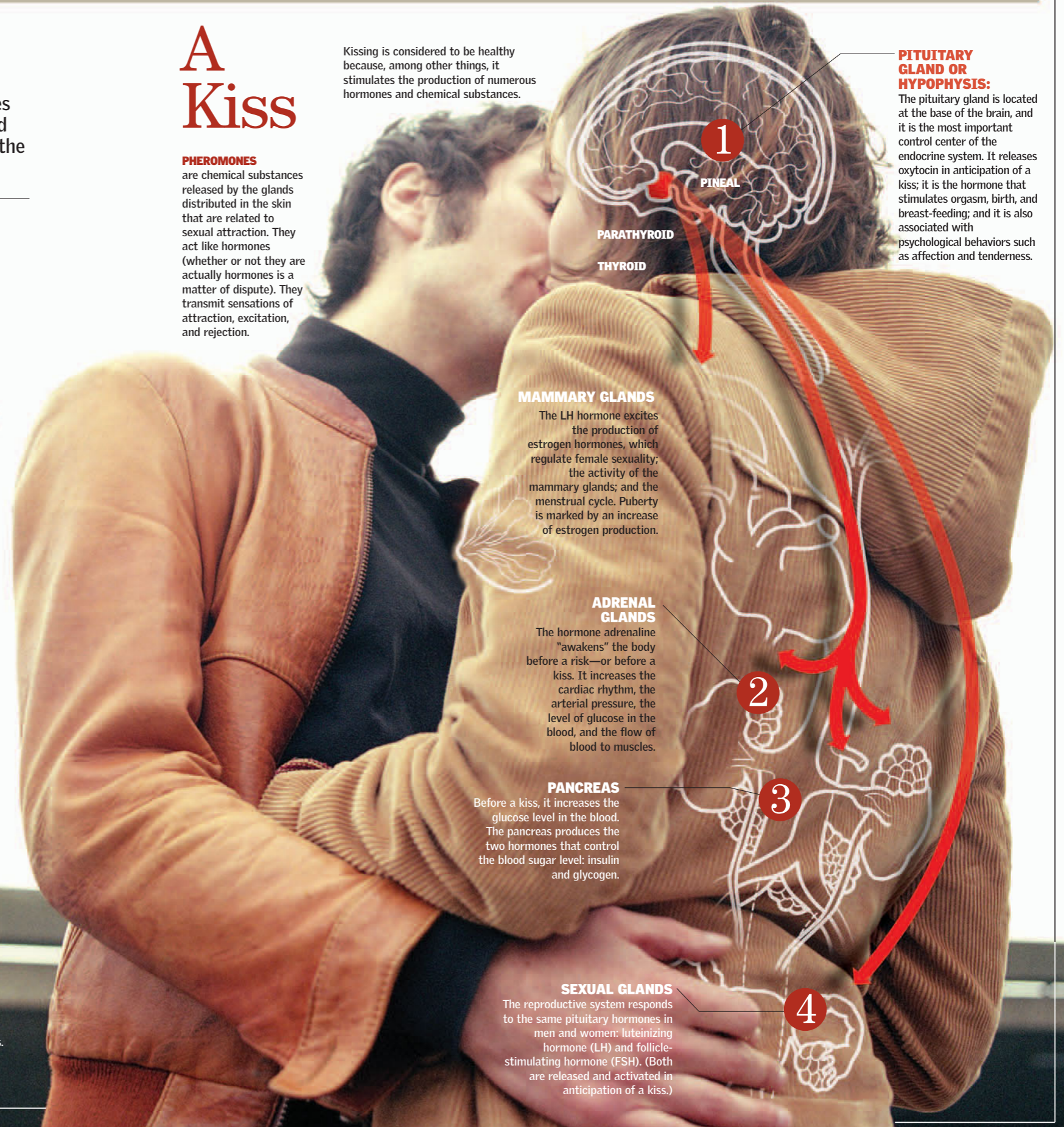
## The Confidence Hormone

Oxytocin, the hormone that influences basic functions, such as being in love, orgasm, birth, and breast-feeding, is associated with affection and tenderness. It is a hormone that stimulates the formation of bonds of affection.

# A Kiss

Kissing is considered to be healthy because, among other things, it stimulates the production of numerous hormones and chemical substances.

**PEROMONES** are chemical substances released by the glands distributed in the skin that are related to sexual attraction. They act like hormones (whether or not they are actually hormones is a matter of dispute). They transmit sensations of attraction, excitation, and rejection.



**PITUITARY GLAND OR HYPHYSIS:**  
The pituitary gland is located at the base of the brain, and it is the most important control center of the endocrine system. It releases oxytocin in anticipation of a kiss; it is the hormone that stimulates orgasm, birth, and breast-feeding; and it is also associated with psychological behaviors such as affection and tenderness.

**1**  
PINEAL  
PARATHYROID  
THYROID

**MAMMARY GLANDS**  
The LH hormone excites the production of estrogen hormones, which regulate female sexuality; the activity of the mammary glands; and the menstrual cycle. Puberty is marked by an increase of estrogen production.

**2**  
**ADRENAL GLANDS**  
The hormone adrenaline "awakens" the body before a risk—or before a kiss. It increases the cardiac rhythm, the arterial pressure, the level of glucose in the blood, and the flow of blood to muscles.

**3**  
**PANCREAS**  
Before a kiss, it increases the glucose level in the blood. The pancreas produces the two hormones that control the blood sugar level: insulin and glycogen.

**4**  
**SEXUAL GLANDS**  
The reproductive system responds to the same pituitary hormones in men and women: luteinizing hormone (LH) and follicle-stimulating hormone (FSH). (Both are released and activated in anticipation of a kiss.)



# Male Reproductive System

The male reproductive system is the complex of organs that leads to a man's production of one of two types of cells necessary for the creation of a new being. The principal organs are the two testicles, or male gonads, and the penis. The testicles serve as a factory for the production of millions of cells called spermatozoa, which are minute messengers of conception bearing the genetic information for the fertilization of the ovum. The penis is linked to the urinary apparatus, but for reproduction it is the organ that functions as a vehicle for semen, a liquid through which the spermatozoa can reach their destination. The word "semen" comes from Greek and means "seed." ●

## Testicles and Spermatozoa

The seminiferous tubes in the testicles are covered with spermatogenic cells. By a process of successive cellular divisions called meiosis, the spermatogenic cells are transformed into spermatozoa, the term for the gametes, or male sexual cells, the bearers of half of the genetic information of a new individual. The spermatozoa fertilize the ovum, or

female gamete, which contains the other half of the genetic information. The number of chromosomes is kept constant because the spermatozoa and the ovum are both haploid cells (cells that possess half of the genetic information of other cells). When the two haploid cells unite, the fertilized egg, or zygote, is a diploid cell (which contains a total of 46 chromosomes).

### THE TESTICLES

The sexual organs that produce sperm

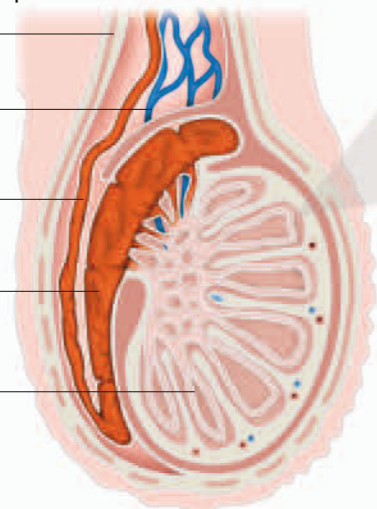
**SPERMATIC CORD**  
Connects the testicles to the body

**BLOOD VESSELS**  
are numerous, and they connect to the vas deferens.

**DEFERENT DUCT (DUCTUS DEFERENS)**  
Connects the epididymis with the seminal vesicle

**EPIDIDYMIS**  
The tube where the semen matures and enters the deferent duct

**SEMINIFEROUS TUBE**  
Semen is produced here. Each testicle has thousands of them.



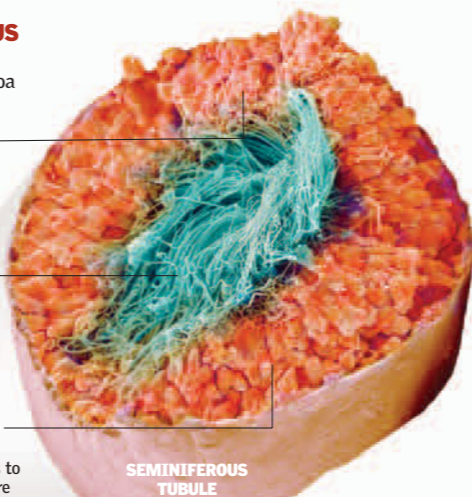
### SEMINIFEROUS TUBULE

Where spermatozoa are produced

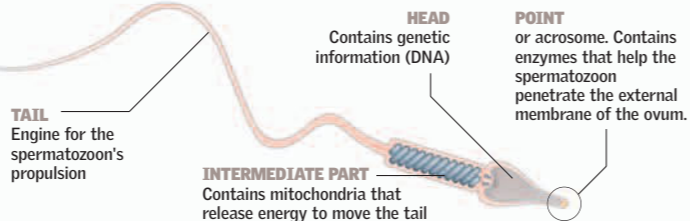
**SPERMATOCYTES** are formed by repeated reproduction of the spermatogonia.

**MATURE SPERM**  
The division of the spermatocytes forms spermatozoa.

**SPERMATOZOIA** move from the seminiferous tubules to the epididymis, where they are stored.



### SPERMATOZOON Male reproductive cell



## Internal Structure of the Penis

The most characteristic organ of a man's body, the penis has a cylindrical form with a double function for the urinary system and the reproductive system. In its normal, or relaxed, state the penis carries urine from the body via the urethra during urination. In its erect state its rigidity permits it to be introduced into the female vagina and to release sperm through ejaculation. The penis consists of spongy tissue

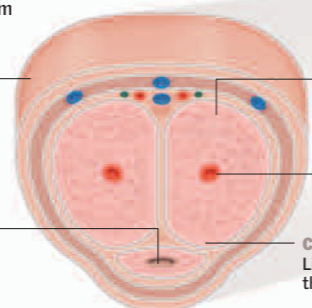
supplied with blood vessels. The circulatory system supplies abundant blood to these vessels during sexual arousal so that the spongy tissue becomes swollen because of the filled blood vessels. This produces an erection, which makes copulation possible. The body of the penis surrounds the urethra and is connected to the pubic bone. The prepuce covers the head (glans) of the penis, which is located above the scrotum.

### THE PENIS

transfers the sperm to the woman.

**EXTERNAL SKIN**  
Covers the whole organ

**URETHRA**  
Extends through the spongy tissue



**SPONGY TISSUE**  
Swells when it fills with blood, sustaining the erection

**ARTERY**  
Its dilation causes the erection.

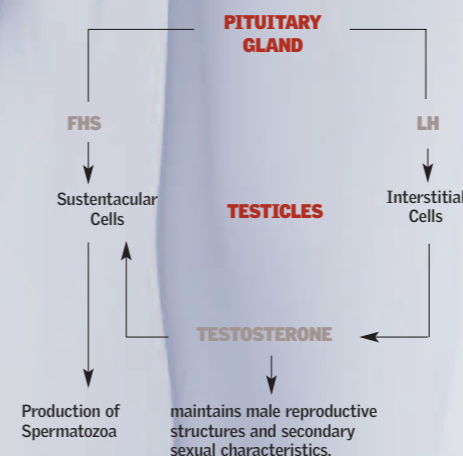
**CAVERNOUS BODIES**  
Like the spongy tissue, these also fill with blood.

**93° F (34° C)**

IS THE IDEAL APPROXIMATE TEMPERATURE REQUIRED BY THE TESTICLES TO PRODUCE SEMEN.

It is lower than the normal body temperature of 98.6° F (37° C) because that temperature would be too warm for this function. This explains why the testicles are outside of the body. Depending on the ambient temperature, they extend or retract.

### THE GLANDS



## Prostate and Epididymis

The prostate is a gland located in front of the rectum and below the bladder. It is the size of a walnut, and it surrounds the urethra, a tube that carries urine from the bladder. The prostate produces the liquid for the semen, which carries the spermatozoa. During orgasm, muscular contractions occur that send the liquid from the prostate out through the urethra. The epididymis is a duct that, when stretched out to its full length, is approximately 20 feet (5 m) long. In the male body it is extremely coiled and lies on the back surface of the testicles, where it is connected with the corresponding vas deferens. The vas deferens stores spermatozoa and provides them with an exit route. The seminal vesicles are two membranous receptacles that connect to both sides of the vas deferens and form the ejaculatory duct.

**150 million**

THE NUMBER OF SPERMATOZOIA THAT EACH 0.06 CUBIC INCH (1 ML) OF SEMEN CAN CONTAIN

**PROSTATE**  
Gland that secretes a creamy liquid (semen) along with the ejaculated sperm

**EJACULATORY DUCT**  
A short tube that carries the sperm to the urethra

**TESTICLE**  
Gland that produces sperm

**SCROTUM**  
Sac of skin that contains the testicles

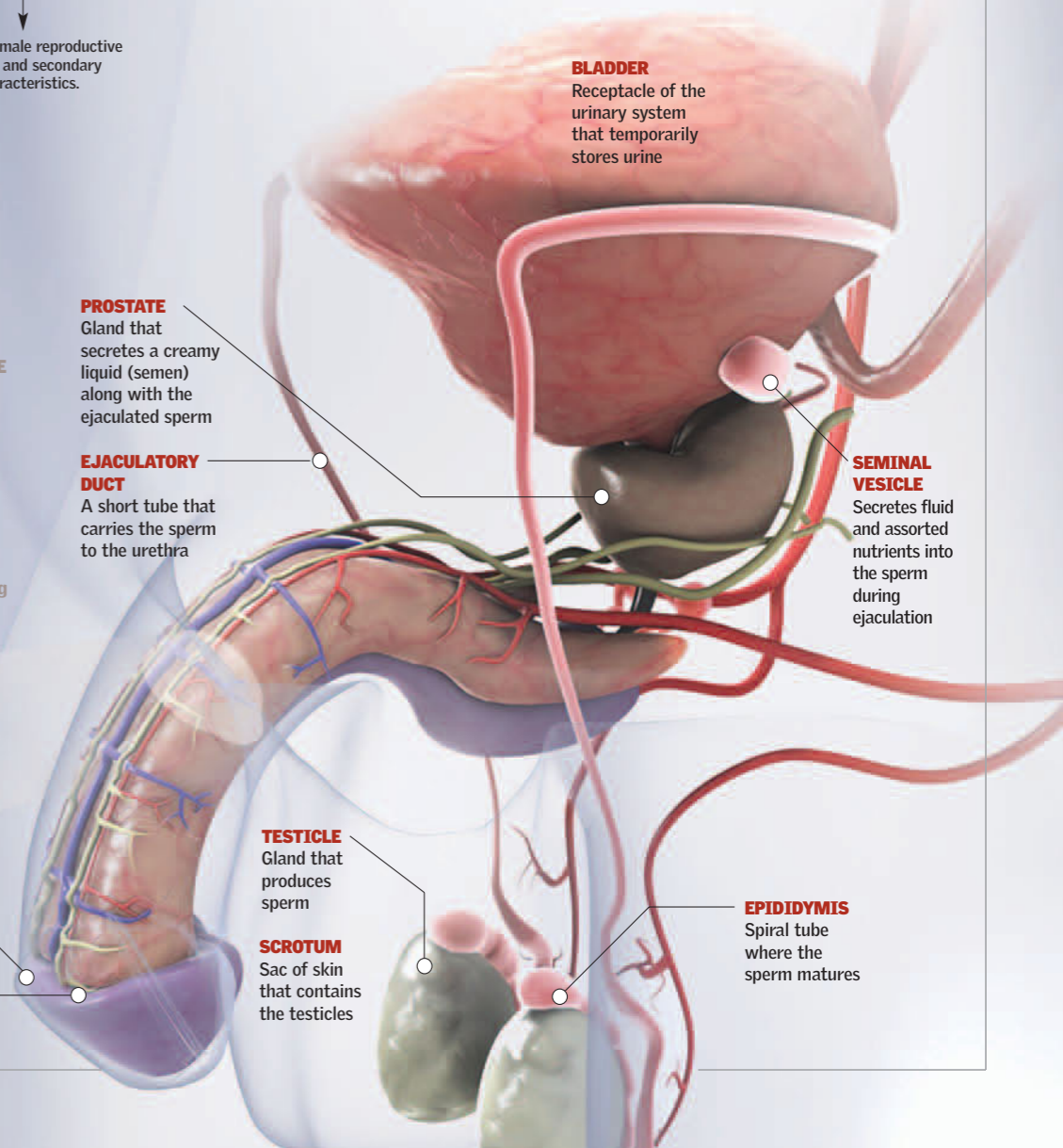
**BLADDER**  
Receptacle of the urinary system that temporarily stores urine

**SEMINAL VESICLE**  
Secretes fluid and assorted nutrients into the sperm during ejaculation

**EPIDIDYMIS**  
Spiral tube where the sperm matures

**PREPUCE**  
Covers and protects the head of the penis

**GLANS**  
Extremity of the penis





# Female Reproductive System

Its primary function is the production of ova, and its organs are arranged so as to allow the fertilization of the ovum by a spermatozoon of the male reproductive system and from that moment to facilitate a series of processes known collectively as pregnancy for the creation of a new being. The internal organs of the female reproductive system are the vagina, the uterus, the ovaries, and the fallopian tubes. The external genitalia, generally referred to as the vulva, are relatively hidden and include the labia majora and minora, the clitoris, the urinary meatus, Bartholin's glands, and the vaginal orifice that leads to the vagina. The menstrual cycle governs the system's function. ●

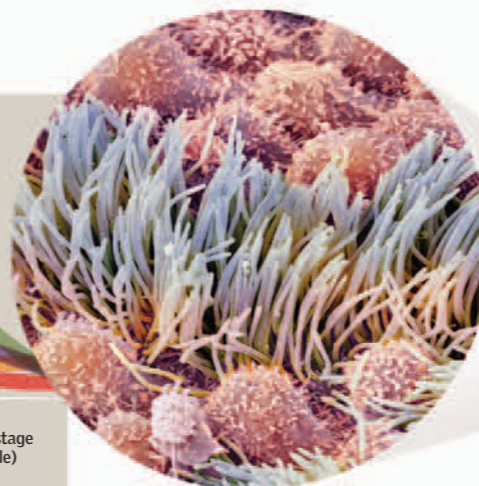
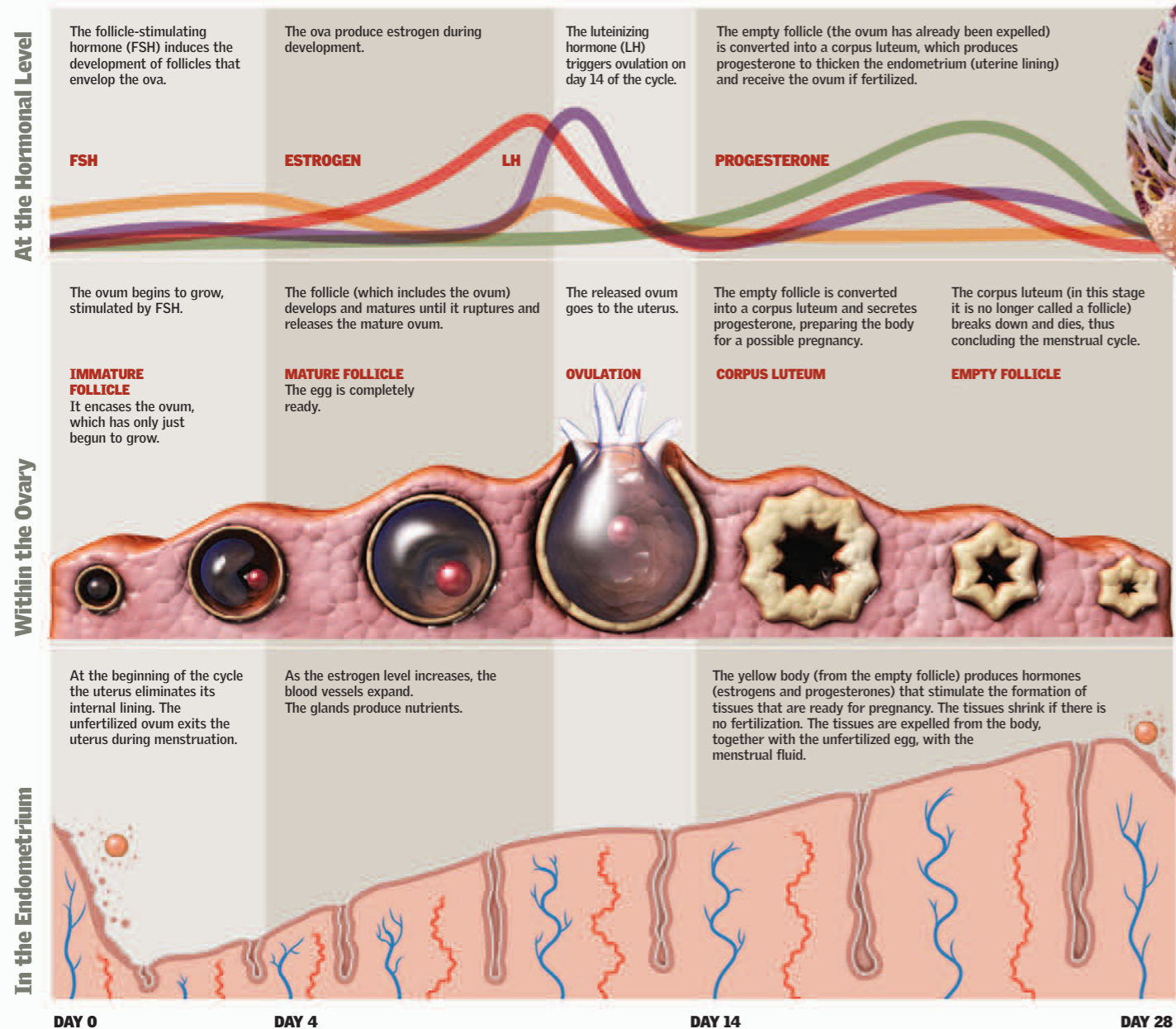
## 2 million

IS THE APPROXIMATE NUMBER OF OVA THAT AN INFANT GIRL HAS IN HER BODY AT BIRTH. BETWEEN THE AGES OF 10 AND 14, ABOUT 300,000 TO 400,000 OVA REMAIN, OF WHICH ONLY 400 WILL MATURE COMPLETELY OVER HER LIFETIME.

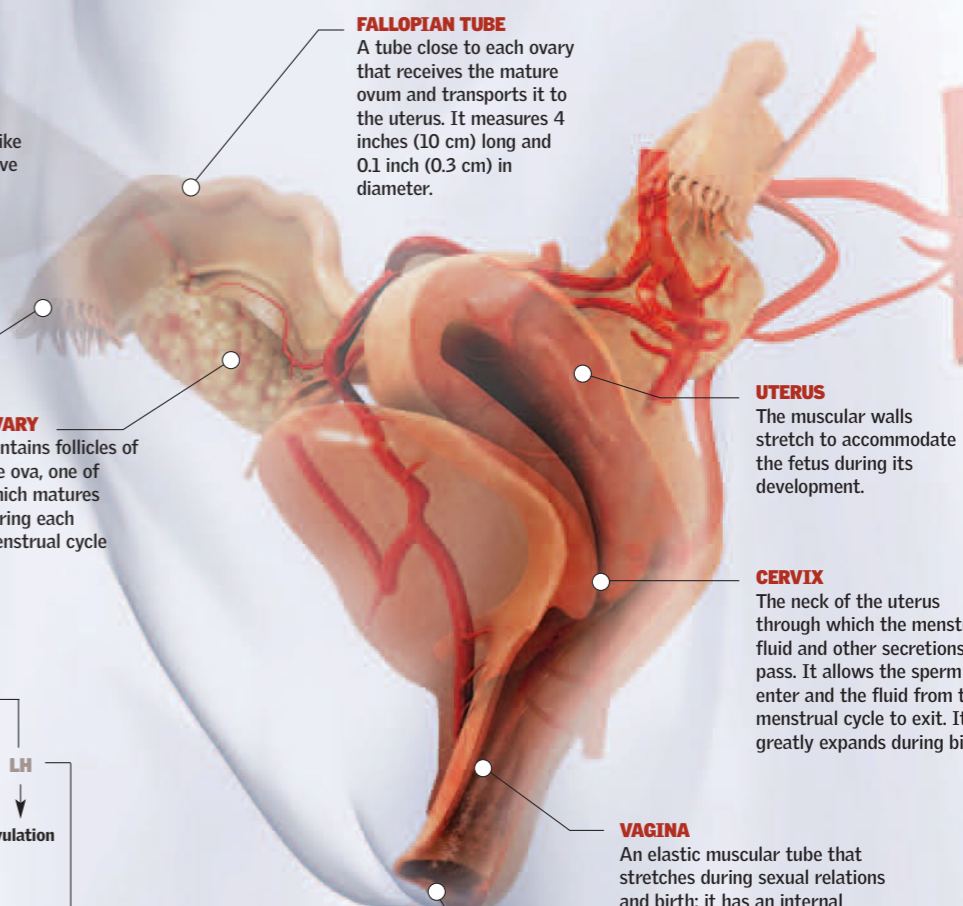
## Menstruation: The Key to Female Reproduction

The female reproductive system is more protected than that of the male because the bony structure of the pelvis houses and shields it. Its development begins around the age of 10, when the female hormones begin a three- to four-year process during which the genital organs, the breasts, the pubic hair, and the general shape of the body change. Toward the age of 13, sometimes earlier or later, the first menstruation, called the menarche, occurs, signaling the beginning of a woman's fertility. She will normally remain fertile for several decades. During menopause, when fertilization is no longer possible, a woman's sexual life is usually not affected and can continue normally.

## The 28 Days of the Menstrual Cycle



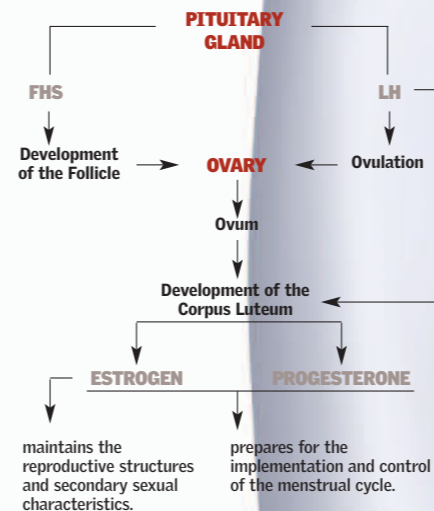
Cilia, tiny hairlike structures, move the ova very smoothly.



**FALLOPIAN TUBE**  
A tube close to each ovary that receives the mature ovum and transports it to the uterus. It measures 4 inches (10 cm) long and 0.1 inch (0.3 cm) in diameter.

**FIMBRIAE**  
Filamentary formations that guide the released ovum toward the fallopian tube during ovulation

**THE GLANDS**



**UTERUS**  
The muscular walls stretch to accommodate the fetus during its development.

**CERVIX**  
The neck of the uterus through which the menstrual fluid and other secretions pass. It allows the sperm to enter and the fluid from the menstrual cycle to exit. It greatly expands during birth.

**VAGINA**  
An elastic muscular tube that stretches during sexual relations and birth; it has an internal mucous membrane that provides lubrication and an acid medium that acts as a defense against infection. It serves as the pathway of the uterus to the exterior.

**CLITORIS**  
A sensitive protuberance of tissue that responds to sexual stimulation



# The Senses and Speech

## HEALTHY AND SHINY SKIN

The health of the skin depends upon a diet that provides the organism with a sufficient amount of proteins and minerals.

## SMELL AND TASTE 70-71

## TOUCH AND THE SKIN 72-73

## ANATOMY OF THE EYE 74-75

## THE MECHANICS OF HEARING 76-77

## SPEECH AND NONVERBAL LANGUAGE 78-79



Everything we know about the world comes to us through the senses. Traditionally it was thought that we had only five: vision, hearing, touch, smell,

and taste. However, for some time now we have known that we have many additional classes of sensations—such as pain, pressure, temperature, muscular sensation, and a sense of

motion—that are generally included in the sense of touch. The areas of the brain involved are called somatosensory areas. Although we often take our senses for granted, each

one of them is delicate and irreplaceable. Without them it is nearly impossible to understand our surroundings. They are a bridge between us and everything alive on the Earth. ●

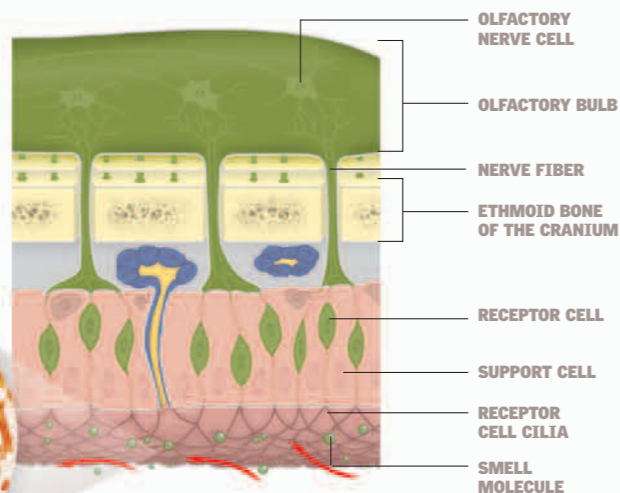


# Smell and Taste

These two senses of the body function as powerful allies of the digestive system. Taste involves the perception of dissolved chemical substances arriving, for example, in the form of food. Taste sensation is principally seated on the upper surface of the tongue, and saliva is a fundamental ingredient for dissolving and tasting. Smell involves the perception of these chemicals when they take the form of dispersed aromas. The sense of smell operates at a greater distance than that of taste and can capture substances floating in the environment. It is thought that smell is some 10,000 times more sensitive than any of our other senses. ●

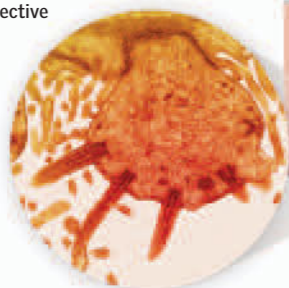## Olfactory Cells

These are located deep in the nasal cavity, extended over the so-called olfactory epithelium. It is calculated that some 25 million cells are located there. Their useful life is, on average, 30 days, after which they are replaced by new cells. They have a dual function. One end of each olfactory receptor is connected to the olfactory bulb and transmits the sensations it records, so that the bulb is able to send the nerve impulses to the brain with the necessary information. The other end terminates in a group of cilia, or microscopic hairs, which serve a protective function within the mucosa.



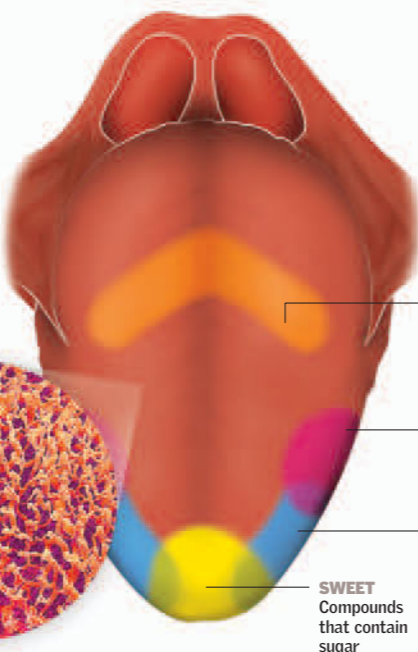
**10,000**

THE NUMBER OF ODORS THE SENSE OF SMELL CAN DISTINGUISH



## Gustatory Papillae

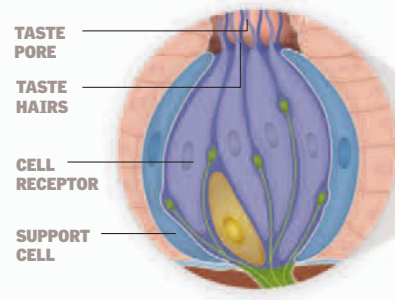
The tongue is the principal seat of the sense of taste. It has great mobility at the bottom of the mouth and contains between 5,000 and 12,000 gustatory papillae. Each of these papillae has approximately 50 sensory cells, which have an average life span of 10 days. The salivary glands are activated by the ingestion of food or just before ingestion. They generate an alkaline liquid called saliva, a chemical solvent that, together with the tongue, breaks down the substances of which food is composed and makes it possible to differentiate between them by taste. The tongue takes charge of perceiving these tastes via the fungiform papillae, which give the tongue its rough appearance.



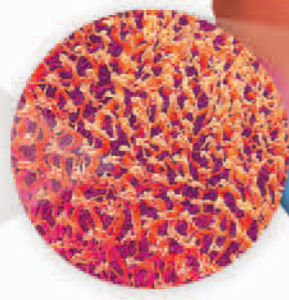## 4 Flavors

THE SURFACE OF THE TONGUE CAN DISTINGUISH: SWEET, SALTY, SOUR, AND BITTER.

### GUSTATORY PAPILLA



### SURFACE OF THE TONGUE



## Taste Center

The area of the brain that receives information from the tongue

IMPULSES FROM THE GLOSSOPHARYNGEAL NERVE

TRIGEMINAL NERVE IMPULSES

### OLFACTORY BULB

Located behind the nose, it receives information directly from the nasal fossae.

### OLFACTORY NERVE FIBERS

The upper section of the nasal fossae is the seat of the olfactory nerve and the sense of smell. The complex, as a whole, is called the "yellow spot."

### GLOSSOPHARYNGEAL NERVE

Collects the sensory impressions of taste from the posterior one third of the tongue

### TRIGEMINAL NERVE

Receives sensory information from the entire face, but especially from the nasal fossae and the mouth

### TONGUE

The principal seat of the sense of taste, with its thousands of gustatory papillae



# Touch and the Skin

**T**ouch is one of the five senses. Its function is to perceive sensations of contact, pressure, and temperature and to send them to the brain. It is located in the skin (the integument), the organ that covers the entire outside of the body for protection. The cellular renewal of the skin is continuous, and when recording external changes (of temperature, for example), it activates reflexive mechanisms to open or close the pores and, thus, to maintain the required body temperature. Secretions, such as those of the sweat glands, also contribute to this process by reducing heat. Like the sebaceous glands, they are important for hydration and hygiene in the areas where they are located. ●

## The Thinnest and the Thickest

▶ The thinnest skin on the body is that of the eyelids.  
 ▶ The thickest is that of the sole of the foot. Both provide, like all the skin of the body, a protective function for muscles, bones, nerves, blood vessels, and interior organs. It is thought that hair and fingernails are modified types of skin. Hair grows over the whole body, except for the palms of the hands, the soles of the feet, the eyelids, and the lips.

### UPPER SQUAMOUS LAYER

or hornlike layer. It is superficial, granulated, and transparent.

### EPIDERMIS

Impermeable to water. It is external and is the thinnest layer. It is wear-resistant.

### DERMIS

The middle layer, which is below the epidermis and is thicker

### SUBCUTANEOUS FAT

Also called the hypodermis. It is an energy reservoir that acts as a thermal insulator and cushion.

### MERKEL DISK

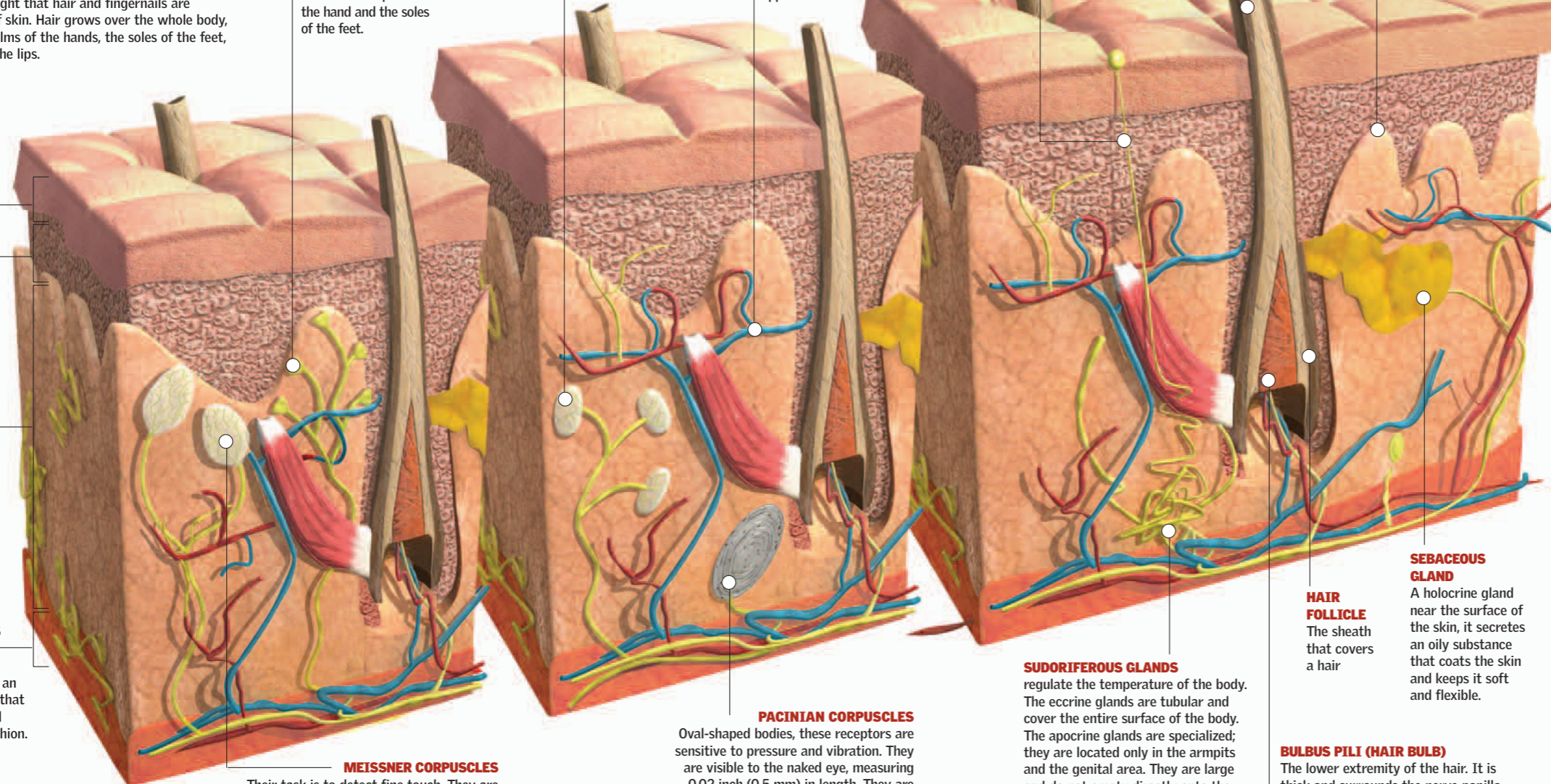
or Merkel cell. It is specialized to detect pressure. They are located in the palms of the hand and the soles of the feet.

### RUFFINI CORPUSCLE

Capsules deep in the skin and the ligaments; stretch receptors

### VENULAE

Small blood vessels. When they break, because of a blow for example, hematomas appear.



**MEISSNER CORPUSCLES**  
 Their task is to detect fine touch. They are in the fingers, breasts, genitals, and lips.

**PACINIAN CORPUSCLES**  
 Oval-shaped bodies, these receptors are sensitive to pressure and vibration. They are visible to the naked eye, measuring 0.02 inch (0.5 mm) in length. They are located deep in the hypodermis.

**SUDORIFEROUS GLANDS**  
 regulate the temperature of the body. The eccrine glands are tubular and cover the entire surface of the body. The apocrine glands are specialized; they are located only in the armpits and the genital area. They are large and do not empty directly onto the skin but into the pilous follicle.

**BULBUS PILI (HAIR BULB)**  
 The lower extremity of the hair. It is thick and surrounds the nerve papilla.

**HAIR FOLLICLE**  
 The sheath that covers a hair

**SEBACEOUS GLAND**  
 A holocrine gland near the surface of the skin, it secretes an oily substance that coats the skin and keeps it soft and flexible.

**HAIR SHAFT**  
 The part of the hair bulb that extends above the skin

**BASAL CELL LAYER**  
 The deepest layer of the epidermis

**SUDORIFEROUS CONDUIT**  
 Sweat, a liquid secreted by the sudoriferous gland and composed of water, salts, and toxins, passes through this conduit.

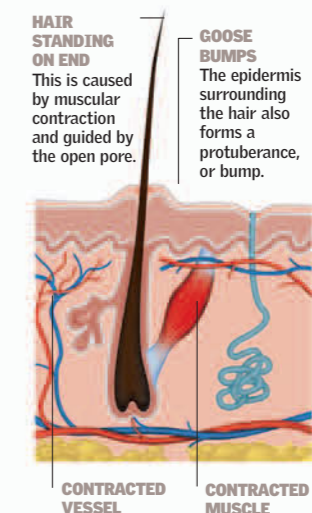
## Skin

A MAN'S SKIN PRODUCES A GREATER QUANTITY OF SEBUM, OR OILY SECRETION, THAN THAT OF A WOMAN. THEREFORE, A MAN'S SKIN IS TOUGHER AND GREASIER THAN A WOMAN'S.

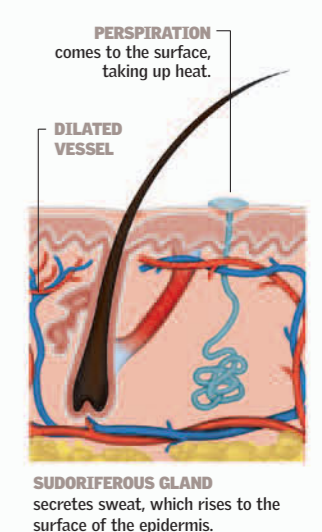
## Responding to Temperature

▶ When the skin perceives the sensation of cold, the blood vessels and the muscles contract. The purpose of this is to prevent the escape of heat; as a consequence, the hairs stand on end, resulting in what is commonly called goose bumps. The opposite happens in response to heat: the

blood vessels dilate because the skin has received instructions from the brain to dissipate heat, and the vessels emit heat as if they were radiators. The sudoriferous glands exude sweat onto the surface of the skin. The evaporation of sweat removes heat from the skin.



**A COLD**  
 As with fear, cold puts a person's hair on end—literally! The contraction of both the blood vessels and the muscles causes the hair on the skin to stand on end.



**B HEAT**  
 causes the secretion of sweat, which increases as the temperature rises. Cooling is caused by the evaporation of the sweat, which carries heat away from the body.

## Nails

▶ They are hard and hornlike.  
 ▶ Their principal component is keratin, a protein that is also present in the skin and the hair. Their function is to cover and protect the ends of the fingers

and toes. Their cells arise from the proliferative matrix and advance longitudinally. Once outside the body, they die. That is why there is no pain when you cut them.

### A SHIELD FOR THE FINGERS AND TOES

The fingernail can be seen with the unaided eye, but the protective structure of the fingers

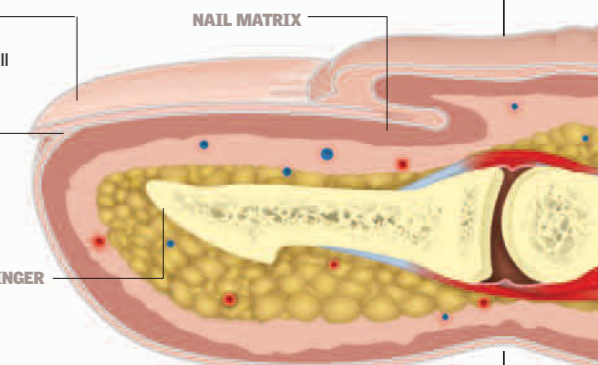
and toes also includes their matrix and bone structure.

**NAIL**  
 The cells called corneocytes are full of keratin.

**ROOT**  
 The keratinization process pushes the cells outward, toward the nail.

**NAIL MATRIX**

**A BONE OF THE FINGER**





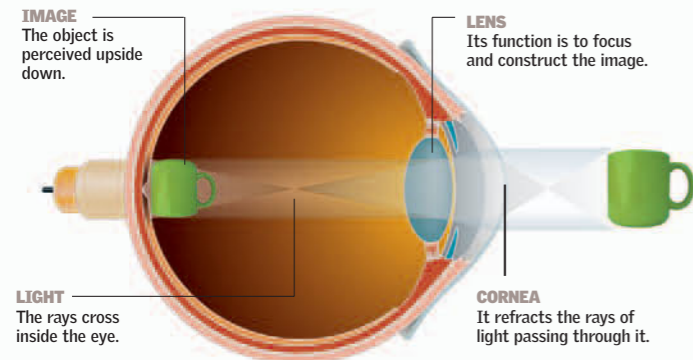
# Anatomy of the Eye

Almost all the information that comes from the world into the brain depends on vision. The eye, one of the most complex organs of the body, allows us to judge the size and texture of an object even before we touch it or to know how far away it is. More than 100 million cells are activated instantaneously in the presence of light, converting the image perceived into nerve impulses that are transmitted to the brain. For this reason 70 percent of all the body's sensory receptors are concentrated in the eyes. It is vital that the brain receive information in a correct form: otherwise, things would appear to be distorted. ●

## How Does the Eye See?

An object reflects light in all directions. The light is partially focused by the cornea, which refracts the entering rays. The lens focuses the rays of light, changing its shape to give the light the focus it needs. The rays cross the inside of the eye. The light arrives at the retina, and

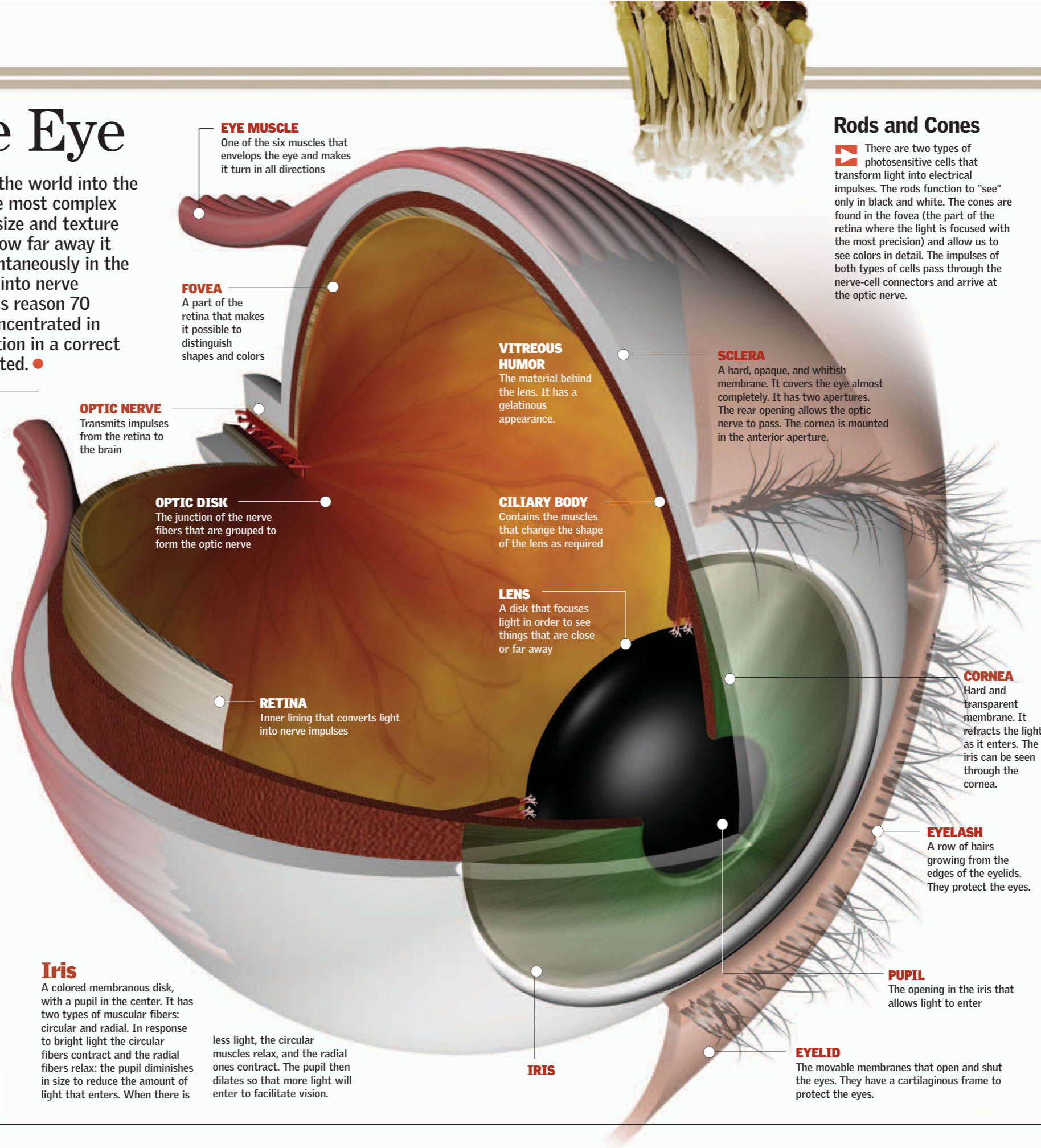
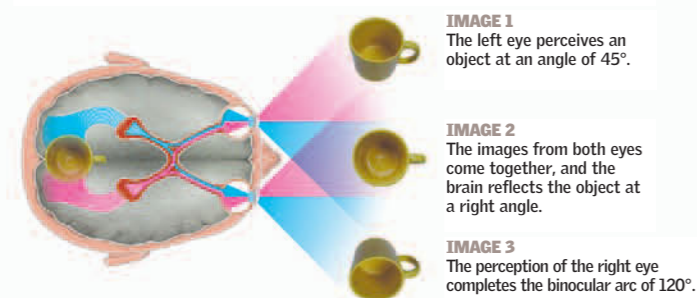
the rays perceived produce an inverted image of the object. The retina sends this information to the brain, which processes it and constructs a correct image of the object. Thanks to the fovea the eye can perceive details such as the shape and color of objects.



## Seeing in Three Dimensions

When the eyes look ahead, the field of vision is binocular because both eyes see at the same time, each one from a different perspective. The images are superimposed at an angle of

approximately 120°. This allows stereoscopic vision (two images of the same object from different angles, without deformation). The brain perceives the image in three dimensions.

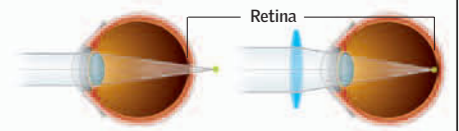


## Rods and Cones

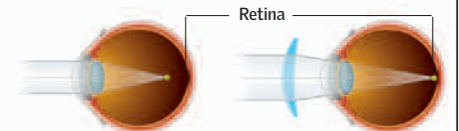
There are two types of photosensitive cells that transform light into electrical impulses. The rods function to "see" only in black and white. The cones are found in the fovea (the part of the retina where the light is focused with the most precision) and allow us to see colors in detail. The impulses of both types of cells pass through the nerve-cell connectors and arrive at the optic nerve.

## VISION PROBLEMS

The most common problems involve seeing things out of focus. These are hypermetropia and myopia. Both can be corrected by the use of lenses. A hereditary condition called color blindness, or Daltonism, is less frequent.



**A HYPEROPIA (FARSIGHTEDNESS)**  
This condition makes it difficult to see objects that are close to us. It happens when the image is focused behind the retina. It can be corrected by convex (converging) lenses, which make the rays of light strike the retina properly.

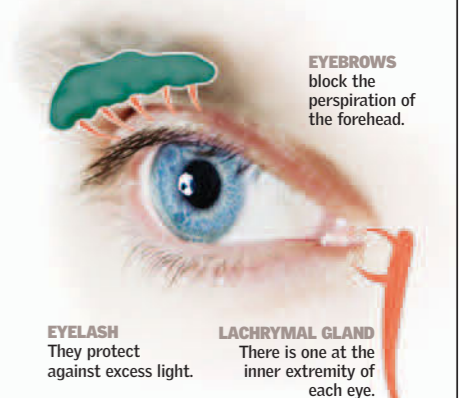


**B MYOPIA (NEARSIGHTEDNESS)**  
Here the image is formed in front of the retina. This usually occurs when the ocular sphere is longer than normal. The myopic person has difficulty seeing distant objects. Myopia is corrected with concave (diverging) lenses or by an operation using a laser.

**C COLOR BLINDNESS**  
Persons who are color blind have problems distinguishing between certain colors. It is a hereditary illness caused by the absence of the types of cone cells that are sensitive to yellow, green, or blue.

## Protection

THE EYELIDS PROTECT THE EYES FROM BRIGHT LIGHT AND DUST. THE EYELASHES REDUCE EXCESS LIGHT. THE EYEBROWS KEEP SWEAT OUT OF THE EYES. THE NASOLACHRYMAL DUCT TAKES THE TEARS FROM THE NASAL CAVITY TO THE LACHRYMAL DUCTS—THE OPENINGS AT THE EXTREMITIES OF THE EYES—WHERE THEY ARE SECRETED.





# Mechanics of Hearing

The ear is the sense responsible for hearing and maintaining equilibrium. When the ear perceives sounds, it registers its characteristics—volume, tone, and timbre—as well as the direction from which it comes. A group of nerve terminals receives information about the body's motion and transmits this to the brain in order to maintain dynamic and static equilibrium. The ear is important for communication by means of speech or other means, such as music. The ear is capable of distinguishing a great range of volumes, from the buzzing of a mosquito to the roar of an airplane. The ear contains the smallest bones of the body. ●

## Frequencies

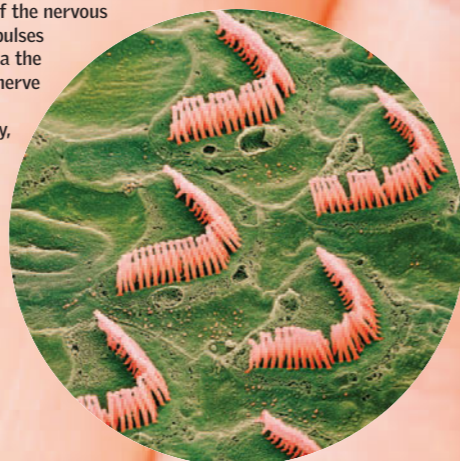The frequency of a sound is the speed at which the sound makes the air vibrate. It is measured in units called hertz (Hz): one hertz corresponds to one vibration per second. High frequencies correspond to high sounds, and low frequencies to low sounds. The human ear can hear sounds between 20 and 20,000 vibrations per second.

### FREQUENCIES AUDIBLE TO HUMANS AND ANIMALS

SUBJECT	MINIMUM	MAXIMUM
Person 10 years old	20 Hz	20,000 Hz
Person 60 years old	20 Hz	12,000 Hz
Dog	60 Hz	45,000 Hz
Frog	100 Hz	3,000 Hz
Bat	1,000 Hz	120,000 Hz
Cat	60 Hz	65,000 Hz

## Organ of Corti

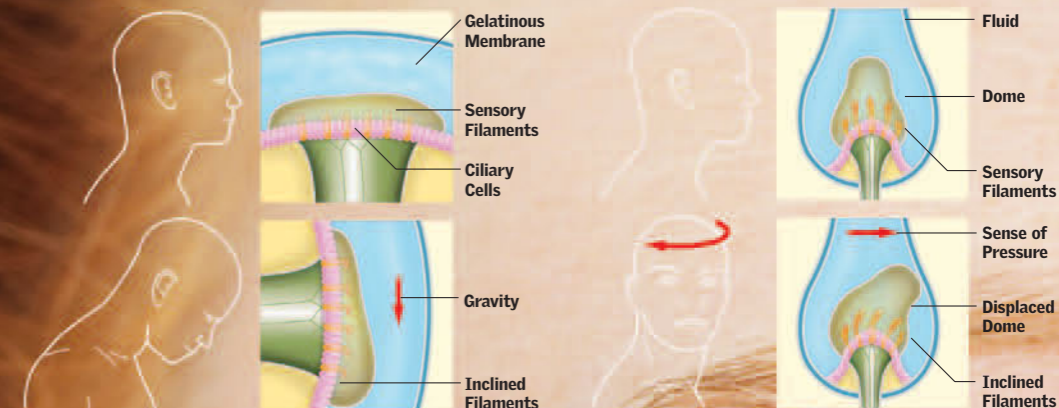
Contains ciliary cells that collect vibrations and transform mechanical energy into energy of the nervous system. Next the impulses arrive at the brain via the cochlear nerve. The nerve cells do not have a regenerative capacity, so if they are lost along with them.



## Equilibrium

Dynamic and static equilibrium are maintained by the inner ear. Above the cochlea there are three semicircular canals, which are spiral-shaped conduits. Inside the canals are a gelatinous membrane and thousands of cilia, or hairlike structures, traversed by a cranial nerve that connects them to the brain. When the head moves, this

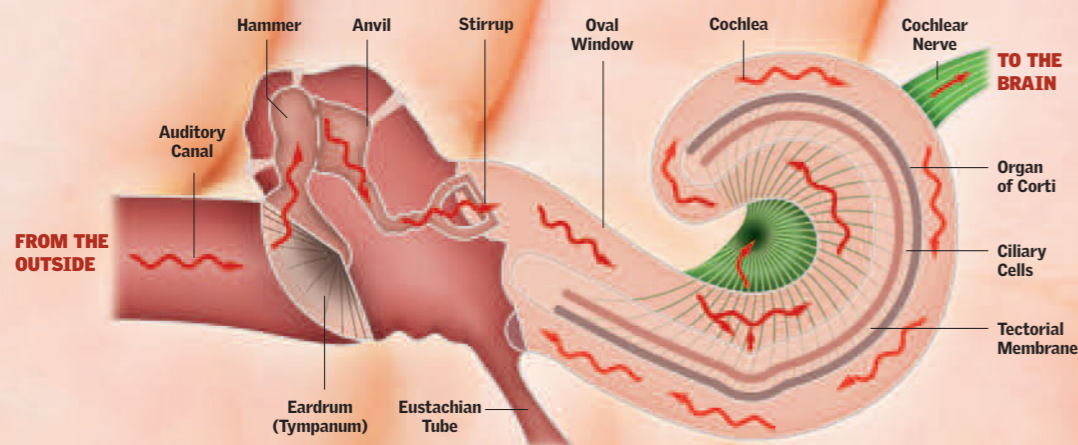
gelatinous membrane is displaced, and the tiny cilia send the brain information about the velocity and the direction of this displacement. On that basis the body can move as required to maintain equilibrium. Excessive motion produces seasickness, because the cilia continue to move even when the motion stops.



**LINEAR MOTION**  
The displacement of the gelatinous membrane, caused by a difference in height, changes the structure of the auditory cilia.

**ROTATIONAL MOTION**  
The gelatinous membrane takes on the shape of a dome so that lateral motion will also disturb its equilibrium.

## THE PROCESSING OF SOUND



- ENTRANCE**  
The sound wave is captured by the ear and enters via the auditory canal.
- VIBRATION**  
The tympanum registers the intensity of the wave.
- TRANSMISSION**  
The vibration of the eardrum is transmitted to the hammer, from the hammer to the anvil, from the anvil to the stirrup, from the stirrup to the oval window, from there to the cochlea, and from there to the cochlear nerve, whose electrical impulses are transmitted to the brain.

## EXTERNAL EAR

**AURICULAR PAVILION**  
or pavilion of the ear. The only visible part of the ear. It consists of cartilage and skin. It captures the sound vibrations and redirects them into the ear, preventing echo.

**EXTERNAL AUDITORY CANAL**  
It is on average 1 inch (2.5 cm) long.

## MIDDLE EAR

**EARDRUM**  
It vibrates, and its vibrations are perceived by the three bones of the inner ear (hammer, anvil, and stirrup).

**LIGAMENT**  
Maintains the hammer in its position.

**HAMMER**  
Transmits the eardrum's vibrations. It is 0.3 inch (8 mm) long.

**ANVIL**  
Receives the hammer's vibrations

**STIRRUP**  
Transmits vibrations to the oval window. It is 0.15 inch (4 mm) long.

## INNER EAR

### VESTIBULAR APPARATUS

**EUSTACHIAN TUBE**  
Connects the middle ear with the back of the nose and the pharynx. It controls the air pressure in the ear, at times through yawning.

### VESTIBULAR NERVE

**VESTIBULE**  
Oval window or labyrinth. Encased in the temporal bone, one conduit goes to the cochlea (for hearing), and two go to the semicircular canals (for equilibrium).

**COCHLEAR NERVE**  
Brings the nerve impulses of the inner ear to the brain

**COCHLEA**  
A tubular, spiral structure filled with fluid that receives vibrations, which are then transmitted to the brain by the organ of Corti. These vibrations produce waves in the fluid, which stimulate the cilia of the organ of Corti. The cochlea allows differences in volume to be identified.

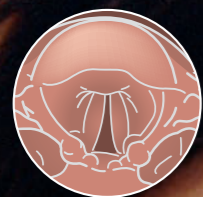

# Speech and Nonverbal Language

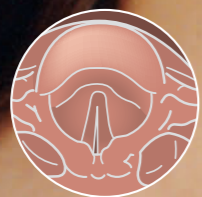Speaking is the verbal expression of a language and includes articulation, which is the manner in which words are formed. However, one can make oneself understood by means other than the spoken word, such as with signs, facial expressions, or gestures. These are examples of what is called nonverbal communication, whereby even silence can be expressive. ●

## Language and Speech

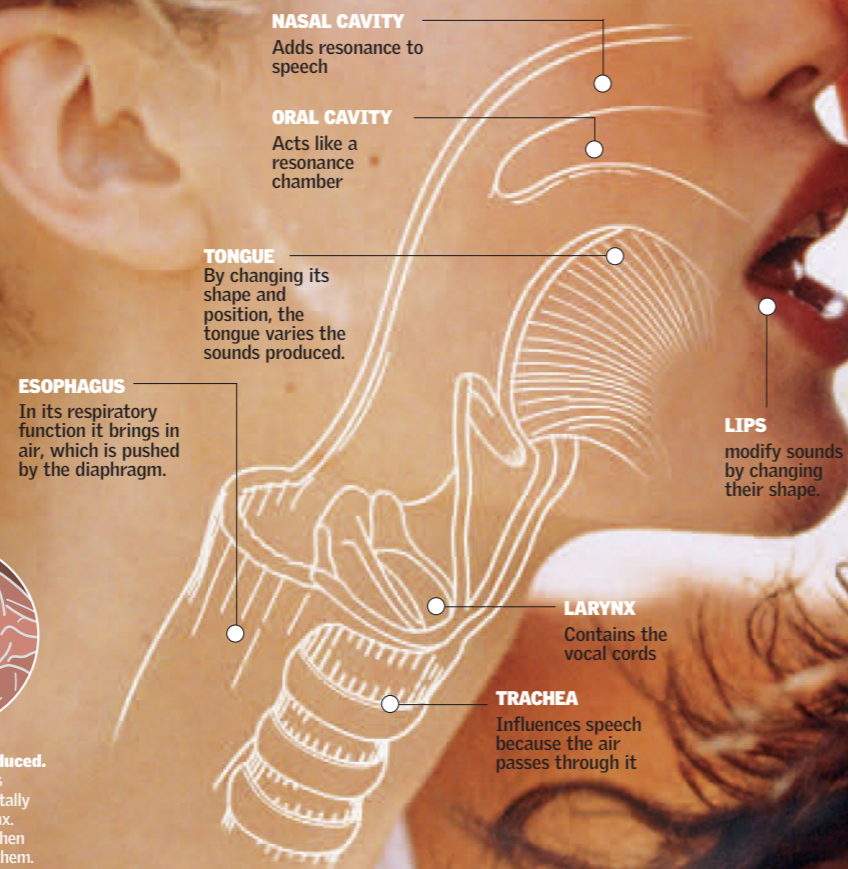
Linguists explain that the organs of speech necessary to express language in sounds, which constitute the fundamental elements of speech, are just as independent of language as a telegraph apparatus is of the Morse code it transmits. Linguists also compare language (the verbal system of communication that is almost always written) with a symphony whose score exists independently of the musicians who play it. The vocal cords behave like instruments. They are folds of muscle that open and close to produce sounds. When they are not producing vocal sounds, normal breathing occurs. Under the control of the brain, the vocal cords produce sounds that are modified by the lips and the tongue to create speech.



**A Passage of Air**  
The vocal cords relax and open to allow air to pass to and from the lungs. No sound is produced because the vocal cords do not vibrate, which is the basis for sound.



**B Sound Is Produced.**  
The vocal cords stretch horizontally above the larynx. They tighten when air flows past them. Sound is the vibration of the vocal cords.



**NASAL CAVITY**  
Adds resonance to speech

**ORAL CAVITY**  
Acts like a resonance chamber

**TONGUE**  
By changing its shape and position, the tongue varies the sounds produced.

**ESOPHAGUS**  
In its respiratory function it brings in air, which is pushed by the diaphragm.

**LIPS**  
modify sounds by changing their shape.

**LARYNX**  
Contains the vocal cords

**TRACHEA**  
Influences speech because the air passes through it

## Language of Gesture

The expressivity of the human face is the result of more than 30 muscles that tense small areas of the skin when they contract. Most of them operate in pairs. Their use is reflexive in most cases, as in the gestures, facial

expressions, and grimaces that often accompany the spoken word and are silent expressions in certain situations. In other cases, however, such as the art of acting, their use and mastery can be studied and practiced. The usual example of


this is the art of mimes, who can stage complete dramas that are transmitted very effectively with no recourse to the spoken word or use of the voice.

**Broca**  
Controls the articulation of speech.


**Visual**  
Receives and analyzes the nerve impulses from the eye.

**Wernicke**  
Controls the comprehension of language.


**FACIAL EXPRESSIONS**  
The muscles of the face also serve to communicate feelings.



**FROWNING**  
Action of the corrugator muscles on the eyebrows



**SURPRISE**  
The muscles of the forehead are contracted.



**SMILE**  
Action of the smile muscles and the zygomaticus major



# Control Centers

**NERVE CELLS**  
Microscope  
photograph of a  
group of neurons

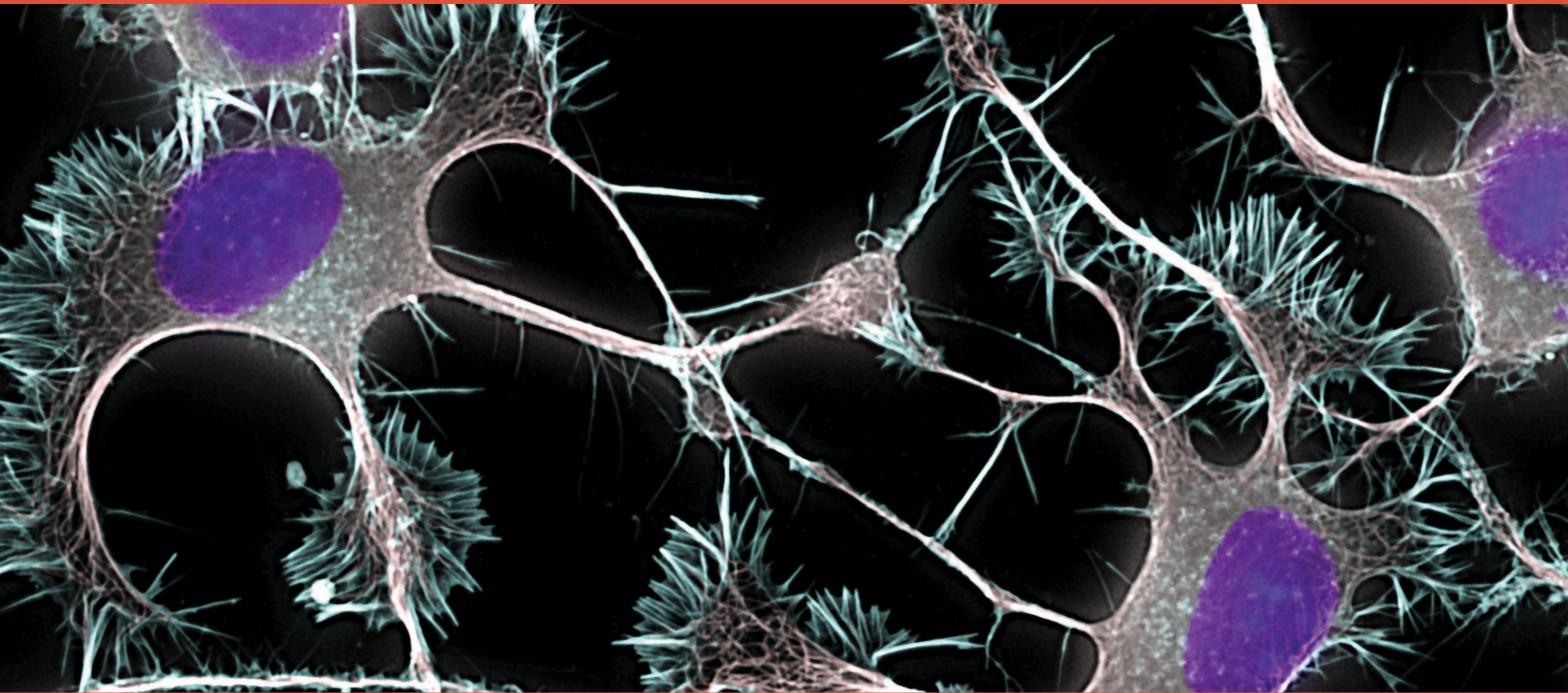
**NERVOUS SYSTEM 82-83**

**NEURONS 84-85**

**THE BRAIN 86-87**

**THE PERIPHERAL NERVES 88-89**

**DREAM AND MEMORY 90-91**



**B**rain tissue consists of thousands of millions of neurons that continually send each other signals through connections called synapses.

Thanks to this network the brain can remember, calculate, decide, think, dream, create, and express emotions. We invite you to understand the secrets about how these activities of the brain

are accomplished. What determines the formation of synapses and neuronal networks? Where are intelligence and memory located? Is it possible to stimulate brain cells? What happens

during a dream? What are nerves, and how are they formed? What functions are carried out by each region of the brain? You will find all this and much more in this chapter, including incredible images. ●



# Nervous System

The body's most complex system, many of whose characteristics and potentialities are still unknown. Together with the endocrine system, the brain has the job of controlling the organism. Its specific functions are rapid and intellectual

activities, such as memory, emotions, and will. The brain is divided into three portions: the central (the brain and the spinal cord), the peripheral (nerves of the spinal cord and cranium), and the vegetative (or autonomic function). ●

## The Great Coordinator

The nervous system acts as the great coordinator of the functions of all the parts and organs of the body. In simpler organisms, such as unicellular organisms, the same cell receives sensations and responds to them without requiring intermediation or specialized coordination. However, in more complex organisms such as the human body, the cells of the different parts of the body are differentiated, as are the functions of the organs that these cells make up. Thus there are receptor cells, which receive stimuli (such as the cells of the organs linked to the eye or the senses). There are also effector cells (such as those of the muscles or the glands), which are involved in the organism's responses. The nervous system links these functions together through its three principal parts: the brain, the spinal cord, and the nerves in general. The nerves consist of numerous axons and dendrites, enveloped by a sheath of conjunctive tissue. These groups of neurons are called ganglia when they are outside the brain and the spinal cord, and they are called nuclei when they are inside.

**300 feet (90 m) per second**

THE SPEED AT WHICH IT IS CALCULATED THAT A NERVE IMPULSE TRAVELS IN A NERVE WITH A MYELINATED SHEATH

## Central

Consists of the brain (cerebrum, cerebellum, and spinal bulb) and the spinal column. It receives information from the sense organs and sends instructions to the muscles and other organs. It also processes and coordinates the nervous signals transmitted by the peripheral system.

## Peripheral

Its functions are to provide information to the central nervous system and to coordinate movements. It is divided into sensory, somatic, and autonomic divisions. The sensory division informs the central nervous system about external changes detected by the senses (such as pain) or internal changes (such as a full bladder). The somatic division sends instructions for the conscious movement of different muscles, such as for shaking hands or kicking a ball. The autonomic division (vegetative nervous system) automatically controls the functioning of the internal organs, such as the heart.

**BRAIN**  
The great center of activity

**FACIAL NERVE**  
Permits the movement of facial muscles

**COMMON PALMAR DIGITAL NERVE**  
Controls the muscles of the palm of the hand

**CEREBELLUM**  
Controls equilibrium and the coordination of movements

**VAGUS NERVE**  
Branches out toward various organs and participates in the control of cardiac rhythm

**SPINAL CORD**  
A bundle of nerves that starts at the base of the brain and extends along two thirds of the vertebral column

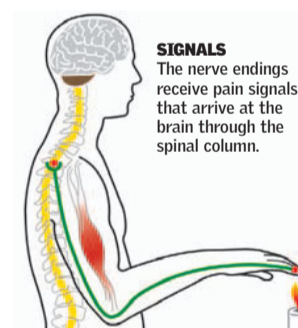
**LUMBAR PLEXUS**  
Controls the lower region of the shoulder and part of the hip and the legs. It receives the nerves that arise in the lumbar region of the spine.

**MEDIAL NERVE**  
Controls the muscles that cover the wrist and surround the forearm

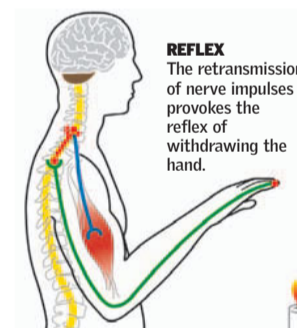
**CUBITAL NERVE**  
Muscles of the forearm and hand

**SCIATIC NERVE**  
Innervates the joints and muscles of the hip tendon

## PAIN AND THE NERVOUS RESPONSE



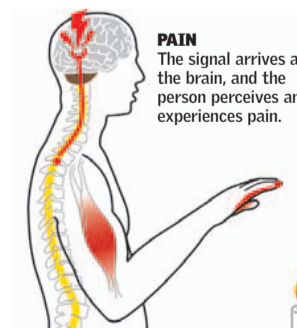**SIGNALS**  
The nerve endings receive pain signals that arrive at the brain through the spinal column.



**REFLEX**  
The retransmission of nerve impulses provokes the reflex of withdrawing the hand.

**1** The reflex action of withdrawing the hand or another part of the body from an object that may cause pain (for example, by being pricked or subjected to heat) is an automatic response. Thus the pain receptors in the skin of the fingers detect the heat stimulus from a flame and send nerve impulses via the sensory nerves to the spinal cord. The impulses move at high speed through the medulla along pathways of associated neurons.

**2** Within thousandths of a second after detecting the pain stimulus, the nerve impulses reach the motor neurons. These neurons transmit the impulses to the flexor muscles in the upper part of the arm. Once the impulses have been received, the muscles contract, the arm bends, and the fingers move away from the flame before any pain is consciously felt.



**PAIN**  
The signal arrives at the brain, and the person perceives and experiences pain.

**3** The pain is felt when the nerve fibers in the spinal cord bring the nerve impulses to the sensory areas of the brain. The sensation of pain is felt only after the hand has been withdrawn from the fire by reflex action.

**TIBIAL NERVE**  
Innervates the muscles of the leg

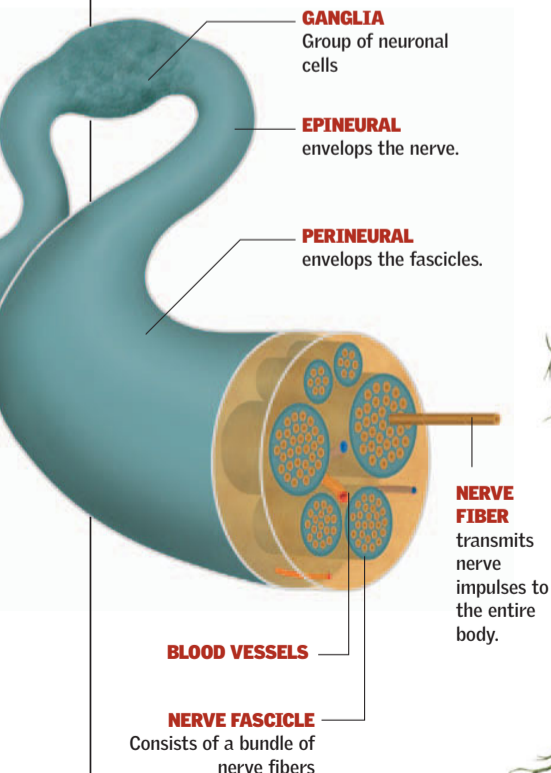
**COMMON NERVE OF THE FIBULA**  
Controls the movements of the muscles that lift the leg

**EXTERNAL PLANTAR NERVE**  
Permits flexion of the toes

**0.001**

WHEN A FIBER TRANSMITS A NERVE IMPULSE, A CERTAIN AMOUNT OF TIME IS NEEDED BEFORE IT CAN TRANSMIT THE NEXT IMPULSE. THIS "REST," WHICH IS KNOWN AS THE REFRACTORY PERIOD, LASTS BETWEEN 0.001 AND 0.005 SECOND.

## Structure of a Nerve



**GANGLIA**  
Group of neuronal cells

**EPINEURAL**  
envelops the nerve.

**PERINEURAL**  
envelops the fascicles.

**NERVE FIBER**  
transmits nerve impulses to the entire body.

**BLOOD VESSELS**

**NERVE FASCICLE**  
Consists of a bundle of nerve fibers



# Neurons

Neurons are cells that make up the nervous system. Their function is to transmit impulses in the form of electrical signals carrying information to the brain and from there to the periphery. The neurons provide the basis for the system's activities and form a highly complex communication network. They are surrounded and protected by other nerve cells that are not excitable, called glial cells, which constitute more than half of all an organism's nerve cells. ●

## Plasticity

Each neuron is essentially made up of a body, an axon, and many dendrites. The communication that is established among neurons resembles a conversation, or a continuous ongoing exchange of information. Until recently it was thought that neurons, unlike other tissue, could not be regenerated once lost. Today not only is it known that this is not so, but it is also known that the capabilities of the brain and the nervous system are more a function of the circuits and connections that are established among the neurons than of the number of neurons per se. These connections are activated, deactivated, and modified by very diverse factors (such as learning, food, habits, exercise, the effects of drugs and accidents). Some neurons can regenerate if they have been damaged.

**SYNAPTIC NODE**  
The terminal point of the axon branch, it contains chemicals that transmit nerve impulses.

**MYELIN SHEATH**  
A fatty layer that insulates the axons of some neurons in order to accelerate nerve impulse transmission. In the peripheral nervous system, this sheath consists of Schwann cells.

**RANVIER'S NODE**  
An opening in the myelin sheath that aids in the transmission of nerve impulses

**MITOCHONDRIA**  
provide energy to the cell.

**AXON**  
Nerve fiber that transmits impulses

**NUCLEUS**  
Contains the neuron's genetic material

**SCHWANN CELL**  
A glial cell that surrounds an axon

**CELL BODY**  
Generates the vital processes of the neuron cell

**DENDRITE**  
Protuberance that captures signals from other neurons. A neuron can have about 200 dendrites; the number of dendrites varies from cell to cell.

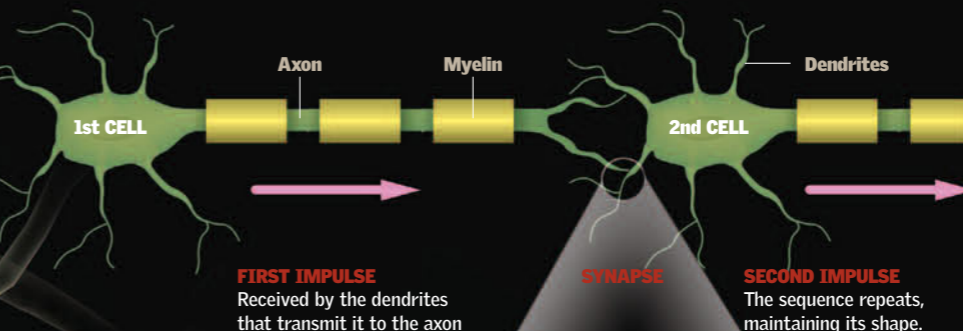
**100 billion**  
THE NUMBER OF INTERCONNECTED NEURONS IN A HUMAN BEING

**500 million**  
IS THE NUMBER OF SYNAPSES (CONNECTIONS AMONG NEURONS) FORMED IN 0.06 CUBIC INCH (1 CU MM) OF A BRAIN'S NERVE TISSUE. OVERALL, THE BRAIN HAS 1 QUADRILLION SYNAPSES.

## Transmission and Synapses

The synapse is the point of communication between neurons. It comprises a synaptic cleft, a synaptic knob, and a target to which the nerve signal is directed. In order for a neuron to be activated, there must be a stimulus that converts the electrical charge inside the membrane of the cell from

negative to positive. The nerve impulse travels via the axon toward the synaptic knob and brings about the release of chemical substances called neurotransmitters. These in turn can elicit a response from the target to which the stimulus is directed.



### COMPONENTS OF THE SYNAPSE

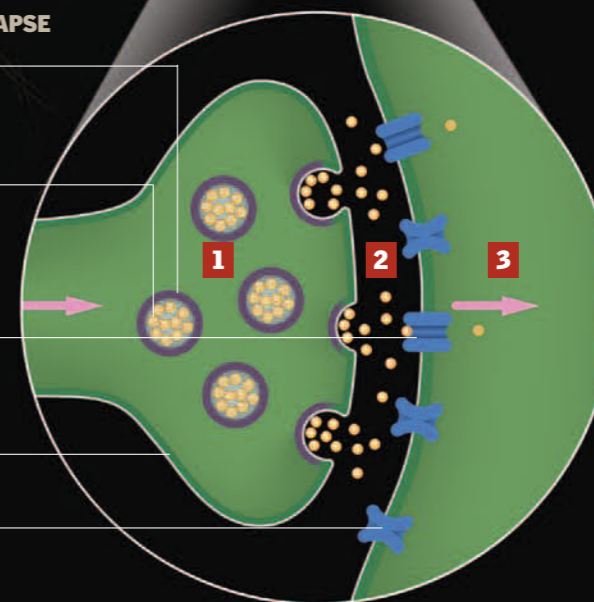
**SYNAPTIC VESICLES**  
Sacs that contain neurotransmitter molecules brought to the synaptic cleft via calcium ions

**NEUROTRANSMITTERS**  
Chemical molecules released by the synaptic vesicles toward the synaptic cleft. From there they influence the transmission of the impulse.

**POINT OF RECEPTION**  
The neurotransmitter combines with protein receptors at the point of neuronal communication.

**CELL MEMBRANE**  
The charge inside the cell membrane is negative.

**MICROTUBULES**  
Structures that help transport neurotransmitter molecules to the synaptic membrane.



### TRANSMISSION OF NERVE IMPULSES

**1 Without Information**  
When the neuron is at rest, the sodium ions inside it are uniformly distributed so that the electrical charge inside the cell membrane is permanently negative.

**2 The Impulse Arrives**  
The arrival of the neurotransmissions at the dendrites causes a reversal of the charge, which becomes positive in this area, giving it a tendency to move in the direction of the negatively charged part of the cell.

**3 Transmission of Information**  
The positive charge travels toward the negatively charged axon until it reaches the synapse and thus the other cell. The areas it has left return to their stable (negative) state.

### TYPES OF NEURONS ACCORDING TO THEIR COMPLEXITY

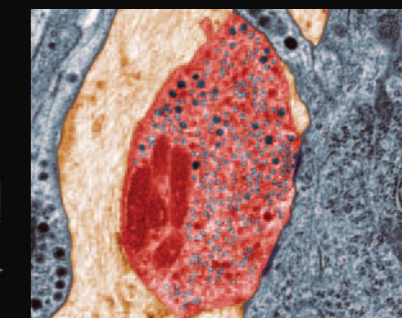
**UNIPOLAR.** Two branches of the same axon extend from one cell body.

**BIPOLAR.** Two separate axons extend from each end of a cell body.

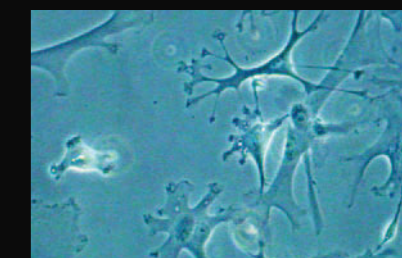
**MULTIPOLAR.** One axon and a number of dendrites extend from a cell body.

## Neuromuscular Union

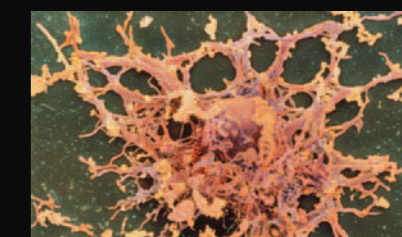
This is a special kind of synapse between the neurons and the skeletal muscle fibers that causes voluntary contraction of the muscles.



The axon of a neuron links itself with a muscle fiber. At the point of contact a chemical synapse is produced between the neuron and an effector, a muscle with electrically excitable tissue, and movement results.



**ASTROCYTES** are cells located in cerebral tissue, where they exceed neurons in number. Astrocytes have some delicate protuberances that are linked to the blood vessels and that regulate the flow of nutrients and waste between neurons and blood.



**OLIGODENDROCYTES** are the cells that form the myelin sheath around the nerve fibers of the brain and the spinal column. Their function is similar to that of Schwann cells in the peripheral nervous system



# The Brain

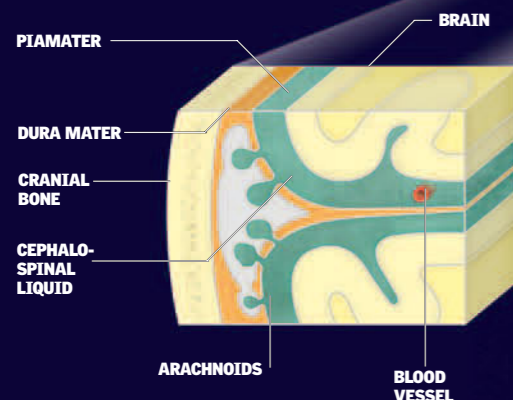
The brain is the body's control center. Underneath its folds more than 100 billion neurons organize and examine incoming information and act as a guide for the organism. In spite of amounting to only 2 percent of the total weight of a human body, the brain alone uses one fifth of the oxygen inhaled. It is one of the most fragile parts of the body and, therefore, one of the most protected. Along with the spinal cord, the brain forms the central nervous system, which gives instructions to the peripheral nervous system. ●

**3 pounds (1.4 kg)**

AVERAGE WEIGHT OF AN ADULT BRAIN. AT BIRTH THE BRAIN WEIGHS BETWEEN 12 AND 14 OUNCES (350 AND 400 G).

## MENINGES

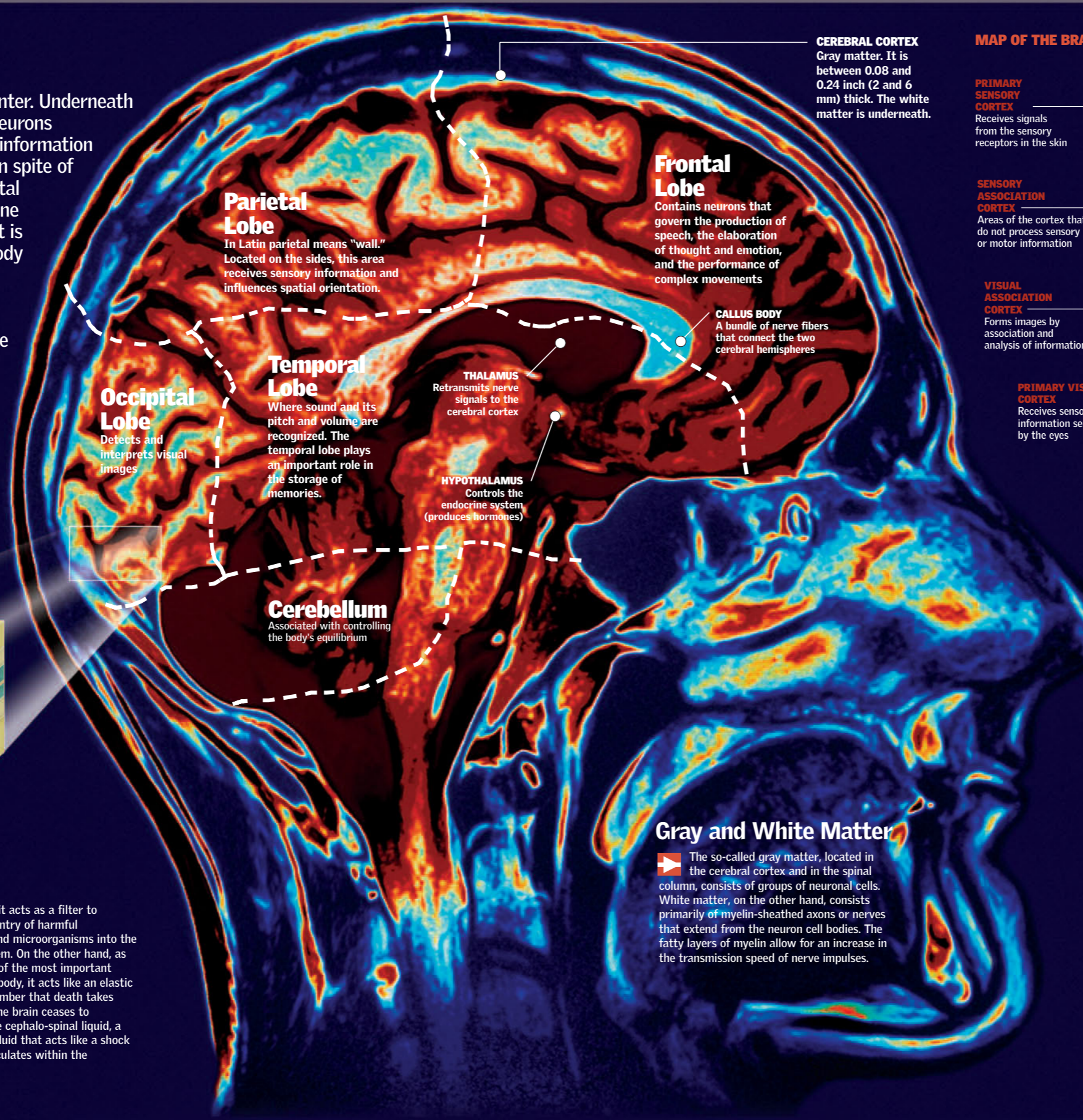
Protective membranes covering the brain



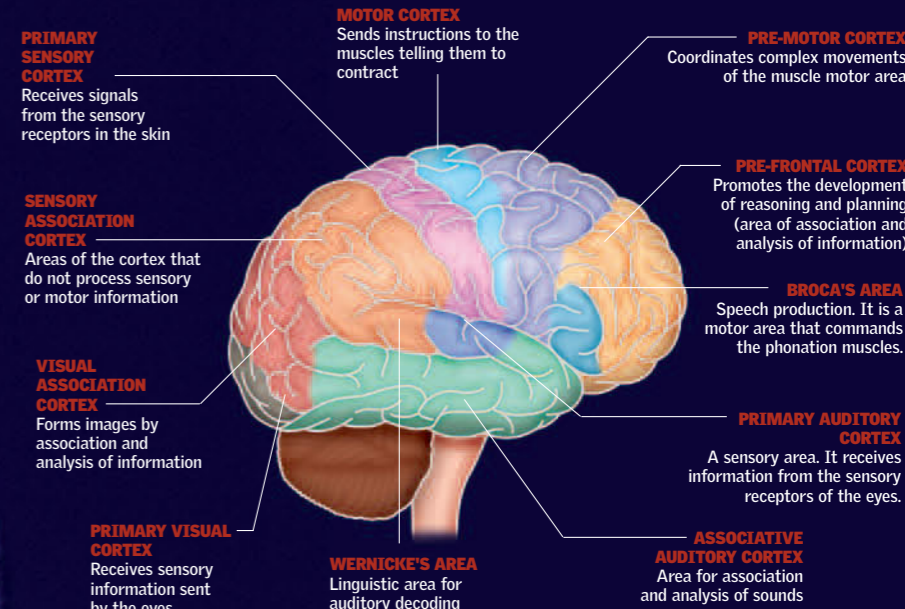
## Meninges

There are three membranes, called meninges, that cover the brain. The outermost one covers the inside of the cranium, and it contains veins and arteries that feed blood to the cranial bones. It is called dura mater. The middle membrane is known as the arachnoid and consists of netlike elastic connective tissue. The pia mater, the thinnest of the three, is the closest to the surface of the cerebral cortex. Its functions are primarily protective.

On one hand it acts as a filter to prevent the entry of harmful substances and microorganisms into the nervous system. On the other hand, as the covering of the most important organ of the body, it acts like an elastic helmet (remember that death takes place when the brain ceases to function). The cephalo-spinal liquid, a transparent fluid that acts like a shock absorber, circulates within the meninges.



## MAP OF THE BRAIN



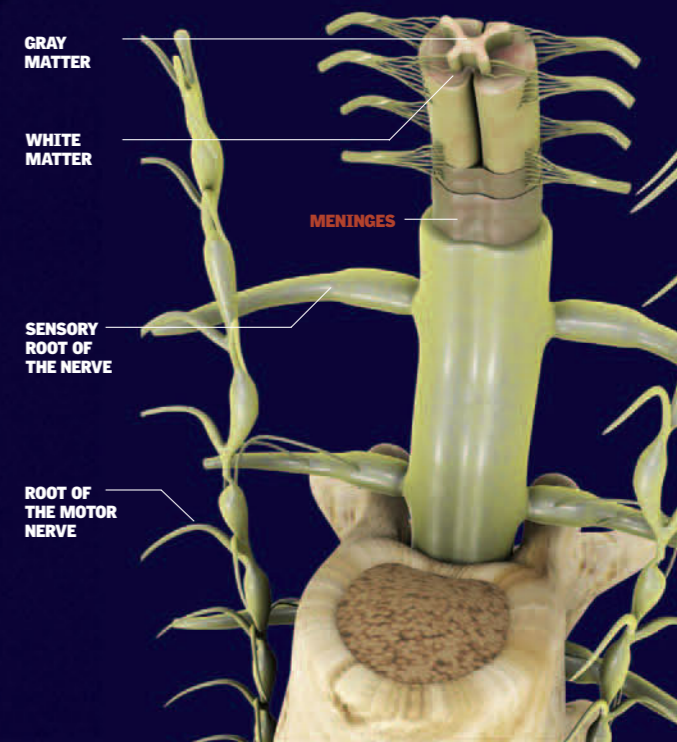
## Spinal Medulla

The spinal medulla is the spinal cord, which goes from the cephalic trunk to the lumbar region. Together with the brain it forms the central nervous system. It can reach a length of 18 inches (45 cm). It is composed of gray and white matter. The gray matter is located in its core, in tissue consisting essentially of neurons.

Surrounding the gray matter is white matter that contains the nerve fibers that transmit signals to and from the brain. The spinal nerves extend outward from the medulla to the body and its extremities. Paralysis in one or more parts of the body can result if the spinal cord is damaged.

## Gray and White Matter

The so-called gray matter, located in the cerebral cortex and in the spinal column, consists of groups of neuronal cells. White matter, on the other hand, consists primarily of myelin-sheathed axons or nerves that extend from the neuron cell bodies. The fatty layers of myelin allow for an increase in the transmission speed of nerve impulses.



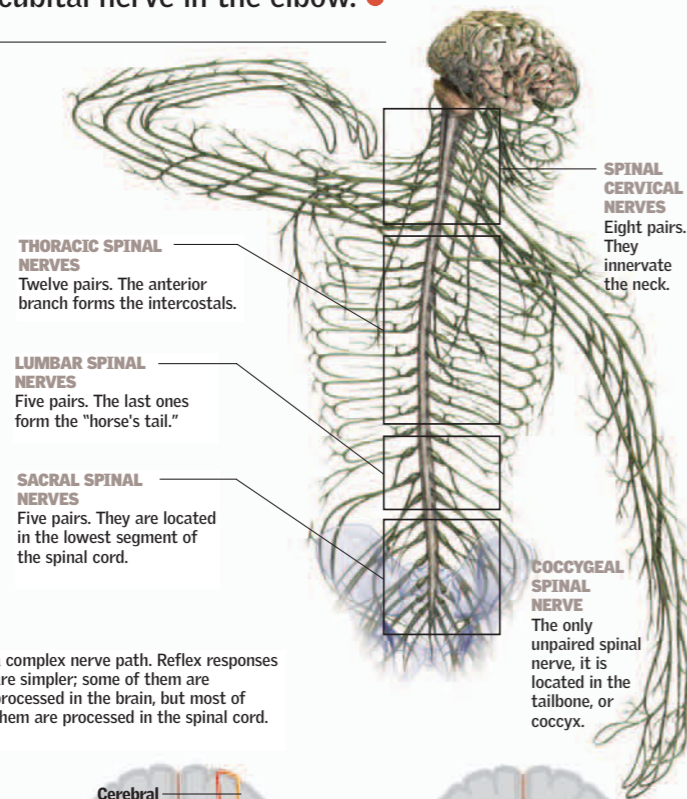


# Peripheral Nerves

The peripheral nerves have the task of bringing information to and from the brain and spinal column. Depending on their location, they may be cranial or spinal nerves. The sensory fibers in the peripheral nerves receive information from the outside world, the skin, and the internal organs and transmit it to the central nervous system; the motor fibers begin to contract the skeletal muscles and transmit signals in the opposite direction from the sensors. The nerves are located deep in the body, with some exceptions, such as the cubital nerve in the elbow. ●

## Spinal Nerves

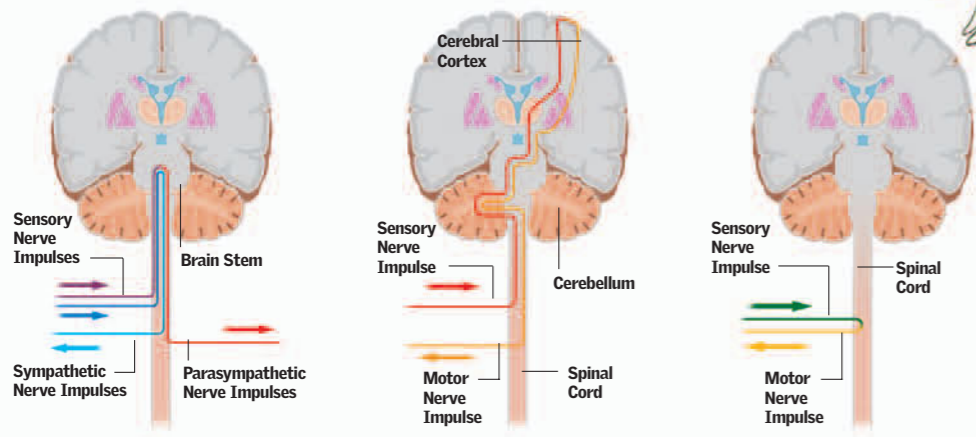
There are 31 pairs of spinal nerves that begin at the spinal cord and extend through the spaces between the vertebrae. Each nerve is divided into numerous branches. These nerves control most of the body's skeletal muscles, as well as the smooth muscles and the glands. The cervical nerves serve the muscles of the chest and shoulders. The lumbar nerves serve the abdomen and part of the legs, and the sacral nerves control the rest of the legs and the feet.



## THE THREE RESPONSES

The nerve receptors gather information that goes to the cerebral cortex and to the spinal cord. The response can be automatic, ordering dilation or contraction. Voluntary response implies

a complex nerve path. Reflex responses are simpler; some of them are processed in the brain, but most of them are processed in the spinal cord.



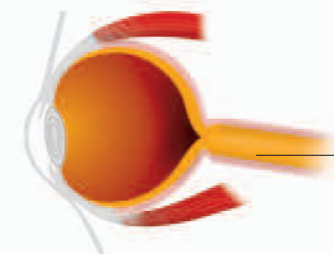
**A AUTOMATIC RESPONSE**  
The impulses, or sympathetic (dilation) or parasympathetic (contraction) response signals, travel over separate pathways.

**B VOLUNTARY RESPONSE**  
The sensory impulses that activate voluntary responses occur in various areas of the brain. The nerve path is complex.

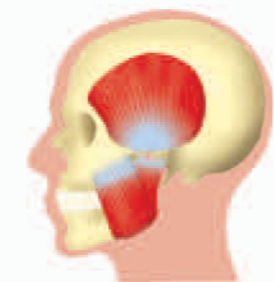
**C REFLEXES**  
Some are processed in the brain, but most of them are processed in the spinal cord, where the impulse is processed and the reply is sent.

## Cranial Nerves

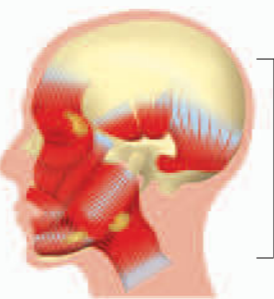
The 12 pairs of cranial nerves extend from the lower part of the brain, as can be seen in the main illustration. Except for the vagus nerve, the cranial nerves control the muscles of the head in the neck region or bring nerve impulses from sense organs, such as the eyes, to the brain. In the case of nerve impulses that come from the eyes, it is the pair of optical nerves that record the sensations from the retina of the eye. The olfactory nerve works the same way for the nose.



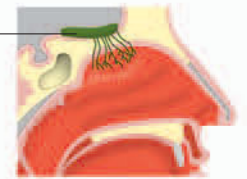
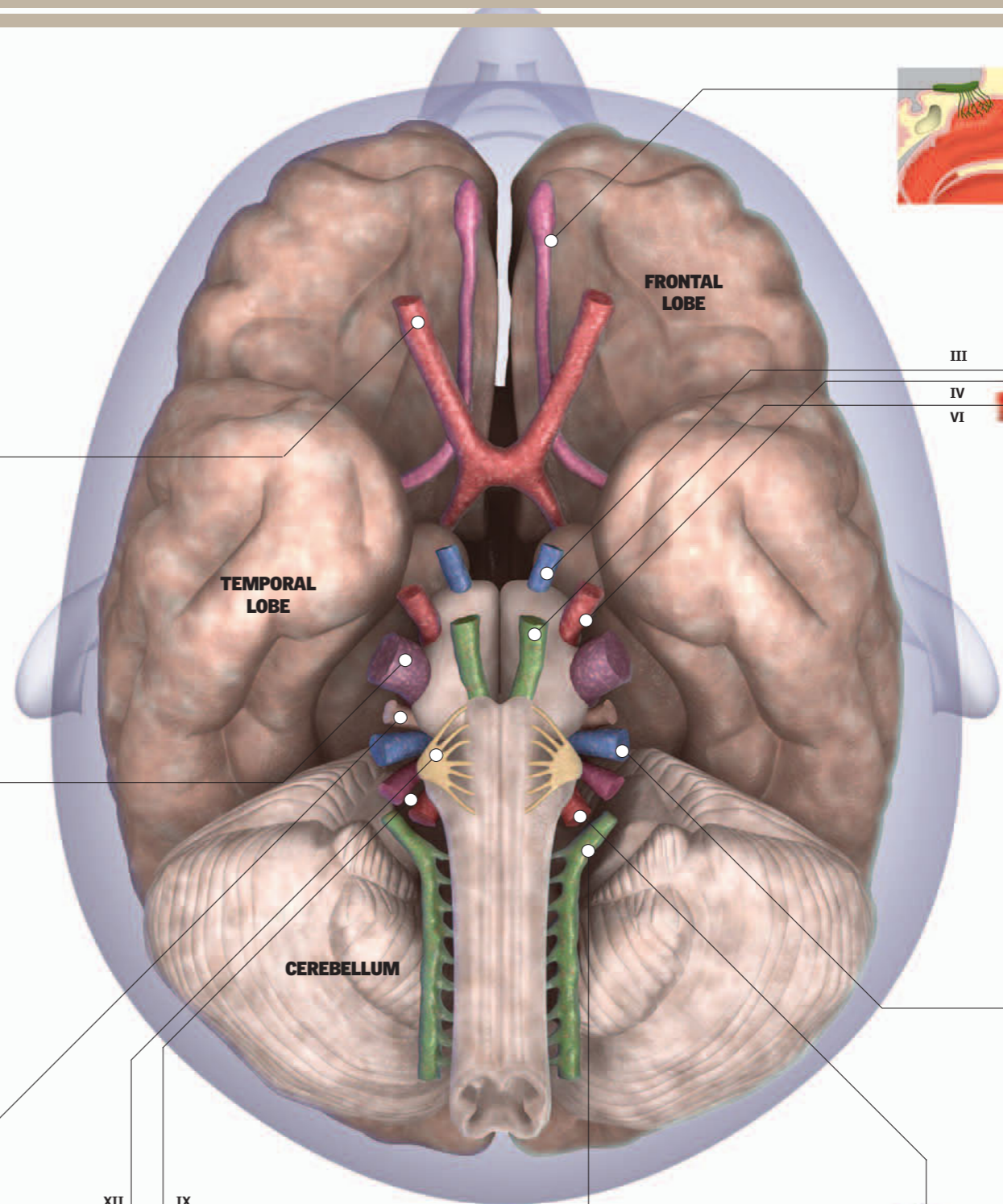
**PAIR II**  
Optic nerve. Supplies the retina. Transmits signals, from the photo receptors, perceived as vision.




**PAIR V**  
Trigeminal nerve. Controls the muscles involved in chewing and transmits sensory information from the eyes, the teeth, and the side of the face.



**PAIR VII**  
Facial nerve. Controls the muscles of facial expressions and the salivary and tear glands. Transmits sensory information from the taste buds.



**PAIR I**  
Olfactory nerve. Innervates the internal and upper region of the nose and transmits signals from the olfactory cells that are perceived as the sense of smell.



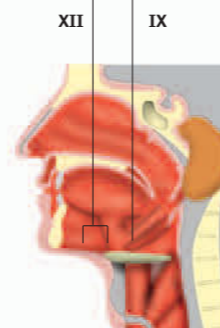
**PAIR III**  
Oculomotor nerve. Controls the movements of the eye and the eyelid. It changes the shape of the pupil and the lens.

**PAIR IV**  
Trochlear nerve. Controls the oblique muscle above the eye.

**PAIR VI**  
Abducens nerve. The nerve that moves the external lateral rectus muscle of the eye.

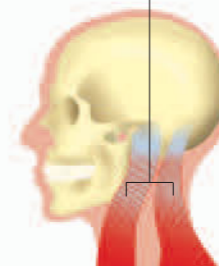


**PAIR VIII**  
The cochlear vestibular nerve. Transmits sensory signals from the inner ear, which are perceived as sound; enables equilibrium.

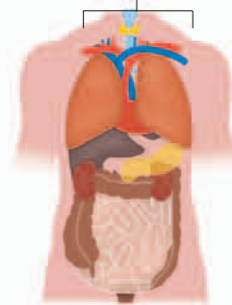


**PAIR IX**  
Glossopharyngeal nerve. Controls the salivary glands and transmits sensory signals from the tongue and the pharynx.

**PAIR XII**  
Hypoglossal nerve. Controls the movements of the tongue.



**PAIR XI**  
Accessory nerve. Its function is to control the muscles involved in swallowing and moving the head.



**PAIR X**  
Vagus nerve. Also called the 10th cranial nerve. Among its other functions, it controls the muscles and glands of various internal organs, such as the heart, the lungs, and the stomach.



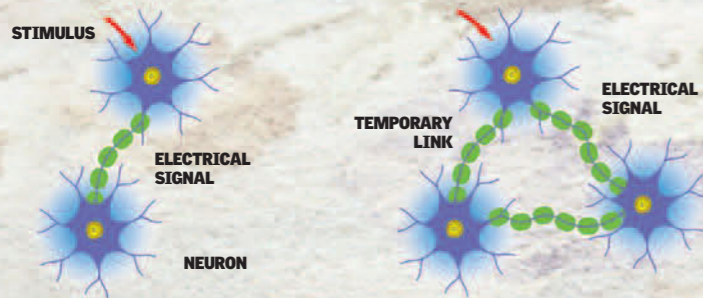
# Dream and Memory

To be able to process the information gathered during the day, the brain takes advantage of periodic dream states. During a dream the brain reduces its activities, and its patterns of thought are disconnected from the external world. The passage from consciousness to dreaming (and from dreaming to consciousness) is the task of neurotransmitters, chemical substances that are manufactured and released from the reticular activator system, a regulator in the cephalic talus, which lies in the brain stem. ●

## Formation of Memory

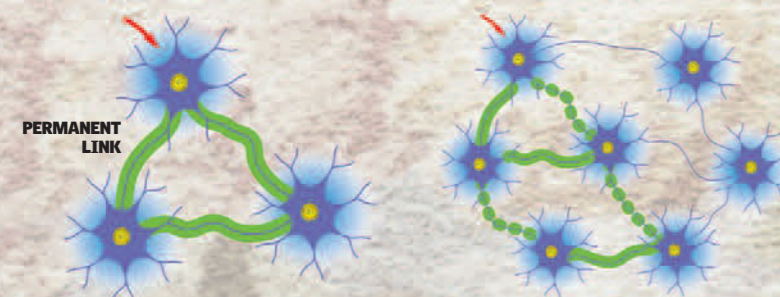
Memory is a set of processes in which unconscious associations are capable of retaining and recording highly varied information. This information can be perceived consciously or unconsciously and ranges from

ideas and concepts to sensations that were previously experienced or processed. Memory has many forms, but the two basic ones are the long-term and short-term memory.



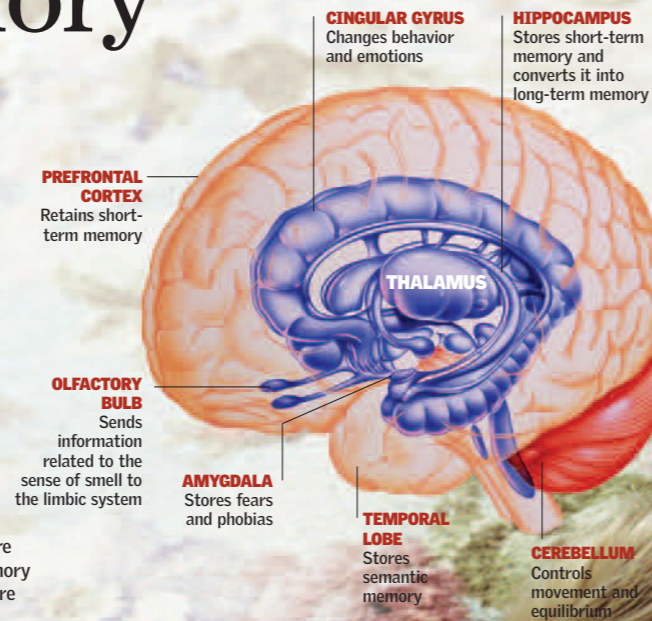
**1 CONNECTION.** An experience triggers a pattern (or model to be repeated), exciting two neurons. To form long-term memory the template that was generated earlier by the short-term memory must be replicated. When a stimulus is received, the neuron reacts, sending an impulse to a neighboring neuron.

**2 LINK FORMATION.** The nerve impulses sent to the neighboring neurons generate a greater capacity for response from the cells that sent the impulses. A temporary union is formed among the cells. In the future, they will be more likely to trigger a nerve impulse together. A neuronal template is beginning to be created.



**3 DEEPER LINKS.** Every time an event is remembered, a nerve impulse is triggered. As a recollection is repeated, the neurons become more solidly connected. Then the neurons begin to send joint impulses, no matter which was excited first. The development of connections is strengthened with repetition or notable or stressful events.

**4 EXPANDING NETWORK.** With successive repetition, different groups of neurons begin to form a neuronal network that represents the long-term memory. The more complex the network, the more accessible and durable the memory will be. Each group of neuronal cells represents a different aspect through which one accesses the complete memory.



## Limbic System

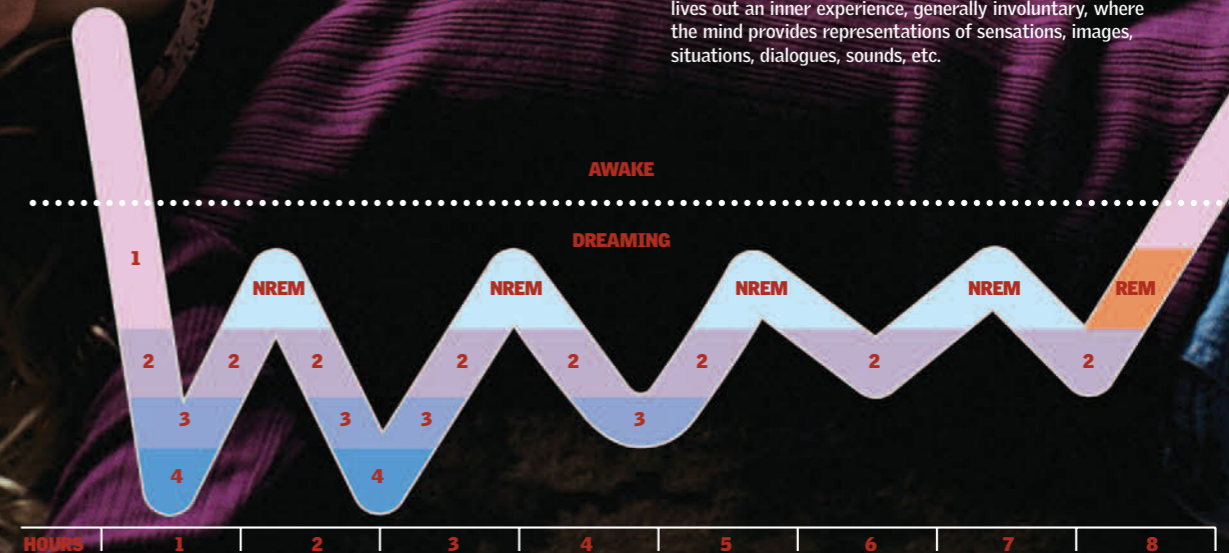
Consists of a complex of structures that wrap around the upper part of the brain stem. These structures control emotions such as annoyance and happiness. They protect us from danger and play an important role in memory formation. For example, the amygdala produces fear when processing danger. The hippocampus permits us to store and remember short-term memories that are brought to the cortex. When the hippocampus is damaged, new memories cannot be incorporated.

## REM

The acronym for Rapid Eye Movement. The eyes move, though the body is stationary.

## Dream Patterns

A pattern is a model that serves as a template, or mold, to obtain the same format. During sleep the two great patterns are REM and NREM, with their four phases. REM sleep is the most enigmatic; it is thought that dreams are produced during REM. During that time the human being lives out an inner experience, generally involuntary, where the mind provides representations of sensations, images, situations, dialogues, sounds, etc.



**PHASE 1**  
Transition between waking and sleeping. The electroencephalograph (EEG), a device that measures cerebral activity, registers alpha waves. The body is relaxed, but if someone disturbs the sleeping person then he or she will wake up.

**PHASE 2**  
Second-phase NREM. The EEG pattern is more irregular. Waking up the person is more difficult.

**PHASE 3**  
Delta waves appear. The vital signs decrease: respiration and the heartbeat slow down, and the body temperature falls.

**PHASE 4**  
Now the dream phase or phase of deep sleep occurs. The delta waves are dominant, and the vital signs drop to minimal levels.

**PHASE REM**  
Rapid Eye Movement. The vital signs increase. The skeletal muscles become inhibited. Dreams enter the scene.

**20 seconds**

THE TIME AFTER WHICH SHORT-TERM MEMORY LOSES INFORMATION (SUCH AS A TELEPHONE NUMBER) THAT HAS NOT BEEN USED



# Glossary

## Acid

Substance that, in solution, increases the concentration of hydrogen ions and combines with bases to form salts.

## Adrenaline

Hormone secreted primarily by the adrenal medulla of the adrenal glands. It constricts blood vessels and is used as a medicine.

## Allele

Gene variant that encodes a trait. One diploid cell contains one allele of each parent for each characteristic.

## Amino Acid

Organic chemical whose molecular composition includes an amino group (derived from ammonia) and a carboxyl group (a radical that characterizes organic acids).

## Antigen

Substance that causes an immune response, such as the production of antibodies, when introduced into the body.

## Aorta

Largest artery in the body, originating in the left ventricle of the heart. Down to the diaphragm it is called the thoracic aorta and then the abdominal or ventral aorta to the point where it branches.

## Aortic Arch

Curve in the aortic artery near its origin at the heart. The arch has the shape of a shepherd's crook.

## Apparatus

Complex of organs that fulfills one function. In the physiology of the human body it is also used as a synonym for system. For example, the digestive apparatus, reproductive apparatus, or respiratory apparatus.

## Artery

Blood vessel that brings blood from the heart to the entire body.

## Arthroscopy

Surgical procedure used by orthopedic surgeons to inspect, diagnose, and treat problems in the joints. It consists of making a small incision and inserting an arthroscope, an instrument the size of a pencil that contains a small lens and a lighting system to magnify and illuminate the interior. The light is transmitted via fiber optics to the end of the arthroscope, and the interior of the joint can be observed via a miniature television camera.

## Articulation

Joint between two bones of the body.

## ATP

Adenosine triphosphate. A molecule produced primarily by mitochondria that functions as the primary energy source for the cells.

## Atrium

The name for each of the two chambers of the heart that receive blood from the veins.

## Basal Metabolism

Activity level of the body functions during rest or while fasting.

## Bones

Rigid structures, rich in calcium, that make up the skeleton.

## Carpal

The structure of the wrist, composed of eight connected bones arranged in two rows. On the side toward the arm it joins with the cubital and radial bones, and on the side toward the hand it joins with the metacarpal bones.

## Cartilage

Flexible skeletal tissue consisting of isolated groups of cells within a collagenous matrix.

## Celiac Artery

Artery that brings blood from the heart to the stomach and the other organs of the abdomen.

## Cellular Membrane

The flexible covering of all living cells, which contains the cytoplasm. It regulates the exchange of water and gases between the cell and its exterior.

## Chromatin

Complex substance in the cell nucleus composed of nucleic acid and proteins.

## Cilium

Tiny hairlike protuberance on a cell with a locomotive function in a liquid medium.

## Coagulation

Organic process in which the blood turns from a liquid to a solid state and whose normal purpose is to stop bleeding.

## Coccyx

Bone formed by the fusion of the last vertebrae. At its base it articulates with the sacral bone. In human beings and other vertebrates that do not have a tail, it is an actual bone.

## Coronal

A name given to the frontal bone, located at the anterior and superior part of the cranium. At birth the frontal bone or coronal is divided into two halves, which fuse over time. In medicine this can also refer to a suture that joins the frontal bone with the two parietal bones.

## Coronary Arteries

A pair of arteries, originating in the aortic artery, that branch out and supply blood to the heart.

## Cortex

The gray material present in most areas of the brain. It is the largest part of the central nervous system. The majority of the most advanced functions occur in the cortex.

## Corticoids

Hormonal steroids produced by the adrenal gland cortex. Corticoids can be produced artificially. They have a therapeutic application as anti-inflammatory drugs.

## Cystoscope

Apparatus used to explore the inner surface of the bladder.

## Cytoplasm

A compartment of eukaryotic cells, bounded by a cellular membrane and the membranes of the cell's organelles.

## Diaphragm

Respiratory muscle between the thorax and the abdomen.

## Digestion

The set of processes through which the digestive system converts food into substances that can be assimilated by the organism.

## Diploid

A cell with two complete sets of chromosomes. It is denoted by the symbol 2n.

## Dislocation

The displacement of any bone from its normal position in a joint.

## DNA

Deoxyribonucleic acid. A double helix molecule containing encoded genetic information.

## Ejaculation

The action of expelling semen.

## Embryo

The result of the fertilization of an ovum by a sperm cell. It can develop to become a mature organism.

## Emulgent Arteries

Arteries that bring blood from the heart to the kidneys, also called renal arteries.

## Endocardium

Membrane that lines the walls of the heart. It consists of two layers: an exterior, consisting of connective tissue, and an interior, of endothelial tissue.

## Endometrium

Mucous membrane covering the inner walls of the uterus.

## Endoplasmic Reticulum

Network of membranes in the cell that are interconnected through the cytoplasm and whose function is the synthesis and assembly of proteins.

## Endothelial

Organic tissue that lines wall-like structures within the body, such as those of the pleura or of blood vessels.

## Enzyme

Protein that helps regulate the chemical processes within a cell.

## Erythropoiesis

The creation of red blood cells, stimulated by the action of a protein called erythropoietin.

## Follicle

Inward fold of the epidermis in the form of a sac, which usually surrounds the base of a hair.

## Gene

Unit of information of a chromosome; it is a sequence of nucleotides in a DNA molecule that fulfills a specific function.

## Gland

Organ that has the function of producing secretions that can be expelled through the skin or mucous membranes (salivary glands or sweat glands, for example) or into the bloodstream (the thyroid, for example).

## Haploid

From the Greek *haplous*, meaning single. A haploid cell has a single set of chromosomes, unlike the diploid cells. Gametes are haploid.

## Hemostatic

Substance or agent that halts hemorrhaging.

## Hippocampus

Part of the brain that governs the memory.

## Holocrine

Gland with an exclusively secretory function or whose secretion consists of disintegrated cells of the gland itself, such as the sebaceous glands.

## Homeostasis

Complex of self-regulatory phenomena that keep the composition and the properties of the body's internal environment constant. It is said that homeostasis is reached when the body's internal environment contains the optimum concentrations of gases, nutrients, ions, and water; when



its temperature is optimum; and when the volume of fluids is optimum for the life of the cells.

## Hormone

The product of the glandular secretion whose function is to stimulate, inhibit, or regulate the action of other glands, systems, or organs of the body.

## Innominate Bones

A pair of bones, one in each hip, which join the sacrum and the coccyx to form the pelvis. They consist of the fusion of the iliac, the ischium, and the pubic bones.

## Lobes

Rounded protuberances of organs, such as the liver, the lungs, or the brain.

## Lysosome

Protein that can break down the constituent substances of the walls of certain bacteria and is, hence, a potent antibacterial.

## Meiosis

Type of cell division in which two successive divisions of the nucleus of a diploid cell create four haploid nuclei. As a result of this mechanism, gametes or spores are produced.

## Meristem

Tissue with cells that produce other cells by cellular division.

## Metabolism

Complex of chemical reactions that take place continuously within cells to synthesize complex substances from simpler substances or to degrade a substance into simpler substances. An example is the digestive process.

## Metacarpal

Middle part of the skeletal structure of the hand, between the wrist (carpal bones) and the phalanges. It consists of five bones, which are the largest bones of the hand.

## Metatarsal

Part of the skeletal structure of the foot, between the tarsus (posterior part of the foot) and the phalanges (toes). It consists of five bones and is usually called the sole of the foot.

## Micturition

Act of urinating, or expelling urine.

## Mitochondria

Organelle that has a double membrane. The final stage of the aerobic respiration process takes place in mitochondria, where ATP is obtained by breaking down sugars and other substances.

## Mitosis

Nuclear division in a cell that forms daughter nuclei identical to the parent.

## Mucous Membrane

Covering of body cavities that communicate with the exterior (such as the nose). A mucous membrane contains numerous single-celled glands that secrete mucus.

## Muscles

Organs composed of fibers capable of contracting.

## Myocardium

Muscular part of the heart, between the pericardium and the endocardium.

## Nucleic Acid

Molecule that carries genetic information about the cell. There are two types: DNA and RNA.

## Nucleus

The part of the cell that contains the DNA with its genetic information.

## Organ

Any part of the body that accomplishes a function.

## Osmosis

Movement of a liquid through a selectively permeable membrane.

## Papillae

Conical protuberances, usually sensory, formed on the skin or mucous membranes (especially the tongue) by the branching of nerves and blood vessels.

## Pericardium

Pair of membranes that surround the heart.

## Phagocytes

Cells found in blood and tissue. They capture bacteria or any other kind of noxious particles and "phagocytize," or "eat," them, absorbing them into their cytoplasm and later digesting them.

## Phalanges

Bones of the fingers and toes. They extend to the metacarpal bones in the hand and the metatarsals in the foot. Starting from the metacarpals and the metatarsals, they are sequentially numbered: first, second, and third phalanges (of each finger or toe). The word "phalanges" commonly designates the first phalanges, or each of the jointed parts of the fingers or toes.

## Physiology

Study of the functions of the organism.

## Polymer

Macromolecule consisting of repeated structural units, called monomers.

## Popliteus

Section of the leg opposed to, or behind, the knee.

## Protein

Substance that makes up the cells. It is a biopolymer consisting of one or several chains of

amino acids, fundamental for the constitution and functioning of living material, such as enzymes, hormones, and antibodies.

## Ranine Artery

Artery that branches out toward the front of the tongue.

## Respiration

The act and effect of inhaling air, primarily through the nose, to take in the substances that the body requires, such as oxygen, and after processing them exhaling unneeded substances, such as carbon dioxide.

## Ribosome

Organelle located in the cytoplasm that governs the formation of proteins based on information provided by the nucleic acids.

## Ribs

Long and curved bones. They originate at the back of the body at the spinal column and curve forward. They are called "true" if they end at the sternum and "false" if they remain floating without completely enclosing the rib cage.

## Schwann Cells

Cells that produce myelin, a fatty insulating substance that prevents electrical signals from losing strength as they move away from the body of the neuron.

## Semen

The spermatozoa and fluids produced in the male genital organs. It is often called sperm.

## Sensation

Physiological process of receiving and recognizing stimuli produced by vision, hearing, smell, taste, touch, or the body's spatial orientation.

## Sleep

State of repose characterized by inactivity or suspension of the senses and voluntary motion.

The cerebral activity called dreaming takes place during sleep.

## Spinal

Relating to the spine.

## Spinal Bulbar

Part of the cerebral trunk that goes from the annular protuberance to the cranium's occipital foramen.

## Spine

The neuroskeletal axis that runs along the medial dorsal of the body and consists of a series of short bones called vertebrae, which are arranged in a column and jointed with each other.

## Sternum

Bone of the anterior thorax, which joins the front of the ribs.

## Striated Muscle

Muscle used for voluntary motion. Its muscle fibers show striations, or grooves.

## Subclavian Arteries

Pair of arteries, one of which branches off from the brachiocephalic trunk (on the right side of the body) and the other from the aortic arc (on the left). They run toward the shoulder on each side and, after passing below the clavicle, become the axillary artery.

## System

Complex of organs that participates in any of the principal functions of the body. A synonym of "apparatus."

## Tarsal

The skeletal structure of the leg between the foot and the metatarsal. It consists of seven bones that constitute the posterior part of the foot.

## Tissue

Group of identical cells that together accomplish a function.

## Uterus

Hollow viscera of the female reproductive system. It is located inside a woman's pelvis. In the uterus, or womb, either menstrual fluid is produced or a fetus develops until it is born.

## Veins

Blood vessels that bring blood from the entire body toward the heart.

## Ventricles

Cavities of the heart that receive blood from their respective atrium (right or left) and pump it through the arteries.

## Viscera

Organs located in the principal cavities of the body (such as the stomach or the liver within the abdominal cavity).

## Vitamins

Organic substances present in food. The body ingests them to ensure the balance of various vital functions. There are different kinds of vitamins, designated with the letters A, B, C, etc.



# Index

## A

abducens nerve, 89  
 ABO blood system, 40  
 accessory nerve, 89  
 Achilles tendon, 31  
 actin filament, muscle fibers, 33  
 active transport, 13  
 Adam's apple, 46  
 adipose cell, 55  
 adrenal gland, 59, 61, 63  
 adrenocorticotropin hormone (ACTH), 62  
 afferent lymphatic vessel, 44  
 agranulocyte, 41  
 alveoli, 46, 48, 49  
 amino acid, protein synthesis, 55  
 amphiarthrose joint, 28  
 amygdala, 90, 91  
 anabolism, 55  
 anaphase (cell division), 15  
 anterior tibia, 31  
 anti-diuretic hormone (ADH), 62  
 antibody, 43  
 antioxidant, 14  
 aortic artery (aorta), 36, 39  
 aortic valve, 39  
 arm  
   bones, 20  
   circulatory system, 36-37  
   joints, 28  
   movement, 32, 33  
   muscles, 30  
 artery, 36-37, 38  
   kidneys, 58, 61  
   knees, 29  
   lungs, 49  
 astrocyte, 85  
 atlas bone, 26, 28  
 axial bone, 21  
 axis bone, 26, 28  
 axon, 32, 84

## B

bacteria, 44, 45  
 basal joint, 28  
 Bernard, Claude, 60  
 bicep muscle, 30, 31  
 bile, 54  
 bladder, 58, 65  
 blood  
   circulation, 16, 36-37  
   components, 40-41  
   glucose level regulation, 54, 55  
   groups, 40  
   oxygenation, 38, 40  
   purification in kidneys, 60  
 bone  
   cell types, 23  
   cervical, 27  
   development, 23  
   fracture repair, 23  
   function, 22  
   lever function, 33  
   skeleton, 20-21  
   structure, 22-23  
   types, 21  
   *See also joint*  
 bone marrow, 22, 40, 43  
 bone shaft, 22, 23  
 Bowman capsule, 61  
 brain, 86-87  
   astrocyte, 85  
   communication, 79  
   cranial nerves, 88-89  
   cranium, 20  
   dream states, 90, 91  
   infant, 9  
   limbic system, 91  
   memory formation, 90, 91  
   neurons, 8-9, 84-85  
   olfactory receptors, 71  
   taste center, 71  
   weight, 9  
 brain cell, 8-9  
 Broca's area, 79, 87

## C

bronchi, 47, 49  
 bronchial tree, 48  
 calcanum (calcaneus), 21, 27  
 calcium, 11, 22, 23  
 callus body, 87  
 capillary, 36, 37, 49  
 carbon, 11  
 cardiac muscle, 30, 31  
   *See also heart*  
 carotid artery, 36  
 carpal bone, 20  
 cell  
   division: *See mitosis*  
   size, 6-7  
   structure, 12-13  
   transport mechanisms, 13  
 cell theory, 12  
 cellular membrane, 13  
 central nervous system, 82, 87  
   brain: *See brain*  
   spinal cord: *See spinal cord*  
 centriole, 13, 15  
 cerebellum (brain), 82, 86, 89, 90  
 cerebral cortex (brain) 9, 86-87, 88  
 cervical vertebra, 26  
 cervix (uterine), 67  
 cheekbone (zygomatic bone), 24-25  
 chemical element, contents of human body, 11  
 chlorine, 11  
 cholesterol, formation, 54  
 chromosome, 14  
 circulatory system, 16, 36-37  
   *See also artery; heart; vein*  
 clavicle, 20  
 clitoris, 67  
 coccyx (tailbone), 21, 26, 27  
 cochlea, 76, 77  
 cochlear vestibular nerve, 89  
 colon, 57  
 color blindness, 75

communication, 78, 79  
 compact bone, 22  
 connective tissue, perineurium, 32  
 cornea, 74, 75  
 cortisol, 62  
 cranial nerve, 88-89  
 cranium, 20  
   muscles, 33  
   sinuses, 25  
 cubital nerve, 83  
 cubitum, 20  
 cytology, 12  
 cytoplasm, 12, 13  
 cytoskeleton, 12

## D

Da Vinci, Leonardo, 20  
 deltoid muscle, 30  
 dendrite, 8, 84  
 diaphragm, 47, 48  
 diaphysis (bone), 22, 23  
 diarthrose joint, 28  
 diastolic: *See heartbeat*  
 dieting, muscle loss, 30  
 diffusion (cell), 13  
 digestive system, 17  
   digestive process, 51  
   intestine: *See intestine*  
   liver, 54-55  
   overview, 50  
   pancreas, 54, 55  
   peristalsis, 53  
   spleen, 42, 55  
   stomach, 51, 52-53  
 disease, 45  
 DNA, 13  
 dorsal vertebra, 26  
 dreaming, 90, 91

## E

ear, 76, 77  
   cranial nerves, 89  
 efferent lymphatic vessel, 45  
 ellipsoid joint, 28  
 endocrine system, 17, 62-63  
   hypothalamus, 10, 86  
   pancreas, 55  
   *See also hormone*  
 endoplasmic reticulum, 12, 13  
 enzyme  
   digestive process, 50  
   pancreatic juice, 55  
 epididymis, 65  
 epiglottis, 46  
 epiphysis (bone), 23  
 equilibrium, 77  
   cerebellum, 86  
 esophagus, 50, 52  
 estrogen, 62, 63  
   menstrual cycle, 66  
 ethmoid bone, 24-25  
 excrement, 10, 51  
 eye, 74-75  
   brain, 79, 87  
   cranial nerves, 88, 89  
   muscles, 30  
   sleep, 91

## F

face  
   bones, 24-25  
   cranial nerves, 88, 89  
   muscles, 30, 31  
   nonverbal communication, 79  
 facial nerve, 88  
 facilitated diffusion (cell), 13  
 fallopian tube, 66, 67  
 farsightedness (hyperopia), 75  
 fascicle, muscle fibers, 32

fat, storage, 55  
 female  
   menopause, 67  
   menstrual cycle, 66  
   milk production, 62  
   pelvis, 21  
   reproductive system, 16, 67  
   sexuality, 63  
   skin, 73  
   urinary system, 59  
 femur (thigh bone), 20, 21  
   artery, 29  
   vein, 37  
 fiber: *See muscular fiber*  
 fibula, 21, 29  
 finger, 20  
   *See also hand*  
 flat bone, 21  
 follicle-stimulating hormone (FSH), 62, 66  
 fontanel, 24  
 food, 17  
   digestive process, 50-51, 52, 56-57  
   source of water, 10  
 foot  
   articulation, 28  
   bones, 27  
   movement, 33  
   muscles, 31  
   nerves, 83  
   toenails, 73  
 foramen magnum, cranium, 24  
 fracture, repair, 23  
 free radical, 14  
 frontal bone, 24-25  
 frontal lobe (brain), 87, 89  
 frontal muscle, 30  
 frowning, 31, 79  
 fusion, bones, 23

## G

gallbladder, 54  
 gastrocnemius, 31



glomerulus, 58, 61  
 glosso-pharyngeal nerve, 89  
 gluteus maximus, 31  
 glycogen, storage, 54, 55  
 Golgi apparatus, 12  
 goose bump, 73  
 granulocyte, 41  
 gray matter (brain), 87  
 growth hormone (GH), 62  
 growth plate, 23  
 gustatory papilla, 70

## H

hair, temperature regulation, 73  
 hand  
   bones, 20, 27  
   fingernails, 73  
   joints, 28  
   nerves, 83  
   touch, 9  
 Havers conduit, bony tissue, 22  
 Hayflick, Leonard, 15  
 Hayflick limit (cell longevity), 15  
 head  
   bone structure, 24-25  
   circulatory system, 36  
   movement, 33  
   muscles, 30  
 hearing, 76, 77  
 heart, 36, 38-39  
   cardiac muscle, 31  
   valves, 39  
 heartbeat, 38  
 hematosis, 49  
 herniated disc, 26  
 hippocampus, 90, 91  
 homeostasis, 17, 58  
 Hooke, Robert, 12  
 hormone, 17, 62  
   digestive process, 50  
   menstrual cycle, 66  
   *See also* endocrine system; pheromone

humerus, 20, 28  
 hydrogen, 11  
 hypermobility, 28  
 hyperopia (farsightedness), 75  
 hypoglossal nerve, 89  
 hypophysis: *See* pituitary gland  
 hypothalamus, 10, 86

## I

ilium, 20  
 immune system, 43, 44  
   spleen, 55  
   *See also* lymphatic system; white blood cell  
 infant  
   bones, 23  
   brain development, 8-9  
   cranium, 24  
 inferior maxillary, 20, 25  
 inferior vena cava, 36, 59  
 insulin, 11, 55  
 interphase (cell division), 14  
 intestinal mucosa, 44  
 intestine, 51, 56-57  
   duodenum, 52, 54  
 iodine, 11  
 iris, 74  
 iron, 11  
 irregular bone, 21

## J

jaw bone, 20  
 joint, 28-29  
   lever function, 33  
   noise, 29  
 jugular vein, 36

## K

kidney, 58, 59, 60-61  
   Bowman capsule, 61  
   nephrons, 61  
   renal vein, 36  
 kissing, hormone stimulation, 63  
 knee  
   articulation, 28  
   joint, 29  
 kneecap (patella), 21, 29

## L

lachrymal bone, 24-25  
 lachrymal gland, 44  
 larynx, 46, 47  
 leg  
   bones, 21  
   circulatory system, 36-37  
   knee: *See* knee  
   muscles, 31  
   nerves, 83  
 lens (eye), 74  
 Leonardo da Vinci, 20  
 leukocyte, 41  
 ligament, knee, 29  
 limbic system, 91  
 liver, 54-55  
 long bone, 21  
 lumbar vertebra, 27  
 lung, 47, 48-49  
   circulatory system, 36, 38  
 luteinizing hormone (LH), 62, 63, 66  
 lymphatic system, 16, 42-43  
   lymph nodes, 44-45  
   lymphocytes, 45  
 lysosome, 12

## M

macrophage, 45-46  
 magnesium, 11  
 male  
   hormones, 62  
   pelvis, 21  
   reproductive system, 17, 64-65  
   skin, 73  
   urinary system, 59  
 master gland: *See* pituitary gland  
 melanocyte-stimulating hormone (MSH), 62  
 memory formation, 90, 91  
 men: *See* male  
 menarche, 67  
 meninges, 86, 87  
 meniscus, 29  
 menopause, 67  
 menstrual cycle, 66  
 metabolism, 55  
 metacarpal bone, 20  
 metaphase (cell division), 14  
 metatarsal bone, 21  
 milk, production, 62  
 mitochondria, 13  
 mitosis, 6-7, 12, 14-15  
 mitral valve, 39  
 mouth  
   digestive function, 50, 51  
   sound production, 78  
   swallowing, 52  
 mucous secretion, 44  
 muscle  
   function: *See* muscular fiber  
   movement, 30, 87  
   types, 31  
 muscular fiber, 32-33  
   glycogen storage, 55  
 muscular system, 17, 30-31  
 musculoskeletal system, 18-19, 30  
   *See also* muscular system; skeletal system  
 myelin sheath, 84  
   oligodendrocytes, 85  
 myofibril, muscle fibers, 33

myopia (nearsightedness), 75  
 myosin filament, muscle fibers, 33

## N

nails, 73  
 nasal concha, 24-25  
 nasal fossa,  
   olfactory nerve, 71  
   sensations, 9  
 nearsightedness (myopia), 75  
 neck, bones, 28  
 nephron, 60, 61  
 nervous system, 16, 82-83  
   brain: *See* brain  
   neuron: *See* neuron  
   pain signals, 83  
   spinal column, 20, 26-27  
   spinal cord, 87  
 neuromuscular union, 85  
 neuron, 8-9, 84-85, 86  
   dendrites, 8, 84  
   microscope photograph, 80-81  
 neurotransmitter, 9, 85  
 nitrogen, 11  
 nonverbal communication, 78, 79  
 nose  
   bones, 24-25  
   cranial nerves, 88, 89  
   nasal fossa, 9, 71  
   olfactory cells, 70  
   sound production, 78  
 NREM (non-rapid eye movement) sleep, 91  
 nucleole, 13  
 nucleus, 12, 13

## O

oblique muscle, 30  
 occipital bone, 20, 24-25  
 occipital lobe (brain), 86

occipital muscle, 30  
 oculomotor nerve, 89  
 olfactory cell, 70  
 olfactory nerve, 71, 89  
 oligodendrocyte, 85  
 optic nerve, 88  
 orbicular muscle, 30  
 organ of Corti, 76  
 osteoblast, 23  
 osteoclast, 23  
 ovary, 66, 67  
 ovulation, 66  
 ovum, 66, 67  
 oxygen, 11, 40  
 oxytocin, 62, 63

## P

pain signal, 83  
 palatine, 24-25  
 pancreas, 11, 54, 55, 63  
 parietal bone, 24  
 patella (kneecap), 21, 29  
 pathogen, types, 45  
 pectoralis major, 30  
 pedis, 31  
 pelvis, 20, 67  
   joint, 21  
 penis, 59, 64, 65  
 periosteum, 22, 23  
 peripheral nervous system, 82, 88-89  
 peristalsis, digestive system, 51, 53  
 peroxisome (organelle), 13  
 perspiration: *See* sweat; sweat gland  
 Peyer's patch, 42  
 phalange, 20, 21  
 pharynx, 47, 50  
 pheromone, 63  
 phosphorus, 11  
 photosensitive cell, 75  
 pituitary gland, hormones, 62, 63  
 plane, 28  
 plasma, 41



plasma membrane: *See* cellular membrane  
 platelet, 41  
 popliteal artery, 29  
 pore (cell), 13  
 potassium (K), 11  
 pregnancy, 66, 67  
 progesterone, menstrual cycle, 66  
 prolactin, 62  
 prophase (cell division), 14  
 prostate gland, 65  
 protein, 11  
   metabolism, 12, 54  
   synthesis, 55  
 protozoa, pathogens, 45  
 pulmonary artery, 48  
 pulmonary valve, 39  
 pylorus, 52

## Q-R

quadriceps, 31  
 radius, 20, 28  
 Ranvier's node, 84  
 rapid eye movement (REM) sleep, 91  
 rectus abdominis, 30  
 red blood cell, 40  
 REM sleep, 91  
 renal vein, 36  
 reproductive system  
   female, 16, 66-67  
   hormones, 62  
   male, 17, 64-65  
 respiration, 9, 46  
   process, 46-47, 48  
 respiratory system, 17, 46-47  
   *See also* lung  
 retina, 74, 75  
 Rh factor, 40  
 rib cage, 20, 26  
 ribosome, 12  
 rough endoplasmic reticulum, 12

## S

sacroiliac joint, 21  
 sacrum, 20, 26, 27  
 salivary gland, 44, 70  
 salt: *See* sodium  
 sarcomere, muscle fibers, 33  
 Schleiden, Mathias, 12  
 Schwann, Theodor, 12  
 Schwann cell, 84  
 sciatic nerve, 83  
 sclera, 75  
 sebaceous gland, 44, 73  
 sensation: *See* hearing; smell; taste; touch;  
   vision  
 septum, 39  
 sesamoid bone, 21  
 sexual attraction, 63  
 short bone, 21  
 shoulder, articulation, 28  
 sight, 74-75  
 sinus cavity, 25  
 skeletal system (skeleton), 16  
   structure, 20-21  
   *See also* joint; musculoskeletal system  
 skin, 9, 44, 72-73, 87  
   cellular division, 14  
   melanocyte production, 62  
   wound healing, 45  
 sleep, 91  
 smell, 70, 71, 90  
 smooth endoplasmic reticulum, 13  
 smooth muscle, 30, 31  
 sodium, 11  
 speech, 78, 87  
 speech recognition technology, 24  
 spermatozoa, 64  
 sphenoid bone, 24-25  
 spheroid, 28  
 spinal column, 20, 26-27  
 spinal cord, 26, 82, 87, 88  
 spinal medulla, 87  
 spinal nerve, 88  
 spleen, 42, 43, 55

splenius muscle, 30  
 spongy bone, 22  
 Starling, Ernest, 62  
 sternocleidomastoid muscle, 30  
 sternum, 20, 26  
 stomach, 51, 52-53  
 striated muscle, 17, 30, 31  
 subclavian vein, 42  
 sugar, regulation in blood, 11  
 sulfur, 11  
 superior maxillary, 24-25  
 superior vena cava, 36, 39  
 swallowing, 52  
 sweat, 10, 73  
 sweat gland, 44  
 synapse, 8, 85  
 synaptic node, 84  
 synarthrose joint, 28  
 systole: *See* heartbeat

## T

T cell, 45  
   *See also* lymphatic system  
 tailbone (coccyx), 21, 26, 27  
 Takagi, Kenji, 29  
 tarsal bone, 21  
 taste, 70, 71  
   types, 9  
 technology, speech recognition, 24  
 teeth, structure, 50  
 telophase (cell division), 15  
 temperature regulation, 73  
 temporal artery, 36  
 temporal bone, 24-25  
 temporal lobe (brain), 86, 89, 90  
 temporal vein, 36  
 tendinous cord, 39  
 testicle, 64, 65  
 testosterone, 62, 63, 65  
 thalamus, 86  
 thigh bone: *See* femur  
 thirst, control, 10

thoracic vertebra, 26  
 thumb, joints, 28  
 thymus, 42, 43  
 thyroid-stimulating hormone (TSH), 62  
 tibia, 21, 29  
 toe, nails, 73  
 tongue  
   functions, 50, 51  
   gustatory papillae, 70, 71  
   nervous system, 88  
   sensations, 9  
   sound production, 78  
 tonsils, 42  
 touch, 9, 72-73  
 trachea, 46, 47, 49  
 transport mechanism (cell), 13  
 trapezium muscle, 30  
 triceps muscle, 30  
 tricuspid valve, 39  
 trigeminal nerve, 71, 88  
 trochlear nerve, 89

## U

ureter, 58, 59  
 urethra, 58  
 urinary system, 17, 58-59  
   gender differences, 59  
   kidneys, 60-61  
 urine, 10, 58, 59, 64  
   Bowman capsule, 61  
   production, 60  
 uterus, 66, 67

## V

vacuole, 13  
 vagina, 66, 67  
   bacteria, 44  
 vagus nerve, 82, 89

valve  
   heart, 39  
   lymphatic system, 45  
 vein, 36-37  
   inferior vena cava, 36, 59  
   kidneys, 58, 61  
   lymphatic system, 42  
   superior vena cava, 36, 39  
 vertebral column: *See* spinal column  
 vesicle, 13  
 villi (intestine), 57  
 virus, pathogens, 45  
 vision, 74-75, 87  
 vocal cord, 46, 78  
   *See also* speech  
 vomer (bone), 24-25  
 vulva, 66

## W-Z

water  
   fluid exchange, 10, 59  
   intake, 10  
   intestines, 56  
 Wernicke's area (brain), 79  
 white blood cell, 41, 45  
 white matter (brain), 87  
 women: *See* female  
 wound healing, 45  
 Z band, muscle fibers, 33  
 zygomatic bone (cheekbone), 24-25





## HUMAN BODY I


Britannica Illustrated  
Science Library



ENCYCLOPEDIA  
Britannica<sup>®</sup>



# HUMAN BODY II



Britannica Illustrated Science Library





## **About the pagination of this eBook**

Due to the unique page numbering scheme of this book, the electronic pagination of the eBook does not match the pagination of the printed version. To navigate the text, please use the electronic Table of Contents that appears alongside the eBook or the Search function.

For citation purposes, use the page numbers that appear in the text.



# HUMAN BODY II



**Britannica Illustrated Science Library**

Encyclopædia Britannica, Inc.

Chicago ■ London ■ New Delhi ■ Paris ■ Seoul ■ Sydney ■ Taipei ■ Tokyo



# Britannica Illustrated Science Library

© 2008 Editorial Sol 90

All rights reserved.

**Idea and Concept of This Work:** Editorial Sol 90

**Project Management:** Fabián Cassan

**Photo Credits:** Corbis, ESA, Getty Images, Graphic News, NASA, National Geographic, Science Photo Library

**Illustrators:** Guido Arroyo, Pablo Aschei, Carlos Francisco Bulzomi, Gustavo J. Caironi, Hernán Cañellas, Leonardo César, José Luis Corsetti, Vanina Farías, Manrique Fernández Buente, Joana Garrido, Celina Hilbert, Inkspot, Jorge Ivanovich, Iván Longuini, Isidro López, Diego Martín, Jorge Martínez, Marco Menco, Marcelo Morán, Ala de Mosca, Diego Mourellos, Laura Mourellos, Pablo Palastro, Eduardo Pérez, Javier Pérez, Ariel Pirovansky, Fernando Ramallo, Ariel Roldán, Marcel Socías, Néstor Taylor, Trebol Animation, Juan Venegas, Constanza Vicco, Coralia Vignau, Gustavo Yamin, 3DN, 3DOM studio

**Composition and Pre-press Services:** Editorial Sol 90

**Translation Services and Index:** Publication Services, Inc.

**Portions © 2008 Encyclopædia Britannica, Inc.**

Encyclopædia Britannica, Britannica, and the thistle logo are registered trademarks of Encyclopædia Britannica, Inc.

## Britannica Illustrated Science Library Staff

### Editorial

Michael Levy, *Executive Editor, Core Editorial*

John Rafferty, *Associate Editor, Earth Sciences*

William L. Hosch, *Associate Editor, Mathematics and Computers*

Kara Rogers, *Associate Editor, Life Sciences*

Rob Curley, *Senior Editor, Science and Technology*

David Hayes, *Special Projects Editor*

### Art and Composition

Steven N. Kapusta, *Director*

Carol A. Gaines, *Composition Supervisor*

Christine McCabe, *Senior Illustrator*

### Media Acquisition

Kathy Nakamura, *Manager*

### Copy Department

Sylvia Wallace, *Director*

Julian Ronning, *Supervisor*

### Information Management and Retrieval

Sheila Vasich, *Information Architect*

### Production Control

Marilyn L. Barton

### Manufacturing

Kim Gerber, *Director*

## Encyclopædia Britannica, Inc.

Jacob E. Safra, *Chairman of the Board*

Jorge Aguilar-Cauz, *President*

Michael Ross, *Senior Vice President, Corporate Development*

Dale H. Hoiberg, *Senior Vice President and Editor*

Marsha Mackenzie, *Director of Production*

International Standard Book Number (set):

978-1-59339-797-5

International Standard Book Number (volume):

978-1-59339-810-1

Britannica Illustrated Science Library: Human Body II 2008

Printed in China



www.britannica.com



# Human Body II





# Contents

## From Zygote to Embryo

Page 6

## Fetal Development and Childbirth

Page 22

## Microlife

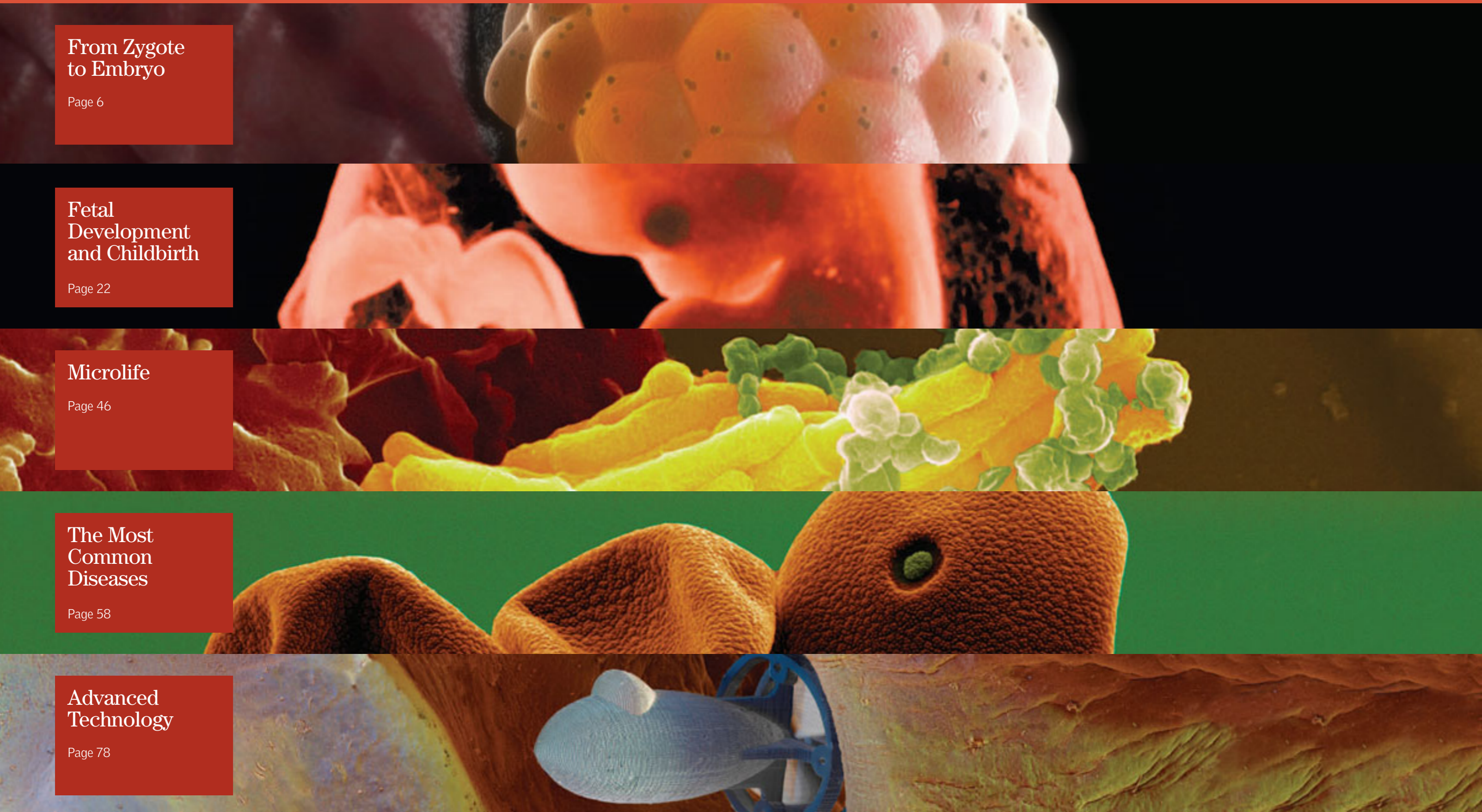
Page 46

## The Most Common Diseases

Page 58

## Advanced Technology

Page 78





# The Miracle of Life

**SOURCE OF HEALTH**  
Breast milk is especially rich in antibodies, and when accompanied with love and affection, it provides a sense of security, warmth, and well-being.

This is a moving book. A guide for parents as well as young people, it recounts in detail the almost magical way in which babies evolve from the very moment that fertilization occurs. Thanks to new technological advances, today it is possible to visualize and re-create images of what happens inside a woman's body when a sperm travels through the uterus and the gelatinous membrane that surrounds the egg. Incredible photos show, day by day, how the embryo evolves, when the heart begins to beat, and even when the brain, eyes, legs, arms, mouth, and teeth are formed. This book contains a wealth of information, with photographic details that show you the inside of the body from a totally new viewpoint.

The book is divided into five chapters. The first two are dedicated to the formation and development of the baby, and the rest deal with everything that happens to the body when it gets sick—from how the HIV/AIDS virus affects us to what happens when arteries become blocked because of fat deposits. The

information, reviewed by professionals and accompanied by incredible illustrations, will captivate you from the first page. The last chapter is devoted to tracing the landscape of future medicine. The surprising advances in molecular biology and genetics allow us to have new therapeutic and diagnostic tools that make it possible to think that, in the future, humans will live eternally. The themes covered and shown here have a scientific basis. We tell you, for example, which mechanisms regulate the operation of the genes and how these mechanisms can correct certain errors in the DNA—the starting point for many illnesses of genetic origin, including many forms of cancer. In a not too distant future, nanomachines (many times smaller than a cell) could be guided inside the body to eliminate obstructions in blood vessels or to kill cancer cells. With particles the size of amino acids, sick cells could be eliminated without damaging the healthy ones. Like guided missiles, the molecules would go directly to the damaged cells. This type of therapy has already been demonstrated in mice and rats, and, although the tests are still in development, it is expected that within the next few years this type of revolutionary treatment, which combines genetics with pharmacology, could be applied. Currently there are patients on whom certain drugs have toxic effects or do not have the desired effect; in the future, drugs could be made according to the genetic makeup of each patient.

Another aspect to highlight in the use of new technologies is related to health informatics, or medical informatics, in which all kinds of patient information is managed. Such a system already allows all hospitals in some cities, such as Vienna, Austria, to communicate

digitally. That way a doctor can quickly access the medical record of the person through a remote communication network such as the Internet. It is not strange to imagine that in coming years everyone will carry their medical records on a keychain that, when connected to a computer, would provide all their medical information. There is real evidence that in the next decades the way that medicine will treat diseases requiring the replacement of organs or tissues will also change. The tissue created in the laboratory will be genetically identical to the patient's, so there will be no rejection. Once this is achieved, transplants and artificial organ implants will be a thing of the past. Today in the cases of heart failure, when the treatments do not work, a transplant is sought. In a few more years, this will be unnecessary. Ventricular assistance devices, combined with stem-cell implants, will be used to allow regeneration of the damaged muscle.

In addition, the health of many people will be determined during fetal development. As a result of the advances in prenatal diagnostic methods, the possibility has appeared in recent years of carrying out surgical procedures to correct certain congenital problems inside the womb. It is not difficult to foresee the development of medical units in which the fetus is a patient. Even though many of these advances are still in the research stage, it is not unrealistic to believe that they will end up being useful. Several decades ago, nobody would have thought about replacing sick organs with healthy ones or the possibility of choosing a baby's sex. So why not fantasize about virtual medicine that is safer, simpler, and more effective or even about the possibility of living forever? ●



# From Zygote to Embryo

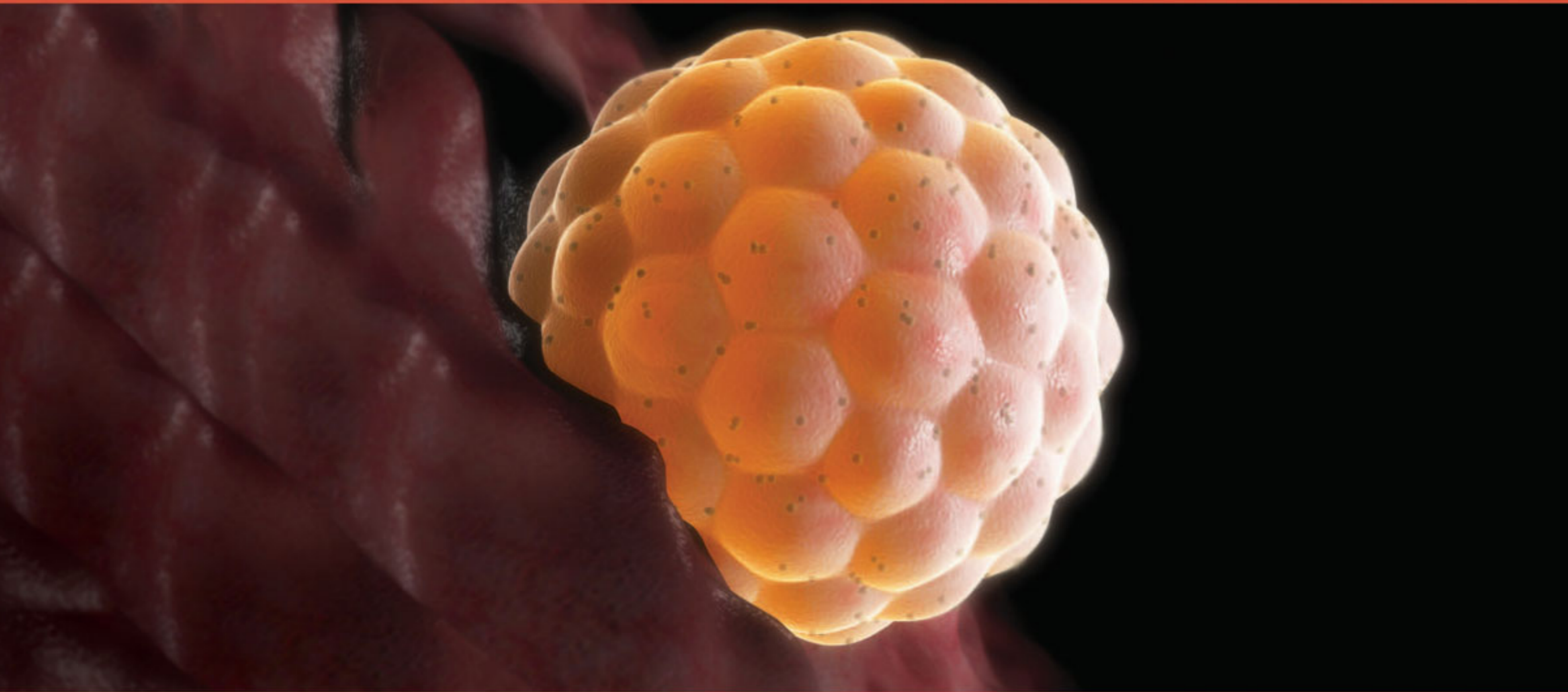## FERTILIZED EGG

After fertilization, the egg implants itself in the endometrium and begins to develop.

THE ORIGIN OF SEX AND LIFE 8-9

FERTILIZATION OF THE EGG 10-13

FIRST HUMAN FORMS 14-21



**F**rom conception until the third month of pregnancy, what takes place inside the mother's belly? Day by day, during the phases of mitosis, what happens at this

embryonic stage, the most critical one during pregnancy? What changes does the embryo go through? Here we present incredible images that show the embryo from its formation to the moment it

implants itself in the endometrium and measures about 0.2 inch (5 mm). At what time do the heartbeats begin and the eyes, mouth, and legs begin to form? Also, what is the role of the placenta, the

organ that gives the unborn baby the different nutrients and oxygen it needs to continue developing? Turn the page. ●

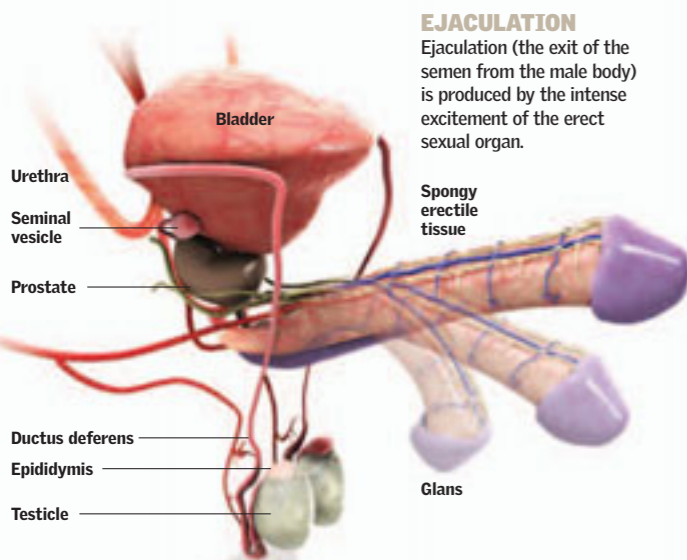


# The Origin of Sex and Life

The origin of human reproduction is sexual. Men and women can have sex any time during the year, unlike most other species, which have their specific times of heat. The ability to have sex begins at puberty, the age when the sexual organs develop. Women are fertile from their first menstrual period until menopause at around age 45. Although their sexual activity continues after this age, they no longer produce eggs, the female sexual gametes capable of being fertilized by sperm. ●

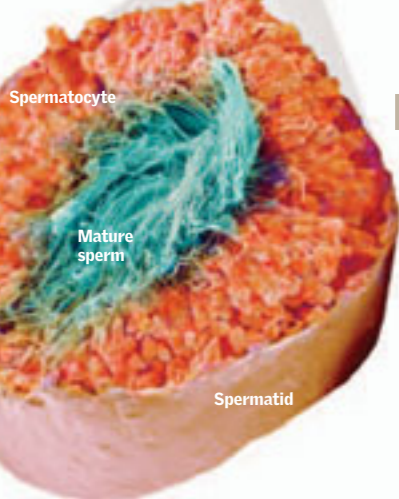
## The Male Sexual Apparatus

The testicles, or male sexual glands, lie below the pelvis within a structure called the scrotum. It is there that sperm—the mobile sex cells—are produced. During sexual intercourse, these cells, if they reach the female vaginal canal, head toward the egg so that one of them may fertilize it. The ductus deferens is the path through which the sperm travels to be joined by materials from the seminal vesicles and the prostate. This combination makes up the semen, which, in the moments of maximum sexual excitement, will move to the urethra to exit the man's body through the penis.



**EJACULATION**  
Ejaculation (the exit of the semen from the male body) is produced by the intense excitement of the erect sexual organ.

### SEMINIFEROUS TUBULE



**1 FROM REST TO AN ERECTION**  
A physical or mental stimulus causes the cavernous bodies to fill with blood and the penis to swell.

**2 EJACULATION**  
If the penis continues being stimulated, the seminal vesicle contracts and expels the semen.

**SPERM PRODUCTION**  
Sperm originates inside the 10,000 seminiferous tubules at a rate of 120 million a day and are stored in the epididymis. This process requires a temperature of 93° F (34° C), which the testicles achieve by being outside the abdomen.

## Gametes and Hormones

Testicles and ovaries are glands that produce the sex cells, or gametes—sperm and eggs, respectively. Gametes are haploid cells. In other words, they possess half the chromosomes of any other human tissue cell, which contains a total of 46. Upon uniting at conception, each gamete contributes half of the genetic load of the new embryo. The sex glands also produce hormones that determine secondary characteristics and, in women, ovulation.

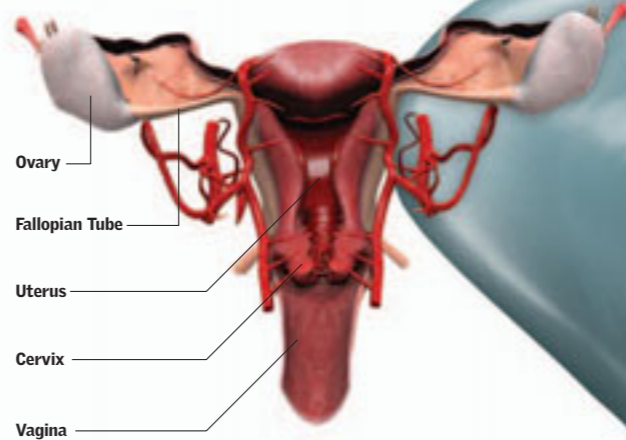
**FALLOPIAN TUBE**  
A tube 4 to 5 inches (10-12 cm) in length and about 0.1 inch (3 mm) in diameter, with internal cilia that propel the egg toward the uterus.

**FIMBRIAE**  
form a tunnel through which the mature egg is introduced into the fallopian tubes.

**28**  
DAYS A TYPICAL MENSTRUAL CYCLE LASTS

**OVARY**  
contains many follicles with immature eggs and releases hormones responsible for the menstrual cycle and female sexual activity.

### FRONT VIEW



## The Menstrual Cycle

The uterus is prepared for the implantation of the fertilized egg. For this, the woman's hormones have stimulated the uterus to thicken its internal wall (endometrium). If no egg is implanted, the thickened wall breaks down and the waste material is disposed of outside the body, together with the unfertilized egg. This process is synchronized with ovulation and is repeated regularly throughout the woman's fertile life, from puberty until menopause.

**Menstruation**  
The female body disposes of the dead cells from the endometrium.

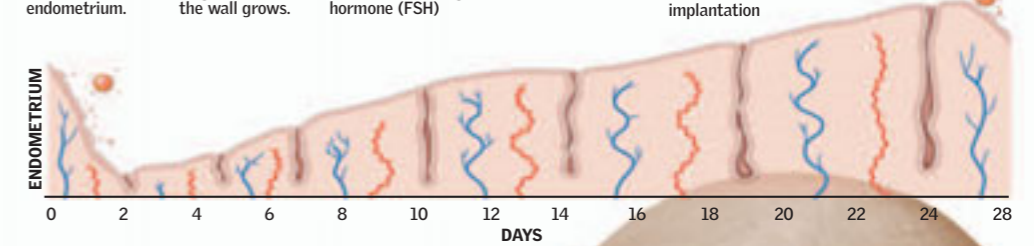
**Thickening**  
The blood vessels of the uterus lengthen, and the wall grows.

**Maximum hormone levels**  
Estrogen, luteinizing hormone (LH), and follicle-stimulating hormone (FSH)

**Ovulation**  
occurs around the 14th day after menstruation.

**Increase in progesterone**  
The hormone that prepares the endometrium for implantation

**Arrival of the egg**  
If it is fertilized, it becomes implanted; if not, menstruation occurs.

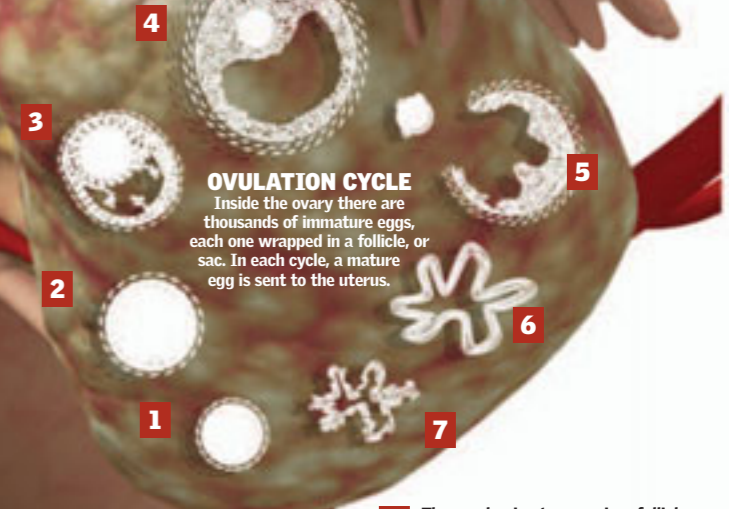

## The Sexual Organs of the Woman

With the exception of the vulva, which is external, the female sexual apparatus (which allows a woman to have an active sexual life, become pregnant, and give birth) lies completely inside the abdominal cavity, where it is supported and protected by the pelvis. Its basic shape is that of a cavity formed by the vagina and the uterus. The ovaries produce the

eggs, or sex cells, and hormones. Periodically a mature egg leaves the ovary and installs itself in the uterus (ovulation). There, if it has not been fertilized in the fallopian tube, the body will expel it naturally together with the residues of the endometrium (menstruation).

**OVULATION CYCLE**  
Inside the ovary there are thousands of immature eggs, each one wrapped in a follicle, or sac. In each cycle, a mature egg is sent to the uterus.



- 1 The egg begins to grow in a follicle, stimulated by FSH.**
- 2 Protection**  
The follicular cells form an envelope around the egg.
- 3 Maturing of the egg**  
The egg bulges from the ovarian walls, and hormonal secretions increase.
- 4 Maximum size**  
The follicle has formed a fluid-filled cavity.
- 5 Ovulation**  
Halfway through the cycle, the follicle bursts and releases a mature egg.
- 6 Formation of the corpus luteum**  
The ruptured follicle closes and releases progesterone.
- 7 Degeneration of the corpus luteum**  
occurs only if the egg has not been fertilized.

**UTERUS**  
A pear-shaped cavity with thick, muscular walls. Its internal wall is the endometrium.

**VAGINA**  
Cavity that is anatomically prepared to receive the penis during sexual intercourse

**BLADDER**



# Fertilization of the Egg

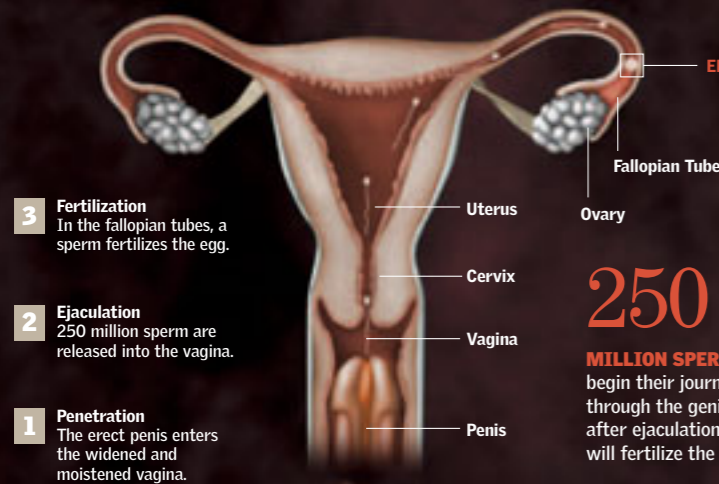
**F**ertilization is the starting point for the development of pregnancy. After intercourse, two sex cells, or gametes, fuse together, giving rise to an ovum, or zygote, where the chromosomes of the two gametes are united. In humans, these sex cells are the sperm and the egg. For conception of a new life, a sperm must fertilize the egg in a tough competition with hundreds of millions of other sperm. ●

## The Journey of a Sperm

▶ After ejaculation, millions of sperm begin their journey through the genital tract. Only 200 will reach the egg. The trip toward the fallopian tubes takes anywhere from 15 minutes to several hours. To reach them, sperm use their tails, and they are helped by contractions in the

walls of the vagina and the uterus. Inside the egg, the sperm loses its tail and midsection, which dissolve. The head, which contains the genetic material, moves toward the plasma membrane of the egg. The march toward fertilization is underway.

### FROM PENETRATION TO FERTILIZATION



- 1 Penetration**  
The erect penis enters the widened and moistened vagina.
- 2 Ejaculation**  
250 million sperm are released into the vagina.
- 3 Fertilization**  
In the fallopian tubes, a sperm fertilizes the egg.

**250**

**MILLION SPERM** begin their journey through the genital tract after ejaculation. Only one will fertilize the egg.

## The Sperm

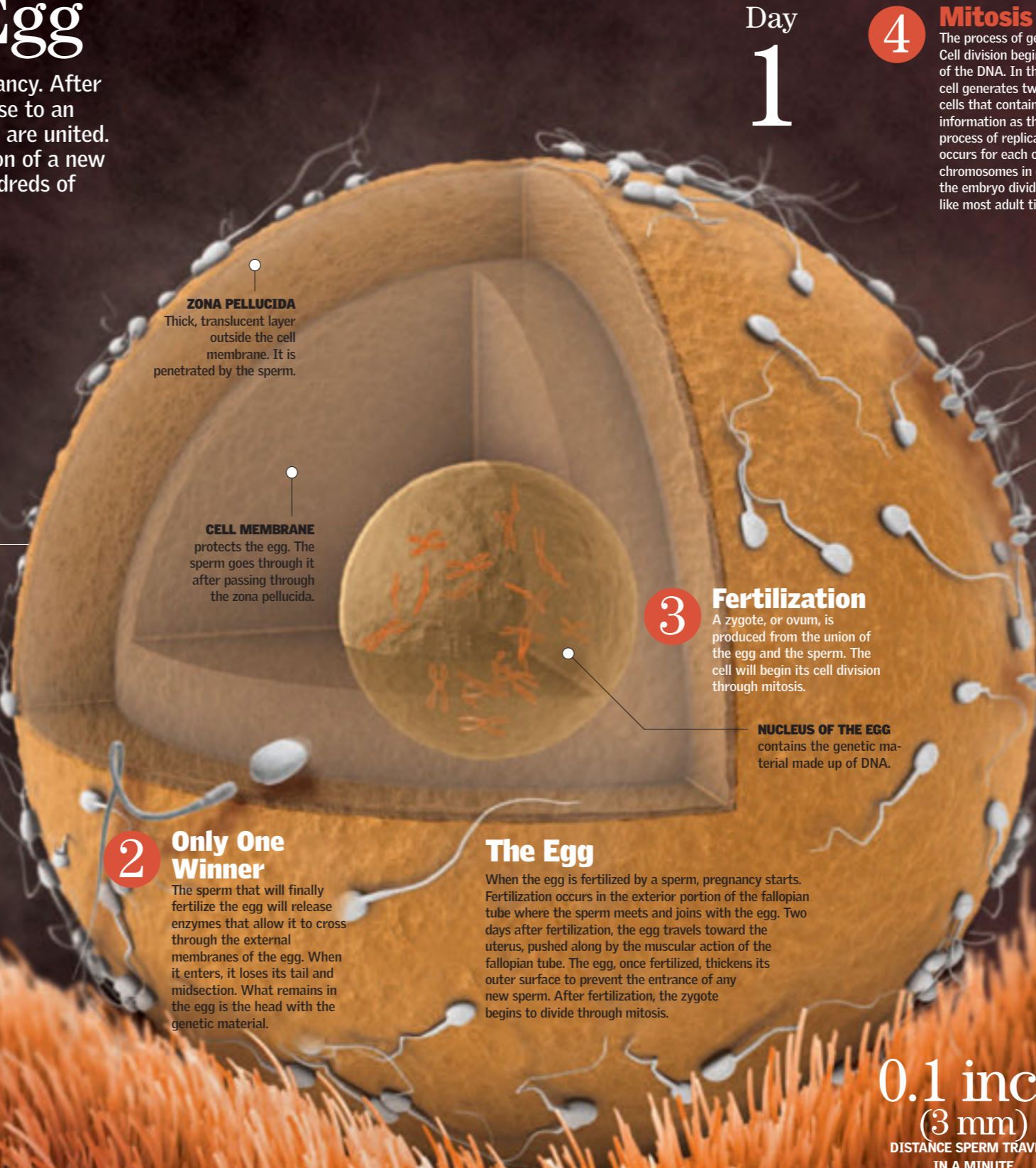The male sex cell. With a tail, a head, and a midsection, millions of sperm fight to fertilize the egg, a mission that only one of them will accomplish. It measures 0.002 inch (0.05 mm) in length.

**MIDSECTION** contains mitochondria that release energy to move the tail.

**HEAD** contains the genetic information (DNA).

**TAIL** helps the sperm move through the external membranes of the egg.

- 1 In the Race**  
Hundreds of millions of sperm go in search of the egg immediately after ejaculation during reproduction.



- 2 Only One Winner**  
The sperm that will finally fertilize the egg will release enzymes that allow it to cross through the external membranes of the egg. When it enters, it loses its tail and midsection. What remains in the egg is the head with the genetic material.

## The Egg

When the egg is fertilized by a sperm, pregnancy starts. Fertilization occurs in the exterior portion of the fallopian tube where the sperm meets and joins with the egg. Two days after fertilization, the egg travels toward the uterus, pushed along by the muscular action of the fallopian tube. The egg, once fertilized, thickens its outer surface to prevent the entrance of any new sperm. After fertilization, the zygote begins to divide through mitosis.

**0.1 inch (3 mm)**  
DISTANCE SPERM TRAVELS IN A MINUTE

## Zona pellucida

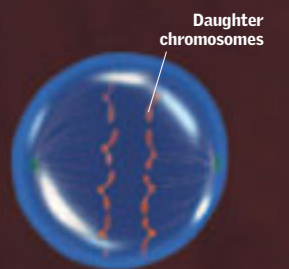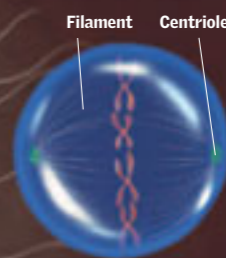
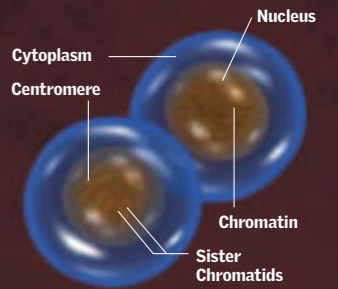
A membrane of glycoproteins that surrounds the plasma membrane of an oocyte, a female sex cell. This structure attracts the sperm and is vital for the release of the sperm head. In humans, the membrane degenerates and breaks down five days after fertilization.

Day 1

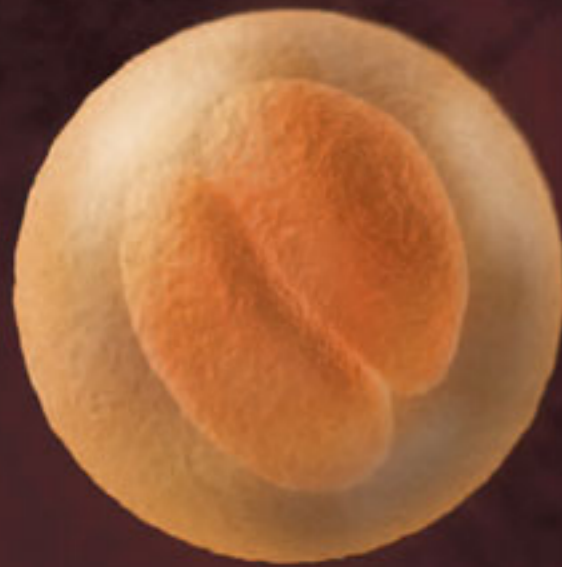- 4 Mitosis**  
The process of generating new cells. Cell division begins with the replication of the DNA. In this way, a "mother" cell generates two identical "daughter" cells that contain the same genetic information as the mother cell. The process of replication for cell division occurs for each of the 46 chromosomes in each cell. The cells of the embryo divide through mitosis, just like most adult tissue cells.

### PHASES OF MITOSIS

- 1 Prophase**  
The DNA of the chromosomes has already been copied. Two identical strands are formed, joined at the center by a structure called a centromere.
- 2 Metaphase**  
The membrane that covers the cell nucleus disappears, and filaments form in the cell. The chromosomes align themselves along these filaments across the middle of the cell.
- 3 Anaphase**  
The filaments "tug" the duplicated chromosomes. The duplicated individual chromosomes move toward the two ends of the cell.
- 4 Telophase**  
The filaments disappear, and a new nuclear envelope forms around each group of 46 chromosomes. The nucleus has divided in two.
- 5 Late telophase**  
The new cells have been formed. The daughter cells contain the same genetic material as the original cell.







Day  
**2**

**Zygote**

The resultant cell from the union of the male gamete (sperm) with the female gamete (egg) in sexual reproduction is called the zygote. Its cytoplasm and organelles are from the maternal egg. It contains all the necessary genetic material for fetal development.

**0.004  
inch  
(0.1 mm)**  
DIAMETER OF  
THE ZYGOTE

**Fertilization**

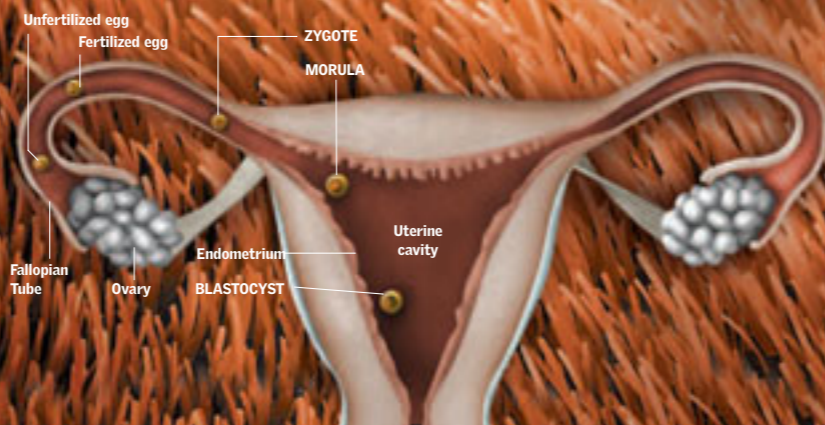
Fertilization occurs in the upper part of the fallopian tube. When the head of the sperm penetrates a mature egg, the nuclei of both sex cells, each one with 23 chromosomes, fuse to form the zygote, or ovum. With 46 chromosomes, the zygote will begin the process of successive cell divisions through mitosis. It will begin the journey from the fallopian tubes toward the endometrium, where it will implant itself.

**12 hours**

How long it takes the zygote, or ovum, to divide through mitosis. Compact masses are successively formed in these cellular multiplications.

**The Zygote's Journey**

Once the sex cells have formed the zygote, it begins the journey toward the uterus through the fallopian tube. During this journey, several cellular divisions will take place. Before entering the uterine cavity, a mulberry-shaped compact cellular mass is formed (the morula). Within the uterus, cellular divisions take place every 12 hours until the blastocyst stage (about 64 cells) has been reached. Once on the uterine lining, the blastocyst adheres to it, and shortly thereafter implantation takes place. From that moment, embryonic growth begins.



**Formation of the Morula**

The zygote goes through three stages of cell division. While it travels through the fallopian tube, it divides first into two and then into four identical cells. After 72 hours, it will have reached the stage of 16 cells, at which point a mulberry-shaped cell agglomerate called the morula is formed (the name comes from the Latin

word *morum*, meaning "mulberry"). The morula continues its journey through the fallopian tube until it reaches the uterus. Cell division continues until a more solid ball with 64 cells, the blastocyst, is formed. Once the blastocyst attaches itself to the interior of the uterus, the formation of the embryo begins.

**X-ray of the morula**

The morula is made up of 16 cells in its initial state. As it divides, it will reach 64 cells, at which time it becomes a blastocyst.

**BLASTOMERES**

Small cells that make up the body of the morula

**MEMBRANE**

Covers the cellular mass; made up of proteins.

**LIQUID**

Fluid develops within the intercellular spaces.

**Morula**

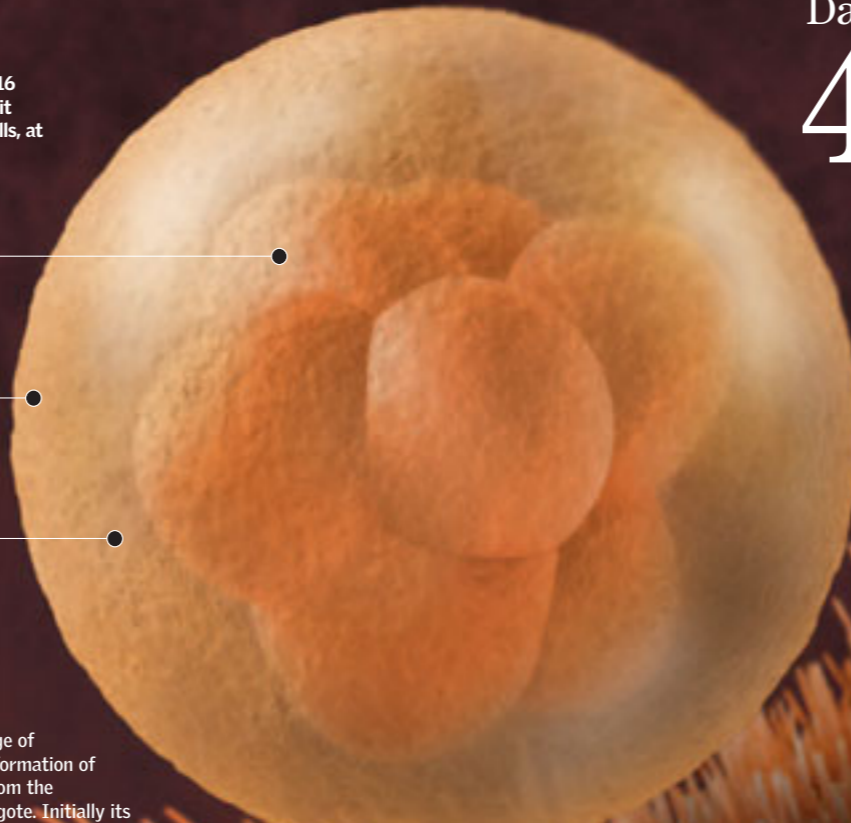
The second important stage of development prior to the formation of the blastocyst. It forms from the repeated mitosis of the zygote. Initially its interior contains 16 blastomeres, which are the first cells that develop from the zygote. Inside the morula, these cells are uniform in shape, size, and physiological potential.

**9 days**

**AFTER FERTILIZATION**

The blastocyst, the stage prior to the embryonic stage, implants itself in the uterine wall.

Day  
**4**



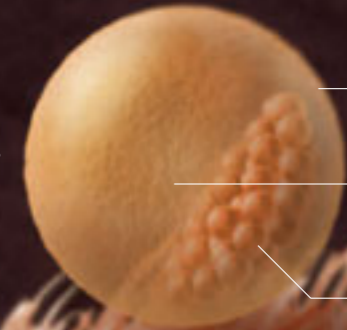
**Implantation**

After cellular division to 64 cells, the morula becomes a blastocyst, a more compact and solid mass. Once formed, the blastocyst moves freely in the uterine cavity for 48 hours before finding a place to implant itself in the endometrium. The endometrium relaxes to ease implantation of

the blastocyst. Nine days after fertilization, the embryo will already be in the uterine wall. After implantation, the embryo begins to grow. If the woman has very low levels of estrogen and progesterone, the endometrium can rupture and cause implantation to occur in the wrong place.

**Blastocyst**

The last step before growth of the embryo. The cellular mass is covered with an external layer called the trophoblast. The trophoblast releases enzymes that help the blastocyst adhere to the endometrium.



**TROPHOBLAST**  
forms the embryonic part of the placenta.

**CAVITY, OR BLASTOCOEL**  
contains liquid that passes through the zona pellucida from the uterine cavity.

**MASS OF CELLS**  
They make up the embryo, or embryoblast.

IT IMPLANTS NINE DAYS AFTER FERTILIZATION.

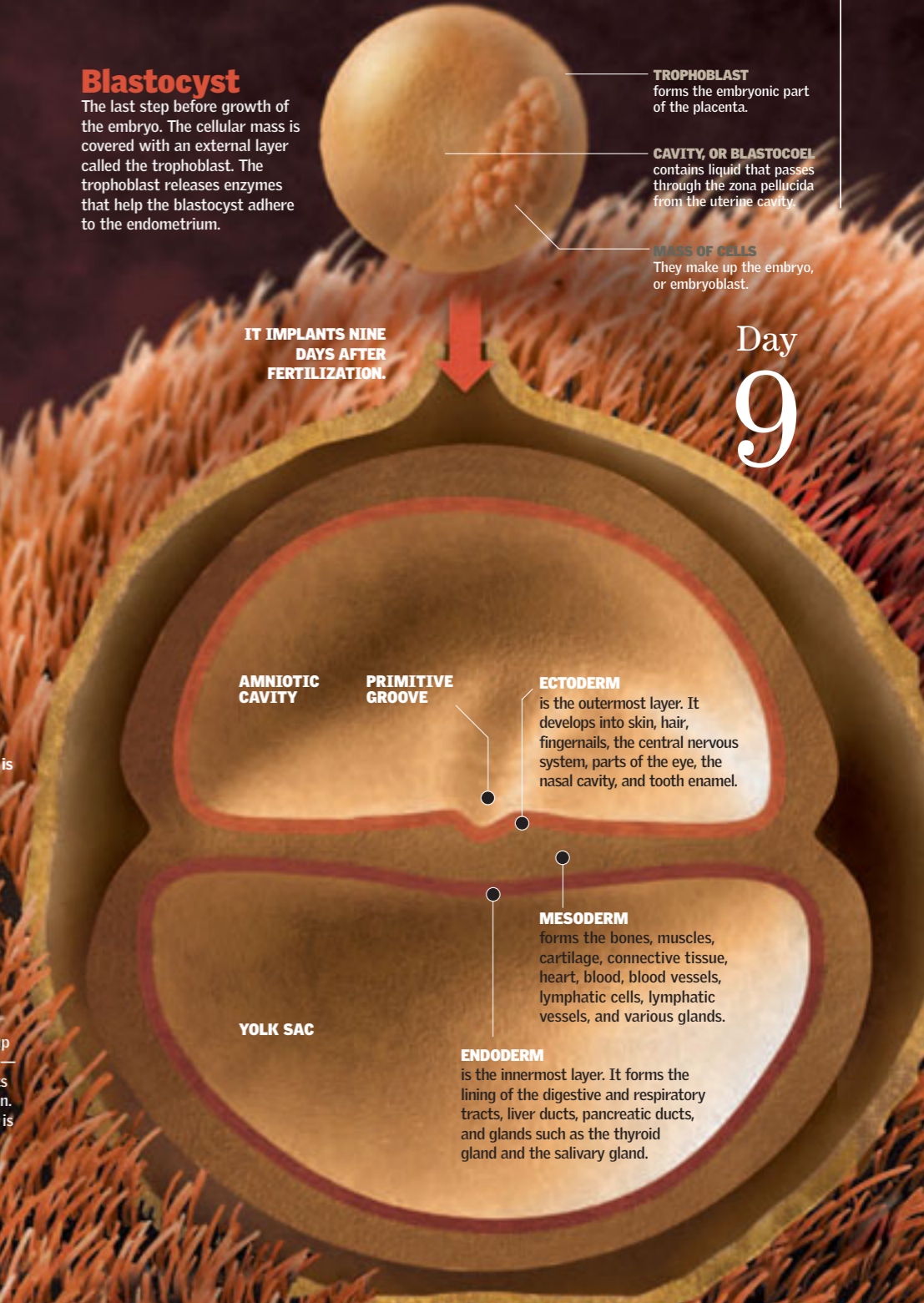
Day  
**9**

**Trilaminar disk**

begins to form from the embryonic bilaminar disk and is complete by day 15. From the trilaminar disk, three germinative layers will develop; they will give rise to the distinct parts of the body: mesoderm, endoderm, and ectoderm.

**The Endometrium**

The inner layer of the uterine wall, it is made up of the myometrium—the external musculature—and the endometrium—the internal mucosa. Its function is to receive the ovum for implantation. When there is no pregnancy, the endometrium is the bloody tissue lost during menstruation.





# First Human Forms

**N**ine days after fertilization, the blastocyst has installed itself in the wall of the uterine endometrium, where it will spend the rest of the nine months of gestation before being born. The blastocyst measures slightly more than 0.004 inch (0.1 mm), and the uterine wall increases in size and attains a spongy consistency, the product of an intense supply of hormones by the ovaries. The uterine wall is where the stages of embryonic development will continue. The formation of the various kinds of tissues begins, and in the third week, the heartbeat starts. ●

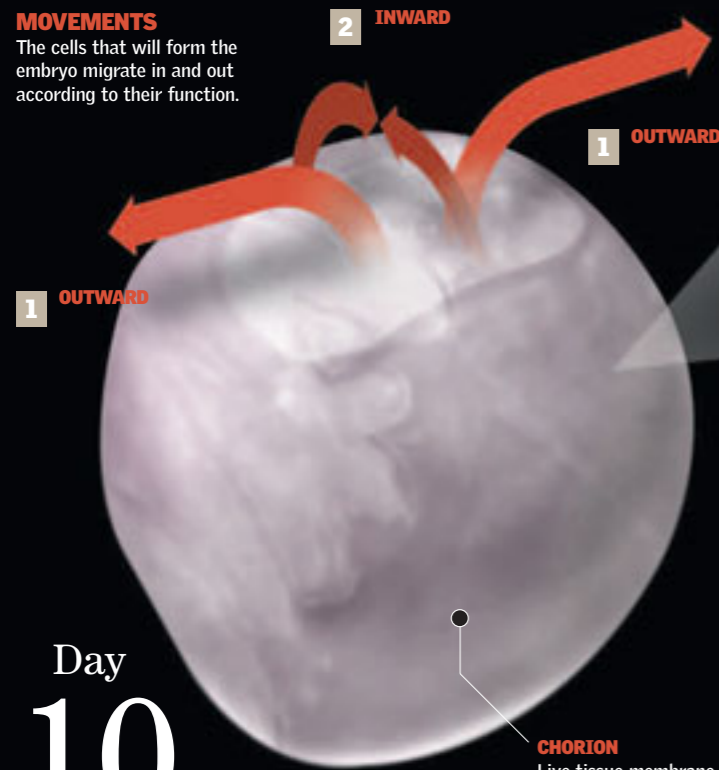
## Protective Membrane

▶ The rubbing of the blastocyst against the zona pellucida of the endometrium (normally in the back of the uterus, the part closest to the spine) leads to the release of enzymes that

interact with the embryo. The blastocyst has little trouble penetrating the porous wall. At the same time, a new membrane forms: the chorion, which will protect the embryo.

## MOVEMENTS

The cells that will form the embryo migrate in and out according to their function.



Day  
**10**

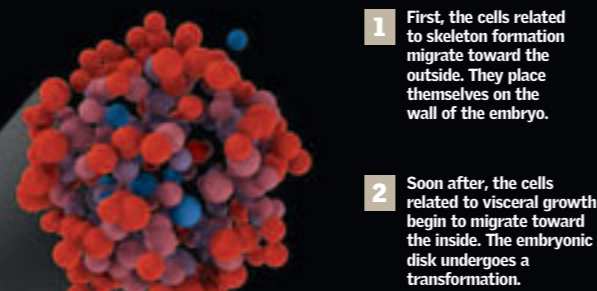
## The Placenta Forms

▶ From the implanted blastocyst, new cellular formations begin to branch out over the chorion. These branches (called trophoblasts) are the source of the placenta, a disk-shaped interchange organ that grows between the chorion and the tissues of the endometrium. In the placenta, the blood

vessels of the mother intertwine with those of the embryo without joining. The embryoblast, which contains the source of primitive blood for the development of the liver and the marrow, grows under this disk, which serves as a protective and immunological barrier.

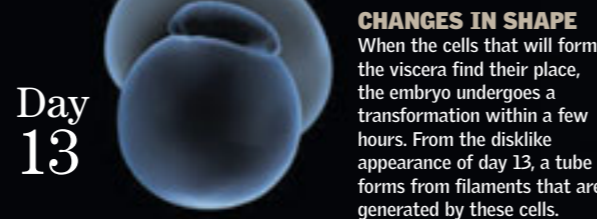
## Cellular Differentiation

Inside the embryo are cells that will form the skeleton as well as cells that will make up the viscera. Originally undifferentiated, they begin to move, seeking their place. Some cells will move outward (those that will form the skeleton) and others inward (those that will make up the viscera). The latest research has shown that some cells release certain chemicals that provoke other cells to do certain tasks. These substances are called morphogens.



## Morphogenesis

includes the formation of the tissues and organs of the embryo. In this process, the cells are distributed along specific sites according to the tissues or organs they will form.



**1,000 cells**

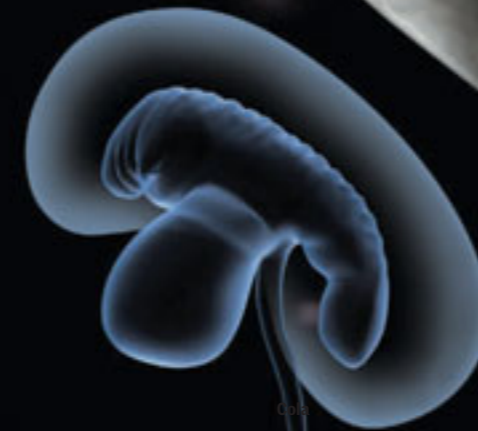**MAKE UP THE HUMAN EMBRYO BY THE TIME THE PLACENTA IS FORMED (DAY 13) AND GASTRULATION BEGINS.**

**8 inches (20 cm)**

is the average diameter of the placenta responsible for blood circulation between the mother and the fetus at the time of birth.

**87 gallons (330 L) A DAY**

The amount of blood that must circulate through the umbilical cord to sustain embryonic growth.



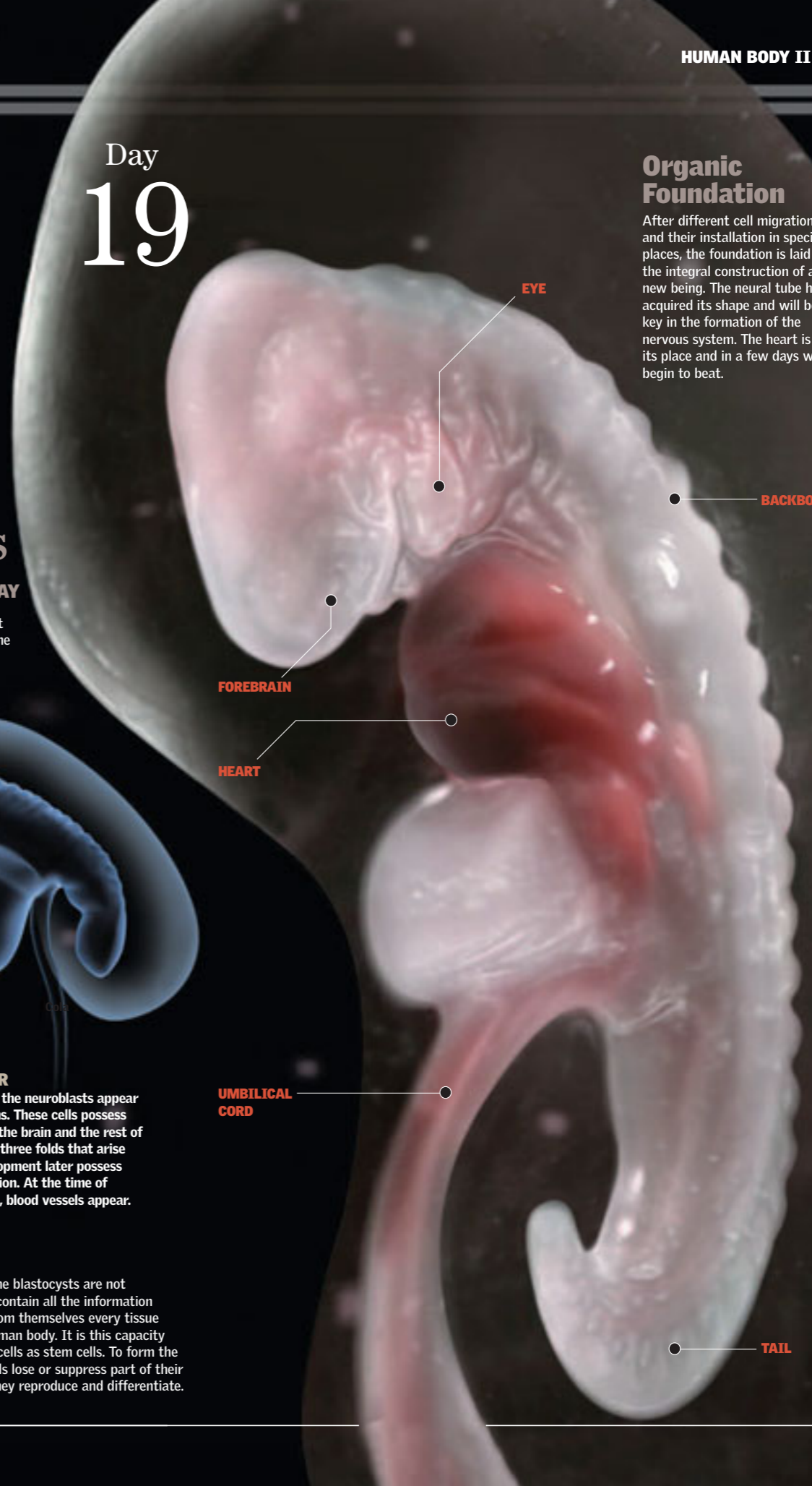
## ORGAN PRECURSOR

Between days 16 and 19, the neuroblasts appear and the neural tube forms. These cells possess information to generate the brain and the rest of the nervous system. The three folds that arise during neural tube development later possess sensory and motor function. At the time of neural tube development, blood vessels appear.

## Stem Cells

The cells that make up the blastocysts are not differentiated, and they contain all the information necessary to generate from themselves every tissue that will make up the human body. It is this capacity that distinguishes these cells as stem cells. To form the various tissues, these cells lose or suppress part of their genetic information as they reproduce and differentiate.

Day  
**19**



## Organic Foundation

After different cell migrations and their installation in specific places, the foundation is laid for the integral construction of a new being. The neural tube has acquired its shape and will be key in the formation of the nervous system. The heart is in its place and in a few days will begin to beat.



## Embryonic Stage

▶ It is still impossible to see a human shape at this moment of intrauterine development. The embryo is smaller than a grain of rice and has at one end a type of curved tail that will disappear as development progresses. In the interior and in the folds of the embryo there are groups of various cells, each one with different instructions according to the organs they must form. In this period, the cells of the cardiovascular system initiate the beating of the heart.

Day  
**22**

**LENGTH:** 0.2 inch (4 mm)  
**WEIGHT:** 0.001 ounce (0.03 g)

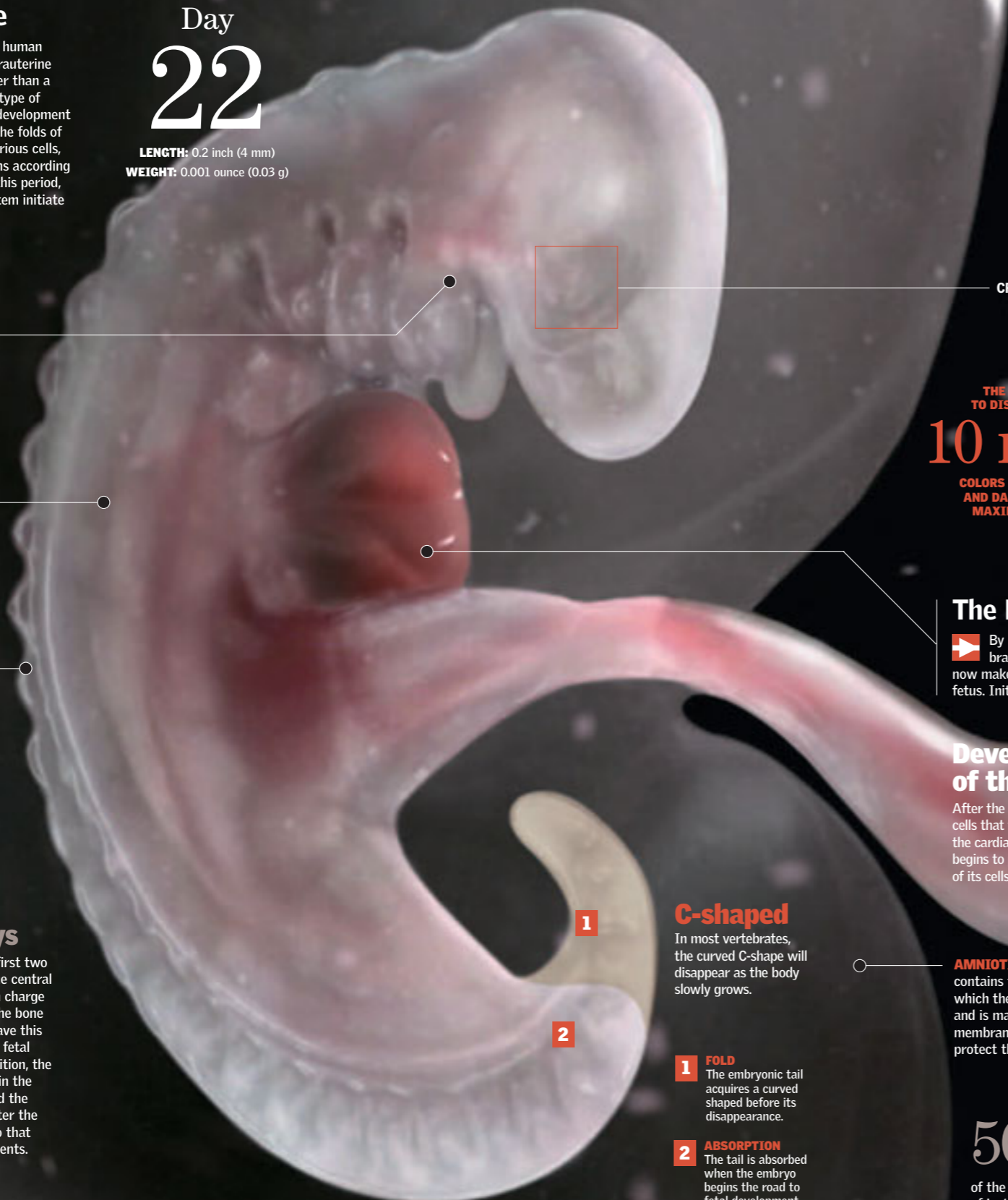
**ESOPHAGUS**  
separates from the breathing tube to allow the appropriate development of the digestive system.

**LUNGS**  
begin to develop. They are the last organs to acquire their shape and be completely functional.

**SPINE**  
has 40 pairs of muscles and 33 pairs of vertebrae. It is the hardest part of the embryo.

## Liver and Kidneys

During the embryonic period, the first two months of gestation, the liver is the central organ for blood production. It is in charge of producing blood cells because the bone marrow, the substance that will have this function with the beginning of the fetal period, is not yet complete. In addition, the primitive kidneys begin to appear in the embryo from a protuberance called the mesonephric ridge. The kidneys filter the metabolic waste from the blood so that the embryo receives only the nutrients.



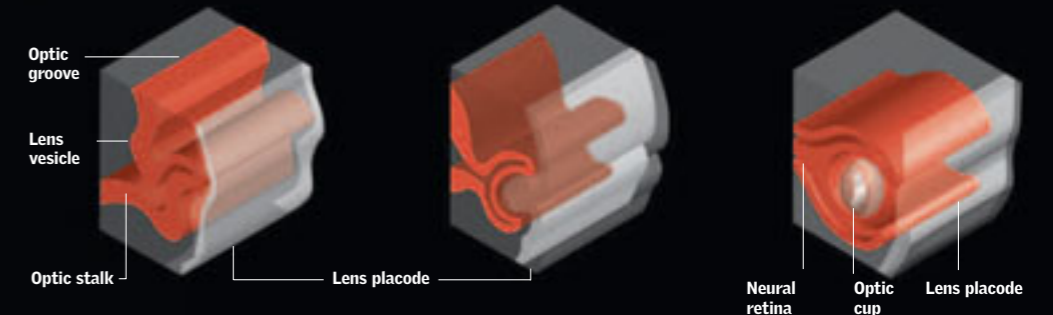
**127 million**  
The average number of cells in the eye when it acquires its definitive shape.

## Formation of the Eye

▶ All vertebrates' eyes develop according to the same process. From certain changes in the ectodermal layer and invagination patterns on the surface of the embryo, the eye develops an "inverted" retina, in which the initial detection of light rays occurs in the outermost portion. In this way, the light-sensitive elements are situated on the outer regions, and the neural connection

with the brain is in the inner region. The retina houses in its interior light-sensitive cells that have the function of receiving light and transmitting the correct information to the brain. The final development in the eye's functionality will occur at approximately the seventh month, when the baby will open its eyes for the first time and will react to changes of shade between light and dark.

### DEVELOPMENT OF THE EYE



**1 DEVELOPMENT OF THE PLACODE**  
By day 30, the lens placode, a region on the embryonic surface, comes in contact with the optic stalk.

**2 FORMATION OF THE VESICLE**  
A day later, invagination of the lens placode takes place, and the lens vesicle forms.

**3 DEVELOPMENT OF THE RETINA**  
On day 32, the neural retina and the pigment epithelium are formed. The lens vesicle detaches from the placode.

**THE EYE WILL BE ABLE TO DISTINGUISH BETWEEN 10 million**  
COLORS AND SHADES OF LIGHT AND DARK WHEN IT REACHES MAXIMUM DEVELOPMENT.

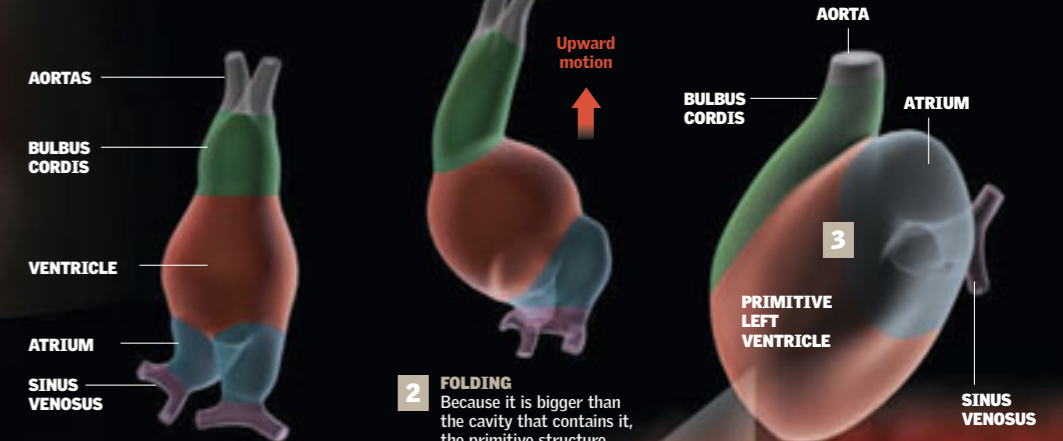
## The Heart Begins to Beat

▶ By day 22, the heart is already active, just like the brain. Its division into subregions has begun, and it now makes up, together with the brain, half the size of the fetus. Initially the heart is simply a pump that maintains

the flow of blood in the body and toward the placenta. When the four chambers are developed, the heart acquires the ability to gather the blood from the lungs and distribute it toward the organs throughout the body.

## Development of the Heart

After the differentiation of the cells that form the blood vessels, the cardiac muscle appears and begins to pump with the beating of its cells.



**1 GROWTH**  
The cardiac tube grows and appears divided into different regions separated externally by grooves.

**2 FOLDING**  
Because it is bigger than the cavity that contains it, the primitive structure folds into an S shape.

**3**  
The heart cells begin to beat. They all pump blood in unison. The heart has begun to function.

**4 THE CELLS BEAT**  
The heart cells begin to beat. They all pump blood in unison. The heart has begun to function.

## C-shaped

In most vertebrates, the curved C-shape will disappear as the body slowly grows.

**1 FOLD**  
The embryonic tail acquires a curved shape before its disappearance.

**2 ABSORPTION**  
The tail is absorbed when the embryo begins the road to fetal development.

**AMNIOTIC SAC**  
contains the liquid in which the fetus floats and is made up of two membranes that protect the embryo.

**50%**

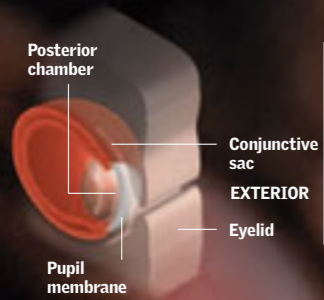
of the embryo is composed of just two organs: the heart and the brain.

**HEART SURFACE**



### Changes in the Head

The brain, the organ of the central nervous system that coordinates all muscle movement, begins to develop. Inside it, the pituitary gland (hypophysis) begins to form. It will produce growth hormone and other hormones. The jaw and the facial muscles also begin to develop.



**4 EYE**  
The eyelid forms. A membrane prepares the final shape of the pupil.

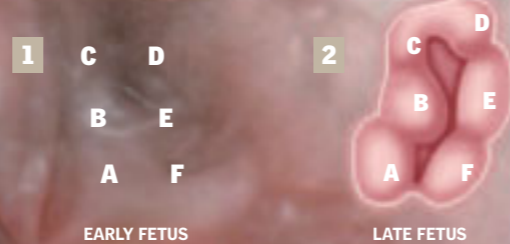
**CORD**  
The umbilical cord begins to develop and, by the time of birth, can measure up to two feet (60 cm) in length.

### Arms and Legs

Small buds begin to appear that will grow until they form the arms and legs. Up to this moment, the arms are in their right place and will remain in proportion to this stage of development. They are only missing the development of the hands. The legs begin to develop, but they take longer than the arms and hands.

**LOWER LIMB BUD** appears on day 32.

### THE FORMATION OF THE EXTERNAL EAR



**THE ARM**  
is developed but is still missing the complete formation of the fingers.

**UPPER LIMB BUD** appears at day 26.

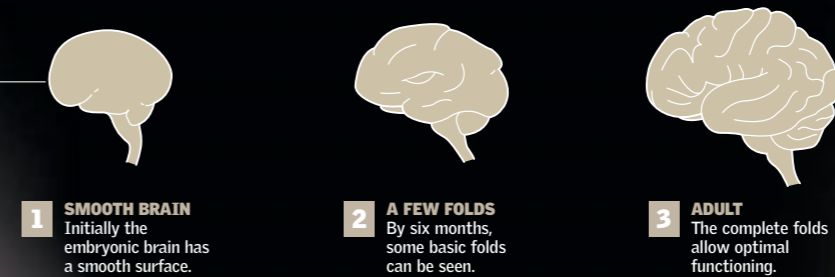**HAND PLATE** appears at day 33.

**DIGITAL RAYS** appear at day 40.

**TISSUE**  
Connective tissue forms. It will engender the cells that form the cartilage, bones, and support tissues.

### THE FOLDS OF THE BRAIN

develop as the months of intrauterine life go by.



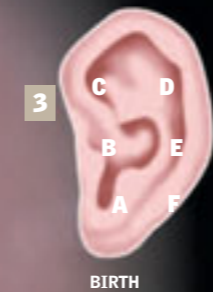**1 SMOOTH BRAIN**  
Initially the embryonic brain has a smooth surface.

**2 A FEW FOLDS**  
By six months, some basic folds can be seen.

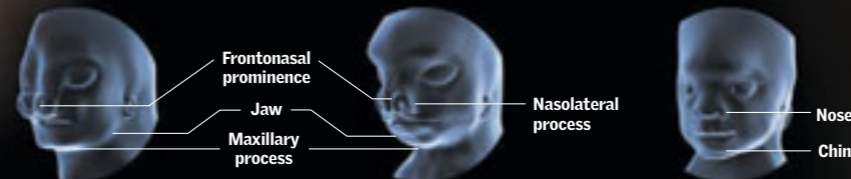
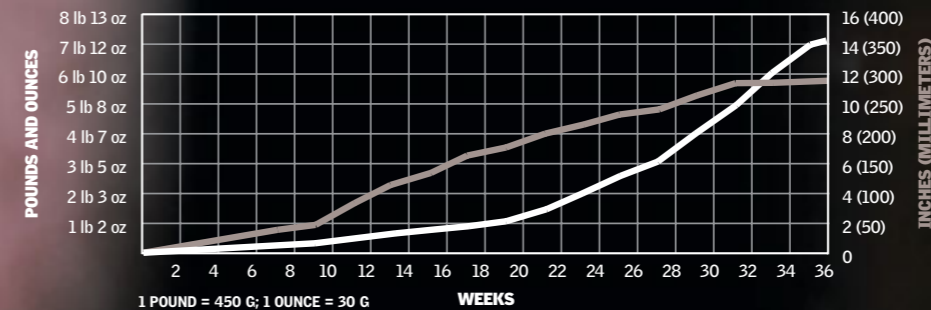
**3 ADULT**  
The complete folds allow optimal functioning.

### The External Ear

Three auricular hillocks can be found in the first arch and three more in the second. As the jaw and teeth develop, the ears move up from the neck toward the sides of the head. Two ectodermic derivations appear in the cephalic region of the embryo: the otic placode and the lens placode. At birth, the external ear exhibits its typical shape.



### GROWTH OF THE FETUS



### FEATURES BECOME DISTINCT

**1 Lower jaw** begins to develop by day 37, together with the lips.

**2 Nose** is roughed out by the invagination of the frontonasal prominence on day 39.

**3 Chin** is already proportional by day 40. The nose has acquired its definitive shape.

### Formation of the Face

The facial characteristics are quickly delineated. The pharyngeal arches that surround the stomodeum in the center of the face are configured. The mandibular processes and the frontonasal prominence can already be identified. From the pharyngeal arch, the maxillary process will also develop, which will give rise to the

premaxillary, the maxillary, the zygomatic bone, and part of the temporal bone. At the roof of the embryo's mouth, the primitive palate is constructed. Through an invagination in the frontonasal prominence, the nose is shaped. The same thing happens with the chin, which acquires normal proportions by day 40 of intrauterine life.

**4 The shape of the face** has begun to develop and will continue to do so until the third month.

Day  
**40**

**LENGTH:** 0.4 inch (10 mm)  
**WEIGHT:** 0.004 ounce (0.1 g)

### Eyes

The optical vesicles develop on both sides of the head, move toward the center, and form the eyes, as will the ducts that will make up the inner ear.

Day  
**36**

**LENGTH:** 0.4 inch (9 mm)  
**WEIGHT:** 0.002 ounce (0.05 g)



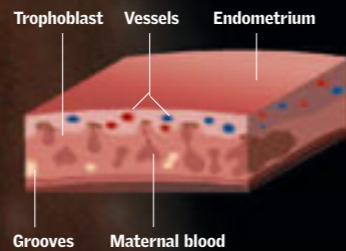
Day  
**44**

LENGTH: 0.6 inch (16 mm)  
WEIGHT: 0.02 ounce (0.5 g)

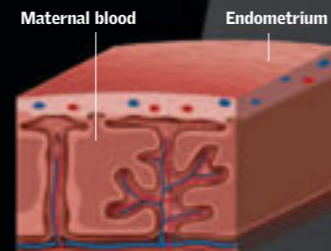
### Changes in the Brain

At this stage, the brain connects with the nervous system. The gland responsible for the production of the hormones begins to develop in it.

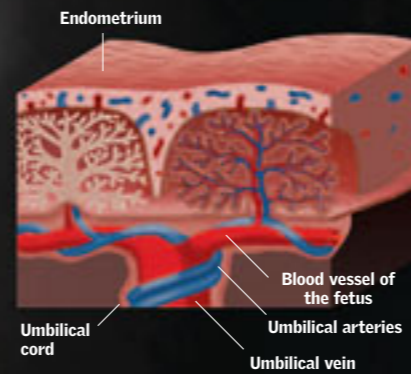
**1 FORMATION OF THE PLACENTA**  
The cells of the trophoblast extend inside the blood vessels of the uterus. The blood from the mother flows from these vessels toward empty spaces inside the trophoblast.



**2 THE PLACENTA AS FILTER**  
The mother's blood and that of the fetus do not have direct contact inside the placenta. They are separated by a barrier of cells. Oxygen, nutrients, and antibodies travel through the barrier and reach the fetus. The waste is returned to the placenta.



**3 END OF THE PLACENTA**  
The placenta continues its development as the fetus grows, such that, by the end of the pregnancy, it measures about eight inches (20 cm). It is connected to the baby by the umbilical cord.

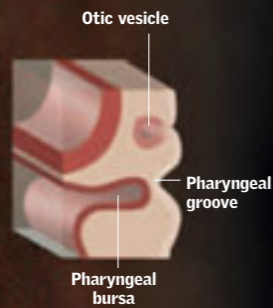


### Development of the Placenta

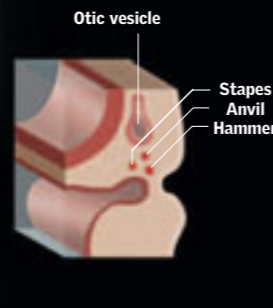
The placenta is a special organ that provides the fetus with different nutrients and oxygen. It also absorbs the waste that the fetus produces and acts as a protective barrier against any harmful substances. The placenta forms from the

trophoblast, the external layer of the blastocyst (mass of cells implanted in the uterus after fertilization). It begins to develop after implantation, and by the tenth day, it is complete. The placental hormones help preserve the endometrium.

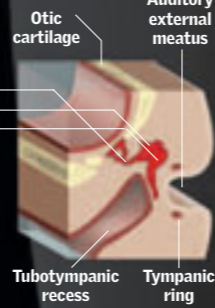
### INTERNAL EAR AND MIDDLE EAR



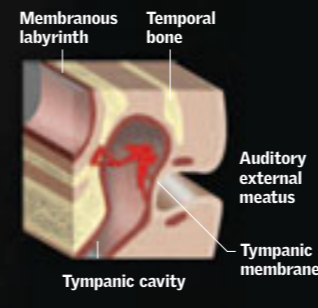
**1 22 DAYS**  
A visible groove appears in the place where the ear will be.



**2 28 DAYS**  
The structures that will give rise to the bones of the middle ear appear.



**3 32 DAYS**  
The middle ear is formed (stapes, anvil, and hammer).



**4 60 DAYS**  
The auditory external meatus develops from the pharyngeal groove.

### BRAIN

After 51 days, the fourth ventricle of the brain controls the flow of blood, and the circulatory system begins to develop.

### THE THALAMUS

The skull begins to form. On day 52, the thalamus develops and can be distinguished. The eyes move toward the front.

**6 weeks**

**THE FINGERS APPEAR** Although the hand has a shape resembling a small paddle, the digits are becoming distinct.

### THE EAR

begins its development in the fourth week but will not be complete until the sixth month, when it carries out the function of bodily equilibrium.

### The Pregnancy Test

A short time after fertilization, the placenta releases a hormone called human chorionic gonadotropin (HCG). The appearance and rapid increase in the concentration of this hormone in the urine are indicators of the existence of a pregnancy. A common pregnancy test contains antibodies that react to the presence of HCG. The user places the tip of the testing device in contact with her urine and waits an indicated amount of time. The presence of two lines in the display will indicate the existence of a pregnancy, while a single line will indicate the opposite. If the test is negative, repeating the test is recommended.



### HOW IT WORKS

**ABSORPTION OF URINE**  
An absorbent tip is placed under the urine stream for six seconds, until it is moist.

**RESULT**  
Two lines indicate the presence of pregnancy. If there is only one, it is recommended the test be repeated within 48 to 72 hours.

**99%**

EFFECTIVE IN DETECTING PREGNANCY

### Everything in Place and Working

During this period, the brain and the nervous system develop rapidly. On both sides of the head, the optic vesicles that will make up the eyes have formed, as have the ducts that will make up the inner ear. The heart already beats strongly, and the digestive and respiratory apparatus have begun to take shape. Small buds that will grow to form the arms and legs appear. The fetus, measured from the top of the head to the coccyx, by the sixth week will have reached 0.6 inch (16 mm).

### INTERNAL ORGANS

At this stage, all the essential organs begin to develop in the gastrointestinal, respiratory, and reproductive systems.

Day  
**60**

LENGTH: 1.2 inches (3 cm)  
WEIGHT: 0.1 ounce (3 g)



# Fetal Development and Childbirth

## FIRST TRIMESTER

Picture of an eight-week-old baby. The development of the brain, heart, and extremities can be noted.

## NEURON DEVELOPMENT 24-25

BOY OR GIRL? 26-27

GROWTH BEGINS 28-29

INTENSE MOVEMENTS 30-31

## REFINEMENT OF HEARING 32-33

CLOSER WITH EVERY MOMENT 34-35

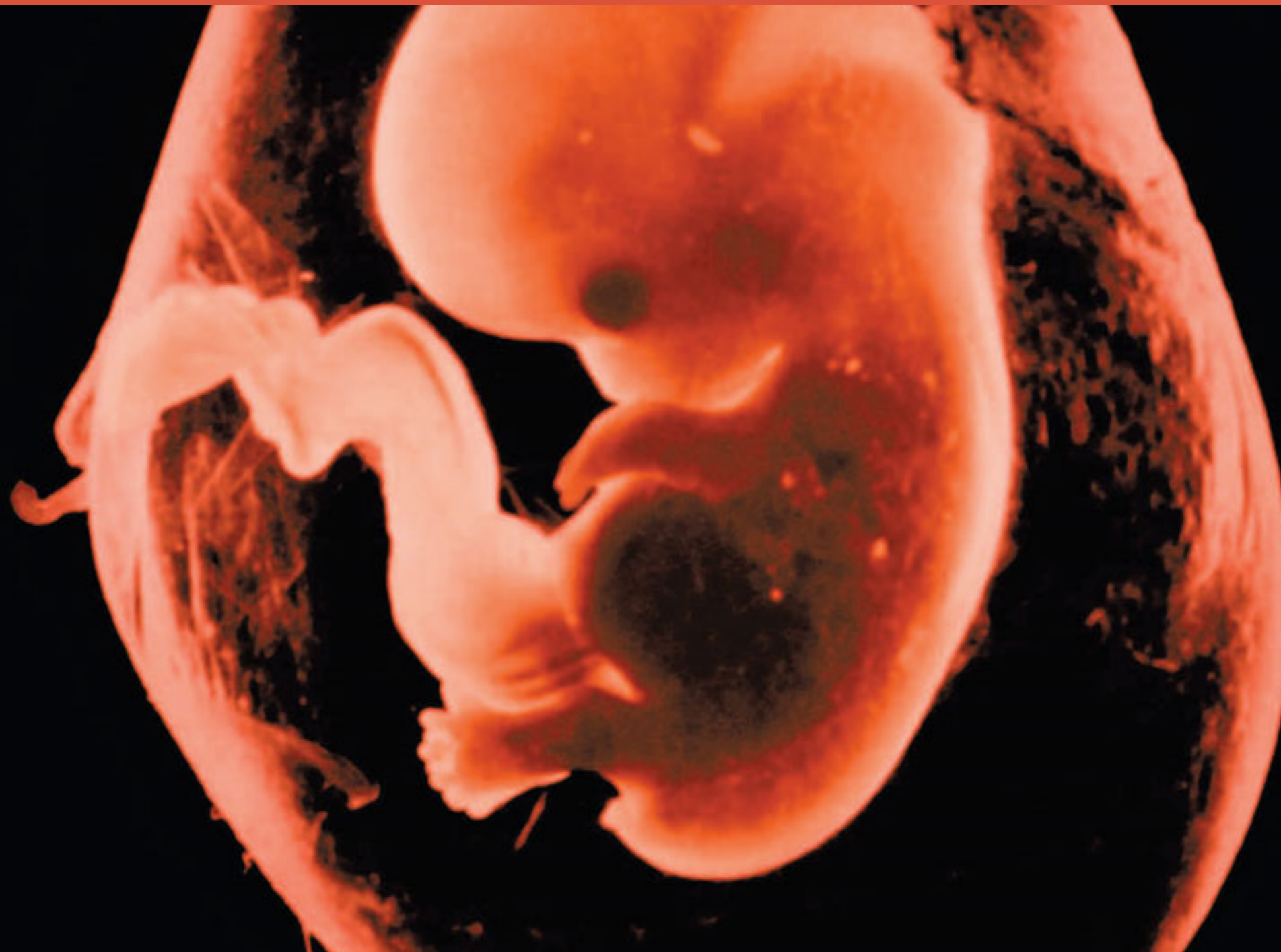CRUCIAL MOMENTS 36-37

FORTY WEEKS OF SWEET ANTICIPATION 38-39

## CHILDBIRTH, ONE MORE STEP 40-41

AFTER CHILDBIRTH 42-43

AN ANSWER TO THE RESEMBLANCE 44-45



The fetus's growth continues progressing day by day, and this chapter illustrates the most notable changes that can be seen. By now, it is possible

to distinguish ovaries from testicles, to observe the external parts of the ear, and to see the limbs flex. We will also use pictures to tell you about DNA, the key substance of the body that enables

hereditary characteristics to be passed from one generation to the next. Which tests must pregnant women take to find out if fetal development is normal? What are the most notable changes that the

woman's body goes through, and what happens once the baby begins to breathe and live outside the womb? ●



# Neuron Development

The third month of fetal development brings distinct changes compared with previous stages. What was once called the embryo is now a fetus. The number of neurons in the brain increases rapidly, and toward the end of the month the fetus has the same number of nerve cells as an adult. However, the interneuron connections have not been established. During this month, through nerve impulses, the network will take shape, which in later months will allow voluntary movements of the joints. ●

**100 billion neurons** are formed between the third and seventh months of fetal development inside the mother's womb.

**THE AXON**  
Nerve fiber that extends from the cell and transmits nerve impulses

**MYELIN ENVELOPE**  
Fatty layer that insulates the axons of some neurons and accelerates the transmission of impulses

**SYNAPTIC NODE**  
Axon terminal. Contains chemical substances (neurotransmitters) that transmit nerve impulses.

**NEURON NUCLEUS**  
contains the genetic information to synthesize the necessary substances for the nerve cell.

**CELL BODY**  
The neurotransmitters that transmit nerve impulses are synthesized here.

**DENDRITES**  
are projections of the neuron that capture and receive the nerve impulses of the other neurons.

**Neuron**  
The neuron is the most important cell in the nervous system. Through the transmission of nerve impulses, they establish connections to other neurons to make the brain function.

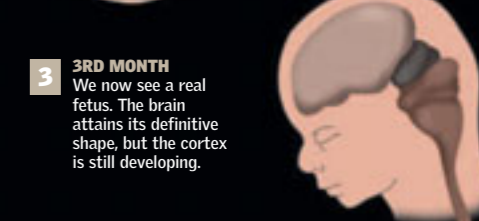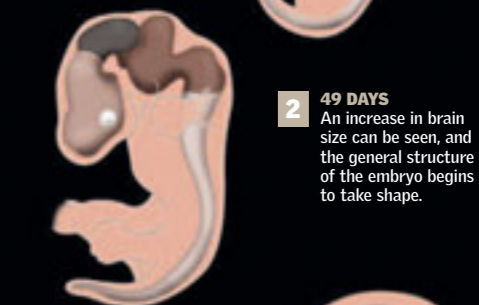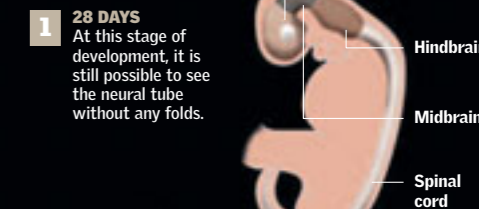
## The Nervous System

In the third month of gestation, the fetus's developing brain changes significantly compared with previous stages. Toward the end of the month, it will have the same number of nerve cells as an adult. The nerves that run from the brain begin to be covered with myelin, a protective lipid layer that insulates the axons of some neurons to speed the transmission of impulses. The nerves and muscles begin to establish connections, setting the foundation for movement controlled by the cerebral cortex. Although the fetus can make a fist and clasp its hands, the movements are still involuntary since the nervous system is not complete.

**640 miles per hour (400 km/h)**  
IS THE SPEED AT WHICH MATURE CELLS OF THE NERVOUS SYSTEM TRANSMIT ELECTRICAL IMPULSES.

## Formation of the Brain

Developing from folds in the neural tube, the brain finishes taking shape by the third month. Later it will develop the folds of the cortex.



## 1 Electrical conduction

Nerve impulses travel through neurons as electrical impulses caused by changes in the ionic concentration inside and outside the cells.

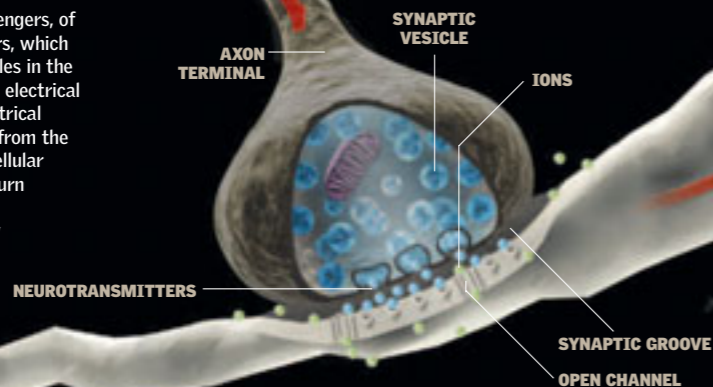


## 2 Chemical conduction

The neurons connect through synaptic spaces, where the impulses are conducted chemically through the release of neurotransmitters.

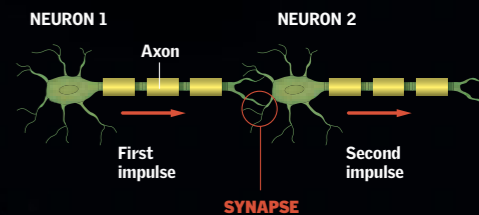
## Chemical Conduction

Chemical conduction occurs when there is transmission between neurons. It works through the so-called neurotransmitters, or chemical messengers, of nerve impulses. The neurotransmitters, which are stored in vesicles (small receptacles in the nerve endings), are released when an electrical signal reaches the nerve ending (electrical conduction). The transmitters travel from the synaptic node of the neuron to the cellular membrane of another cell, which in turn contains receptors that receive the released chemicals. These electrically charged particles (ions) enter the new nerve cell and initiate a new impulse that will be sent to another neuron.



## Electrical Conduction

The nerve impulses inside a neuron travel as electrical impulses. After an electrical impulse is generated, it travels through the axon. This conduction is produced by the exchange of calcium and potassium ions along the length of the nerve cell membrane.



## 3 Synaptic connection

The electrical impulse reaches the vesicles. The neurotransmitters are released into the synaptic gap and travel to the second cell. The impulse is transmitted electrically.

TO NEURON 3



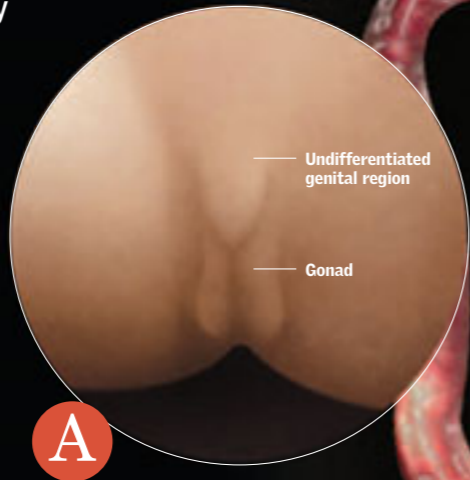
# Boy or Girl?

**B**y the third month of pregnancy, the mother may be anxious to find out if the unborn baby will be a boy or a girl. Although the sex of the fetus has been determined genetically since fertilization, it still cannot be observed at this early stage of development. By the second trimester, at about 12 weeks, the fetus's genitals begin to appear but still cannot be distinguished as being male or female. The initial undifferentiated bulge has a particular shape that allows it to turn into either a penis or a clitoris. ●

## Sex Is Defined

▶ Until the fifth week after fertilization, the embryonic sex organs of boys and girls are identical. Genetically, sex has already been defined, but under a microscope, the genital regions are indistinguishable. The female and male genitals are not yet differentiated. In the third month, the initial bulge that has developed has a characteristic form and is shaped in such a manner that it can

turn into either a penis or a clitoris, with the usual characteristics of either. The genitals have a groove in the urethra that is distinctive. If this groove closes, then a boy is on its way. If it stays open, then the baby will be a girl. The genitals of the fetus, then, begin to grow in the fourth week, becoming visible and external in the eighth week. However, the sex will not be distinguishable until after the 12th week.



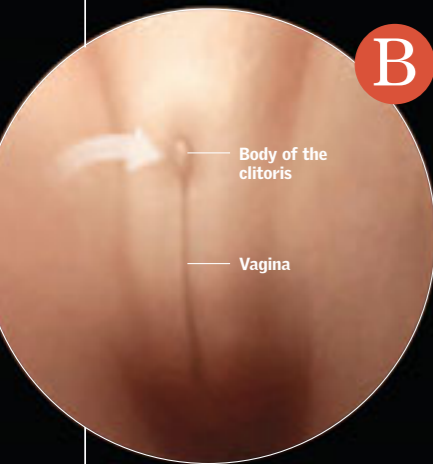
## Undefined

Each embryo has an undifferentiated genital system and the structures necessary to develop into either sex. The gonads are sexually undefined and have both male and female components.

**THE CORD** is completely mature and is rolled up so that the baby can move around without any risk.

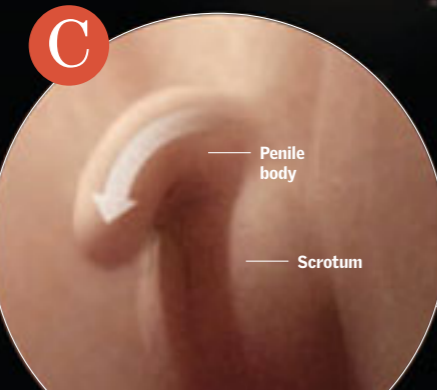
## If It Is a Girl

The vulva (which contains separate openings for the vagina and urethra) and the vagina develop from the same common structures. The clitoris will begin to form from a bulge in the urogenital sinus, the genital tubercle. The intervention of hormones is key in influencing the differential formation of each organ. The evolution might be different, but the origin is exactly the same.



## If It Is a Boy

By the 11th week, the genital tubercle lengthens rapidly and forms the penis. The components of what will be the genitals are progressively modified and form the elements that define the external genitalia of the male—testicles, scrotum, and penis.



**3.5 inches (9 cm)**

**SECOND TRIMESTER**  
By the beginning of the second trimester, the fetus measures 3.5 inches (9 cm) long.

Month

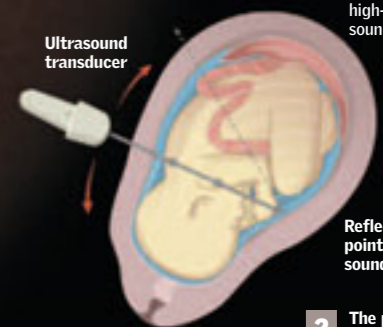
**3**

**LENGTH: 4 inches (10 cm)**  
**WEIGHT: 1.6 ounces (45 g)**

## The Sonogram

▶ An ultrasound image, also known as a sonogram, uses inaudible sound waves to produce images of the different structures of the body. During the examination, a small device called a transducer is pressed against the skin. It generates high-frequency sound waves that pass into the body and return as echoes as the sound waves bounce against organs, blood-vessel walls, and tissues. A special computer converts the echoes into an image.

### HOW A SONOGRAM IS MADE



**1** **Transmission of impulses**  
The ultrasound transducer emits high-frequency sound waves.

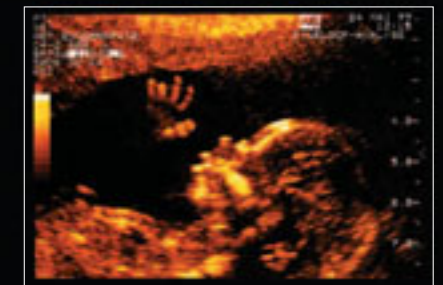**2** **The path**  
The ultrasound impulses pass through the body's tissues and bounce off surfaces.

**3** **Detecting the echo**  
Some impulses are reflected as echoes that the wand picks up and sends to the sonograph.

**THE HEAD** is still disproportionately large in relation to the body. It represents a third of the length of the fetus's body.

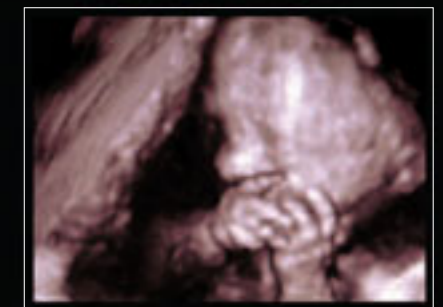**THE EYES** are completely formed, although they are very far apart. They have been slowly moving toward the front of the head throughout embryonic and fetal development.

**THE HANDS** already have fully developed fingers. They have fingernails and the shape of human extremities.



### FORMING THE IMAGE

The sonograph calculates the distance from the wand to the tissues, the echo intensity, and the return time of each echo in millionths of a second. Some sonographs show three-dimensional images. They show the entire surface of the fetus and help to identify any deformation.



## The Sperm

▶ According to popular belief, to conceive a boy one must have sex on the day the woman is ovulating or the day after, since sperm with a Y chromosome (determinant of the male sex) are quicker than those that contain the X chromosome (female) and reach the egg first. If the desire is to have a girl, it is best to have sex a few days earlier: X sperm are slower, but have more endurance and live longer.

### LIFE COMPARISON

X	72 hours
Y	48 hours

The sperm with an X chromosome are slower but have more endurance. They can last up to 72 hours. The sperm with a Y chromosome, on the other hand, are quicker but last only approximately 48 hours.



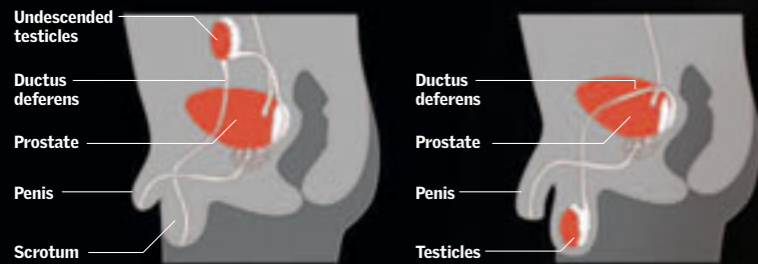
# Growth Begins

During the fourth month, the mother senses the fetus's first movements. The fetal body changes; its face is completely formed. The skin has a pinkish tone, and the first ribs and cartilage appear. The external sex organs finish forming, and the internal ones differentiate. The first subtle movements of the fetus begin, although they are barely perceptible because of its small size. The fetus now occupies the entire uterine cavity and pushes the abdomen forward. Its extremities can be clearly seen. The little one enters its full growth phase. ●

## Sex Development

▶ During this period, the fetus begins to reveal the differences in its urogenital system. The undifferentiated gonad, which has male and female components that developed during the

embryonic stage, is converted into ovaries in a girl or testicles in a boy. In either case, its presence will determine the development of the individual's sexual characteristics.



**1 MALE GONAD**  
Toward the seventh week, it has already been determined whether the fetus is XY (male) or XX (female). If a gonad is evolving into a testicle, the undifferentiated gonad increases in size as it descends into the scrotum.

**2 DESCENT OF THE TESTICLES**  
At about the eighth week, the testicles leave the abdominal cavity and descend toward the scrotum. For males, the presence of the testicles and the actions of their hormones are necessary.

## Amniocentesis

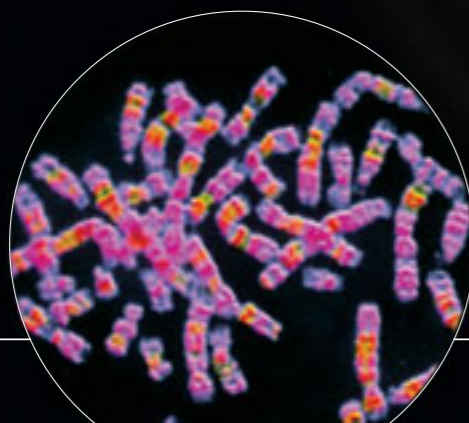
▶ is a test that is performed by studying the amniotic fluid in the sac that surrounds the fetus. After the insertion of a hollow needle into the abdominal wall of the uterus, a small amount of liquid is extracted. It is not a routine test, and it is invasive. It is done when there is suspicion of abnormalities that cannot be detected with other tests (e.g., tests for spina bifida or metabolic diseases).

### COMPONENTS OF THE AMNIOTIC FLUID

**98 % water**  
**2 % Organic solutes:** proteins, lipids, carbohydrates, and nonprotein hydrogenated components. **Inorganic solutes:** zinc, copper, iron, and magnesium.

## Chromosomal Study

Amniocentesis gives a cytogenetic map (map of chromosomes) from which different chromosomal disorders can be detected, such as Down syndrome (an extra chromosome in pair 21) or the existence of an abnormal gene that can cause neurological or metabolic diseases.



**160**

is the number of heartbeats per minute in the early stages of intrauterine life. Toward the end of gestation, the number drops to 120.

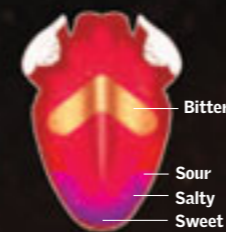### LOWER LIMBS

In this stage, the legs grow rapidly in a proportional manner and are longer than the arms.

## The Taste Buds

develop at this stage, although they are activated only in the last trimester of gestation. The tongue has approximately 10,000 taste buds.

### THE TONGUE



## Month

**4**

**LENGTH:** 5.9 inches (15 cm)  
**WEIGHT:** 5.3 ounces (150 g)

## Changes in the Brain

▶ The brain continues its growth and starts to develop folds. During most of the intrauterine period, many neuron cells are produced per second. A large portion of energy will be concentrated solely on the development of this vital organ. The areas of the brain that show the greatest growth at this stage are those that control motor skills and memory. The regions that control the basic urges such as hunger are also forming.

### MOTOR CORTEX

will send signals to the muscles to move the body.

### PREMOTOR CORTEX

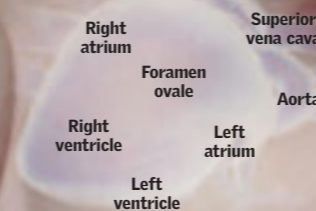will coordinate more complex movements, such as playing musical instruments.

### FINGERS

The fetus's genetic uniqueness also starts to become evident in the development of its fingerprints.

### EARS

The ossicles (tiny bones) begin to harden. The fetus can sense its mother's voice and heartbeat.

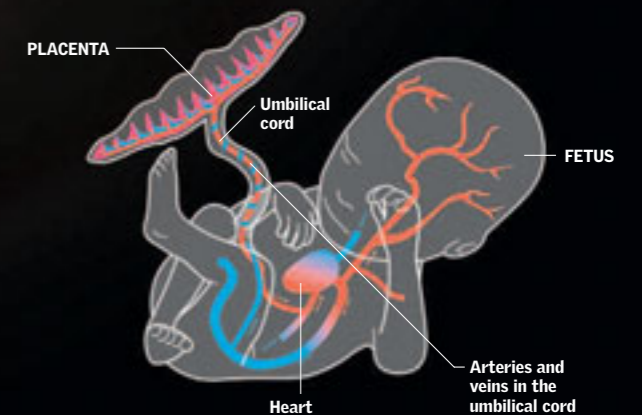


## The Heart

At this stage, it beats at the mother's heart rate and pumps more than 6 gallons (25 l) of blood each day. Its size is large relative to the body. The foramen ovale in the fetal heart is a hole that allows the blood to circulate from the right atrium to the left one. It will close during the first three months after birth.

## Circulatory System

▶ The fetus receives oxygen and nutrients from the placenta through the umbilical cord, so its circulatory system differs from that of a newborn baby. During intrauterine life, its heart is the center of a system interconnected with the lungs and liver through arterial and venous ducts that, after birth, will close and become ligaments.



### BONES

can be distinguished with X-rays and have begun to change from cartilage into calcified bones.

### THE SKIN

is still translucent, thin, and wrinkled, and it allows the developing blood vessels and bones to be seen.

### UPPER LIMBS

The fetus begins to move and flex the joints of its extremities.



# Intense Movements

The fifth month of intrauterine life reveals marked changes: the fetus's movements are more obvious and intense and are perceptible to the touch. During this period, it is important to have ultrasound exams to check for the position of the placenta, the proper circulation between the uterus and placenta, and the risk of premature birth. The future baby's features are clearly visible. ●

## Energetic Movement

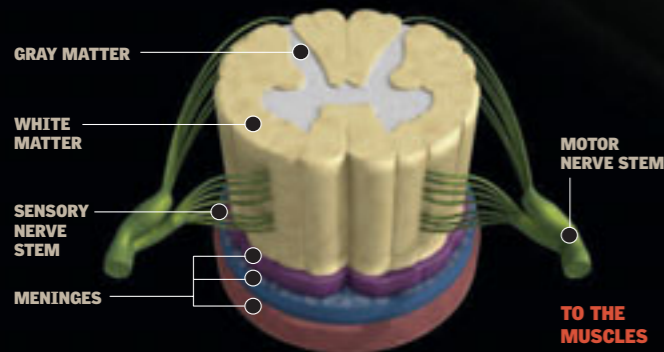
Because of the accelerated growth and development of its internal organs, the fetus is much more active. It turns, moves from side to side, and finds ways to be more comfortable inside the uterus. It is exploring the surroundings where it lives, which makes its movements strong enough to notice. When she least expects it, the mother can receive a kick from the unborn baby. Anyone that gets close to the mother's belly can hear the fetal heartbeat through a special device.

## Spinal Cord

begins to develop in the fetus. The spinal cord will be the communication link between the brain and the rest of the body. The spinal cord receives and transmits information through the nerves. The nerve impulse stimulates the muscle to move.

### MUSCLE MOVEMENT

- 1 The brain processes sensory data and sends information to the spinal cord.
- 2 The spinal cord receives the nerve impulse from the brain and sends a response to the muscle.



## Internal Organs

are in a maturing stage and most are already formed. However, the lungs and the digestive system are not yet complete. The fetus cannot maintain its body temperature or survive outside the uterus.

Month  
**5**

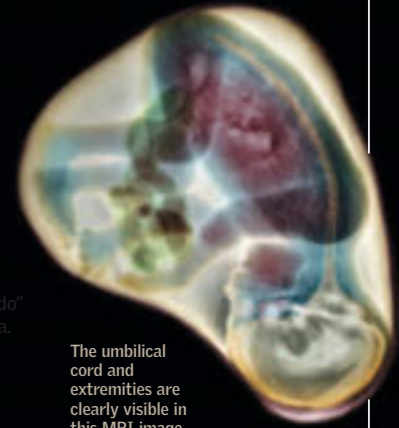**LENGTH:** 7.9 inches (20 cm)  
**WEIGHT:** 17.6 ounces (500 g)

## Exploration

It is very important for the mother to have prenatal tests done periodically to monitor for possible problems or abnormalities in the fetus. Different techniques can be used to verify the fetal position and the development of its features. Sonographs produce images of the internal organs or masses for diagnostic purposes. Three-dimensional magnetic resonance imaging (MRI) allows the diagnosis of previously undetectable diseases and pathologies. In addition, it is not harmful to the fetus. 4-D ultrasound allows monitoring of the fetus in real time.

## MRI

Magnetic resonance imaging allows diagnosis of the fetal position when this is difficult to accomplish with other techniques. This can be helpful in planning for the birth. Unlike conventional X-rays, magnetic resonance imaging does not have harmful effects on the fetus because it does not emit any ionizing radiation. Use of the "quebrado" process is recommended from the moment a fetal abnormality is suspected until birth.

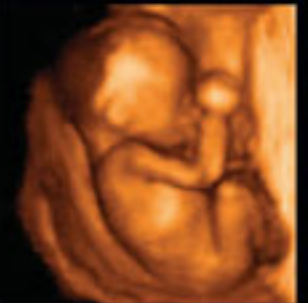

**THE HEAD** is the part of the body that develops most actively. Eyes, mouth, nose, and ears are almost completely formed.

**LANUGO** is the fine hair that appears in the fifth month of gestation. It covers the entire body.

## 4-D Ultrasound

Incorporating the dimension of time into ultrasound exams has made it easier to observe the fetus, since the parents can see it in three dimensions and in real time while it moves. The use of 4-D ultrasound is not limited to obstetrics; it is also a tool to check the status of other organs, such as the liver, the uterus, and the ovaries.



**IN ACTION**  
The growing baby can be clearly distinguished in a three-dimensional ultrasound, which also allows fetal movement to be seen.

## Defense System

With its body and organs well formed, the fetus now enters a stage of maturation characterized by, among other things, the construction of a defense system. Fatty deposits accumulate and settle in different parts of the body, such as the neck and chest, to generate body heat and maintain the body temperature. The fetus also develops a fledgling immune system that will partially protect it from some infections.

## A Song to Life

Even though the ear has not reached its peak development, it can already perceive sounds from the outside, besides those coming from the mother (heart, stomach sounds). The mother's physical state and her mood strongly influence the future baby, who can tell at all times if things are right or not.

**AMNIOTIC FLUID**  
The baby can swallow it and even taste the substances that float in it, because the taste buds are already developing.



# Refinement of Hearing

**D**uring the sixth month of gestation, the ears exhibit their peak development. The fetus is sensitive to sounds outside the uterus and can hear very loud sounds. The cochlea, in the inner ear, is vital for processing sounds and already has attained its characteristic coiled shape. This is the month where the fetus prepares for life as an independent being. ●

## Recognizing the Parents' Voices

▶ With the perfection of the sense of hearing, the baby not only can hear noises and voices from outside but also can memorize them. It can recognize both the mother's and the father's voices. Since the fetus can respond to external stimuli, the parents are usually recommended to talk and play music. It can also move to the rhythm of the music and shows musical preferences. With its eardrums fully developed and fully functional, the fetus can now hear sounds originating from itself, such as its heartbeat.

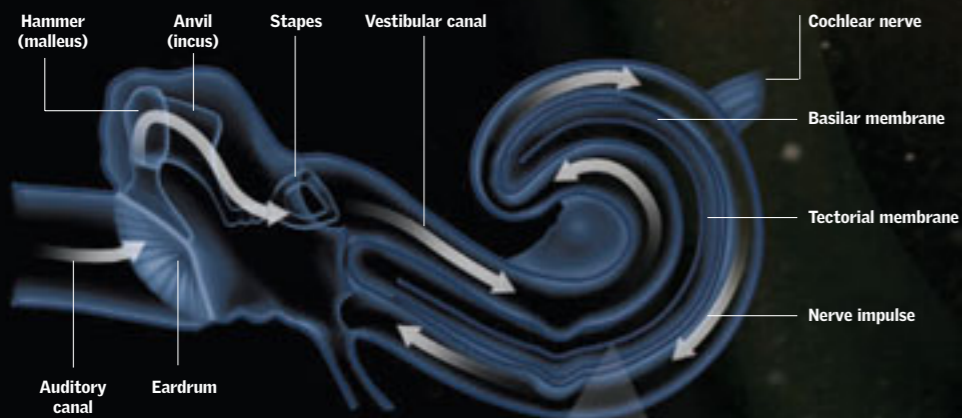
## Balance

The functioning of the sense of hearing is essential also for understanding the sense of balance. The inner ear has fluid that sends nerve impulses to the brain to update the information about the body's movement and to maintain balance and posture.

**0.1 in**  
**(3 mm)**

THE SIZE OF THE STIRRUP, THE SMALLEST BONE OF THE EAR

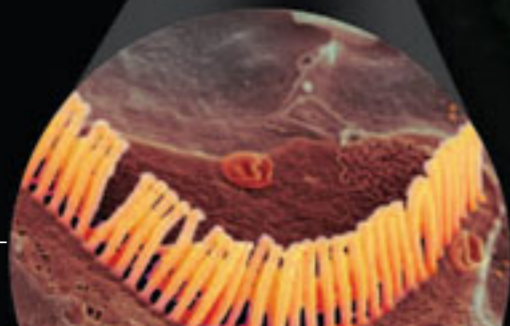
### SOUND WAVE PATH



- 1 Sound waves enter the outer ear canal and are transmitted to the eardrum.
- 2 The eardrum receives the sound waves as vibrations, which later reach the cochlea.
- 3 In the cochlea, the organ of Corti gathers the vibrations through hair cells.
- 4 Filaments in the cochlea are agitated and stimulate the nerves to send messages to the brain.

**15,000**

**HAIR CELLS** are in the organ of Corti. They convert the sound vibrations into nerve impulses, which travel to the brain to be processed as sound.



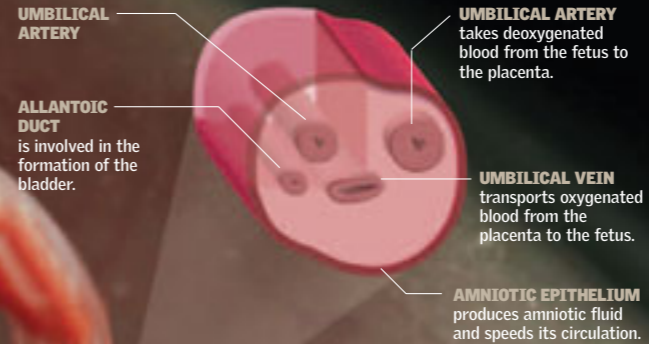
**20**

**THE HOURS** per day that the fetus sleeps. When awake, it is very active.

Month  
**6**

**LENGTH:** 9.8 inches (25 cm)  
**WEIGHT:** 2 pounds 3 ounces (1 kg)

### CROSS SECTION OF THE UMBILICAL CORD



ENLARGED AREA

## The Umbilical Cord

▶ is the structure that connects the fetus to the placenta. It constitutes the immunological, nutritional, and hormonal link with the mother. It contains two arteries and a vein that regulate the exchange of nutritional substances and oxygen-rich blood between the embryo and the placenta. It is 12 to 39 inches (30-100 cm) in length, connects the fetus's navel to the placenta, and constitutes the first physical tie between the mother-to-be and the fetus. Usually there are no complications related to the umbilical cord, although there are cases where knots form that block the flow of blood. These knots can be deadly if they are not controlled or corrected.

**FEET** are defined and acquire their shape. The toenails become visible.

**FLAVORS**  
The fetus can distinguish sweet and bitter flavors; of course, it prefers sweet.

**HANDS**  
The first lines appear on the palms. The fingers can be seen.

**KICKS**  
The joints are already developed and the baby kicks with rapid movements.

**PRIMARY AUDITORY CORTEX** receives incoming sounds.

ENLARGED AREA

**ASSOCIATION CORTEX** interprets the sound.



# Closer with Every Moment

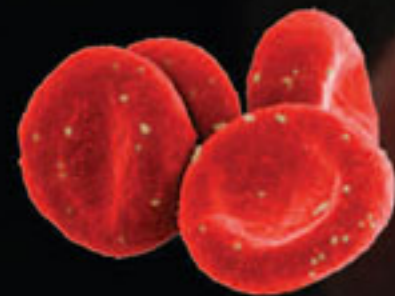
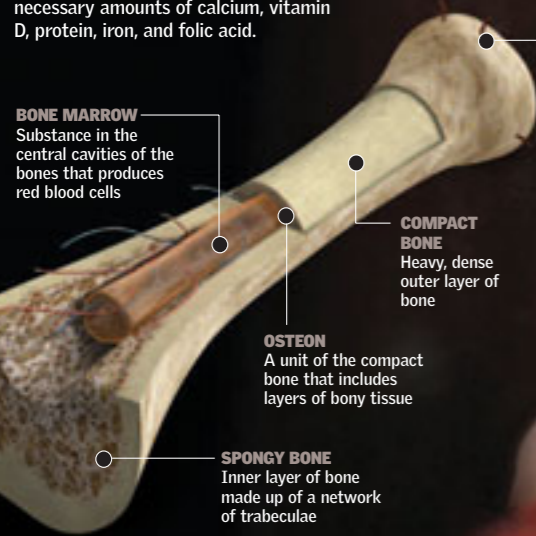The beginning of the third trimester of pregnancy marks a key point in gestation. The process of strengthening and calcification of the bones of the fetus begins. Its body needs nutrients, such as calcium, folic acid, and iron. The baby can already open and close its hands (which will soon have defined fingerprints) and also opens and closes its mouth, sticks out its tongue, and can even suck its thumb. Its skin is still very thin but has begun to turn opaque. The bones and muscles begin to have more consistency. The organs are completely formed. ●

## Bone Calcification

The baby's bones have begun the process of strengthening through the buildup of calcium and also phosphorus. Bone growth is regulated by many hormones. As the bones are getting harder, appropriate nutrition is important in order to provide the necessary amounts of calcium, vitamin D, protein, iron, and folic acid.

**300** THE NUMBER OF BONES IN A FETUS.

After birth and before reaching adulthood, the skeletal system goes through a fusion process that reduces the number of bones to 206.



## Red Blood Cells

The production of blood cells develops in the longer calcified bones, such as the femur, in a liquid substance called bone marrow, which is found in certain bone cavities.

## Month 7

**LENGTH:** 12 inches (30 cm)  
**WEIGHT:** 3 pounds 5 ounces (1.5 kg)

## Central Nervous System

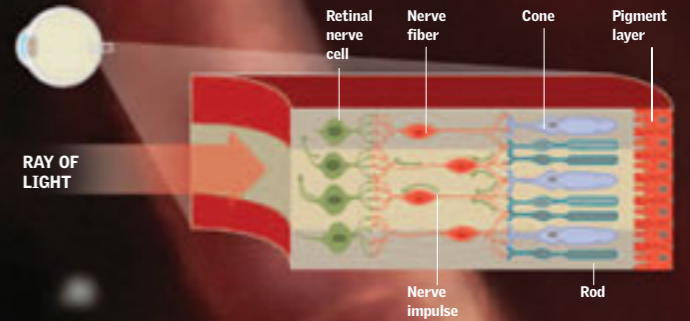
The folds in the cerebral cortex undergo rapid development that is more noticeable toward the end of the month. The body temperature and breathing are already controlled by the central nervous system, which controls the inhalation of air.

## The Fetus Opens Its Eyes

The optical structure is practically fully formed. The fetus can open and close its eyes, which will keep their sky blue color until the second week after birth, since the definitive pigmentation is attained

through exposure to light. With the general development of the eyes, the fetus can already distinguish changes from light to dark. It might also be able to see its hand clearly, since it puts it into its mouth with ease.

### REACTION TO LIGHT



- 1 Light enters**  
through the pupil and reaches the pigment layer in the retina.
- 2 Nerve impulse**  
The cone and rod cells, when stimulated, transmit impulses to the fibers.
- 3 Reception**  
The retinal nerve cells receive the impulse and relay the information to the brain.

## Glucose Tolerance Test

In the seventh month of pregnancy, a crucial test is performed to detect the possible presence of gestational diabetes (diabetes that develops during pregnancy). In this test, called the Glucose Tolerance Test, or the O'Sullivan Test, a glucose load (about 1.8 ounces [50 g]) is administered orally to the fasting woman. An hour later, blood is drawn and the glucose level is measured.

### THE SKIN

is no longer transparent and takes on a more opaque color. Layers of fat begin to accumulate under the epidermis, which makes the skin smoother.

### REFLEX

The typical reflex of thumb sucking is perfectly developed by the seventh month.

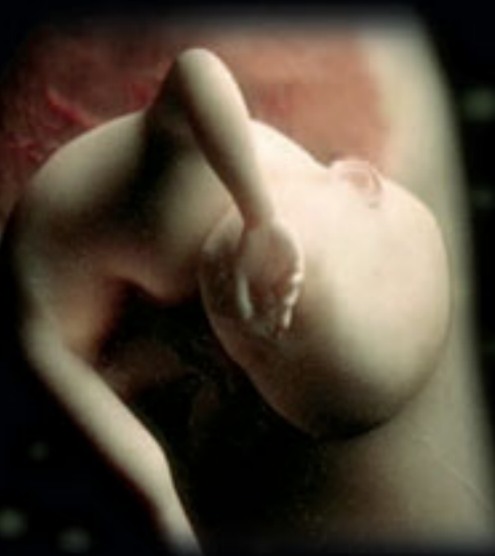

# Crucial Moments

The eighth month of pregnancy brings many obvious changes to the fetus. The lanugo disappears from the fetus's face, and the limbs become chubby. Birth is imminent, and before the month is finished, most fetuses assume a head-down position. The space in which the fetus has to move within the uterus is minimal, so during this time the fetus remains almost still. Except for the lungs, the organs are fully functional. That is why birth at this stage entails many risks. ●

## Final Preparations

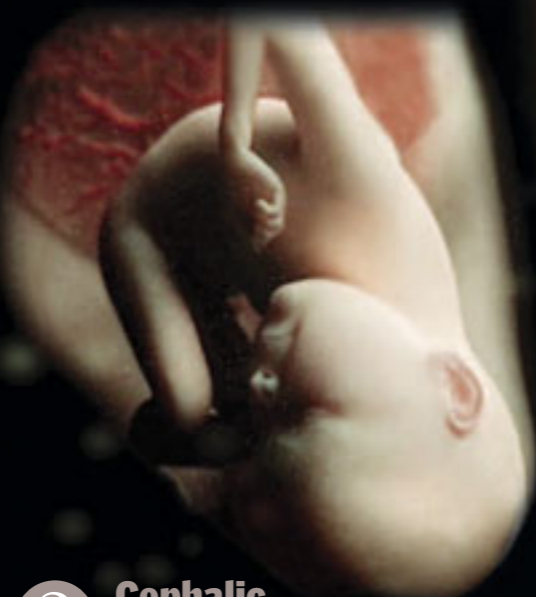▶ At the beginning of the eighth month, the unborn baby's kicks become increasingly forceful and frequent. The shifting toward its final position begins, which in most cases is cephalic (the head toward the pelvis), although sometimes it is breech (with the buttocks toward the pelvis). If the baby is in a breech position, a cesarean section might be necessary. It is common to do ultrasound exams at this stage to verify that the baby's weight is adequate.



**1 Reduced Space**  
Since the fetus has reached a considerable size, it now has little room in which to move. Hence, it begins to turn and kick forcefully.

**20 million**

**THE NUMBER OF ALVEOLI** the fetus has before birth. Lung development will continue until eight years of age, and the child will end up having 300 million alveoli.

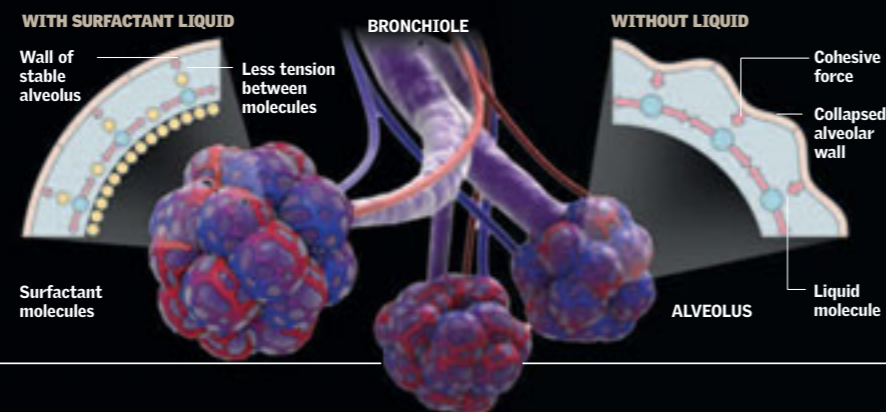


**2 Cephalic Presentation**  
In 90 percent of cases, the fetus is positioned so that the head will come out first during delivery.

## Appearance of the Pulmonary Surfactant

In the eighth month of pregnancy, a substance called surfactant appears in the alveoli. This liquid covers the alveoli, which are surrounded by blood vessels and provide the surface for gaseous exchange. The surfactant maintains equilibrium in the lungs and keeps them from completely

collapsing after every breath. With the presence of proteins and lipids with hydrophobic and hydrophilic regions, water is absorbed by the former regions and air is absorbed by the latter. A baby born at eight months can have problems because it lacks surfactant.



**MECONIUM** is a dark green substance that is found inside the intestine. It is the first thing excreted by the baby after birth.

**10**

**THE PROPORTION OF THE FETUS'S HORMONE PRODUCTION** compared with an adult. After birth, the ratio decreases.

## Rh Disease

▶ When a baby's mother is Rh-negative and the father is Rh-positive, the baby can inherit the Rh-positive blood from the father. In this case, there is the danger that some of the baby's red blood cells may enter the mother's bloodstream. Red blood cells with the Rh factor are foreign to the mother's system, and her body will try to eliminate them by producing antibodies. The risk of this development increases after the first pregnancy.

**ADRENAL GLANDS**  
Located above the kidneys, the glands that produce adrenaline have already attained the size of those of a teenager.

**THE SKIN** is pink and smooth. The fetus continues to accumulate fat reserves in the epidermis. The hair that has protected it disappears.

Month **8**  
**LENGTH:** 13.8 inches (35 cm)  
**WEIGHT:** 5 pounds 8 ounces (2.5 kg)

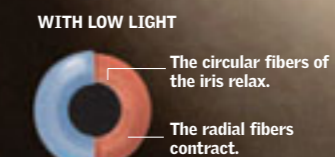

**3 Final Position**  
The fetus has assumed its final position before delivery. Its buttocks will start pressing against the mother's diaphragm.

**INTERNAL ORGANS** are completely developed, except for the lungs, which have yet to be completely coated with surfactant.

**SENSE OF TASTE**  
The fetus drinks amniotic fluid and can already distinguish flavors with its developing taste buds.

**THE EARS** are already mature. The fetus can perceive low sounds better than high ones.

**EYESIGHT**  
The fetus begins to blink. The iris can dilate and contract according to the light it receives, even though the fetus is not yet fully able to see.





# Forty Weeks of Sweet Anticipation

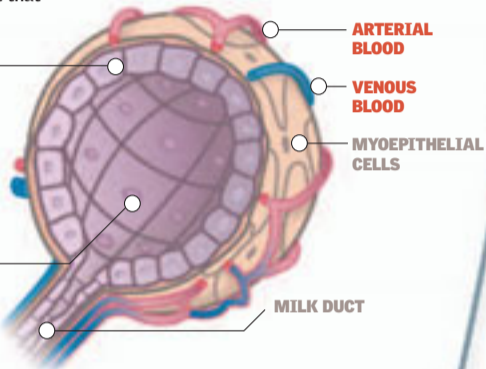
The pregnancy is reaching its end. During the last few months, besides the enlargement of the belly and breasts, the mother has undergone many psychological and emotional changes because of altered hormone levels. Now, a step away from birth, it is possible that she might not sleep well and may tire easily. Moreover, in this situation, certain fears and anxieties are common to every woman, so it is best to be well informed. ●

## The alveolus

is the functional unit that produces milk.

**MILK-SECRETING CELL**  
Each cell functions as a complete unit, producing milk with all its constituents.

**INTERNAL CAVITY (LUMEN)**  
Secreted milk is stored here.



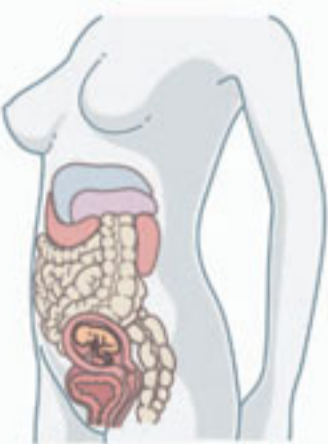
## MILK EJECTION

When the ducts contract as a response to oxytocin (let-down reflex), the milk flows inside the galactophorous, or lactiferous, ducts toward the reservoir of the mammary gland.



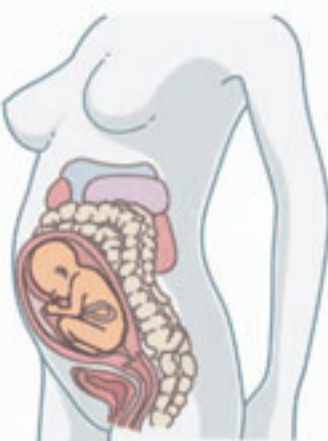## Changes per Trimester

A pregnancy lasts 40 weeks, which by convention are divided into three trimesters. Each trimester corresponds to a series of more or less specific changes that come from the fetus's different developmental stages. Many of these transformations are painful, such as the pressure of the enlarged womb against the spine. There is also an increase in weight, dizziness, mood swings, and changes in heart rate.



### 1 First Trimester

During the first trimester of pregnancy, the body prepares to carry the fetus. The woman's breasts grow and their conditioning for breast-feeding begins. Dizziness and nausea are frequent during this period, the cause of which is not precisely known. Also normal is an increased need to urinate due to the activity of certain hormones that generate a need to empty the bladder repeatedly. It may also be apparent that the waistline is beginning to fade.



### 2 Second Trimester

is the period when it first becomes noticeable that the woman is pregnant. The uterus now extends from the pubic bone to the navel, and the belly is noticeable. The heart rate is altered by changes in the circulatory system. Varicose veins can also form in the legs due to the difficulty blood has returning through the veins from the lower limbs.

### 3 Third Trimester

The skin stretches over the belly and very soft contractions begin to be felt. The uterus has grown and pushes on the bladder, which in some cases causes incontinence. In this period, back pains become more recurrent. The large volume of the belly can often cause deformations of the spine. In some women, breathing difficulties and repeated fatigue can develop. It is also normal to develop hemorrhoids.

## VITAL CHANGES

- 1 Menstruation is interrupted. Women with regular periods (between 28 and 30 days) can notice this more easily.
- 2 Discomfort. Itching of the breasts, nausea, dizziness, and tiredness, even before the first month is finished.
- 3 The uterus expands. At eight weeks, this is perceptible through a gynecological exam.
- 4 Movements are felt. Beginning in the fourth month, it is possible to perceive the movements of the fetus's hands and feet by ultrasound.

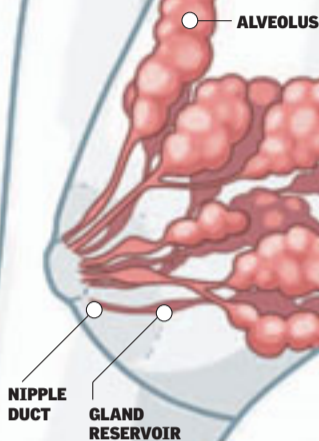
## The Breasts

are made up of adipose tissue and a system of ducts that extend from the mammary glands to the outside. Along their length, they are covered by two layers of cells: an inner one (epithelial) and a

discontinuous outer one (myoepithelial). At the beginning of pregnancy, the increase in the hormone progesterone triggers the enlargement of the breasts, which increase by one size in the first six weeks.

**GALACTOPHOROUS DUCTS**  
The largest ones are in the nipple and branch out within the breast.

**PHYSIOLOGICAL CHANGES**  
With pregnancy, they become larger and the nipple and the areola get darker, the skin on the breasts stretches, and the ducts widen.



**NIPPLE**  
The galactophorous ducts lead here.

**AREOLA**  
Circular region 0.5 to 1 inch (15-25 mm) in diameter. It contains sebaceous glands. Its size varies with the pregnancy.

## Breast-feeding

THE BABY IS NOURISHED NOT ONLY BY THE MILK BUT ALSO BY THE PHYSICAL CONTACT WITH ITS MOTHER.

## MILK COMPOSITION

ELEMENTS	%
Water	87
Proteins	1.5
Casein	0.5
Fat	3.8
Carbohydrates	7.0
Other	0.2

**NEW LIFE**  
has grown from a mere embryo, and the woman's entire belly grows to accommodate this increase in size.

40%  
MORE BLOOD IS PUMPED BY A PREGNANT WOMAN'S HEART.



# Childbirth, One More Step

Finally, the long-awaited day has arrived—the end of gestation and the moment of delivery. Labor is said to begin with the onset of regular uterine contractions. Labor has four stages: dilation, expulsion, delivery proper, and delivery of the placenta. With each contraction, a little more of the baby's head appears, and after about 15 minutes, the rest of the body comes out by itself and the umbilical cord is cut.

## Labor

The labor process of birth is a joint effort between the fetus and the mother. Labor is divided into four stages: dilation, which starts with the contractions; expulsion, in which the fetus travels down the birth canal; delivery; and delivery of the placenta. Once the umbilical cord is cut, the newborn begins to breathe independently with its own respiratory system.

### 1 Dilation

As the mother's uterus begins to contract, the upper part of the fetus is pushed downward. The fetus begins its descent. Its first stop will be the pelvis before it reaches the birth canal.

Month  
**9**

**LENGTH:** 19.7 inches (50 cm)  
**WEIGHT:** 6 pounds 10 ounces (3 kg)

SIDE VIEW

**AMNIOCHORIAL SAC** is filled with amniotic fluid, which protects the fetus and provides it with space for movement.

**OBLIQUE DIAMETER** 4.3 inches (11 cm)

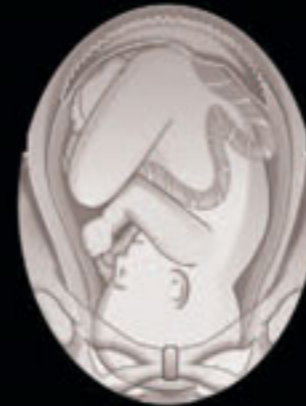## Contractions

The regular and frequent contractions of the uterus generally appear on the date of delivery. They are indispensable for childbirth to be natural and spontaneous. The uterus is a muscle, and each contraction shortens the muscle fibers of the cervix and contracts it to open it. The stage of contractions

is the first phase of labor and the most important. If it proceeds normally, the baby will come out of the uterus naturally and begin its journey to the outside. Without contractions, the mother will not be able to push the baby, and it will be necessary to resort to assisted-labor techniques.

### PUSHING THE FETUS

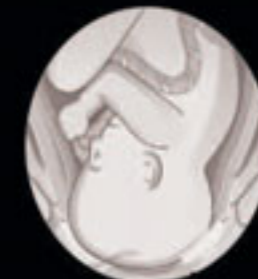- In preparation for delivery, the mother's uterus begins to contract at short intervals.
- The mother's uterus contracts, putting more pressure on the upper part and pushing the fetus, which begins its descent.
- The opening of the cervix dilates gradually with each contraction. The dilation is complete when it reaches 4 inches (10 cm).



4 inches (10 cm)

### THE CERVIX

The contractions of the uterus cause the gradual dilation of the cervix. It dilates completely when the opening is 4 inches (10 cm) in diameter. From this moment, labor passes to the second stage. The amniotic membranes can rupture at any time.



Cervix

## Relaxation

After each contraction, the mother should be able to relax the uterus so that the fetus gets enough oxygen. Without relaxation, the amount of blood reaching the fetus is reduced because the uterus flattens the blood vessels as it contracts.

### THE SKULL

Until 18 months after birth, the skull will have cracks between its bones that will later fuse.

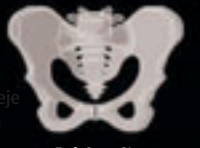
## The Pelvis

It is important to know the shape and size of the future mother's pelvis to determine how difficult delivery will be. Any difference between the dimensions of the mother's pelvis and the unborn baby's head could obstruct normal delivery.



Pelvic entrance 5.1 inches (13 cm)

**ROUND PELVIS** is the most common pelvis shape. Sometimes it may be oval-shaped. The pelvic exit usually has a diamond shape.

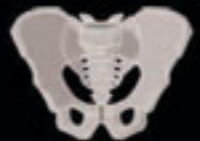

Pelvic exit 4.3 inches (11 cm)



Pelvic entrance 4.7 inches (12 cm)

**TRIANGULAR PELVIS** In some cases, the pelvic entrance is triangular and the exit is narrower. Delivery is more complicated in these cases.



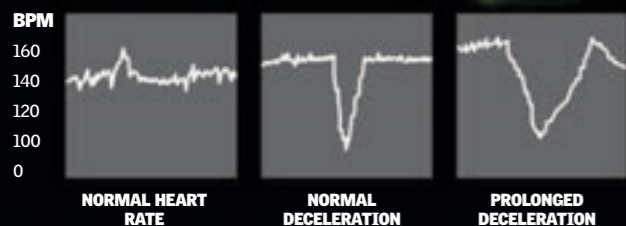
Pelvic exit 4 inches (10 cm)

### 4 Exit to the outside

Once the head passes through the birth canal, the baby passes its shoulders, one at a time. The rest of the body comes out without difficulty. Finally the umbilical cord is cut.

## Fetal Monitoring

During labor, the fetus's heart rate, between 120 and 160 beats per minute, is monitored. The rate decreases with each contraction and then returns to normal. If this does not happen, it could be problematic.



### 2 First obstacle

The pelvis is the first obstacle that the fetus must face. To overcome it, the fetus adjusts its head according to the largest diameter, the oblique one, which is normally 4.3 inches (11 cm).



### 3 Birth Canal

The fetus finds that the birth canal has stretched. It rests its head on the pelvis and pushes against it. It pushes on the coccyx and is able to get its head out.

**0.4 inch (1 cm) per hour**

is the rate of cervix dilation for first-time mothers. The rate increases with subsequent births.



# After Childbirth

Once the baby is born, many changes take place in the child and in the mother. After the umbilical cord is cut, the baby begins to breathe on its own, and its circulatory system is autonomous. For the mother—in pain, with breasts full of milk, and a crying baby—the situation can be stressful. At this new stage, the best thing for the brand-new mother is to rely on her intuition to understand what it is that this much-anticipated baby needs. At the same time, the presence of an involved father will favor the development of a deeper and more intense bond with the child. ●

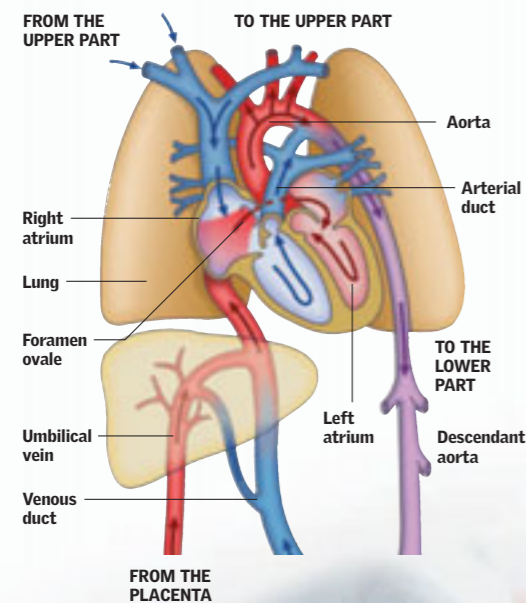
## Changes in Circulation

The fetus's circulatory system, which receives oxygen and nutrients from the placenta, is different from that of the baby after its umbilical cord is cut. The fetus's heart, which receives blood from the mother through the cord, has an oval opening called the foramen ovale. This hole, which allows

blood to flow from the left atrium to the right one, closes after birth. The arterial duct, a tube that takes blood from the lungs to the aorta, also closes. The same happens with the umbilical blood vessels. When these ducts close, those that remain in the newborn's circulatory system become ligaments.

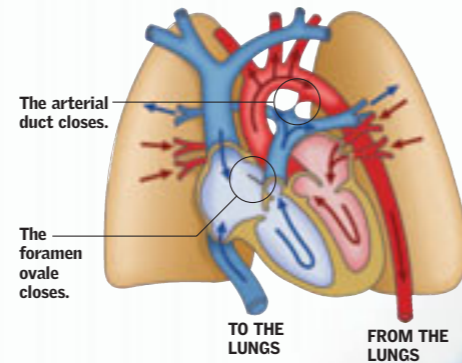
### BEFORE THE UMBILICAL CORD IS CUT

- 1 The oxygenated blood enters the right atrium through the umbilical cord.
- 2 Since the lungs are contracted, they exert pressure in the opposite direction to that of the blood and force it to change direction.
- 3 The blood reaches the aorta mostly through the foramen ovale and, to a lesser extent, through the arterial duct. Once in the aorta, the blood is distributed throughout the body. This brings oxygen and nourishes the fetus.



### AFTER THE UMBILICAL CORD IS CUT

- 4 Upon the cutting of the umbilical cord, the baby stops receiving blood from the mother.
- 5 The newborn takes its first breath and fills its lungs with air for the first time. The direction of blood flow reverses.
- 6 Blood is oxygenated in the lungs and reaches the aorta through the pulmonary veins. At the same time, the foramen ovale closes and a ligament forms in its place.



## Hormonal Changes

During pregnancy, the levels of prolactin, a hormone produced in the anterior lobe of the pituitary gland (hypophysis), increase. This hormone remains at high levels while the mother breast-feeds. Prolactin is the hormone that causes milk production in the mammary glands. Another hormone released after pregnancy is oxytocin. Oxytocin brings on a reflex that causes

milk to come out of the nipple. It is produced in the posterior lobe of the pituitary gland. The secretion of both prolactin and oxytocin, vital hormones in breast-feeding, is stimulated when the baby sucks on the breast. Milk production increases as the baby grows and requires more milk for feeding.

## 7.9 gallons (30 liters)

is the average amount of milk produced by the mother in a month. The breast milk contains lactose (a type of sugar), proteins, and fats.

## Sexual Disorders

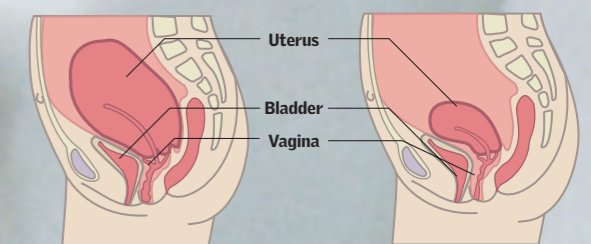
The months after childbirth are usually traumatic for the sex life of the couple. In the beginning, sexual desire may be diminished due to the place assumed by the baby as the new center of attention. Moreover, in the first three months after childbirth, there may be vaginal dryness

stemming from a lack of lubrication caused by hormonal changes. It is also normal for intercourse to be painful because of the scarring of wounds caused by the delivery. It is all a matter of time—time to readjust to the new situation, to give oneself permission to experience new sensations.

## Everything Returns to Normal

During the postpartum period, the genital tract gradually returns to its state prior to the pregnancy. The uterus expels the remaining placental tissue in the

form of a liquid called lochia, which is red at first, but later takes on a whitish color. The vagina gradually returns to its original size.



- 1 After birth, within a month, the placental site has healed, but the uterus is still distended.
- 2 Until the uterus returns to its original size, contractions continue and can be painful.



# An Answer to the Resemblance

The baby has the mother's eyes but the father's hair color; the nose is like the grandfather's, and the mouth is like the grandmother's. These and other possible combinations are caused by genetic inheritance. The genes transmitted by the father combine with genes in the mother's egg, forming a single cell that will turn into a new human being. Through cell division during the baby's growth inside the uterus, the genes will expand, and the dominant ones will impose themselves over the recessive ones. In the case of twins, the physical resemblance results because they share the same genes. ●

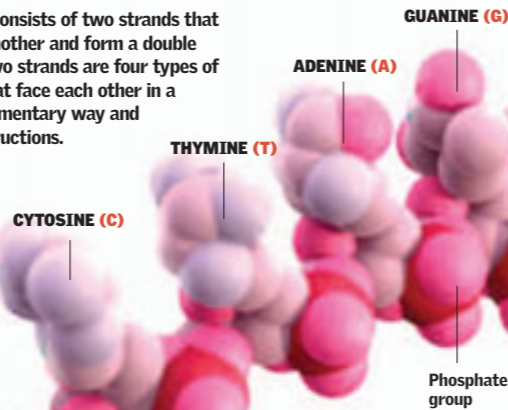
MODEL DNA CHAIN

## The Genes

Each human cell (except for a few, such as red blood cells) has a nucleus. Inside the nucleus are the genes, contained in the chromosomes. Each cell nucleus has 46 chromosomes with the person's genetic information. Each gene has information with a code that determines a function in the body, such as hair color. Each living being has its own genetic identification, and the genes ensure that the individual grows and functions in a certain way.

### DNA STRUCTURE

The DNA molecule consists of two strands that twist around one another and form a double helix. Joining the two strands are four types of nucleotide bases that face each other in a specific and complementary way and provide a cell's instructions.



## 2 The Bases

face each other when the strands are lined up opposite one another. Adenine is always matched to thymine and guanine to cytosine.

### INSTRUCTIONS

The sequence of the nucleotide bases (adenine, cytosine, guanine, and thymine) determines the message that will be transmitted.

COMPLEMENTARY DNA CHAIN

## 1 DNA Strands

Every strand is made of a sequence of nucleotides. Each nucleotide is composed of a phosphate group, a sugar, and a nitrogenated base.

25,000

GENES ARE CONTAINED IN THE NUCLEUS OF EACH CELL IN THE HUMAN BODY.

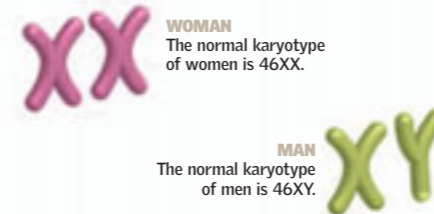
## Identical and Fraternal Twins

It is estimated that one in 70 childbirths produces either identical (monozygotic) or fraternal (dizygotic) twins. Identical twins have the same genes and therefore are alike and of the same sex. They come from one fertilized egg. In some cases, twins share the placenta. Fraternal twins, on the other hand, are the same in age but not in genetic material. They come from two eggs that are released at the same time and are fertilized by different sperm.



## Chromosomes

are like long, thin threads, rolled into an X-shape, that contain DNA. The genetic information is stored inside them. Their characteristic shape helps in the transmission of genes to the next generation. Each cell contains a total of 46 chromosomes arranged in 23 pairs. To form gametes, the cell divides twice, resulting in cells with 23 chromosomes instead of 46. When the sex cells join, the cell they create is a zygote, which has the 46 chromosomes necessary to form a human being.



WOMAN  
The normal karyotype of women is 46XX.

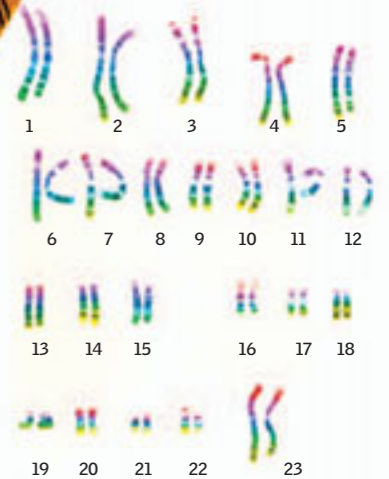
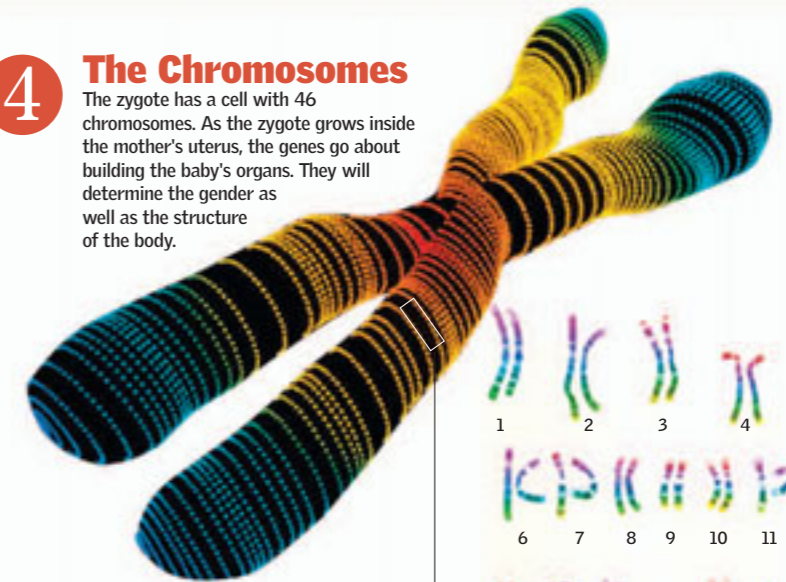
MAN  
The normal karyotype of men is 46XY.

## 3 Double helix

The most common structure of DNA, a double helix, is formed from the union of two chains.

## 4 The Chromosomes

The zygote has a cell with 46 chromosomes. As the zygote grows inside the mother's uterus, the genes go about building the baby's organs. They will determine the gender as well as the structure of the body.



### 23 PAIRS OF CHROMOSOMES

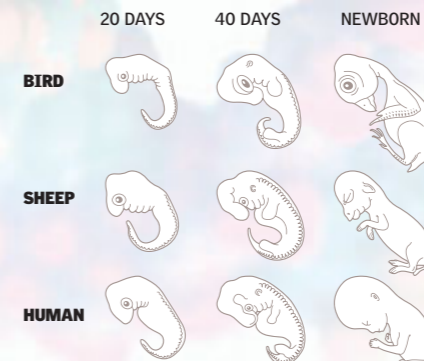
are classified according to their size. The largest pair is called chromosome 1, the next one chromosome 2, and so on until the last one, which is either XX or XY. In this way, the genes in each chromosome can be located and studied.

DNA STRUCTURE

## Resemblances

If one observes different vertebrate embryos, the similarities between them are notable. These resemblances reveal that they are all descended from a common ancestor. The development of the body parts is marked by very similar genes. Morphologically all embryos possess a segmented tail, a heart with two cavities, and branchial (gill) clefts. The greatest difference appears in fish, which retain the branchial clefts. In other groups (amphibians, birds, mammals), one of the clefts transforms into the ear canal and the other into the eustachian tube. In spite of the changes in outer appearance, the observable patterns of internal organization tend to be preserved.

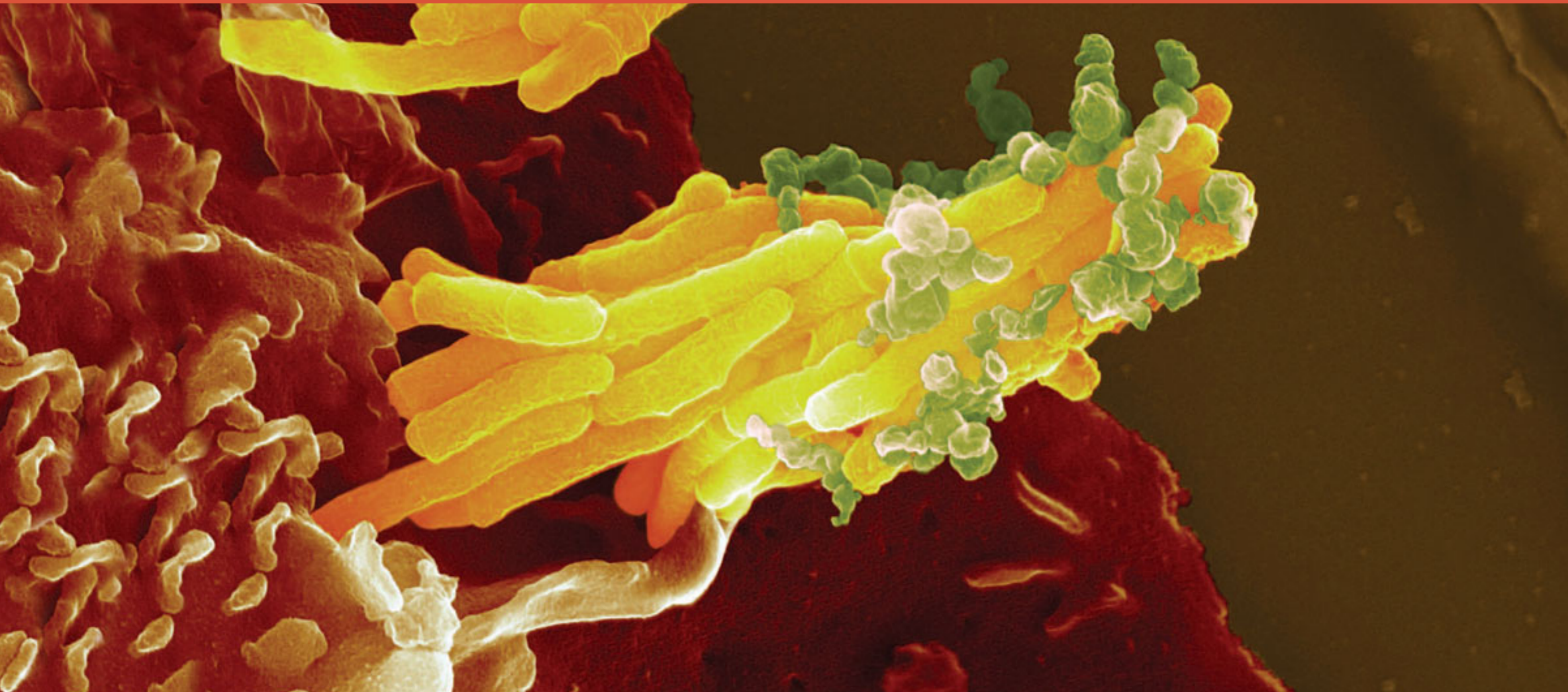
### GENETIC DEVELOPMENT



## Made-to-Order Babies

Genetics is also used to find out which genes a baby will have. If the mother and the father have a defective gene, they could opt for preimplantation genetic diagnosis to make sure that the baby will be born healthy. This controversial method can determine if the embryo will be a boy or a girl, and it also prevents hereditary health risks. In preimplantation, the mother takes a drug to produce eggs, which are then fertilized with a sperm from the father. Later a DNA test is done on the embryos' cells, and then two or three healthy embryos are selected and implanted in the mother's uterus.





**W**hat is a bacterium? What is a virus? How do antibiotics act on them? What function do the red and white blood cells

perform when they are in action? Did you know that white blood cells are bigger than the red ones and that, by changing shape, they can pass through capillary walls to reach different tissues

and hunt down foreign organisms that are in the way, such as bacteria or cancer cells? In this chapter, we will also show you how platelets, another defense system of the body, prevent

hemorrhages, or bleeding. While learning about our internal functions, you will be surprised and captivated by illustrations and much more. ●



# Bacteria

Bacteria are the smallest, most abundant, and hardiest life-forms on Earth. They are so microscopic that 0.06 cubic inch (1 ml) of saliva may contain up to 40 million bacterial cells. They exist and live everywhere, from our skin to the smallest cracks in rocks. Most are benign and even vital to the survival of other living beings, but some are pathogenic and can cause diseases, some of them deadly. Almost all nourish themselves by absorbing substances from their surroundings, but some make use of the energy of the sun, and others use the chemical energy in volcanic emissions. All are made up of one cell and usually reproduce by dividing in two. ●

## What Are Bacteria?

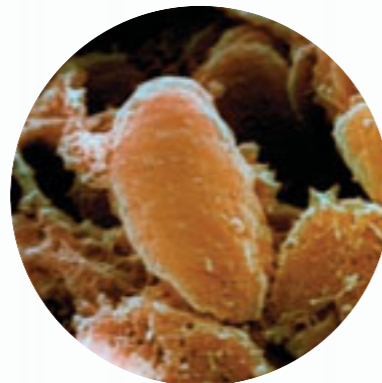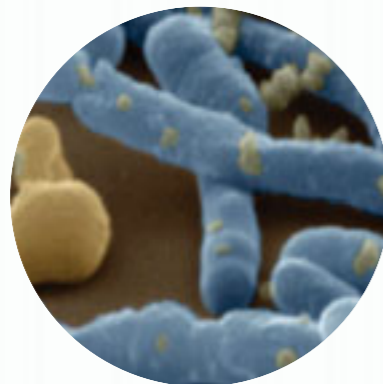
Bacteria have the capacity to survive in extremely hostile environments, even at temperatures of 480° F (250° C). For this reason, they are the most ancient living organisms on the planet. In a common habitat, such as the human mouth, there can be as many as 25 different species of bacilli among the 40 million bacterial cells in just 0.06 cubic inch (1 ml) of saliva. And,

if there are so many in just a small amount of saliva, imagine how many there might be in the entire world—millions and millions of species. However, only 1 percent of bacteria produce diseases. Likewise, 70 percent of antibiotics are produced through bacterial fermentation.

## CLASSIFICATION OF BACTERIA

Some 10,000 bacteria species have been identified, and it is estimated that there are still many left to be discovered. They are classified both by their shape and through chemical tests to help identify specific species.

- A COCCUS**  
Spherical cocci can live isolated, and others can group into pairs, chains, or branches.
- B BACILLUS**  
Many bacteria have this rod-shaped form.
- C VIBRIO**  
These bacteria have the shape of a comma or boomerang.
- D SPIRILLA**  
This class of bacteria has a corkscrew shape.



## Benign

Almost all bacteria are benign and even healthy for living beings. *Lactobacillus acidophilus*, for example, is a bacterium that transforms lactose into lactic acid to produce yogurt, and it is also present in the human body in the vagina and in the intestinal tract. The bacterium *Rhizobium*, on the other hand, allows roots of legume plants to absorb nitrogen from the soil.

## Harmful

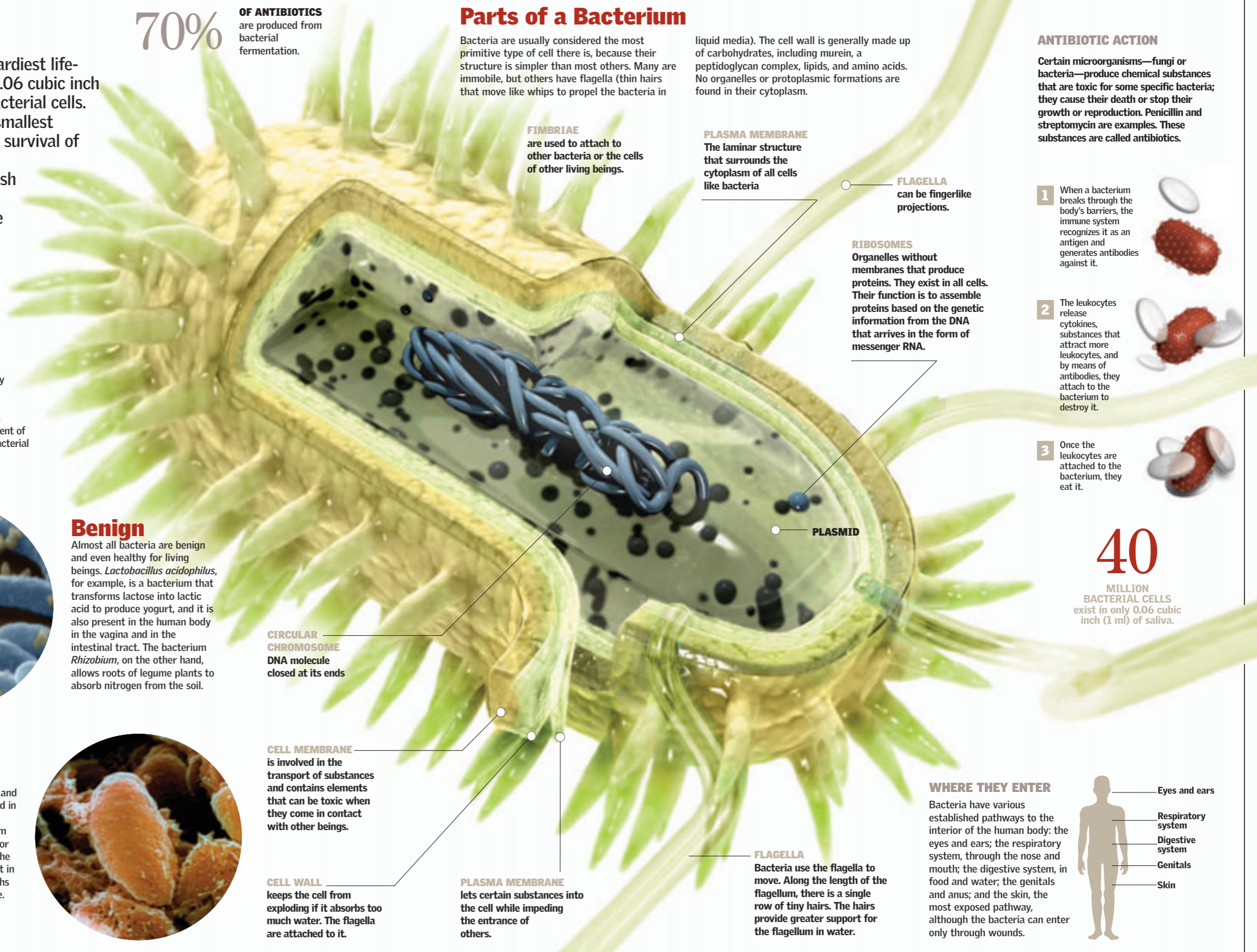
Harmful bacteria are pathogenic and are present in all living beings and in agricultural products. They can transfer from food to people, from people to food, or among people or foodstuffs. In the 14th century, the *Yersinia pestis* bacterium, present in rats and fleas, caused many deaths in what was known as the plague.

**70%** OF ANTIBIOTICS are produced from bacterial fermentation.

## Parts of a Bacterium

Bacteria are usually considered the most primitive type of cell there is, because their structure is simpler than most others. Many are immobile, but others have flagella (thin hairs that move like whips to propel the bacteria in

liquid media). The cell wall is generally made up of carbohydrates, including murein, a peptidoglycan complex, lipids, and amino acids. No organelles or protoplasmic formations are found in their cytoplasm.



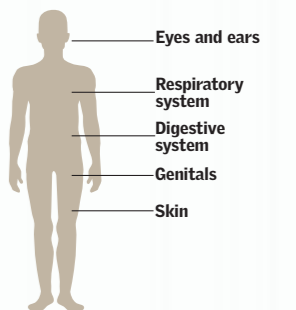
**ANTIBIOTIC ACTION**  
Certain microorganisms—fungi or bacteria—produce chemical substances that are toxic for some specific bacteria; they cause their death or stop their growth or reproduction. Penicillin and streptomycin are examples. These substances are called antibiotics.

- 1** When a bacterium breaks through the body's barriers, the immune system recognizes it as an antigen and generates antibodies against it.
- 2** The leukocytes release cytokines, substances that attract more leukocytes, and by means of antibodies, they attach to the bacterium to destroy it.
- 3** Once the leukocytes are attached to the bacterium, they eat it.

**40** MILLION BACTERIAL CELLS exist in only 0.06 cubic inch (1 ml) of saliva.

## WHERE THEY ENTER

Bacteria have various established pathways to the interior of the human body: the eyes and ears; the respiratory system, through the nose and mouth; the digestive system, in food and water; the genitals and anus; and the skin, the most exposed pathway, although the bacteria can enter only through wounds.





# Minuscule Life

**V**iruses are not, in a strict sense, life-forms. They cannot live independently and are at the limit of inert material. They lack systems to obtain and store energy and to synthesize protein. For this reason, they are symbiotes committed to the cells, both prokaryotes and eukaryotes, on which they depend for their reproduction. Their structure might be nothing more than a simple envelope of protein that surrounds a package of nucleic acid (DNA or just RNA). In the case of bacteriophages, they invade bacteria and inoculate their own DNA into them. New viruses are produced from the copy of the genetic material. ●

## Anatomy of a Bacteriophage

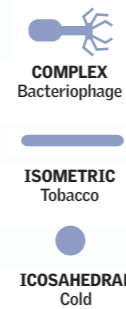
This very small virus attacks bacteria exclusively. It has a capsid that contains the strand of DNA that is injected into the bacteria through a hollow tail body that has six fibers; these fibers allow it to attach to the cell wall.

### "Filterable Viruses"

In 1898, while the origin of certain plant diseases was being studied, Dutch microbiologist Martinus Beijerinck discovered that some infections persisted even when filters for all known bacteria were used. He deduced that the responsible agents must be much smaller than bacteria. He called them "filterable virus," a word from the Latin related to "poison." They are so small that they cannot be seen with an optical microscope. Today we know that their structure does not even support the organelles of a cell: they are just chemical packages inserted in a protein coat.

#### ORNATE SHAPES

The shape of a virus has a close relationship to the chemical composition of its envelope. The proteins that compose it are expressed in the form of crystals, which take on geometric shapes, primarily simple and complex polyhedrons.



### Invaded Bacterium

When they reach the cell wall of a bacterium, bacteriophage viruses suddenly abandon their inert appearance: they attach to the surface of the live cell and inject their DNA, which allows the virus to make copies of itself. The life of the

bacteria is altered by the takeover of the viral DNA, which gives instructions to manufacture different parts of new viruses. When the attacked cell dies, its remains are used by other nearby bacteria.

#### 1 Adrift

The virus does not have locomotion. As an inert object, it is transported by water and air. When it finds a live bacterium, it becomes activated and attaches itself to the cell wall by means of six fibers on its tail.

**30 minutes**

is how long the virus takes to destroy a bacterium at normal room temperature.

#### Attachment

Through its fibers, the virus adheres to the wall of the bacterium.

#### 2 The Attack

When the virus reaches the wall of a live cell, it releases an enzyme that begins to dissolve the wall. A small hole is thus opened in the wall of the bacterium, through which the virus directly injects its DNA.

#### 3 DNA Is Reproduced

The bacterium has already been invaded, and the viral DNA reprograms it. The normal activity in the bacterium stops, and it begins to build the separate parts that will form new viruses (mostly viral DNA).

**200**

copies of the virus come out of a cell attacked and destroyed by a bacteriophage.

#### 4

### Integral Production

The viral DNA that has been replicated provides instructions to the bacterium for the correct

and automatic formation of the different parts of the new viruses. Once they are produced separately, the only thing left is the final assembly and proliferation of the virus copies.

#### 5

### Assembly

New capsids, tail bodies, and fibers are joined to create new bacteriophages. Once they are formed, the new viruses must wait for the break down of the bacterial wall in order to be released and attack other bacteria.

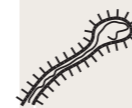#### 6

### The End of the Bacterium

The viral DNA causes the bacterium to produce a substance called lysozyme. This enzyme provokes the destruction and death of the bacterium because it digests the cell wall from the inside. When the bacterium disintegrates, the new viruses disperse. They are ready to attack again.

#### NOTORIOUS FAMILIES

**WITH RNA.** These virus families do not have DNA in their genetic material.



**FILOVIRUSES**  
One is the Ebola virus, which causes a type of hemorrhagic fever.



**RETROVIRUSES**  
The best known is HIV, which produces AIDS. The HTLV retrovirus can cause leukemia.



**CORONAVIRUSES**  
Cause diseases that range from the common cold to SARS and atypical pneumonia.



**FLAVIVIRUSES**  
Very numerous, they cause hepatitis, West Nile fever, encephalitis, and dengue.

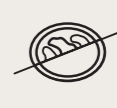**WITH DNA.** Further divided into simple-strand and double-strand viruses.



**HEPADNAVIRUSES**  
Only the hepatitis B and D viruses belong to this family.



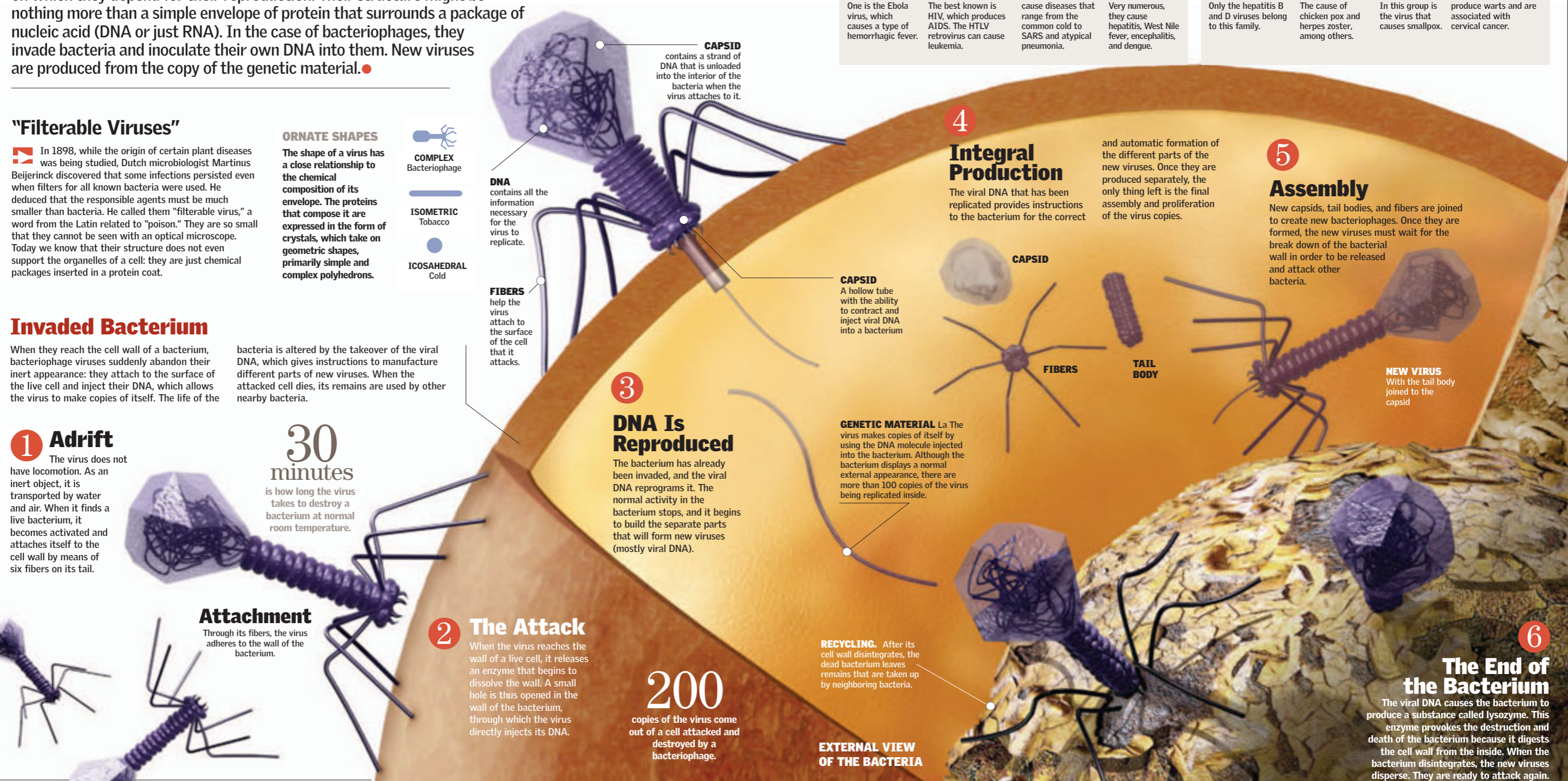
**HERPESVIRUSES**  
The cause of chicken pox and herpes zoster, among others.



**POXVIRUSES**  
In this group is the virus that causes smallpox.



**PAPILLOMAVIRUSES**  
Produce warts and are associated with cervical cancer.





# Fungi

Fungi are living beings from the Fungi kingdom that are similar to plants, but they do not have the ability to synthesize their own food; this forces many of them to be parasites of other vegetables or animals and, of course, humans. Multicellular fungi tend to be formed by filaments and spores that reproduce very easily; others are unicellular. Infections by fungi (mycosis) tend to be superficial, such as ringworm or athlete's foot, caused by dermatophytes, but they can be systemic if, for example, they colonize the blood. ●

0.00020 inch  
(5 microns)

SPORES LARGER THAN THIS SIZE TEND TO CAUSE SURFACE REACTIONS BECAUSE OF THEIR DIFFICULTY IN PENETRATING THE SKIN. THAT IS WHY THE SPECIES IN *ALTERNARIA*, *CLADOSPORIUM*, *ASPERGILLUS*, AND *PENICILLIUM* COMMONLY PRODUCE ALLERGIES.

## Parasitic Cells

▶ Not all fungi cause disease. Many, which are essentially saprophytes, have a beneficial purpose. They grow on organic matter that they decompose through exoenzymes, and then they absorb and recycle it. By not being able to carry out photosynthesis, their ability to obtain energy and biosynthesis depends on the organic material they absorb.

## Penicillium

This microscopic fungus, very common in the domestic environment, is used in the production of blue cheeses and is the base for the first antibiotic created by man: penicillin. Its antibiotic properties were discovered by accident.

### SPORANGIA

The spherical sacs that contain the reproductive cells (spores). Because these are small and asexual, they are called conidia. As happens with all multicellular fungi of the deuteromycota type, the sporangia mature and break, releasing the conidia.

0.7 ounce (20 g)

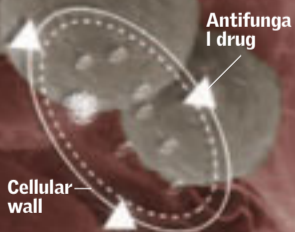The amount of penicillin that can be obtained for each quart (about 1 l) of culture of the *Penicillium chrysogenum* fungus with current biotechnological methods. Penicillin alters the cell wall of bacteria and destroys them.

## Getting Rid of Fungi

▶ Fungal infections respond to a variety of drug treatments. More superficial infections, such as oral candidiasis, respond to the local application of antimycotic substances. Deeper systemic infections, however, particularly in persons with some sort of immune system deficiency, can be more difficult to cure. Sometimes they require prolonged administration (as long as several months) of drugs that are taken orally and act systemically (throughout the entire body). These drugs frequently have a level of toxicity that must be taken into account when evaluating the advantages and disadvantages of each treatment.

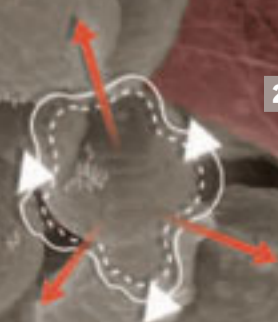### 1 THE CELL

Mycotic cells, which on their own are harder to treat than bacteria, look a lot like human cells. The drugs used must be sufficiently selective to attack only these cells and not human cells.



### 2 THE DRUG

The main action of antimycotic drugs is to damage the envelope of the mycotic cell, which makes up 90 percent of its mass. This way, the cytoplasm is left without support and dissolves in the bloodstream.



### ALMOST WITHOUT DIFFERENCE

The cells that make up the different parts of a fungus are not very different from each other. Each has a polysaccharide wall that does not alter its permeability.

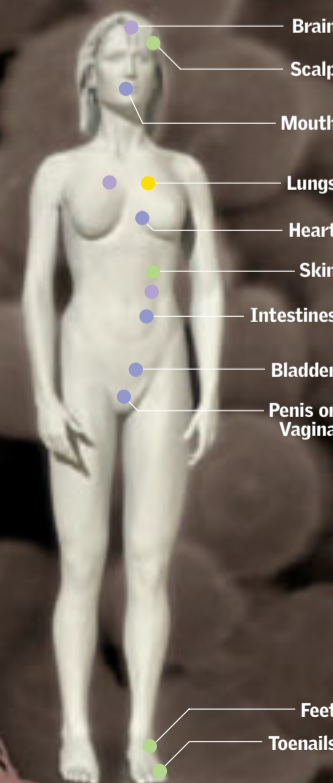
### HYPHA

The hyphae are the filaments that make up the body of a multicellular fungus. Generally they form a networked structure (mycelium). The portion of the hypha that rises to branch off and form conidiophores is called the stalk. The fungus is the ensemble of all the hyphae and can have many stalks.

## WHERE THEY COMMONLY INVADE

Fungi are very simple organisms. In human tissues, some species generate superficial wounds (in the toenails or

fingernails, skin, or mucous membranes) or even fatal infections in some internal organs.



**CRYPTOCOCCOSIS**  
This infection can cause certain forms of meningitis (inflammation of the meninges, the membranes that cover the brain) and pneumonias (lung infections). It can also affect the skin and the bones.

**ASPERGILLOSIS**  
*Aspergillus fumigatus* is a fungus that tends to spread through air-conditioning systems. It attacks the lungs of persons with a suppressed immune system.

**DERMATOPHYTOSIS**  
This fungal infection is the most common superficial mycotic infection and can affect toenails or fingernails (onychomycosis), the feet (athlete's foot), and the scalp (ringworm). Ringworm can cause hair loss.

**CANDIDIASIS**  
*Candida* species prefer mucous membranes, so they attack such areas as the mouth or vagina. Alteration of the natural flora of the vagina can lead to this type of infection, and more than half of all women have suffered from such an infection at some time.



# Bad Company

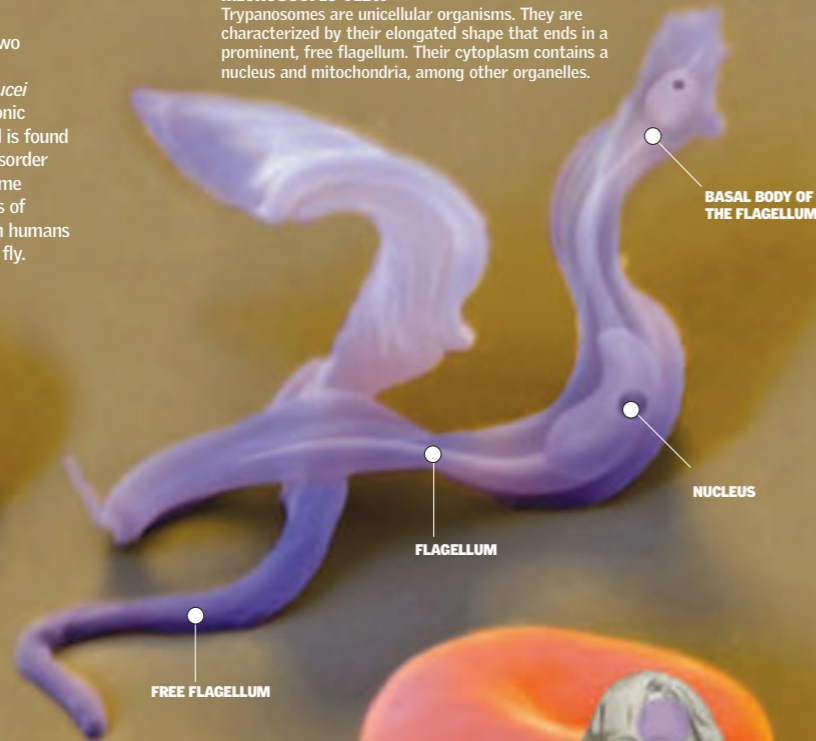
Microorganisms can be habitual companions of the human body. There are bacteria that live in the digestive tract and interact in a positive way with humans because they exchange nutrients. However, there is a group of parasitic protists that obtain benefits from the relationship at the expense of the host's health. They are called endoparasites, and they can produce chronic diseases that, in some cases, can be deadly. ●

## Sleeping Sickness

This disease in humans is caused by two subspecies of protists of the genus *Trypanosoma*: *T. brucei gambiense* and *T. brucei rhodiense*. *T. brucei gambiense* causes a chronic disease that develops over several years and is found mostly in central and western Africa. The disorder caused by the *T. brucei rhodiense* has the same syndrome but develops in weeks in countries of southern and eastern Africa. The infection in humans is caused by the bite of an insect, the tsetse fly.

### MICROSCOPIC VIEW

Trypanosomes are unicellular organisms. They are characterized by their elongated shape that ends in a prominent, free flagellum. Their cytoplasm contains a nucleus and mitochondria, among other organelles.



### TRYPANOSOMA BRUCEI

Location	Africa
Size	0.001 inch (30 microns)
Disease	Sleeping Sickness

### DISTRIBUTION

The tsetse fly, which transmits the trypanosome, is found in Africa between 15° N and 20° S. More than 60 million people are potential victims of sleeping sickness in this region.

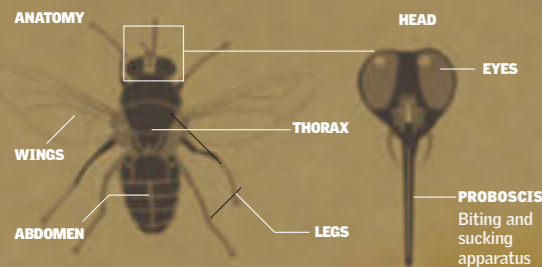
### THE DISEASE, STEP BY STEP

- FIRST SYMPTOMS**  
The small wounds in the skin allow the parasite to enter into the blood.
- SLEEPINESS**  
Through blood circulation, the trypanosome lodges in different organs of the human body.
- SERIOUS ILLNESS**  
The endoparasite reproduces in bodily fluids, such as blood, lymph, and cerebrospinal liquid.

## The Tsetse Fly

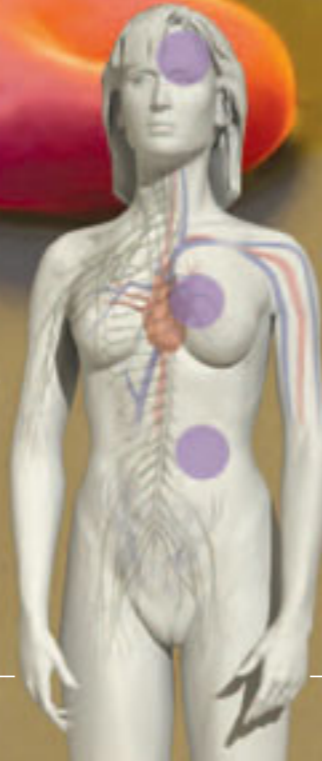Tsetse flies are representative of the genus *Glossina*. These dipterous insects are grouped into 23 species of African flies that feed on human blood; in other words, they are

hematophagous. The fly's bite and saliva deposited on the human skin cause victims to scratch themselves. This opens the way for the parasites present in the fly's saliva to enter the blood.



## Epidemic

Sleeping sickness is limited to the African continent. It is an epidemic that affects more than 36 countries. In 1999, the World Health Organization (WHO) confirmed 40,000 cases of the sickness but estimated between 300,000 and 500,000 persons were infected with the parasite. In 2005, following increased surveillance efforts, the number of actual cases was estimated between 50,000 and 70,000.



0.001 INCH (0.03 MM)

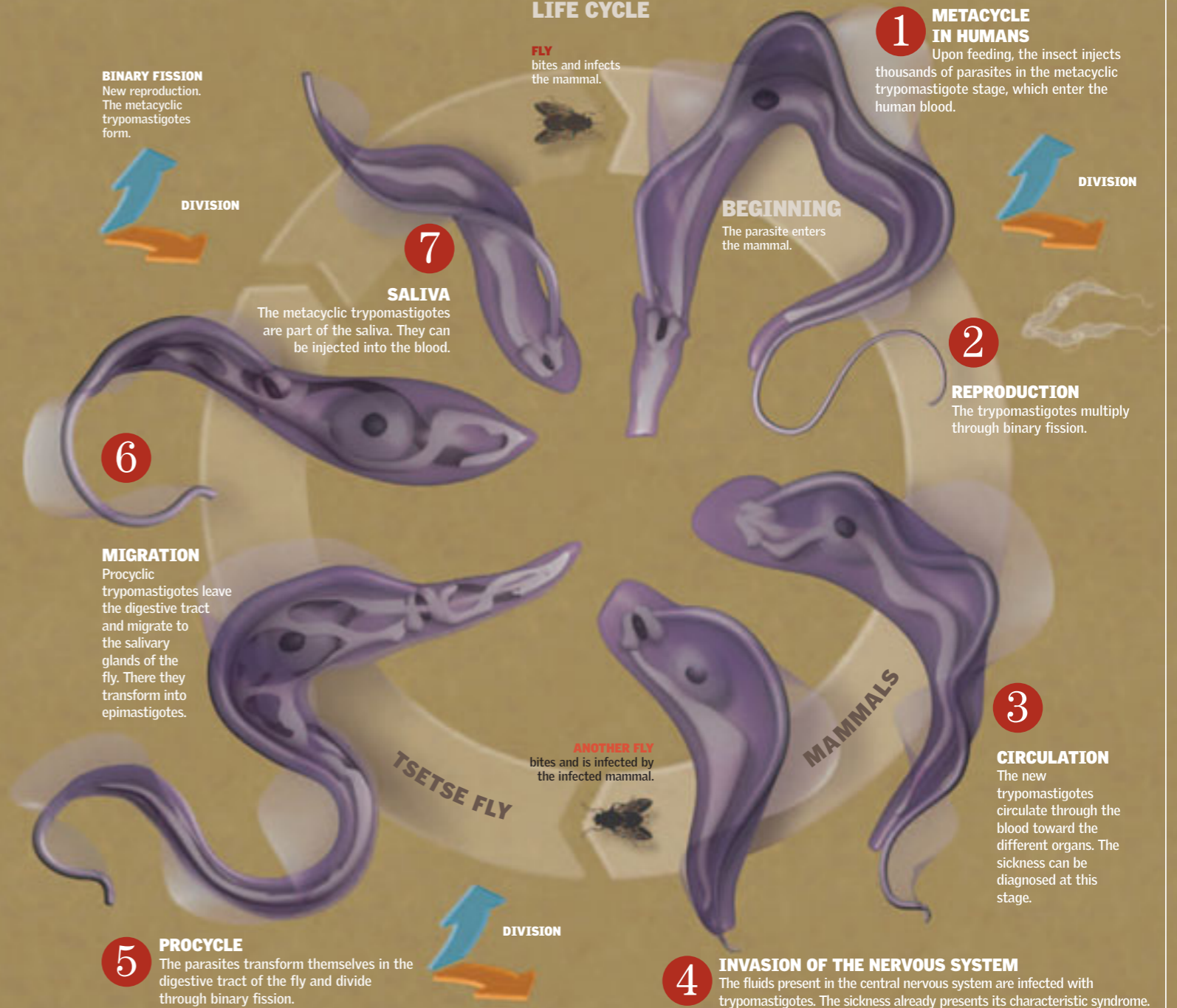
**BLOOD**  
The first tissue to be invaded by the protozoan

## Deadly Nightmare

*Trypanosoma brucei gambiense*, the tsetse fly, and the human body are the three players in this disease. The fly sucks human blood, which already contains the parasites. The parasites undergo a series of transformations inside the body of the fly and finally lodge themselves in its salivary glands. When the fly with parasites in its saliva searches for food and bites a person, it

transfers the trypanosomes. The first phase of the sickness, similar to other diseases, includes itching, fever, headaches, and joint pain. Later the endoparasite crosses the hematoencephalic barrier and attacks the central nervous system. There it disrupts vital neurological processes—including the waking and sleeping cycle—which causes drowsiness and even death.

### LIFE CYCLE



**1 METACYCLE IN HUMANS**  
Upon feeding, the insect injects thousands of parasites in the metacyclic trypomastigote stage, which enter the human blood.

**2 REPRODUCTION**  
The trypomastigotes multiply through binary fission.

**3 CIRCULATION**  
The new trypomastigotes circulate through the blood toward the different organs. The sickness can be diagnosed at this stage.

**4 INVASION OF THE NERVOUS SYSTEM**  
The fluids present in the central nervous system are infected with trypomastigotes. The sickness already presents its characteristic syndrome.

**BINARY FISSION**  
New reproduction. The metacyclic trypomastigotes form.

**DIVISION**

**7 SALIVA**  
The metacyclic trypomastigotes are part of the saliva. They can be injected into the blood.

**6**

**MIGRATION**  
Procyclic trypomastigotes leave the digestive tract and migrate to the salivary glands of the fly. There they transform into epimastigotes.

**DIVISION**

**5 PROCYCLE**  
The parasites transform themselves in the digestive tract of the fly and divide through binary fission.

**FLY BITES AND INFECTS THE MAMMAL.**

**BEGINNING**  
The parasite enters the mammal.

**DIVISION**

**MAMMALS**

**TSETSE FLY**

**ANOTHER FLY BITES AND IS INFECTED BY THE INFECTED MAMMAL.**



# Life and Protection

**W**hite and red blood cells are the main cellular components of blood, and they play important roles in the body. The red blood cells transport oxygen from the lungs to the tissues, and they carry carbon dioxide on their return. They live for about 120 days and then die in the spleen. The white blood cells have a smaller presence than the red ones, but they are in charge of protecting against infections, and they roam the body looking for viruses and bacteria. ●

## White Blood Cells

▶ These cells occur mainly in the blood and circulate through it to fight infections or foreign bodies, but they can occasionally attack the normal tissues of their own body. They are part of the human body's immune defense. For each white blood cell in the blood, there are 700 red blood cells. White blood cells, however, are larger. Unlike the red ones, they have a nucleus. By changing shape, they can go through capillary walls to reach tissues and hunt their prey.

### ANATOMY OF A WHITE BLOOD CELL

In a drop of blood, there can be about 375,000 white blood cells with different shapes and functions. They are divided into two groups: the granulocytes, which have granules in the cytoplasm, and the agranulocytes, which do not and which include the lymphocytes and the monocytes. Monocytes engulf the invader, ingest it, and then digest it.



- 1** White blood cells can come out of blood vessels and move between the tissues. When they detect an intruder, they approach to hunt it down.
- 2** The cell stretches, forming a pseudopodium, or false leg, which pushes against the medium, and it then propels the rest of the cell to advance toward the bacterium.
- 3** It traps the bacterium and destroys it. During the fight against the infection, millions of white blood cells may die and appear as pus.

**PSEUDOPODIUM** serves as a locomotive device for certain protozoa and leukocytes.



## Hunter

The white blood cell detects the presence of organisms harmful to the body and traps them. The invaders are engulfed and destroyed.

## Red Blood Cells

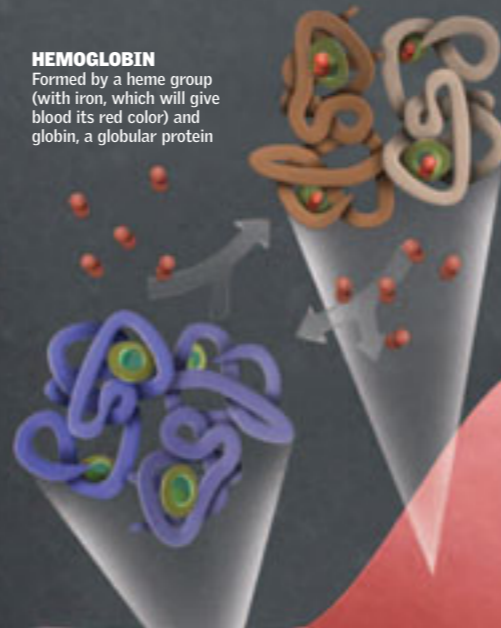
▶ The main carriers of oxygen to the cells and tissues of the body, red blood cells make up 99 percent of the cells in the blood. They have a biconcave shape so that they have a larger surface for oxygen exchange in the tissues. In addition, they have a flexible membrane that allows the red blood cells to go through the smallest blood vessels, obtain oxygen from the lungs, and discharge it in the tissues. The cells do not have a nucleus.

### ANATOMY OF A RED BLOOD CELL

The cell has the shape of a flattened disk that is depressed in the center. This shape gives it a large surface in relation to its volume. In this way, the hemoglobin molecules that transport oxygen are never far from the cell membrane, which helps them pick up and deposit oxygen.

### HEMOGLOBIN

Formed by a heme group (with iron, which will give blood its red color) and globin, a globular protein




### OXYHEMOGLOBIN

Formed when the hemoglobin takes up oxygen and gives blood its colorsangre.

## Platelets

▶ These small cells are key to stopping any bleeding. They intervene in blood clotting and form a platelet plug. If a blood vessel is cut and the endothelium is affected, the platelets modify their structure and join the injured tissue to form the plug.



**1** Platelets accumulate and form a plug in the wound.

**2** The red blood cells close in. Together with a protein network they form the blood clot. The white blood cells fight the infection.

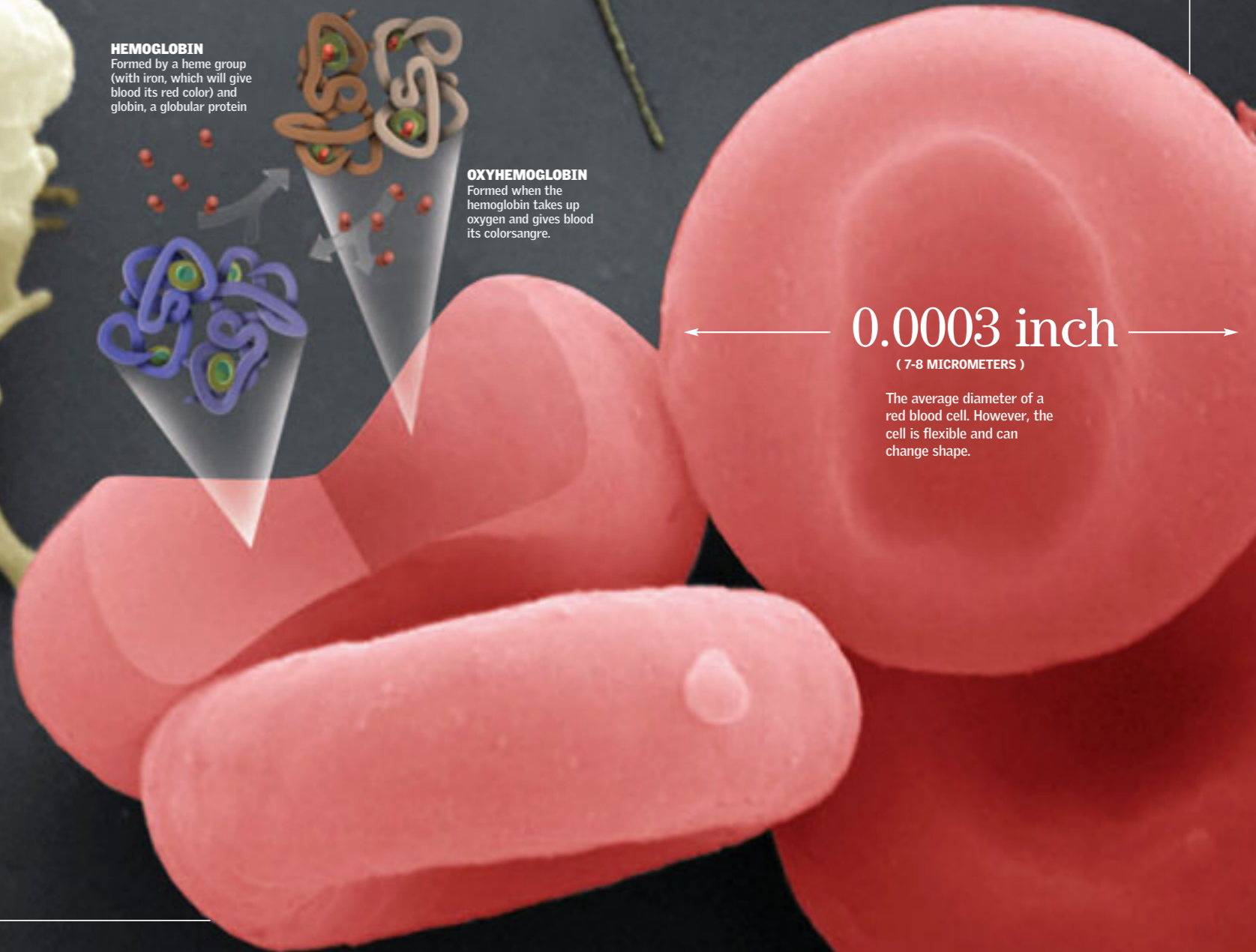
**200,000**

red blood cells are produced daily by a human being.

**0.0003 inch**

( 7-8 MICROMETERS )

The average diameter of a red blood cell. However, the cell is flexible and can change shape.





# The Most Common Diseases

## POLLEN

An enlarged photo of the pollen of Timothy grass (*Phleum pratense*), one of the most allergenic and best-known grasses because it causes hay fever

## CANCER 60-61

NEUROLOGICAL PROBLEMS 62-63

BONE DEGENERATION 64-65

CIRCULATORY CONDITIONS 66-67

RESPIRATORY INFECTIONS 68-69

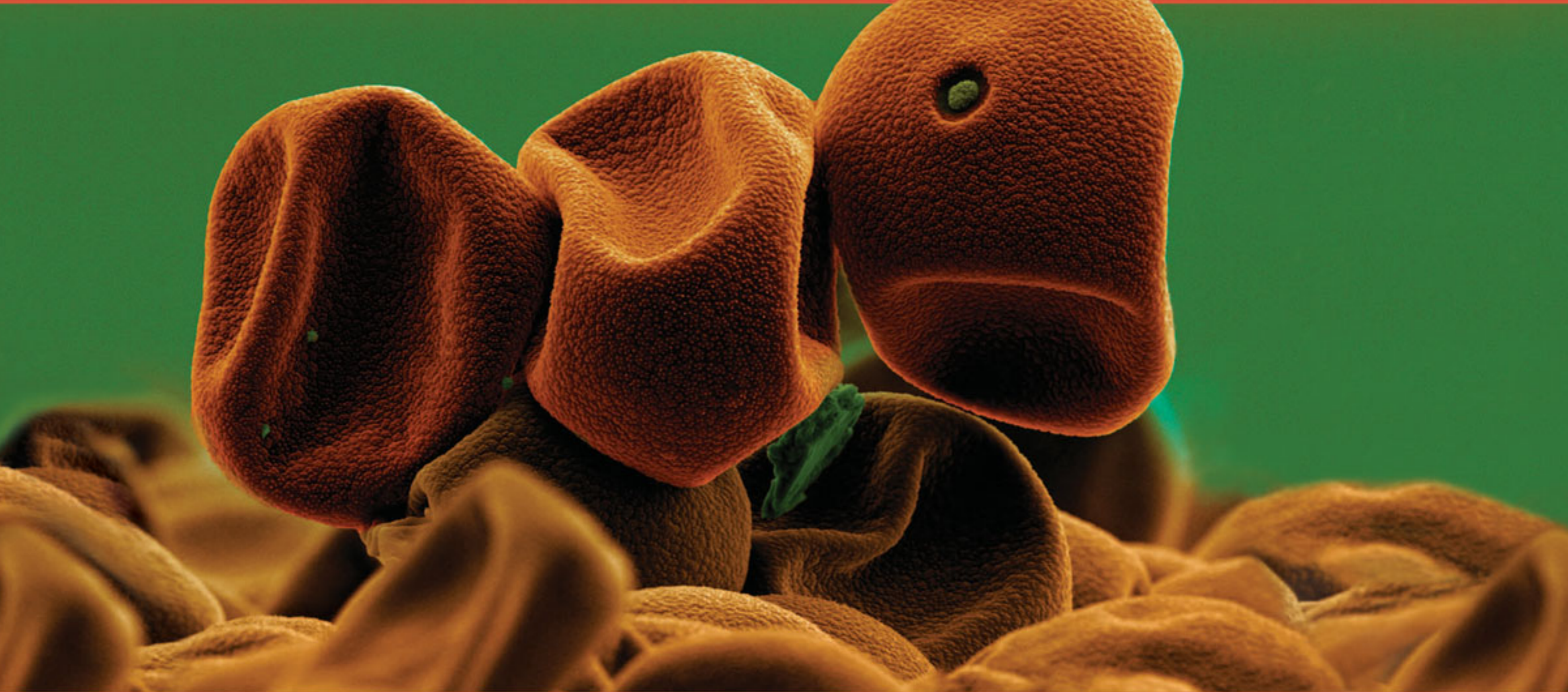
## EXCESSES IN THE DIGESTIVE

SYSTEM 70-71

INTESTINES AND COLON 72-73

ALLERGIES: A MODERN EVIL 74-75

AIDS 76-77



Allergies are the body's response to a foreign substance, called an allergen. The most common are pollen, mites, animal dander, and nut

proteins. In this chapter, we tell you which are the most common diseases that humankind suffers from today—some of them worse than others—their symptoms, and how they can be avoided.

The information, written in an accessible and understandable way, is accompanied by pictures and full-color images that reveal, for example, how metastasis happens and how the AIDS virus attacks.

Turn the page and you will discover unknown and astounding aspects of human disease. ●



# Cancer

The word "cancer" describes a group of more than 200 diseases caused by uncontrolled cell division. The genes of normal cells change so that regular cell death (apoptosis) does not take place, and the tissues grow much larger than normal. Some factors, such as tobacco use and excessive exposure to different types of radiation, can notably increase the chances of developing cancer. In other cases, the genes that alter the normal functions of cells can be inherited. ●

## How It Behaves

In general, cancer consists of the abnormal growth of cells. When the cells of a tissue undergo disorderly and accelerated cell division, they can invade other, healthy tissues in the body and often destroy them. Instead of undergoing a controlled and programmed cell death (apoptosis), cancer cells continue proliferating. They can form a lump or bulge in an organ, called a tumor. Tumors are called malignant if they are formed by cancer cells; otherwise they are called benign.

## Phases of Cancer

Before the definitive formation of cancer, there are two prior noncancerous stages: hyperplasia and dysplasia. The cell volume increases as the cells

undergo uncontrolled cell division. The proliferation can be detected through studies done under a microscope (biopsies).



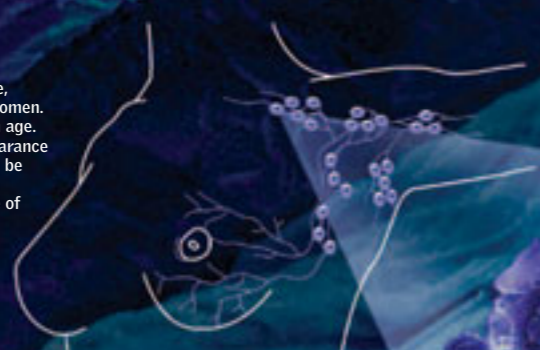**1 HYPERPLASIA**  
Although the cell structure remains normal, the tissue increases in size. Hyperplasia is reversible.

**2 DYSPLASIA**  
The tissue loses its normal appearance. Like hyperplasia, this stage can be detected with microscopic tests.

**3 CÁNCER**  
The cells grow uncontrollably and settle in one place. If they migrate and spread to other parts of the body, it is called metastasis.

## Breast Cancer

One in nine women develops this disease, which causes the most deaths among women. The risk of breast cancer increases with age. The most common symptom is the appearance of a small lump in the breast, which can be removed early with surgery. Other symptoms of cancer are the appearance of blood in the nipple and dimples in the breast skin. A mammogram is usually used to detect cancer. If the results of this study are positive, then treatment can begin early.



**CANCER CELLS**  
An agglomeration of cancer cells exhibits a protein nucleus (green) and the Golgi apparatus (pink).

## Common Symptoms

Although they are not always indicators of cancer, unusual bleeding, unexplained changes in weight, indigestion, and difficulty swallowing can be signs of tumors.

## Metastasis

Metastasis occurs when cancer cells pass from their original proliferation site to another that they were not in direct contact with (e.g., from the lungs to the brain). To achieve this migration, the cells build their own circulatory and feeding systems.

This allows them to penetrate the blood vessels (intravasation) and survive after extravasation. Only one in every 1,000 cells can survive the complex intermediate processes, but if metastasis does occur, it is almost irreversible and causes irreparable damage.

**CHAOTIC DIVISION**  
Through a genetic alteration of mitosis, the cells divide rapidly and indefinitely.

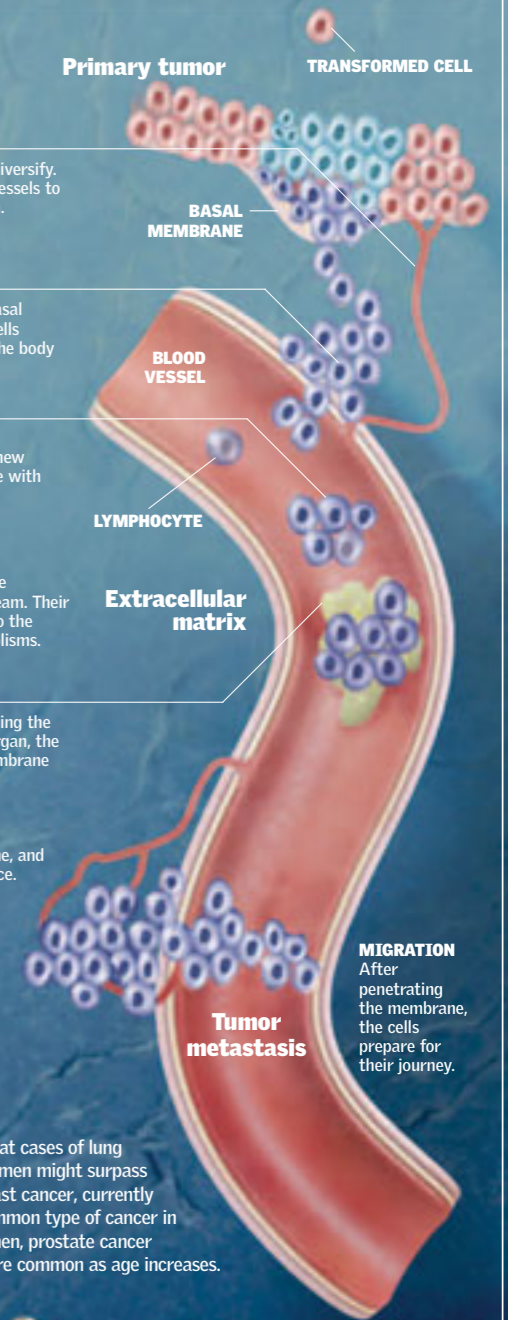
## Most Frequent Cancers

The most common cancer is lung cancer. Because of the large smoking population, the incidence of this cancer remains high. In recent years, the frequency of lung cancer in women has increased, and it

is possible that cases of lung cancer in women might surpass those of breast cancer, currently the most common type of cancer in women. In men, prostate cancer becomes more common as age increases.

## METASTASIS: STEP BY STEP

- 1 ANGIOGENESIS**  
The cancer cells divide and diversify. They form their own blood vessels to receive nutrients and oxygen.
- 2 INTRAVASATION**  
After passing through the basal membrane, the metastatic cells invade the blood vessels of the body and enter the bloodstream.
- 3 MIGRATION**  
The cells travel through the bloodstream and move to a new organ, different from the one with the original tumor.
- 4 INTERACTION**  
Cancer cells interact with the lymphocytes in the bloodstream. Their adhesion to platelets leads to the formation of tumorous embolisms.
- 5 INVASION**  
Before migrating and producing the secondary tumor in a new organ, the cells adhere to the basal membrane of the blood vessels.
- 6 EXTRAVASATION**  
The cells break the membrane, and the final migration takes place. They deposit themselves in metastatic form and begin angiogenesis to arrange for a capillary system that can provide them with nutrients. From there, they begin their growth.



- |          |         |
|----------|---------|
| LUNG     | BREAST  |
| PANCREAS | KIDNEY  |
| BLADDER  | COLON   |
| PROSTATE | OVARIES |
| RECTUM   | UTERUS  |
| BONE     | SKIN    |

**TUMORS**  
are produced when the cancer cells group and form agglomerates. Tumors can be benign (noncancerous) or malignant.



# Neurological Problems

**D**iseases that directly affect the brain cause structural, biochemical, or electrical changes in the brain or the spinal cord. When some of these diseases (Alzheimer's, Parkinson's, multiple sclerosis) affect the body, different symptoms appear, such as memory and reasoning disorders, tremors, rigidity of movements, paralysis, or loss of sensation. The challenge for science is to discover a way to reverse them. So far, the symptoms can only be reduced. ●

## Language

The language region of the brain also deteriorates. People who suffer from Alzheimer's tend to have trouble carrying out and expressing complex reasoning. Language disorders include lack of initiative in speaking and slowness to respond to the listener.

## Motor cortex

## Symptoms of Alzheimer's Disease

The first manifestations of the disease are linked to the loss of ability for verbal expression. There is also a gradual loss of memory as the disease progresses. In later phases, persons with Alzheimer's can become incapable of taking care of themselves because of damage to the motor cortex.

## Parkinson's Disease

➤ Parkinson's disease is a degenerative disease that attacks one in 200 persons, mostly over 60 years of age. This neurological disorder, which affects more men than women, progressively deteriorates the

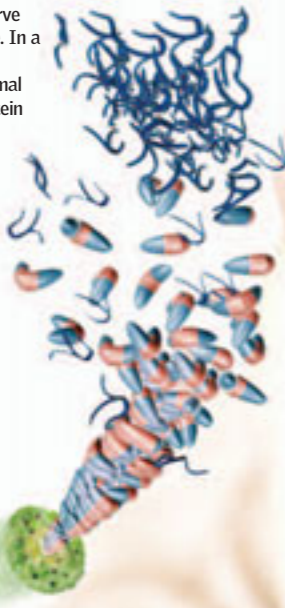central nervous system. The cause of the disease is unknown. Its appearance is related to the reduction of dopamine in certain brain structures. Among the main noticeable effects are tremors, muscle rigidity, and a slowing of body movements. Parkinson's also causes complications in speech, walking, and carrying out daily chores. Progressively tremors in the arms and legs occur, followed by facial inexpressiveness and repetition of movements.

## Memory

is progressively damaged. In the beginning, close relatives might not be recognized. Later, memory loss is complete.

## Alzheimer's Disease

➤ Alzheimer's disease, which has no cure, affects mostly persons over 60 years of age. Age and the aging process are determining factors. The cortex of the brain suffers atrophy, which is permanent because nerve cells cannot regenerate. In a brain affected by Alzheimer's, the abnormal deposit of amyloid protein forms neuritic (senile) plaques in the brain tissue. Tangles of degeneration (neurofibrillary tangles) form, which progressively damage the brain's functioning.



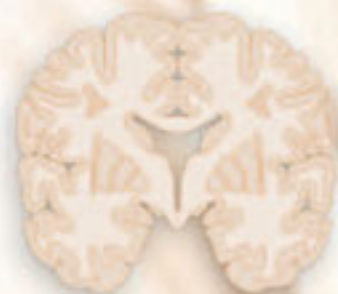**MICROTUBULES** help transmit nerve impulses throughout the body. Alzheimer's disease causes disintegration of the microtubules.

## Neurons

Alzheimer's disease causes the appearance of senile plaques and tangles of degeneration that damage the neurons.

## Deterioration

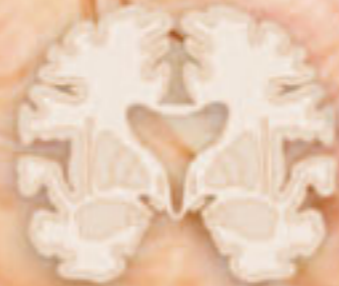As the disease progresses, the brain loses volume, and the sections of the cortex that carry out different processes are progressively damaged. The areas of the cortex shrink.



NORMAL BRAIN



**1 HEALTHY CORTEX** The different areas of the brain maintain their functional size. The cortex, which contains the nerve cells, is thick.



WITH ALZHEIMER'S DISEASE



**2 DAMAGED CORTEX** The size of the neurons is reduced (atrophy). The surface of the brain cortex is reduced.

## EXPRESSIONS

Persons affected by Parkinson's disease tend to suffer from rigidity in their facial expressions.

## ELECTRICAL CONDUCTION

occurs inside each neuron, preceding the interneural synapse. In Parkinson's disease, the connections and their ability to function are reduced dramatically.

## SYMPTOMS

Muscle rigidity and slowing movement. Body posture is characterized by a forward bending of the head and trunk.

## DOPAMINE

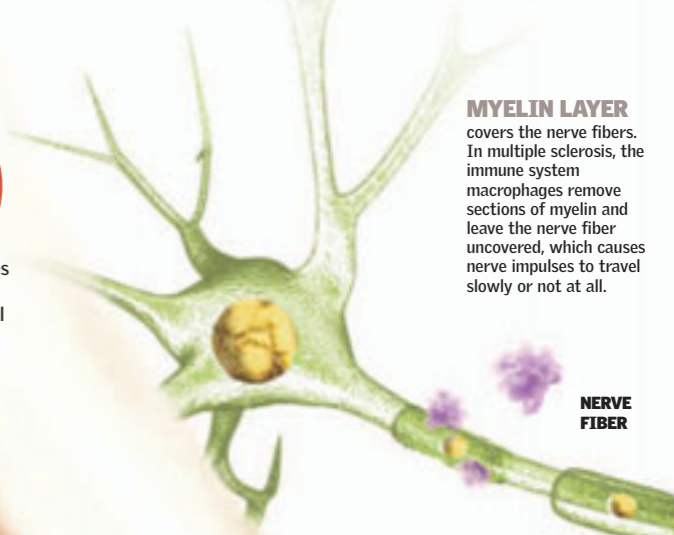
Produced by the substantia nigra in the brain and transported by the nerve fibers, one function of this neurotransmitter is to influence the body's movements. The basal ganglia (deep inside the brain) receive reduced levels of dopamine. The execution of regular movements becomes altered.

## Multiple Sclerosis

➤ A common neurological disorder that appears sometime between the ages of 20 and 40, it can cause distorted or double vision, paralysis of the lower limbs or one-half of the body, clumsy movements, and difficulty in walking. Multiple sclerosis occurs when the immune system damages the layers of myelin that cover nerve fibers.

50

percent of persons over 80 suffer from neurological diseases.



## MYELIN LAYER

covers the nerve fibers. In multiple sclerosis, the immune system macrophages remove sections of myelin and leave the nerve fiber uncovered, which causes nerve impulses to travel slowly or not at all.

## NERVE FIBER



# Bone Degeneration

Because joints are made to function in very specific ways, any abnormal movement tends to cause injury. Some injuries can result from falling or being struck, while others can be caused by degeneration of the joint. The general term for inflammation of the joints is arthritis. In the bones, the loss of bone mass is called osteoporosis and is usually related to aging. ●

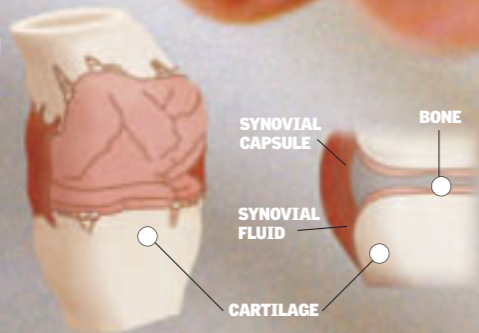
## Osteoarthritis

Osteoarthritis, the most common form of arthritis, is the process of progressive erosion of the joint cartilage. Unlike rheumatoid arthritis, which can affect other organs, osteoarthritis affects only the joints, either in a few specific joints or throughout the body. The joint degeneration of osteoarthritis could worsen due to congenital defects, infections, or obesity. Because cartilage normally erodes with age, osteoarthritis affects persons close to 60 years of age.

### PHASES OF THE DISEASE

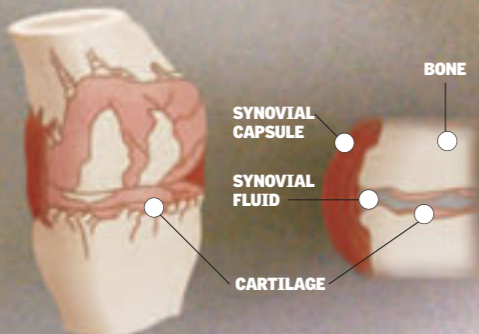
#### 1 DETERIORATION

Osteoarthritis causes progressive damage of the cartilage. When the cartilage cells die, cracks appear on the surface of the bone. From this moment on, the synovial fluid begins to leak. Later the fluid enters the cartilage and causes it to degenerate.



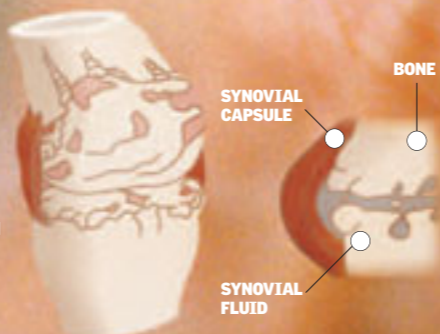
#### 2 BONE FRACTURE

The cartilage is worn away down to the bone and breaks its surface. From this erosion, a hole appears. New blood vessels begin to grow. To fill the gap, a plug develops that is made up of fibrocartilage.



#### 3 EXPOSED BONE

The plug disappears and leaves the bone surface exposed. If the surface fractures become deeper, the synovial fluid can enter the bone marrow and form a cyst surrounded by weakened bone. Osteophytes (bone spurs) can appear.



30%

or more of the mineral density of the bone is lost through the degeneration of osteoporosis.

JOINT

BONE

### STRUCTURE

The joint is normally made up of cartilage that is lubricated by the synovial fluid to allow ease of movement.

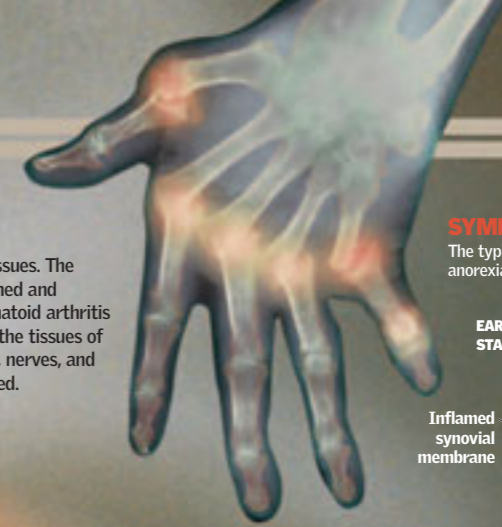SYNOVIAL MEMBRANE

SYNOVIAL FLUID

## Rheumatoid Arthritis

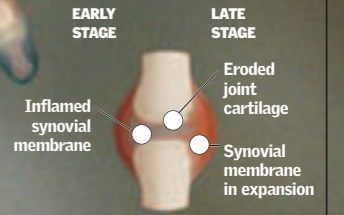
In this autoimmune disease, the immune system, triggered by some antigen in a predisposed person, begins to

attack the body's tissues. The joints become inflamed and deformed. As rheumatoid arthritis develops over time, the tissues of the eyes, skin, heart, nerves, and lungs may be affected.



### SYMPTOMS

The typical symptoms are fatigue, anorexia, and muscle and joint pain.



## Symptoms of Osteoarthritis

The most common signs of the degeneration of the joint cartilage are the deformation and swelling of the joints. Some cases might include numbness and limited movement of the joint.

## Osteoporosis

Between the fifth and sixth decade of life, the bones tend to become more porous and to decrease in thickness. Both men and women lose bone mass, even if they are healthy. The levels of estrogen decrease rapidly in women after menopause, leading to osteoporosis in many cases. In men, the reduction in testosterone is gradual, and the likelihood of suffering from osteoporosis is lower.

## Gout

is caused by high levels of uric acid in the blood. The acid is deposited in the joints, causing inflammation. Primary gout is due to a congenital metabolic error, and secondary gout is caused by any other metabolic disorder.



NORMAL BONE



WITH OSTEOPOROSIS

### HEALTHY BONE

An outer membrane, the periosteum, wraps around a band of hard, cortical bone and spongy bone.

### FRAGILE BONE

As it loses bone mass, the bone's central channel widens, and cracks appear in the osteons.

### REDUCED MASS

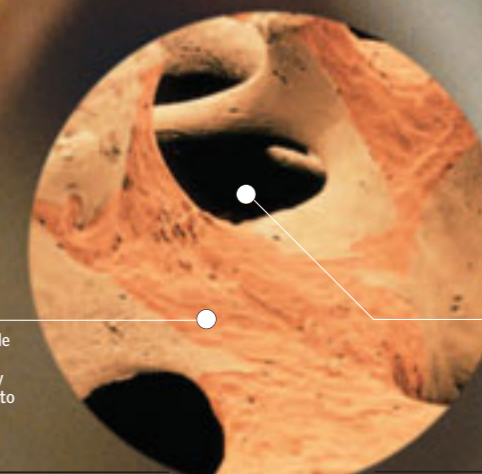
Osteoporosis generates a decrease of total bone mass. As a consequence, pores appear that could weaken the bone.

### PORES

appear on the bone surface as a consequence of tissue degeneration and the progressive erosion of the bone.

### SURFACE

is more susceptible to fracture as the bone loses rigidity because of injury to the bone cells.





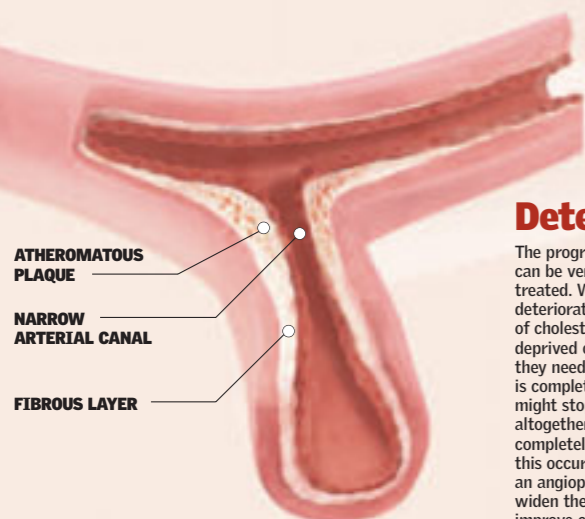
# Circulatory Conditions

Among the most frequent diseases that affect the circulatory system are those that result from blockages of the arteries and veins. The buildup of fat in the arteries can lead to arteriosclerosis, which blocks the supply of blood to the tissues. In many cases, as in a myocardial infarction, there are no warning signs. This could lead to the death of the tissue that loses blood supply. Certain drugs can be used to dilate blocked blood vessels. ●

## Arteriosclerosis

Arteriosclerosis of the cardiac blood vessels, or heart disease, is caused by a narrowing of the arteries as cholesterol, cells, and other substances accumulate in the lining of these vessels. Arterial obstruction is gradual; it begins when excess fats and cholesterol build up in the blood. These substances infiltrate the lining of the

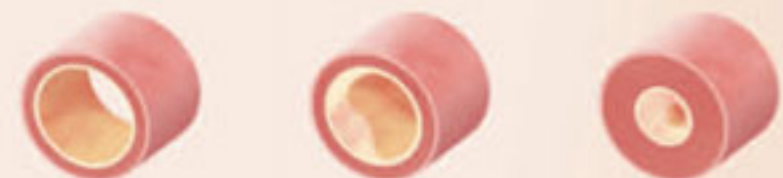arteries to create microscopic damage sites. Atheromata form, which in turn develop into fatty masses called plaque. The appearance of these plaques thickens the arterial walls and prevents the normal flow of blood, thus reducing the blood flow.



**ATHEROMATOUS PLAQUE**  
**NARROW ARTERIAL CANAL**  
**FIBROUS LAYER**

## Deterioration

The progression of arteriosclerosis can be very dangerous if it is not treated. When the arteries deteriorate because of the presence of cholesterol, the organs can be deprived of the amount of blood they need to function. If the artery is completely blocked, an organ might stop receiving blood altogether and, as a consequence, completely lose its function. When this occurs in the heart, for example, an angioplasty must be done to widen the vessel once again and improve circulation in the tissue.



- 1 FREE** Without the formation of fatty plaque, the blood flows normally.
- 2 WITH ATHEROMATOUS PLAQUE** Inside this plaque, cholesterol and other substances accumulate.
- 3 BLOCKAGE** The arterial wall thickens and the artery is blocked.

## Vena Cava

The superior vena cava takes the blood from the head and arms to the right atrium. The inferior vena cava takes deoxygenated blood returning from the lower trunk and limbs to the right atrium.

## Aorta

The largest blood vessel in the body, with an internal diameter of 1 inch (2.5 cm). It takes blood with fresh oxygen to all parts of the body.

## Pulmonary Artery

branches out from the right ventricle. Each branch takes deoxygenated blood to the lungs. The pulmonary artery is the only artery that transports deoxygenated blood.

## Pulmonary Hypertension

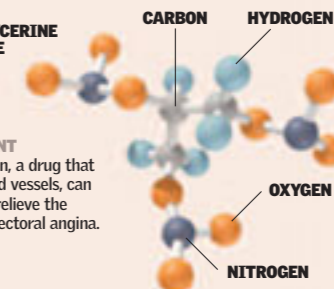
When the blood pressure in the pulmonary artery increases, the walls thicken. The blood pumped by the heart is reduced.



## Pectoral Angina

Chest pains could be a warning sign that the cardiac muscle is not receiving enough blood to keep up with the demands of the work it is doing. In pectoral angina, very strong chest pains occur because of the arteries that are obstructed by arteriosclerosis.

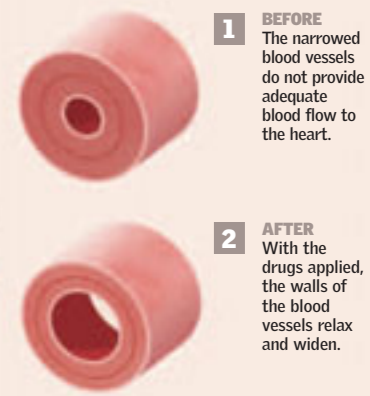
### NITROGLYCERINE MOLECULE



**TREATMENT** Nitroglycerin, a drug that dilates blood vessels, can be used to relieve the effects of pectoral angina.

## WIDENING VESSELS

To reestablish adequate blood flow, drugs such as nitroglycerin can be used. The narrow blood vessels dilate, and the heart does not have to work so hard.



**1 BEFORE** The narrowed blood vessels do not provide adequate blood flow to the heart.

**2 AFTER** With the drugs applied, the walls of the blood vessels relax and widen.

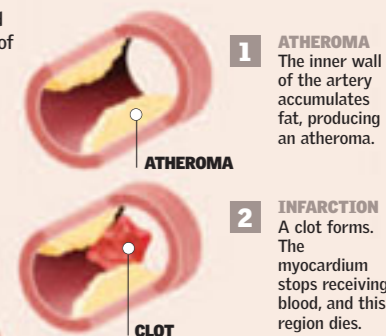
## Heart Attack

An infarction usually happens suddenly, almost without warning. The pain in the chest area can be like angina but generally is more severe and does not go away with rest. A person who suffers an attack experiences excessive sweat, weakness, and, in some cases, loss of consciousness. The attack could be a direct consequence of the lack of

blood volume. If the artery begins to fill with fat after the partial obstruction of a blood vessel by a plaque, a lesion in its wall may form, resulting in the formation of a thrombus that could block the blood vessel. This could deprive a portion of the myocardium of oxygen, which would then produce a heart attack.

## HOW IT HAPPENS

A blockage in a coronary artery prevents blood from reaching the muscle. If the blockage is complete, the blood-deprived muscle dies.



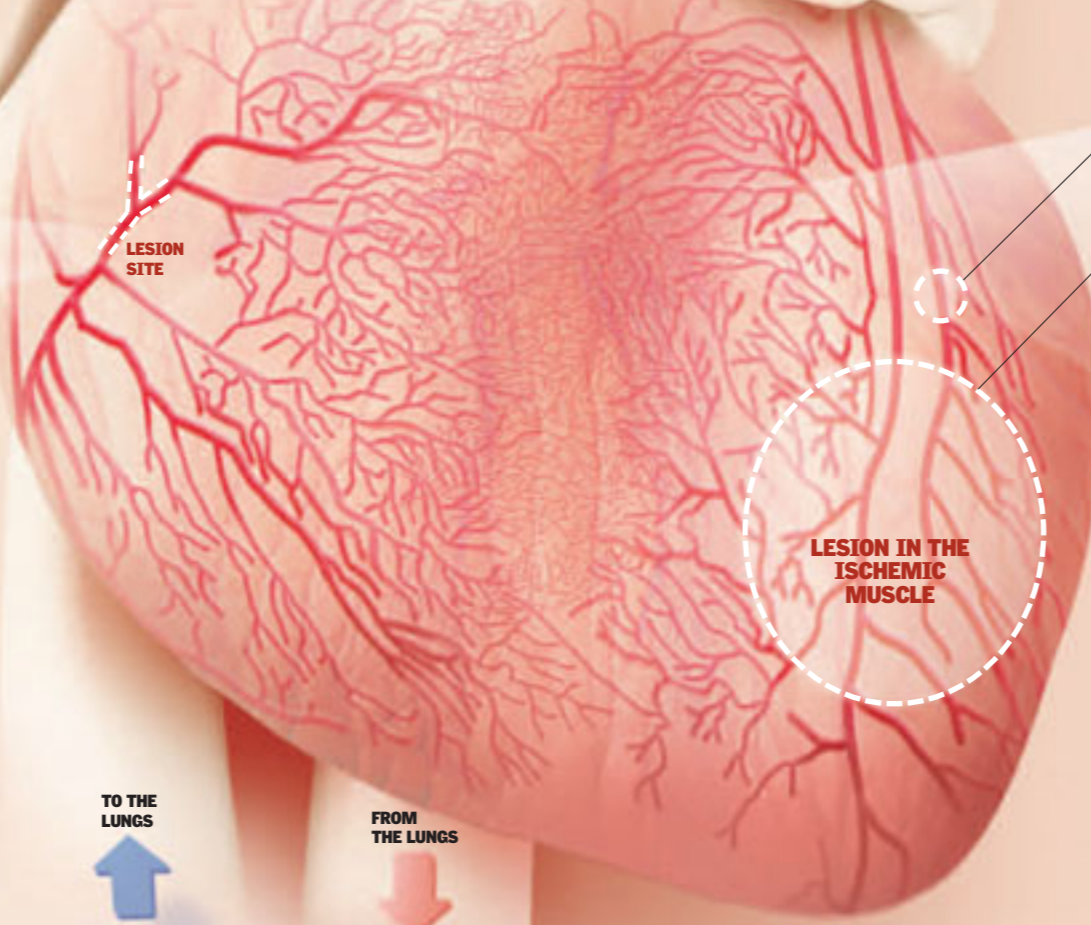
**1 ATHEROMA** The inner wall of the artery accumulates fat, producing an atheroma.

**2 INFARCTION** A clot forms. The myocardium stops receiving blood, and this region dies.

## DETECTION

When a heart attack occurs, the muscle fibers release enzymes into the bloodstream.

**ENZYMES** make it possible to estimate the severity of the attack. If enzyme levels are high, it was severe.



**LESION SITE**  
**AREA WITHOUT BLOOD CIRCULATION**

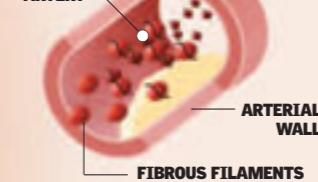
**MUSCLE FIBERS OF THE HEART**

**LESION IN THE ISCHEMIC MUSCLE**

## THROMBUS IN THE ARTERY

forms when blood platelets come into contact with collagen in the lining of the artery. Fibrous filaments appear that interact with the platelets, and the clot grows. The artery becomes blocked.

## CLOT THAT BLOCKS THE ARTERY



## Thrombosis

Unlike a natural clot that forms to prevent blood loss from an injured blood vessel, in arteriosclerosis, the blood vessels are already damaged. This causes a predisposition to form a thrombus when an atheroma ruptures. In thrombosis, unlike arteriosclerosis, clots form that in many cases can migrate through the bloodstream and lodge somewhere away from the original site.

TO THE LUNGS

FROM THE LUNGS



# Respiratory Infections

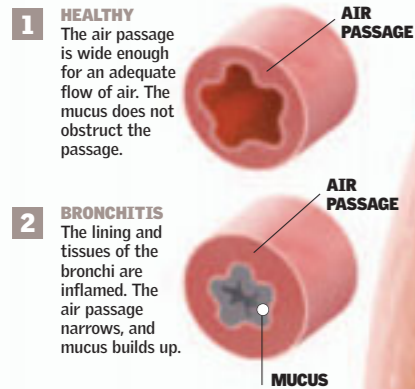
In many cases, respiratory-tract obstructions can cause severe complications. Although bronchitis is more often related to a viral or bacterial infection, the chronic form is associated with the consumption of tobacco, because the smoking habit has severe consequences for the respiratory system. In cases of pneumonia or complications associated with the respiratory tract, bacteria or other airborne microorganisms are usually responsible for the infection. ●

## Acute Bronchitis

An inflammation of the bronchi that develops suddenly, it can result from an infection of the respiratory tract or exposure to toxins, irritants, or atmospheric pollutants. Acute bronchitis is usually caused by a virus. The common symptoms are cough, which increases the need to salivate, and in some instances a high fever. In acute bronchitis, the tissues and membranes of the bronchi become inflamed, and the air passages narrow. The amount of mucus increases, causing congestion.

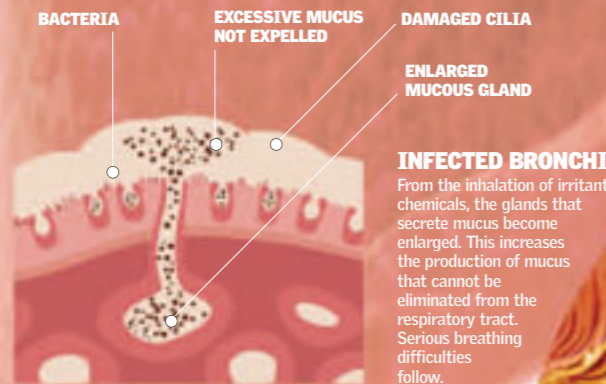
### HOW IT HAPPENS

The disease usually affects the large- and medium-sized bronchi. In children or older persons, the infection can expand and inflame the bronchioles and lung tissue.



## Chronic Bronchitis

The most common cause of chronic bronchitis is the irritation of the bronchi by chemical substances. The effect of tobacco, which contains nicotine, is another primary factor in the development of chronic bronchitis. The typical symptoms are cough with phlegm, hoarseness, and difficulty breathing. One effect of smoking is an excessive production of mucus, followed by enlargement of the mucous glands and dysfunction of the cilia. Thus, the respiratory tract can be affected and can even function as a medium for the growth of some bacteria. In some cases, chronic bronchitis can be brought on by recurrent episodes of acute bronchitis.

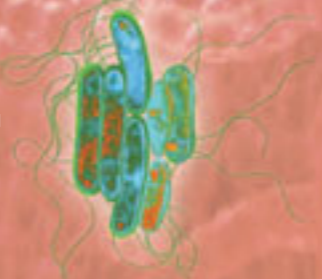


## Bronchi

The lung has two main bronchi that branch out from the trachea. These two bronchi branch out further into an intricate network of bronchial branches that provide space for the passage of air in the lungs.

## Pneumonia

causes the inflammation of the smallest bronchioles and the alveolar tissue. In 1976, a bacteria was detected, *Legionella pneumophila* (pictured), that causes a severe, rapidly spreading form of pneumonia.

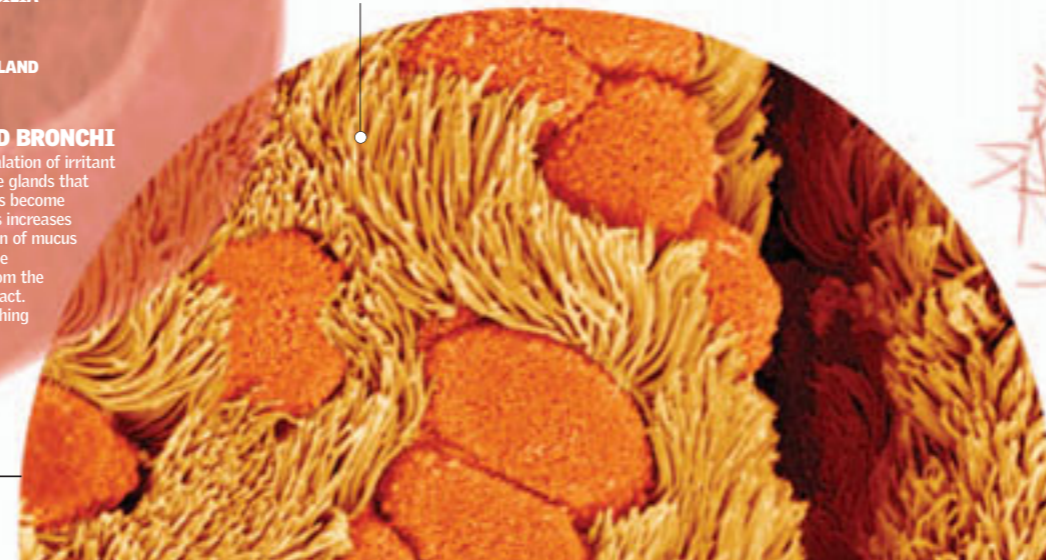

## Cilia

are small hairs located in the bronchi. The mucus in the respiratory tract is expelled by the cilia.


## Bronchioles

Terminations located in the bronchi of each lung. Their function is key in the respiratory system: they connect with the alveoli, where the gaseous exchange takes place. If the bronchioles are damaged, natural breathing is impeded.



## Alveoli

These microscopic bags of air in the lungs have a structure with thin, elastic walls. They take in air from the ducts of bronchioles. The inner surface of the alveoli has macrophages that destroy bacteria. If a significant number of alveoli are destroyed, breathing can become difficult.



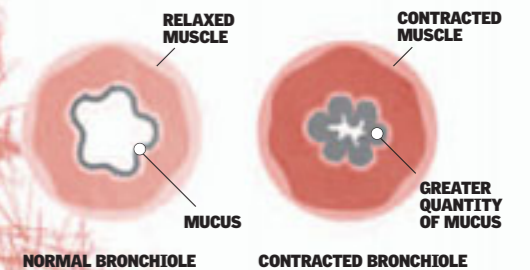
**EXCHANGE OF GASES**  
Oxygen enters the blood by diffusion through the alveolar walls. Carbon dioxide diffuses from the blood to the alveoli and is exhaled from there.

## Asthma

Asthma attacks are characterized by recurrent episodes of an out-of-breath feeling caused by the constriction of the airways. The smallest bronchi and bronchioles become inflamed and filled with mucus, causing difficulty in breathing. The most recurrent type of asthma is the allergic kind, which develops in childhood.

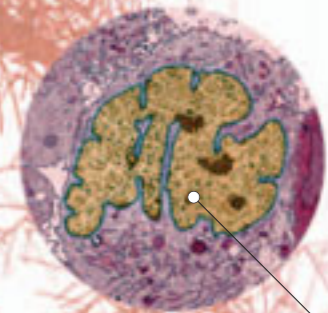
### BRONCHIOLE CONTRACTION

Normally the bronchiole is relaxed, and the air flows freely. Upon contraction of the muscle, there is a shortage of air and the space for its circulation is limited.



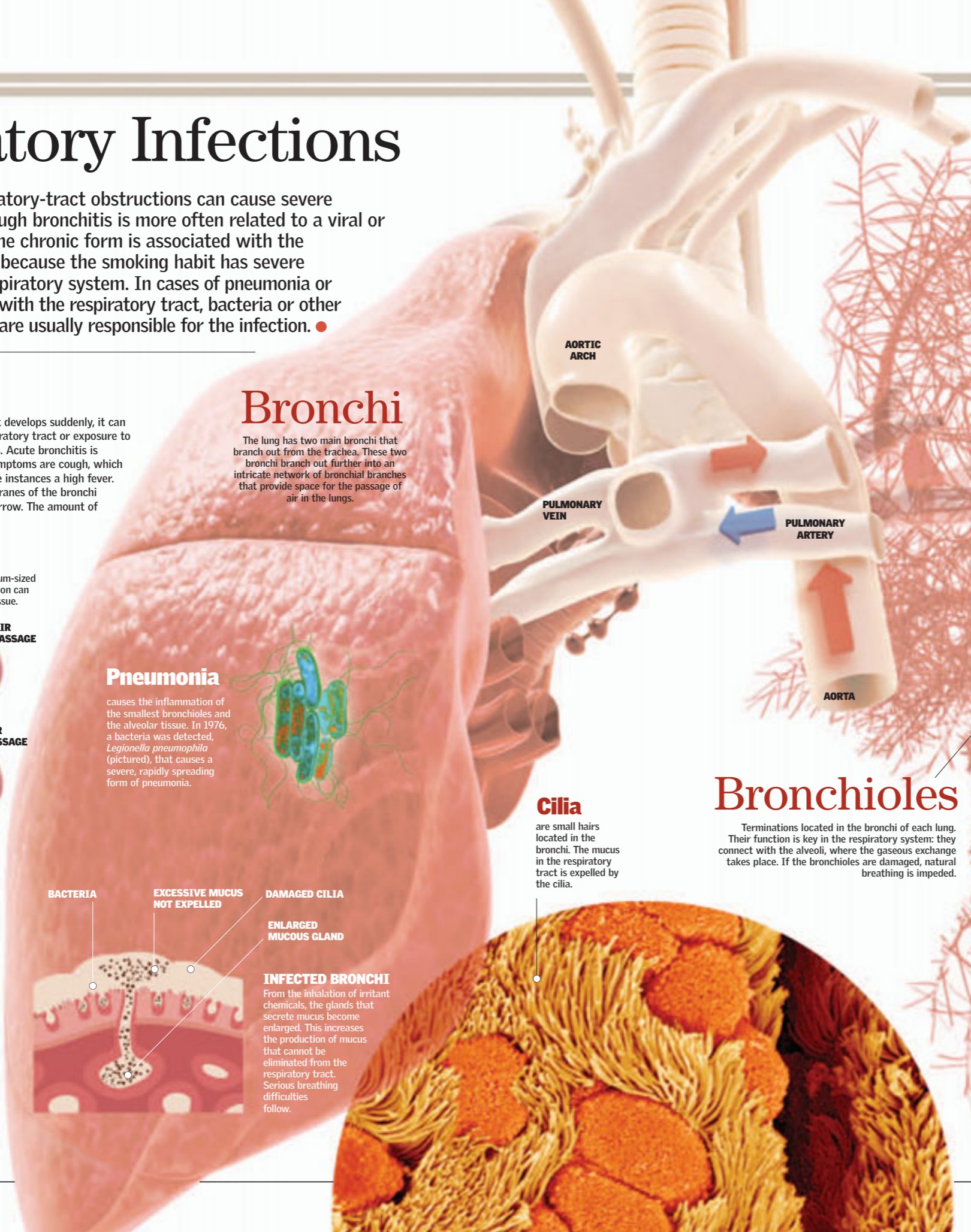
## Lung Cancer

The growth of cancer cells (pictured) is caused by tobacco in 90 percent of cases. Of the 4,000 chemical substances in tobacco, 40 components have a carcinogenic potential that causes the appearance of atypical cells. When these cells grow, cancer cells multiply.



**NUCLEUS**  
is elongated and projects extensions outside the cell wall. It contains chromatin, DNA, and proteins.

**BRONCHI**  
These branched structures end in bronchioles, which are connected to the alveoli through air ducts.





# Excesses in the Digestive System

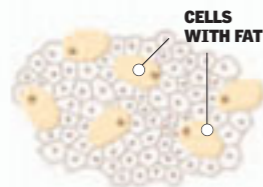
Diseases that affect the organs of the digestive system, such as the stomach, pancreas, and liver, find their origin in alcoholic drinks, poor nutrition, or bacteria that break down the layers of tissue and harm the organs. Diseases, such as cirrhosis, hepatitis B, gallstones, and ulcers, can lead to irreparable damage in different parts of the body. ●

## Cirrhosis

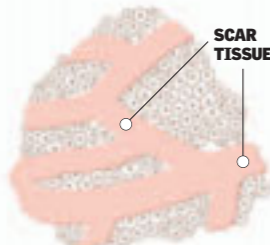
This liver disease causes fibrosis and dysfunction of the liver. The main causes are chronic alcoholism and infection with the hepatitis C virus. Cirrhosis can cause a buildup of fluid in the abdomen (ascites), clotting disorders, increased blood pressure in the hepatic veins of the digestive tract,

with dilation and risk of rupture, and confusion or changes in the level of consciousness (hepatic encephalopathy). Some symptoms are edema in the lower limbs, bloody vomit, jaundice (yellowish skin), generalized weakness, weight loss, and kidney disorders.

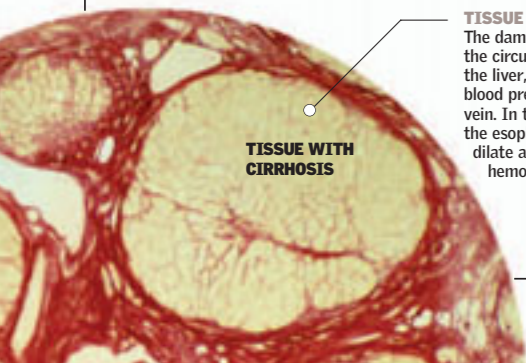
**A FATTY LIVER** can appear as a result of excessive alcohol consumption. The liver contains fat cells that infiltrate, become larger, and enlarge the liver.



**B ALCOHOLIC HEPATITIS** Alcohol consumption induces enzymes to produce acetaldehyde, which generates inflammation. This damages the hepatic cells, impairing normal liver function.



**C CIRRHOSIS** Bands of damaged tissue separate the cells. This stage of destruction is irreversible and can also stem from other causes, such as viral hepatitis.

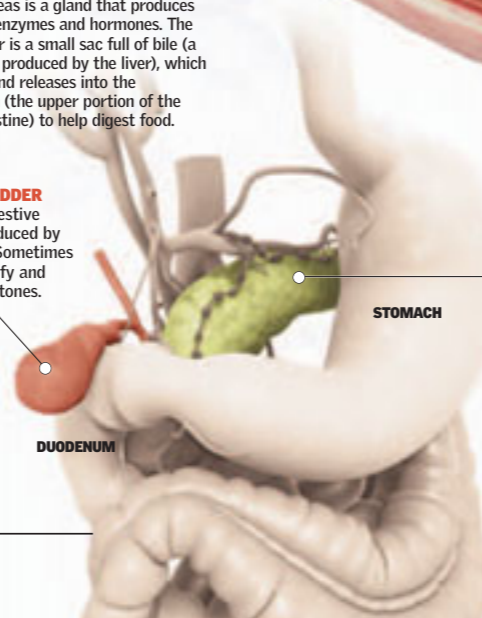


**TISSUE** The damaged tissue affects the circulation of blood in the liver, increasing the blood pressure in the portal vein. In the lower part of the esophagus, the veins dilate and a digestive hemorrhage can occur.

## Pancreas and Gallbladder

The pancreas is a gland that produces digestive enzymes and hormones. The gallbladder is a small sac full of bile (a substance produced by the liver), which it stores and releases into the duodenum (the upper portion of the small intestine) to help digest food.

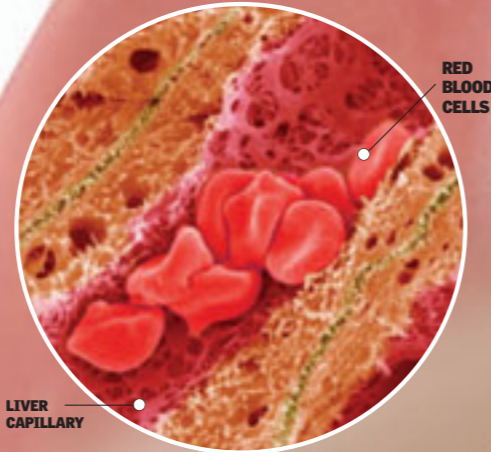
**GALLBLADDER** stores digestive juices produced by the liver. Sometimes they solidify and form gallstones.



**PANCREAS** secretes pancreatic juices, which contain the enzymes necessary to digest foods, into the duodenum.

## Cleaning

Substances carried in the blood are modified during their passage through the liver, which cleans and purifies the blood supply, breaks down certain chemical substances, and synthesizes others.

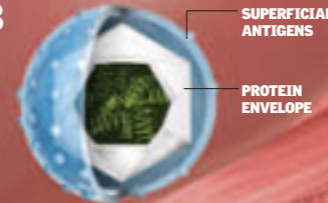


## Liver

The blood coming from the organs of the digestive system reaches the liver through the portal vein. The liver removes the toxic by-products from the body, synthesizes and stores nutrients, and contributes to the digestion of food by producing bile.

## Hepatitis B

is transmitted by blood and blood products, contaminated needles, unprotected sex, and from mother to child during birth.



## Stomach

Food substances are stored here for some time before proceeding to the intestine. By this point, the food is in an advanced state of digestion, in which the original substances have been converted into simpler ones that pass through the intestinal wall and into the blood.



## Gastritis

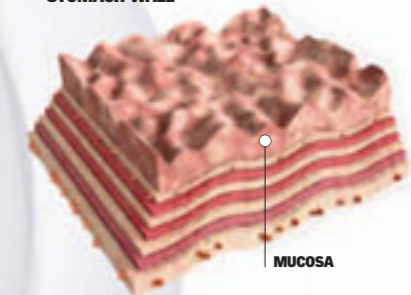
An inflammation of the mucous membrane of the stomach, it may have various causes, including alcohol consumption, anti-inflammatory medication, and smoking tobacco. It is also associated with *Helicobacter pylori* bacteria.

## Peptic Ulcer


A sore in the mucous membrane of the stomach or duodenum. Peptic ulcers are common, and one of the main causes is infection by the bacterium *Helicobacter pylori*. However, some are caused by the prolonged use of nonsteroidal anti-inflammatory agents, such as aspirin and ibuprofen.

In some instances, stomach or pancreatic tumors can cause ulcers. The relationship between ulcers and certain types of foods or stress has not been clearly demonstrated. The main symptom is abdominal pain that is more common at night, when the stomach is empty, or two to three hours after eating.


### STOMACH WALL



### ACUTE ULCER



### CHRONIC ULCER



1

### EARLY STAGES

When the barrier of protective mucosa is altered and the stomach juices come into contact with the cells of the mucosa, erosion occurs.

2

### DEEPENING

The sore completely penetrates the mucosa, reaching the muscle layer of the mucosa and submucosa. An ulcer is formed.

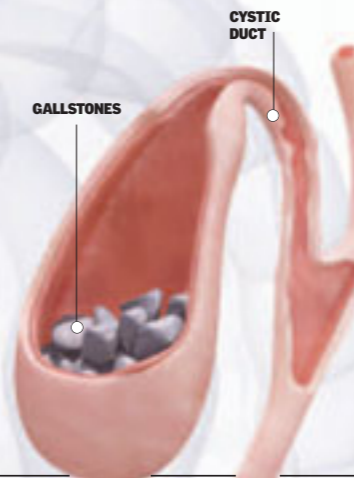
3

### COMPLICATIONS

As the stomach wall is more deeply eroded, a large artery could be damaged enough to cause a hemorrhage. It could also lead to peritonitis.

## Gallstones

form inside the gallbladder, an organ that stores the bile secreted by the liver. Bile is a solution of water, salts, lecithin, cholesterol, and other substances. If the concentration of these components changes, stones may form. They can be as small as a grain of sand or can grow to about 1 inch (3 cm) in diameter depending on how long they have been forming.



1

### OBSTRUCTION

The bile is blocked from leaving the gallbladder by a gallstone. This causes pain and inflammation of the gallbladder.

2

### INFLAMMATION

The inflammation progresses by means of various mechanisms. The contents of the gallbladder can become infected and form pus.

3

### RUPTURE

If the process continues and the inflammation is very significant, the gallbladder could rupture.

4

### CONTRACTION

If the process is repeated, the gallbladder could shrink and lose its shape.

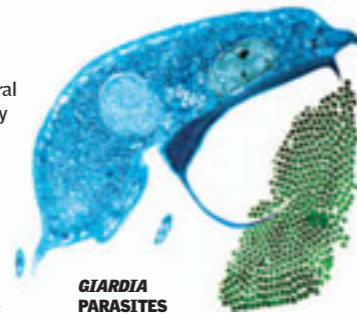

# Intestines and Colon

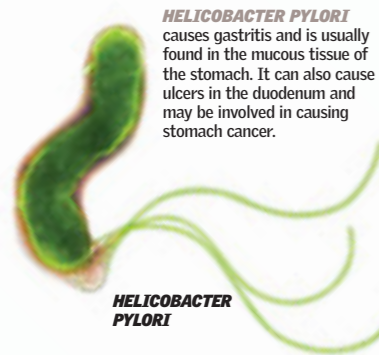
Intestinal infections and inflammations are among the most common disorders of the digestive system. In developing nations, an increase in infant mortality has been due to some of these diseases. Many are bacterial and can be treated with the ingestion of fluids or antibiotics, but others can be caused by a problem of the digestive system. ●

## Intestinal Infections

The most common intestinal infection is viral gastroenteritis, but it can also be caused by bacteria or protozoa. Almost all infections are transmitted by ingesting contaminated water or food. The most common symptoms are vomiting, diarrhea, and abdominal pain. Viral gastroenteritis is a self-limiting process that resolves itself in several days simply by replacing fluids to prevent dehydration, but other infections must be treated with antibiotics.

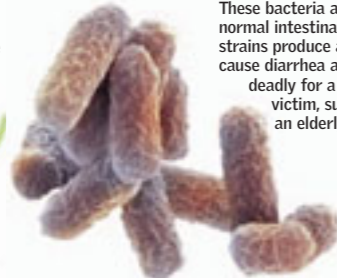

GIARDIA PARASITES



HELICOBACTER PYLORI

HELICOBACTER PYLORI causes gastritis and is usually found in the mucous tissue of the stomach. It can also cause ulcers in the duodenum and may be involved in causing stomach cancer.

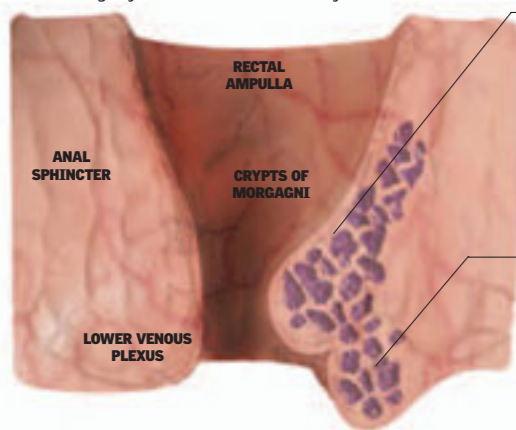


ESCHERICHIA COLI

ESCHERICHIA COLI These bacteria are part of the normal intestinal flora. Some strains produce a toxin that can cause diarrhea and even be deadly for a susceptible victim, such as a baby or an elderly person.

## Hemorrhoids

These dilatations of veins occur in the venous plexus in the mucosa of the rectum and anus. If the affected veins are in the superior plexus, they are called internal hemorrhoids. Those of the inferior venous plexus are located below the anorectal line and are covered by the outer skin. The drainage system in the area lacks any valves.



### TYPES OF HEMORRHOIDS

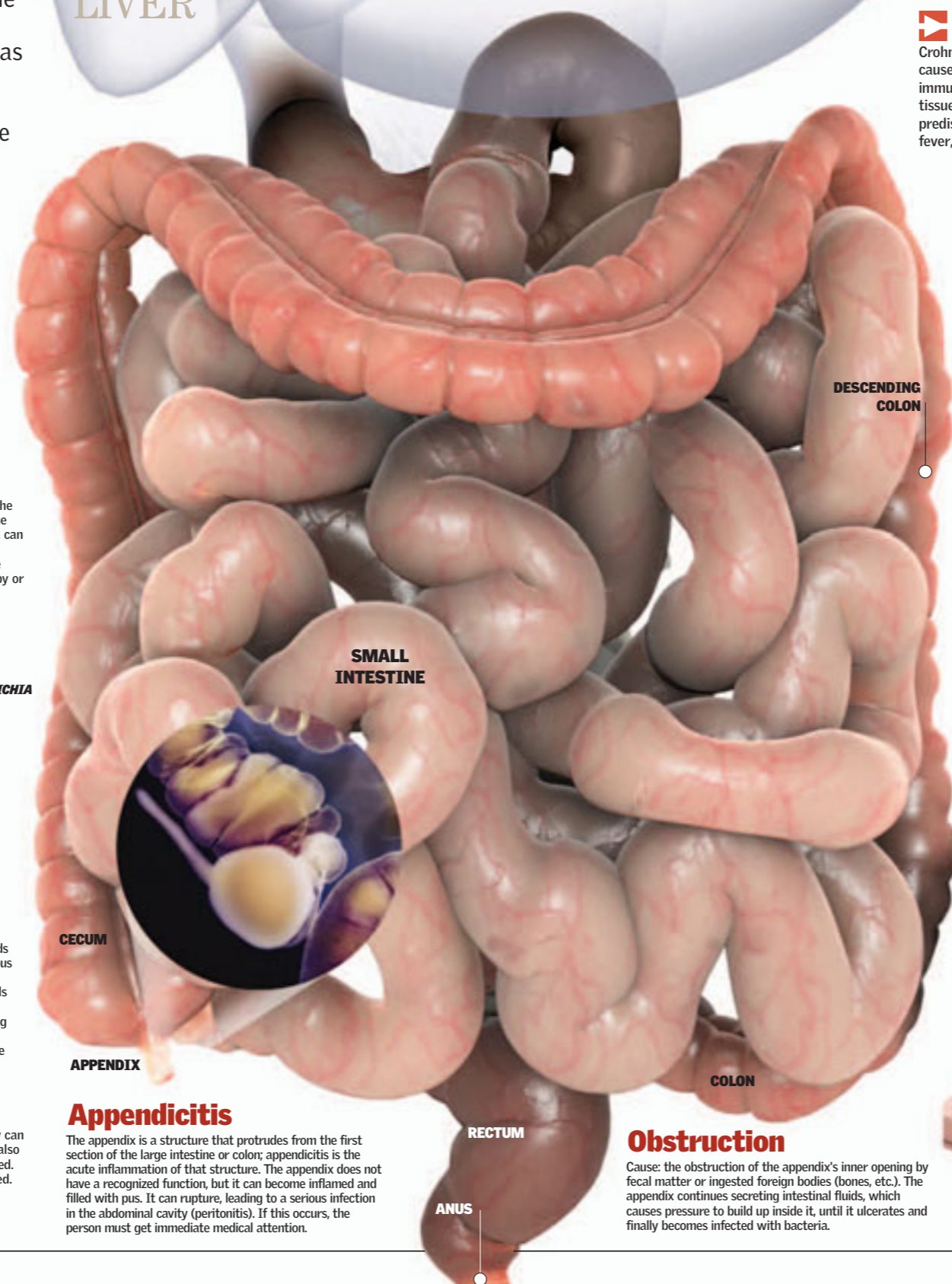
There are two types of hemorrhoids: internal and external.

**1 INTERNAL** Classified according to grades. Grade I hemorrhoids are located in the submucous tissue and bleed bright red blood. Grade II hemorrhoids protrude during defecation but recede once the pushing stops. Grade III come out while defecating, and Grade IV are irreducible and are always prolapsed.

**2 EXTERNAL** Come from the inferior hemorrhoidal plexus. They can swell and cause pain and also become ulcerated and bleed. Thrombosis can be resolved.

LIVER

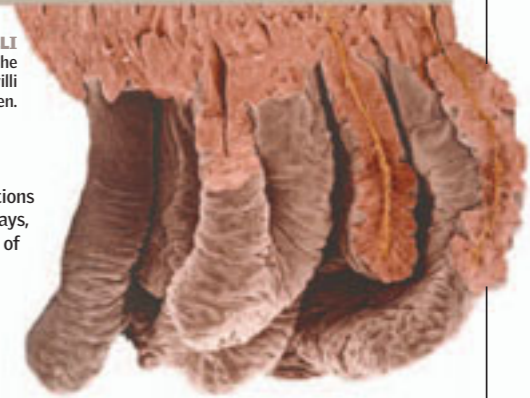Stomach



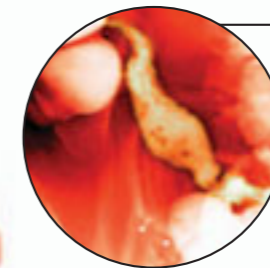
## Intestinal Inflammation

Intestinal inflammations include ulcerative colitis and Crohn's disease. They can be caused by an attack of the immune system on the body's own tissues or by genetic predisposition. Symptoms include fever, blood loss, abdominal pain,

**GASTRIC VILLI**  
This image shows the walls of the duodenum where the gastric villi can be seen.



and diarrhea. These conditions can be diagnosed with X-rays, a colonoscopy, or a biopsy of the intestinal tissue. The treatment might include anti-inflammatory drugs.



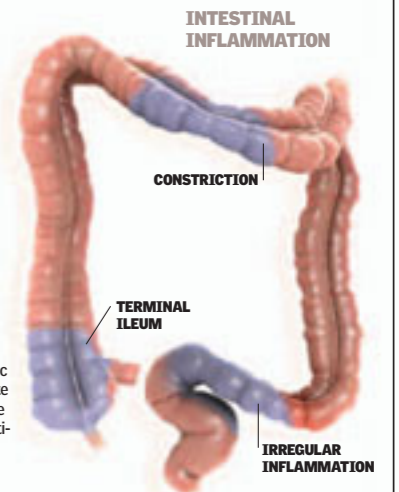
## Colitis

Ulcerative colitis is an inflammatory disease of the colon and rectum. It is characterized by the inflammation and ulceration of the colon's inner wall. Typical symptoms include diarrhea (sometimes bloody) and frequent abdominal pain.

## Ulcer

A peptic ulcer is a sore, or chronic erosive lesion, of the lining of the stomach or the duodenum (the first section of the small intestine). Peptic ulcers are common and can originate from a bacterial infection or in some cases from the prolonged use of anti-inflammatory drugs.

**Crohn's Disease**  
Crohn's disease is a chronic autoimmune condition in which the individual's immune system attacks its own intestine, causing inflammation.



INTESTINAL INFLAMMATION

CONSTRICTION

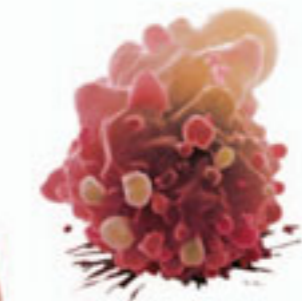
TERMINAL ILEUM

IRREGULAR INFLAMMATION

## Colon Cancer

This type of cancer is one of the most common in industrialized nations. Risk factors include family medical history, intestinal polyps, and advanced age. The symptoms are blood in the stool, a change in intestinal habits,

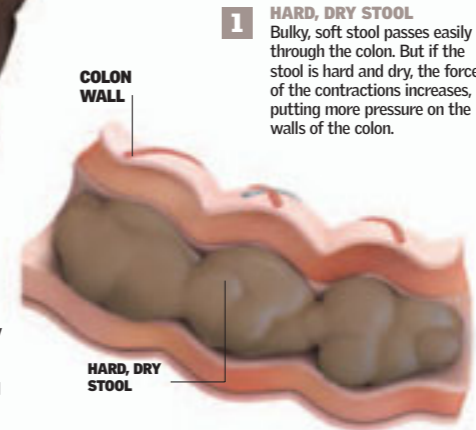
and abdominal pain. People over 50 years of age should be evaluated by their doctor to check for the presence of blood in the stool (as seen in the photo), and if this test is positive a colonoscopy should be performed.



## Diverticulitis

The inflammation or infection of a pouch, called a diverticulum, formed in the wall of the large intestine (colon). It is believed to be caused by the slow movement of food through the intestines, which builds up a constant

pressure. This increases and pushes on the inside walls of the colon, forming pouches. Ingested food or stool becomes trapped in a pouch, leading to inflammation and infection.

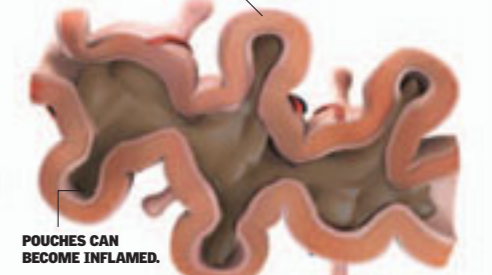


COLON WALL

HARD, DRY STOOL

**1 HARD, DRY STOOL**  
Bulky, soft stool passes easily through the colon. But if the stool is hard and dry, the force of the contractions increases, putting more pressure on the walls of the colon.

**2 DIVERTICULA**  
Increasing pressure against the inner intestinal lining forms pouches in weak spots of the muscle wall. These pouches can then become inflamed, causing pain and distension.



POUCHES CAN BECOME INFLAMED.

## Appendicitis

The appendix is a structure that protrudes from the first section of the large intestine or colon; appendicitis is the acute inflammation of that structure. The appendix does not have a recognized function, but it can become inflamed and filled with pus. It can rupture, leading to a serious infection in the abdominal cavity (peritonitis). If this occurs, the person must get immediate medical attention.

## Obstruction

Cause: the obstruction of the appendix's inner opening by fecal matter or ingested foreign bodies (bones, etc.). The appendix continues secreting intestinal fluids, which causes pressure to build up inside it, until it ulcerates and finally becomes infected with bacteria.

CECUM

APPENDIX

SMALL INTESTINE

DESCENDING COLON

COLON

RECTUM

ANUS



# Allergies: A Modern Evil

**S**neezing and watery eyes, rashes and skin irritation, swelling, and itching. These are just some of the most common symptoms of allergies, a condition that affects millions of people throughout the world, especially in developed countries. What is the cause of allergies? The immune system does not function properly: it overreacts, attacking foreign substances that normally would not cause any harm. These invaders, called allergens, might include pollen, mold, and dust mites, among many other possibilities. ●

## An Attack on an Innocent

**1** In developed countries, the percentage of the population affected by allergies has increased. One reason for this epidemic of modernity is the obsession with cleanliness. This means that the body, from infancy, is not exposed to enough dirt to train the immune system, which then reacts inappropriately to any

foreign substance, no matter how harmless. Upon the first exposure to an allergen, the immune system becomes sensitized. In subsequent exposures, an allergic reaction occurs, which can range from a skin rash to various breathing problems. The reaction varies from person to person.

**3 BURST** When allergens are present, the cells that help the body fight infections malfunction and respond with unnecessary chemical defenses.

**2 COMBINATION** Antibodies, which are the sensors of the immune system, attach themselves to the surface of a mast cell and later bind to the allergen proteins. When there are significant numbers of antibodies, they notify the mast cell about the presence of an intruder.

**1 ENTRANCE** An allergen may enter the body through the lungs, eyes, cuts in the skin, and other mucous membranes.

POLLEN GRAIN

POLLEN PROTEIN

Mast Cell

ANTIBODY

PROSTAGLANDINS

LEUKOTRIENES

HISTAMINE

CYTOKINES

CHEMOKINES

## No Help from Fall

**2** Rhinitis and asthma, like the other respiratory allergies, increase with the arrival of fall. They are incapacitating, and they exact an enormous cost in terms of lost work and school days. The cold, in turn, irritates the respiratory tract, making it more susceptible to infections, especially viral ones. Changes in the

respiratory mucous membranes and the immune system activate or reactivate the allergies. A cold, for example, can trigger a bronchial asthma attack. Moreover, the lack of ambient ventilation because of the cold weather and the concentration of indoor allergens, such as mites and fungi, increase and contribute to triggering this disease.

## Test

The most effective way to identify the allergens responsible is through a series of pricks on the patient's arm to inoculate them with drops of allergen solutions. This test can identify the cause or causes of the illness and its treatment.



## Asthma

This illness has grown by 50 percent in the last 10 years. Currently, it is estimated that between 100 and 150 million persons suffer from this disease, and although it is more frequent in young children, between 3 percent and 7 percent of the adult population could be affected.

## 6 SUBSEQUENT RESPONSES

Cytokines and chemokines, which slowly damage the tissue and recruit other cells, are strongly related to the symptoms of acute and chronic asthma.



WASP

## Best-Known Allergens

**2** Among all the substances that can produce an allergic reaction, these are the most important:

**POLLEN:** Minuscule grains released by plants during their reproductive process. They cause hay fever and breathing problems.

**DUST MITES:** Small insects that live inside the home. They cause allergies and asthma.

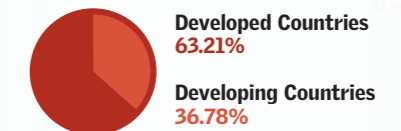
**WASP STINGS:** Some people have an excessive, even deadly, allergic reaction to the sting of a wasp or other insects.

**PEANUTS:** The allergy to this food is rapidly growing. In a few cases, it can be fatal.

**RAGWEED:** A type of weed that is one of the main causes of allergies in the United States. It produces intense rhinoconjunctivitis and, more rarely, asthma. Its pollen is very potent and is the cause of the allergic reaction.

POLLEN GRAINS

## ALLERGIES BY LEVEL OF DEVELOPMENT



Allergies, like obesity, are epidemics of modernity. The more industrialized a country, the greater the affected population. In contrast, in developing regions, such as Africa and Latin America, the number of people affected is much lower. In remote regions, allergies are almost nonexistent.



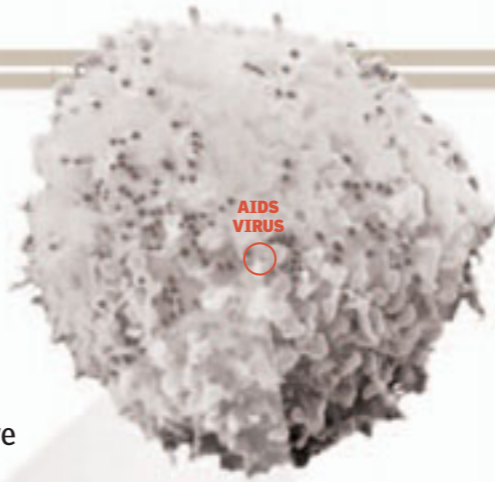
ÁCAROS



# AIDS

**A**cquired Immune Deficiency Syndrome (AIDS) is still considered one of the most important epidemics of the 21st century. Some 40 million people are infected with HIV (human immunodeficiency virus), the virus that causes AIDS; most of them are in Africa. Scientific research is aimed at finding a remedy to stop the development of the virus, but until now they have only produced therapies that slow viral activity. ●

**CD4-positive T Lymphocyte**  
Immune system cell that defends the body against infections



## The AIDS Virus

Human immunodeficiency virus (HIV) is the cause of AIDS. This virus destroys a type of white blood cell, the CD4 T lymphocyte, through the interaction of the viral DNA with the lymphocyte's DNA. These lymphocytes are essential to the immune system's fight against infections. For this reason, persons infected with HIV can suffer severe diseases, and even minor conditions, such as a cold, might be difficult to cure. However, not all those infected with HIV suffer from AIDS, which is the final stage of the disease. A person with HIV is seropositive. When the level of CD4-positive T lymphocytes goes below 200 cells per 1 mm<sup>3</sup> of blood, the disease progresses to the stage of AIDS.

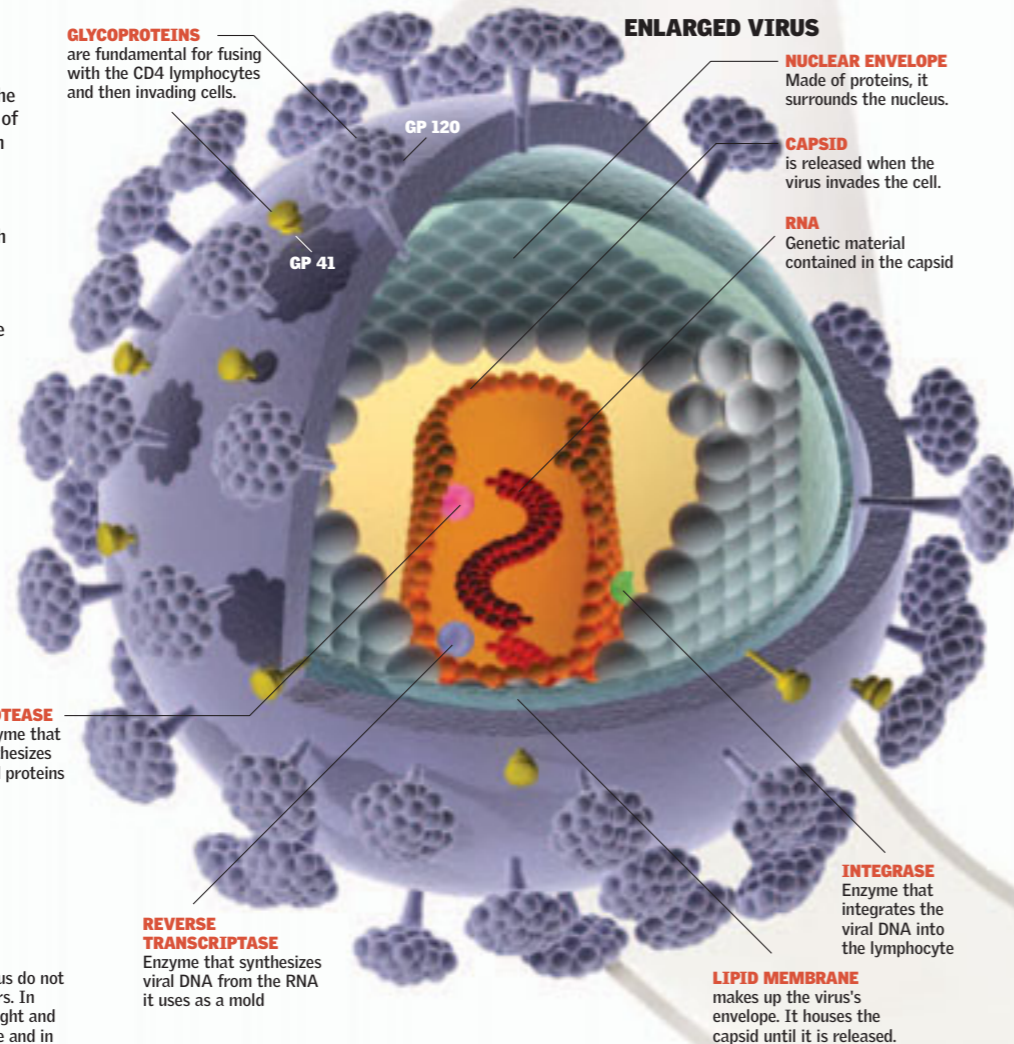
## History and Evolution

The "age of AIDS" began on June 5, 1981. The U.S. Centers for Disease Control found patients with pneumonia that simultaneously suffered from Kaposi sarcoma, a malignant tumor of the skin. It was noted that all the patients had a notable depletion of CD4-positive T lymphocytes. Unprotected sex and the use of needles with infected blood were the typical causes at that time. Today mother-to-child transmission and transfusions of blood and blood products play an important role.

## Symptoms of the Disease

Many people infected with the virus do not develop symptoms for several years. In earlier stages, they might lose weight and have fever without any clear cause and in later stages have frequent diarrhea. Those severely infected are predisposed to develop various infections and cancers.

- Brain** If damaged, it can cause vision problems, weakness, and paralysis.
- Lungs** The most common disease that can be contracted is pneumonia.
- Skin** The appearance of Kaposi's sarcoma, brown and blue spots on the skin, is generally associated with AIDS.
- Digestive system** Persistent diarrhea due to an infection of the gastrointestinal tract by parasites such as *Giardia lamblia* can result.



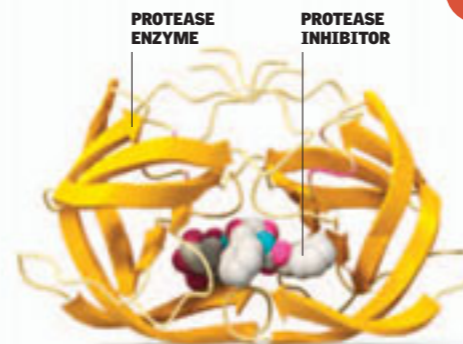
## How the AIDS Virus Works

The virus uses its layer of proteins to attach to the cell that will harbor it. A specific protein (gp120) fuses with a receptor on the CD4-positive T lymphocyte. After the immune system loses many cells, the body is left susceptible to many diseases. Ten years might pass from the time of infection until the development of full-blown AIDS.

**1 VIRAL STRUCTURE**  
Before attachment, the virus's envelope contains a capsid that carries the genetic material. With this material, which contains RNA, the virus will begin to act on the lymphocyte's DNA. The envelope that covers the capsid is made of protein.

**2 ATTACHMENT**  
Through certain receptors on the cell surface, the virus's proteins can link with proteins on the CD4-positive T lymphocyte. The glycoprotein gp120 that covers the virus enables it to fuse with the lymphocyte.

**9 MATURATION**  
The protease enzyme finalizes the process of "cutting" the protein chains into individual proteins. When these combine, they make the HIV functional again and allow it to invade another cell.



## Protease Inhibitor

The drug used to prevent the action of the protease (spheres) attaches to the protease enzyme of the HIV (yellow). The protease inhibitor's power lies in stopping or slowing the formation of specific proteins that are necessary for the synthesis and function of viral DNA. In many cases, protease inhibitor drugs are combined with other medicines, such as antiretroviral drugs.

**8 MIGRATION**  
The virus completely detaches from the infected cell and is free once again. It contains a structure identical to the original.

## Reduction

of lymphocytes occurs through infection with HIV. The immune system weakens, and the defenses are lowered. Vulnerability to diseases increases.

**3 INVASION**  
The virus penetrates the cell and infects it. The capsid is released, and with it goes all the genetic material (RNA) necessary to begin the process of transcription of RNA into viral DNA.

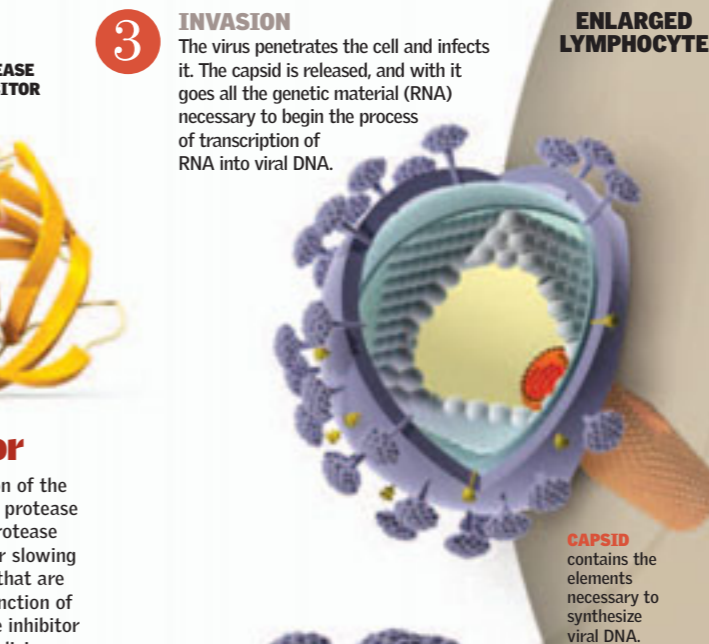
**7 OUTWARD PUSH**  
The new virus model begins to come out of the infected cell. It takes part of the cell membrane with it.

**6 SYNTHESIS**  
Viral protein chains begin to be synthesized. The protease cuts these chains and converts them into individual proteins.

**5 INTEGRATION**  
Integrase inserts the viral DNA into the DNA strand of the lymphocyte. The normal activity of the white blood cell changes because of the new DNA.

**5 HIV DNA**  
Formed by reverse transcriptase from the RNA content in the capsid

**4 TRANSCRIPTION**  
The RNA serves as a mold to synthesize viral DNA. Reverse transcriptase produces the DNA, preparing it to be inserted into the structure of the CD4 T lymphocyte.





# Advanced Technology

## VIRTUAL REALITY

This image shows a microscopic submarine, small enough to travel through an artery.

## EARLY DIAGNOSIS 80-81

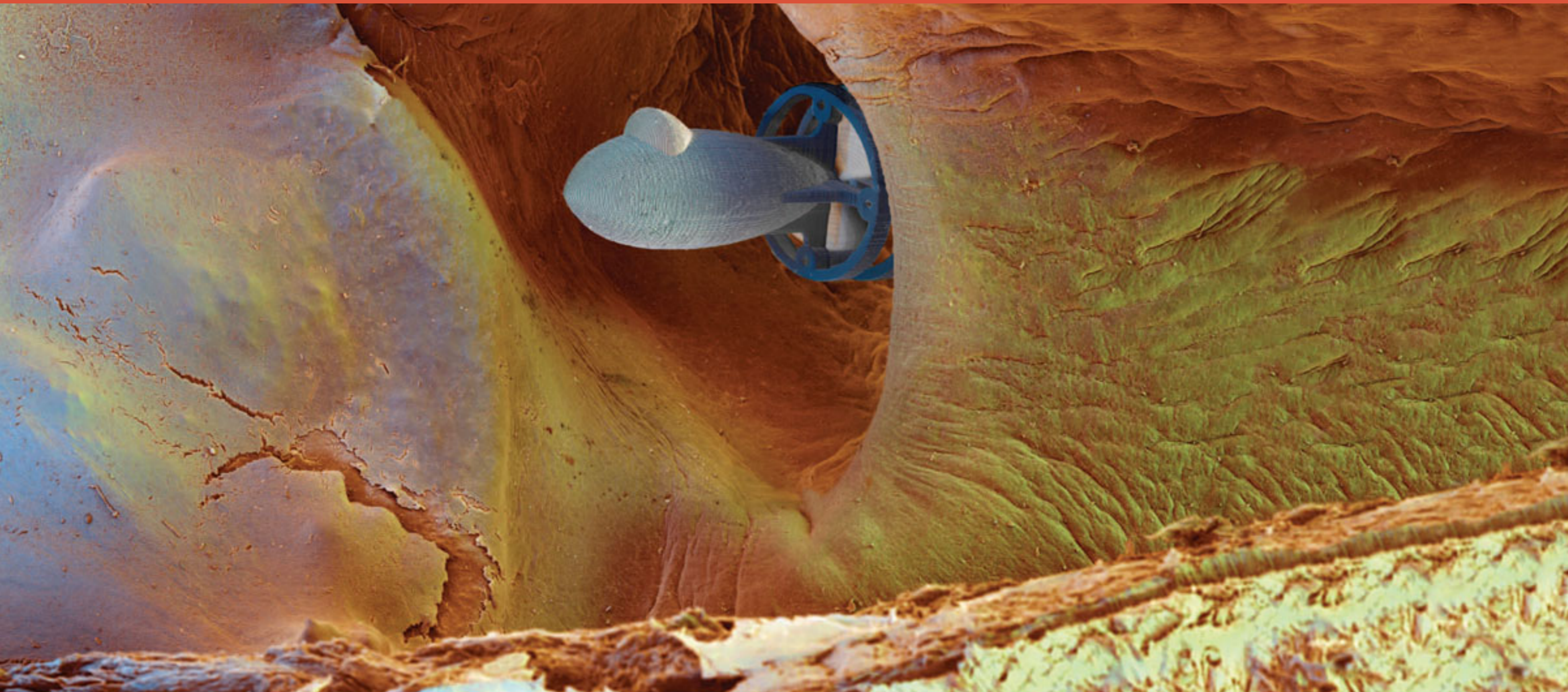## LASER SURGERY 82-83

## TRANSPLANTS 84-85

## ARTIFICIAL ORGANS 86-87

## NANOMEDICINE 88-89

## EN ROUTE TO ETERNITY 90-91



**T**echnology, in the service of medicine, has permitted the understanding and prevention of many serious diseases thanks to the study of early diagnostic

techniques, such as magnetic resonance imaging and positron emission tomography, which provide images of the interior of the body. Future decades, however, promise to bring even more

exciting developments. In this chapter, we will tell you about exciting developments like nanomedicine, whose main objective is to cure diseases from inside the body. For this purpose, devices smaller in

diameter than a human hair have been developed. Among other dreams in the minds of scientists is that of preventing the degeneration of nerve cells. Enjoy the fascinating information offered in this chapter! ●



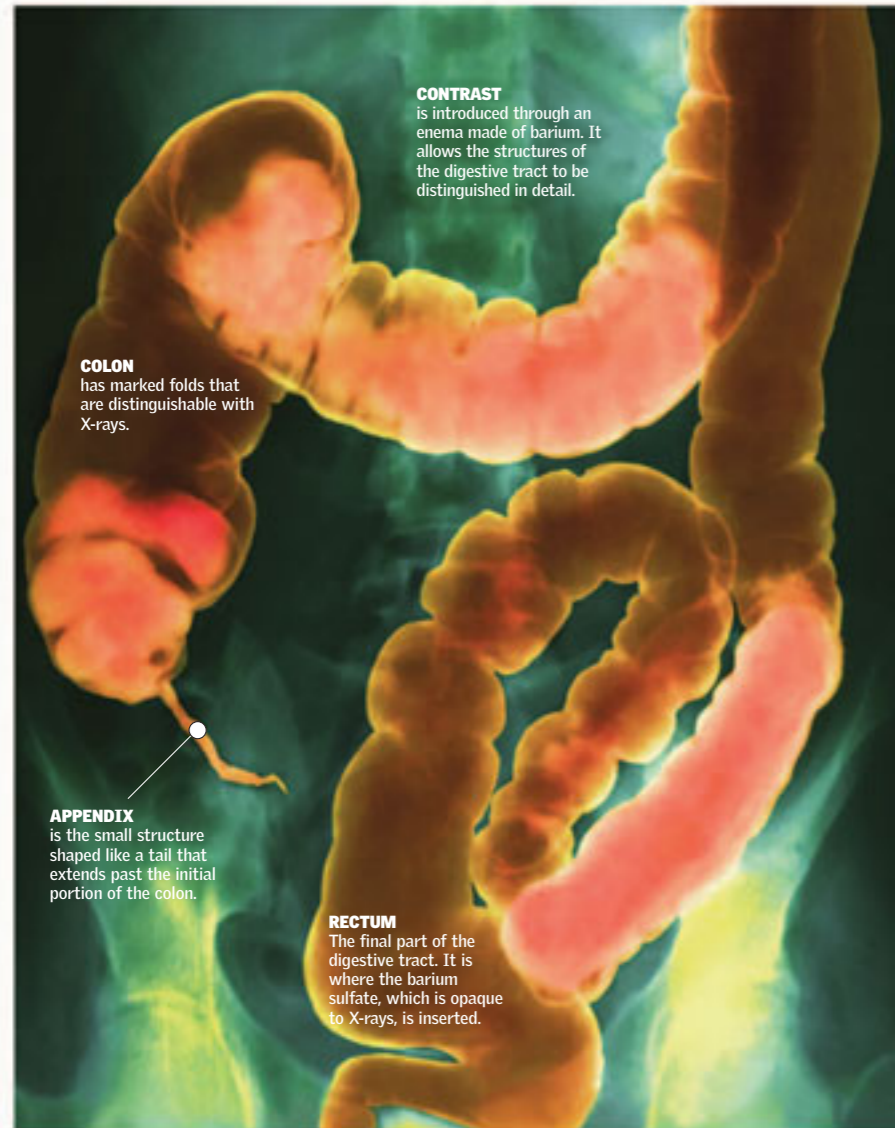
# Early Diagnosis

There are various methods of examining the body to search for possible diseases. One of the most novel procedures is positron emission tomography (PET), which is able to detect the formation of a malignant tumor before it becomes visible through other methods. It is also useful for evaluating a person's response to a specific treatment and for measuring heart and brain function. ●

## X-Rays

The simple emission of X-rays consists of sending out short electromagnetic waves. After passing through the body, they reach a photographic film and create shadow images. The denser structures, like bone, absorb more X-rays and

appear white, whereas the softer tissues appear gray. In other cases, a fluid must be used to fill hollow structures and generate useful images. To examine the digestive tract, for example, a barium sulfate mixture must be ingested.



**CONTRAST** is introduced through an enema made of barium. It allows the structures of the digestive tract to be distinguished in detail.

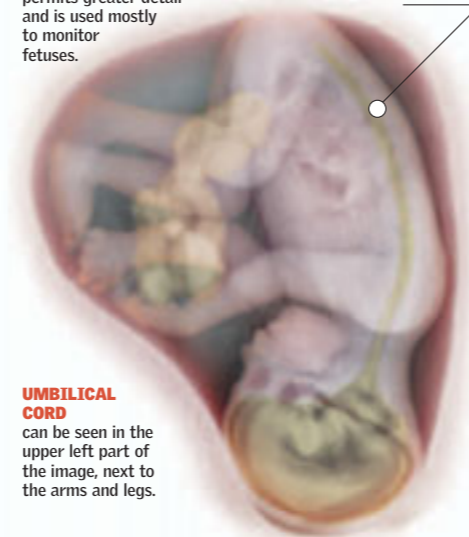
## Scanning Methods

The different techniques for exploring the body aim to detect possible anomalies in the organs and tissues. The latest developments, such as magnetic resonance imaging and positron emission tomography, have surpassed classic X-ray methods. It is now possible to obtain detailed images of tissues and of the metabolic activity of tumor cells.

### 3-D MAGNETIC RESONANCE IMAGING

permits greater detail and is used mostly to monitor fetuses.

**SPINAL CORD** Visible and colored green, like the brain




**UMBILICAL CORD** can be seen in the upper left part of the image, next to the arms and legs.

## Ultrasound


A device called a transducer emits extremely high frequency sound waves. The transducer is passed back and forth over the

part of the body being examined. The sound waves return to the transducer as an echo and are analyzed by a computer.



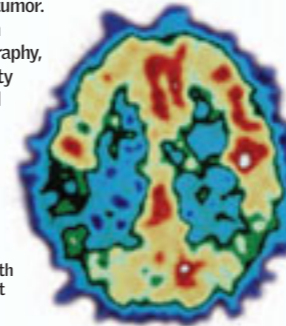
## Encapsulated Camera

A miniature camera enters the body through a capsule and takes detailed pictures of the digestive tract. It travels using the natural movements of the intestinal walls.



## Positron Emission Tomography

This technology enables doctors to obtain detailed information about metabolic issues, such as the cell activity of a tumor. When combined with computerized tomography, it provides high-quality images and advanced knowledge regarding diseases such as cancer. This way, it may be possible to detect an illness before it spreads.



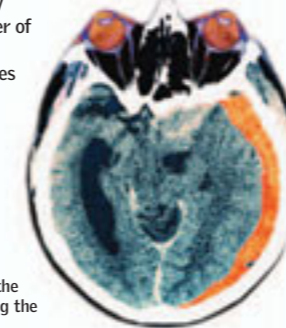
### METABOLIC ACTIVITY

This scan shows the activity in a brain with Alzheimer's disease. There are few zones with high activity (red); most are low (blue-green).

## Computerized Tomography

Computerized tomography (CT) provides information about regions denser than those typically penetrated by X-rays. The tomography covers each millimeter of the body's contour, providing many images of cross sections of the body. By

combining these images, a three-dimensional grayscale picture of a particular organ can be obtained.



### INTERNAL HEMORRHAGE

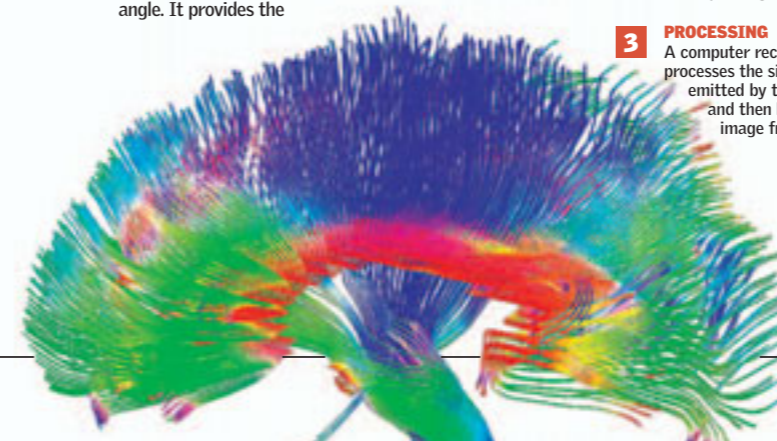
In this CT scan, a hematoma (in orange) can be seen that was formed from a blood clot after an injury to the membranes surrounding the brain.

## Magnetic Resonance Imaging

A technique that uses a cylindrical chamber capable of producing a magnetic field 40,000 times stronger than the Earth's. Unlike X-rays, magnetic resonance allows imaging of soft tissues (like fat) and from every angle. It provides the

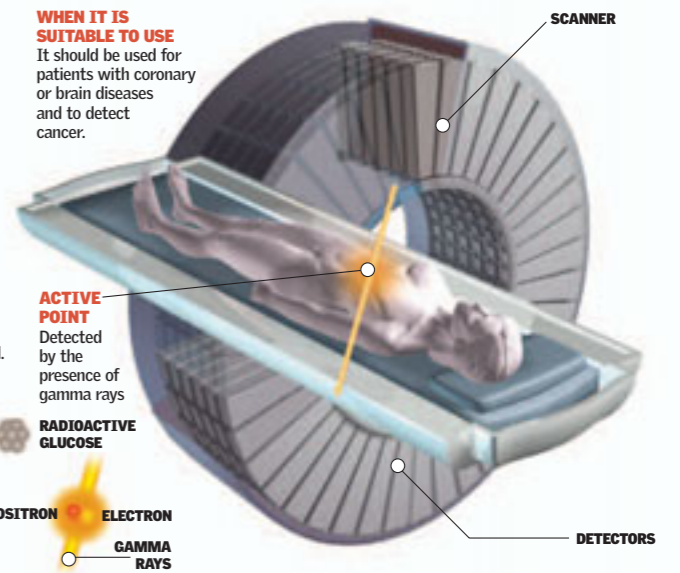
most detailed images and is used most frequently for examining the brain.

**BRAIN** The fibers of the nerve cells that transmit electrical signals are shown in color.



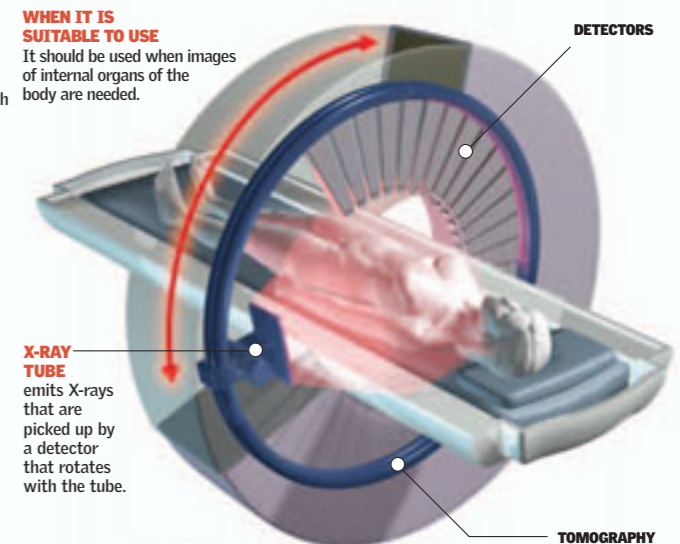
## HOW IT WORKS

- 1 INJECTION** The patient receives a dose of radioactive glucose, or FDG, which is taken up by affected organs.
- 2 POSITRONS** The active tumors take up large amounts of glucose. When the FDG decays, it emits positrons.
- 3 GAMMA RAYS** are emitted when the positrons collide with electrons and are annihilated.
- 4 IMAGES** A computer receives the rays and converts them into images that provide details about possible tumors.



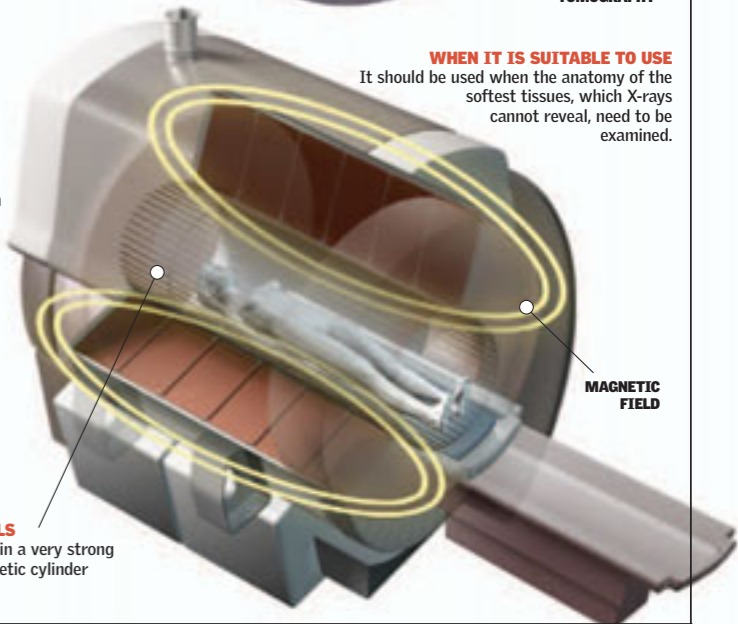
## HOW IT WORKS

- 1 SCAN** The patient enters the tomography machine through an opening that divides the body contour into sections.
- 2 X-RAY TUBE** rotates simultaneously with the detector to completely X-ray the patient.
- 3 RECEPTION** The detectors sense the intensity of the rays as they pass over each point of the body.
- 4 IMAGE** The information is processed by a computer that integrates the data into images.



## HOW IT WORKS

- 1 MAGNETIC FIELD** acts on the hydrogen atoms of the body when the patient enters the magnetized chamber.
- 2 RADIO WAVES** are applied to the hydrogen atoms. Upon receiving these waves, they emit a corresponding radio wave.
- 3 PROCESSING** A computer receives and processes the signals emitted by the atoms and then builds an image from them.





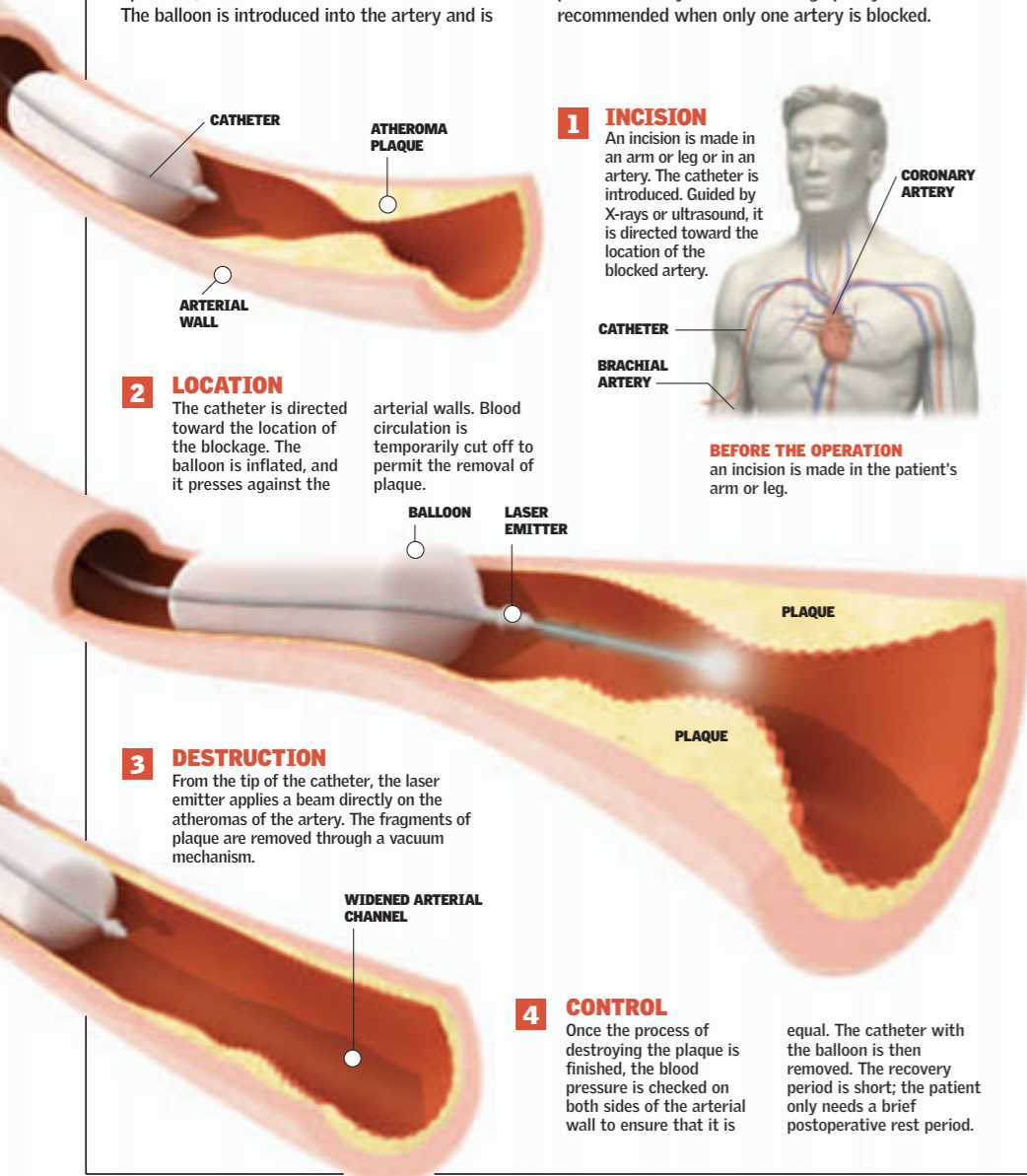
# Laser Surgery

**S**urgeries performed with laser beam techniques are much simpler than traditional procedures. Lasers are frequently used in eye surgery. They can close blood vessels in the retina. Lasers can also burn papillomas (benign epithelial tumors) and excise precancerous lesions from the mouth without scarring. Currently lasers are used to break down kidney stones and to open clogged arteries. ●

## Laser Angioplasty

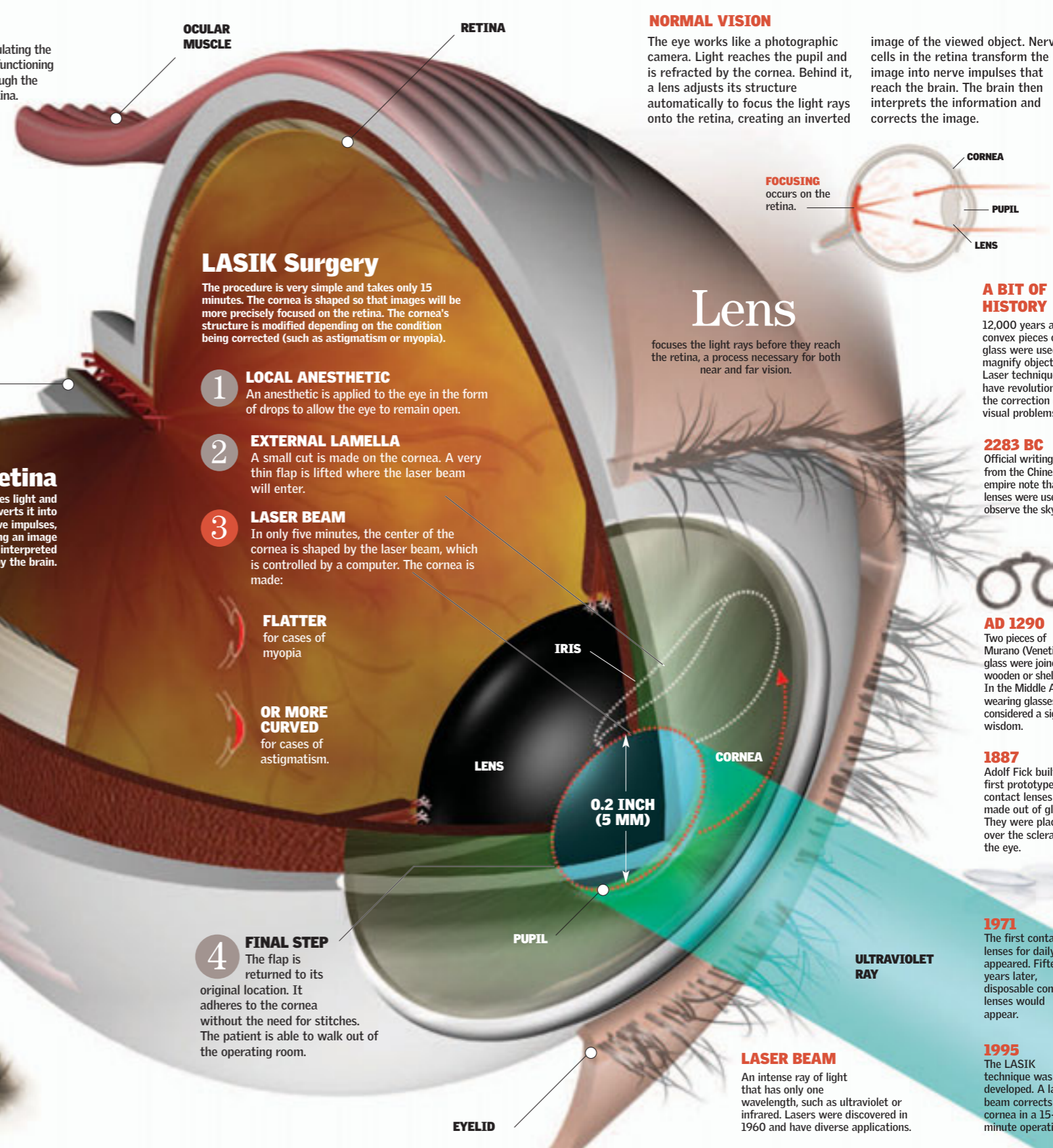
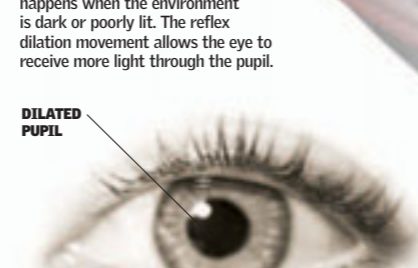
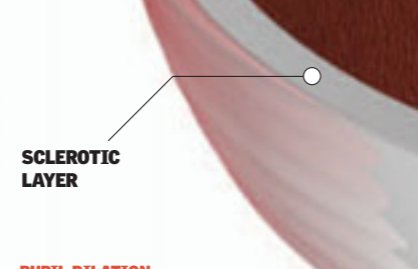

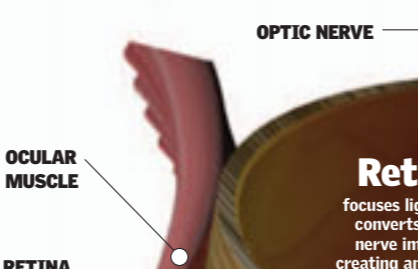
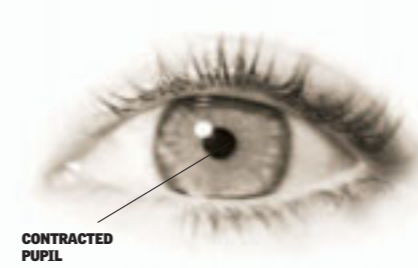
When fatty deposits (atheromas) accumulate in the arteries, plaque forms, and the internal channel for blood flow narrows. Laser angioplasty can be used to eliminate this plaque. In this operation, a catheter with a small balloon is used. The balloon is introduced into the artery and is

inflated to momentarily cut off the circulation. The plaque is removed easily by a laser emitter located at the tip of the catheter. The laser angioplasty operation is quick, and the patient's recovery period is usually short. Laser angioplasty is recommended when only one artery is blocked.



## Pupil Contraction

The pupil plays an important role in regulating the light that enters the eye. In a normally functioning eye, light enters through the pupil, passes through the cornea and the lens, and finally reaches the retina. When the ambient light is intense, the pupil contracts. This causes the eye to receive less light and prevents glare. The contraction of the pupil is a reflex action.



## LASIK Surgery

The procedure is very simple and takes only 15 minutes. The cornea is shaped so that images will be more precisely focused on the retina. The cornea's structure is modified depending on the condition being corrected (such as astigmatism or myopia).

**1 LOCAL ANESTHETIC**  
An anesthetic is applied to the eye in the form of drops to allow the eye to remain open.

**2 EXTERNAL LAMELLA**  
A small cut is made on the cornea. A very thin flap is lifted where the laser beam will enter.

**3 LASER BEAM**  
In only five minutes, the center of the cornea is shaped by the laser beam, which is controlled by a computer. The cornea is made:

**FLATTER**  
for cases of myopia

**OR MORE CURVED**  
for cases of astigmatism.

**4 FINAL STEP**  
The flap is returned to its original location. It adheres to the cornea without the need for stitches. The patient is able to walk out of the operating room.



# Transplants

When the possibilities for treating certain diseases run out, the only remaining alternative is to replace the sick organ with another one through a transplant. The organs can come from a live person (as long as it does not cause harm to that person, as in the case of kidney donation) or from a donor corpse. Today the most novel transplant is the face transplant, which involves working with many nerves and is highly complex. ●

## The Mouth and Nose of Another Person

The operation for replacing the damaged face (generally due to burns) is still in its developing stage. The first recorded case of a successful transplant was that of Isabelle Dinoire, a French woman who lost her nose, her chin, and her lips when she was savagely attacked by her dog in 2005. The surgery was partial, and it restored those parts she had lost with skin donated by a sick woman suffering a case of cerebral coma. The

complex operation included the ligation of blood vessels and nerves between the donating tissue and the beneficiary.

**The nerves** can only be joined through microsurgery. The operation is very complicated because the face is full of nerve endings.

**REMOVAL**  
The skin of the patient's face is removed. A wide range of injuries can be treated with this surgery. The transplant can be partial or total. In France, a woman attacked by a dog lost her nose, lips, and chin and underwent a partial face transplant to recover these parts.

**PREPARATION**  
Since the face is a complex framework of blood vessels, capillaries, arteries, and veins, care must be taken during the insertion of the new face. The original muscles and nerves are left on the patient. Blood vessels are cut before the surgery. Later they will be joined to the donated skin.

**ALIGNMENT**  
The surgeons position the donated skin, aligning it exactly over the face of the patient. Through microsurgery, the blood vessels and nerves are connected to the new tissue. As the blood begins to circulate, the face takes on a progressively pinker color, characteristic of tissue with normal blood supply.

**RESTORATION**  
The skin is sutured, as shown in the image. The areas should normalize within 14 days. After the surgery, the patient usually requires psychological treatment

to better cope with the idea that he or she now possesses a "hybrid" face, with his or her own bone structure, but the skin and fatty tissues of someone else.

## Organ Transplants

Of the two types of transplant operations (organs and tissues), organ transplants are by far the more difficult. They require complex surgeries to achieve the splicing of vessels and ducts. Tissue transplants are simpler: cells are injected, to be implanted later.

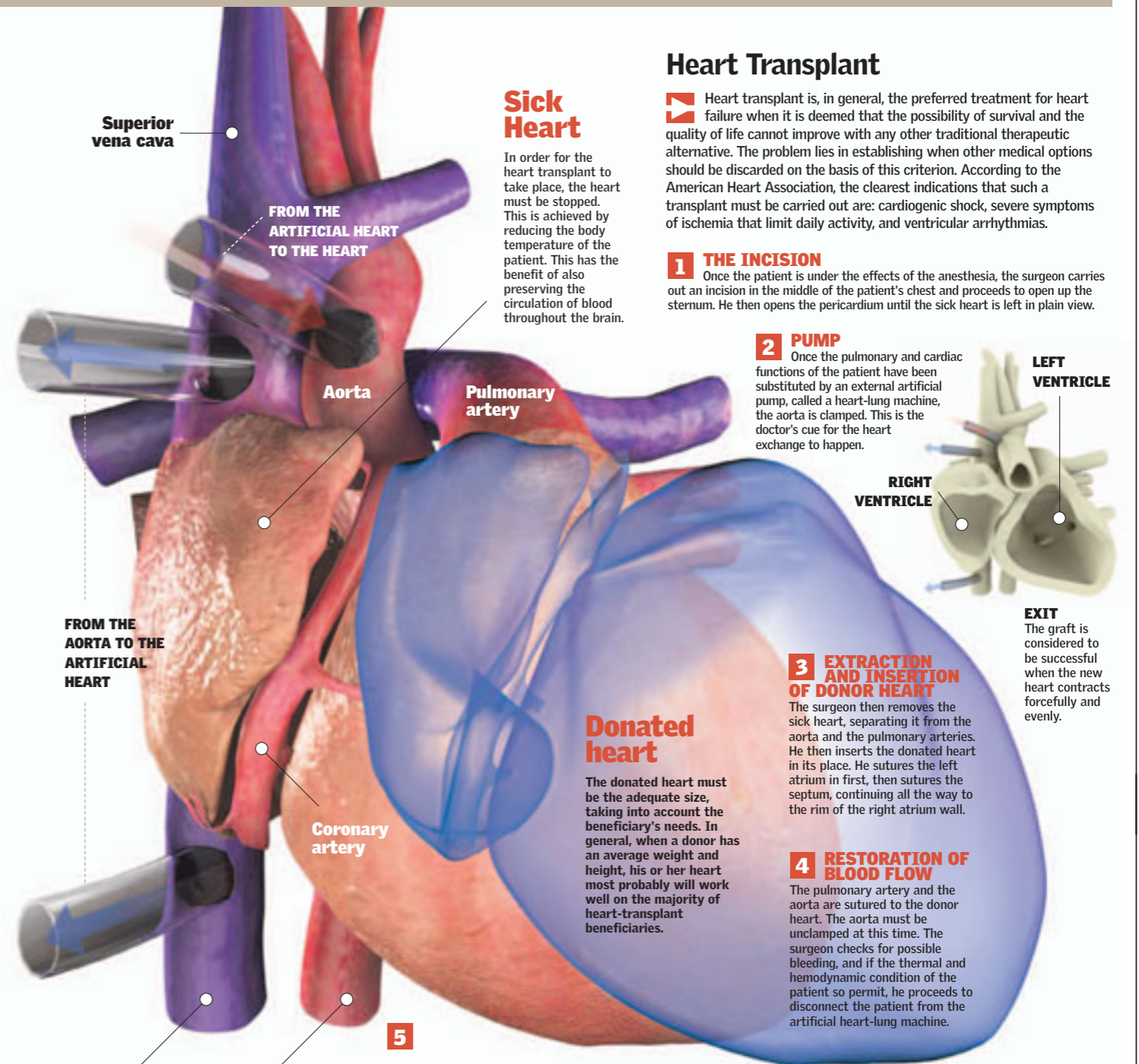
### TYPES OF TRANSPLANTS

**Allograft:** Consists of the donation of organs from one individual to another genetically different individual of the same species.

**Autograft:** A transplant in which the donor and the recipient are the same person. The typical case is a skin graft from a healthy site to an injured one.

**Isograft:** A transplant in which the donor and the recipient are genetically identical.

**Xenograft:** A transplant in which the donor and the recipient are of different species (e.g., from a monkey to a human). This type generates the strongest rejection response by the body of the recipient.



### Sick Heart

In order for the heart transplant to take place, the heart must be stopped. This is achieved by reducing the body temperature of the patient. This has the benefit of also preserving the circulation of blood throughout the brain.

## Heart Transplant

Heart transplant is, in general, the preferred treatment for heart failure when it is deemed that the possibility of survival and the quality of life cannot improve with any other traditional therapeutic alternative. The problem lies in establishing when other medical options should be discarded on the basis of this criterion. According to the American Heart Association, the clearest indications that such a transplant must be carried out are: cardiogenic shock, severe symptoms of ischemia that limit daily activity, and ventricular arrhythmias.

### 1 THE INCISION

Once the patient is under the effects of the anesthesia, the surgeon carries out an incision in the middle of the patient's chest and proceeds to open up the sternum. He then opens the pericardium until the sick heart is left in plain view.

### 2 PUMP

Once the pulmonary and cardiac functions of the patient have been substituted by an external artificial pump, called a heart-lung machine, the aorta is clamped. This is the doctor's cue for the heart exchange to happen.

### 3 EXTRACTION AND INSERTION OF DONOR HEART

The surgeon then removes the sick heart, separating it from the aorta and the pulmonary arteries. He then inserts the donated heart in its place. He sutures the left atrium in first, then sutures the septum, continuing all the way to the rim of the right atrium wall.

### 4 RESTORATION OF BLOOD FLOW

The pulmonary artery and the aorta are sutured to the donor heart. The aorta must be unclamped at this time. The surgeon checks for possible bleeding, and if the thermal and hemodynamic condition of the patient so permit, he proceeds to disconnect the patient from the artificial heart-lung machine.

### Donated heart

The donated heart must be the adequate size, taking into account the beneficiary's needs. In general, when a donor has an average weight and height, his or her heart most probably will work well on the majority of heart-transplant beneficiaries.

### 5 INTENSIVE CARE

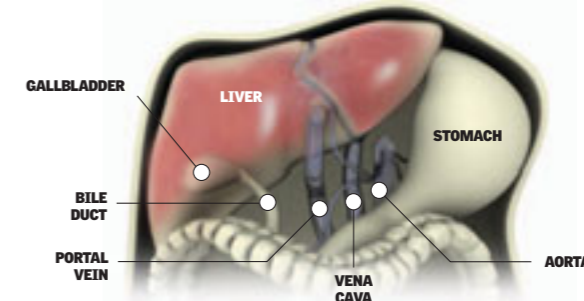
With the help of drainage tubes, the surgeon proceeds to close the breast incision. Finally, the patient, under

constant surveillance, is transported to the intensive care unit. Once the postoperative period is over, the patient is released and

begins a supervised ambulatory program in which he or she resumes physical movement such as walking.

## Liver Transplant

People who suffer advanced, irreversible, life-threatening hepatic conditions now have the possibility of attempting a liver transplant. The most typical liver transplant cases are those of people who suffer chronic hepatitis or primary biliary cirrhosis, an autoimmune disease. Patients must not be infected in any way and cannot be suffering from any cardiac or pulmonary disease at the time.



### 1 DONATED LIVER

The organ, along with all its blood vessels and its bile duct, is removed immediately after the death of the donor.

### 2 THE NEW LIVER

is fused with the vena cava and the rest of the blood vessels. The opposite ends of the bile duct are sutured. A probe is inserted inside the reconstructed bile duct to drain the blood and the bile.



# Artificial Organs

The search for alternative solutions to save human lives has reached its maximum development thus far with the construction of artificial organs. The AbioCor artificial heart is currently being improved, and it is expected that by 2008 it will have a useful life of five years. Similarly bionics has made it possible for blind persons to perceive images through impulses transmitted to the brain by video footage from a camera that acts as a retina. ●

## The Development of Bionics

Advancements in bionics have begun to fulfill the wish that has been searched for in recent years: artificial organs literally identical to the natural ones—that is, organs that will not come with a limited useful life like other electronic devices. The world has already witnessed 16 successful bionic eye implants, and bionic arms are currently under

development. Jesse Sullivan, the first bionic man, is able to control his artificial arms with his brain: the nerves of the lost arms were embedded in his chest, and when the patient thinks about closing his fist, a portion of the muscles in his chest contract, and the electrodes that detect the muscle activity “tell” the bionic arm to close the fist.

### A BIONIC EYE

A microchip is placed at the back of the human eye. It is connected to a miniature video camera, which captures images that the chip later processes. The information is then sent as impulses to the brain, which interprets them.

### ARMS

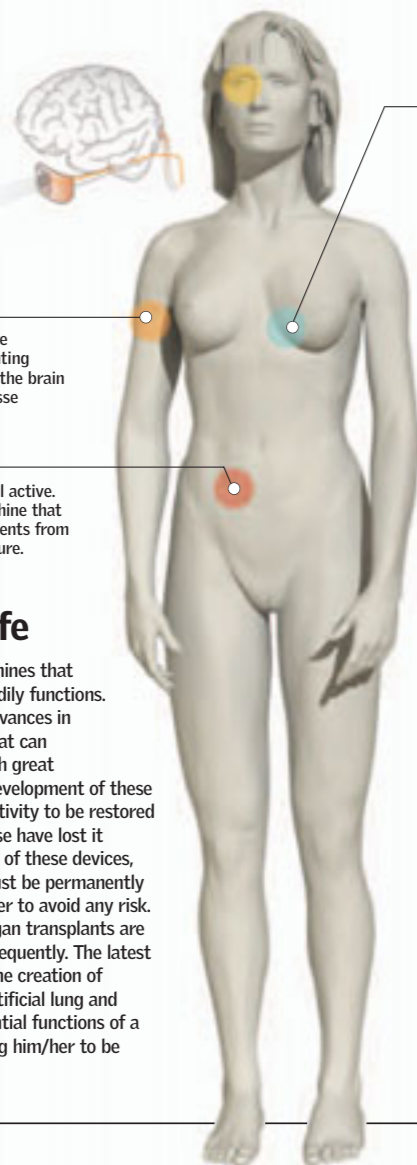
Today surgeries for prosthetics are common. The possibility of implanting joints that could be controlled by the brain was achieved with the case of Jesse Sullivan in 2001.

### ARTIFICIAL KIDNEY

Research to improve dialysis is still active. The patient is connected to a machine that removes impurities and toxic elements from the blood in the event of renal failure.

## Machines of Life

There are currently machines that can replace damaged bodily functions. Scientific developments and advances in bionics have created devices that can functionally replace organs with great effectiveness. The successful development of these machines has allowed organ activity to be restored in patients who would otherwise have lost it forever. The clear disadvantage of these devices, however, is that the patient must be permanently attached to the machine in order to avoid any risk. To overcome this limitation, organ transplants are being sought more and more frequently. The latest medical advancements led to the creation of artificial organs, such as the artificial lung and heart, which can perform essential functions of a patient's body without requiring him/her to be connected to a bulky machine.



### ARTIFICIAL LUNG

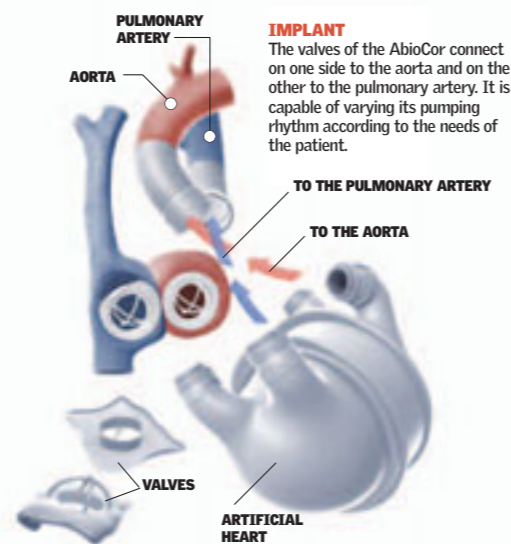
It consists of an intravenous device that permits breathing. It is inserted in a vein in the leg and is later positioned inside the vena cava, the largest vein for blood return to the heart. Fibrous membranes introduce oxygen into the body and remove carbon dioxide from it. Although not intended for prolonged use, it helps provide information that can guide future studies.

### Heart 2006

The AbioCor heart was designed especially to support a patient's circulatory system and to prolong the lives of people who would otherwise die from cardiovascular failure. The heart, developed by Abiomed, is completely implantable in the body.

## Artificial Heart

AbioCor was a milestone in the development of the artificial heart. Unlike its predecessor, the Jarvik-7, AbioCor is the first mechanical heart that can be totally self-contained in the patient's body. It functions almost exactly the same as a natural heart. It has two ventricles and two valves that regulate blood circulation. The AbioCor heart is powered without the need for cables or tubes that pass through the patient's body.



## HISTORY OF THE ARTIFICIAL HEART

**1 JARVIK-7**  
Robert Jarvik designed the first artificial heart, which was placed inside a patient in 1982. The Jarvik-7 functioned with an external air compressor, which provided power.

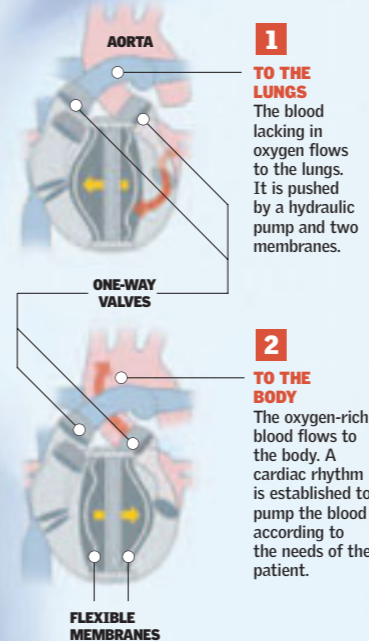


**2 ABIOCOR**  
Unlike its predecessor, the AbioCor does not require an external power source. It was the first artificial heart to be fully implanted into a patient. It is still being developed, and scientists are attempting to extend its useful life to five years. It has already been authorized for use in the United States.



### PUMPING SYSTEM

The heart developed by Abiomed is based on a hydraulic pump located at the center. Powered by a battery, the artificial heart reproduces the natural heart's performance almost identically. The deoxygenated blood goes to the lungs, and the oxygenated blood goes to the body.



**1 TO THE LUNGS**  
The blood lacking in oxygen flows to the lungs. It is pushed by a hydraulic pump and two membranes.

**2 TO THE BODY**  
The oxygen-rich blood flows to the body. A cardiac rhythm is established to pump the blood according to the needs of the patient.

### WITHOUT INCISIONS


The transcutaneous energy transfer (TET) system allows the battery to transfer energy to an internal battery through the skin. This way, potential infections caused by maintaining an opening in the abdomen are avoided.



2

## AbioCor Heart

is made up of two ventricles with valves. Each ventricle pushes 2 gallons (8 l) of blood a minute and emits 100,000 beats in a day. The right ventricle pushes the blood toward the lungs, and the left one pushes it toward the rest of the vital organs and the body. The operation of the mechanical heart replicates that of a natural heart. It is made of titanium and plastic.



5

### INTERNAL BATTERY

recharges directly from the external battery. It allows the patient a certain degree of autonomy, since it can run for an hour and a half without needing to connect to the external battery at the waist.



3



4

### CONTROL SYSTEM

regulates the rhythm with which the artificial heart pumps the blood. Depending on the needs of the patient, it can be increased or decreased. The internal control system is an electronic device capable of detecting any type of anomaly and making it known so that the patient can act on it.

1

### EXTERNAL BATTERIES

prevent the use of tubes, and the patient does not have to be immobilized. This source of power eliminates the need to connect to external machines to recharge the batteries. The device is worn at the waist and is portable.



# Nanomedicine

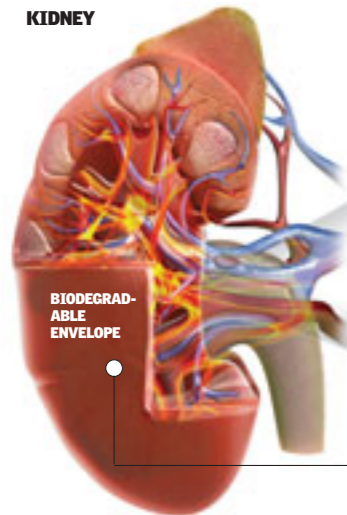
The prefix "nano" indicates the scale on which the latest scientific developments are taking place: one billionth of a meter. From nanotechnology, advances have appeared in what is called nanomedicine. The main objective of this variant of nanotechnology is to obtain cures for diseases from inside the body and at a cellular or molecular level. Devices smaller than the diameter of a human hair have even been developed.

## Nano-scaffolds for Regenerating Organs

The latest developments regarding the possibility of creating organs starting from a patient's own cells have demonstrated that by 2014 it may be possible to obtain a natural kidney simply through cellular regeneration rather than through a transplant. Beginning with biodegradable nanomolds, different organs could be created. The latest developments were able to produce a

regenerated bladder in 1999. After being created, it was implanted successfully in seven patients. The procedure was done by doctor Anthony Atala of Wake Forest University. A section of a kidney that secretes a substance similar to urine has already been produced. Millions of nephrons still need to be regenerated, however, to achieve a fully functional kidney.

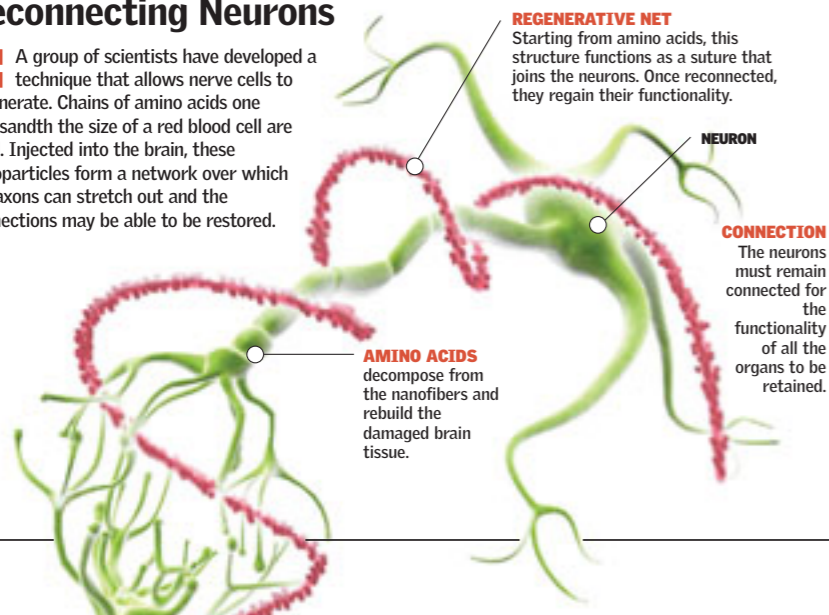
### KIDNEY



- CELL CULTURE**  
Cells from the patient's own kidney are taken to prepare for their insertion into the mold that will be used to reconstruct the organ.
- MOLD**  
A biodegradable mold is made in the shape of the kidney, in which the cells will be implanted and begin to grow. Then the blood vessels that will feed the organ will begin to develop.
- FUNCTIONAL KIDNEY**  
When the vessel system is completely developed and the organ receives sufficient blood, the biodegradable mold disappears.

## Reconnecting Neurons

A group of scientists have developed a technique that allows nerve cells to regenerate. Chains of amino acids one thousandth the size of a red blood cell are used. Injected into the brain, these nanoparticles form a network over which the axons can stretch out and the connections may be able to be restored.



**REGENERATIVE NET**  
Starting from amino acids, this structure functions as a suture that joins the neurons. Once reconnected, they regain their functionality.

**NEURON**

**CONNECTION**  
The neurons must remain connected for the functionality of all the organs to be retained.


**AMINO ACIDS**  
decompose from the nanofibers and rebuild the damaged brain tissue.

## Nanotechnology

By working at the scale of a nanometer (10<sup>-9</sup> meters), nanotechnology can currently be used in numerous areas of electronics, optics, and biomedicine. This state-of-the-art development builds devices so small that they can only be measured on the molecular scale. Today the most important and safest advances are the nanodevices used to detect cancer in its early stages. The nanoparticles can be between 100 and 10,000 times smaller than a human cell. Their size is similar to that of the larger biological molecules, such as enzymes. Nanoparticles smaller than 50 nanometers can easily enter any cell, while those smaller than 20 nanometers can move outside the blood vessels and circulate throughout the body.

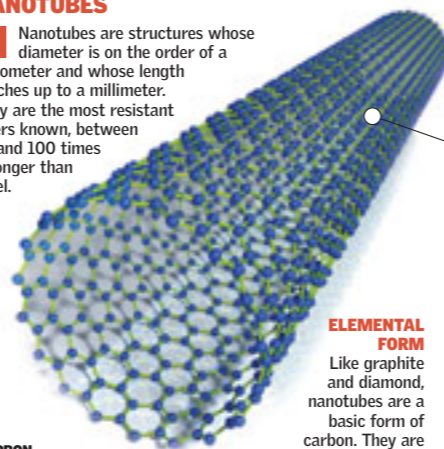
### MICROSCOPIC MOTOR

Smaller in diameter than a hair and 100 times thinner than a sheet of paper, micromotors are the basis for tiny machines that could travel through the body and destroy tumors or bacteria in their paths.



### NANOTUBES

Nanotubes are structures whose diameter is on the order of a nanometer and whose length reaches up to a millimeter. They are the most resistant fibers known, between 10 and 100 times stronger than steel.

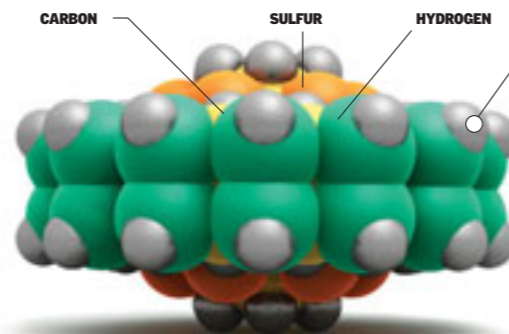


**ELEMENTAL FORM**  
Like graphite and diamond, nanotubes are a basic form of carbon. They are used in heavy industry.

### CARBON NANOTUBE

### NANOTECHNOLOGIC MOLECULE

Each sphere of the molecule represents an atom: carbon in yellow, hydrogen in green, and sulfur in orange. It is based on fullerenes.



MULTIPLES OF A METER IN DESCENDING ORDER  
METER DECIMETER CENTIMETER MILLIMETER  
MICROMETER NANOMETER ANGSTROM  
PICOMETER FEMTOMETER ATTOMETER  
ZEPTOMETER YOCTOMETER

30,000 nanometers

### Scales

Nanotechnologies can reach unimaginably small dimensions. The developments achieved to this day have been at the level of a micrometer, which corresponds to a fraction of a cell, and of a nanometer, which corresponds to a particle (about the size of five molecules of water) scale.

### MILLIMETER

Equivalent to a thousandth of a meter. Abbreviated mm.  
10<sup>-3</sup>m

### MICROMETER

Equivalent to a millionth of a meter. Abbreviated μm.  
10<sup>-6</sup>m

### NANOMETER

Equivalent to a billionth of a meter. Abbreviated nm.  
10<sup>-9</sup>m

### ANGSTROM

Equivalent to one ten billionth of a meter. Abbreviated Å.  
10<sup>-10</sup>m

### A RELATIONSHIP OF SCALES

The relation between the diameter of a stem cell and that of a nanoparticle is similar in proportion to the relation between the diameter of a tennis ball and that of a small asteroid.

20,000 Nanometers

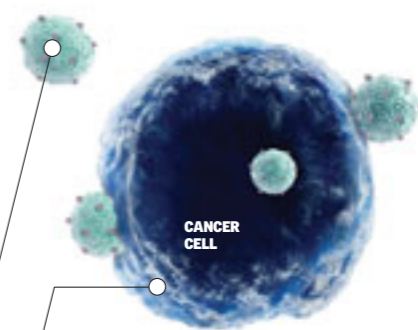
### EMBRYONIC STEM CELL

## Nanoparticles

The use of nanoparticles to combat diseases such as cancer has been carried out successfully in rats by scientists Robert Langer and Omid Farokhzad. The nanoparticles are one thousandth the size of the period at the end of this sentence. They are made up of carbon polymers that

directly attack the cancer cells and destroy them without harming surrounding healthy cells. They act like guided missiles. This approach would make it possible to surpass the complications of chemotherapy. It is estimated that its full development will be complete in 2014.

### NANOPARTICLE

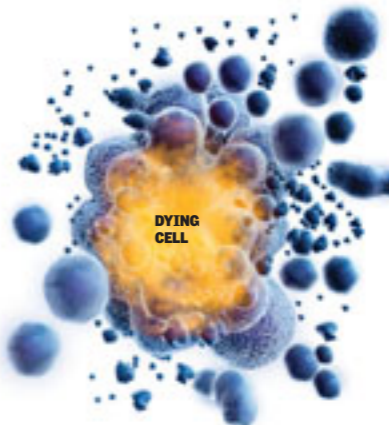
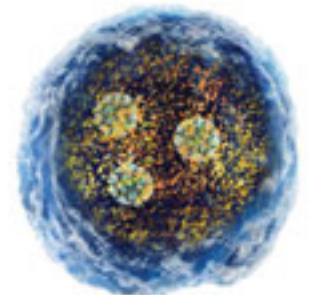


### 1 NANOSHIELDS

The small carbon "bombs" detect the cancer cells and go directly toward them. They adhere to the tumor and prepare for their second phase: unloading.

### 2 UNLOADING

Once the nanoparticles have entered the tumor, they release their carbon load, which contains instructions to destroy the cell.



### 3 EXPLOSION

The attacked tumor cells are destroyed, and they die. Unlike chemotherapy, the surrounding healthy cells are not harmed.

**NANOPARTICLES AND CELLS**  
To understand the scale at which nanoscipy works, we can compare the particles involved: a nanoparticle is to a cell what a grain of sand is to a football stadium.

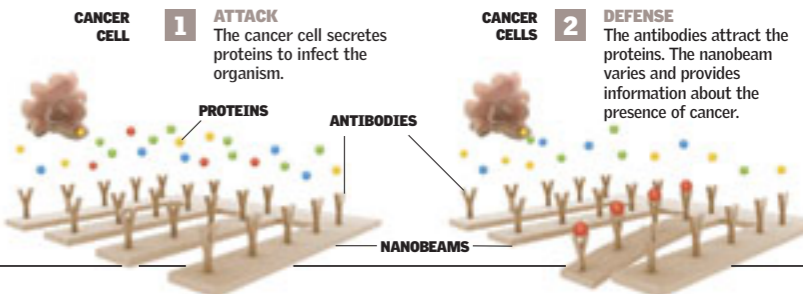


A GRAIN OF SAND IN A FOOTBALL STADIUM

## Nanosopic Beams

Small microscopic and flexible beams that are built with semiconductors using lithographic techniques. These beams are covered with molecules capable of adhering to specific DNA. If a cancer cell secretes its molecular

products, the antibodies placed on the flexible beams will bind to the secreted proteins. This generates a change in the physical properties of these beams, and researchers can read and interpret this information in real time.



### CANCER CELL

**1 ATTACK**  
The cancer cell secretes proteins to infect the organism.

### CANCER CELLS

**2 DEFENSE**  
The antibodies attract the proteins. The nanobeam varies and provides information about the presence of cancer.

### PROTEINS

### ANTIBODIES

### NANOBEAMS



# En Route to Eternity

The dream of an eternal body seems to dominate scientific study today. The possibility of building a nerve system from a network of cables, proposed through developments in neuroscience, and the building of metallic muscle systems are two examples of steps that are being taken in that

direction. According to some specialists, the future promises the creation of a bionic body, without ties to flesh. In this scenario, every health problem could be solved through metallic implants. There is even a study that explores the possibility of repairing DNA after cell death to assure the eternal youth of cells. ●

## DNA Repair

Biologist Miroslav Radman discovered that the bacteria *Deinococcus radiodurans* can be revived after being clinically dead,

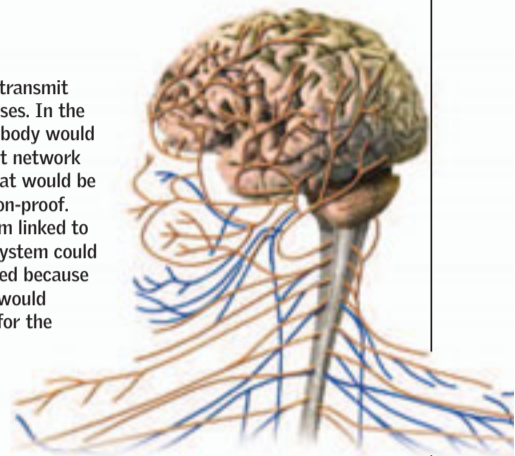
through the repair of its DNA. If DNA could be copied rapidly and the genome of dead human cells could be reconstructed, then the death of cells could be reversed, and all their organic functions could be restored: protein synthesis, lipids, and membranes.



## Self-Healing Cells

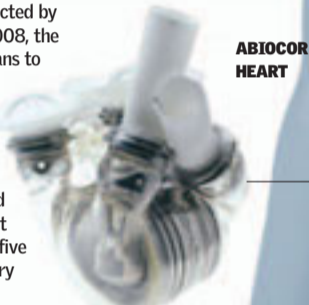
The dream of having a body in which there is no degeneration of nerve cells is on its way to becoming a reality: neuroscientist John Donoghue of Brown University is trying to re-create the nervous system through optical fibers. These fibers would

be used to transmit brain impulses. In the future, the body would be a perfect network of fibers that would be degeneration-proof. Any problem linked to the nerve system could be eliminated because the cables would substitute for the nerves.



## Artificial Organs

Today efforts continue to design artificial organs that could replace organs that have been damaged or affected by severe diseases. By 2008, the Abiomed company plans to have the AbioCor heart developed to perfection. Although initial trials have been unsuccessful, Abiomed plans to design a heart that lasts for at least five years. Even so, it is very expensive: at least \$100,000.

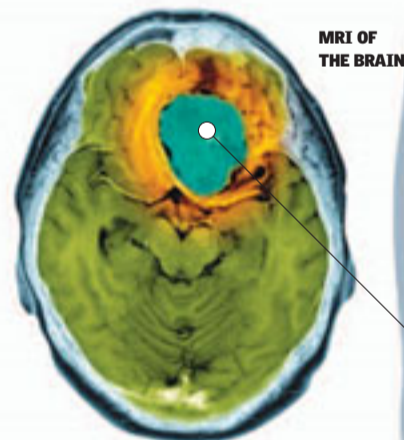
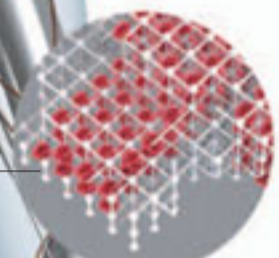


**4,000**  
The number of stem-cell transplants worldwide

## Organ Regeneration

Anthony Atala of Wake Forest University is the leading pioneer of organ-regeneration

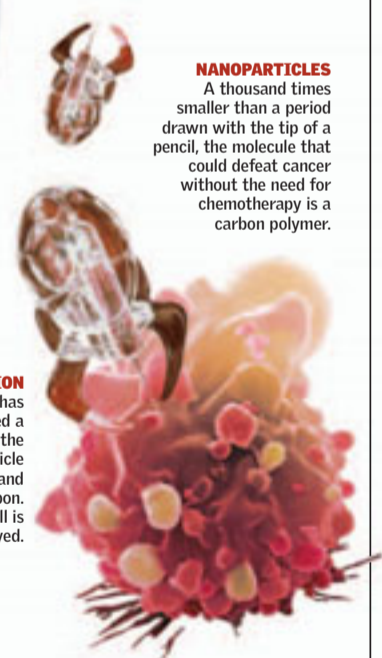
research. In 1999, he was able to re-create a bladder from cells extracted from other tissue. Atala and his team estimate that by 2014 great advancements will have occurred in the regeneration of the most complex organ: the kidney. Once a kidney can be regenerated, transplants and artificial organ implants will become a thing of the past.



**TUMOR**  
A meningioma appears in the magnetic resonance image. It can be removed with surgery.

**200 years**  
is predicted to be the estimated life expectancy by the 22nd century.

**NANOPARTICLES**  
A thousand times smaller than a period drawn with the tip of a pencil, the molecule that could defeat cancer without the need for chemotherapy is a carbon polymer.

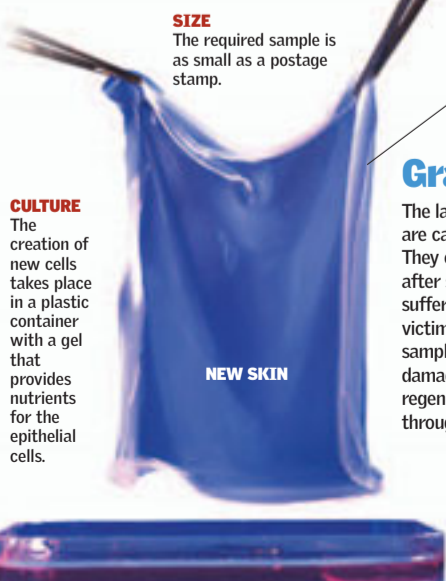

**INVASION**  
Once it has detected a cancer cell, the nanoparticle penetrates it and unloads its carbon. The sick cell is destroyed.

## Scan of the Body

The images obtained from magnetic resonance imaging (MRI) permit exploration of the body in 360 degrees. The most extensive use of MRI, however, is in the complete scanning of the brain to obtain a variety of images, which permits doctors to observe both the surface and the inside of

the brain. Magnetic resonance imaging is one of the most commonly employed medical techniques for obtaining accurate images of the different organs of the body. Its resolution capability permits even the scanning of tissues.



**SIZE**  
The required sample is as small as a postage stamp.

## Graft

The latest skin grafts are called autografts. They can save lives after severe injuries suffered by serious burn victims. From a small sample of healthy tissue, damaged tissue can be regenerated in three weeks through a cell culture.


**CULTURE**  
The creation of new cells takes place in a plastic container with a gel that provides nutrients for the epithelial cells.

## Cancer

If the studies by Robert Langer of the Massachusetts Institute of Technology (MIT) and Omid Farokhzad of Harvard University prove to be beneficial, chemotherapy will become a thing of the past. By using particles the size of amino acids (nanoparticles), cancer cells could be eliminated without harming the healthy cells located near

them. Like guided missiles, the molecules go directly to the infected cells. Carbon polymers have been successfully tested in rats to eliminate the cancerous cells by penetrating them and injecting their content. Tests are still in development, and scientists estimate that by 2014 it will be possible to apply these new drugs.

NANOPARTICLE



**60,000**

nanometric molecules would be necessary to cover the diameter of a human hair. Building devices at this level could speed up all kinds of treatment.

## Bionic Limbs

In 2005, the Rehabilitation Institute of Chicago performed the implantation of an artificial arm controlled by the brain. The University of Texas has been investigating an elastic metal that could replace natural

muscles. The artificial muscular system is 100 times stronger and more resistant than human tissue. If these developments work out, they would provide a way of successfully replacing damaged joints.



# Glossary

## Agonist

Chemical product that, in addition to combining with a receptor (such as an antagonist), stimulates it, producing an observable effect. The term is also applied to a muscle that carries out a specific movement.

## Allele

Variation of a gene in the population that codifies a specific trait. A diploid cell contains an allele from each parent for each characteristic.

## Allergen

Substance or material capable of provoking an allergic reaction.

## Alzheimer's Disease

A specific type of breakdown of the nervous system that causes cognitive disorders. It is related to advanced age.

## Angiogenesis

Growth (normal or abnormal, depending on the circumstances) of new blood vessels in an organ or tissue.

## Antagonist

Substance that inhibits or interferes with the action of other substances (hormones or enzymes). The term is also applied to muscles that, in the same anatomical region, act in opposite directions.

## Antibiotic

Medicine that kills certain microorganisms or that impedes their growth and spread. It is used to treat infections.

## Antigen

Substance that, when introduced into an animal body, results in defense reactions, such as the formation of antibodies.

## Aorta

The largest artery in the body, it starts in the left ventricle of the heart. It is called the thoracic aorta until it reaches the diaphragm, and below that it is called the abdominal aorta, where it later bifurcates into the iliac arteries.

## Arterial Hypertension

Elevated blood pressure, above 140 millimeters of mercury (systolic) and above 90 mm (diastolic).

## Artery

Each one of the blood vessels through which the blood travels from the heart to supply the whole body.

## Arthritis

Inflammation of the joint that could be the result of several causes.

## Atherosclerosis

The accumulation of lipids (especially cholesterol) in the internal walls of the arteries; one of the main causes of diseases of the circulatory system.

## Autonomous Nervous System

Part of the nervous system that regulates involuntary processes (heart rhythm, pupil dilation, stomach contractions, etc.). It includes the sympathetic and parasympathetic systems.

## Bacterium

Microscopic organism that divides in two to reproduce. There are bacteria that are innocuous, pathogenic, and even beneficial to the human body.

## Blastocyst

Cell mass, resulting from the division of the morula, that gives rise to the embryo.

## Calcification

Fixation of calcium, an essential trace element for the formation of bones.

## Cancer

Disease caused by the appearance and uncontrolled growth of a mass of abnormal tissue (malignant tumor).

## Cell Membrane

Flexible envelope of all living cells that contains the cytoplasm. The membrane regulates the exchange of water and gases with the exterior.

## Central Nervous System

Structure made up of the brain and the spinal cord.

## Cerebral Cortex

Made up of gray matter present on the surface of the brain. It is the largest part of the central nervous system. Many of the most advanced functions take place in this cortex.

## Cholesterol

Unsaturated lipid found in the body's tissues and in blood plasma. It is also found in elevated concentrations in the liver, spinal cord, pancreas, and brain. Cholesterol is ingested through some foods and is synthesized by the liver, then passed to the blood as HDL cholesterol, considered protective, or as LDL cholesterol, which in excess leads to the development of atherosclerosis.

## Chromosome

Structure that carries the genes. These exist in the nucleus of each eukaryotic cell.

## Cilia

Small cellular appendages shaped like hairs and used for locomotion in a liquid medium.

## Conception

The union of a sperm with an egg.

## Cytoplasm

Compartment in eukaryotic cells surrounded by the cell membrane.

## Dermatophytosis

Infection in the skin caused by some species of fungi.

## Diabetes

Chronic disease characterized by elevated levels of blood glucose due to metabolic disorders.

## DNA

Deoxyribonucleic acid. Organic molecule with the shape of a double helix that contains the coded genetic information of an individual.

## Dominance

Functional attribute of the genes by which they manifest their effect, regardless of the effect of the allele that accompanies them.

## Embryo

Product of fertilization of the egg by a sperm; it can develop into an adult organism.

## Endoplasmic Reticulum

Organelle made up of a network of membranes that joins the nucleus of a cell to the Golgi complex. Protein synthesis takes place in it.

## Enzyme

Protein that helps to regulate the chemical processes of a cell, usually triggering or accelerating a reaction.

## Erythrocytes

Red blood cells; they carry oxygen.

## Estrogens

Female hormones produced by the ovaries and by the adrenal glands. They stimulate the growth of cells in the endometrium, the ovaries, and the breasts.

## Fetus

The human body in gestation, after the third month and until birth.

## Flagellum

Filament-like structure that is found on some bacteria and is used for locomotion.

## Follicle

Sac-shaped gland located in the skin or in the mucous membranes.

## FSH

Follicle stimulating hormone. Female hormone involved in the ovulation process.

## Fungus

Live unicellular or multicellular organism belonging to the Fungi kingdom.

## Gene

Information unit of a chromosome; the sequence of nucleotides in a DNA molecule that carries out a specific function.

## Genome

The entire complex of chromosomes and their genes; the totality of the genetic material in a cell or individual.

## Genotype

Genetic constitution of a single cell or an organism with reference to a single characteristic or set of characteristics; the sum of all the genes present in an individual.

## Graft

Implantation into an organism of a portion of live tissue that comes from another organism or another part of the same one. Also, the portion of tissue to be implanted.

## Hemoglobin

Protein (globin) associated with a porphyrin that contains iron (heme group) and is found inside the red blood cells; it transports oxygen.

## Hormone

Product of gland secretion, its function is to stimulate, inhibit, or regulate the action of other glands, systems, or organs of the body.

## Immune System

Set of processes centered on the blood and the lymphatic system that is activated to defend the human body against diseases.

## Insulin

Hormone secreted by the pancreas that is responsible for the metabolism of glucose in the body.

## Ion

Atom of an element or a molecule that is electrically charged because it has gained or lost electrons from its normal configuration.

## Joint

The area where a bone or a skeletal organ comes together with another.

## Laser

From the acronym for Light Amplification by Stimulated Emission of Radiation, it is a luminous artificial emission of variable frequency. Its energy can be controlled because of the coherence of its beams.



## Leukocyte

White blood cell. A component cell of the blood, its main function is to defend the body from infectious agents.

## Lipids

Organic chemical compounds formed mostly by hydrogen and carbon. Cholesterol and edible oils are the best known.

## Lymph

Liquid that moves through the lymphatic system.

## Lymphatic System

Ensemble of lymphatic vessels and ganglia that is independent of blood flow. It acts as a regulator of osmotic equilibrium in the body and as an activator of the immune system.

## Lymphocyte

Belongs to the group of white blood cells. It is present in the blood and in the lymphatic system.

## Lymphoma

Neoplastic disease that originates in the lymphatic system.

## Meiosis

Type of cell division in which two successive cell divisions of the nucleus of a diploid cell result in four haploid nuclei. As a result of this mechanism, gametes or spores are produced.

## Metabolism

Set of chemical reactions that are constantly carried out by cells to synthesize complex substances from simpler ones or to degrade the former to obtain the latter, as in the digestive process, for example. The activity level of body functions at rest and while fasting is called basal metabolism.

## Metastasis

Spreading of a cancerous tissue, making it capable of attacking organs other than the one from which it originated.

## Mitochondria

Organelle that is bounded by a double membrane. Within the mitochondria, ATP is obtained from the decomposition of sugars and other substances—the final step in aerobic respiration.

## Mitosis

Division of a cell in which two identical cells are formed from the parent cell.

## Morula

Early stage in the development of a multicellular organism, made up of 16 to 64 cells. It gives rise to the blastocyst.

## Mycosis

Infection caused by fungi.

## Nanotechnology

Industrial technology that permits the fabrication of microscopic devices.

## Neurotransmitter

Chemical substances responsible for the transmission of the nerve impulse through the neuron synapses.

## Nucleus

Part of the cell inside the cytoplasm. The nucleus contains almost all the DNA in a cell.

## Osmosis

Diffusion of water through a semipermeable membrane.

## Ovulation

Release of the mature egg from the ovary through the fallopian tube.

## Oxyhemoglobin

Hemoglobin of arterial blood that is loaded with oxygen.

## Oxytocin

Female hormone produced by the hypothalamus, it is transported to the hypophysis and is later released into the bloodstream. In women, it is responsible for, among other functions, the milk-ejection reflex and uterine contractions.

## Parkinson's Disease

Neurological disorder caused by a deficit of the neurotransmitter called dopamine.

## Pectoral Angina

Oppressive pain located in the retrosternal region, caused by an insufficient flow of oxygenated blood to the cardiac muscle.

## Phenotype

Physical expression of a genotype.

## Platelet

Cellular component of blood that takes part in the clotting process.

## Progesterone

Female hormone involved in the menstrual cycle and gestation.

## Protein

Substance that makes up parts of the cells. It is formed by one or more chains of amino acids and is fundamental to the constitution and functioning of the essentials of life, such as enzymes, hormones, and antibodies.

## Protozoa

Microscopic, unicellular, heterotrophic organisms that live in an aqueous medium and that reproduce through bipartition.

## Reflex

Automatic and involuntary reaction of the nervous system that is produced in response to a stimulus.

## Ribosome

An organelle located in the cytoplasm, it directs the formation of proteins based on the information given by the nucleic acids.

## RNA

Ribonucleic acid, similar to DNA but used to transport a copy of the DNA to the ribosome, where proteins are manufactured.

## Saturated Fats

Fats of animal origin that are involved in nutrition.

## Schwann Cells

Cells that produce myelin, a fatty insulating substance; it covers the nerve fibers that keeps the electrical signals from losing speed as they get farther away from the body of the neuron.

## Semen

Combination of sperm and liquid substances produced in the male genital system.

## Somatotropin

Human growth hormone, secreted by the pituitary gland (hypophysis).

## Spirillum

Flagellated bacterium with a helical or spiral form.

## Spore

Reproductive cell of a fungus.

## Sugar

Generic name of the organic chemical compounds known as carbohydrates.

## Synthesis

Chemical process in which two or more molecules join to produce a larger one.

## Systemic

Describes a disorder that affects several organs or the body as a whole.

## Testosterone

Androgenic hormone related to the primary as well as secondary male sexual traits. It is produced by the testicles and to a lesser extent by the adrenal glands and ovaries in women.

## Thrombus

Solid mass of blood formed inside a vein or artery. If it travels through the circulatory system, it is called an embolus, which can cause an obstruction.

## Tissue

Group of identical cells that carry out a common function.

## Transcription

Copying of the genetic code of the DNA into another molecule, such as RNA.

## Transplant

Insertion of live tissue into a living organism from another organism (living or not).

## Tumor

Any alteration of the tissues that produces an increase in volume.

## Vagus Nerve

Also called the pneumogastric nerve, it is the 10th of the 12 cranial pairs. It originates in the brainstem and innervates the pharynx, esophagus, larynx, trachea, bronchia, heart, stomach, and liver.

## Vein

Each one of the blood vessels that take deoxygenated blood to the heart.

## Vibrio

Genus of elongated bacteria in the shape of a comma with a single cilium, such as the one that produces cholera.

## Virus

Organism at the boundary between living and inert. It can be potentially pathogenic, and it can consist of a protein capsule (capsid) that surrounds the genetic material (DNA or RNA).

## Vitamin

One of the organic substances that ensures the equilibrium of vital functions and constitution of the tissues. They are designated with the letters of the alphabet.

## Zona Pellucida

Envelope that protects the egg; the sperm must negotiate it during fertilization.

## Zygote

The diploid cell formed by the union of the sperm and the egg after fertilization; also called the ovum.



# Index

## A

**AbioCor artificial heart**, 86-87  
potential, 90

**Acquired Immune Deficiency Syndrome:**  
*See* **AIDS**

**acute bronchitis**, 68

**adenine**, 44

**adrenal gland**, eight month fetus, 37

**Africa**

AIDS, 76

sleeping sickness, 54-55

**agranulocyte**, 56

**AIDS (Acquired Immune Deficiency Syndrome)**, 76-77 *See also* **HIV**

**alcoholism**, 70

**allantoic duct**, 33

**allergen**, 58, 74

identification, 75

**allergy**, 58, 74-75

asthma, 69

fungal, 52-53

**allograft**, 84

**alveolus**, 38, 69

**Alzheimer's disease**, 62-63

brain activity scan, 81

**amniocentesis**, 28

**amniotic fluid**, 28, 31

**amniotic sac**, 17

**anesthesia**, epidural, 41

**angina, pectoral**, 67

**angioplasty**, laser surgery, 82

**antibiotic**, 49

bacteria, 48

penicillin, 52-53

**antibody**, 74, 89

**anus**, hemorrhoid, 72

**appendicitis**, 72, 73

**appendix**

appendicitis, 72, 73

X-rays, 80

**arm**

artificial limb, 86, 91

embryonic bud formation, 18, 21

**arteriosclerosis**, 66

**artery**

angioplasty, 82

circulatory conditions, 66

pulmonary, 67

umbilical, 33

**arthritis:** *See* **osteoarthritis; rheumatoid arthritis**

**artificial organ (bionics)**, 85, 86-87, 90, 91

**aspergillosis**, 53

**asthma**, 69, 75

**astigmatism**, laser surgery, 83

**Atala, Anthony**, 88, 91

**atheroma**

heart attacks, 67

laser angioplasty, 82

**athlete's foot**, 53

**atypical pneumonia**, 51

**autograft**, 84, 91

**autoimmune system**

Crohn's disease, 73

rheumatoid arthritis, 65

**axon**, 24

## B

**bacillus bacteria**, 48

**bacteria**, 48-49

bacteriophages, 50-51

disease treatment: *See* **antibiotic**

gastroenteritis, 72

peptic ulcer, 71, 73

pneumonia: *See* **pneumonia**

*See also specific entries, for example*

**Helicobacter pylori**

**bacteriophage**, 50-51

**balance**, six month fetus, 32

**Beijerinck, Martinus**, 50

**bile**, 71

**bionics (artificial organ)**, 85, 86-87, 90, 91

**birth canal:** *See* **vagina**

**bladder**, cellular regeneration, 88

**blastocyst**, 12, 13-15

**blastomere**, 12

**blood**, 56-57

bacterial infection, 46-47

cell types: *See* **platelet; red blood cell; white blood cell**

circulation: *See* **circulatory system**

clotting, 57

embryonic production, 16

liver, 71

Rh disease, 37

**blood pressure:** *See* **pulmonary hypertension**

**bone**

degeneration, 64-65

fetal calcification, 34

structure, 34

**brain**

AIDS effects, 76

diagnostic scans, 81, 91

**diseases**, 62-63

early embryonic development, 18, 19, 20, 21

five month fetus, 30

four month fetus, 29

neuron development, 24-25

six month fetus, 32

three month fetus, 25

**branchial cleft**, 45

**breast:** *See* **mammary gland; milk production**

**breast cancer**, 60

**breech presentation**, 36

**bronchiole**, 69

**bronchitis**, 68

**bulbus cordis**, 17

## C

**calcification**, fetal bones, 34

**camera**, diagnostic tools, 80

**cancer**, 60-61

colon, 73

lung, 61, 69

nanomedicine, 89, 91

uterine cervix, 51

**candidiasis**, 53

**CD4-positive T lymphocyte**, 76

**cell division**, mitosis, 11

**cellular regeneration**, 88

**central nervous system**

Parkinson's disease, 63

seven month embryo, 35

sleeping sickness, 55

**cephalic presentation**, 36

**cervix (uterine)**

cancer, 51

childbirth, 41

**cesarean section**, 36

**chest pain:** *See* **pectoral angina**

**chicken pox**, 51

**childbirth**

fetal presentation, 36, 37

labor, 40-41

pain management, 41

**chorion**, 14

**chromosome**

amniocentesis, 28

bacterial, 48, 49

sex differentiation, 27, 45

**chronic bronchitis**, 68

**circulatory disease**, 66-67

**circulatory system**

disease, 66-67

four month embryo, 29

newborn, 42

umbilical cord, 33

**cirrhosis**, 70

**clitoris**, 26

**coccus bacteria**, 48

**cochlea (ear)**, 32

**cold weather allergy**, 75

**colitis**, 73

**colon**

cancer, 73

diseases, 72, 73

X-ray, 80

**common cold virus**, 51

**computerized tomography (CT)**, 81

**conidia:** *See* **sporangia**

**connective tissue**, embryonic formation, 18

**contact lens**, 83

**contraction:** *See* **childbirth**

**coronavirus**, 51

**Crohn's disease**, 73

**cryptococcosis**, 53

**cytosine**, 44

## D

**defense system**, 31

*See also* **immune system**

**degenerative disease**

bones, 64-65

Parkinson's disease, 63

**dendrite**, 25

**dengue**, 51

**dermatophytosis**, 53

**diabetes, gestational**, 35

**diagnosis, medical**, 80-81

*See also specific terms, for example* **X-ray**

**digestive system**

AIDS effects, 76

diseases, 70-73

**dilation**, childbirth, 40

**Dinoire, Isabelle**, 84

**disease:** *See organ systems and types of disease by name*

**diverticulitis**, 73

**DNA**

bacterial, 48, 49

bacteriophage, 50, 51

fertilization, 11

repair, 90

structure, 44-45

*See also* **RNA**

**Donoghue, John**, 91

**dopamine**, Parkinson's disease, 63

**double helix:** *See* **DNA**

**drug:** *See* **medicine**

**dust mite**, 75

**dysplasia**, 60

## E

**ear**

balance, 32

eight month fetus, 37

embryonic formation, 19, 20, 21

fetal sound perception, 31

four month fetus, 29

structure, 32

**economic development**, allergy incidence, 74, 75

**ectoderm**, 13

**egg**, fertilization, 10-11

**ejaculation (sperm)**, 8

**elderly, the**

Alzheimer's disease, 62-63

osteoarthritis, 64, 65

osteoporosis, 65

Parkinson's disease, 63

**embryo**

formation, 13, 14-15, 16

vertebrate similarities, 45

*See also specific organs, for example* **arm**

**encapsulated camera**, 80

**encephalitis**, 51

**endoderm**, 13

**endometrium**, 13

**endoparasite**, 54-55

**enzyme**, AIDS progression, 76

**epidural anesthesia**, 41

**Escherichia coli**, 72

**esophagus**, embryonic formation, 16

**eye**

artificial implant, 86

early embryonic formation, 17, 19, 21

eight month fetus, 37

eyelid formation, 18, 19

laser surgery, 82-83

pupil, 82

seven month fetus, 35



three month fetus, 27  
**eyeglasses**, history, 83

**F**

**face**, embryonic formation, 19  
**face transplant**, 84  
**fallopian tube**, 8, 12  
**Farokhzad, Omid**, 89, 91  
**fatty liver**, 70  
**female reproductive system**, 8-9  
 karyotype, 45  
 menstrual cycle, 9  
 third month formation, 26  
 X chromosome speed, 27  
*See also* **childbirth**; **postpartum period**

**fertilization**, 10-13

**fetal phase**  
 day twenty two, 16-17  
 day thirty six, 18  
 day forty, 19  
 day forty-four, 20  
 day sixty, 21  
 month three, 27  
 month four, 28-29  
 month five, 30-31  
 month six, 32-33  
 month seven, 34-35  
 month eight, 36-37  
 month nine, 40-41

**fetus**  
 first movement, 28  
 growth rate, 19  
 neuron development, 24-25  
 parental voice, 32  
 phases: *See* **fetal phase**  
 prenatal surgery, 5  
 sex differentiation, 26-27  
 3D magnetic resonance imaging, 80  
*See also* **embryo**; **childbirth**; **zygote**

**Fick, Adolf**, 83  
**filovirus**, 51

**filterable virus**, 50  
**fimbriae**, bacterial, 49  
**finger**  
 fetal formation, 21  
 fetal thumb sucking, 35  
 four month fetus, 29  
**first trimester**, 39  
*See also* **fetal phase**

**flagella**, bacterial, 49  
**flavor**, fetal perception, 33  
**food allergy**, 75  
**foot**, sixth month fetus, 33  
**foramen ovale**, 42  
 four month fetus, 29  
**4D ultrasound**  
 prenatal tests, 31  
*See also* **ultrasound**

**fraternal twin**, 44  
**fungus**, 52-53

## G

**gallbladder**, 70, 71  
**gallstone**, 71  
**gamete**, 8  
**gastric villi**, 73  
**gastritis**, 70  
**gastroenteritis**, 72  
**gene**, 44  
**genetic diagnosis**, 45  
**gestational diabetes**, 35  
**Giardia parasite**, 72  
**Glucose Tolerance Test (O'Sullivan test)**, 35  
**glycoprotein**, 76  
**gout**, 65  
**graft**, skin, 91  
**granulocyte**, 56  
**guanine**, 44

## H

**hand**  
 digit formation, 21  
 six month fetus, 33  
 three month fetus, 27

**head**  
 embryonic stage, 18, 21  
 five month fetus, 31  
 three month fetus, 27

**health informatics**: *See* **medical informatics**

**hearing**, sixth month fetus, 32

**heart**  
 AbioCor artificial heart, 86-87, 90  
 arteriosclerosis, 66  
 blood circulation, 66-67  
 embryonic formation, 15, 17  
 embryonic heartbeat, 28  
 fetus, 29  
 foramen ovale: *See* **foramen ovale**  
 heart attack, 67  
 Jarvik-7 artificial heart, 86  
 newborns, 42  
 regeneration treatment, 5  
 transplant, 85

**Helicobacter pylori**, 70, 72  
**hematoma**, CT scan, 81  
**hemoglobin**, 57  
**hemorrhoid**, 72  
**hepadnavirus**, 51  
**hepatitis B**, 51, 71  
**hepatitis C**, 70  
**hepatitis D**, 51  
**herpes virus**, 51  
**herpes zoster**, 51  
**HIV (human immunodeficiency virus)**, 51, 76  
*See also* **AIDS**

**hormone**, 8, 20, 43  
**HTLV retrovirus**, 51  
**human chorionic gonadotropin (HCG)**, 20  
**human immunodeficiency virus**: *See* **HIV**  
**hyperplasia**, 60  
**hypertension**: *See* **pulmonary hypertension**  
**hypha**, 53

**hypophysis**: *See* **pituitary gland**

## I-K

**identical twin**, 44

**immune system**  
**allergies**: *See* **allergy**  
 antibiotic action: *See* **antibiotic**  
 fetal development, 31  
 red and white blood cells, 56  
 rheumatoid arthritis, 65  
*See also* **AIDS**; **autoimmune system**; **white blood cell**

**impulse transmission**, 24, 25  
**industrialization**, allergy incidence, 74, 75  
**infarction**: *See* **heart attack**

**inheritance, genetic**, 44-45  
**integrase**, 76

**intestine**  
 infection, 72  
 inflammation, 73

**isograft**, 84  
**Jarvik, Robert**, 86  
**Jarvik-7** (artificial heart), 86  
**joint**, degeneration, 64, 65  
**Kaposi's sarcoma**, 76

**kidney**  
 artificial organ, 86  
 cellular regeneration, 88  
 embryonic formation, 16

disappearance, 36  
**laser surgery**, 82-83  
**LASIK surgery**, 83

**leg**  
 embryonic bud formation, 18, 21  
 four month fetus, 28

**Legionella pneumophila**, 68  
**leukemia**, 51  
**life support system**, 86  
**light**, fetal reaction, 35, 37

**liver**  
 artificial organ, 86  
 cirrhosis, 70  
 embryonic formation, 16  
 function, 70, 71  
 transplant, 85

**lochia**, postpartum processes, 43

**lung**  
 AIDS effects, 76  
 artificial organ, 86  
 cancer, 61, 69  
 embryonic formation, 16  
 infections, 68-69  
 newborn, 42  
 structure, 69  
 surfactant, 36

**lymphocyte**, 56  
 CD4-positive T lymphocytes, 76

**lysosome**, 51

## M

**magnetic resonance imaging (MRI)**, 80, 81  
 brain scan, 91  
 prenatal tests, 31  
*See also* **3D magnetic resonance imaging**

**male reproductive system**, 8  
 karyotype, 45  
 testicle, 28  
 third month fetus, 26  
 Y chromosome speed, 27

**mammary gland**, 38  
*See also* **milk production**

**mammogram**, 60  
**mast cell**, 74  
**meconium**, 36  
**medical informatics**, 5  
**medical technology**: *See specific terms, for example* **ultrasound**

**medicine**, 78-91  
 bacterial infection: *See* **antibiotic**  
 fetal monitoring, 28, 31  
 fungal infection, 53  
 HIV treatment, 77

**memory loss**, 62

**men**  
 cancers, 61  
 Parkinson's disease, 63  
 prostate cancer, 61  
 sex differentiation, 26, 45  
*See also* **male reproductive system**

**meningitis**, 53  
**menopause**, 8  
**menstrual cycle**, 9, 39  
**mesoderm**, 13  
**metastasis**, 60, 61  
**metric measurement**, 89  
**micromotor**, 88  
**microtubule**, 62  
**milk production**, 38  
 hormones, 43

**mitosis**, 11  
**monocyte**, 56  
**morphogen**, 14  
**morphogenesis**, 14  
**morula**, 12  
**multiple sclerosis**, 63  
**Mycobacterium tuberculosis**, 46-47  
**myelin envelope**, 24, 25  
 multiple sclerosis, 63  
**myopia**, laser surgery, 83



## N

nail, fungal infection, 53  
 nanomedicine, 88-89  
 nanoparticle, 89, 91  
 nanotechnology, 5, 88  
   dimensions, 89  
   nanoparticle research, 91  
   nanoscopic beam, 89  
   nanotube, 88  
 nanotube, 88  
 nervous system  
   cellular differentiation, 15  
   fetal development, 25  
   neurological disorders, 62-63  
   optical fiber recreation, 90  
   *See also* brain; central nervous system  
 neuroblast, 15  
 neurological disorder, 62-63  
 neuron  
   Alzheimer's disease, 62  
   development, 24-25  
   regeneration, 88  
 neurotransmitter, 24  
   dopamine, 63  
   synthesis, 25  
 nitroglycerin, 67  
 nucleotide base, 44

## O

onychomycosis, 53  
 optical fiber, medical research, 91  
 organ  
   regeneration, 88, 90, 91  
   transplant: *See* transplant  
 organ of Corti, 32  
 osteoarthritis, 64, 65  
 osteoporosis, 64  
 O'Sullivan test: *See* Glucose Tolerance Test  
 ovary, 28

ovulation cycle, 9  
 oxyhemoglobin, 57  
 oxytocin, 43

## P

pain management, childbirth, 41  
 pancreas, 70  
 papillomavirus, 51  
 parental voice, fetal recognition, 32  
 Parkinson's disease, 63  
 pathogen: *See* bacteria; virus  
 peanut, allergies, 75  
 pectoral angina, 67  
 pelvis, childbirth, 40, 41  
 penicillin, 53  
 Penicillium, 52-53  
 penis, 8, 10, 26  
 peptic ulcer, 71, 73  
 pituitary gland (hypophysis), embryonic  
   development, 18  
 placenta, 14, 20, 21, 33  
 plague, 48  
 plaque  
   angioplasty, 82  
   heart disease, 66  
 platelet, 57  
 pneumonia, 51, 53, 68  
 pollen, allergies, 58-59, 74, 75  
 Positron Emission Tomography (PET), 80, 81  
 postpartum period  
   normalcy, 43  
   sexual disorders, 42  
 poxvirus, 51  
 pre-implantation genetic diagnosis, 45  
 pregnancy, 38  
   hormonal changes, 43  
   trimesters, 39  
   *See also* fetal phase  
 pregnancy test, 20  
 prenatal surgery, future technology, 5  
 prolactin, 43

prostate cancer, 61  
 protease inhibitor, AIDS, 77  
 protozoa, 72  
 pseudopodium, 56  
 pulmonary artery, 67  
 pulmonary hypertension, 67  
 pulmonary surfactant, 36

## R-S

Radman, Miroslav, 90  
 ragweed, allergies, 75  
 rectum  
   hemorrhoid, 72  
   inflammatory disease, 73  
   X-rays, 80  
 red blood cell, 56, 57  
   production, 34  
   Rh disease, 37  
 regeneration, organs, 88, 90, 91  
 reproduction, 8  
   fertilization, 10-13  
   implantation, 13  
   zygote stage, 12  
   *See also* female reproductive system; male  
   reproductive system  
 respiratory system  
   allergies, 75  
   infection, 68-69  
   *See also* lung  
 retrovirus, 51  
 reverse transcriptase, 76  
 Rh disease, 37  
 rheumatoid arthritis, 65  
 Rhizobium bacteria, 48  
 ribosome, 49  
 ringworm, 53  
 RNA, 51, 76, 77  
   *See also* DNA  
 SARS, 51  
 scanning method, 80-81  
 second trimester, 39

*See also* fetal phase  
 sex differentiation (fetus)  
   fourth month, 28  
   third month, 26-27  
 sexual disorder, postpartum, 42  
 skin  
   AIDS effects, 76  
   four month fetus, 29  
   fungal infection, 53  
   graft, 84, 91  
   seven month fetus, 35  
 skull, newborn, 41  
 sleeping sickness, 54-55  
 smallpox, 51  
 smoking: *See* tobacco smoking  
 sonogram: *See* ultrasound  
 sonograph, 27, 31  
 sperm, 10-11  
   chromosome speed, 27  
   production, 8  
 spinal cord, formation, 30  
 spine, formation, 16  
 spirilla bacteria, 48  
 sporangia, 52  
 stem cell, 15  
 stomach, diseases, 70, 71  
 sound, fetal perception, 31  
 Sullivan, Jesse, 86  
 surgery  
   lasers, 82-83  
   transplants, 84-85  
 synaptic node, 25

## T

T lymphocyte, 76  
 taste  
   eight month fetus, 37  
   four month fetus, 29  
   five month fetus, 31  
   six month fetus, 33  
 testicle, descent, 28

thalamus, formation, 21  
 third trimester, 39  
   *See also* fetal phase  
 3D magnetic resonance imaging, 80  
   *See also* magnetic resonance imaging  
 thrombosis, 67  
 thrombus, 67  
 thymine, 44  
 Timothy grass (*Phleum pratense*), 58-59  
 tissue, transplants, 84  
 tobacco smoking  
   bronchitis, 68  
   carcinogenic potential, 69  
   lung cancer, 61  
 tongue, 29  
 transplant, 84-85  
   future alternatives, 5  
   *See also* bionics  
 trimester, 39  
   *See also* fetal phase  
 Trypanosoma (protist), 54-55  
 tsetse fly, 54, 55  
 tumor, 60, 61, 82  
 twins, 44

## U

ulcer: *See* peptic ulcer  
 ultrasound, 27, 80  
   five month fetus, 30  
   4D ultrasound, 31  
 umbilical cord  
   blood circulation, 42  
   development, 18  
   four month fetus, 29  
   six month fetus, 33  
 uric acid, blood levels, 65  
 uterus, 9  
   childbirth, 40  
   postpartum, 43  
   pregnancy, 39  
   uterine wall, 14

## V-W

vagina (birth canal), 9, 10, 41, 42, 43  
 vena cava, 66  
 vertebrate, embryos, 45  
 vibrio bacteria, 48  
 viral gastroenteritis, 72  
 virus, 50-51  
   acute bronchitis, 68  
   HIV, 76, 77  
 vision  
   laser surgery, 83  
   seven month fetus, 35  
 wart, 51  
 wasp sting, allergies, 75  
 West Nile fever, 51  
 white blood cell, 56  
   CD4-positive T lymphocytes, 76  
 women  
   breast cancer, 60  
   cancers, 61  
   candidiasis, 53  
   lung cancer, 61  
   pregnancy and childbirth, 38-41  
   sex differentiation, 26, 45  
   *See also* female reproductive system

## X-Z

X chromosome  
   chromosomes, 45  
   sperm, 27  
 X-ray, 80  
 xenograft, 84  
 Y chromosome,  
   chromosomes, 45  
   sperm, 27  
 Yersinia pestis, 48  
 zona pellucida, 11  
 zygote, 11, 12-13, 45





HUMAN BODY II

Britannica Illustrated  
Science Library

ENCYCLOPEDIA  
Britannica<sup>®</sup>

