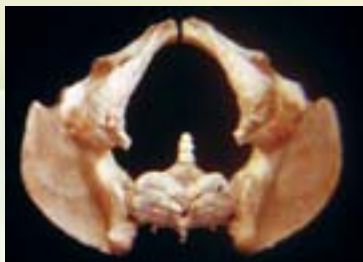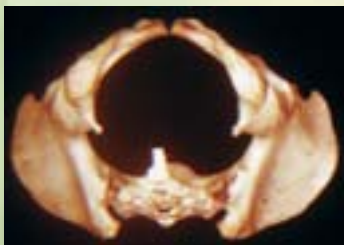

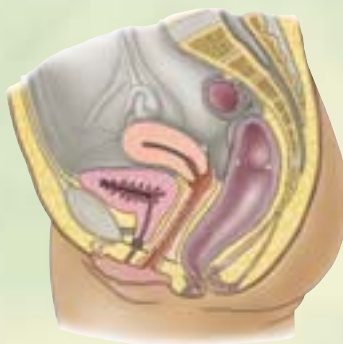
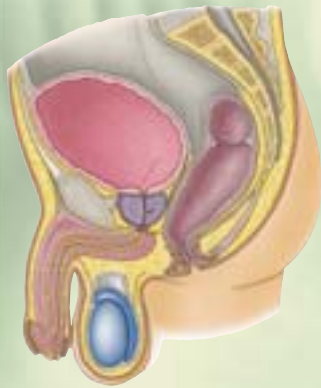3

Pelvis and Perineum



INTRODUCTION TO THE PELVIS AND PERINEUM / 357

PELVIC GIRDLE / 357

Bones and Features of the Pelvic Girdle / 358

Orientation of the Pelvic Girdle / 360

Joints and Ligaments of the Pelvic Girdle / 364

PELVIC CAVITY / 368

Walls and Floor of the Pelvic Cavity / 369

Peritoneum and Peritoneal Cavity
of the Pelvis / 376

Pelvic Fascia / 377

NEUROVASCULAR STRUCTURES OF THE PELVIS / 379

Pelvic Nerves / 379

Pelvic Arteries / 383

Pelvic Veins / 389

Lymph Nodes of the Pelvis / 391

PELVIC VISCERA / 391

Urinary Organs / 391

Male Internal Genital Organs / 405

Female Internal Genital Organs / 410

Rectum / 429

PERINEUM / 433

Fasciae and Pouches of the Urogenital
Triangle / 438

Features of the Anal Triangle / 442

Male Perineum / 451

Female Perineum / 461

MEDICAL IMAGING OF THE PELVIS AND PERINEUM / 467

Radiography / 467

Ultrasonography / 468

Computed Tomography / 469

Magnetic Resonance Imaging / 471

Introduction to the Pelvis and Perineum

The term *pelvis* (L. basin) is used to denote a variety of structures: a region, the pelvic girdle, and the pelvic cavity.

In common usage, the pelvis is the part of the trunk infero-posterior to the abdomen and is the area of transition between the trunk and the lower limbs. Anatomically, the pelvis is the space or compartment surrounded by the pelvic girdle (bony pelvis), part of the appendicular skeleton of the lower limb (Fig. 3.1). The pelvis is subdivided into *greater* and *lesser pelvises*. The greater pelvis affords protection to inferior abdominal viscera similar to the way the inferior thoracic cage protects superior abdominal viscera. The lesser pelvis provides the skeletal framework for both the *pelvic cavity* and the *perineum*—compartments of the trunk separated by the musculofascial *pelvic diaphragm*. Externally, the pelvis is covered or overlapped by the inferior anterolateral abdominal wall anteriorly, the gluteal region of the lower limb posterolaterally, and the perineum inferiorly.

The *perineum*¹ refers both to the *area* of the surface of the trunk between the thighs and the buttocks, extending from

¹The term *perineum* has been used different ways, in different languages, and in different circumstances. In its most restricted sense, and in obstetrics, it has been used to refer to the area superficial to the perineal body, between the vulva or scrotum and the anus or to the perineal body itself. In an intermediate sense, it has included only the superficial (surface) area of the pelvis bounded by the thighs laterally, the mons pubis anteriorly, and the coccyx posteriorly. In its widest sense, as used in *Terminologia Anatomica* (the international anatomical terminology) and in this book, it refers the region of the body that includes all structures of the anal and urogenital triangles, superficial and deep, extending as far superiorly as the inferior fascia of the pelvic diaphragm.

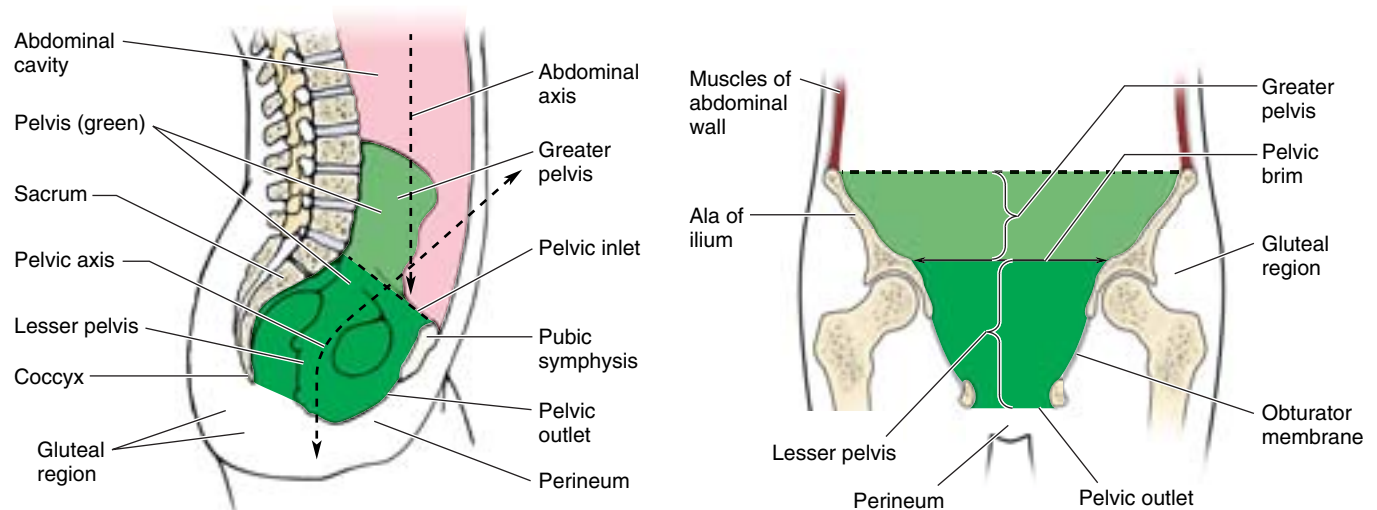
the coccyx to the pubis, and to the shallow *compartment* lying deep (superior) to this area and inferior to the pelvic diaphragm. The perineum includes the anus and external genitalia: the penis and scrotum of the male and the vulva of the female. Anatomically, “regions” are defined by an area of the surface of the body, so there is no external “pelvic region” per se; although commonly used, it is not a term recognized by *Terminologia Anatomica* (FICAT, 1998).

THE BOTTOM LINE: The pelvis is the space enclosed by the pelvic girdle, which is subdivided into the greater pelvis (the inferior part of the abdominal cavity, which receives the protection of the alae of the ilia) and the lesser pelvis (the space inside the bony ring of pelvis inferior to the pelvic brim). The lesser pelvis provides the skeletal framework for both the pelvic cavity and the perineum, which are separated by the musculofascial pelvic diaphragm. The term *perineum* refers to both the region that includes the anus and external genitalia and to a shallow compartment deep to that area. The inferior anterolateral abdominal wall, gluteal region, and perineum overlap the pelvis.

Pelvic Girdle

The **pelvic girdle** is a basin-shaped ring of bones that connects the vertebral column to the two femurs. The *primary* functions of the pelvic girdle are to:

- Bear the weight of the upper body when sitting and standing.
- Transfer that weight from the axial to the lower appendicular skeleton for standing and walking.



(A) Medial view of left half of bisected trunk

(B) Anterior view of coronal section

Figure 3.1. Pelvis and perineum. A and B. The pelvis (green) is the space (compartment) within the pelvic girdle, overlapped externally by the abdominal and gluteal (lower limb) regions and the perineum. Thus the pelvis has no external surface area. The greater pelvis (light green) is pelvic by virtue of its bony boundaries, but abdominal in terms of its contents. The lesser pelvis (dark green) provides the bony framework for the pelvic cavity and deep perineum.

- Provide attachment for the powerful muscles of locomotion and posture, as well as those of the abdominal wall, withstanding the forces generated by their actions.

Consequently, the pelvic girdle is quite strong and rigid, especially compared to the pectoral (shoulder) girdle. These aspects of the pelvic girdle will be discussed more thoroughly elsewhere (Chapter 2, in relation to the abdominal wall; Chapter 4, in relation to the vertebral column; and Chapter 6, in relation to the lower limb).

The *secondary* functions of the pelvic girdle, discussed here, are to:

- Contain and protect the pelvic viscera (inferior parts of the urinary tracts and the internal reproductive organs) especially but also the inferior abdominal viscera (intestines), while permitting passage of their terminal parts (and, in females, a full-term fetus) via the perineum.
- Provide support for the abdominopelvic viscera and gravid (pregnant) uterus.
- Provide attachment for the erectile bodies of the external genitalia.
- Provide attachment for the muscles and membranes that assist in these functions by forming the pelvic floor and filling gaps that exist in or around it.

Bones and Features of the Pelvic Girdle

In the mature individual, the pelvic girdle is formed by three bones (Fig. 3.2A):

- Right and left **hip bones** (coxal bones; pelvic bones): large, irregularly shaped bones, each of which develops from the fusion of three bones, the *ilium*, *ischium*, and *pubis*.
- **Sacrum**: formed by the fusion of five, originally separate, sacral vertebrae.

The internal (medial or pelvic) aspects of the hip bones bound the pelvis, forming its lateral walls; these aspects of the bones are emphasized here. Their external aspects, primarily involved in providing attachment for the lower limb muscles, are discussed in Chapter 5. As they are part of the vertebral column, the sacrum and coccyx are discussed in detail in Chapter 4.

In infants and children, the hip bones consist of three separate bones that are united by a **triradiate** (i.e., radiating in three directions) **cartilage** at the **acetabulum** (Fig. 3.2B), the cup-like depression in the lateral surface of the hip bone, which articulates with the head of the femur. After puberty, the ilium, ischium, and pubis fuse to form the hip bone. The two hip bones are joined anteriorly at the **pubic symphysis** (L. *symphysis pubis*) and articulate posteriorly with the sacrum at the **sacroiliac joints** to form the pelvic girdle.

The **ilium** is the superior, fan-shaped part of the hip bone (Fig. 3.2B & C). The **ala**, or **wing of the ilium**, represents the spread of the fan; and the **body of the ilium**, the handle of the

fan. On its external aspect, the body participates in formation of the acetabulum. The **iliac crest**, the rim of the fan, has a curve that follows the contour of the ala between the **anterior** and the **posterior superior iliac spines**. The anteromedial concave surface of the ala forms the iliac fossa. Posteriorly, the **sacropelvic surface of the ilium** features an **auricular surface** and an **iliac tuberosity**, for synovial and syndesmotic articulation with the sacrum, respectively.

The **ischium** has a body and ramus (L. branch). The **body of the ischium** helps form the acetabulum and the **ramus of the ischium** forms part of the **obturator foramen**. The large posteroinferior protuberance of the ischium is the **ischial tuberosity**; the small pointed posteromedial projection near the junction of the ramus and body is the **ischial spine**. The concavity between the ischial spine and the ischial tuberosity is the **lesser sciatic notch**. The larger concavity, the **greater sciatic notch**, is superior to the ischial spine and is formed in part by the ilium.

The **pubis** is an angulated bone with a **superior pubic ramus**, which helps form the acetabulum, and an **inferior pubic ramus**, which helps form the obturator foramen. A thickening on the anterior part of the **body of the pubis** is the **pubic crest**, which ends laterally as a prominent knob or swelling, the **pubic tubercle**. The lateral part of the superior pubic ramus has an oblique ridge, the **pecten pubis** (pectineal line of pubis).

The pelvis is divided into *greater (false)* and *lesser (true)* **pelves** by the oblique plane of the **pelvic inlet** (superior pelvic aperture) (Figs. 3.1 and 3.2A). The bony edge (rim) surrounding and defining the pelvic inlet is the **pelvic brim**, formed by the:

- *Promontory and ala of the sacrum* (superior surface of its lateral part, adjacent to the body).
- A **right and left linea terminalis** (terminal line) together form a continuous oblique ridge consisting of the:
 - **Arcuate line** on the inner surface of the ilium.
 - *Pecten pubis* (pectineal line) and *pubic crest*, forming the superior border of the superior pubic ramus and body.

The **pubic arch** is formed by the **ischiopubic rami** (conjoined inferior rami of the pubis and ischium) of the two sides (Fig. 3.2A & C). These rami meet at the *pubic symphysis*, their inferior borders defining the **subpubic angle**. The width of the subpubic angle is determined by the distance between the right and the left ischial tuberosities, which can be measured with the fingers in the vagina during a pelvic examination. The **pelvic outlet** (inferior pelvic aperture) is bounded by the (Fig. 3.3C):

- *Pubic arch* anteriorly.
- *Ischial tuberosities* laterally.
- Inferior margin of the *sacrospinous ligament* (running between the coccyx and the ischial tuberosity) *posterolaterally*.
- *Tip of the coccyx* posteriorly.

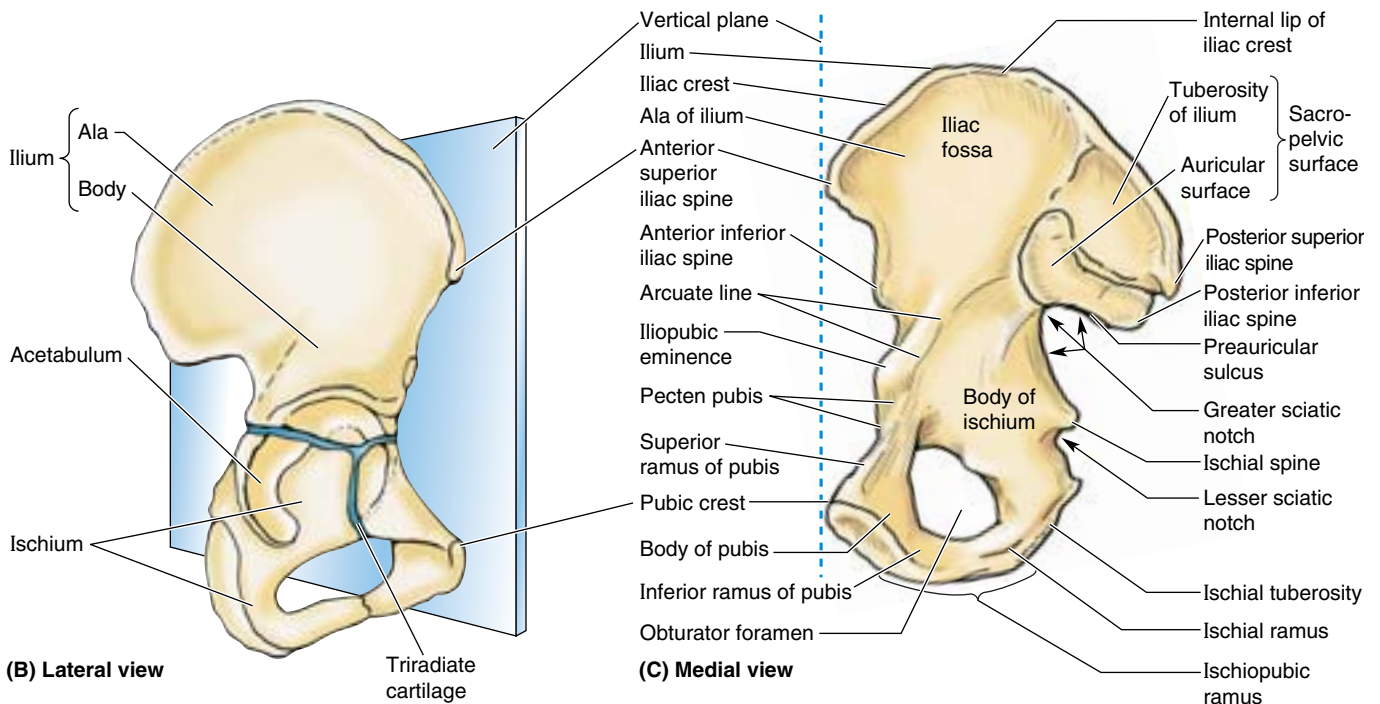
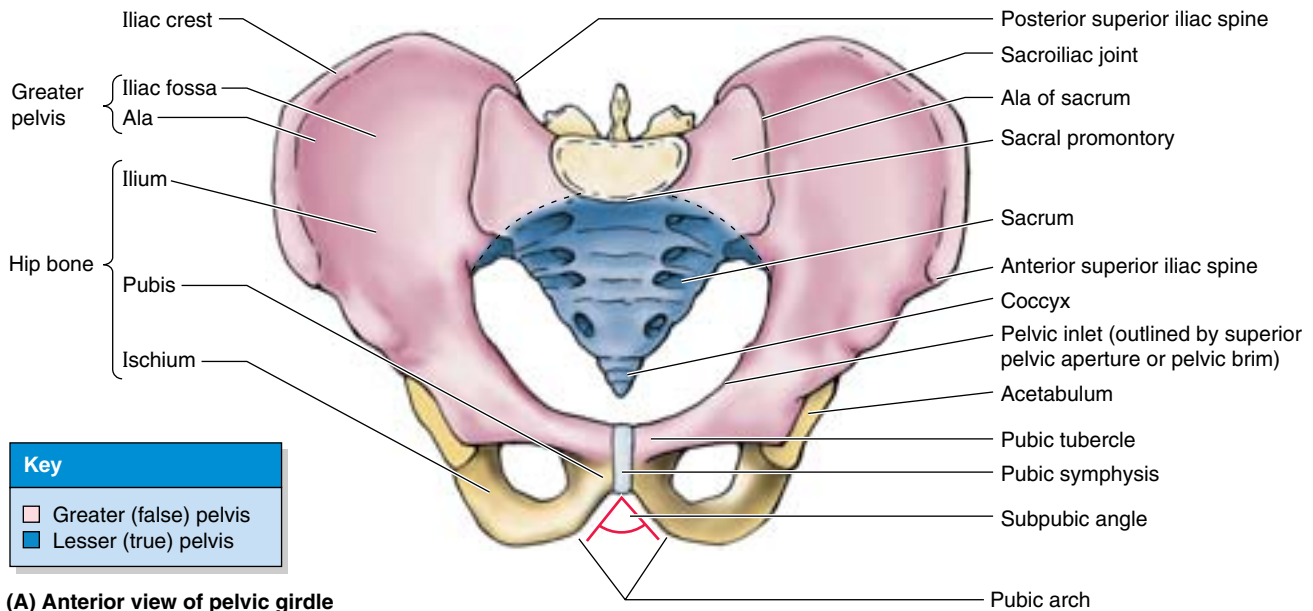


Figure 3.2. Pelvic girdle. **A.** The pelvic girdle is formed by the two hip bones anteriorly and laterally and the sacrum posteriorly. The sacrum is also part of the vertebral column, in continuity with the lumbar vertebrae superiorly and the coccyx inferiorly. **B.** When a child's hip bone is in the anatomical position, the anterior superior iliac spine (ASIS) and the anterior aspect of the pubis lie in the same vertical plane. The hip bone at this stage is composed of three bones—ilium, ischium, and pubis—that meet in the cup-shaped acetabulum. The bones are not fused at this age but are united by a triradiate cartilage along a Y-shaped line (blue). **C.** An adult's right hip bone in the anatomical position shows the bones when fused.

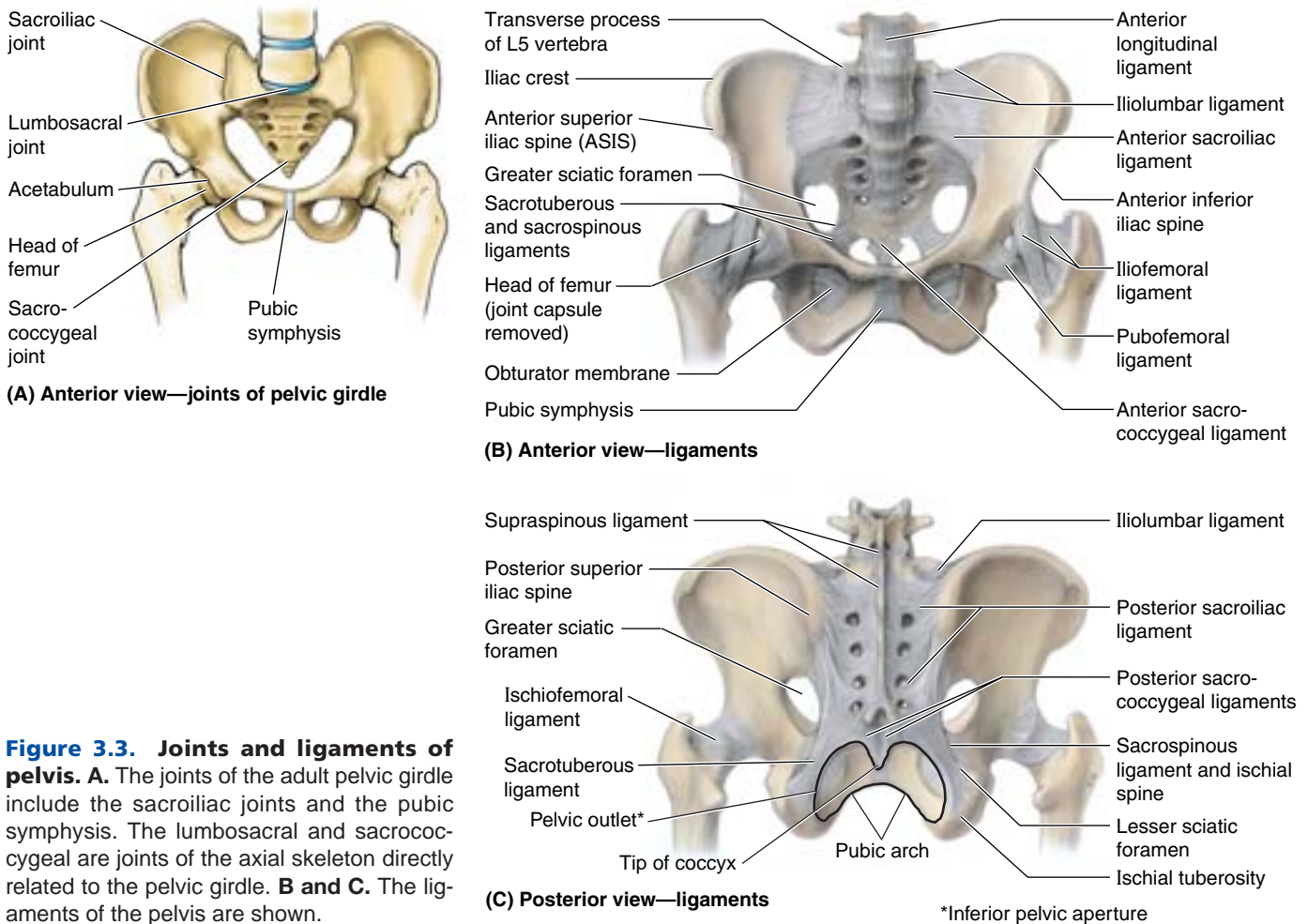


Figure 3.3. Joints and ligaments of pelvis. **A.** The joints of the adult pelvic girdle include the sacroiliac joints and the pubic symphysis. The lumbosacral and sacrococcygeal are joints of the axial skeleton directly related to the pelvic girdle. **B and C.** The ligaments of the pelvis are shown.

The boundaries of the pelvic outlet are also the deep boundaries of the perineum.

The **greater pelvis** (false pelvis, pelvis major) is the part of the pelvis (Fig. 3.2A):

- Superior to the pelvic inlet.
- Bounded by the iliac alae posterolaterally and the antero-superior aspect of the S1 vertebra posteriorly.
- Occupied by abdominal viscera (e.g., the ileum and sigmoid colon).

The **lesser pelvis** (true pelvis, pelvis minor) is the part of the pelvis:

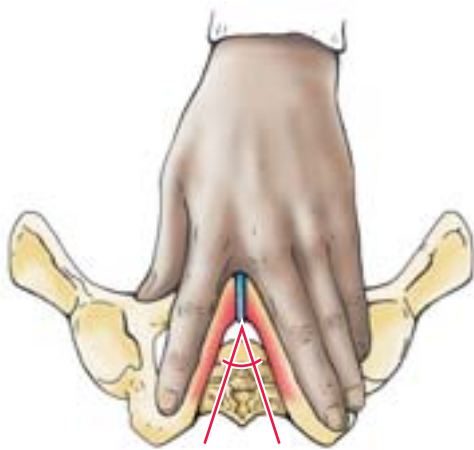
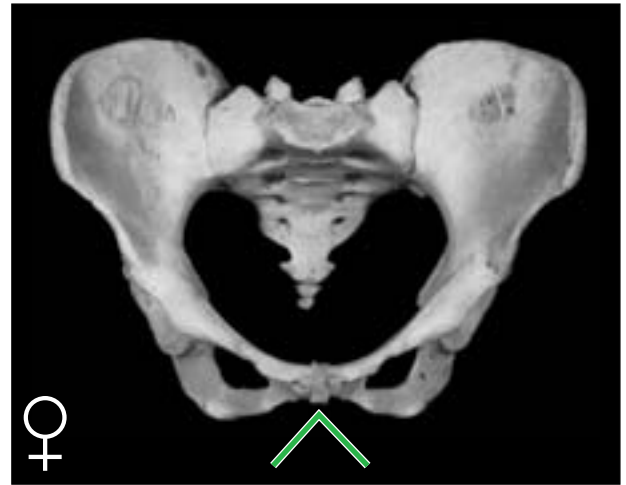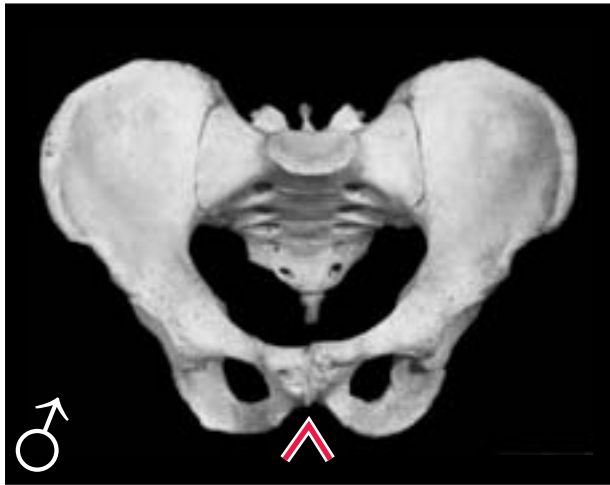
- Between the *pelvic inlet* and the *pelvic outlet*.
- Bounded by the pelvic surfaces of the hip bones, sacrum, and coccyx.
- That includes the true *pelvic cavity* and the deep parts of the *perineum* (perineal compartment), specifically the ischioanal fossae.
- Of major obstetrical and gynecological significance.

The concave superior surface of the musculofascial pelvic diaphragm forms the floor of the true pelvic cavity, which is thus deepest centrally. The convex inferior surface of the pelvic diaphragm forms the roof of the perineum, which is therefore shallow centrally and deep peripherally. Its lateral parts (ischioanal fossae) extending well up into the lesser pelvis. The terms *pelvis*, *lesser pelvis*, and *pelvic cavity* are commonly used incorrectly, as if they were synonymous terms.

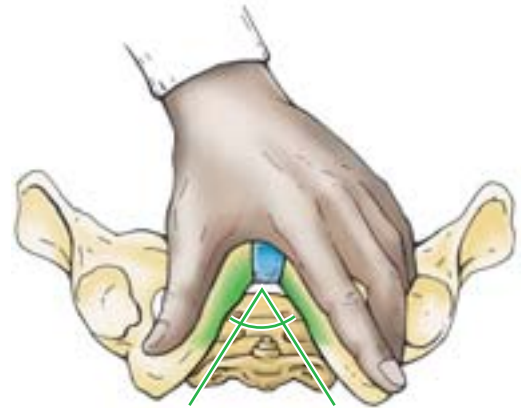
Orientation of the Pelvic Girdle

When a person is in the anatomical position, the right and left ASISs and the anterior aspect of the pubic symphysis lie in the same vertical plane (Fig. 3.2B). When a pelvic girdle in this position is viewed anteriorly (Fig. 3.2A; Table 3.1A & B), the tip of the coccyx appears close to the center of the pelvic inlet, and the pubic bones and pubic symphysis constitute more of a weight-bearing floor than an anterior wall. In the median view (Fig. 3.1A), the sacral promontory is located directly superior to the center of the pelvic outlet (site of the perineal body). Consequently, the curved axis of the pelvis intersects the axis of the abdominal cavity at an oblique angle.

Table 3.1. Comparison of Male and Female Bony Pelves



(A)



(B)

Bony Pelvis	Male (♂)	Female (♀)
General structure	Thick and heavy	Thin and light
Greater pelvis (pelvis major)	Deep	Shallow
Lesser pelvis (pelvis minor)	Narrow and deep, tapering	Wide and shallow, cylindrical
Pelvic inlet (superior pelvic aperture)	Heartshaped, narrow	Oval and rounded; wide
Pelvic outlet (inferior pelvic aperture)	Comparatively small	Comparatively large
Pubic arch and subpubic angle	Narrow (< 70°)	Wide (> 80°)
Obturator foramen	Round	Oval
Acetabulum	Large	Small
Greater sciatic notch	Narrow (~ 70°); inverted V	Almost 90°

The pelvic girdles of males and females differ in several respects (Table 3.1). These sexual differences are related mainly to the heavier build and larger muscles of most men and to the adaptation of the pelvis (particularly the lesser pelvis) in women for parturition (childbearing). The *male pelvic girdle*

is heavier and thicker than the female girdle and usually has more prominent bone markings. The *female pelvic girdle* is wider, shallower, and has a larger pelvic inlet and outlet. The *subpubic angle* is nearly a right angle in females; it is considerably less in males (approximately 60°).

Variations in the Male and Female Pelves

Although anatomical differences between male and female pelves are usually clear cut, the pelvis of any person may have some features of the opposite sex. The pelvic types shown in Figure B3.1A and C are most common in males, B and A in white females, B and C in black females, whereas D is uncommon in both sexes. The **gynecoid pelvis** is the normal female type (Fig. B3.1B); its pelvic inlet typically has a rounded oval shape and a wide transverse diameter. An **android** (masculine or funnel-shaped) pelvis in a woman may present hazards to successful vaginal delivery of a fetus (Fig. B3.1A).

In **forensic medicine** (the application of medical and anatomical knowledge for the purposes of law), identification of human skeletal remains usually involves the diagnosis of sex. A prime focus of attention is the pelvic girdle because sexual differences usually are clearly visible. Even fragments of the pelvic girdle are useful in determining sex.

Pelvic Diameters (Conjugates)

The size of the lesser pelvis is particularly important in obstetrics because it is the bony canal through which the

fetus passes during a vaginal birth. To determine the capacity of the female pelvis for childbearing, the diameters of the lesser pelvis are noted radiographically or manually during a pelvic examination. The minimum anteroposterior (AP) diameter of the lesser pelvis, the **true** (obstetrical) **conjugate** from the middle of the sacral promontory to the posterosuperior margin (closest point) of the pubic symphysis (Fig. B3.2A & B), is the narrowest *fixed* distance through which the baby's head must pass in a vaginal delivery. This distance, however, cannot be measured directly during a pelvic examination because of the presence of the bladder. Consequently, the **diagonal conjugate** (Fig. B3.2B) is measured by palpating the sacral promontory with the tip of the *middle* finger, using the other hand to mark the level of the inferior margin of the pubic symphysis on the examining hand (Fig. B3.2C). After the examining hand is withdrawn, the distance between the tip of the *index* finger (1.5 cm shorter than the middle finger) and the marked level of the pubic symphysis is measured to estimate the true conjugate, which should be 11.0 cm or greater.

In all pelvic girdles, the ischial spines extend toward each other, and the **interspinous distance** between them is normally the narrowest part of the **pelvic canal** (the passageway through the pelvic inlet, lesser pelvis and pelvic outlet, through which a baby's head must pass at birth; ►

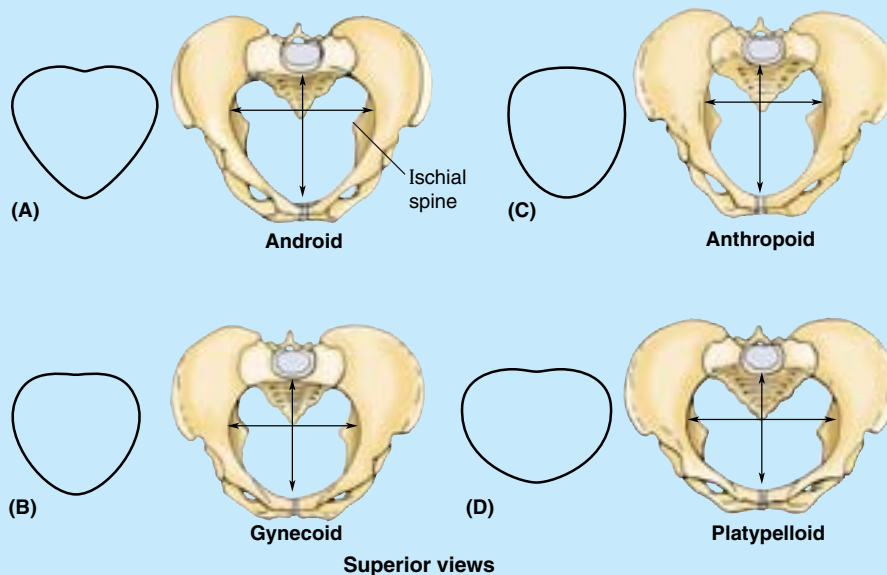


Figure B3.1

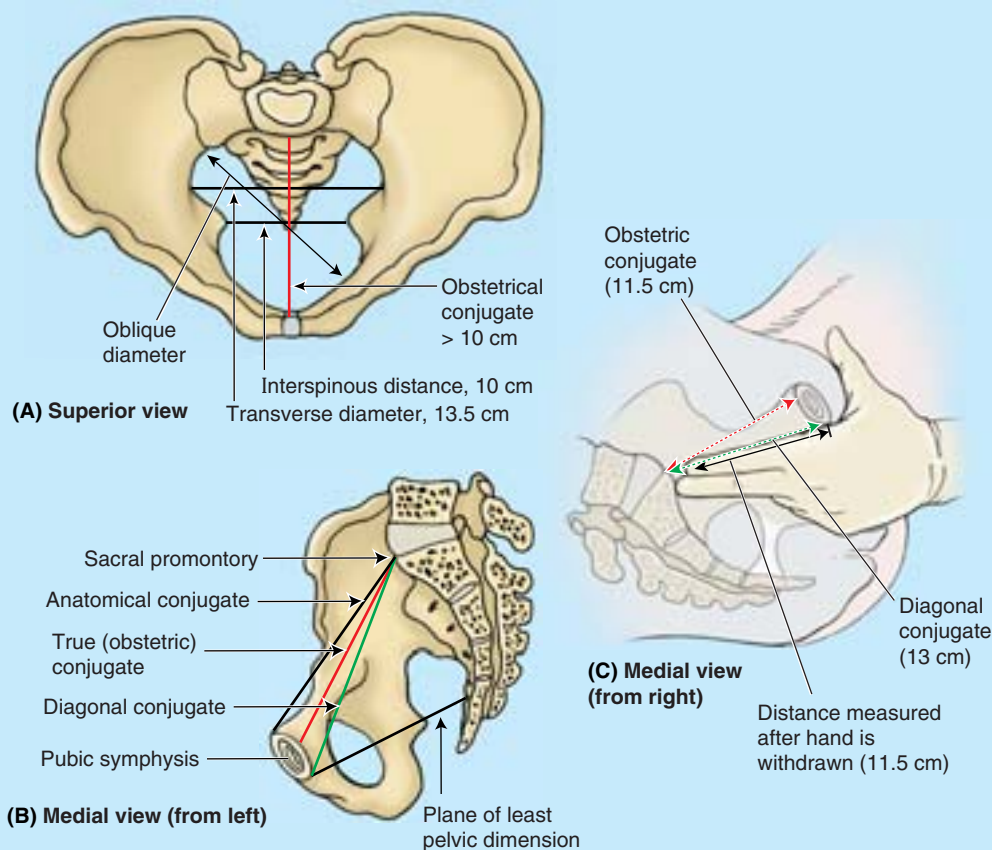


Figure B3.2

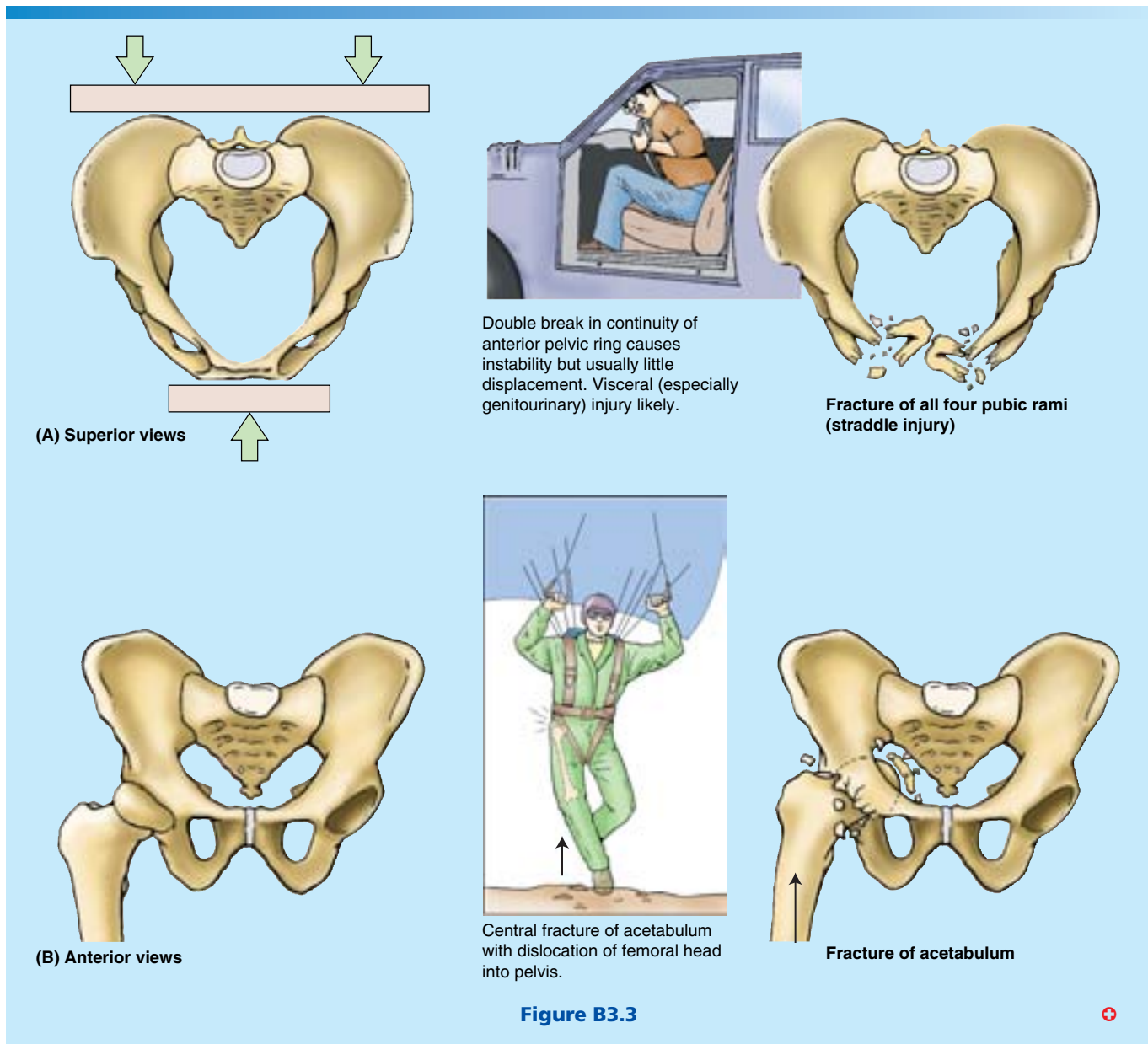
Fig. B3.2B), but it is not a fixed distance (see clinical correlation [blue] box “Relaxation of Pelvic Ligaments and Increased Joint mobility during Pregnancy,” in this chapter). During a pelvic examination, if the ischial tuberosities are far enough apart to permit three fingers to enter the vagina side by side, the subpubic angle is considered sufficiently wide to permit passage of an average fetal head at full term.

Pelvic Fractures

Anteroposterior compression of the pelvis occurs during crush accidents (e.g., when a heavy object falls on the pelvis) (Fig. B3.3A). This type of trauma commonly produces fractures of the pubic rami. When the pelvis is compressed laterally, the acetabula and ilia are squeezed toward each other and may be broken. Fractures of the bony pelvic ring are almost always multiple fractures or a fracture combined with a joint dislocation. To illustrate this, try breaking a pretzel ring at just one point. Some pelvic fractures result from the tearing away of bone by the strong ligaments associated with the sacroiliac joints (these ligaments

are shown in Figs 3.3 and 3.4A). Pelvic fractures can result from direct trauma to the pelvic bones, such as occurs during an automobile accident (Fig. B3.3A), or be caused by forces transmitted to these bones from the lower limbs during falls on the feet (Fig. B3.3B). Weak areas of the pelvis, where fractures often occur, are the pubic rami, the acetabula (or the area immediately surrounding them), the region of the sacroiliac joints, and the alae of the ilium.

Pelvic fractures may cause injury to pelvic soft tissues, blood vessels, nerves, and organs. Fractures in the pubo-obturator area are relatively common and are often complicated because of their relationship to the urinary bladder and urethra, which may be ruptured or torn. Falls on the feet or buttocks from a high ladder may drive the head of the femur through the acetabulum into the pelvic cavity, injuring pelvic viscera, nerves, and vessels. In individuals < 17 years of age, the acetabulum may fracture through the triradiate cartilage into its three developmental parts (Fig. 3.2B) or the bony acetabular margins may be torn away. ▶



THE BOTTOM LINE: The pelvic girdle is an articulated bony ring composed of the sacrum and two hip bones. Whereas the pelvic girdle is part of the appendicular skeleton of the lower limb, the sacrum is also part of the axial skeleton, continuous with the lumbar vertebrae superiorly and coccyx inferiorly. The hips bones are formed by the fusion of the ilium, ischium, and pubis. The primary functions of the pelvic girdle are weight bearing and transfer; secondary functions include protection and support of abdominopelvic viscera and housing and attachment for structures of the genital and urinary systems. The pelvic girdle is in the anatomical position when its three anterior-most points (right and left ASISs and anterior aspect of pubic symphysis) lie in the same vertical plane. Male and female pelvis are distinct; the characteristic features of the

normal (gynecoid) female pelvis reflect the fact that the fetus must traverse the pelvic canal during childbirth. Because atypical female pelvis may not be conducive to a vaginal birth, determination of the pelvic diameters is of clinical importance.

Joints and Ligaments of the Pelvic Girdle

The primary joints of the pelvic girdle are the *sacroiliac joints* and the *pubic symphysis* (Fig. 3.3A). The sacroiliac joints link the **axial skeleton** (the skeleton of the trunk, composed of the vertebral column at this level) and the **inferior appendicular skeleton** (skeleton of the lower limb). The lumbosacral and sacrococcygeal joints, although joints of the axial skeleton, are

directly related to the pelvic girdle. Strong ligaments support and strengthen these joints.

Sacroiliac Joints

The **sacroiliac joints** are strong, weight-bearing compound joints, consisting of an anterior synovial joint (between the ear-shaped *auricular surfaces* of the sacrum and ilium, covered with articular cartilage) and a posterior syndesmosis (between the *tuberosities* of the same bones) (Figs. 3.3 and 3.4). The articular (auricular) surfaces of the synovial joint have irregular but congruent elevations and depressions that interlock. The

sacroiliac joints differ from most synovial joints in that limited mobility is allowed, a consequence of their role in transmitting the weight of most of the body to the hip bones. Weight is transferred from the axial skeleton to the ilia and then to the femurs during standing (Fig. 3.3A & B) and to the ischial tuberosities during sitting. As long as tight apposition is maintained between the articular surfaces, the sacroiliac joints remain stable.

Unlike a keystone at the top of an arch, the sacrum is actually suspended between the iliac bones and is firmly attached to them by posterior and interosseous sacroiliac

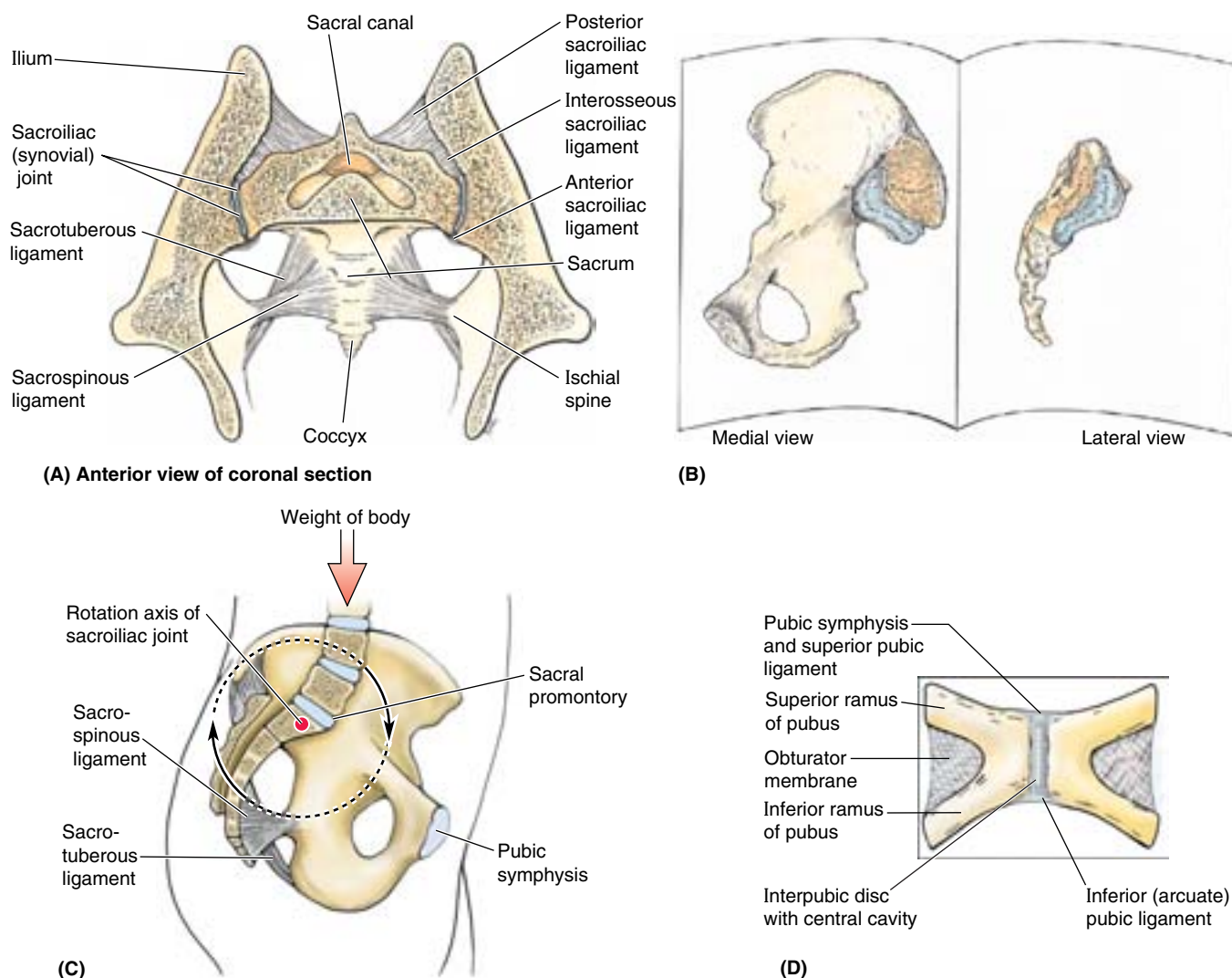


Figure 3.4. Sacroiliac joints and pubic symphysis with associated ligaments. **A.** The posterior half of a coronally sectioned pelvic girdle and its sacroiliac joints are shown. The strong interosseous sacroiliac ligaments lie deep (anteroinferior) to the posterior sacroiliac ligaments and consist of shorter fibers connecting the tuberosity of the sacrum to the tuberosity of the ilium, suspending the sacrum. **B.** The auricular surfaces and tuberosities of the ilium and sacrum are demonstrated. **C.** The weight of the body is transmitted to the sacrum anterior to the axis of rotation at the sacroiliac joint. The tendency for increased weight or force to rotate the upper sacrum anteriorly and inferiorly is resisted by the strong sacrotuberous and sacrospinous ligaments anchoring the inferior sacrum and coccyx to the ischium. **D.** The pubic symphysis is a secondary cartilaginous joint between the bodies of the pubic bones (Fig. 3.3).

ligaments (Figs. 3.3B and 3.4A). The thin **anterior sacroiliac ligaments** are merely the anterior part of the fibrous capsule of the synovial part of the joint. The abundant **interosseous sacroiliac ligaments** (lying deep between the tuberosities of the sacrum and ilium and occupying an area of approximately 10 cm²) are the primary structures involved in transferring the weight of the upper body from the axial skeleton to the two ilia of the appendicular skeleton. The **posterior sacroiliac ligaments** are the posterior external continuation of the same mass of fibrous tissue. Because the fibers of the interosseous and posterior sacroiliac ligaments run obliquely upward and outward from the sacrum, the axial weight pushing down on the sacrum actually pulls the ilia inward (medially) so that they compress the sacrum between them, locking the irregular but congruent surfaces of the sacroiliac joints together. The iliolumbar ligaments are accessory ligaments to this mechanism.

Inferiorly, the posterior sacroiliac ligaments are joined by fibers extending from the posterior margin of the ilium (between the posterior superior and posterior inferior iliac spines) and the base of the coccyx to form the **sacrospinous ligament**. This massive ligament thus passes from the posterior ilium and lateral sacrum and coccyx to the ischial tuberosity, transforming the sciatic notch of the hip bone into a large sciatic foramen. The **sacrospinous ligament**, passing from lateral sacrum and coccyx to the ischial spine, further subdivides this foramen into **greater** and **lesser sciatic foramina**.

Most of the time, movement at the sacroiliac joint is limited by the interlocking of the articulating bones and the sacroiliac ligaments to slight gliding and rotary movements (Fig. 3.4C). When landing after a high jump or when weightlifting in the standing position, exceptional force is transmitted through the bodies of the lumbar vertebrae to the superior end of the sacrum. Because this transfer of weight occurs anterior to the axis of the sacroiliac joints, the superior end of the sacrum is pushed inferiorly and anteriorly. However, rotation of the superior sacrum is counter-

balanced by the strong sacrotuberous and sacrospinous ligaments that anchor the inferior end of the sacrum to the ischium, preventing its superior and posterior rotation (Figs. 3.3B & C and 3.4A–C). By allowing only slight upward movement of the inferior end of the sacrum relative to the hip bones, resilience is provided to the sacroiliac region when the vertebral column sustains sudden increases in force or weight.

Pubic Symphysis

This secondary cartilaginous joint consists of a fibrocartilaginous interpubic disc and surrounding ligaments uniting the bodies of the pubic bones in the median plane (Figs. 3.3 and 3.4D). The **interpubic disc** is generally wider in women. The ligaments joining the bones are thickened at the superior and inferior margins of the symphysis, forming superior and inferior pubic ligaments. The **superior pubic ligament** connects the superior aspects of the pubic bodies and interpubic disc, extending as far laterally as the pubic tubercles. The **inferior (arcuate) pubic ligament** (Fig. 3.4D) is a thick arch of fibers that connects the inferior aspects of the joint components, rounding off the *subpubic angle* as it forms the apex of the *pubic arch* (Fig. 3.2A; Table 3.1). The decussating, fibers of the tendinous attachments of the rectus abdominis and external oblique muscles also strengthen the pubic symphysis anteriorly (see Chapter 2).

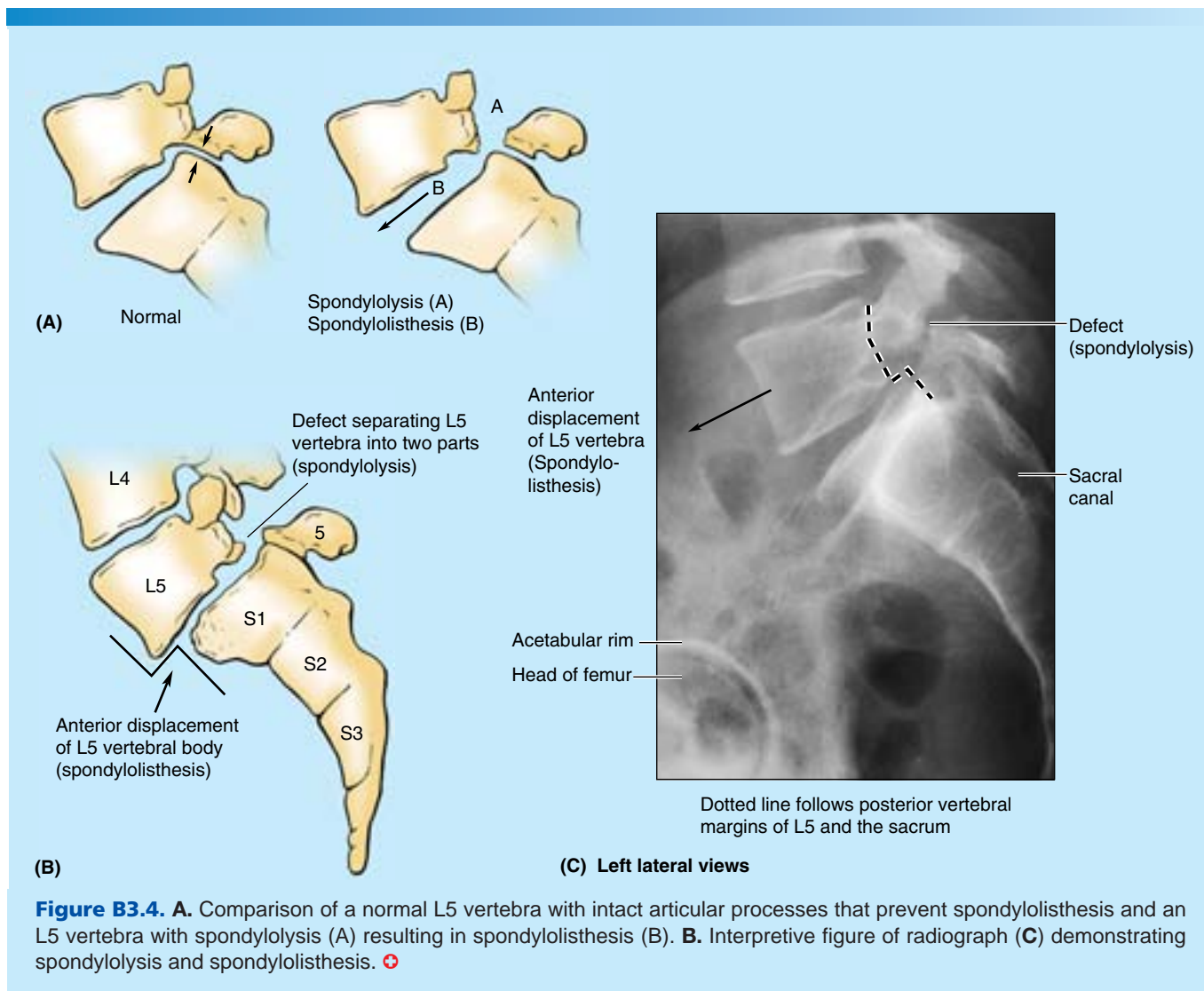
Lumbosacral Joints

L5 and S1 vertebrae articulate at the anterior **intervertebral (IV) joint** formed by the **IV disc** between their bodies (Fig. 3.3A) and at two posterior **zygapophysial joints** (facet joints) between the articular processes of these vertebrae. The facets on the S1 vertebra face posteromedially, interlocking with the anterolaterally facing inferior articular facets of the L5 vertebra, preventing the lumbar vertebra from sliding anteriorly down the incline of the sacrum. These joints are further strengthened by fan-like **iliolumbar ligaments** radiating from the transverse processes of the L5 vertebra to the ilia (Fig. 3.3B & C).

Spondylolysis and Spondylolisthesis

Spondylolysis is a defect allowing part of a *vertebral arch* (the posterior projection from the vertebral body that surrounds the spinal canal and bears the articular, transverse, and spinal processes) to be separated from its body. Spondylolysis of vertebra L5 results in the separation of the vertebral body from the part of its vertebral arch bearing the inferior articular processes. The inferior articular processes of L5 normally interlock with the articular processes of the sacrum. When the defect is bilateral, the body of the L5 vertebrae may slide anteriorly on the sacrum (**spondylolisthe-**

sis) so that it overlaps the sacral promontory (Fig. B3.4A). The intrusion of the L5 body into the pelvic inlet reduces the AP diameter of the pelvic inlet, which may interfere with parturition. It may also compress spinal nerves, causing low back or lower limb pain (see Chapter 4). Obstetricians test for spondylolisthesis by running their fingers along the lumbar spinous processes. An abnormally prominent L5 process indicates that the anterior part of L5 vertebra and the vertebral column superior to it may have moved anteriorly relative to the sacrum and the vertebral arch of L5. Medical images, such as sagittal MRI, are taken to confirm the diagnosis and to measure the AP diameter of the pelvic inlet. ►



Sacrococcygeal Joint

The **sacrococcygeal joint** is a secondary cartilaginous joint (Fig. 3.3A) with an IV disc. Fibrocartilage and ligaments join the apex of the sacrum to the base of the coccyx. The

anterior and posterior **sacrococcygeal ligaments** are long strands that reinforce the joint, much like the anterior and posterior longitudinal ligaments do for the superior vertebrae (Fig. 3.3B & C).

Relaxation of Pelvic Ligaments and Increased Joint Mobility during Pregnancy

The larger cavity of the interpubic disc of females increases in size during pregnancy. This change in size increases the circumference of the lesser pelvis and contributes to increased flexibility of the pubic symphysis. Increased levels of sex hormones and the presence of the hormone *relaxin* cause the pelvic ligaments to relax during the latter half of pregnancy, allowing increased movement at the pelvic

joints. Relaxation of sacroiliac joints and the pubic symphysis permits as much as a 10–15% increase in diameters (mostly transverse, including the interspinous distance), facilitating passage of the fetus through the pelvic canal. The coccyx is also allowed to move posteriorly.

The one diameter that remains unaffected is the true (conjugate) diameter between the sacral promontory and the posterosuperior aspect of the pubic symphysis. Relaxation of sacroiliac ligaments causes the interlocking mechanism of the sacroiliac joint to become less effective, permitting greater rotation of the pelvis and ▶

contributing to the lordotic (“swayback”) posture often assumed during pregnancy with the change in the center of gravity. Relaxation of ligaments is not limited to the pelvis, and the possibility of joint dislocation increases during late pregnancy. +

THE BOTTOM LINE: The sacroiliac joints are specialized compound synovial and syndesmotomic joints, the structures of which reflect both the primary (weightbearing/weight transfer and stability) and the secondary (parturition) functions of the pelvis. Strong interosseous and posterior sacroiliac ligaments suspend the sacrum between the ilia, transferring weight and stabilizing the bony ring of the pelvis. The synovial joints allow slight but significant movement during childbirth, when the pubic symphysis and the

ligaments are softened by hormones. To counterbalance the weight of the upper body and additional forces generated by activities such as jumping and load bearing, which are received by the superior sacrum anterior to the rotatory axis of the sacroiliac joints, the inferior end of the sacrum is anchored to the ischium by the substantial sacrotuberous and sacrospinous ligaments.

Pelvic Cavity

The *abdominopelvic cavity* extends superiorly into the thoracic cage and inferiorly into the pelvis, so that its superior and inferior parts are relatively protected (Fig. 3.5A). Perforating wounds in either the thorax or the pelvis may therefore involve the abdominopelvic cavity and its contents. The funnel-shaped **pelvic cavity**—the space bounded peripherally by the bony, ligamentous, muscular pelvic walls and floor—is the inferoposterior part of the abdominopelvic cavity, continuous

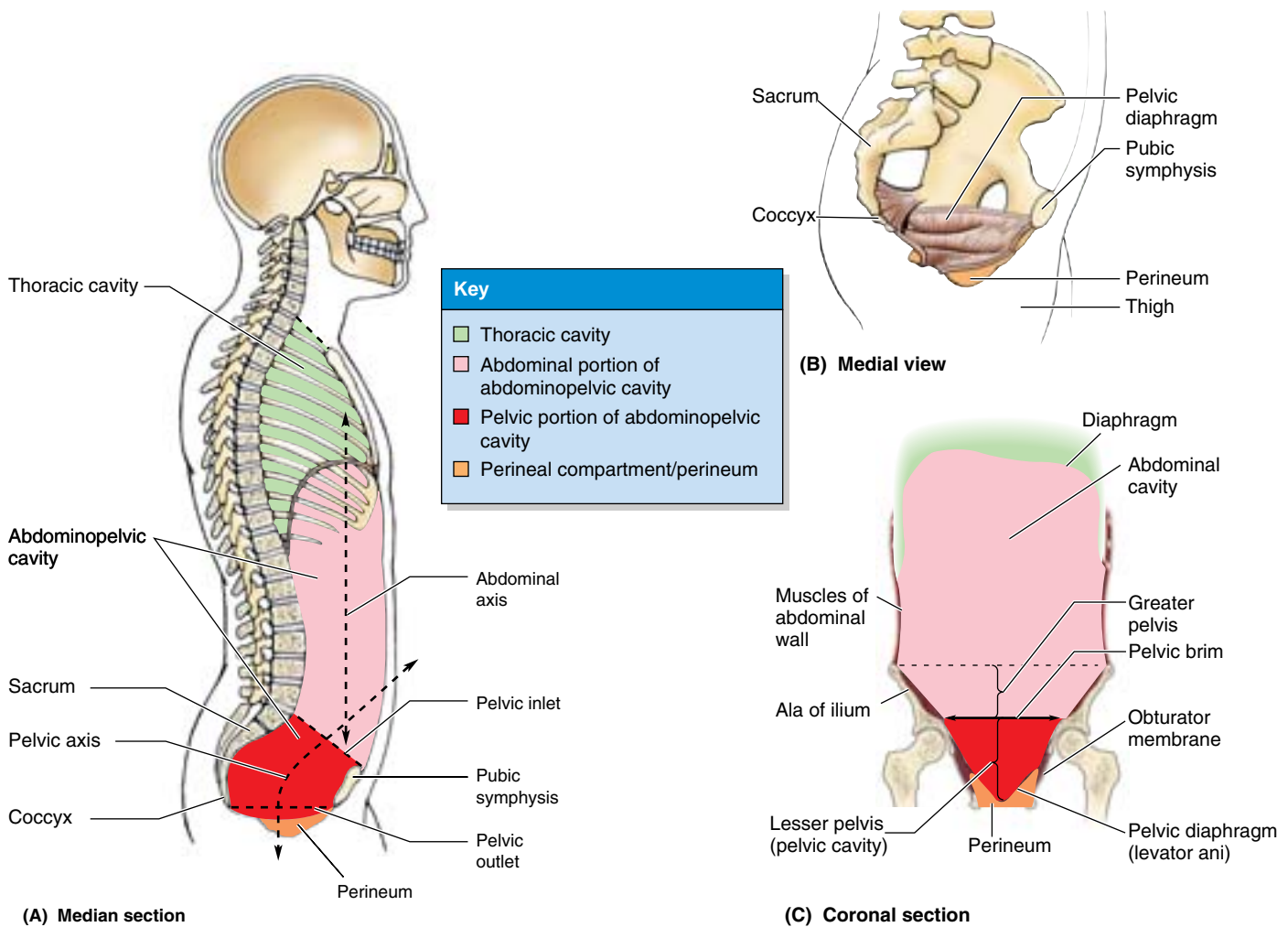


Figure 3.5. Thoracic and abdominopelvic cavities. A and C. These sections of the trunk show the relationship of the thoracic and abdominopelvic cavities. Although the greater pelvis and lesser pelvis (pelvic cavity) are actually continuous, they are demarcated by the plane of the pelvic inlet (defined by the pelvic brim). B. The pelvic diaphragm is a dynamic barrier separating the lesser pelvis and the perineum, forming the floor of the former and roof of the latter.

with the abdominal cavity at the *pelvic inlet* but angulated posteriorly from it (Fig. 3.5A & C). Although continuous, the abdominal and pelvic cavities are described separately for descriptive purposes, facilitating the regional approach.

The pelvic cavity contains the terminal parts of the ureters and the urinary bladder, rectum, pelvic genital organs, blood vessels, lymphatics, and nerves. In addition to these distinctly pelvic viscera, it also contains what might be considered an overflow of abdominal viscera: loops of small intestine (mainly ileum) and, frequently, large intestine (appendix and transverse and/or sigmoid colon). The pelvic cavity is limited inferiorly by the musculofascial *pelvic diaphragm*, which is suspended above (but descends centrally to the level of) the *pelvic outlet*, forming a bowl-like *pelvic floor*. The pelvic cavity is bounded posteriorly by the coccyx and inferiormost sacrum, with the superior part of the sacrum forming a roof over the posterior half of the cavity (Fig. 3.5A & B). The bodies of the pubic bones and the pubic symphysis uniting them form an anteroinferior wall that is much shallower (shorter) than the posterosuperior wall and ceiling formed by sacrum and coccyx. Consequently, the **axis of the pelvis** (a line in the median plane defined by the center point of the pelvic cavity at every level) is curved, pivoting around the pubic symphysis. The curving form of the axis and the disparity in depth between the anterior and the posterior walls of the cavity are important factors in the mechanism of fetal passage through the pelvic canal.

Walls and Floor of the Pelvic Cavity

The pelvic cavity has an anteroinferior wall, two lateral walls, a posterior wall (or posterolateral wall and a roof), and a floor (Fig. 3.6; Table 3.2).

Anteroinferior Pelvic Wall

The anteroinferior pelvic wall (more of a weight-bearing floor than an anterior wall in the anatomical position) is formed primarily by the bodies and rami of the pubic bones and the pubic symphysis (Figs. 3.4D and 3.6B–D). It participates in bearing the weight of the urinary bladder.

Lateral Pelvic Walls

Figure 3.6B & C shows the lateral pelvic wall being constructed as layers are added in a “reversed-dissection” sequence. The lateral pelvic walls are formed by the right and left hip bones, each of which includes an obturator foramen closed by an **obturator membrane** (Fig. 3.6A). The fleshy attachments of the **obturator internus muscles** cover and thus pad most of the lateral pelvic walls (Figs. 3.6C). The fleshy fibers of each obturator internus converge posteriorly, become tendinous, and turn sharply laterally to pass from the lesser pelvis through the *lesser sciatic foramen* to attach to the greater trochanter of the femur. The medial surfaces of these muscles are covered by **obturator fascia**, thickened centrally as a *tendinous arch* that provides attachment for the pelvic diaphragm (Fig. 3.6D). Because this diaphragm is the bound-

ary between the pelvis and the perineum, forming the floor of the pelvic cavity and the roof of the perineum (Fig. 3.7A), this attachment divides the muscle into a superior pelvic portion and an inferior perineal portion (Fig. 3.7B). Medial to the pelvic portions of these muscles are the obturator nerves and vessels and other branches of the internal iliac vessels.

Posterior Wall (Posterolateral Wall and Roof)

In the anatomical position, the posterior pelvic wall consists of a bony wall and roof in the midline (formed by the sacrum and coccyx) and musculoligamentous posterolateral walls, formed by the ligaments associated with the sacroiliac joints and **piriformis muscles** (Fig. 3.6A–C). The ligaments include the anterior sacroiliac, sacrospinous, and sacrotuberous ligaments. The piriformis muscles arise from the superior sacrum, lateral to its pelvic foramina (Fig. 3.6A; Table 3.2A). The muscles pass laterally, leaving the lesser pelvis through the *greater sciatic foramen* to attach to the superior border of the greater trochanter of the femur (Table 3.2B). These muscles occupy much of the greater sciatic foramen, forming the posterolateral walls of the pelvic cavity (Fig. 3.6A). Immediately deep (anteromedial) to these muscles (often embedded in the fleshy fibers) are the nerves of the *sacral plexus* (Fig. 3.6D). A gap at the inferior border of the piriformis allows passage of neurovascular structures between the pelvis and the lower limb (gluteal region).

Pelvic Floor

The pelvic floor is formed by the bowl- or funnel-shaped **pelvic diaphragm**, which consists of the coccygeus and levator ani muscles and the fascias (*L. fasciae*) covering the superior and inferior aspects of these muscles (Figs. 3.6A and 3.7; Table 3.2). The pelvic diaphragm separates the pelvic cavity from the perineum within the lesser pelvis.

The **coccygeus muscles** arise from the lateral aspects of the inferior sacrum and coccyx, their fleshy fibers underlying the deep surface of the sacrospinous ligament (Fig. 3.6B & C). The **levator ani** (a broad muscular sheet) is the larger and more important part of the pelvic floor. It is attached to the bodies of the pubic bones anteriorly, to the ischial spines posteriorly, and to a thickening in the obturator fascia (the **tendinous arch of the levator ani**) between the two bony sites on each side. The pelvic diaphragm thus stretches between the anterior, the lateral, and the posterior walls of the lesser pelvis, giving it the appearance of a hammock suspended from these attachments, closing much of the ring of the pelvic girdle. An anterior gap between the medial borders of the levator ani muscles of each side—the **urogenital hiatus**—gives passage to the urethra and, in females, the vagina.

The levator ani consists of three parts, designated according to the attachment and course of its fibers (Figs. 3.6A & D and 3.7; Table 3.2):

- **Puborectalis:** the thicker, narrower, medial part of the levator ani, consisting of muscle fibers that are continuous between the posterior aspects of the right and left pubic

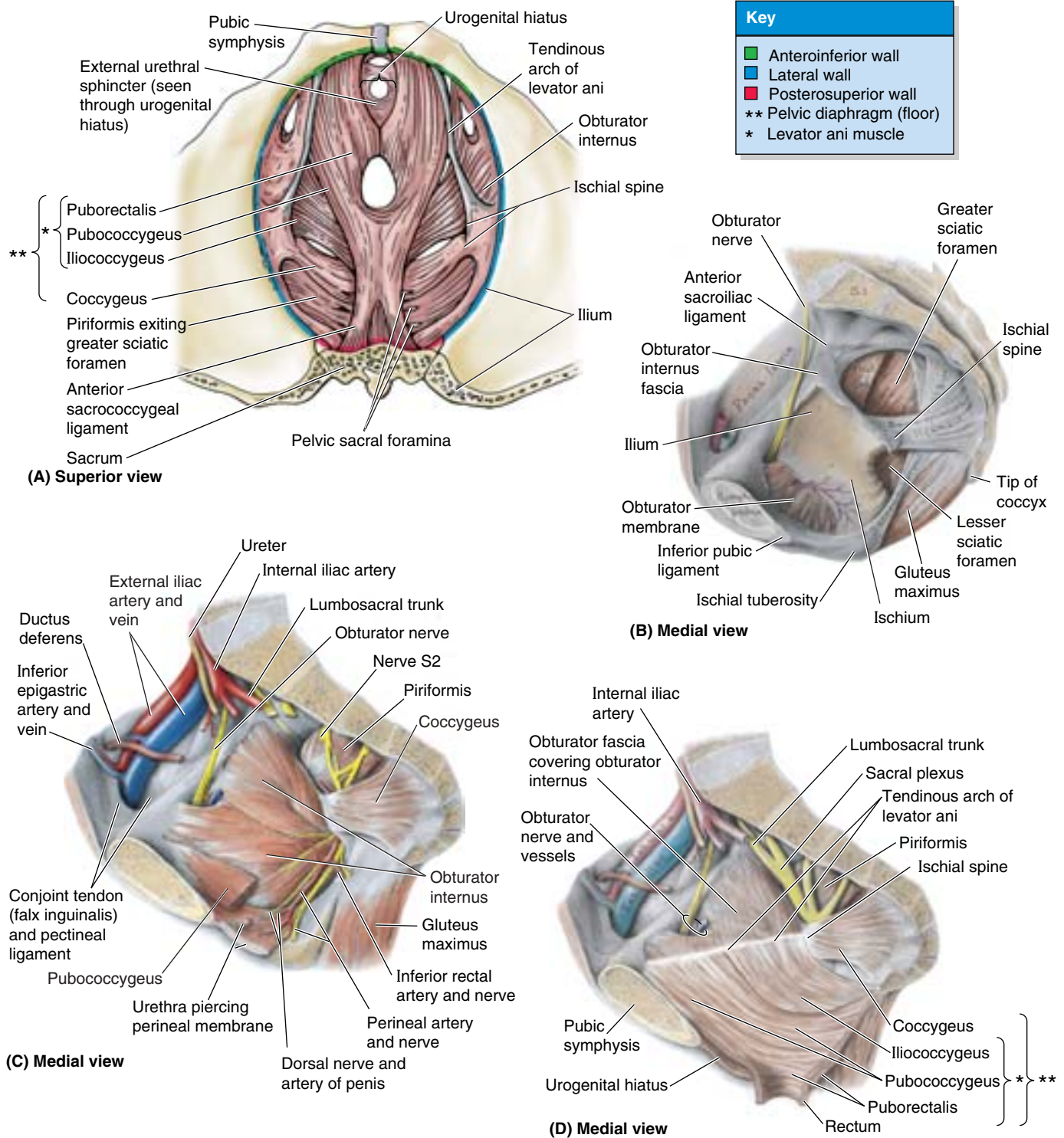
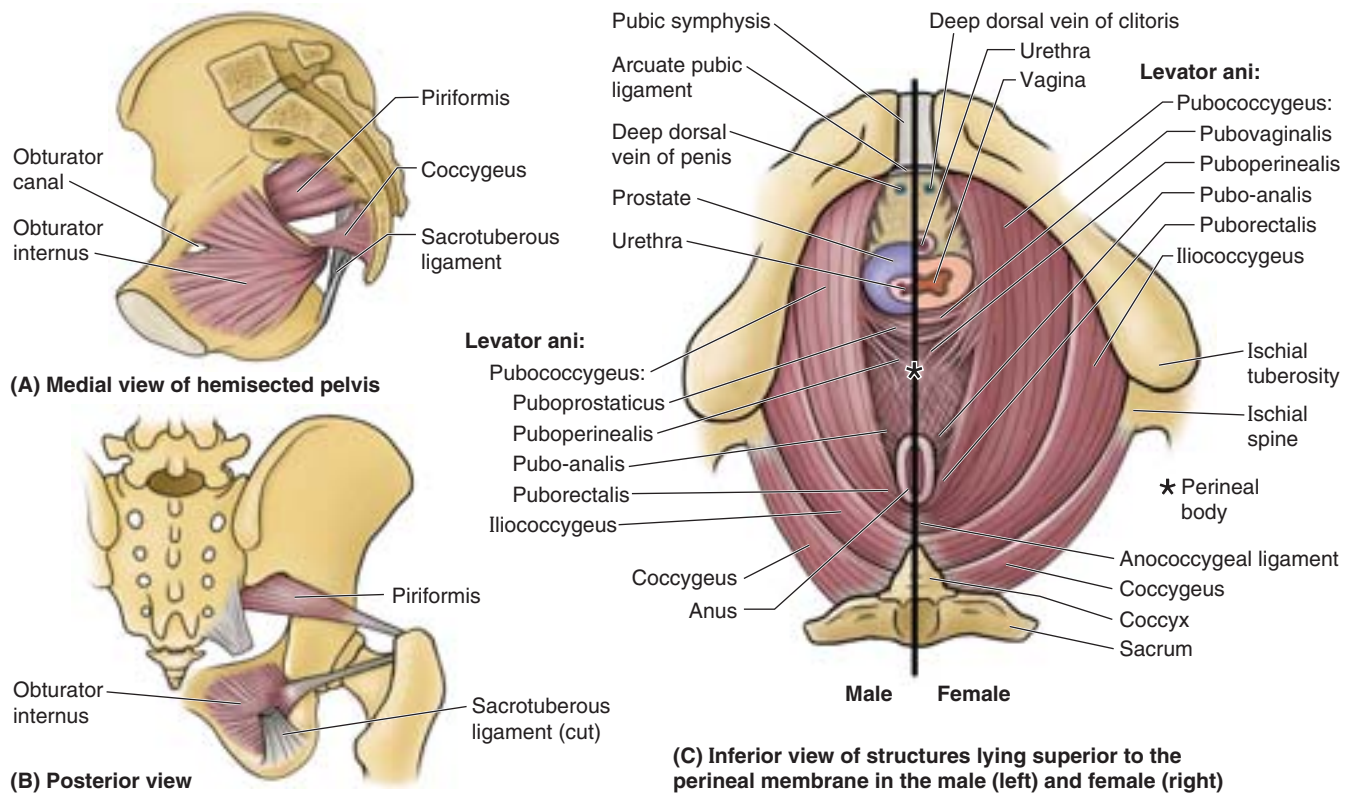


Figure 3.6. Floor and walls of pelvis. **A.** The floor of the pelvis is formed by the pelvic diaphragm, encircled by and suspended in part from the pubic symphysis and pubic bones anteriorly, the ilia laterally, and the sacrum and coccyx posteriorly. Parts **B** through **D** show the staged reconstruction of the parietal structures of the right hemipelvis. **B.** Posterolaterally, the coccyx and inferior part of the sacrum are attached to the ischial tuberosity by the sacrotuberous ligament and to the ischial spine by the sacrospinous ligament. The obturator membrane, composed of strong interlacing fibers, fills the obturator foramen. **C.** The muscles of the lesser pelvis are added. The obturator internus pads the lateral wall of the pelvis, its fibers converging to escape posteriorly through the lesser sciatic foramen (see part **B**). **D.** The levator ani is added, suspended from a thickening in the obturator fascia (the tendinous arch), which extends from the pubic body to the ischial spine.

Table 3.2. Muscles of the Pelvic Walls and Floor



(C) Inferior view of structures lying superior to the perineal membrane in the male (left) and female (right)

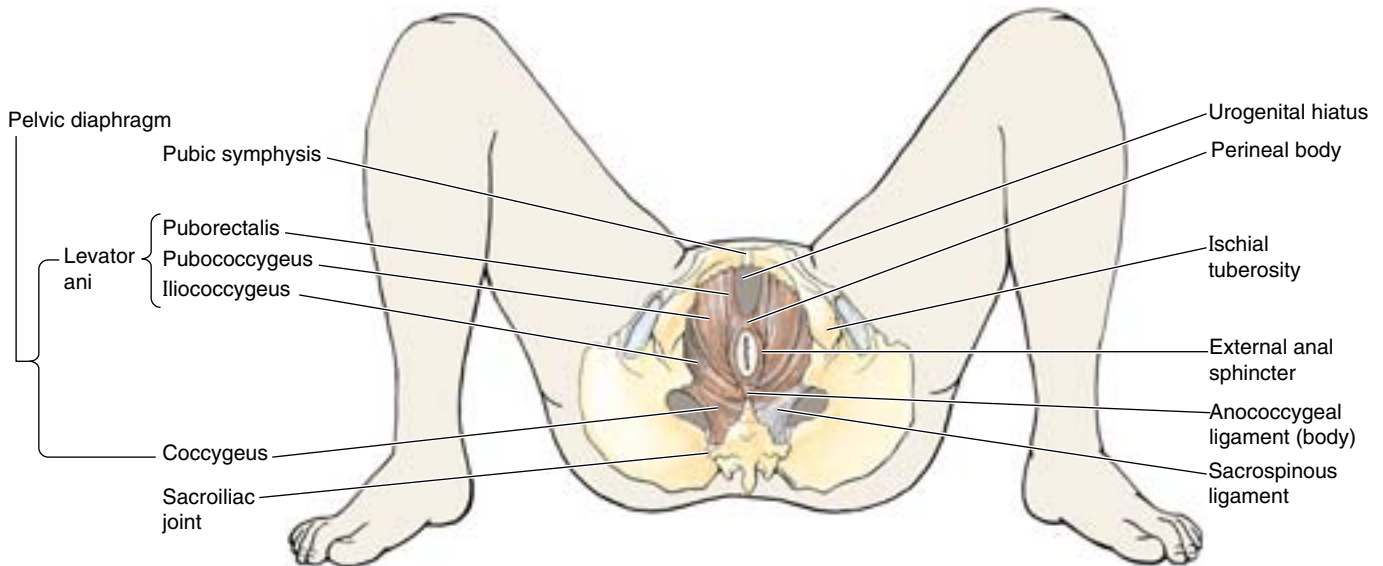
Boundary	Muscle	Proximal Attachment	Distal Attachment	Innervation	Main Action
Lateral wall	Obturator internus	Pelvic surfaces of ilium and ischium; obturator membrane	Greater trochanter of femur	Nerve to obturator internus (L5, S1, S2)	Rotates thigh laterally; assists in holding head of femur in acetabulum
Posterolateral wall	Piriformis	Pelvic surface of S2–S4 segments; superior margin of greater sciatic notch and sacrotuberous ligament	Greater trochanter of femur	Anterior rami of S1 and S2	Rotates thigh laterally; abducts thigh; assists in holding head of femur in acetabulum
Floor	Coccygeus (ischio-coccygeus)	Ischial spine	Inferior end of sacrum	Branches of S4 and S5 spinal nerves	Forms small part of pelvic diaphragm that supports pelvic viscera; flexes coccyx
	Levator ani (pubococcygeus and iliococcygeus)	Body of pubis; tendinous arch of obturator fascia; ischial spine	Perineal body; coccyx; anococcygeal ligament; walls of prostate or vagina, rectum, and anal canal	Nerve to levator ani (branches of S4), inferior anal (rectal) nerve, and coccygeal plexus	Helps support pelvic viscera and resists increases in intra-abdominal pressure

bodies. It forms a U-shaped muscular sling (puborectal sling) that passes posterior to the anorectal junction (Fig. 3.8), bounding the urogenital hiatus. This part plays a major role in maintaining fecal continence.

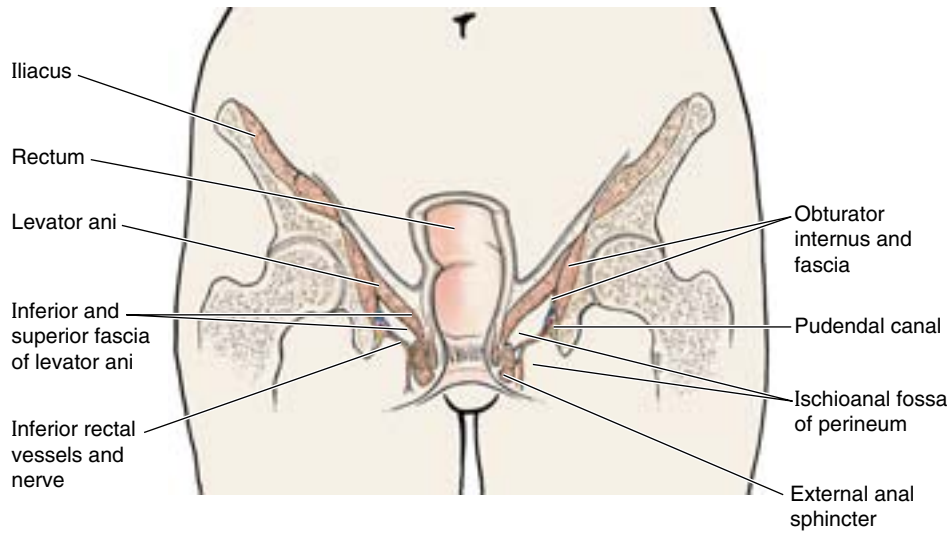
- **Pubococcygeus:** the wider but thinner intermediate part of the levator ani, which arises lateral to the puborectalis from the posterior aspect of the body of the pubis and anterior tendinous arch (Figs. 3.6A & D and 3.7; Table 3.2). It passes posteriorly in a nearly horizontal plane; its lateral

fibers attach to the coccyx and its medial fibers merge with those of the contralateral muscle to form a fibrous raphe or tendinous plate, part of the **anococcygeal body or ligament** between the anus and the coccyx (often referred to clinically as the “levator plate”).

- **Iliococcygeus:** the posterolateral part of the levator ani, which arises from the posterior tendinous arch and ischial spine. It is thin and often poorly developed (aponeurotic) and also blends with the anococcygeal body posteriorly.



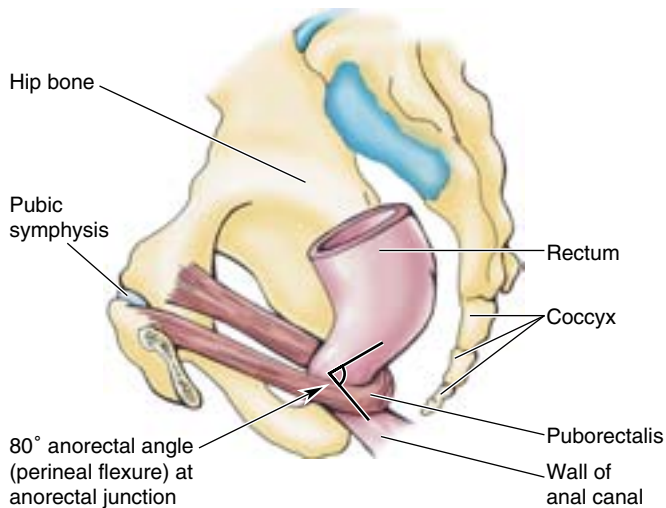
(A) Inferior view of perineum, lithotomy position



(B) Anterior view of schematic coronal section

Figure 3.7. Pelvic diaphragm and anorectum in situ. A and B.

The components of the pelvic diaphragm (levator ani and coccygeus) form the floor of the pelvic cavity and the roof of the perineum. **B.** The basin-like nature for which the pelvis was named is evident in this cross-section. The fat-filled ischioanal fossae of the perineum also lie within the bony ring of the lesser pelvis.



Medial view from left

Figure 3.8. Puborectalis muscle.

Most of left hip bone has been removed to demonstrate that this part of the levator ani is formed by continuous muscle fibers following a U-shaped course around the anorectal junction. The puborectalis thus forms a puborectal sling, the tonus of which is responsible for maintaining the anorectal angle (perineal flexure).

The levator ani forms a dynamic floor for supporting the abdominopelvic viscera. It is tonically contracted most of the time to support the abdominopelvic viscera and to assist in maintaining urinary and fecal continence. It is actively contracted during activities such as forced expiration, coughing, sneezing, vomiting, and fixation of the trunk during strong movements of the upper limbs (e.g., when lifting heavy objects), primarily to increase support of the viscera during periods of increased intra-abdominal pressure (resisting forces that would push it through the pelvic outlet), and perhaps secondarily to contribute to the increased pressure (to aid expulsion). Penetrated centrally by the anal canal, the levator ani is funnel shaped, with the U-shaped puborectalis

looping around the “funnel spout,” its tonic contraction bends it anteriorly. Active contraction of the (voluntary) puborectalis portion is important in maintaining fecal continence immediately after rectal filling or during peristalsis when the rectum is full and the involuntary sphincter muscle is inhibited (relaxed). The levator ani must relax to allow urination and defecation. The increased intra-abdominal pressure for defecation is provided by contraction of the (thoracic) diaphragm and muscles of the anterolateral abdominal wall. Acting together, the parts of the levator ani elevate the pelvic floor after their relaxation and the consequent descent of the pelvic diaphragm that occurs during urination and defecation.

Injury to the Pelvic Floor

During childbirth, the pelvic floor supports the fetal head while the cervix of the uterus is dilating to permit delivery of the fetus. The perineum, levator ani, and pelvic fascia may be injured during childbirth (Fig. B3.5A); the pubococcygeus, the main and most medial part of the levator ani, is torn most often (Fig. B3.5B). This part of the muscle is important because it encircles and supports the urethra, vagina, and anal canal. Weakening of the levator ani and pelvic fascia, resulting from stretching or tearing during childbirth, may alter the position of the neck of the bladder and the urethra. These

changes may cause *urinary stress incontinence*, characterized by dribbling of urine when intra-abdominal pressure is raised during coughing and lifting, for instance.

Prenatal “Relaxation” Training for Participatory Childbirth

Parents wishing to participate actively in the birth of their baby may take prenatal training (e.g., Lamaze classes) that, among other things, attempts to train women to learn how to relax voluntarily the muscles of the pelvic floor while simultaneously increasing intra-abdominal pressure through contraction of the diaphragm and anterolateral

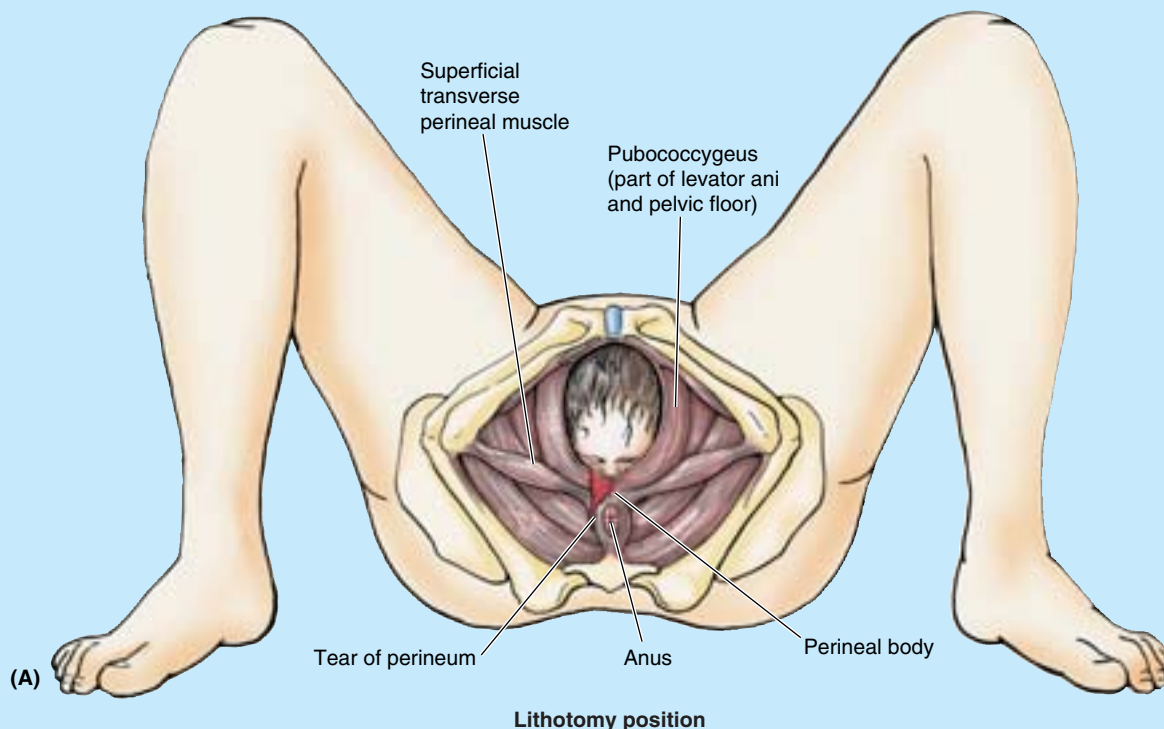
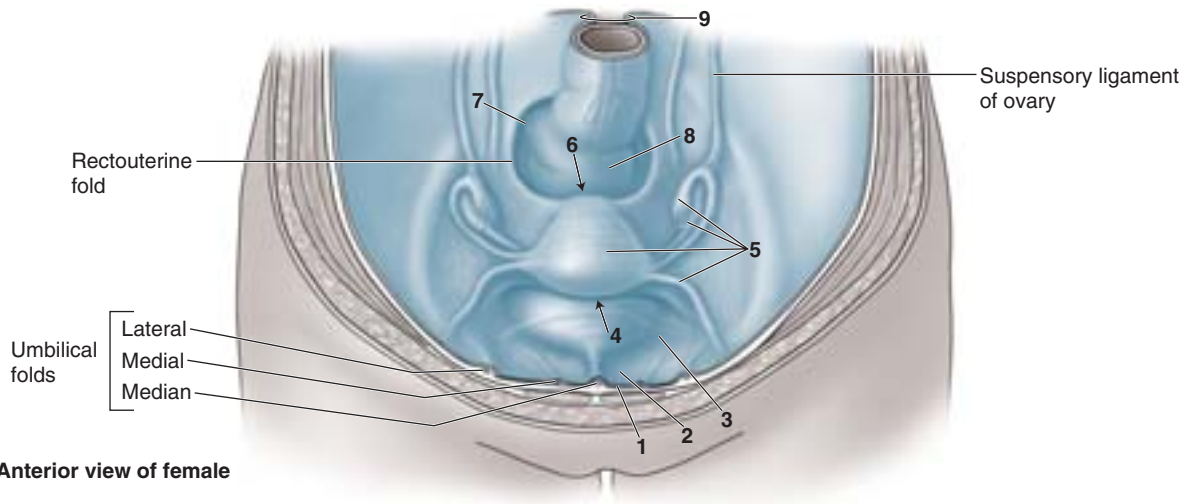
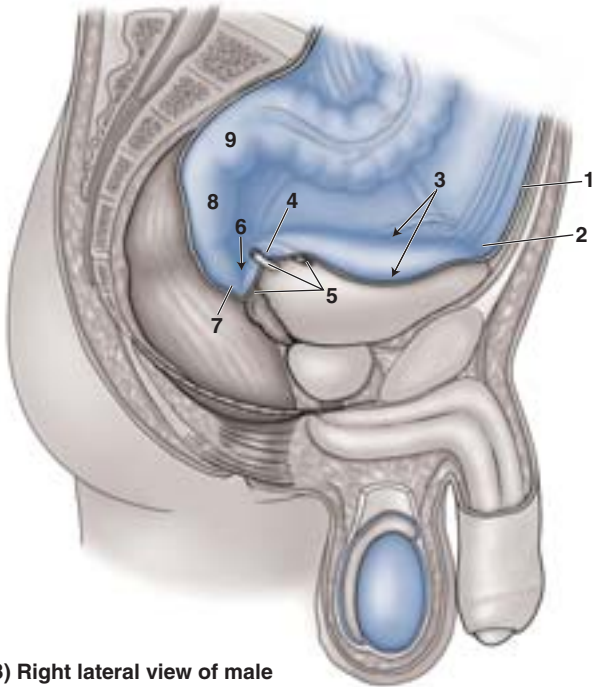


Figure B3.5

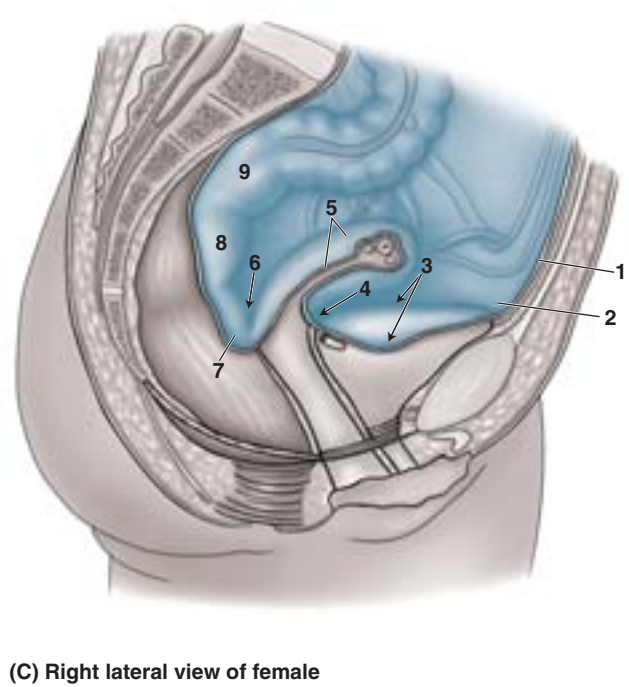
Table 3.3. Peritoneal Reflections in the Pelvis^a



(A) Anterior view of female



(B) Right lateral view of male



(C) Right lateral view of female

Male (Fig. B)	Female (Fig. A & C)
1. Descends anterior abdominal wall (loose attachment allows insertion of bladder as it fills)	1. Descends anterior abdominal wall (loose attachment allows insertion of bladder as it fills)
2. Reflects onto superior surface of bladder, creating supravescical fossa	2. Reflects onto superior surface of bladder, creating supravescical fossa
3. Covers convex superior surface (roof) of bladder and slopes down sides of roof to ascend lateral wall of pelvis, creating paravesical fossae on each side	3. Covers convex superior surface (roof) of bladder and slopes down sides of roof to ascend lateral wall of pelvis, creating paravesical fossae on each side
4. Descends posterior surface of bladder as much as 2 cm	4. Reflects from bladder roof onto body of uterus forming vesicouterine pouch
5. Laterally, forms fold over ureters (ureteric fold), ductus deferens, and superior ends of seminal glands	5. Covers body and fundus of uterus and posterior fornix of vagina; extends laterally from uterus as double fold or mesentery—broad ligament that engulfs uterine tubes, ovaries, and round ligaments of uterus

(continues)

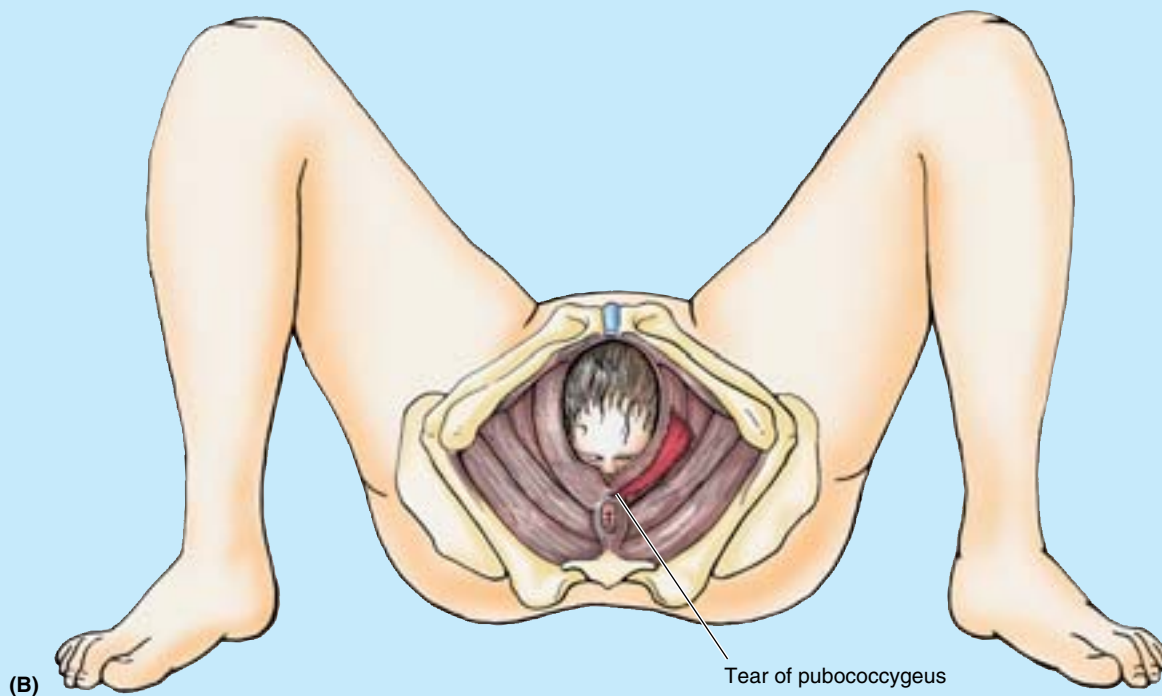


Figure B3.5 (Continued)

abdominal wall muscles. The aim of this method is to facilitate passage of the fetus through the birth canal, actively pushing (“bearing down”) to aid the uterine contractions that expel the baby without providing resistance (and per-

haps minimizing obstetrical tearing) caused by contraction of the pelvic muscles. Except when defecating or urinating, the natural reflex is to contract pelvic musculature in response to increased intra-abdominal pressure. +

THE BOTTOM LINE: The pelvic cavity, between the pelvic inlet superiorly and the pelvic diaphragm inferiorly, contains the terminal parts of the urinary and alimentary systems, the internal genital organs, the associated vascular structures, and the nerves supplying both the pelvis and lower limbs. The pubic symphysis and bones of the lesser pelvis bound the cavity; they do so directly in the region of the midline anteriorly and posterosuperiorly. The lateral walls are padded by the obturator internus muscles. The sacrotuberous and sacrospinous ligaments form the greater sciatic foramen in the posterolateral walls. This foramen is

filled by the structures that traverse it, including the piriformis muscles. The dynamic floor of the pelvic cavity is the hammock-like pelvic diaphragm, composed of the levator ani and coccygeus muscles. The levator ani is a tripartite, funnel-shaped muscular sheet formed by the puborectalis, pubococcygeus, and iliococcygeus muscles. In addition to the levator’s general role of supporting abdominopelvic viscera as part of the pelvic diaphragm, the puborectalis is particularly involved in maintaining fecal continence. The ability of the musculofascial pelvic floor to relax and distend is critical to the functions of defecation and parturition.

Table 3.3. Peritoneal Reflections in the Pelvis (Continued)

Male (Fig. B)	Female (Fig. A & C)
6. Reflects from bladder and seminal glands onto rectum, forming rectovesical pouch	6. Reflects from vagina onto rectum, forming rectouterine pouch
7. Rectovesical pouch extends laterally and posteriorly to form pararectal fossae on each side of rectum	7. Rectouterine pouch extends laterally and posteriorly to form pararectal fossae on each side of rectum
8. Ascends rectum; from inferior to superior, rectum is subperitoneal and then retroperitoneal	8. Ascends rectum; from inferior to superior, rectum is subperitoneal and then retroperitoneal
9. Engulfs sigmoid colon beginning at rectosigmoid junction	9. Engulfs sigmoid colon beginning at rectosigmoid junction

^aNumbers refer to table figures.

Peritoneum and Peritoneal Cavity of the Pelvis

The parietal peritoneum lining the abdominal cavity continues inferiorly into the pelvic cavity but does not reach the pelvic floor, from which it is separated by the pelvic viscera—onto which it is reflected—and the pelvic fascia in which the viscera are embedded (Table 3.3). Except for the ovaries and uterine tubes, the pelvic viscera are not completely ensheathed by the peritoneum, lying inferior to it for the main part; only their superior and superolateral surfaces are covered. Only the uterine tubes (except for their ostia, which are open) are intraperitoneal and suspended by a mesentery. The ovaries, although suspended in the peritoneal cavity by a mesentery, are not covered with glistening peritoneum; instead a special, relatively-dull epithelium of cuboidal cells covers them.

A loose areolar layer between the transversalis fascia and the parietal peritoneum of the inferior part of the anterior abdominal wall allows the bladder to expand between these layers as it becomes distended with urine. The region superior to the bladder (1 in Table 3.3) is the only site where the parietal peritoneum is not firmly bound to the underlying structures. Consequently, the level at which the peritoneum reflects onto the superior surface of the bladder, creating the **supravesical fossa** (2 in Table 3.3) is variable, depending on the fullness of the bladder. When the peritoneum reflects from the abdominopelvic wall onto the pelvic viscera and fascia, a series of folds and fossae are created (2–7 in Table 3.3).

In the female, as the peritoneum at or near the midline reaches the posterior border of the roof of the bladder, it reflects onto the anterior aspect of the uterus at the uterine neck or isthmus (see “Female Internal Genital Organs,” in this chapter); thus it is not related to the anterior vaginal fornix, which is subperitoneal in location. The peritoneum passes over the fundus and descends the entire posterior aspect of the uterus onto the posterior vaginal wall before reflecting superiorly onto the anterior wall of the inferior rectum (rectal ampulla). The “pocket” thus formed between the uterus and the rectum is the **rectouterine pouch** (or cul-de-sac, of Douglas) (6 in Table 3.3C). The median rectouterine pouch is often described as the being inferiormost extent of the peritoneal cavity in the female, but often its lateral extensions on each side of the rectum, the **pararectal fossae**, are deeper.

Prominent peritoneal ridges, the **rectouterine folds**, formed by underlying fascial ligaments demarcate the lateral boundaries of the pararectal fossae (Table 3.3A). As the peritoneum passes up and over the uterus in the middle of the pelvic cavity, a double peritoneal fold, the **broad ligament of the uterus**, extends between the uterus and the lateral pelvic wall on each side, forming a partition that separates the paravesical fossae and pararectal fossae of each side. The uterine tubes, ovaries, ligaments of the ovaries, and round ligaments of the uterus are enclosed within the broad liga-

ments. Subdivisions of the broad ligament related to these structures will be discussed with the uterus later in this chapter. Recall that in the female the pelvic peritoneal cavity communicates with the external environment via the uterine tubes, uterus, and vagina.

In males and in women who have had their uterus removed (a *hysterectomy*), the central peritoneum descends a short distance (as much as 2 cm) down the posterior surface (base) of the bladder and then reflects superiorly onto the anterior surface of the inferior rectum, forming the **rectovesical pouch**, often described as the inferiormost extent of the peritoneal cavity in those lacking a uterus. Once again, however, the lateral continuities of the rectovesical pouch to each side of the rectum, the pararectal fossae, are often deeper than the median portion. The female rectouterine pouch is normally deeper (extends farther caudally) than the male rectovesical pouch. In the male, a gentle peritoneal fold or ridge, the **ureteric fold**, is formed as the peritoneum passes up and over the ureter and *ductus (vas) deferens* (the secretory duct of the testis) on each side of the posterior bladder, separating the paravesical and pararectal fossae; in this regard, it is the male equivalent of the broad ligament. Posterior to the ureteric folds and lateral to the central rectovesical pouch, the peritoneum often descends far enough caudally to cover the superior ends or superior posterior surfaces of the *seminal glands (vesicles)* and *ampullae of the ductus deferens*. Except for these sites (and the testis in its tunica vaginalis, which is derived from peritoneum), the male reproductive organs are not in contact with the peritoneum.

In both sexes, the inferior third of the rectum is below the inferior limits of the peritoneum (i.e., it is subperitoneal), the middle third is covered with peritoneum only on its anterior surface, and the superior third is covered on both its anterior and its lateral surfaces. The rectosigmoid junction, near the pelvic brim, is intraperitoneal.

THE BOTTOM LINE: The peritoneum lining the abdominal cavity continues into the pelvic cavity, reflecting onto the superior aspects of most pelvic viscera (only the lengths of the uterine tubes, but not their free ends, are fully intraperitoneal and have a mesentery). In so doing, the peritoneum creates a number of folds and fossae. Because the peritoneum is not firmly bound to the suprapubic abdominal wall, the bladder is able to expand between the peritoneum and the anterior abdominal wall as it fills, elevating the supravesical fossae. The rectovesical pouch and its lateral extensions, the pararectal fossae, are the inferiormost extents of the peritoneal cavity in males. In females, the uterus is located between the bladder and rectum, creating uterovesical and rectouterine pouches. The lateral extensions of the peritoneal fold engulfing the uterine fundus form the broad ligament, a transverse duplication

of peritoneum separating the paravesical and pararectal fossae. The rectouterine fossa and its lateral extensions, the pararectal fossae, are the inferiormost extents of the peritoneal cavity in females.

Pelvic Fascia

The **pelvic fascia** is connective tissue that occupies the space between the membranous peritoneum and the muscular pelvic walls and floor not occupied by the pelvic viscera. This “layer” is a continuation of the comparatively thin (except around kidneys) endoabdominal fascia that lies between the muscular abdominal walls and the peritoneum superiorly. Traditionally, the pelvic fascia has been described as having parietal and visceral components (Fig. 3.9).

Membranous Pelvic Fascia: Parietal and Visceral

The **parietal pelvic fascia** is a membranous layer of variable thickness that lines the inner (deep or pelvic) aspect of the muscles forming the walls and floor of the pelvis (Fig. 3.9). The parietal pelvic fascia therefore covers the pelvic surfaces of the obturator internus, piriformis, coccygeus, levator ani, and part of the urethral sphincter muscles. Specific parts of the parietal fascia are named for the muscle they cover (e.g., obturator fascia). This layer is continuous superiorly with the transversalis and iliopsoas fascias.

The **visceral pelvic fascia** includes the membranous fascia that directly ensheathes the pelvic organs, forming the adventitial layer of each. The membranous parietal and visceral layers become continuous where the organs penetrate the pelvic floor (Fig. 3.9A & C). Here the parietal fascia thickens, forming the **tendinous arch of pelvic fascia**, a continuous bilateral band running from the pubis to the sacrum along the pelvic floor adjacent to the viscera (Fig. 3.9B, D, & E). The anteriormost part of this tendinous arch (**puboprostatic ligament** in males; **pubovesical ligament** in females) connects the prostate to the pubis in the male or the fundus (base) of the bladder to the pubis in the female. The posteriormost part of the band runs as the **sacrogenital ligaments** from the sacrum around the side of the rectum to attach to the prostate in the male or the vagina in the female.

Endopelvic Fascia: Loose and Condensed

Usually, the abundant connective tissue remaining between the parietal and the visceral membranous layers is considered part of the visceral fascia, but various authors label parts of it as parietal. It is probably more realistic to consider this remaining fascia simply as extraperitoneal or *subperitoneal endopelvic fascia* (Fig. 3.9A & C), which is continuous with both the parietal and the visceral membranous fascias. This fascia forms a connective tissue matrix or packing material for the pelvic viscera (Fig. 3.9B & D). It varies markedly in density and content. Some of it is extremely loose **areolar (fatty) tissue**, relatively devoid of all but minor lymphatics and nutrient vessels. In dissection or surgery, the fingers can

be pushed into this loose tissue with ease, creating actual spaces by blunt dissection; for example, between the pubis and the bladder anteriorly and between the sacrum and the rectum posteriorly). These *potential spaces*, normally consisting only of a layer of loose fatty tissue, are the **retropubic** (or *prevesical*, extended posterolaterally as *paravesical*) and **retrorectal** (or *presacral*) spaces, respectively. The presence of loose connective tissue here accommodates the expansion of the urinary bladder and rectal ampulla as they fill.

Although these types of endopelvic fascia do not differ much in their gross appearance, other parts of the endopelvic fascia have a much more fibrous consistency, containing an abundance of collagen and elastic fibers and, according to some authors, a scattering of smooth muscle fibers. These parts are often described as “fascial condensations” or pelvic “ligaments.” For example, during dissection, if you insert the fingers of one hand into the retropubic space and the fingers of the other hand into the presacral space and attempt to bring them together along the lateral pelvic wall, you will find that they do not meet or pass from one space to the other. They encounter the so-called **hypogastric sheath**, a thick band of condensed pelvic fascia. This fascial condensation is not merely a barrier separating the two potential spaces; it gives passage to essentially all the vessels and nerves passing from the lateral wall of the pelvis to the pelvic viscera, along with the ureters and, in the male, the ductus deferens. As it extends medially from the lateral wall, the hypogastric sheath divides into three laminae (leaflets or wings) that pass to or between the pelvic organs, conveying neurovascular structures and providing support. Because of the latter function, they are also referred to as ligaments. The anteriormost lamina, the **lateral ligament of the bladder**, passes to the bladder, conveying the superior vesical arteries and veins. The posteriormost lamina passes to the rectum, conveying the middle rectal artery and vein.

In the male, the middle lamina forms a relatively thin fascial partition, the **rectovesical septum** (Fig. 3.9D), between the posterior surface of the bladder and the prostate anteriorly and the rectum posteriorly. In the female, the middle lamina is markedly more substantial than the other two, passing medially to the uterine cervix and vagina as the **transverse cervical (cardinal) ligament**, also known clinically as the *lateral cervical* or *Mackenrodt ligament* (Fig. 3.9B). In its superiormost portion, at the base of the peritoneal broad ligament, the uterine artery runs transversely toward the cervix while the ureters pass immediately inferior to them as they pass on each side of the cervix heading anteriorly toward the bladder. This relationship (“water passing under the bridge”) is an especially important one for surgeons (see clinical correlation [blue] boxes “Iatrogenic Injury of the Ureters during Ligation of Uterine Artery” and “Iatrogenic Injury of the Ureters during Ligation of Ovarian Artery,” in this chapter). The transverse cervical ligament, and the way in which the uterus normally “rests” on top of the bladder, provide the main passive support for the uterus. The perineal muscles provide dynamic support

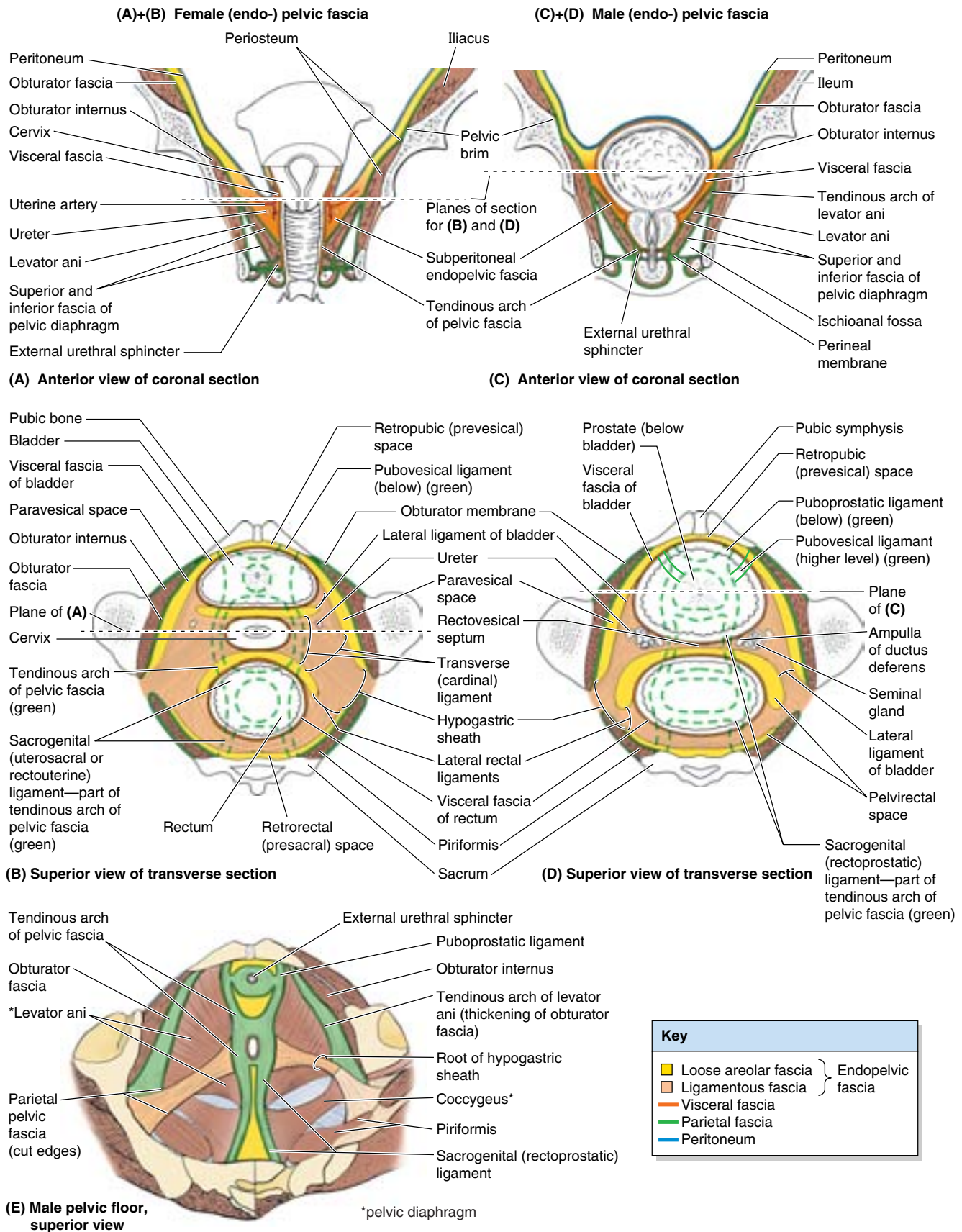


Figure 3.9. Pelvic fascia: endopelvic fascia and fascial ligaments. Sections of female (A and B) and male (C and D) pelvis demonstrating the parietal and visceral fascia and the endopelvic fascia between them, with its ligamentous and loose areolar components. E. The pelvic fascial ligaments adjacent to the male pelvic floor are shown (viscera, visceral fascia, and loose areolar endopelvic fascia removed). The tendinous arch of the levator ani is a thickening of the obturator (parietal) fascia, providing the anterolateral attachment (origin) of the levator ani. The tendinous arch of the pelvic fascia is a thickening at the point of reflection of parietal fascia onto the pelvic viscera, where it becomes visceral fascia.

for the uterus by contracting during moments of increased intra-abdominal pressure (sneezing, coughing, etc.). Passive and dynamic supports together resist the tendency for the uterus to fall or be pushed through the hollow tube formed by the vagina (uterine prolapse). The transverse cervical ligament has enough fibrous content to anchor wide loops of suture during surgical repairs.

In addition to the ischioanal fossae inferior to the pelvic diaphragm (i.e., in the perineum) (Fig. 3.9A & C), there is a surgically important potential **pelvirectal space** in the loose extraperitoneal connective tissue superior to the pelvic diaphragm (Fig. 3.9D). It is divided into anterior and posterior regions by the **lateral rectal ligaments** (rectal stalks), which are the posterior laminae of the hypogastric sheaths. These ligaments connect the rectum to the parietal pelvic fascia at the S2–S4 levels (Fig. 3.9B & D). The middle rectal arteries and rectal nerve plexuses are embedded in the lateral rectal ligaments.

THE BOTTOM LINE: Membranous parietal pelvic fascia, continuous with the fascia lining the abdominal cavity, lines the pelvic walls and reflects onto the pelvic viscera as pelvic visceral fascia. The right and left lines of reflection are thickened into paramedian fascial bands extending from pubis to coccyx, the tendinous arches of the pelvic fascia. The subperitoneal space between the parietal and visceral pelvic fascias is occupied with fatty endopelvic fascia. This endopelvic fascial matrix has loose areolar portions, occupying potential spaces, and condensed fibrous tissue, surrounding neurovascular structures in transit to the viscera while also tethering (supporting) the viscera. The two portions of endopelvic fascia are indistinct in appearance but have distinctly different textures. The primary fascial condensations form the hypogastric sheaths along the posterolateral pelvic walls. As these fascial sheaths extend toward the viscera, three laminae are formed, including the lateral ligament of the bladder anteriorly and the lateral rectal ligaments posteriorly. In females, the middle lamina is the transverse cervical or cardinal ligament that passively supports the vagina and uterine cervix, while conveying their neurovasculature. In males, the middle lamina is the rectovesical septum.

Neurovascular Structures of the Pelvis

The major neurovascular structures of the pelvis lie extraperitoneally against the posterolateral walls. The nerves lie most external or superficial (adjacent to the walls), with the vascular structures internal or deep (medial) to them. Generally, the veins are external (lateral) to the arteries (Fig. 3.11A–C).

Pelvic Nerves

The pelvis is innervated mainly by the **sacral** and **coccygeal spinal nerves** and the *pelvic part of the autonomic nervous*

system. The piriformis and coccygeus muscles form a bed for the sacral and coccygeal nerve plexuses (Fig. 3.10A). The anterior rami of the S2 and S3 nerves emerge between the digitations of these muscles. At or immediately superior to the pelvic brim, the descending part of the L4 nerve unites with the anterior ramus of the L5 nerve to form the thick, cord-like **lumbosacral trunk** (Figs. 3.6D and 3.10A; Table 3.4). The trunk passes inferiorly, on the anterior surface of the ala of the sacrum, and joins the sacral plexus.

Sacral Plexus

The **sacral plexus** is located on the posterolateral wall of the lesser pelvis, where it is closely related to the anterior surface of the piriformis muscle. The two main nerves arising from the sacral plexus, the *sciatic* and *pudendal nerves*, lie external to the parietal pelvic fascia. Most branches of the sacral plexus leave the pelvis through the *greater sciatic foramen*.

The **sciatic nerve** is the largest nerve in the body. It is formed by the anterior rami of spinal nerves L4–S3, which converge on the anterior surface of the piriformis (Fig. 3.10A; Table 3.4). Most commonly, the sciatic nerve passes through the greater sciatic foramen inferior to the piriformis to enter the gluteal region (Fig. 3.10B). It then descends along the posterior aspect of the thigh to supply the posterior aspect of the lower limb (see Chapter 5).

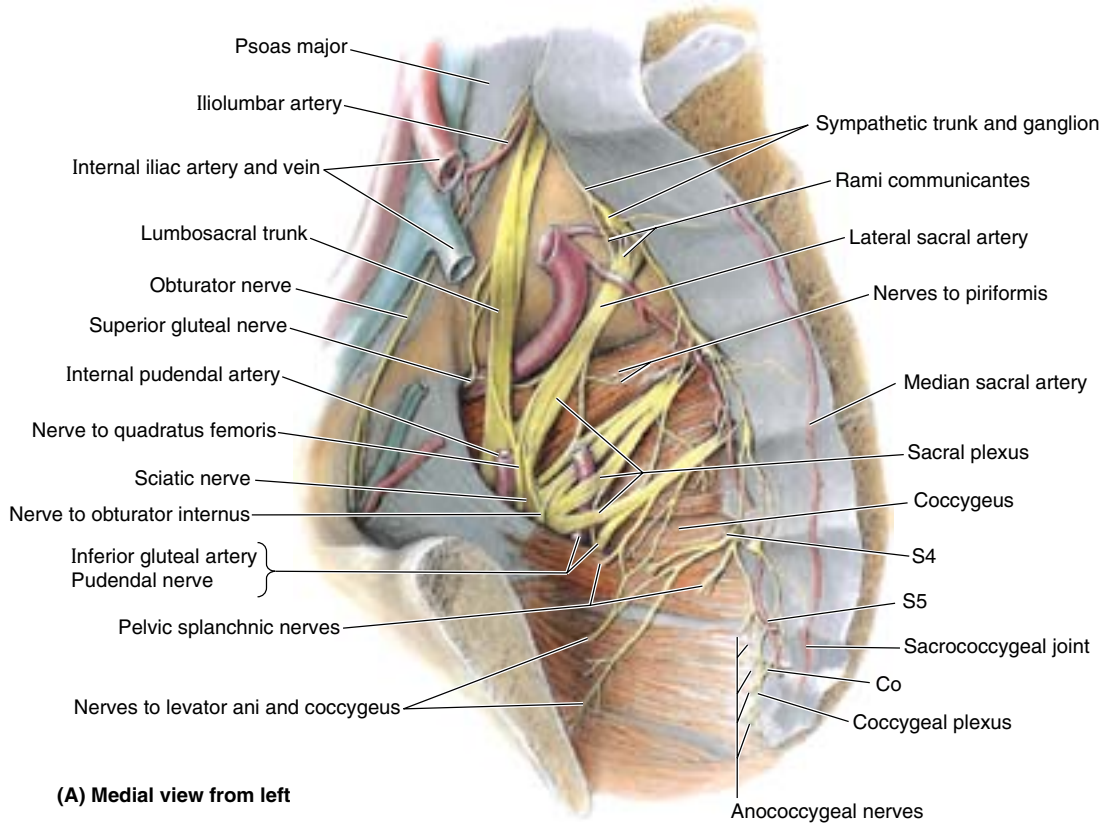
The **pudendal nerve** is the main nerve of the perineum and the chief sensory nerve of the external genitalia. It is derived from the anterior rami of spinal nerves S2–S4 (Table 3.4). Accompanied by the internal pudendal artery, it leaves the pelvis through the greater sciatic foramen between the piriformis and the coccygeus muscles. It then hooks around the ischial spine and sacrospinous ligament and enters the perineum through the lesser sciatic foramen (Fig. 3.10B). It supplies the skin and muscles of the perineum.

The **superior gluteal nerve** arises from the anterior rami of spinal nerves L4–S1 and leaves the pelvis through the greater sciatic foramen, superior to the piriformis (Fig. 3.10A; Table 3.4). It supplies three muscles in the gluteal region: the gluteus medius and minimus and the tensor of the fascia lata (see Chapter 5).

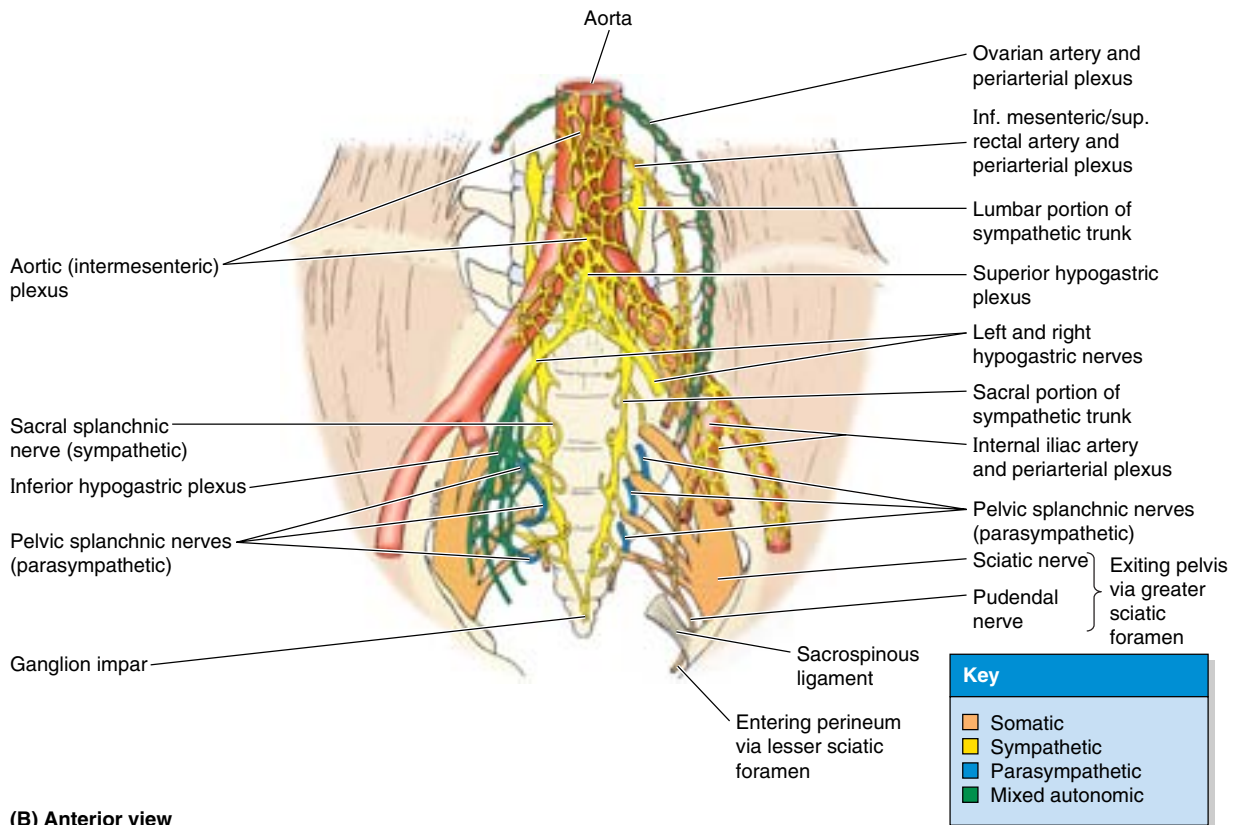
The **inferior gluteal nerve** arises from the anterior rami of spinal nerves L5–S2 and leaves the pelvis through the greater sciatic foramen (Table 3.4), inferior to the piriformis and superficial to the sciatic nerve. It accompanies the inferior gluteal artery and breaks up into several branches, which supply the overlying gluteus maximus muscle (see Chapter 5).

Obturator Nerve

The **obturator nerve** arises from the anterior rami of spinal nerves L2–L4 of the *lumbar plexus* in the abdomen (greater pelvis) and enters the lesser pelvis (Fig. 3.10A). It runs in the extraperitoneal fat along the lateral wall of the pelvis to the *obturator canal*, an opening in the obturator membrane that otherwise fills the obturator foramen. Here it divides into anterior and posterior parts, which leave the pelvis through this canal and supply the medial thigh muscles (see Chapter 5). No pelvic structures are supplied by the obturator nerve.

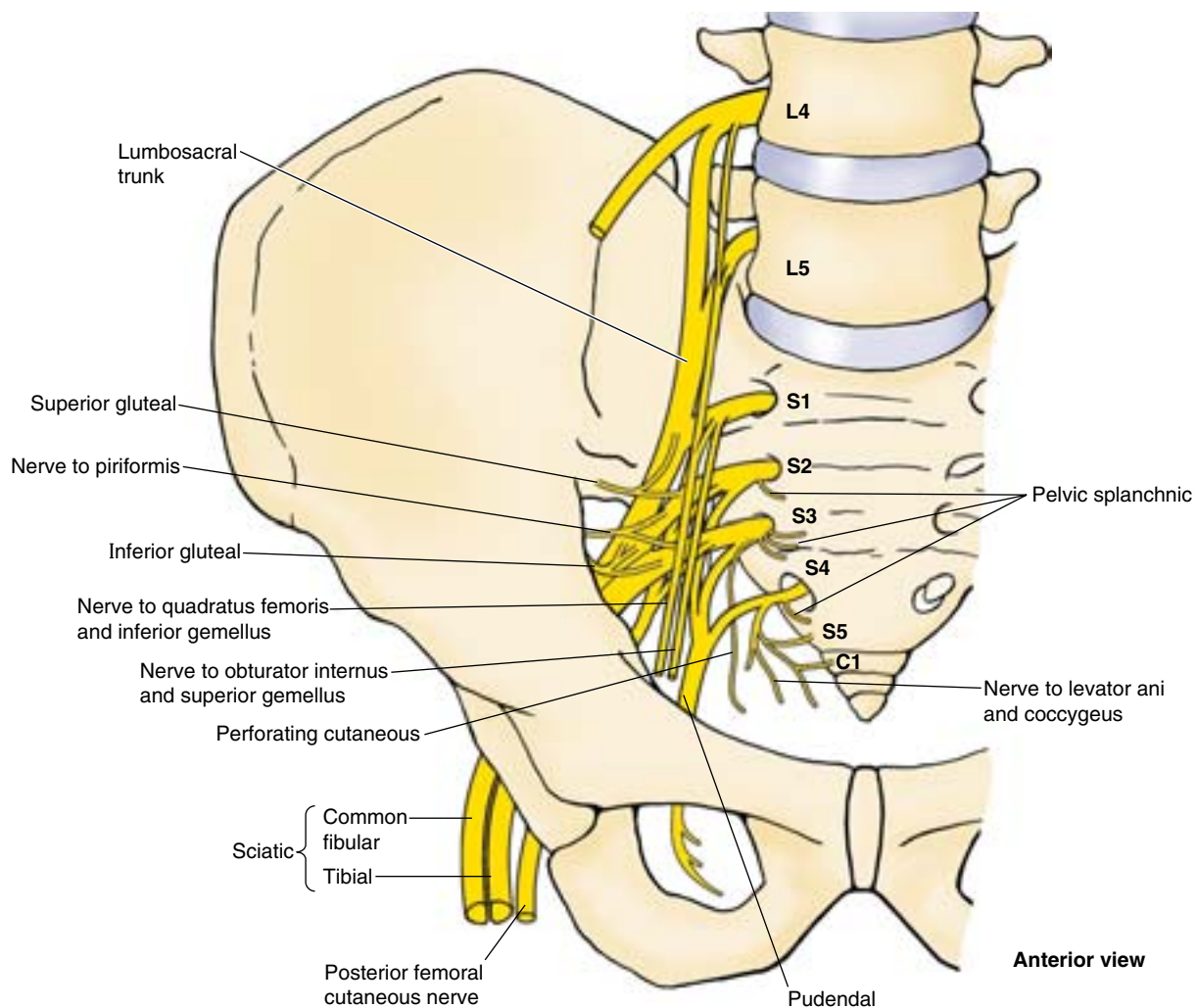


(A) Medial view from left



(B) Anterior view

Figure 3.10. Nerves and nerve plexuses of pelvis. **A.** Somatic nerves (sacral and coccygeal nerve plexuses) and the pelvic (sacral) part of the sympathetic trunk are shown. Although located in the pelvis, most of the nerves seen here are involved with the innervation of the lower limb rather than the pelvic structures. **B.** Autonomic nerves are demonstrated. The superior hypogastric plexus is a continuation of the aortic (intermesenteric) plexus. It divides into left and right hypogastric nerves as it enters the pelvis. The hypogastric and pelvic splanchnic nerves merge to form the inferior hypogastric plexuses, which thus consist of both sympathetic and parasympathetic fibers. Autonomic (sympathetic) fibers also enter the pelvis via the sympathetic trunks and periarterial plexuses.

Table 3.4. Somatic Nerves of the Pelvis

Nerve	Origin	Distribution
Sciatic	L4, L5, S1, S2, S3	Articular branches to hip joint and muscular branches to flexors of knee in thigh and all muscles in leg and foot
Superior gluteal	L4, L5, S1	Gluteus medius and gluteus minimus muscles
Nerve to quadratus femoris and inferior gemellus	L4, L5, S1	Quadratus femoris and inferior gemellus muscles
Inferior gluteal	L5, S1, S2	Gluteus maximus
Nerve to obturator internus and superior gemellus	L5, S1, S2	Obturator internus and superior gemellus muscles
Nerve to piriformis	S1, S2	Piriformis muscle
Posterior femoral cutaneous	S2, S3	Cutaneous branches to buttock and uppermost medial and posterior surfaces of thigh
Perforating cutaneous	S2, S3	Cutaneous branches to medial part of buttock
Pudendal	S2, S3, S4	Structures in perineum: sensory to genitalia; muscular branches to perineal muscles, external urethral sphincter, and external anal sphincter
Pelvic splanchnic	S2, S3, S4	Pelvic viscera via inferior hypogastric and pelvic plexuses
Nerves to levator ani and coccygeus	S3, S4	Levator ani and coccygeus muscles

Injury to the Pelvic Nerves

During childbirth, the fetal head may compress the nerves of the mother's sacral plexus, producing pain in the lower limbs. The *obturator nerve* is vulnerable to injury during surgery (e.g., during removal of cancerous lymph nodes from the lateral pelvic wall). Injury to this nerve may cause painful spasms of the adductor muscles of the thigh and sensory deficits in the medial thigh region (see Chapter 5). ❖

Coccygeal Plexus

The **coccygeal plexus** is a small network of nerve fibers formed by the anterior rami of S4 and S5 and the **coccygeal nerves** (Fig. 3.10A). It lies on the pelvic surface of the coccygeus and supplies this muscle, part of the levator ani, and the sacrococcygeal joint. The **anococcygeal nerves** arising from this plexus pierce the coccygeus and anococcygeal ligament to supply a small area of skin between the tip of the coccyx and the anus.

Pelvic Autonomic Nerves

Autonomic nerves enter the pelvic cavity via four routes (Fig. 3.10B):

- **Sacral sympathetic trunks:** primarily provide sympathetic innervation to the lower limbs.
- **Periarterial plexuses** of superior rectal, ovarian, and internal iliac arteries: postsynaptic, sympathetic, vasomotor fibers to involved artery and its derivative branches.
- **Hypogastric plexuses:** most important route by which sympathetic fibers are conveyed to the pelvic viscera.
- **Pelvic splanchnic nerves:** pathway for parasympathetic innervation of pelvic viscera and descending and sigmoid colon.

The hypogastric plexuses and pelvic splanchnic nerves merge within the pelvis.

The **sacral sympathetic trunks** are the inferior continuation of the lumbar sympathetic trunks (Fig. 3.10A & B). Each of the sacral trunks is diminished in size from that of the lumbar trunks and usually has four sympathetic ganglia. The sacral trunks descend on the pelvic surface of the sacrum just medial to the pelvic sacral foramina and converge to form the small median **ganglion impar** (coccygeal ganglion) anterior to the coccyx. The sacral sympathetic trunks descend posterior to the rectum in the extraperitoneal connective tissue and send communicating branches (gray rami communicantes) to each of the anterior rami of the sacral and coccygeal nerves. They also send small branches to the median sacral artery and the inferior hypogastric plexus. The primary function of the sacral

sympathetic trunks is to provide postsynaptic fibers to the sacral plexus for sympathetic (vasomotor, pilomotor, and sudomotor) innervation of the lower limb.

The **periarterial plexuses** of the ovarian, superior rectal, and internal iliac arteries are minor routes by which sympathetic fibers enter the pelvis. Their primary function is vasomotion of the arteries they accompany.

The **hypogastric plexuses** (superior and inferior) are networks of sympathetic and visceral afferent nerve fibers. The main part of the **superior hypogastric plexus** is a prolongation of the **intermesenteric plexus** (see Chapter 2), which lies inferior to the bifurcation of the aorta (Fig. 3.10B). It carries fibers conveyed to and from the intermesenteric plexus by the L3 and L4 splanchnic nerves. The superior hypogastric plexus enters the pelvis, dividing into right and left **hypogastric nerves**, which descend on the anterior surface of the sacrum. These nerves descend lateral to the rectum within the **hypogastric sheaths** and then spread in a fan-like fashion as they merge with the pelvic splanchnic nerves to form the right and left **inferior hypogastric plexuses**.

The **inferior hypogastric plexuses** thus contain both sympathetic and the parasympathetic fibers as well as visceral afferent fibers, which continue through the lamina of the hypogastric sheath to the pelvic viscera, upon which they form sub-plexuses collectively referred to as the **pelvic plexuses**. In both sexes, sub-plexuses are associated with the lateral aspects of the rectum and inferolateral surfaces of the bladder. In addition, in the male, sub-plexuses are also associated with the prostate and seminal glands; in females, sub-plexuses are also associated with the cervix of the uterus and the lateral fornices of the vagina.

Pelvic splanchnic nerves arise in the pelvis from the anterior rami of spinal nerves S2–S4 of the sacral plexus (Fig. 3.10; Table 3.4). They convey presynaptic parasympathetic fibers derived from the S2–S4 spinal cord segments, which make up the sacral outflow of the parasympathetic (craniosacral) nervous system, and visceral afferent fibers from cell bodies in the spinal ganglia of the corresponding spinal nerves. The greatest contribution of these fibers is usually from the S3 nerve.

The hypogastric/pelvic system of plexuses, receiving sympathetic fibers via lumbar splanchnic nerves and parasympathetic fibers via pelvic splanchnic nerves, innervate the pelvic viscera. Although the sympathetic component largely produces vasomotion as elsewhere, here it also inhibits peristaltic contraction of the rectum and stimulates contraction of the internal genital organs during orgasm, producing ejaculation in the male. Because the pelvis does not include a cutaneous area, pelvic sympathetic fibers do not produce pilomotion or vasomotion functions. The parasympathetic fibers distributed within the pelvis stimulate contraction of the rectum and bladder for defecation and urination, respectively. Parasympathetic fibers in the prostatic plexus penetrate the pelvic floor to reach the erectile bodies of the external genitalia, producing erection.

Visceral Afferent Innervation in the Pelvis

Visceral afferent fibers travel with autonomic nerve fibers, although the sensory impulses are conducted centrally, retrograde to the efferent impulses conveyed by the autonomic fibers. All visceral afferent fibers conducting reflexive sensation (information that does not reach consciousness) travel with parasympathetic fibers. Thus, in the case of the pelvis, they travel through the pelvic and inferior hypogastric plexuses and the pelvic splanchnic nerves to the spinal sensory ganglia of spinal nerves S2–S4.

The paths followed by visceral afferent fibers conducting pain from the pelvic viscera differ in terms of course and destination, depending on whether the viscus or part of the viscus from which the pain is emanating is located superior or inferior to the **pelvic pain line**. Except in the case of the alimentary canal, the pelvic pain line corresponds to the inferior limit of the peritoneum (Table 3.3A–C). Intraperitoneal abdominopelvic viscera, or aspects of visceral structures that are in contact with the peritoneum, are superior to the pain line; subperitoneal pelvic viscera or portions of viscera are inferior to the pain line. In the case of the alimentary tract (large intestine), the pain line does not correlate with the peritoneum; the pain line occurs in the middle of the sigmoid colon.

Visceral afferent fibers conducting pain impulses from abdominopelvic viscera superior to the pain line follow sympathetic fibers retrograde, ascending through hypogastric/aortic plexuses, abdominopelvic splanchnic nerves, lumbar sympathetic trunks, and white rami communicantes to reach cell bodies in the inferior thoracic/upper lumbar spinal ganglia. Afferent fibers conducting pain impulses from the viscera or portions of viscera inferior to the pain line follow the parasympathetic fibers retrograde through the pelvic and inferior hypogastric plexuses and pelvic splanchnic nerves to reach cell bodies in the spinal sensory ganglia of S2–S4.

THE BOTTOM LINE: Progressing from the pelvic cavity outward, as when dissecting the pelvis, the retroperitoneal hypogastric/pelvic autonomic nerve plexuses are encountered first (nearest the viscera), then pelvic arteries, pelvic veins, and finally the pelvic somatic nerves and sympathetic trunks, the latter two being adjacent to the pelvic walls. Somatic nerves within the pelvis form the sacral plexus, primarily concerned with innervation of the lower limbs and perineum. The pelvic portions of the sympathetic trunks are also primarily concerned with innervation of the lower limbs. Autonomic nerves are primarily brought to the pelvis via the superior hypogastric plexus (sympathetic fibers) and pelvic splanchnic nerves (parasympathetic fibers), the two merging to form the inferior hypogastric and pelvic plexuses. Sympathetic fibers to the pelvis produce vasomotion and contraction of internal genital organs during orgasm; they also inhibit rectal peristalsis. Pelvic parasympathetic fibers stimulate bladder and rectal emptying and extend to the erectile bodies of the external genitalia to

produce erection. Visceral afferent fibers travel retrogradely along the autonomic nerve fibers. Visceral afferents conveying unconscious reflex sensation follow the course of the parasympathetic fibers to the spinal sensory ganglia of S2–S4, as do those transmitting pain sensations from the viscera inferior to the pelvic pain line (structures that do not contact the peritoneum plus the distal sigmoid colon and rectum). Visceral afferent fibers conducting pain from structures superior to the pelvic pain line (structures in contact with the peritoneum, except for the distal sigmoid colon and rectum) follow the sympathetic fibers retrogradely to inferior thoracic and superior lumbar spinal ganglia.

Pelvic Arteries

The pelvis is richly supplied with arteries, among which multiple anastomoses occur, providing an extensive collateral circulation. Details concerning the origin, course, distribution, and anastomoses of the arteries of both the greater and lesser pelvises are summarized in Table 3.5 and Figure 3.11. Six main arteries enter the lesser pelvis of females, whereas four main arteries enter the lesser pelvis of males: the internal iliac and ovarian arteries (females only) are paired, and the median sacral and superior rectal arteries are unpaired.

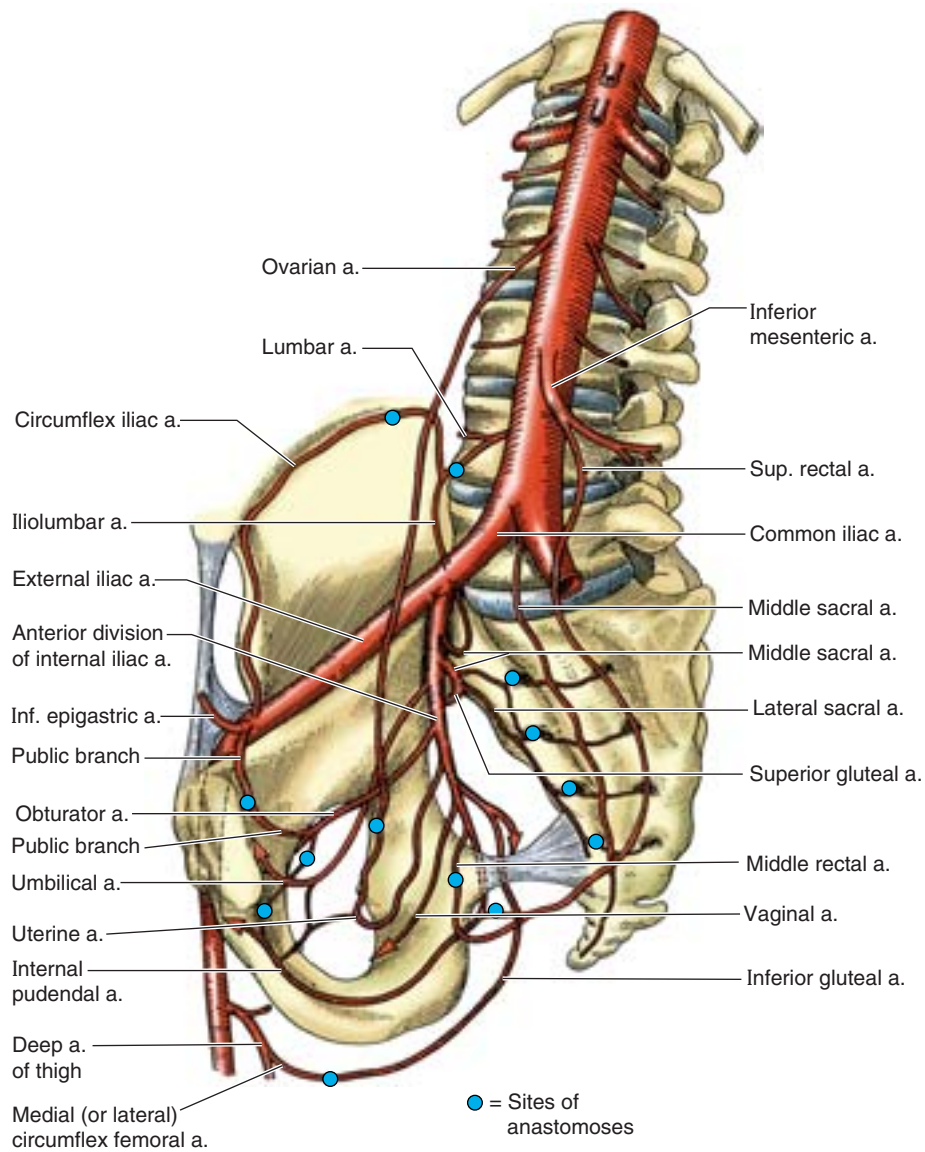
Internal Iliac Artery

Each **internal iliac artery**, approximately 4 cm long, begins as the **common iliac artery** and bifurcates into the internal and external iliac arteries at the level of the IV disc between the L5 and the S1 vertebrae. The ureter crosses the common iliac artery or its terminal branches at or immediately distal to the bifurcation (Fig. 3.11C; Table 3.5). The internal iliac artery is separated from the sacroiliac joint by the internal iliac vein and the lumbosacral trunk. It descends posteromedially into the lesser pelvis, medial to the external iliac vein and obturator nerve and lateral to the peritoneum. The internal iliac artery is the principal artery of the pelvis, supplying most of the blood to the pelvic viscera and some to the musculoskeletal part of the pelvis (Fig. 3.11; Table 3.5); however, it also supplies branches to the gluteal region, medial thigh regions, and the perineum.

Although variations are common, the internal iliac artery usually ends at the superior edge of the greater sciatic foramen by dividing into anterior and posterior divisions (trunks). The branches of the **anterior division of the internal iliac artery** are mainly visceral (i.e., they supply the bladder, rectum, and reproductive organs), but they also include parietal branches that pass to the buttock and thigh. The arrangement of the visceral branches is variable. The following arteries discussed next commonly arise as branches of the anterior division of the internal iliac artery.

Umbilical Artery. Before birth, the umbilical arteries are the main continuation of the internal iliac arteries, passing along the lateral pelvic wall and then ascending the anterior abdominal wall to and through the umbilical ring into the umbilical cord.

(cont'd on p. 387)

Table 3.5. Arteries of the Pelvis

Artery	Origin	Course	Distribution	Anastomoses
Gonadal:	Abdominal aorta	Descends retroperitoneally;		
testicular (♂)		traverses inguinal canal and enters scrotum;	Abdominal ureter, testis, and epididymis	Cremasteric, artery of ductus deferens
ovarian (♀)		crosses pelvic brim, descends in suspensory ligament of ovary	Abdominal and/or pelvic ureter, ovary, and ampullary end of uterine tube	Uterine artery via tubal and ovarian branches
Superior rectal	Continuation of inferior mesenteric artery	Crosses left common iliac vessels and descends into pelvis between layers of sigmoid mesocolon	Superior part of rectum	Middle rectal artery; inferior rectal (internal pudendal) artery
Median sacral	Posterior aspect of abdominal aorta	Descends close to midline over (L4,) L5 vertebrae and sacrum and coccyx	Inferior lumbar vertebrae, sacrum, and coccyx	Lateral sacral artery (via medial sacral branches)
Internal iliac	Common iliac artery	Passes over pelvic brim to reach pelvic cavity	Main blood supply to pelvic organs, gluteal muscles, and perineum	

Table 3.5. Arteries of the Pelvis (Continued)

Artery	Origin	Course	Distribution	Anatomoses
Anterior division of internal iliac	Internal iliac artery	Passes anteriorly along lateral wall of pelvis, dividing into visceral, obturator, and internal pudendal arteries	Pelvic viscera, muscles of superior medial thigh, and perineum	
Umbilical	Anterior division of internal iliac artery	Runs a short pelvic course, gives off superior vesical arteries, then obliterates, becoming medial umbilical ligament	Superior aspect of urinary bladder and, in some males, ductus deferens (via superior vesical arteries and artery to ductus deferens)	(Occasionally the patent part of the umbilical artery)
Superior vesical	(Patent proximal umbilical artery)	Usually multiple; pass to superior aspect of urinary bladder	Superior aspect of urinary bladder; in some males, ductus deferens (via artery to ductus deferens)	Inferior vesical (δ); vaginal artery (\varnothing)
Obturator		Runs anteroinferiorly on obturator fascia of lateral pelvic wall, exiting pelvis via obturator canal	Pelvic muscles, nutrient artery to ilium, head of femur, and muscles of medial compartment of the thigh	Inferior epigastric (via pubic branch); umbilical artery
Inferior vesical (δ)	(Superior or inferior vesical artery)	Passes subperitoneally in lateral ligament of bladder, giving rise to prostatic artery (δ) and occasionally the artery to the ductus deferens	Inferior aspect of male urinary bladder, prostate, and seminal glands; occasional ductus deferens	Superior vesical artery
Artery to ductus deferens (δ)	(Inferior vesical artery)	Runs subperitoneally to ductus deferens	Ductus deferens	Testicular artery; cremasteric artery
Prostatic branches (δ)		Descends on posterolateral aspects of prostate	Prostate and prostatic urethra	Deep perineal (internal pudendal)
Uterine (\varnothing)		Runs anteromedially in base of broad ligament/superior cardinal ligament, gives rise to vaginal branch, then crosses ureter superiorly to reach lateral aspect of uterine cervix.	Uterus, ligaments of uterus, medial parts of uterine tube and ovary, and superior vagina	Ovarian artery (via tubal and ovarian branches); vaginal artery
Vaginal (\varnothing)		Divides into vaginal and inferior vesical branches, the former descending on the vagina, the latter passing to the urinary bladder.	Vaginal branch: lower vagina, vestibular bulb, and adjacent rectum; inferior vesical branch: fundus of urinary bladder	Vaginal branch of uterine artery, superior vesical artery
Internal pudendal		Exits pelvis via infrapiriform part of greater sciatic foramen, enters perineum (ischioanal fossa) via lesser sciatic foramen, passes via pudendal canal to UG triangle	Main artery of perineum, including muscles and skin of anal and urogenital triangles; erectile bodies	(Umbilical artery; prostatic branches of inferior vesical artery in males)
Middle rectal		Descends in pelvis to inferior part of rectum	Seminal glands and inferior part of rectum	Superior and inferior rectal arteries
Inferior gluteal		Exits pelvis via infrapiriform part of greater sciatic foramen	Pelvic diaphragm (coccygeus and levator ani) piriformis, quadratus femoris, superiormost hamstrings, gluteus maximus, and sciatic nerve.	Deep femoral artery (via medial and lateral femoral circumflex arteries)
Posterior division of internal iliac	Internal iliac artery	Passes posteriorly and gives rise to parietal branches	Pelvic wall and gluteal region	
Illiolumbar		Ascends anterior to sacroiliac joint and posterior to common iliac vessels and psoas major, dividing into iliac and lumbar branches	Psoas major, iliacus, and quadratus lumborum muscles; cauda equina in vertebral canal	Circumflex iliac artery and 4th (and lowest) lumbar artery
Lateral sacral (superior and inferior)	Posterior division of internal iliac artery	Runs on anteromedial aspect of piriformis to send branches into pelvic sacral foramina	Piriformis, structures in sacral canal, erector spinae, and overlying skin	Medial sacral arteries (from median sacral artery)
Superior gluteal		Exits pelvis via suprapiriform portion of greater sciatic foramen	Piriformis, all three gluteal muscles, and tensor of fascia lata	Lateral sacral, inferior gluteal, internal pudendal, deep circumflex femoral, lateral circumflex femoral

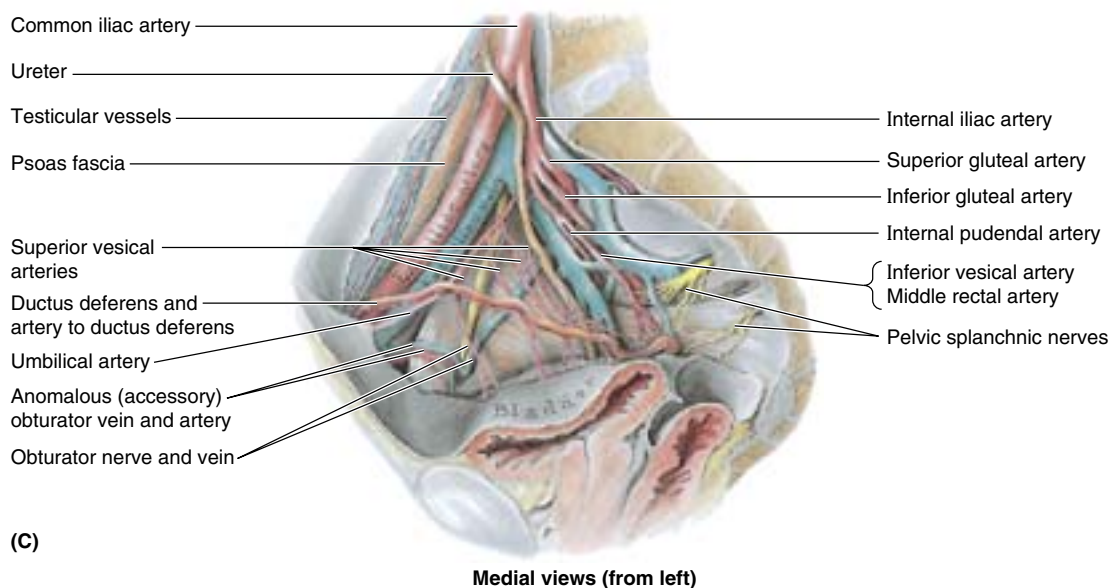
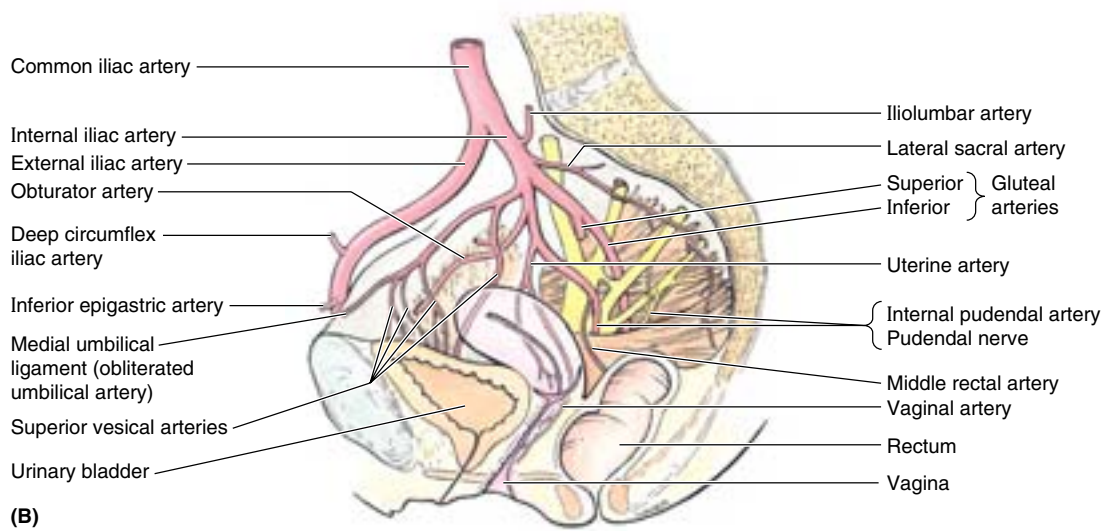
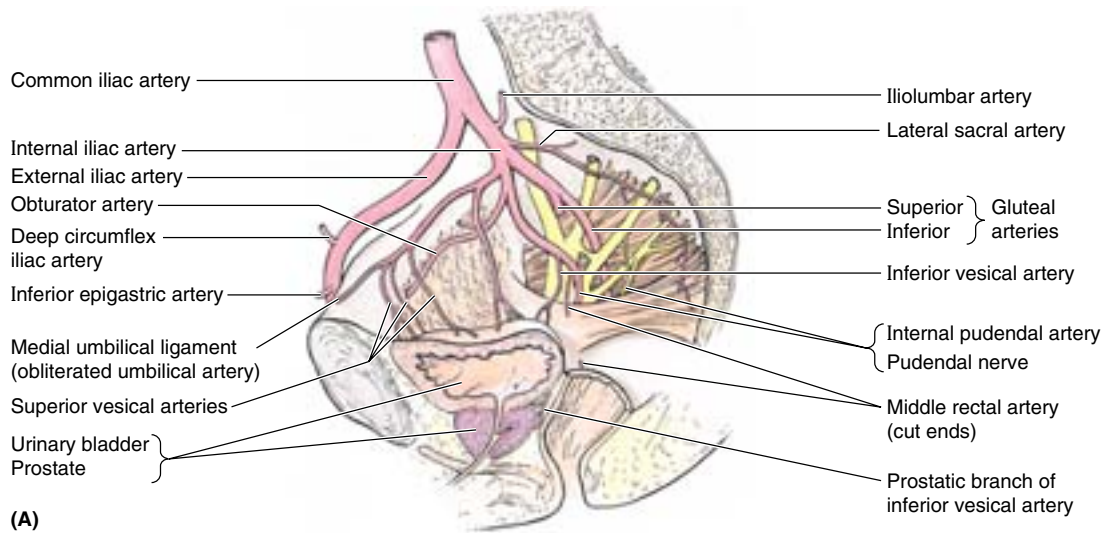


Figure 3.11. Arteries and neurovascular relationships of pelvis. The arteries of the male pelvis (A) and female pelvis (B) are shown. Anterior divisions of the internal iliac arteries usually supply most of the blood to pelvic structures. The arteries are internal (lie medial) to the nerves making up the sacral plexus. C. The neurovascular structures of the male pelvis are shown. Generally, the pelvic veins lie between the pelvic arteries (which lie medially or internally) and the somatic nerves (which lie laterally or externally).

At this stage of life, the **umbilical arteries** conduct oxygen- and nutrient-deficient blood to the placenta for replenishment. When the umbilical cord is cut, the distal parts of these vessels no longer function and become occluded distal to branches that pass to the bladder. The *occluded parts* form fibrous cords called the **medial umbilical ligaments** or cords of the umbilical arteries (Figs. 3.11A & B and 3.14B; Table 3.5). The ligaments raise folds of peritoneum (the *medial umbilical folds*) on the deep surface of the anterior abdominal wall (see Chapter 2). Postnatally, the *patent part of the umbilical artery* runs anteroinferiorly between the urinary bladder and the lateral wall of the pelvis, giving off the **superior vesical artery** (or arteries) that supplies (or arise as) numerous branches to the fundus of the urinary bladder (Fig. 3.11; Table 3.5). In males, the **artery to the ductus deferens** usually arises as a branch of the superior vesical artery.

Obturator Artery. The origin of the **obturator artery** is variable; usually it arises close to the origin of the umbilical artery, where it is crossed by the ureter. It runs anteroinferiorly on the obturator fascia on the lateral wall of the pelvis and passes between the obturator nerve and vein. It then leaves the pelvis through the *obturator canal* and supplies the muscles of the medial thigh. Within the pelvis, the obturator artery gives off muscular branches, a nutrient artery to the ilium, and a pubic branch. The **pubic branch** arises just before the obturator artery leaves the pelvis. It ascends on the pelvic surface of the pubis to anastomose with its fellow of the opposite side and the pubic branch of the *inferior epigastric artery*, a branch of the external iliac artery. In a common variation (20%), an **aberrant** or **accessory obturator artery** arises from the inferior epigastric artery and descends into the pelvis along the usual route of the pubic branch (Fig. 3.11C; Table 3.5). Surgeons performing hernia repairs must keep this common variation in mind. The extrapelvic distribution of the obturator artery is described with the lower limb (see Chapter 5).

Inferior Vesical Artery. The **inferior vesical artery** occurs only in males, being replaced by the vaginal artery in females (Fig. 3.11A; Table 3.5). It passes to the fundus of the urinary bladder, where it supplies the seminal glands, prostate, fundus of the bladder, and inferior part of the ureter. The branches to the ductus deferens and prostate are the *artery to the ductus deferens* and the *prostatic artery*. The artery to the ductus deferens may arise from the superior vesical artery.

Middle Rectal Artery. The **middle rectal artery** may arise independently from the internal iliac artery, or it may arise in common with the inferior vesical artery or the internal pudendal artery (Fig. 3.11; Table 3.5). The middle rectal artery supplies the inferior part of the rectum, anastomosing with the superior and inferior rectal arteries, supplying the seminal glands and prostate (or the vagina).

Vaginal Artery. The **vaginal artery** is the homolog to the inferior vesical artery in males. It runs anteriorly and then passes along the side of the vagina, where it supplies numerous branches to the anterior and posterior surfaces of the

vagina, posteroinferior parts of the urinary bladder, and the pelvic part of the urethra (Figs 3.11B and 3.12; Table 3.5). It anastomoses with the vaginal branch of the uterine artery.

Uterine Artery. The **uterine artery** usually arises separately and directly from the internal iliac artery, but it may arise from the umbilical artery. It is the homolog to the artery to the ductus deferens in the male. It descends on the lateral wall of the pelvis, anterior to the internal iliac artery, and enters the root of the broad ligament. Here it passes medially to reach the lateral margin of the uterus immediately superior to the lateral part of the fornix of the vagina (Fig. 3.12). As it passes medially in the broad ligament, the uterine artery passes directly superior to the ureter near the lateral part of the fornix of the vagina. The relationship of ureter to artery is often remembered by the phrase *Water (urine) passes under the bridge* (uterine artery). On reaching the side of the cervix, the uterine artery divides into a smaller descending **vaginal branch**, which supplies the cervix and vagina, and a larger **ascending branch**, which runs along the lateral margin of the uterus, supplying the body and fundus of the uterus. The ascending branch bifurcates into **ovarian** and **tubal branches**, which continue within the broad ligament to supply the medial ends of the ovary and uterine tube and anastomose with the ovarian and tubal branches of the ovarian artery.

Iatrogenic Injury of the Ureters during Ligation of Uterine Artery

The fact that the ureter passes immediately inferior to the uterine artery near the lateral part of the fornix of the vagina is clinically important. The ureter is in danger of being inadvertently clamped (crushed), ligated, or transected during a **hysterectomy** (excision of uterus) when the uterine artery is ligated and severed to remove the uterus. The point at which the uterine artery and ureter cross lies approximately 2 cm superior to the ischial spine. ☺

Internal Pudendal Artery. The **internal pudendal artery**, larger in males than in females, passes inferolaterally, anterior to the piriformis muscle and sacral plexus (Fig. 3.11; Table 3.5). It leaves the pelvis between the piriformis and the coccygeus muscles by passing through the inferior part of the *greater sciatic foramen*. The internal pudendal artery then passes around the posterior aspect of the ischial spine or the sacrospinous ligament and enters the *ischioanal fossa* through the *lesser sciatic foramen*. The internal pudendal artery, along with the internal pudendal veins and branches of the pudendal nerve, passes through the pudendal canal in the lateral wall of the ischioanal fossa (Fig. 3.7B). As it exits the pudendal canal, medial to the ischial tuberosity, the internal pudendal artery divides into its terminal branches, the *deep and dorsal arteries of the penis or clitoris*.

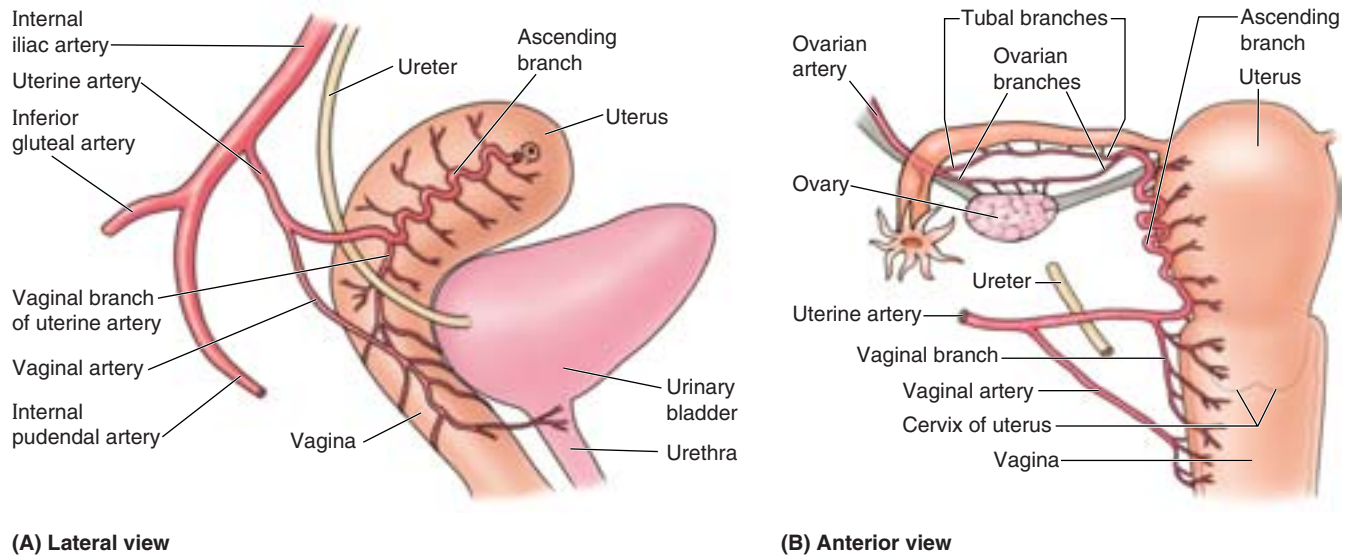


Figure 3.12. Uterine and vaginal arteries. **A.** The origin of the arteries from the anterior division of the internal iliac artery and distribution to the uterus and vagina are shown. **B.** The anastomoses between the ovarian and tubal branches of the ovarian and uterine arteries and between the vaginal branch of the uterine artery and the vaginal artery provide potential pathways of collateral circulation. These communications occur, and the ascending branch courses, between the layers of the broad ligament.

Inferior Gluteal Artery. The inferior gluteal artery passes posteriorly between the sacral nerves (usually S2 and S3) and leaves the pelvis through the inferior part of the *greater sciatic foramen*, inferior to the piriformis muscle (Fig. 3.11; Table 3.5). It supplies the muscles and skin of the buttock and the posterior surface of the thigh.

Posterior Division of the Internal Iliac Artery. The following three arteries are branches of the posterior division of the internal iliac artery:

- **Superior gluteal artery:** This artery passes posteriorly and runs between the lumbosacral trunk and the anterior ramus of the S1 nerve. It leaves the pelvis through the superior part of the *greater sciatic foramen*, superior to the piriformis muscle, to supply the gluteal muscles in the buttocks.
- **Iliolumbar artery:** This artery runs superolaterally in a *recurrent fashion* (turning sharply backward relative to its source) to the iliac fossa. Within the fossa, the artery divides into an *iliac branch*, which supplies the iliacus muscle and ilium, and a *lumbar branch*, which supplies the psoas major and quadratus lumborum muscles.
- **Lateral sacral arteries:** These arteries, usually made up of superior and inferior arteries on each side, may arise from a common trunk. The lateral sacral arteries pass medially and descend anterior to the sacral anterior rami, giving off spinal branches, which pass through the anterior sacral foramina and supply the spinal meninges enclosing the roots of the sacral nerves. Some branches of these arteries pass from the sacral canal through the posterior sacral foramina and supply the erector spinae muscles of the back and skin overlying the sacrum.

Ligation of the Internal Iliac Artery and Collateral Circulation in the Pelvis

Occasionally the internal iliac artery is ligated to control pelvic hemorrhage. Because of the numerous anastomoses between the artery's branches and adjacent arteries (Table 3.5), ligation does not stop blood flow but it does reduce blood pressure, allowing *hemostasis* (arrest of bleeding) to occur. Examples of collateral pathways to the internal iliac artery include the following pairs of anastomosing arteries: lumbar and iliolumbar, median sacral and lateral sacral, superior rectal and middle rectal, and inferior gluteal and deep artery of the thigh. Blood flow in the artery is maintained, although it may be reversed in the anastomotic branch. The collateral pathways may maintain the blood supply to the pelvic viscera, gluteal region, and genital organs. 🚫

Ovarian Artery

The **ovarian artery** arises from the abdominal aorta inferior to the renal artery but considerably superior to the inferior mesenteric artery (Table 3.5). As it passes inferiorly, the ovarian artery adheres to the parietal peritoneum and runs anterior to the ureter on the posterior abdominal wall, usually giving branches to it (Fig. 3.12). As it enters the lesser pelvis, it crosses the origin of the external iliac vessels. It then runs medially in the suspensory ligament of the ovary and enters

the superolateral part of the broad ligament, dividing into an **ovarian branch** and a **tubal branch**, which supply the ovary and uterine tube, respectively (Fig. 3.12B). These branches anastomose with the corresponding branches of the uterine artery.

Iatrogenic Injury of the Ureters during Ligation of Ovarian Artery

The ureters are vulnerable to injury when the ovarian vessels are ligated during an **ovariectomy** (excision of ovary) because these structures are close to each other as they cross the pelvic brim. ❖

Median Sacral Artery

The **median sacral artery** is a small unpaired artery that usually arises from the posterior surface of the abdominal aorta, just superior to its bifurcation, but it may arise from its anterior surface (Table 3.5). This vessel runs anterior to the bodies of the last one or two lumbar vertebrae, the sacrum, and the coccyx and ends in a series of anastomotic loops. Before the median sacral artery enters the lesser pelvis, it sometimes gives rise to a pair of *L5 arteries*. As it descends over the sacrum, the median sacral artery gives off small parietal (lateral sacral) branches that anastomose with the lateral sacral arteries. It also gives rise to small visceral branches to the posterior part of the rectum, which anastomose with the superior and middle rectal arteries. The median sacral artery represents the caudal end of the embryonic dorsal aorta, which reduced in size as the tail-like caudal eminence of the embryo disappeared.

Superior Rectal Artery

The **superior rectal artery** is the direct continuation of the inferior mesenteric artery (Table 3.5). It crosses the left common iliac vessels and descends in the sigmoid mesocolon to the lesser pelvis. At the level of the S3 vertebra, the superior rectal artery divides into two branches, which descend on each side of the rectum and supply it as far inferiorly as the internal anal sphincter. The superior rectal artery anastomoses with branches of the middle rectal artery (a branch of the internal iliac artery) and with the inferior rectal artery (a branch of the internal pudendal artery).

Pelvic Veins

Pelvic venous plexuses are formed by the interjoining veins surrounding the pelvic viscera (Fig. 3.13B & C). These intercommunicating networks of veins are clinically important. The various plexuses within the lesser pelvis (rectal, vesical, prostatic, uterine, and vaginal) unite and are drained mainly by the **internal iliac veins**, but some of them drain through the superior rectal vein into the inferior mesenteric vein or through lateral sacral veins into the *internal vertebral venous*

plexus (see Chapter 4). Additional paths of venous drainage from the lesser pelvis include the parietal **median sacral vein**, the **superior rectal vein** (to the portal system) (Fig. 3.13A) and, in females, the ovarian veins.

The internal iliac veins merge with the external iliac veins to form the **common iliac veins**, which unite at the level of vertebra L4 or L5 to form the **inferior vena cava** (Fig. 3.13A). The internal iliac veins lie posteroinferior to the internal iliac arteries; their tributaries are similar to the branches of the arteries, except that there are no veins accompanying the umbilical arteries between the pelvis and the umbilicus.

The **iliolumbar veins** from the iliac fossae of the greater pelvis usually drain into the common iliac veins. The **superior gluteal veins**, the accompanying veins (*L. venae comitantes*) of the superior gluteal arteries of the gluteal region, are the largest tributaries of the internal iliac veins except during pregnancy, when the uterine veins become larger. Testicular veins traverse the greater pelvis as they pass from the deep inguinal ring toward their posterior abdominal terminations, but do not usually drain pelvic structures.

THE BOTTOM LINE: Multiple anastomosing arteries provide a collateral circulatory system that helps ensure an adequate blood supply to the greater and lesser pelvis. Most arterial blood is delivered to the lesser pelvis by the internal iliac arteries, which commonly bifurcate into an anterior division (providing all the visceral branches) and a posterior division (usually exclusively parietal). Postnatally, the umbilical arteries become occluded distal to the origin of the superior vesical arteries and, in the male, the artery to the ductus deferens. The inferior vesical (males) and vaginal arteries (females) supply the inferior bladder and pelvic urethra. The inferior vesical artery also supplies the prostate; the vaginal artery supplies the superior vagina. The uterine artery is exclusively female, but both sexes have middle rectal arteries.

Parietal branches of the anterior trunk in both sexes include the obturator, inferior gluteal, and internal pudendal arteries, the main branches of which arise outside of the lesser pelvis. A clinically significant aberrant obturator artery arises from the inferior epigastric vessels in approximately 20% of the population. The iliolumbar, superior gluteal, and lateral sacral arteries are parietal branches of the posterior division of the internal iliac artery, distributed outside of the lesser pelvis. The iliolumbar is a major supply to structures of the iliac fossae (greater pelvis). The gonadal arteries of both sexes descend into the greater pelvis from the abdominal aorta, but only the ovarian arteries enter the lesser pelvis.

The venous plexuses associated with and named for the various pelvic viscera intercommunicate with each other and the internal vertebral (epidural) venous plexuses of the vertebral canal. However, most venous blood exits the pelvis via the internal iliac veins.

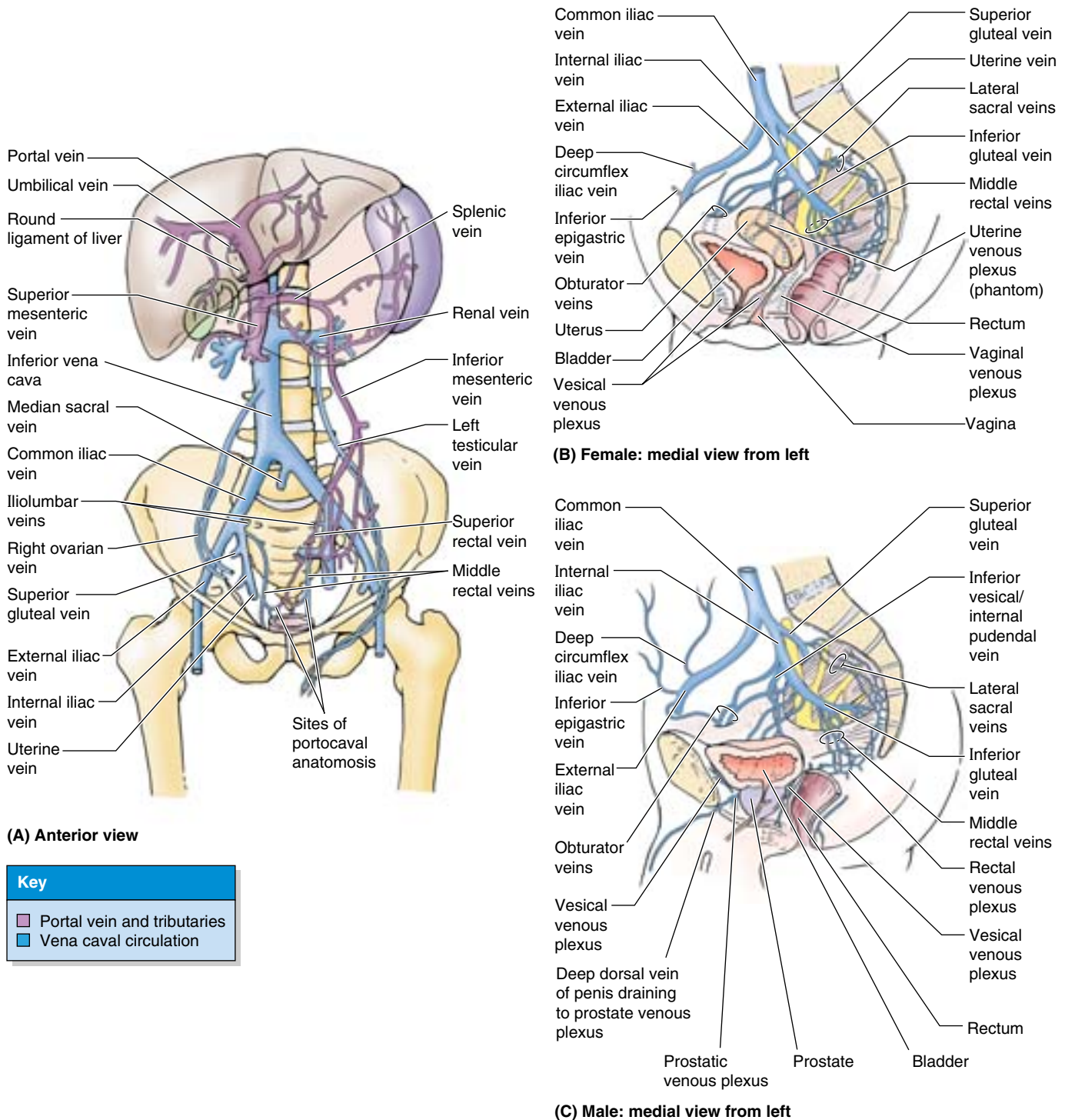


Figure 3.13. Pelvic veins. A. The female (*right*) and male (*left*) patterns of portal and systemic (vena caval) venous systems of the abdominopelvic cavity are shown. Venous drainage from pelvic organs flows mainly to the caval system via the internal iliac veins. The upper rectum normally drains into the portal system, although the superior rectal veins anastomose with the middle and inferior rectal veins, which are tributaries of the internal iliac veins. The female (B) and male (C) pelvic veins and venous plexuses are demonstrated.

Lymph Nodes of the Pelvis

The lymph nodes receiving lymph drainage from pelvic organs are variable in number, size, and location and division into definite groups is often somewhat arbitrary. Four primary groups of nodes are located in or adjacent to the pelvis, named for the blood vessels with which they are associated (Table 3.6):

- **External iliac lymph nodes:** lie above the pelvic brim, along the external iliac vessels. They receive lymph mainly from the inguinal lymph nodes; however, they receive lymph from pelvic viscera, especially the superior parts of the middle to anterior pelvic organs. Whereas most of the lymphatic drainage from the pelvis tends to parallel routes of venous drainage, the lymphatic drainage to the external iliac nodes does not. These nodes drain into the common iliac nodes.
- **Internal iliac lymph nodes:** clustered around the anterior and posterior divisions of the internal iliac artery and the origins of the gluteal arteries. They receive drainage from the inferior pelvic viscera, deep perineum, and gluteal region and drain into the common iliac nodes.
- **Sacral lymph nodes:** lie in the concavity of the sacrum, adjacent to the median sacral vessels. They receive lymph from posteroinferior pelvic viscera and drain either to internal or common iliac nodes.
- **Common iliac lymph nodes:** lie superior to the pelvis and receive drainage from the three main groups listed above, beginning a common route for drainage from the pelvis that passes next to the lumbar (caval/aortic) nodes. Inconstant direct drainage to the common iliac nodes occurs from some pelvic organs (e.g., from the neck of the bladder and inferior vagina).

Additional minor groups of nodes (e.g., the **pararectal nodes**) occupy the connective tissue along the branches of the internal iliac vessels. In females, lymphatic drainage from the ovaries and uterine tubes follows the ovarian veins to the lumbar (caval/aortic) nodes; in males the testis and epididymis also drain to the lumbar nodes, but these structures lie outside the pelvis. Both primary and minor groups of pelvic nodes are highly interconnected, so that many nodes can be removed without disturbing drainage. The interconnections also allow cancer to spread in virtually any direction, to any pelvic or abdominal viscus. While the lymphatic drainage tends to parallel the venous drainage (except for that to the external iliac nodes, where proximity provides a rough guide), the pattern is not sufficiently predictable to allow the progress of metastatic cancer from pelvic organs to be anticipated or staged in a manner comparable to that of breast cancer progressing through the axillary nodes.

THE BOTTOM LINE: Lymphatic drainage from the pelvis follows a pattern that generally, but not reliably, follows the pattern of venous drainage through variable minor and major sets of lymph nodes, the latter including the sacral,

internal, external, and common iliac nodes. Aspects of the anterior to middle pelvic organs, approximately at the level of (and including) the roof of the undistended urinary bladder, drain to the external iliac nodes, independent of the venous drainage. The pelvic lymph nodes are highly interconnected, so that lymphatic drainage (and metastatic cancer) can pass in almost any direction, to any pelvic or abdominal organ.

Pelvic Viscera

The **pelvic viscera** include the urinary bladder and parts of the ureters, the reproductive system, and the distal part of the alimentary tract (rectum). Although the sigmoid colon and parts of the small bowel extend into the pelvic cavity, they are abdominal rather than pelvic viscera. The sigmoid colon is continuous with the rectum anterior to S3 vertebra.

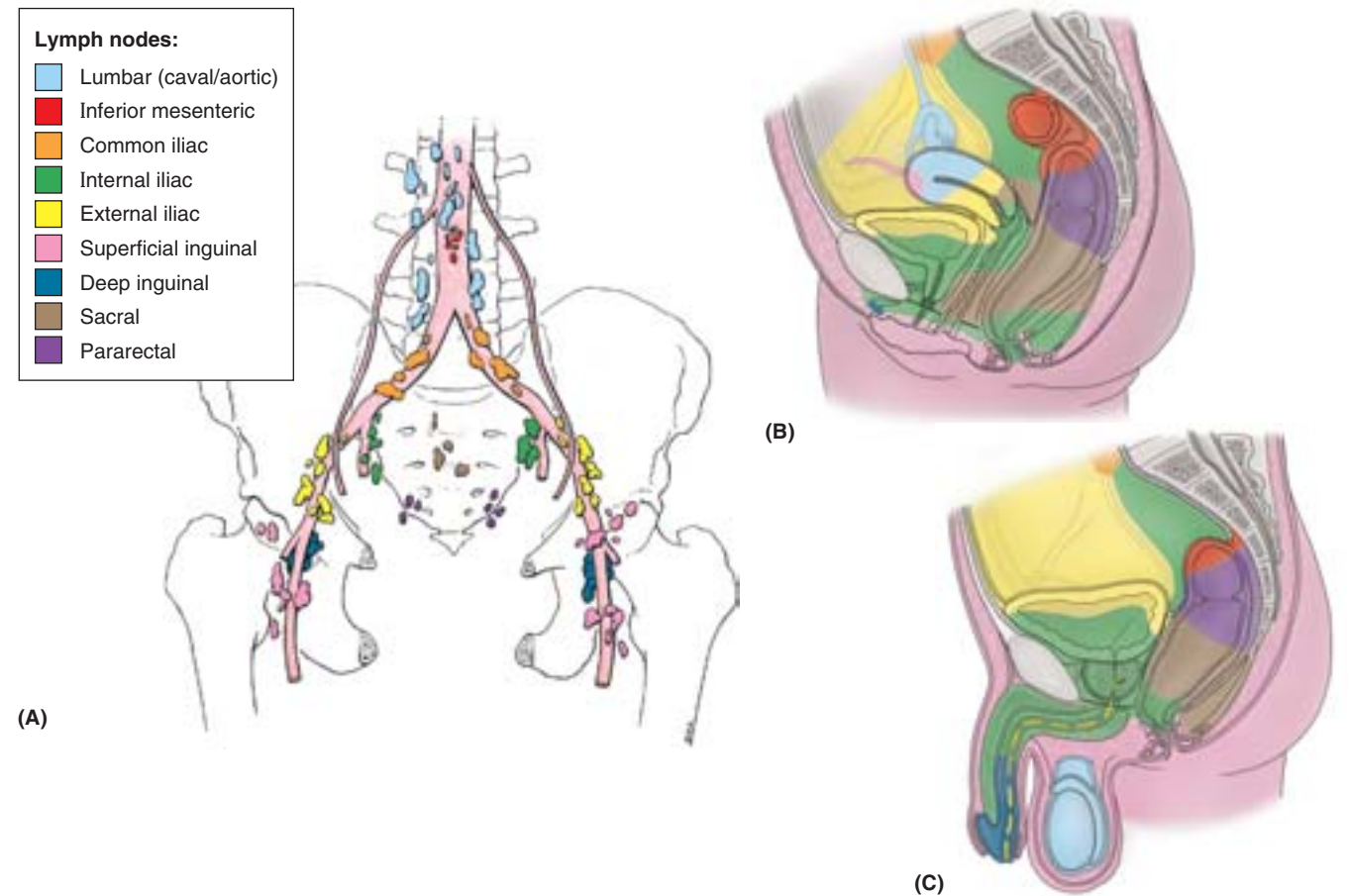
Urinary Organs

The pelvic urinary organs (Fig. 3.14) are the:

- Ureters, which carry urine from the kidneys.
- Urinary bladder, which temporarily stores urine.
- Urethra, which conducts urine from the bladder to the exterior.

Ureters

The **ureters** are muscular tubes, 25–30 cm long, that connect the kidneys to the urinary bladder. The ureters are retroperitoneal; their superior halves are in the abdomen (see Chapter 2) and their inferior halves lie in the pelvis. As the ureters cross the bifurcation of the common iliac artery or the beginning of the external iliac artery (Fig. 3.14A) they pass over the pelvic brim, thus leaving the abdomen and entering the lesser pelvis. The pelvic parts of the ureters run on the lateral walls of the pelvis, parallel to the anterior margin of the greater sciatic notch, between the parietal pelvic peritoneum and the internal iliac arteries. Opposite the ischial spine, they curve anteromedially, superior to the levator ani, to enter the urinary bladder. The inferior ends of the ureters are surrounded by the **vesical venous plexus** (Fig. 3.13B & C). The ureters pass obliquely through the muscular wall of the urinary bladder in an inferomedial direction, entering the outer surface of the bladder approximately 5 cm apart, but their internal openings into the lumen of the empty bladder are separated by only half that distance. This oblique passage through the bladder wall forms a one-way “flap valve,” the internal pressure of the filling bladder causing the intramural passage to collapse. In addition, contractions of the bladder musculature act as a sphincter preventing the reflux of urine into the ureters when the bladder contracts, increasing internal pressure during micturition. Urine is transported down the ureters by means of peristaltic contractions, a few drops being transported at intervals of 12–20 sec.

Table 3.6. Lymphatic Drainage of the Structures of the Pelvis and Perineum

Lymph Node Group	Structures Typically Draining to Lymph Node Group	
Lumbar	<p><i>Female:</i> along ovarian vessels</p> <p><i>Male:</i> along testicular vessels</p>	<p>Gonads and associated structures; common iliac nodes</p> <p><i>Female:</i> ovary; uterine tube (except isthmus and intrauterine parts); fundus of uterus</p> <p><i>Male urethra:</i> testis; epididymis</p>
Inferior mesenteric	Superiormost rectum; sigmoid colon; descending colon; pararectal nodes	
Common iliac	External and internal iliac lymph nodes	
Internal iliac	Inferior pelvic structures; deep perineal structures; sacral nodes	<p><i>Female:</i> base of bladder; inferior pelvic ureter; anal canal (above pectinate line); inferior rectum; middle and upper vagina; cervix; body of uterus</p> <p><i>Male:</i> prostatic urethra; prostate; base of bladder; inferior pelvic ureter; inferior seminal glands; cavernous bodies; anal canal (above pectinate line); inferior rectum</p>
External iliac	Anterosuperior pelvic structures; deep inguinal nodes	<p><i>Female:</i> superior bladder; superior pelvic ureter; upper vagina; cervix; lower body of uterus</p> <p><i>Male:</i> superior bladder; superior pelvic ureter; upper seminal gland; pelvic part of ductus deferens; intermediate and spongy urethra (secondary)</p>

(continues)

Table 3.6. Lymphatic Drainage of the Structures of the Pelvis and Perineum (continued)

Lymph Node Group	Structures Typically Draining to Lymph Node Group
Superficial inguinal	Lower limb; superficial drainage of inferolateral quadrant of trunk, including anterior abdominal wall inferior to umbilicus, gluteal region, and superficial perineal structures <i>Female:</i> superolateral uterus (near attachment of round ligament); skin of perineum including vulva; ostium of vagina (inferior to hymen); prepuce of clitoris; perianal skin; anal canal inferior to pectinate line <i>Male:</i> skin of perineum including skin and prepuce of penis; scrotum; perianal skin; anal canal inferior to pectinate line
Deep inguinal	Glans of clitoris or penis; superficial inguinal nodes <i>Female:</i> glans of clitoris <i>Male:</i> glans of penis; distal spongy urethra
Sacral	Posteroinferior pelvic structures: inferior rectum; inferior vagina
Pararectal	Superior rectum

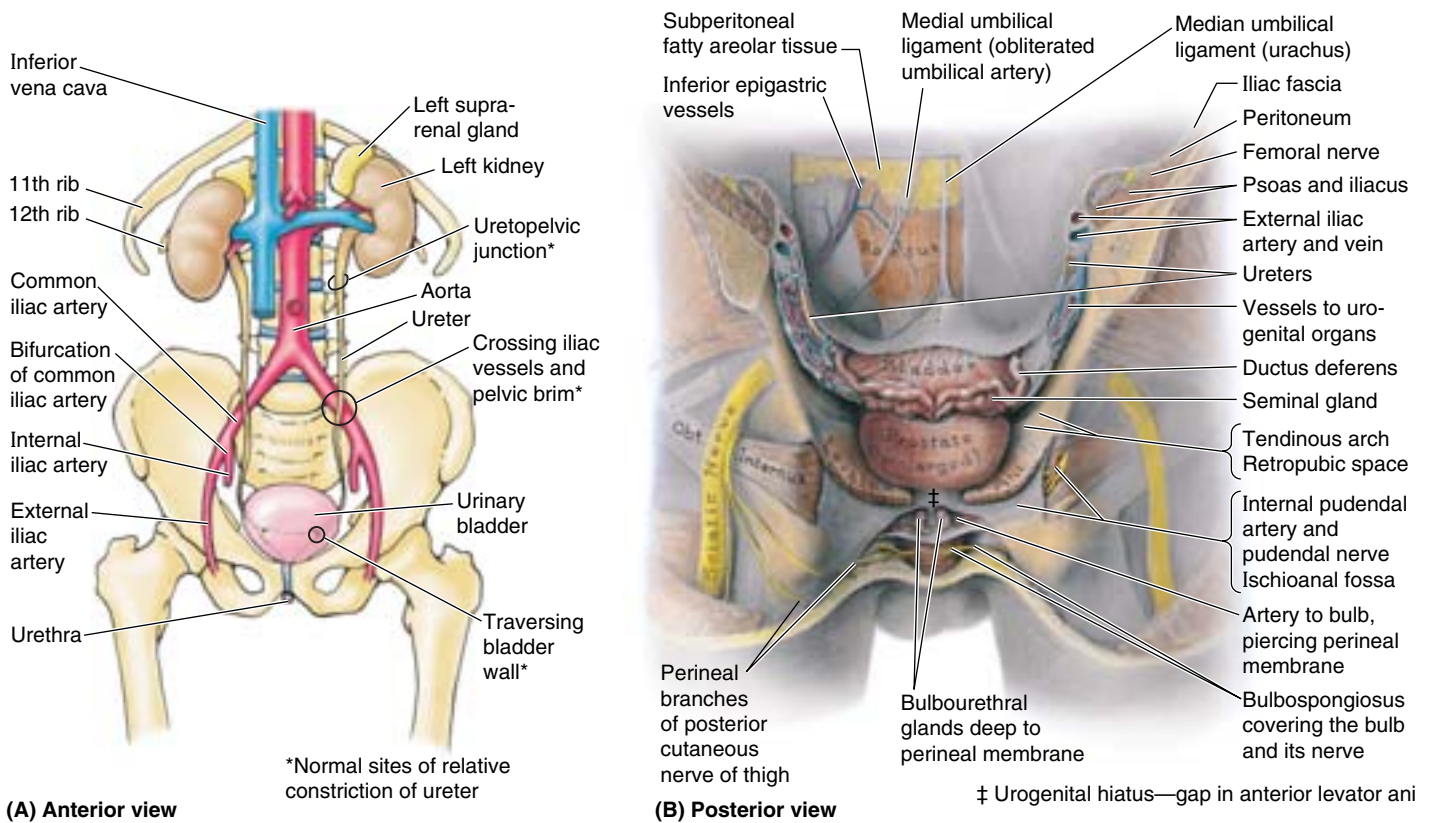


Figure 3.14. Genitourinary viscera. A. This view of the urinary apparatus demonstrates the course and normal sites of relative constriction of the ureters. **B.** In this posterior dissection approach to the anterior male pelvis, the posterior pelvic wall and rectum have been removed. The medial umbilical ligament (occluded part of umbilical artery) and the median umbilical ligament (remnant of fetal urachus), like the urinary bladder, lie in the subperitoneal loose areolar tissue. The levator ani (pelvic floor) supports the pelvic viscera and separates the pelvic retropubic space from the perineal ischioanal fossae. The free medial (anterior) borders of the levator ani are separated by a gap, the *urogenital hiatus*, through which the urethra (and, in the female, the vagina) passes.

In males, the only structure that passes between the ureter and the peritoneum is the *ductus deferens* (Fig. 3.14B); it crosses the ureter within the ureteric fold of peritoneum. The ureter lies posterolateral to the ductus deferens and enters the posterosuperior angle of the bladder, just superior to the seminal gland.

In females, the ureter passes medial to the origin of the uterine artery and continues to the level of the ischial spine, where it is crossed superiorly by the uterine artery (see clinical correlation [blue] boxes “Iatrogenic Injury of the Ureters during Ligation of Uterine Artery” and “Iatrogenic Injury of the Ureters during Ligation of Ovarian Artery,” in this chapter”). It then passes close to the lateral part of the fornix of the vagina and enters the posterosuperior angle of the bladder.

Arterial Supply of the Ureters. Variable branches from the common iliac, internal iliac, and ovarian arteries extend to and supply the pelvic parts of the ureters, anastomosing along the length of the ureter to form a continuous blood supply

(Fig. 3.15; Table 3.5). The most constant arteries supplying the terminal parts of the ureter in females are branches of the *uterine arteries*. The source of similar branches in males are the *inferior vesical arteries*.

Venous and Lymphatic Drainage of the Ureters. Veins from the ureters accompany the arteries and have corresponding names. Lymph drains sequentially, from superior to inferior, into the lumbar (caval/ aortic) and common iliac nodes (abdominal part) and the external and internal iliac nodes (pelvic part) (Fig. 3.16A).

Innervation of the Ureters. The nerves to the ureters derive from adjacent autonomic plexuses (renal, aortic, superior and inferior hypogastric). The ureters are superior to the pelvic pain line. Afferent (pain) fibers from the ureters follow sympathetic fibers in a retrograde direction to reach the spinal ganglia and spinal cord segments of T11–L1 or L2 (Fig. 3.16B). *Ureteric pain* is usually referred to the ipsilateral lower quadrant of the abdomen, especially to the groin (inguinal region).

Iatrogenic Compromise of the Ureteric Blood Supply

The ureters may be injured during abdominal, retroperitoneal, pelvic, or gynecological operations as a result of inadvertently interrupting their blood supply. Identification of the ureters during their full course through the pelvis is an important preventive measure. The longitudinal anastomoses between arterial branches to the ureter are usually adequate to maintain the blood supply along the length of the ureters, but occasionally they are not. Traction on the ureter during surgery may lead to delayed rupture of the ureter. The denuded ureteral segment becomes gangrenous and leaks or ruptures 7–10 days after surgery. When traction is necessary, it should be applied with great care. It is useful to realize that, although the blood supply to the abdominal segment of the ureter approaches from a medial direction, that of the pelvic segment approaches from a lateral direction (Fig. 3.15); the ureters should be retracted accordingly.

Ureteric Calculi

The ureters are expansile muscular tubes that dilate if obstructed. Acute obstruction usually results from a

ureteric calculus (L. pebble). The symptoms and severity depend on the location, type, and size of the calculus and on whether it is smooth or spiky. Although passage of small calculi usually causes little or no pain, larger ones produce severe pain. The pain caused by a calculus is a *colicky pain* (resembling colonic pain), which results from hyperperistalsis in the ureter superior to the level of the obstruction. Ureteric calculi may cause complete or intermittent obstruction of urinary flow. The obstruction may occur anywhere along the ureter but it occurs most often at the three sites where the ureters are normally relatively constricted (Fig. 3.14A): (1) at the junction of the ureters and renal pelvis, (2) where they cross the external iliac artery and pelvic brim, and (3) during their passage through the wall of the urinary bladder. The presence of calculi can often be confirmed by abdominal radiographs or an intravenous urogram (see Chapter 2). Ureteric calculi may be removed by open surgery, by endoscopy (**endourology**), or lithotripsy. **Lithotripsy** uses shock waves to break up a stone into small fragments that can be passed in the urine. ❖

THE BOTTOM LINE: The ureters carry urine from the renal pelvis to the urinary bladder. They descend subperitoneally into the pelvis, passing inferior to the ductus deferens of the male or the uterine artery of the female, the latter relationship being of particular surgical importance. They penetrate the bladder wall obliquely from its posteroinferior angle, creating a one-way valve. The

pelvic portion of each ureter is served by the inferior vesical (male) or vaginal (female) artery, the vesical venous plexus and internal iliac veins, and the external (superior part) and inferior iliac (lower part) lymph nodes. Calculi, likely to become entrapped where the ureter crosses the pelvic brim or enters the bladder, produce severe groin pain.

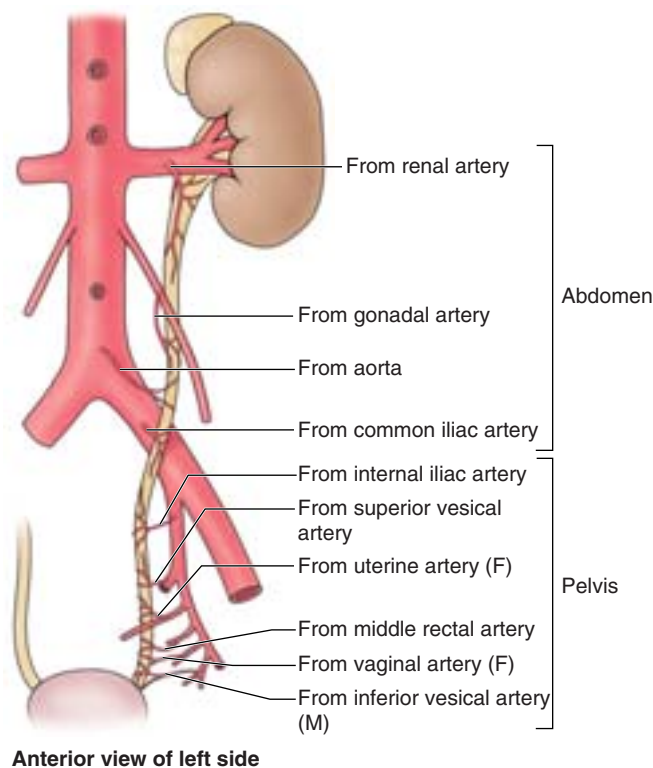


Figure 3.15. Blood supply of ureter. Branches supplying the abdominal half of the ureter approach medially, while those supplying the pelvic half approach laterally. During surgery, the ureters are avoided and left undisturbed when possible; if necessary, traction of the ureters should be applied gently and only toward the blood supply to avoid disruption of the small (delicate) branches.

Urinary Bladder

The **urinary bladder**, a hollow viscus with strong muscular walls, is characterized by its distensibility (Fig. 3.17A). The urinary bladder is a temporary reservoir for urine and varies in size, shape, position, and relationships according to its content and the state of neighboring viscera. When empty, the adult urinary bladder is located in the lesser pelvis, lying partially superior to and partially posterior to the pubic bones (Fig. 3.17B). It is separated from these bones by the potential *retropubic space* (of Retzius) and lies mostly inferior to the peritoneum, resting on the pubic bones and pubic symphysis anteriorly and the pelvic floor posteriorly (Fig. 3.17). The bladder is relatively free within the extraperitoneal subcutaneous fatty tissue, except for its neck, which is held firmly by the lateral ligaments of bladder and the tendinous arch of the pelvic fascia—especially its anterior components, the *puboprostatic ligament* in males and the *pubovesical ligament* in females (Figs. 3.9 and 3.17).

In infants and young children, the urinary bladder is in the abdomen even when empty (Fig. 3.18A). The bladder usually enters the greater pelvis by 6 years of age; however, it is not located entirely within the lesser pelvis until after puberty. An

empty bladder in an adult lies almost entirely in the lesser pelvis, its superior surface level with the superior margin of the pubic symphysis (Fig. 3.18B). As the bladder fills, it enters the greater pelvis as it ascends in the extraperitoneal fatty tissue of the anterior abdominal wall (Fig. 3.17A). In some individuals, a full bladder may ascend to the level of the umbilicus.

At the end of micturition (urination) the bladder of a normal adult contains virtually no urine. When empty, the bladder is somewhat tetrahedral (Fig. 3.18B) and externally has an apex, body, fundus, and neck. The bladder's four surfaces (superior, two inferolateral, and posterior) are most apparent when viewing an empty, contracted bladder that has been removed from a cadaver, when the bladder appears rather boat shaped.

The **apex of the bladder** points toward the superior edge of the pubic symphysis when the bladder is empty. The **fundus of the bladder** is opposite the apex, formed by the somewhat convex posterior wall. The **body of the bladder** is the major portion of the bladder between the apex and the fundus. The fundus and *inferolateral surfaces* meet inferiorly at the **neck of the bladder**.

The **bladder bed** is formed by the structures that directly contact it. On each side, the pubic bones and the fascia covering the levator ani and the superior obturator internus lie in contact with the inferolateral surfaces of the bladder (Fig. 3.18C). Only the superior surface is covered by peritoneum. Consequently, in males the fundus is separated from the rectum centrally by only the fascial rectovesical septum and laterally by the seminal glands and ampullae of the ductus deferentes (Fig. 3.17A); in females the fundus is directly related to the superior anterior wall of the vagina (Fig. 3.17B). The bladder is enveloped by a loose connective tissue visceral fascia.

The walls of the bladder are composed chiefly of the **detrusor muscle**. Toward the neck of the male bladder, the muscle fibers form the involuntary **internal urethral sphincter**. This sphincter contracts during ejaculation to prevent *retrograde ejaculation* (*ejaculatory reflux*) of semen into the bladder. Some fibers run radially and assist in opening the **internal urethral orifice**. In males, the muscle fibers in the neck of the bladder are continuous with the fibromuscular tissue of the prostate, whereas in females these fibers are continuous with muscle fibers in the wall of the urethra. The **ureteric orifices** and the internal urethral orifice are at the angles of the **trigone of the bladder** (Fig. 3.18C). The ureteric orifices are encircled by loops of detrusor musculature that tighten when the bladder contracts to assist in preventing reflux of urine into the ureter. The **uvula of the bladder** is a slight elevation of the trigone; it is usually more prominent in older men owing to enlargement of the posterior lobe of the prostate (see Fig. 3.20A).

Arterial Supply of the Bladder. The main arteries supplying the bladder are branches of the internal iliac arteries (Table 3.5). The *superior vesical arteries* supply anterosuperior parts of the bladder. In males, *inferior vesical arteries*

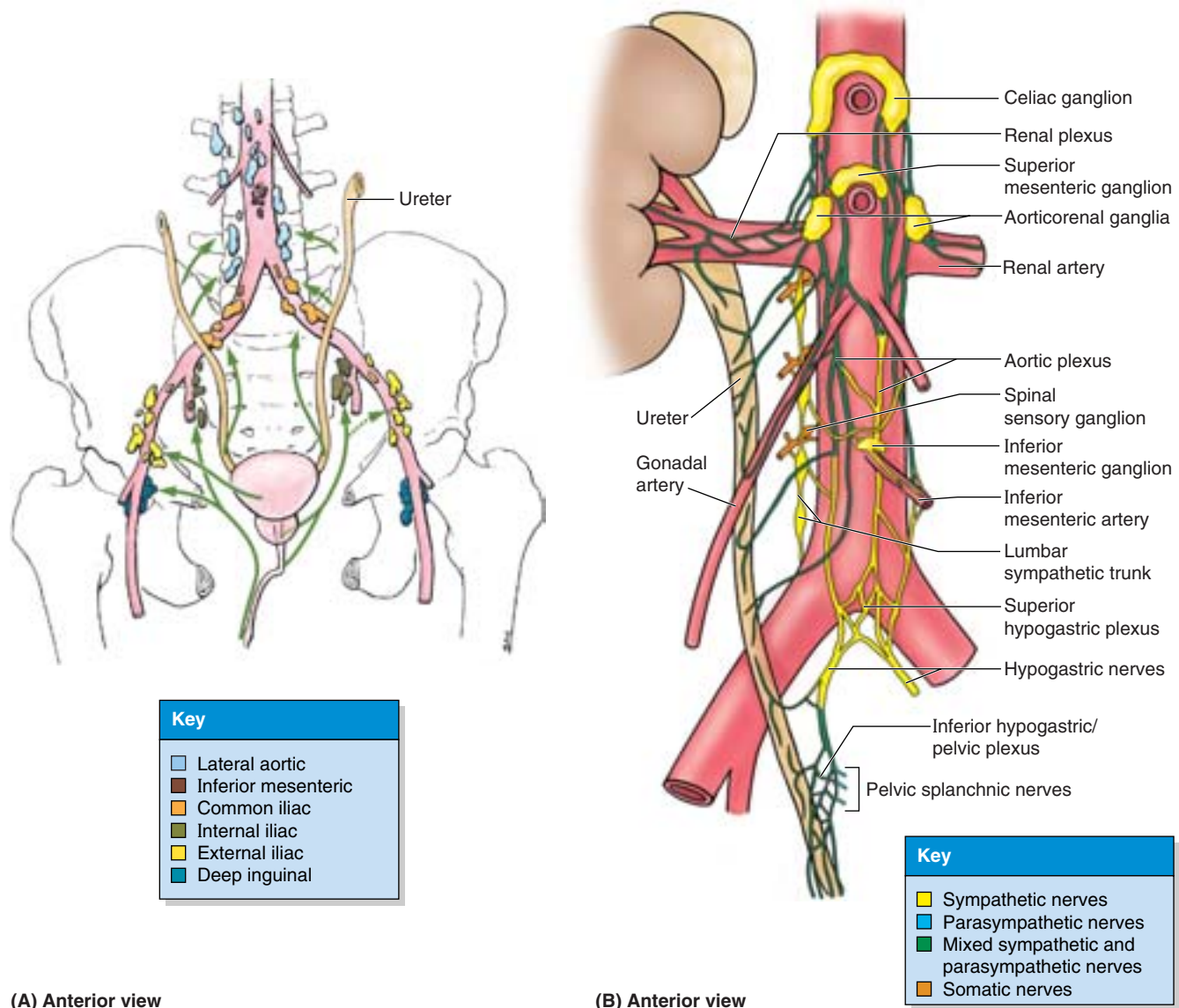
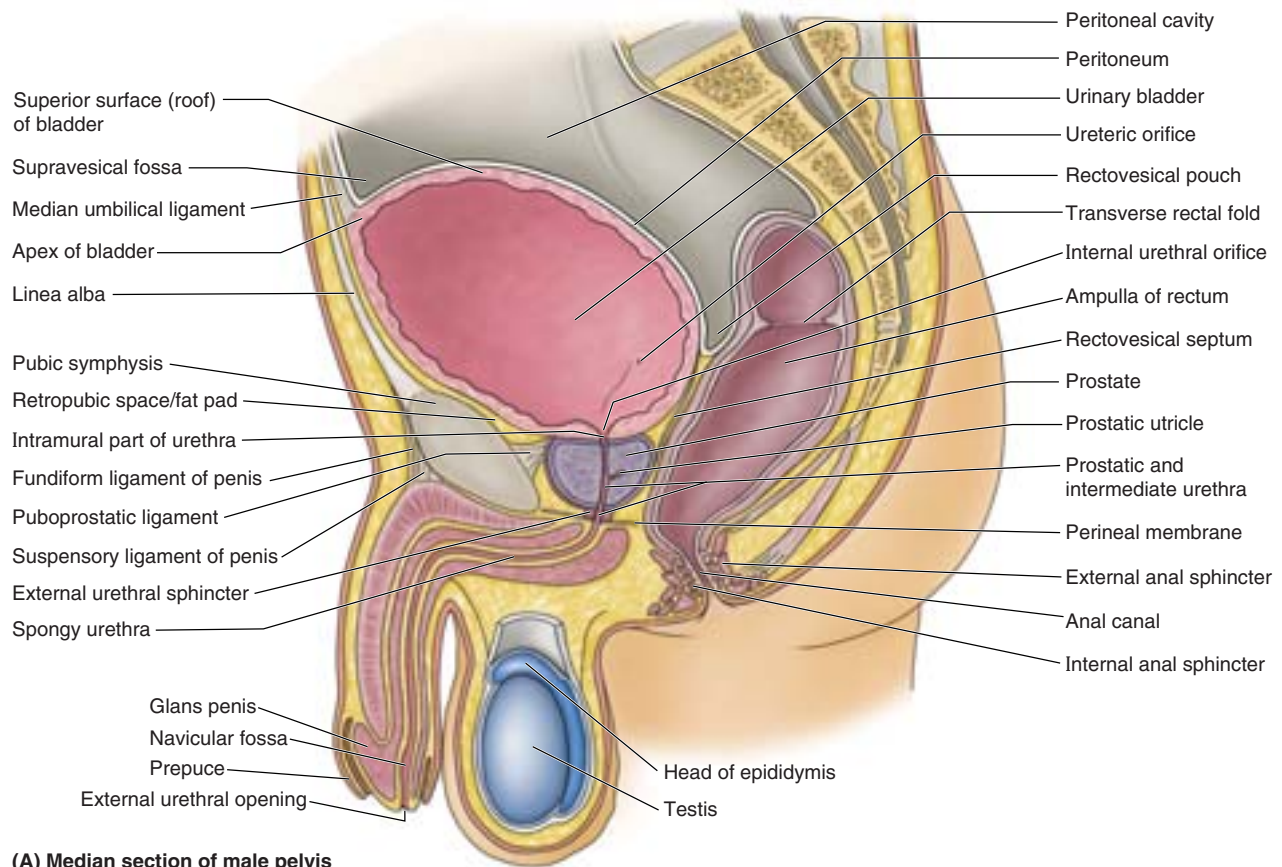


Figure 3.16. Lymphatic drainage of lower urinary system and innervation of ureter. **A.** The lymphatic drainage of the ureters, urinary bladder, and urethra in the male is shown. The *arrows* indicate the direction of lymph flow to the lymph nodes. The same routes are followed from the urinary systems of females. **B.** Nerve fibers from the renal, aortic, and superior and inferior hypogastric plexuses extend to the ureter, carrying visceral afferent and sympathetic fibers to the T10–L1 spinal sensory ganglia and cord segments and parasympathetic fibers primarily from the S2–S4 spinal cord segments.

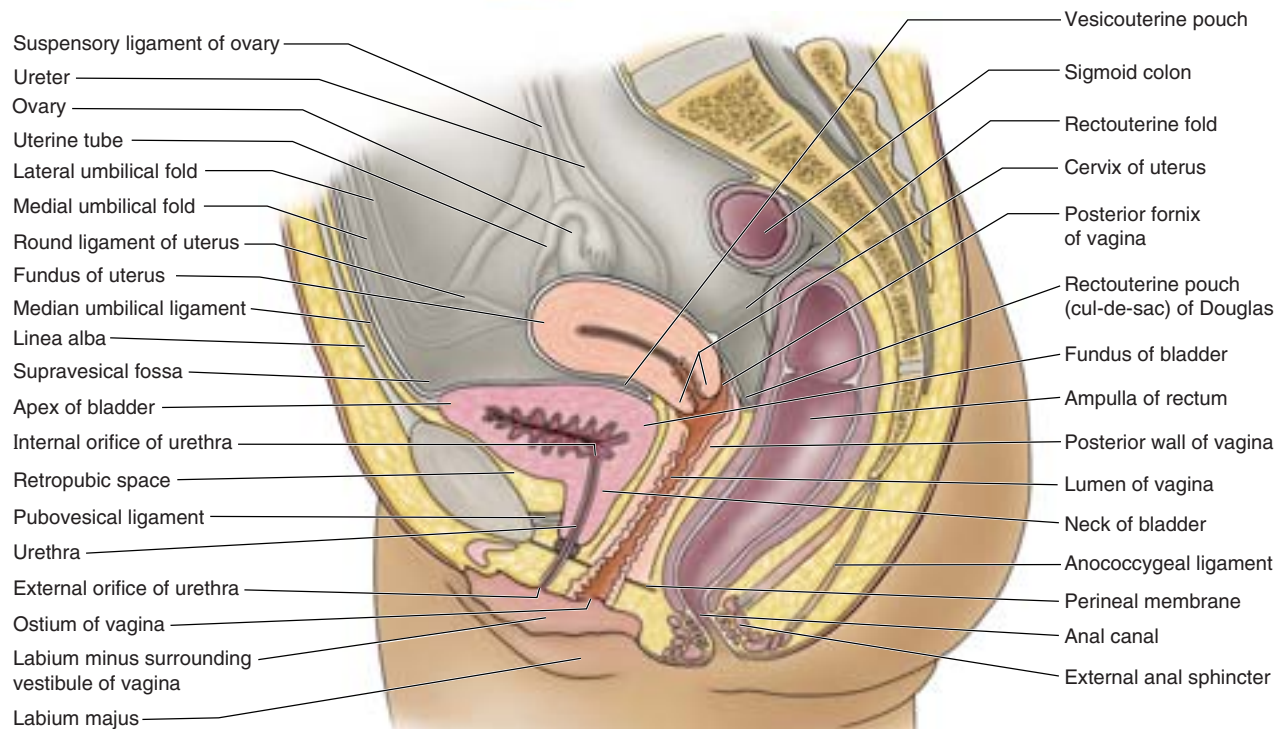
supply the fundus and neck of the bladder. In females, the *vaginal arteries* replace the inferior vesical arteries and send small branches to posteroinferior parts of the bladder (Fig. 3.11B). The obturator and inferior gluteal arteries also supply small branches to the bladder.

Venous and Lymphatic Drainage of the Bladder. The names of the veins correspond to the arteries and are tributaries of the internal iliac veins. In males, the *vesical venous plexus* is continuous with the *prostatic venous plexus* (Fig. 3.13C) and the combined plexus complex envelops the fundus of the bladder and prostate, the seminal glands, the ductus deferentes,

and the inferior ends of the ureters. It also receives blood from the deep dorsal vein of the penis, which drains into the prostatic venous plexus. The *vesical venous plexus* is the part of the plexus complex that is most directly associated with the bladder itself. It mainly drains through the inferior vesical veins into the internal iliac veins; however, it may drain through the sacral veins into the *internal vertebral venous plexuses* (see Chapter 4). In females, the vesical venous plexus envelops the pelvic part of the urethra and the neck of the bladder, receives blood from the *dorsal vein of the clitoris*, and communicates with the *vaginal or uterovaginal venous plexus* (Fig. 3.13B).



(A) Median section of male pelvis



(B) Median section of female pelvis

Figure 3.17. Viscera in hemisected male and female pelvises. **A.** In this male pelvis, the urinary bladder is distended, as if full. Compare its relation to the anterior abdominal wall, pubic symphysis, and level of the supravesical fossa to that of the non-distended (empty) bladder in part **B.** **B.** In this female pelvis, the uterus was sectioned in its own median plane and is depicted as though it coincided with the median plane of the body, which is seldom the case. With the bladder empty, the normal disposition of the uterus shown here—bent on itself (anteflexed) at the junction of the body and cervix and tipped anteriorly (anteverted)—causes its weight to be borne mainly by the bladder. The urethra lies anterior and parallel to the lower half of the vagina.

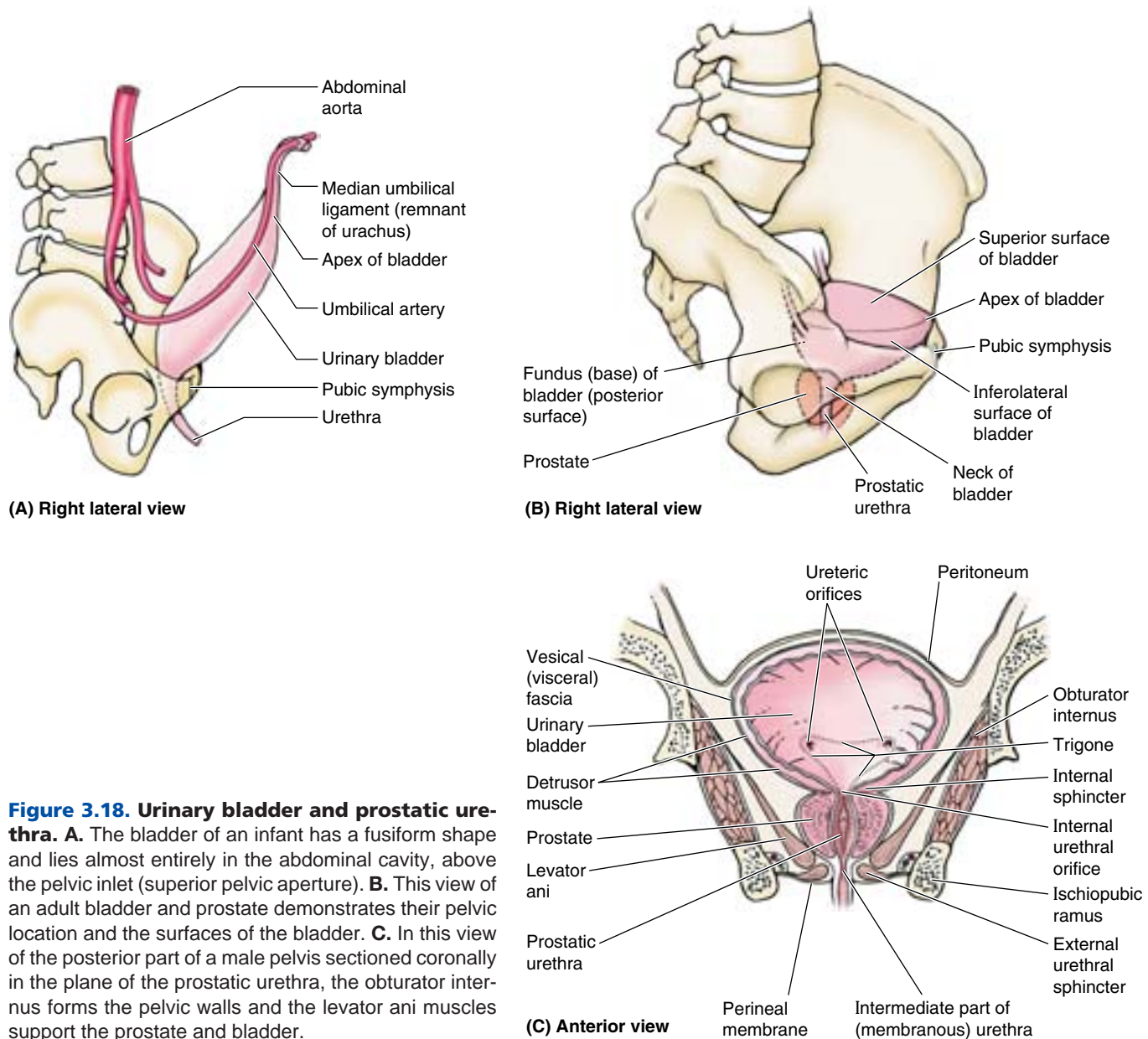


Figure 3.18. Urinary bladder and prostatic urethra. **A.** The bladder of an infant has a fusiform shape and lies almost entirely in the abdominal cavity, above the pelvic inlet (superior pelvic aperture). **B.** This view of an adult bladder and prostate demonstrates their pelvic location and the surfaces of the bladder. **C.** In this view of the posterior part of a male pelvis sectioned coronally in the plane of the prostatic urethra, the obturator internus forms the pelvic walls and the levator ani muscles support the prostate and bladder.

In both sexes, **lymphatic vessels** from the superolateral aspects of the bladder pass to the *external iliac lymph nodes* (Fig. 3.16A; Table 3.6), whereas those from the fundus and neck pass to the *internal iliac lymph nodes*. Some vessels from the neck of the bladder drain into the sacral or common iliac lymph nodes.

Innervation of the Bladder. Sympathetic fibers are conveyed from inferior thoracic and upper lumbar spinal cord levels to the vesical (pelvic) plexuses primarily through the hypogastric plexuses and nerves, whereas parasympathetic fibers from sacral spinal cord levels are conveyed by the

pelvic splanchnic nerves and the inferior hypogastric plexus (Fig. 3.19). The parasympathetic fibers are motor to the detrusor muscle and inhibitory to the internal urethral sphincter of the male bladder. Hence, when visceral afferent fibers are stimulated by stretching, the bladder contracts reflexively, the internal urethral sphincter relaxes (in males), and urine flows into the urethra. With toilet training, we learn to suppress this reflex when we do not wish to void. The sympathetic innervation that stimulates ejaculation simultaneously causes contraction of the internal urethral sphincter, to prevent reflux of semen into the bladder. A sympathetic

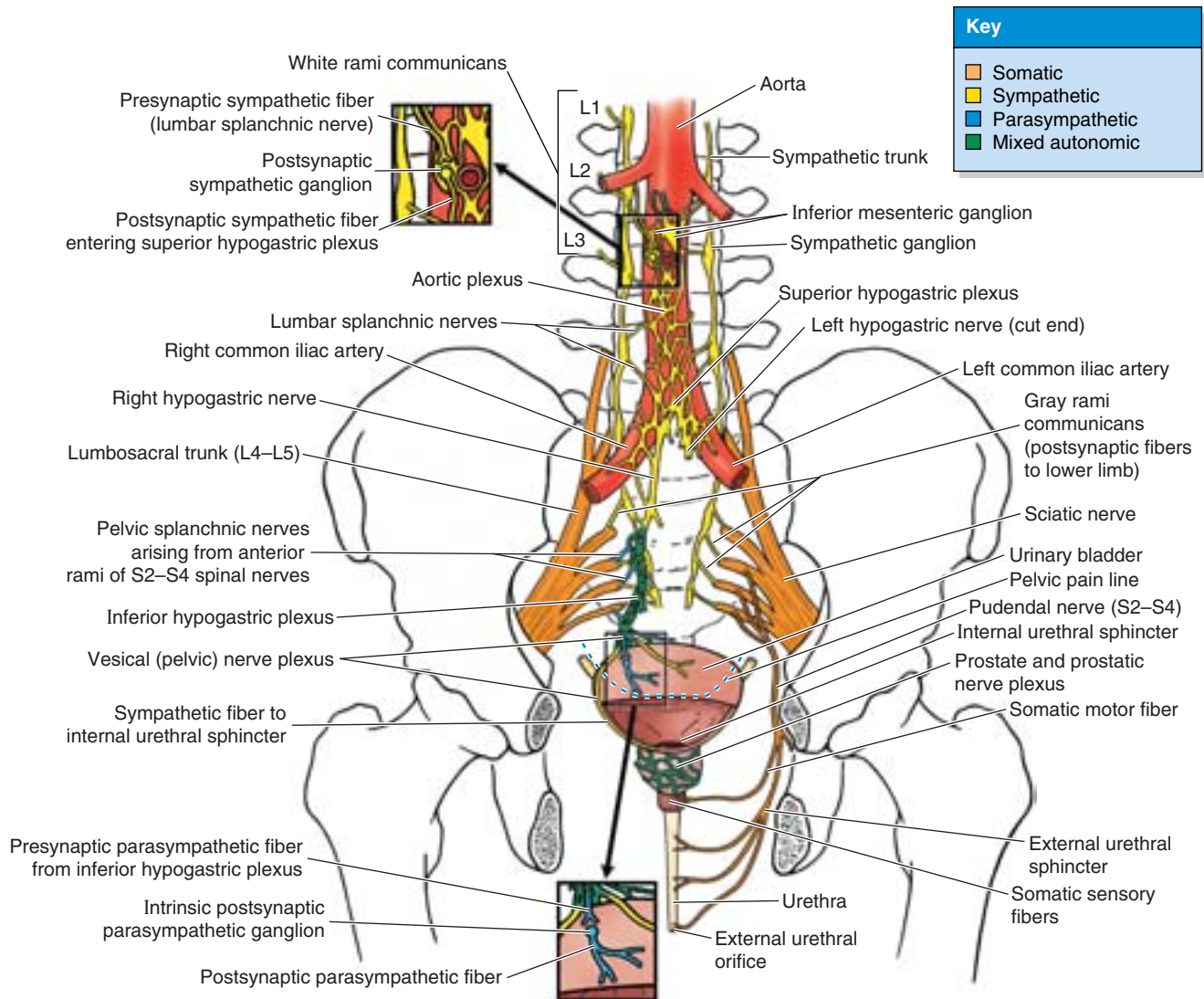


Figure 3.19. Innervation of bladder and urethra. Presynaptic sympathetic fibers from the T11–L2 or L3 spinal cord levels involved in innervation of the bladder, prostate, and proximal urethra pass via lumbar splanchnic nerves to the aortic/hypogastric system of plexuses, synapsing in the plexuses en route to the pelvic viscera. Presynaptic parasympathetic fibers to the bladder arise from neurons in the S2–S4 spinal cord segments and pass from the anterior rami of spinal nerves S2–S4 via the pelvic splanchnic nerves and inferior hypogastric and vesical (pelvic) plexuses to the bladder. They synapse with postsynaptic neurons located on or near the bladder wall. Visceral afferent fibers conveying reflex information and pain sensation from subperitoneal viscera (inferior to the pelvic pain line) follow parasympathetic fibers retrogradely to the S2–S4 spinal ganglia, whereas those conducting pain from the bladder roof (superior to the pelvic pain line) follow sympathetic fibers retrogradely to the T11–L2 or L3 spinal ganglia. The pelvic (sacral) sympathetic trunk primarily serves the lower limb. The somatic nerves shown here are distributed to the perineum.

response at moments other than ejaculation (e.g., self-consciousness when standing at the urinal in front of a waiting line) can cause the internal sphincter to contract, hampering the ability to urinate until parasympathetic inhibition of the sphincter occurs.

Sensory fibers from the bladder are visceral; reflex afferents follow the course of the parasympathetic fibers, as do those

transmitting pain sensations (such as results from overdistension) from the inferior part of the bladder. The superior surface (roof) of the bladder is covered with peritoneum and is therefore superior to the *pelvic pain line*; thus pain fibers from the superior bladder follow the sympathetic fibers retrogradely to the inferior thoracic and upper lumbar spinal ganglia (T11–L2 or L3).

Cystocele—Hernia of the Bladder

Loss of bladder support in females by damage to the perineal muscles or their associated fascia can result in herniation of the bladder into the vaginal wall (Fig. B3.6A). A cystocele may also result from prolapse of pelvic viscera secondary to injury to the pelvic floor during childbirth.

Suprapubic Cystotomy

Although the superior surface of the empty bladder lies at the level of the superior margin of the pubic symphysis (Fig. B3.6B), as the bladder fills it extends superiorly above the symphysis into the loose areolar tissue between the parietal peritoneum and anterior abdominal wall (Fig. B3.6C). The bladder then lies adjacent to this wall without the intervention of peritoneum. Consequently, the distended bladder may be punctured (*suprapubic cystotomy*) or approached surgically superior to the pubic

symphysis for the introduction of in-dwelling catheters or instruments without traversing the peritoneum and entering the peritoneal cavity (Fig. B3.6D). Urinary calculi, foreign bodies, and small tumors may also be removed from the bladder through a suprapubic extraperitoneal incision.

Rupture of the Bladder

Because of the superior position of the distended bladder, it may be ruptured by injuries to the inferior part of the anterior abdominal wall or by fractures of the pelvis. The rupture may result in the escape of urine extraperitoneally or intraperitoneally. Rupture of the superior part of the bladder frequently tears the peritoneum, resulting in *extravasation (passage) of urine into the peritoneal cavity*. Posterior rupture of the bladder usually results in passage of urine extraperitoneally into the perineum. ▶

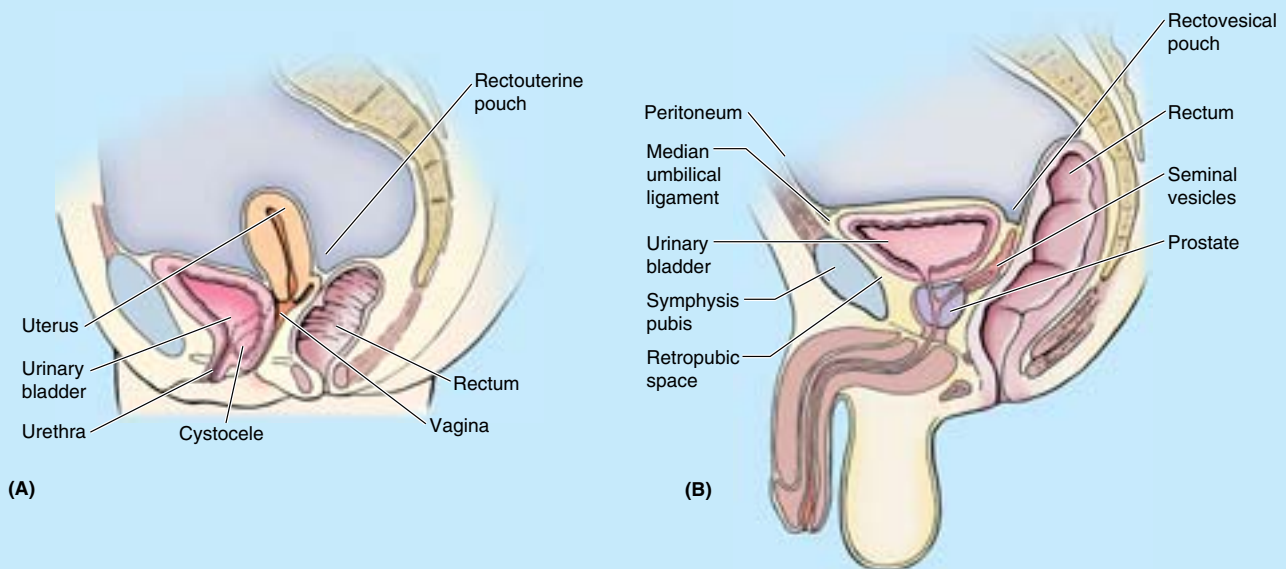


Figure B3.6

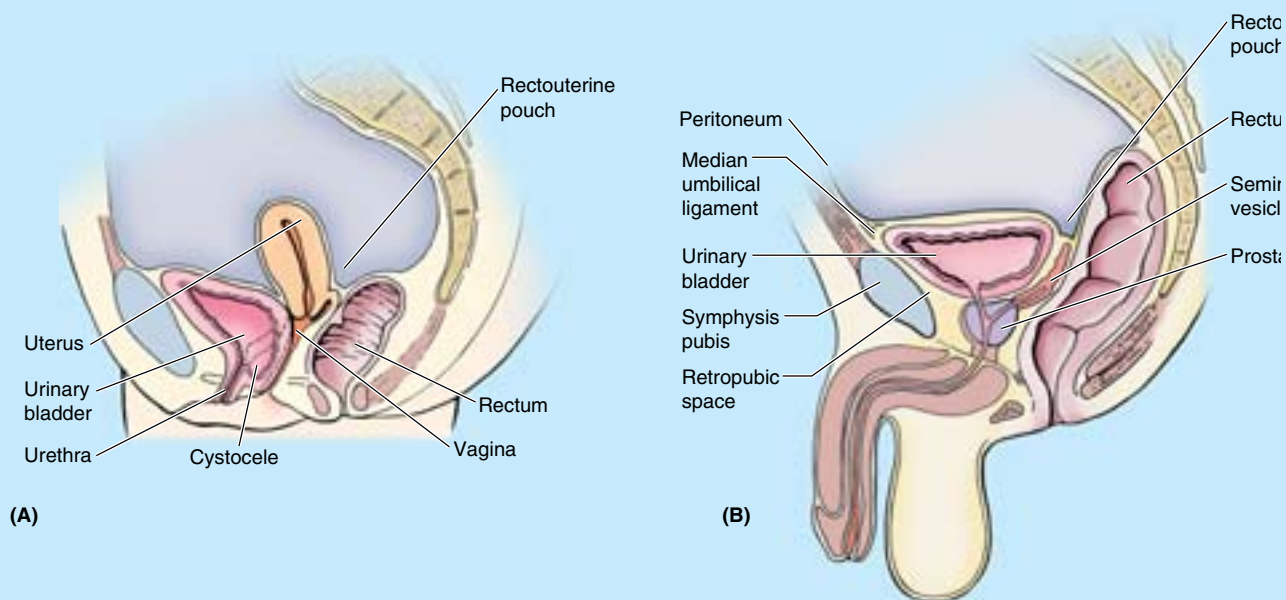


Figure B3.6. (Continued)

Cystoscopy

The interior of the bladder and its three orifices can be examined with a *cystoscope* (see clinical correlation [blue] box “Ureteric Calculi,” in this chapter). During *transurethral resection of a tumor*, the instrument is passed into the bladder through the urethra (Fig. B3.7). Using a high-frequency electrical current, the tumor is removed in small fragments that are washed from the bladder with water. +

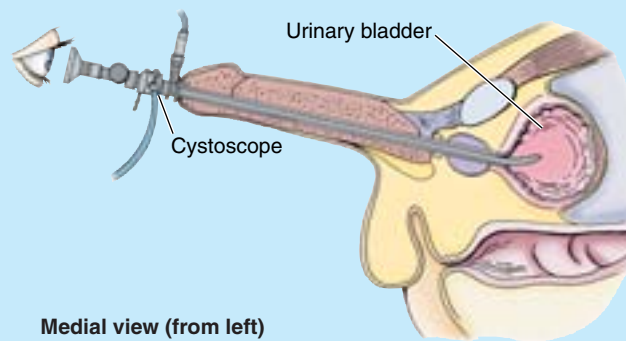


Figure B3.7

THE BOTTOM LINE: The superior and inferior portions of the urinary bladder are quite distinct anatomically and functionally. The body is highly distensible, embedded in loose extraperitoneal fat, and covered on its superior aspect with peritoneum, all of which allow expansion with filling. In contrast, the relatively indistensible neck is anchored in place by pelvic ligaments and the floor of the bladder overlying it (which includes the trigone of the bladder) and remains relatively unchanged with filling. Most of the bladder body is served by superior vesical arteries and veins and lymphatic vessels that drain to external iliac lymph nodes. The neck and adjacent inferior body are served by inferior vesical arteries, the vesical venous plexus, and lymphatic vessels

that drain to internal iliac nodes. Sympathetic fibers from inferior thoracic and superior lumbar spinal cord segments maintain the tonus of the bladder neck and, in males during ejaculation, stimulate contraction of the internal urethra sphincter to prevent reflux of semen. Parasympathetic fibers conveyed by pelvic splanchnic nerves from the S2–S4 spinal cord segments inhibit the neck musculature and stimulate increased tonus of the detrusor muscle of the bladder walls for urination. Visceral afferent fibers conducting pain sensation from the roof of the bladder (superior to the pelvic pain line) follow the sympathetic fibers retrogradely to spinal sensory ganglia; the remaining visceral afferent fibers follow the parasympathetic fibers.

Proximal Male Urethra

The **male urethra** is a muscular tube (18–22 cm long) that conveys urine from the *internal urethral orifice* of the urinary bladder to the *external urethral orifice*, located at the tip of the glans penis in males (Fig. 3.17A). The urethra also provides an exit for semen (sperms and glandular secretions). In the *flaccid* (non-erect) state, the urethra has a double curvature. For descriptive purposes, the urethra is divided into four parts, described in Table 3.7 and demonstrated in Figures 3.17A and 3.20. The distal *intermediate part* and *spongy urethra* will be described further with the perineum (later in this chapter).

The **intramural part of the urethra (preprostatic urethra)** varies in diameter and length, depending on whether the bladder is filling (bladder neck is tonically contracted so the internal urethral orifice is small and high; the *filling internal urethral orifice*) or emptying (the neck is relaxed so the orifice is wide and low; the *emptying internal urethral orifice*). The most prominent feature of the **prostatic urethra** is the **urethral crest**, a median ridge between bilateral grooves, the **prostatic sinuses** (Fig. 3.20). The secretory ducts of the prostate, the *prostatic ducts*, open into the prostatic sinuses. The **seminal colliculus** is a rounded eminence in the middle of the urethral crest with a slit-like orifice that opens into a small cul-de-sac, the **prostatic utricle** (Figs. 3.20 and 3.21). The prostatic utricle is the vestigial remnant of the embryonic uterovaginal canal, the surrounding walls of which, in the female, constitute the primordium of the uterus and a part of the vagina (Moore and Persaud, 2003). The *ejaculatory ducts* open into the prostatic urethra via minute, slit-like openings located adjacent to and occasionally just within the orifice of the prostatic utricle. Thus urinary and reproductive tracts merge at this point.

Arterial Supply of the Proximal Male Urethra. The proximal two parts of the urethra are supplied by *prostatic*

branches of the inferior vesical and middle rectal arteries (Figs. 3.11A & C and 3.22; Table 3.5).

Venous and Lymphatic Drainage of the Proximal Male Urethra. The veins from the proximal two parts of the urethra drain into the *prostatic venous plexus* (Fig. 3.22). The lymphatic vessels pass mainly to the *internal iliac lymph nodes*; a few vessels drain into the *external iliac lymph nodes* (Fig. 3.16A; Table 3.6).

Innervation of the Proximal Male Urethra. The nerves are derived from the prostatic plexus (mixed sympathetic, parasympathetic, and visceral afferent fibers) (Fig. 3.19). The **prostatic plexus** is one of the pelvic plexuses (an inferior extension of the vesical plexus) arising as organ-specific extensions of the inferior hypogastric plexus.

Female Urethra

The **female urethra** (approximately 4 cm long and 6 mm in diameter) passes anteroinferiorly from the *internal urethral orifice* of the urinary bladder (Fig. 3.17B), posterior and then inferior to the pubic symphysis, to the *external urethral orifice*. The musculature surrounding the internal urethral orifice of the female bladder is not organized into an internal sphincter. In females, the **external urethral orifice** is located in the vestibule, directly anterior to the *vaginal orifice*. The urethra lies anterior to the vagina (forming an elevation in the anterior vaginal wall) (Fig. 3.27C); its axis is parallel to that of the vagina. The urethra passes with the vagina through the pelvic diaphragm, external urethral sphincter, and perineal membrane. Urethral glands are present, particularly in the superior part of the urethra. One group of glands on each side, the *paraurethral glands*, are homologues to the prostate. These glands have a common paraurethral duct, which opens (one on each side) near the external urethral orifice. The inferior half of the urethra is located in the perineum and is discussed in that section.

Table 3.7. Parts of the Male Urethra

Part	Length	Location/Disposition	Features
Intramural (preprostatic) part	0.5–1.5 cm	Extends almost vertically through neck of bladder	Surrounded by internal urethral sphincter; diameter and length vary, depending on whether bladder is filling or emptying
Prostatic urethra	3.0–4.0 cm	Descends through anterior prostate, forming a gentle, anteriorly concave curve; is bounded anteriorly by a vertical trough-like part (rhabdosphincter) of external urethral sphincter	Widest and most dilatable part; features urethral crest with seminal colliculus, flanked by prostatic sinuses into which prostatic ducts open; ejaculatory ducts open onto colliculus, hence urinary and reproductive tracts merge in this part
Intermediate (membranous) part	1.0–1.5 cm	Passes through deep perineal pouch, surrounded by circular fibers of external urethral sphincter; penetrates perineal membrane	Narrowest and least distensible part (except for external urethral orifice)
Spongy urethra	~ 15 cm	Courses through corpus spongiosum; initial widening occurs in bulb of penis; widens again distally as navicular fossa (in glans penis)	Longest and most mobile part; bulbourethral glands open into bulbous part; distally, urethral glands open into small urethral lacunae entering lumen of this part

Arterial Supply of the Female Urethra. Blood is supplied to the female urethra by the *internal pudendal* and *vaginal arteries* (Figs. 3.11B and 3.12A; Table 3.5).

Venous and Lymphatic Drainage of the Female Urethra. The veins follow the arteries and have similar names (Fig. 3.13B). Most lymphatic vessels from the urethra pass to the *sacral* and *internal iliac lymph nodes* (Table 3.6), but a few vessels from the distal urethra drain into the *inguinal lymph nodes*.

Innervation of the Female Urethra. The nerves to the urethra arise from the *vesical (nerve) plexus* and the *pudendal nerve*. The pattern is similar to that in the male (Fig. 3.19), given the absence of a prostatic plexus and an internal urethra sphincter. Visceral afferents from most of the urethra run in the pelvic splanchnic nerves, but the termination receives somatic afferents from the pudendal nerve. Both the visceral and the somatic afferent fibers extend from cell bodies in the S2–S4 spinal ganglia.

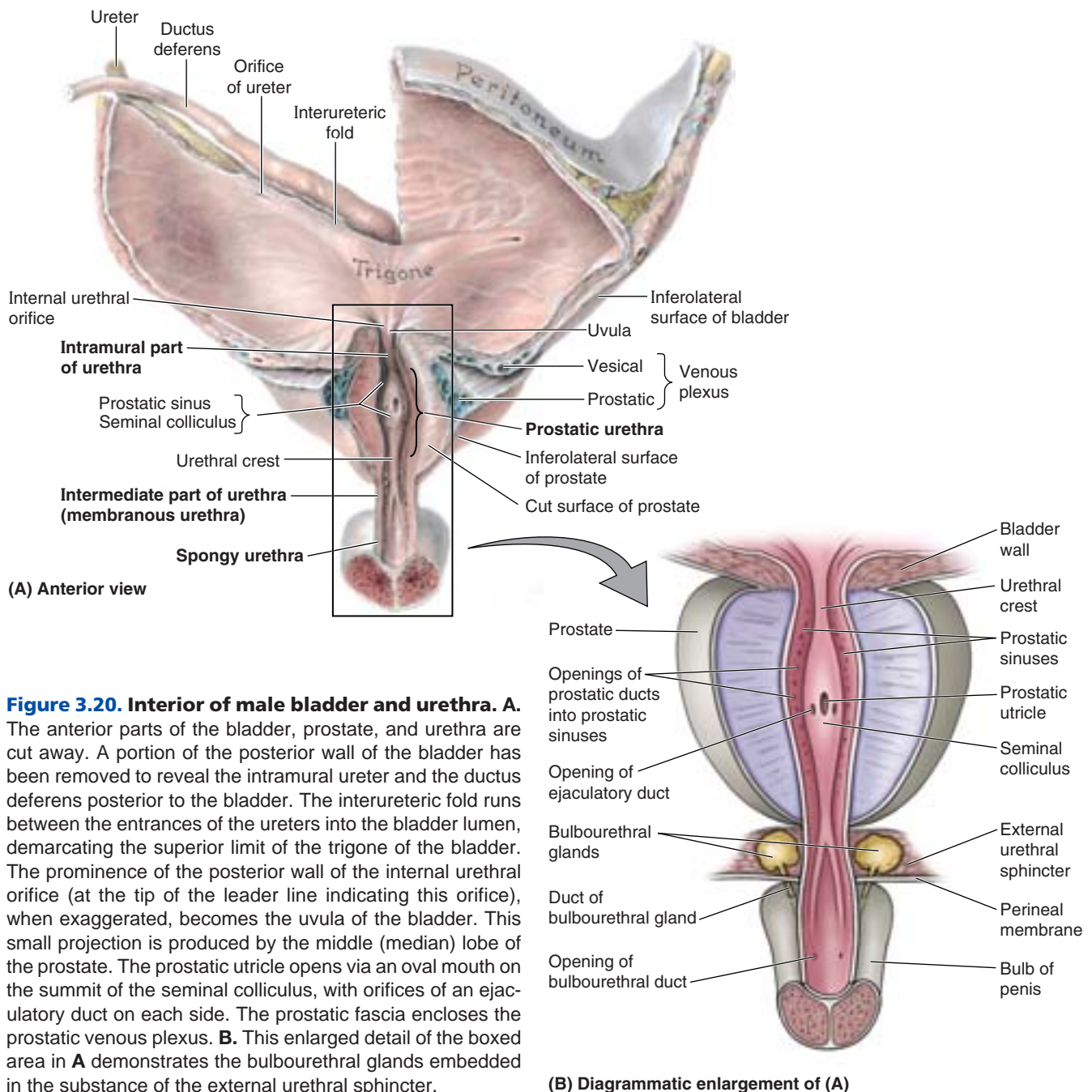


Figure 3.20. Interior of male bladder and urethra. A.

The anterior parts of the bladder, prostate, and urethra are cut away. A portion of the posterior wall of the bladder has been removed to reveal the intramural ureter and the ductus deferens posterior to the bladder. The interureteric fold runs between the entrances of the ureters into the bladder lumen, demarcating the superior limit of the trigone of the bladder. The prominence of the posterior wall of the internal urethral orifice (at the tip of the leader line indicating this orifice), when exaggerated, becomes the uvula of the bladder. This small projection is produced by the middle (median) lobe of the prostate. The prostatic utricle opens via an oval mouth on the summit of the seminal colliculus, with orifices of an ejaculatory duct on each side. The prostatic fascia encloses the prostatic venous plexus. **B.** This enlarged detail of the boxed area in **A** demonstrates the bulbourethral glands embedded in the substance of the external urethral sphincter.

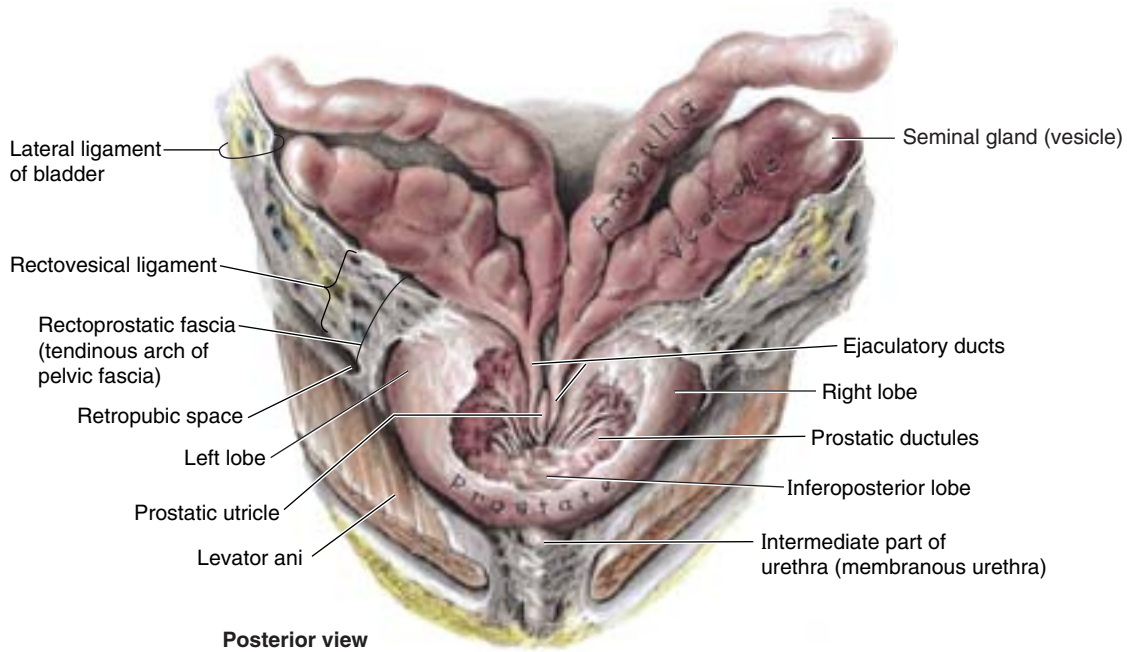


Figure 3.21. Dissection of posterior part of prostate, lateral ligament of bladder, and rectoprostatic fascia. The ejaculatory ducts are formed by the merger of the duct of the seminal gland and the ductus deferens. The vestigial prostatic utricle, usually seen as an invagination in an anterior view, appears in this posterior dissection as an evagination lying between the ejaculatory ducts.

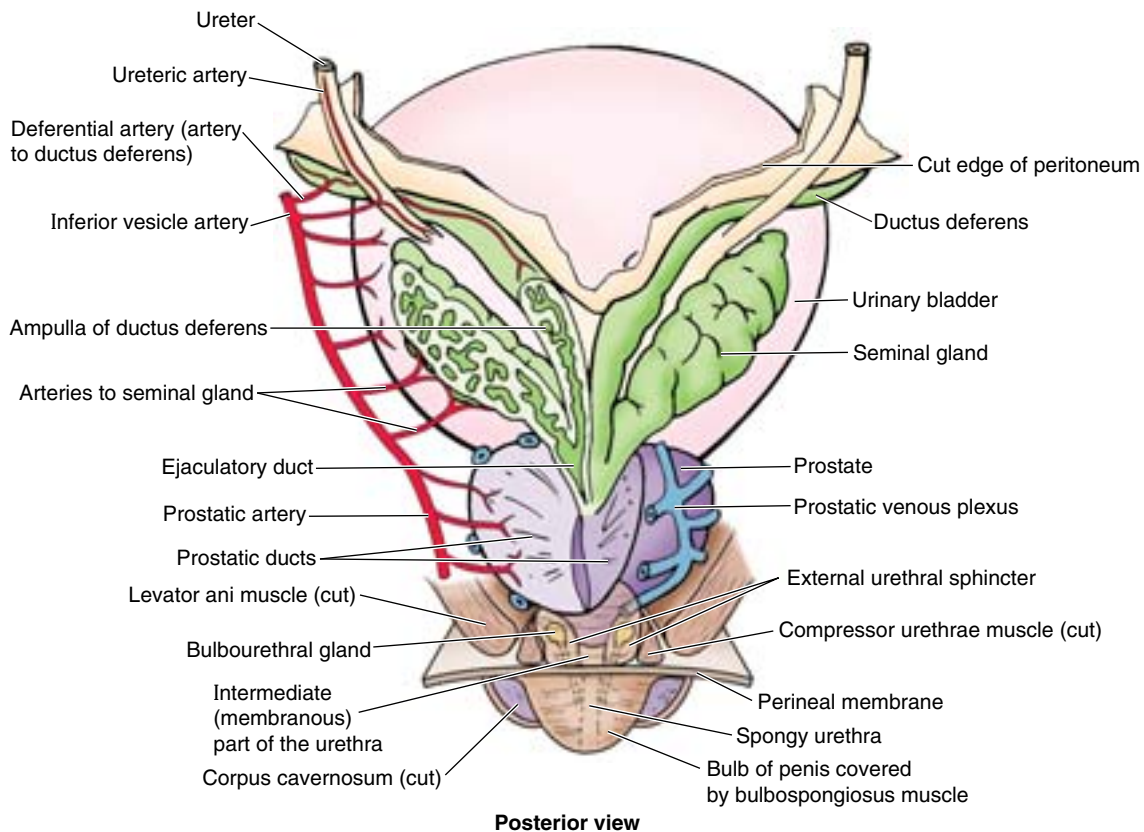


Figure 3.22. Urinary bladder, seminal glands, terminal parts of ductus deferens, and prostate. The left seminal gland and ampulla of the ductus deferens are dissected free and sliced open. Part of the prostate is also cut away to expose the ejaculatory duct. The perineal membrane lies between the external genitalia and the deep part of the perineum (anterior recess of ischioanal fossa). It is pierced by the urethra, ducts of the bulbourethral glands, dorsal and deep arteries of the penis, cavernous nerves, and the dorsal nerve of the penis.

Clinically Significant Differences between Male and Female Urethrae

The female urethra is distensible because it contains considerable elastic tissue, as well as smooth muscle. It can be easily dilated without injury; consequently, the passage of catheters or cystoscopes is easier in females than in males. Infections of the urethra, and especially the bladder, are more common in women because the female urethra is short, more distensible, and is open to the exterior through the vestibule of the vagina. ❖

THE BOTTOM LINE: The male urethra consists of four parts, two of which are the intramural and prostatic parts. The intramural part varies in length and caliber, depending on whether the bladder is filling or emptying. The prostatic urethra is distinguished both by its surroundings and the structures that open into it. It is surrounded by the prostate, the muscular anterior “lobe” that includes the trough-like superior extension of the external urethral sphincter anteriorly, and by the glandular lobes posteriorly. Opening into the prostatic sinuses on each side of the urethral crest are the prostatic ducts. The vestigial utricle is a relatively large opening in the center of the seminal colliculus, flanked by the tiny openings of the ejaculatory ducts. Thus the reproductive and urinary tracts merge within the prostatic urethra.

The female urethra runs parallel to the vagina. It is firmly attached to and indents the anterior vaginal wall centrally and distally.

Male Internal Genital Organs

The male internal genital organs include the testes, epididymides (singular = epididymis), ductus deferentes (singular = ductus deferens), seminal glands, ejaculatory ducts, prostate, and bulbourethral glands (Figs. 3.22 and 3.23). Although external in position postnatally, the testes and epididymides (described in Chapter 2) are considered internal genital organs on the basis of their developmental position and homology with the internal female gonads (ovaries).

Ductus Deferens

The **ductus deferens** (deferent duct, vas deferens) is the continuation of the duct of the epididymis. The ductus deferens:

- Has relatively thick muscular walls and a minute lumen, giving it a cord-like firmness.
- Begins in the tail of the epididymis, at the inferior pole of the testis.

- Ascends posterior to testis, medial to the epididymis.
- Is the primary component of the spermatic cord.
- Penetrates the anterior abdominal wall via the inguinal canal.
- Crosses over the external iliac vessels and enters the pelvis.
- Passes along the lateral wall of the pelvis, where it lies external to the parietal peritoneum.
- Ends by joining the duct of the seminal gland to form the *ejaculatory duct*.

During the pelvic part of its course, the ductus deferens maintains direct contact with the peritoneum; no other structure intervenes between them. The ductus crosses superior to the ureter near the posterolateral angle of the bladder, running between the ureter and the peritoneum of the ureteric fold to reach the fundus of the bladder. The relationship of the ductus deferens to the ureter in the male is similar, although of lesser clinical importance, to that of the uterine artery to the ureter in the female. The developmental basis of this relationship is shown in Figure 3.24. Posterior to the bladder, the ductus deferens at first lies superior to the seminal gland, then descends medial to the ureter and the gland. Here the ductus deferens enlarges to form the **ampulla of the ductus deferens** before its termination (Fig. 3.22).

Arterial Supply of the Ductus Deferens. The tiny *artery to the ductus deferens* usually arises from a superior (sometimes inferior) vesical artery (Figs. 3.22 and 3.23; Table 3.5) and terminates by anastomosing with the testicular artery, posterior to the testis.

Venous and Lymphatic Drainage of the Ductus Deferens. Veins from most of the ductus drain into the testicular vein, including the distal pampiniform plexus. Its terminal portion drains into the vesicular/prostatic venous plexus. Lymphatic vessels from the ductus deferens end in the *external iliac lymph nodes* (Fig. 3.25; Table 3.6).

Male Sterilization

The common method of male sterilization is a **deferentectomy**, popularly called a *vasectomy*. During this procedure, part of the ductus deferens is ligated and/or excised through an incision in the superior part of the scrotum (Fig. B3.8). Hence, the subsequent ejaculated fluid from the seminal glands, prostate, and bulbourethral glands contains no sperms. The unexpelled sperms degenerate in the epididymis and the proximal part of the ductus deferens. *Reversal of a deferentectomy* is successful in favorable cases (patients < 30 years of age and ▶

< 7 years postoperation) in most instances. The ends of the sectioned ductus deferentes are reattached under an operating microscope. ❖

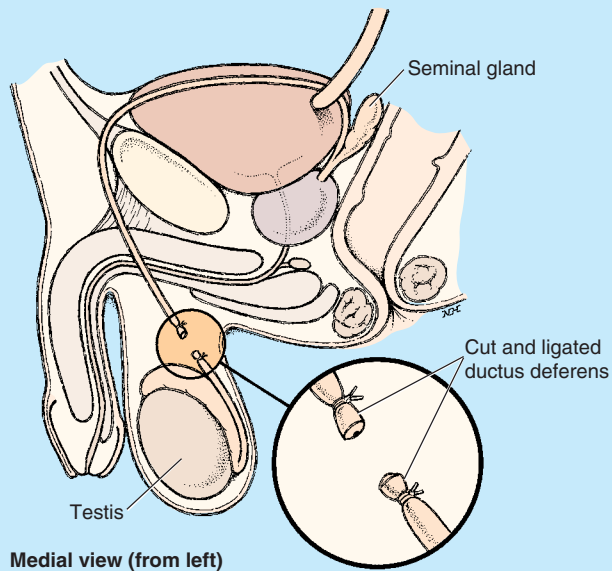


Figure B3.8

THE BOTTOM LINE: The cord-like ductus deferens is the primary component of the spermatic cord, conducting sperms from the epididymis to the ejaculatory duct. Its distal portion is superficial within the scrotum (and, therefore, easily accessible for deferentectomy) before it penetrates the anterior abdominal wall via the inguinal canal. Its pelvic portion lies immediately external to the peritoneum, with its terminal portion enlarging externally as its lumen becomes tortuous internally, forming the ampulla of the ductus deferens.

Seminal Glands

Each seminal gland (vesicle) is an elongated structure (typically approximately 5 cm long but sometimes much shorter) that lies between the fundus of the bladder and the rectum (Figs. 3.21 and 3.23). The seminal glands are obliquely placed glands superior to the prostate and do not store sperms, as their name implies. They secrete a thick alkaline fluid with fructose (an energy source for the sperms) and a coagulating agent that mixes with the sperms as they pass into the ejaculatory ducts and urethra. The superior ends of the seminal glands are covered with peritoneum and lie posterior to the ureters, where the peritoneum of the *rectovesical pouch* separates them from the rectum. The inferior ends of the seminal glands are closely related to the rectum and are separated from it only by the *rectovesical septum* (Fig. 3.23). The duct of the seminal gland joins the ductus deferens to form the *ejaculatory duct*.

Arterial Supply of the Seminal Glands. The arteries to the seminal glands derive from the *inferior vesical* and *middle rectal arteries* (Fig. 3.22; Table 3.5).

Venous and Lymphatic Drainage of the Seminal Glands. The veins accompany the arteries and have similar names (Fig. 3.13C). The iliac lymph nodes receive lymph from the seminal glands: the *external iliac nodes* from the superior part, and the *internal iliac nodes* from the inferior part (Fig. 3.25; Table 3.6).

Abscesses in the Seminal Glands

Localized collections of pus (abscesses) in the seminal glands may rupture, allowing pus to enter the peritoneal cavity. Seminal glands can be palpated during a rectal examination, especially if enlarged or full. They are palpated most easily when the bladder is moderately full. They can also be massaged to release their secretions for microscopic examination to detect *gonococci*, for example (the organisms that cause gonorrhea). ❖

Ejaculatory Ducts

The ejaculatory ducts are slender tubes that arise by the union of the ducts of a seminal glands with the ductus deferentes (Figs. 3.21–3.23). The ejaculatory ducts (approximately 2.5 cm long) arise near the neck of the bladder and run close together as they pass anteroinferiorly through the posterior part of the prostate and along the sides of the prostatic utricle. The ejaculatory ducts converge to open on the seminal colliculus by tiny, slit-like apertures on, or just within, the opening of the prostatic utricle (Fig. 3.19). Although the ejaculatory ducts traverse the glandular prostate, prostatic secretions join the seminal fluid in the prostatic urethra after the ejaculatory ducts have terminated.

Arterial Supply of the Ejaculatory Ducts. The arteries to the ductus deferens, usually branches of the superior (but frequently inferior) vesical arteries, supply the ejaculatory ducts (Figs. 3.22–3.23).

Venous and Lymphatic Drainage of the Ejaculatory Ducts. The veins join the *prostatic* and *vesical venous plexuses* (Fig. 3.13C). The lymphatic vessels drain into the *external iliac lymph nodes* (Fig. 3.25).

Prostate

The prostate (approximately 3 cm long, 4 cm wide, and 2 cm in AP depth) is the largest accessory gland of the male reproductive system (Figs. 3.19 and 3.21–3.23). The glandular part makes up approximately two thirds of the prostate; the other third is fibromuscular. The firm, walnut-size prostate surrounds the *prostatic urethra*. The **fibrous capsule of the prostate** is dense and neurovascular, incorporating the prostatic plexuses of veins and nerves. All this is surrounded in turn by the *visceral layer of the pelvic fascia*, forming a fibrous *prostatic sheath* that is thin anteriorly, continuous anterolaterally with the *puboprostatic ligaments*, and

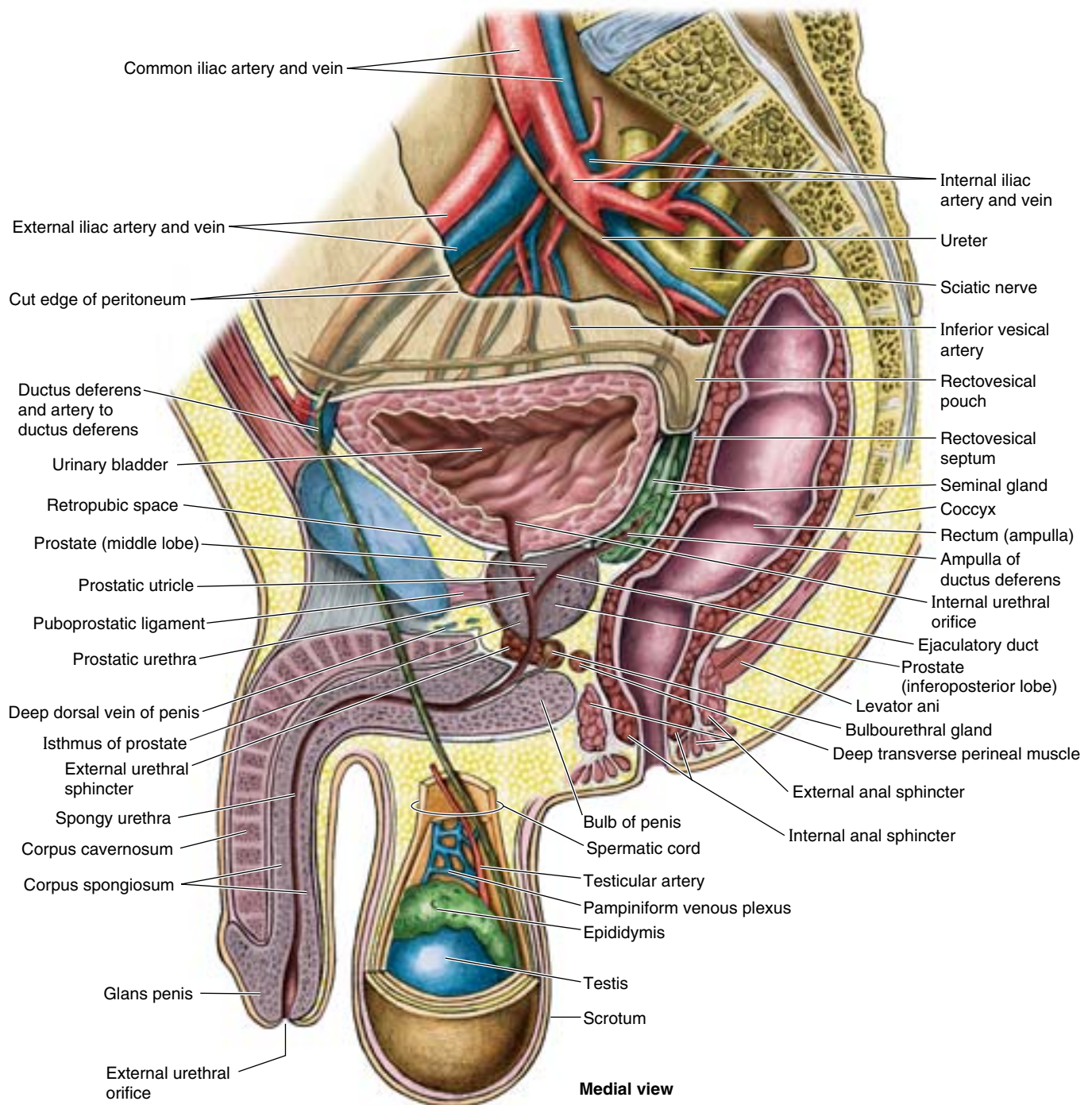


Figure 3.23. Hemisected male pelvis and perineum (right half). The genital organs are demonstrated: testis, epididymis, ductus deferens, ejaculatory duct, and penis, with the accessory glandular structures (seminal gland, prostate, and bulbourethral gland). The spermatic cord connects the testis to the abdominal cavity, and the testis lies externally in a musculo-cutaneous pouch, the scrotum.

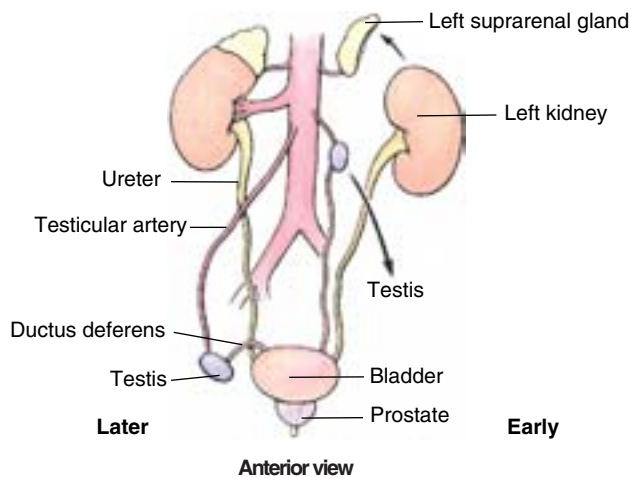
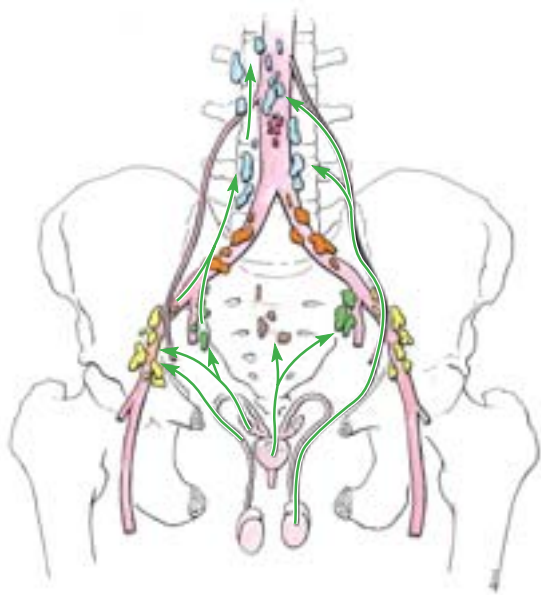


Figure 3.24. Structures crossing male ureter in abdomen and pelvis. During development, as the testis descends inferiorly and laterally from its original position (medial to the site of the kidneys on the posterior abdominal wall) to and then through the inguinal canal, the ureter is crossed by testicular vessels in the abdomen and by the ductus deferens in the pelvis. This relationship is retained throughout life.



Key		
■ Lumbar (caval/aortic)	■ Internal iliac	■ Sacral
■ Inferior mesenteric	■ External iliac	■ Pararectal
■ Common iliac		

Figure 3.25 Lymphatic drainage of male internal genital organs. Lymphatic drainage of the testis, ductus deferens, seminal glands, and prostate is shown. The arrows indicate the direction of lymph flow to the lymph nodes.

dense posteriorly where it blends with the *rectovesical septum*. The prostate has

- A base closely related to the neck of the bladder.
- An apex that is in contact with fascia on the superior aspect of the urethral sphincter and deep perineal muscles.
- A muscular anterior surface, featuring mostly transversely oriented muscle fibers forming a vertical, trough-like hemisphincter (rhabdosphincter), which is part of the urethral sphincter, separated from the pubic symphysis by retroperitoneal fat in the retropubic space.
- A posterior surface that is related to the ampulla of the rectum.
- Inferolateral surfaces that are related to the levator ani.

Although not clearly distinct anatomically, the following lobes of the prostate are traditionally described (Figs. 3.21 and 3.23):

- The **isthmus of the prostate** (commissure of prostate; historically, the anterior “lobe”) lies anterior to the urethra. It is fibromuscular, the muscle fibers representing a superior continuation of the urethral sphincter muscle, and contains little, if any, glandular tissue.
- The **inferoposterior** (posterior) **lobe** lies posterior to the urethra and inferior to the ejaculatory ducts; it is readily palpable by digital rectal examination.
- The **right and left** (lateral) **lobes** on either side of the urethra form the major part of the prostate.
- The **middle** (median) **lobe** lies between the urethra and the ejaculatory ducts and is closely related to the neck of the bladder. Enlargement of the middle lobe is believed to be at least partially responsible for the formation of the *wvula* that may project into the internal urethral orifice (Fig. 3.20).

Some authors, especially urologists and sonographers, divide the prostate into peripheral and central (internal) zones. The central zone is comparable to the middle lobe. Within each lobe are four lobules, which are defined by the arrangement of the ducts and connective tissue.

The **prostatic ducts** (20–30) open chiefly into the grooves, the *prostatic sinuses*, that lie on either side of the seminal colliculus on the posterior wall of the prostatic urethra. Prostatic fluid, a thin, milky fluid, provides approximately 20% of the volume of semen (a mixture of secretions produced by the testes, seminal glands, prostate, and bulbourethral glands) and plays a role in activating the sperms.

Arterial Supply of the Prostate. The prostatic arteries are mainly branches of the internal iliac artery (Fig. 3.11A & C; Table 3.5), especially the *inferior vesical arteries* but also the internal pudendal and middle rectal arteries.

Venous and Lymphatic Drainage of the Prostate. The veins join to form a plexus around the sides and base of the prostate (Figs. 3.13C and 3.22). This **prostatic venous**

plexus, between the fibrous capsule of the prostate and the prostatic sheath, drains into the *internal iliac veins*. The prostatic venous plexus is continuous superiorly with the *vesical venous plexus* and communicates posteriorly with the *internal vertebral venous plexus*. The lymphatic vessels terminate chiefly in the *internal iliac lymph nodes*, but some drainage may pass to the *sacral nodes* (Fig. 3.25; Table 3.6).

Bulbourethral Glands

The two pea-size **bulbourethral glands** (Cowper glands) lie posterolateral to the intermediate part of the urethra, largely embedded within the external urethral sphincter (Figs. 3.20B and 3.22–3.23). The **ducts of the bulbourethral glands** pass through the perineal membrane with the intermediate urethra and open through minute apertures into the proximal part of the spongy urethra in the bulb of the penis. Their mucus-like secretion enters the urethra during sexual arousal.

Innervation of the Internal Genital Organs of the Male Pelvis

The ductus deferens, seminal glands, ejaculatory ducts, and prostate are richly innervated by sympathetic nerve

fibers. Presynaptic sympathetic fibers originate from cell bodies in the intermediolateral cell column of the T12–L2 (or L3) spinal cord segments. They traverse the paravertebral ganglia of the sympathetic trunks to become components of lumbar (abdominopelvic) splanchnic nerves and the hypogastric and pelvic plexuses. Presynaptic parasympathetic fibers from S2 and S3 spinal cord segments traverse *pelvic splanchnic nerves*, which also join the inferior hypo-gastric/pelvic plexuses. Synapses with postsynaptic sympathetic and parasympathetic neurons occur within the plexuses, en route to or near the pelvic viscera. As part of an orgasm, the sympathetic system stimulates rapid peristaltic-like contractions of the ductus deferens, and the combined contraction of and secretion from the seminal and prostate glands provides the vehicle (semen) and the expulsive force to discharge the sperms (*L. spermatozoa*) during ejaculation. The function of the parasympathetic innervation of the internal genital organs is unclear. However, parasympathetic fibers traversing the prostatic nerve plexus form the *cavernous nerves* that pass to the erectile bodies of the penis, which are responsible for producing penile erection.

Hypertrophy of the Prostate

The prostate is of considerable medical interest because enlargement or **benign hypertrophy of the prostate (BHP)**, is common after middle age, affecting virtually every male who lives long enough. An enlarged prostate projects into the urinary bladder and impedes urination by distorting the prostatic urethra. The middle lobe usually enlarges the most and obstructs the internal urethral orifice; the more the person strains, the more the valve-like prostatic mass occludes the urethra. BHP is a common cause of urethral obstruction, leading to **nocturia** (need to void during the night), **dysuria** (difficulty and/or pain during urination), and **urgency** (sudden desire to void). BHP also increases the risk of bladder infections (cystitis) as well as kidney damage.

The prostate is examined for enlargement and tumors (focal masses or asymmetry) by *digital rectal examination* (Fig. B3.9). The palpability of the prostate depends on the fullness of the bladder. A full bladder offers resistance, holding the gland in place and making it more readily palpable. The malignant prostate feels hard and often irregular. In advanced stages, cancer cells metastasize both via lymphatic routes (initially to the internal iliac and sacral lymph nodes and later to distant nodes) and via venous routes (by way of the internal vertebral venous plexus, to the vertebrae and brain).

Because of the close relationship of the prostate to the prostatic urethra, obstructions may be relieved endoscopically. The instrument is inserted transurethrally through the external urethral orifice and spongy urethra into the prostatic urethra. All or part of the prostate, or just

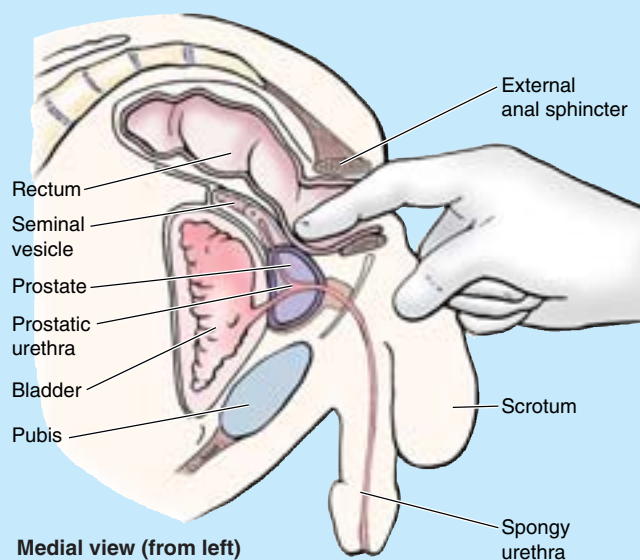


Figure B3.9

the hypertrophied part, is removed (*transurethral resection of the prostate; TURP*). In more serious cases, the entire prostate is removed along with the seminal glands, ejaculatory ducts, and the terminal parts of the deferent ducts (**radical prostatectomy**). TURP and improved open operative techniques attempt to preserve the nerves and blood vessels associated with the capsule of the prostate that pass to and from the penis, increasing the possibility for patients to retain sexual function after surgery as well as restoring normal urinary control. +

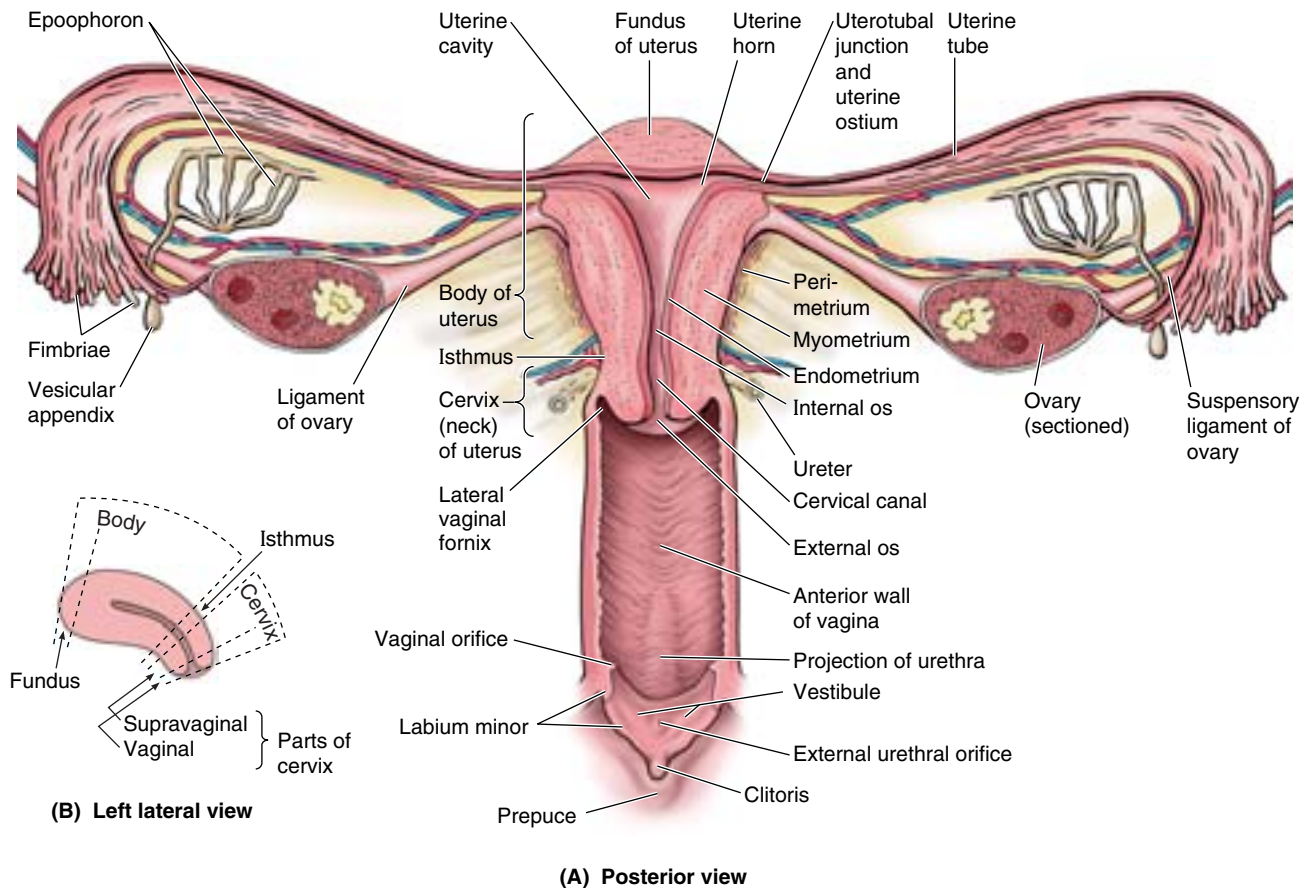


Figure 3.26. Internal female genital organs. A. In this coronal section, the parts of the uterus are demonstrated, including the uterine walls, cervix, and uterine cavity. The uterine tube and ovarian ligament are attached, close together, to the lateral wall of the uterus. The epoophoron is a collection of rudimentary tubules in the mesosalpinx (mesentery of uterine tube). The epoophoron and vesicular appendage are vestiges of the embryonic mesonephros. **B.** This median section of the uterus demonstrates the parts of the body and cervix, which are separated by the isthmus.

THE BOTTOM LINE: Obliquely placed seminal glands converge at the base of the bladder, where each gland merges with the ipsilateral ductus deferens to form an ejaculatory duct. The two ejaculatory ducts immediately enter the posterior aspect of the prostate, running closely parallel through the gland to open on the seminal colliculus. Prostatic ducts open into prostatic sinuses, adjacent to the seminal colliculus. Thus the major secretions and sperms are delivered to the prostatic urethra. The seminal glands and prostate produce by far the greatest portion of the seminal fluid, indispensable for transport and delivery of sperms. These internal genital organs, located within the anterior male pelvis, receive blood from the inferior vesicle and middle rectal arteries, which drain into the continuous prostatic/vesicle venous plexus. Their lymphatic vessels drain to internal and external iliac nodes. Sympathetic fibers from lumbar levels stimulate the contraction and secretion resulting in ejaculation. The function of parasympathetic fibers from S2–S4 to the in-

ternal genital organs is unclear, but those traversing the prostatic nerve plexus to form the cavernous nerves produce erection.

Female Internal Genital Organs

The female internal genital organs include the vagina, uterus, uterine tubes, and ovaries.

Vagina

The **vagina**, a musculomembranous tube (7–9 cm long), extends from the cervix of the uterus to the *vestibule*, the cleft between the labia minora. It contains the vaginal and external urethral orifices and the openings of the two greater vestibular glands (Figs. 3.26 and 3.27A–C). The superior end of the vagina surrounds the cervix.

The vagina:

- Serves as a canal for menstrual fluid.
- Forms the inferior part of the pelvic (birth) canal.

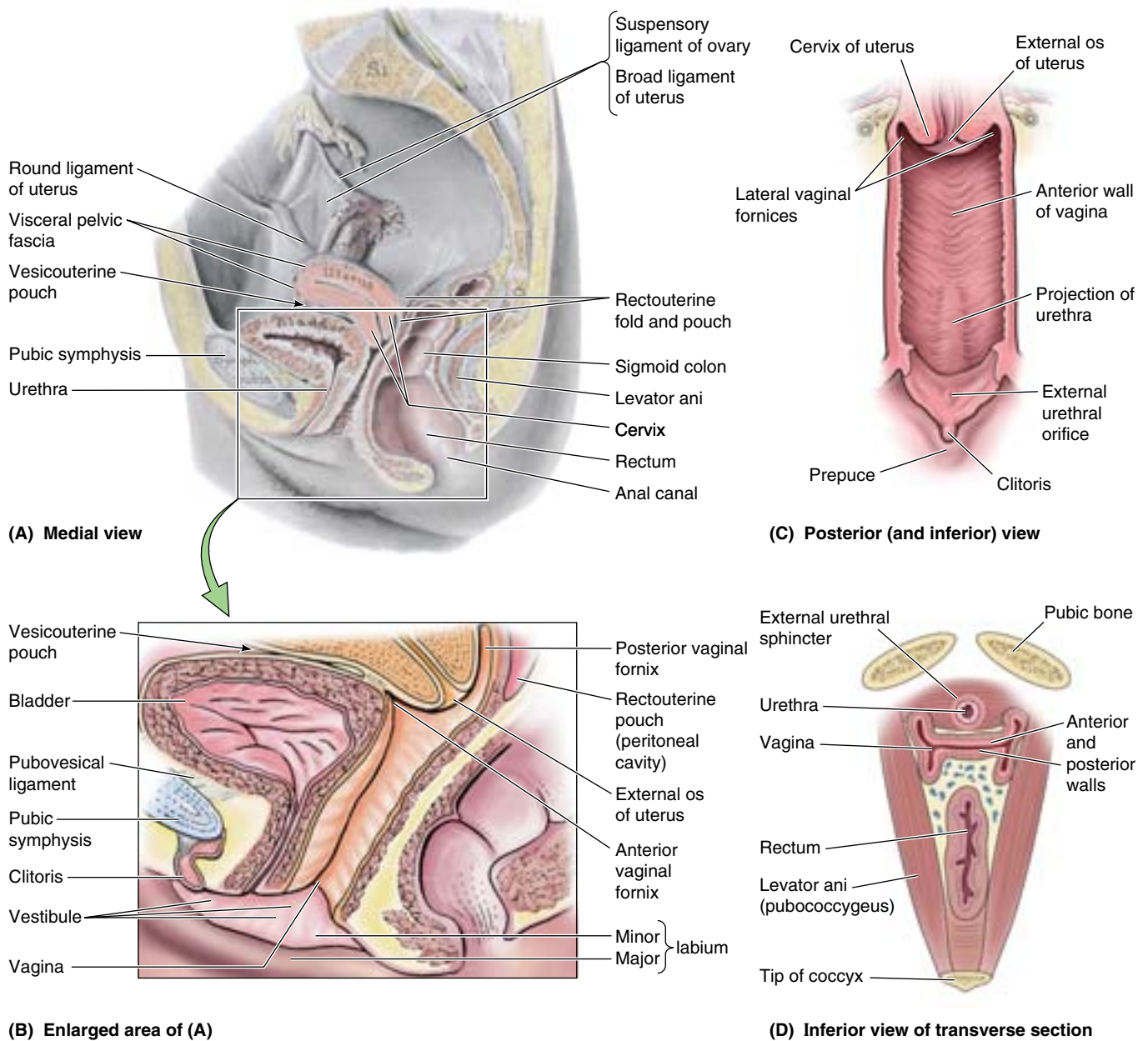


Figure 3.27. Vagina. A and B. The axes of the urethra and vagina are parallel, and the urethra is adherent to the anterior vaginal wall. Placing a finger in the vagina can help direct the insertion of a catheter through the urethra into the bladder. **C.** This view of the anterior wall of the vagina demonstrates the projection of the cervix (superiorly) and urethra (inferior and anteriorly) into the vagina. **D.** A transverse section through the inferior female pelvic organs as they penetrate the pelvic floor through the urogenital hiatus (the gap between the right and the left sides of the levator ani) demonstrates the disposition of the non-distended lumina.

- Receives the penis and ejaculate during sexual intercourse.
- Communicates superiorly with the **cervical canal** (a fusiform canal extending from the isthmus of the uterus to the external os of the uterus) and inferiorly with the vestibule.

The vagina is usually collapsed (H-shaped in cross section) so that its anterior and posterior walls are in contact (Fig. 3.27D), except at its superior end where the cervix holds

them apart. The vagina lies posterior to the urethra, which projects into its inferior anterior wall, and urinary bladder, and it lies anterior to the rectum, passing between the medial margins of the levator ani muscles. The **vaginal fornix**, the recess around the cervix, has *anterior*, *posterior*, and *lateral parts* (Figs. 3.26A and 3.27B). The **posterior vaginal fornix** is the deepest part and is closely related to the rectouterine pouch. Four muscles compress the vagina and act as sphincters: **pubovaginalis**, **external urethral sphinc-**

ter, **urethrovaginal sphincter**, and **bulbospongiosus** (Fig. 3.28). The relations of the vagina are (Fig. 3.27) as follows:

- Anteriorly: the fundus of the urinary bladder and urethra.
- Laterally: the levator ani, visceral pelvic fascia, and ureters.
- Posteriorly (inferior to superior): the anal canal, rectum, and rectouterine pouch.

Arterial Supply of the Vagina

The arteries supplying the superior part of the vagina derive from the *uterine arteries*; the arteries supplying the middle and inferior parts of the vagina derive from the *vaginal* and *internal pudendal arteries* (Figs. 3.12 and 3.29).

Venous and Lymphatic Drainage of the Vagina

The vaginal veins form **vaginal venous plexuses** along the sides of the vagina and within the vaginal mucosa (Fig. 3.29). These veins are continuous with the *uterine venous plexus* as the **uterovaginal venous plexus** and drain into the internal iliac veins through the uterine vein. This plexus also communicates with the vesical and rectal venous plexuses.

The vaginal lymphatic vessels drain from the parts of the vagina as follows (Fig. 3.30; Table 3.6):

- Superior part: to the internal and external iliac lymph nodes.
- Middle part: to the internal iliac lymph nodes.

- Inferior part: to the sacral and common iliac nodes.
- External orifice: to the superficial inguinal lymph nodes.

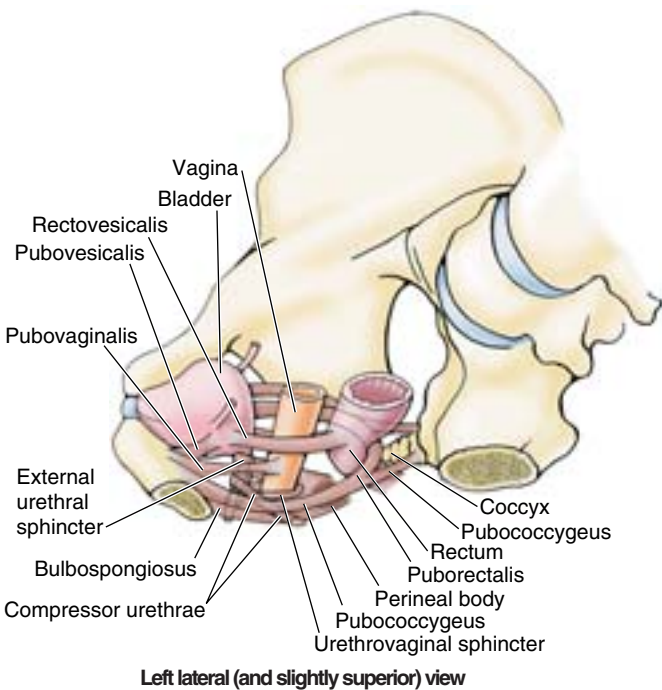


Figure 3.28. Muscles compressing urethra and vagina. Muscles that compress the vagina and act as sphincters include the pubovaginalis, external urethral sphincter (especially its urethrovaginal sphincter part), and bulbospongiosus. The compressor urethrae and external urethral sphincter compress the urethra.

Distension of the Vagina

The vagina can be markedly distended, particularly in the region of the posterior part of the fornix. For example, distension of this part allows palpation of the sacral promontory during a pelvic examination (see clinical correlation [blue] box “Pelvic Diameters (Conjugates),” in this chapter) and accommodates the erect penis during intercourse. The vagina is especially distended by the fetus during parturition, particularly in an AP direction when the fetus’s shoulders are delivered. Lateral distension is limited by the ischial spines, which project posteromedially, and the sacrospinous ligaments extending from these spines to the lateral margins of the sacrum and coccyx. The birth canal is thus deep anteroposteriorly and narrow transversely at this point, causing the fetus’s shoulders to rotate into the AP plane (Fig. B3.10). ▶

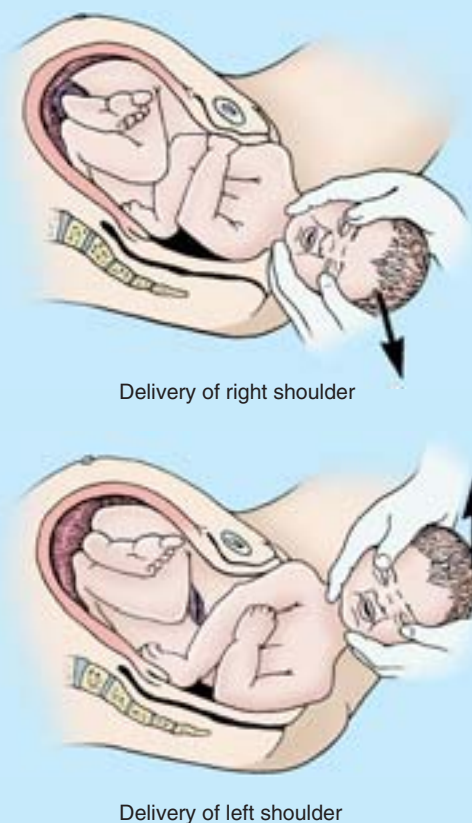


Figure B3.10

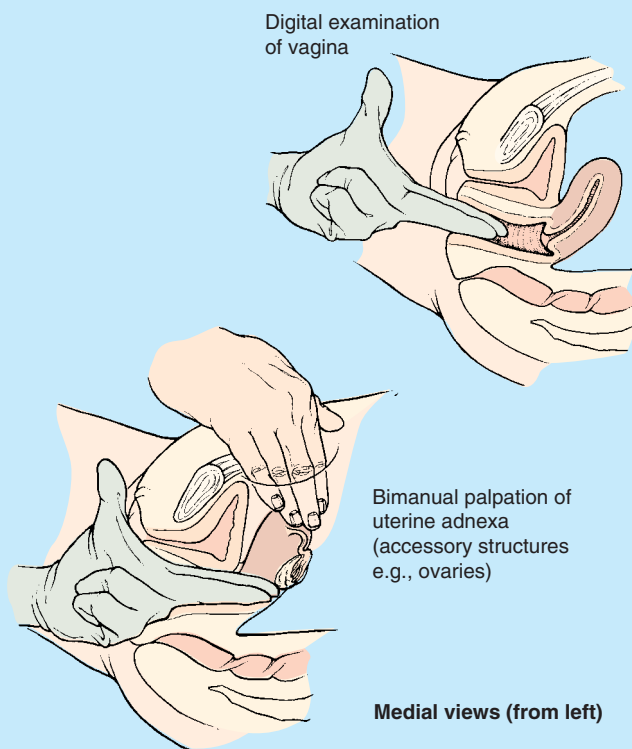


Figure B3.11

Digital Examination through the Vagina

Because of its relatively thin, distensible walls and central location within the pelvis, the cervix, ischial spines, and sacral promontory can be palpated with the digits in the

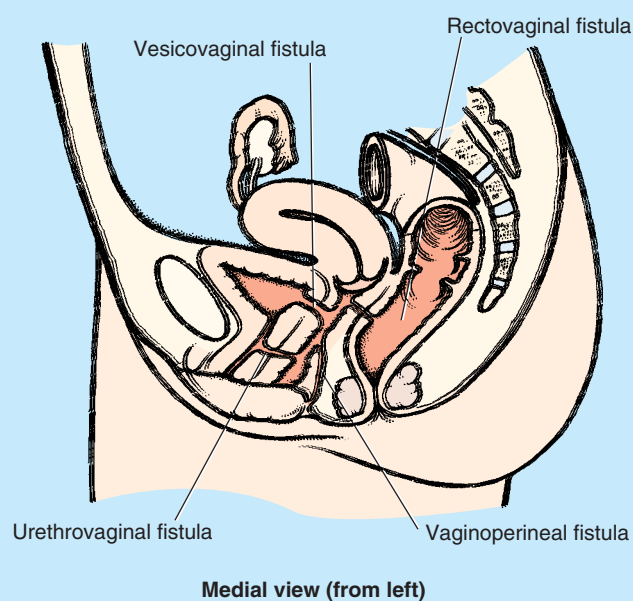


Figure B3.12

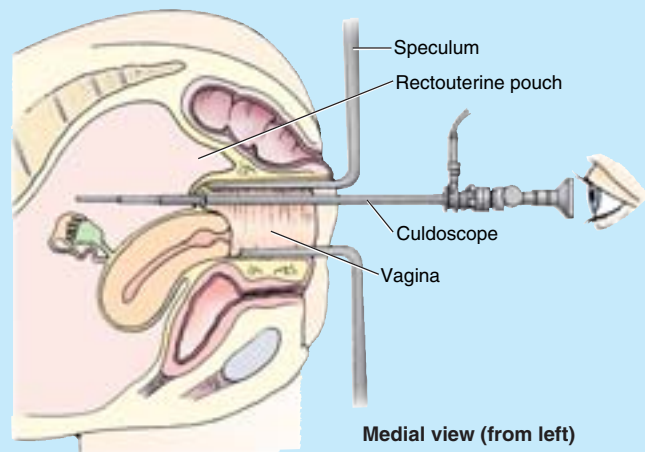


Figure B3.13

vagina and/or rectum (**manual pelvic examination**). Pulsations of the uterine arteries may also be felt through the lateral parts of the fornix, as may irregularities of the ovaries, such as cysts (Fig. B3.11).

Vaginal Fistulae

Because of the close relationship of the vagina to adjacent pelvic organs, obstetrical trauma during long and difficult labor may result in weaknesses, necrosis, or tears in the vaginal wall and sometimes beyond. These may form or subsequently develop into open communications (**fistulas**) between the vaginal lumen and that of the adjacent bladder, urethra, rectum, or perineum (Fig. B3.12). Urine enters the vagina from both *vesicovaginal* and *urethrovaginal fistulas*; but the flow is continuous from the former and occurs only during micturition from the latter. Fecal matter may be discharged from the vagina when there is a *rectovaginal fistula*.

Culdoscopy and Culdocentesis

An endoscopic instrument (*culdoscope*) can be inserted through the posterior part of the vaginal fornix (Fig. B3.13) to examine the ovaries or uterine tubes (e.g., for the presence of a tubal pregnancy). Because it involves less disruption of tissue, *culdoscopy* has been largely replaced by *laparoscopy*, which, however, provides greater flexibility for operative procedures and better visualization of pelvic organs (see clinical correlation [blue] box “Laparoscopic Examination of Pelvic Viscera,” in this chapter). There is also less risk of bacterial contamination of the peritoneal cavity. A pelvic abscess in the rectouterine pouch can be drained through an incision made in the posterior part of the vaginal fornix (*culdocentesis*). Similarly, fluid in the peritoneal cavity (e.g., blood) can be aspirated by this technique. ⚠

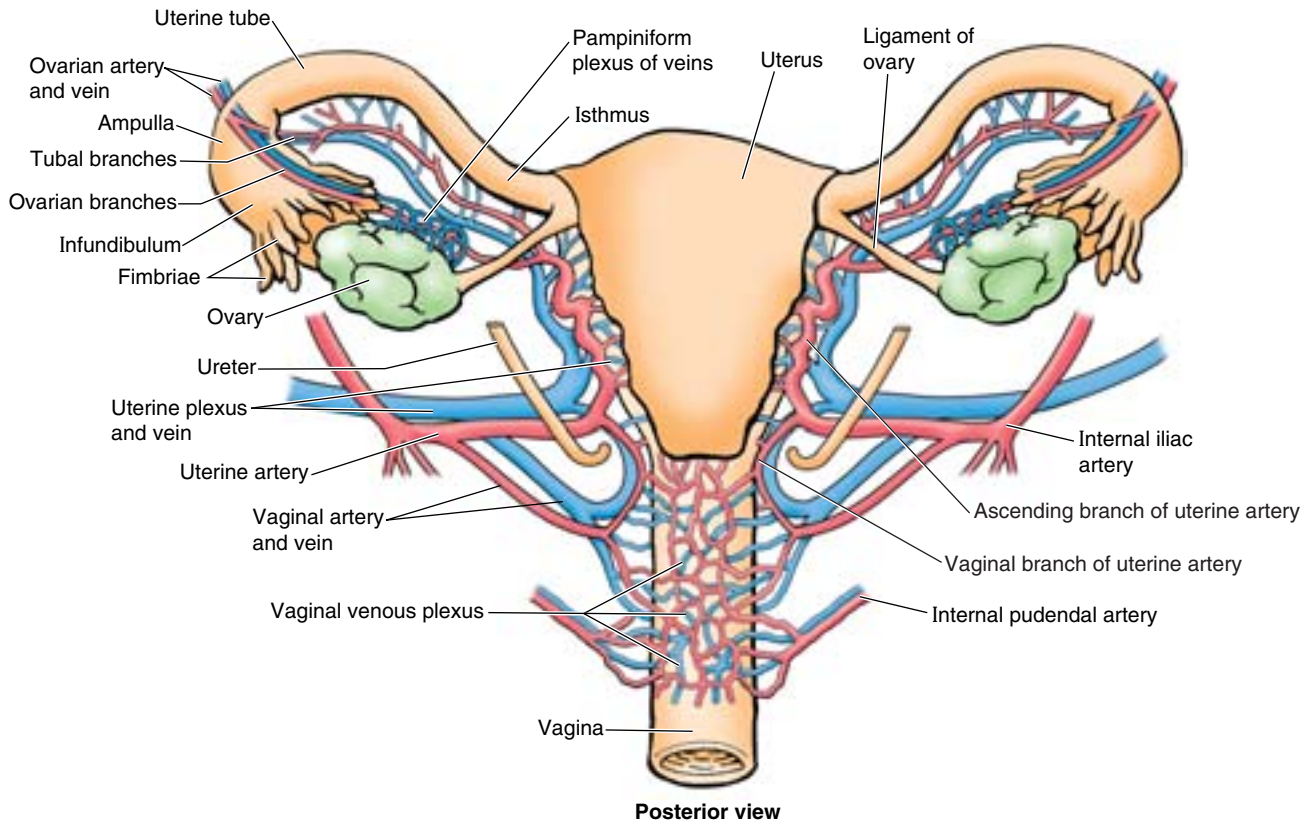
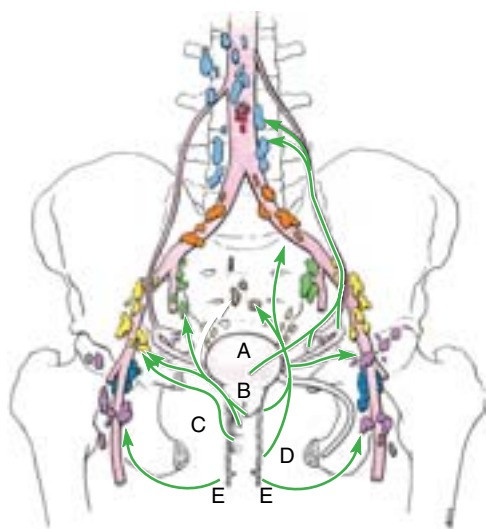


Figure 3.29. Blood supply and venous drainage of uterus, vagina, and ovaries. The broad ligament of the uterus is removed to show the anastomosing branches of the ovarian artery from the aorta and the uterine artery from the internal iliac artery supplying the ovary, uterine tube, and uterus. The veins follow a similar pattern, flowing retrograde to the arteries, but are more plexiform, including a pampiniform plexus related to the ovary and continuous uterine and vaginal plexuses (collectively, the uterovaginal plexus).



- A = Body and fundus of uterus, uterine tubes and ovaries
- B = Cervix of uterus and vaginal fornices
- C = Middle part of vagina
- D = Inferior part of vagina
- E = Vestibule of vagina

Key		
■ Lumbar (caval/aortic)	■ Internal iliac	■ Deep inguinal
■ Inferior mesenteric	■ External iliac	■ Sacral
■ Common iliac	■ Superficial inguinal	■ Pararectal

Lymphatic drainage

Figure 3.30. Lymphatic drainage of female internal genital organs. The arrows indicate the direction of lymph flow to the lymph nodes.

THE BOTTOM LINE: The vagina is a musculomembranous passage connecting the uterine cavity to the exterior, allowing the entrance/insertion of the penis, ejaculate, tampons, or examining digits and the exit of a fetus or menstrual fluid. The vagina lies between and is closely related to the urethra anteriorly and rectum posteriorly but is separated from the latter by the peritoneal rectouterine pouch superiorly and the fascial rectovaginal septum inferiorly. It is indented (invaginated) anterosuperiorly by the uterine cervix so that an encircling pocket or vaginal fornix is formed around it. Most of the vagina is located within the pelvis, receiving blood via pelvic branches of the internal iliac artery (uterine and vaginal arteries) and draining directly into the uterovaginal venous plexus and, via deep (pelvic) routes, to the internal and external iliac and sacral lymph nodes. The inferiormost part of the vagina is located within the perineum, receiving blood from the internal pudendal artery and draining via superficial (perineal) routes into superficial inguinal nodes. The vagina is capable of remarkable distension, enabling manual examination (palpation) of pelvic landmarks and viscera (especially the ovaries) as well as of pathology (e.g., ovarian cysts).

Uterus

The **uterus** (womb) is a thick-walled, pear-shaped, hollow muscular organ. The embryo and fetus develop in the uterus, its muscular walls adapting to the growth of the fetus and then providing the power for its expulsion during childbirth. The non-gravid (non-pregnant) uterus usually lies in the lesser pelvis, with its body lying on the urinary bladder and its cervix between the urinary bladder and the rectum (Figs. 3.27A & B and 3.31A). The adult uterus is usually *anteverted* (tipped anterosuperiorly relative to the axis of the vagina) and *anteflexed* (flexed or bent anteriorly relative to the cervix) so that its mass lies over the bladder. The position of the uterus changes with the degree of fullness of the bladder and rectum. Although its size varies considerably, the uterus is approximately 7.5 cm long, 5 cm wide, and 2 cm thick and weighs approximately 90 g. The uterus is divisible into two main parts (Fig. 3.26): the body and cervix.

The **body of the uterus**, forming the superior two thirds of the organ, includes the **fundus of the uterus**, the rounded part that lies superior to the orifices of the uterine tubes. The body lies between the layers of the broad ligament and is freely movable (Fig. 3.31B). It has two surfaces: vesical (related to the bladder) and intestinal. The body is demarcated from the cervix by the **isthmus of the uterus**, a relatively constricted segment, approximately 1 cm long (Figs. 3.26 and 3.31B).

The **cervix of the uterus** is the cylindrical, relatively narrow inferior third of the uterus, approximately 2.5 cm long in an adult non-pregnant woman. For descriptive purposes, two parts are described: a *supravaginal part* between the isthmus and the vagina, and a *vaginal part*, which protrudes into the vagina. The rounded vaginal part sur-

rounds the *external os of the uterus* and is surrounded in turn by a narrow space, the *vaginal fornix* (Fig. 3.27). The supravaginal part is separated from the bladder anteriorly by loose connective tissue and from the rectum posteriorly by the *rectouterine pouch*.

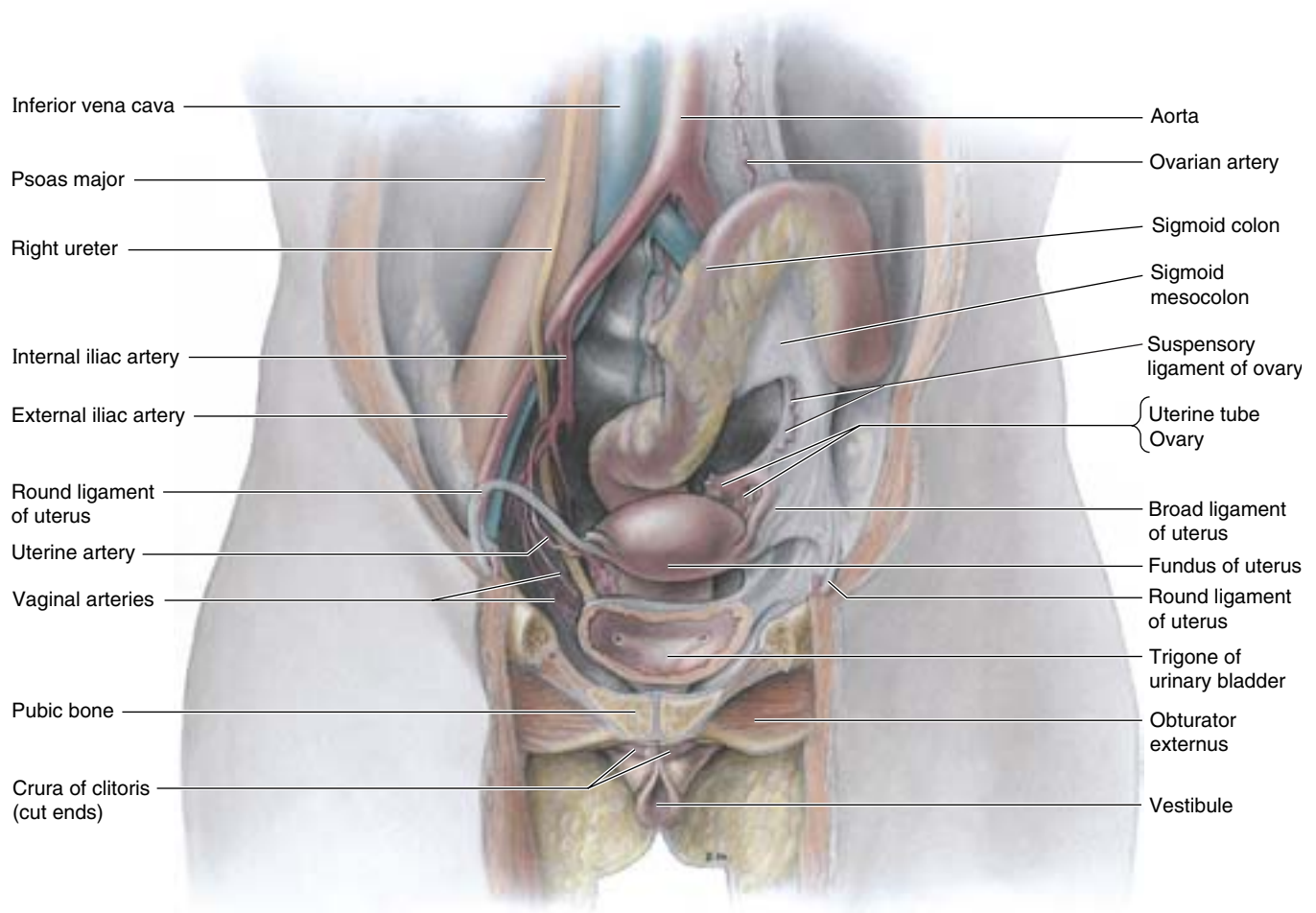
The slit-like uterine cavity is approximately 6 cm in length from the external os to the wall of the fundus. The uterine horns (*L. cornua*) are the superolateral regions of the uterine cavity, where the uterine tubes enter (Fig. 3.26A). Incomplete fusion of the embryonic paramesonephric ducts from which the uterus is formed results in a variety of congenital anomalies (e.g., double or bicornate uterus; see “Medical Imaging of the Pelvis and Perineum,” in this chapter). The uterine cavity continues inferiorly as the fusiform *cervical canal*. The canal extends from a narrowing inside the isthmus of the uterine body, the **anatomical internal os**, through the supravaginal and vaginal parts of the cervix, communicating with the lumen of the vagina through the external os (Figs. 3.26 and 3.31B). The uterine cavity (in particular, the cervical canal) and the lumen of the vagina together constitute the birth canal through which the fetus passes at the end of gestation.

The wall of the body of the uterus consists of three coats, or layers (Fig. 3.26):

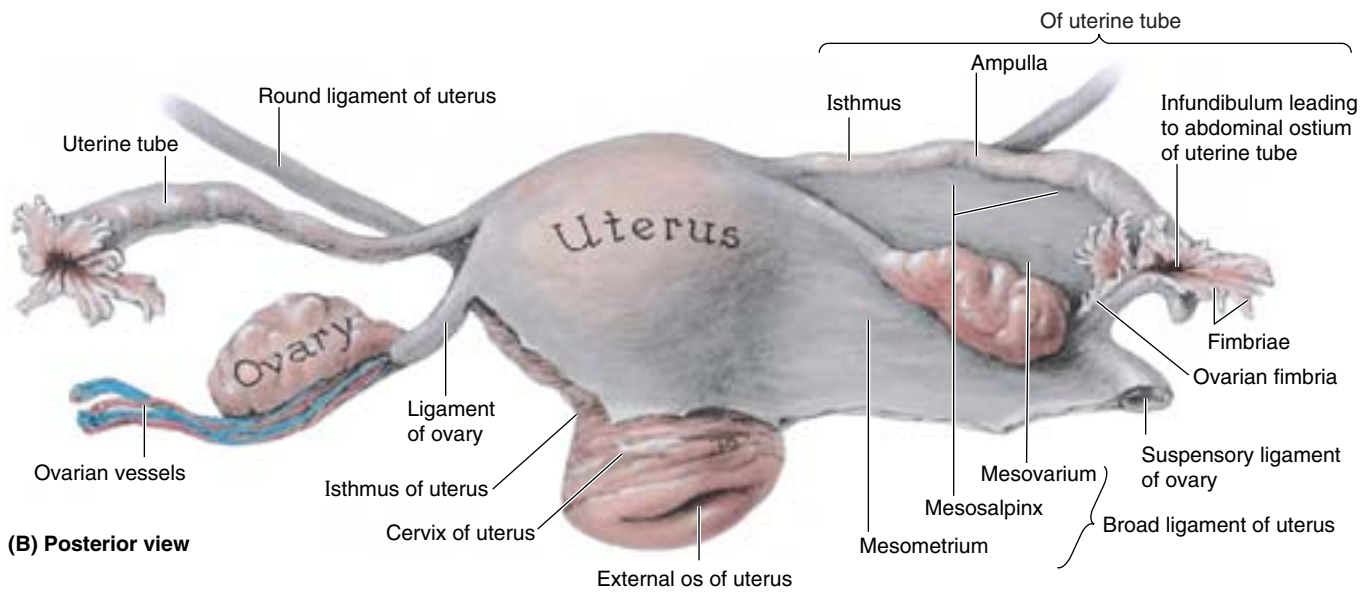
- **Perimetrium**—the serosa or outer serous coat—consists of peritoneum supported by a thin layer of connective tissue.
- **Myometrium**—the middle coat of smooth muscle—becomes greatly distended (more extensive but much thinner) during pregnancy. The main branches of the blood vessels and nerves of the uterus are located in this coat. During childbirth, contraction of the myometrium is hormonally stimulated at intervals of decreasing length to dilate the cervical os and expel the fetus and placenta. During the menses, myometrial contraction may produce cramping.
- **Endometrium**—the inner mucous coat—is firmly adhered to the underlying myometrium. The endometrium is actively involved in the menstrual cycle, differing in structure with each stage of the cycle. If conception occurs, the blastocyst becomes implanted in this layer; if conception does not occur, the inner surface of this coat is shed through menstruation.

The amount of muscular tissue in the cervix is markedly less than in the body of the uterus. The cervix is mostly fibrous and is composed mainly of collagen with a small amount of smooth muscle and elastin.

Ligaments of the Uterus. Externally, the **ligament of the ovary** attaches to the uterus posteroinferior to the uterotubal junction (Figs. 3.26 and 3.31B). The **round ligament of the uterus** (*L. ligamentum teres uteri*) attaches anteroinferiorly to this junction (Fig. 3.31A & B). These two ligaments are vestiges of the *ovarian gubernaculum*, related to the descent of the gonad from its developmental position on the posterior abdominal wall (see Chapter 2).



(A) Anterior view



(B) Posterior view

Figure 3.31. Female pelvic viscera. A. In this dissection of the female genital organs, the bladder and adjacent anterior pelvis (superior ramus and bodies of pubic bones) have been coronally sectioned and the anterior segment has been removed. On the right side, the uterine tube, ovary, broad ligament, and peritoneum covering the lateral wall of the pelvis have been removed to display the ureter and branches of the internal iliac artery. **B.** This dissection reveals the uterus, ovaries, uterine tubes, and related structures. The broad ligament is removed on the right side.

The **broad ligament of the uterus** is a double layer of peritoneum (mesentery) that extends from the sides of the uterus to the lateral walls and floor of the pelvis. This ligament assists in keeping the uterus in position. The two layers of the broad ligament are continuous with each other at a free edge that surrounds the uterine tube. Laterally, the peritoneum of the broad ligament is prolonged superiorly over the vessels as the **suspensory ligament of the ovary**. Between the layers of the broad ligament on each side of the uterus, the ligament of the ovary lies posterosuperiorly and the round ligament of the uterus lies anteroinferiorly. The uterine tube lies in the anterosuperior free border of the broad ligament, within a small mesentery called the **mesosalpinx**. Similarly, the ovary lies within a small mesentery called the **mesovarium** on the posterior aspect of the broad ligament. The largest part of the broad ligament, inferior to the mesosalpinx and mesovarium, which serves as a mesentery for the uterus itself, is the mesometrium.

The uterus is a dense structure located in the center of the pelvic cavity. The principal supports of the uterus holding it in this position are both passive and active or dynamic. Dynamic support of the uterus is provided by the pelvic diaphragm. Its tone during sitting and standing and active contraction during periods of increased intra-abdominal pressure (sneezing, coughing, etc.) is transmitted through the surrounding pelvic organs and the endopelvic fascia in which they are embedded. Passive support of the uterus is provided by its position—the way in which the normally *anteverted* and *anteflexed* uterus rests on top of the bladder. When intra-abdominal pressure is increased, the uterus is pressed against the bladder. The cervix is the least mobile part of the uterus because of the passive support provided by attached condensations of endopelvic fascia (ligaments), which may also contain smooth muscle (Fig. 3.9B):

- *Transverse cervical* (cardinal) *ligaments* extend from the cervix and lateral parts of the fornix of the vagina to the lateral walls of the pelvis.
- *Uterosacral ligaments* pass superiorly and slightly posteriorly from the sides of the cervix to the middle of the sacrum; they are palpable during a rectal examination.

Together these passive and active supports keep the uterus centered in the pelvic cavity and resist the tendency for the uterus to fall or be pushed through the vagina (see clinical correlation [blue] box “Disposition of the Uterus and Uterine Prolapse,” in this chapter).

Relations of the Uterus. Peritoneum covers the uterus anteriorly and superiorly (Figs. 3.27A & B and 3.31B), except for the cervix. The peritoneum is reflected anteriorly from the uterus onto the bladder and posteriorly over the posterior part of the fornix of the vagina to the rectum.

Anteriorly, the uterine body is separated from the urinary bladder by the **vesicouterine pouch**, where the peritoneum is reflected from the uterus onto the posterior margin of the superior surface of the bladder. Posteriorly, the uterine body and supravaginal part of the cervix are separated from the sigmoid colon by a layer of peritoneum and the peritoneal cavity and from the rectum by the *rectouterine pouch*. Laterally, the uterine artery crosses the ureter superiorly, near the cervix (Fig. 3.29).

Summary of the relations of the uterus:

- *Anteriorly* (anteroinferiorly in its normal anteverted position): the vesicouterine pouch and superior surface of the bladder; the supravaginal part of the cervix is related to the bladder and is separated from it by only fibrous connective tissue.
- *Posteriorly*: the rectouterine pouch containing loops of small intestine and the anterior surface of rectum; only the visceral pelvic fascia uniting the rectum and uterus here resists increased intra-abdominal pressure
- *Laterally*: the peritoneal broad ligament flanking the uterine body and the fascial transverse cervical ligaments on each side of the cervix and vagina; in the transition between the two ligaments, the ureters run anteriorly slightly superior to the lateral part of the vaginal fornix and inferior to the uterine arteries, usually approximately 2 cm lateral to the supravaginal part of the cervix.

Arterial Supply of the Uterus. The blood supply of the uterus derives mainly from the *uterine arteries*, with potential collateral supply from the ovarian arteries (Fig. 3.29).

Venous and Lymphatic Drainage of the Uterus. The *uterine veins* enter the broad ligaments with the arteries and form a **uterine venous plexus** on each side of the cervix. Veins from the uterine plexus drain into the internal iliac veins.

Lymphatic vessels from the uterus drain in many directions, coursing along the blood vessels that supply it as well as the ligaments attached to it (Fig. 3.30; Table 3.6):

- Most lymphatic vessels from the fundus and superior uterine body pass along the ovarian vessels to the *lumbar (cavallaortic) lymph nodes*; but some vessels from the fundus, particularly those near the entrance of the uterine tubes and attachments of the round ligaments, run along the round ligament of the uterus to the *superficial inguinal lymph nodes*.
- Vessels from most of the uterine body and some from the cervix pass within the broad ligament to the *external iliac lymph nodes*.
- Vessels from the uterine cervix also pass along the uterine vessels, within the transverse cervical ligaments, to the *internal iliac lymph nodes*, and along uterosacral (sacrogenital) ligaments to the *sacral lymph nodes*.

Cervical Cancer, Cervical Examination, and Pap Smear

Until 1940, cervical cancer was the leading cause of death in North American women (Krebs, 2000). The decline in the incidence and number of women dying from cervical cancer is related to the accessibility of the cervix to direct visualization and to cell and tissue study by means of Pap (Papanicolaou) smears, leading to the detection of premalignant cervical conditions (Copeland, 2000; Morris and Burke, 2000). The vagina can be distended with a *vaginal speculum* to enable inspection of the cervix (Fig. B3.14A & B). To prepare a Pap smear, a spatula is placed on the external os of the uterus (Fig. B3.14A). The spatula is rotated to scrape cellular material from the mucosa of the vaginal cervix (Fig. B3.14C), followed by an insertion of a cytobrush into the cervical canal that is rotated to gather cellular material from the supravaginal cervical mucosa. The cellular material is then placed on glass slides for microscopic examination (Fig. B3.14D & E).

Examination of the Uterus

The size and disposition of the uterus may be examined by *bimanual palpation* (Fig. B3.15A). Two fingers of the right hand are passed superiorly in the vagina, while the other hand is pressed inferoposteriorly on the pubic region of the

anterior abdominal wall. The size and other characteristics of the uterus can be determined in this way (e.g., whether the uterus is in its normal anteverted position). When softening of the uterine isthmus occurs (*Hegar sign*), the cervix feels as though it were separated from the body. Softening of the isthmus is an early sign of pregnancy. The uterus can be further stabilized through rectovaginal examination, which is used if examination via the vagina alone does not yield clear findings (Fig. B3.15B)

Lifetime Changes in the Normal Anatomy of the Uterus

The uterus is possibly the most dynamic structure in human anatomy (Fig. B3.16). At birth, the uterus is relatively large and has adult proportions (body to cervical ratio = 2:1) due to the prepartum (before childbirth) influence of the adult maternal hormones (Fig. B3.16A). Several weeks **postpartum** (after childbirth), childhood dimensions and proportions are obtained: the body and cervix are approximately of equal length (body to cervical ratio = 1:1), with the cervix being of greater diameter (thickness) (Fig. B3.16B). Because of the small size of the pelvic cavity during infancy, the uterus is mainly an abdominal organ. The cervix remains relatively large (approximately 50% of total uterus) throughout childhood. During puberty, the uterus (especially its body) grows rapidly in size, once again assuming adult proportions (Fig. B3.16C). In the ►

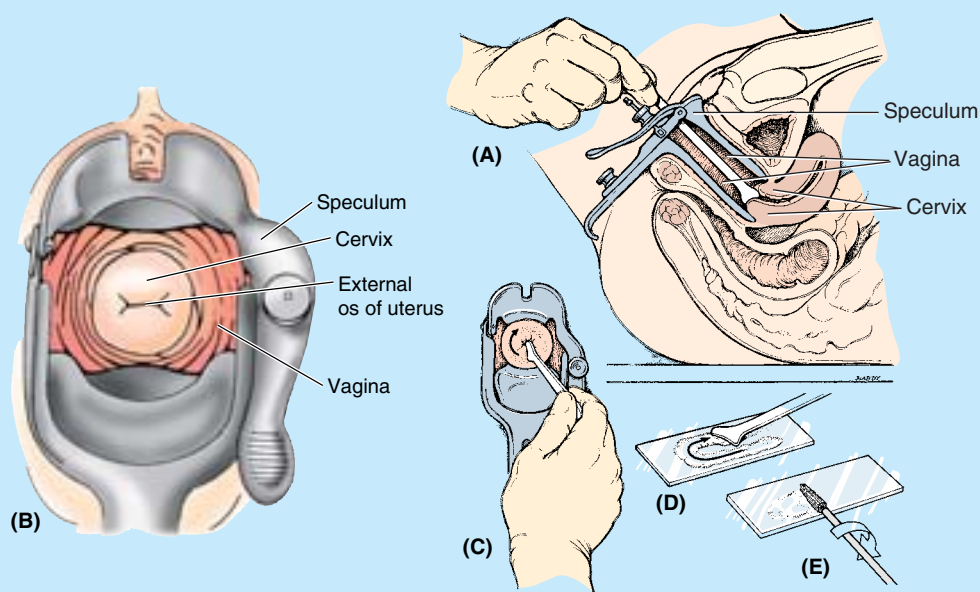


Figure B3.14

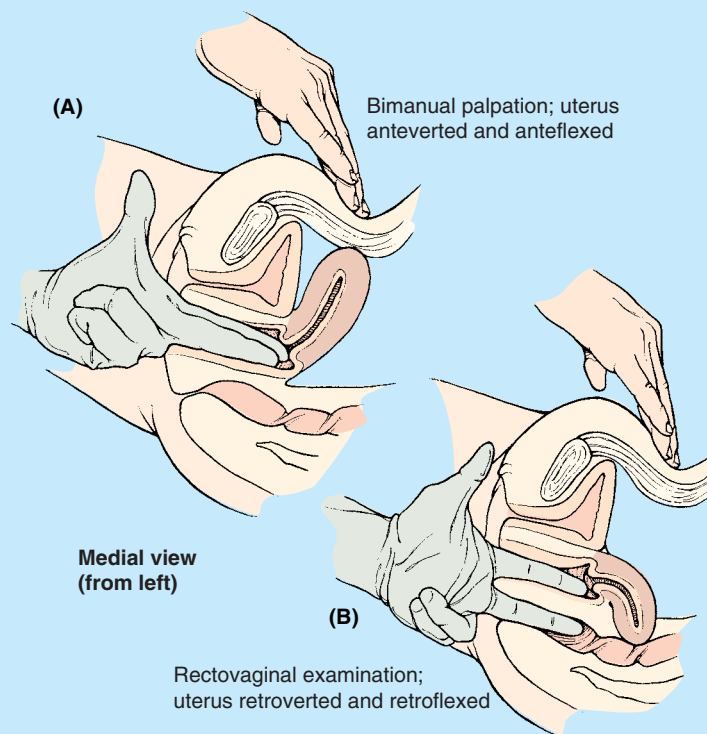


Figure B3.15

postpubertal, premenopausal, non-pregnant woman, the body is pear shaped; the thick-walled superior two thirds of the uterus lies within the pelvic cavity (Fig. B3.16D). During this phase of life, the uterus undergoes monthly changes in size, weight, and density in relation to the menstrual cycle.

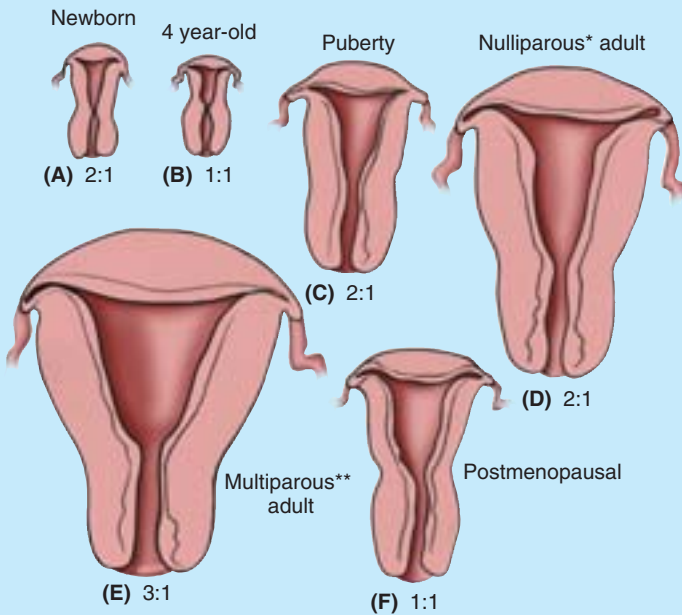
Over the 9 months of pregnancy, the uterus expands greatly to accommodate the fetus, becoming larger and increasingly thin walled (Fig. B3.16G). At the end of pregnancy (B3.16G, line 10), the fetus “drops,” as the head becomes engaged in the lesser pelvis. The uterus becomes nearly membranous, with the fundus dropping below its highest level (achieved in the 9th month), at which time it extends superiorly to the costal margin, occupying most of the abdominopelvic cavity (Fig. B3.16H). Immediately after delivery, the large uterus becomes thick walled and edematous (Fig. B3.16I), but its size reduces rapidly. The multiparous non-gravid uterus has a large and nodular body and usually extends into the greater pelvis, often causing a slight protrusion of the inferior abdominal wall in lean women (Figs. B3.16E & J and 3.64).

During menopause (46–52 years of age), the uterus (again, especially the body) decreases in size. Postmenopause, the uterus is involuted and regresses to a markedly smaller size, once again assuming childhood

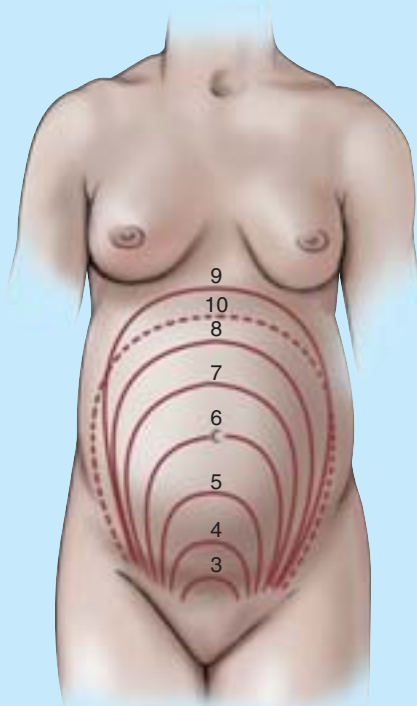
proportions (Fig. B3.16F). All these stages represent *normal anatomy* for the particular age and reproductive status of the woman.

Disposition of the Uterus and Uterine Prolapse

When intra-abdominal pressure is increased, the normally anteverted and anteфлекted uterus is pressed against the bladder (Fig. B3.17A). However, the uterus may assume other dispositions, including excessive anteфлекtion (Fig. B3.17B), anteфлекtion with retroversion (Fig. B3.17C), and retroфлекtion with retroversion (Fig. B3.17D). Instead of pressing the uterus against the bladder, increased intra-abdominal pressure tends to push the retroverted uterus, a solid mass positioned upright over the vagina (a flexible, hollow tube), into or even through the vagina (Fig. B3.17E–G). A retroverted uterus will not necessarily prolapse but is more likely to do so, and pregnancies involving a retroverted uterus are considered to be higher risk pregnancies. The situation is exacerbated in the presence of a disrupted perineal body or with atrophic (“relaxed”) pelvic floor ligaments and muscles (see clinical correlation [blue] box “Disruption of Perineal Body,” in this chapter). ▶

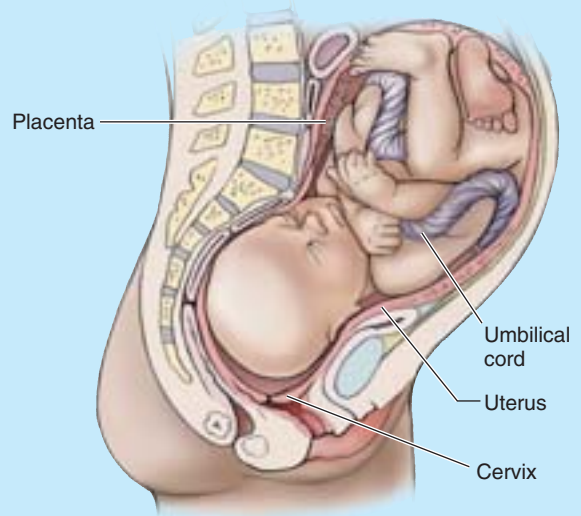


(A-F) Anterior views

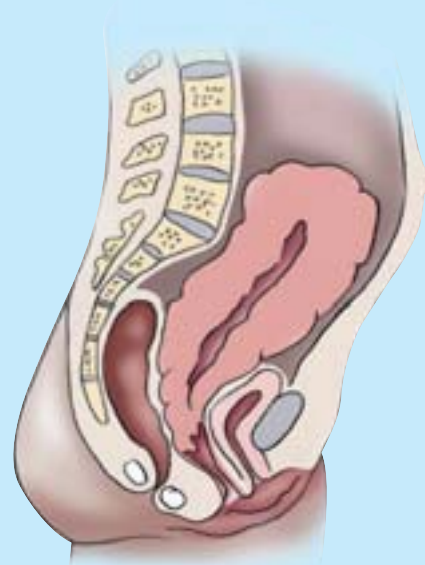

(G) Monthly changes in size of uterus during pregnancy

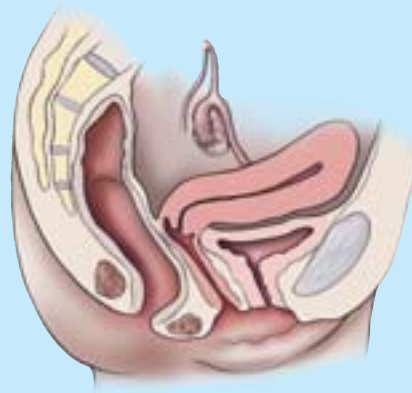*Never having borne an infant
**Having given birth to an infant two or more times



(H) Uterus at end of pregnancy



(I) Postpartum uterus (immediately following childbirth)



(J) Multiparous** uterus

Figure B3.16 ►

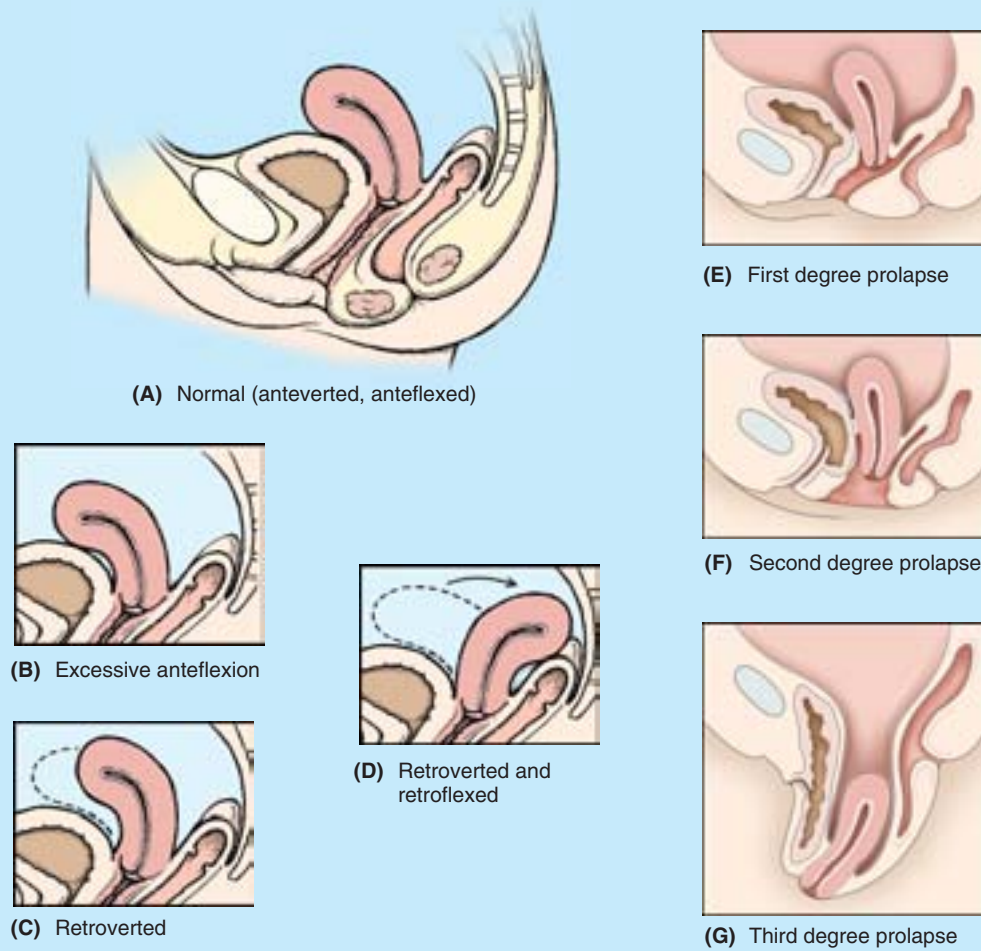


Figure B3.17

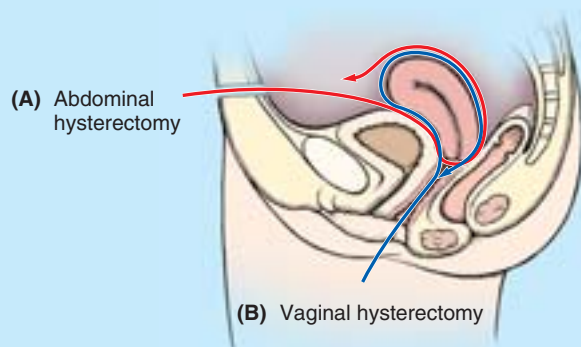


Figure B3.18

Hysterectomy

Owing to the frequency of uterine and cervical cancer, **hysterectomy**, excision of the uterus (*G. hystera*), is a relatively common procedure. The uterus may be surgically approached and removed through the anterior abdominal wall or through the vagina (Fig. B3.18). +

THE BOTTOM LINE: Shaped like an inverted pear, the uterus is the organ in which the blastocyst (early embryo) implants and develops into a mature embryo and then a fetus. Although its size and proportions change during the various phases of life, the non-gravid uterus consists of a body and cervix, demarcated by a relatively narrow isthmus. The uterus has a trilaminar wall consisting of (1) an inner vascular and secretory endometrium, which undergoes cyclical changes to prepare for implantation to occur and sheds with menstrual flow if it does not; (2) a hormonally stimulated intermediate smooth muscle myometrium, which dilates the cervical canal (exit) and expels the fetus during childbirth; and (3) visceral peritoneum (perimetrium), which covers most of the fundus and body (except for a bare area abutting the bladder) and continues bilaterally as the broad ligament (mesometrium).

The uterus is normally anteverted and anteflexed so that its weight is borne largely by the urinary bladder, although it also receives significant passive support from the transverse cervical ligaments and active support from the muscles of the pelvic floor. The uterine artery supplies the uterus and, during pregnancy, the placenta. The uterus drains to the uterovaginal venous plexus and to all major groups of pelvic lymph nodes, with parts near the attachments of the round ligaments draining to superficial inguinal nodes.

Innervation of the Vagina and Uterus

Only the inferior one fifth to one quarter of the vagina is somatic in terms of innervation. Innervation of this part of the vagina is from the *deep perineal nerve*, a branch of the *pudendal nerve*, which conveys sympathetic and visceral afferent fibers but no parasympathetic fibers (Fig. 3.32). Only this somatically innervated part is sensitive to touch

and temperature, even though the somatic and visceral afferent fibers have their cell bodies in the same (S2–S4) spinal ganglia.

Most of the vagina (superior three quarters to four fifths) is visceral in terms of its innervation. Nerves to this part of the vagina and to the uterus are derived from the **uterovaginal nerve plexus**, which travels with the uterine artery at the junction of the base of the (peritoneal) broad ligament and the superior part of the (fascial) transverse cervical ligament. The uterovaginal nerve plexus is one of the pelvic plexuses that extends to the pelvic viscera from the inferior hypogastric plexus. Sympathetic, parasympathetic, and visceral afferent fibers pass through this plexus.

Sympathetic innervation originates in the inferior thoracic spinal cord segments and passes through *lumbar splanchnic nerves* and the intermesenteric-hypogastric-pelvic series of plexuses. Parasympathetic innervation originates in the S2–S4 spinal cord segments and passes through the *pelvic splanchnic nerves* to the inferior hypogastric-uterovaginal plexus. The visceral afferent innervations of the superior (intraperitoneal; fundus and body) and inferior (subperitoneal; cervical) parts of the uterus and vagina differ in terms of course and destination. Visceral afferent fibers conducting pain impulses from the intraperitoneal uterine fundus and body (superior to the *pelvic pain line*) follow the sympathetic innervation retrograde to reach cell bodies in the inferior thoracic-superior lumbar spinal ganglia. Afferent fibers conducting pain impulses from the subperitoneal uterine cervix and vagina (inferior to the pelvic pain line) follow the parasympathetic fibers retrograde through the uterovaginal and inferior hypogastric plexuses and pelvic splanchnic nerves to reach cell bodies in the spinal sensory ganglia of S2–S4. All visceral afferent fibers from the uterus and vagina not concerned with pain (those conveying unconscious sensations) also follow the latter route.

Anesthesia for Childbirth

Several options are available to women to reduce the pain and discomfort experienced during childbirth. *General anesthesia* has advantages for emergency procedures and for women who choose it over regional anesthesia. General anesthesia renders the mother unconscious; she is unaware of the labor and delivery. Clinicians monitor and regulate maternal respiration and both maternal and fetal cardiac function. Childbirth occurs passively under the control of maternal hormones with the assistance of an obstetrician. The mother is spared pain and discomfort but is unaware of the earliest moments of her baby's life.

Women who choose *regional anesthesia*, such as a spinal, pudendal nerve, or caudal epidural block, often wish to participate actively (e.g., using the Lamaze method) and be

conscious of their uterine contractions to “bear down,” or push, to assist the contractions and expel the fetus, yet do not wish to experience all the pain of labor.

A **spinal block**, in which the anesthetic agent is introduced with a needle into the spinal subarachnoid space at the L3–L4 vertebral level (A in Fig. B3.19), produces complete anesthesia inferior to approximately the waist level. The perineum, pelvic floor, and birth canal are anesthetized, and motor and sensory functions of the entire lower limbs, as well as sensation of uterine contractions, are temporarily eliminated. The mother is conscious, but she must depend on electronic monitoring of uterine contractions. If labor is extended or the level of anesthesia is inadequate, it may be difficult or impossible to re-administer the anesthesia. Because the anesthetic agent is heavier than cerebrospinal fluid, it remains in the inferior spinal ►

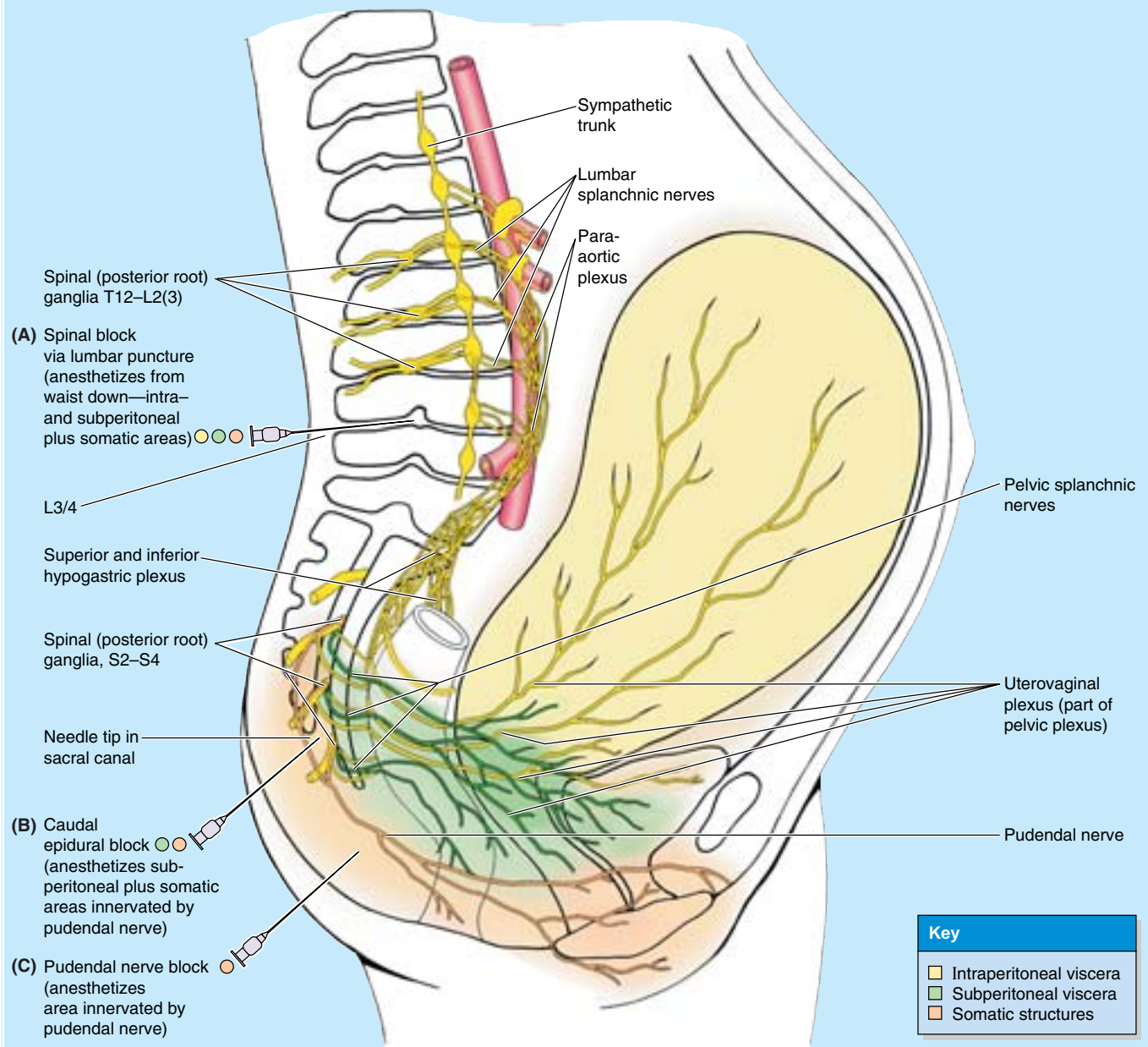


Figure B3.19

subarachnoid space while the patient is inclined. The anesthetic agent circulates into the cerebral subarachnoid space in the cranial cavity when the patient lies flat following the delivery. A severe headache is a common sequel to spinal anesthesia.

A **pudendal nerve block** is a peripheral nerve block that provides local anesthesia over the S2–S4 dermatomes (the majority of the perineum) and the inferior quarter of the vagina (C in Fig. B3.19). It does not block pain from the superior birth canal (uterine cervix and superior vagina), so

the mother is able to feel uterine contractions. It can be re-administered, but to do so may be disruptive and involve the use of a sharp instrument in close proximity to the infant's head. The anatomical basis of the administration of a pudendal block is provided in the clinical correlation (blue box "Administration of Pudendal and Ilioinguinal Nerve Blocks," in this chapter.

The **caudal epidural block** is a popular choice for participatory childbirth (B in Fig. B3.19). It must be administered in advance of the actual delivery, which is not ►

possible with a precipitous birth. The anesthetic agent is administered using an in-dwelling catheter in the *sacral canal* (see Chapter 4), enabling administration of more anesthetic agent for a deeper or more prolonged anesthesia, if necessary. Within the sacral canal, the anesthesia bathes the S2–S4 spinal nerve roots, including the pain fibers from the uterine cervix and superior vagina, and the afferent fibers from the pudendal nerve. Thus the entire birth canal, pelvic floor, and majority of the perineum are

anesthetized, but the lower limbs are not usually affected. The pain fibers from the uterine body (superior to the pelvic pain line) ascend to the inferior thoracic–superior lumbar levels; these and the fibers superior to them are not affected by the anesthetic, so the mother is aware of her uterine contractions. With epidural anesthesia, no “spinal headache” occurs because the vertebral epidural space is not continuous with the cranial epidural space (see Chapter 4). ➔

THE BOTTOM LINE: The inferiormost (perineal) portion of the vagina receives somatic innervation via the pudendal nerve (S2–S4) and is, therefore, sensitive to touch and temperature. The remainder of the vagina and uterus is pelvic and thus visceral in its location, receiving innervation from autonomic and visceral afferent fibers. All unconscious, reflex-type sensation travels retrogradely along the parasympathetic pathways to the S2–S4 spinal sensory ganglia, as does pain sensation arising in the subperitoneal uterus (primarily cervix) and vagina (inferior to the pelvic pain line)—that is, from the birth canal. However, pain sensation from the intraperitoneal uterus (superior to the pelvic pain line) travels retrogradely along the sympathetic pathway to the inferiormost thoracic and superior lumbar spinal ganglia. Epidural anesthesia may be administered to take advantage of the discrepancy in the pain pathways to facilitate participatory childbirth methods; uterine contractions are felt, but the birth canal is anesthetized.

Uterine Tubes

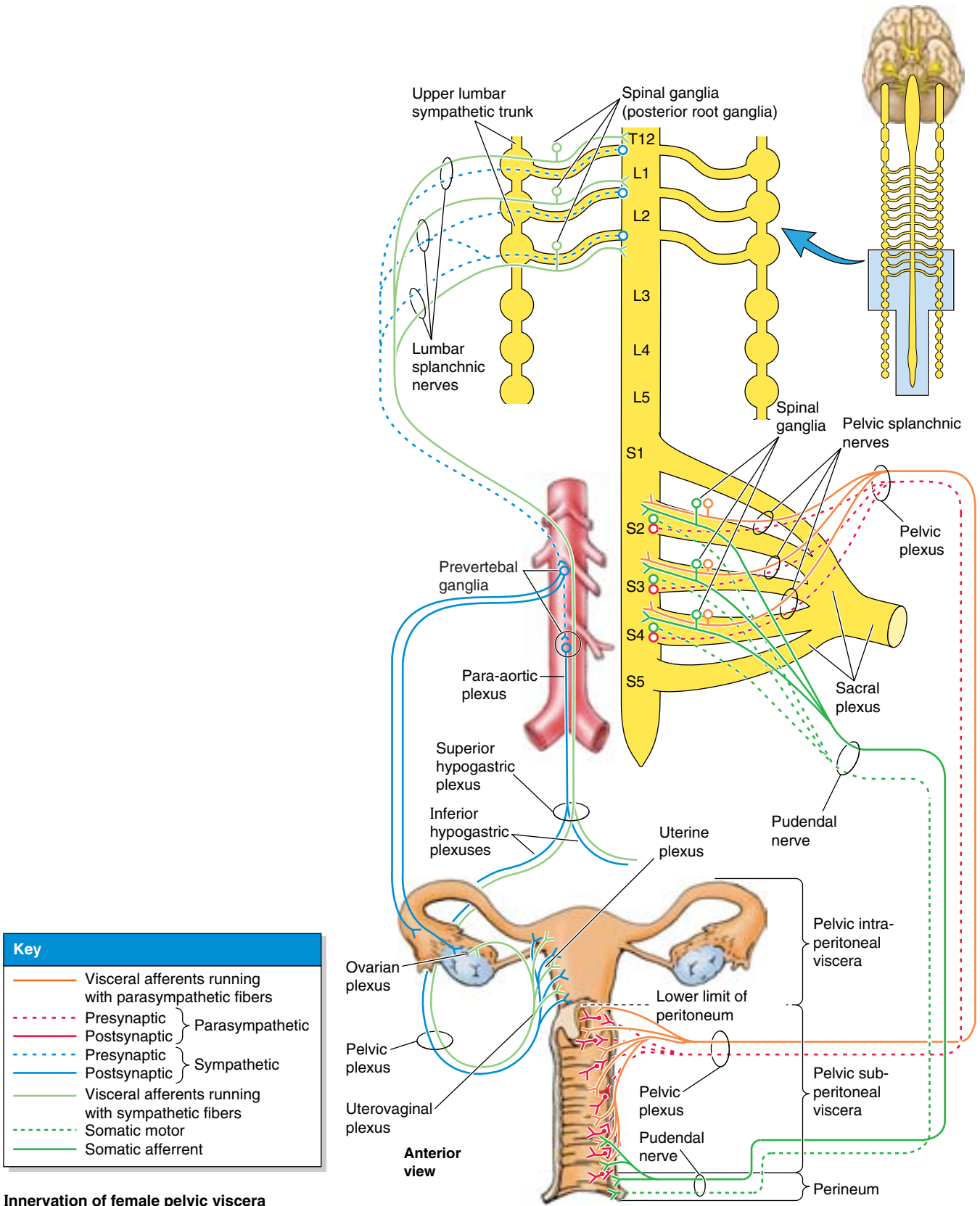
The **uterine tubes** (oviducts; formerly called fallopian tubes) conduct the oocyte (ovum), discharged monthly from an ovary during child-bearing years, from the periovarian peritoneal cavity to the uterine cavity. They also provide the usual site of fertilization. They extend laterally from the *uterine horns* and open into the peritoneal cavity near the ovaries

(Figs. 3.26 and 3.31). The uterine tubes (approximately 10 cm long) lie in the *mesosalpinx* in the free edges of the broad ligaments. In the “ideal” disposition, as typically illustrated, the tubes extend symmetrically posterolaterally to the lateral pelvic walls, where they arch anterior and superior to the ovaries in the horizontally disposed broad ligament. In reality, as seen in an ultrasound examination, the tubes are commonly asymmetrically arranged with one or the other often lying superior and even posterior to the uterus.

The uterine tubes are divisible into four parts, from lateral to medial (Fig. 3.31B):

- **Infundibulum:** the funnel-shaped distal end of the tube that opens into the peritoneal cavity through the **abdominal ostium**; the finger-like processes of the fimbriated end of the infundibulum (the **fimbriae**) spread over the medial surface of the ovary; one large **ovarian fimbria** is attached to the superior pole of the ovary.
- **Ampulla:** the widest and longest part of the tube, which begins at the medial end of the infundibulum; fertilization of the oocyte usually occurs in the ampulla.
- **Isthmus:** the thick-walled part of the tube, which enters the uterine horn.
- **Uterine part:** the short intramural segment of the tube that passes through the wall of the uterus (Fig. 3.26) and opens via the **uterine ostium** into the uterine cavity at the uterine horn.

Figure 3.32. Innervation of female internal genital organs. Pelvic splanchnic nerves, arising from the S2–S4 anterior rami, supply parasympathetic motor fibers to the uterus and vagina (and vasodilator fibers to the erectile tissue of the clitoris and bulb of the vestibule; not shown). Presynaptic sympathetic fibers traverse the sympathetic trunk and pass through the lumbar splanchnic nerves to synapse in prevertebral ganglia with postsynaptic fibers; the latter fibers travel through the superior and inferior hypogastric plexuses to reach the pelvic viscera. Visceral afferent fibers conducting pain from intraperitoneal structures (such as the uterine body) travel with the sympathetic fibers to the T12–L2 spinal ganglia. Visceral afferent fibers conducting pain from subperitoneal structures, such as the cervix and vagina (i.e., the birth canal), travel with parasympathetic fibers to the S2–S4 spinal ganglia. Somatic sensation from the opening of the vagina also passes to the S2–S4 spinal ganglia via the pudendal nerve. In addition, muscular contractions of the uterus are hormonally induced.



Key	
—	Visceral afferents running with parasympathetic fibers
- - -	Presynaptic
—	Postsynaptic
- - - } —	Parasympathetic
- - -	Presynaptic
—	Postsynaptic
- - - } —	Sympathetic
—	Visceral afferents running with sympathetic fibers
- - -	Somatic motor
—	Somatic afferent

Innervation of female pelvic viscera

Infections of the Female Genital Tract

Because the female genital tract communicates with the peritoneal cavity through the abdominal ostia of the uterine tubes, infections of the vagina, uterus, and tubes may result in *peritonitis*. Conversely, inflammation of the tube (**salpingitis**) may result from infections that spread from the peritoneal cavity. A major cause of infertility in women is blockage of the uterine tubes, often the result of salpingitis.

Patency of the Uterine Tubes

Hysterosalpingography

Patency of the uterine tubes may be determined by a radiographic procedure involving injection of a water-soluble radiopaque material into the uterus and tubes (**hysterosalpingography**). See “Medical Imaging of the Pelvis and Perineum,” later in this chapter.

Endoscopy

Patency of the uterine tubes can also be determined by **hysteroscopy**, examination of the interior of the tubes using an endoscopic instrument (*hysteroscope*), which is introduced through the vagina and uterus.

Ligation of the Uterine Tubes

Ligation of the uterine tubes is a surgical method of birth control. Oocytes discharged from the ovaries that enter the tubes of these patients degenerate and are soon absorbed. Most surgical sterilizations are done by either abdominal tubal ligation or laparoscopic tubal ligation. **Abdominal tubal ligation** is usually performed through a short suprapubic incision made at the pubic hairline (Fig. B3.20A). **Laparoscopic tubal ligation** is done with a laparoscope, which is similar to a small telescope with a powerful light (Fig. B3.20B). It is inserted through a small incision, usually near the umbilicus.

Ectopic Tubal Pregnancy

In some women, collections of pus may develop in the uterine tube (**pyosalpinx**) and the tube may be partly occluded by adhesions. In these cases, the blastocyst may not be able to pass along the tube to the uterus, although sperms have obviously done so. The blastocyst may implant in the mucosa of the uterine tube, producing an **ectopic tubal pregnancy**. Although implantation may occur in any part of the tube, the common site is in the ampulla (Fig. B3.21). ▶

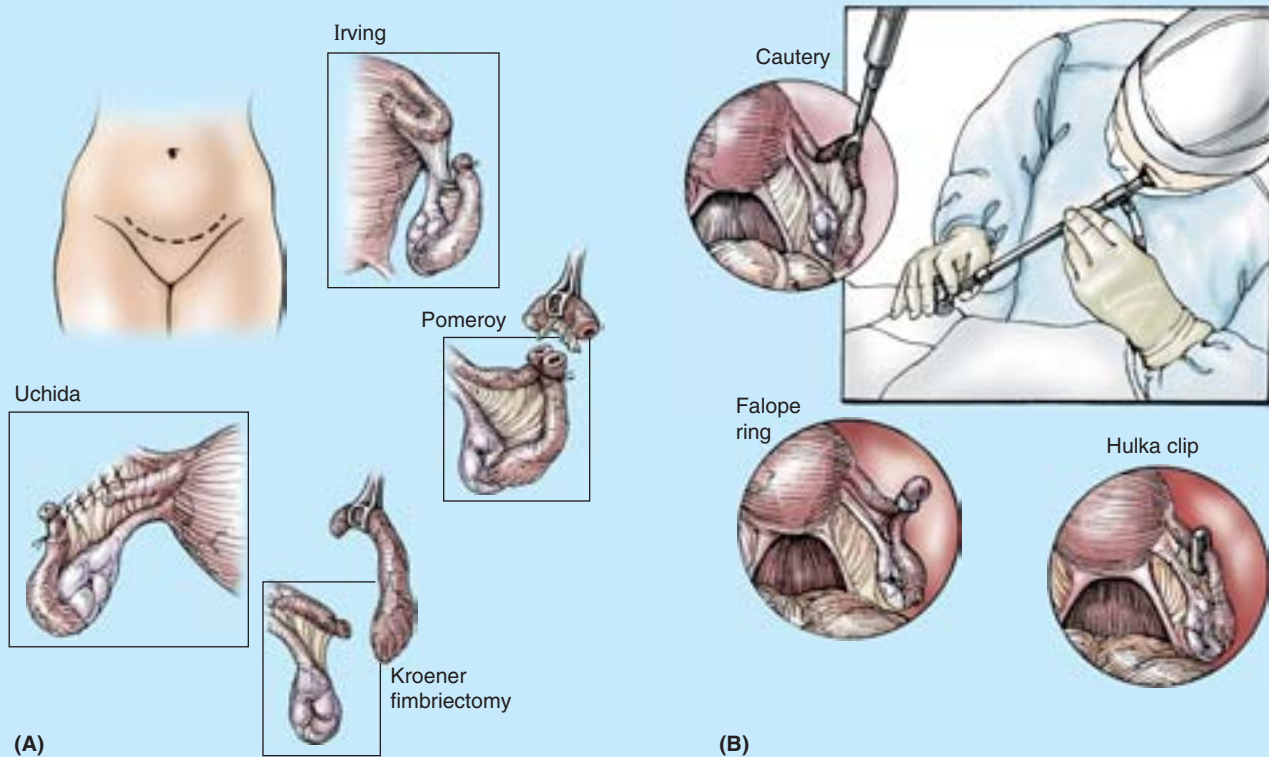


Figure B3.20

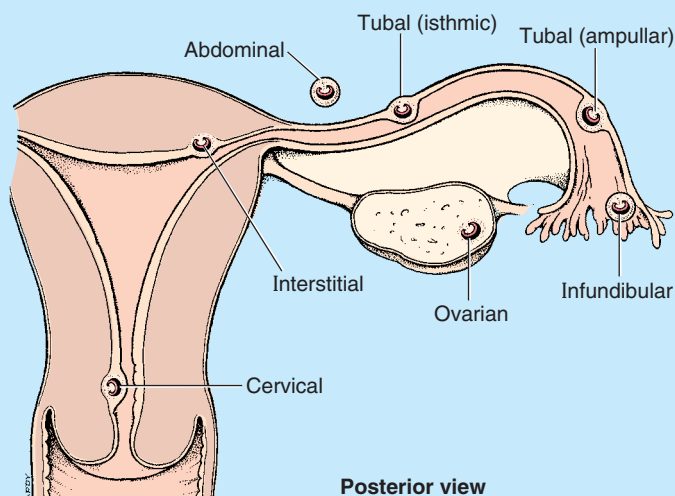


Figure B3.21

Tubal pregnancy is the most common type of ectopic gestation; it occurs in approximately 1 of every 250 pregnancies in North America (Moore and Persaud, 2003). If not diagnosed early, ectopic tubal pregnancies may result in rupture of the uterine tube and severe hemorrhage into the abdominopelvic cavity during the first 8 weeks of gestation. Tubal rupture and the associated hemorrhage constitute a threat to the mother's life and result in death of the embryo.

On the right side, the appendix often lies close to the ovary and uterine tube. This close relationship explains why a *ruptured tubal pregnancy* and the resulting peritonitis may be misdiagnosed as acute appendicitis. In both cases, the parietal peritoneum is inflamed in the same general area, and the pain is referred to the right lower quadrant of the abdomen.

Remnants of the Embryonic Ducts

Occasionally the mesosalpinx between the uterine tube and the ovary contains embryonic remnants (Fig. 3.26). The *epoophoron* forms from remnants of the mesonephric tubules of the *mesonephros*, the transitory embryonic kidney. There may also be a persistent *duct of the epoophoron* (duct of Gartner), a remnant of the mesonephric duct that forms the ductus deferens and ejaculatory duct in the male. It lies between layers of the broad ligament along each side of the uterus and/or vagina. A *vesicular appendage* is sometimes attached to the infundibulum of the uterine tube. It is the remains of the cranial end of the mesonephric duct that forms the *ductus epididymis* (Moore and Persaud, 2003). Although these vestigial structures are mostly of embryological and morphological interest, they occasionally accumulate fluid and form cysts (e.g., Gartner duct cysts). ❖

THE BOTTOM LINE: The uterine tubes are the conduits and the site of fertilization for oocytes discharged into the peritoneal cavity. Coursing in a peritoneal fold (mesosalpinx) that makes up the superior margin of the broad ligament, each uterine tube has a fimbriated, funnel-like infundibulum, a wide ampulla, a narrow isthmus, and a short uterine part that traverses the uterine wall to enter the cavity.

Ovaries

The **ovaries** are almond-shaped and -sized female gonads in which the ova develop. They are also endocrine glands that produce reproductive hormones. The ovaries are typically located near the attachment of the broad ligament to the lateral pelvic walls, suspended from both by peritoneal folds: from the posterosuperior aspect of the broad ligament by

the mesovarium and from the lateral pelvic walls by the suspensory ligaments of the ovaries (Fig. 3.31). In prepubertal females, the surface of the ovary is covered by a smooth layer of ovarian surface epithelium, a single layer of cuboidal cells that gives the surface a dull, grayish appearance, contrasting with the shiny surface of the adjacent peritoneal mesovarium with which it is continuous. After puberty, the surface becomes progressively scarred and distorted because of the repeated rupture of ovarian follicles and discharge of oocytes that are part of ovulation. The scarring is less in women who have been taking oral contraceptives that inhibit ovulation.

The ovarian vessels, lymphatics, and nerves pass to and from the superolateral aspect of the ovary within the *suspensory ligament of the ovary*, which actually constitutes the lateral part of the mesovarium of the broad ligament. The ovary also

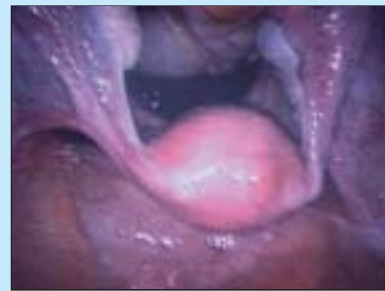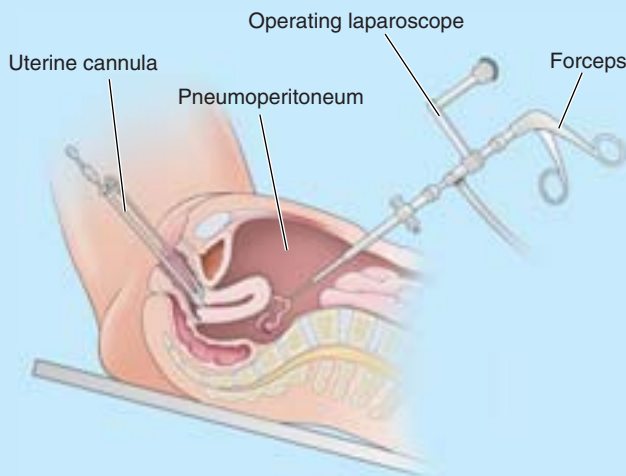
attaches to the uterus by the *ligament of the ovary*, which runs within the mesovarium. This ligament is a remnant of the superior part of the ovarian gubernaculum of the fetus (see Fig. 2.14). The ligament of the ovary connects the proximal (uterine) end of the ovary to the lateral angle of the uterus, just inferior to the entrance of the uterine tube. Because the ovary is

suspended in the peritoneal cavity and its surface is not covered by peritoneum, the oocyte expelled at ovulation passes into the peritoneal cavity. However, its intraperitoneal life is short because it is usually trapped by the fimbriae of the infundibulum of the uterine tube and carried into the ampulla, where it may be fertilized.

Laparoscopic Examination of Pelvic Viscera

Visual examination of the pelvic viscera is especially useful in diagnosing many conditions affecting the pelvic viscera, such as *ovarian cysts* and tumors, *endometriosis* (the presence of functioning endometrial tissue outside the uterus), and ectopic pregnancies. **Laparoscopy** involves inserting a *laparoscope* into the peritoneal cavity through

a small (approximately 2 cm) incision below the umbilicus (Fig. B3.22). Insufflation of inert gas creates a pneumoperitoneum to provide space to visualize, and the pelvis is elevated so that gravity will pull the intestines into the abdomen. The uterus can be externally manipulated to facilitate visualization, or additional openings (ports) can be made to introduce other instruments for manipulation or to enable therapeutic procedures (e.g., ligation of the tubes). +



Laparoscopic view of normal pelvis

Figure B3.22

THE BOTTOM LINE: The ovaries are suspended by two peritoneal folds (the mesovarium from the posterosuperior aspect of the broad ligament and the vascular suspensory ligament of the ovary from the lateral wall of the pelvis) and attached to the uterus by the ovarian ligament. The peritoneum ends at the ovary itself. It is replaced on the surface of the ovary with a duller, cuboidal epithelium.

Neurovascular Structures Serving the Ovaries and Uterine Tubes

Arterial Supply of the Ovaries and Uterine Tubes. The *ovarian arteries* arise from the abdominal aorta (Table 3.5) and descend along the posterior abdominal wall. At the pelvic brim, they cross over the external iliac vessels and enter the suspensory ligaments (Fig. 3.31A), approaching the lateral as-

pects of the ovaries and uterine tubes. The ascending branches of the *uterine arteries* (branches of the internal iliac arteries), course along the lateral aspects of the uterus to approach the medial aspects of the ovaries and tubes (Figs. 3.12B and 3.29). Both the ovarian and ascending uterine arteries terminate by bifurcating into *ovarian* and *tubal branches*, which supply ovaries and tubes from opposite ends and anastomose with each other, providing a collateral circulation from abdominal and pelvic sources to both structures.

Venous and Lymphatic Drainage of the Ovaries and Uterine Tubes. Veins draining the ovary form a vine-like pampiniform plexus of veins in the broad ligament near the ovary and uterine tube (Fig. 3.29). The veins of the plexus usually merge to form a singular **ovarian vein**, which leaves the lesser pelvis with the ovarian artery. The right ovarian vein ascends to enter the *inferior vena cava*; the left ovarian vein

drains into the *left renal vein* (Fig. 3.13). The *tubal veins* drain into the *ovarian veins* and *uterine (uterovaginal) venous plexus* (Fig. 3.29). The lymphatic vessels from the ovary join those from the uterine tubes and fundus and follow the ovarian blood vessels as they ascend to the *right and left lumbar (cavalaortic) lymph nodes* (Fig. 3.30).

Innervation of the Ovaries and Uterine Tubes. The nerve supply derives partly from the *ovarian plexus*, descending with the ovarian vessels, and partly from the *uterine (pelvic) plexus* (Fig. 3.32). The ovaries and uterine tubes are intraperitoneal and, therefore, are superior to the *pelvic pain line*. Thus visceral afferent pain fibers ascend retrogradely with the descending sympathetic fibers of the ovarian plexus and lumbar splanchnic nerves to cell bodies in the T11–L1 spinal sensory ganglia. Visceral afferent reflex fibers follow parasympathetic fibers retrogradely through the uterine (pelvic) and inferior hypogastric plexuses and the pelvic splanchnic nerves to cell bodies in the S2–S4 spinal sensory ganglia.

THE BOTTOM LINE: The ovaries and uterine tubes receive a double (collateral) blood supply from the abdominal aorta via the ovarian arteries and from the internal iliac artery via the uterine arteries. This collateral circulation allows the ovaries to be spared to supply estrogen when a hysterectomy necessitates ligation of the uterine arteries. Lymphatic drainage and sympathetic and visceral afferent pain fibers travel with the ovarian vessels. Parasympathetic and visceral afferent reflex fibers traverse pelvic plexuses and pelvic splanchnic nerves.

Rectum

The **rectum** (*L. rectus*, straight; a term coined during ancient studies on animals to describe the distal part of the gut) is the pelvic part of the alimentary tract and is continuous proximally with the sigmoid colon (Fig. 3.33) and distally with the

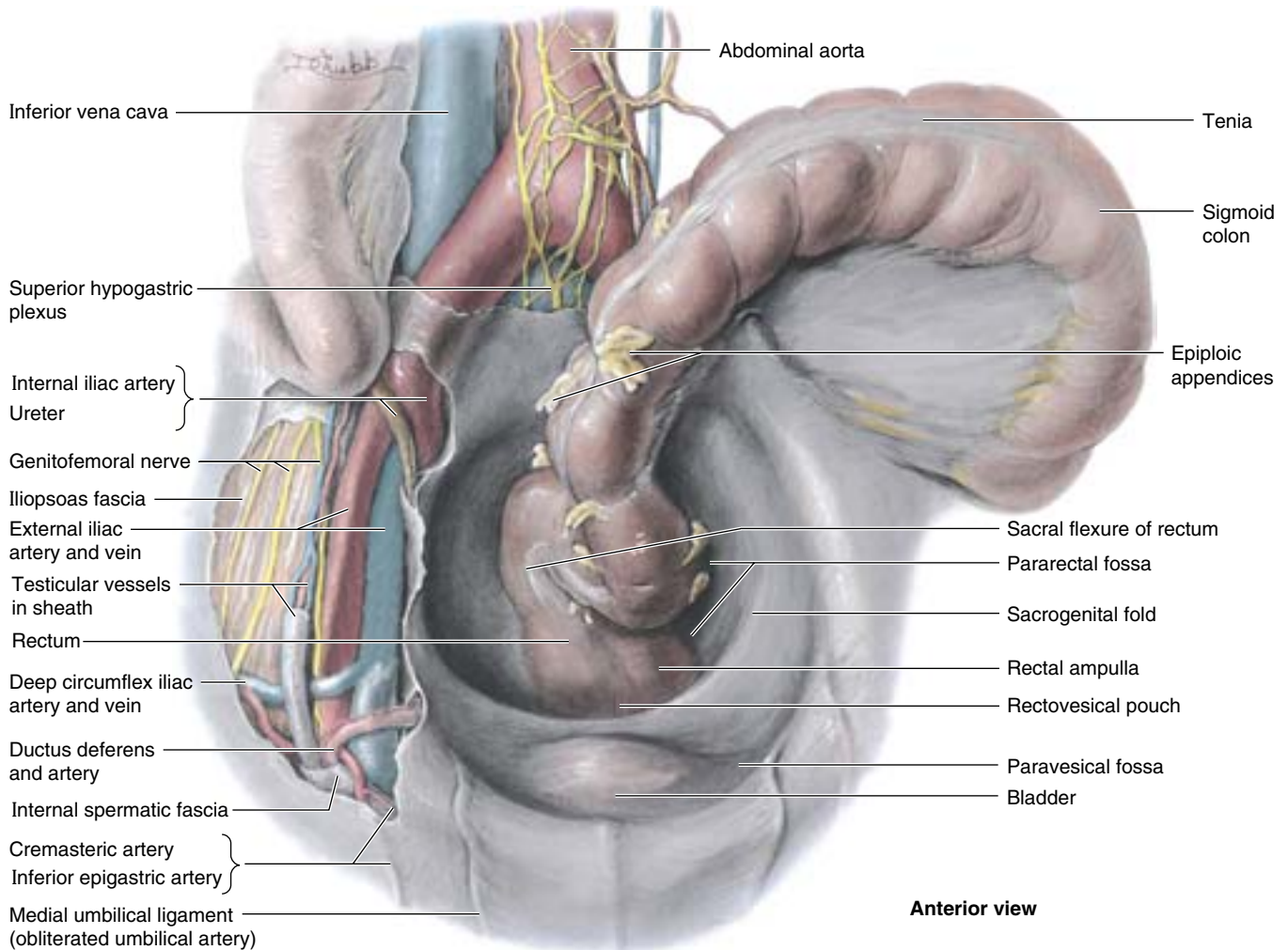


Figure 3.33. Male greater and lesser pelvis. The peritoneum has been removed superior to sacral promontory and right iliac fossa, revealing the superior hypogastric plexus lying in the bifurcation of the abdominal aorta and the common/external iliac vessels above the pelvic brim. The internal iliac artery, ureter, and ductus deferens cross the pelvic brim to enter the lesser pelvis, deep (external) to the peritoneum.

anal canal. The **rectosigmoid junction** lies anterior to the S3 vertebra. At this point, the teniae of the sigmoid colon spread out to form a continuous outer longitudinal layer of smooth muscle, and the fatty omental appendices are discontinued (see Fig. 2.41). The rectum follows the curve of the sacrum and coccyx, forming the **sacral flexure of the rectum**. The rectum ends anteroinferior to the tip of the coccyx, immediately before a sharp posteroinferior angle (the **anorectal flexure of the anal canal**) that occurs as the gut perforates the pelvic diaphragm (levator ani). The roughly 80° anorectal flexure is an important mechanism for fecal continence, being maintained during the resting state by the tonus of the pubo-rectalis muscle and by its active contraction during peristaltic contractions if defecation is not to occur. With the flexures of the rectosigmoid junction superiorly and the anorectal junction inferiorly, the rectum has an S shape when viewed laterally.

Three sharp **lateral flexures of the rectum (superior, intermediate, and inferior)** are apparent when the rectum is viewed anteriorly. The flexures are formed in relation to three internal infoldings (**transverse rectal folds**): two on the left and one on the right side. The folds overlie thickened parts of the circular muscle layer of the rectal wall (Fig. 3.34B). The dilated terminal part of the rectum, lying directly superior to and supported by the pelvic diaphragm (levator ani) and anococcygeal ligament, is the **ampulla of the rectum** (Figs.

3.17B, 3.33, and 3.34). The ampulla receives and holds an accumulating fecal mass until it is expelled during defecation. The ability of the ampulla to relax to accommodate the initial and subsequent arrivals of fecal material is another essential element of maintaining fecal continence.

Peritoneum covers the anterior and lateral surfaces of the superior third of the rectum, only the anterior surface of the middle third, and no surface of the inferior third because it is subperitoneal (Table 3.3). In males, the peritoneum reflects from the rectum to the posterior wall of the bladder, where it forms the floor of the *rectovesical pouch*. In females, the peritoneum reflects from the rectum to the posterior part of the fornix of the vagina, where it forms the floor of the *rectouterine pouch*. In both sexes, lateral reflections of peritoneum from the superior third of the rectum form *pararectal fossae* (Fig. 3.33), which permit the rectum to distend as it fills with feces.

The rectum lies posteriorly against the inferior three sacral vertebrae and the coccyx, anococcygeal ligament, median sacral vessels, and inferior ends of the sympathetic trunks and sacral plexuses. In males, the rectum is related anteriorly to the fundus of the urinary bladder, terminal parts of the ureters, ductus deferentes, seminal glands, and prostate (Fig. 3.23). The *rectovesical septum* lies between the fundus of the bladder and the ampulla of the rectum and is closely associated with the seminal glands and prostate. In females, the rec-

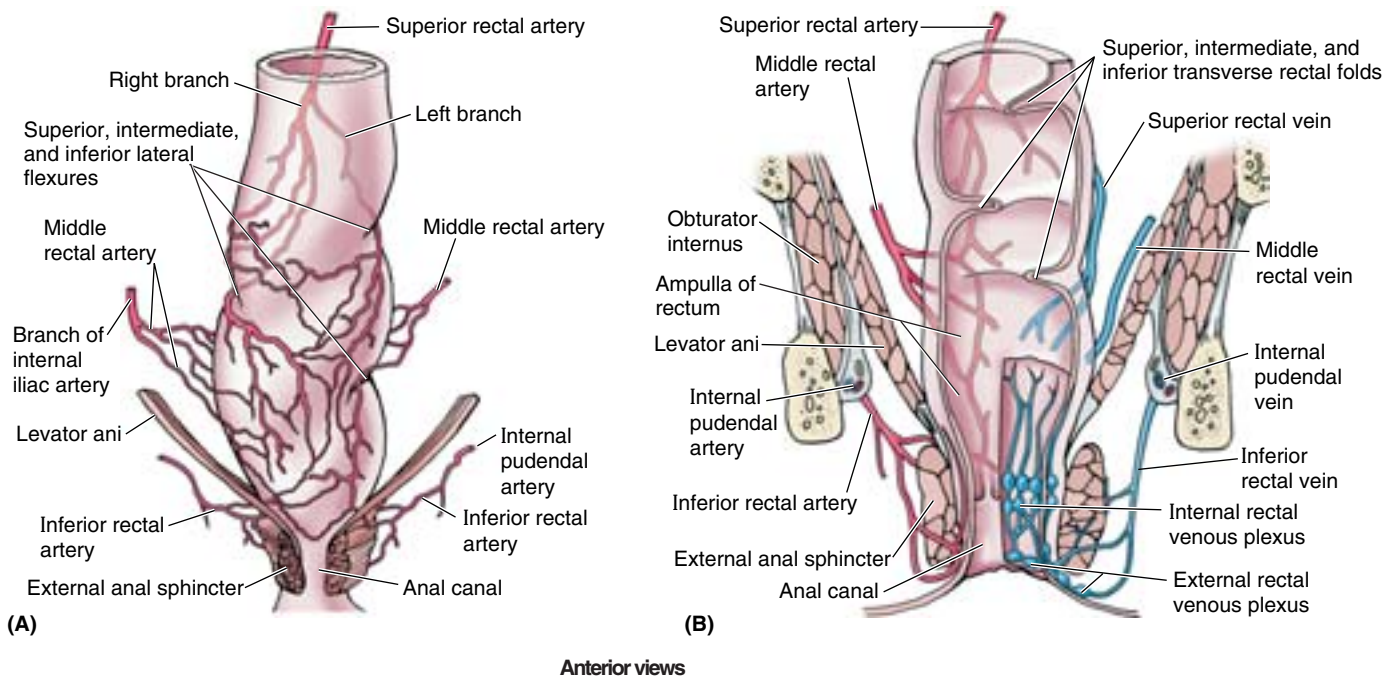


Figure 3.34. Arteries and veins of rectum and anal canal. A. In this anterior view of the arteries, there are two right middle rectal arteries. Despite their name, the inferior rectal arteries, which are branches of the internal pudendal arteries, mainly supply the anal canal. The three sharp lateral flexures of the rectum reflect the way in which the lumen navigates the transverse rectal folds (shown in part B) on the internal surface. **B.** This coronal section of the rectum and anal canal shows the arterial supply and venous drainage. The internal and external rectal venous plexuses are most directly related to the anal canal. The flexures and transverse rectal folds help support the weight of the feces.

tum is related anteriorly to the vagina and is separated from the posterior part of the fornix and the cervix by the *rectouterine pouch* (Fig. 3.27). Inferior to this pouch, the weak rectovaginal septum separates the superior half of the posterior wall of the vagina from the rectum.

Arterial Supply of the Rectum

The *superior rectal artery*, the continuation of the inferior mesenteric artery, supplies the proximal part of the rectum (Fig. 3.34). The right and left *middle rectal arteries*, usually arising from the inferior vesical arteries, supply the middle and inferior parts of the rectum. The *inferior rectal arteries*, arising from the internal pudendal arteries, supply the anorectal junction and anal canal. Anastomoses between these arteries provide potential collateral circulation.

Venous and Lymphatic Drainage of the Rectum

Blood from the rectum drains through the superior, middle, and inferior rectal veins (Fig. 3.34B). Anastomoses occur between the portal and systemic veins in the wall of the anal canal. Because the superior rectal vein drains into the portal venous system and the middle and inferior rectal veins drain into the systemic system, these anastomoses are clinically important areas of portacaval anastomosis (see Fig. 2.59). The submucosal rectal venous plexus surrounds the rectum and communicates with the vesical venous plexus in males and the uterovaginal venous plexus in females. The **rectal venous plexus** consists of two parts (Fig. 3.34B): the **internal rectal venous plexus** just deep to the mucosa of the anorectal junction and the subcutaneous **external rectal venous plexus**

external to the muscular wall of the rectum. Although these plexuses bear the term *rectal*, they are primarily “anal” in terms of location, function, and clinical significance (see “Venous and Lymphatic Drainage of the Anal Canal,” later in this chapter).

Lymphatic vessels from the superior half of the rectum pass to the **pararectal lymph nodes** (located directly on the muscle layer of the rectum) and then ascend to the *inferior mesenteric lymph nodes*, either via *sacral lymph nodes* or more directly passing through nodes along the superior rectal vessels (Fig. 3.35; Table 3.6). The inferior mesenteric nodes drain into the *lumbar (caval/aortic) lymph nodes*. Lymphatic vessels from the inferior half of the rectum drain directly to *sacral lymph nodes* or, especially from the distal ampulla, follow the middle rectal vessels to drain into the *internal iliac lymph nodes*.

Innervation of the Rectum

The nerve supply to the rectum is from the sympathetic and parasympathetic systems (Fig. 3.36). The sympathetic supply is from the lumbar spinal cord, conveyed via lumbar splanchnic nerves and the hypogastric/pelvic plexuses and through the periarterial plexus of the inferior mesenteric and superior rectal arteries. The parasympathetic supply is from the S2–S4 spinal cord level, passing via the pelvic splanchnic nerves and the left and right inferior hypogastric plexuses to the rectal (pelvic) plexus. Because the rectum is inferior (distal) to the pelvic pain line, all visceral afferent fibers follow the parasympathetic fibers retrogradely to the S2–S4 spinal sensory ganglia.

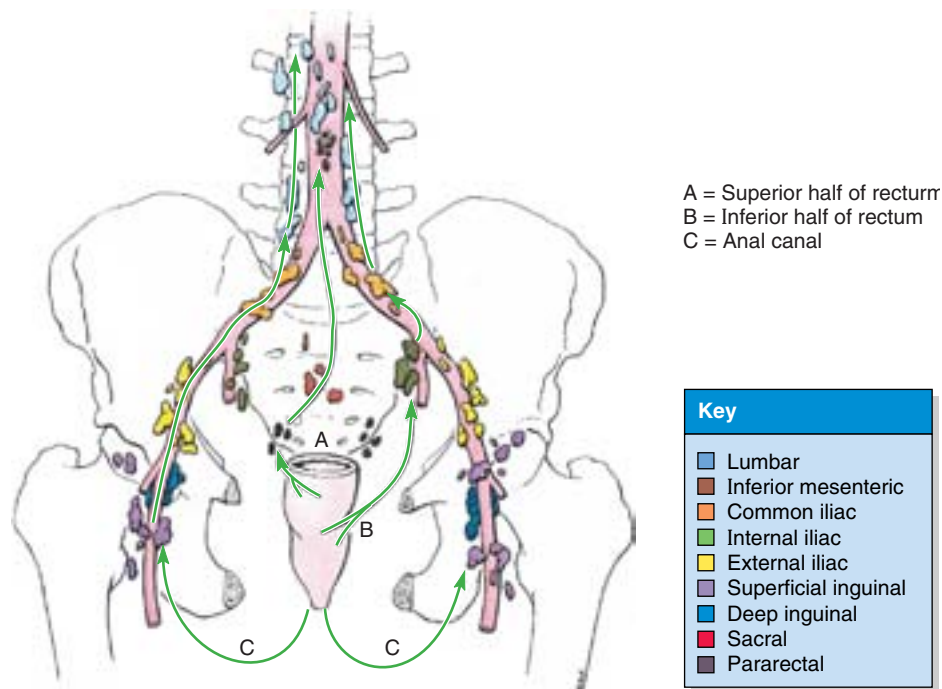


Figure 3.35. Lymphatic drainage of rectum and anal canal. The arrows indicate the direction of lymph flow to the lymph nodes.

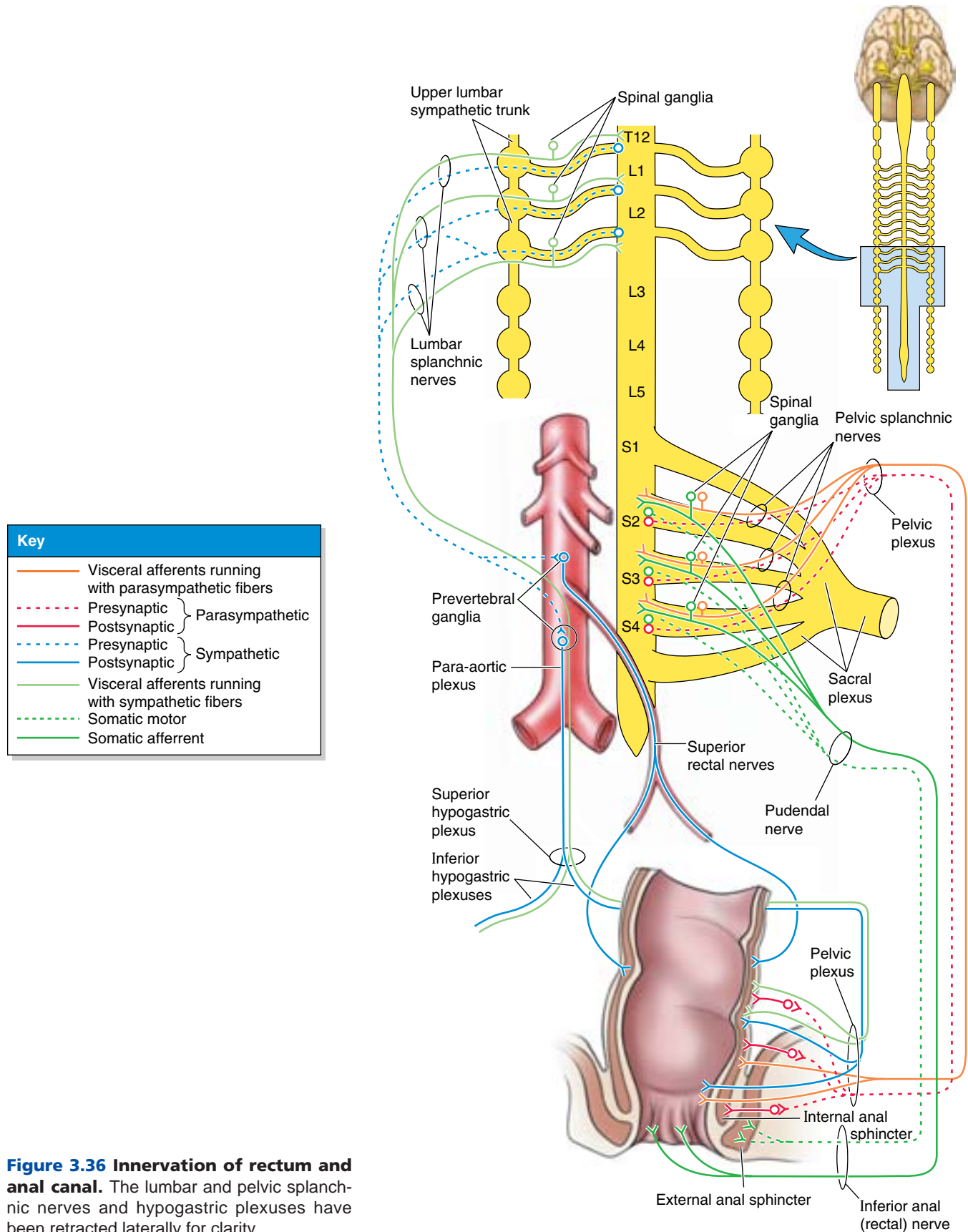


Figure 3.36 Innervation of rectum and anal canal. The lumbar and pelvic splanchnic nerves and hypogastric plexuses have been retracted laterally for clarity.

Rectal Examination

Many structures related to the anteroinferior part of the rectum may be palpated through its walls (e.g., the prostate and seminal glands in males and the cervix in females). In both sexes, the pelvic surfaces of the sacrum and coccyx may be palpated. The ischial spines and tuberosities may also be palpated. Enlarged internal iliac lymph nodes, pathological thickening of the ureters, swellings in the ischioanal fossae (e.g., ischioanal abscesses and abnormal contents in the rectovesical pouch in the male or the rectouterine pouch in the female) may also be palpated. Tenderness of an inflamed appendix may also be detected rectally if it descends into the lesser pelvis (pararectal fossa).

The internal aspect of the rectum can be examined with a *proctoscope*, and biopsies of lesions may be taken through this instrument. During insertion of a *sigmoidoscope*, the curvatures of the rectum and its acute flexion at the rectosigmoid junction have to be kept in mind so that the patient does not undergo unnecessary discomfort. The operator must also know that the *transverse rectal folds*, which provide useful landmarks for the procedure, may temporarily impede passage of these instruments.

Resection of the Rectum

When resecting the rectum in males (e.g., during cancer treatment), the plane of the rectovesical septum (a fascial septum extending superiorly from the perineal body) is located so that the prostate and urethra can be separated from the rectum. In this way, these organs are not damaged during the surgery. ❖

THE BOTTOM LINE: The rectum accumulates and temporarily stores feces. It begins at the rectosigmoid junction as the teniae of the sigmoid colon spread and unite into a continuous longitudinal layer of smooth muscle and the omental appendices cease. It ends with the anorectal flexure as the gut penetrates the pelvic diaphragm, becoming the anal canal. Despite the Latin meaning of the term (straight), the rectum is concave anteriorly as the sacral flexure and has three lateral flexures formed in relation to the internal transverse rectal folds. The rectum enlarges into the rectal ampulla directly above the pelvic floor. Its superior, middle, and inferior parts are, respectively, intraperitoneal, retroperitoneal, and subperitoneal. Collateral arterial circulation and a portocaval venous anastomosis result from anastomoses of the superior and middle rectal vessels. Lymphatic vessels from the superior rectum pass

to inferior mesenteric lymph nodes, many passing through pararectal nodes en route; those from the inferior rectum drain to sacral and internal iliac nodes. Sympathetic nerve fibers pass to the rectum (especially blood vessels and internal anal sphincter) from lumbar spinal cord segments via the hypogastric/pelvic plexuses and the periarterial plexus of the superior rectal artery. Parasympathetic and visceral afferent fibers involve the middle sacral spinal cord segments and spinal ganglia.

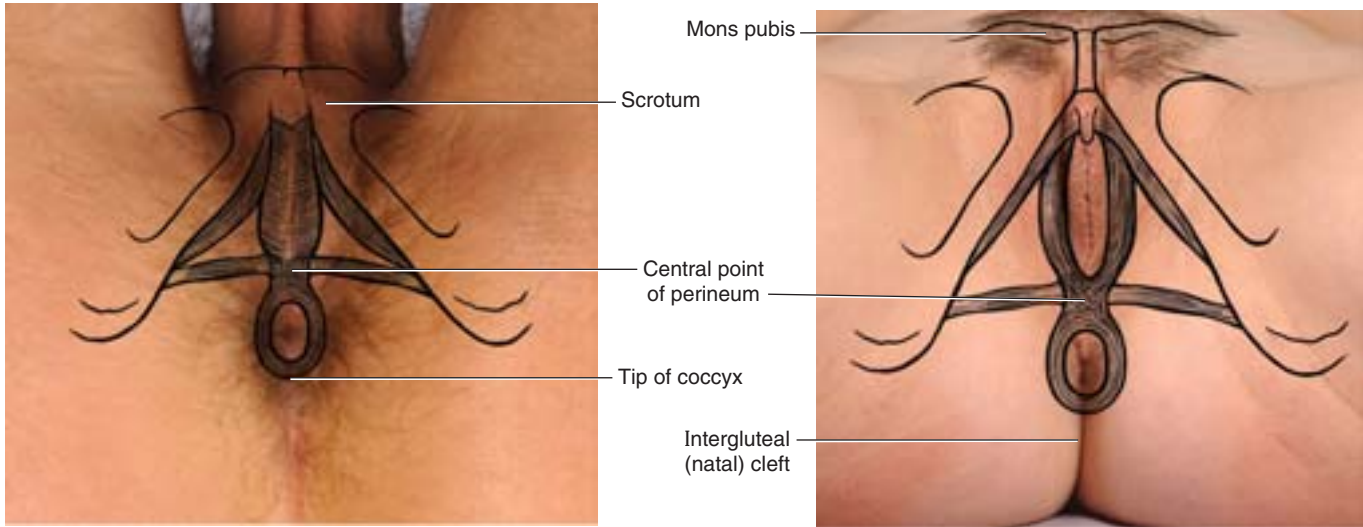
Perineum

The **perineum** refers to both an external surface area and a shallow “compartment” of the body. The perineum (*perineal compartment*) is bounded by the pelvic outlet and is separated from the pelvic cavity by the pelvic diaphragm, which is formed by the levator ani and coccygeus muscles. In the anatomical position, the surface of the perineum (*perineal area*) is the narrow region between the proximal parts of the thighs; however, when the lower limbs are abducted, it is a diamond-shaped area extending from the mons pubis anteriorly, the medial surfaces (insides) of the thighs laterally, and the gluteal folds and superior end of the intergluteal (natal) cleft posteriorly (Fig. 3.37).

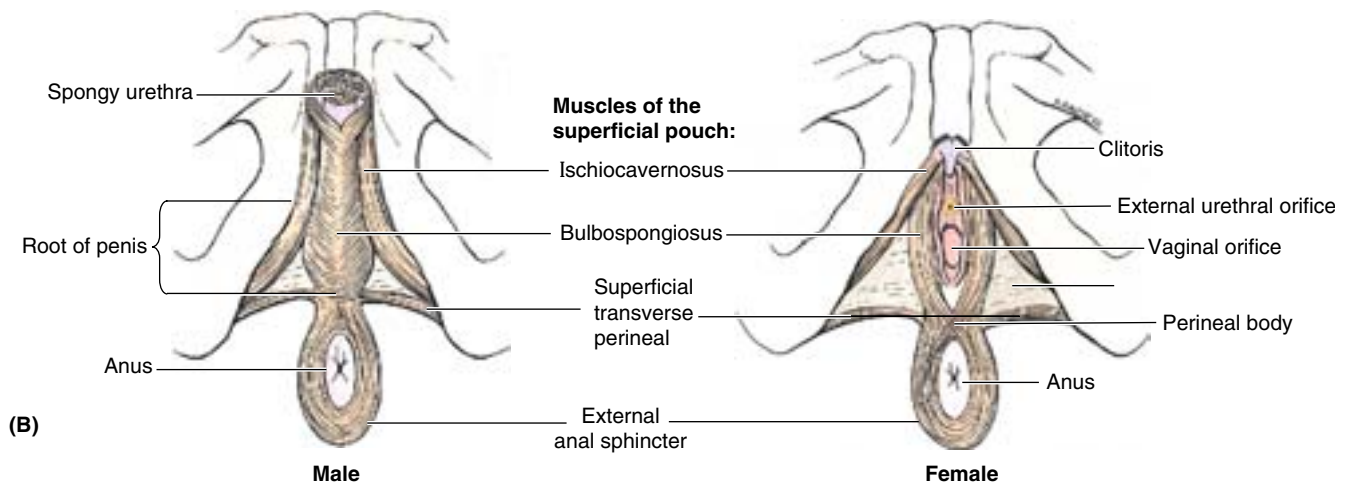
The osseofibrous structures marking the boundaries of the perineum (perineal compartment) (Fig. 3.38) are the:

- *Pubic symphysis*, anteriorly.
- *Inferior pubic rami* and *ischial rami*, anterolaterally.
- *Ischial tuberosities*, laterally.
- *Sacrospinous ligaments*, posterolaterally.
- Inferiormost *sacrum* and *coccyx*, posteriorly.

A transverse line joining the anterior ends of the ischial tuberosities divides the diamond-shaped perineum into two triangles, the oblique planes of which intersect at the transverse line (Fig. 3.38A & B). The **anal triangle** lies posterior to this line. The anal canal and its orifice, the anus, constitute the major deep and superficial features of the triangle, lying centrally surrounded by ischioanal fat. The **urogenital (UG) triangle** is anterior to this line. In contrast to the open anal triangle, the UG triangle is “closed” by a thin sheet of tough, deep fascia, the **perineal membrane**, which stretches between the two sides of the pubic arch, covering the anterior part of the pelvic outlet (Fig. 3.39C). The perineal membrane thus fills the anterior gap in the pelvic diaphragm (the urogenital hiatus, Fig. 3.39A) but is perforated by the urethra in both sexes and by the vagina of the female. The membrane and the ischiopubic rami to which it attaches provide a foundation for the erectile bodies of the external genitalia—the penis and scrotum of males and the vulva of females—which are the superficial features of the triangle (Fig. 3.37).

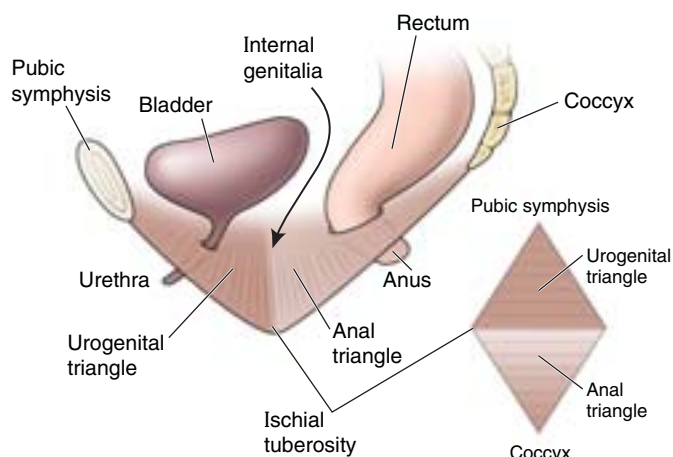


(A)

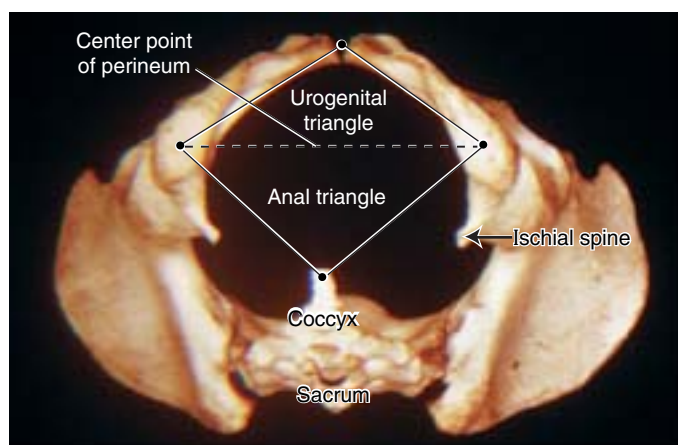


(B)

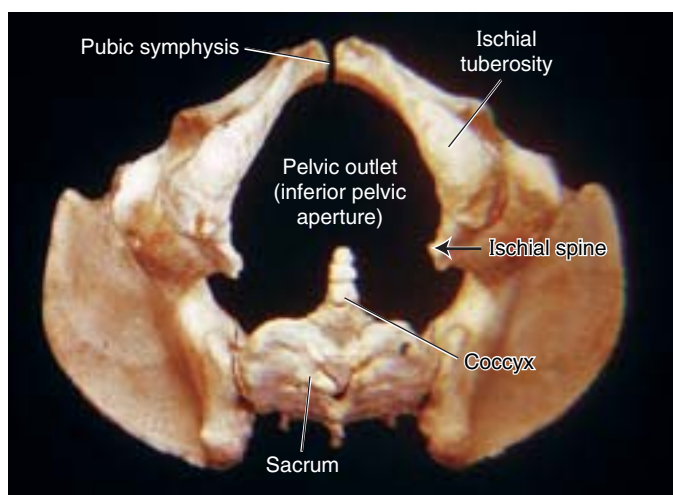
Figure 3.37. Male and female perineum. A. Surface features and projections of the osseous boundaries and structures in the perineal compartment. The penis and some of the scrotum (part of the perineum) are retracted anteriorly and thus not shown. B. The muscles of the superficial perineal pouch (space) are shown, corresponding to the projected structures in part A.



(A)



(B) Female



(C) Male

Figure 3.38. Disposition and boundaries of perineum.

A. The diamond-shaped perineum overlies the pelvic outlet; the perineum and outlet are bounded by the same osseofibrous structures. The two triangles (urogenital and anal) that together make up the perineum do not occupy the same plane. **B.** This view of the female pelvis is the one that the obstetrician visualizes in his or her mind's eye when the patient is on the examining table. **C.** The features bounding the pelvic outlet and perineum are identified on this male pelvis.

The midpoint of the line joining the ischial tuberosities is the **central point of the perineum** (Figs. 3.37A and 3.38A). This is the location of the **perineal body**, which is an irregular mass, variable in size and consistency and containing collagenous and elastic fibers and both skeletal and smooth muscle (Fig. 3.37B). The perineal body lies deep to the skin, with relatively little overlying subcutaneous tissue, posterior to the vestibule or bulb of the penis and anterior to the anus and anal canal. The perineal body is the site of convergence and interlacing of fibers of several muscles, including the:

- Bulbospongiosus.
- External anal sphincter.
- Superficial and deep transverse perineal muscles.
- Smooth and voluntary slips of muscle from the external urethral sphincter, levator ani, and muscular coats of the rectum.

Anteriorly, the perineal body blends with the posterior border of the perineal membrane (Fig. 3.39D & E) and superiorly with the rectovesical or rectovaginal septum.

Disruption of the Perineal Body

The perineal body is an especially important structure in women because it is the final support of the pelvic viscera, linking muscles that extend across the pelvic outlet, like crossing beams supporting the overlying pelvic diaphragm. Stretching or tearing the attachments of perineal muscles from the perineal body can occur during childbirth, removing support from the pelvic floor. As a result, *prolapse of pelvic viscera*, including prolapse of the bladder (through the urethra) and prolapse of the uterus and/or vagina (through the vaginal orifice) may occur. (Various degrees of prolapse are illustrated in clinical correlation [blue] box “Disposition of the Uterus and Uterine Prolapse,” in this chapter). The perineal body can also be disrupted by trauma, inflammatory disease, and infection, which can result in the formation of a *fistula* (abnormal canal) connected to the vestibule (see clinical correlation [blue] box “Vaginal Fistulae,” in this chapter). Attenuation of the perineal body, associated with diastasis (separation) of the puborectalis and pubococcygeus parts of the levator ani, may also result in the formation of a *cystocele*, *rectocele*, and/or *enterocele*, hernial protrusions of part of the bladder, rectum, or rectovaginal pouch, respectively, into the vaginal wall (Fig. B3.23). ▶

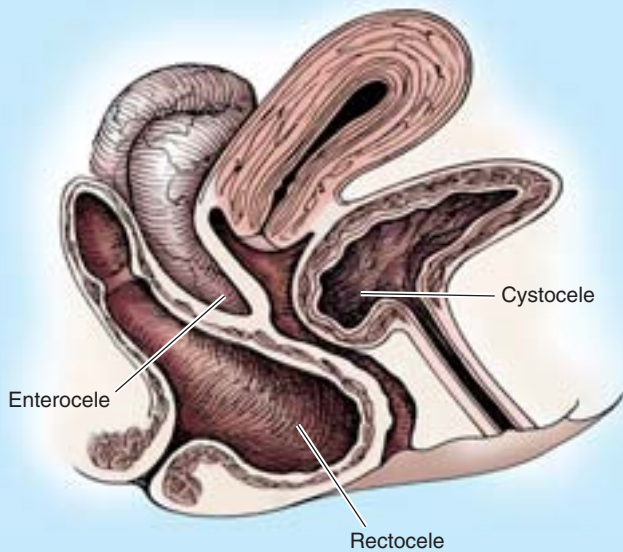
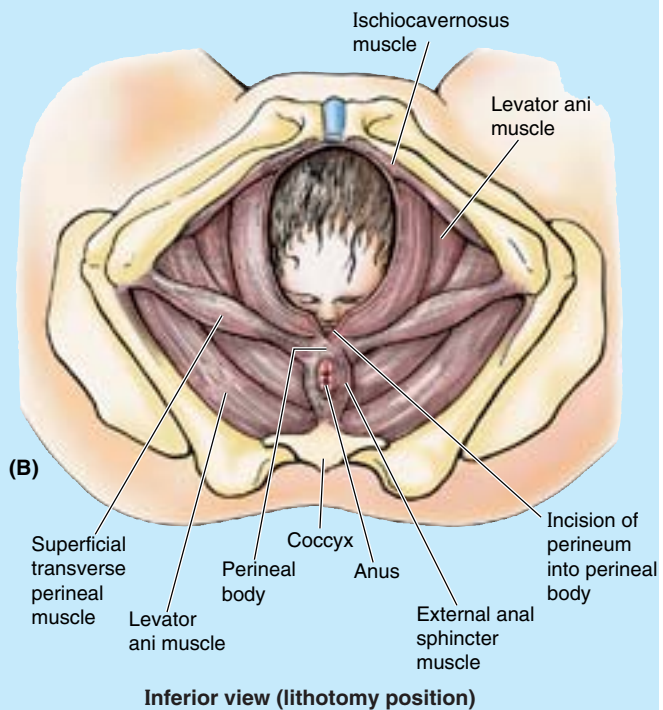
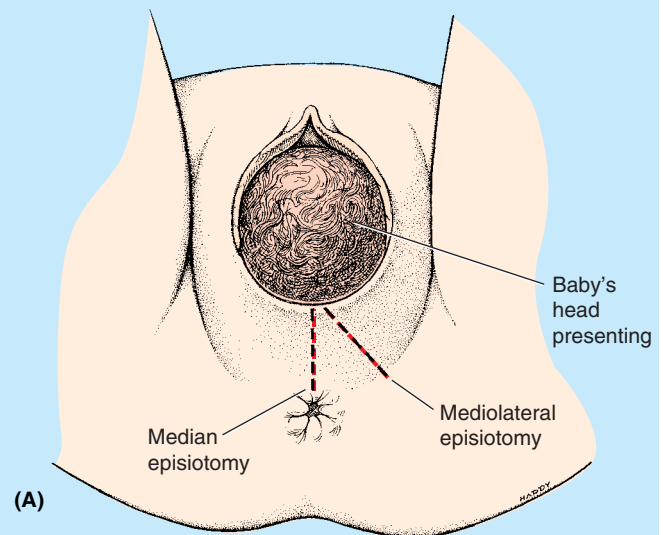


Figure B3.23

Episiotomy

During vaginal surgery and labor, an **episiotomy** (surgical incision of the perineum and inferoposterior vaginal wall) is often made to enlarge the vaginal orifice. It was long held that episiotomy decreases the prevalence of excessive perineal body attenuation and decreases trauma to the pelvic diaphragm, preventing jagged tears of the perineal muscles. Episiotomies are still performed in > 50% of vaginal deliveries in the United States (Gabbe et al., 2002). It is generally agreed that episiotomy is indicated when descent of the fetus is arrested or protracted, when instrumentation is necessary (e.g., use of obstetrical forceps), or to expedite delivery when there are signs of fetal distress. However, routine prophylactic episiotomy is widely debated.

The perineal body is the major structure incised during a **median episiotomy** (Fig. B3.24A). The rationale of the median incision is that the scar produced as the wound heals will not be greatly different from the fibrous tissue surrounding it. Also, because the incision extends only partially into this fibrous tissue, some physicians believe that the incision is more likely to be self-limiting, resisting further tearing. However, when further tearing does occur, it is directed toward the anus, and sphincter damage or anovaginal fistulae are potential sequelae. Recent studies indicate median episiotomies are associated with an increased incidence of severe lacerations, associated in turn with an increased incidence of long-term incontinence and pelvic prolapse.



Inferior view (lithotomy position)

Figure B3.24

Mediolateral episiotomies are also performed (Fig. B3.24A). These episiotomies do not appear to increase the incidence of severe laceration and are less likely to be associated with damage to the anal sphincters and canal. (*Note: the clinical use of the term *mediolateral* is technically inappropriate here; it actually refers to an incision that is initially a median incision that then turns laterally as it proceeds posteriorly, circumventing the perineal body and directing further tearing away from the anus.*)

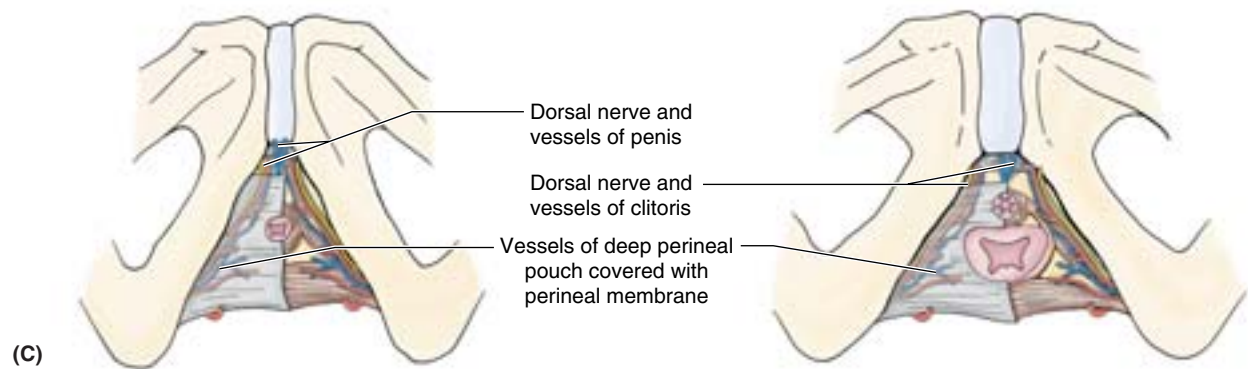
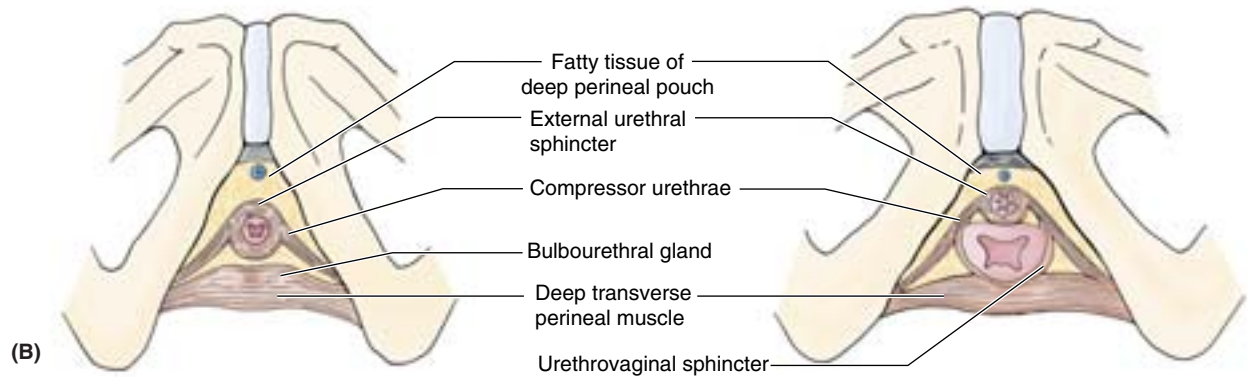
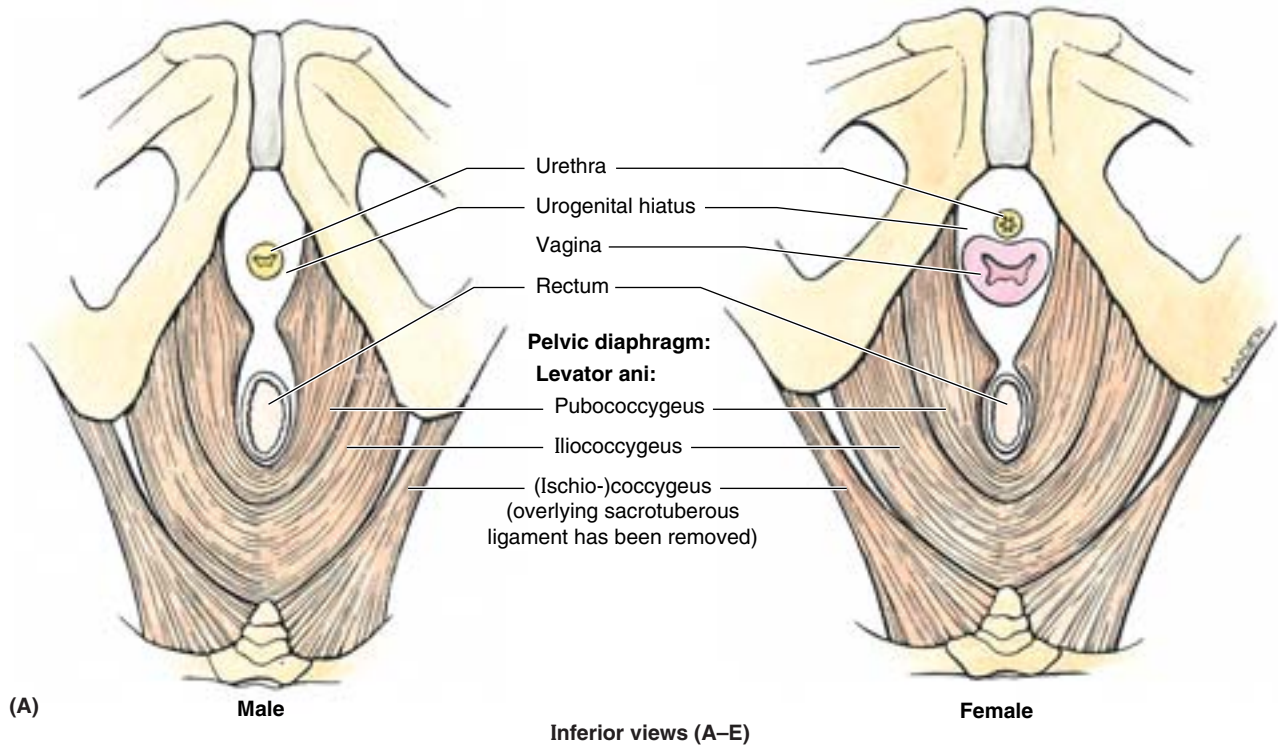


Figure 3.39. Male and female layers of perineum. The layers of the perineum are shown as being built up from deep (A) to superficial (E) layers. **A.** The pelvic outlet is almost closed by the pelvic diaphragm (levator ani and coccygeus muscles), forming the floor of the pelvic cavity and, as viewed here, the roof of the perineum. The urethra (and vagina in females) and rectum pass through the urogenital hiatus of the pelvic diaphragm. **B and C.** The external urethral sphincter and deep transverse perineal muscle span the region of the urogenital hiatus, which is closed inferiorly by the perineal membrane extending between the ischiopubic rami.

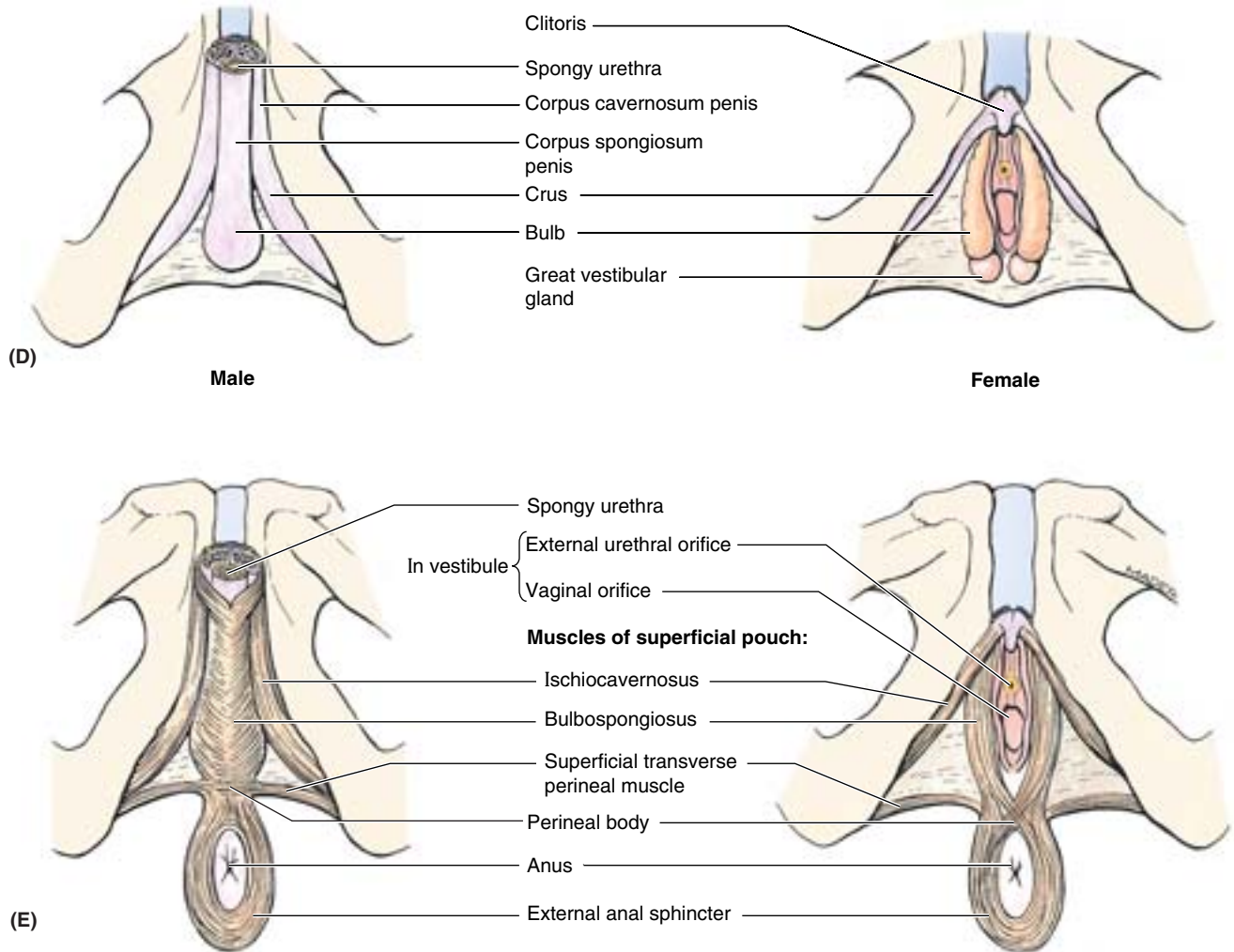


Figure 3.39 Continued. **D** and **E**. Inferior to perineal membrane, the superficial perineal pouch or space contains the erectile bodies and the muscles associated with them.

THE BOTTOM LINE: The perineum is the diamond-shaped compartment bounded peripherally by the osseofibrous pelvic outlet and deeply (superiorly) by the pelvic diaphragm. The term is also applied to the surface area overlying this compartment. The urogenital triangle (anteriorly) and anal triangle (posteriorly) that together compose this diamond-shaped area lie at angles to each other. Their intersecting planes define the transverse line (extending between ischial tuberosities) that is the base of each triangle. Centrally, the UG triangle is perforated by the urethra and, in females, by the vagina; the anal triangle is perforated by the anal canal. The perineal body is a musculofibrous mass between the UG and the anal perforating structures at the center point of the perineum.

Fasciae and Pouches of the Urogenital Triangle

Perineal Fasciae²

The perineal fascia consists of superficial and deep layers. The **subcutaneous tissue of the perineum**, or *superficial perineal fascia*, like that of the inferior anterior abdominal wall (see

²The terminology used in this section (in boldface) was recommended by the *Federative International Committee on Anatomical Terminology* (FICAT) in 1998; however, because many clinicians concerned with the perineum use eponyms, the authors have placed commonly used terms in parentheses so that the FICAT terminology will be understood by all readers.

Chapter 2) consists of a superficial *fatty layer* and a deep *membranous layer* (Colles fascia) (Fig. 3.40A & B). In females, the fatty layer makes up the substance of the labia majora and mons pubis and is continuous anteriorly and superiorly with the fatty layer of subcutaneous tissue of the abdomen (Camper fascia) (Fig. 3.40A & C). In males, the fatty layer is greatly diminished in the urogenital triangle, being replaced altogether in the penis and scrotum with smooth (dartos) muscle. It is continuous between the penis or scrotum and thighs with the fatty layer of subcutaneous tissue of the abdomen (Fig. 3.40B & E). In both sexes, the fatty layer of subcutaneous tissue of the perineum is continuous posteriorly with the ischioanal fat pad in the anal region (Fig. 3.40D).

The **membranous layer of subcutaneous tissue of the perineum** does not extend into the anal triangle, being attached posteriorly to the posterior margin of the perineal membrane and the perineal body (Fig. 3.40A & B). Laterally it is attached to the fascia lata (deep fascia) of the superiormost medial aspect of the thigh (Fig. 3.40C & E). Anteriorly in the male, the membranous layer of subcutaneous tissue is continuous with the **dartos fascia** of the penis and scrotum; however, on each side of and anterior to the scrotum, the membranous layer becomes continuous with the membranous layer of subcutaneous tissue of the abdomen (Scarpa fascia) (Fig. 3.40B). In females, the membranous layer passes superior to the fatty layer forming the labia majora and becomes continuous with the membranous layer of subcutaneous tissue of the abdomen (Fig. 3.40A & C).

The (**deep**) **perineal fascia** (investing or Gallaudet fascia) intimately invests the ischiocavernosus, bulbospongiosus, and superficial transverse perineal muscles (Fig. 3.40A & E). It is also attached laterally to the ischiopubic rami. Anteriorly it is fused to the suspensory ligament of the penis (Fig. 3.50) and is continuous with the deep fascia covering the external oblique muscle of the abdomen and the rectus sheath. In females, the perineal fascia is fused with the suspensory ligament of the clitoris and, as in males, with the deep fascia of the abdomen.

THE BOTTOM LINE: The subcutaneous tissue of the perineum includes a superficial fatty layer and a deeper membranous layer (Colles fascia), which are continuous with corresponding layers of the inferior anterior abdominal wall. In females, the fatty layer is thick within the mons pubis and labia majora, but in males, it is replaced by smooth dartos muscle in the penis and scrotum. The membranous layer is limited to the UG triangle, fusing with the deep fascia at the posterior border (base) of the triangle. In males, this layer extends into the penis and scrotum, where it is closely associated with the loose, mobile skin of those structures.

Superficial Perineal Pouch

The **superficial perineal pouch** (compartment) is a potential space between the membranous layer of subcutaneous tissue

and the perineal membrane, bounded laterally by the ischiopubic rami (Figs. 3.39D & E and 3.40).

In males, the superficial perineal pouch contains the:

- *Root* (bulb and crura) *of the penis* and associated muscles (*ischiocavernosus* and *bulbospongiosus*).
- Proximal (bulbous) part of the *spongy urethra*.
- *Superficial transverse perineal muscles*.
- *Deep perineal branches* of the internal pudendal vessels and pudendal nerves.

In females, the superficial perineal pouch contains the:

- *Clitoris* and associated muscles (*ischiocavernosus*).
- *Bulbs of the vestibule* and surrounding muscle (*bulbospongiosus*).
- *Greater vestibular glands*.
- *Superficial transverse perineal muscles*.
- Related vessels and nerves (*deep perineal branches* of the internal pudendal vessels and pudendal nerves).

The structures of the superficial perineal pouch will be discussed in greater detail, specific to each sex, under “Male Perineum” and “Female Perineum,” later in this chapter.

Deep Perineal Pouch

The **deep perineal pouch** (space) is bounded inferiorly by the perineal membrane, superiorly by the inferior fascia of the pelvic diaphragm, and laterally by the inferior portion of the obturator fascia (covering the obturator internus muscle) (Fig. 3.40C & E). It includes the fat-filled anterior recesses of the ischioanal fossa. The superior boundary in the region of the urogenital hiatus is indistinct.

In both sexes, the deep perineal pouch contains

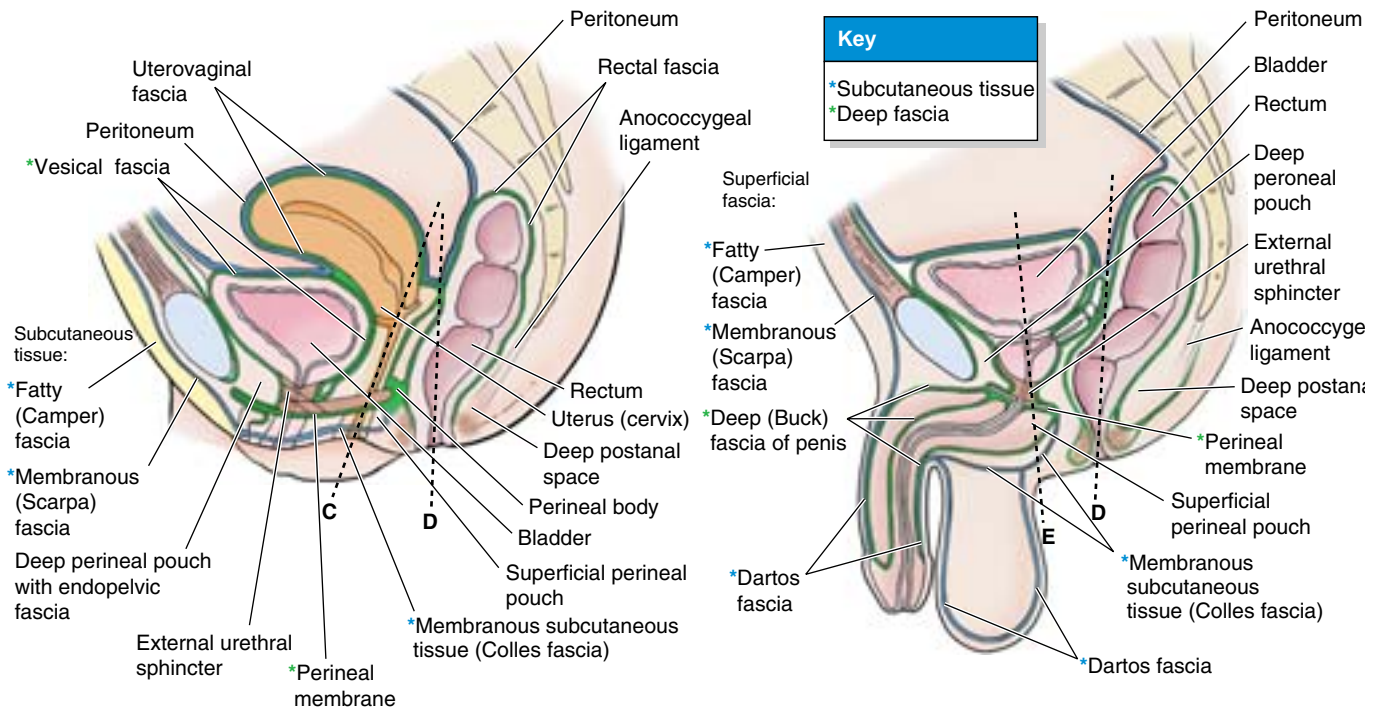
- Part of the urethra, centrally.
- The inferior part of the external urethral sphincter muscle, above the center of the perineal membrane, surrounding the urethra.
- Anterior extensions of the ischioanal fat pads.

In males, the deep perineal pouch contains the:

- *Intermediate part of the urethra*, the narrowest part of the male urethra.
- *Deep transverse perineal muscles*, immediately superior to the perineal membrane (on its superior surface), running transversely along its posterior aspect.
- *Bulbourethral glands*, embedded within the deep perineal musculature.
- Dorsal neurovascular structures of the penis.

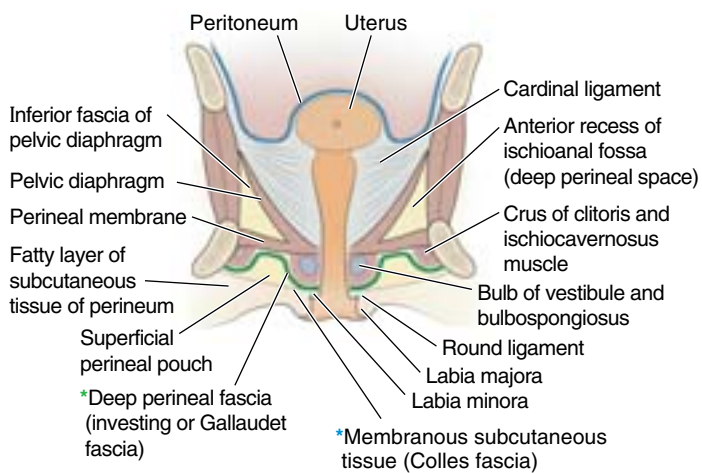
In females, the deep perineal pouch contains the:

- Proximal part of the *urethra*.

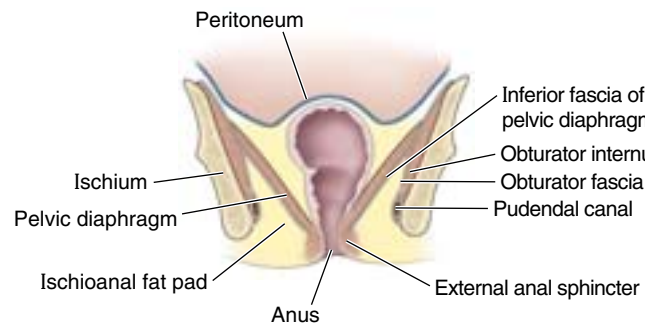


(A) Median section of female

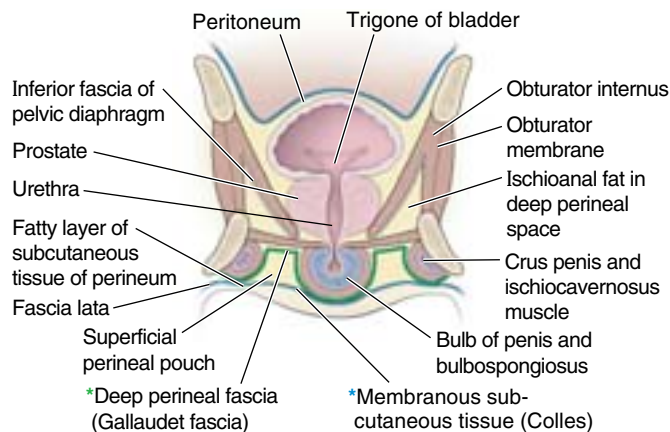
(B) Median section of male



(C) Anterior view of coronal section of female



(D) Anterior view of coronal section



(E) Anterior view of coronal section of male

Figure 3.40. Fasciae of perineum. A and B. These median sections, viewed from left, demonstrate the fasciae in the female and male. The planes of the sections shown in parts C–E are indicated. C. This coronal section of the female UG triangle is in the plane of the vagina. D. This coronal section of the anal triangle is in the plane of the lower rectal and anal canals. E. This coronal section of the male UG triangle is in the plane of the prostatic urethra.

- A mass of smooth muscle in the place of deep transverse perineal muscles on the posterior edge of the perineal membrane, associated with the perineal body.
- Dorsal neurovasculature of the clitoris.

Past and Current Concepts of Deep Perineal Pouch and External Urethral Sphincter. Traditionally, a trilaminar, triangular *UG diaphragm* has been described as making up the deep perineal pouch. Although the classical descriptions appear justified when viewing only the superficial aspect of the structures occupying the deep pouch (Fig. 3.41A), the long-held concept of a flat, essentially two-dimensional diaphragm is erroneous. According to this concept, the UG diaphragm consisted of the perineal membrane (inferior fascia of the UG diaphragm) inferiorly and a superior fascia of the UG diaphragm superiorly. The deep pouch was the space between the two fascial membranes, occupied by a flat muscular sheet consisting of a disc-like sphincter urethra anterior to or within an equally two-dimensional, transversely oriented deep transverse perineal muscle. In males, the bulbourethral glands were also considered occupants of the pouch. Only the descriptions of the perineal membrane and deep transverse perineal muscles of the male (with embedded glands) appear to be supported by evidence, which includes medical imaging of live subjects (Myers et al., 1998a, 1998b).

In the female, the posterior edge of the perineal membrane is typically occupied by a mass of smooth muscle in the place of the deep transverse perineal muscles (Wendell-Smith, 1995). Immediately superior to the posterior half of the perineal membrane, the flat, sheet-like, deep transverse perineal muscle, when developed (typically only males), offers dynamic support for the pelvic viscera. As described by Oelrich (1980), however, the urethral sphincter muscle is not a flat, planar structure, and the only “superior fascia” is the intrinsic fascia of the external urethral sphincter muscle. Contemporary views consider the *inferior fascia of the pelvic diaphragm* to be the superior boundary of the deep pouch

(Fig. 3.40C–E). In both views, the strong *perineal membrane* is the inferior boundary (floor) of the deep pouch, separating it from the superficial pouch. The perineal membrane is indeed, with the perineal body, the final passive support of the pelvic viscera.

The *external urethral sphincter* is more like a tube or trough than like a disc. In the male only the inferior part of the muscle forms a circular investment (a true sphincter) for the intermediate part of the urethra inferior to the prostate (Fig. 3.41B). Its larger, trough-like part extends vertically to the neck of the bladder as part of the isthmus of the prostate, displacing glandular tissue and investing the prostatic urethra anteriorly and anterolaterally only. Apparently, the muscular primordium is established around the whole length of the urethra before development of the prostate. As the prostate develops from urethral glands, the posterior and posterolateral muscle atrophies or is displaced by the prostate. Whether this part of the muscle compresses or dilates the prostatic urethra is a matter of some controversy.

In the female, the external urethral sphincter is more properly a “urogenital sphincter,” according to Oelrich (1983). Here, too, he describes a part forming a true anular sphincter around the urethra (Fig. 3.41C), with several additional parts extending from it: a superior part, extending to the neck of the bladder; a subdivision described as extending inferolaterally to the ischial ramus on each side (the compressor urethrae muscle); and yet another band-like part, which encircles both the vagina and the urethra (urethrovaginal sphincter). In both the male and female, the musculature described is oriented perpendicular to the perineal membrane, rather than lying in a plane parallel to it. Other authors substantiate most of Oelrich’s description but dispute the encircling of the urethra in the female, claiming that the muscle is not capable of sphincteric action. Furthermore, they assert that sectioning the perineal nerve supplying the “sphincter” does not result in incontinence, but this may be a consequence of innervation from multiple sources.

Rupture of the Urethra in Males and Extravasation of Urine

Fractures of the pelvic girdle, especially those resulting from separation of the pubic symphysis and puboprostatic ligaments, often cause a *rupture of the intermediate part of the urethra*. Rupture of this part of the urethra results in the extravasation of urine and blood into the deep perineal pouch (Fig. B3.25A); the fluid may pass superiorly through the urogenital hiatus and distribute extraperitoneally around the prostate and bladder.

The common site of *rupture of the spongy urethra* and *extravasation (escape) of urine* is in the bulb of the penis (Fig.

B3.25B). This injury usually results from a forceful blow to the perineum (*straddle injury*), such as falling on a metal beam or, less commonly, from the incorrect passage (*false passage*) of a transurethral catheter or device that fails to negotiate the angle of the urethra in the bulb of the penis. Rupture of the corpus spongiosum and spongy urethra results in urine passing from it (extravasating) into the superficial perineal space. The attachments of the perineal fascia determine the direction of flow of the extravasated urine. Urine may pass into the loose connective tissue in the scrotum, around the penis, and superiorly, deep to the membranous layer of subcutaneous connective tissue of the inferior anterior abdominal wall. ►

The urine cannot pass far into the thighs because the membranous layer of superficial perineal fascia blends with the fascia lata, enveloping the thigh muscles, just distal to the inguinal ligament. In addition, urine cannot pass posteriorly into the anal triangle because the superficial and deep layers of perineal fascia are continuous with

each other around the superficial perineal muscles and with the posterior edge of the perineal membrane between them. Rupture of a blood vessel into the superficial perineal pouch resulting from trauma would result in a similar containment of blood in the superficial perineal pouch. ❖

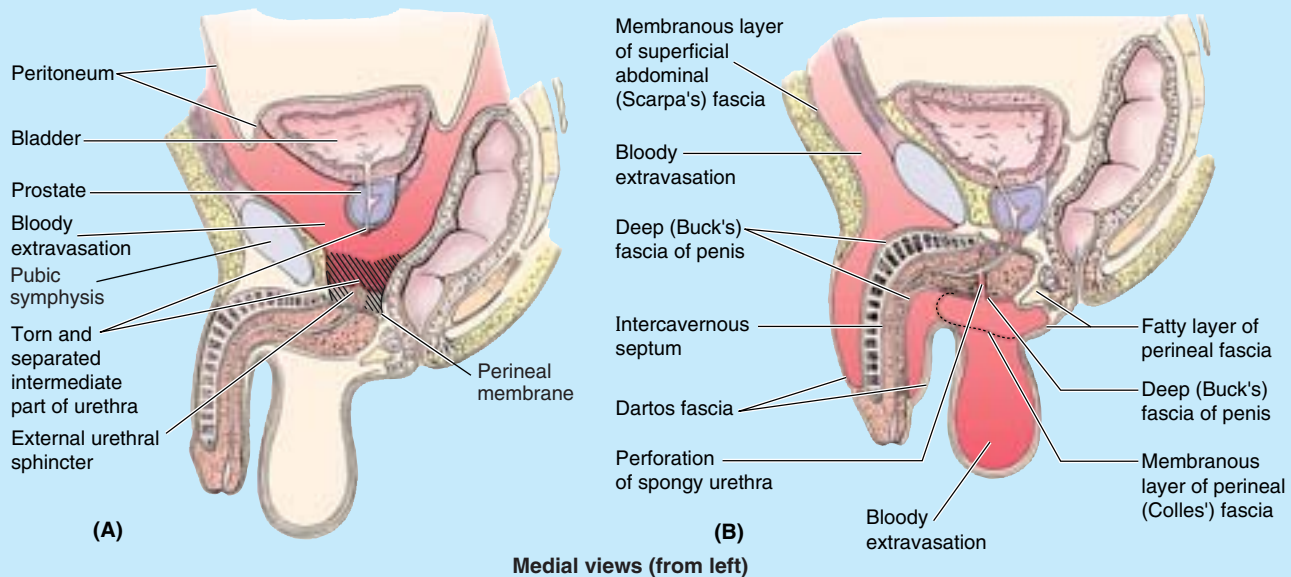


Figure B3.25

THE BOTTOM LINE: The planar perineal membrane divides the urogenital triangle of the perineum into superficial and deep perineal pouches. The superficial perineal pouch is between the membranous layer of subcutaneous tissue of the perineum and the perineal membrane and is bounded laterally by the ischiopubic rami. The deep perineal pouch is between the perineal membrane and the inferior fascia of the pelvic diaphragm and is bounded laterally by the obturator fascia. The superficial pouch contains the erectile bodies of the external genitalia and associated muscles, the superficial transverse perineal muscle, deep perineal nerves and vessels, and in females the greater vestibular glands. The deep pouch includes the fat-filled anterior recesses of the ischioanal fossae (laterally), the deep perineal muscle and inferiormost part of the external urethral sphincter, the part of the urethra traversing the perineal membrane and inferiormost external urethral sphincter (the intermediate urethra of males), the dorsal nerves of the penis/clitoris, and in males the bulbourethral glands.

Features of the Anal Triangle

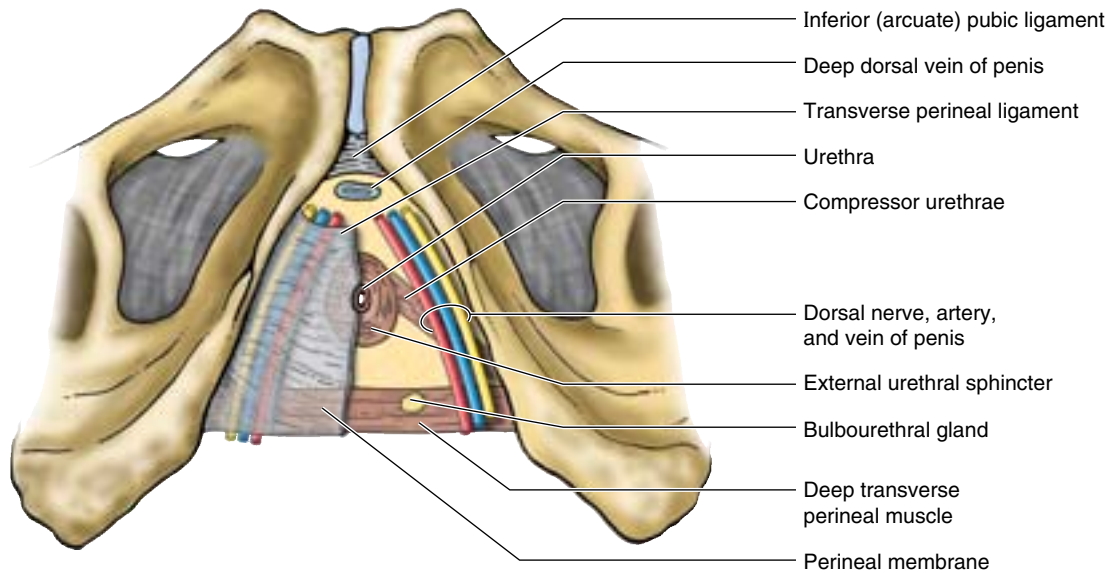
Ischioanal Fossae

The ischioanal fossae (formerly called ischiorectal fossae) on each side of the anal canal are large fascia-lined, wedge-shaped

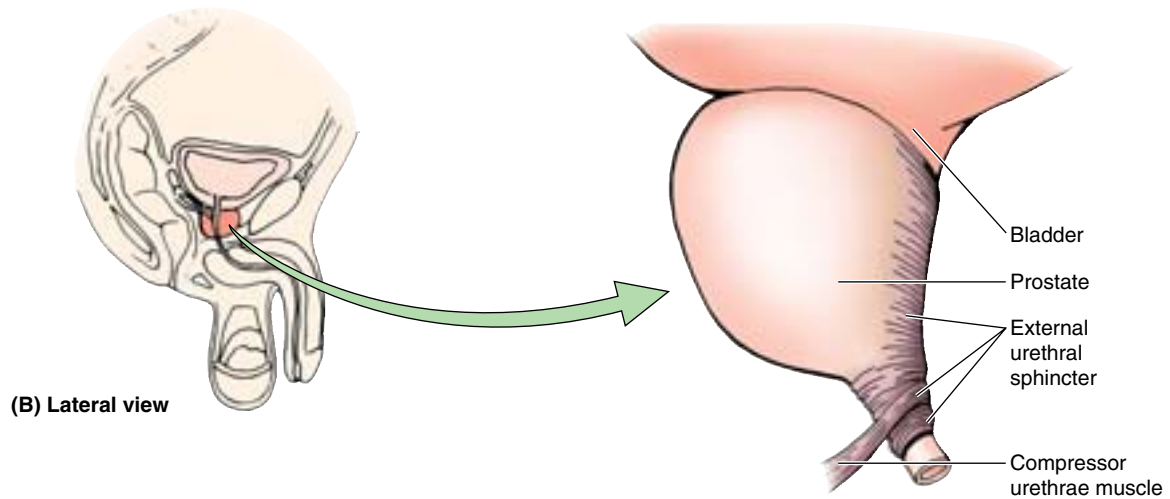
spaces between the skin of the anal region and the pelvic diaphragm (Figs. 3.40D, 3.42A, and 3.43). The apex of each fossa lies superiorly where the levator ani muscle arises from the obturator foramen. The ischioanal fossae, wide inferiorly and narrow superiorly, are filled with fat and loose connective tissue. The two ischioanal fossae communicate by means of the *deep postanal space* over the *anococcygeal ligament* (body), a fibrous mass located between the anal canal and the tip of the coccyx (Figs. 3.40A & B and 3.42B).

Each ischioanal fossa is bounded

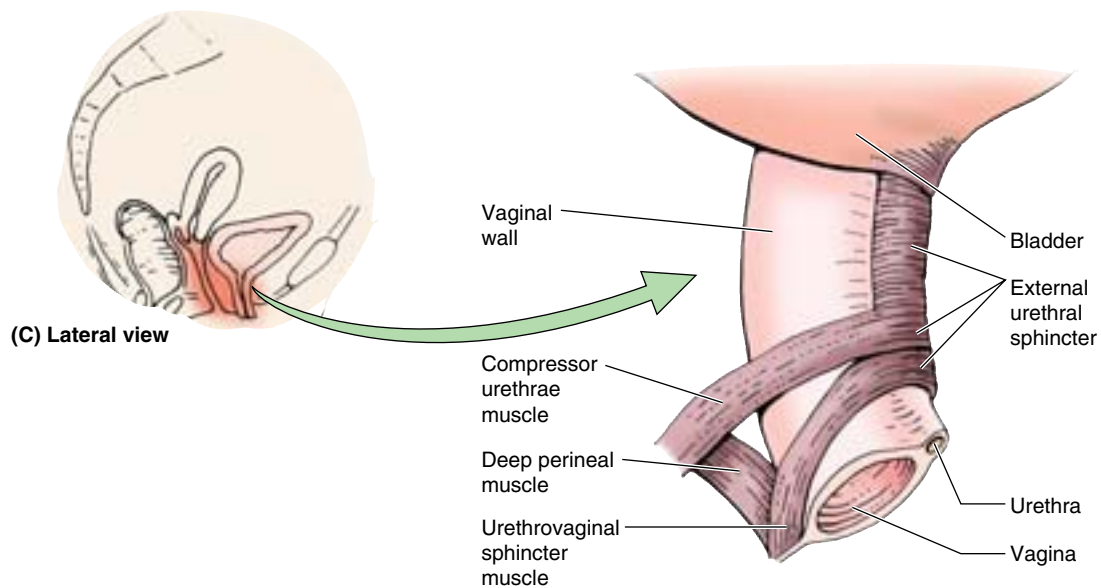
- Laterally by the ischium and overlapping inferior part of the obturator internus, covered with obturator fascia.
- Medially by the external anal sphincter, with a sloping superior medial wall or roof formed by the levator ani as it descends to blend with the sphincter; both structures surround the anal canal.
- Posteriorly by the sacrotuberous ligament and gluteus maximus.
- Anteriorly by the bodies of the pubic bones, inferior to the origin of the puborectalis. These parts of the fossae, extending into the UG triangle superior to the perineal membrane (and musculature on its superior surface), are known as the **anterior recesses of the ischioanal fossae**.



(A) Anteroinferior view



(B) Lateral view



(C) Lateral view

Figure 3.41. Deep perineal pouch and male and female external urethral sphincters. A. The deep perineal pouch is seen through (left side) and after removal of the perineal membrane (right side). B. The trough-like fibers of the male external urethral sphincter ascend to neck of bladder as part of isthmus of prostate. C. The female urethral sphincter is shown.

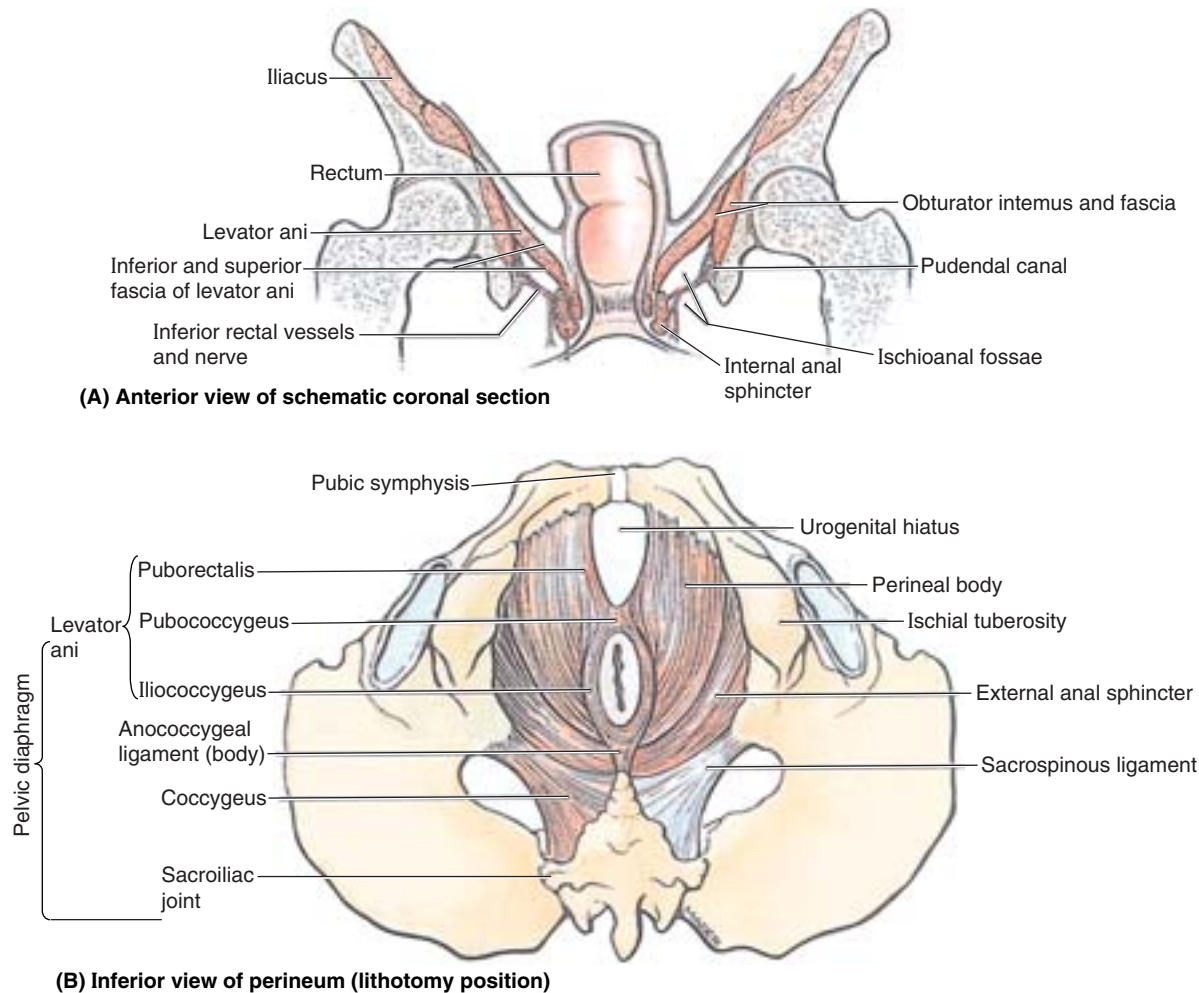


Figure 3.42. Pelvic diaphragm and ischioanal fossae. **A.** Coronal section of the pelvis in the plane of the rectum, anal canal, and ischioanal fossae. **B.** Inferior view of pelvic diaphragm in situ. Left sacrospinous ligament has been removed.

Each ischioanal fossa is filled with a **fat body of the ischioanal fossa**. These fat bodies support the anal canal but they are readily displaced to permit descent and expansion of the anal canal during the passage of feces. The fat bodies are traversed by tough, fibrous bands, as well as by several neurovascular structures, including the inferior anal/rectal vessels and nerves and two other cutaneous nerves, the perforating branch of S2 and S3 and the perineal branch of S4 nerve.

Pudendal Canal and Its Neurovascular Bundle

The **pudendal canal** (Alcock canal) is an essentially horizontal passageway within the obturator fascia that covers the medial aspect of the obturator internus and lines the lateral wall of the ischioanal fossa (Figs. 3.42A and 3.43). The internal pudendal artery and vein, the pudendal nerve, and the nerve to the obturator internus enter this canal at the lesser sciatic notch, inferior to the ischial spine. The internal pudendal vessels and the pudendal nerve supply and drain blood from and innervate, respectively, most of the perineum. As the artery and nerve enter the canal, they give rise to the **inferior rectal**

artery and nerve, which pass medially to supply the external anal sphincter and the perianal skin (Figs. 3.43 and 3.44; Table 3.8). Toward the distal (anterior) end of the pudendal canal, the artery and nerve both bifurcate, giving rise to the *perineal nerve and artery*, which are distributed mostly to the superficial pouch (inferior to the perineal membrane), and to the *dorsal artery and nerve of the penis or clitoris*, which run in the deep pouch (superior to the membrane). When the latter structures reach the dorsum of the penis or clitoris, the nerves run distally on the lateral side of the continuation of the internal pudendal artery as they both proceed to the glans.

The perineal nerve has two branches: the **superficial perineal nerves** give rise to posterior scrotal or labial (cutaneous) branches, and the **deep perineal nerve** supplies the muscles of the deep and superficial perineal pouches, the skin of the vestibule, and the mucosa of the inferiormost part of the vagina. The inferior rectal nerve communicates with the posterior scrotal or labial and perineal nerves. The **dorsal nerve of the penis or clitoris** is the primary sensory nerve serving the male or female organ, especially the sensitive glans at the distal end.

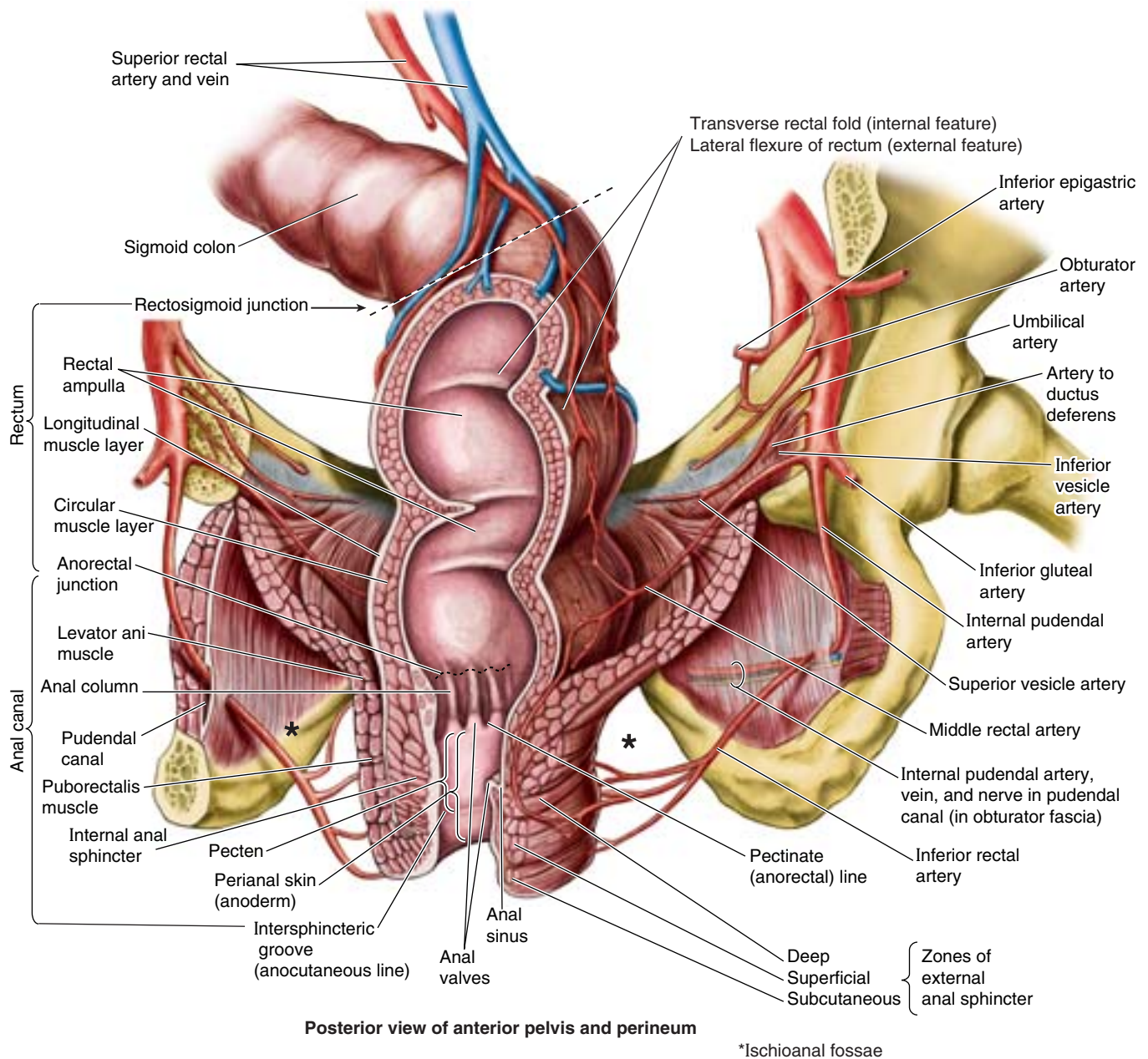


Figure 3.43. Rectum and anal canal, levator ani, and ischioanal fossa. The left posterolateral third of the rectum and anal canal have been removed to demonstrate the luminal features. The pudendal canal, the space within the obturator fascia covering the medial surface of the obturator internus and lining the lateral wall of the ischioanal fossa, transmits the pudendal vessels and nerves.

Starvation and Rectal Prolapse

The fat bodies of the ischioanal fossae, along with the buccal fat pads (see Chapter 7), are among the last reserves of fatty tissue to disappear with starvation. In the absence of the support provided by the ischioanal fat, rectal prolapse is relatively common. ❌

THE BOTTOM LINE: The ischioanal fossae are fascia-lined, wedge-shaped spaces occupied by ischioanal fat bodies. The fat bodies provide supportive packing that can be compressed or pushed aside to permit the temporary descent and expansion of the anal canal or vagina for passage of feces or a fetus. The fat bodies are traversed by inferior anal/rectal neurovasculature. The pudendal canal is an important passageway in the lateral wall of the fossa,

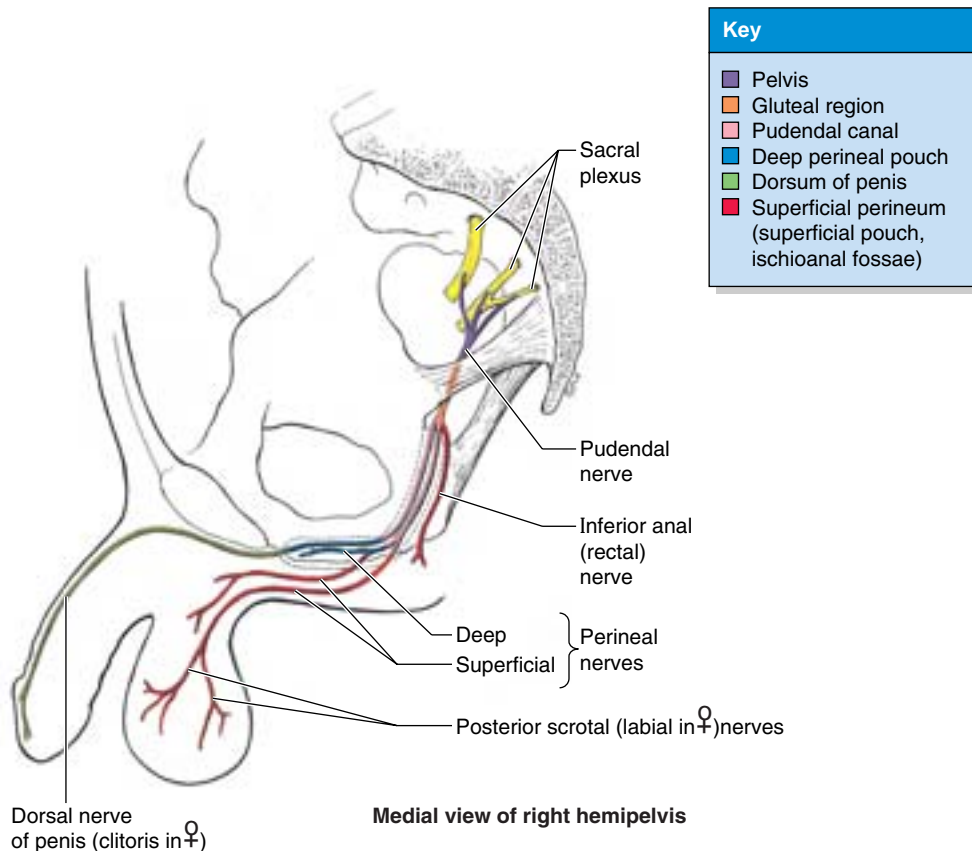


Figure 3.44. Distribution of pudendal nerve. The five regions traversed by the nerve are shown. The pudendal nerve supplies the skin, organs, and muscles of the perineum; therefore, it is concerned with micturition, defecation, erection, ejaculation, and, in the female, parturition. Although the pudendal nerve is shown here in the male, its distribution is similar in the female because the parts of the female perineum are homologs of those in the male.

between layers of the obturator fascia, for neurovasculature passing to and from the UG triangle.

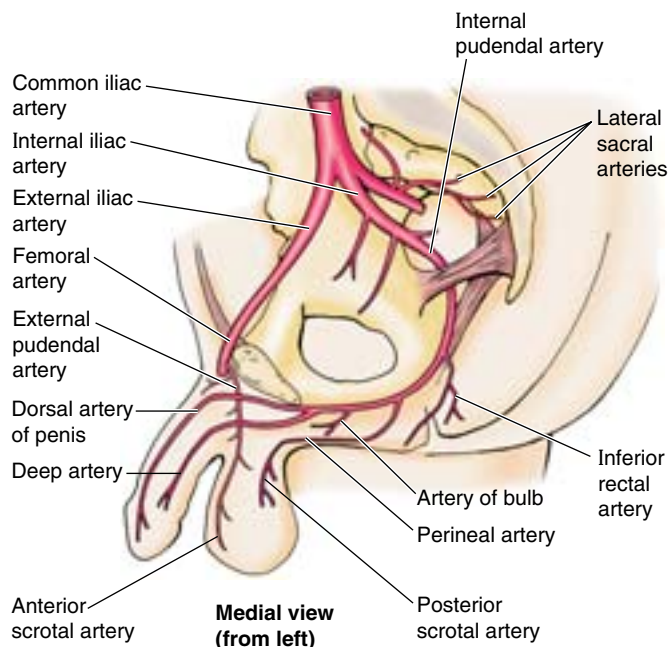
Anal Canal

The **anal canal** is the terminal part of the large intestine, and of the entire alimentary canal. It extends from the superior aspect of the pelvic diaphragm to the **anus** (Figs. 3.42B and 3.43). The canal (2.5–3.5 cm long) begins where the rectal ampulla narrows at the level of the U-shaped sling formed by the puborectalis muscle (Fig. 3.7). The canal ends at the anus, the external outlet of the alimentary tract. The anal canal, surrounded by internal and external anal sphincters, descends posteroinferiorly between the anococcygeal ligament and the perineal body. The canal is collapsed, except during passage of feces. Both sphincters must relax before defecation can occur.

The **internal anal sphincter** (Figs. 3.42A and 3.43) is an involuntary sphincter surrounding the superior two thirds of the anal canal. It is a thickening of the circular muscle layer. Its contraction (tonus) is stimulated and maintained by sympathetic fibers from the superior rectal (periarterial) and hypogastric plexuses; its contraction is inhibited by parasymp-

athetic fiber stimulation, both intrinsically in relation to peristalsis and extrinsically by fibers passing through the pelvic splanchnic nerves. This sphincter is tonically contracted most of the time to prevent leakage of fluid or flatus; however, it relaxes (is inhibited) temporarily in response to distension of the rectal ampulla by feces or gas, requiring voluntary contraction of the puborectalis and external anal sphincter if defecation or flatulence is not to occur. The ampulla relaxes after initial distension (when peristalsis subsides) and tonus returns until the next peristalsis or until a threshold level of distension occurs, at which point inhibition of the sphincter is continuous until distension is relieved.

The **external anal sphincter** is a large voluntary sphincter that forms a broad band on each side of the inferior two thirds of the anal canal (Figs. 3.39E, 3.42, and 3.43). This sphincter is attached anteriorly to the perineal body and posteriorly to the coccyx via the anococcygeal ligament (body); it blends superiorly with the puborectalis muscle. For descriptive purposes, it is described as having subcutaneous, superficial, and deep parts; these are zones rather than muscle bellies and are often indistinct. The external anal sphincter is supplied mainly by S4 through the inferior rectal nerve (Fig. 3.44),

Table 3.8. Arteries of the Perineum

Artery	Origin	Course	Distribution in Perineum
Internal pudendal	Anterior division of internal iliac artery	Leaves pelvis through greater sciatic foramen; hooks around ischial spine to enter perineum via lesser sciatic foramen; immediately enters pudendal canal	Primary artery of perineum and external genital organs
Inferior rectal	Internal pudendal artery	Arises at entrance to pudendal canal; traverses ischioanal fossa to anal canal	Anal canal inferior to pectinate line; anal sphincters; perianal skin
Perineal	Terminal branch of perineal artery	Arises within pudendal canal; passes to superficial pouch (space) on exit	Supplies superficial perineal muscles and scrotum of male/vestibule of female
Posterior scrotal or labial	Terminal branch of perineal artery	Runs in superficial fascia of posterior scrotum or labia majora	Skin of scrotum or labia majora and minora
Artery of bulb of penis or vestibule	Terminal branch	Pierces perineal membrane to reach bulb of penis or vestibule	Supplies bulb of penis (including bulbar urethra) and bulbourethral gland (male) or bulb of vestibule and greater vestibular gland (female)
Deep artery of penis or clitoris	Terminal branch	Pierces perineal membrane to enter crura of corpora cavernosa of penis or clitoris; branches run proximally and distally	Supplies most erectile tissue of corpora cavernosa of penis or clitoris via helicine arteries
Dorsal artery of penis or clitoris		Passes to deep pouch; pierces perineal membrane and traverses suspensory ligament of penis or clitoris to run along dorsum of penis or clitoris to glans	Deep perineal pouch; skin of penis; fascia of penis or clitoris; distal corpus spongiosum of penis, including spongy urethra; glans of penis or clitoris
External pudendal, superficial, and deep branches	Femoral artery	Pass medially from thigh to reach anterior aspect of the urogenital triangle of perineum	Anterior aspect of scrotum and skin at root of penis of male; mons pubis and anterior aspect of labia of female

although its deep part also receives fibers from the nerve to the levator ani, in common with the puborectalis, with which it contracts in unison to maintain continence when the internal sphincter is relaxed (except during defecation).

Internally, the superior half of the mucous membrane of the anal canal is characterized by a series of longitudinal ridges called **anal columns** (Fig. 3.43). These columns contain the terminal branches of the superior rectal artery and vein. The **anorectal junction**, indicated by the superior ends of the anal columns, is where the rectum joins the anal canal. At this point, the wide rectal ampulla abruptly narrows as it traverses the pelvic diaphragm. The inferior ends of the anal columns are joined by **anal valves**. Superior to the valves are small recesses called **anal sinuses**. When compressed by feces, the anal sinuses exude mucus, which aids in evacuation of feces from the anal canal. The inferior comb-shaped limit of the anal valves forms an irregular line (the **pectinate line**), which indicates the junction of the superior part of the anal canal (visceral; derived from the embryonic hindgut) and the inferior part (somatic; derived from the embryonic proctodeum).

The anal canal superior to the pectinate line differs from the part inferior to the pectinate line in its arterial supply, innervation, and venous and lymphatic drainage (Fig. 3.45). These differences result from the different embryological origins of the superior and inferior parts of the anal canal (Moore and Persaud, 2003).

Arterial Supply of the Anal Canal. The *superior rectal artery* supplies the anal canal superior to the pectinate line (Figs. 3.34A and 3.45). The two *inferior rectal arteries* supply the inferior part of the anal canal as well as the surrounding muscles and perianal skin. The *middle rectal arteries* assist with the blood supply to the anal canal by forming anastomoses with the superior and inferior rectal arteries.

Venous and Lymphatic Drainage of the Anal Canal.

The *internal rectal venous plexus* drains in both directions from the level of the pectinate line. Superior to the pectinate line, the internal rectal plexus drains chiefly into the *superior rectal vein* (a tributary of the inferior mesenteric vein) and the portal system (Figs. 3.34B and 3.45). Inferior to the pectinate line, the internal rectal plexus drains into the *inferior rectal veins* (tributaries of the caval venous system) around the margin of the external anal sphincter. The *middle rectal veins* (tributaries of the internal iliac veins) mainly drain the muscularis externa of the ampulla and form anastomoses with the superior and inferior rectal veins. In addition to the abundant venous anastomoses, the rectal plexuses receive multiple arteriovenous anastomoses (AVAs) from the superior and middle rectal arteries.

The normal submucosa of the anorectal junction is markedly thickened and in section has the appearance of cavernous (erectile) tissue owing to the presence of the sacculated veins of the internal rectal venous plexus. The vascular submucosa is especially thickened in the left lateral, right anterolateral, and right posterolateral positions, forming “anal cushions” (also referred to as threshold pads, corpora cavernosa recti, and anorectal cavernous bodies) at the point of closure of the anal canal. Because these cushions contain plexuses of saccular veins capable of directly receiving arterial blood via multiple AVAs, they are variably pliable and turgid and form a sort of flutter valve that contributes to the normally water- and gas-tight closure of the anal canal.

Superior to the pectinate line, the lymphatic vessels drain deeply into the *internal iliac lymph nodes* and through them into the common iliac and lumbar lymph nodes (Figs. 3.35 and 3.47). Inferior to the pectinate line, the lymphatic vessels drain superficially into the **superficial inguinal lymph nodes**, as does most of the perineum (Table 3.6).

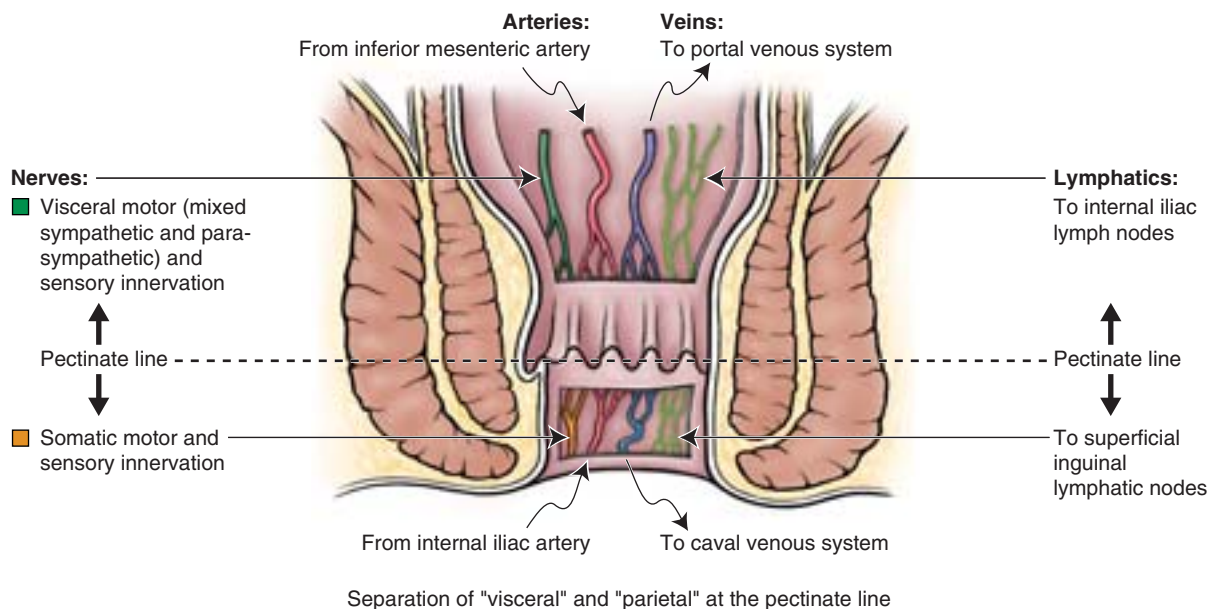


Figure 3.45. Changes occurring at pectinate line. Vessels and nerves superior to the pectinate line are visceral; those inferior to the pectinate line are parietal or somatic. This orientation reflects the embryological development of the anorectum.

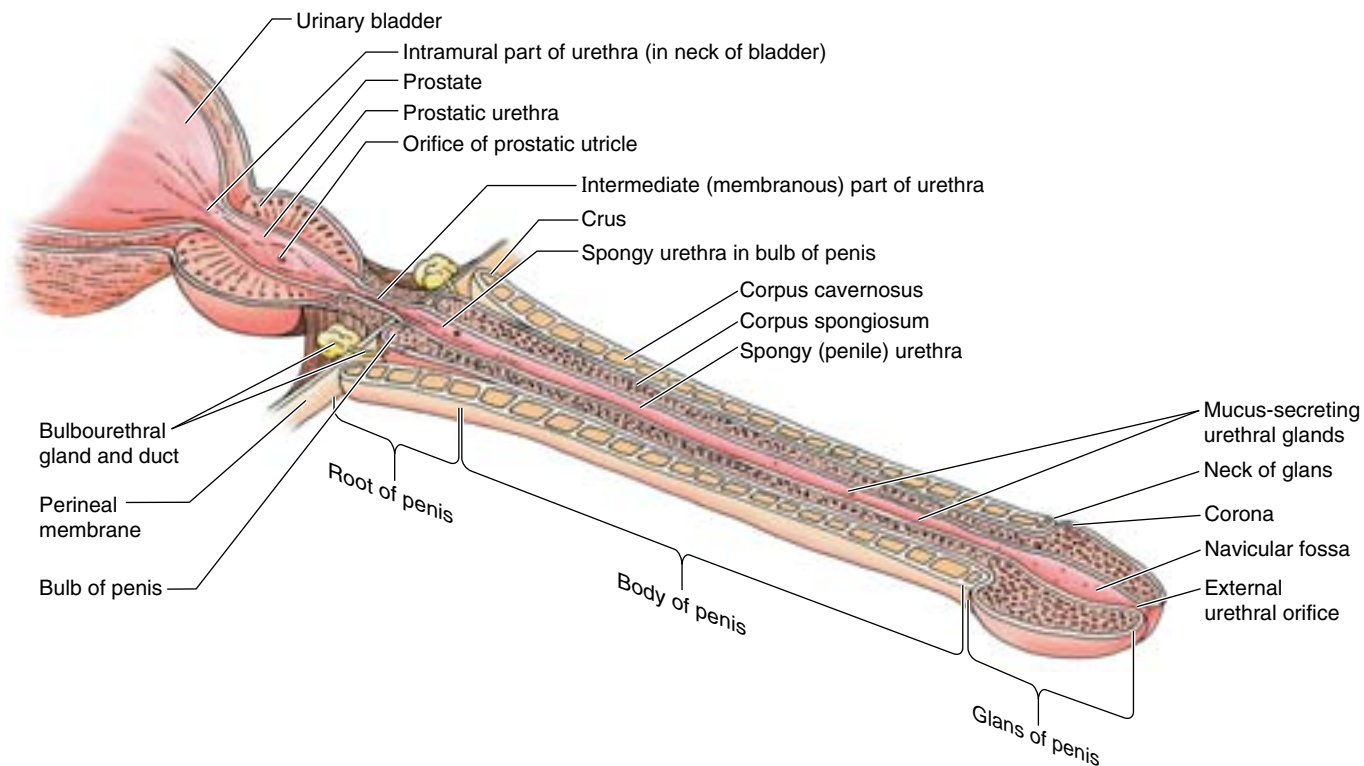


Figure 3.46 Male urethra and associated structures. The urethra has four parts: the vesicular part (in the bladder neck), the prostatic urethra, the intermediate part (membranous urethra), and the spongy (cavernous) urethra. The ducts of the bulbourethral glands open into the proximal part of the spongy urethra. The urethra is not uniform in its caliber: the external urethral orifice and intermediate part are narrowest. Attempting to approach this “straight-line” position as much as possible facilitates passage of a catheter or other transurethral device.

Innervation of the Anal Canal. The nerve supply to the anal canal superior to the pectinate line is visceral innervation from the *inferior hypogastric plexus*, involving sympathetic, parasympathetic, and visceral afferent fibers (Figs. 3.36 and 3.45). Sympathetic fibers maintain the tonus of the internal anal sphincter. Parasympathetic fibers inhibit the tonus of the internal sphincter and evoke peristaltic contraction for defecation. The superior part of the anal canal, like the rectum superior to it, is inferior to the pelvic pain line; all visceral afferents travel with the parasympathetic fibers to spinal sensory ganglia S2–S4. Superior to the pectinate line, the anal canal is sensitive only to stretching, which evokes sensations at both the conscious and the unconscious (reflex) levels. For example, distension of the rectal ampulla inhibits (relaxes) the tonus of the internal sphincter. The nerve supply of the anal canal inferior to the pectinate line is somatic innervation derived from the *inferior anal (rectal) nerves*, branches of the pudendal nerve. Therefore, this part of the anal canal is sensitive to pain, touch, and temperature. Somatic efferent fibers stimulate contraction of the voluntary external anal sphincter.

The Pectinate Line—A Clinically Important Landmark

The *pectinate line* (also called the dentate or mucocutaneous line by some clinicians) is a particularly important landmark because it is visible and approximates the level of important anatomical changes related to the transition from visceral to parietal (Fig. 3.45), affecting such things as the types of tumors that occur, and the direction in which they metastasize.

Anal Fissures and Perianal Abscesses

The ischioanal fossae are occasionally the sites of infection, which may result in the formation of **ischioanal abscesses** (Fig. B3.26A). These collections of pus are ▶

quite painful. Infections may reach the ischioanal fossae in several ways:

- After *cryptitis* (inflammation of the anal sinuses).
- Extension from a pelvirectal abscess.
- After a tear in the anal mucous membrane.
- From a penetrating wound in the anal region.

Diagnostic signs of an ischioanal abscess are fullness and tenderness between the anus and the ischial tuberosity. A perianal abscess may rupture spontaneously, opening into the anal canal, rectum, or perianal skin.

Because the ischioanal fossae communicate posteriorly through the *deep postnatal space*, an abscess in one fossa may spread to the other one and form a semicircular “horseshoe-shaped” abscess around the posterior aspect of the anal canal. In chronically constipated persons, the anal valves and mucosa may be torn by hard feces. An **anal fissure** (slit-like lesion) is usually located in the posterior midline, inferior to the anal valves. It is painful because this region is supplied by sensory fibers of the inferior rectal nerves. **Perianal abscesses** may follow infection of anal fissures, and the infection may spread to the ischioanal fossae and form ischioanal abscesses or spread into the pelvis and form **pelvirectal abscesses**. An *anal fistula* may result from the spread of an anal infection and cryptitis. One end of this abnormal canal (fistula) opens into the anal canal and the other end opens into an abscess in the ischioanal fossa or into the perianal skin.

Hemorrhoids

Internal hemorrhoids (piles) are prolapses of rectal mucosa (more specifically, of the so-called rectal cushions) containing the normally dilated veins of the *internal rectal venous plexus* (Fig. B3.26B). Internal hemorrhoids are thought to result from a breakdown of the muscularis mucosae, a smooth muscle layer deep to the mucosa. They occur quite predictably in the left lateral, right anterolateral, and right posterolateral positions (positions of anal cushions). Internal hemorrhoids that prolapse through the anal canal are often compressed by the contracted sphincters, impeding blood flow. As a result, they tend to strangulate and ulcerate. Because of the presence of abundant arteriovenous anastomoses, bleeding from internal hemorrhoids is characteristically bright red. Although all forms of internal hemorrhoids (including normal anal cushions misinterpreted as abnormalities) were once treated aggressively, current practice is to treat only prolapsed, ulcerated internal hemorrhoids. **External hemorrhoids** are thromboses (blood clots) in the veins of the *external rectal venous plexus* and are covered by skin. Predisposing factors for hemorrhoids include pregnancy, chronic constipation and

prolonged toilet sitting and straining, and any disorder that impedes venous return, including increased intra-abdominal pressure.

The anastomoses between the superior, middle, and inferior rectal veins form clinically important communications between the portal and systemic venous systems ▶

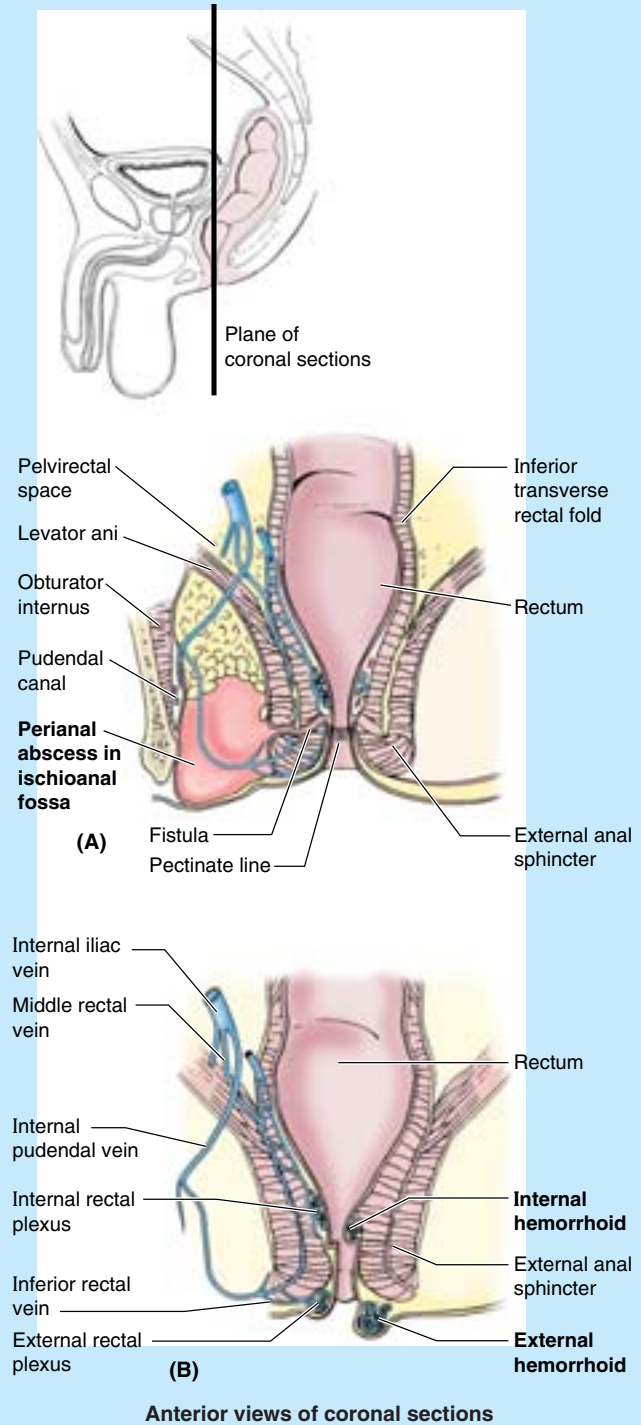


Figure B3.26

(see Fig. 2.59). The superior rectal vein drains into the inferior mesenteric vein, whereas the middle and inferior rectal veins drain through the systemic system into the inferior vena cava. Any abnormal increase in pressure in the valveless portal system or veins of the trunk may cause enlargement of the superior rectal veins, resulting in an increase in blood flow or stasis in the internal rectal venous plexus. In the *portal hypertension* that occurs in relation to *hepatic cirrhosis*, the portocaval anastomosis between the superior and the middle and inferior rectal veins, along with portocaval anastomoses elsewhere, may become varicose. Those in the esophagus are especially prone to rupture. It is important to note that the veins of the rectal plexuses *normally* appear varicose (dilated and tortuous), even in newborns, and that internal hemorrhoids occur most commonly in the *absence* of portal hypertension.

Regarding pain from and the treatment of hemorrhoids, it is important to note that the anal canal superior to the pectinate line is visceral; thus it is innervated by visceral afferent pain fibers, so that an incision or needle insertion in this region is painless. Internal hemorrhoids are not painful and can be treated without anesthesia. However, inferior to the pectinate line, the anal canal is somatic, supplied by the inferior anal (rectal) nerves containing somatic sensory fibers. Therefore, it is sensitive to painful stimuli (e.g., to the prick of a hypodermic needle). External hemorrhoids can be painful but often resolve in a few days.

Anorectal Incontinence

Stretching of the pudendal nerve(s) during a traumatic childbirth can result in *pudendal nerve damage* and anorectal incontinence. ❖

THE BOTTOM LINE: The anal canal is the terminal part of both the large intestine and the alimentary tract, the anus being the external outlet. Closure (and thus fecal continence) is maintained by the coordinated action of the involuntary internal and voluntary external anal sphincters. The sympathetically stimulated tonus of the internal sphincter maintains closure, except during filling of the rectal ampulla and when inhibited during a parasympathetically stimulated peristaltic contraction of the rectum. During these moments, closure is maintained (unless defecation is permitted) by voluntary contraction of the puborectalis and external anal sphincter. Internally, the pectinate line demarcates the transition from visceral to somatic neurovascular supply and drainage. The canal is surrounded by superficial and deep venous plexuses, the veins of which normally have a varicose appearance. Thromboses in the superficial plexus, and mucosal prolapse, including portions of the deep plexus, constitute painful external and insensitive internal hemorrhoids, respectively.

Male Perineum

The **male perineum** includes the external genitalia, perineal muscles, and anal canal. The **male external genitalia** include the urethra, scrotum, and penis.

Distal Male Urethra

The male urethra is subdivided into four parts: intramural (preprostatic), prostatic, intermediate, and spongy. The intramural and prostatic parts are described with the pelvis (earlier in this chapter). Details concerning all four parts of the male urethra are provided and compared in Table 3.7.

The **intermediate (membranous) part of the urethra** begins at the apex of the prostate and traverses the deep perineal pouch, surrounded by the external urethral sphincter. It then penetrates the perineal membrane, ending as the urethra enters the bulb of the penis (Fig. 3.46). Posterolateral to this part of the urethra are the small *bulbourethral glands* and their slender ducts, which open into the proximal part of the spongy urethra.

The **spongy urethra** begins at the distal end of the intermediate part of the urethra and ends at the *external urethral orifice*, which is slightly narrower than any of the parts of the urethra. The lumen of the spongy urethra is approximately 5 mm in diameter; however, it is expanded in the bulb of the penis to form the **intraulbar fossa** and in the glans of the penis to form the **navicular fossa**. On each side, the slender *ducts of the bulbourethral glands* open into the proximal part of the spongy urethra; the orifices of these ducts are extremely small. There are also many minute openings of the ducts of mucus-secreting **urethral glands** (Littre glands) into the spongy urethra.

Arterial Supply of the Distal Male Urethra. The arterial supply of the intermediate and spongy parts of the urethra is from branches of the *dorsal artery of the penis* (Fig. 3.39C; Table 3.8).

Venous and Lymphatic Drainage of the Distal Male Urethra. Veins accompany the arteries and have similar names. Lymphatic vessels from the intermediate part of the urethra drain mainly into the *internal iliac lymph nodes* (Fig. 3.47; Table 3.6); whereas most vessels from the spongy urethra pass to the *deep inguinal lymph nodes*, but some lymph passes to the external iliac nodes.

Innervation of the Distal Male Urethra. The innervation of the intermediate part of the urethra is the same as that

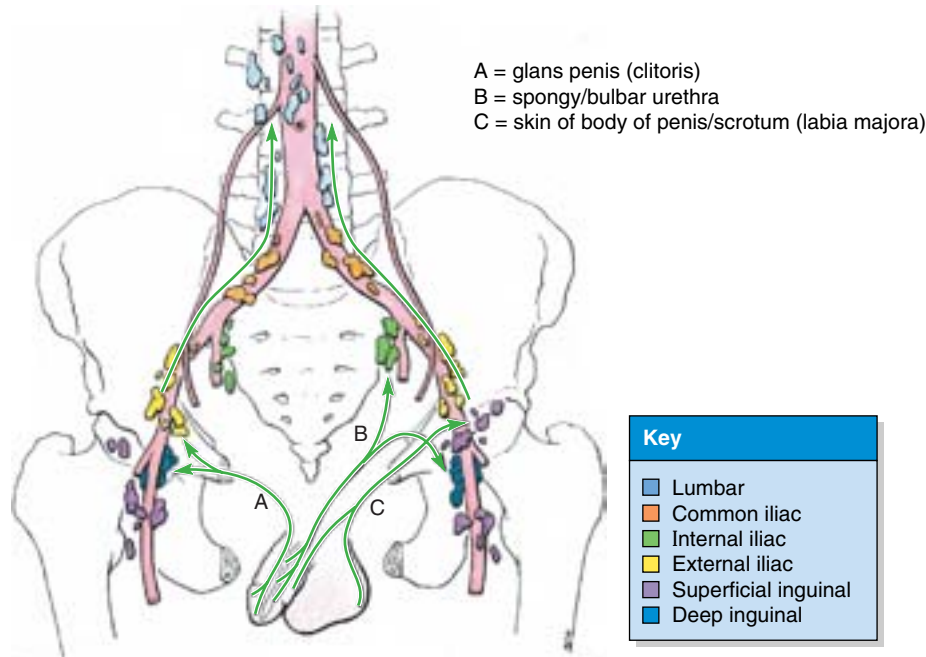


Figure 3.47. Lymphatic drainage of penis, spongy urethra, and scrotum.
 The arrows indicate the direction of lymph flow to the lymph nodes.

of the prostatic part: autonomic (efferent) innervation via the *prostatic nerve plexus*, arising from the *inferior hypogastric plexus*. The sympathetic innervation is from the lumbar spinal cord levels via the lumbar splanchnic nerves, and the parasympathetic innervation is from the sacral levels via the

pelvic splanchnic nerves. The visceral afferent fibers follow the parasympathetic fibers retrogradely to sacral spinal sensory ganglia. The dorsal nerve of the penis, a branch of the *pudendal nerve*, provides somatic innervation of the spongy part of the urethra (Fig. 3.44).

Urethral Catheterization

Urethral catheterization is done to remove urine from a person who is unable to micturate. It is also performed to irrigate the bladder and to obtain an uncontaminated sample of urine. When inserting catheters and *urethral sounds* (slightly conical instruments for exploring and dilating a constricted urethra) the curves of the male urethra must be considered. Just distal to the perineal membrane, the spongy urethra is well covered inferiorly and posteriorly by erectile tissue of the bulb of the penis; however, a short segment of the intermediate part of the urethra is unprotected (Fig. B3.27). Because the urethral wall is thin and because of the angle that must be negotiated to enter the intermediate part of the spongy urethra, it is vulnerable to rupture during the insertion of urethral catheters and sounds. The intermediate part, the least distensible part, runs inferoanteriorly as it passes through the external urethral sphincter. Proximally, the prostatic part takes a slight curve that is concave anteriorly as it traverses the prostate. ▶

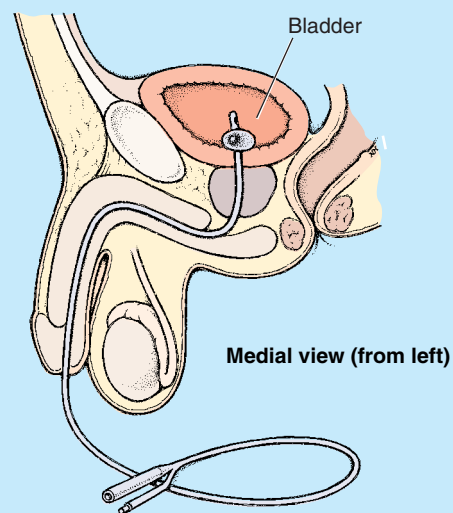


Figure B3.27

Urethral stricture may result from external trauma of the penis or infection of the urethra. Urethral sounds are used to dilate the constricted urethra in such cases. The spongy urethra will expand enough to permit passage of an instrument approximately 8 mm in diameter. The external urethral orifice is the narrowest and least distensible part of the urethra; hence, an instrument that passes through this opening normally passes through all other parts of the urethra. ⊕

THE BOTTOM LINE: The intermediate urethra is the shortest and narrowest part of the male urethra, the limit of its distension normally being the same as that of the external urethral orifice. It is encircled by voluntary muscle of the inferior part of the external urethral sphincter before perforating the perineal membrane. Immediately inferior to the membrane, the urethra enters the corpus spongiosum and becomes the spongy urethra, the longest part of the male urethra. The spongy urethra has expansions at each end, the intrabulbar and navicular fossae. The intermediate and spongy parts are supplied and drained by the same dorsal (blood) vessels of the penis but differ in terms of innervation and lymphatic drainage, that for the intermediate part following visceral paths and that for the spongy part follows somatic paths.

Scrotum

The **scrotum** is a cutaneous fibromuscular sac for the testes and associated structures. It is situated posteroinferior to the penis and inferior to the pubic symphysis. The bilateral embryonic formation of the scrotum is indicated by the midline **scrotal raphe** (Fig. 3.48), which is continuous on the ventral surface of the penis with the **penile raphe** and posteriorly along the median line of the perineum with the **perineal raphe**. Internally, deep to the scrotal raphe, the scrotum is divided into two compartments, one for each testis, by a prolongation of the dartos fascia, the **septum of the scrotum**. The testes and epididymides and their coverings are described with the abdomen (see Chapter 2).

Arterial Supply of the Scrotum. Anterior scrotal arteries, terminal branches of the **external pudendal arteries** (from the femoral artery), supply the anterior aspect of the scrotum; **posterior scrotal arteries**, terminal branches of the superficial perineal branches of the *internal pudendal arteries*, supply the posterior aspect (Table 3.8). The scrotum also receives branches from the cremasteric arteries (branches of the inferior epigastric arteries).

Venous and Lymphatic Drainage of the Scrotum. The scrotal veins accompany the arteries, sharing the same names but draining primarily to the *external pudendal veins*. Lymphatic vessels from the scrotum carry lymph to the *superficial inguinal lymph nodes* (Fig. 3.47; Table 3.6).

Innervation of the Scrotum. The anterior aspect of the scrotum is supplied by derivatives of the *lumbar plexus*: **anterior scrotal nerves**, derived from the *ilioinguinal nerve*, and the *genital branch of the genitofemoral nerve*. The posterior aspect of the scrotum is supplied by derivatives of the sacral plexus: **posterior scrotal nerves**, branches of the *superficial perineal branches* of the *pudendal nerve*, and the *perineal branch of the posterior femoral cutaneous nerve* (Figs. 3.44 and 3.49A). Sympathetic fibers conveyed by these nerves assist in the thermoregulation of the testes (see Chapter 2), stimulating contraction of the smooth dartos muscle in response to cold or stimulating the scrotal sweat glands while inhibiting contraction of the dartos muscle in response to excessive warmth.

Distension of the Scrotum

The scrotum is easily distended. In persons with large indirect inguinal hernias, for example (see Chapter 2), the intestine may enter the scrotum, making it as large as a soccer ball. Similarly, inflammation of the testes (**orchitis**), associated with mumps, bleeding in the subcutaneous tissue, or chronic lymphatic obstruction (as occurs in the parasitic disease *elephantiasis*), may produce an enlarged scrotum.

Palpation of the Testes

The soft, pliable skin of the scrotum makes it easy to palpate the testes and the structures related to them (e.g., the epididymis and ductus deferens). The left testis commonly lies at a more inferior level than does the right one. ⊕

THE BOTTOM LINE: The scrotum is a dynamic, fibromuscular cutaneous sac for the testes and epididymides. Its internal subdivision by a septum of dartos fascia is demarcated externally by a median scrotal raphe. The anterior aspect of the scrotum is served by anterior scrotal blood vessels and nerves, continuations of external pudendal blood vessels and branches of the lumbar nerve plexus; the posterior aspect of the scrotum is served by posterior scrotal blood vessels and nerves, continuations of internal pudendal blood vessels and branches of the sacral nerve plexus. Sympathetic innervation of smooth dartos muscle and sweat glands assists thermoregulation of the testes.

Penis

The **penis** is the male copulatory organ and, by conveying the urethra, provides the common outlet for urine and semen (Figs. 3.46, 3.48, and 3.49). The penis consists of a *root*, *body*, and *glans*. It is composed of three cylindrical bodies of erectile cavernous tissue: the paired **corpora cavernosa** dorsally and

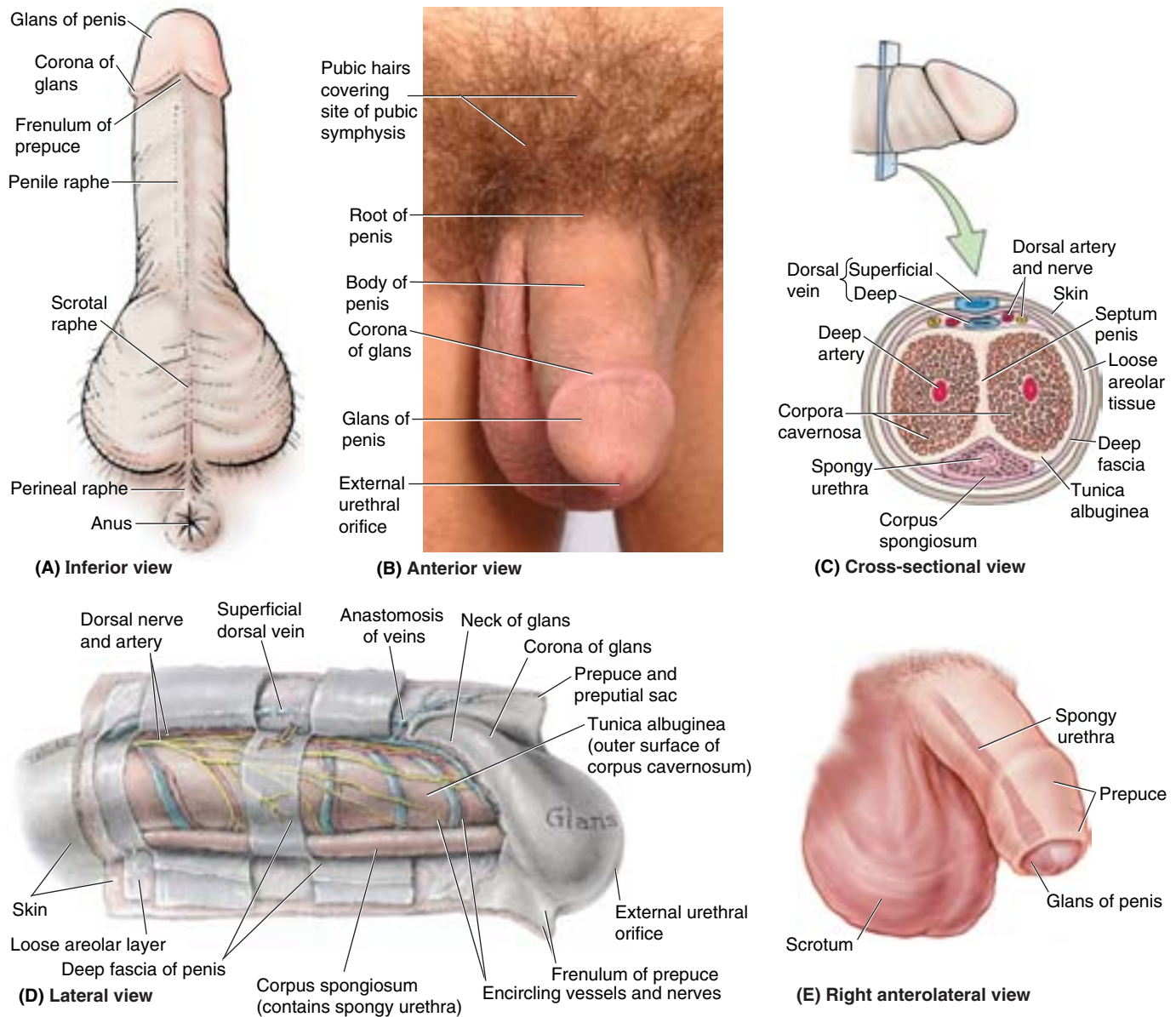


Figure 3.48. Penis and scrotum. **A.** The urethral surface of the circumcised penis is shown. The spongy urethra is deep to the cutaneous penile raphe. The scrotum is divided into right and left halves by the cutaneous scrotal raphe, which is continuous with the penile and perineal raphes. **B.** The dorsum of the circumcised penis and the anterior surface of the scrotum are shown. The penis comprises a root, body, and glans. **C.** The penis contains three erectile masses: two corpora cavernosa and a corpus spongiosum (containing the spongy urethra). **D.** The skin of the penis extends distally as the prepuce, overlapping the neck and corona of the glans. **E.** An uncircumcised penis.

single **corpus spongiosum** ventrally. (Note that in the anatomical position, the penis is erect; when the penis is flaccid, its dorsum is directed anteriorly.) Each *cavernous body* has an outer fibrous covering or capsule, the **tunica albuginea** (Fig. 3.48C). Superficial to the outer covering is the **deep fascia of the penis** (Buck fascia), the continuation of the deep perineal fascia that forms a strong membranous covering for the corpora cavernosa and corpus spongiosum, binding them together (Fig. 3.48C & D). The corpus spongiosum contains the spongy urethra. The corpora cavernosa are fused with

each other in the median plane, except posteriorly where they separate to form the **crura of the penis** (Figs. 3.47 and 3.50). Internally, the cavernous tissue of the corpora is separated (usually incompletely) by the **septum penis** (Fig. 3.48C).

The **root of the penis** (*L. radix penis*), the attached part, consists of the crura, bulb, and ischiocavernosus and bulbospongiosus muscles (Fig. 3.46). The root is located in the superficial perineal pouch, between the perineal membrane superiorly and the deep perineal fascia inferiorly. The **crura** and **bulb of the penis** contain masses of erectile tissue. Each

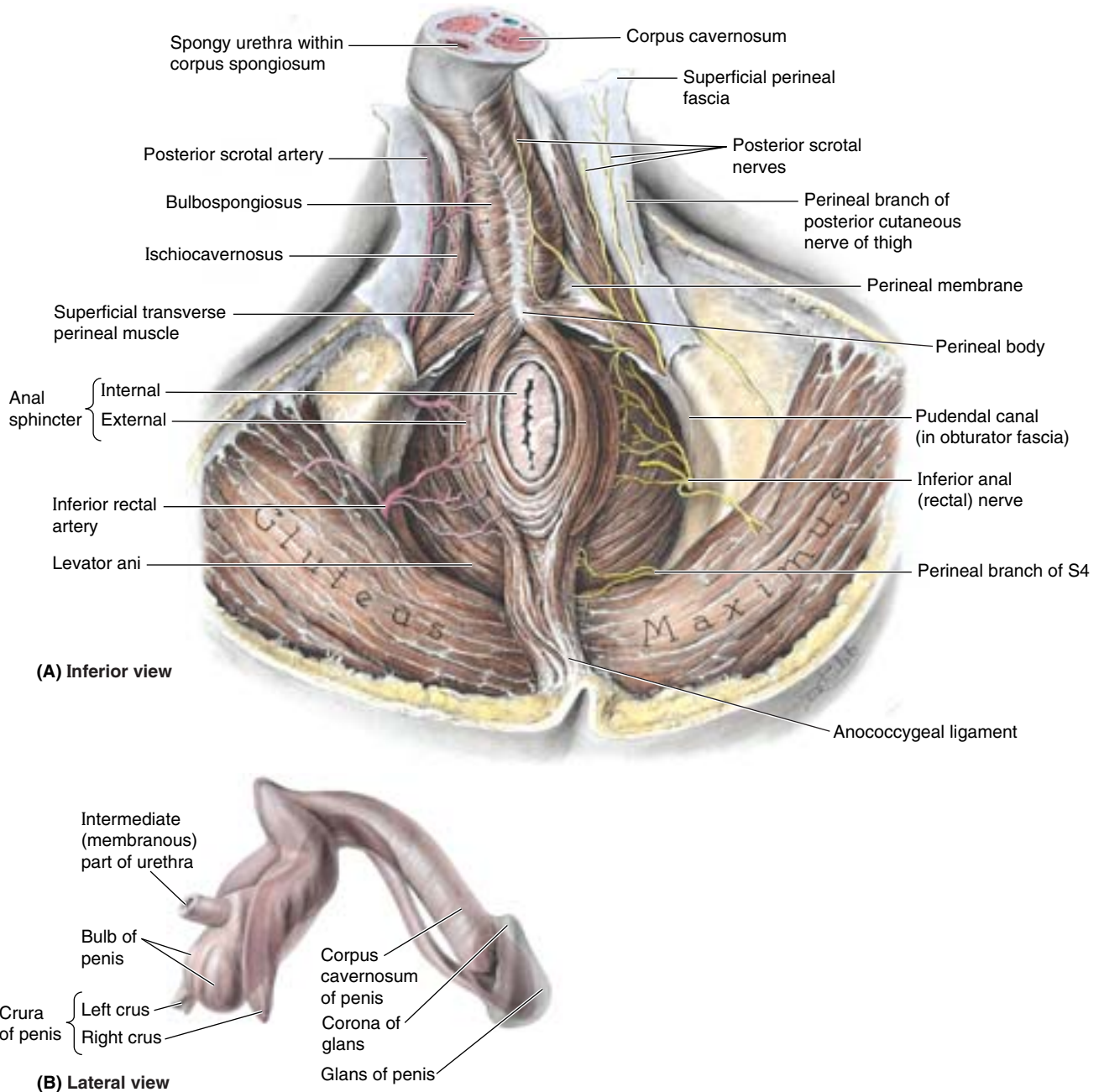
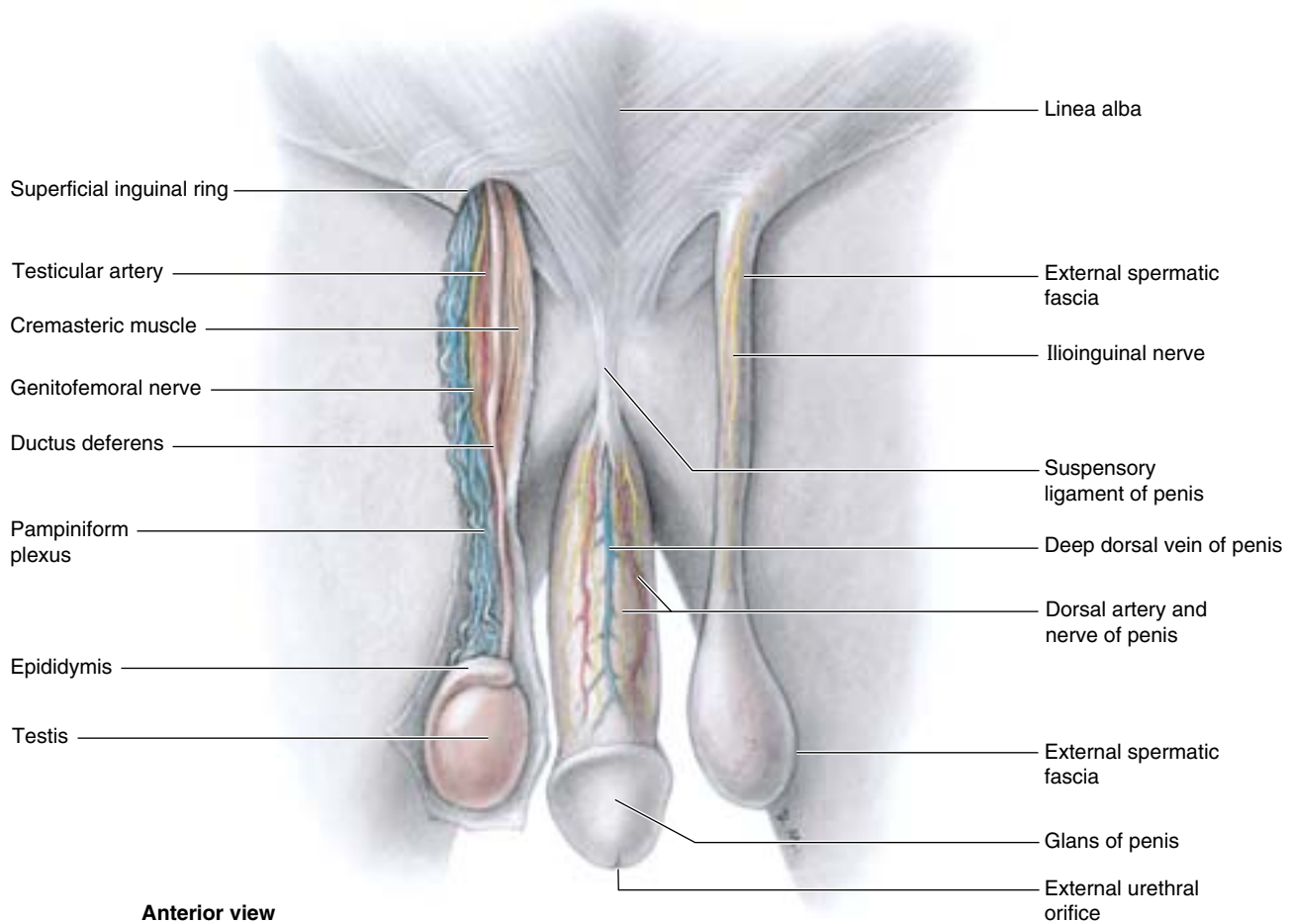


Figure 3.49. Male perineum and structure of penis. A. The anal canal is surrounded by the external anal sphincter, with an ischioanal fossa on each side. The inferior anal (rectal) nerve branches from the pudendal nerve at the entrance to the pudendal canal and, with the perineal branch of S4, supplies the external anal sphincter. **B.** The corpus spongiosum has been separated from the corpora cavernosa. The natural flexures of the penis are preserved. The glans penis fits like a cap over the blunt ends of the corpora cavernosa.

crus is attached to the inferior part of the internal surface of the corresponding ischial ramus (Fig. 3.39D), anterior to the ischial tuberosity. The enlarged posterior part of the bulb of the penis is penetrated superiorly by the urethra, continuing from its intermediate part (Fig. 3.49B).

The **body of the penis** is the free pendulous part that is suspended from the pubic symphysis (Figs. 3.46 and 3.48B). Except for a few fibers of the bulbospongiosus near the root

of the penis and the ischiocavernosus that embrace the crura, the body of the penis has no muscles. The penis consists of thin skin, connective tissue, blood and lymphatic vessels, fascia, the corpora cavernosa, and the corpus spongiosum containing the spongy urethra (Fig. 3.48C). Distally, the corpus spongiosum expands to form the conical **glans of the penis**, or head of the penis (Figs. 3.48A, B, & D and 3.49B). The margin of the glans projects beyond the ends of the corpora



Anterior view

Figure 3.50. Vessels and nerves on dorsum of penis and contents of spermatic cord. This dissection of the penis and spermatic cord shows their vessels and nerves. The skin, including the scrotum, has been removed. The superficial (dartos) fascia covering the penis has also been removed to expose the midline deep dorsal vein and the bilateral dorsal arteries and nerves of the penis. The triangular suspensory ligament of the penis attaches to the pubic symphysis and blends with the deep fascia of the penis.

cavernosa to form the **corona of the glans**. The corona overhangs an obliquely grooved constriction, the **neck of the glans**, which separates the glans from the body of the penis. The slit-like opening of the spongy urethra, the *external urethral orifice* (meatus), is near the tip of the glans.

The skin of the penis is thin, darkly pigmented relative to adjacent skin, and connected to the tunica albuginea by loose connective tissue. At the neck of the glans, the skin and fascia of the penis are prolonged as a double layer of skin, the **prepuce** (foreskin), which in uncircumcised males covers the glans to a variable extent (Fig. 3.48E). The **frenulum of the prepuce** is a median fold that passes from the deep layer of the prepuce to the urethral surface of the glans (Fig. 3.48A & D).

The **suspensory ligament of the penis** is a condensation of deep fascia that arises from the anterior surface of the pubic symphysis (Fig. 3.50). The ligament passes inferiorly and splits to form a sling that is attached to the deep fascia of the penis at the junction of its root and body. The fibers of the suspensory ligament are short and taut, anchoring the erectile bodies of the penis to the pubic symphysis. The **fundiform**

ligament of the penis is an irregular mass or condensation of collagen and elastic fibers of the subcutaneous tissue that descends in the midline from the linea alba superior to the pubic symphysis. The ligament splits to surround the penis and then unites and blends inferiorly with the dartos fascia forming the scrotal septum. The fibers of the fundiform ligament are relatively long and loose and lie superficial (anterior) to the suspensory ligament.

Arterial Supply of the Penis. The penis is supplied mainly by *branches of the internal pudendal arteries* (Figs. 3.48C & D and 3.50; Table 3.8).

- **Dorsal arteries of the penis:** run on each side of the deep dorsal vein in the dorsal groove between the corpora cavernosa, supplying the fibrous tissue around the corpora cavernosa, the corpus spongiosum and spongy urethra, and the penile skin.
- **Deep arteries of the penis:** pierce the crura proximally and run distally near the center of the corpora cavernosa, supplying the erectile tissue in these structures.

- **Arteries of the bulb of the penis:** supply the posterior (bulbous) part of the corpus spongiosum and the urethra within it as well as the bulbourethral gland.

In addition, **superficial and deep branches of the external pudendal arteries** supply the penile skin, anastomosing with branches of the internal pudendal arteries.

The deep arteries of the penis are the main vessels supplying the cavernous spaces in the erectile tissue of the corpora cavernosa and are, therefore, involved in the erection of the penis. They give off numerous branches that open directly into the cavernous spaces. When the penis is flaccid, these arteries are coiled, restricting blood flow; they are called **helicine arteries of the penis** (*G. helix*, a coil).

Venous and Lymphatic Drainage of the Penis. Blood from the cavernous spaces is drained by a venous plexus that joins the **deep dorsal vein of the penis** in the deep fascia (Figs. 3.48C and 3.50). This vein passes between the laminae of the suspensory ligament of the penis, inferior to the arcuate pubic ligament and anterior to the perineal membrane, to enter the pelvis, where it drains into the prostatic venous plexus. Blood from the superficial coverings of the penis drain into the **superficial dorsal vein(s)**, which drain(s) into the **superficial external pudendal vein**. Some blood also passes to the

internal pudendal vein. Lymph from the skin of the penis drains initially to the **superficial inguinal lymph nodes**, that from the glans and distal spongy urethra drain to the **deep inguinal** and **external iliac nodes**, and that from the cavernous bodies and proximal spongy urethra drain to the **internal iliac nodes** (Fig. 3.47; Table 3.6).

Innervation of the Penis The nerves derive from the S2–S4 spinal cord segments and spinal ganglia, passing through the pelvic splanchnic and pudendal nerves, respectively (Fig. 3.51). Sensory and sympathetic innervation is provided primarily by the **dorsal nerve of the penis**, a terminal branch of the **pudendal nerve**, which arises in the pudendal canal and passes anteriorly into the deep perineal pouch. It then runs to the dorsum of the penis, where it runs lateral to the dorsal artery (Figs. 3.48C and 3.50). It supplies both the skin and glans of the penis. The penis is richly provided with a variety of sensory nerve endings, especially the glans penis. Branches of the **ilioinguinal nerve** supply the skin at the root of the penis. Cavernous nerves, conveying parasympathetic fibers independently from the prostatic nerve plexus, innervate the helicine arteries of the erectile tissue. The sexual functions of the penis are explained under “Erection, Emission, and Ejaculation,” later in this chapter.

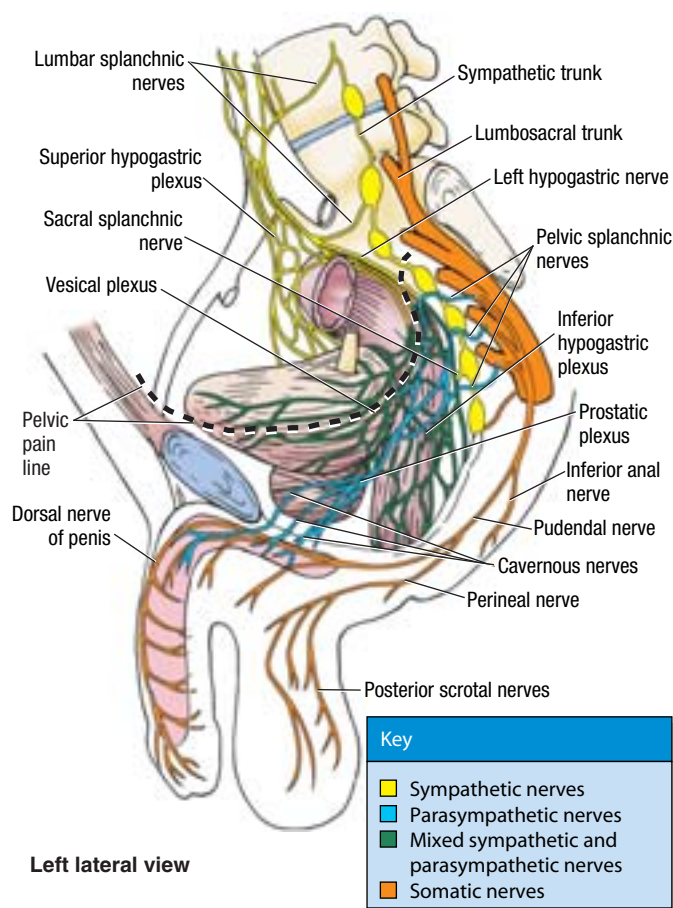


Figure 3.51. Nerves of perineum. The pudendal nerve conveys the majority of sensory, sympathetic, and somatic motor fibers to the perineum. Although originating from the same spinal cord segments from which the pudendal nerve is derived, the parasympathetic fibers of the cavernous nerves course independently of the pudendal nerve. With the exception of the cavernous nerves, parasympathetic fibers do not occur outside of the head, neck, or cavities of the trunk. The cavernous nerves arise from the prostatic plexus of males and from the vesical plexus of females. They terminate on the arteriovenous anastomoses and helicine arteries of the erectile bodies, which, when stimulated, produce erection of the penis or engorgement of the clitoris and vestibular bulb in females.

Hypospadias

Hypospadias is a common congenital anomaly of the penis, occurring in 1 in 300 newborns. In the simplest and most common form, *glanular hypospadias*, the external urethral orifice is on the ventral aspect of the glans. In other infants, the defect is in the body of the penis (*penile hypospadias*) (Fig. B3.28), or in the perineum (*penoscrotal* or *scrotal hypospadias*). Hence, the external urethral orifice is on the urethral surface of the penis. The embryological basis of glanular and penile hypospadias is failure of the *urogenital folds* to fuse on the ventral surface of the developing penis and form the spongy urethra. The embryological basis of scrotal hypospadias is failure of the *labioscrotal folds* to fuse and form the scrotum. The cause of hypospadias is not clearly understood, but it appears to have a multifactorial origin (i.e., genetic and environmental factors are involved). Close relatives of patients with hypospadias are more likely than the general population to have the anomaly. It is generally believed that hypospadias is associated with an inadequate production of androgens by the fetal testes. Differences in the timing and degree of hormonal insufficiency probably account for the different types of hypospadias (Moore and Persaud, 2003). The less common but more severe forms of hypospadias, in which the external urethral orifice is located on the penile body or in the perineum, may interfere with normal urination in the usual male standing position. (Walsh, 1998)

Phimosis, Paraphimosis, and Circumcision

The prepuce of the penis is usually sufficiently elastic for it to be retracted over the glans penis. In some males, it fits tightly over the glans and cannot be retracted easily (*phimosis*) if at all. As there are modified sebaceous glands in the prepuce, the oily secretions of cheesy consistency (*smegma*) from them accumulate in the **preputial sac**, located between the glans and prepuce, causing irritation. In some males, retraction of the prepuce over the glans

constricts the neck of the glans so much that there is interference with the drainage of blood and tissue fluid. In patients with this condition (*paraphimosis*) the glans may enlarge so much that the prepuce cannot be drawn over it. Circumcision is commonly performed in such cases. **Circumcision**, surgical excision of the prepuce, is the most commonly performed minor surgical operation on male infants. Although it is a religious practice in Islam and Judaism, it is often done routinely for non-religious reasons (a preference usually explained in terms of tradition or hygiene) in North America. In adults, circumcision is usually performed when phimosis or paraphimosis is present. ❖

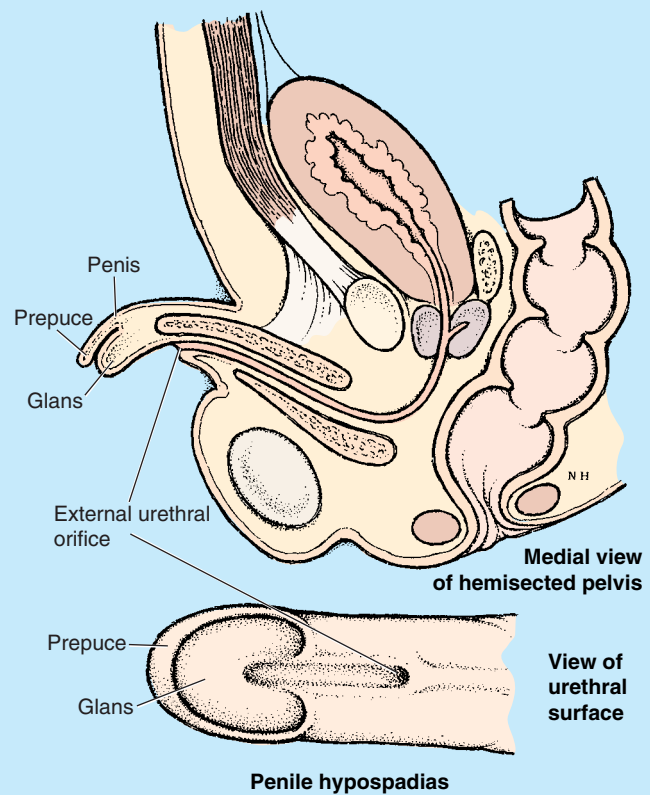


Figure B3.28

THE BOTTOM LINE: The penis is the male copulatory organ and common final conveyor of urine and semen. It is formed mainly of thin, mobile skin overlying three cylindrical bodies of erectile cavernous tissue, the paired corpora cavernosa, and a single corpus spongiosum containing the spongy urethra. The erectile bodies are bound together by deep fascia of the penis, except posteriorly (at the root) where they separate into the crura and bulb of the penis. The crura attach to the ischiopubic rami, but all parts of the root are attached to the perineal membrane. At the junction of root and body, the penis is attached to the pubic symphysis by the suspensory ligament of the penis.

The ischiocavernosus muscles ensheath the crura, and the bulbospongiosus ensheath the bulb, its most anterior fibers encircling the most proximal part of the body (which otherwise has no muscles) and deep dorsal vessels. The glans of the penis is a distal expansion of the corpus spongiosum, which has the external urethral orifice at its tip and a projecting corona that overhangs the neck of the glans. Unless removed by circumcision, the neck is covered by the prepuce or foreskin.

Except for skin near its root, the penis is supplied mainly by branches of the internal pudendal arteries. The dorsal arteries supply most of the body and glans, whereas the

deep arteries supply the cavernous tissue, their terminal helicine arteries opening to engorge the sinuses with blood at arterial pressure, causing erection. Superficial structures drain via the superficial dorsal vein to external pudendal veins, whereas the erectile bodies drain via the deep dorsal vein to the prostatic venous plexus. Sensory and sympathetic innervation is provided mainly by the dorsal nerve of the penis, but the helicine arteries that directly produce erection are innervated by cavernous nerves, extensions of the prostatic nerve plexus.

Perineal Muscles of the Male

The **superficial perineal muscles**, located in the superficial perineal pouch, include the superficial transverse perineal, bulbospongiosus, and ischiocavernosus muscles (Fig. 3.49A). Details about the attachments, innervation, and actions of these muscles are provided in Table 3.9. The **superficial transverse perineal muscles** and bulbospongiosus muscles join the external anal sphincter in attaching centrally to the perineal body, crossing the pelvic outlet like intersecting beams, supporting the perineal body to aid the pelvic diaphragm in supporting the pelvic viscera. Simultaneous contraction of the superficial perineal muscles (plus the deep transverse perineal muscle) during penile erection provides a firmer base for the penis.

The *bulbospongiosus muscles* form a constrictor that compresses the bulb of the penis and the corpus spongiosum, thereby aiding in emptying the spongy urethra of residual urine and/or semen. The anterior fibers of the bulbospongiosus, encircling the most proximal part of the body of the penis, also assist erection by increasing the pressure on the erectile tissue in the root of the penis. At the same time, they also compress the deep dorsal vein of the penis, impeding venous drainage of the cavernous spaces and helping promote enlargement and turgidity of the penis.

The **ischiocavernosus muscles** surround the crura in the root of the penis. They force blood from the cavernous spaces in the crura into the distal parts of the corpora cavernosa, which increases the turgidity (firm distension) of the penis during erection. Contraction of the ischiocavernosus muscles also compresses the tributaries of deep dorsal vein of the penis leaving the crus of the penis, thereby restricting venous outflow from the penis and helping maintain the erection.

Because of their function during erection and the activity of the bulbospongiosus subsequent to urination and ejaculation to expel the last drops of urine and semen, the perineal muscles are generally more developed in males than in females.

THE BOTTOM LINE: In addition to their bony origins, the voluntary superficial and deep muscles of the perineum are also attached to the perineal membrane (by which they are separated) and the perineal body. In addition to the sphincteric functions of the external anal and urethral sphincters for maintaining fecal and urinary continence, the male perineal muscles function as a group to provide a base for the penis and support for the perineal body (which in turn sup-

ports the pelvic diaphragm). The ischiocavernosus and bulbospongiosus muscles both constrict venous outflow from the erectile bodies to assist erection, simultaneously pushing blood from the penile root into the body. In addition, the bulbospongiosus muscle constricts around the bulb of the penis to express the final drops of urine or semen. Because of these multiple functions, the perineal muscles are generally relatively well developed in males. The perineal muscles are innervated by muscular branches of the pudendal nerve.

Erection, Emission, and Ejaculation

When a male is stimulated erotically, arteriovenous anastomoses, by which blood is normally able to bypass the “empty” potential spaces or sinuses of the corpora cavernosa, are closed. The smooth muscle in the fibrous trabeculae and coiled helicine arteries relaxes (is inhibited) as a result of parasympathetic stimulation (S2–S4 through the cavernous nerves from the **prostatic nerve plexus**). Consequently, the helicine arteries straighten, enlarging their lumina and allowing blood to flow into and dilate the cavernous spaces in the corpora of the penis. The bulbospongiosus and ischiocavernosus muscles compress veins egressing from the corpora cavernosa, impeding the return of venous blood. As a result, the corpora cavernosa and corpus spongiosum become engorged with blood at venous pressure, causing the erectile bodies to become turgid (enlarged and rigid), and an **erection** occurs.

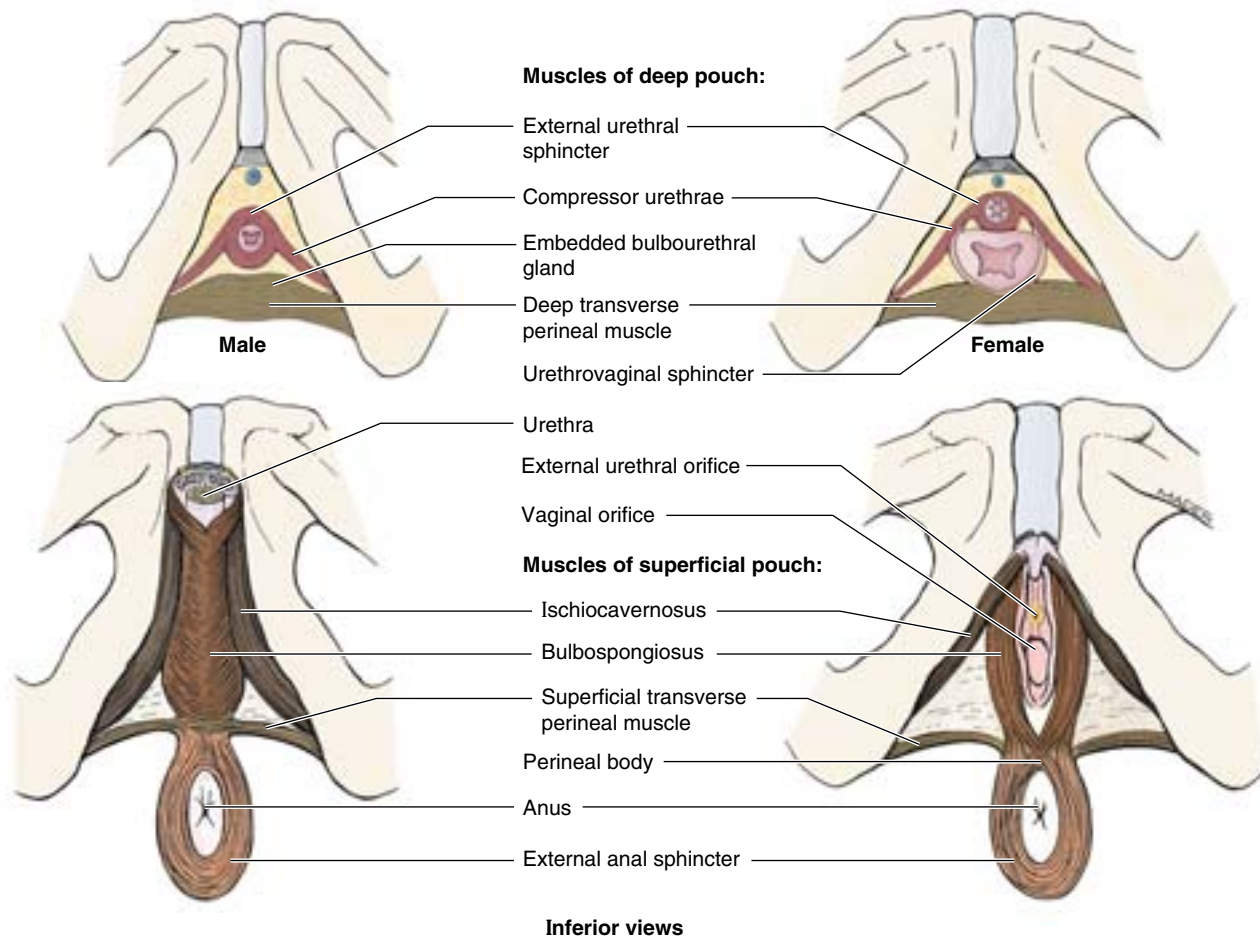
During **emission**, semen (sperms and secretions) is delivered to the prostatic urethra through the ejaculatory ducts after peristalsis of the ductus deferentes and seminal glands. Prostatic fluid is added to the seminal fluid as the smooth muscle in the prostate contracts. Emission is a sympathetic response (L1–L2 nerves). During **ejaculation**, semen is expelled from the urethra through the external urethral orifice. Ejaculation results from:

- Closure of the internal urethral sphincter at the neck of the urinary bladder, a sympathetic response (L1–L2 nerves).
- Contraction of the urethral muscle, a parasympathetic response (S2–S4 nerves).
- Contraction of the bulbospongiosus muscles, from the pudendal nerves (S2–S4).

After ejaculation, the penis gradually returns to a flaccid state (**remission**), resulting from sympathetic stimulation, which causes constriction of the smooth muscle in the coiled arteries. The bulbospongiosus and ischiocavernosus muscles relax, allowing more blood to be drained from the cavernous spaces in the penile corpora into the deep dorsal vein.

When a lesion of the prostatic plexus or cavernous nerves results in an inability to achieve an erection (**impotence**), a surgically implanted, semirigid or inflatable penile prosthesis may assume the role of the erectile bodies, providing the rigidity necessary to insert and move the penis within the vagina during intercourse.

Table 3.9. Muscles of the Perineum



Inferior views

Muscle	Origin	Course and distribution	Innervation	Main Action
External and sphincter	Skin and fascia surrounding anus; coccyx via anococcygeal ligament	Passes around lateral aspects of anal canal, insertion into perineal body	Inferior anal (rectal) nerve, a branch of pudendal nerve (S2–S4)	Constricts anal canal during peristalsis, resisting defecation; supports and fixes perineal body and pelvic floor
Bulbospongiosus	<i>Male:</i> median raphe on ventral surface of bulb of penis; perineal body	<i>Male:</i> surrounds lateral aspects of bulb of penis and most proximal part of body of penis, inserting into perineal membrane, dorsal aspect of corpora spongiosum and cavernosa, and fascia of bulb of penis	Muscular (deep) branch of perineal nerve, a branch of pudendal nerve (S2–S4)	<i>Male:</i> supports and fixes perineal body/pelvic floor; compresses bulb of penis to expel last drops of urine/semen; assists erection by compressing outflow via deep perineal vein and by pushing blood from bulb into body of penis
	<i>Female:</i> perineal body	<i>Female:</i> passes on each side of lower vagina, enclosing bulb and greater vestibular gland; inserts into pubic arch and fascia of corpora cavernosa of clitoris		<i>Female:</i> supports and fixes perineal body/pelvic floor; “sphincter” of vagina; assists in erection of clitoris (and perhaps bulb of vestibule); compresses greater vestibular gland
Ischiocavernosus	Internal surface of ischiopubic ramus and ischial tuberosity	Embraces crus of penis or clitoris, inserting onto the inferior and medial aspects of crus and to perineal membrane medial to crus		Maintains erection of penis or clitoris by compressing outflow veins and pushing blood from the root of penis or clitoris into the body of penis or clitoris

(continued)

Table 3.9. Muscles of the Perineum (Continued)

Muscle	Origin	Course and distribution	Innervation	Main action
Superficial transverse perineal	Internal surface of ischiopubic ramus and ischial tuberosity	Passes along inferior aspect of posterior border of perineal membrane to perineal body	Muscular (deep) branch of perineal nerve, a branch of pudendal nerve (S2–S4)	Supports and fixes perineal body/pelvic floor to support abdominopelvic viscera and resist increased intra-abdominal pressure
Deep transverse perineal		Passes along superior aspect of posterior border of perineal membrane to perineal body and external anal sphincter		
External urethra sphincter	(Compressor urethra portion only)	Surrounds urethra superior to perineal membrane; in males, it also ascends anterior aspect of prostate; in females, some fibers also enclose vagina (urethrovaginal sphincter)	Dorsal nerve of penis or clitoris, the terminal branch of the pudendal nerve (S2–S4)	Compresses urethra to maintain urinary continence; in females, urethrovaginal sphincter portion also compresses vagina

Female Perineum

The **female perineum** includes the female external genitalia, perineal muscles, and anal canal.

Female External Genitalia

The **female external genitalia** (Figs. 3.52–3.55) include the mons pubis and labia majora (enclosing the pudendal cleft), labia minora (enclosing the vestibule), clitoris, bulbs of the vestibule, and greater and lesser vestibular glands. The synonymous terms **vulva** and **pudendum** include all these parts;

the term *pudendum* is commonly used clinically. The vulva serves:

- As sensory and erectile tissue for sexual arousal and intercourse.
- To direct the flow of urine.
- To prevent entry of foreign material into the urogenital tract.

Mons Pubis. The **mons pubis** is the rounded, fatty eminence anterior to the pubic symphysis, pubic tubercles, and

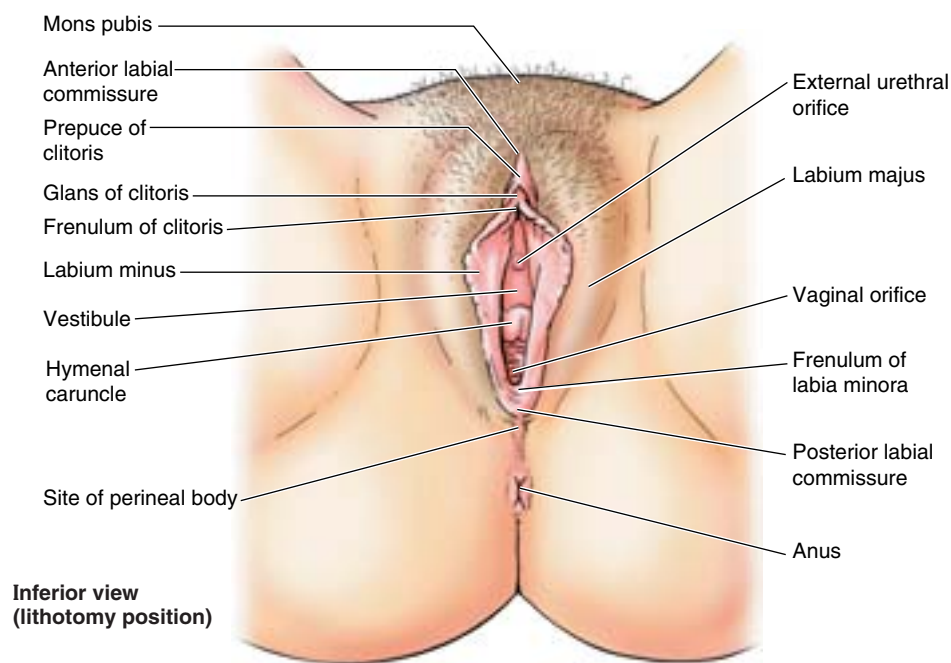
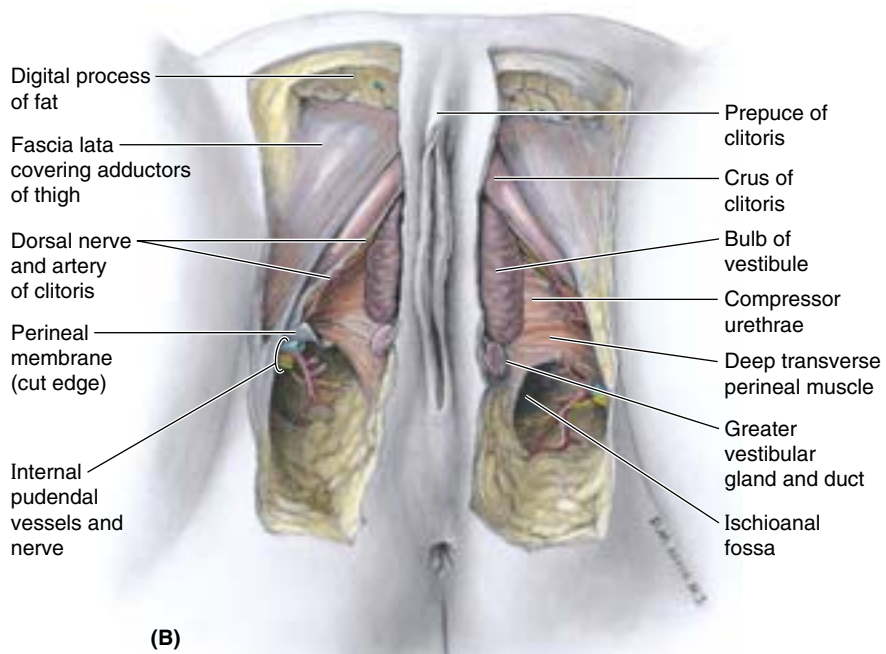
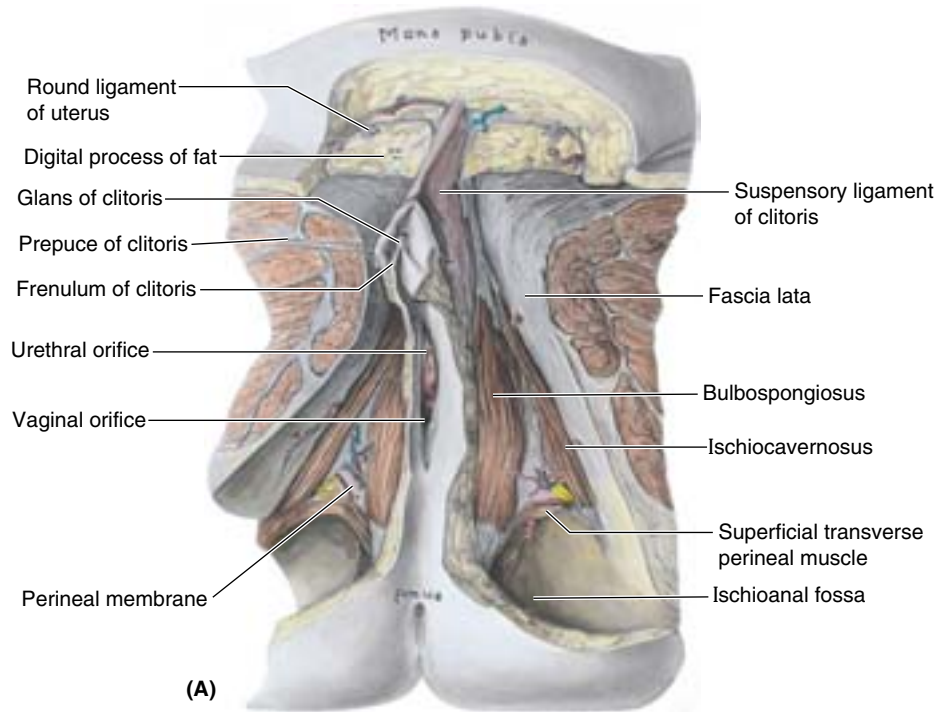


Figure 3.52. Female external genitalia. The labia majora and minora are separated to show the vestibule, into which the external urethral orifice and the vaginal orifice open.



Inferior views

Figure 3.53. Female perineum. **A.** A superficial dissection of the superficial pouch is shown. Encapsulated digital processes of fat pass deep to the thick superficial fatty tissue of the mons pubis, largely filling the labia majora. The prepuce of the clitoris forms a hood over the clitoris. Notice the ischioanal fossae lateral to the anal canal. **B.** This deeper dissection of the superficial pouch reveals the bulbs of the vestibule and the greater vestibular glands and ducts. The internal pudendal vessels and pudendal nerve are shown emerging from the pudendal canal.

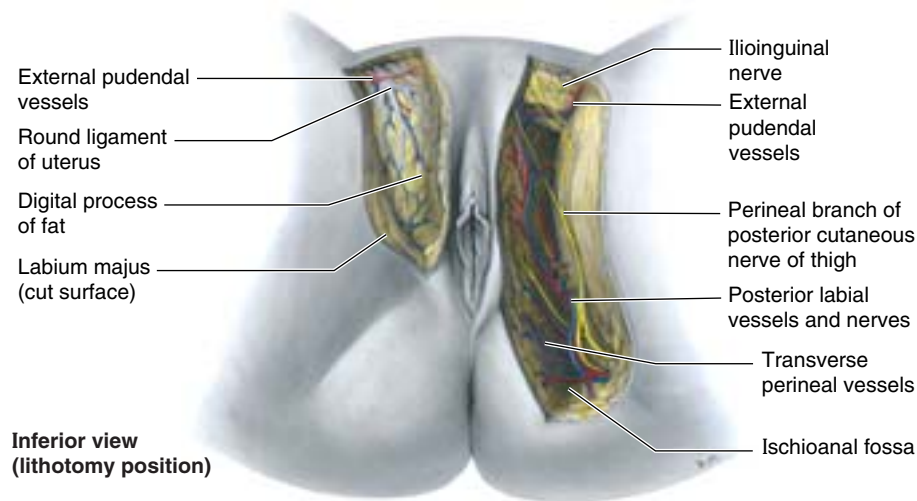


Figure 3.54. Female perineum. This subcutaneous dissection demonstrates the posterior labial vessels and nerves (S2–S3), joined by the perineal branch of the posterior cutaneous nerve of the thigh (S1–S3) running anteriorly almost to the mons pubis. The vessels anastomose here with the external pudendal vessels and the terminal branches of the nerves overlapping with those of the ilioinguinal nerve (L1). On the right side, the round ligament of the uterus terminates in the fat of the labium majus.

superior pubic rami (Fig. 3.52). The eminence is formed by a mass of fatty subcutaneous tissue (Fig. 3.53A). The amount of fat increases at puberty and decreases after menopause. The surface of the mons is continuous with the anterior abdominal wall. After puberty, the mons pubis is covered with coarse pubic hairs.

Labia Majora. The **labia majora** are prominent folds of skin that indirectly provide protection for the urethral and vaginal orifices. Each labium majus—largely filled with a finger-like “digital process” of loose subcutaneous tissue containing smooth muscle and the termination of the round ligament of the uterus (Figs. 3.53B and 3.54)—passes inferoposteriorly from the mons pubis toward the anus. The labia majora lie on the sides of a central depression (a narrow slit

when the thighs are adducted), the **pudendal cleft**, within which are the labia minora and vestibule (Fig. 3.52). The external aspects of the labia majora in the adult are covered with pigmented skin containing many sebaceous glands and are covered with crisp pubic hair. The internal aspects of the labia are smooth, pink, and hairless. The labia are thicker anteriorly where they join to form the **anterior commissure**. Posteriorly, in nulliparous women (never having borne children) they merge to form a ridge, the **posterior commissure**, which overlies the perineal body and is the posterior limit of the vulva. This commissure usually disappears after the first vaginal birth.

Labia Minora. The **labia minora** are rounded folds of fat-free, hairless skin. They are enclosed in the pudendal cleft and immediately surround the **vestibule** into which both the external urethral and the vaginal orifices open. They have a core of spongy connective tissue containing erectile tissue at their base and many small blood vessels. Anteriorly, the labia minora form two laminae. The medial laminae of each side unite as the **frenulum of the clitoris**. The lateral laminae unite anterior to (or often anterior and inferior to, thus overlapping and obscuring) the glans of the clitoris, forming the **prepuce (foreskin) of the clitoris**. In young women, especially virgins, the labia minora are connected posteriorly by a small transverse fold, the **frenulum of the labia minora (fourchette)**. Although the internal surface of each labium minus consists of thin moist skin, it has the pink color typical of mucous membrane and contains many sebaceous glands and sensory nerve endings.

Clitoris. The **clitoris** is an erectile organ located where the labia minora meet anteriorly. The clitoris consists of a **root** and a **body**, which are composed of two crura; two cor-

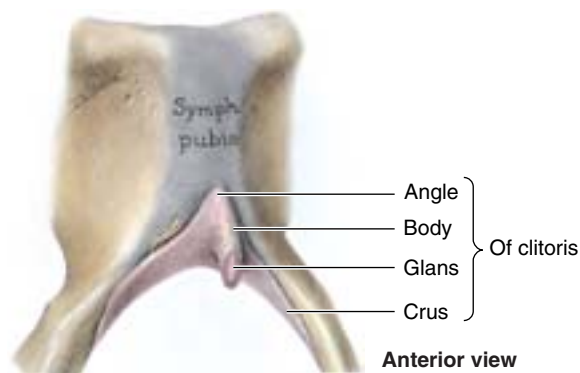


Figure 3.55. Clitoris. The surrounding soft tissues have been removed to reveal the parts of the clitoris. In many details, the clitoris resembles the structure of the penis, of which it is a homolog, although it is of reduced scale and has no association with the urethra.

pora cavernosa; and the **glans of the clitoris**, which is covered by a prepuce (Figs. 3.53 and 3.55). Together, the body and glans of the clitoris are approximately 2 cm in length and < 1 cm in diameter. In contrast to the penis, the clitoris is not functionally related to the urethra or to urination. It functions solely as an organ of sexual arousal. The clitoris is highly sensitive and enlarges on tactile stimulation. The glans of the clitoris is the most highly innervated part of the clitoris and is densely supplied with sensory endings.

Vestibule. The **vestibule** is the space surrounded by the labia minora into which the orifices of the urethra and vagina and the ducts of the greater and lesser vestibular glands open (Figs. 3.52 and 3.53B). The *external urethral orifice* is located 2–3 cm posteroinferior to the glans of the clitoris and anterior to the vaginal orifice (Figs. 3.52 and 3.53A). On each side of the external urethral orifice are the openings of the ducts of the **paraurethral glands**. The size and appearance of the **vaginal orifice** vary with the condition of the **hymen**, a thin anular fold of mucous membrane immediately within the vaginal orifice surrounding the lumen. After its rupture, only remnants of the hymen, **hymenal caruncles** (tags), are visible. These remnants demarcate the vagina from the vestibule. The hymen has no established physiological function. It is considered primarily a developmental vestige, but its condition (and that of the frenulum of the labia minora) often provides critical evidence in cases of child abuse and rape.

Bulbs of the Vestibule. The **bulbs of the vestibule** are paired masses of elongated erectile tissue, approximately 3 cm in length (Fig. 3.53B). The bulbs lie along the sides of the vaginal orifice, superior or deep to (not within) the labia minora, immediately inferior to the perineal membrane (see Fig. 3.40C). They are covered inferiorly and laterally by the bulbospongiosus muscles extending along their length. The bulbs are homologous with the bulb of the penis of the corpus spongiosum.

Female Circumcision

Although illegal and now being actively discouraged in most countries, female circumcision is widely practiced in some cultures. The operation performed during childhood removes the prepuce of the clitoris and commonly also removes part or all of the clitoris and the labia minora. This disfiguring procedure is thought to inhibit sexual arousal and gratification.

Vulvar Trauma

The highly vascular bulbs of the vestibule are susceptible to disruption of vessels as the result of trauma (e.g., athletic injuries such as jumping hurdles, sexual assault, and obstetrical injury). These injuries often result in vulvar hematomas in the labia majora, for example. ⚡

Vestibular Glands. The **greater vestibular glands**, approximately 0.5 cm in diameter, are located on each side of the vestibule, posterolateral to the vaginal orifice and inferior to the perineal membrane; thus they are in the superficial perineal pouch (Fig. 3.53B). The greater vestibular glands (Bartholin glands) are round or oval and are partly overlapped posteriorly by the *bulbs of the vestibule*, and like the bulbs, are partially surrounded by the bulbospongiosus muscles. The slender ducts of these glands pass deep to the bulbs of the vestibule and open into the vestibule on each side of the vaginal orifice. These glands secrete mucus into the vestibule during sexual arousal. The **lesser vestibular glands** are small glands on each side of the vestibule that open into it between the urethral and the vaginal orifices. These glands secrete mucus into the vestibule, which moistens the labia and vestibule.

Infection of the Greater Vestibular Glands

The greater vestibular glands are usually not palpable, but are so when infected. Occlusion of the vestibular gland duct can predispose the individual to infection of the gland. The greater vestibular gland is the site or origin of most vulvar adenocarcinomas. **Bartholinitis**, inflammation of the greater vestibular glands, may result from a number of pathogenic organisms. Infected glands may enlarge to a diameter of 4–5 cm and impinge on the wall of the rectum. Occlusion of the vestibular gland duct without infection can result in the accumulation of mucin (**Bartholin cyst**). ⚡

Arterial Supply of the Vulva. The abundant arterial supply to the vulva is from the *external* and *internal pudendal arteries* (Figs. 3.53B and 3.54). The *internal pudendal artery* supplies most of the skin, external genitalia, and perineal muscles. The labial arteries are branches of the internal pudendal artery, as are those of the clitoris.

Venous and Lymphatic Drainage of the Vulva. The labial veins are tributaries of the *internal pudendal veins* and accompanying veins (*L. venae comitantes*) of the internal pudendal artery. Venous engorgement during the excitement phase of the sexual response causes an increase in the size and consistency of the clitoris and the bulbs of the vestibule. The clitoris becomes turgid, elongating in approximately 10% of women. The vulva contains a rich network of lymphatic vessels that pass laterally to the *superficial inguinal lymph nodes* (Fig. 3.56). The glans of the clitoris and anterior labia minora may also drain to the deep inguinal nodes or directly to the internal iliac nodes.

Innervation of the Vulva. The anterior aspect of the vulva (mons pubis, anterior labia) is supplied by derivatives of the lumbar plexus: the **anterior labial nerves**, derived from

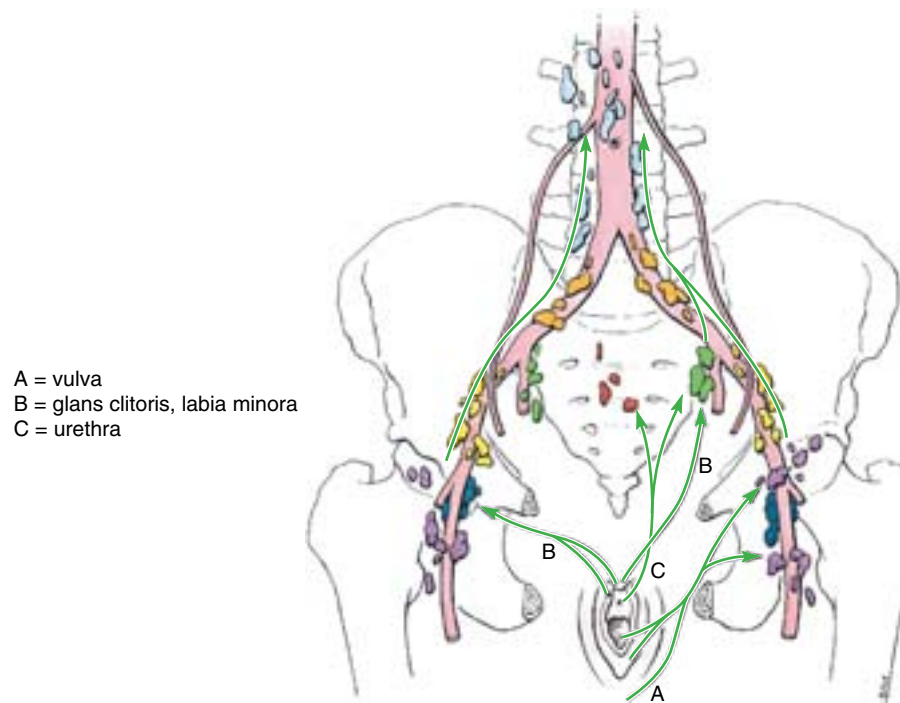


Figure 3.56. Lymphatic drainage of vulva or pudendum. The arrows indicate the direction of lymph flow to the lymph nodes.

the *ilioinguinal nerve*, and the *genital branch of the genitofemoral nerve*. The posterior aspect of the vulva is supplied by derivatives of the sacral plexus: the *perineal branch of the posterior cutaneous nerve of the thigh* laterally and the *pudendal nerve* centrally (Figs. 3.54 and 3.57; Table 3.4). The latter is the primary nerve of the perineum. Its **posterior labial nerves** (terminal *superficial branches of the perineal nerve*) supply the labia; *deep and muscular branches of the perineal nerve* supply

the orifice of the vagina and superficial perineal muscles; and the *dorsal nerve of the clitoris* supplies deep perineal muscles and sensation to the clitoris. The bulb of the vestibule and erectile bodies of the clitoris receive parasympathetic fibers via *cavernous nerves* from the uterovaginal nerve plexus. Parasympathetic stimulation produces increased vaginal secretion, erection of the clitoris, and engorgement of erectile tissue in the bulbs of the vestibule.

Administration of Pudendal and Ilioinguinal Nerve Blocks

To relieve perineal pain during childbirth, **pudendal nerve block anesthesia** may be performed by injecting a local anesthetic agent into the tissues surrounding the pudendal nerve (Fig. B3.29). The injection is made where the pudendal nerve crosses the lateral aspect of the sacrospinous ligament, near its attachment to the ischial spine. The needle may be passed through the overlying skin (as illustrated) or, more commonly perhaps, through the vagina parallel to the palpating finger. Because the fetus's head is usually sta-

tioned within the lesser pelvis at this stage, it is important that the physician's finger is always positioned between the needle tip and the baby's head during the procedure. To abolish sensation from the anterior part of the perineum, an **ilioinguinal nerve block** is performed. When patients continue to complain of pain sensation after proper administration of a pudendal or pudendal and ilioinguinal nerve blocks, it is usually the result of overlapping innervation by the perineal branch at the posterior cutaneous nerve of the thigh. Other types of anesthesia for childbirth are explained and compared in the clinical correlation (blue) box "Anesthesia for Childbirth," in this chapter. ►

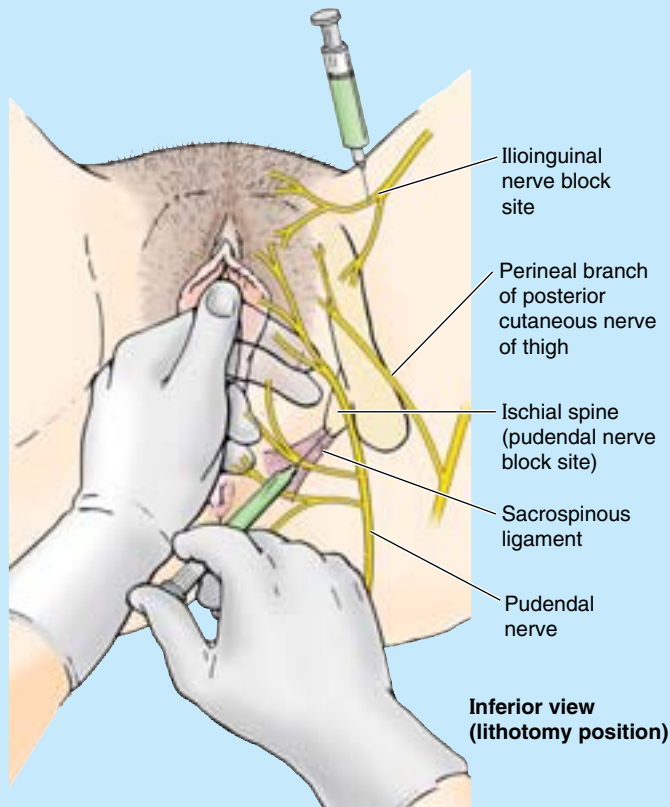
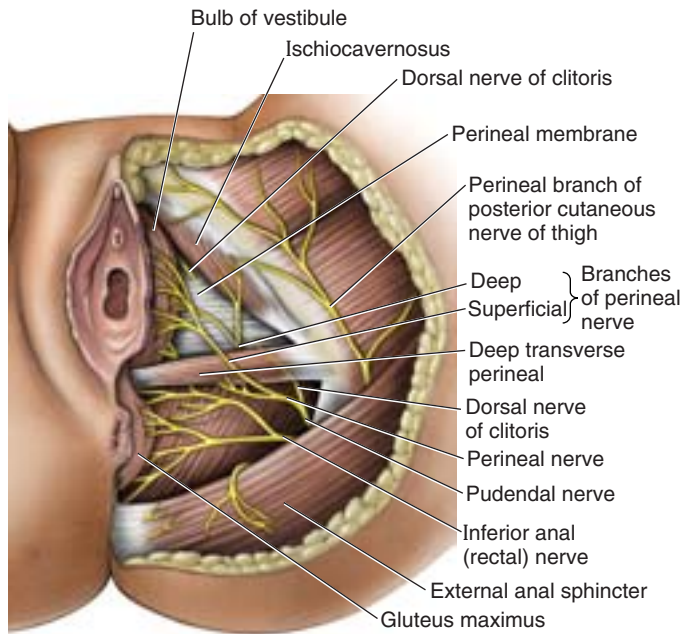


Figure B3.29



Inferior view (lithotomy position)

Figure 3.57. Nerves of female perineum. In this view, the skin, subcutaneous tissue (fatty and membranous layers), and ischioanal fat bodies have been removed. Most of the area and most features of the perineum are innervated by branches of the pudendal nerve (S2–S4). The origin of the inferior anal nerve from the pudendal nerve is obscured from view by the inferior margin of the gluteus maximus muscle.

THE BOTTOM LINE: The female external genitalia consist of concentric folds (labia) surrounding an organ for sexual stimulation (clitoris) and the separate orifices of the urinary and reproductive systems. The fat-filled mons pubis and labia majora surround the pudendal cleft, covering and protecting its contents (e.g., bearing the body's weight when sitting on a bicycle). The fat-free labia minora attach to and cover the glans of the clitoris while surrounding the vestibule, into which the external urethral and vaginal orifices and vestibular glands open. The erectile clitoris, consisting of a highly sensitive glans, short body, and crura that attach to the pubic rami and perineal membrane, functions solely as a tactile sensory organ. A hymen or its remnants, hymenal caruncles, demarcate the vagina from the vestibule and the vaginal orifice. Immediately superior to the bases of the labia minora on each side of the vaginal orifice, the bulbs of the vestibule are paired masses of erectile tissue, homologous with the bulb of the penis. The internal pudendal vessels serve most of the vulva, with the external pudendal vessels serving a smaller anterior area. Except for the glans of the clitoris and associated structures (which drain to deep inguinal and external iliac nodes), lymph from the perineum drains to the superficial inguinal nodes.

Innervation is primarily from the pudendal nerve, with additional cutaneous innervation anteriorly from anterior labial nerves (ilioinguinal and genitofemoral nerves), and laterally from the posterior cutaneous nerve of the thigh. Parasympathetic fibers, passing independently from the pelvis to the perineum as cavernous nerves, innervate the erectile tissues.

Perineal Muscles of the Female

The *superficial perineal muscles* include the *superficial transverse perineal*, *ischiocavernosus*, and *bulbospongiosus muscles* (Fig. 3.53A & B). Details of their attachments, innervation and action are provided in Table 3.9.

Kegel Exercises for Increased Development of Female Perineal Muscles

In females, the superficial transverse perineal muscle, bulbospongiosus, and external anal sphincter, through their common attachment to the perineal body, form crossing beams over the pelvic outlet to support the perineal body, as in males. In the absence of the functional demands related to urination, penile erection, and ejaculation in males, the muscles are commonly relatively undeveloped in women. However, when developed, they contribute to the support of the pelvic viscera, and help prevent urinary stress incontinence and postpartum ▶

prolapse of pelvic viscera. Therefore, many gynecologists as well as prepartum classes for participatory childbirth recommend that women practice Kegel exercises (named for J. H. Kegel, a 20th-century U.S. gynecologist) using the perineal muscles, such as successive interruption of the urine flow during urination. Prepartum childbirth classes emphasize that in learning to voluntarily contract and relax the perineal muscles, women become prepared to resist the tendency to contract the musculature during uterine contractions, allowing a less obstructed passage for the fetus and decreasing the likelihood of tearing the perineal muscles.

Vaginismus

The initial distension of the bulbospongiosus and transverse perineal muscles are thought to trigger the involuntary spasms of the perivaginal and levator ani muscles of *vaginismus*, an emotional (psychosomatic) gynecological disorder. Vaginismus is encountered clinically when pelvic examination is attempted. In mild forms, it causes *dyspareunia* (painful intercourse); in severe forms, it prevents vaginal entry and is reportedly a cause of unconsummated marriages (Fromm, 2003). ❖

THE BOTTOM LINE: Although homologous to the male muscles, the perineal muscles of the female are generally less well developed. In addition to the sphincteric functions of the external anal and urethral sphincters for maintaining fecal and urinary continence, the female perineal muscles are also capable of supporting the perineal body (which in turn support the pelvic diaphragm). Learning to control perineal muscles through routine (Kegel) exercises may reduce the risk of obstetrical laceration of perineal muscles and of prolapse of the pelvic viscera. The perineal muscles are innervated by muscular branches of the pudendal nerve.

Medical Imaging of the Pelvis and Perineum

Various diagnostic imaging techniques are used to diagnose pelvic disease and fractures and to assess congenital anomalies of the pelvis and pelvic organs.

Radiography

Plain radiographs of the pelvis (Fig. 3.58) are often used as initial screening studies in patients with symptoms of pelvic disease (e.g., ureteric calculi, bowel obstruction). ▶

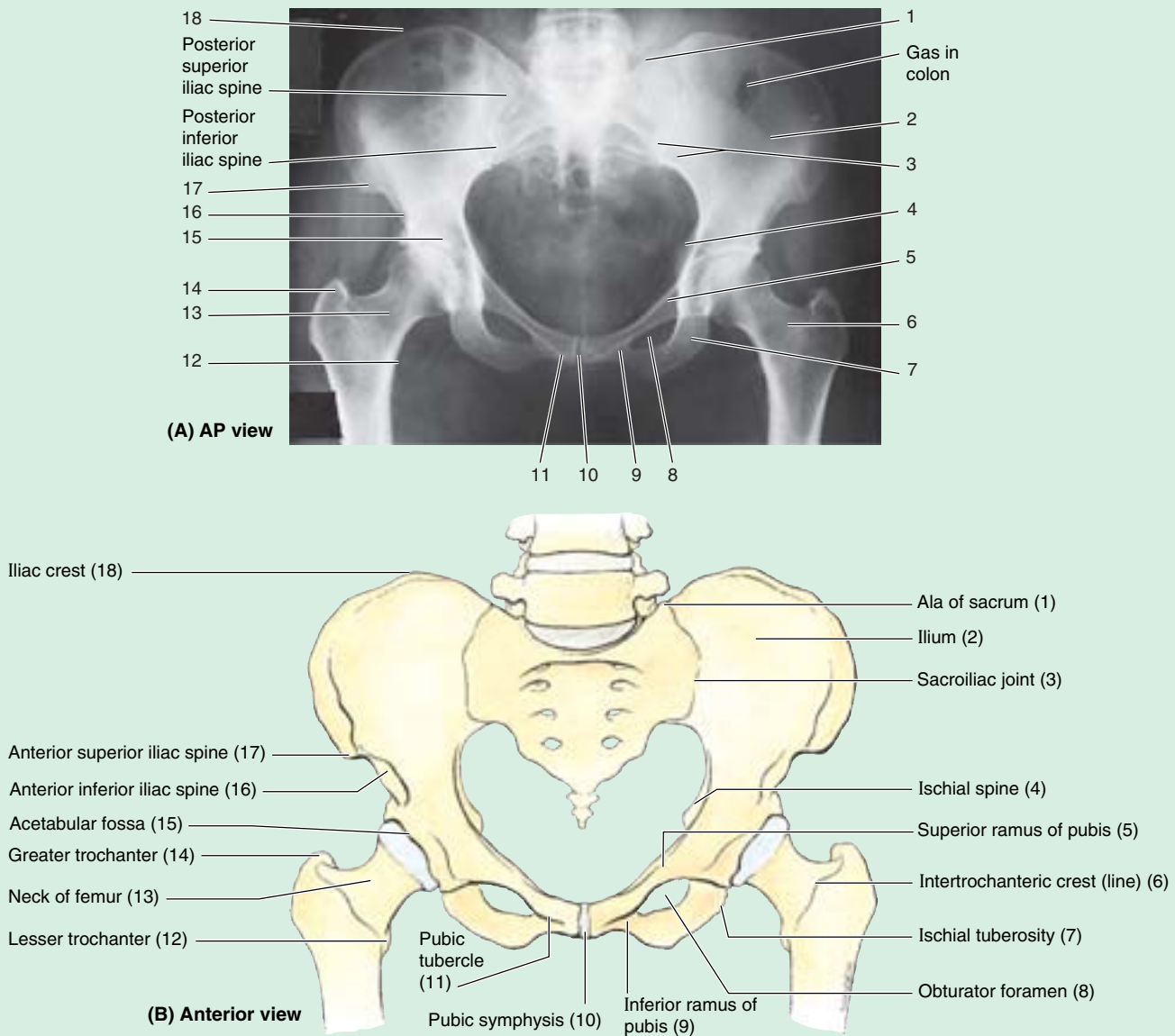


Figure 3.58. Radiograph of pelvis. A. This female pelvis demonstrates a wide subpubic angle and separation of the ischial spines. (Courtesy of Dr. E. L. Lansdown, Professor of Medical Imaging, University of Toronto, Toronto, ON, Canada.) **B.** The bony pelvis.

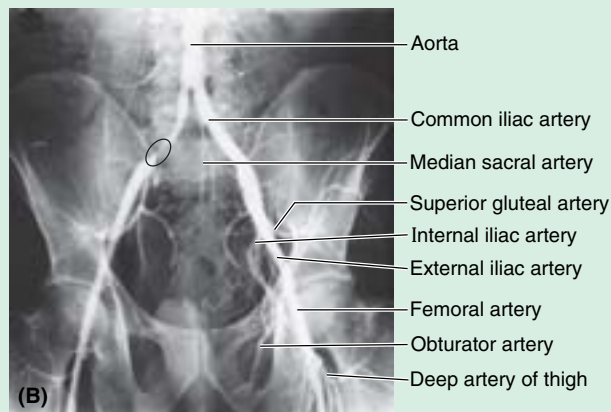
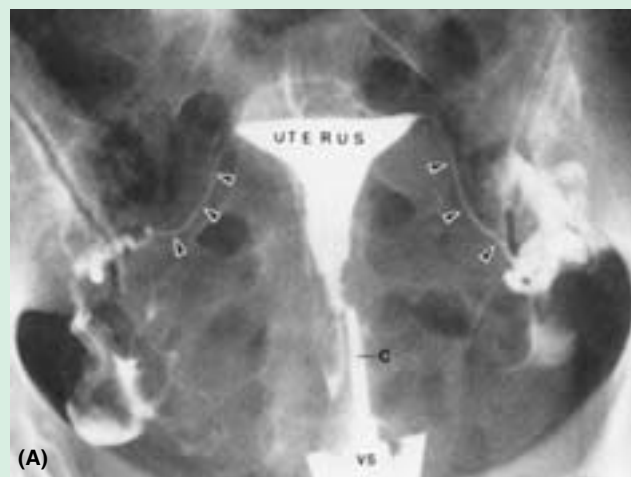
Contrast agents enhance the visualization of pelvic organs and vessels.

Hysterosalpingography, in which radiopaque dye is injected into the uterine cavity and tubes, is used for demonstrating tubal anatomy and patency (Fig. 3.59A) and for detecting uterine and tubal abnormalities (e.g., bicornuate uteri) (Fig. 3.59B).

Arteriography, visualization of arteries by X-ray imaging after injection of a radiopaque contrast medium, is used to demonstrate the pelvic arteries (Fig. 3.59C).

Ultrasonography

Ultrasonography (US; sonography) is used for obstetrical examination and for early evaluation of pelvic problems, such as screening examinations of high-risk patients for carcinoma and evaluation of congenital anomalies. Transabdominal US scanning requires a fully distended urinary bladder to displace the bowel loops from the pelvis and to provide an acoustical window through which to observe pelvic anatomy. The introduction of transrectal and ►



AP views

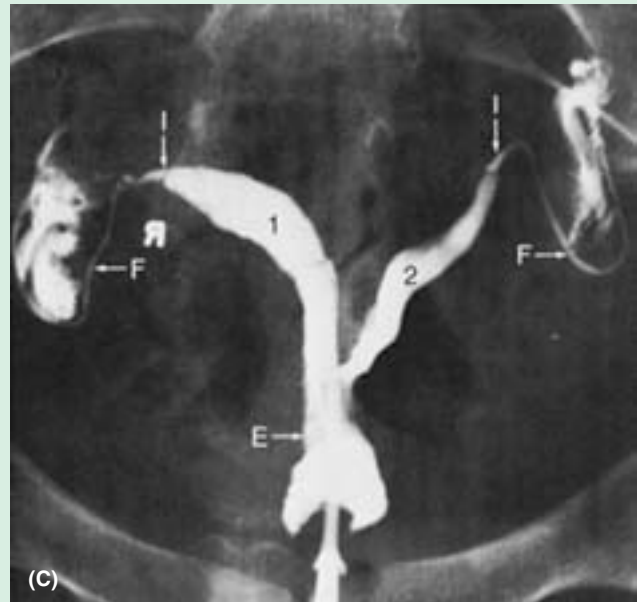


Figure 3.59. Radiograph of uterus and uterine tubes (hysterosalpingogram). **A.** Radiopaque material was injected into the uterus through the external os of the uterus. The contrast medium traveled through the triangular uterine cavity and uterine tubes (*arrowheads*) and passed into the pararectal fossae of the peritoneal cavity (lateral to the *arrowheads*). The female genital tract is in direct communication with the peritoneal cavity and is, therefore, a potential pathway for the spread of an infection from the vagina and uterus. *c*, catheter in the cervical canal, *vs*, vaginal speculum. **B.** For this iliac arteriogram, radiopaque dye has been injected into the aorta in the lumbar region. Features demonstrated include bifurcation of the aorta into right and left common iliac arteries (anterior to L4), bifurcation of the common iliacs into internal and external iliac arteries (opposite the sacroiliac joint at the level of the lumbosacral disc), and a site of narrowing (stenosis) of the right common iliac artery (*circled area* on the arteriogram). (Courtesy of Dr. D. Sniderman, Associate Professor of Medical Imaging, University of Toronto, Toronto, ON, Canada.) **C.** This hysterosalpingogram shows a bicornate uterus. *1* and *2*, uterine cavity; *E*, cervical canal; *F*, uterine tube; *I*, isthmus of tube. (Reprinted with permission from Stuart GCE, Reid DF: Diagnostic studies. In Copeland LJ (ed): *Textbook of Gynecology*. Philadelphia, Saunders, 1993.)

transvaginal ultrasonography has resulted in enhanced resolution of pelvic structures (Fig. 3.60). Transvaginal and transrectal ultrasonography enables the placing of the probe closer to the structures of interest, allowing increased resolution. For example, intrauterine blastocyst implantations can be distinguished 7–10 days earlier than with transabdominal scanning.

Computed Tomography

The anatomy of the pelvis is well demonstrated by CT. The presence of extraperitoneal fat and the relative absence of motion artifacts makes it possible to obtain excellent resolution (Fig. 3.61). An **axial scan**, a CT scan that is transverse to the axis of the body, is usually satisfactory; ►

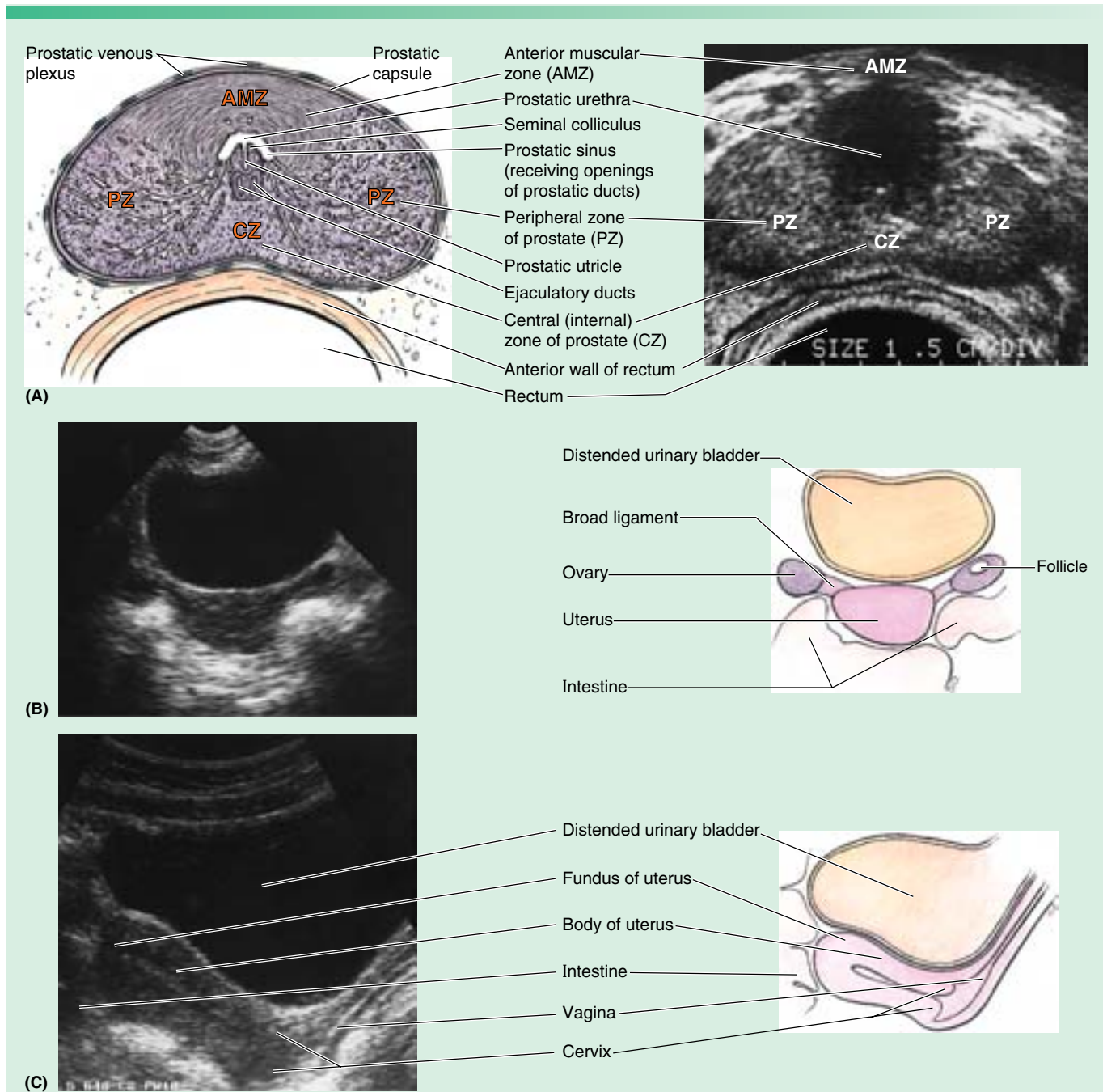


Figure 3.60. Ultrasound scans. **A.** In this transverse (transrectal) scan, the probe was inserted into the rectum to scan the anteriorly located prostate. The ducts of the glands in the peripheral zone open into the prostatic sinuses, whereas the ducts of the glands in the central (internal) zone open into the prostatic sinuses and the seminal colliculus. **B.** A transverse scan of a female’s pelvis is shown. **C.** A sagittal scan is shown. (Courtesy of Dr. A. M. Arenson, Assistant Professor of Medical Imaging, University of Toronto, Toronto, ON, Canada.)

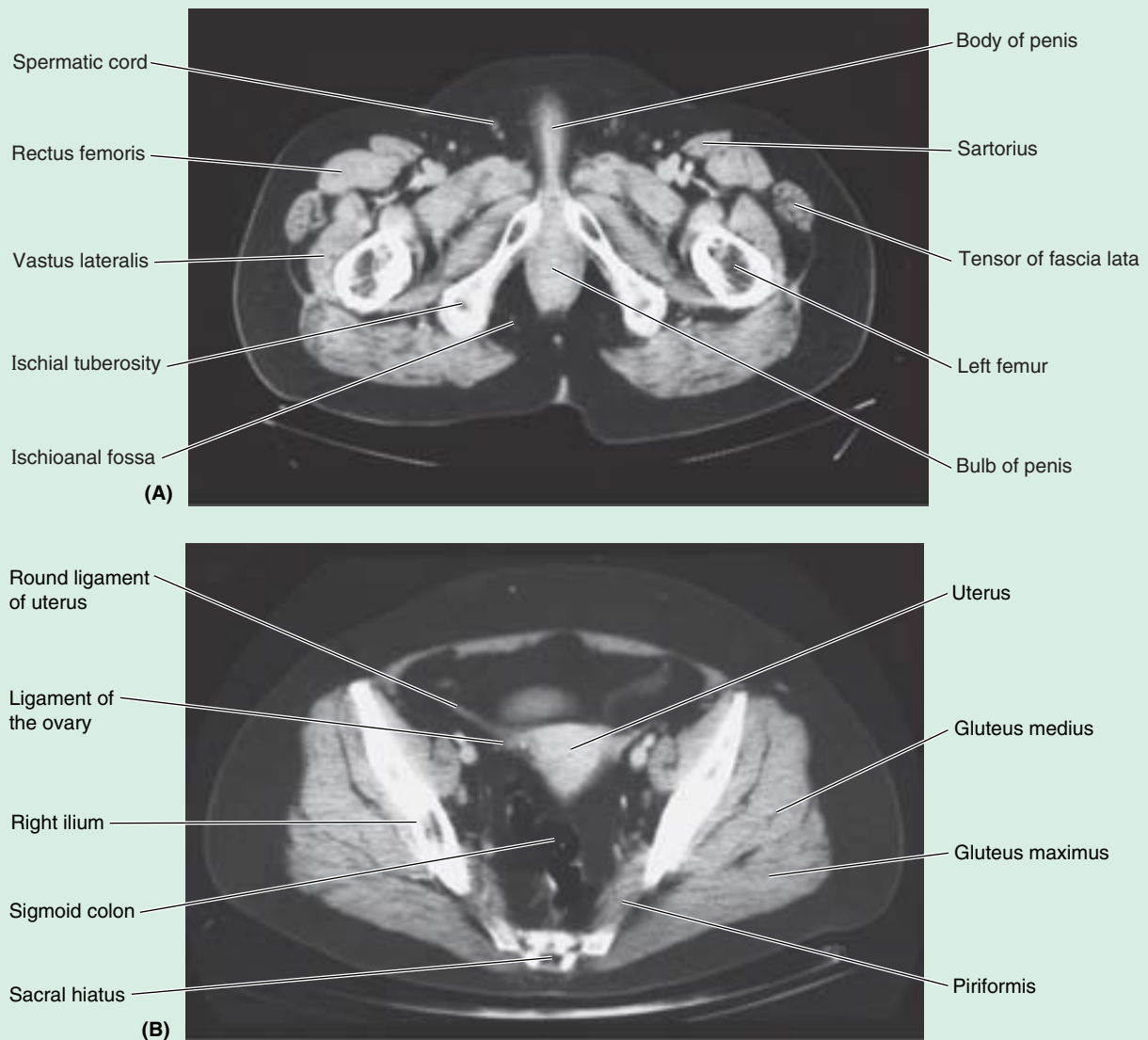
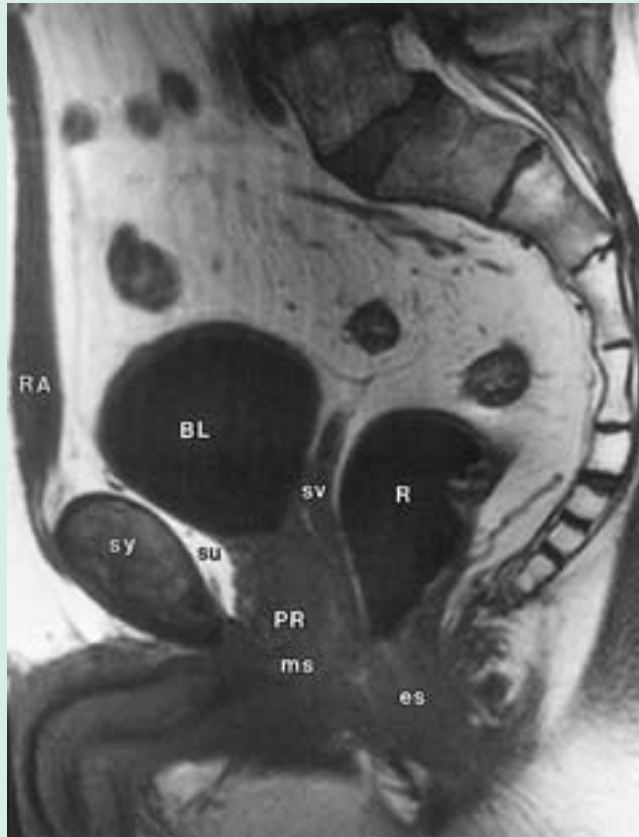


Figure 3.61. Transverse CT images of pelvis. The male (A) and female (B) pelvises are shown. (Courtesy of Dr. Donald R. Cahill, Department of Anatomy, Mayo Medical School, Rochester, MN.)

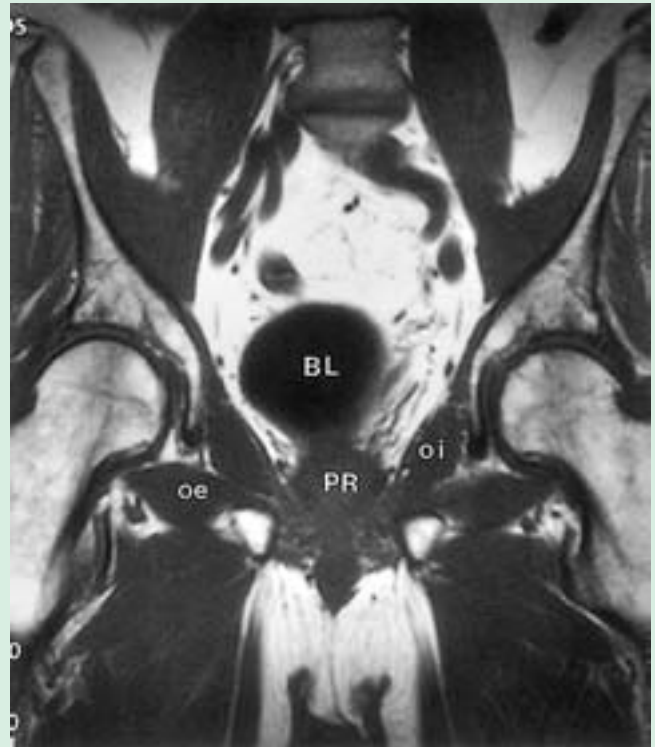
however, reformation of images into sagittal and coronal planes can provide additional information. CT is an important modality for assessing local tumor extent and in detecting metastases. It is also accurate in detecting post-operative and other abscesses.

Magnetic Resonance Imaging

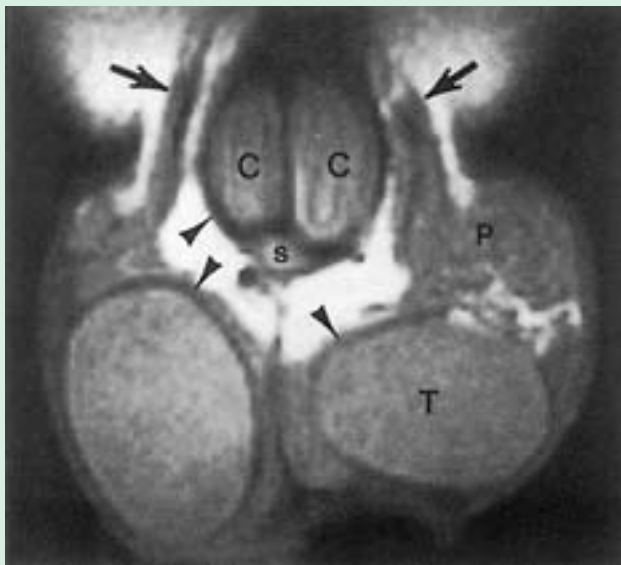MRI provides excellent evaluation of pelvic structures (Figs. 3.62 and 3.63) and permits outstanding delineation of the uterus and ovaries (Fig. 3.64). It also permits the identification of tumors (e.g., a myoma, or benign neoplasm) and congenital anomalies (e.g., bicornuate uterus). 🚫



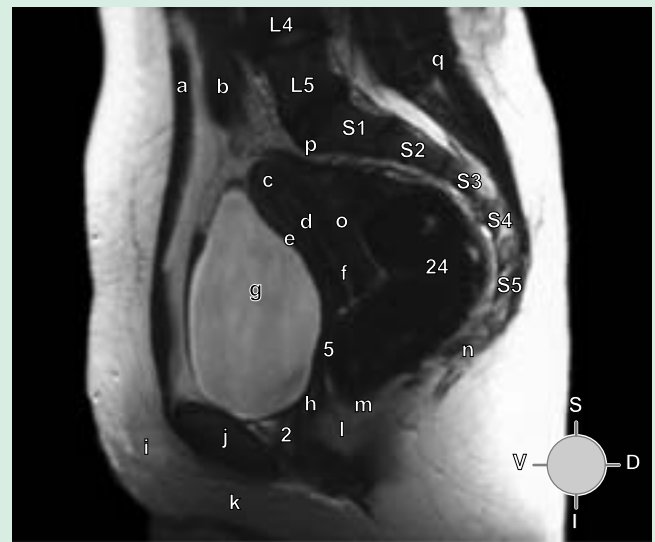
(A) Median section from left



(B) Coronal section



(C) Coronal section



(D) Median section

Figure 3.62 MRI of male pelvis and perineum. **A.** A median section is shown. The plane for the section shown in **B** is indicated. **B.** This coronal section (of the same patient as in part **A**) is at the level of the femoral heads. **C.** A coronal section showing the normal penis and testes. **D.** In this median section of the female pelvis, the bladder is distended causing a retroversion of the uterus and making potential spaces of the vesicouterine and rectouterine pouches.

Key for A

BL	Urinary bladder
es	External anal sphincter
ms	Membranous urethra
PR	Prostate
R	Rectum
RA	Rectus abdominis
su	Prevesical (retropubic) space
sv	Seminal gland
sy	Pubic symphyses

Key for B

BL	Urinary bladder
oe	Obturator externus
oi	Obturator internus
PR	Prostate

Key for C

Large arrows	spermatic cords
Arrow heads	tunica albuginea of testis and erectile bodies of penis
C	Corpus cavernosum
P	Pampiniform venous plexus
s	corpus spongiosum
T	Testis

Key for D

a	Rectus abdominis muscle
b	Peritoneal cavity
c	Fundus of uterus
d	Body of uterus
e	Retrovesicular pouch
f	Cervical os of uterus
g	Bladder
h	Urethra
i	Mons pubis
j	Pubic symphyses
k	Labia majora
l	Central perineal tendon
m	Anus
n	Coccyx
o	Rectouterine pouch
p	Sacral promontory
q	Erector spinae muscle
L	Lumbar vertebrae (followed by the number of the specific vertebra)
S	Sacral vertebrae (followed by the number of the specific vertebra)

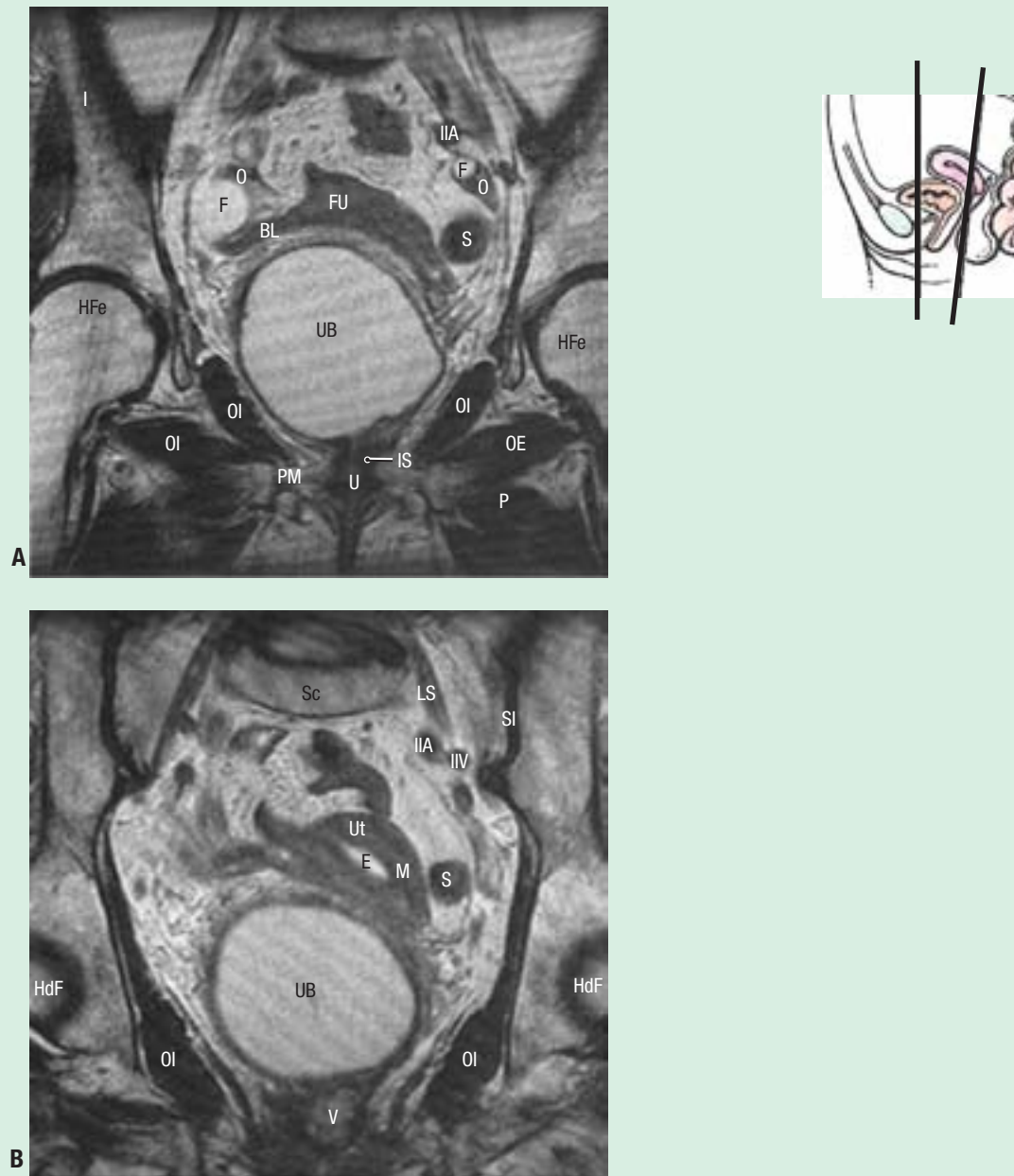


Figure 3.63. MRI studies of female pelvis. A and B. Coronal sections, along with an orientation drawing, are shown.

Key		IIV	Internal iliac vein	PM	Perineal membrane
BL	Broad ligament	IS	Internal urethral sphincter	S	Sigmoid colon
E	Endometrium	LS	Lumbosacral trunk	Sc	Sacrum
F	Follicle in ovary	M	Myometrium	SI	Sacroiliac joint
FU	Fundus of uterus	O	Ovary	U	Urethra
HdF	Head of femur	OE	Obturator externus	UB	Urinary bladder
I	Ilium	OI	Obturator internus	Ut	Uterus
IIA	Internal iliac artery	P	Pectineus	V	Vagina

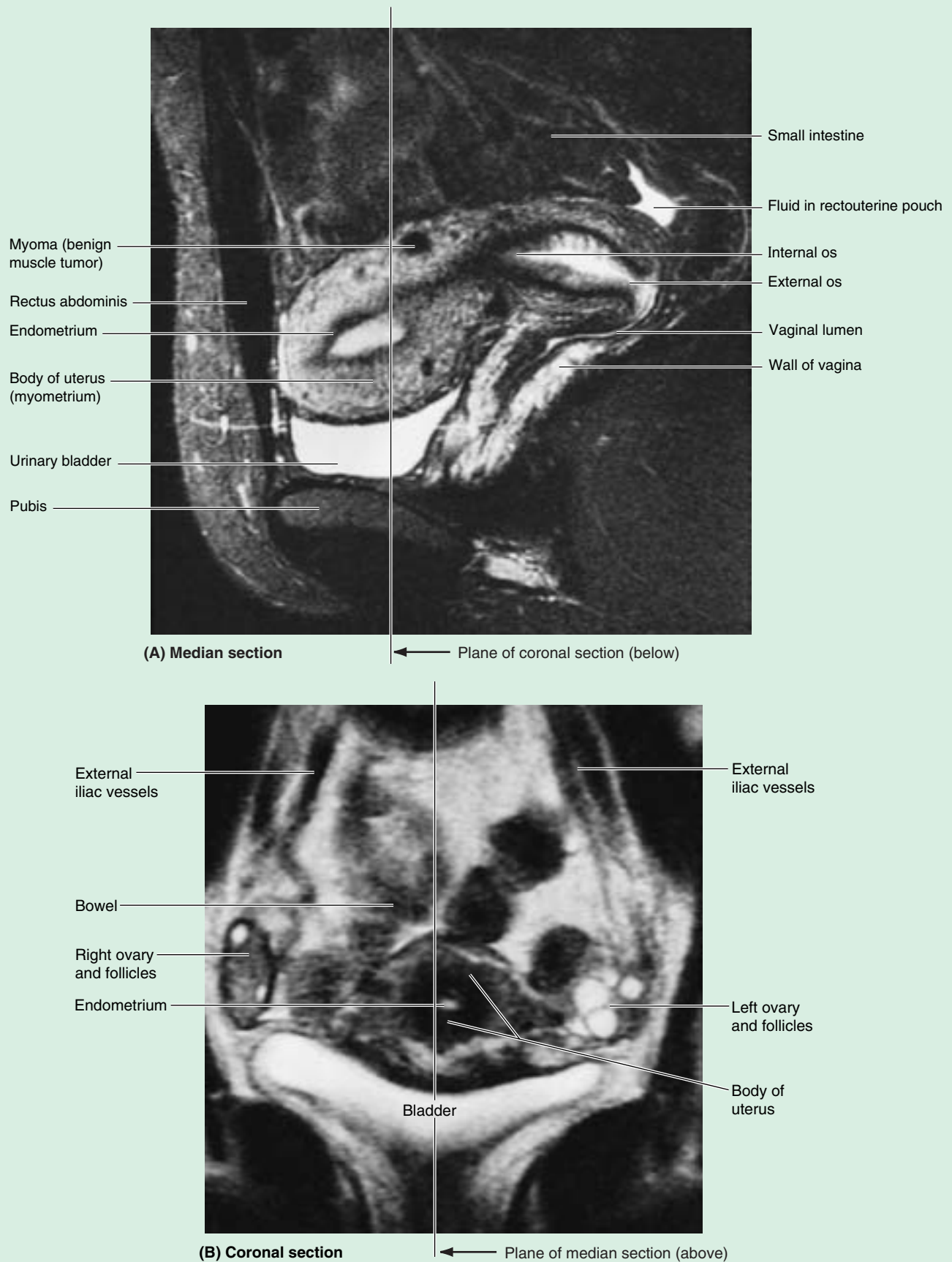


Figure 3.64. MRI studies of female pelvis. A and B. The urinary bladder, body of the uterus, vagina, and intestine are demonstrated. Compare the coronal section (part B) with the dissected specimen shown in Figure 3.31A. (Courtesy of Dr. Shirley McCarthy, Department of Diagnostic Radiology, Yale University and Yale-New Haven Hospital, New Haven, CT.)

References and Suggested Readings

- Beckmann CRB, Ling FW, Laube DW, Smith RP, Barzansky BM, Herbert WNP: *Obstetrics and Gynecology*, 4th ed., Baltimore, Lippincott Williams & Wilkins, 2002.
- Behrman RE, Kliegman RM, Arvin AM (eds): *Nelson Textbook of Pediatrics*, 16th ed. Philadelphia, Saunders, 2000.
- Berek JS: *Novak's Gynecology*, 12th ed., Baltimore, Lippincott, Williams & Wilkins, 1996.
- Cahill DR, Orland MJ, Miller G: *Atlas of Human Cross-Sectional Anatomy*, 3rd ed. New York, Wiley-Liss, 1994.
- Copeland LJ (ed): *Textbook of Gynecology*, 2nd ed. Philadelphia, Saunders, 2000.
- Federative International Committee on Anatomical Terminology [FICAT]: *Terminologia Anatomica: International Anatomical Nomenclature*. Stuttgart, Thieme, 1998.
- Fromm LM: Psychological aspects of gynecology. In Copeland LJ (ed): *Textbook of Gynecology*, 2nd ed. Philadelphia, Saunders, 2000.
- Gabbe SG, Niebyl JR, Simpson JL: *Obstetrics—Normal and Problem Pregnancies*, 4th ed., New York, Churchill Livingstone, 2002.
- Hatch K: Urinary tract injury and fistula. In Copeland LJ (ed): *Textbook of Gynecology*, 2nd ed. Philadelphia, Saunders, 2000.
- Krebs H-B: Premalignant lesions of the cervix. In Copeland LJ (ed): *Textbook of Gynecology*, 2nd ed. Philadelphia, Saunders, 2000.
- Moore KL, Persaud TVN: *The Developing Human. Clinically Oriented Embryology*, 7th ed. Philadelphia, Saunders, 2003.
- Morris M, Burke TW: Cervical cancer. In Copeland LJ (ed): *Textbook of Gynecology*, 2nd ed. Philadelphia, Saunders, 2000.
- Myers RP, Cahill DR, Devine RM, King BF: Anatomy of radical prostatectomy as defined by magnetic resonance imaging. *J Urol* 159:2148, 1998a.
- Myers RP, King BF, Cahill DR: Deep perineal “space” as defined by magnetic resonance imaging. *Clin Anat* 11:132, 1998b.
- Oelrich TM: The urethral sphincter muscle in the male. *Am J Anat* 158:229, 1980.
- Oelrich TM: The striated urogenital sphincter muscle in the female. *Anat Rec* 205:223, 1983.
- O’Rahilly R: *Gardner-Gray-O’Rahilly Anatomy. A Regional Study of Human Structure*, 5th ed. Philadelphia, Saunders, 1986.
- Stormont TJ, Cahill DR, King BF, Myers RP: Fascias of the male external genitalia and perineum. *Clin Anat* 7:115, 1994.
- Stuart GCE, Reid DF: Diagnostic studies. In Copeland LJ (ed): *Textbook of Gynecology*, 2nd ed Philadelphia, Saunders, 2000.
- Walsh PC, Retnik AB, Vaughn ED, Wein AJ: *Campbell's Urology*, 7th ed. Philadelphia, Saunders, 1998.
- Wendell-Smith CP, Wilson PM: The vulva, vagina, and urethra and the musculature of the pelvic floor. In Phillip E, Setchell M, Ginsburg J (eds): *Scientific Foundations of Obstetrics and Gynecology*. Oxford, Butterworth-Heinemann, 1991.
- Wendell-Smith CP: Muscles and fasciae of the pelvis. In Williams PL, Bannister LH, Berry MM, Collins P, Dussek JE, Fergusson MWJ (eds): *Gray's Anatomy, The Anatomical Basis of Medicine and Surgery*, 38th ed. Edinburgh, Churchill-Livingstone, 1995.
- Williams PL, Bannister LH, Berry MM, Collins P, Dussek JE, Fergusson MWJ (eds): *Gray's Anatomy, The Anatomical Basis of Medicine and Surgery*, 38th ed. Edinburgh, Churchill Livingstone, 1995.