

3 1761 01134579 0



UNIVERSITY OF TORONTO

NERVES OF THE HUMAN BODY

WITH DIAGRAMS

C. R. Whitaker

OLD
CLASS
MA
H
c. 1
BMED

Handle with

EXTREME CARE

This volume is damaged or brittle
and **CANNOT** be repaired!

- photocopy *only if necessary*
- return to staff
- *do not* put in bookdrop


Gerstein Science Information Centre



NERVES OF THE HUMAN BODY

HUGHES'
Nerves of the Human
Body

With Plates



BY

CHAS. R. WHITTAKER, F.R.C.S. (ED.), F.R.S.E., ETC.

SENIOR DEMONSTRATOR OF ANATOMY, SURGEONS' HALL, EDINBURGH; LECTURER
ON BIOLOGY, NEW SCHOOL OF MEDICINE, EDINBURGH

*Author of "A Manual of Surgical Anatomy," "Essentials of
Surface Anatomy," Etc.*

SECOND EDITION, REVISED AND ENLARGED

230135
6.3.29

EDINBURGH
E. & S. LIVINGSTONE
17 TEVIOT PLACE

1918

PREFACE TO SECOND EDITION.

In this new edition of the late Professor Hughes's Handbook on the Nerves of the Body, the letterpress has been rewritten and enlarged, while new blocks have been made from the plates of the original edition.

The old terminology has been adopted through the text. Where these terms differ materially from the B.N.A. the latter have been placed within brackets.

The author desires to thank Dr A. Walker for his valuable assistance in reading the proofs, and for compiling the Index.

CHAS. R. WHITTAKER.

British Expeditionary Force,
1918.

CONTENTS.

CRANIAL NERVES.

	PAGE
FIRST OR OLFACTORY	I
SECOND OR OPTIC	I
THIRD OR OCULO-MOTOR	I
FOURTH OR TROCHLEAR	2
FIFTH OR TRIGEMINAL	5
OPHTHALMIC DIVISION	7
SUPERIOR MAXILLARY DIVISION	7
INFERIOR MAXILLARY DIVISION	8
GANGLIA OF TRIGEMINAL	II
CILIARY	12
MECKEL'S	12
OTIC	13
SUBMAXILLARY	13
SIXTH OR ABDUCENS	13
SEVENTH OR FACIAL	14
EIGHTH OR AUDITORY	16
NINTH OR GLOSSO-PHARYNGEAL	19
TENTH OR VAGUS	20
ELEVENTH OR SPINAL ACCESSORY	25
TWELFTH OR HYPOGLOSSAL	26

SPINAL NERVES.

POSTERIOR PRIMARY DIVISIONS	29
ANTERIOR PRIMARY DIVISIONS	31
CERVICAL PLEXUS	31
BRACHIAL PLEXUS	35
THORACIC INTERCOSTALS	44
ABDOMINAL INTERCOSTALS	46
SUBCOSTAL	47
LUMBAR PLEXUS	48
ANTERIOR CRURAL	49
OBTURATOR	50
SACRAL PLEXUS	51
INTERNAL PUDIC	55

	PAGE
GREAT SCIATIC	56
INTERNAL POPLITEAL	57
POSTERIOR TIBIAL	57
MEDIAL PLANTAR	58
LATERAL PLANTAR	58
EXTERNAL POPLITEAL	59
ANTERIOR TIBIAL	59
MUSCULO-CUTANEOUS	60

SYMPATHETIC SYSTEM.

CERVICAL PORTION OF SYMPATHETIC	63
THORACIC PORTION OF SYMPATHETIC	66
LUMBAR PORTION OF SYMPATHETIC	69
PELVIC PORTION OF SYMPATHETIC	69
SYMPATHETIC PLEXUSES	70
CARDIAC PLEXUSES	70
CŒLIAC PLEXUS	70
PELVIC PLEXUSES	71

PLATES.

1. FIRST TO FOURTH CRANIAL NERVES	3
2. FIFTH CRANIAL NERVE	9
3. SUPERFICIAL NERVES OF FACE AND NECK	17
4. FACIAL AND AUDITORY NERVES	21
5. EIGHTH PAIR OF NERVES	27
6. HYPOGLOSSAL NERVE	33
7. CERVICAL PLEXUS	39
8. BRACHIAL PLEXUS	45
9. LUMBO-SACRAL PLEXUS	53
10. SYMPATHETIC SYSTEM	61
11. CUTANEOUS AREAS OF UPPER EXTREMITY	67
12. CUTANEOUS AREAS OF LOWER EXTREMITY	73

Nerves of the Human Body.



CRANIAL NERVES.

FIRST OR OLFACTORY NERVE (Plate I.).

The olfactory nerve comprises (*a*) the olfactory filaments; (*b*) olfactory bulb; (*c*) olfactory tract; and (*d*) olfactory roots.

Olfactory Filaments.—These non-medullated fibres, twenty in number, are the axons of the bipolar nerve cells situated in the olfactory mucous membrane. Three groups are described (*a*) *medial*, from the nasal septum; (*b*) *central*, from the roof of the nose, and (*c*) *lateral*, from the lateral wall. The filaments pass through the cribriform plate (lamina cribrosa) of the ethmoid, to enter the under surface of the olfactory bulb.

Olfactory Bulb.—A small oval-shaped mass of grey matter resting upon the upper surface of the cribriform plate.

Olfactory Tract.—This elongated band of white matter arises from the posterior extremity of the olfactory bulb, and occupies a groove, the olfactory sulcus, on the inferior aspect of the frontal lobe. It is connected to the cerebrum by the olfactory roots (*striæ*).

Olfactory Roots.—There are two olfactory roots, the lateral of which can be traced to the piriform area of the temporal lobe, while the medial root passes to the gyrus fornicatus.

SECOND OR OPTIC NERVE (Plate I.).

Along with the second pair of cranial nerves the optic chiasma and the optic tracts are described. The optic nerves are connected to the brain through the agency of the optic tracts.

Optic Tracts.—Arise from the pulvinar of the optic thalamus, from the lateral and medial corpora geniculata, and from the brachium of the superior colliculus. The tracts wind round the crura cerebri (cerebral peduncles) and join the optic chiasma. In the chiasma the medial fibres decussate with the corresponding fibres of the opposite tract, while the lateral fibres pass on to the eyeball of the same side.

Optic Chiasma.—This commissure lies on the inferior surface of the floor of the third ventricle, and is lodged in a groove immediately in front of the olivary eminence. In the posterior part of the chiasma will be found a bundle of fibres linking up the optic tracts, the *commissure of Gudden*.

Optic Nerves.—These nerves pierce the dura mater to enter the orbit through the optic foramen. Each is accompanied by the ophthalmic artery. Directed forwards and laterally the nerve runs beneath the superior rectus muscle. Here it is crossed obliquely by the nasal (naso-ciliary) nerve and the ophthalmic artery, and is surrounded by the ciliary nerves and vessels. It penetrates the eyeball one-eighth of an inch on the medial side of the antero-posterior axis, and having passed through the sclerotic and choroid coats, spreads out to form the inner layer of the retina. The *arteria centralis retinae* lies in the substance of the nerve.

THIRD OR OCULO-MOTOR NERVE (Plate I.).

Deep Origin.—From the grey matter of the aqueduct of Sylvius (*aquæductus cerebri*).

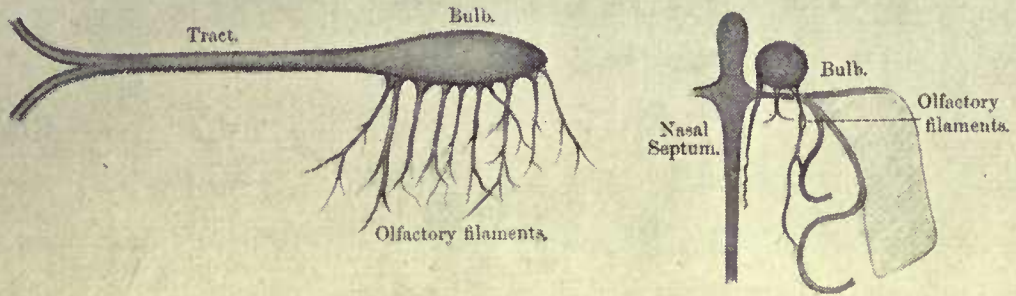
Superficial Origin.—The nerve emerges on the medial side of the crus cerebri (cerebral peduncle) immediately anterior to the pons.

Course.—From its superficial origin the nerve passes forwards between the posterior cerebral and superior cerebellar arteries to pierce the dura mater close to the posterior clinoid process. It next traverses the lateral wall of the cavernous sinus, and enters the orbit through the sphenoidal (superior orbital) fissure by passing between the two heads of the lateral rectus. In the orbit it supplies all the muscles, except the superior oblique and lateral rectus. As it lies in the sphenoidal fissure, the oculo-motor divides into two parts which are separated by the nasal (naso-ciliary) nerve. The upper portion supplies the superior rectus and levator palpebræ superioris, while the inferior division innervates the inferior rectus, medial rectus, and inferior oblique. This latter branch furnishes the motor root to the ciliary ganglion.

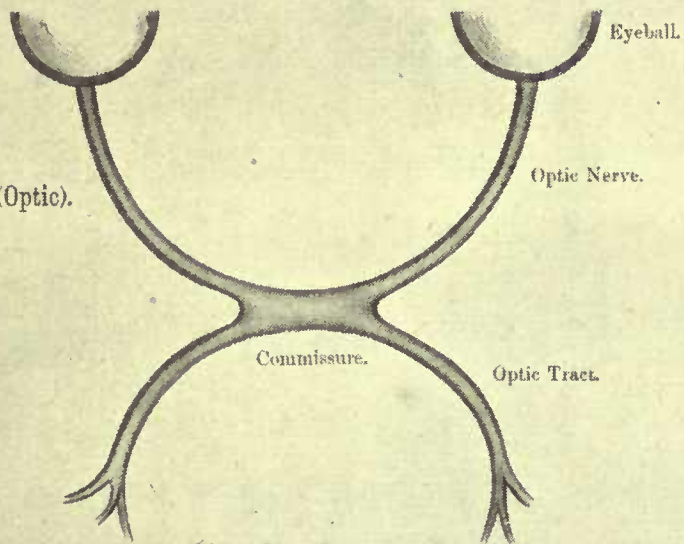
PLATE I.

Plate I.

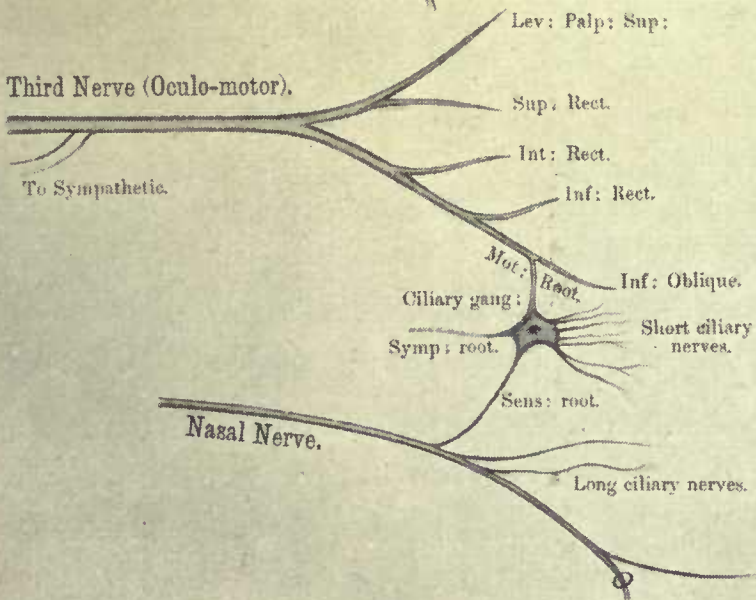
First Nerve (Olfactory).




Second Nerve (Optic).




Third Nerve (Oculo-motor).



Fourth Nerve (Trochlear).



Sixth Nerve (Abducens).



Communications.—As the third nerve lies in the lateral wall of the cavernous sinus, it is connected with the cavernous sympathetic plexus. It also receives a minute twig from the ophthalmic division of the trigeminal.

FOURTH OR TROCHLEAR NERVE (Plate I.).

Deep Origin.—From the grey matter of the aqueduct of Sylvius (aquæductus cerebri) immediately below the origin of the oculo-motor nerve. From this it passes to the anterior medullary velum where it decussates with its fellow of the opposite side.

Superficial Origin.—It emerges from the upper part of the anterior medullary velum, and passes round the cerebral peduncle.

Course.—After piercing the dura mater behind the posterior clinoid process, the trochlear proceeds forwards in the lateral wall of the cavernous sinus, and enters the orbit *via* the sphenoidal (superior orbital) fissure. It supplies the superior oblique muscle on its upper surface.

Communications.—These are similar to those of the oculo-motor nerve.

FIFTH OR TRIGEMINAL NERVE (Plate II.).

The trigeminal nerve has two roots, motor and sensory.

Deep Origin.—(a) *Motor*; the motor nucleus is situated in the tegmental portion of the pons, on the medial side of the main sensory nucleus; (b) *sensory*; these fibres arise from the nerve cells of the Gasserian (semilunar) ganglion. They terminate in the main sensory nucleus in the tegmentum of the pons, and also in a column of grey matter continuous with the substantia gelatinosa of the spinal cord.

A *mesencephalic root* issues from the grey matter around the aqueduct of Sylvius; authorities differ as to whether this root joins the motor or sensory part of the trigeminal.

Superficial Origin.—The roots emerge from the lateral aspect of the pons, and proceeding forwards enter a small pocket of dura mater, the *cavum Meckelii*.

Course.—In the *cavum Meckelii* a large ganglion, the Gasserian (semilunar), develops upon the sensory root. The ganglion lies in the middle cranial fossa near the apex of the petrous portion of the temporal bone. The motor root of the trigeminal passes beneath the ganglion. It is important to note the chief relations of the

ganglion, namely the cavernous sinus on the medial side, and the internal carotid artery, which is first inferior then medial. Three trunks arise from the anterior border of the ganglion; the ophthalmic and superior maxillary divisions are entirely sensory; the inferior maxillary division is a mixed nerve, as it is joined by the motor root.

OPHTHALMIC DIVISION (Plate II.).

After furnishing a small twig to the dura mater, the ophthalmic division travels forwards in the lateral wall of the cavernous sinus, and enters the orbit through the medium of the sphenoidal (superior orbital) fissure. In the fissure it splits into three branches, namely the frontal, nasal (naso-ciliary), and lacrimal. The frontal and lacrimal nerves enter the orbit above the muscles, but the nasal nerve passes between the two heads of the lateral rectus.

Communications.—In the wall of the cavernous sinus, the ophthalmic division communicates with the sympathetic, oculo-motor, trochlear, and abducens nerves.

The Lacrimal Nerve passes along the outer part of the orbit to supply the lacrimal gland, conjunctiva, and skin of the upper eyelid.

The Frontal Nerve divides into the *supra-orbital* and *supra-trochlear* which lie beneath the roof of the orbit. The former is the larger and is situated laterally to the supra-trochlear. It reaches the scalp by means of the supra-orbital notch, divides into medial and lateral, and communicates with the temporal branches of the facial nerve. The supra-trochlear runs above the pulley of the superior oblique muscle; it communicates with the infra-trochlear branch of the nasal. The frontal nerve is distributed to the mucous membrane of the frontal air sinus, and to the integument of the upper eyelid, forehead, and scalp.

The Nasal (Naso-Ciliary) Nerve crosses the optic nerve obliquely from the lateral to the medial side, lying under cover of the superior rectus and superior oblique muscles. After leaving the orbit by the anterior ethmoidal foramen, the nerve passes over the cribriform plate of the ethmoid and enters the nose through the nasal slit. In the nose the nerve gives off a medial branch to the nasal septum, and a lateral branch which reaches the face between the nasal bone and alar cartilage. It supplies the skin on the lower part of the side of the nose, communicating with the zygomatic branches of the facial.

Three branches arise from the nasal nerve in the orbit:—(a) a twig to the ciliary ganglion; (b) two long ciliary nerves to the eye-

ball; and (c) the infra-trochlear, which passes beneath the pulley of the superior oblique muscle to supply the skin of the medial parts of the eyelids and upper part of the nose. It communicates with the zygomatic branches of the facial nerve.

SUPERIOR MAXILLARY DIVISION (Plate II.)

After traversing the outer wall of the cavernous sinus, the superior maxillary division emerges from the middle cranial fossa by means of the foramen rotundum, and enters the speno-maxillary (pterygo-palatine) fossa. The nerve crosses the fossa, and leaves it *via* the inferior orbital fissure to run in the infra-orbital groove and canal. Here it becomes the infra-orbital nerve, and appears on the face at the infra-orbital foramen where it divides into its terminal branches.

The branches of the superior maxillary division can be classified according to their origin as (a) cranial; (b) pterygo-palatine; (c) infra-orbital; and (d) facial.

Branches—

(a) **Cranial.**—A small *recurrent* branch to the dura mater.

(b) **Pterygo-Palatine:**—

(1) *Spheno-palatine*, two twigs to Meckel's (spheno-palatine) ganglion.

(2) *Orbital* (zygomatic) passes to the orbit through the inferior orbital fissure, and divides into temporal (zygomatoco-temporal) and malar (zygomatoco-facial). Each of these perforates the malar (zygomatic) bone to supply the skin in its vicinity, and communicates with the corresponding branches of the facial nerve.

(3) *Posterior superior dental* (*alveolar*) enter the minute foramina on the zygomatic surface of the maxilla to supply the molar teeth.

(c) **Infra-Orbital.** — *Middle and anterior dental* (*alveolar*) nerves arise from the infra-orbital, and tunnelling the anterior wall of the antrum of Highmore (maxillary antrum) innervate the premolar, canine, and incisor teeth.

(d) **Facial:**—

(1) *Palpebral* to skin of lower eyelid.

(2) *Nasal* to skin of side of nose.

(3) *Labial* to skin of upper lip.

They communicate with the zygomatic branches of the facial, forming the infra-orbital plexus.

INFERIOR MAXILLARY DIVISION (Plate II.)

This consists of a sensory portion derived from the Gasserian (semilunar) ganglion together with the motor root of the trigeminal. The two portions pass separately through the foramen ovale, and join immediately afterwards to form a common trunk which lies in the pterygo-maxillary region, beneath the external pterygoid. After supplying a *recurrent* branch to the dura mater, which enters the cranium through the foramen spinosum, the trunk furnishes a twig to the *internal pterygoid*, and divides into a small or anterior, and a large or posterior division.

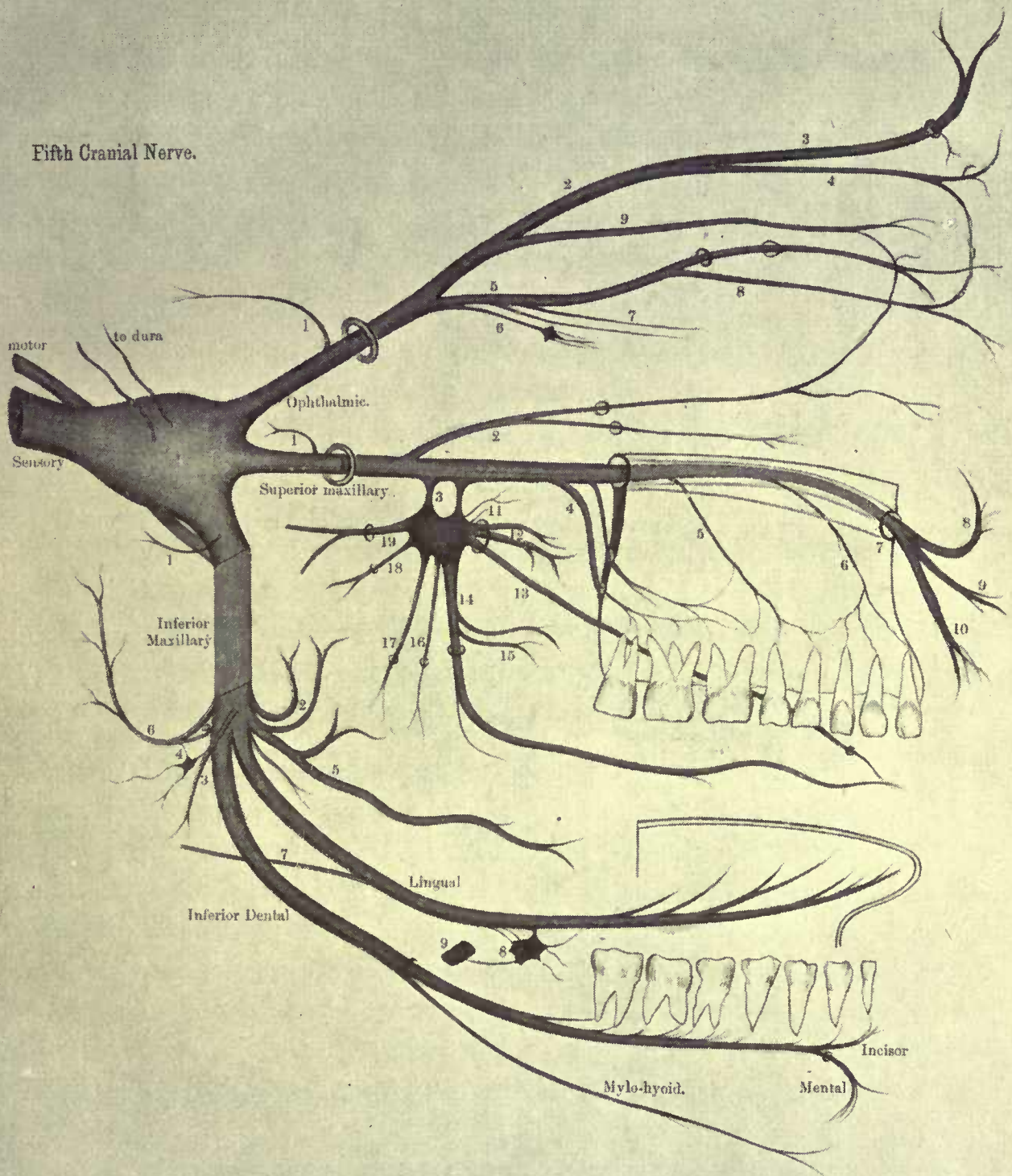
The Anterior Division is chiefly motor in function, and supplies:—

- (a) *Deep temporal branches*, two in number, to the temporal muscle.
- (b) *Masseteric* passes through the sigmoid (mandibular) notch of the lower jaw to the masseter.
- (c) *Pterygoid* to the external pterygoid.
- (d) *Long buccal* (a sensory branch) goes between the two heads of the external pterygoid, pierces the buccinator, and supplies the skin and mucous membrane of the cheek. It communicates with the corresponding branches of the facial.

The **Posterior Division** of the inferior maxillary gives off the auriculo-temporal, inferior dental (alveolar) and lingual branches. The AURICULO-TEMPORAL nerve arises by two rootlets which embrace the middle meningeal artery; it then passes backwards on the medial side of the neck of the mandible, between the latter and the internal lateral (spheno-mandibular) ligament, to reach the parotid gland. From the gland the auriculo-temporal crosses the zygomatic arch, posterior to the superficial temporal artery, and terminates in branches which innervate the skin of the temporal region, and effect communications with the temporal branches of the facial. The branches of the auriculo-temporal are:—

- (a) *Articular* to the temporo-maxillary joint.
- (b) *Glandular* to the parotid gland.
- (c) *Auditory* to the external auditory meatus and tympanic membrane.

Fifth Cranial Nerve.



KEY TO PLATE II.

Ophthalmic division.—1. Recurrent. 2. Frontal. 3. Supraorbital. 4. Supra-trochlear. 5. Nasal. 6. To ciliary ganglion. 7. Long ciliary. 8. Infra-trochlear. 9. Lacrimal.

Superior maxillary division.—1. Recurrent. 2. Orbital. 3. Spheno-palatine. 4. Posterior dental. 5. Middle dental. 6. Anterior dental. 7. Infra-orbital. 8. Palpebral. 9. Nasal. 10. Labial. 11. Orbital. 12. Superior nasal. 13. Naso-palatine. 14. Anterior palatine. 15. Inferior nasal. 16. Posterior palatine. 17. Lateral Palatine. 18. Pharyngeal. 19. Vidian.

Inferior maxillary.—1. Recurrent. 2. Deep temporal. 3. To internal pterygoid. 4. Otic ganglion. 5. Long buccal. 6. Auriculo-temporal. 7. Chorda tympani. 8. Submaxillary ganglion. 9. Facial artery.

- (d) *Cutaneous* to the upper half of the lateral aspect of the pinna, and the skin of the temporal region.
- (e) *Communicating* to the otic ganglion and facial nerve.

The **Inferior Dental (Alveolar)** nerve descends beneath the external pterygoid muscle to the interval between the internal lateral ligament and the ramus of the mandible. Here it enters the inferior dental (alveolar) canal, along which it passes as far as the mental foramen, giving off twigs in its course to the teeth. While in the canal the inferior dental divides into *mental* and *incisor* branches.

The branches of the inferior dental are :—

- (a) *Mylo-hyoid* given off from the main trunk previous to its entry into the canal. It occupies a groove on the medial surface of the bone, and in the sub-maxillary triangle of the neck, supplies the mylo-hyoid and anterior belly of the digastric muscles.
- (b) *Incisor* is distributed to the incisor and canine teeth.
- (c) *Mental* emerges from the mental foramen to supply the skin of the chin and lower lip, and the mucous membrane of the latter. It communicates with the supramandibular branch of the facial.

The **Lingual** nerve is smaller than the inferior dental, and as it descends upon the internal pterygoid, occupies an anterior plane to that nerve. After passing beneath the mucous membrane of the mouth in the interval between the mylo-hyoid and the hyoglossus, the lingual runs below Wharton's (sub-maxillary) duct to supply the anterior two-thirds of the tongue along its dorsum and sides. Near its origin the nerve is joined at an acute angle by the *chorda tympani* branch of the facial. The lingual nerve furnishes two twigs to the sub-maxillary ganglion, and communicates with the hypoglossal.

GANGLIA OF THE TRIGEMINAL.

In addition to the Gasserian (semilunar) there are four ganglia connected with the trigeminal nerve. These are :—

- (a) With the OPTHALMIC division—the *ciliary ganglion*.
- (b) With the SUPERIOR MAXILLARY division—*Meckel's (sphenopalatine) ganglion*.
- (c) With the INFERIOR MAXILLARY division—the *otic and sub-maxillary ganglia*.

Each ganglion receives sensory, motor, and sympathetic roots, and each gives off small branches of distribution.

CILIARY GANGLION (Plate I.).

Relations.—The ganglion occupies the back of the orbit between the lateral rectus muscle and the optic nerve. It lies in front of the ophthalmic artery.

Roots.—The sensory or long root is derived from the nasal (naso-ciliary) branch of the ophthalmic, the motor or short root from the inferior division of the oculo-motor, and the sympathetic root from the plexus around the internal carotid artery.

Branches—

Twelve to fourteen short ciliary nerves which accompany the optic nerve to the eyeball. They innervate the ciliary muscle and the iris.

The *circular fibres* of the iris are supplied by the oculo-motor nerve, and the *radial fibres* by the sympathetic.

MECKEL'S GANGLION (Plate II.).

Relations.—Meckel's or the spheno-palatine ganglion is found in the spheno-maxillary (pterygo-palatine) fossa. It lies immediately below the superior maxillary nerve and near to the spheno-palatine foramen.

Roots.—The sensory roots of the spheno-palatine ganglion are derived from the superior maxillary, while the motor and sympathetic fibres are conveyed by the Vidian (nerve of the pterygoid canal). The Vidian is formed by the junction of the greater superficial petrosal branch of the facial nerve with the deep petrosal branch of the carotid sympathetic plexus.

Branches—

There are seven branches arranged in four groups, namely :—

- (a) *Orbital*, a minute twig to the orbital periosteum.
- (b) *Pharyngeal* supplies the mucous membrane of the roof of the pharynx.
- (c) *Palatine*, anterior, middle, and posterior, which descend through separate bony canals to ramify in the mucous membrane of the hard and soft palate. The anterior palatine gives off an *inferior nasal* branch to the mucous membrane of the nose.
- (d) *Nasal* enter the nose *via* the spheno-palatine foramen. They are two in number, a *superior nasal*, and a *naso-palatine*. The latter crosses the root of the nose and passes obliquely downwards grooving the vomer. The naso-palatines leave the nose through the foramina of

Scarpa, the left nerve lying in front of the right one. On the palate they communicate with the anterior palatine.

OTIC GANGLION (Plates II. and IV.).

Relations.—The ganglion lies immediately below the foramen ovale, in front of the middle meningeal artery, and in close contact with the nerve to the internal pterygoid.

Roots.—The motor fibres are derived from the nerve to the internal pterygoid, the sensory ones from the smaller superficial petrosal nerve (*see* facial nerve), and the sympathetic element from the plexus around the middle meningeal artery.

Branches—

Two muscles are supplied by the ganglion (*a*) the tensor tympani, and (*b*) the tensor palati. Communicating branches are given off to the Vidian, auriculo-temporal, and chorda tympani.

SUBMAXILLARY GANGLION (Plate II.).

Relations.—The ganglion rests upon the hyoglossus, between the lingual nerve and Wharton's (submaxillary) duct.

Roots.—From the lingual, chorda tympani, and the sympathetic plexus upon the facial (external maxillary) artery.

Branches—

These are distributed to the submaxillary and sublingual salivary glands.

SIXTH OR ABDUCENS NERVE (Plate I.).

Deep Origin.—The dorsal part of the tegmentum of the pons, near the middle line.

Superficial Origin.—The nerve emerges from beneath the lower border of the pons just above the lateral side of the pyramid of the medulla.

Course.—From its superficial origin the nerve is directed forwards, and pierces the dura mater near the lateral border of the dorsum sellæ. It next passes in the medial wall of the cavernous sinus, lying laterally to the internal carotid artery. It afterwards enters the orbit through the sphenoidal (superior orbital) fissure between the two heads of the lateral rectus, and supplies that muscle on its deep surface.

Communications.—The sixth nerve communicates with (*a*) the ophthalmic division of the trigeminal, and (*b*) the carotid sympathetic plexus.

SEVENTH OR FACIAL NERVE (Plate IV.).

Deep Origin.—There are two separate elements in the seventh nerve, a motor portion, the facial nerve proper, and a sensory part, the *pars intermedia* (*nervus intermedius*). They unite at the bottom of the internal auditory meatus.

(a) *Facial nerve proper.*—The fibres arise from a nucleus in the lower part of the pons near the superior olive. From this nucleus, the fibres pass backwards and slightly medially, to hook round the nucleus of the abducens nerve from the lateral to the medial side. They next travel downwards, laterally, and forwards to their superficial origin.

(b) *Pars intermedia.*—The nerve fibres which issue from the cells of the geniculate ganglion of the facial divide into two groups. The peripheral set form the greater superficial petrosal and the chorda tympani, while the central group become the *pars intermedia*, and entering the brain terminate in the upper part of the grey matter associated with the tractus solitarius.

Superficial Origin.—The lower border of the pons, on the medial side of the auditory nerve, the *pars intermedia* resting between the latter and the facial nerve proper.

Course.—The facial passes into the internal auditory meatus, lying superficial to the *pars intermedia* and the auditory nerves; at the bottom of the meatus it enters the aqueductus Fallopii (facial canal). In the canal the facial is lodged during its passage through the petrous portion of the temporal bone. The course of the nerve is somewhat complex. It is first directed laterally between the cochlea and the vestibule, then backwards along the medial wall of the tympanum, and finally arches over the fenestra ovalis to proceed downwards on the posterior wall of the tympanum, immediately in front of the lateral semicircular canal. Emerging from the stylo-mastoid foramen the facial reaches the parotid gland, where it lies on a level with the lower margin of the tragus, and splits into two divisions, temporo-facial and cervico-facial, to supply the muscles of the face.

The *geniculate ganglion* is situated on the seventh nerve at the junction of the lateral and backward parts of its course.

Branches—

- (a) A communicating branch from the pars intermedia as it lies in the internal auditory meatus.
- (b) The geniculate ganglion receives a twig from the vestibular trunk of the auditory nerve, and gives off three branches:—
- (1) *Greater superficial petrosal* emerges from the hiatus Fallopii to join the deep petrosal from the carotid sympathetic plexus, thus forming the Vidian (*see* trigeminal nerve).
 - (2) A minute nerve to the tympanic branch of the glossopharyngeal. The union of the two forms the *lesser superficial petrosal* which goes to the otic ganglion.
 - (3) *External superficial petrosal* to middle meningeal sympathetic plexus.
- (c) Nerve to stapedius muscle.
- (d) Chorda tympani leaves the tympanum through the canal of Huguier (petro-tympanic fissure) to join the lingual beneath the external pterygoid (*see* trigeminal nerve).
- (e) Communicating twig to Arnold's nerve (auricular branch of the vagus).
- (f) In the neck three branches arise:—
- (1) Posterior auricular.
 - (2) Nerve to stylo-hyoid.
 - (3) Nerve to posterior belly of digastric.

The posterior auricular divides into auricular and occipital branches. It supplies the occipito-frontalis (epicranius), auricularis posterior, and the intrinsic muscles of the auricle.

- (g) In the parotid gland the branches of the facial form the parotid plexus. They are:—

- | | | |
|-----------------------------|---|--|
| (1) Temporo-facial division | { | Temporal
Zygomatic
Infra-orbital |
| (2) Cervico-facial division | { | Buccal
Supramandibular
Inframandibular |

The muscles innerved by these branches are shown in the table.

NERVE.	MUSCLES.
Temporal . . .	Orbicularis palpebrarum ; corrugator supercillii ; auricularis anterior and superior ; frontalis.
Malar (zygomatic) .	Orbicularis palpebrarum and zygomaticus major.
Supra-orbital . . .	Muscles of nose and lower lip.
Buccal	Buccinator and muscles passing to angle of mouth.
Supramandibular .	Depressor anguli oris ; depressor labii inferioris ; orbicularis oris ; levator menti.
Inframandibular .	Platysma.

EIGHTH OR AUDITORY NERVE (Plate IV.)

The auditory nerve consists of two elements, *cochlear* and *vestibular*, the fibres of which arise in the internal ear from the spiral and vestibular ganglia respectively.

Central Connections—

(a) *Cochlear division* can be traced to the dorsal and ventral cochlear nuclei on the corresponding sides of the restiform body.

(b) *Vestibular division* passes to

- (1) The dorsal vestibular nucleus in the floor of the fourth ventricle.
- (2) The lateral vestibular nucleus (Deiters’).
- (3) The superior vestibular nucleus (Bechterew’s), and
- (4) The cerebellar cortex.

Superficial Origin.—The vestibular division enters the pons on the medial aspect of the restiform body, while the cochlear division enters on the lateral part of that body.

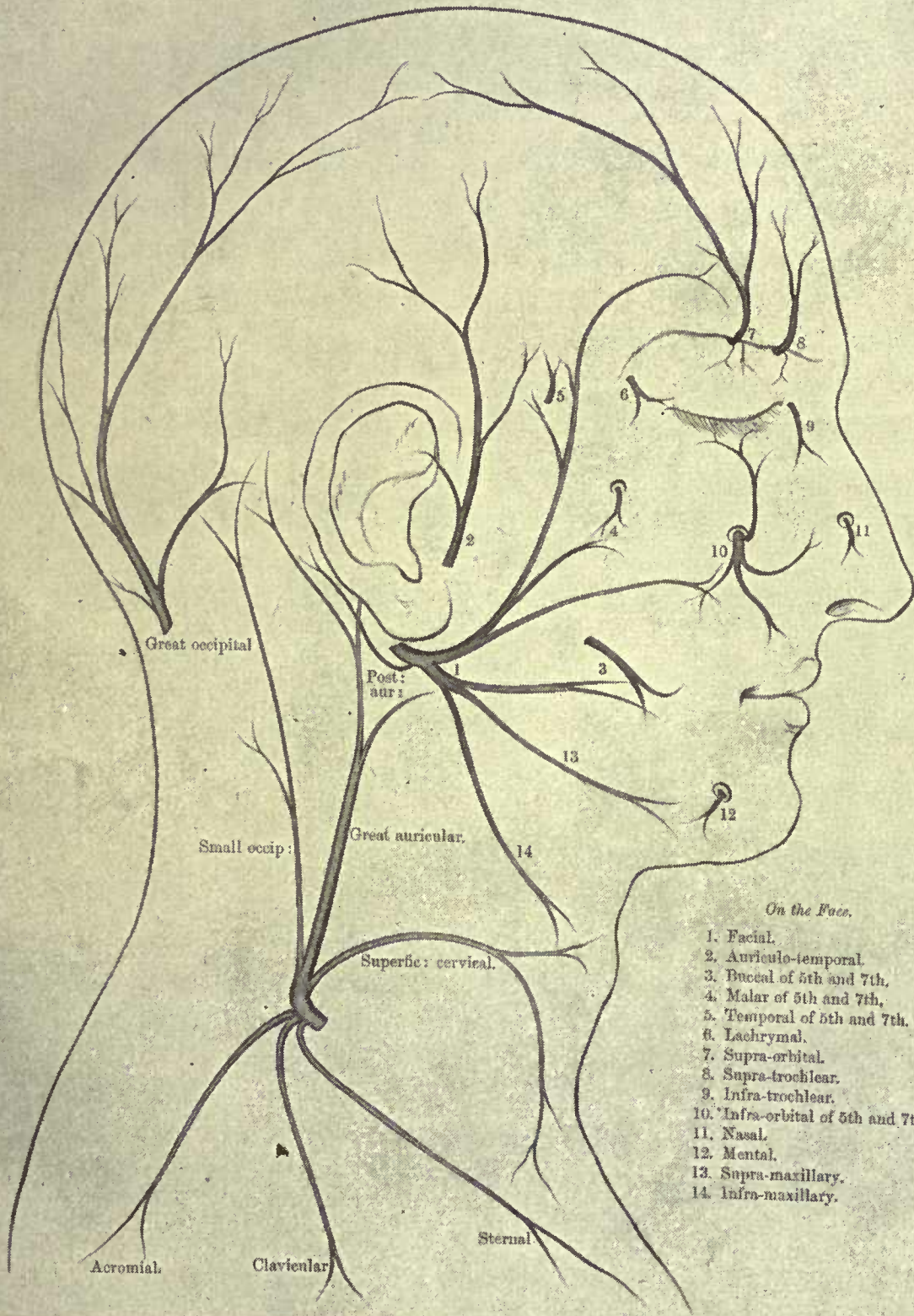
Course.—The nerve accompanies the facial and pars intermedia into the internal auditory meatus, lying below the two former nerves. In the meatus it divides into two, superior or vestibular, and inferior or cochlear.

After further subdivision the branches pierce the lamina cribrosa at the bottom of the meatus. The vestibular division receives twigs from the pars intermedia, and gives off a communicating branch to the geniculate ganglion of the facial.

PLATE III.

Plate III.

Superficial Nerves of Face and Front of the Neck, with their Communications.



Branches—

Auditory.	{	Cochlear .	{	to sacculæ.
			{	to posterior semicircular canal.
	{	Vestibular .	{	to organ of Corti.
			{	to utricle.
			{	to superior semicircular canal.
			{	to lateral semicircular canal.

NINTH OR GLOSSO-PHARYNGEAL NERVE

(Plate V.)

Deep Origin.—From the dorsal nucleus, nucleus ambiguus and tractus solitarius in the floor of the fourth ventricle, at the back of the medulla. The greater number of the fibres, however, arise from ganglia on the nerve trunk.

Superficial Origin.—The nerve emerges from the medulla as a series of five or six filaments between the olivary and restiform bodies. The fibres are below the facial, and above the vagus.

Course.—The rootlets unite as a single trunk which leaves the skull through the middle compartment of the jugular foramen, along with the vagus and spinal accessory. The glosso-pharyngeal is enclosed in a separate sheath of dura mater. In the foramen it presents two ganglia, the jugular and the petrous. The former is of small size, and only involves a few of the fibres of the nerve; it occupies the upper part of the foramen; no branches arise from it. The petrous ganglion lies in the lower part of the foramen and gives off three or four branches.

In the neck the nerve appears between the internal carotid artery and the internal jugular vein. It then passes between the internal and external carotid arteries, winds round the stylo-pharyngeus muscle, and finally reaches the under surface of the base of the tongue by going beneath the hyoglossus.

Branches—

Ganglionic.	{	To superior cervical ganglion of sympathetic.
		To Arnold's nerve (auricular branch of vagus).
		To vagus (occasionally).
Cervical.	{	Tympanic nerve to stylo-pharyngeus.
		Pharyngeal.
Terminal.	{	Tonsillar.
		Lingual to mucous membrane of posterior third of dorsum of tongue.

The tympanic or Jacobson's nerve enters Jacobson's canal (on the bony ridge between the carotid canal and the jugular foramen) to form along with twigs from the carotid sympathetic plexus, the *tympanic plexus*. It then joins a small branch from the geniculate ganglion of the facial to produce the lesser superficial petrosal, the latter going to the otic ganglion.

TENTH OR VAGUS NERVE (Plate V.)

Deep Origin.—Similar to that of the glossopharyngeal nerve, but only a few afferent fibres pass to the tractus solitarius.

Superficial Origin.—Twelve to fifteen rootlets emerge from the medulla, lateral to the restiform body, and between the glossopharyngeal above, and the spinal accessory below.

Course.—The nerve leaves the cranium through the posterior compartment of the jugular foramen. It occupies the same sheath of dura mater as the spinal accessory. As the vagus lies in the foramen, two ganglia are formed in connection with it. The upper and smaller one is termed the *ganglion jugulare*, while the other is called the *ganglion nodosum*.

The nerve descends between the internal carotid artery and the internal jugular vein. Entering the carotid sheath the vagus travels downwards, lying behind and between the common carotid artery and internal jugular vein.

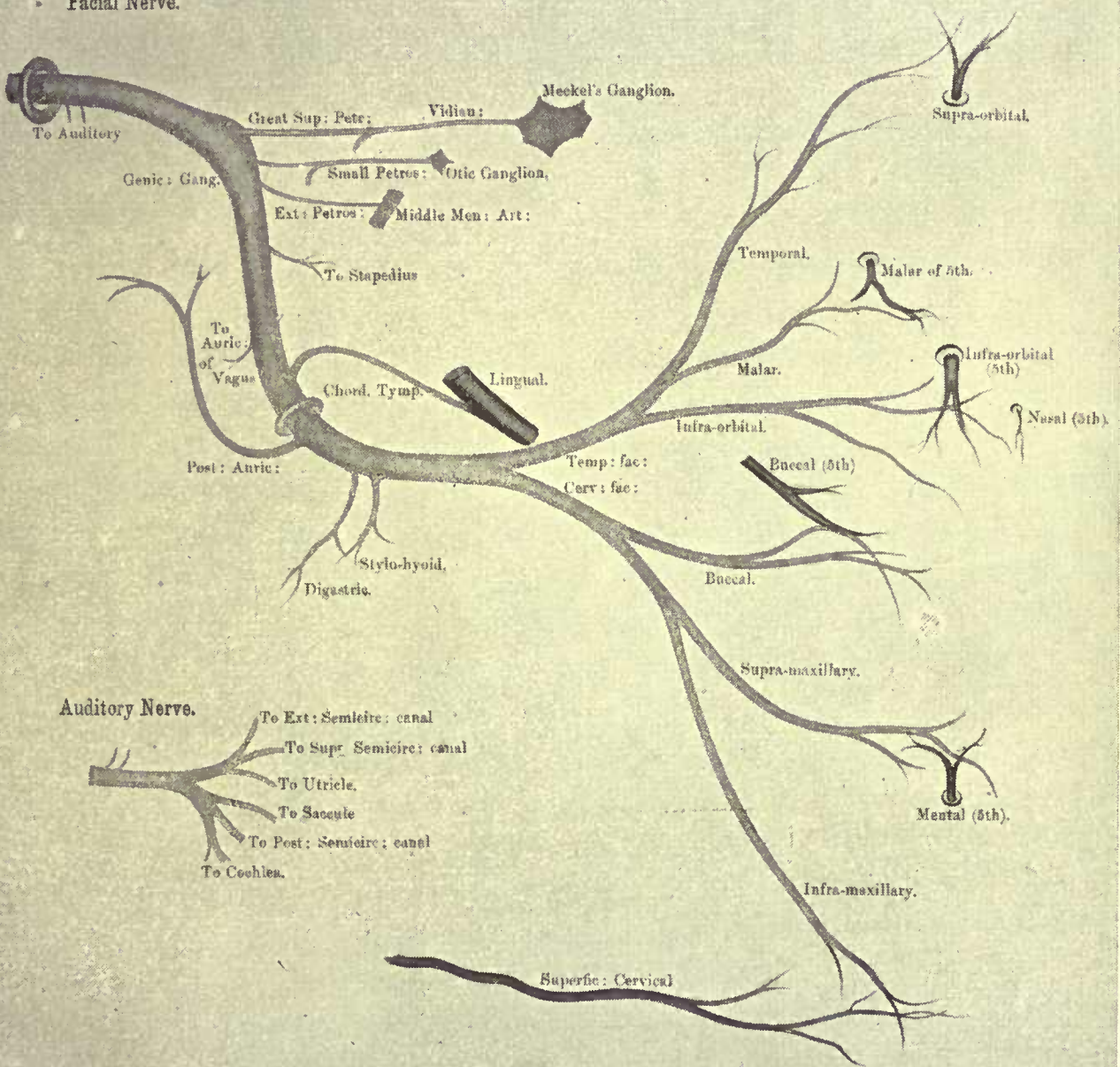
The RIGHT VAGUS passes over the first part of the subclavian artery, and reaches the thorax behind the right innominate vein. In the superior mediastinum it is found on the right side of the innominate artery and trachea, and is posterior to the superior vena cava. After running along the lateral margin of the trachea to the posterior mediastinum, the nerve splits up into several branches at the back of the root of the lung; these form the *posterior pulmonary plexus*. From the plexus the vagus issues as two cords, which after crossing the vena azygos major, pass on to the œsophagus and unite with the vagus of the opposite side as the *œsophageal plexus*. The nerve leaves the plexus as a single trunk which descends in front of the gullet, traverses the corresponding opening in the diaphragm, and is distributed to the posterior surface of the stomach. Communicating fibres are furnished to the cœliac, splenic, and left renal plexuses.

The LEFT VAGUS enters the thoracic cavity between the left common carotid and subclavian arteries, lying posterior to the left

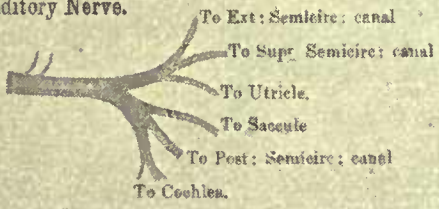
PLATE IV.

Plate IV.

Facial Nerve.



Auditory Nerve.



innominate vein and left phrenic nerve. After crossing in front of the aortic arch, it breaks up at the back of the root of the lung into the *posterior pulmonary plexus*. From this plexus the two efferent nerves travel over the descending thoracic aorta, and reaching the œsophagus, form the *œsophageal plexus*. The issuing nerve passes through the œsophageal orifice of the diaphragm in front of the gullet. It ramifies over the anterior surface of the stomach; certain of the branches pass in the gastro-hepatic ligament to the hepatic plexus.

Branches—

- (a) *Meningeal* from the jugular ganglion innervates the dura mater of the posterior fossa.
- (b) *Auricular* (Arnold's nerve) arises from the jugular ganglion, and receives a small twig from the glossopharyngeal. It enters the skull through a minute orifice in the jugular fossa, traverses the petrous part of the temporal, where it communicates with the facial, and emerges from the bone at the auricular fissure. Arnold's nerve supplies the skin of the posterior aspect of the auricle, communicating there with the posterior auricular.
- (c) *Pharyngeal* springs from the upper part of the ganglion nodosum. Its fibres are derived from the spinal accessory. This branch reaches the pharyngeal wall by passing between the external and internal carotid arteries. It divides into several branches which join branches of the glossopharyngeal and cervical sympathetic to form the pharyngeal plexus. The plexus distributes twigs to the pharyngeal mucous membrane, constrictors of the pharynx, and all the muscles of the soft palate, with the exception of the tensor palati (supplied by the otic ganglion). One branch (the lingual) from the plexus communicates with the hypoglossal.
- (d) *Superior laryngeal* takes origin from the ganglion nodosum about its middle. It passes downwards and medially behind the external and internal carotid arteries. The nerve bifurcates into a small lateral branch, the *external laryngeal*, which supplies the inferior constrictor and crico-thyroid muscles, and a larger *internal laryngeal*. The latter insinuates itself between the middle and inferior constrictors to perforate the thyreo-hyoid membrane. It innervates the laryngeal mucous membrane, and communicates with the recurrent (inferior)

laryngeal nerve. The motor fibres of the superior laryngeal come from the spinal accessory.

(e) *Recurrent (inferior) laryngeal*.—On the right side this nerve arises in the lower part of the neck, and hooks backwards beneath the first part of the subclavian artery. The left recurrent laryngeal takes origin in the thorax, and winds backwards around the aortic arch on the lateral side of the ligamentum arteriosum. Each nerve passes obliquely upwards and medially behind the subclavian, common carotid, and inferior thyreoid arteries. In addition, on the left side the nerve occupies the groove between the œsophagus and trachea. It is sheltered by the inferior pole of the thyreoid body, and reaches the larynx by passing beneath the inferior constrictor muscle. The recurrent laryngeal supplies the intrinsic muscles of the larynx, the fibres being derived from the spinal accessory. In addition to communicating with the inferior cervical ganglion of the sympathetic and with the internal laryngeal, the recurrent laryngeal furnishes branches to the heart, trachea, œsophagus, and inferior constrictor.

(f) *Cardiac*.—There are two groups, cervical and thoracic.

(1) Cervical; the upper ones are of small size and join the deep cardiac plexus. The lower branch which arises at the root of the neck, differs on the two sides. That on the right side passes to the deep cardiac plexus, while the left one crosses in front of the aortic arch to enter the superficial cardiac plexus.

(2) Thoracic; these branches arise in the superior mediastinum. On the right side they are partly derived, while on the left side they are entirely derived, from the recurrent laryngeal. In both cases they pass to the deep cardiac plexus.

(g) *Pulmonary*.—A few twigs reach the front of the root of the lung, which join with branches of the cardiac plexuses (see sympathetic nerves) to join the anterior pulmonary plexus. The posterior pulmonary plexus is composed of the greater part of the vagus, together with branches from the second, third, and fourth thoracic sympathetic ganglia. From the plexuses twigs accompany the bronchi and pulmonary vessels to the lungs.

(h) *Œsophageal*.—These branches are given off above and below the root of the lung.

Communications.—In addition to the communications already mentioned, the jugular ganglion receives twigs from the superior cervical ganglion of the sympathetic, and the spinal accessory. The nodal ganglion communicates with (a) the superior cervical ganglion of the sympathetic; (b) the hypoglossal; (c) the loop between the first and second cervical nerves; (d) the spinal accessory. It is by means of the last-named communication that the vagus nerve receives inhibitory fibres for the heart, together with the motor fibres for the soft palate, œsophagus, larynx, stomach, intestines, and lungs.

ELEVENTH OR SPINAL ACCESSORY NERVE

(Plate V.).

The spinal accessory is derived partly from the brain, and partly from the spinal cord.

(a) Cerebral portion—

- (1) *Deep origin*.—The nucleus ambiguus in the medulla oblongata immediately below the glossopharyngeal and vagus.
- (2) *Superficial origin*.—The lateral aspect of the medulla in series with, and below, the vagus.

(b) Spinal Portion—

- (1) *Deep origin*.—Anterior column of grey matter of the spinal medulla, near its lateral margin.
- (2) *Superficial origin*.—The filaments emerge from the lateral surface of the spinal cord as low as the sixth cervical nerve.

Course.—The spinal part ascends in the spinal canal between the ligamentum denticulatum and the posterior nerve roots, to enter the posterior cranial fossa through the foramen magnum. Having joined with its accessory portion, it leaves the skull through the middle compartment of the jugular foramen, lying posterior to the vagus and glossopharyngeal nerves. It passes over the internal jugular vein, then beneath the posterior belly of the digastric and stylo-hyoid muscles, to run below the transverse process of the atlas. At this level it is crossed superficially by the occipital artery. The nerve next pierces the sterno-mastoid obliquely, and emerging from the muscle, traverses the posterior triangle to ramify on the under surface of the trapezius.

The spinal accessory supplies the sterno-mastoid and the trapezius, communicating in the former muscle with the second cervical nerve, and in the latter with the third and fourth cervicals.

TWELFTH OR HYPOGLOSSAL NERVE (Plate VI.)

Deep origin.—From the grey matter of the floor of the fourth ventricle, and the antero-lateral part of the grey matter around the central canal. The hypoglossal nucleus extends from immediately above the decussation of the pyramids to the level of the striæ medullares.

Superficial origin.—The nerve issues from the front of the medulla between the pyramid and olivary body. There are numerous filaments which form two groups. Each group occupies a separate compartment of dura mater.

Course.—The nerve bundles unite in the anterior condyloid foramen (hypoglossal canal), as a complete trunk, which reaches the neck behind the internal jugular vein and the internal carotid artery. Proceeding downwards between these two vessels, the nerve passes beneath the posterior belly of the digastric and the stylo-hyoid. It then hooks round the occipital artery, crosses the external carotid and the first part of the lingual superficially, to enter the sub-maxillary triangle. In this triangle the nerve disappears beneath the mylo-hyoid, resting upon the hyoglossus just below Wharton's duct, and reaches the tongue medial to the lingual artery.

Branches—

- (a) Recurrent, to the dura mater of the posterior fossa.
- (b) Descending, arises as the hypoglossal crosses the internal carotid. It lies on the anterior part of the carotid sheath, and is joined by the descending cervical (from the second and third cervicals). The nerve thus formed is termed the ansa hypoglossi; it supplies the omo-hyoid, sterno-hyoid, and sterno-thyreoid.
- (c) Thyreo-hyoid, innervates the thyreo-hyoid muscle.
- (d) Lingual, supplies the hyoglossus, genio-hyoid, genio-hyoglossus, and the intrinsic muscles of the tongue. The infra-hyoid muscles and the genio-hyoid are supplied by fibres derived from the first three cervical nerves.

Communications.—With (a) the lingual; (b) nodal ganglion of the vagus; (c) superior cervical ganglion of the sympathetic; (d) loop between first and second cervicals, and (e) the descending cervical.

Fourth Ventricle.

Olfactory body.

Level of foramen magnum

I.—Glossopharyngeal Nerve.

1. Jugular Ganglion.
2. Petrous Ganglion.
3. Tympanic branch.
4. Communication with Arnold's Nerve.
5. " " Pneumogastric.
6. " " Sympathetic.
7. To Carotid Plexus.
8. Tonsillitic.
9. Pharyngeal.
10. Lingual.

Tympanic Branch (3).

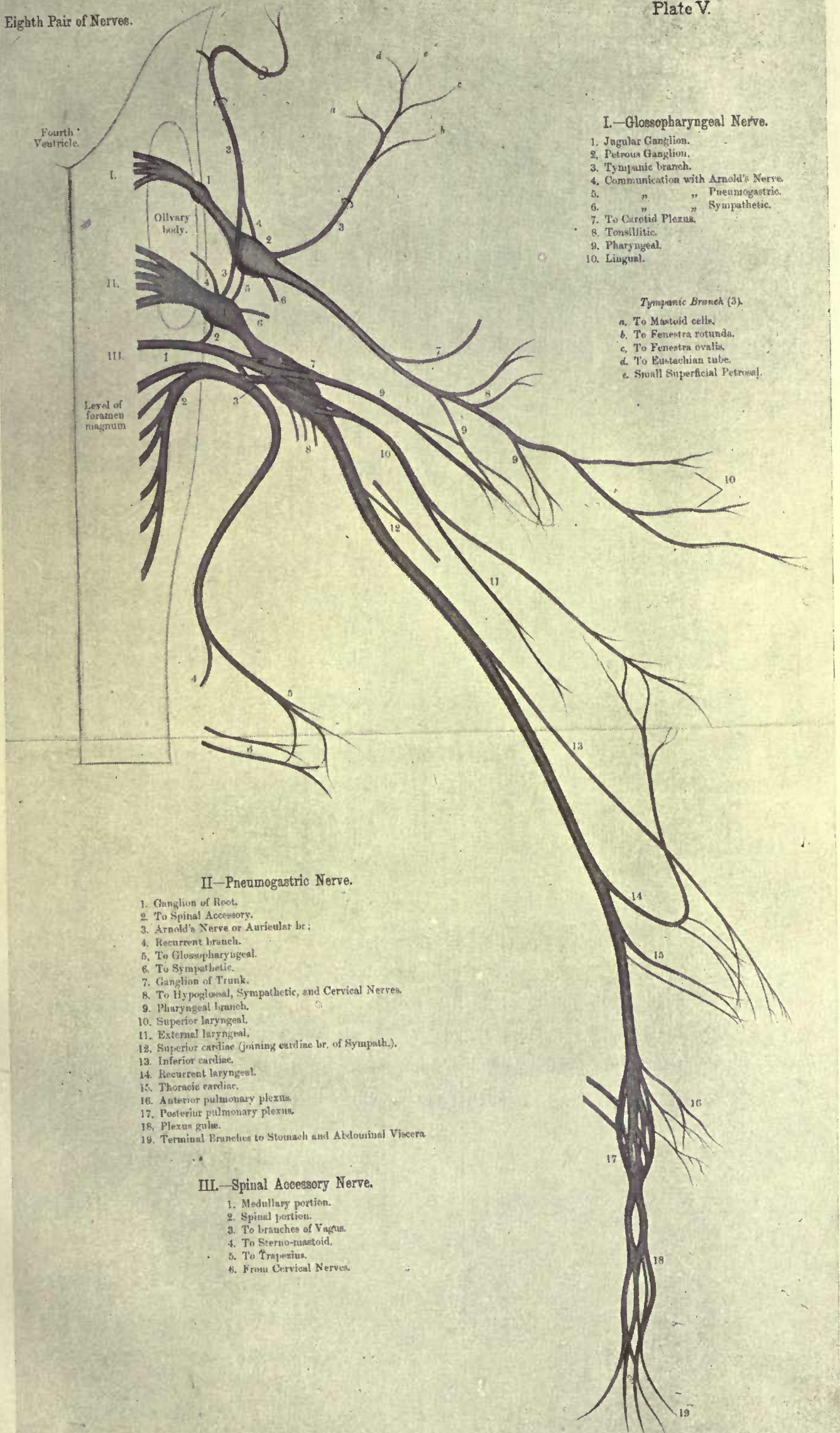
- a. To Mastoid cells.
- b. To Fenestra rotunda.
- c. To Fenestra ovalis.
- d. To Eustachian tube.
- e. Small Superficial Petrosal.

II.—Pneumogastric Nerve.

1. Ganglion of Root.
2. To Spinal Accessory.
3. Arnold's Nerve or Auricular br.
4. Recurrent branch.
5. To Glossopharyngeal.
6. To Sympathetic.
7. Ganglion of Trunk.
8. To Hypoglossal, Sympathetic, and Cervical Nerves.
9. Pharyngeal branch.
10. Superior laryngeal.
11. External laryngeal.
12. Superior cardiac (joining cardiac br. of Sympath.).
13. Inferior cardiac.
14. Recurrent laryngeal.
15. Thoracic cardiac.
16. Anterior pulmonary plexus.
17. Posterior pulmonary plexus.
18. Plexus gule.
19. Terminal Branches to Stomach and Abdominal Viscera.

III.—Spinal Accessory Nerve.

1. Medullary portion.
2. Spinal portion.
3. To branches of Vagus.
4. To Sternocleidomastoid.
5. To Trapezius.
6. From Cervical Nerves.



SPINAL NERVES.

There are thirty-one pairs of spinal nerves. They are named according to the vertebræ in relation to which they emerge. The thirty-one pairs comprise eight cervical, twelve thoracic, five lumbar, five sacral, and one coccygeal. Each nerve arises by two roots, an anterior or motor, and a posterior or sensory, the latter having a ganglion, which is usually lodged within the intervertebral foramen through which the nerve passes. The anterior fibres issue from the antero-lateral column of the cord, and the posterior fibres from the postero-lateral sulcus. The posterior root is larger than the anterior. Both nerve roots pierce the dura mater independently. In the case of the roots of the cervical and thoracic nerves the dural orifices lie opposite the intervertebral foramina, while in the lumbar and sacral regions the dural openings are at a higher level than the intervertebral foramina.

The nerve roots vary both in size and in direction. Those of the lower lumbar and upper sacral are the largest; the last sacral and the coccygeal are the smallest. As regards direction, the upper cervical nerves run horizontally, the lower cervical and thoracic obliquely, while the lumbar, sacral, and coccygeal nerve roots are vertical. The lumbar, sacral, and coccygeal nerve roots arise from the *cauda equina*. Immediately beyond the spinal ganglion the two roots join to form a short trunk or spinal nerve, which divides into anterior and posterior primary divisions. These divisions contain both motor and sensory fibres. Before the division occurs, each spinal nerve gives off a minute recurrent or meningeal branch. This is joined by a twig from the connecting branch between the anterior division and the neighbouring sympathetic ganglion. The meningeal nerve passes inwards through the intervertebral foramen to supply the vertebral column and dura mater.

The anterior divisions are destined for the innervation of the muscles and integument of the upper and lower extremities, together with those of the antero-lateral regions of the neck, thorax, and abdomen.

POSTERIOR PRIMARY DIVISIONS OF SPINAL NERVES.

With the exception of the first cervical, fourth sacral, fifth sacral and coccygeal nerves, the posterior primary divisions separate into lateral and medial branches.

Cervical Nerves.—

C. 1. The posterior primary division of the first cervical is termed the suboccipital. It enters the suboccipital triangle where it breaks up to supply the superior oblique, inferior oblique, rectus capitis, posticus major and minor, and the complexus. It communicates with the second cervical nerve.

C. 2-8. The lateral branches are muscular to the splenius, cervicalis ascendens, transversalis cervicis, and trachelo-mastoid. The medial branch of the second is called the great occipital. The medial branches of the third, fourth, and fifth supply the semispinalis and complexus, then pierce the splenius and trapezius to become cutaneous near the spinous processes of the vertebræ. Those of the remaining cervical nerves supply the semispinalis.

The great occipital passes over the inferior oblique, to penetrate the complexus and trapezius, furnishing twigs to the former, and accompanies the occipital artery to the back of the scalp. It communicates with the small occipital nerve of the cervical plexus.

Thoracic Nerves.—The lateral branches of the upper six innervate the ileocostalis; those of the lower six however, become cutaneous in a line with the angles of the ribs. The medial branches of the first six, after supplying the transverso-spinalis muscle, become cutaneous near the vertebral spines; that of the second is the longest, extending over the scapula. The corresponding branches of the lower six thoracics are muscular to the multifidus spinæ.

Lumbar Nerves.—The lateral branches supply the erector spinæ, those of the upper three terminating as cutaneous nerves. The medial twigs end in the multifidus spinæ.

Sacral Nerves.—The posterior divisions of the last two sacrals do not subdivide, but are connected to each other by a loop, the fifth sacral being also joined to the coccygeal. They terminate in the skin in the region of the coccyx. The lateral branches of the first three sacrals are cutaneous, while the medial branches supply the multifidus spinæ.

ANTERIOR PRIMARY DIVISIONS OF SPINAL NERVES.

The anterior primary divisions are generally much larger than the posterior divisions. Each is connected, near its origin, by one or two filaments, with a ganglion of the sympathetic. With the exception of the lower eleven thoracic nerves, the anterior primary divisions form plexuses.

CERVICAL PLEXUS (Plate VII.).

The cervical plexus is formed by the anterior primary divisions (rami) of the first four cervical nerves. It is situated opposite the upper four cervical vertebræ under cover of the sterno-mastoid. The first cervical appears between the rectus capitis lateralis, and the rectus capitis anticus minor (rectus capitis anterior). The second, third, and fourth pass behind the vertebral artery, then forwards between the adjacent intertransverse muscles, and make their appearance between the rectus capitis anticus major (longus capitis) in front, and the scalenus medius behind. The first cervical joins the second cervical nerve. The second, third, and fourth cervicals divide into ascending and descending branches. These unite to form a series of loops which constitute the plexus.

Branches.—The branches of the plexus may be classified into three sets, namely, cutaneous, muscular, and communicating. Their distribution is shown in the table.

TABLE OF BRANCHES.

SUPERFICIAL OR CUTANEOUS	$\left\{ \begin{array}{l} \textit{Ascending} \\ \textit{Transverse} \end{array} \right.$	$\cdot \left\{ \begin{array}{l} \text{Great auricular.} \\ \text{Small occipital.} \\ \text{Superficial cervical.} \end{array} \right\}$	(C. 2, 3).	
				$\left\{ \begin{array}{l} \textit{Descending} \\ \textit{Muscular} \end{array} \right.$
DEEP .	$\left\{ \begin{array}{l} \textit{Communicating} \end{array} \right.$	$\cdot \left\{ \begin{array}{l} \text{Prevertebral muscles (C. 1, 2, 3, 4).} \\ \text{Sterno-mastoid (C. 2).} \\ \text{Trapezius, levator scapulæ,} \\ \text{scalenus medius, scalenus posterior,} \\ \text{and diaphragm (C. 3, 4).} \end{array} \right.$	$\left\{ \begin{array}{l} \text{To vagus.} \\ \text{To hypoglossal.} \end{array} \right\}$	
				$\left\{ \begin{array}{l} \text{To spinal accessory (C. 2, 3, 4).} \\ \text{Communicans hypoglossi (C. 2, 3).} \\ \text{Superior cervical ganglion of sym-} \\ \text{pathetic (C. 1, 2, 3, 4).} \end{array} \right.$

The six cutaneous branches of the cervical plexus emerge from beneath the posterior border of the sterno-mastoid, about its middle.

(a) The *small occipital* passes upwards along the posterior border of the sterno-mastoid to pierce the deep fascia near the apex of the posterior triangle of the neck. Its branches are :—

- (1) Cervical.
- (2) Auricular.
- (3) Mastoid.
- (4) Occipital.

It communicates with the great occipital, great auricular, and posterior auricular nerves.

(b) The *superficial cervical* (cutaneous colli) crosses the sterno-mastoid transversely beneath the platysma and the external jugular vein. On reaching the anterior triangle it splits into superior and inferior branches, the former of which communicate with the inframandibular branch of the facial.

(c) The *great auricular*, is the largest cutaneous branch of the cervical plexus. It winds round the posterior border of the sterno-mastoid to pass over it obliquely towards the pinna of the ear. The branches are :—

- (1) Mastoid.
- (2) Auricular.
- (3) Facial.

It communicates with the posterior auricular and the small occipital.

(d) The names of the descending branches indicate their distribution. The sternal branch sends filaments to the sterno-clavicular joint.

Of the deep branches, special attention must be directed to the communicans hypoglossi and to the phrenic.

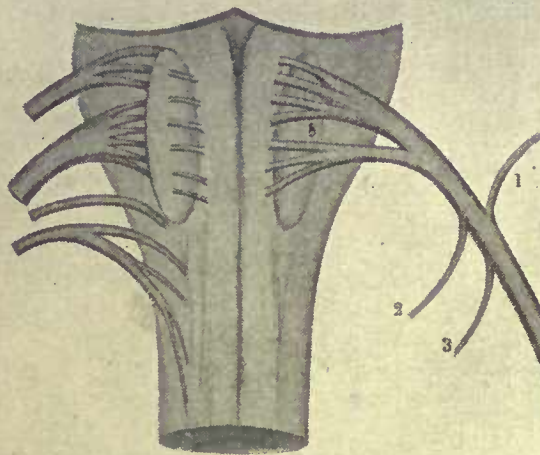
Communicans hypoglossi.—Formed by two twigs from the second and third cervicals, it passes in front of the carotid sheath to join the descendens hypoglossi from the hypoglossal. The resulting nerve, the ansa hypoglossi, supplies the omo-hyoid, sterno-hyoid, and sterno-thyreoid.

Phrenic.—This is derived from the third, fourth, and fifth cervicals, but arises mainly from the fourth cervical nerve. The

PLATE VI.

Plate VI.

Hypoglossal Nerve.



Hypoglossal Nerve.

1. To Vagus.
2. To Sympathetic.
3. To Cervical Nerves.
4. Descendens noni.
5. Communicans noni.
6. To Thyro-hyoid.
7. To Muscles of Tongue.
8. Olivary body.



phrenic frequently receives a twig from the nerve to the subclavius (*see* brachial plexus).

From its origin it descends upon the scalenus anterior, crosses the second part of the subclavian artery (the first part on the left side), and the internal mammary artery, to enter the thorax. In the neck the phrenic lies behind the omo-hyoid, transverse cervical and suprascapular (transverse scapular) vessels, the subclavian vein, and on the left side, the thoracic duct.

In its thoracic course the nerve runs almost vertically over the root of the lung, and between the pericardium and the mediastinal pleura. Just before reaching the diaphragm, the phrenic divides into several branches, which pierce the muscle separately to ramify on its lower surface. The right phrenic is shorter and more vertical than the left one; it forms a lateral relation of the right innominate vein and superior vena cava. The left phrenic crosses in front of the left vagus and the aortic arch.

The phrenic supplies the diaphragm, pericardium, and pleura. The right nerve communicates with a small sympathetic ganglion on the abdominal aspect of the diaphragm.

BRACHIAL PLEXUS (Plate VIII.).

The brachial plexus occupies the lower part of the posterior triangle of the neck and the upper part of the axilla. It is formed by the anterior primary divisions of the lower four cervical nerves together with a considerable portion of the first thoracic, and is usually augmented by a communicating twig from the fourth cervical. The nerves appear between the scalenus anticus and scalenus medius muscles.

In the neck the plexus is in intimate relation to the third part of the subclavian artery, being superior and posterior to that vessel. It is crossed superficially by the posterior belly of the omo-hyoid, likewise by the transverse cervical and suprascapular arteries. The plexus passes behind the clavicle to reach the axilla, the lower trunk grooving the upper surface of the first rib. Here it becomes enclosed within the axillary sheath, lying laterally to the axillary artery. The junction of the fifth and sixth cervical nerves produces an *upper trunk*, the seventh, remaining separate, becomes the *middle trunk*, while a *lower trunk* is formed by the union of the eighth cervical and first thoracic nerves. Each of the three trunks divides into an anterior and posterior branch. The anterior branches of the upper and middle trunks unite as the *lateral cord*, the anterior branch of

the lower trunk is continued as the *medial cord*, and the posterior divisions of the trunks join together as the *posterior cord*.

Branches—

The branches consist of two sets (*a*) those given off in the posterior triangle, *supra-clavicular*, and (*b*) those arising in the axilla, *infra-clavicular*.

Supra-clavicular Branches.

(*a*) *Arising from front of plexus—*

- (1) Nerves to longus colli and scalenus anticus (C. 5, 6, 7, 8).
- (2) Communicating twigs to phrenic (C. 5).
- (3) Nerve to subclavius (C. 5, 6). This nerve forms an anterior relation of the third part of the subclavian artery.

(*b*) *Arising from back of plexus—*

- (1) Nerves to scalenus medius and posticus (C. 5, 6, 7, 8).
- (2) Nerve to rhomboids or dorsal scapular (C. 5), pierces the scalenus medius, and runs downwards under cover of the levator anguli scapulæ to supply that muscle, together with the rhomboideus major and minor.
- (3) Long thoracic or nerve of Bell (C. 5, 6, 7), perforates the scalenus medius as two trunks. The nerve supplies the serratus magnus (anterior).
- (4) Supra-scapular (C. 5, 6) passes beneath the trapezius, and reaches the dorsum of the scapula through the suprascapular notch. It innervates the supraspinatus and infraspinatus, and furnishes an articular twig to the shoulder joint.

Infra-clavicular Branches.

- (*a*) *From the lateral cord.* Lateral anterior thoracic, musculo-cutaneous, and lateral head of median nerve.
- (*b*) *From the medial cord.* Medial anterior thoracic, lesser internal cutaneous (medial cutaneous of arm), internal cutaneous (medial cutaneous of forearm), ulnar, and medial head of median.
- (*c*) *From the posterior cord.* Three subscapulars, circumflex. (axillary), and musculo-spiral (radial).

Branches of Lateral Cord.

- (1) *Lateral anterior thoracic* (C 5, 6, 7). This nerve pierces the costo-coracoid membrane to supply the pectoralis

major. It communicates with the medial anterior thoracic.

- (2) *Musculo-cutaneous* (C 5, 6). The musculo-cutaneous lies on the lateral side of the third part of the axillary artery. After passing through the coraco-brachialis, the nerve descends obliquely between the biceps and brachialis anticus, to appear at the elbow on the lateral edge of the biceps tendon. Here it perforates the deep fascia, and after forming a posterior relation of the median-basilic vein, divides into anterior and posterior branches. In its course through the arm it supplies the coraco-brachialis, biceps, and brachialis anticus; a small twig is also furnished to the humerus. The terminal branches innervate the skin on the front and back of the forearm near the radial border, extending as far as the wrist and root of the thumb. The musculo-cutaneous gives off articular branches to the elbow and wrist joints; it also communicates with the radial in the lower part of the forearm, and with the inferior lateral cutaneous branch of the musculo-spiral.

Branches of Medial Cord.

- (1) *Medial anterior thoracic* (C. 8, T. 1), supplies both the pectoralis major and minor; it communicates with the lateral anterior thoracic.
- (2) *Lesser internal cutaneous* (T. 1), lies between the third part of the axillary artery and vein, then crosses either in front of or behind the vein, to be distributed to the skin of the lower half of the arm on its medial and posterior aspects. It is joined by the intercosto-humeral nerve (the lateral cutaneous branch of the second thoracic).
- (3) *Internal cutaneous* (C. 8, T. 1), after forming an anterior relation of the third part of the axillary artery, passes downwards on the medial side of the brachial to become cutaneous in the lower third of the arm. In the vicinity of the elbow it divides into anterior and posterior branches. The nerve supplies the skin on the anterior and posterior surfaces of the forearm near the ulnar border; it communicates with the ulnar nerve in the lower part of the forearm.

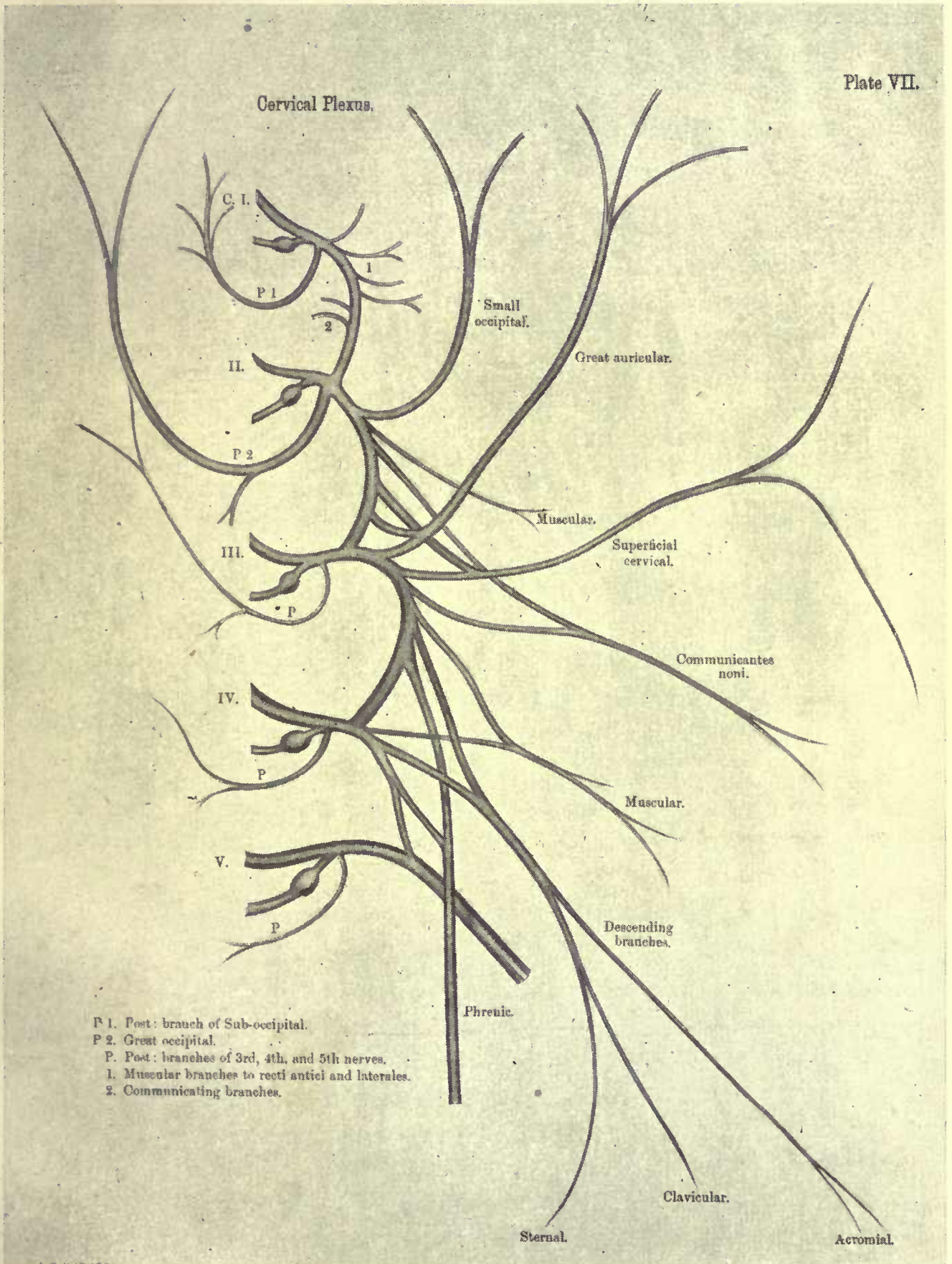
- (4) *Ulnar* (C. 8, T. 1). In the axilla the ulnar nerve intervenes between the third part of the axillary artery and the axillary vein. From this position it passes downwards on the medial side of the brachial, to pierce the medial intermuscular septum opposite the insertion of the coraco-brachialis, along with the inferior profunda (superior ulnar collateral) artery. It reaches the interval between the medial epicondyle and the olecranon process, and enters the forearm between the two heads of the flexor carpi ulnaris. Here it follows a straight course as far as the wrist, lying beneath the flexor carpi ulnaris, supported by the flexor profundus digitorum, and forming an intimate medial relation of the ulnar artery in its lower two-thirds. Together with the ulnar artery it enters the hand by passing over the anterior annular (transverse carpal) ligament, lying between the artery and the pisiform bone. In the palm the nerve divides into two terminal branches, superficial and deep.

Branches—

- (a) *Articular* to the elbow joint.
- (b) *Muscular*, to the flexor carpi ulnaris and medial half of flexor profundus digitorum.
- (c) *Palmar cutaneous*, given off about two inches above the wrist, accompanies the ulnar artery, and supplies the skin of the palm and hypothenar eminence.
- (d) *Dorsal cutaneous*, arises in the middle third of the forearm, and reaches the back of the hand by passing beneath the tendon of the flexor carpi ulnaris about two or three inches above the wrist. It innervates the skin of the medial side of the little finger, and the adjacent sides of the little and ring fingers on their dorsal surfaces. Over the back of the hand the nerve communicates with the superficial branch of the radial.
- (e) *Terminal branches*. The superficial branch supplies the palmaris brevis, and furnishes two digital nerves, one to the medial aspect of the little finger, and the other to the contiguous sides of the little and ring fingers on their palmar surfaces. This latter communicates with a digital branch of the median. The deep part accompanies the profunda branch of the ulnar artery between the abductor and flexor brevis minimi digiti, and to

PLATE VII.

Plate VII.



the medial side of and below the hook of the unciform. It crosses the palm from the medial to the lateral side, lying in the concavity of the deep palmar arch, and supplies the abductor, opponens, and flexor brevis minimi digiti; the two medial lumbricales; the interossei; the oblique and transverse adductors of the thumb; and the deep head of the flexor brevis pollicis.

Branches of Posterior Cord.

- (1) *Three subscapular nerves.* The short or upper (C. 5, 6) supplies the subscapularis; the long or middle (C. 6, 7, 8) innervates the latissimus dorsi, while the lower subscapular (C. 5, 6) is distributed to the subscapularis and teres major.
- (2) *Circumflex (axillary) (C. 5, 6).* For a short distance the nerve forms a posterior relation of the third part of the axillary artery, but on reaching the lower border of the subscapularis, it passes backwards through the quadrilateral space in company with the posterior circumflex artery. After giving off an articular twig to the shoulder-joint, the circumflex divides into an anterior and a posterior division. The former supplies the anterior part of the deltoid, and also the skin over its middle third; the latter innervates the posterior part of the deltoid, the teres minor, and sends a cutaneous filament to the skin over the lower third of the deltoid. The branch to the teres minor presents a pseudoganglion.
- (3) *Musculo-spiral (C. 5, 6, 7, 8, T. 1).* This is the largest branch of the brachial plexus. At first it lies behind the first part of the axillary artery, resting upon the subscapularis, latissimus dorsi, and teres major. It then passes behind the brachial, and accompanies the superior profunda artery downwards and backwards between the long and medial heads of the triceps, to enter the musculo-spiral groove. In this groove it winds round the back of the humerus between the lateral and medial heads of the triceps. Having pierced the lateral intermuscular septum, it descends in the sulcus between the supinator longus (brachio-radialis) and brachialis anticus, to a point just above the lateral epicondyle, where it divides into the radial and the posterior interosseous.

Branches—

Besides the terminal ones, three sets are given off from the musculo-spiral—axillary, in the musculo-spiral groove, and after leaving the groove. The axillary branches are :—

- (a) *Muscular*, to long and medial heads of triceps; one of the latter accompanies the ulnar nerve and is therefore called the *ulnar collateral nerve*.
- (b) *Internal cutaneous*, distributed to the skin of the back of the arm as far as the elbow. (Plate XI.).

In the musculo-spiral groove the branches are :—

- (c) *Muscular*, to lateral and medial heads of triceps, and to the anconæus.
- (d) *Lateral cutaneous*, two in number, an upper and a lower. The upper supplies the integument of the lateral and front aspects of the arm in its lower half, while the lower is distributed to the skin on the posterior aspect of the lateral side of the forearm (Plate XI.).

After leaving the musculo-spiral groove, cutaneous, articular, and muscular branches are given off.

- (e) *Articular*, to the elbow joint.
- (f) *Muscular*, to the supinator longus (brachio-radialis), extensor carpi radialis longior, and brachialis anticus.
- (g) *Radial*. The radial, which is entirely a cutaneous nerve, is continued downwards beneath the supinator longus (brachio-radialis), and is in close contact about the middle of its course with the lateral side of the radial artery. In the lower part of the forearm it passes backwards beneath the supinator longus tendon, becomes cutaneous, and divides into a lateral and a medial portion. The lateral extends to the radial side of the thumb, communicates with a branch of the musculo-cutaneous, and furnishes filaments to the thenar eminence. The medial portion, after communicating with the posterior branch of the musculo-cutaneous, gives off a twig to join the dorsal branch of the ulnar. It subsequently divides into four branches; the first supplies the ulnar side of the thumb; the second, the radial aspect of the index finger; the third, the contiguous sides of the index and middle fingers, while the fourth is distributed to the adjacent sides of the middle and

ring fingers. The first extends as far as the nail of the thumb, but the remaining branches generally terminate over the first interphalangeal joints of the fingers.

(h) *Posterior interosseous*. This nerve winds round the upper end of the radius, and pierces the supinator brevis (supinator) to reach the back of the limb. For some distance it lies between the superficial and deep layer of muscles, but a little below the middle of the forearm it dips beneath the long extensor of the thumb to reach the interosseous membrane. On this it is continued as far as the dorsum of the wrist, where it terminates in a gangliform enlargement, from which filaments are distributed to the carpal articulations. Before the nerve passes to the back of the forearm, it supplies the extensor carpi radialis brevior and the supinator brevis. On the back of the forearm it innervates the extensor communis digitorum, extensor minimi digiti, extensor carpi ulnaris, extensor indicis, and the three extensors of the thumb.

From Lateral and Medial Cords.

Median nerve.—(C. 6, 7, 8, T. 1). The nerve arises from the lateral and medial cords by two heads, the medial of which passes superficially to the third part of the axillary artery to reach its lateral side. It descends in company with the brachial artery, crossing over (sometimes under) that vessel opposite the insertion of the coraco-brachialis, to lie medial to it at the elbow. The median enters the forearm between the two heads of the pronator radii teres, and then passes between the flexor sublimis digitorum and the flexor profundus digitorum, to appear at the wrist between the palmaris longus and the flexor carpi radialis, almost midway between the two styloid processes. It enters the palm beneath the anterior annular ligament, becomes expanded, and gives off its terminal branches. In the forearm the nerve is closely associated with the median branch of the anterior interosseous artery.

Branches—

- (1) *Articular*, to the elbow joint.
- (2) *Muscular*, to the flexor carpi radialis, pronator radii teres, palmaris longus, and flexor sublimis digitorum.
- (3) *Anterior interosseous*, accompanies the artery of the same name, and supplies the lateral half of the flexor profundus digitorum, the flexor longus pollicis, and pronator quad-

ratus. It ends beneath the last-named muscle, giving off a small filament to the wrist joint.

- (4) *Palmar cutaneous*, pierces the deep fascia in the lower part of the forearm, and passes over the anterior annular ligament to be distributed to the skin of the palm.
- (5) *Terminal*. There are two terminal branches, a lateral and a medial. The former innervates the abductor, opponens, and lateral head of the flexor brevis pollicis, subsequently giving off three digital branches. The first digital runs along the lateral border of the thumb; the second along its medial border, and the third along the lateral border of the index finger. A small twig passes from the third digital to the first lumbrical muscle. The medial branch furnishes the fourth and fifth digital nerves. The fourth supplies the second lumbrical, and then divides into branches for the contiguous sides of the index and middle fingers. The fifth digital is distributed to the adjacent sides of the middle and ring fingers. It communicates with the ulnar and frequently sends a small twig to the third lumbrical. The digital nerves give off branches to both the front and the back of the fingers, and in addition supply the interphalangeal joints.

In the palm the digital nerves lie under cover of the superficial palmar arch, but on the fingers they are anterior to the digital vessels.

THORACIC NERVES (Plate VIII.).

With the exception of the first, the anterior primary divisions of the thoracic nerves do not form plexuses, but extend forwards singly under the name of intercostal nerves. The upper six are termed thoracic intercostal, the seventh to the eleventh, are abdominal intercostals, while the twelfth is called the subcostal.

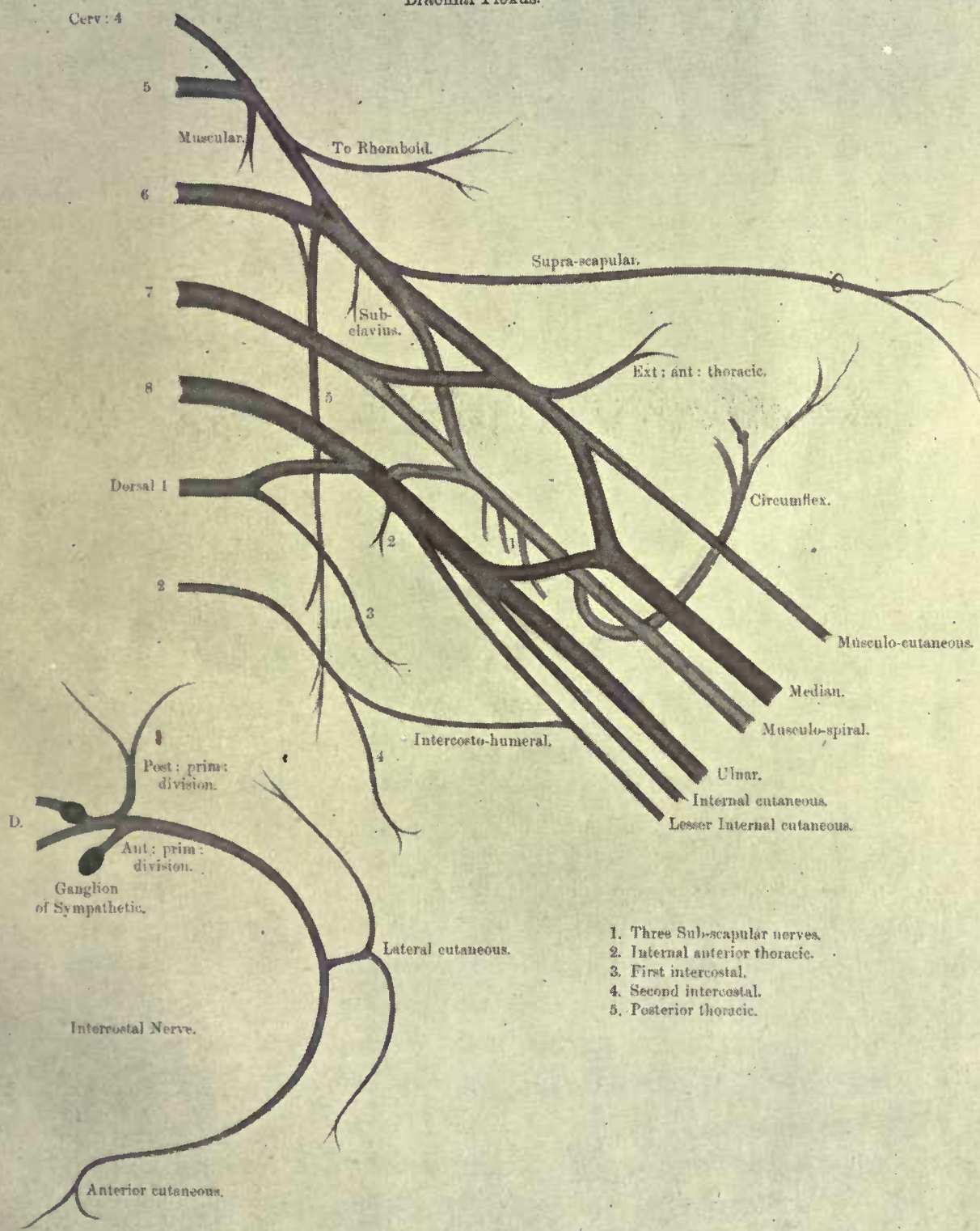
THORACIC INTERCOSTALS.

The thoracic intercostals communicate with the sympathetic near the intervertebral foramina, after which they pass in front of the superior costo-transverse ligament and the levatores costarum, being clothed by the pleura and the endo-thoracic fascia. Proceeding forwards between the internal and external intercostal muscles, the nerves about halfway between the sternum and the vertebral column, give off a *lateral cutaneous* branch. They subsequently

PLATE VIII.

Plate VIII.

Brachial Plexus.



1. Three Sub-scapular nerves.
2. Internal anterior thoracic.
3. First intercostal.
4. Second intercostal.
5. Posterior thoracic.

continue their course, and near the sternum pierce the internal mammary vessels and triangularis sterni muscle; perforate the internal intercostal again, then the anterior intercostal membrane and the pectoralis major, to become the *anterior cutaneous* nerves.

The lateral cutaneous branches emerge through the external intercostals and serratus magnus (anterior.) After a short course, each divides into an anterior and a posterior branch; the anterior ones pass over the lower margin of the pectoralis major, and the posterior wind round the latissimus dorsi. The first intercostal has no lateral cutaneous branch; that of the second does not divide into anterior and posterior, but reaching the axilla becomes the intercosto-humeral nerve, which joins the lesser internal cutaneous of the brachial plexus.

ABDOMINAL INTERCOSTALS.

The abdominal intercostals differ from the thoracic intercostals in the anterior part of their course. After perforating the internal intercostals, they pass between the costal origins of the diaphragm to travel forwards between the internal oblique and transversalis muscles. Each nerve penetrates the posterior layer of the sheath of the rectus, ramifies in the muscle, and emerges through the anterior layer of the sheath as an anterior cutaneous nerve.

The lateral cutaneous nerves of the abdomen arise in a similar manner to those of the thorax, and after piercing the external intercostal and external oblique muscles, divide into anterior and posterior branches. The former extend over the external oblique, and the latter over the latissimus dorsi.

SUBCOSTAL.

The subcostal is the anterior primary division of the twelfth thoracic. It runs beneath the external arcuate (lateral lumbo-costal) ligament of the diaphragm, and crosses the quadratus lumborum superficially to pierce the middle lamella of the lumbar fascia. From here it extends forwards between the transversalis and internal oblique muscles, and below the last rib, being accompanied by the subcostal vessels. The remainder of the course corresponds to that of an abdominal intercostal nerve. The lateral cutaneous branch is very large, and after becoming superficial about two inches above the iliac crest, is distributed to the integument of the glutæal region.

The muscles supplied by the anterior divisions of the thoracic nerves are external and internal intercostals; levatores costarum;

subcostals; serratus posticus superior (T. 1, 2, 3, 4); serratus posticus inferior (T. 9, 10, 11); triangularis sterni (T. 3, 4, 5, 6): external oblique, internal oblique, transversalis, and rectus abdominis (T. 6, 7, 8, 9, 10, 11, 12).

LUMBAR PLEXUS (Plate IX.).

This plexus is produced by the anterior primary divisions of the first four lumbar nerves, the first being reinforced by a communicating twig from the last thoracic. The fourth lumbar, in addition to entering into the composition of the plexus, sends a branch to the fifth lumbar to form the lumbo-sacral cord. The plexus lies in the substance of the psoas muscle, in front of the transverse processes of the lumbar vertebræ.

The ilio-hypogastric and ilio-inguinal are derived from the first lumbar; the genito-crural (femoral) from the first and second; the lateral cutaneous from the second and third; the anterior crural (femoral) from the second, third, and fourth; the obturator from the second, third, and fourth; while muscular twigs are given to the quadratus lumborum and psoas.

Branches—

(a) *Muscular—*

(1) From the first, second, and third to the quadratus lumborum.

(2) From the third to the psoas.

(b) *Ilio-hypogastric* (T. 12, L. 1). Appears at the upper part of the lateral border of the psoas, crosses the quadratus lumborum superficially, pierces the transversalis, proceeds forwards between it and the internal oblique, and divides into an iliac and a hypogastric branch. The former perforates the internal and external obliques to become superficial just above the iliac crest. It traverses the iliac crest a little posterior to the iliac branch of the subcostal nerve, and is distributed to the skin of the buttock. The hypogastric branch runs forwards between the transversalis and internal oblique muscles, furnishing twigs to both, and passes through the external oblique a little above the external (subcutaneous) abdominal ring, to innervate the skin of the abdominal wall just above the pubes.

(c) *Ilio-inguinal* (L. 1) is smaller than the ilio-hypogastric and has a course similar to that nerve, but lies on a slightly

lower level. It, however, passes down the inguinal canal, to become superficial by emerging from the external (subcutaneous) abdominal ring. It supplies the integument of the inguinal region and scrotum (labia majora in females), and does not give off an iliac branch.

(d) *Genito-crural (femoral)* (L. 1, 2) pierces the psoas obliquely, to descend upon the surface of that muscle and divide into a genital and a crural (femoral) branch. The former crosses over the external iliac artery to the inguinal canal. Here it becomes a constituent of the spermatic cord, and supplies the cremaster muscle together with the skin of the scrotum. In females it is associated with the round ligament of the uterus, and is distributed to the skin of the groin. The crural branch passes beneath Poupart's (inguinal) ligament on the lateral side of the femoral artery, to innervate the skin over the upper part of Scarpa's triangle. It communicates there with the medial cutaneous of the anterior crural.

(e) *Lateral cutaneous* (L. 2, 3). Appears at the lateral margin of the psoas muscle. It crosses the iliac fossa to go beneath Poupart's (inguinal) ligament close to the anterior superior iliac spine, and after a short course, divides into anterior and posterior branches. The anterior is distributed to the skin of the lateral part of the front of the thigh as far as the knee. The posterior branch supplies the integument of the lateral aspect of the buttock and upper part of the back of the thigh.

ANTERIOR CRURAL.

(f) *Anterior Crural (Femoral)* (L. 2, 3, 4). Emerges from the lateral border of the psoas in its lower part. It passes beneath Poupart's ligament in the sulcus between the iliacus and psoas muscles—about half an inch on the lateral side of the femoral artery. At the upper part of Scarpa's triangle the nerve divides into superficial and deep portions. The trunk of the nerve supplies branches to the iliacus muscle and femoral artery.

The anterior division gives off the middle and medial cutaneous nerves, and a branch to the pectineus, which runs behind the femoral artery. The middle cutaneous pierces and supplies the sartorius muscle; it then splits

into two portions, anterior and posterior, which innervate the skin of the front and medial part of the thigh as far as the knee. The middle cutaneous communicates with the crural branch of the genito-crural, and also with the medial cutaneous. The medial cutaneous after passing down over the femoral artery likewise divides into an anterior and posterior branch. These branches perforate the fascia lata separately, the former supplying the skin down to the knee, while the latter descends on the medial side of the knee to be distributed to the integument of the medial aspect of the upper part of the leg.

The posterior division follows the posterior border of the sartorius. It gives off muscular and articular twigs, and one cutaneous branch, namely, the medial or long saphenous. The muscular branches supply the rectus femoris, vastus lateralis, crureus (vastus intermedius), subcrureus, and vastus medialis. From the nerve to the rectus femoris twigs are furnished to the hip-joint, while from the nerves to the vasti and subcrureus branches are prolonged to the knee-joint.

The long saphenous (L. 3, 4) is the largest branch of the anterior crural, and descends through Hunter's canal, in close contact with the femoral artery—lying first on the lateral side and then crossing over to the medial side of the vessel. It becomes superficial on the medial aspect of the knee, after piercing the aponeurotic roof of Hunter's canal. From thence it is continued along the medial side of the leg with the long saphenous vein, to pass in front of the medial malleolus, and terminate about the middle of the medial border of the foot. In addition to branches which supply the skin of the medial surface of the leg and foot, it furnishes a communicating twig to join branches of the obturator and medial cutaneous beneath the sartorius, and a patellar branch which unites with twigs from the medial, middle, and lateral cutaneous nerves on the front of the knee, forming the *patellar plexus*.

OBTURATOR.

- (g) **Obturator** (L. 2, 3, 4). Emerges on the medial side of the psoas. It runs along the lateral wall of the pelvis,

under cover of the external iliac vein, then above the obturator vessels, to traverse the upper part of the obturator foramen. In the foramen it divides into anterior and posterior portions.

The anterior portion enters the thigh above the obturator externus, and passes down over the adductor brevis, but under cover of the pectineus and adductor longus. From it the following branches arise:—

- (1) *Muscular*, to gracilis, adductor longus, adductor brevis, and pectineus.
- (2) *Articular*, to hip-joint.
- (3) *Communicating* twig, to unite with branches of the long saphenous and medial cutaneous nerves beneath the sartorius.
- (4) A *terminal* branch, which ramifies over the femoral artery.

The posterior division pierces the obturator externus, and runs behind the adductor brevis to the anterior surface of the adductor magnus.

This division gives off:—

- (1) *Muscular*, to the obturator externus and adductor magnus.
 - (2) *Articular*, to the knee (the geniculate branch of the obturator), which perforates the adductor magnus to accompany the popliteal artery. It enters the knee-joint through the posterior ligament.
- (h) *Accessory obturator* (L. 3, 4). This nerve is only occasionally present. After running beneath the iliac fascia, and along the medial border of the psoas, it leaves the pelvis by passing over the ascending ramus of the pubes. On reaching the thigh it joins the anterior division of the obturator, supplying the pectineus and the hip-joint.

SACRAL PLEXUS (Plate IX.).

The sacral plexus occupies the posterior wall of the pelvic cavity, lying on the anterior surface of the piriformis muscle and behind the pelvic fascia. It is formed by the union of the lumbo-sacral cord from the fourth and fifth lumbar nerves, together with the anterior primary divisions of the first three, and part of the fourth, sacral

nerves. The lumbo-sacral cord descends behind the common iliac vessels, and in front of the sacro-iliac joint. The sacral nerves issue from the anterior sacral foramina between the slips of origin of the piriformis.

The plexus usually consists of two bands, an upper large band, the sciatic, triangular in outline with the apex at the great sacro-sciatic foramen, and a lower smaller band, the pudic (pudendal). The former becomes the great sciatic nerve; the latter, the internal pudic (pudendal). The branches of the plexus are muscular, visceral, cutaneous, great sciatic, superior and inferior glutæal, and internal pudic.

Branches—

(a) Muscular—

- (1) Twigs to piriformis from first and second sacrals.
- (2) Nerve to obturator internus (L. 5, S. 1, 2) leaves the pelvis through the great sacro-sciatic foramen, furnishes a twig to the superior gemellus on reaching the buttock, and disappears through the small sacro-sciatic foramen to terminate in the obturator internus.
- (3) Nerve to quadratus femoris (L. 4, 5, S. 1) emerges from the pelvis in a similar manner to that of the preceding nerve. In addition to the quadratus femoris, it supplies the inferior gemellus and also the hip-joint.

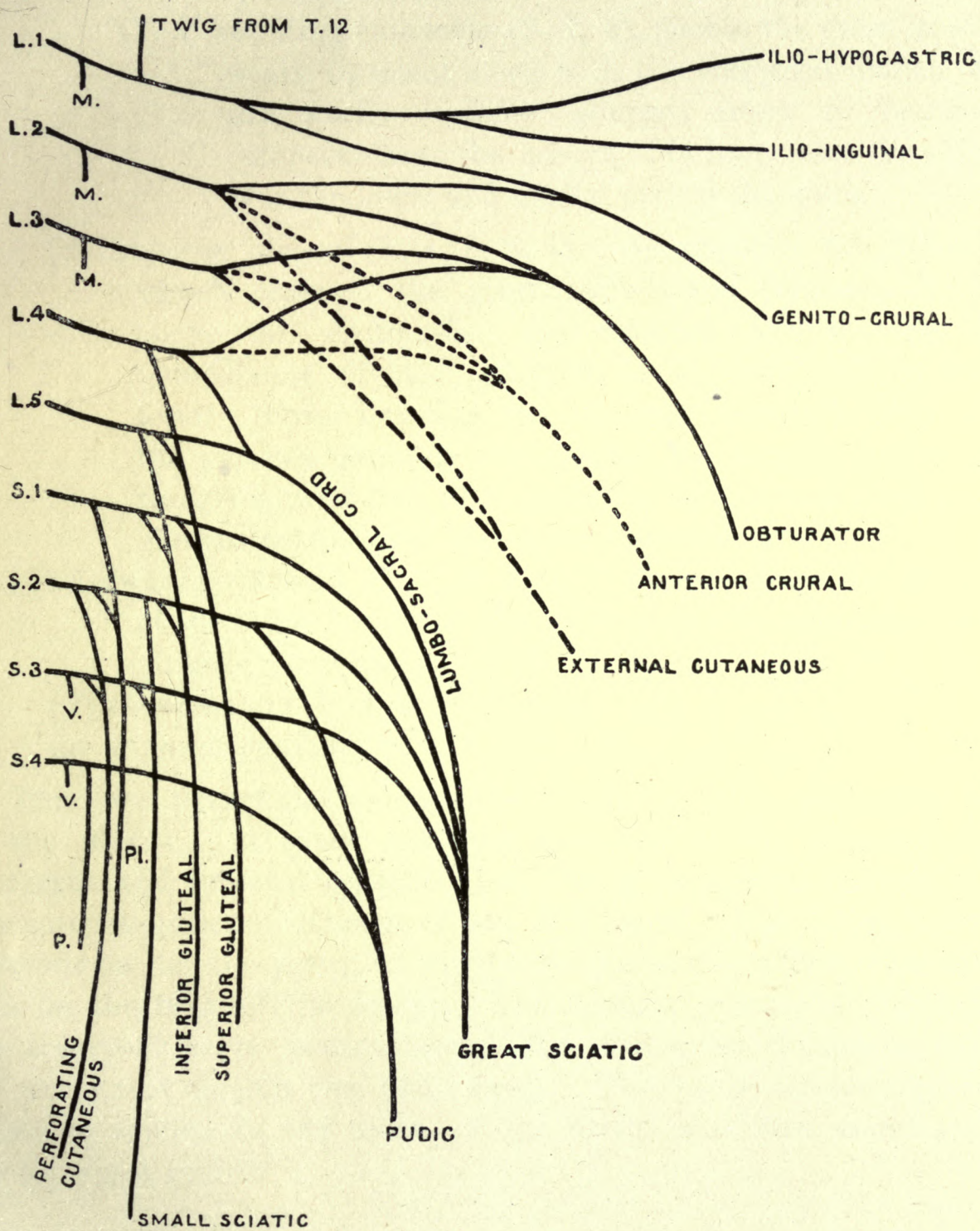
(b) Visceral, arise from the third and fourth sacral. They are distributed to the pelvic viscera.

(c) Cutaneous—

- (1) Small sciatic (posterior cutaneous nerve of thigh) (S. 2, 3), passes between the piriformis and coccygeus to leave the pelvis *via* the great sacro-sciatic foramen. Descending under cover of the great sciatic it reaches the thigh at the lower border of the glutæus maximus. It supplies the skin of the back of the thigh, and of the back of the calf for a short distance (Plate XII.), while glutæal branches innervate the skin of the lower half of the buttock. The small sciatic gives off a distinct branch, the long pudendal, at the lower edge of the glutæus maximus. This branch curves medially over the origin of the hamstring muscles, and becomes

PLATE IX.

LUMBO-SACRAL PLEXUS.



M. Muscular.
V. Visceral.

P. Perineal.
Pi. Nerve to Piriformis.

cutaneous near the pubic arch. It is distributed to the skin of the scrotum, root of the penis, anus, and the upper part of the medial aspect of the thigh. The long pudendal communicates with the superficial perineals, inferior hæmorrhoidal, and ilio-inguinal nerves.

(2) Perforating cutaneous (S. 2, 3), pierces the great sacro-sciatic ligament along with the coccygeal branch of the sciatic (inferior glutæal) artery to become cutaneous near the coccyx. It innervates the skin over the lower and medial part of the nates.

(d) *Superior glutæal* (L. 4, 5, S. 1). Accompanies the glutæal vessels through the great sacro-sciatic foramen, lying above the piriformis. On reaching the buttock it immediately divides into two, a superior and an inferior. Both branches are directed forwards between the glutæus minimus and medius, the former supplying the glutæus medius, and, the latter the glutæus minimus, glutæus medius, and the tensor fasciæ femoris.

(e) *Inferior glutæal* (L. 5, S. 1, 2). Emerges from the pelvis at the lower border of the piriformis. It innervates the glutæus maximus.

(f) *Great sciatic* (L. 4, 5, S. 1, 2, 3).

(g) *Internal pudic* (S. 2, 3, 4).

The lower part of the fourth sacral does not assist in the formation of the plexus. It sends muscular branches to the levator ani, coccygeus, and external sphincter ani, also a connecting filament to the anterior primary division of the fifth sacral. The latter nerve descends on the coccygeus, to supply that muscle together with the skin on the back of the coccyx. The anterior primary division of the coccygeal nerve passes through the sacro-sciatic ligaments and the coccygeus to join the fifth sacral. The name *sacro-coccygeal plexus* is applied to the union of the fourth and fifth sacral and the coccygeal nerves.

INTERNAL PUDIC.

The internal pudic (pudendal) passes between the coccygeus and piriformis to leave the pelvis through the great sacro-sciatic foramen. It winds over the spine of the ischium on the medial side of the pudic vessels, and disappears through the lesser sacro-sciatic foramen, to reach the hinder end of the ischio-rectal fossa. Here it enters a

membranous canal, Alcock's canal, on the lateral wall of the fossa. In this it divides into three branches, inferior hæmorrhoidal, perineal, and dorsal nerve of the penis or clitoris.

Branches—

- (a) *Inferior hæmorrhoidal*, pierces the medial wall of Alcock's canal to cross the ischio-rectal fossa in a horizontal manner. It supplies the external sphincter muscle and the perineal skin. The anterior filaments communicate with the long pudendal and superficial perineal nerves.
- (b) *Perineal*, runs forwards in Alcock's canal, lying below the internal pudic vessels, to divide into superficial and deep branches. The superficial branches are the lateral and medial superficial perineal nerves; they are prolonged forwards to the skin of the scrotum, or lateral labium pudendi. The deep branches supply the following muscles, sphincter ani externus, levator ani, transversus perinei, ischio-cavernosus and bulbo-cavernosus.
- (c) *Dorsal nerve of the penis or clitoris*, pierces the triangular ligament accompanied by the internal pudic artery. It then passes between the two limbs of the suspensory ligament of the penis, to extend forwards along the dorsum of the penis or clitoris to terminate in the glans. Twigs are given off to the compressor urethræ muscle.

GREAT SCIATIC.

The great sciatic nerve is a thick bundle of nerve fibres which essentially consists of four separate elements. These are, from the medial to the lateral side, the nerve to the hamstrings, the internal popliteal (tibial), the external popliteal (common peroneal), and the nerve to the short head of the biceps. The nerve emerges from the pelvis through the great sacro-sciatic foramen, below and behind the piriformis, then proceeds downwards, resting successively upon the os innominatum, superior gemellus, obturator internus, inferior gemellus, quadratus femoris, and adductor magnus. At a point a little below the middle of the thigh, the main trunk separates into its terminal divisions, the internal and external popliteal nerves. Overlapping the great sciatic are the piriformis, sciatic artery, small sciatic nerve, and the glutæus maximus. In the thigh it is crossed superficially by the long head of the biceps. The nerve is accompanied by a branch of the sciatic (inferior glutæal) artery, called the comes nervi ischiadici.

The muscles supplied by the great sciatic are the semi-tendinosus, semi-membranosus, long head of the biceps, and part of the adductor magnus.

INTERNAL POPLITEAL.

This is the larger of the two popliteal nerves, and passes down the middle of the popliteal space as far as the lower border of the popliteal muscle, where it becomes the posterior tibial nerve. At first it lies away from, and to the lateral side of, the popliteal artery, but becomes superficial to that vessel in the middle of the popliteal space, finally reaching its medial side.

Branches—

- (a) *Muscular*, to the gastrocnemius, soleus, plantaris, and popliteus.
- (b) *Articular*, two or three in number, accompany the superior medial, inferior medial, and azygos, articular arteries to the knee-joint.
- (c) *Cutaneous*, ramus communicans tibialis. It descends between the two heads of the gastrocnemius to join the ramus communicans fibularis of the external popliteal.

POSTERIOR TIBIAL.

The posterior tibial extends from the lower border of the popliteus to a point almost midway between the medial malleolus and the calcaneum. Here, beneath the medial annular ligament (lig. laciniatum) it divides into the medial and lateral plantar nerves. In the calf it accompanies the posterior tibial vessels in the interval between the superficial and deep flexors. At first it lies on the medial side of the vessels, but about the middle of the leg it crosses to their lateral side.

Branches—

- (a) *Muscular*, to the tibialis posticus, flexor longus digitorum, and flexor longus hallucis.
- (b) *Articular*, to the ankle-joint.
- (c) *Cutaneous*, (calcaneal) pierce the medial annular ligament to supply the skin of the heel and posterior part of the sole of the foot.

MEDIAL PLANTAR.

The medial is the larger of the two plantars, and is closely associated with the medial plantar artery. It passes forward from under cover of the medial annular ligament and the abductor hallucis, to the sulcus between that muscle and the flexor brevis digitorum.

Branches—

- (a) *Muscular*, to abductor hallucis and flexor brevis digitorum.
- (b) *Articular*, to tarsal and metatarsal joints.
- (c) *Cutaneous*, to skin on medial aspect of sole.
- (d) *Digital*.

The first digital supplies the flexor brevis hallucis and the skin over the ball of the great toe, and the medial aspect of that toe. The second gives off an offset to the first lumbrical muscle, and divides to innervate the adjacent sides of the first and second toes. The third divides to supply the contiguous sides of the second and third toes, while the fourth digital in a similar manner is distributed to the adjacent sides of the third and fourth toes. The digital nerves furnish small twigs to the nails of the toes.

LATERAL PLANTAR.

The lateral plantar accompanies the artery of the same name obliquely across the sole, under cover of the flexor accessorius (quadratus plantæ). It is continued forward in the interval between the flexor brevis digitorum and the abductor minimi digiti. Opposite the base of the fifth metatarsal bone it divides into superficial and deep portions.

Branches—

- (a) *Muscular*, to the accessorius and abductor minimi digiti.
- (b) *Cutaneous*, to the lateral side of the sole of the foot.
- (c) *Superficial portion*, supplies the flexor brevis minimi digiti, and gives off two digital branches, the first to the lateral aspect of the little toe, and the second to the contiguous sides of the little and fourth toes. This latter branch communicates with the digital of the medial plantar.
- (d) *Deep portion*. The deep portion follows the corresponding part of the lateral plantar artery, beneath the flexor accessorius and the oblique head of the adductor hallucis. It supplies the interossei, lateral three lumbricals, and the adductor hallucis. Articular twigs pass to the tarsal and the tarso-metatarsal joints.

EXTERNAL POPLITEAL.

The external popliteal, or common peroneal, rises from the bifurcation of the great sciatic in the lower part of the thigh. It passes along the lateral aspect of the popliteal space, parallel to the biceps tendon. After running between the biceps and the lateral head of the gastrocnemius, it winds round the neck of the fibula, enters the peroneus longus, and divides into musculo-cutaneous (superficial peroneal), the anterior tibial (deep peroneal), and the recurrent tibial.

Branches—

- (a) *Muscular*, to the short head of the biceps.
- (b) *Articular*, one or two branches to the knee-joint.
- (c) *Recurrent tibial*, supplying the upper part of the tibialis anticus, the superior tibio-fibular joint, and the knee-joint.
- (d) *Cutaneous*, two in number, a lateral cutaneous branch, and the ramus communicans fibularis. The former innervates the skin over the lateral aspect of the upper two thirds of the back of the leg. The communicans fibularis joins the communicans tibialis of the internal popliteal to form the lateral or short saphenous. This nerve, in company with the short saphenous vein, passes downwards, behind the lateral malleolus to terminate on the lateral side of the little toe. It is distributed to the skin of the lower third of the back of the leg, together with the lateral aspect of the foot and little toe. Articular twigs are furnished to the ankle and tarsal joints.
- (e) *Anterior tibial*.
- (f) *Musculo-cutaneous*.

ANTERIOR TIBIAL.

The anterior tibial runs obliquely forwards, beneath the peroneus longus, extensor longus digitorum, and extensor longus hallucis. Here it descends on the interosseus membrane as far as the ankle-joint, lying first on the lateral side of the anterior tibial vessels, then superficial to them, and lastly, near the ankle-joint, on the lateral side again. It reaches the dorsum of the foot by passing beneath the anterior annular ligament (lig. transversum cruris). On the dorsum of the foot the anterior tibial divides into medial and lateral portions.

Branches—

- (a) *Muscular*, to the tibialis anticus, the extensor longus

digitorum, the extensor longus hallucis, and the peroneus tertius.

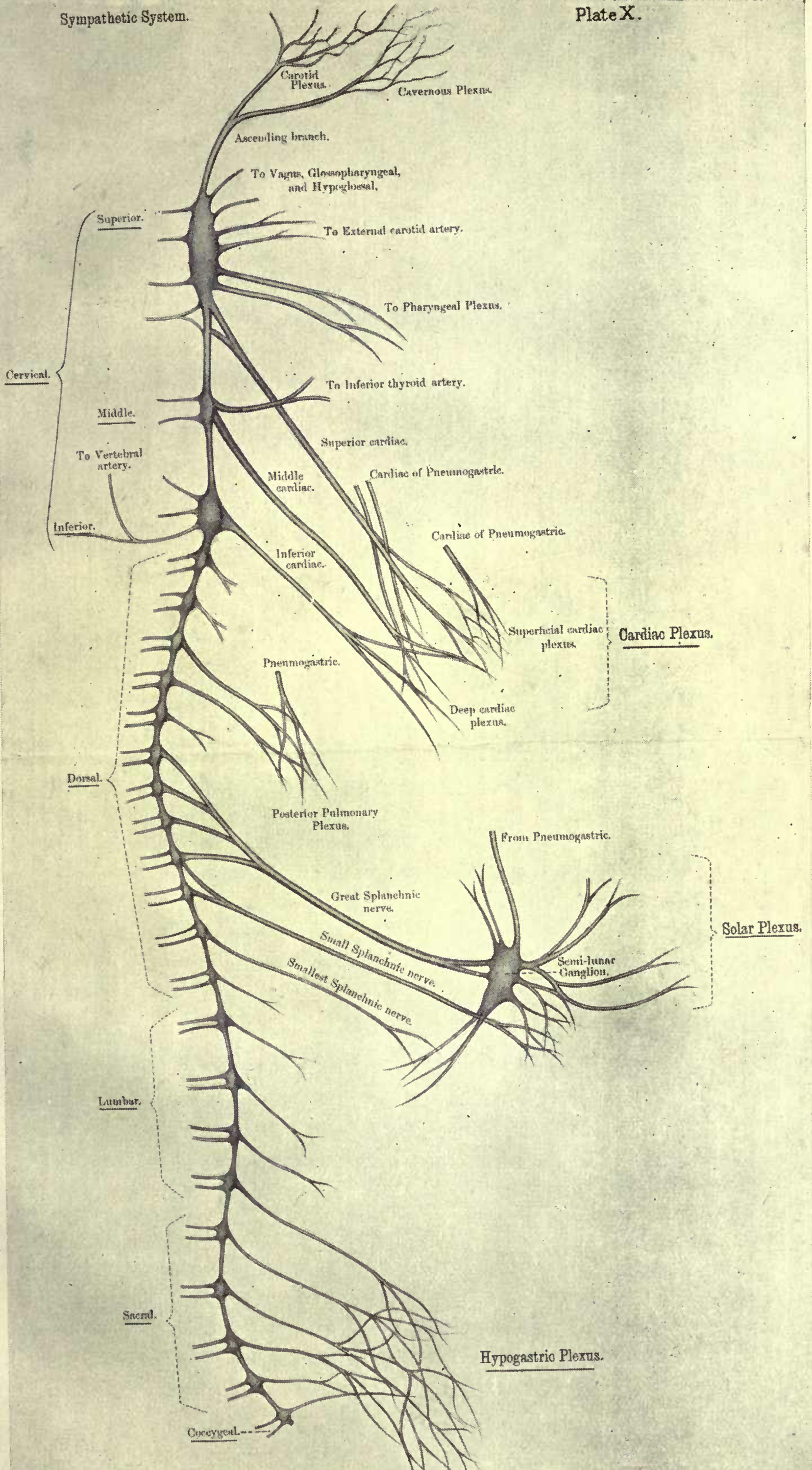
- (b) *Articular*, to the ankle-joint.
- (c) *Medial*. This is conveyed along the lateral side of the dorsalis pedis artery to the first interosseous space, where it divides to supply the adjacent aspects of the great and second toes.
- (d) *Lateral*, runs behind the extensor brevis digitorum, beneath which it becomes enlarged. From the enlargement filaments are given off to the extensor brevis digitorum, and the articulations of the tarsus.

MUSCULO-CUTANEOUS.

The musculo-cutaneous descends between the peroneal muscles and the extensor longus digitorum to pierce the deep fascia, as two branches, in the lower third of the leg. The two branches, the medial and the lateral, pass to the dorsum of the foot over the anterior annular ligament.

Branches—

- (a) *Muscular*, to the peroneus longus and peroneus brevis.
- (b) *Medial*, supplies the skin of the lateral aspect of the lower third of the leg, a branch to the medial side of the big toe which communicates with the long saphenous, and a branch to the adjacent sides of the second and third toes.
- (c) *Lateral*. Like the preceding nerve the lateral branch innervates the lateral aspects of the lower third of the leg. On the dorsum of the foot it divides into two, to innervate the adjacent sides of the third, fourth, and fifth toes. It communicates with the short saphenous.



SYMPATHETIC SYSTEM.

The sympathetic system consists of (a) two gangliated nerve cords extending along the front of the vertebral column from the basis cranii to the coccyx; (b) several plexuses associated with the cords; and (c) efferent nerves from the cords and plexuses. Each cord comprises twenty-one or twenty-two ganglia of a reddish-grey colour united by vertically-arranged commissural fibres. There are three cervical ganglia, ten or eleven thoracic, four lumbar, and four sacral. These ganglia are termed *vertebral*. Ganglia are also present in the pre-vertebral plexuses, the *collateral ganglia*, likewise in the walls of viscera and blood-vessels, *terminal ganglia*.

The sympathetic effects communication with the anterior primary divisions of the spinal nerves by means of medullated fibres, the *white rami communicantes*, and non-medullated fibres, the *grey rami communicantes*. Each grey ramus gives off a small filament to join the recurrent branch of the corresponding spinal nerve. Of the white rami, some terminate in the vertebral ganglia, while others travel up or down the gangliated cord to emerge as efferent nerves. These may pass to the collateral and terminal ganglia, or proceed direct to the viscera and blood-vessels. The commissural fibres connecting the vertebral ganglia are partly medullated and partly non-medullated, the former being derived from the spinal nerves, the latter from the ganglia themselves.

CERVICAL PORTION OF SYMPATHETIC.

The cervical portion of the sympathetic is found behind the carotid sheath, resting upon the prevertebral fascia and muscles. It does not possess any white rami communicantes. Three ganglia are usually present, superior, middle, and inferior; the middle ganglion may be absent.

Superior Cervical Ganglion.—This is the largest of the sympathetic ganglia, being about one inch in length. It is fusiform in outline and lies opposite the second and third cervical vertebræ, between the internal jugular vein and the internal carotid artery.

Branches—

- (a) *Central.*
- (1) Grey rami communicantes to the anterior primary divisions of the first four cervical nerves.
 - (2) To the petrous ganglion of the glossopharyngeal.
 - (3) To the jugular ganglion of the vagus.
 - (4) To the hypoglossal.
- (b) *Peripheral.*
- (1) Pharyngeal to the pharyngeal plexus (see below).
 - (2) Superior cardiac. This descends behind the carotid sheath to the thorax, and on the right side enters the deep cardiac plexus. The left nerve crosses the arch of the aorta to reach the superficial cardiac plexus.
 - (3) External carotid branches which form the external carotid plexus.
 - (4) Ascending, which accompanies the internal carotid artery through the carotid canal and divides into a lateral portion, the carotid plexus, and a medial portion, the cavernous plexus. The carotid plexus communicates with the abducens and the Gasserian ganglion of the trigeminal. It gives off the great deep petrosal and the carotico - tympanic. The former unites with the large superficial petrosal from the geniculate ganglion of the facial to form the Vidian, which passes to Meckel's ganglion. The carotico-tympanic proceeds to the tympanic plexus in the middle ear. This plexus is made up of the carotico-tympanic branch of the glossopharyngeal, and a filament from the geniculate ganglion of the facial. The small superficial petrosal links the plexus to the otic ganglion. The cavernous plexus communicates with the oculo-motor, trochlear, and ophthalmic division of the trigeminal.

It gives twigs to the pituitary body and furnishes the sympathetic root to the ciliary ganglion.

Middle Cervical Ganglion.—This ganglion lies over the inferior thyroid artery, behind the carotid sheath, and opposite the cricoid cartilage.

Branches—

- (a) *Central.* (1) Grey rami communicantes, to the anterior primary divisions of the fifth and sixth cervicals.
 (2) Ansa subclavia, a loop connecting the middle and inferior cervical ganglia.
- (b) *Peripheral.* (1) Middle cardiac, extends to the deep cardiac plexus.
 (2) Thyroid, to the thyroid body.

Inferior Cervical Ganglion.—A ganglion of considerable size nestling behind the first part of the subclavian artery, and between the transverse process of the seventh cervical vertebra and the neck of the first rib. It is incompletely separated from the first thoracic ganglion.

Branches—

- (a) *Central.* (1) Grey rami communicantes, to the anterior primary divisions of the seventh and eighth cervical nerves.
 (2) Ansa subclavia, to middle cervical ganglion.
- (b) *Peripheral.* (1) Inferior cardiac, to the deep cardiac plexus.
 (2) Vertebral, to vertebral plexus.
 (3) Subclavian, to subclavian artery; it communicates with the phrenic nerve.

Functional Distribution—

- (a) *Pupillo-dilator fibres* (T. 1, 2, 3), run in the ascending branch of the superior cervical ganglion, pass to the Gasserian ganglion, and from thence along the ophthalmic division of the trigeminal, and the long ciliary nerves.
- (b) *Vaso-constrictor fibres.*
- (c) *Secretory*, to salivary glands (T. 2, 3).
- (d) *Accelerator fibres* of heart (T. 2, 3, 4).
- (e) *Pilo-motor fibres* of face and neck.

THORACIC PORTION OF SYMPATHETIC.

The thoracic portion of the sympathetic rests upon the necks of the ribs and the intercostal vessels and nerves. It is clothed by the parietal layer of the pleura. There are usually ten or eleven ganglia.

Branches—

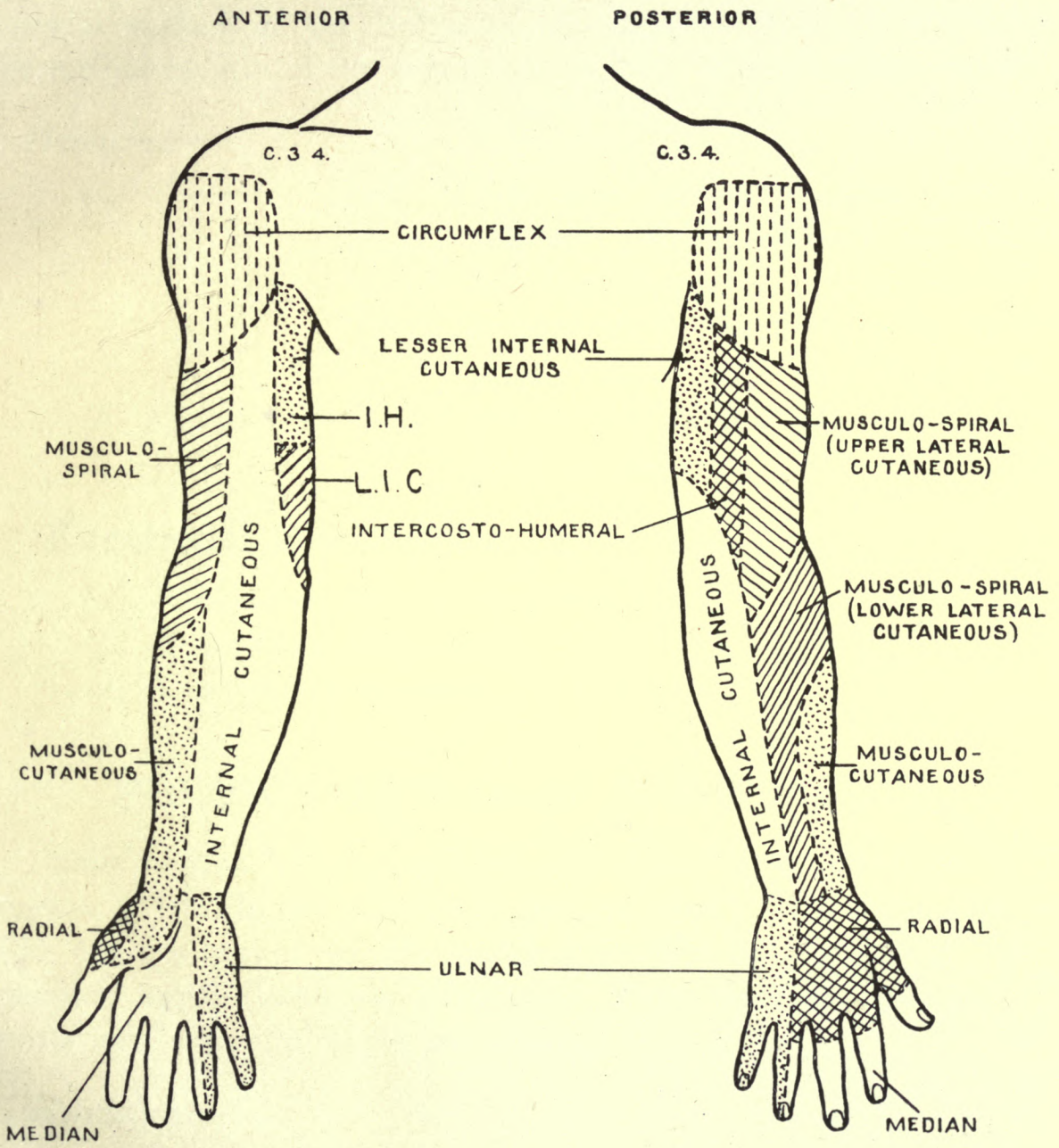
- (a) *Central.*
- (1) White rami communicantes, from the anterior primary divisions of the lower eleven thoracic nerves. Those of the upper five are distributed to the head and neck, while the remainder are connected with the thoracic and abdominal viscera.
 - (2) Grey rami communicantes, pass to the anterior primary divisions of all the thoracic nerves.
- (b) *Peripheral.*
- (1) Pulmonary, to the posterior pulmonary plexus from opposite the second, third, and fourth ganglia.
 - (2) Aortic, to the aorta from the first five ganglia.
 - (3) Great splanchnic, arises from the gangliated cord between the fifth or sixth and ninth ganglia. The nerve pierces the crus of the diaphragm to terminate in the semilunar (coeliac) ganglion.
 - (4) Lesser splanchnic, springs from the gangliated cord opposite the ninth and tenth ganglia, and enters the abdomen along with the great splanchnic, to end in the aortico-renal ganglion.
 - (5) Least splanchnic, emerges from the last thoracic ganglion. It passes through the diaphragm along with the other splanchnics, but enters the renal plexus.

Functional Distribution.

- (a) *Vaso-constrictor fibres of limbs.*
- (b) *Vaso-constrictor fibres of pulmonary vessels.*
- (c) *Pilo-motor fibres of limbs.*

PLATE XI.

CUTANEOUS AREAS OF UPPER EXTREMITIES.



I. H. Intercosto-Humeral.
L. I. C. Lesser Internal Cutaneous.

- (d) *Vaso-motor fibres of abdominal blood-vessels.*
- (e) *Vaso-inhibitory fibres of stomach and intestines.*
- (f) *Constrictor fibres to the spleen.*
- (g) *Motor fibres to musculature of rectum.*

LUMBAR PORTION OF SYMPATHETIC.

The lumbar ganglia are usually four in number; they lie on the anterior surface of the bodies of the upper lumbar vertebræ, along the medial margin of the psoas, and in front of the lumbar vessels.

Branches—

- (a) *Central.*
 - (1) White rami communicantes, from the anterior primary division of the first two lumbar nerves.
 - (2) Grey rami communicantes, to the anterior primary divisions of the lumbar nerves.
- (b) *Peripheral.* Aortic, to the abdominal aorta and the aortic plexus.

Functional Distribution.

- (a) *Vaso-motor fibres of the penis.*
- (b) *Motor fibres to bladder.*
- (c) *Motor fibres to uterus.*

PELVIC PORTION OF SYMPATHETIC.

This portion of the sympathetic rests upon the front of the sacrum, medial to the anterior sacral foramina. The trunks on each side are connected on the anterior surface of the coccyx by the ganglion impar (coccygeal ganglion.) There are four ganglia. The white rami communicantes are absent.

Branches—

- (a) *Central.* Grey rami communicantes, to the anterior primary divisions of the sacral and coccygeal nerves.
- (b) *Peripheral.*
 - (1) Visceral, to join the pelvic plexuses.
 - (2) Parietal, distributed over the middle sacral vessels.

Functional Distribution.—

- (a) *Motor and inhibitory fibres to rectum.*
- (b) *Motor fibres to bladder.*

- (c) *Motor fibres to uterus.*
- (d) *Vaso-dilator fibres of penis.*
- (e) *Secretory fibres of prostate gland.*

SYMPATHETIC PLEXUSES.

Cardiac Plexuses.

Superficial Cardiac Plexus.—

This plexus is situated in front of the pericardium, and beneath the concavity of the arch of the aorta. It is formed by (a) the cardiac branch from the superior cervical ganglion of the left sympathetic cord, and (b) the inferior cervical cardiac branch of the left vagus. A small ganglion, the ganglion of Wrisberg, is found at the junction of the nerves.

Branches—

- (1) To the left half of the deep cardiac plexus.
- (2) To the left anterior pulmonary plexus.
- (3) Along the right coronary artery to the heart muscle.

Deep Cardiac Plexus.—

The deep cardiac plexus lies behind the aortic arch, slightly superior to the bifurcation of the trachea. There are two lateral halves closely connected by numerous cross branches. The right sector comprises (a) the cervical and thoracic branches of the right vagus; (b) twigs from the right recurrent laryngeal and right sympathetic. The left sector is made up of (a) the superior cervical branch of the left vagus; (b) twigs from the left recurrent laryngeal; (c) the middle and inferior cardiac branches from the left sympathetic, and (d) filaments from the superficial cardiac plexus.

Branches—

- (a) From right sector
 - (1) To right coronary plexus.
 - (2) To left coronary plexus.
 - (3) To right anterior pulmonary plexus.
- (b) From left sector
 - (1) To left coronary plexus.
 - (2) To left anterior pulmonary plexus.

COELIAC PLEXUS.

The coeliac or solar plexus is found behind the stomach, in front to the upper part of the abdominal aorta, and between the crura of the diaphragm. Closely associated with the plexus are the two semi-

lunar (cœliac) ganglia. Each is placed upon a crus of the diaphragm and partially covered by the corresponding suprarenal gland. In addition, the inferior vena cava forms an important anterior relation of the right ganglion. Suspended from the lower pole of each is the aortico-renal ganglion. The plexus itself contains an indefinite number of minute ganglia. Certain nerves pass from the thorax to blend with the cœliac plexus. The right vagus furnishes several large branches to the plexus; the great splanchnic terminates in the superior extremity of the semilunar ganglion, while the lesser splanchnic joins the lower part of the aortico-renal ganglion. From the cœliac plexus filaments stream out over the aorta and its main branches to form subsidiary plexuses; other twigs are distributed to the abdominal surface of the diaphragm.

The aortic plexus is prolonged into the pelvis as the two hypogastric nerves.

Branches—

- | | | |
|---------------------------|---|---|
| (a) <i>Cœliac plexus,</i> | { | Coronary plexus, to œsophagus and stomach.
Splenic plexus, to spleen, stomach, and pancreas.
Hepatic plexus, to liver, biliary passages, stomach, duodenum, and pancreas. |
|---------------------------|---|---|
- (b) *Phrenic plexus,* to diaphragm, suprarenal plexus, and on the left side to œsophagus. It communicates with the phrenic nerves. A small ganglion, the phrenic, is found on the right side.
- (c) *Suprarenal plexus,* to suprarenal gland.
- (d) *Renal plexus,* the least splanchnic nerve terminates in this plexus. It furnishes twigs to the suprarenal plexus and supplies the kidneys.
- (e) *Superior mesenteric plexus,* to small intestine and large intestine as far as the end of the transverse colon.
- (f) *Spermatic or ovarian plexus,* to testis in male, and Fallopian tube, ovary, and broad ligament in female.
- (g) *Inferior mesenteric plexus,* supplies descending colon, iliac colon, pelvic colon, and upper part of rectum.

PELVIC PLEXUSES.

The two hypogastric nerves ramify over the first segment of the sacrum to form the hypogastric plexus. The plexus splits into two halves which flank the rectum, each half being termed a pelvic plexus,

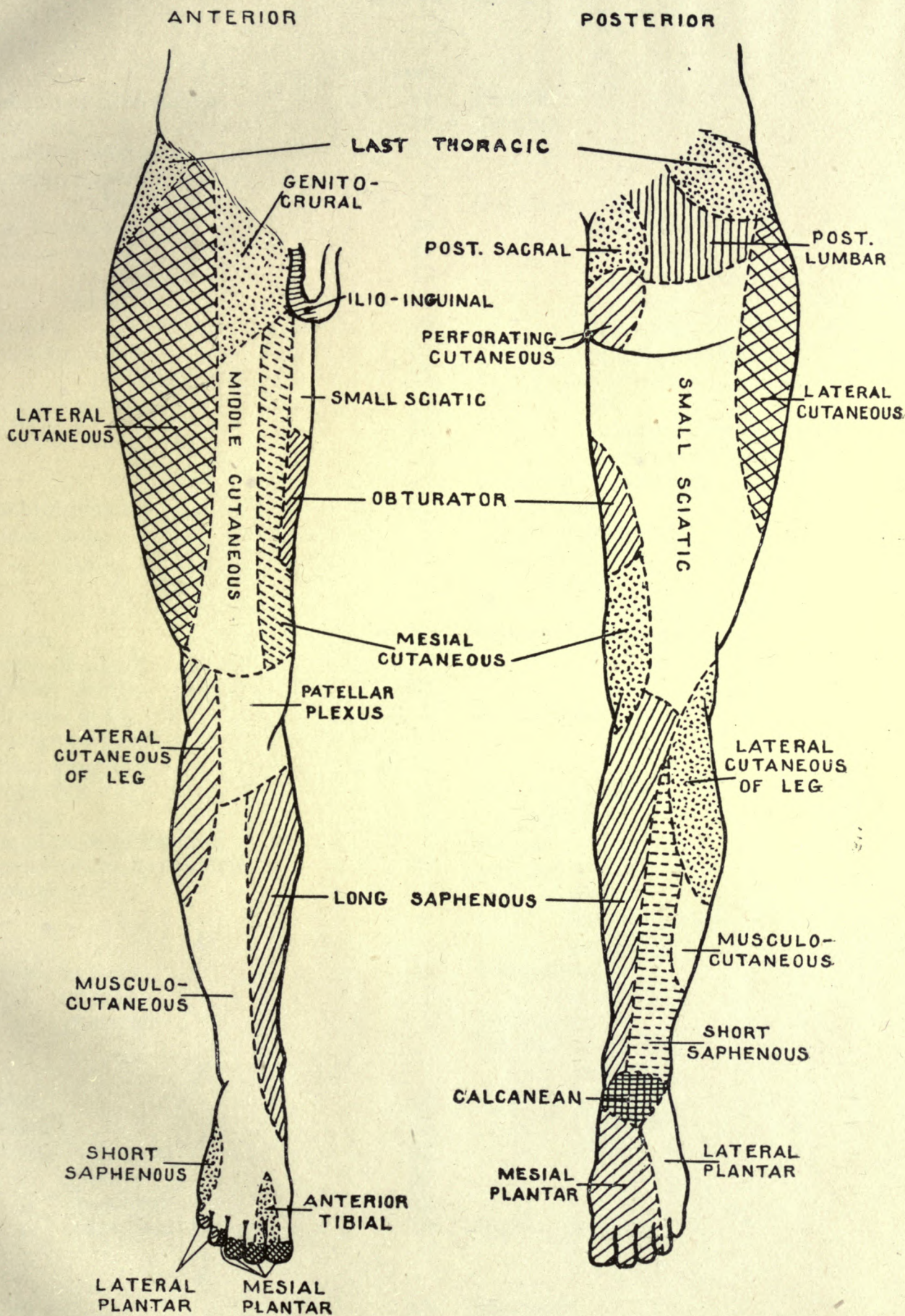
From the pelvic plexuses filaments accompany branches of the internal iliac (hypogastric) artery to supply the pelvic viscera.

Branches—

- (a) *Hæmorrhoidal plexus*, is distributed to the rectum.
- (b) *Vesical plexus*, innervates the lower part of the ureter, the bladder, seminal vesicles, and vasa deferentia (deferent ducts).
- (c) *Prostatic plexus*, to the prostate, neck of the bladder, urethra, and penis.
- (d) *Utero-vaginal plexus*, in females only. It corresponds to the prostatic plexus in males. It supplies the uterus, vagina, urethra, and clitoris.

PLATE XII.

CUTANEOUS AREAS OF LOWER EXTREMITIES.



INDEX.

	PAGE		PAGE
A			
Abdominal intercostals	47	Fourth	5
Abducens	13	Frontal	6
Accessory obturator	51	G	
Alveolar, superior	7	Ganglion, ciliary	6, 12
,, inferior	8	,, Gasserian	5
Ansa hypoglossi	26	,, geniculate	14
Anterior crural	49	,, inferior cervical	65
,, interosseous	43	,, jugulare	20
,, tibial	59	,, Meckel's	12
Arnold's	23	,, middle cervical	65
Auricular, great	31	,, nodosum	20
,, posterior	15	,, otic	13
Auriculo-temporal	8	,, submaxillary	13
Axillary	41	,, superior cervical	63
B			
Brachial plexus	35	Ganglion of Wrisberg	70
Buccal, long	8	Genito-crural	49
,, short	15	Glosso-pharyngeal	19
C			
Cardiac	24, 70	Great auricular	31
Cavum Meckelii	5	,, sciatic	55, 56
Cervical plexus	31	Greater superficial petrosal	15
Chiasma, optic	1, 2	Gudden's commissure	2
Chorda tympani	15	H	
Ciliary ganglion	6, 12	Hypoglossal	26
Circumflex	41	I	
Cochlear	16	Ilio-hypogastric	48
Commissure of Gudden	2	,, -inguinal	48
Communicans hypoglossi	32	Incisor	11
Crura cerebri	2	Inferior dental	8
D			
Dental, inferior	11	,, glutæal	55
,, middle	7	,, hæmorrhoidal	56
,, posterior	7	,, maxillary	6, 8
E			
Eighth	16	Infraorbital	7
Eleventh	25	,, trochlear	7
External laryngeal	23	Intercostals	44
,, plantar	58	Internal cutaneous	37
,, popliteal	59	,, laryngeal	23
,, superficial petrosal	15	,, plantar	58
F			
Facial	14	,, popliteal	57
Femoral	49	,, pudic	55
Fifth	5	J	
First	1	Jugular ganglion	20
L			
Facial	14	Lacrimal	6
Femoral	49	Laryngeal	23
Fifth	5	Lateral anterior thoracic	36
First	1	,, cutaneous	49

	PAGE		PAGE
Lateral plantar	58	Plexus patellar	50
Lesser internal cutaneous	37	,, pelvic	71
,, superficial petrosal	15	,, posterior pulmonary	23
Lingual	8, 11	,, sacral	51
Long buccal	8	Posterior auricular	15
,, pudendal	52	,, interosseous	43
,, saphenous	50	,, superior dental	7
Lumbar plexus	48	,, tibial	57
M		R	
Masseteric	8	Radial	42
Maxillary inferior	6, 8	Ramus communicans fibularis	59
,, superior	6, 7	,, ,, tibialis	59
Medial anterior thoracic	37	Recurrent laryngeal	24
,, plantar	58	S	
Median	43	Sacral plexus	51
Mental	11	Saphenous	50
Musculo-cutaneous (arm)	37	Second	1
,, (leg)	60	Semilunar ganglion	5
Musculo-spiral	41	Seventh	14
Mylo-hyoid	11	Sixth	13
N		Small occipital	32
Nasal	6	,, sciatic	52
Naso-palatine	12	Spheno-palatine	7
Ninth	17	Spinal accessory	25
O		Subcostal	47
Obturator	50	Submaxillary ganglion	11
Oculo-motor	2	Subscapular	41
Œsophageal plexus	20	Superficial cervical	32
Olfactory bulb	1	Superior laryngeal	23
,, filaments	1	,, glutæal	55
,, nerves	1	,, maxillary	67
,, roots	1	Supraorbital	6
,, sulcus	1	,, scapular	36
,, tract	1	,, trochlear	6
Ophthalmic division	6	T	
Optic chiasma	1	Tenth	20
,, nerves	1	Third	2
,, thalamus	2	Thoracic	44
,, tracts	1	Trigeminal	5
Orbital	7	Trochlear	5
Otic ganglion	11	Twelfth	26
P		U	
Palatine	12	Ulnar	38
Pars intermedia	14	V	
Perforating cutaneous	55	Vagus	20
Petrosal	15	Vestibular	16
Phrenic	32	W	
Plexus, anterior pulmonary	23	Wrisberg's ganglion	70
,, brachial	35	Z	
,, cardiac	70	Zygomatic	7
,, cervical	31		
,, celiac	70		
,, coronary	70		
,, lumbar	48		
,, œsophageal	20		

MA.

H.

230135

Author Hughes, Alfred Williams

Title Hughes' nerves of the human body. (Whittaker.)

University of Toronto
Library

DO NOT
REMOVE
THE
CARD
FROM
THIS
POCKET

Acme Library Card Pocket
Under Pat. "Ref. Index File"
Made by LIBRARY BUREAU

