

K-QM

34

H67

1902

UC-NRLF



\$B 198 920

Outlines of Anatomy

Holmes

U 31734





THE LIBRARY
OF
THE UNIVERSITY
OF CALIFORNIA

PRESENTED BY
PROF. CHARLES A. KOFOID AND
MRS. PRUDENCE W. KOFOID

OUTLINES OF ANATOMY

A GUIDE TO THE METHODICAL
STUDY OF THE HUMAN BODY
IN THE DISSECTING ROOM * *

BY

EDMUND W. HOLMES, A.B., M.D

Demonstrator of Anatomy, University of Pennsylvania (1892-
1901); Surgeon to the Methodist Episcopal Hospital; Con-
sulting Surgeon to the State Asylum for the Insane,
Norristown; Consulting Surgeon to the
Northern Dispensary, etc., etc.

SECOND EDITION.

PRESS OF
THE NEW ERA PRINTING COMPANY,
LANCASTER, PA.
1902.

COPYRIGHT, 1897,
BY EDMUND W. HOLMES.

COPYRIGHT, 1902,
BY EDMUND W. HOLMES.

K-41154

H67

1902

Biol.

Lib.

DEDICATION.

TO THE THOUSANDS OF
STUDENTS IN ANATOMY AND IN SURGERY,
WHO DURING THE PAST NINETEEN YEARS
OF ACTIVE TEACHING,
HAVE HONORED MY INSTRUCTIONS
WITH THEIR EARNEST ATTENTION ;
COMRADES IN STUDY, FRIENDS ALWAYS ;
THIS LITTLE VOLUME IS
MOST CORDIALLY DEDICATED.

522257

PREFACE TO THE SECOND EDITION.

“The Outlines of Anatomy” was written in an endeavor to introduce method and discipline into the dissecting room, and by thus securing cleaner and more systematic work, to revivify if possible, the interest in practical anatomy. The success of the *method* being of far more importance than the success of the book, it is particularly gratifying to the author that a second edition is urgently called for. The book cannot be used as a quiz compend; it does not take the place of the larger treatises; it is only of value in connection with the cadaver, and as in the present form it seems to fulfill the purposes for which it was published, but few changes have been made in the text.

If the whole period of dissection is more than twenty-eight days, the additional time can well be applied by taking *two* days, for each of the assignments up to and including the fourteenth, thus making forty-two days in all for the dissecting of a part with as many hours per day as is deemed advisable.

1930 Chestnut Street, Philadelphia,

January 1, 19 2.

PREFACE.

AN experience of many years in the teaching of large classes in anatomy and in surgery has convinced the author that the average medical student is eager and willing to learn, if he can do so without too great personal inconvenience, but the methods of anatomical instruction in many of our colleges are not provocative of extraordinary enthusiasm. Too often we find the rooms inaccessible and uncleanly, without museum preparations or other proper facilities for instruction; the bodies imperfectly preserved or injected; the students themselves not required to attend except as they please; no notice taken of their presence or absence; and without any standard of acquirement being maintained, it is expected that their knowledge of the complexities of human anatomy shall be attained by a single dissection of each part, made without system, and often unaided.

The method which the author advocates, now in vogue at the University of Pennsylvania, requires proper material, properly injected; set hours in the anatomical rooms; uniformity in attendance and work, secured by the calling of the roll; each dissector upon homologous parts dissecting out the same tissues upon the same

day, personally guided by competent instructors in attendance throughout the dissecting room hours, with, at the end of each twenty-eight-day period, an examination upon the part dissected.

This little book is intended to systematize the work particularly for the students under the author's care. It is supplemental to, but does not in any way take the place of, the larger anatomies; and being an outline or working manual, constant reference is made to the standard authority.

As it is an elementary treatise, no emphasis is laid upon points of applied anatomy. The diagrams, being for illustration and not for embellishment, perhaps lack somewhat of artistic symmetry, for which the author is alone responsible.

If in any way it shall contribute to orderliness and discipline in a dissecting room; if it shall aid in securing better and more methodical habits of work among the students; if it shall in only a slight degree revivify the interest in practical human anatomy, which of late years has been overshadowed by less important branches, the object of this book will have been amply accomplished.

1626 Mount Vernon Street, Philadelphia,
August 2, 1897.

CONTENTS.

	PAGE
PREFACE	5
INTRODUCTION	9
CHAPTER I.	
THE DISSECTION OF THE UPPER EXTREMITY	14
CHAPTER II.	
THE DISSECTION OF THE LOWER EXTREMITY	38
CHAPTER III.	
THE DISSECTION OF THE HEAD AND NECK	69
CHAPTER IV.	
THE DISSECTION OF THE THORAX AND ABDOMEN	108

INTRODUCTION.

THE student, at the entrance into his medical course, is at once confronted with the study of Anatomy. He should realize that this is the most difficult and the most comprehensive of the major branches in the curriculum—the foundation of the whole fabric, the keystone of the entire arch. Further, he should have impressed upon his mind that the only opportunity the majority will ever have for the study of practical anatomy is in the medical-school days. Hygiene, chemistry, experimental physiology, the practice of medicine or of surgery, may be carried on at home. Every large town is destined to have its bacteriological laboratory; but the dissection of the human body can only be done here and now.

Many of our matriculates could come to us much better prepared than they do. The custom of “reading” Gray—*i. e.*, skimming over a thousand pages in a cursory way—is worse than useless, because it is a waste of time that could be employed to better advantage. It is not what we read, but what we master that is of benefit. They had, therefore, far better devote themselves exclusively to the sections upon osteology and myology, and master these thoroughly first. The reason that so few retain their anatomy is

because the methods of teaching and study are defective. It requires only a casual glance to demonstrate that the course of artery or nerve is largely a description of the bony or muscular structures it passes over. Apart from their surgical importance, a thorough mastery of these preliminary structures before attempting the vascular or nervous trunks will amply repay. Even after the matriculates enter the medical school, more attention should be paid to these, not in the way of memorizing, but in understanding their relative positions. There is a great deal of humbug in the average dissecting-room work, and it is almost painful, considering the value of the cadavera, that our schools should be so blind. No one should be allowed to touch a human body until he appreciates the *privilege*, and has some knowledge of what he is about to investigate. Wet museum preparations and models should be largely used in the earlier days of the session for the novice. Much can be taught in this way, as we teach a puzzle to a child—taking it apart and putting it together again until he knows it thoroughly. With the wet specimens all dissected out, which could readily be accumulated each session for the preliminary studies of the following year, layer upon layer of muscle should be taken off and replaced, taken off and replaced, a dozen times or more, until the relative positions and interrelations are thoroughly fixed in all their details.

A set of bones should be obtained, and each student required to mark the origins red and the insertions blue, in chalk, finally preparing a set for future reference for themselves, in water colors. Few schools have wet preparations kept in jars for the use of students in the rooms. Every year most useful "material" is thus wasted.

Next in importance come the fascias. The medical student is yet unborn who has made a complete dissection of the fascias; yet clinically and topographically they are of great significance; They form sheaths of muscles, arteries, and nerves. they separate muscles into groups, giving an indication of their function and nerve supply; they divide off regions into separate compartments, and pathologically define the path of pus, of extravasations of blood, and the deformities of burns.

The bones, muscles, and fascias can be all studied on previously dissected wet preparations, with some aid perhaps from models; and then, and not till then, should the new student be allowed to put a scalpel into a dead body, and even then only under the direct supervision of his demonstrators. Applied anatomy should be ignored in a first dissection. In the higher grade of schools it is deferred till the third year.

In entering a dissecting room a student will require :

A standard text-book on anatomy.*

* At the University of Pennsylvania, Gray or Morris, Holden or Heath's "Dissector," and Deaver's "Surgical Anatomy," are recommended.

A case of instruments containing :

- 1 cartilage knife,
- 2 large scalpels,
- 1 small scalpel,
- 1 pair of dissecting forceps,
- 1 pair of scissors,
- 1 tenaculum,
- 1 pair of chain hooks,
- 1 blow-pipe,
- 1 grooved director,
- 1 post-mortem needle, with thread.

Two ounces of carbolized glycerine.

Two muslin roller bandages, three inches wide.

Some squares of muslin.

An ounce of carbolized vaseline.

A dozen bichloride of mercury tablets.

$\frac{1}{4}$ lb. package of chloride of lime.

℥iv of aromatic spirits of ammonia.

It is more economical to get a case of instruments of *good quality*, as it will facilitate the dissecting work, and they can be used in after years in making post-mortem examinations. The carbolized glycerine should be applied at the end of the day's dissection, the edges of the skin and fascia neatly tacked together with needle and thread, the squares of muslin, dipped in corrosive sublimate solution 1:500, wrapped about the part, and the whole retained with the three-inch roller bandage. Before beginning dissection, especially if the viscera are to be handled or the cavities examined, anointing the hands with the carbolized

vaseline will prevent excoriation of the skin, and also render the odor less abiding. For cleansing the hands afterwards, clean the nails, scrub with abundant soapsuds; make a fresh solution of chloride of lime and immerse the hands thoroughly, and then rub upon them some aromatic spirits of ammonia. The mustard and oatmeal mixture is recommended by some.

The tabulations throughout the book are not intended for memorizing, but as checks for completed dissections.

Finally, do not despair of learning your anatomy. Keep at it. Ignorance of the branch is the most frequent cause of mistakes in practice. There is nothing that will give you greater confidence in your operative surgery. Even the manual dexterity attained by the use of the scalpel will stand you in good stead, especially if you practice the use of the knife and the passage of instruments with both hands alike; and do not forget, the years at the medical college will probably afford the only opportunity you will have to study it practically.

Anatomical knowledge cannot be crammed in, it must soak in. It cannot be acquired in a hurry, it must be absorbed slowly; cannot be all retained, at the first trial, it must be learned seven times. It should be taught not by the ear alone, but by the sight and by the touch; not only by lecture, but also by frequent demonstration upon the cadaver, and by dissection.

CHAPTER I.

Dissection of the Upper Extremity.

FIRST DAY.

Make an incision and remove the integument, as per Diagram I, from areas marked 1 and 2.

Study the origin of the platysma myoides muscle.

Note in the superficial fascia :

Its two layers.

The mammary gland, with its nipple and areola.

The superficial nerves from the cervical plexus, the anterior and lateral cutaneous nerves from the intercostals, the cutaneous branches from the internal mammary, axillary, and intercostal arteries.

The cephalic vein in its groove with the descending acromio-thoracic artery.

Demonstrate the deep fascia, cleaning it thoroughly from the mid-sternal line to the posterior boundary of the axilla so as to show its pectoral and axillary divisions. Note the conical shape of the latter. Loosen the pectoral fascia from the clavicle and sternum, and turn it outwards to expose :

1. Pectoralis major muscle (two portions).
2. Deltoid, and groove between them.

Clean the former muscle thoroughly, and study its origin and insertion.

SECOND DAY.

Detach the pectoralis major muscle from its clavicular and costosternal origin, and reflect it outwards.

Study the interpectoral and axillary leaflets of the deep fascia, and the costo-coracoid membrane, pierced by the cephalic vein, the acromio-thoracic artery and vein, the superior thoracic artery, and the anterior thoracic nerve; and the clavi-pectoral fascia.

Detach the anterior layer of the costo-coracoid membrane from the clavicle, to expose the subclavius muscle, its origin and insertion.

Clean off the pectoralis minor muscle, noting the division of the costo-coracoid membrane at its upper edge, and study its origin and insertion. Detach the costal origin of the pectoralis minor muscle to expose the axillary space.

Read the description of the boundaries of the axillary space in Gray's or Morris' "Anatomy," and review the fascias and muscles as thus far exposed.

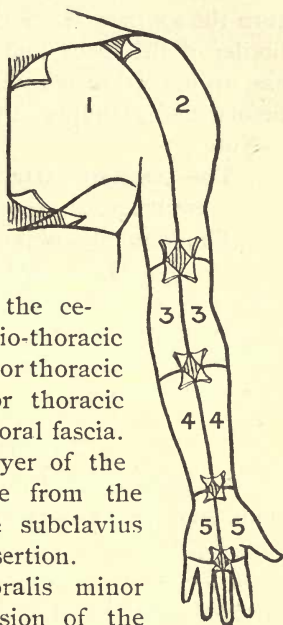


DIAGRAM I.

THIRD DAY.

The Axillary Space.

Dissect off the costo-coracoid membrane and turn the axillary fascia over the posterior inferior border of the space, and define the coracoid process, an important bony landmark. Clear out the areolar and glandular tissues filling in the space.

Note :

The axillary artery and vein and their branches.

The brachial plexus, its cords and branches.

Study the origin and insertion of the sub-scapularis muscle ; the insertion of the serratus magnus muscle, and the long thoracic nerve, which runs about three inches from the margin of the pectoralis major muscle.

FOURTH DAY.

REVIEW :—Axillary artery and its three divisions, and the axillary vein.

The axillary artery divided into 3 parts by the pectoralis minor.	{	<ol style="list-style-type: none"> 1. Superior thoracic ; acromio-thoracic. 2. Long thoracic ; alæ thoracic. 3. Anterior and posterior circumflex ; sub-scapular (dorsalis scapulæ).
---	---	---

Brachial plexus—its three cords.

Outer cord.	{	<ol style="list-style-type: none"> External anterior thoracic. Outer head of median. External cutaneous.
-------------	---	---

Inner cord.	{ Internal anterior thoracic. Inner head of median. Ulnar. Internal cutaneous. Lesser internal cutaneous (joined by the intercosto-humeral branch of the second or third intercostal nerve).
Posterior cord.	{ Three sub-scapular nerves. Musculo-spiral nerve. Circumflex nerve (one nerve sup- plying two muscles).

Second-year students will study the relations of nerves and arteries, and the nerve supply of particular muscles.

FIFTH DAY.

Denude No. 3, Diagram I, to about three inches below the bend of the elbow.

In the superficial fascia note :

The superficial veins, particularly the cephalic and basilic, and their points of passage through the fascias.

The cutaneous branches of the external, internal, and lesser internal cutaneous and the circumflex nerves ; also, two external cutaneous branches of the musculo-spiral nerve.

The venous M at the bend of the elbow.

Clean off the superficial fascia, and note carefully the attachments of the deep fascia to the external and internal condyloid ridges, separating the muscles into groups and pierced by the musculo-spiral nerve and superior profunda artery, the ulnar nerve, the inferior profunda artery, and the anastomotica magna; also note the epitrochlear glands.

Clean off the muscles of the *arm*, leaving the bicapital fascia. Study the origin and insertion of the coraco-brachialis, biceps, and brachialis anticus muscles.

SIXTH DAY.

Clean off the brachial artery, and the venæ comites, and its branches.

Branches of the brachial artery.	{	<ol style="list-style-type: none"> 1. Superior profunda. 2. Inferior profunda. 3. Anastomotica magna. 4. Muscular, and nutrient to humerus.
---	---	---

Note the continuation of the branches of the brachial plexus in their relation to the arteries, particularly the musculo-spiral nerve, dividing into radial and posterior interosseous branches.

Study relations of brachial artery. Review axillary space and arm.

SEVENTH DAY.

Denude as far as wrist (Diagram I). In the superficial fascia take notice of:

The ulnar, median, and radial veins.

The formation of the cephalic and basilic veins, and their relation to structures beneath.

The internal cutaneous nerve, the external cutaneous nerve (two branches), the cutaneous branches of ulnar and median nerves.

Clean off the superficial fascia, to expose the deep fascia, and trace the intermuscular septa to their bony attachments. Divide it in the lines of the superficial incisions, not overlooking the bicipital fascia, the vertical and transverse intermuscular septa, and the aperture for the communication between the superficial and deep veins.

Four flexors and one pronator arise from the inner condyle.

The supinator longus muscle [*inter alia*] from the external condyloid ridge, and certain extensors and supinators from the external condyle.

EIGHTH DAY.

Clean off the following muscles and study their origin and their insertion, so far as the cutaneous incisions will allow :

1. Pronator radii teres.
2. Flexor carpi radialis.
3. Palmaris longus.
4. Flexor sublimis digitorum.
5. Flexor carpi ulnaris.

Note that all these have a common origin, (1) from internal condyle, (2) from fascia of forearm,

(3) from intermuscular septa ; but the pronator radii teres and the flexor sublimis digitorum and the flexor carpi ulnaris have additional bony attachments, while the flexor sublimis digitorum is the only one attached to all three bones—humerus, radius, ulna.

The triangle at the bend of the elbow, its boundaries and contents.

NINTH DAY.

Dissect the radial artery and its branches, the radial recurrent and muscular.

The musculo-spiral nerve dividing into radial and posterior interosseous nerves, and their relations.

The radial nerve, with its branches and muscular supply.

The ulnar artery and its branches, the anterior and posterior ulnar recurrent, the interosseous trunk dividing into

Interosseous trunk.	{	Posterior interosseous	{	and how it gets to the back of the forearm.
		Anterior interosseous		{

Ulnar nerve.	{	Appreciating how it gets from the arm into the forearm, and the muscles it supplies :
		One and a half muscles in the forearm.

One and a half muscles of the thumb. One and a half fingers, anteriorly and posteriorly.

TENTH DAY.

Denude the superficial fascia of the palmar surface of the hand and notice fully its granular fat and the three palmar-cutaneous branches of the nerves.

Clean off the superficial fascia, without destroying the palmaris brevis muscle.

Outline the anterior annular ligament, with its bony attachments, and its continuations above and below.

Follow downward the division of the deep palmar fascia into four slips, and the sub-division of each of these four into two, and their attachment to the transverse metacarpal ligaments, thus binding down the flexor tendons.

Make a careful vertical incision from the tip of the middle finger to the *distal edge* of the annular ligament to expose the bursa beneath, and the vertical septa sub-dividing the hand into three portions; and the relation of the synovial sheaths of the tendons of thumb, middle and little fingers to the bursa.

Study the structures going over and under the annular ligament, with the origin and insertion of the palmaris longus and palmaris brevis

muscles, and then divide the annular ligament vertically in the middle line.

Second-year students will consider the influence of the fascias in determining the pointing of palmar abscesses.

ELEVENTH DAY.

Follow the superficial group of muscles down to their insertion, and note the extent of the synovial sheaths.

Learn the formation of the superficial palmar arch and its branches, and note particularly that the latter are directed toward the inter-digital clefts and are embedded in fat and areolar tissue.

<p><i>Superficial palmar arch</i> formed by the ulnar with the superficialis volæ, or by a branch from the radialis in- dicens.</p>	}	<p>4 digitals joined (except- ing the first) by the 3 palmar interossei from the <i>deep arch</i> to form the collateral digital. Muscular. Cutaneous.</p>
---	---	--

Follow these arteries to their terminal anastomoses.

Fix the boundaries of the thenar, hypo-thenar, and central regions of the palm, and their several contents. Distinctly appreciate where the superficial and deep arches cross the palm.

Note what separates them from each other.

TWELFTH DAY.

Dissect the deep layer of muscles of the forearm, namely :

Flexor profundus digitorum,	} Their origin and insertion.
Flexor longus pollicis,	
Pronator quadratus,	

Read carefully in "Gray" the median nerve and its branches. Also the origin and insertion of the supinator longus, and follow the deep group of muscles to their insertion.

Study carefully again :

1. The superficial and deep fascias of the hand.
2. The insertion and interrelation of the flexor sublimis and flexor profundus digitorum muscles ; also, the vaginal sheaths, the ligamenta brevia et vasculosa ; also, the anastomosis of the anterior carpal arteries.

THIRTEENTH DAY.

Notice the contents of the three sub-divisions of the hand :

1. Thenar.

The abductor pollicis muscle,
The opponens pollicis muscle,
The flexor brevis pollicis muscle,
The adductor pollicis muscle.

Look out for the superficialis volæ artery, and, deeper, the main trunk of the radial artery itself.

2. *Hypo-thenar.*

The abductor minimi digiti muscle,
 The flexor brevis minimi digiti muscle,
 The opponens minimi digiti muscle.

3. *Central Division.*

Its formation and limitations.

Review the bursa under the annular ligament and its important relations to the synovial sheaths of the tendons ; also, study again the tendons of the flexor longus pollicis, flexores sublimis et profundus digitorum, and the way they are bound down by the sub-divisions of the deeper fascia.

The superficial arch, its formation and branches.

The superficial branches of the median and ulnar nerves, and their distribution to the fingers, and their relations to the tendons of the flexor sublimis digitorum muscle.

FOURTEENTH DAY.

Work out the lumbricales muscles, with their origin and insertion.

Cut and turn down the tendons of the flexor sublimis et profundus digitorum muscles.

Dissect the deep branches of the ulnar and median nerves, and the method of formation of the deep arch and its branches.

<i>Deep Palmar</i>		Princeps pollicis.
<i>Arch formed</i>		Radialis indicis.
by the radial		Recurrent artery to carpus.

with a communicating branch from the ulnar.	}	Three perforating arteries to dorsum.
		Three interosseous arteries to roots of fingers.

A layer of fascia covers the palmar interossei muscles, and to this is attached the perpendicular septa from the deep palmar fascia.

Clear this off to expose the palmar interossei muscles and the transverse metacarpal ligament.

FIFTEENTH DAY.

Working in conjunction with the dissectors upon the head and trunk, turn the body into the prone position.

Remove the integument of the area marked 8 in Diagram II.

Clean off thoroughly the dense fascia covering the deltoid muscle, noting its bone attachments, its fasciculi, and its extensions to form the supra- and infraspinous aponeuroses. Remove this to expose the deltoid from origin to insertion. Study the insertion of the latissimus dorsi muscle, which has been synchronously exposed by the student working upon the trunk, and the insertion of the trapezius muscle shown by the dissector upon the head.

Detach the deltoid by an incision along the lower borders of the clavicle, acromion process, and spine of the scapula, and reflect it downwards.

Second-year students will note its relations to the insertion of the coraco-brachialis muscle, to the musculo-spiral groove, and to the shoulder joint.

Study again the origin and insertion of the subscapularis muscle.

Dissect off the firm fascias covering the surraspinatus, the infraspinatus, the teres major and the teres minor muscles; and appreciate the quadrilateral and triangular spaces formed in conjunction with the long head of the triceps muscle, and the important structures passing through them. In conjunction with the dissec-

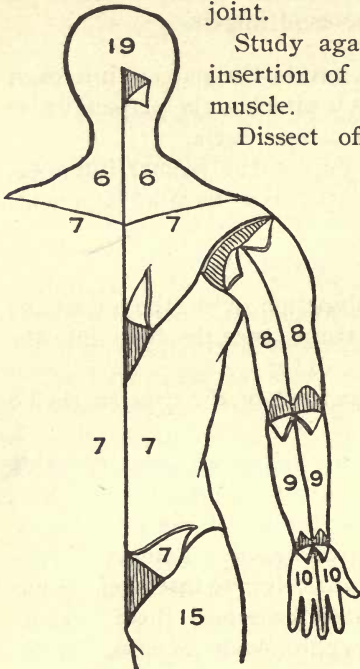


DIAGRAM II.

tors upon the head and thorax, lift the rhomboids and study in full the origin and insertion of the serratus magnus and the latissimus dorsi muscles, and the arteries anastomosing about the scapula.

SIXTEENTH DAY.

Study the superficial nerves on the back of the arm, branches from the intercosto-humeral, musculo-spiral, and lesser internal cutaneous nerves.

Clear off the deep fascia, noticing its bony attachments. Look out for the epitrochlear lymphatic glands.

Remove the deep fascia and study the three heads and the insertion of the triceps extensor muscle, particularly the involucre covering the olecranon.

Study the anconeus muscle, which may be considered as an expansion downward of the fibers of the triceps.

Master thoroughly the boundaries and contents of the musculo-spiral groove.

Dissect out carefully the vascular anastomoses about the elbow.

SEVENTEENTH DAY.

Remove the skin over the areas marked 9, Diagram II, from the dorsal surface of the forearm, noticing the superficial branches from the internal cutaneous, musculo-spiral, radial, and ulnar nerves.

Lay bare the superficial fascia marked 10, Diagram II, and note the venous arch on the back of the hand, its method of formation, the vena salvatella, and the venous extensions along the forearm.

Clean off the deep fascia, recognizing its septa and bony attachments, outlining the posterior annular ligament, which is to be left *in situ*.

Lay open the deep fascia and follow down the origin and insertion of the supinator longus, the extensor carpi radialis longior and the extensor carpi radialis breviar muscles, noticing the radial nerve at the lower third emerging from beneath the tendon of the supinator longus.

EIGHTEENTH DAY.

Dissect out and study :

Extensor communis digitorum muscle,	} Their origin and insertion.
Extensor minimi digiti muscle,	
Extensor carpi ulnaris muscle.	

Note their nerve supply, and the artery running between them and the deeper group; then cut the extensor communis digitorum and extensor minimi digiti midway between origin and insertion, and remove the attachments of the extensor carpi ulnaris and of the anconeus to the olecranon, so as to expose the :

Extensor ossis metacarpi pollicis,	} Dissect their origin and insertion.
Extensor primi internodii pol- licis,	
Extensor secundi internodii pol- licis,	
Extensor indicis.	

The supinator brevis (one of the most difficult muscles to rightly comprehend).

The posterior interosseous nerve,	} And how they get to the back of the forearm.
The posterior interosseous artery.	

Compare the course of the anterior interosseous artery with the posterior interosseous artery, and the anterior interosseous nerve with the posterior interosseous nerve.

The recurrent interosseous artery.

NINETEENTH DAY.

Study the posterior annular ligament, its bony attachments, its septa, compartments, and contents of each.

The course and branches of the radial artery upon the back of the hand, and particularly its method of gaining access to the palm.

Master the distribution of the radial nerve.

The insertion of the extensor groups of the muscles into the phalanges must next be worked out, together with the vincula uniting the tendons of the extensor communis digitorum, noticing especially those of the ring finger. Compare the method of insertion of the extensor communis digitorum with that of the flexores sublimis et profundis digitorum.

Study again the nerve supply of the back of the forearm and hand; do not overlook the

posterior carpal arch, its formation and its branches of distribution.

Work out the origin and insertion of the four lumbricales muscles, and of the four dorsal and three palmar interossei muscles, and notice their nervous supply. Note the anastomosis of the arteries upon the front and back of the hand.

TWENTIETH DAY.

Make a diagram of the vascular and nervous supply of the shoulder, arm, forearm, and hand.

TWENTY-FIRST DAY.

The second-year student will also study the nerve supply of the various muscles, and the following anastomoses :

In the axilla,	} With their surgical relations,
Around the scapula,	
About the elbow,	
At the wrist,	
In the hand,	

and will also work out the articulations.

TWENTY-SECOND TO TWENTY-EIGHTH DAYS.

Review the whole dissection of the upper extremity.

Review :

The branches of the radial artery.	{	<p>Radial recurrent, muscular, superficialis volæ, Anterior and posterior carpal, Metacarpal, Dorsalis pollicis, Dorsalis indicis, The deep palmar arch (as above).</p>			
The branches of the ulnar artery.	{	<p>Anterior and posterior ulnar recurrent.</p> <table border="0" style="margin-left: 20px;"> <tr> <td style="vertical-align: middle; padding-right: 5px;">Inter- osseous trunk.</td> <td style="font-size: 2em; vertical-align: middle; padding-right: 5px;">{</td> <td> <p>Anterior interosseous (median artery), Posterior interosseous (inter- osseous recurrent).</p> </td> </tr> </table> <p>Muscular, Anterior and posterior carpal, Deep communicating, Superficial palmar arch (as above).</p>	Inter- osseous trunk.	{	<p>Anterior interosseous (median artery), Posterior interosseous (inter- osseous recurrent).</p>
Inter- osseous trunk.	{	<p>Anterior interosseous (median artery), Posterior interosseous (inter- osseous recurrent).</p>			
The branches of the median nerve.	{	<p>None in the arm, Muscular and anterior inter- osseous. { To all the muscles of the fore- arm, excepting the flexor carpi ulnaris and one-half of the flexor profundus digitorum.</p> <p>Palmar cutaneous, Five digitals to three and a half fingers anteriorly, Two lumbricales, Two and a half muscles of the thumb.</p>			

The branches of the ulnar nerve.	{	Articular to elbow and to wrist,
		Cutaneous. { Palmar cutaneous, Digital cutaneous, Dorsal cutaneous.
		Deep palmar,
		Muscular branches. { To one and a half muscles of the thumb, To two lumbricales, To all the interossei.
The branches of the musculo-spiral nerve.	{	Muscular to five muscles— Triceps. Anconeus. Brachialis anticus in part. Supinator longus. Extensor carpi radialis longior.
		Three cutaneous to arm and forearm,
		Radial { External cutaneous to thumb, Internal cutaneous to adjacent sides of thumb, forefinger, mid- dle and ring fingers.
		Posterior interosseous—to all muscles of radial and posterior brachial regions, excepting anconeus, supinator longus, and extensor carpi radialis longior.

See that you have dissected these branches of the arteries and nerves.

TABLE I.—THE MUSCLES OF THE UPPER EXTREMITY.

MUSCLE.	ORIGIN.	INSERTION.	FUNCTION.	NERVE SUPPLY.
Pectoralis major	Inner half of clavicle, lateral half sternum, cartilages of six to seven ribs.	Anterior bicipital ridge of humerus.	Adduction of arm.	External anterior thoracic.
Pectoralis minor	Third, fourth and fifth ribs.	Coracoid process of scapula.	Draws scapula towards median line.	Internal anterior thoracic.
Subclavius.	Cartilage of first rib.	Middle of clavicle.	Depresses the clavicle.	Fifth and sixth cervical.
Deltoid	Outer third of clavicle, acromion process and spine of scapula.	Middle of shaft of humerus.	Abducts arm.	Circumflex nerve.
Subscapularis.	Subscapular fossa.	Lesser tuberosity of humerus.	Internal rotator of humerus.	Subscapular nerve.
Coraco-brachialis	Apex of coracoid process.	Middle of shaft of humerus.	Draws humerus forward and inward.	Musculo-cutaneous nerve.
Biceps.	Short head from coracoid process; long head from upper margin of glenoid cavity.	Tuberosity of the radius.	Flexor and supinator of the forearm.	Musculo-cutaneous nerve.
Brachialis anticus	Outer and inner surfaces of humerus (lower one-half) and fascia.	Coronoid process of ulna.	Flexor of forearm.	Musculo-cutaneous, musculospiral.*
Pronator-radialii teres.	One head from internal condyle; small head from coracoid process of ulna.	Middle of outer surface of shaft of radius.	Pronator of forearm.	Median nerve.
Flexor carpi radialis	Inner condyle of humerus and fascia.	Base of second metacarpal.	Flexor of wrist.	Median nerve.

* Certain muscles have a double function through their double nerve supply. The latest investigations seem to indicate the presence of an intra-muscular nerve plexus through which the muscular fibers are simultaneously innervated.

THE MUSCLES OF THE UPPER EXTREMITY.—Continued.

MUSCLE.	ORIGIN.	INSERTION.	FUNCTION.	NERVE SUPPLY.
Palmaris longus. . . .	Inner condyle of humerus and fascia.	Annular ligament, palmar fascia.	Tensor of palmar fascia, flexor of wrist.	Median nerve.
Flexor carpi ulnaris . .	One head from inner condyle of humerus, the other from olecranon and by aponeurosis from two-thirds of posterior border of the ulna.	Pisiform bone, metacarpal bone of little finger.	Flexor of wrist.	Ulnar nerve.
Flexor sublimis digitorum.	(1) From internal condyle of humerus; (2) from coronoid process of ulna; (3) from oblique line of radius.	Into lateral margins of second phalanges of four lesser fingers.	Flexor of fingers.	Median nerve.
Flexor profundus digitorum.	Upper two-thirds of anterior internal and posterior (by aponeurosis) surface of ulna; and one-half of interosseous membrane.	Into bases of terminal phalanges of four lesser fingers.	Flexor of fingers.	One-half ulnar nerve, one-half median nerve.
Lumbricales (4). . . .	Tendons of flexor profundus.	Expansion of extensors.	Flexors of first phalanges, extensors of second and third.	Median and ulnar nerves (deep).
Flexor longus pollicis. .	Anterior surface of radius from below tuberosity to insertion of pronator quadratus (sometimes from coronoid process of ulna).	Into base of terminal phalanx of thumb.	Flexor of thumb.	Anterior interosseous nerve (median).
Pronator quadratus. . .	Anterior lower fourth of ulna.	Anterior lower fourth of radius.	Pronator of hand.	Anterior interosseous nerve (median).

Abductor pollicis	Ridge of trapezium and annular ligament.	Radial side of base of first phalanx of thumb.	Abducts the thumb.	Median nerve.
Opponens pollicis	Trapezium and annular ligament.	Radial side of metacarpal bone of thumb.	Flexor and adductor of thumb.	Median nerve.
Flexor brevis pollicis	(1) Trapezium and annular ligament; (2) trapezoid, os magnum, base of third metacarpal, sheath of flexor carpi radialis. Palmar surface of third metacarpal.	On both sides of base of first phalanx of thumb.	Flexor of the thumb.	Ulnar nerve (deep branch).
Adductor pollicis	Annular ligament and palmar fascia.	Ulnar side of base of first phalanx of thumb.	Adducts the thumb.	Ulnar nerve (deep branch).
Palmaris brevis	Pisiform bone and tendon of flexor carpi ulnaris. Annular ligament, unciform process. Annular ligament, unciform process.	Integument of ulnar side of hand.	Wrinkles the skin of palm.	Ulnar nerve.
Abductor minimi digiti.		Ulnar side of base of first phalanx.	Abductor of little finger.	Ulnar nerve.
Flexor brevis minimi digiti		Ulnar side of base of first phalanx.	Flexor of little finger.	Ulnar nerve.
Opponens minimi digiti.		Ulnar margin of fifth metacarpal.	Deepens cup of Diogenes.	Ulnar nerve.
Palmar interossei (3)	Second, fourth and fifth metacarpals.	Corresponding first phalanges.	Abductors to median line of middle finger.	Ulnar (deep branch).
Dorsal interossei (4)	Adjacent sides of metacarpals.	First phalanges of fore, middle, and ring fingers.	Adductors; acting together the interossei flex the first phalanges and extend the second and third.	Ulnar (deep branch).

THE MUSCLES OF THE UPPER EXTREMITY.—Continued.

MUSCLE.	ORIGIN.	INSERTION.	FUNCTION.	NERVE SUPPLY.
Supraspinatus	Fascia and supraspinous fossa.	Great tuberosity of humerus.	Abductor and external rotator of arm.	Suprascapular.
Infraspinatus	Fascia and infraspinous fossa.	Great tuberosity of humerus.	External rotator of arm.	Suprascapular.
Teres minor	Axillary border of scapula.	Great tuberosity of humerus.	External rotator of humerus.	Circumflex.
Teres major	Inferior angle of scapula.	With latissimus dorsi into posterior bicipital ridge of humerus.	Adductor and internal rotator.	Subscapular.
Serratus magnus	Nine digitations from eight ribs.	Posterior border of scapula.	Inspiratory muscle.	Long thoracic (fifth, sixth and seventh).
Triceps	(1) Below glenoid cavity; greater tuberosity to upper margin of musculo-spiral groove; (3) humerus from below musculo-spiral groove) almost to trochlear surface.	Olecranon with involucrum into fascia.	Extensor of forearm.	Musculo-spiral.
Subanconeus	Humerus above olecranon fossa.	Posterior ligament.	Tensor of synovial sheath.	Musculo-spiral nerve.
Supinator longus	Supra-condyloid ridge of humerus, and fascia.	Styloid process of radius.	Supinates hand and forearm.	Musculo-spiral.
Extensor carpi radialis longior.	Supra-condyloid ridge of humerus.	Radial side of second metacarpal.	Extensor of wrist and hand.	Musculo-spiral.

Extensor carpi radialis brevis.	Supra-condyloid ridge of humerus and common tendon.	Radial side of third metacarpal.	Extensor of wrist and hand.	Posterior osseous.	inter-
Extensor communis digitorum.	External condyle of humerus, fascia, and intermuscular septum.	Second and third phalanges of the four fingers.	Extensor of four fingers	Posterior osseous.	inter-
Extensor minimi digiti.	External condyle of humerus, septum.	Second and third phalanges of little finger.	Extensor of little finger.	Posterior osseous.	inter-
Extensor carpi ulnaris.	External condyle of humerus, fascia, and posterior border of ulna.	Base of fifth metacarpus.	Extensor of wrist.	Posterior osseous.	inter-
Anconeus.	External condyle of humerus.	Olecranon, posterior surface of ulna.	Extensor of fore arm.	Musculo-spiral.	
Supinator brevis.	External condyle, external lateral ligament, ridge on ulna, and orbicular ligament.	Above posterior and below bicipital tuberosity of radius.	Supinator of forearm.	Posterior osseous.	inter-
Extensor ossis metacarpi pollicis.	Radius, middle third posterior ulna, middle third posterior interosseous membrane.	Base of first metacarpus.	Extensor of thumb.	Posterior osseous.	inter-
Extensor primi interodii pollicis.	Radius below preceding and interosseous membrane.	First phalanx of thumb.	Extensor of first phalanx.	Posterior osseous.	inter-
Extensor secundi interodii pollicis.	Ulna below the extensor metacarpi and interosseous membrane.	Second phalanx of thumb.	Extensor of second phalanx.	Posterior osseous.	inter-
Extensor indicis.	Posterior surface of ulna below preceding metacarp.	Second and third phalanges of index finger.	Extensor of index finger.	Posterior osseous.	inter-

CHAPTER II.

Dissection of the Lower Extremity.

FIRST DAY.

Make an incision and remove the integument as per Diagram III, from areas marked 11 and 12.

Note in the superficial fascia :

Its division into two layers. {

1. The *upper* blending with a similar layer upon the abdomen.
2. The *under* joining the fascia lata below Poupart's ligament and forming the cribriform fascia in the region of the saphenous opening.

Between the two layers trace :

The superficial epigastric artery,	} And their venæ comites.
The superficial external pudic artery,	
The superficial circumflex iliac artery,	
The anastomotica magna artery (at knee),	
The long saphenous vein.	

The cutaneous branches of the external cutaneous nerve, of the middle and internal cutaneous nerves, of the crural branch of the genito-crural nerve, and some fibers from the ilio-inguinal nerve.

Demonstrate carefully the *under layer* where it is attached to the margins of the saphenous opening and pierced by the superficial epigastric artery, the long saphenous vein, and some lymphatic trunks; hence its name, "cribriform fascia."

Study the lymphatic glands surrounding the saphenous opening which receive from the inner side of the leg and dorsum of the foot and (a portion) from the outer side and empty into the deep inguinal glands around the femoral artery and vein, and some of the efferent vessels into the lymphatic gland in the femoral canal.

Dissect away the superficial fascia, working carefully in the region of the saphenous opening, which is just below Poupart's ligament, and to the outer side of the spine of the pubis, to expose the fascia lata or deep fascia of the thigh.

Read in Gray or Morris' "Anatomy" a description of the femoral hernial region.

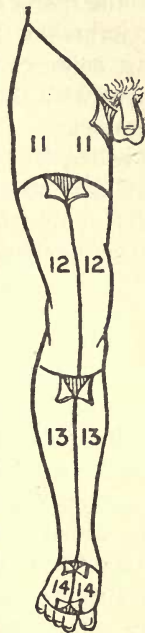

DIAGRAM III.

SECOND DAY.

Follow the outer or sartorial portion (iliac portion) of the fascia lata up to its junction with Poupart's ligament, and note as it passes *over*

the femoral vessels its edge is called the "falciform edge," and forms the outer boundary of the saphenous opening; also, as the inner or pubic portion of the fascia lata goes *behind* the femoral vessels, it forms the inner edge of the saphenous opening, being continuous underneath Poupart's ligament with the iliac fascia and with Gimbernat's ligament. The upper part of the falciform edge is called Hey's or Burns' ligament.

Clean off the cribriform fascia, being careful not to destroy the saphenous opening nor the structures going through it.

THIRD DAY.

Make an incision from the lower margin of the saphenous opening through the fascia lata outwards for about two inches, and a similar one parallel to it just below Poupart's ligament, and carefully reflect the fascia outwards. This will expose, underneath, the femoral sheath formed by the transversalis fascia in front and the iliac fascia behind it, both blending at the lower margin of the saphenous opening, being adherent there to its edge and to the sheath of the femoral vessels.

Make three vertical incisions to show you that two vertical septa divide the sheath into three compartments occupied from without inwards by (1) the femoral artery, (2) the femoral vein, (3) the smallest of all, by some areolar tissue and a lymphatic gland; the last (3) being the canal in

which a femoral hernia usually descends is called the femoral canal, and is therefore to the inner side of the vein. The saphenous opening is therefore its outlet, strengthened by the cribriform fascia as already described. Pass the finger up the canal and under Poupart's ligament ; it will pass into the abdominal cavity through the so-called upper opening of the canal, " the *femoral ring*," which is also protected by some areolar tissue and fat derived from the transversalis fascia, denominated the " septum crurale." The canal is only three-quarters of an inch long ; note its boundaries, its relations, and its exact position as described in the larger anatomical treatises.

As the femoral hernia comes down here it must carry all the structures mentioned before it.

Coverings of a femoral hernia from within outwards.	}	Sac or peritoneum. Subperitoneal fat. Septum crurale. Femoral sheath. Cribriform fascia. Superficial fascia. Skin.
---	---	--

Look at Diagram VIII, and study the formation of the femoral ring and sheath with the dissector upon the abdomen.

Review femoral hernia, and study its relations to the blood vessels, to the surrounding structures, and to the inguinal hernias. How would you tell a femoral from an inguinal hernia ?

FOURTH DAY.

Look for the external cutaneous nerve piercing the fascia lata about three or four inches below Poupart's ligament, and dividing into anterior and posterior branches.

Cut the saphenous vein off and turn it downwards.

Make a vertical incision in the fascia lata from the middle of Poupart's ligament downwards, and turn it in either direction, being careful not to injure the prepatellar bursa.

Note :

The ilio-tibial band and its attachment.

The origin and insertion of the tensor vaginæ femoris muscle.

The septa and their bony attachments separating the quadriceps extensor, on the outside from the flexor group, on the inside from the adductor group. Another septum in turn separates the adductor group from the flexors on their inner side.

Clean up and study the formation of "*Scarpa's triangle*," its boundaries, floor and contents.

Branches of the common femoral artery.	{	Superficial epigastric artery Superficial circumflex iliac artery, Superficial external pudic artery, Deep external pudic ar- tery,	}	Their distribution.
--	---	---	---	------------------------

The common femoral divides into :	Superficial femoral artery,	{ Giving off the anastomotic magna artery in Hunter's canal and becoming the popliteal artery at the opening in the adductor magnus muscle.	}
	Profunda femoris artery,		
			} Their distribution.

Study the relations of the femoral artery and vein below Poupart's ligament, at the apex of "Scarpa's triangle" and in Hunter's canal.

Study the relation of the superficial to the profunda femoris artery.

The anterior crural nerve.	Anterior trunk.	{ Middle cutaneous nerve. Internal cutaneous nerve. Long saphenous nerve.	}
	Pos- terior trunk.		

The crural branch of the genito-crural nerve.

The inguinal branch of the ilio-inguinal nerve.

The external cutaneous nerve direct from the lumbar plexus.

FIFTH DAY.

Study the nerve supply, and the origin and insertion of the sartorius muscle, then cut it in the middle.

Demonstrate the origin and insertion of the quadriceps extensor cruris muscle and each of its sub-divisions.

Study the formation and boundaries of Hunter's canal, noting that it occupies the middle third of the thigh, its relative position in regard to Scarpa's triangle above and the popliteal space below, its contents, and the relation of nerve, artery, and vein. Denude Areas 13 and 14, Diagram III.

Dissect the venous arch upon the dorsum of the foot, and follow the long saphenous vein upwards, observing its relation to the inner malleolus, with the nerve of the same name contiguous to it.

Note the differences of the course of the long saphenous nerve in the leg, and in the thigh, with its relations.

The musculo-cutaneous nerve piercing the deep fascia at the lower third of the leg, with its two branches.

Do not overlook the external, or short saphenous vein and nerve in their relation to the external malleolus.

Clean off the superficial fascia.

Note the ilio-tibial band inserted on the outer side, and the insertion of the sartorius muscle on the inner side, with its expansion into the deep fascia.

Dissect the four cutaneous nerves supplying the dorsum of the foot.

Remove the deep fascia from the leg, leaving the external annular ligament and the two peroneal tendons ; and the anterior annular ligament, with its bony attachments and three compartments, binding down :

The tibialis and anticus muscle, The extensor proprius pollicis muscle, The extensor longus digitorum muscle, The peroneus tertius muscle,	}	Their origin and insertion.
---	---	-----------------------------------

Now having denuded the whole of the anterior portion of the thigh and leg, and followed up the superficial branches of the nerves and arteries, return to the inner side of the thigh and dissect out the pectineus muscle, the gracilis muscle, the insertion of the ilio-psoas muscle ; in connection with the dissector upon the abdomen, later on look up its origin also,—and then work out the adductor longus, the adductor brevis, and the adductor magnus muscles from origin to insertion.

SIXTH DAY.

Note that the adductor magnus is perhaps the most important muscle of the group.

What structures lay upon it anteriorly ? What posteriorly ? What vessels pierce it ? Where does the femoral become popliteal ? Look out for the internal or long saphenous vein, and the superficial branches of the anastomotica magna at the insertion of the sartorius muscle, and follow out the distribution of the artery. Study the

obturator nerve, its articular and muscular filaments. Why is there pain at the knee in some cases of coxalgia?

Review in detail: Scarpa's triangle, its boundaries, floor, and contents, with their relations; femoral hernia, its coverings, their method of formation, and its relations; Hunter's canal, its position on the thigh, formation, where it begins and ends, its contents and relations.

Lift the adductor group sufficiently to study the obturator externus muscle, particularly with reference to its origin, and do not neglect the obturator membrane, with the foramen above and to the inner side, transmitting certain vessels and nerves, and trace so far as you can at present the sub-divisions of the obturator artery.

SEVENTH DAY.

Dissect out the prepatellar bursa, and the patellar arterial anastomosis; also study the group of muscles inserted together upon the inner and anterior surface of the tibia, particularly the expansion of the sartorius muscle as it spreads to its insertion. Notice that the deep fascia by its septa separates the peroneal group of muscles from the extensors in front, and from the flexors, behind, being attached to the tibial ridge (shin) very firmly. A later dissection will show that the muscles of the calf are further sub-divided by an intermuscular septum into two sets, thus making four distinct groups in the leg.

Dissect out :

The anterior tibial artery (a branch of popliteal reaching the front of the leg by passing between the bones).	}	Recurrent tibial. Muscular. Nutrient. External malleolar. Internal malleolar.	}	Their distribution.
--	---	---	---	---------------------

Anterior tibial nerve (a branch of the external popliteal or peroneal nerve which reaches the front of the leg by passing around the head of the fibula and piercing the peroneus longus muscle).	}	Muscular branches. Anterior tibial (branches to toes). Musculo-cutaneous branches to toes).
---	---	---

Long saphenous nerve (its origin) and distribution to dorsum.

Short saphenous nerve (its origin), and distribution to dorsum. Follow the four extensor muscles to their insertion.

EIGHTH DAY.

The eighth day is assigned to the dissector upon the abdomen for working out the perineum. As this will interfere somewhat with the dissection upon the leg, the time may be profitably occupied in reviewing the work already done, especially as the student upon the abdomen will upon the ninth day make a lateral section to the

right side of the symphysis pubis, which will, of necessity, destroy somewhat the part of the dissection of the leg thus sawn through.

NINTH DAY.

Clean off and dissect the origin and insertion of the extensor brevis digitorum muscle, noting particularly the attachment and relations of its innermost tendon.

Follow out the ramifications and branches of the dorsalis pedis artery ; not neglecting the communicating branch to the plantar arch.

Dorsalis pedis artery.	{	Tarsal. Metatarsal. Communicating. Dorsalis hallucis artery.	{	Three dorsal interossei arteries.
------------------------	---	---	---	-----------------------------------

Clean off the peroneal group of muscles and run the peroneus brevis and the peroneus tertius from origin to insertion ; leaving the peroneus longus muscle for a more convenient season.

TENTH DAY.

Elevate the foot upon a wooden block.

Remove the skin from the sole of the foot according to lines of incision as marked in Area 18, Diagram IV, page 53.

Note the granular fat in the superficial fascia, and compare it with the superficial fascia in the palm of the hand. Consider the cutaneous nerves from the external and internal plantar

nerves. Remove the granular, fatty superficial fascia to expose the *deep fascia*.

Note :

Its bony attachments.

Its sub-divisions at the heads of the metatarsal bones, where it is attached to the sheaths of the flexor tendons, and the relative positions of the vessels and nerves.

Its three vertical septa dividing the sole of the foot into the three compartments (compare with the palm of the hand).

Its continuation with the deep fascia upon the dorsal surface.

Second-year students will study the effect of this fascia upon the functions of the foot, and the various deformities produced by its contraction.

Remove the deep plantar fascia.

ELEVENTH DAY.

Study the origin and insertion of the first layer of muscles, being careful not to injure important structures lying deeper.

First layer of muscles.	}	Abductor pollicis. Abductor minimi digiti. Flexor brevis digitorum.	}	Their origin and insertion.
-------------------------	---	---	---	-----------------------------

Cut these in their middle and reflect them either way to expose :

The external and internal plantar arteries and nerves, and

The second layer of muscles :	{ { { {	The tendons of the flexor longus digitorum muscle.	} Their origin and insertion.
		The accessorius muscle, with its two heads.	
		The four lumbricales muscles.	
		The tendon of the flexor longus pollicis.	

Note how, as in the hand, the flexores longus et brevis digitorum are perforans et perforatus, and have the ligamenta vaginalia, ligamenta brevia, and the vincula vasculosa.

TWELFTH DAY.

Clean off the posterior tibial artery behind the inner malleolus and trace its division into the external and internal plantar arteries.

Follow up the internal plantar artery to its ultimate ending at the inner side of the great toe.

Notice the external plantar artery as it goes to form the plantar arch, and see where and how it crosses the sole of the foot. Between what layers?

Follow out the posterior tibial nerve and its sub-divisions from the internal malleolus so far as the present dissection will allow.

Divide the second layer of muscles about midway in the foot, and reflect it in either direction to study :

The third layer of muscles.	<table border="0"> <tr> <td style="font-size: 4em; vertical-align: middle;">{</td> <td style="padding-left: 10px;"> <ol style="list-style-type: none"> 1. Flexor brevis pollicis, 2. Adductor pollicis, 3. Flexor brevis minimi digiti, 4. Transversus pedis. </td> <td style="font-size: 4em; vertical-align: middle;">}</td> <td style="padding-left: 10px; vertical-align: middle;"> Their relation, position, and origin and insertion (not too mi- nutely). </td> </tr> </table>	{	<ol style="list-style-type: none"> 1. Flexor brevis pollicis, 2. Adductor pollicis, 3. Flexor brevis minimi digiti, 4. Transversus pedis. 	}	Their relation, position, and origin and insertion (not too mi- nutely).
{	<ol style="list-style-type: none"> 1. Flexor brevis pollicis, 2. Adductor pollicis, 3. Flexor brevis minimi digiti, 4. Transversus pedis. 	}	Their relation, position, and origin and insertion (not too mi- nutely).		

Cut the flexor brevis and adductor pollicis near their origin and turn them down to complete the study of :

The external plan- tar artery in con- junction with the communicating branch of the dor- salis pedis artery, forming	<table border="0"> <tr> <td style="font-size: 4em; vertical-align: middle;">}</td> <td style="padding-left: 10px; vertical-align: middle;">The plantar arch :</td> <td style="font-size: 4em; vertical-align: middle;">{</td> <td style="padding-left: 10px; vertical-align: middle;"> Three posterior per- forating arteries. Four digital ar- teries. Anterior perforating arteries. </td> </tr> </table>	}	The plantar arch :	{	Three posterior per- forating arteries. Four digital ar- teries. Anterior perforating arteries.
}	The plantar arch :	{	Three posterior per- forating arteries. Four digital ar- teries. Anterior perforating arteries.		

The communicating branch of the dorsalis pedis, after completing the arch, gives off its terminal digital branches to supply the inner side of the great toe and the adjacent sides of the great and second toes.

THIRTEENTH DAY.

Follow the posterior tibial nerve from the internal malleolus to its division into the external and internal plantar nerves, and then to their ultimate distribution.

External plantar nerve.	}	Superficial branch supplies :	Cutaneous branches to the sole, To the flexor brevis minimi digiti, To the interosseous muscles in the fourth space, Digital branches to the outer side of the little toe and contiguous sides of fourth and fifth toes.
		Deep branch accompanies the artery beneath the adductor pollicis and supplies :	The nerves to the two outer lumbricales, Transversus pedis and to all the dorsal and plantar interosseous muscles excepting to those of the fourth interosseous space.
Internal plantar nerve supplies :	}	Cutaneous branches to sole, Abductor pollicis and flexor brevis digitorum muscles, Flexor brevis pollicis muscle, First and second lumbricales, Cutaneous surfaces of three and a half toes from within outwards.	

There is often a connecting twig between the external and internal plantar nerves, through the intervention of which the final distribution varies somewhat.

FOURTEENTH DAY.

Work out the origin and insertion of the peroneus longus muscle, and of the dorsal and plantar interossei muscles, and review the thigh, leg and foot.

FIFTEENTH DAY.

Working in conjunction with the dissectors upon the upper extremity, turn the body into the prone position.

Make an incision along the crest of the ilium, and another in the median line from the base of the sacrum to the tip of the coccyx, and a transverse cut just below the gluteal fold, and denude Area 15, Diagram IV.

In the superficial fascia, look for the cutaneous branches of the last dorsal nerve and of the ilio-hypogastric nerves, and for a few branches from the posterior divisions of the external cutaneous nerves, and from the lower lumbar, add upper sacral nerves, and some cutaneous branches of the small sciatic nerve. The prominence of the buttock depends upon the amount of adipose tissue present.

Clean off the superficial fascia to expose the deep fascia (fascia lata), with its osseous attachments, which below shuts in the popliteal space,

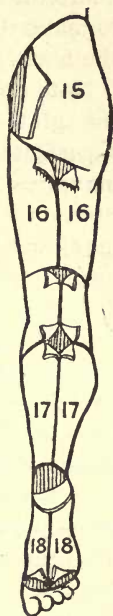


DIAGRAM IV.

and note how the fascia may be made tense or lax by flexion or extension of the leg.

Clean the deep fascia off from the gluteus maximus muscle, flexing and inverting the thigh to make the tissues tense, and cutting parallel to the fibers of the muscle.

Note that the fascia lata anteriorly divides over the gluteus medius muscle, one portion going superficial, and the other deeper than the gluteus maximus muscle, which is thus ensheathed. Study the origin and insertion of the gluteus maximus, and the gluteal fold. Cut this muscle away from its origin, and turn it outwards and downwards, remembering that its anterior margin overlaps the *medius*.

It is a work of some difficulty to separate these two muscles. The gluteus medius arises from the ilium between the superior and middle curved lines and the part of the crest between them, and from the deep fascia ; the gluteus maximus from the superior curved line of the ilium and the crest, from the sacrum and coccyx, and from the fascia ; running obliquely downwards and outwards to the trochanter, a cellular interval separating the two muscles. The fascia lata covers the anterior two-thirds of the medius, its posterior third being concealed by the maximus. If the deep fascia is lifted from the maximus until its extreme external edge is reached, the muscle can then be cleaned throughout its extent without disturbing the fibers of the gluteus medius.

Structures beneath the gluteus maximus muscle.

- Leaflet of deep fascia,
- The gluteus medius muscle,
- The superficial branch of the gluteal artery,
- The piriformis muscle,
- The great sciatic nerve,
- The small sciatic nerve,
- The sciatic vessels,
- The pudic vessels and nerve,
- The obturator internus muscle, and nerve to same,
- The two gemelli muscles,
- A small portion of the insertion of the obturator externus,
- The quadratus femoris muscle,
- The great sacro-sciatic ligament,
- The great trochanter and muscles attached,
- Three bursæ:
 - One between the maximus and great trochanter,
 - One between the maximus and tuber ischii,
 - One between the maximus and the fascia over the vastus internus.

Identify each of these.

SIXTEENTH DAY.

Denude the Area 16, Diagram IV, being careful not to destroy the communicantes peronei et poplitei forming the short saphenous nerve, nor the short saphenous vein.

Note the small sciatic nerve coming out under the border of the gluteus maximus muscle, and its cutaneous distribution from above downwards as far as the middle of the leg. Also, trace the inferior pudendal branch below the tuber ischii into the superficial fascia of the perineum, to be finally distributed to the skin of the perineum and scrotum.

The muscular branches of this nerve supply the gluteus maximus.

Study the origin and insertion of the gluteus medius, and notice a small artery coming up between it and the pyriformis; and another artery running downwards between the gluteus maximus and the pyriformis muscles.

With the handle of the scalpel, separate the medius from the minimus beneath it, using the two terminal gluteal vessels as a guide, and cut the gluteus medius about one and a half inches from its origin and reflect its two portions.

Dissect the insertion of the pyriformis muscle, following it up as far as the great sacro-sciatic notch.

Learn the structures going through the greater and lesser sacro-sciatic openings, and those appearing above and below the pyriformis muscle.

Trace the pubic vessels and nerves as they emerge from the great sacro-sciatic notch, round the spine of the ischium into the lesser sacro-sciatic notch.

Dissect out :

The sciatic artery, $\left\{ \begin{array}{l} \text{A coccygeal branch.} \\ \text{Comes nervi ischiadici.} \\ \text{Anastomodic branch.} \end{array} \right.$

Clean off the insertion of the obturator internus muscle and the origin and insertion of the two gemelli.

SEVENTEENTH DAY.

Study the part which has been particularized as the popliteal space, and clean off the deep fascia marked 16, Diagram IV, and follow the great sciatic nerve to its bifurcation, preserving the *crucial* anastomosis (*q. v.*).

Study the origin and insertion of the gluteus minimus muscle, and the two branches of the superior gluteal nerve supplying a branch to the tensor vaginae femoris muscle, also the origin and insertion of the quadratus femoris muscle.

Dissect out the obturator externus muscle from origin to insertion. This is one of the most difficult muscles of the body to comprehend (if feasible, in conjunction with the dissectors on the abdomen, follow the pyriformis and obturator internus muscles to their origin). The dissector upon the right leg will have to study these with his comrade upon the left side in consequence of the section of the pelvis to the right side of the symphysis.

Outline the greater and lesser sciatic ligaments and the boundaries of the greater and lesser sciatic notches.

Note the four perforating arteries, and in this connection review the structures anterior to and posterior to the adductor magnus muscle.

Study the origin and insertion of the biceps, semimembranosus and semitendinosus muscles.

EIGHTEENTH DAY.

Denude the areas marked 17, Diagram IV, and follow the external saphenous nerve in the superficial fascia, noting its formation by the union of the communicans peronei and of the communicans poplitei branches, and also the external saphenous vein.

Clear off the loose fascia and fat and lymphatics from the popliteal space and back of the leg. Remember there are no lymphatic glands below the popliteal space.

Cut the deep fascia covering the calf in the same lines as the superficial incisions, and particularly trace the intermuscular septum therefrom, separating (imperfectly) the superficial from the deep set of muscles, preserving the internal lateral ligament, and recognizing that this completes the four separate muscular compartments in the leg. The compartments thus studied furnish a key not only to the groups of muscles, but also to their nerve supply, and the limitations of pus formations.

Study the origin by two heads and the insertion of the gastrocnemius.

Cut the two heads and reflect downwards to reveal the origin of the plantaris and soleus muscles.

Note the plantaris muscle, its origin and insertion and its course. It has sometimes been mistaken for a nerve.

Dissect out the origin and insertion of the soleus muscle, particularly that portion attached to the oblique line of the tibia in relation to the ligation of the posterior tibial artery.

Divide the plantaris and cut the soleus near its origin, noticing the tendinous expansion of the fascia underneath it which protects the vessels, and also the intermuscular septum already referred to.

Notice where the femoral artery comes through the adductor magnus muscle to form the popliteal artery.

Study the course of the great sciatic nerve from where it emerges beneath the gluteus maximus muscle, its bony references, its course from the back of the thigh, what muscle it passes anterior to, and where it divides into the external and internal popliteal nerve.

Dissect out the popliteal artery, its four articular, azygos, and sural branches and their ultimate distribution.

Follow the external popliteal nerve as it runs under cover of the biceps and trace it outwards around the fibula and through the peroneus longus muscle to its division into the musculocutaneous and anterior tibial, as already seen.

It gives off the communicans peronei branch in its course.

NINETEENTH DAY.

Study thoroughly the boundaries and contents of the popliteal space, with their relations. Note the fascial covering of the popliteus muscle, which is an expansion of the tendinous insertion of the semimembranosus ; also the origin and insertion of the popliteus muscle.

Note relatively :

The point of bifurcation of the great sciatic nerve.

The point of bifurcation of the popliteal artery.

The course of the external popliteal nerve.

The course of the internal popliteal nerve.

How the external popliteal nerve gets to the front of the leg.

How the anterior tibial artery gets to the front of the leg.

Study the floor of the popliteal space.

Lift the incomplete intermuscular septum in the calf to expose the deep layer of muscles. The flexor longus pollicis, the outermost, and the smaller, arising from the smaller bone, the fibula.

The flexor longus digitorum muscle, the innermost, and the larger, arising from the larger bone, the tibia.

The tibialis posticus muscle, intermediate in position, arising from both tibia and fibula.

Study the origin and insertion of each in

connection with the dissection of the foot, already completed.

Dissect out the course and branches of the posterior tibial artery and nerve, and in particular their relations at the internal malleolus.

Branches of the small sciatic nerve.	{	Muscular. { Inferior gluteal to the gluteus maximus muscle. Ascending cutaneous to skin over the same muscle. Descending cutaneous to skin of thigh. Inferior pudendal to perineum and scrotum. Terminal cutaneous to integument as far down as middle of calf.
Branches of the great sciatic nerve.	{	Articular to hip. Muscular to flexors and to adductor magnus. Internal popliteal nerve (afterwards the posterior tibial). External popliteal nerve.
Branches of the popliteal artery.	{	Muscular. { Superior. { Inferior or sural. Cutaneous. Superior articular. { External. { Internal. Inferior articular. { External. { Internal. Azygos articular.

Branches of the anterior tibial artery.	{	Recurrent tibial (sometimes two).
		Muscular.
		Internal malleolar.
		External malleolar.
Posterior tibial artery.	{	Peroneal (anterior peroneal).
		Muscular.
		Nutrient.
		Communicating.
		Internal calcanean.
Posterior tibial nerve.	{	Muscular.
		Plantar cutaneous.
		External plantar nerve.
		Internal plantar nerve.
Relations of structures behind the internal malleolus.	{	Tibialis posticus.
		Flexor longus digitorum.
		Vein.
		Posterior tibial artery.
		Vein.
		Posterior tibial nerve.
		Flexor longus pollicis.

Work out the *seven* interosseous muscles, noting that they are grouped, as regards function, around the second toe.

TWENTIETH DAY.

Make a diagram of the vascular and nervous supply of the thigh, leg and foot, and review the whole dissection.

TWENTY-FIRST DAY.

The second-year student will also master the nerve supply of the various muscles and arterial anastomoses: (1) about the thigh; (2) in the popliteal space; (3) at the ankle; (4) in the foot, and will also work out the articulation, particularly of the hip, knee and ankle.

TWENTY-SECOND TO THE TWENTY-EIGHTH DAY.

Review the whole dissection of the lower extremity.

TABLE II.—THE MUSCLES OF THE LOWER EXTREMITY.

MUSCLE.	ORIGIN.	INSERTION.	FUNCTION.	NERVE SUPPLY.
Quadriceps femoris. (1) Vastus externus; (2) Vastus internus; (3) Crureus; (4) Rectus femoris.	(1) Outer side of femur, linea aspera and septum; (2) inner side of femur, linea aspera and septum; (3) anterior surface of femur, (4) anterior inferior spine of ilium above acetabulum. Anterior surface of femur.	Patella.	Extensor of leg.	Anterior crural.
Subcrureus	Anterior surface of femur.	Synovial pouch of knee. Fascia lata.	Tensor of synovial pouch. Tensor of fascia lata.	Anterior crural. Superior gluteal.
Tensor vaginæ femoris.	Outer lip of crest of ilium.	Internal and anterior surface of tibia.	The tailor muscle.	Anterior crural nerve.
Sartorius	Anterior superior spinous process of the ilium.	Ilio-pectineal eminence. Lesser trochanter of femur.	Tensor of iliac fascia. Flexor and external rotator of femur.	Lumbar. Lumbar.
Psoas parvus	Last dorsal and first lumbar vertebræ.	Lesser trochanter and line leading to linea aspera.	Flexor and external rotator of femur.	Anterior crural.
Psoas magnus	Last dorsal and five lumbar vertebræ.	I, line leading from lesser trochanter to the linea aspera.	Flexor and adductor of thigh.	Anterior crural obturator.
Iliacus internus	Iliac fossa, ilio-lumbar ligament and base of sacrum, anterior superior and inferior spinous processes of ilium.	Internal and anterior surface of tibia.	Flexor and adductor of thigh.	Obturator.
Pectineus	Ilio-pectineal line and bone in front of it.			
Gracilis	Rami of pubes and ischium (three inches).			

Adductor longus	Pubes below crest.	Linea aspera of femur.	Adductor and flexor of thigh.	Obturator.
Adductor brevis	Descending ramus of pubes.	Linea aspera.	Adductor and flexor of thigh.	Obturator.
Adductor magnus	Ramus of pubes, ramus and tuberosity of the ischium.	Linea aspera from great trochanter to adductor tubercle.	Adductor of thigh.	Obturator and great sciatic.
Obturator externus	Body and ramus of pubes, ramus of ischium, and obturator membrane.	Digital fossa of femur.	External rotator of femur.	Obturator.
Tibialis anticus	Outer tuberosity and shaft of tibia and fascia.	Internal cuneiform base of first metatarsal.	Flexor of tarsus.	Anterior tibial.
Extensor longus digitorum.	Outer tuberosity of tibia, upper three-fourths shaft of fibula, interosseous membrane and fascia.	Second and third phalanges of four lesser toes.	Flexor of the tarsus, extensor of the toes.	Anterior tibial.
Extensor proprius pollicis.	Middle two-fourths of anterior surface of tibia, and interosseous membrane.	Base of terminal phalanx of great toe.	Extensor of great toe.	Anterior tibial.
Peroneus tertius	Lower fourth of anterior surface of fibula, and interosseous membrane.	Dorsal surface of fifth metatarsus.	Flexor of foot.	Anterior tibial nerve.
Peroneus longus	Head and shaft of fibula and fascia.	Base of first metatarsus.	Extends foot upon leg.	Musculo-cutaneous (external popliteal).
Peroneus brevis	Lower half of shaft of fibula, and from fascia.	Dorsal surface of fifth metatarsus.	Extends foot upon leg.	Musculo-cutaneous.
Extensor brevis digitorum.	Os calcis, cuboid, astragalus and annular ligament.	First phalanx of great toe, extensor tendons of second, third and fourth toes.	Extends the phalanges of the toes.	Anterior tibial.

THE MUSCLES OF THE LOWER EXTREMITY.—Continued.

MUSCLE.	ORIGIN.	INSERTION.	FUNCTION.	NERVE SUPPLY.
Gluteus maximus.	Ilium between crest and superior curved line, sacrum, coccyx and sacro-sciatic notch.	Line leading from great trochanter to linea aspera and fascia lata.	Extensor and external rotator of femur.	Inferior gluteal (small sciatic).
Gluteus medius.	Between superior and middle curved lines and outer lip of crest of ilium.	Outer surface of great trochanter.	Extensor and rotator of thigh.	Superior gluteal.
Gluteus minimus.	Between middle and inferior curved lines of ilium and great sciatic notch.	Anterior border of great trochanter.	Extensor and rotator of thigh	Superior gluteal.
Pyramidalis	Sacrum between first and fourth foramina, and from great sacro-sciatic notch.	Upper border of great trochanter.	External rotator of thigh.	Sacral plexus.
Gemellus superior	Spine of ischium.	Upper border of great trochanter.	External rotator of thigh.	Sacral plexus.
Obturator internus	Rami of pubes and ischium, border of ischium itself and obturator membrane.	Upper border of great trochanter.	External rotator of thigh.	Sacral plexus.
Gemellus inferior.	Tuberosity of ischium.	Upper border of great trochanter.	External rotator of thigh.	Sacral plexus.
Quadratus femoris	Outer border of tuberosity of ischium.	Linea quadrati.	External rotator of thigh.	Sacral plexus.
Biceps femoris	(1) Tuber ischii; (2) linea aspera.	Outer side of head of fibula.	Flexor of leg on thigh.	Great sciatic.
Semitendinosus.	Tuber ischii with biceps.	Internal anterior surface of tibia.	Flexor of leg on thigh.	Great sciatic.

Seminembranosus	Tuber ischii above and out- side of biceps.	Posterior to inner tuberosity of tibia, posterior ligament of knee, etc. Tendo Achillis.	Flexor of leg on thigh.	Great sciatic.
Gastrocnemius	Above external and internal condyles of femur.	Os calcis.	Flexor of leg.	Internal popliteal.
Plantaris	Above external condyle of femur.	Tendo Achillis.	Tensor of plantar fascia.	Internal popliteal.
Soleus	Head and surface of fibula, oblique line and internal border of tibia.		Flexor of leg.	Internal popliteal.
Popliteus	External condyle and pos- terior ligament.	Superior fifth posterior bor- der of tibia, above oblique line.	Flexor of leg.	Internal popliteal.
Flexor longus pollicis.	Internal surface shaft of fibula.	Base of last pha- lanx of great toe.	Flexor of pha- lanx.	Posterior tibial nerve.
Flexor longus digi- torum.	Posterior surface of tibia, be- low oblique line.	Bases of terminal phalanges of four toes.	Flexors of pha- langes.	Posterior tibial.
Tibialis posticus	Posterior surface of tibia, fibula and interosseous membrane.	Tuberosity of scaphoid and internal cunei- form.	Extensor of tar- sus upon leg.	Posterior tibial.
Abductor pollicis	Inner tuberosity of os calcis, internal annular ligament, plantar fascia and septum.	Base of first phalanx of great toe.	Abductor of great toe.	Internal plantar.
Flexor brevis digi- torum.	Inner tuberosity of os calcis, plantar fascia and septum.	Both sides of base of first phalan- ges.	Flexor of pha- langes.	Internal plantar.
Abductor minimi digiti.	Outer tuberosity of os calcis and fascia.	First phalanx of little toe.	Abductor of little toe.	External plantar.

THE MUSCLES OF THE LOWER EXTREMITY.—Continued.

MUSCLE.	ORIGIN.	INSERTION.	FUNCTION.	NERVE SUPPLY.
Flexor accessorius . . .	Os calcis.	Tendons of flexor longus digitorum.	Draws tendons directly backwards.	External plantar.
Lumbricales (4)	Tendons of flexor digitorum.	Inner side of phalanges of four lesser toes.	Flex the proximal joints and extend the other joints of the toes.	Internal and external plantar.
Flexor brevis pollicis.	Cuboid bone, external cuneiform tendon of tibialis posticus.	Both sides of base of first phalanx of great toe.	Flexor of great toe.	Internal plantar nerve.
Adductor pollicis	Tarsal extremity of second, third and fourth metatarsus and sheath of peroneus longus.	Base of first phalanx of great toe.	Adductor of great toe.	External plantar.
Flexor brevis minimi digiti.	Base of metatarsus of little toe.	Base of first phalanx.	Flexor of little toe.	External plantar.
Transversus pedis	Fifth metatarsal, transverse metatarsal ligament.	First phalanx of great toe.	Adductor of great toe.	External plantar.
Plantar interossei (3) . .	Third, fourth and fifth metatarsals.	Corresponding first phalanges.	Adductors, flexors of first phalanges and extensors of second.	External plantar (deep branch), fourth by superficial branch.
Dorsal interossei (4) . .	Adjacent sides of metatarsals	First phalanx, second toe both sides; third and fourth toes outer side of the first phalanx.	Abductors, flexors of first phalanges and extensors of second.	External plantar (deep branch), fourth by superficial branch.

CHAPTER III.

The Dissection of the Head and Neck.

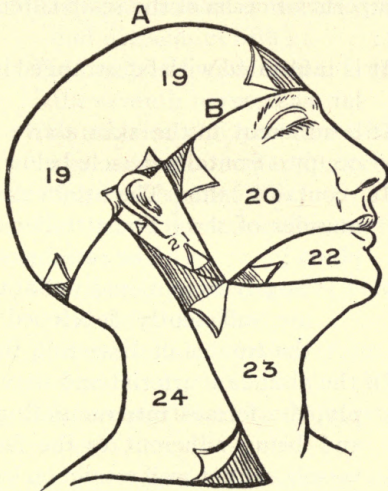


DIAGRAM V.

FIRST DAY.

- The five layers of the scalp. {
1. The skin.
 2. The superficial fascia.
 3. The occipito-frontalis muscle.
 4. The subaponeurotic areolar tissue.
 5. Pericranium.

Make the first incision, *A*, in the median line, from the glabella to the inion, and a second, *B*, horizontally above the eyebrows and ears,

between the same points, and denude the areas marked 19, Diagram V, in the directions indicated, being careful not to remove the second layer ; draw firmly upon the skin, the roots of the hair being a valuable guide.

The superficial fascia of the scalp is remarkable because :

1. It is infiltrated with fat arranged in granular masses.
2. It is adherent to the skin above and the occipito-frontalis muscle below.
3. It contains the { The attollens aurem,
muscles of the { The attrahens aurem,
pinna : { The retrahens aurem.

It is only exceptionally that the latter are sufficiently developed to repay the trouble of dissecting them.

4. Of the abundant arterial and nervous supply, the former interosculating freely, and being adherent to the fascia, the vessels cannot well retract on being cut, hence the free hemorrhage and the difficulty in applying ligatures.

Arteries in
the superficial fascia.

The superficial branches of the :
Supraorbital (from ophthalmic),
Frontal (from ophthalmic),
Anterior temporal (from temporal),
Posterior temporal (from temporal),
Posterior auricular (from external carotid),
Occipital (from external carotid).

Nerves in
the superficial fascia.

- The superficial branches of:
- The supratrochlear nerve (from first division of fifth),
 - The supraorbital nerve (from first division of fifth),
 - The temporo-malar nerves (from second division of fifth),
 - The temporal and malar branches of the seventh nerve,
 - The anterior and posterior divisions of the auriculo-temporal nerve (from third division of fifth),
 - The posterior auricular nerve (from seventh),
 - The auricularis magnus (from second and third cervical),
 - The occipitalis major (from second cervical),
 - The occipitalis minor (from second cervical).

Dissect out all of these structures in the superficial fascia of the scalp.

SECOND DAY.

Clean off the superficial fascia, leaving the main nervous and vascular trunks as far as possible, to expose the occipito-frontalis muscle, with its two muscular bellies and intervening aponeurosis.

Make an incision transversely from auricle to auricle to reveal the subaponeurotic areolar

tissue and pericranium. Note that the first three layers of the scalp are firmly bound together, and fully appreciate that the fourth layer, the subaponeurotic areolar layer, is, in some respects, the most important surgically, especially as regards sepsis. Study in "Gray" or "Morris" the venous connections with the diploë.

Pack the mouth with strips of muslin and sew the lips together, and also the eyelids. Prolong the incision in the median line from the glabella to the upper lip, and then transversely outwards to the angle of the jaw, and upwards in front of the auricle, and denude Areas 20 and 21, Diagram V. Draw well on the skin and remove carefully, keeping the edge of the scalpel directed towards the integument. Remember that the muscles of expression are adherent to the skin. Note the supraorbital and frontal veins form the angular, which is the commencement of the facial vein. The amount of subcutaneous fat varies greatly with the individual, and may best be removed from the delicate muscles beneath, either with the scissors curved on the flat, or by scraping with the edge of the scalpel in the direction of the particular muscular fibers.

Dissect out the following muscles :

Orbicularis palpebrarum (two portions),	} Their origin and insertion.
Corrugator supercillii,	
Pyramidalis nasi,	

Notice the areolar tissue in the upper lid, the favorite seat of black eye.

Study the canthi, the fissura palpebrarum, the lacus lachrymalis, the puncta, the tendo oculi, the canaliculi, and insert a probe into the lachrymal sac and duct. Notice the position of the lachrymal gland. Dissect out :

The layers of the upper lid.	{	Skin,
		Areolar tissue (orbicularis palpebrarum),
		Palpebral ligament,
		Tendon of levator palpebræ superioris,
		Tarsal cartilage,
		Meibomian glands, Conjunctiva.

Dissect the anterior portion of the occipitofrontalis muscle, and note that it blends with the three muscles mentioned, and expose the supra-orbital foramen, or notch, with the artery, vein, and nerve of the same name passing through it, and just above it a small aperture in the upper part of the notch which transmits a vein from the diploë to join the ophthalmic vein.

THIRD DAY.

Reflect the posterior part of the occipitofrontalis to expose the *temporal fascia*; study its origin.

Note:

Its two layers attached to the zygoma. Between its layers some fat and a small branch of the temporal artery and the

temporal branch of the orbital nerve (second branch of the fifth). The temporal muscle is attached to its under surface.

Remove the temporal fascia to expose the *origin* of the temporal muscle, which study, and detach; and then proceed to remove the brain.

Saw through the outer table of the skull on a circumferential line about an inch above the orbit in front, and about the same distance above the great occipital protuberance behind, breaking the inner table with chisel and mallet. Look out for the meningeal arteries running between the skull and the membranes, especially the middle meningeal, a branch of internal maxillary, and its two main sub-divisions. Call on one of the table demonstrators to assist you in the removal of the brain and membranes. Make an antero-posterior incision with the scissors through the dura on either side of the superior longitudinal sinus. If the brain is too soft for preservation, scoop it out with the fingers, sponge out the interior of the membranes, and study the different portions of the dura, its sub-divisions and sinuses as described in "Gray" or "Morris." If the brain proves to be in good condition, make a transverse incision through the membranes in the region of the vertex, cut the falx cerebri about half an inch posterior to the *crista galli* and strip the membranes away from the cerebrum; lift the anterior lobes so that you can see what you are doing, and cut first the optic nerves, then the other

nerves at the base, removing the pituitary body from the sella turcica, if possible, freeing the anterior and middle lobes; incise the tentorial attachment to the petrous portion of the temporal bone so that the cerebellum can be lifted, then press the knife into the foramen magnum deeply to cut the cord, lift the whole encephalon and free the tentorium from the transverse portion of the crucial ridge. After removal, place the brain in a fifty per cent. solution of chloride of zinc for ten days, and at the end of that time, after immersing it for a few moments in water to rid it of the excess of acid, put it into strong alcohol.

Replace the remains of the meninges for investigation later, with the fossæ and foramina at the base of the skull, the orbit, and the eyeball.

Denude Area 22, Diagram V. Scrape away the fat upon the face, noticing particularly the "buccal pad."

FOURTH DAY.

Dissect the muscles of expression without destroying vessels or nerves.

The superficial layer of the muscles of expression from the median line outwards.	}	Levator labii superioris alæque nasi. Levator labii superioris. Zygomaticus major. Zygomaticus minor. Risorius (from platysma).
---	---	---

Note that all of these converge to the orbicularis oris muscle, which also clean off, and study its origin and insertion. Lift the levator labii superioris to expose the infraorbital foramen, and the vessels and nerves of the same name and the one muscle of the *deep layer*, the levator anguli oris, which is beneath the levator labii superioris, and between the two the infraorbital vessels and nerves pass and subdivide.

Below the mouth dissect out :

Levator labii inferioris muscle,	} Their origin and insertion.
The depressor labii inferioris muscle,	
The depressor anguli oris mus- cle.	

And note the position of the mental foramen and the emerging structures.

FIFTH DAY.

Study the formation of the external jugular vein and then clean off the superficial fascia to expose the deep fascias covering in the parotid and masseteric regions, remembering that they are extensions of the first layer of the deep cervical fascia (*q. v.*) ; remove them, carefully avoiding the important structures beneath, to expose the masseter muscle, its origin and insertion, having the socia parotidis upon it and the main portion of the parotid gland overlapping it.

Structures in and about the parotid gland to be dissected out.

Stenson's duct, its course and where it finally ends.

Just above Stenson's duct, the transverse facial artery.

Just below Stenson's duct, a large branch of the seventh nerve.

The facial nerve, its pes anserinus, and its main sub-divisions.

The temporo-maxillary vein.

The termination of the external carotid artery, dividing into temporal and maxillary branches.

The auriculo-temporal nerve (branch of third division of fifth).

The processes of the parotid gland—

To root of styloid process.

To glenoid fossa.

Beneath the lower jaw.

Socia parotidis upon the masseter muscle.

There is no royal road here ; each one of these structures, in turn, must be caught up on the face and traced backwards through the glandular mass carefully.

Dissect out the distribution of the facial nerve upon the face.

Facial nerve upon the face.	{	Temporo-facial.	{	Temporal.
				Malar.
				Infraorbital.
	{	Cervico-facial.	{	Buccal.
				Supramaxillary.
				Inframaxillary.

SIXTH DAY.

Carry the incision from the chin to the sternum, from mid-sternum to the base of the mastoid process and along the clavicle to the acromion, and denote Areas 23 and 24, Diagram V.

Study the superficial fascia of the neck, together with the platysma myoides muscle, its origin and insertion and its prolongation, the risorius; the anterior jugular vein, the external jugular vein, with its accompanying lymph glands, the posterior external jugular vein and

The branches of the (superficial) cervical plexus.	}	Superficialis colli.
		Auricularis magnus.
		Occipitalis minor.
		Acromial.
		Clavicular.
		Sternal.

Note the irradiation from a central hub, posterior to the mid-point of the sterno-mastoid muscle.

Dissect out also the inframaxillary branches of the facial nerve.

Cut the platysma myoides muscle from its origin, and turn it upwards and inwards over the lower jaw to expose the deep fascia of the neck. (Diagram VI.)

Study Diagram VI in connection with the description in the text-books.

Make an incision just above the suprasternal notch to exhibit the space of Burns, which is occupied by a little fat, a lymphatic gland, a transverse vein connecting the two anterior jugulars, and the sternal attachment of the sterno-mastoid muscle.

Upon a grooved director incise the anterior part of the fascial sheath of the sterno-mastoid muscle ; study the muscle from origin to insertion,

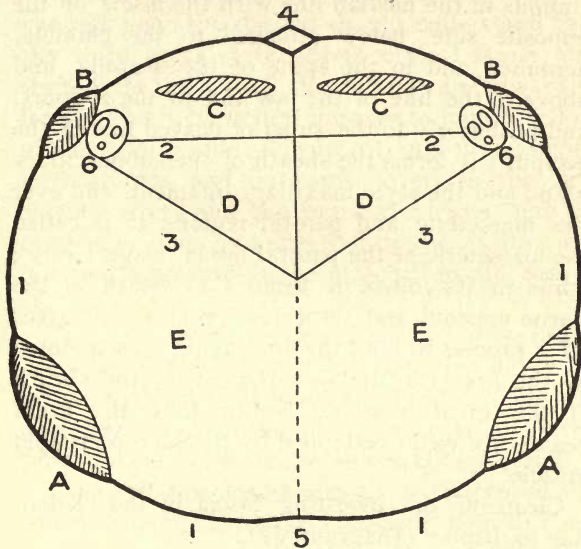


DIAGRAM VI.
THE DEEP CERVICAL FASCIA.
(SCHEMATIC.)

- | | |
|--|--|
| 1. Investing fascia of neck. | A—Trapezius muscle. |
| 2. Pretracheal layer. | B—Sterno-cleido-mastoid muscle. |
| 3. Prevertebral layer. | C—Depressor muscles of the larynx |
| 4. Space of Burns. | D—Trachea, œsophagus, thyroid gland and isthmus. |
| 4-5. Median line of neck. | E—Prevertebral muscles and vertebrae. |
| 5. Spinous processes of vertebrae. | F—Line of incision. |
| 6. Carotid artery, internal jugular vein, pneumogastric nerve. | |

then cut it in the middle and reflect in both directions, being careful to preserve the spinal accessory nerve and its branches, and the three sterno-mastoid arteries.

SEVENTH DAY.

Follow the investing layer as it is shown, continuous in the median line with the fascia on the opposite side, below attached to the clavicle, acromion and to the spine of the scapula, and above to the line of the jaw and to the zygoma, and posteriorly to the superior curved line of the occiput ; it forms the sheath of the submaxillary gland and the stylo-maxillary ligament, and over the masseteric and parotid regions it is called the masseteric or the parotid fascia, respectively ; while in its course it forms the sheath of the sterno-mastoid and trapezius muscles, and gives off a process to bind the omo-hyoid muscle down to the first rib, and is adherent to the sheath of the great vessels. Notice that the great vessels are well overlapped by the sterno-mastoid muscle.

Clean off the investing fascia in the median line to display (Diagram VI) :

The depressor muscles of the larynx	{	Sterno-hyoid. Sterno-thyroid. Thyro-hyoid. Omo-hyoid.	}	Their origin and insertion and nerve supply.
---	---	--	---	---

Cut the sterno-hyoid and the sterno-thyroid muscles in the middle to exhibit the *pretracheal* layer of the cervical fascia, which passes behind them and meets the fascia of the opposite side in the median line ; downwards it extends to the pericardium, outwards as far as the carotid sheath,

and upwards it gives processes which ensheath the thyroid body and the trachea.

Although it cannot be dissected out with advantage now, the student should understand that the third layer of the deep cervical fascia also starts from the carotid sheath and runs inward in front of the prevertebral muscles to join its fellow of the opposite side ; downwards into the posterior mediastinum, and outwards covers in the subclavian artery and the brachial plexus, and accompanies them as a sheath into the axilla ; and it extends upwards to be attached to the base of the skull.

The stylo-maxillary ligament is a process of the deep fascia derived from the investing layer attached to the styloid process and to the angle and posterior margin of the inferior maxilla, and separates the parotid from the submaxillary gland.

Clean off the deep fascia so as to expose the common carotid artery in its sheath, with its companions, the internal jugular vein, and the pneumogastric nerve. Notice the ansa hypoglossi upon its sheath giving off branches to the depressor muscles of the larynx, and behind look for the inferior thyroid artery (branch of the thyroid axis), and the middle (thyroid) ganglion of the sympathetic, the sympathetic trunk itself and the recurrent laryngeal nerve.

Follow the common carotid artery up to its bifurcation into the external and internal carotids. Notice the relative positions of the two, and fol-

low up the external carotid, in front of which you will find :

The digastric and stylo-hyoid muscles,
The lingual and facial veins,
The hypoglossal nerve,

before its disappearance underneath the submaxillary gland.

Study the origin and insertion of the digastric and stylo-hyoid muscles and the suprahyoid aponeurosis. Note the submaxillary gland and its sheath formed from the investing layer of the deep fascia ; lift it to see how it rests upon the posterior part of the mylo-hyoid muscle and goes around its posterior edge, and between it and the hyo-glossus muscle gives off its duct (Wharton's).

Follow the facial artery (branch of the external carotid) up under the digastric and stylo-hyoid muscles, underneath the submaxillary gland, where it gives off its submaxillary branches, on to the face, just in front of the masseter muscle, upon the buccinator muscle, under the two zygomatici, upon the levator labii superioris until it reaches the side of the nose, running alongside of which it finally ends at the inner canthus in the angular artery.

Dissect out the facial vein and the lingual vein, and note that while the facial vein runs directly from the inner canthus to the anterior margin of the masseter muscle, the artery as described above

forms the sides of a triangle of which the vein therefore is the base, and as they cross over the inferior maxilla the vein is posterior to the artery and finally empties into the internal jugular vein.

Study the hypoglossal nerve as it crosses the external carotid just below the digastric tendon, giving off the descendens noni and the thyro-hyoid branch, itself terminating in the lingual muscles.

EIGHTH DAY.

Note the submental vessels (branches of the facial) upon the mylo-hyoid muscle, and clear off the mylo-hyoid muscle itself, cutting the submaxillary gland loose so far that it may be turned backwards to show the relation to the deeper part of the gland, as already referred to; then lift the anterior belly of the digastric, and stylo-hyoid muscle, from their hyoid attachment.

Study the origin and insertion of the mylo-hyoid muscle, and note that it partly overlaps the hyoglossus and covers in the genio-hyoid muscle in the median line which, therefore, is on a deeper plane. In conjunction with the dissector upon the opposite side, notice the median raphé at the junction of the two mylo-hyoids.

Detach the mylo-hyoid from its hyoid attachment, and in the median line from its fellow of the opposite side, and turn it upwards to expose :

Structures under the mylo-hyoid muscle.	{	At the median line, the	} Study			
		genio-hyoid muscle.		} their origin		
		Laterally (in part), the hyo-			} and	
		glossus muscle.				} insertion.
		Above (in part), the stylo-				
		glossus muscle.				
		The hypoglossal nerve (twelfth).				
		The gustatory nerve (branch of fifth).				
		The submaxillary ganglion (between duct and gustatory nerve).				
		Wharton's duct.				
The sublingual gland.						
The genio-hyo-glossus muscle.						
The buccal mucosa.						

The hyo-glossus is a very important muscle ; study its origin and insertion and its relations as follows :

A. Structures on the external surface of the hyo-glossus muscle,
 The digastric, the stylo-hyoid, and the stylo-glossus muscles,
 The gustatory nerve,
 The submaxillary ganglion,
 Wharton's duct,
 Part of the submaxillary gland,
 The hypoglossal nerve,
 The sublingual gland.

B. Structures on the deep surface of the hyo-glossus muscle,
 The genio-hyo-glossus muscle,
 The lingual muscles,
 The middle constrictor,
 The lingual vessels,
 The glosso-pharyngeal nerve.

Study the structures mentioned in class *A*; notice the suprahyoid branch of the lingual artery runs just above the hyoid bone, and then detach the hyo-glossus muscle from its hyoid attachment, and study structures under class *B*.

Go back to the external carotid, and take each one of the branches in turn, excepting the occipital and internal maxillary, and trace them to their termination, as described in "Gray" or "Morris."

Branches of the external carotid artery.	{ Superior thyroid, Lingual, Facial, Ascending pharyngeal, Posterior auricular, Occipital, Terminal,	{ Temporal, Internal maxillary.

NINTH DAY.

Dissect out the structures of the lips, and review the dissection of the face, parotid and suprahyoid regions as already dissected; then cut the zygoma and turn it, with the masseter muscle, downwards to study the origin and insertion of the temporal muscle.

Divide the ramus of the jaw vertically, just below the condyle, and make a transverse incision just above the dental foramen.

Study the origin and insertion of the pterygoid muscles preparatory to their dissection later on, and then look for the internal lateral ligament. Between that and the lower jaw you will find :

- The external pterygoid muscle,
- The internal maxillary artery,
- The auriculo-temporal nerve,
- The inferior dental nerve,
- The inferior dental artery.

Dissect the course and branches of the internal maxillary artery :

- | | | |
|--------------|---|--|
| First part. | { | Tympanic,
Deep auricular,
Inferior dental,
Meningea media,
Meningea parva. |
| Second part. | { | Deep temporal,
Buccal,
Two pterygoids. |

The third portion must be left for a future dissection.

Note the internal maxillary vein, the pterygoid plexus, the temporo-maxillary vein, and trace the last down to where it divides into two portions, one of which joins the facial vein, and the other, after receiving the posterior auricular vein, becomes the external jugular.

Pick up the auriculo-temporal nerve as it passes between the internal lateral ligament and the lower jaw, and dissect it to where it joins the

portion already worked out, accompanying the temporal artery, and then trace it backwards as a guide to the dissection of the inferior maxillary branch of the fifth nerve, coming out through the foramen ovale.

Look out for the otic ganglion, resting just below the foramen ovale on the deep surface of the inferior maxillary nerve, close to the eustachian tube.

Dissect out the two sub-divisions of the inferior maxillary nerve (third division of fifth) :

Anterior division (smaller) of the inferior maxillary nerve.	}	Masseteric. Deep tempo- ral. Buccal. Pterygoid (2).	}	Motor branches to the muscles of mastication.
--	---	--	---	---

Posterior division (larger) of the inferior maxillary nerve.	}	Auriculo-temporal. Gustatory. Inferior dental.
--	---	--

The chorda tympani (branch of the seventh) joins the gustatory at an acute angle, just below the external pterygoid muscle.

Follow these nerves out to their ultimate distribution, as described in "Gray" or "Morris."

Dissect the buccinator muscle, its origin and insertion and nerve supply, and the pterygo-maxillary ligament, and review the pterygo-maxillary region.

TENTH DAY.

Trace the internal jugular vein from its emergence from the jugular foramen to its entrance into the innominate vein.

Work out the pneumogastric nerve and its branches in the neck :

Branches of the tenth nerve in the neck.	{	Pharyngeal.	{	Ext. laryngeal.
		Sup. laryngeal.		Int. laryngeal.
		Recurrent laryngeal.		
		Cervical cardiac.		

Also the glosso-pharyngeal (ninth) from its emergence from the jugular foramen, passing between the jugular vein and the internal carotid artery, beneath the styloid process and the muscles connected with it, upon the stylo-pharyngeus muscle, and the middle constrictor of the pharynx, just below the stylo-glossus muscle, and finally beneath the hyo-glossus muscle.

Branches of the glosso-pharyngeal nerve in the neck.	{	Carotid,
		Pharyngeal,
		Muscular to the stylo-pharyngeus muscle,
		Tonsillar,
		Lingual.

Notice how the superior laryngeal and recurrent laryngeal (from tenth) enter the larynx, and their function.

Follow the internal carotid artery from its

origin to its entrance into the carotid canal, noticing its relation to the tonsils.

Trace the cervical sympathetic trunk ; note its three ganglia, and particularly the three cardiac nerves—the superior, the middle, and the inferior.

Study the *cervical plexus*, part of which has been already dissected :

Superficial.	{	Ascending.	{	Superficialis colli.
				Auricularis magnus.
				Occipitalis minor.
		Descending.	{	Sternal.
		Supraclavicular.		Clavicular.
				Acromial.
Deep.....	{	Internal.	{	Communicating.
				Muscular.
				Communicans noni.
			Phrenic.	
		External.	{	Communicating.
				Muscular.

—particularly the phrenic nerve ; in conjunction with the dissector upon the thorax, trace it from its originating nerve-roots to its termination in the diaphragm. Compare the phrenic nerve with the external respiratory of Bell.

ELEVENTH DAY.

Follow out the post-cervical chain of lymphatics.

Dissect out the subclavian artery and vein, with their relations to each other and the branches of the artery.

Follow particularly the scalenus anticus muscle, because next to the sterno-mastoid, it is surgically the most important muscle in the neck.

Branches of the subclavian artery (divided into three portions by the scalenus anticus muscle).	First portion.	{ <ul style="list-style-type: none"> Vertebral. Internal mammary. Thyroid axis. 	{ <ul style="list-style-type: none"> Inferior thyroid. Supra-scapular. Transversalis colli.
	Second portion.	{ <ul style="list-style-type: none"> Superior intercostal (right). 	
	Third portion.	{ <ul style="list-style-type: none"> No branches usually. Sometimes posterior scapular. 	

On the left side the *second portion* usually gives off no branch.

Learn that portion of the brachial plexus which lies in the cervical region, its nerve roots, the formation of its trunks, and the muscles between which it emerges. The brachial plexus then has roots, trunks, cords, and branches.

Branches of the brachial plexus above the clavicle.	{ <ul style="list-style-type: none"> Communicating. Muscular. Posterior thoracic (ext. resp. of Bell). Suprascapular.
---	---

Note the scalene tubercle and the carotid tubercle.

TWELFTH DAY.

Study the thyroid gland and isthmus, with its relations to the trachea as described in Gray; dissect out also the cervical portions of the trachea and œsophagus.

Review the cervical dissection thus far worked out.

THIRTEENTH DAY.

Make a transverse incision just above the sternum through the trachea and œsophagus.

Dissect out the muscular and ligamentous structures arising from the hyoid bone.

Note the posterior median raphe at which the constrictors meet. Dissect out:

The stylo-pharyngeus muscle.	} Their origin and insertion.
The superior constrictor muscle.	
The middle constrictor muscle.	
The inferior constrictor muscle.	

Note what structures pass between the superior and the middle, and the middle and the inferior constrictors.

FOURTEENTH DAY.

Study the prevertebral region.

The prevertebral layer of the deep fascia (Diagram VI).

The origin and insertion of the scalenus anticus, with its relations, as it is of great importance.

The scalenus medius.	} Their position; and origin and insertion, in a general way only.
The scalenus minimus.	
The rectus capitis anticus major.	
The rectus capitis anticus minor.	
The rectus capitis lateralis.	

The longus colli muscle, its origin and insertion, in conjunction with the dissector on the chest.

FIFTEENTH DAY.

Working with the students upon the other parts of the body, turn the cadaver into the prone position. Denude Area 6, Diagram II, page 26.

Note how firmly the skin is bound down to the fascia beneath, and how scanty the blood supply is toward the median line.

Study the deep fascia in connection with Diagram VI, page 79.

With the dissector upon the thorax, demonstrate the trapezius muscle, its shape, its origin, its insertion, and its nerve supply. At its median border look out for the occipital artery, and for the occipitalis major nerve.

Do not overlook the ligamentum nuchæ.

Cut the trapezius free from its clavicular and scapular attachments, and reflect it inwards to expose :

The splenius capitis et colli muscle,	} Their origin and insertion.
The levator anguli scapulæ muscle,	
The rhomboideus major muscle,	
The rhomboideus minor muscle,	

The posterior belly of the omo-hyoid muscle.

The posterior scapular artery.

The vertebral aponeurosis.

Cut the splenius loose from the vertebral and cranial attachment and turn it downward, to follow the whole course of the occipital artery (from external carotid) and its branches, particularly the *arteria princeps cervicis*, which divides into a superficial and deep branch, the complexus muscle separating the two.

Study the positions of the complexus, the trachelo-mastoid, and biventer cervicis muscles.

In conjunction with the dissector upon the thorax, after he has removed the vertebral aponeurosis, get a general idea of the erector spinæ muscle and its sub-divisions running up into the neck.

With the dissector upon the arm, lift the rhomboids so as to study with him the serratus magnus muscle and the vessels anastomosing about the scapula.

SIXTEENTH DAY.

Work out the boundaries of the suboccipital triangle, the muscles forming it—the rectus posticus major, the superior and inferior oblique muscles, with their origin and insertion—its floor, its covering; and its contents; also note:

The vertebral artery and vein.

The suboccipital nerve (posterior division of suboccipital) (first cervical).

The occipitalis major nerve (internal branch posterior division of second cervical).

The princeps cervicis artery and its anastomoses.

The profunda cervicis artery and its anastomosis. Compare the four "cervical" arteries.

Do not waste time in attempting to learn the origin and insertion of the fourth, fifth, and sixth layers of muscles, excepting those forming the suboccipital triangle, as already indicated.

In order to continue the dissection of the interior of the pharynx, place the saw at the base of the skull, back of the pharyngeal spine, and make a transverse incision directly upward, posterior to this pharyngeal spine, so as to expose the pharynx in its posterior relations.

SEVENTEENTH DAY.

Make an incision through the median raphé, and dissect out the "fibrous bag" of the pharynx, which lies between the constrictors and the mucous membrane, being attached to the basilar process of the occipital bone by the craniopharyngeal ligament, to the eustachian tube, to the under surface of the petrous portion of the temporal bone, the root of the pterygoid process, to the internal pterygoid plate of the sphenoid bone, becoming continuous with the pterygo-maxillary ligament. Note the interval called "the sinus of Morgagni."

Having completed this, expose the interior of the pharynx.

Note the seven openings.

Lift the mucous membrane from the soft palate and dissect out the levator and the tensor palati, the azygos uvulæ, and the palato-pharyngeus muscles, holding the uvula tense with chain-hooks.

Define the tonsils, with the "pillars of the fauces," noting the muscle contained in each pillar.

At the base of the skull, extending from one eustachian tube to the other, you will find "the pharyngeal tonsil" ; particularly note the relation of the eustachian tube to the posterior nares.

Examine the dissection of the spinal cord made by the student upon the thorax.

EIGHTEENTH DAY.

Dissection of the orbit. With a fine metacarpal saw, through the frontal bone, make a V-shaped incision, with the apex at the sphenoidal fissure. Do not impinge upon the optic foramen, because of the ligament of Zinn, and the number of muscles arising therefrom.

The first thing we see on removing the orbital plate is the periosteum, which will be found to be continuous with the dura through the sphenoidal and optic foramina, dividing at the anterior margin of the orbit into two layers, one to join the periosteum of the skull externally, the other the tarsal cartilage.

Cut the periosteum by a median antero-posterior

incision, remove the fat underneath, and dissect the following structures in order :

Periosteum, its two layers (palpebral ligament).

Subperiosteal fat.

Lachrymal gland, nerve, and artery on the outside, the nerve resting on the external rectus muscle.

Frontal nerve, with the supraorbital artery in the middle, the frontal nerve resting on the levator palpebræ superioris muscle.

Fourth nerve on the inside, the patheticus (fourth) resting on the superior oblique muscle.

Follow these nerves and arteries to their distribution, preserving the supraorbital artery as a guide to the main trunk from which it springs, the ophthalmic.

Make the upper eyelid tense, so as to stretch the levator palpebræ, then divide the frontal nerve to expose :

<p>The obliquus superior muscle, with its pulley and its (fourth) nerve, The levator palpebræ superioris muscle,</p>	}	<p>Origin and insertion.</p>
--	---	--------------------------------------

Cut the levator palpebræ superioris muscle midway to reach the rectus superior muscle underneath, dissect its origin and insertion, and divide it in turn midway, so that the mass of fat and other structures surrounding the optic nerve will be exposed. Taking the optic nerve as a guide :

The superior division of the third nerve, The nasal branch of the fifth nerve, The superior division of the ophthalmic vein, The ophthalmic artery, with its supra-orbital branch, The lenticular ganglion, a quarter of an inch in front of the sphenoidal fissure, sometimes outside of the artery, The main trunk of the ophthalmic artery, The common ophthalmic vein, The sixth nerve (to ext. rectus muscle), The long ciliary nerves and arteries are on <i>either side</i> .	}	Will be found above it. Will be found to its outer side.
--	---	---

The short ciliary arteries and nerves *surround it*.

The arteria centralis retinae is *within it*.

The inferior division of the third nerve, The inferior division of the ophthalmic vein,	}	Will be found beneath it.
--	---	---------------------------

Branches of the ophthalmic artery (veins correspond except as regards the sub-division of the ophthalmic vein as above).

Orbital group.

Ocular group.

{	Lachrymal. Supraorbital. Posterior ethmoidal. Anterior ethmoidal. Palpebral. Frontal. Nasal.
{	Muscular. Anterior ciliary. Short ciliary. Long ciliary. Arteria centralis retinae.

Branches of the ophthalmic nerve (first division of the fifth), sensory.	Lachrymal.	{	To gland.	
			To conjunctiva.	
			To integument of upper lid.	
	Frontal.	Supra-trochlear.	{	To integument of forehead.
				To corrugator supercilii.
				To occipito-frontalis.
Supra-orbital.		{	To integument.	
			To corrugator supercilii.	
			To occipito-frontalis.	
Nasal branch.	{	To orbicularis palpebrarum.		
		To pericranium.		
		Ganglionic, to ophthalmic ganglion.		
		Long ciliary (3), to ciliary muscles and iris.		
Infra-trochlear.	{	To integument.		
		Orbicularis palpebrarum.		

The short ciliary nerves, ten to twelve in number, are branches of the ophthalmic ganglion.

Work out the roots and distribution of the ophthalmic ganglion, and then dissect the three remaining recti muscles.

External rectus muscle,	}	Their origin and insertion.
Internal rectus muscle,		
Inferior rectus muscle,		

Study the ligament of Zinn, from which they all take origin.

Lift the conjunctiva at the lower and inner part of the orbit to expose the lowest muscle, which runs transversely beneath the inferior rectus, the *obliquus inferior*, and study its origin and insertion.

Review the function of the muscles of the eyeball, and their nerve supply.

NINETEENTH DAY.

Remove the contents of the orbit, place the eyeball in alcohol for future study, and lift the conjunctiva from the floor.

Seize the infraorbital nerve as it emerges upon the face from the infraorbital foramen, draw firmly upon it, and with a chisel or fine saw break through the roof of the infraorbital canal, and follow it backwards as a guide until Meckel's ganglion is reached.

By mutual agreement with the fellow-dissector upon the head, an antero-posterior vertical section of the skull must be made, to one side of the nasal septum, so as to study its bony and cartilaginous portions, and also the anterior and posterior nares.

Remove the septum carefully in small portions with forceps, so as to preserve the mucous membrane of the other side intact, and in this way the artery of the septum, a branch of the nasal or sphenopalatine artery, and the naso-palatine

nerve (branch of Meckel's ganglion) going to the anterior palatine fossa, and some filaments of the olfactory nerve may be seen. Cut the mucous membrane along the floor of the inferior meatus and lift it to expose the turbinated bones and the three nasal sinuses, of which the inferior is the most important. Study the description in Gray or Morris, and then remove the turbinated bones to study the infundibulum, the opening into the antrum, and the lachrymo-nasal duct.

Lift the mucous membrane of the hard palate to expose the anterior and posterior palatine canals, to find the anterior and posterior palatine nerves. Take a skull that has been cleaned, and study the position of the sphenopalatine foramen, which opens into the superior meatus just above the posterior margin of the middle turbinated bone. Seize the posterior palatine nerve, and with a chisel or forceps denude the bone vertically between the two foramina, and use the nerve as a guide to Meckel's ganglion. Study the roots and branches of distribution of the ganglion as given in the larger anatomical works.

TWENTIETH DAY.

Lift the dura from the apex of the petrous portion of the temporal bone to expose the gasserian ganglion. Study its roots (sensory only), and its branches (sensory only), and trace:

The ophthalmic branch of the fifth to the sphenoidal fissure.

The superior maxillary branch to the foramen rotundum.

The inferior maxillary branch to the foramen ovale, and dissect the motor root joining the last mentioned.

Make a diagram of the fifth nerve, showing particularly why it is called *trifacial*.

Make a diagram of the cranial and cervical nerves and arteries.

TWENTY-FIRST DAY.

Study the triangles of the neck, and their contents, and the anastomoses of the arteries.

Enumerate the various structures in the median line from the chin to the episternal notch, touching each one in turn, the relations of the cervical part of the œsophagus, and the articulations, particularly of the lower jaw and of the atlas and axis.

If the student has not already done so, he may now study the sinuses of the brain and review the fossæ and foramina of the skull, dissecting out the common carotid artery in its course to the carotid canal and through the cavernous sinus.

TWENTY-SECOND TO THE TWENTY-EIGHTH DAY.

Review the whole dissection of the head and neck, after which the trachea, larynx, hyoid bone, and tongue may be cut out and placed in the alcohol jar, and later on, together with the brain and its membranes, may be studied with the assistance of one of the larger treatises.

TABLE III.—THE ANTERIOR AND LATERAL MUSCLES OF THE HEAD AND NECK.

MUSCLE.	ORIGIN.	INSERTION.	FUNCTION.	NERVE SUPPLY.
Occipito-frontalis.	(1) Superior curved line of occiput and mastoid process; (2) Integument and muscles of eyebrow and pyramidalis nasi.	Central aponeurosis.	Elevates the eyebrows and skin over glabella and throws the forehead into wrinkles.	(1) Occipitalis minor; (2) facial.
Attollens aurem	Aponeurosis of occipito-frontalis	Pinna.	Draws auricle upwards.	Small occipital.
Attrahens aurem.	Aponeurosis of occipito-frontalis.	Helix.	Draws auricle upwards and forwards.	Facial.
Retrahens aurem.	Mastoid process.	Concha.	Draws auricle backwards.	Facial.
Orbicularis palpebrarum.	Inner angle of frontal tendon, nasal process of superior maxilla.	Skin, malar bone, external tarsal ligament.	Draws auricle upwards and forwards.	Facial.
Corrugator supercilii	Inner extremity of superciliary ridge.	Under surface of orbicularis.	Sphincter.	Facial.
Tensor tarsi.	Lachrymal bone.	Tarsal cartilage.	Contracts the brow.	Facial.
Pyramidalis nasi	From occipito-frontalis.	Compressor nasi and fascia	Draws cartilage inwards.	Facial.
Compressor nasi	Canine fossi.	Fascia and cartilage of nose.	Wrinkles glabella.	Facial.
Levator labii superioris alæ quenasii.	Nasal process of superior maxilla.	(1) Ala of nose; (2) upper lip.	Compresses nose.	Facial.
Levator labii superioris.	Superior maxilla and malar just above infraorbital foramen.	Upper lip.	Elevator of wing of nose and upper lip.	Facial.
			Elevator of lip.	Facial.

Zygomatikus major.	Malar bone and zygoma.	Upper lip.	Raises upper lip.	Facial.
Zygomatikus minor.	Malar bone.	Angle of mouth.	Raises upper lip.	Facial.
Risorius.	Platysma myoides.	Angle of mouth.	Risus sardonius.	Facial.
Levator anguli oris.	Canine fossa below the supra-orbital foramen.	Angle of mouth.	Raises angle of mouth.	Facial.
Levator labii inferioris.	Incisive fossa external to symphysis.	Skin of chin.	Levator menti.	Facia
Depressor labii inferioris.	External oblique line of lower jaw.	Orbicularis oris.	Depressor of lower lip.	Facial.
Depressor anguli oris.	External oblique line.	Lower lip.	Depressor of angle of lip.	Facial.
Orbicularis oris.	Septum nasi; alveoli of superior and inferior maxillae.	Surrounds upper and lower lips.	Closes the mouth.	Facial.
Buccinator	Alveolar processes opposite molar teeth; pterygo-maxillary ligament.	Orbicularis oris.	Compresses the check.	Facial, inferior maxillary.
Levator palpebræ superioris.	Lesser wing of sphenoid in front of optic foramen.	Tarsal cartilage.	Eye opener.	Third.
Rectus superior.	Margin of optic foramen.	Eyeball.	Levator.	Third.
Rectus inferior.	Optic foramen.	Eyeball.	Depressor.	Third.
Rectus externus	(1) Optic foramen; (2) zone of Zinn.	Eyeball.	Abductor.	Sixth.
Rectus internus.	Margin of optic foramen.	Eyeball.	Adductor.	Third.
Obliquus superior.	Margin of optic foramen.	Eyeball.	Internal rotator.	Fourth.
Obliquus inferior.	Orbital plate of superior maxilla.	Eyeball.	External rotator.	Third.
Temporal.	Temporal fossa and fascia.	Coronoid process and ramus.	Mastication.	Third division of fifth.
Masseter	Zygoma and superior maxilla.	Ramus, coronoid process and angle.	Mastication.	Third division of fifth.
External pterygoid.	External pterygoid plate, great wing of sphenoid, tuberosity of palate and superior maxilla.	Neck of condyle of lower jaw.	Mastication.	Third division of fifth.

THE ANTERIOR AND LATERAL MUSCLES OF THE HEAD AND NECK. — *Continued.*

MUSCLE.	ORIGIN.	INSERTION.	FUNCTION.	NERVE SUPPLY.
Internal pterygoid	External pterygoid plate, pterygoid process of palate bone.	Inner side of angle of lower jaw.	Mastication.	Third division of fifth.
Platysma myoides	Clavicle, acromion and fascia.	Lower jaw, angle of mouth, skin and fascia.	Tens. r of fascia of neck.	Facial, superficial cervical.
Sterno-mastoid	(1) Sternum; (2) clavicle.	Mastoid process, superior curved line of occiput.	Flexor and rotator.	Spinal accessory, cervical plexus.
Sterno-hyoid.	Clavicle and manubrium.	Hyoid bone.	Depressor of larynx.	Ansa hypoglossi.
Sterno-thyroid.	Manubrium and first rib.	Thyroid cartilage.	Depressor of larynx.	Ansa hypoglossi.
Thyro-hyoid.	Thyroid cartilage.	Body and cornu of hyoid bone.	Depressor of hyoid bone.	Hypoglossal.
Omo-hyoid.	Scapula.	Os hyoides.	Depressor of larynx.	Hypoglossal, vagus, and cervical plexus.
Digastric	(1) Digastric groove.	(2) Lower jaw.	Elevates the hyoid bone.	(1) Facial; (2) inferior dental.
Stylo-hyoid.	Styloid process.	Hyoid bone.	Draws hyoid up and back.	Facial.
Mylo-hyoid	Mylo-hyoid ridge.	Os hyoides and raphé.	Elevator of hyoid bone.	Inferior dental.
Genio-hyoid	Inferior genial tubercle.	Os hyoides.	Elevator of hyoid bone.	Hypoglossal.
Genio-hyo-glossus.	Superior genial tubercle.	Tongue and hyoid bone.	Protrudes the tongue.	Hypoglossal.
Hyo-glossus.	Hyoid bone.	Tongue.	Depresses tongue.	Hypoglossal.
Lingualis.	Tongue.	Tongue.	Depresses tongue.	Chorda tympani.

Stylo-glossus	Styloid process and stylo-maxillary ligament.	Tongue.	Retracts tongue.	Hypoglossa.
Stylo-pharyngeus	Styloid process.	Posterior border of thyroid cartilage.	Draws larynx upward and backward.	Glosso-pharyngeal.
Scalenus anticus	Scalene tubercle.	Transverse processes of third, fourth, fifth and sixth cervical vertebrae.	Flexes the spinal column.	Cervical nerves.
Scalenus medius	First rib.	Transverse processes of lower six cervical vertebrae.	Flexes the spinal column.	Cervical nerves.
Scalenus posticus	Second rib.	Transverse processes of lower three cervical vertebrae.	Flexes the spinal column.	Cervical nerves.
Rectus capitis anticus major.	Third, fourth, fifth and sixth cervical vertebrae.	Basilar process.	Flexor of head.	Suboccipital, cervical plexus.
Rectus capitis anticus minor.	Lateral mass and transverse process of atlas.	Basilar process.	Flexor of head.	Suboccipital, cervical plexus.
Rectus lateralis.	Transverse process of atlas.	Jugular process.	Flexor of head.	Suboccipital.
Longus colli	(1) Third, fourth and fifth cervical vertebrae; (2) bodies of three upper dorsal vertebrae; (3) bodies of three upper dorsal vertebrae.	(1) Atlas; (2) bodies of three lower cervical vertebrae; (3) transverse processes of fifth and sixth cervical vertebrae.	Flexor and rotator of cervical spine.	Lower cervical nerves.
Constrictor superior	Internal pterygoid plate; palate bone, pterygo-maxillary ligament, alveolar process, side of tongue.	Median raphe and pharyngeal spine.	Deglutition.	Pharyngeal plexus and glosso-pharyngeal.

THE ANTERIOR AND LATERAL MUSCLES OF THE HEAD AND NECK.—Continued.

MUSCLE.	ORIGIN.	INSERTION.	FUNCTION.	NERVE SUPPLY.
Constrictor medius . . .	Hyoid bone, stylo-hyoid ligament.	Median raphe.	Deglutition.	Pharyngeal plexus, glosso-pharyngeal.
Constrictor inferior. . .	Thyroid and cricoid cartilage.	Median raphe.	Deglutition.	Pharyngeal plexus, glosso-pharyngeal.
Levator palati.	Apex petrous portion temporal bone.	Soft palate.	Elevator of soft palate.	Branch from Meckel's ganglion.
Tensor palati (circumflexus).	(1) Scaphoid fossa; (2) tendon.	(1) Tendon; (2) soft palate.	Flexor of soft palate.	Branch from otic ganglion.
Azygos uvulae	Nasal spine and aponeurosis	Uvula.	Elevates the uvula.	Meckel's ganglion.
Palato-glossus.	Soft palate.	Side and dorsum of tongue.	Elevates base of tongue.	Meckel's ganglion.
Palato-pharyngeus	Soft palate.	Thyroid cartilage.	Elevator of larynx.	Pharyngeal plexus and Meckel's ganglion.
Crico-thyroid	Front and lateral part of cricoid.	Front and lateral part of thyroid.	Tensor of vocal cords.	Superior laryngeal.
Crico-arytænoides lateralis.	Upper border of side of cricoid.	Outer angle of base of arytenoid.	Closes the glottis.	Recurrent laryngeal.
Arytænoides	Posterior surface, outer border of one arytenoid.	Into similar part of the other.	Closes the glottis.	Superior and recurrent laryngeal.
Crico-arytænoides posterior.	Posterior surface of cricoid.	Outer angle of base of arytenoid.	Opens the glottis.	Recurrent laryngeal.

Thyro-arytænoideus . . .	Receding angle of thyroid.	Base and anterior surface of arytenoid.	Relaxes vocal cords.	Recurrent laryngeal.
Thyro-epiglottideus.	Receding angle of thyroid.	Epiglottis.	Depressor of epiglottis.	Recurrent laryngeal.
Arytæno-epiglottideus superior.	Apex of arytenoid.	Side of epiglottis.	Depressor of epiglottis.	Recurrent laryngeal.
Arytæno-epiglottideus inferior.	Anterior surface of arytenoid.	Upper part of epiglottis.	Compressor sacculi laryngis.	Recurrent laryngeal.

CHAPTER IV.

Dissection of the Thorax and Abdomen.*

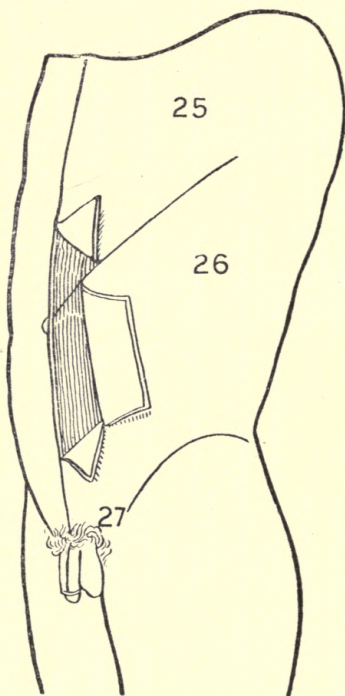


DIAGRAM VII.

FIRST DAY.

Make the incisions and remove the integument as per Diagram VII, from areas marked 25, 26, 27.

The superficial fascia of the abdomen will be found to consist of two layers: the upper fatty; the lower fibrous.

The upper layer, called Camper's fascia, is continuous with the surrounding tissue; in and beneath it you will find:

The cutaneous arteries, derived from

*The dissection of the pectoral muscles and fascias has been assigned to the dissector upon the upper extremity (*q. v.*), and should be reviewed with him later on.

the intercostals and internal mammary, and also the superficial epigastric and superficial circumflex iliac, from the femoral.

<i>The cutaneous nerves.</i>	Anterior.	Terminal branches of the lower dorsal nerves (note where these end).
		Hypogastric branch of the ilio-hypogastric nerve.
	Lateral.	Lateral branches of the lower dorsal nerves.
		Lateral division of the last dorsal nerve.
		Iliac branch of the ilio-hypogastric nerve.
		Iliac branch of the ilio-inguinal nerve.

The superficial lymphatic glands, disposed irregularly along Poupart's ligament, which receive the lymphatic vessels from the scrotum, penis, and skin of the abdomen, perineal and gluteal regions.

The lower layer of the superficial fascia of the abdomen, called "Scarpa's fascia," is attached firmly to the linea alba, to the front of the pubes, and to Poupart's ligament, and through the dartos is continuous with "Colles' fascia"; not being firmly adherent to the spermatic cord, it forms the "*abdomino-scrotal*" opening, which should not be confused with the *external ring*, which is on a deeper plane in the aponeurosis of

the obliquus externus muscle. Pass your finger along the spermatic cord through the abdomino-scrotal opening.

Clean off the superficial fascia to expose the external oblique muscle. Note its origin, the direction of its fibers, and the points of its insertion.

Points of insertion of the obliquus externus muscle :	}	Anterior half of the outer lip of the crest of the ilium.
		Whole length of Poupart's ligament.
		Linea alba.
		Front of pubes and crest.
		Symphysis (inner pillar of ring).
		Spine of pubes (outer pillar of ring).
		Ilio-pectineal line (Gimbernat's ligament).
		Crest of pubes and ilio-pectineal line of opposite side (the triangular ligament).

The triangular ligament, so called, is really a portion of the tendinous fibers of the external oblique muscle of one side, projected across the linea alba to the ilio-pectineal line and crest of the opposite side. It lies behind the inner pillar of the external ring and in front of the conjoined tendon.

Study the external ring, its position with reference to Poupart's ligament and the spine of the pubes, its boundaries, and the intercolumnar fibers derived from the external oblique muscle. Note the triangle of Petit.

Cut the obliquus externus muscle clear from the fourth to the eighth rib, so as to be sure not to disturb the internal oblique; then loosen it from the four lower ribs, insert a grooved director along the iliac crest, cut the muscle free from there, and turn it downwards and inwards to expose the obliquus internus muscle.

Points to be noted about the obliquus internus muscle :	}	The direction of its fibers.
		Its origin and insertion.
		The formation of the conjoined tendon.
		The formation of the cremaster muscle.
		Its relation to the inguinal canal. How it aids in the formation of the sheath of the rectus abdominis muscle.

Lift the obliquus internus muscle from the outer surface of the four lower ribs, from the lumbar fascia, and from the crest of the ilium, to expose the deep circumflex iliac artery (a branch of the femoral), and the transversalis muscle.

Points to be noted about the transversalis muscle :	}	The direction of its fibers.
		Its origin and insertion.
		How it aids to form the conjoined tendon and the sheath of the rectus abdominis muscle.
		Its relation to the inguinal canal.

Study the sheath of the rectus abdominis muscle, and the formation of the linea alba, the linea semilunaris, and the lineæ transversæ. Split the sheath of the rectus above, and then throughout its whole length, to learn of its origin and insertion; within its sheath you will find the pyramidalis.

Cut the rectus abdominis muscle midway, and turn the two portions to expose the semilunar fold of Douglas and the anastomosis of the superior epigastric artery from the internal mammary, with the deep epigastric artery from the external iliac. Review the formation of the sheath of the rectus, one and a half aponeuroses in front, one and a half aponeuroses behind, excepting at the lower fourth posteriorly.

SECOND DAY.

Cut through the transversalis fascia, the subperitoneal fat, and the peritoneum transversely across the whole abdominal cavity on a level with the umbilicus, and within the abdominal cavity notice :

- The urachus,
- The falciform ligament and ligamentum teres,
- The deep epigastric arteries,
- The obliterated hypogastric arteries,
- Hesselbach's triangle,
- The external, middle, and internal inguinal fossæ,
- The internal ring.

I. DIAPHRAGM

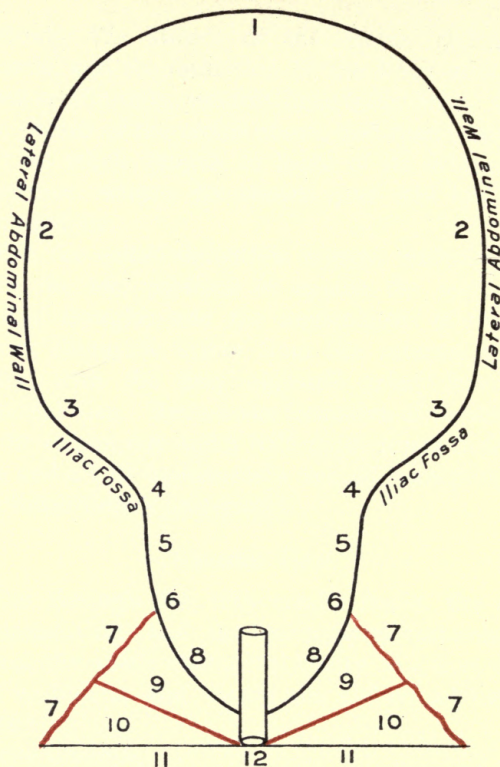


DIAGRAM VIII. A.

THE TRANSVERSALIS FASCIA, THE FIBROUS BAG OF THE ABDOMINAL CAVITY, TRACED FROM SIDE TO SIDE.

(SCHEMATIC.)

- | | |
|--|---------------------------------------|
| 1. Diaphragm. | 7. Obturator fascia. |
| 2. Lateral abdominal wall. | 8. Recto-vesical fascia. |
| 3. Iliac fascia. | 9. Levator ani muscle. |
| 4. Ilio-pectineal line. | 10. Ischio-rectal fossa. |
| 5. Pelvic fascia. | 11. Skin and fascia of anal triangle. |
| 6. Point of division of the pelvic fascia into | 12. The anus. |

13 DIAPHRAGM

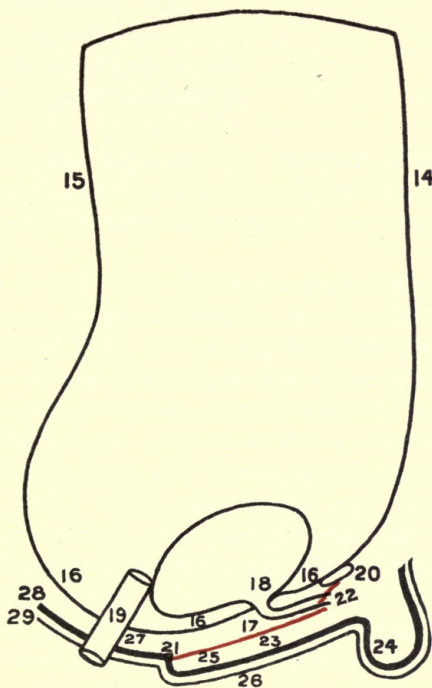


DIAGRAM VIII. B.

THE TRANSVERSALIS FASCIA, THE FIBROUS BAG OF THE ABDOMINAL CAVITY, TRACED ANTERO-POSTERIORLY.

(SCHEMATIC.)

- | | |
|-------------------------------|---|
| 13. Diaphragm. | 23. Colles' fascia. |
| 14. Anterior abdominal wall. | 24. Dartos of the scrotum. |
| 15. Posterior abdominal wall. | 25. First perineal pouch. |
| 16. Recto-vesical fascia. | 26. Skin and superficial fascia of the perineum. |
| 17. The subpubic membrane. | 27. Space occupied by the levator ani |
| 18. Opening for urethra. | 28. Anal fascia. |
| 19. Opening for rectum. | 29. Skin and superficial fascia of the anal triangle. |
| 20. Symphysis pubis. | |
| 21. Perineal center. | |
| 22. Membranous urethra. | |

The spermatic cord,
The vas deferens,
The transversalis fascia,
The parietal peritoneum.

Cautiously separate the parietal peritoneum from the transversalis fascia, and read the description of this important fascia in "Gray" or "Morris."

Try to appreciate that it is a fibrous bag lining the whole of the abdominal and pelvic cavities (Diagrams VIII, *A* and *B*), covering the lower surface of the diaphragm, the inner surface of the transversalis and rectus abdominis muscles, and the anterior surface of the quadratus lumborum and psoas and iliacus muscles; over the latter being called iliac fascia, and its extension downwards over the ilio-pectineal line is denominated the pelvic fascia, which, running to the median line below, joins its fellow of the opposite side—being called there the recto-vesical fascia—and thus forms the floor of the pelvic outlet.

Carefully separate the remaining structures covering in the area marked 27, Diagram VII, and study in your text-book the description of the direct and oblique inguinal hernias, and of the spermatic cord and its components.

Notice the coverings of the hernias are nothing more than the anterior coverings of the abdominal cavity.

Thus the coverings of the :

<i>Abdominal cavity :</i>	<i>Oblique inguinal hernia :</i>
1. Skin.	1. Skin.
2. Superficial fascia.	2. Superficial fascia.
3. Aponeurosis of ext. oblique muscle.	3. Intercolumnar fibers.
4. Internal oblique muscle.	4. } Cremasteric muscle
	5. } or fascia.
5. Transversalis muscle.	6. Infundibuliform fascia.
6. Transversalis fascia.	7. Preperitoneal fat.
7. Preperitoneal fat.	8. Sac.
8. Parietal peritoneum.	

Direct inguinal hernia :

1. Skin.	6. Transversalis fascia.
2. Superficial fascia.	7. Preperitoneal fat.
3. Intercolumnar fibers.	8. Sac.
4. } Conjoined tendon.	
5. }	

Study the relations of the rings to Poupart's ligament; the boundaries of the external ring, of the internal ring, of the inguinal canal—its length, its direction, and its contents—and the relation of the deep epigastric artery to the internal ring.

Why is an oblique inguinal hernia sometimes called external, and a direct inguinal hernia sometimes called internal?

Review the abdominal muscles and the whole subject of hernia before leaving it.

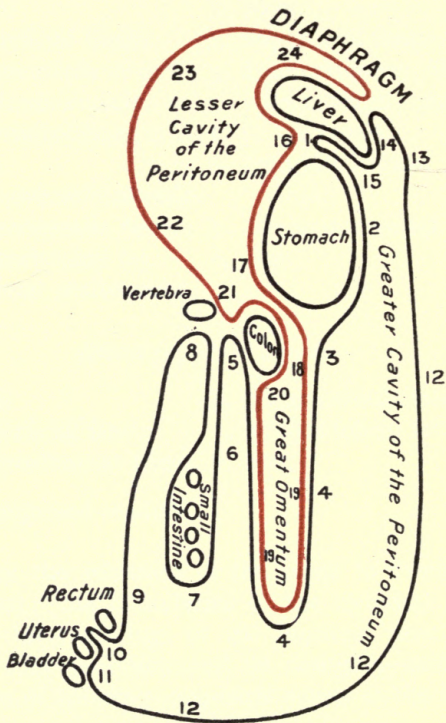


DIAGRAM IX.

SCHEMATIC OUTLINE OF THE GREATER AND LESSER FOLDS OF THE PERITONEUM, TRACED FROM ABOVE DOWNWARDS.

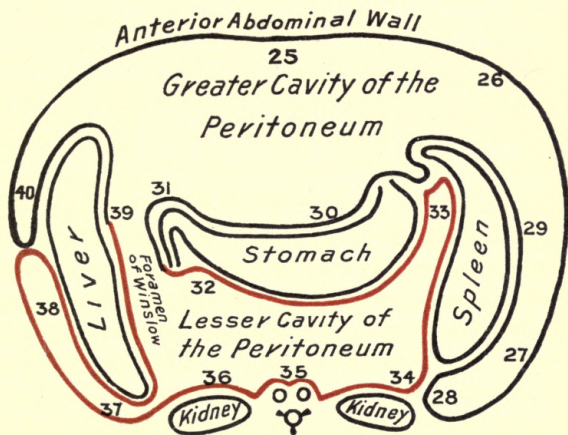


DIAGRAM X.

SCHEMATIC OUTLINE OF THE GREATER AND LESSER FOLDS OF THE PERITONEUM, TRACED FROM SIDE TO SIDE.

THIRD DAY.

The cavity of the abdomen being thoroughly opened, by two vertical incisions on either side of the median line, study the description of the femoral ring, the septum crurale, and the formation of the femoral sheath with the dissector upon the leg. Read up the peritoneum in "Gray" or "Morris" in connection with Diagrams IX and X.

Understand : $\left\{ \begin{array}{l} \text{The greater fold,} \\ \text{The lesser fold,} \\ \text{The greater cavity,} \\ \text{The lesser cavity,} \end{array} \right\}$ Of the peritoneum.

Draw the great omentum down smoothly in front of the small intestines. Place your fingers upon the transverse fissure of the liver, and, with Diagram IX as a guide, follow the peritoneum from above downward, as indicated by the figures (1 to 15) in regular order. Thus, pass from (1) transverse fissure of the liver to (2) anterior surface of the stomach, to (3) anterior to transverse colon, to (4) great omentum; then return to (5) under surface of transverse colon and vertebral column, then to (6 and 7) forming the mesentery holding the small intestine, etc., in place; return to (8) vertebral column, thence down along the vertebral column to (9) promontory of sacrum, to rectum, to (10) Douglas' pouch, to uterus, to (11) the bladder; then to (12) anterior abdominal wall, to (13) under surface of the

diaphragm, to (14) upper surface of the liver, to (15) around the free edge of the liver, to (1) the starting point. This is that greater fold of the peritoneum, and includes the greater cavity of the peritoneum; that lining the abdominal wall is called the parietal portion, and that upon the intestines, liver, and so on, the visceral portion.

To trace the lesser fold of the peritoneum, place the hand at the transverse fissure of the liver, behind the stomach and follow the direction of the figures (16 to 24, Diagram IX). Thus, from (16) transverse fissure of the liver to (17) posterior surface of the stomach, to (18) anterior to the transverse colon, to (19) within the previous folds to form the great omentum, returning to (20) anterior to the transverse colon, (21) to the vertebral column, (22 and 23) anterior to the quadratus lumborum muscle, kidney, etc., to (24) the under surface of the diaphragm; thence to the liver, and back to (16) the place of starting.

Below the level of the transverse colon, the arrangement of the peritoneum is simple; but above, in consequence of the deviation of the stomach from an antero-posterior budding to a latero-transverse position, the arrangement is somewhat more complex.

To trace the peritoneum in the upper part of the abdominal cavity, from side to side, is somewhat more difficult.

In connection with Diagram X, trace it as follows : Beginning at (25) in the median line of the inner surface of the anterior abdominal wall, pass your hand to (26) the lower end of the left costal arch, to (27) the lateral and posterior abdominal wall, to (28) kidney, to (29) spleen, to (30) the lesser curvature of the stomach, to (31) the pyloric end of the stomach and duodenum, to (32) posterior surface of the stomach, to (33) reflection to the spleen, to (34) reflection anterior to kidney, to (35) vertebral column, aorta, and vena cava, to (36) passing in front of kidney, to (37) posterior abdominal wall, to (38) reflection to upper surface of the liver, to (39) the under surface of the liver, to (40) from upper surface of the liver to anterior abdominal wall to (25) the place of starting.

It is evident that which is in front of the stomach is the greater cavity of the peritoneum, that which is behind the stomach is the lesser cavity of the peritoneum, and the narrow passage from one to the other is called the foramen of Winslow.

Study the sub-divisions of the peritoneum :

- | | | |
|---|---|---|
| i. Those which connect
the stomach to cer-
tain viscera : | } | The gastro-colic, or
great omentum.
The gastro-hepatic, or
lesser omentum.
The gastro-splenic
omentum. |
|---|---|---|

2. Those which hold the viscera in place, the false ligaments of the
- | | |
|---|----------|
| } | Spleen. |
| } | Liver. |
| } | Bladder. |
| } | Uterus. |

3. Those which unite certain viscera to the posterior abdominal wall :
- | | |
|---|----------------------------|
| } | The mesentery, |
| } | The meso-appendix, |
| } | The meso-cæcum, |
| } | The ascending meso-colon, |
| } | The transverse meso-colon, |
| } | The descending meso-colon, |
| } | The sigmoid meso-colon, |
| } | The meso-rectum, |
- } Their method of formation and their attachments.

FOURTH DAY.

Take the free edge of the great omentum and draw it, with the transverse colon, sharply upwards over the thorax, and fasten it there.

Notice that the mesentery is six inches wide, and is attached to the left at the second lumbar vertebra, and extends to the right obliquely forwards and downwards to the right sacro-iliac synchondrosis.

Begin over to the left, and remove the anterior layer of the mesentery and the under layer of the ascending and transverse meso-colon, which will expose the superior mesenteric artery and its

branches, with their corresponding veins; also the lymphatic glands and the sympathetic nerve fibers. The lymphatics of the small intestines, called lacteals, enter these mesenteric glands and empty into two or three large trunks which terminate in the thoracic duct. The lymphatics of the large intestine are of two sets: those of the cæcum, ascending and transverse colon enter the mesenteric glands; those of the descending colon and rectum pass to the lumbar glands.

Notice the superior mesenteric artery coming out beneath the pancreas and in front of the third portion of the duodenum, and giving off:

Branches of the superior mesenteric artery.	{	Inferior pancreatico-duodenal.
		Vasa intestini tenuis.
		Ilio-colic.
		Colica dextra.
		Colica media.

In the vasa intestini tenuis note the loops and the anastomoses.

Draw the small intestines firmly over to the right side, and remove the anterior layer of the descending meso-colon, to expose the inferior mesenteric artery and its branches.

Branches of the inferior mesen- teric artery.	{	Colica sinistra.
		Sigmoid.
		Superior hemorrhoidal.

Unfasten the great omentum and draw it down firmly; draw up the free edge of the liver and remove the anterior layer of the gastro-hepatic

(lesser) omentum, and dissect out the five important structures :

Bile duct.

Portal vein.

Hepatic artery.

Lymphatics.

Nerves.

} Note their relations to each other, and trace them upwards and downwards.

FIFTH DAY.

Use the hepatic artery as a guide to the cœliac axis, and clean off the posterior layer of the lesser omentum, being careful not to injure the solar plexus, which surrounds the axis and the root of the superior mesenteric artery, and is apt to be mistaken for areolar tissue.

Trace the branches of the cœliac axis and their sub-divisions, with their corresponding veins. In order to do this, tie a double ligature upon the rectum at the promontory of the sacrum, and cut between them ; similarly ligate the small intestines at the duodeno-jejunal junction. Study the duodeno-jejunal fossa, and the process of peritoneum holding this part of the intestine in place ; then cut between the ligatures, and also through the six inches of the mesentery, freeing a considerable portion of the superior and inferior mesenteric veins, so as to leave a stalk from which to follow up the portal system ; then divide the meso-colon close to the intestine throughout. Remove the large and small intestines, wash them, both inside and out, and place them in a jar for future study.

Draw the stomach well up and study the three portions of the duodenum, its horseshoe curve, the structures emptying into the second portion, and its relations to the stomach, the pancreas, and the gall bladder.

Read the description of the pancreas in "Gray," and note the large artery and vein just above it, the portal vein and the superior mesenteric artery between it and the transverse portion of the duodenum, its tail resting on the spleen and its head in the horseshoe curve of the duodenum, and its duct (Wirsung) and where it ends.

Trace the portal vein beneath the pancreas, comprehend its method of formation, its length (4 inches), the veins emptying into the main trunk, and follow it up to its termination in the transverse fissure of the liver.

Dissect out, from above downwards, the cystic duct, the right and left hepatic ducts, and the common hepatic duct, and the junction of the cystic duct and the common hepatic to form the ductus communis choledochus, and trace it to where it empties into the second portion of the duodenum.

Study the position of the spleen, its relations to its surrounding structures, its vascular supply; trace its vein, emptying into the vena porta, and outline the gastro-splenic omentum.

Follow out the divisions and sub-divisions of the cœliac axis.

Cœliac axis.	{	Gastric (<i>coronaria ventriculi</i>).	
		Hepatic. {	Pyloric.
			Gastro-duodenalis.*
Splenic. {	Cystic.		
	Pancreaticæ magnæ et parvæ.	Gastric (<i>vasa brevia</i>).	
		Gastro-epiploica sinistra.	

Tie off the stomach just beyond its pyloric and œsophageal orifices with double ligatures, cut between them and remove it.

Study the ligaments of the liver, then remove it cutting the vessels, nerves, ducts, and portal vein below, and the vena cava both above and below; the vena cava and the portal vein may be ligated distally before cutting. Place the liver in the jar for future examination.

Strip the peritoneum from the under surface of the diaphragm and from the anterior surface of the kidney, and turn it inwards to study the crura and the two arcuate ligaments of the diaphragm. Read carefully the description of the diaphragm as given in Gray or Morris, its foramina and the structures passing through them, and the cordiform tendon.

On each side of the aorta and close to the crura of the diaphragm, near the suprarenal capsules, look for the semilunar ganglion, which forms part of the sympathetic solar plexus, which is itself around the cœliac axis and the superior mesenteric artery, extending downwards as low as the pancreas and outwards to the suprarenal capsules,

*Gastro-duodenalis—Gastro-epiploica dextra, Pancreatico-duodenalis superior.

and, as has been already remarked, is very apt to be mistaken for areolar tissue.

Between the upper part of the aorta, to the right of and behind it, and the right crus of the diaphragm, upon the front of the body of the second lumbar vertebra, is the receptaculum chyli, together with the commencement of the thoracic duct, and also the ending of the vena azygos major.

SIXTH DAY.

Dissect out the abdominal aorta and its branches from the aortic orifice of the diaphragm to its bifurcation on the body of the fourth lumbar vertebra into the two common iliaes.

Branches of the abdominal aorta.	Phrenic.	<table> <tr> <td rowspan="3"> <table> <tr> <td rowspan="3"> <table> <tr> <td>Gastric.</td> </tr> <tr> <td>Hepatic.</td> </tr> <tr> <td>Splenic.</td> </tr> </table> </td> </tr> </table> </td> </tr> <tr> <td>Coeliac axis.</td> </tr> <tr> <td>Superior mesenteric.</td> </tr> <tr> <td>Suprarenal.</td> </tr> <tr> <td>Renal.</td> </tr> <tr> <td>Spermatic.</td> </tr> <tr> <td>Inferior mesenteric.</td> </tr> <tr> <td>Lumbar.</td> </tr> <tr> <td>Sacra media.</td> </tr> </table>	<table> <tr> <td rowspan="3"> <table> <tr> <td>Gastric.</td> </tr> <tr> <td>Hepatic.</td> </tr> <tr> <td>Splenic.</td> </tr> </table> </td> </tr> </table>	<table> <tr> <td>Gastric.</td> </tr> <tr> <td>Hepatic.</td> </tr> <tr> <td>Splenic.</td> </tr> </table>	Gastric.	Hepatic.	Splenic.	Coeliac axis.	Superior mesenteric.	Suprarenal.	Renal.	Spermatic.	Inferior mesenteric.	Lumbar.	Sacra media.
					<table> <tr> <td rowspan="3"> <table> <tr> <td>Gastric.</td> </tr> <tr> <td>Hepatic.</td> </tr> <tr> <td>Splenic.</td> </tr> </table> </td> </tr> </table>	<table> <tr> <td>Gastric.</td> </tr> <tr> <td>Hepatic.</td> </tr> <tr> <td>Splenic.</td> </tr> </table>	Gastric.	Hepatic.	Splenic.						
							<table> <tr> <td>Gastric.</td> </tr> <tr> <td>Hepatic.</td> </tr> <tr> <td>Splenic.</td> </tr> </table>	Gastric.	Hepatic.	Splenic.					
	Gastric.														
	Hepatic.														
	Splenic.														
	Coeliac axis.														
	Superior mesenteric.														
	Suprarenal.														
	Renal.														
Spermatic.															
Inferior mesenteric.															
Lumbar.															
Sacra media.															

Study the inferior vena cava throughout its whole extent; note how it is formed, how it is contained in a groove on the posterior border of the liver, how it pierces the diaphragm.

Look up the sympathetic system, which will be very much simplified if the general outline of its distribution is comprehended.

In your large anatomies you will find the sym-

pathetic cords lying parallel with each other, extending from the base of the skull to the coccyx, and having upon these cords a series of ganglia arranged like white beads on a string, as follows :

Arrangement of the sympathetic ganglia.	}	Cephalic . . .	4
		Cervical . . .	3
		Dorsal . . .	12
		Lumbar . . .	4
		Sacral . . .	5
		Coccygeal . . .	<u>1</u>
		In all . . .	29

It may assist the student's memory to remark that there are :

29 sympathetic ganglia (pairs).

31 spinal nerves (pairs).

33 vertebræ.

Trace the four lumbar sympathetic ganglia and their cords upon the lumbar vertebræ to either side of the aorta.

Note in the text-book how the cervical ganglia give the cardiac branches to the thoracic structures, and how the dorsal ganglia give the splanchnics to the abdominal structures, ending in the solar, the cœliac, and the renal plexuses :

The main plexuses in the abdominal cavity are :

1. *The solar plexus*, already described.
2. *The aortic plexus*, upon the sides and front of the aorta, between the superior and inferior mesenteric arteries.
3. *The hypogastric plexus*, situated upon the promontory of the sacrum, between the two common iliac arteries.

All of the remaining plexuses are derived from these main ones, and are named according to the arteries they follow, thus: The superior mesenteric plexus follows the superior mesenteric artery, the spermatic plexus (from renal and aortic plexuses) accompanies the spermatic artery, etc.

Study the kidney and the suprarenal capsules in relation to the surrounding parts, particularly with regard to the colon in front and the edge of the quadratus lumborum muscle behind.

Trace the ureter downwards to the ilio-pectineal line, cut it midway in its course, and remove it and the kidney, and place it in the jar with the other viscera.

Study the lumbar fascia, and note it gives origin from its anterior edge to the transversalis abdominis muscle, but as it passes posteriorly it divides into three lamellæ, the *anterior* leaflet passing in front of the quadratus lumborum muscle to be attached to the base of the transverse process of the lumbar vertebræ, and above to the margin of the last rib, where it forms "the ligamentum arcuatum externum"; a *middle* leaflet passing posterior to the free edge of the quadratus lumborum muscle, to be attached to the apex of the transverse processes, therefore separating the quadratus lumborum from the erector spinæ muscle, and a *posterior* leaflet, attached to the apices of the spinous processes, passing therefore posterior to the erector spinæ muscle. The three leaflets of the lumbar fascia, therefore, in short,

ensheath the two muscles, the quadratus lumborum and the erector spinæ.

SEVENTH DAY.

Remove carefully the transversalis fascia and the peritoneum covering the posterior abdominal wall. You will see the branch of the twelfth dorsal nerve just below the last rib.

Dissect out the origin and insertion of the psoas magnus (et parvus, if present) muscle, and comprehend how an abscess from the lumbar, or even the dorsal region, might enter its sheath and travel down underneath Poupart's ligament.

Review the formation of the iliac fascia (Diagram VIII), then turn it inwards to get at the origin and insertion of the iliacus muscle.

Learn in Morris or Gray the formation of the lumbar plexus, and trace from above downwards the following branches :

Lumbar plexus (anterior division of four upper lumbar).	}	Ilio-hypogastric (first).
		Ilio-inguinal (first).
		External cutaneous (second and third).
		Anterior crural (third and fourth).
		Genito-crural (second).
		Obturator (second, third and fourth).
		Accessory obturator (second, third and fourth).

A part of the fourth lumbar nerve joins the fifth lumbar, to form "the *lumbo-sacral cord*," which we shall find subsequently entering the sacral plexus.

It is absolutely necessary that the dissector upon the abdomen should prepare himself for the next day's work (eighth day) by several hours' study at home.

Read in your larger text-books the sections upon "*the perineum*," and review once more the transversalis fascia, in connection with Diagrams VIII, *A* and *B*. Its prolongation over the ilio-pectineal line is called the pelvic fascia, and its extension still further on is called the recto-vesical fascia, which, by joining the fellow of the opposite side in the median line, forms the fibrous floor of the pelvic outlet. See Diagram VIII, *B*, how this floor is pierced by the urethra and the rectum, and by the cervix uteri in the female. Study the quadrilateral outlet of the pelvis, and see how it is subdivided, into two triangles by an imaginary line (bis-ischiatic) drawn through the perineal center between the anterior portions of the two tuber ischii, thus dividing the quadrangle into the *urethral* or vesical, and the *anal* or rectal triangles. Learn the boundaries of each of these triangles.

It is evident from Diagram VIII, *B*, that the anterior part of the recto-vesical fascia (marked 16) is also called the posterior layer of the triangular ligament, being in fact that part of the

recto-vesical fascia which is suprajacent to the urethral triangle.

As the recto-vesical fascia is the fibrous floor of the pelvis, it is also evident that the bladder, with its prostate gland (the corpus uteri in the female), and the greater part of the rectum are within the cavity of the transversalis fascia, and above the recto-vesical portion thereof, while the urethra, the cervix uteri, the anus, a small portion of the rectum, and all of the remaining perineal structures must be outside of it—*i. e.*, below it.

In the male, the structures below the fibrous floor of the pelvis (recto-vesical fascia), from within outwards, are :

In the region of the urethral triangle :

5. The second perineal pouch, containing the membranous urethra, surrounded by the compressor urethræ muscle, Cowper's glands, the pudic vessels and nerve, the artery of the bulb, the dorsal vein of the penis, the vesico-prostatic plexus of veins.

In the region of the anal triangle:

- The levator ani muscle.
- The coccygeus muscle.
- The anal fascia (from obturator).
- The obturator fascia.
- The areolar tissue of the ischio-rectal fossa.
- The inferior hemorrhoidal arteries, veins, and nerve.
- The perineal branch of the fourth sacral nerve.

4. The anterior layer of the triangular ligament. The superficial fascia. Skin.

3. The first perineal pouch, containing the bulb of the corpus spongiosum, surrounded by the accelerator urinæ muscle, the crura of the corpora cavernosa, the erector penis muscles, the transversus perinei muscles, arteries, veins, and nerves, the superficial perineal arteries, veins, and nerves.

2. { Colles' fascia.
Superficial layer of the superficial fascia.

1. Skin.

In the male, the layers of the perineum in the region of the urethral triangle, from without inwards, are :

1. Skin.

2. Superficial fascia. { Fatty layer.
Fibrous layer, called Colles' fascia.

- | | | |
|--|----|---|
| 3. First perineal pouch containing : | } | <p>The accelerator urinæ muscle, surrounding the <i>bulb</i> of the <i>corpus spongiosum</i>.</p> <p>The <i>erectores penis</i>, surrounding the <i>crura</i> of the <i>corpora cavernosa</i>.</p> <p>The <i>transversus perinei</i> muscle.</p> <p>The superficial and transverse perineal arteries and veins.</p> <p>The perineal nerve—superficial perineal.</p> |
| 4. The deep fascia (subpubic membrane), | or | <p>The anterior layer of the triangular ligament.</p> |
| 5. Second perineal pouch, containing : | } | <p>The <i>compressor urethræ</i> muscle surrounding the membranous urethra.</p> <p>The subpubic ligament.</p> <p>The glands of Cowper.</p> <p>The pudic artery, veins, and nerves.</p> <p>The artery of the bulb.</p> <p>The dorsal vein of the penis.</p> <p>The vesico-prostatic plexus of veins.</p> |
| 6. The posterior layer of the triangular ligament, which is derived from the recto-vesical fascia (or the obturator, if you wish). | | |

7. Areolar tissue.

8. Peritoneum.

In alternate layers : fascia, muscle, fascia, muscle, fascia.

The structures in the anal triangle, from without inwards, are :

Skin.

Superficial fascia.

Inferior hemorrhoidal arteries, veins and nerves.

The perineal branch of the fourth sacral nerve.

Areolar tissue and fat.

Anal fascia.

Obturator fascia.

Levator ani muscle.

Obturator internus muscle.

Coccygeus muscle.

cle.

Recto-vesical fascia.

Areolar tissue.

Peritoneum.

Go over these carefully, with book and diagram. It is time well spent, as but few students or practitioners understand the anatomy of the pelvic outlet in the male.

The Female Pelvic Outlet.

The female pelvic outlet is the analogue of the male (the original rib was male) ; therefore the preceding description of the male outlet must be first carefully read over. The boundaries of the quadrilateral space of the urethral and anal triangles, and the anatomy of the ischio-rectal fossa, are practically the same in both sexes. Consult Diagram VIII, *A* and *B*. The transversalis fascia

will be found to form the same intra-abdominal fibrous bag in the female as in the male, with the same projections—the pelvic and its prolongation, the recto-vesical—into the true pelvis; the recto-vesical fascia, therefore, forming the fibrous floor of the pelvis in the female also, pierced between the aperture for the bladder and that for the rectum by a third opening, through which the cervix uteri is thrust. Therefore, in the female the bladder, the greater part of the rectum, and the corpus uteri are above the recto-vesical fascia.

In the female, the structures below the fibrous floor of the pelvis (recto-vesical fascia), from within outwards, are:

<i>In the region of the urethral triangle:</i>	<i>In the region of the anal triangle:</i>
--	--

- | | |
|---|----------------------|
| <p>5. Second perineal pouch, containing the urethra, surrounded by some thin muscular fibers; the constrictor vaginæ muscle; pudic vessels and nerves, dorsal vein of the clitoris, and a venous plexus.</p> <p>4. Anterior layer of the triangular ligament.</p> <p>3. First perineal pouch, containing the semi-bulbs, pars intermedia,</p> | <p>Same as male.</p> |
|---|----------------------|

the sphincter vaginæ,
 the crura of the clitoris,
 the erector clitoridis,
 the transversus perinei
 muscles, the superficial
 and transversus perineal
 vessels and nerves,
 glands of Bartholine.

- | | | | | |
|----|---|---|---|-----------------------------|
| 2. | { | Colles' fascia.
Superficial layer
of the superfi-
cial fascia, | } | Forming the
labia major. |
| 1. | | Skin. | | |

In the female, the layers of the perineum in the region of the urethral triangle, from without inwards, are :

- | | | | |
|----|--|---|--|
| 1. | Skin. | | |
| 2. | Superficial fascia | { | Fatty layer,
Colles' fascia. |
| 3. | The first perineal
pouch, contain-
ing : | { | The semi-bulbs,
The pars intermedia,
The crura clitoridis,
The erector clitoridis,
The sphincter vaginæ,
The superficial and
transverse perineal
vessels and nerves,
The transversus peri-
nei muscle,
Glands of Bartholine. |

Pierced by the vulvar cleft.

- | | | | |
|---|---|---|---|
| 4. Anterior layer of triangular ligament. | } | Pierced by the cervix uteri, with the vagina. | |
| 5. Second perineal pouch, containing : | | | The urethra, surrounded by the compressor urethræ muscle, pudic vessels and nerve.
Dorsal vein of clitoris and venous plexus.
Constrictor vaginæ. |
| 6. The posterior layer of the triangular ligament, which is derived, as in the male, from the recto-vesical fascia. | | | |
7. Areolar tissue.
8. Peritoneum.

The vulvar cleft divides, in the median line, the skin, the superficial fascia, Colles' fascia, and the first perineal pouch. The ostium vaginæ is, as it were, projected downwards through the bulb of the corpus spongiosum, the lateral halves thus becoming the semi-bulbs, or bulbi vestibuli, and the perforated accelerator urinæ, the sphincter vaginæ.

EIGHTH DAY.

The student, having prepared himself by previous study for this dissection, will secure the subject in the dorsal decubitus, with the feet in stirrups. Evert the lower margin of the rectum

so as to see the *white line*, which is just above the external sphincter. Stuff the rectum with cotton, and sew up the anus. Pass a metal sound into the bladder, and secure it there. Hook up the scrotum out of the way.

Note the median raphé. Draw with the handle of the scalpel a line from the symphysis pubis to the tuber ischii, thence to the tip of the coccyx, on both sides, to outline the quadrilateral pubic outlet, and make a transverse marking between

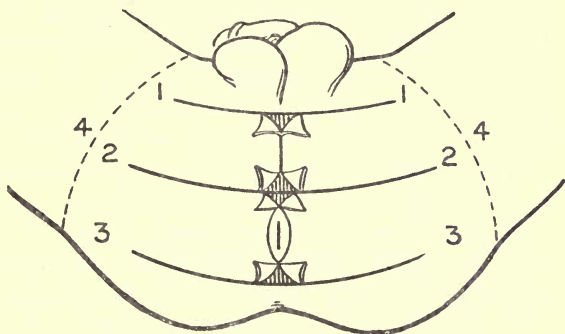


DIAGRAM XI.
THE MALE PERINEUM.

the anterior margins of the two tuber ischii, to determine the urethral and anal triangles. Make incisions, Figures 1, 2, 3, Diagram XI, and denude, being careful to take off the layers as on page 136 *et seq.*

The skin being removed, the fatty layer of the superficial fascia will be found continuous with that of the surrounding structures. Remove

this by an oval incision (4, Diagram XI) well beyond the pelvic outlet. The dissector may easily divide this into a number of layers, but can distinguish them from Colles' fascia by their passing cleanly over the bony boundaries without attachment.

Remove the superficial layer of the superficial fascia to expose "*Colles' fascia*," which is attached on either side to the rami of the pubes and ischium, posteriorly around the transverse perinei muscle, to the anterior layer of the triangular ligament, and in front is continuous with the dartos of the scrotum. This may be well demonstrated by injecting water with a syringe into the *abdomino-scrotal opening*, which will indicate the course of the urine, in a reversed direction, in certain ruptures of the urethra.

Pass a grooved director deeper than Colles' fascia, just to the median line of the ramus pubis; cut down upon and study the *first perineal pouch* (No. 3, page 138), with its contents. Note the perineal center and the division of the pouch by an incomplete median septum, and see that they rest upon the anterior layer of the triangular ligament as a firm basis.

You surely must, by this time, clearly comprehend that this "anterior layer of the triangular ligament" is not as other fascias, but is a specialized membrane closing in the lower part of the pubic arch, very much as the obturator membrane closes in that foramen. Lift the other

half of Colles' fascia on the grooved director, and trace the prolongations of the accelerator urinæ muscle, around the bulb, around the corpora cavernosa, and the root of the penis. Remark the relation of the "*bulb*" to the urethra. Note how it hangs away from the urethra, and is called the bulb of the corpus spongiosum. Note how, at the base of the urethral and anal triangles, the anal fascia joins this subpubic membrane or the anterior layer of the triangular ligament.

Nick the subpubic membrane just to the median line of the ramus of the pubes, slit it up upon the grooved director, and turn it to one side to study the second perineal pouch and its contents (No. 5, page 138). The membranous urethra is of great importance in operative surgery; investigate its length, its position, its relation to the surrounding structures, where it pierces the recto-vesical fascia and subpubic membrane, its distance from the margin of the anus, and its depth from the skin surface.

Removal of the structures in the second perineal pouch brings us to the recto-vesical fascia—that is, the posterior layer at the triangular ligament—and deeper than this we will find areolar tissue and peritoneum.

Review the vesical triangle and its structures from without inwards, and from within outwards (pages 136–139).

The anal triangle.—Dissect the external sphincter, and study its origin and insertion; then follow

out the inferior hemorrhoidal vessels and nerves, and the perineal branch of the fourth sacral nerve. Clean out the areolar tissue and fat of the ischio-rectal fossa (Diagram VIII, *A* and *B*). Study its boundaries, and trace the anal fascia backwards to the obturator fascia, and forwards to its junction with the subpubic membrane at the base of the urethral triangle. Note the relations of the rectum, and how it bulges above the anus, and see how the recto-vesical and anal fascias, with the levator ani muscle between them, converge to the rectum in the median line a short distance above the anus ; hence, a fistula in ano is apt to open there also. Define the *pent roof* shape (Diagram VIII, *A*) of the ischio-rectal fossa, and with the handle of the scalpel clean thoroughly the obturator and anal fascias, if you have not already done so ; trace the obturator fascia forward, becoming adherent to the rami of the pubes and ischium as far as the symphysis. As you run it forwards to the symphysis, you will appreciate that it becomes there continuous once more with the posterior layer of the triangular ligament, a derivation of the recto-vesical fascia from which the obturator fascia also originally sprung ; hence, some authors say that the posterior layer of the triangular ligament comes from the obturator fascia, while others describe it as coming from the recto-vesical fascia : simply two ways of looking at the same thing.

Remove the anal fascia to expose the levator

ani muscle, which arises from the "white line" junction of the obturator and the recto-vesical fascia, having an origin from the symphysis pubis to the spine of the ischium. This "white line" indicates the offset of the obturator fascia from the recto-vesical fascia. The levator ani muscle passes in its insertion obliquely inwards to the median line, to the tips of the coccyx, to the median raphé, to the sides of the rectum, to beneath the prostate, to unite with fibers from the opposite side as far forward as the tendinous center of the perineum, blending with the external sphincter and transversus perinei muscles. In the female, the anterior fibers of the levator ani muscle run to the sides of the vagina.

Dissect out the coccygeus muscle, its origin and insertion, which is virtually a continuation of the levator ani muscle backwards. Lift the levator ani and coccygeus from its origin to expose the recto-vesical fascia, and review the ischio-rectal fossa (p. 139). Lift the edge of the obturator fascia from its attachment to the tuber ischii to expose the pudic artery in Alcock's canal.

Dissection of the Female Genitalia.—Place the body in the dorsal decubitus, the feet in stirrups; shave off the hair, study the external genitalia in Gray or Morris, the mons veneris, the labia majora et minora, the vestibule and fossa navicularis, the fourchette and posterior commissure, the glans clitoridis, the meatus urinarius, the

carunculæ myrtiformes, the ostium vaginæ, the opening of the ducts of Bartholine.

Stuff the vagina with cotton and sew up the outlet. Make transverse incisions at the base of the mons veneris, in front of the anus, and posterior to the anus (Diagram XI, 1, 2, 3), and connect them by a longitudinal incision on either side of the labia majora. Remove the skin from the urethral triangle. The labia majora will be found to be made up of fat and areolar tissue, in the superficial layer of the superficial fascia, with, according to some authors, some ill-defined muscular fibers, Colles' fascia also taking part in their formation. Upon cleaning off the fat and areolar tissue, Colles' fascia will be found divided in the middle line by the vulvar cleft, and continuous with the sheath of the vagina, being attached laterally to the ramus of the pubes and ischium, and posteriorly, as in the male, turning around the transversus perinei muscle to join the subpubic membrane.

Lift Colles' fascia on the grooved director from its external bony attachments, and turn it inwards to study the first perineal pouch and its contents (No. 3, page 141). You will see in the median line the glans clitoridis, the meatus urinarius, and the ostium vaginæ already described; and just to the outer side of the vagina and of the vestibule, the sphincter vaginæ muscle resting upon the semi-bulbs, or bulbi vestibuli, the erectile structures whose extension forwards to the

glans clitoridis is called the pars intermedia. Just at the base of the semi-bulbs you will find the glands of Bartholine, which are said to correspond to Cowper's glands in the male, though somewhat more superficial in the female. The glands of Bartholine are therefore opposite the posterior half of the ostium vaginae, and open by a duct three-quarters of an inch long about the middle of the vaginal outlet. Posterior to the ostium vaginae is a mass of elastic and fibrous tissue, "*the perineal body*," a structure peculiar to females. Study the sphincter vaginae, the erector clitoridis, the transversus perinei muscles, their origin and insertion; note that some of the fibers of the sphincter vaginae pass over the dorsum of the clitoris. Dissect out the superficial perineal vessels and the perineal nerve, and the inferior pudendal nerve. Cut the sphincter vaginae free from the perineal body, and the erector clitoridis from its origin, and turn them forwards, and the transversus perinei from the perineal center, and turn it outwards to study the bulbi vestibuli and the pars intermedia, which are venous plexuses. The arteries of the bulb end in the bulbi vestibuli.

Dissect out the crura of the clitoris and the clitoris itself, with its nervous and vascular supply. Clear off the structures of the first perineal pouch (No. 3, page 141) to study the subpubic membrane, the anterior layer of the triangular ligament, and then lift it upon the grooved director as to study

the second perineal pouch (No. 5, page 142), in which the urethra runs as in the male, with the pudic vessels and nerves and the deep transverse muscles and the constrictor vaginae muscle analogues of the compressor urethrae; and then we arrive once more at the recto-vesical fascia, the posterior layer of the triangular ligament.

The anal triangle is to be dissected as in the male. (Pages 139-140.)

NINTH DAY.

Returning to the interior of the abdomen, lift the peritoneum from the subjacent structures to study the common iliac, the external iliac arteries and their branches and their corresponding veins, at the ilio-pectineal line; then lift the peritoneum from the intrapelvic organs. If the subject is a female, first recognize Douglas' cul-de-sac and the broad ligaments, and make a vaginal examination to mark the extent of the peritoneum in front and behind the uterus.

Remove the peritoneum carefully from the pelvic viscera, to expose from above the transversalis fascia and the pelvic fascia, dividing into its two layers, the recto-vesical and the obturator. Note that the fascia covering the pyriformis muscle is continuous with the obturator fascia.

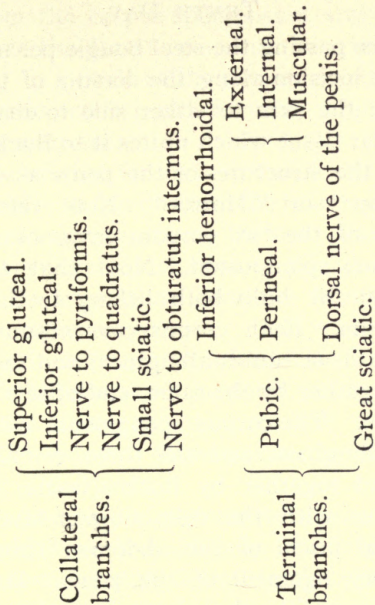
Lift the ureter and the vas deferens out of harm's way, and make an antero-posterior section of the pelvis, sawing well to the right side of the symphysis pubis in front and the sacro-iliac joint

behind. Detach the obturator fascia and the triangular ligament, and study the pelvic viscera in detail from a lateral view. Note the *white line* and the layers of the perinéum, already sufficiently discussed ; Cowper's glands ; the prostate gland, with its sheath, particularly investigating its size and its relation to the second portion of the rectum, the vas deferens, the vesiculæ seminales, the common ejaculatory duct, and the recto-vesical triangle ; the three portions of the rectum ; and, further, the sub-divisions of the recto-vesical fascia, forming sheaths for certain of these structures.

In the female, study the points at which the ovarian and uterine arteries enter the broad ligament, and in a nicely injected subject trace their anastomoses and their branches, and how the main trunks can be reached by the intravaginal or intra-abdominal routes. Dissect the whole pelvic portion of the ureter, and notice its relation to the cervix uteri and the uterine artery. Work out the infundibulo-pelvic ligament, the fallopian tubes and fimbriated extremities, the ovary and its ligament, their pampiniform plexus of veins ; the round ligament and the canal of Nuck, the parovarium, the hydatid of Morgagni, and the tubes of Gärtner. Use the left side of the pelvis for dissecting out the arteries, veins, and nerves.

Common iliac artery.	}	Peritoneal.	}	Deep epigastric artery.	
		Subperitoneal.			
		Ureteric.			
Internal iliac artery.	}	External iliac.	}	Deep circumflex iliac artery.	
		Internal iliac.		}	Muscular— to psoas.
Internal iliac artery.	}	Posterior division.	}	Gluteal.	
		Anterior division.		}	Ilio-lumbar.
					}
}	}	Hypogastric.			
		}	}	Superior, middle and in- ferior vesical.	
}	}			Middle hemorrhoidal.	
		}	}	Uterine { Cervical.	
}	}			Vaginæ azy- gos.	
		}	}	Vaginal.	
}	}			Obturator.	
		}	}	Pudic internal.	
}	}			Sciatic.	
		Internal pubic artery.	}	Muscular.	}
Inferior hemorrhoidal.					
Superficial perineal (transverse perineal).					
Artery of the bulb.					
Artery of the crus (corpora cavernosa).					
Dorsal artery of the penis (cli- toris).					

Sacral plexus formed by anterior division of the lumbo-sacral cord, and first, second, third, and part of fourth sacral nerves.



TENTH DAY.

Practice passing the steel bougie per urethram. Make an incision along the dorsum of the penis, and turn the skin to either side to demonstrate the areolar tissue which unites it to Buck's fascia.

Study the structures of the penis as described in "Gray" or "Morris." Note the relative positions of the two corpora cavernosa and the *one* corpus spongiosum. Note that the glans penis and the bulb both belong to the corpus spongiosum. Each corpus cavernosum has its own sheath, or tunica albuginea, and the two are bound together by the same, and offsets from the trabeculæ. The corpus spongiosum has its own tunica albuginea, and the three erectile bodies are bound together by Buck's fascia, which is continuous with the deep fibrous layer of the superficial fascia of the abdomen through the suspensory ligament of the penis. It is itself continuous with the dartos of the scrotum. Buck's fascia is sometimes called the dartos fascia, and extends from the root of the penis to the glans. It is free from fat and contains some involuntary muscular fibers.

Between the skin and Buck's fascia you will find the branches of the superficial external pudic arteries and veins, and twigs of the ilio-hypogastric nerve. Cut the elastic fascial sheath of the penis along the dorsum, and within it you will find the deep dorsal pudic vessels and nerves: one vein, two arteries, two nerves. Note the

veins from the corpus spongiosum arching up to empty into the dorsal vein, and the arteries anastomosing in a circle at the corona glandis.

Study the arterial and nervous supply of the corpora cavernosa.

Slit the urethra for an inch and a half upon its lower surface to demonstrate the fossa navicularis, with the lacuna magna on its roof; then cut the penis transversely just back of the glans penis, to show its separation from the blunt ends of the two corpora cavernosa; then make another transverse incision, an inch farther back, through the whole thickness of the penis, to demonstrate the erectile tissue, the three tuniçæ albugineæ, and Buck's fascia. Demonstrate the suspensory ligament of the penis.

Reflect the skin of the scrotum to expose the dartos, which we have already found has important connections with Colles' fascia, with Buck's fascia, and with Scarpa's fascia. Cut down upon the testicle, and show that its coverings are those of a complete oblique inguinal hernia, because derived from similar sources.

Coverings of the testicle: (Compare p. 118.)

1. Skin.
2. Dartos.
3. External spermatic fascia, from aponeurosis of external oblique.
4. } Cremasteric fascia, from fibers of internal
5. } oblique and transversalis.
6. } Internal spermatic fascia, from transver-
7. } salis fascia.

8. Tunica vaginalis testis, from the peritoneum.

Dissect out the structures forming the

Spermatic cord.	{	Vas deferens.
		Spermatic artery (from aorta).
		Pampiniform plexus of veins.
		Lymphatics.
		Spermatic sympathetic plexus.
		Processus vaginalis (a relic).
		Artery of the vas (from superior vesical).
Cremasteric artery (from deep epigastric).		

Rub the vas deferens between the fingers, to accustom yourself to the cord-like sensation.

Trace the cord up through the inguinal canal to the internal ring, and the vas deferens from the epididymis to the common ejaculatory duct.

Where does the vas deferens begin and end?

Where does the spermatic cord begin and end?

Review the structures of the perineum and the genitalia, and inguinal hernias.

In the female, trace the round ligament, from within outwards, throughout the inguinal canal, and demonstrate the canal of Nuck.

Cut through the suspensory ligament of the penis; pass the knife under the symphysis, and keeping the edge close to the bony boundaries remove the penis, urethra, prostate, bladder, and rectum en masse, wash them inside and out, and

place them in the alcohol jar. The female pelvic organs may be similarly disposed of.

ELEVENTH DAY.

Dissection of the Thorax.

The dissectors upon the upper extremity have by this time dissected off the pectoral muscles and fascias (*q. v.*).

Clean off one or two of the external intercostal muscles (eleven in all), as they run from the tubercles of the ribs to the costo-chondral junction, and note the external intercostal membrane prolonged (excepting the floating ribs) from this point to the edge of the sternum.

Remove one of the external intercostal muscles to define the intercostal vessels and nerves. The internal intercostal muscles will be better seen in a later dissection from within, but observe that they run in an opposite direction, the two sets forming an X, as far as the angles, where the internal intercostal membrane continues the rest of the way.

Recognize that the external and internal intercostals are counterparts of the external and internal oblique muscles of the abdominal wall.

Saw through the sternum between the attachments of the first and second ribs, and the attachments of the fifth and sixth ribs. Cut the costal cartilages from second to fifth, inclusive.

Lift the part of the sternum thus freed, and define the internal mammary artery, and the

triangularis sterni muscle, which is a continuation upwards of the transversalis abdominis.

Branches of the
internal mam-
mary artery.

Comes nervi phrenici.
Mediastinal.
Thymic.
Pericardiac.
Sternal.
Anterior intercostals.
Perforating.
Superior epigastric.
Musculo-phrenic.

Read up the origin and insertion of the triangularis sterni muscle, then remove it.

Take your larger text-book upon anatomy and read the boundaries of the interpleural space, and its sub-division into the four mediastinal spaces, with the contents of each.

The Interpleural Space.

The superior
mediastinum }
contains :

The thoracic part of the aorta, œsophagus, thoracic duct, the transverse part of the aorta, the innominate artery, the thyroidea ima, the thoracic part of the left carotid and left subclavian, the innominate veins and the upper part of the superior vena cava, the thoracic part of the two pneumogastric nerves, with the left recurrent, the phrenic

The Interpleural Space.

		and cardiac nerves, the remains of the thymus gland, some bronchial lymphatics.
	The anterior mediastinum contains :	Areolar tissue and lymphatics.
		Remains of thymus gland.
		Left internal mammary artery.
	The middle mediastinum contains :	Heart—the ascending portion of the aorta and pulmonary artery, lower half of superior vena cava.
		Phrenic nerves — termination of the great azygos vein.
		Roots of the lungs.
		Lymphatic glands.
	The posterior mediastinum contains :	Third part of the aortic arch.
		Descending thoracic aorta.
		Œsophagus, thoracic duct.
		Pneumogastric nerves.
		Azygos veins.
		Lymphatics.

Dissect out the structures in the anterior mediastinum. Notice the two innominate veins, and the relation of the left innominate to the episternal notch. Follow the pleura with the hand. Carefully map out the position of the lungs in reference to the chest wall, their lobes, and fissures,

Turn the heart up and make similar incisions into the left auricle and ventricle, to investigate the analogous structures, and, in addition, the four pulmonary veins in the left auricle, and the coronary arteries coming off from the aorta. The mitral valve substitutes the tricuspid. Replace the heart and study the valves in their relation to the chest walls, and review your knowledge of "heart murmurs."

Clean off the ductus arteriosus, and trace the foetal circulation.

TWELFTH DAY.

Follow the arch of the aorta from the left ventricle, and get a clear idea of its sub-divisions, limitations, and the way it curves, not from side to side, but obliquely antero-posteriorly. Note the tube conveying the blood to the arteries, the tube conveying the air to the lungs, and the tube conveying the food to the stomach all pass each other anterior to the third dorsal vertebra.

See how the pulmonary artery divides in front, and sends one, the long right pulmonary, through the concavity of the arch, and the other, the short left branch, in front ; per contra, the trachea, behind divides and sends the long left branches through the concavity, and the short right branches behind. Look out, also, for the superficial cardiac plexus, which lies immediately below the arch of the aorta, and is formed by the left superior

sympathetic and the left inferior cervical cardiac branch of the pneumogastric.

Dissect out the venæ cavæ, superior and inferior, and note their positions in regard to the heart and the aorta.

Cut through the pulmonary arteries and veins and the venæ cavæ, and remove the heart and the ascending part of the arch of the aorta, and place them in the alcohol jar. Pull up the transverse part of the arch and study the deep cardiac plexus, which is close to the bifurcation of the trachea, and receives all of the cervical cardiac branches of the sympathetic and pneumogastric nerves of both sides, excepting the left superior sympathetic and the left inferior pneumogastric fibers, which go to the superficial cardiac plexus. Trace the pneumogastric and cardiac branches in front of the arch, and the recurrent laryngeal branch around and posterior to it.

Trace the bronchus to its bifurcation opposite the third dorsal vertebra; compare the length and course of the right and left bronchi with the length and course of the right and left pulmonary arteries.

Trace out the roots of the lungs.	{	Pulmonary artery.
		Two pulmonary veins.
		Bronchus.
		Bronchial artery and vein.
		Pulmonary plexus of nerves.
		Lymphatics and areolar tissue.

Study the relations of these structures from

before backwards, and from above downwards, and note the differences on the two sides.

Dissect the arch of the vena azygos major. Follow the whole course of the phrenic nerve in collaboration with the student upon the head. Review the structures in the middle mediastinum.

THIRTEENTH DAY.

Study the branches of the arch of the aorta, and follow them within their thoracic limits. Notice the relation of the left subclavian to the pleura. Draw the right lung towards the median line and dissect off the pleura, and do the same on the left side to expose the gangliated cord of the sympathetic, which rests upon the necks of the ribs, and the splanchnic branches, and then lift the pleura still further inwards to get at the posterior mediastinum. Follow the thoracic duct upwards and downwards. Master the vena azygos, major and minor, and the hemiazygos, and where they empty; also the superior intercostal veins. Notice the course of the œsophagus, and its relations to the aorta. Trace out the right and left pneumogastrics and the plexuses formed therefrom in the thorax; then clean off the descending thoracic aorta and its branches.

Branches of the descending thoracic aorta.	{	Pericardiac. Bronchial. Œsophageal. Mediastinal. Aortic intercostals (10).
--	---	--

Cut the trachea, and place it and the lungs in the alcohol jar. Trace the aortic intercostals, and look again at the internal intercostal muscles. Review the boundaries and contents of the posterior mediastinum. Review the structures in the four mediastinal spaces.

FOURTEENTH DAY.

Review, with the aid of "Gray" or "Morris," the diaphragm, and consider the structures in contact with its upper and lower surfaces. Review all the structures going through the superior aperture of the thorax, viz: 5 muscles: 2 sternohyoids, 2 sterno-thyroids, and longus colli; the remains of the thymus gland; apex of pleura, both sides; the trachea, œsophagus, thoracic duct; 7 arteries: the innominate, left carotid, left subclavian, 2 internal mammary, 2 superior intercostals; 2 innominate veins; nerves: 2 phrenics, 2 pneumogastrics; 2 sympathetic trunks, recurrent laryngeal, both first dorsal nerves, all the cervical cardiacs.

FIFTEENTH DAY.

In conjunction with the other dissectors, turn the body into the prone position. Denude the areas marked 7 in Diagram II (page 26).

With the student upon the head, study the trapezius muscle, its origin and insertion; and with the man upon the upper extremity, work up the latissimus dorsi muscle. The dissection of

the rhomboideus major and minor and the levator anguli scapulæ belongs to the head and neck.

Make a careful dissection of the ilio-costal region, as operations there are not infrequent. Look up in Gray or Morris the general outline and contents of this region to be now dissected, and read again the description of the lumbar fascia, page 133.

Note that the space between the spinous and transverse processes of the vertebræ posteriorly is filled in by the multifidus spinæ and erector spinæ, while between the transverse processes and the body of the vertebræ, in front lies the psoas magnus muscle, and at the tips of the transverse processes, between the crest of the ilium and the last rib, is the quadratus lumborum muscle, in front of which lies the kidney.

The skin having already been removed, you

Will find in the superficial fascia of the ilio-costal space :	{	Branches of the tenth, eleventh and twelfth dorsal nerves. Branches of the first, second and third lumbar nerves. Cutaneous branches of the intercostal arteries.
--	---	---

Remove the superficial fascia to expose the deep fascia attached to the crest of the ilium and the spinous processes of the vertebræ.

Remove the deep fascia to expose : the aponeurosis of the latissimus dorsi muscle, which arises

from the lumbar spines and from the posterior half of the iliac crest ; the external oblique muscle, with the bit of iliac crest between the two, thus forming *Petit's triangle*, in which the internal oblique can be seen, forming the floor.

Cut the origin of the latissimus dorsi and turn it outwards to show the serratus posticus inferior muscle, the external oblique arising from the outer lip of the iliac crest, the fascia lumborum (*q. v.*, page 133).

The internal oblique muscle with some small branches of the lumbar and deep circumflex iliac arteries.

Remove the internal oblique to exhibit :

The aponeurosis of the transversalis muscle.

The last dorsal nerve and arteries.

Branches of the lumbar arteries.

Remove the lumbar fascia to expose the erector spinæ, dividing above into the sacro-lumbalis and the longissimus dorsi ; and deeper still lies the multifidus spinæ muscle. And note the posterior branches of the dorsal and lumbar nerves, with some branches of the intercostal and lumbar arteries emerging from the substance of the erector spinæ.

Remove the middle layer of the lumbar fascia to expose the quadratus lumborum muscle, with the anterior branches of the three upper lumbar arteries running outwardly upon it.

Study the origin and insertion of the quadratus lumborum, and the relation of the structures to

its anterior surface ; then cut the quadratus muscle free from its insertion to expose the anterior layer of the lumbar fascia, with the branches of the last lumbar, the ilio-hypogastric and ilio-inguinal nerves, and in front of these you will find the transversalis fascia. Study upon a neighbor's subject, in which the viscera have not been removed, the relations of the abdominal viscera.

Get a clear idea of the lumbar and vertebral aponeuroses.

SIXTEENTH DAY.

Make a diagram of the intra-abdominal arteries, veins, and nerves, showing the relation between the portal and systemic systems of veins.

Take the heart and lungs from the jar, and study them in connection with the description in the larger text-books.

Draw a diagram of the interpleural space, and review its sub-divisions and the contents of each.

SEVENTEENTH DAY.

Remove the muscles from the spinous and transverse processes of the vertebræ, and with bone forceps cut through the laminae from the axis to the last lumbar (laminectomy) to expose the spinal canal. Study the membranes of the cord ; its extent, and its enlargements, the ganglia upon the posterior roots and the cauda equina.

Upon removal of the arches, look out for the posterior longitudinal veins; then remove them, with some fatty areolar tissue, to expose the dura mater. Follow one of the posterior roots to the intervertebral foramen to find its ganglion.

Dissect out the *two* posterior spinal arteries; then cut the cord on a level with the axis and the top of the sacrum, remove it from the canal and fix it with tacks upon a board, and dissect out the *one* anterior spinal artery, and the linea splendens also, on its anterior surface. Open the dura and notice the subarachnoid space. Study the pia mater, the linea splendens, the filum terminale, and the ligamentum denticulatum. See the dorsal and lumbar enlargements, and comprehend the reason for their presence. Examine the cauda equina. Make a transverse section to determine the relative position of white and grey matter, and the central canal (canal of Stilling). Demonstrate the anterior, posterior, and lateral fissures of the cord.

EIGHTEENTH DAY.

Take the abdominal viscera from the jar, and study their description in the larger text-books.

Study also the surface of the abdomen as divided into nine regions, if opportunity offers, upon a recently opened body, and learn the contents of each region with not *too* great minuteness

NINETEENTH DAY.

Remove the larynx and trachea from the jar and dissect them thoroughly ; also the pelvic viscera, and study them with the help of " Morris " or " Gray," particularly with reference to the perineum.

TWENTIETH DAY.

Make diagrams : Of the peritoneum from side to side, and from above downwards.

Of the transversalis fascia and its sub-divisions, in a similar way.

Of the perineum and its layers and boundaries.

Of the boundaries of the ischio-rectal region.

TWENTY-FIRST DAY.

Review the dissection of the hernial regions.

TWENTY-SECOND TO TWENTY-EIGHTH DAYS.

Review the whole dissection of the thorax and abdomen.

TABLE IV.—THE MORE IMPORTANT MUSCLES OF THE BACK, OF THE NECK, AND OF THE TRUNK.

MUSCLE.	ORIGIN.	INSERTION.	FUNCTION.	NERVE SUPPLY.
Trapezius	Superior curved line of occiput, ligamentum nuchæ, spinous processes of seventh cervical and all the dorsal vertebræ.	Outer third of clavicle, acromion spine of scapula.	Draws the scapula upwards and to the median line.	Spinal accessory cervical plexus.
Latissimus dorsi	Spinal processes of six lower dorsal, lumbar and sacral vertebræ, crest of ilium, and from three or four lower ribs.	Posterior lip of bicipital groove.	Draws the humerus backward and rotates it inward.	Subscapular.
Levator anguli scapulae.	Transverse processes of four upper cervical vertebræ.	Posterior border of scapula.	Elevator of superior angle of scapula.	Fifth cervical.
Rhomboideus minor	Seventh cervical, first dorsal vertebræ and ligamentum nuchæ.	Root of spine of scapula.	Draws scapula backward to median line.	Fifth cervical.
Rhomboideus major	Four or five upper dorsal vertebræ and supraspinous ligament.	Base of scapula.	Draws scapula to median line.	Fifth cervical.
Serratus posticus superior.	Last cervical and three upper dorsal vertebræ and ligamentum nuchæ.	Second, third, fourth and fifth ribs.	Inspiratory.	Cervical nerves.
Serratus posticus inferior.	Last two dorsal and three lumbar vertebræ and interspinous ligament.	Four lower ribs.	Expiratory.	Dorsal nerves.

(1) Splenius capitis et (2) colli.	Ligamentum nuchæ, last cervical and six upper dorsal vertebræ and from supraspinous ligament.	(1) Mastoid process and surface beneath; (2) transverse processes of the four upper cervical vertebræ.	Rotators and posterior flexors.	Cervical nerves.
Erector spinæ	Sacro-iliac groove, crest of ilium, spines of sacrum, lumbar and three lower dorsal.	Divides into longissimus dorsi and sacro-lumbalis.	Keeps spine erect.	Lumbar and dorsal nerves.
Complexus	Four cervical and three dorsal vertebræ.	Between the superior and inferior curved lines.	Rotators and extensors of head.	Cervical and dorsal nerves.
Rectus capitis posticus major.	Spinous process of axis.	Inferior curved line.	Rotator of head.	Suboccipital.
Rectus capitis posticus minor.	Posterior arch of atlas.	Beneath inferior curved line.	Extends the head.	Suboccipital.
Obliquus capitis inferior.	Spinous process of axis.	Transverse process of atlas.	Rotator of atlas.	Suboccipital.
Obliquus capitis superior.	Transverse process of atlas.	Between superior and inferior curved lines.	Extensor of head.	Suboccipital.
Obliquus externus abdominis.	Eight lower ribs.	Crest of ilium, linea, alba, Poupert's ligament, etc. (See body of text.)	Rotator and flexor of trunk.	Lower intercostal, ilio-hypogastric ilio-inguinal.
Obliquus internus abdominis.	Poupert's ligament, crest of ilium, lumbar fascia.	Crest of pubes and ilio-pectineal line, four lower ribs and sheath of rectus.	Rotator and flexor of trunk.	Lower intercostal, ilio-hypogastric, ilio-inguinal.

THE MORE IMPORTANT MUSCLES OF THE BACK, OF THE NECK, AND OF THE TRUNK.—*Continued.*

MUSCLE.	ORIGIN.	INSERTION.	FUNCTION.	NERVE SUPPLY.
Transversalis abdominis.	Poupart's ligament, crest of ilium, six lower ribs and fascia.	Conjoined tendon and sheath of rectus.	Rotator and flexor of trunk.	Lower intercostal, ilio-hypogastric, ilio-inguinal.
Rectus abdominis.	Crest and symphysis pubis.	Cartilages of fifth, sixth and seventh ribs.	Flexor of trunk.	Same as internal oblique.
Pyramidalis.	Os pubis and anterior pubic ligament.	Linea alba.	Accessory to rectus.	Same as internal oblique.
Quadratus lumborum.	Crest of ilium, ilio-costal ligament, third, fourth and fifth lumbar vertebrae.	Four lumbar vertebrae and last rib.	Expiratory.	Lumbar nerves.
Psoas and iliacus (see Table II).				
Diaphragm.	Ensiiform cartilage, six lower ribs, ligamenta arcuata, and lumbar vertebrae.	Central tendon.	Respiratory.	Phrenic nerve and plexus.
Levator ani.	Body and ramus of pubis, spine of ischium, and "white line."	Apex of coccyx, fibrous raphé, side of rectum beneath prostate, tendinous center of perineum.	Supports lower end of rectum and vagina.	Perineal from pudic.
Coccygeus.	Spine of ischium, lesser sacro-sciatic ligament.	Coccyx and side of sacrum.	Closes pubic outlet posteriorly, supports the coccyx.	Perineal from pudic.

The classification of the muscles of the back, as taught by Professor Piersol, is as follows :

The Muscles of the Back.

Superficial layer.	Superficial group.	{	Latissimus dorsi.
			Trapezius.
Deep layer.	Deep group.	{	Levator anguli scapulæ.
			Rhomboideus minor.
			Rhomboideus major.
			Serratus posticus superior.
			Serratus posticus inferior.
Deep layer.	Deep long muscles.	{	Splenius capitis et colli.
			Extensor dorsi communis. (See below.)
	Deep short muscles.	{	Interspinales.
			Intertransversales.
			Levatores costarum.

The extensor dorsi communis is further subdivided into :

(A) Spino-transversalis (from spinal process to transverse process).	1. Outer series.	{	Ilio-costalis.
			Accessorius.
			Cervicalis ascendens.
	2. Middle series.	{	Longissimus dorsi.
			Transversalis colli.
			Trachelo-mastoid.
	3. Inner series.	{	Spinalis dorsi.
			Spinalis colli.

(B) Transverso-spinalis
(from transverse process to spinous process).

- | | | |
|---|---|--|
| 1. Long series,
between cervical
vertebræ. | { | Semispinalis dorsi.
Semispinalis cervicis.
Semispinalis capitis. |
| 2. Middle series,
between three
vertebræ. | } | Multifidus spinæ. |
| 3. Short series,
between adjacent
vertebræ. | } | Rotatores spinæ. |

INDEX. . .

- ABDOMEN, dissection of, 108,
 168
 Abdomino-scrotal orifice, 109
 Ansa hypoglossi, 104
 Aorta, abdominal, 131
 arch of, 158, 159, 161
 descending thoracic, 159,
 163
 Aponeurosis—
 of scalp, 69
 supra-hyoid, 82
 temporal, 73
 vertebral, 93
 Arch, crural, 38
 deep, 24
 palmar, superficial, 22, 31
 Arches, palatine, 95
 Arteries—
 acromio-thoracic, 14, 15
 alar thoracic, 14
 anastomotica magna of
 thigh, 38, 45
 of arm, 18
 angular, 82
 anterior peroneal, 62
 tibial, 47, 60, 62
 articular of popliteal, 61
 auricular, posterior, 70, 85
 axillary, 16
 axis, thyroid, 90
 coeliac, 130, 131
 azygos, 61
 brachial, course, 18
 of the bulb of urethra, 136
 carotid, common, 81
 internal, 81
 external, 77, 85
 Arteries—
 carpal, of radial, anterior,
 23, 25, 31
 carpal of ulnar, 31
 centralis retinae, 97
 cervical, ascending, 94
 ciliary, long, 95
 circumflex, anterior of arm,
 16
 posterior of arm, 16
 circumflexa ilii, superficial,
 38
 clitoridis, 149
 coeliac axis, 130
 colica dextra, 127
 media, 127
 sinistra, 127
 comes nervi ischiatici, 57
 mediani, 31
 phrenici, 158
 common femoral, 43
 iliac, 153
 communicating, deep, 31
 crucial anastomosis, 57
 descending palatine, 100
 digital of foot, 51
 of great toe, 48, 51
 of hand, 22
 dorsalis indicis, 31
 pollicis, 31
 dorsal of penis, 152
 dorsalis hallucis, 48
 linguae, 84
 pedis, 48
 scapulæ, 16
 epigastric, superficial, 38
 deep, 112, 152

Arteries—

- external carotid, 85
 - circumflex, 43
- external iliac, 152
 - pubic, 38, 42
 - deep, 42
- facial, 82, 85
- femoral, 40, 42, 43
- frontal, 70
- gastric, 130
- gastro-duodenalis, 130
 - epiploica, dextra, 130
 - sinistra, 130
- gluteal, 55
- hæmorrhoidal, 127, 152
- hepatic, 130
- iliac, 153
 - internal, 152
- inferior dental, 86
- infraorbital, 76
- innominate, 158
- intercostal, anterior, 15
 - superior, 90
- internal circumflex, 43
 - mammary, 90, 157
 - maxillary, 85, 86
- interosseous, anterior, 20,
 - 29, 31
 - common, 31
 - dorsal of hand, 31
 - of foot, 48
 - palmar, 35
 - perforating of, 51
 - posterior, 20, 29, 31
 - recurrent, 31
- lachrymal, 96
- lingual, 85
- lumbar, 132
- malleolar, 47
- median, 20, 31
- meningea, 86
- meningeal, middle, 86
- mesenteric, 127, 131
- metacarpal, 31
- metatarsal, 48

Arteries—

- mylo-hyoid, 83
- obturator, 46
- occipital, 70, 85, 92
- ophthalmic, 97
- ovarian, 151
- palmar, arch, deep, 24, 31
 - superficial, 22
- palmaris profunda, 25
- pancreatic, 130
- pancreatico-duodenalis, 130
- perforating of plantar, 51
 - of profunda, 43, 58
- peroneal, 62
- pharyngeal, ascending, 85
- plantar, external, 50, 51
 - internal, 50
- popliteal, 59, 60, 61
- posterior circumflex, 16
 - scapular, 93
 - tibial, 50, 62
- princeps cervicis, 94
 - pollicis, 24
- profunda femoris, 43, 94
 - inferior, 18
 - superior, 18
- pterygoid, 86
- pubic, 55, 56
- pyloric, 130
- radial, 20
 - recurrent, 20, 31
 - in palm, 31
- radialis indicis, 24
- recurrent tibial, 47
- renal, 131
- sacra media, 131
- sciatic, 55, 57
- scapular, posterior, 93
- sigmoid, 127
- spermatic, 156
- spheno-palatine, 100
- splenic, 130
- sterno-mastoid, inferior, 79
 - middle, 79
 - superior, 79

Arteries—

- subclavian, branches of, 90, 160
- subscapular, 16
- superficial circumflex ilii, 42
 - epigastric, 38, 42
 - external pudic, 38, 42
- superficialis volæ, 22, 23, 31
- superior epigastric, 158
 - external articular, 61
 - hæmorrhoidal, 127
 - intercostal, 157
 - internal articular, 61
 - profunda, 18
 - thyroid, 85
- suprascapular, 90
- sural, 61
- tarsal, 48
- temporal, 85
 - anterior, 70
 - posterior, 70
- thoracica acromio, 14, 15, 16
 - alaris, 16
 - long, 16
 - superior, 15, 16
- thyroid axis, 90
 - inferior, 90
- transversalis colli, 90
- ulnar, 20, 31
 - recurrent, 20, 31
 - palmar recurrent, 24
 - ulnaris profunda, 25
- uterine, 151, 152
- vaginal, 152
- vasa intestini tenuis, 127
- vertebral, 90, 93
- vesical, 152
- Axilla, boundaries of, 16
 - dissection of, 15, 16
 - fascias of, 14, 15, 16
- BACK, muscles of, 173
- Bladder, 115
- Brain, dissection of, 74

- Burns, falciform process of, 41
- Bursæ—
 - prepatella, 46
 - under gluteus maximus, 55
 - under tuberosity of ischium, 55

- CANAL, Alcock's, 147
 - crural or femoral, 39
 - of Hunter, 43, 44, 46
- Canthus, 73
- Cartilages, tarsal, 73
- Caruncula lachrymalis, 73
- Cord, spermatic, 117, 156
 - of brachial plexus, 16, 17
 - lumbo-sacral, 135
- Crural arch, see Poupart's ligament.
 - canal, 41

DIAGRAM—

- I, 15
- II, 26
- III, 39
- IV, 53
- V, 69
- VI, 79
- VII, 108
- VIII, 114, 115
- IX, 120
- X, 121
- XI, 143
- Diaphragm, 131, 172
- Diogenes, cup of, 35
- Dissection—
 - of the head and neck, 69
 - of the lower extremity, 38
 - of the orbit, 95
 - of the female perineum, 147
 - of the male perineum, 143
 - of the thorax and abdomen, 157
 - of the upper extremity, 14
- Duct, nasal, 100
- thoracic, 131

Ducts—

- of the parotid gland, 77
- of submaxillary gland, 82
- Wharton's, 82

Ductus, common ejaculatory,
151

Duodenum, 129

EAR, muscles of, 70

Elbow, triangle at bend of, 20

Eustachian tube, 95

Eye, muscles of, 96

Eyelids, structure of, 73

FACE, dissection of, 69

Falx cerebri, 74

Fascia, of the axilla, 15

bicipital, 19

Buck's, 154

cervical, deep, 80

clavi-pectoral, 15

iliac, deep, 40, 134

of the leg, 44, 45, 60

lumbar, 133

pectoral, 14

superficial, 38

plantar, 49

propria of hernia, 41

temporal, 73

Fasciæ—

anal, 136

Colles', 109, 137, 142, 144

of the arm, 18

of the forearm, 19, 28

cribriform, 38, 39, 41

falciform of Burns, 40

lata of thigh, 39, 54

of metacarpus, 31

obturator, 46, 138

palmar, 21

recto-vesical, 117, 135

superficial of abdomen, 108

of thigh, 14

transversalis, 117

Faucium, isthmus, 95

Fissura palpebrarum, 73

Flexor tendons in palm,
sheaths of, 23

Foramen of Winslow, 125

Foramini Thebesii, 160

infraorbital, 76

Fossæ, ischio-rectal, 136

inguinal, 112

GANGLIA, abdominal, sympa-
thetic, 131

cervical, 89

ophthalmic, 97

otic, 106

spheno-palatine 100, 106

submaxillary, 84

Glands—

of Bartholine, 141

Cowper's, 138

epitrochlear, 18

lachrymal, 96

lymphatic of elbow, 18

of inguinal, 109

Meibomian, 73

parotid, 77

popliteal, 58

salivary sublingual, 84

submaxillary, 82

Glabella, 69, 72

Glosso-pharyngeal nerve, 84,
88, 105, 106

HAMSTRING muscles, 61

Heart, dissection of, 160

Hernia—

direct inguinal, 118

femoral, anatomy of parts
concerned, 41

oblique inguinal, 118

Hypoglossal nerve, 82, 84, 104,
105

ILIO-TIBIAL band, 42, 44

Inion, 69

JOINTS, dissection of, 30, 63
 KIDNEYS, 125
 LABIA majora, 147
 minora, 147
 Lachrymal gland, 73, 96
 sac, 73
 Larynx, dissection of, 101
 muscles of, 106, 107
 Ligaments—
 brevia, 23, 50
 falciform, 112
 great sacro-ischiatic, 55, 57
 Gimbernat's, 110
 Hay's, 40
 of hip joint, 63
 annular of ankle, 43
 of wrist, 21
 of arm, 23, 34
 of leg, 65
 metacarpus, 21
 of jaw, internal lateral, 86
 lesser sacro-ischiatic, 57
 nuchæ, 92
 palpebral, 73
 of pterygo-maxillary, 87
 posticum of Winslow, 60
 Poupart, 38
 sciatic, 57
 stylorum, 81
 suspensory of penis, 156
 triangular of ex. oblique, 110
 of urethra, 137, 140
 vaginalia, 50
 vasculosa, 23, 50
 Winslow, posticum of, 60
 arcuata, 130
 Line, white, of rectum, 143
 of fascia, 151
 Linea alba, 112
 Liver, 125, 131
 Lower, tubercle of, 160
 Lungs, 162
 Lymphatic glands of small
 intestine, 127

MAMMARY gland, 14
 arteries, 14
 Meckel's ganglion, 100, 106
 Mediastinum, 158, 159
 Membrane, costo-coracoid, 15
 obturator, 46
 subpubic, 138, 145
 Mesentery, the, 126
 Morgagni, sinus of, 94
 Muscles—
 abdominal, 171, 172
 abductor indicis, 35
 abductor minimi digiti, 24, 35
 pedis, 49, 67
 pollicis, 33, 49
 pedis, 49, 67
 accessorius, 50
 adductor brevis, 45, 65
 longus, 45, 65
 magnus, 45, 65
 pollicis, 23, 35
 pedis, 50, 51, 68
 anconeus, 27, 32, 37
 arytæno epiglottideus, 107
 arytænoideus, 106
 attollens aurem, 70, 102
 atrahens aurem, 70, 102
 azygos uvulæ, 106
 biceps of arm, 18, 33
 of leg, 67
 brachialis anticus, 18, 32
 buccinator, 82, 103
 coccygeus, 172
 complexus, 93
 compressor nasi, 102
 coraco-brachialis, 18, 26, 33
 corrugator supercilii, 72, 102
 crico-arytænoideus lateralis,
 106
 posticus, 106
 crico-thyroideus, 106
 crureus, 64
 deltoid, 14, 15, 25, 33
 depressor anguli oris, 76,
 103

Muscles—

- labii inferioris, 76, 103
- diaphragm, 172
- digastricus, 81, 104
- erector clitoridis, 141
- spinæ, 171
- extensor brevis digitorum, 28, 48, 65
- carpi radialis brevior, 28, 37
- longior, 28, 32, 36
- carpi ulnaris, 28, 37
- communis digitorum, 28, 37
- indicis, 37
- longus digitorum 45, 65
- minimi digiti, 28, 37
- ossis met. pollicis, 28, 37
- primi internodii pollicis, 28, 37
- secundi internodii pollicis, 28, 37
- proprius pollicis, 45, 65
- flexor accessorius, 68
- brevis digitorum, 49, 67
- minimi digiti, 24, 35, 58
- pedis, 51
- pollicis, 23, 35, 68
- pedis, 51
- carpi radialis, 19, 33
- ulnaris, 19, 34
- longus digitorum, 50, 60, 67
- pollicis, 23, 34, 60, 67
- profundus digitorum, 23, 34
- sublimis digitorum, 19, 23, 34
- gastrocnemius, 59, 67
- gemelli, 55, 66
- genio-hyo-glossus, 84, 104
- hyoid, 104
- gluteus maximus, 54, 66
- medius, 54, 55, 66

Muscles—

- minimus, 57, 66
- gracilis, 45, 64
- hyo-glossus, 84, 104
- iliacus, 45, 64
- inferior constrictor of pharynx, 91, 106
- infraspinatus, 36
- intercostal, 14
- interosseous of foot, 68
- of hand, 25, 35
- latissimus dorsi, 25, 170
- levator anguli oris, 76, 103
- scapulæ, 93, 170
- ani, 172
- labii inferioris, 76
- superioris alæque nasi, 75
- levator labii proprius, 75
- palati, 106
- palpebrarum, 73, 96, 103
- longus colli, 104
- lumbricales, 24, 34, 68
- pedis, 50
- masseter, 76, 103
- of mastication, 87, 103
- middle constrictor of pharynx, 84, 91, 106
- mylo-hyoid, 83, 84, 104
- obliquus externus abdominis, 110
- inferior, 103
- internus abdominis, 111, 171
- superior, 93, 96, 103
- capitis, 93, 103
- obturator externus, 55, 57, 65
- internus, 55, 57, 66
- occipito-frontalis, 69, 102
- opponens digiti minimi, 24, 35
- pollicis, 23, 35
- orbicularis oris, 76, 103
- palpebrarum, 72, 73, 102

Muscles—

- omo-hyoid, 80, 104
- palato-glossus, 106
 - pharyngeus, 106
- palmaris brevis, 21, 35
- palmaris longus, 34
- pectineus, 45, 64
- pectoralis major, 14, 33
 - minor, 15, 33
- peronei, 48, 65
- Piersol's classification, 173
- plantaris, 59, 67
- platysma myoides, 14, 104
- palmaris longus, 19, 34
- popliteus, 67
- pronator quadratus, 23, 34
 - radii teres, 19, 33
- psoas magnus, 45, 64, 134
 - parvus, 64, 134
- ptergoidei, 103, 104
- pyramidalis, 172
 - nasi, 72, 102
- pyriformis, 55, 66
- quadratus femoris, 55, 66
 - lumborum, 172
- quadriceps femoris, 42, 44
- recti of the eye, 98, 103
- rectus abdominis, 111, 172
- rectus capitis anticus major,
 - 92, 105
 - minor, 92, 105
- rectus capitis lateralis, 92, 105
 - posticus major, 171
 - minor, 171
 - femoris, 14
- retrahens aurem, 70, 102
- risorius, 77, 103
- rhomboideus, 170
- sartorius, 43, 64
- scalenus anticus, 91, 105
 - medius, 92, 105
 - posticus, 92, 105
- semimembranosus, 67
- semitendinosus, 66

Muscles—

- serratus magnus, 26, 37, 93
 - posticus inferior, 93, 170
 - superior, 93, 170
- soleus, 59, 67
- splenius capitis et colli, 171,
- sterno-cleido mastoideus, 79, 104
 - hyoid, 80, 104
 - thyroid, 80, 104
- stylo-glossus, 84, 105
 - hyoideus, 81, 104
 - pharyngeus, 91, 105
- subconeus, 36
- subclavius, 15, 33
- subcrureus, 64
- sublimis digitorum, 19, 23, 34
- subscapularis, 33
- superior retractor of pharynx, 91, 105
- supinator brevis, 29, 37
 - radii longus, 19, 32, 36
- supraspinatus, 36
- temporal, 103
- tensor vaginæ femoris, 42, 64
 - palati, 106
 - tarsi, 102
- teres major, 36
 - minor, 36
- thyro-arytænoideus, 107
 - epiglottideus, 107
 - hyoid, 80, 104
- tibialis anticus, 45, 65
- posticus, 60, 67
- trachelo-mastoid, 93
- transversalis abdominis, 111 172
 - pedis, 51, 68
- trapezius, 25, 92, 170
- triangularis sterni, 158
- triceps extensor cubiti, 26, 32, 36
- vastus externus, 64
 - internus, 64

Muscles—

- zygomaticus major, 103
- minor, 103

Musculo-spiral groove, 26

NASAL fossæ, posterior openings of, 100

Neck, dissection of, 80

Nerves—

- acromial, 78
- anterior crural, 43, 64, 134
- cutaneous of abdomen, 134
- tibial, 47, 65
- auricularis magnus, 71, 78, 89
- auriculo-temporal, 71, 86
- auricular posterior, 71
- buccal branch of facial, 77
- carotid of pharyngeal 88
- cervical, 33, 105, 170, 171
- clavicular, branch of, 78
- cervical, superficial, 78
- cervico-facial, 77
- chorda tympani, 104
- ciliary, 97
- circumflex, 17, 33, 36
- communicans peronei, 55
- poplitei, 55
- noni, 104
- crural branch of genito-crural, 134
- cutaneous of neck, 78
- of thigh, 43
- dental inferior, 86
- descendens noni, 104
- dorsal branch of ulnar, 29
- external cutaneous of arm, 16
- of leg, 38, 42, 53
- laryngeal, 81, 88
- respiratory of Bell, 89
- facial, 77, 104
- cervical branch of, 103
- fifth pair, 97, 101, 103
- fourth pair, 96, 103

Nerves—

- frontal, 96
- genital branch of genito-crural, 43
- genito-crural, 38, 43
- gluteal, 53, 66, 153
- glosso-pharyngeal, 84, 88, 105, 106
- great sciatic, 55, 61, 105, 106
- occipital, 71, 92, 94
- gustatory, 84, 87
- hypo-glossal, 82, 84, 104, 105
- ilio-hypogastric, 53, 109, 134, 171, 172
- inguinal, 38, 109, 134, 171, 172
- inferior dental, 104
- laryngeal or recurrent, 81, 90
- inframaxillary of facial, 77
- orbital or facial, 77
- intercostal, 14
- intercosto-humeral, 17
- intercostal, lateral cutaneous of, 14
- internal cutaneous of arm, 17, 19
- interosseous, anterior, 29, 34
- posterior, 29, 37
- lachrymal, 96
- laryngeal, 88, 106, 107
- lesser cutaneous of arm, 17
- sciatic, 55, 56, 61
- lingual, 84, 87
- of glosso-pharyngeal, 84, 88
- long or inferior pudendal, 56, 61
- long saphenous, 43
- lumbar, 53, 64, 171
- maxillary, inferior, 87, 102
- median, 16, 17, 31, 33, 34
- 35

Nerves—

- median in the palm, 31
- masseteric, 97
- motor oculi, 97
- musculo-cutaneous, 33, 44, 47, 65
 - spiral, 17, 18, 20, 36
- obturator, 46, 64, 65, 134
- occipitalis major, 71, 92, 94
 - minor, 71, 78, 89, 102
 - sub, 93, 105, 171
- optic, 97, 98
- palatine, 100
- palmar branch of median, 31
 - of ulnar, 32
- palmar cutaneous of median, 21, 31
- perineal, superficial, 152
- peroneal, 47
- pes anserinus, 77
- pharyngeal, 105
- phrenic, 89, 172
- plantar, 48, 52, 67, 68
- pneumogastric, 88
- popliteal, 60, 65, 67
- portio dura, 77
- posterior auricular, 77
 - tibial, 50, 62, 67
 - thoracic, 90
- pubendal, inferior, 61
- pubic, 56, 153
- radial, 29
- recurrent or inferior laryngeal, 106, 107
- sacral, 53
- saphenous, long, 44, 47
 - short, 47
- sciatic, great, 55, 59, 60, 61, 66, 153
 - lesser, 55, 61
- sixth pair, 97, 102
- spinal accessory, 104, 170
- subscapular, 17, 33, 36, 170
- superior gluteal, 57, 64, 67
 - maxillary, 101

Nerves—

- supraclavicular, 78
 - maxillary branch of facial, 77
 - orbital, 71
 - scapular, 36
 - trochlear, 71
- sympathetic, 132
- temporo-facial, 77
 - malar, 71
- third pair, 97, 102
- thoracic, anterior, 16, 17, 33
 - long, 89
- trifacial, 97, 101, 103
- ulnar, 17, 18, 20, 32, 33, 34, 35
 - deep palmar branch of, 29
 - dorsal cutaneous of, 29
- Nervus accessorius, 104
- Nose, dissection of, 100
- ESOPHAGUS, 101
- Orbit, dissection of, 95, 97
- Os hyoides, 74
- Otic ganglion, 106
- Ovaries, 151
- PALATE, arteries of, 95
- Palm, dissection of, 42
- Papilla lachrymalis, 73
- Parotid gland, 77
 - socia, 76, 77
- Penis, 154
- Perineum, female, 140
 - male, 135, 136
- Peritoneum, 117, 121, 124
- Pes anserinus, 77
- Pharynx, dissection of, 94
 - muscles of, 91
- Piersol's classification, 173
- Pinna of ear, 70
- Platysma, 14, 104
- Pleura, 158
- Plexus of nerves—
 - axillary, 16, 89

- Plexus of nerves—
 brachial, 16, 90
 cervical, 14, 78, 89
 hypogastric, 132
 infraorbital, 76
 lumbar, 134
 sacral, 66, 153
 solar, 130, 134
 sympathetic, 130
 Popliteal space, 59
 Pouches, perineal, 136, 137,
 140
 recto-vaginal, 121
 Poupart's ligament, 38
 Process, coracoid, 16
- RECEPTACULUM chyli, 131
 Ring, abdomino-scrotal, 109
 crural or femoral, 41
 external abdominal, 110
 internal abdominal, 112
- SAPHENOUS, openings of fascia
 lata, 38
 Scalp, dissection of, 69
 Scrotum, dissection of, 154
 Septum, intermuscular of arm,
 18
 of thigh, 42
 crurale, 41
 nasi, 99
 Sheath for extensor tendons of
 wrist, 29
 of femoral vessels, 41
 of penis, 154
 vaginal of hand, 23
 Sinuses, nasal, 100
 of Morgagni, 94
 Sole of the foot, 49
 Space, interpleural, 158
 axillary, 16
 ilio-costal, 165
 popliteal, 59, 60
 Spermatic cord, 117
- Spinal accessory, 79
 cord, dissection of, 167
 Spleen, 125
 Steno's duct, 77
 Stenson's duct, 77
 Subarachnoid fluid, 101
 Suprahyoid aponeurosis, 82
- TENDO Achillis, 67
 oculi, 73
 palpebrarum, 73
 Tendon, central of diaphragm,
 172
 of perineum, 143
 Testes, dissection of, 155
 Thorax, dissection of, 157, 164
 Tongue, dissection of, 101
 Tonsils, pillars of, 96
 Trachea, 101
 Triangle, at bend of elbow, 20
 of Hesselbach, 112
 of neck, 101
 of perineum, 135
 of Petit, 166
 of Scarpa, 42, 46
 suboccipital, 93
 Trochlea, of superior oblique
 muscle, 96
 Tube, eustachian, 95
 Tubercle, carotid, 90
 of Lower, 160
 scalene, 90
- URACHUS, 112
 Ureter, 150
 Urethra, female, 142
 male, 145
 Uvula, 95
- VAGINA, 142
 Valsalva, sinuses of, 160
 Valves, 160
 Vas deferens, 117, 150
 Veins—
 angular, 82

Veins—

anterior jugular, 78
 axillary, 16
 basilic, 17
 cephalic, 14, 15, 17
 circumflex ilii, 42
 epigastric, 38
 external jugular, 76, 78
 facial, 82
 femoral, 40
 frontal, 72
 innominate, 88, 158
 internal jugular, 88
 lingual, 82
 median, 18
 basilic, 17
 cephalic, 17
 profunda, 16
 ophthalmic, 97
 pampiniform, 156
 portal, 128
 posterior jugular, 78
 pterygoid plexus of, 86

Veins—

radial, 18
 salvatella, 27
 saphenous, long or internal,
 38, 44
 short or external, 44
 short or posterior, 44
 supraorbital, 72
 temporo-maxillary, 77
 ulnar, anterior, 18
 posterior, 27
 vertebral, 93
 Venous M, 17
 Vena cava, inferior, 131, 162
 superior, 162
 azygos major, 131, 163
 Vestibule in female, 140

 WINSLOW, foramen of, 123
 posterior ligament of, 60

 ZINN, zone of, 95

