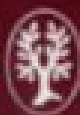
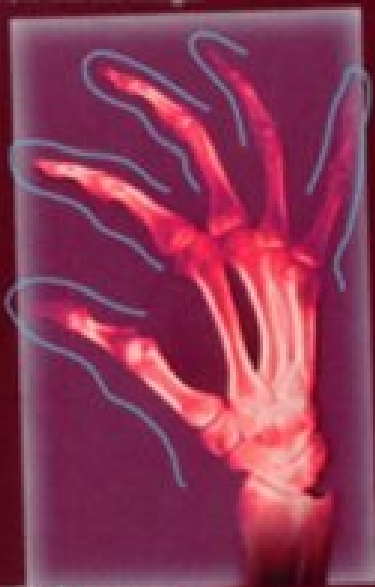
THIEME FLEXIBOOK

Torsten B. Moeller  
Emil Reif

Pocket Atlas of  
**Radiographic Anatomy**

*Second edition, revised and enlarged*



**Thieme**

# Pocket Atlas of Radiographic Anatomy

Second edition, revised and enlarged

Torsten B. Moeller, M.D.

Am Caritas-Krankenhaus  
Dillingen/Saar  
Germany

Emil Reif, M.D.

Am Caritas-Krankenhaus  
Dillingen/Saar  
Germany

243 Illustrations



Thieme  
Stuttgart · New York 2000



*Library of Congress Cataloging-in-Publication Data*

Moeller, Torsten B.

[Taschenatlas der Roentgenanatomic. English]

Pocket atlas of radiographic anatomy / Torsten B. Moeller, Emil Reif.—2nd ed., rev. and enlarged.

p. cm.

Translation of the 1998 German ed.

Includes bibliographical references and index.

ISBN 3-13-784202-6—ISBN 0-86577-874-4

1. Human anatomy—Atlases. 2. Radiography, Medical—Atlases. I. Title. II. Reif, Emil. [DNLM: 1. Anatomy—Atlases. 2. Anatomy—Handbooks. 3. Radiography—Atlases.

4. Radiography—Handbooks. QS 17 M726t 2000 a]

QM25.M55613 2000

611'.0022'221—dc21

99-040802

Translated by John Grossman, Berlin, Germany

This book is an authorized revised and enlarged translation of the 2nd German edition published and copyrighted 1998 by Georg Thieme Verlag, Stuttgart, Germany. Title of the German edition: Taschenatlas der Röntgenanatomic

Some of the product names, patents, and registered designs referred to in this book are in fact registered trademarks or proprietary names, even though specific reference to this fact is not always made in the text. Therefore, the appearance of a name without designation as proprietary is not to be construed as a representation by the publisher that it is in the public domain. This book, including all parts thereof, is legally protected by copyright. Any use, exploitation, or commercialization outside the narrow limits set by copyright legislation, without the publisher's consent, is illegal and liable to prosecution. This applies in particular to photostat reproduction, copying, mimeographing or duplication of any kind, translating, preparation of microfilms, and electronic data processing and storage.

© 2000 Georg Thieme Verlag,  
Rüdigerstrasse 14,  
D-70469 Stuttgart, Germany  
Thieme New York, 333 Seventh Avenue,  
New York, NY 10001, USA

Typesetting by primustype R. Hurler  
GmbH, D-73274 Notzingen, Germany  
typeset on Textline/HerculesPro  
Printed in Germany by Offizin Andersen  
Nexö, Leipzig

ISBN 3-13-784202-6 (GTV)  
ISBN 0-86577-874-4 (TNY) 1 2 3 4 5 6

**Important Note:** Medicine is an ever-changing science undergoing continual development. Research and clinical experience are continually expanding our knowledge, in particular our knowledge of proper treatment and drug therapy. Insofar as this book mentions any dosage or application, readers may rest assured that the authors, editors, and publishers have made every effort to ensure that such references are in accordance with **the state of knowledge at the time of production of the book.**

Nevertheless, this does not involve, imply, or express any guarantee or responsibility on the part of the publishers in respect to any dosage instructions and forms of application stated in the book. **Every user is requested to examine carefully** the manufacturer's leaflets accompanying each drug and to check, if necessary in consultation with a physician or specialist, whether the dosage schedules mentioned therein or the contraindications stated by the manufacturers differ from the statements made in the present book. Such examination is particularly important with drugs that are either rarely used or have been newly released on the market. Every dosage schedule or every form of application used is entirely at the user's own risk and responsibility. The authors and publishers request every user to report to the publishers any discrepancies or inaccuracies noticed.

---

To Bernie and Arlene,  
Bryan and Nancy Riegner,  
Southfield, Michigan

Despite the introduction of digital radiography, the process of obtaining and evaluating radiographic images has not changed significantly in recent years, nor has the importance of a good knowledge of the anatomic details of conventional radiographs. This book is a case in point. We were very pleased with the wide distribution of the first edition, which has been an additional incentive to improve a number of details, include even better images, replace some of the drawings, and include a few new radiographs. The structure of the second edition also strictly follows that of *Normal Findings in Radiology* and *Pocket Atlas of Radiographic Positioning*. Our intention in this is to present clearly and concisely each respective chapter of conventional diagnostic radiography and to avoid unnecessary repetition. At the same time, we give the reader the opportunity to examine different aspects of the same material with the same degree of clarity, which may prove important on another occasion. We have employed a consistent style and the same radiographs to structure the material and make it more readily accessible for reading, learning, or reference purposes.

Dillingen, Summer 1999

Torsten B. Möller  
Emil Reif

**Skeletal Imaging 1**

**Skull 2**

Posterior-Anterior View of the Skull 3

Lateral View of the Skull 5

Towne View of the Posterior Skull 7

Waters View of the Nasal Sinuses 9

Occipitofrontal View of the Nasal Sinuses 11

Posterior-Anterior View of the Orbit 13

Rhese View of the Orbit 15  
Maxilla 17

Ramus of the Mandible 19

Clementschietsch View of the Mandible 21

Pantomogram of the Jaw and Facial Bones 23

**Skull: Lateral View of the Nose 24**

Zygomatic Arch 25

**Skull 26**

Base of the Skull 27

Altschul View of the Petrous Ridge 29

Schüller View of the Petrous Bone 31

Stenvers View of the Petrous Bone 33

Mayer View of the Petrous Bone 35

Lateral View of the Sella Turcica 37

Anterior-Posterior View of the Sella Turcica 39

**Spine 40**

Anterior-Posterior Full-length View of the Spine 41

Anterior-Posterior View of the Cervical Spine 43

Lateral View of the Cervical Spine 45

Oblique View of the Cervical Spine 47

Anterior-Posterior View of the Thoracic Spine 49

Lateral View of the Thoracic Spine 51

Anterior-Posterior View of the Lumbar Spine 53

Lateral View of the Lumbar Spine 55

Oblique View of the Lumbar Spine 57

Anterior-Posterior View of the Pelvis 59

Anterior-Posterior View of the Pelvis in a Child 61

Inlet View of the Pelvis 63

Guthmann's View of the Pelvis 65

Iliac Wing View of the Pelvis 67

Obturator View of the Pelvis 69

Thirty-degree Anterior Oblique View of the Sacroiliac Joint 71

Anterior-Posterior View of the Sacrum 73

Lateral View of the Sacrum 75

Anterior-Posterior View of the Coccyx 77

Lateral View of the Coccyx 79

**Upper Extremities 80**

Osseous Hemithorax 81

Anterior-Posterior View of the Sternum 83

Lateral View of the Sternum 85

Stress View of Both Shoulders 87

Anterior-Posterior View of the Clavicle 89

Oblique View of the Clavicle 91

Acromioclavicular Joint 93

## VI Table of Contents

- Anterior-Posterior View of the Scapula 95
- Lateral View of the Scapula 97
- Anterior-Posterior View of the Shoulder 99
- Anterior-Posterior Abduction View of the Shoulder 101
- Axial View of the Shoulder 103
- Tangential View of the Shoulder 105
- Transthoracic View of the Shoulder 107
- Anterior-Posterior View of the Upper Arm 109
- Lateral View of the Upper Arm 111
- Anterior-Posterior View of the Elbow 113
- Lateral View of the Elbow 115
- Axial View of the Elbow 117
- Oblique View of the Radius 119
- Anterior-Posterior View of the Forearm 121
- Lateral View of the Forearm 123
- Anterior-Posterior View of the Hand 125
- Oblique View of the Hand 127
- Anterior-Posterior View of the Wrist 129
- Lateral View of the Wrist 131
- Carpal Tunnel 133
- Scaphoid Views 135
- Special View of the Pisiform 137
- Finger in Two Planes 139
- Lower Extremities 140**
- Full-length Anterior-Posterior Weight-bearing View of the Leg 141
- Anterior-Posterior View of the Hip 143
- Lauenstein View of the Hip 145
- Tangential View of the Femoral Head (Schneider I) 147
- Tangential View of the Femoral Head (Schneider II) 149
- Axial View of the Hip 151
- Anterior-Posterior View of the Thigh 153
- Lateral View of the Thigh 155
- Anterior-Posterior View of the Knee 157
- Lateral View of the Knee 159
- Frik Tunnel View of the Knee 161
- Thirty, Sixty, and Ninety-degree Views of the Patella 163
- Anterior-Posterior View of the Lower Leg 165
- Lateral View of the Lower Leg 167
- Anterior-Posterior View of the Ankle 169
- Lateral View of the Ankle 171
- Anterior-Posterior View of the Foot 173
- Lateral View of the Foot 175
- Lateral View of the Calcaneus 177
- Tangential View of the Calcaneus 179
- Anterior-Posterior View of the Metatarsals 181
- Oblique View of the Metatarsals 183
- Anterior-Posterior View of the Forefoot 185
- Oblique View of the Forefoot 187
- Anterior-Posterior and Lateral Views of the Great Toe 189
- Anatomy of Miscellaneous Plain Films 191**
- Routine Radiographs 192**
- Posterior-Anterior Chest Radiograph 193

Posterior-Anterior Chest Radiograph (Heart and Major Vessels) 195

Lateral Chest 197

Segments of the lung 199

Anterior Oblique View of the Right Chest 201

Anterior Oblique View of the Left Chest 203

Abdomen with the Patient Standing 205

Abdomen with the Patient Supine 207

**Spot Images 208**

Craniocaudal Mammogram 209

Mediolateral Mammogram 211

Anterior-Posterior Spot View of the Trachea 213

Lateral Spot View of the Trachea 215

**Tomography 216**

Anterior-Posterior Tomogram of the Pulmonary Hilum 217

Lateral Tomogram of the Right Hilum of the Lung 219

Tomogram of the Sacroiliac Joint 221

**Contrast Studies 223**

**Gastrointestinal System 224**

Anterior-Posterior View of the Hypopharynx 225

Lateral View of the Hypopharynx 227

Esophagus 229

Esophagus and Stomach 231

Stomach 233

Stomach and Duodenum 235

Stomach and Small Bowel 237

Small Bowel 239

Spot Film of the Ileocecal Region 241

Colon 243

Rectum 245

Defecography 247

**Intravenous Contrast Studies 248**

Intravenous Urogram 249

Intravenous Cholecystocholangiogram 251

**Arthrography 252**

Posterior-Anterior Wrist Arthrogram 253

Lateral Wrist Arthrogram 255

Anterior-Posterior Shoulder Arthrogram 257

Oblique Shoulder Arthrogram 259

Knee Arthrogram 261

Ankle Arthrogram 263

**Arteriography 264**

Anterior-Posterior Internal Carotid Arteriogram, Arterial Phase 265

Lateral Internal Carotid Arteriogram, Arterial Phase 267

Anterior-Posterior Internal Carotid Arteriogram, Venous Phase 269

Lateral Internal Carotid Arteriogram, Venous Phase 271

Anterior-Posterior Vertebral Arteriogram, Arterial Phase 273

Lateral Vertebral Arteriogram, Arterial Phase 275

Anterior-Posterior Vertebral Arteriogram, Venous Phase 277

Lateral Vertebral Arteriogram, Venous Phase 279

Anterior-Posterior Angiogram of the Cervical Vessels 281

Anterior-Posterior Aortic Arch Angiogram 283

- Pulmonary Arteriogram, Arterial Phase 285
- Anterior-Posterior Pulmonary Arteriogram, Venous Phase 287
- Celiac Trunk Angiogram, Arterial Phase 289
- Celiac Trunk Angiogram, Venous Phase 291
- Superior Mesenteric Arteriogram, Arterial Phase 293
- Superior Mesenteric Arteriogram, Venous Phase 295
- Renal Arteriogram, Arterial Phase 297
- Renal Arteriogram, Venous Phase 299
- Pelvic Aortic Angiogram 301
- Lower Extremity Angiogram of the Thigh 303
- Lower Extremity Angiogram of the Knee 305
- Lower Extremity Angiogram of the Lower Leg 307
- Lower Extremity Angiogram of the Ankle and Foot 309
- Venography 310**
- Anterior-Posterior Superior Vena Cava Venogram 311
- Anterior-Posterior Inferior Vena Cava Venogram 313
- Lateral Inferior Vena Cava Venogram 315
- Upper Extremity Venogram of the Axilla 317
- Upper Extremity Venogram of the Forearm 319
- Lower Extremity Venogram 321
- Special Studies 323**
- Special Studies 324**
- Anterior-Posterior Thoracic Myelogram 325
- Lateral Thoracic Myelogram 327
- Anterior-Posterior Lumbar Myelogram 329
- Lateral Lumbar Myelogram 331
- Oblique Lumbar Myelogram 333
- Anterior-Posterior Bipedal Lymphangiogram, Channel Phase 335
- Oblique Bipedal Lymphangiogram, Channel Phase 337
- Anterior-Posterior Bipedal Lymphangiogram, Nodal Phase 339
- Anterior-Posterior Left Bronchogram 341
- Lateral Left Bronchogram 343
- Lateral Parotid Sialogram 345
- Anterior-Posterior Parotid Sialogram 347
- Hysterosalpingogram 349
- Galactogram 351
- ERCP (Endoscopic Retrograde Cholangiopancreatography) 353
- Index 354**

**Skull**

---

**Spine**

---

**Upper Extremities**

---

**Lower Extremities**

---

**Routine Radiographs**

---

**Contrast Studies**

---

**Special Studies**

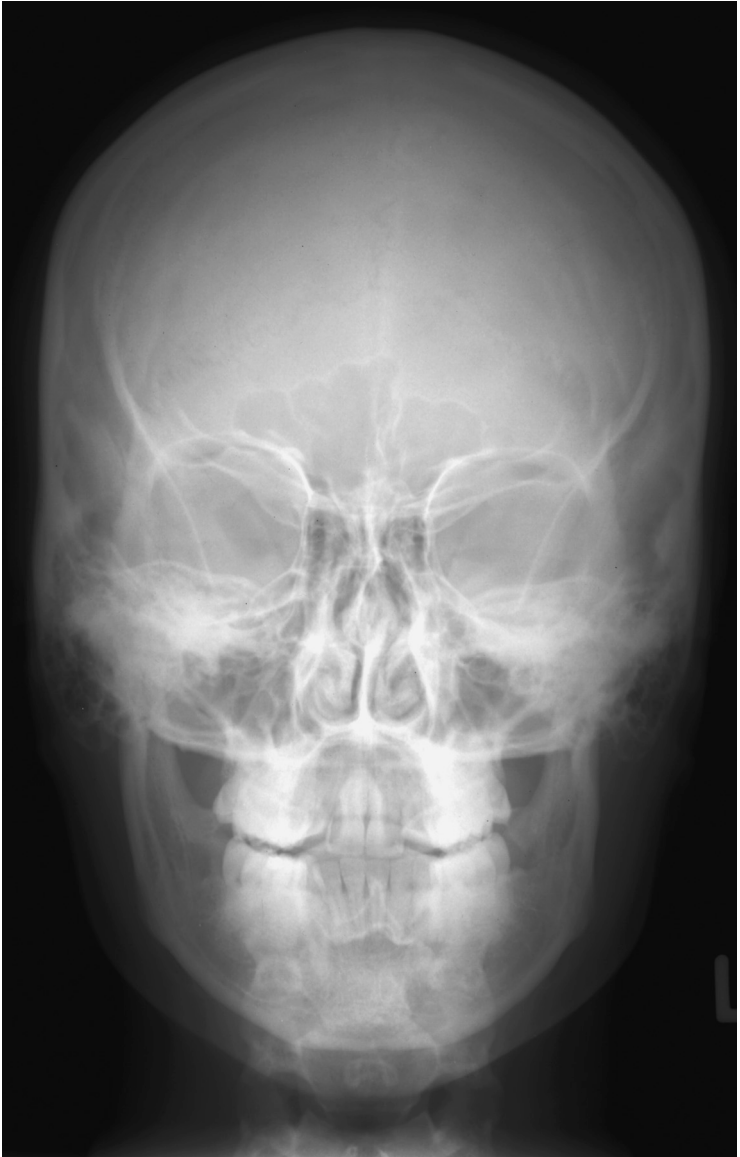

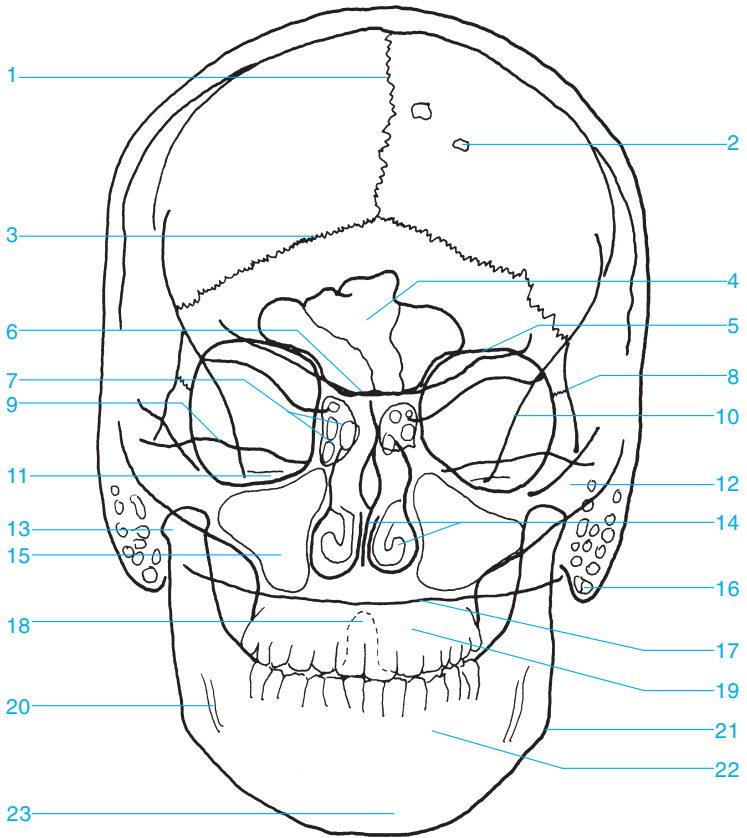


---

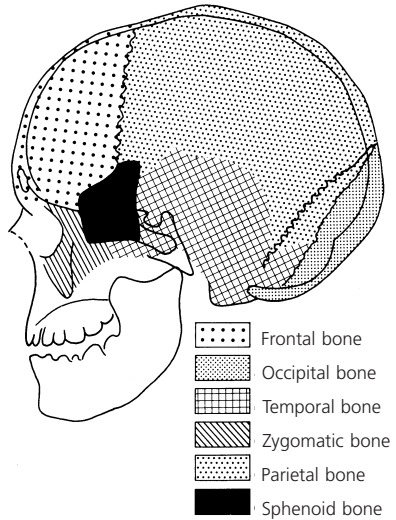
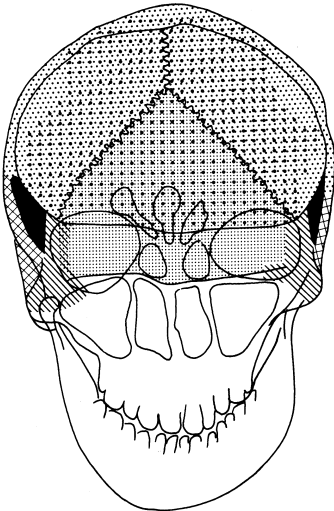
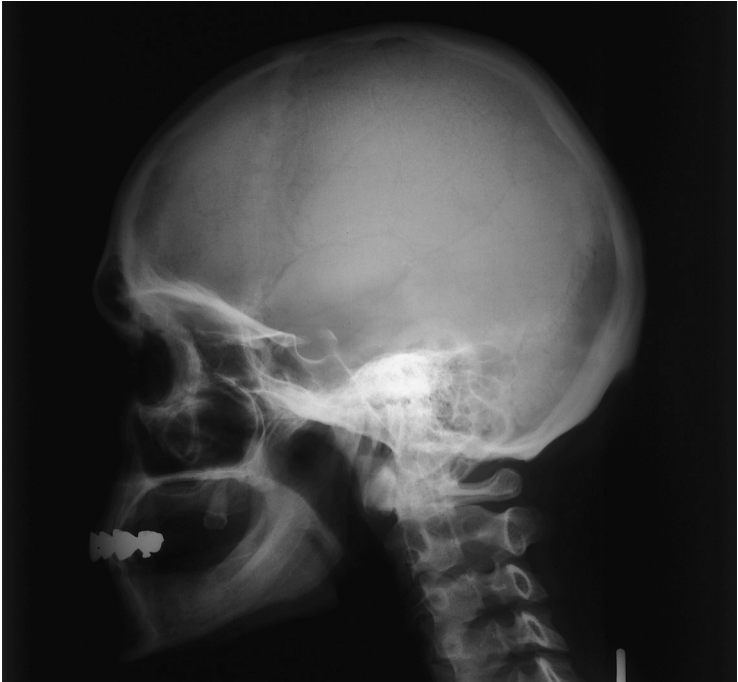# Skeletal Imaging

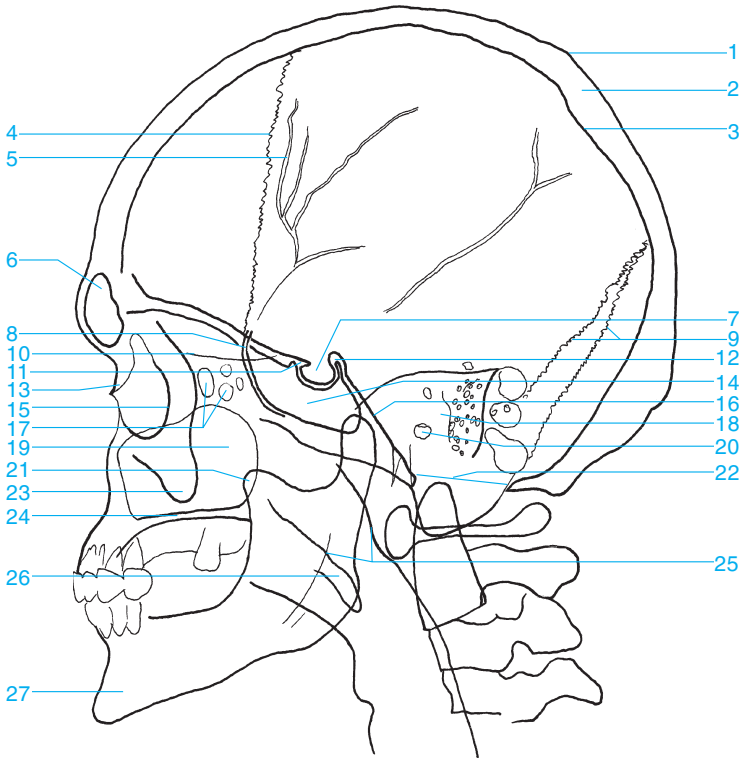
---



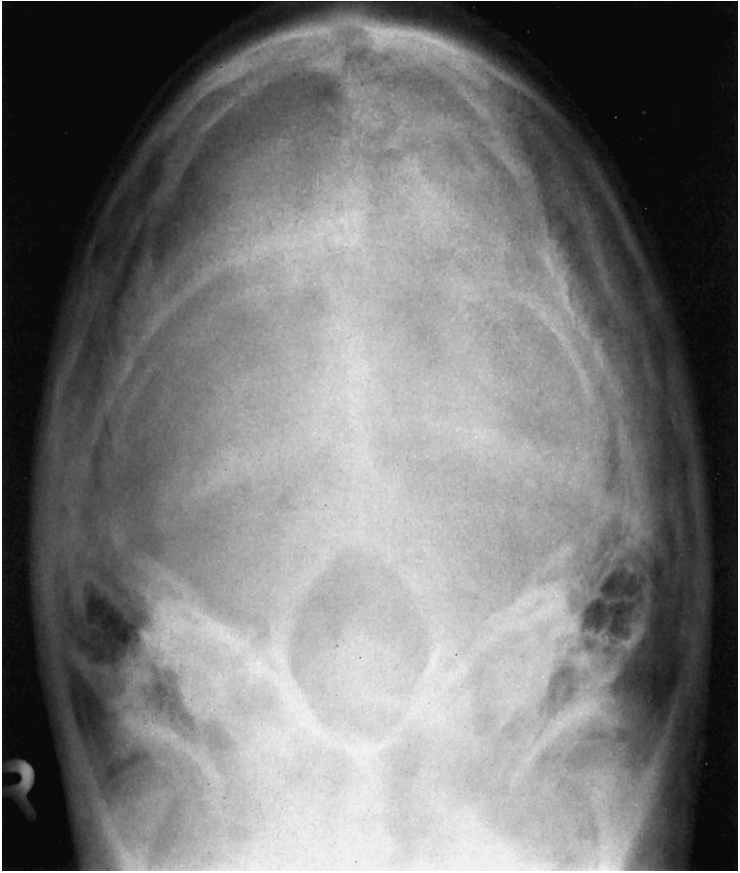

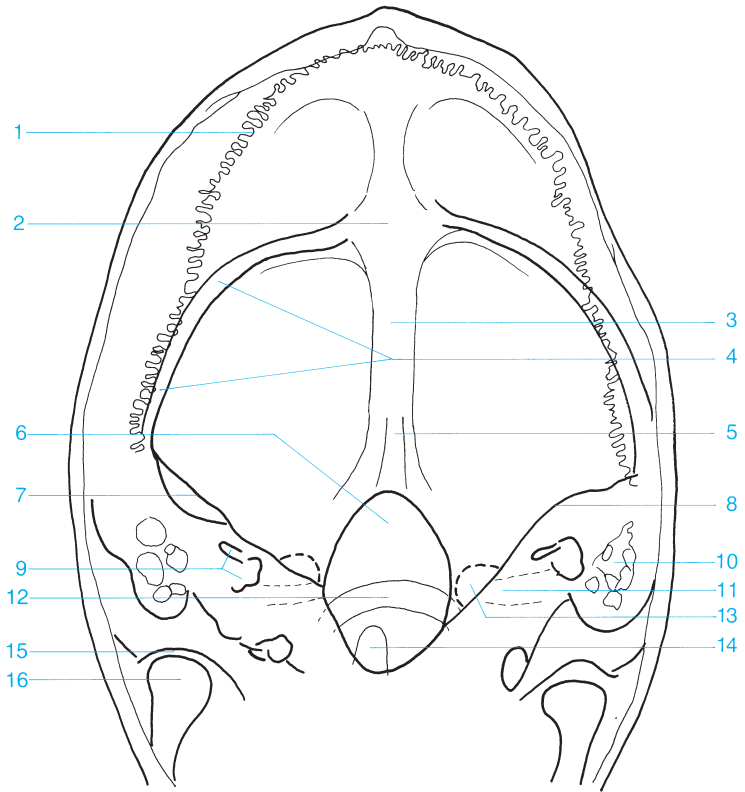
- |                            |  |
|----------------------------|--|
| 1 Sagittal suture          | 13 Condylar process of the mandible      |
| 2 Pacchionian granulations | 14 Nasal septum and inferior nasal bones |
| 3 Lambdoid suture          | 15 Maxillary sinus                       |
| 4 Frontal sinus            | 16 Mastoid process                       |
| 5 Roof of the orbit        | 17 Occiput                               |
| 6 Sphenoid                 | 18 Dens of the axis                      |
| 7 Ethmoid sinus            | 19 Maxilla                               |
| 8 Frontozygomatic suture   | 20 Mandibular canal                      |
| 9 Petrous ridge            | 21 Angle of the mandible                 |
| 10 Innominate line         | 22 Mandible                              |
| 11 Internal auditory canal | 23 Mental protuberance                   |
| 12 Zygomatic arch          |  |





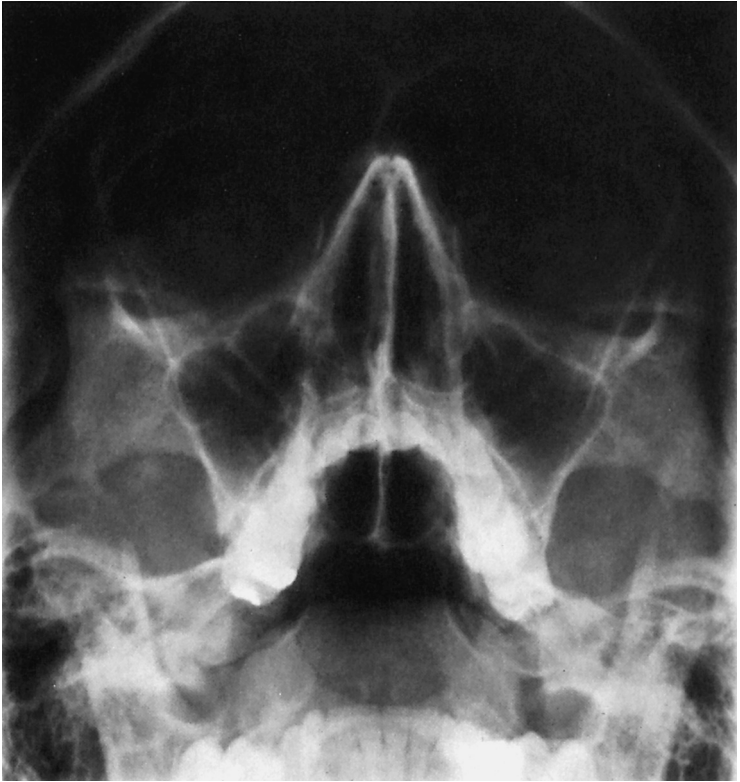- |   |   |
|---|---|
| 1 Outer table of the parietal bone      | 15 Zygomatic bone (lateral wall of the orbit) |
| 2 Diploe                                | 16 Clivus                                     |
| 3 Inner table of the parietal bone      | 17 Ethmoid sinus                              |
| 4 Coronal suture                        | 18 Petrous portion of the temporal bone       |
| 5 Groove of the middle meningeal artery | 19 Maxillary sinus                            |
| 6 Frontal sinus                         | 20 Opening of the external auditory canal     |
| 7 Pituitary fossa                       | 21 Coronoid process of the mandible           |
| 8 Greater wing of the sphenoid          | 22 Foramen magnum                             |
| 9 Lambdoid suture                       | 23 Zygomatic process                          |
| 10 Cribriform plate                     | 24 Hard palate                                |
| 11 Anterior clinoid process             | 25 Nasopharynx                                |
| 12 Posterior clinoid process            | 26 Soft palate                                |
| 13 Nasal bone                           | 27 Mandible                                   |
| 14 Sphenoid sinus                       |   |





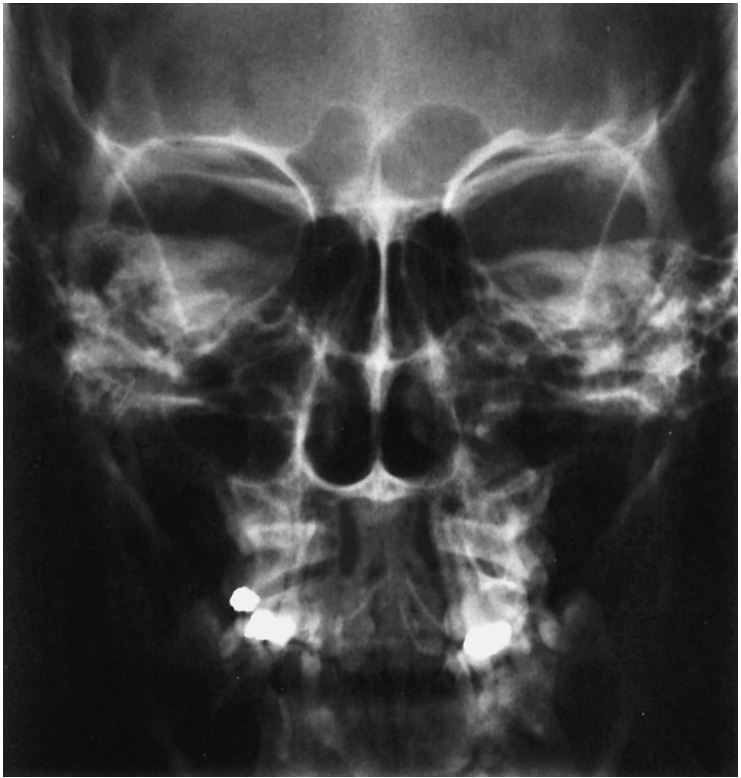
- |   |                                |
|---|--------------------------------|
| 1 Lambdoid suture                                 | 9 Semicircular canals          |
| 2 Occipital protuberances (external and internal) | 10 Mastoid air cells           |
| 3 Occipital bone                                  | 11 Internal auditory canal     |
| 4 Sulcus of the transverse sinus                  | 12 Posterior arch of the atlas |
| 5 Occipital crest                                 | 13 Jugular foramen             |
| 6 Foramen magnum                                  | 14 Dens                        |
| 7 Petrous bone                                    | 15 Temporomandibular joint     |
| 8 Arcuate eminence                                | 16 Condyle of the mandible     |

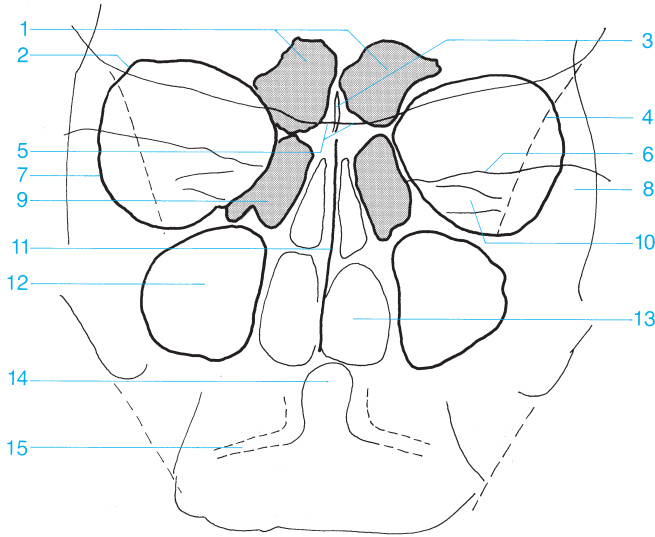




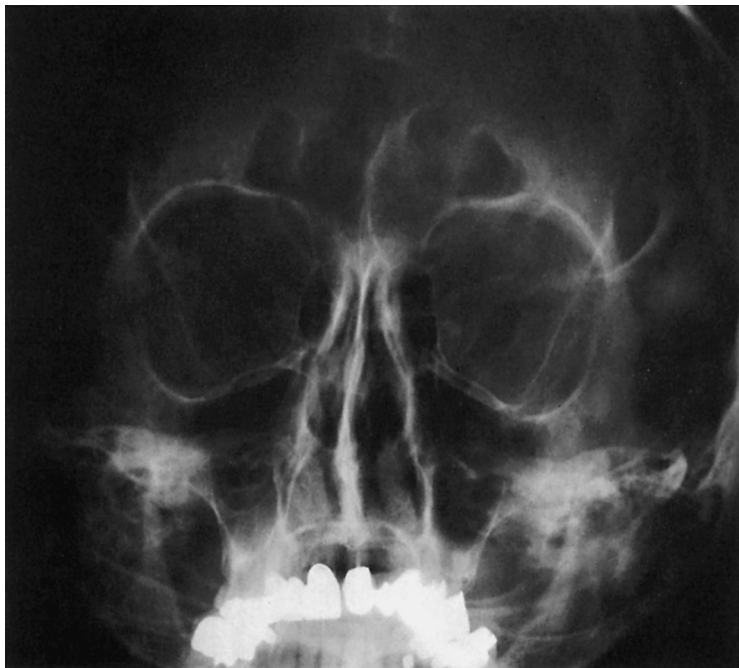

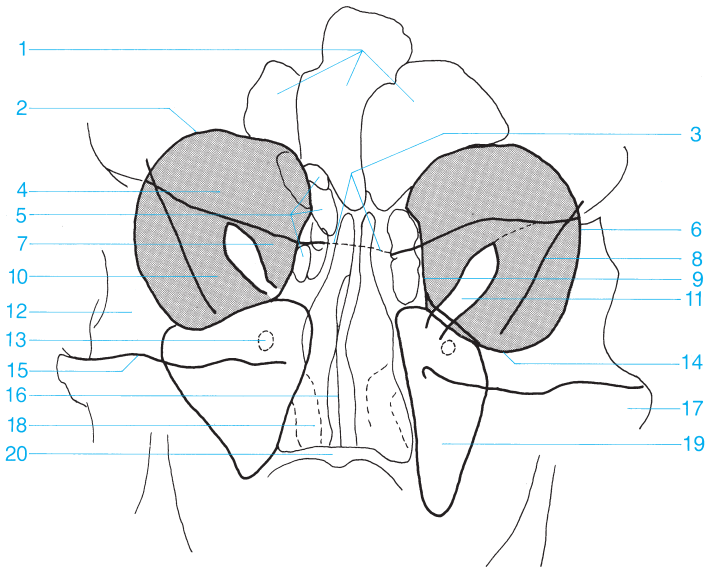
- |                                       |   |
|---------------------------------------|---|
| <b>1</b> Frontal sinus                | <b>11</b> Maxillary sinus                 |
| <b>2</b> Nasal bone                   | <b>12</b> Alveolar recess of the maxilla  |
| <b>3</b> Anterior ethmoid sinus       | <b>13</b> Sphenoid sinus                  |
| <b>4</b> Orbit                        | <b>14</b> Foramen ovale                   |
| <b>5</b> Nasal septum                 | <b>15</b> Alveolar process of the maxilla |
| <b>6</b> Greater wing of the sphenoid | <b>16</b> Condyle of the mandible         |
| <b>7</b> Infraorbital foramen         | <b>17</b> Petrous ridge                   |
| <b>8</b> Foramen rotundum             | <b>18</b> Tongue                          |
| <b>9</b> Posterior ethmoid sinus      | <b>19</b> Mandible                        |
| <b>10</b> Zygomatic bone              |   |



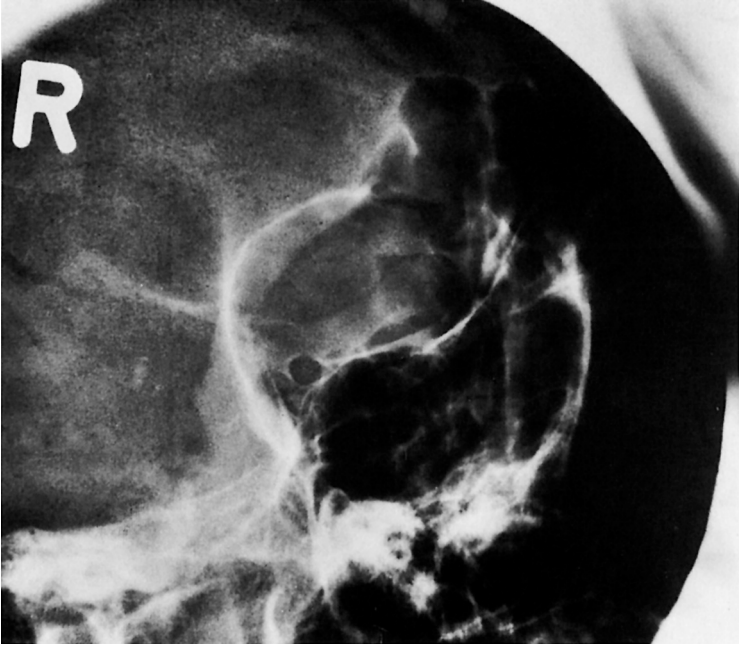



- |                                    |                                   |
|------------------------------------|-----------------------------------|
| <b>1</b> Frontal sinus             | <b>9</b> Anterior ethmoid sinus   |
| <b>2</b> Roof of the orbit         | <b>10</b> Internal auditory canal |
| <b>3</b> Crista galli              | <b>11</b> Nasal septum            |
| <b>4</b> Innominate line           | <b>12</b> Maxillary sinus         |
| <b>5</b> Sphenoid                  | <b>13</b> Nasal cavity            |
| <b>6</b> Petrous ridge             | <b>14</b> Dens                    |
| <b>7</b> Lateral wall of the orbit | <b>15</b> Atlantoaxial joint      |
| <b>8</b> Zygomatic bone            |                                   |





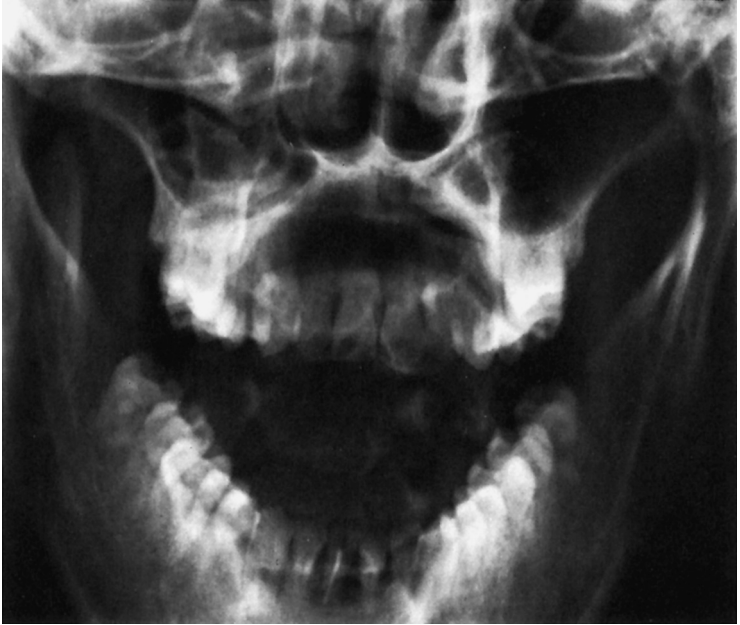- |  |   |
|--|---|
| <b>1</b> Frontal sinus                 | <b>12</b> Frontal process of the zygomatic bone |
| <b>2</b> Roof of the orbit             | <b>13</b> Foramen rotundum                      |
| <b>3</b> Sphenoid                      | <b>14</b> Floor of the orbit                    |
| <b>4</b> Orbit (gray background)       | <b>15</b> Petrous ridge                         |
| <b>5</b> Ethmoid sinus                 | <b>16</b> Nasal septum                          |
| <b>6</b> Lateral wall of the orbit     | <b>17</b> Zygomatic arch                        |
| <b>7</b> Lesser wing of the sphenoid   | <b>18</b> Inferior turbinate                    |
| <b>8</b> Innominate line               | <b>19</b> Maxillary sinus                       |
| <b>9</b> Orbital plate                 | <b>20</b> Hard palate                           |
| <b>10</b> Greater wing of the sphenoid |   |
| <b>11</b> Superior orbital fissure     |   |

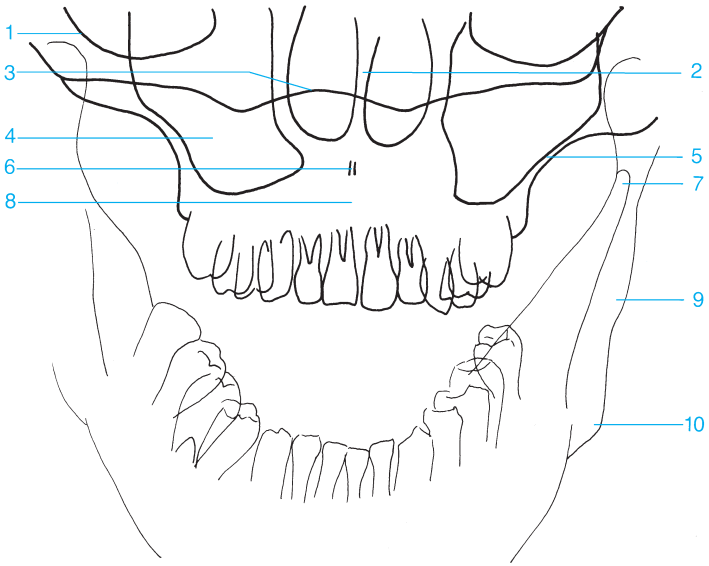




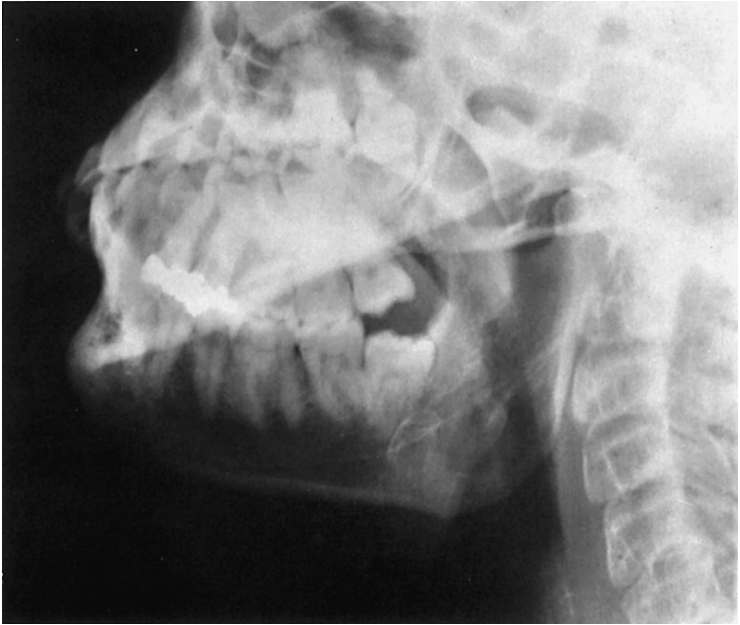- |  |  |
|--|--|
| <b>1</b> Frontal sinus                     | <b>8</b> Lateral wall of the orbit             |
| <b>2</b> Roof of the orbit                 | <b>9</b> Superior orbital fissure              |
| <b>3</b> Left lesser wing of the sphenoid  | <b>10</b> Sphenoid sinus                       |
| <b>4</b> Right lesser wing of the sphenoid | <b>11</b> Zygomatic arch                       |
| <b>5</b> Sphenoid                          | <b>12</b> Petrous portion of the temporal bone |
| <b>6</b> Ethmoid sinus                     | <b>13</b> Maxillary sinus                      |
| <b>7</b> Optic canal                       |  |

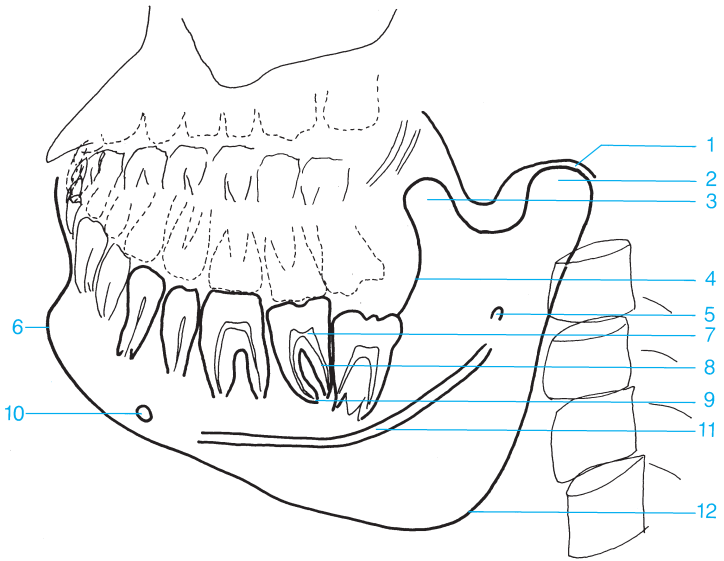




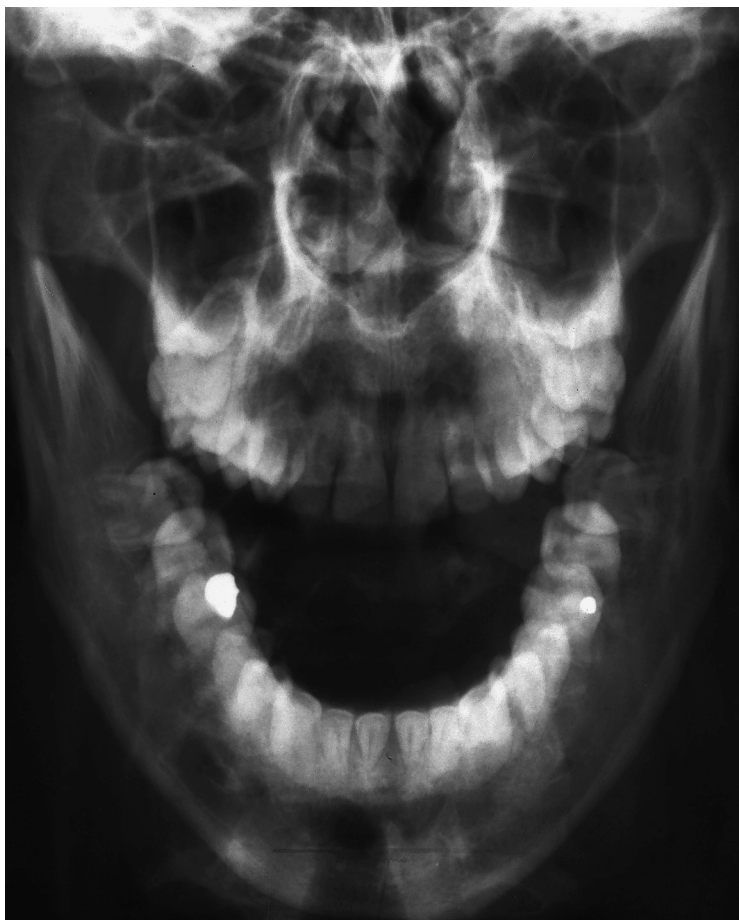

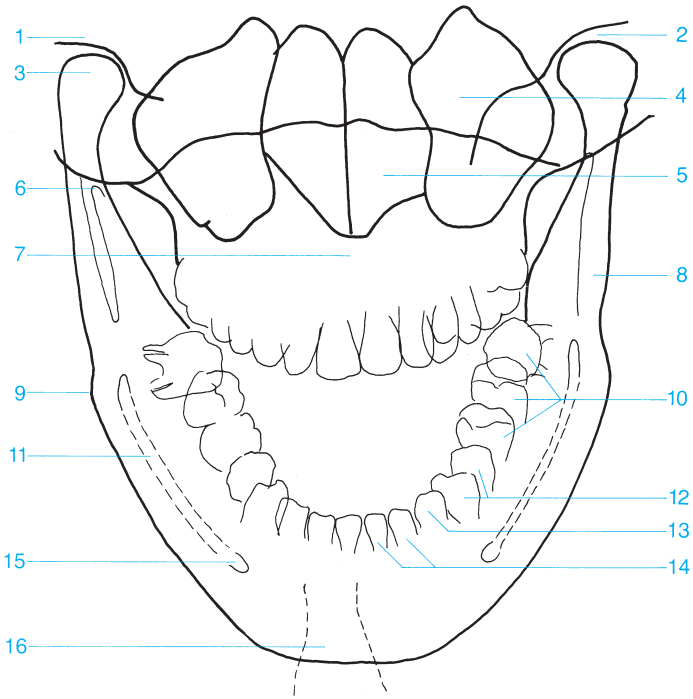
- |                                      |                                 |
|--------------------------------------|---------------------------------|
| <b>1</b> Floor of the orbit          | <b>6</b> Anterior nasal spine   |
| <b>2</b> Nasal septum                | <b>7</b> Coronoid process       |
| <b>3</b> Base of the skull           | <b>8</b> Maxilla                |
| <b>4</b> Maxillary sinus             | <b>9</b> Ramus of the mandible  |
| <b>5</b> Lateral wall of the maxilla | <b>10</b> Angle of the mandible |



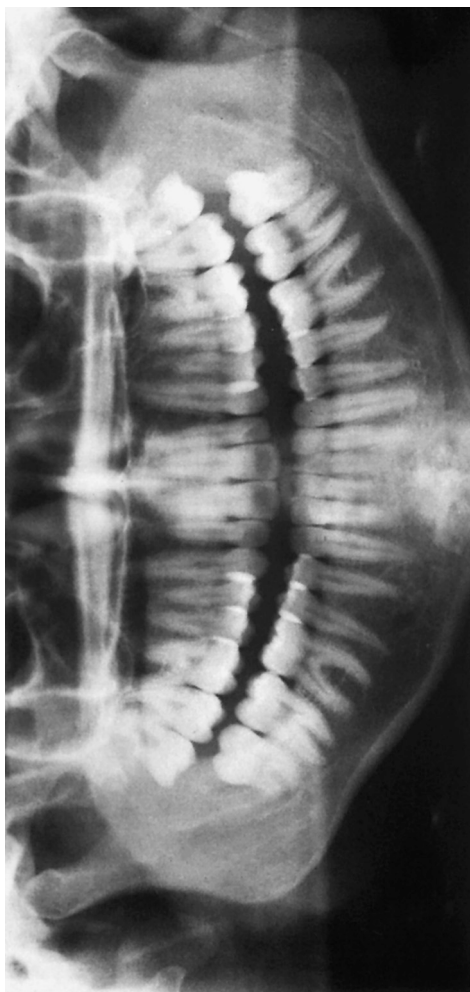

- |   |                                 |    |                             |
|---|---------------------------------|----|-----------------------------|
| 1 | Temporomandibular joint         | 7  | Pulp cavity                 |
| 2 | Condyle of the mandible         | 8  | Root canal                  |
| 3 | Coronoid process                | 9  | Apical foramen of the tooth |
| 4 | Cortex of ramus of the mandible | 10 | Mental foramen              |
| 5 | Mandibular foramen              | 11 | Mandibular canal            |
| 6 | Mental protuberance             | 12 | Angle of the mandible       |





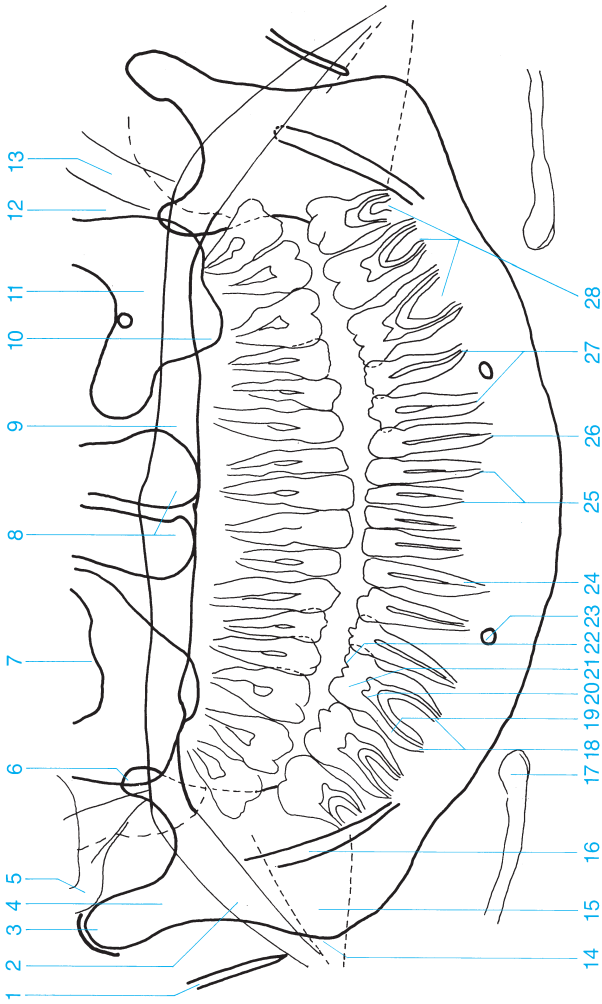
- |                                  |  |
|----------------------------------|--|
| <b>1</b> Temporal bone           | <b>10</b> Molars   |
| <b>2</b> Temporomandibular joint | <b>11</b> Mandibular canal   |
| <b>3</b> Condyle of the mandible | <b>12</b> Premolars  |
| <b>4</b> Maxillary sinus         | <b>13</b> Canines  |
| <b>5</b> Nasal cavity            | <b>14</b> Incisors   |
| <b>6</b> Coronoid process        | <b>15</b> Mental foramen   |
| <b>7</b> Maxilla                 | <b>16</b> Mental protuberance (trachea superimposed as radiolucent band) |
| <b>8</b> Ramus of the mandible   |  |
| <b>9</b> Angle of the mandible   |  |



- 1 Styloid process
- 2 Soft palate
- 3 Condyle of the mandible
- 4 Condylar process
- 5 Zygomatic arch
- 6 Coronoid process
- 7 Floor of the orbit
- 8 Nasal cavity
- 9 Hard palate
- 10 Alveolar recess of the maxilla

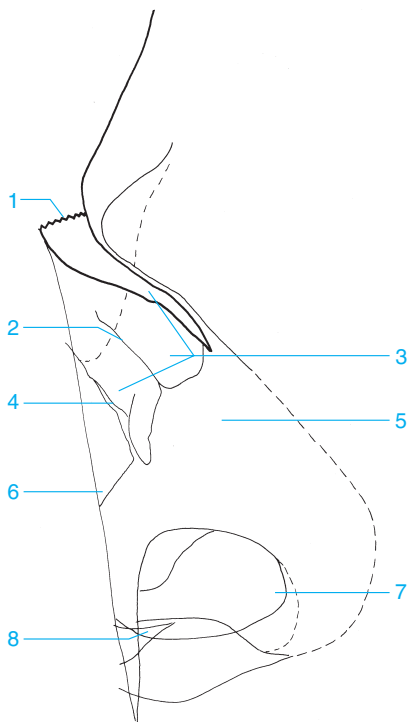
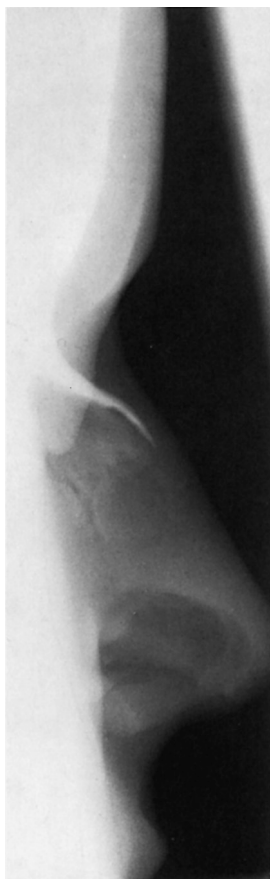- 11 Maxillary sinus
- 12 Pterygopalatine fossa
- 13 Pterygoid process
- 14 Angle of the mandible
- 15 Shadow of the tongue
- 16 Mandibular canal
- 17 Hyoid bone
- 18 Apical foramen of the tooth
- 19 Root canal

- 20 Pulp cavity
- 21 Dentin
- 22 Enamel
- 23 Mental foramen
- 24 Root of the tooth
- 25 Incisor
- 26 Canine
- 27 Premolar
- 28 Molar



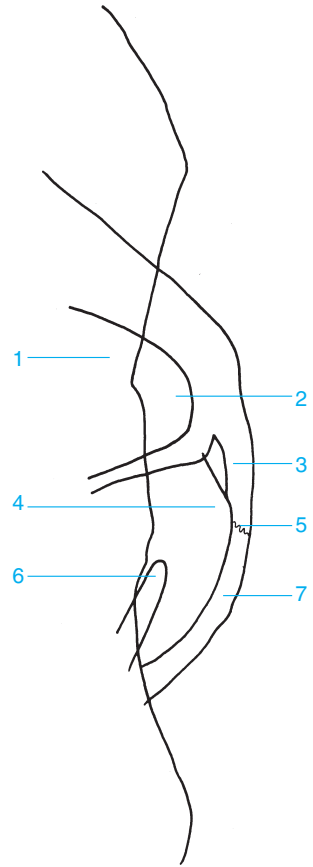
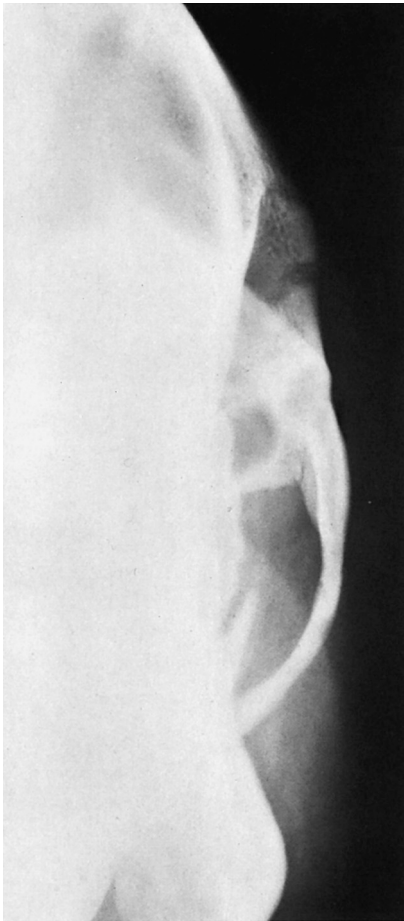


## 24 Skull: Lateral View of the Nose



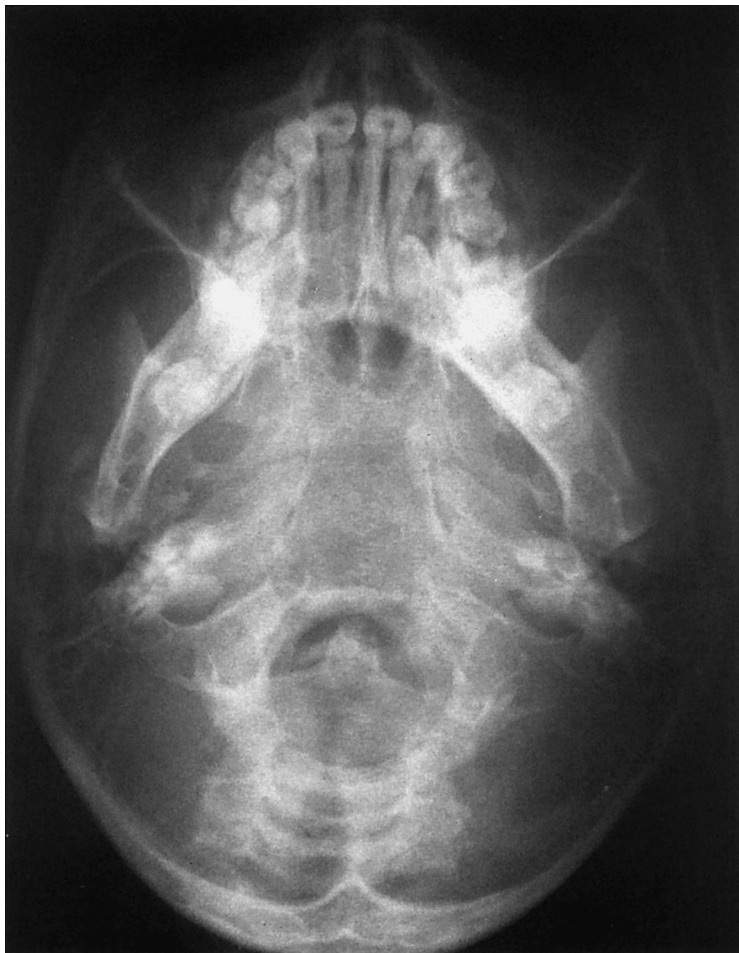- 1 Frontonasal suture
- 2 Ethmoidal groove
- 3 Nasal bone
- 4 Nasomaxillary suture

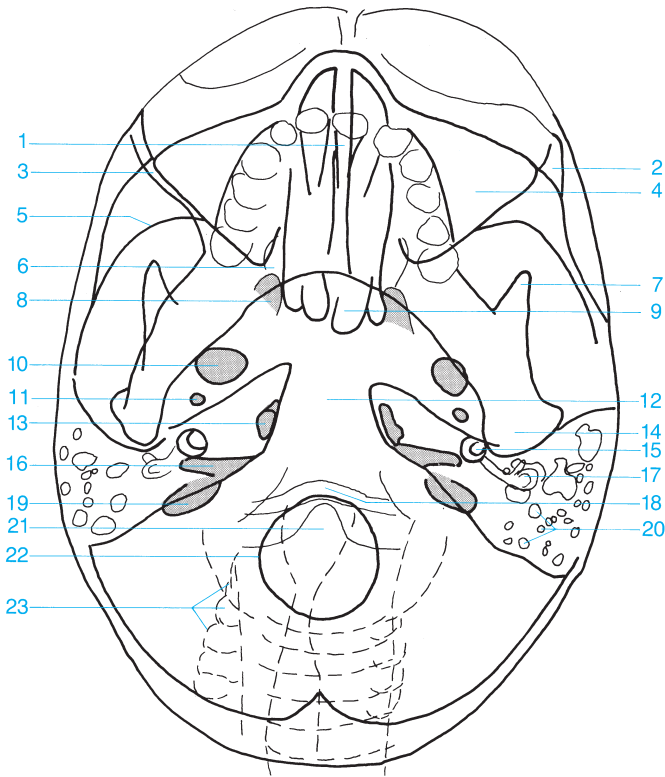
- 5 Nasal cartilage
- 6 Maxilla
- 7 Vestibule of nose
- 8 Anterior nasal spine



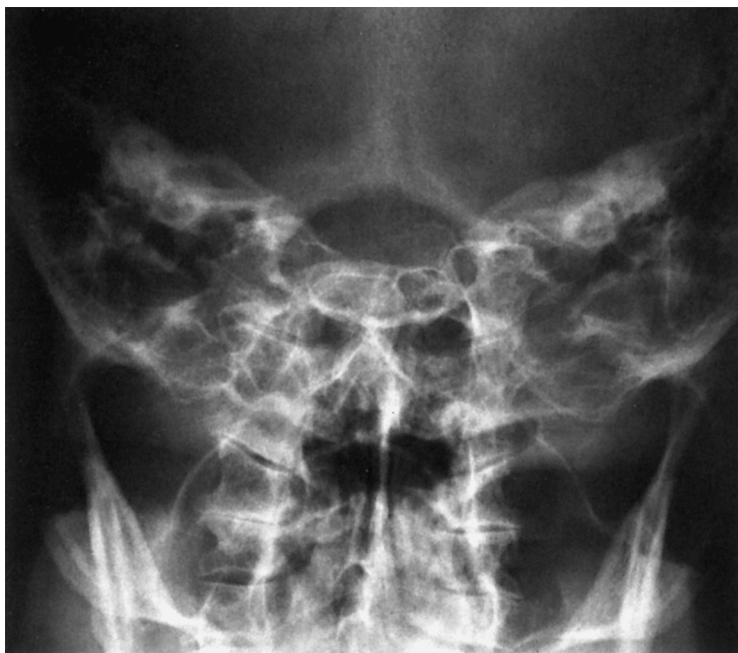- 1 Maxillary sinus
- 2 Zygomatic recess (of the maxillary sinus)
- 3 Zygomatic arch
- 4 Temporal fossa

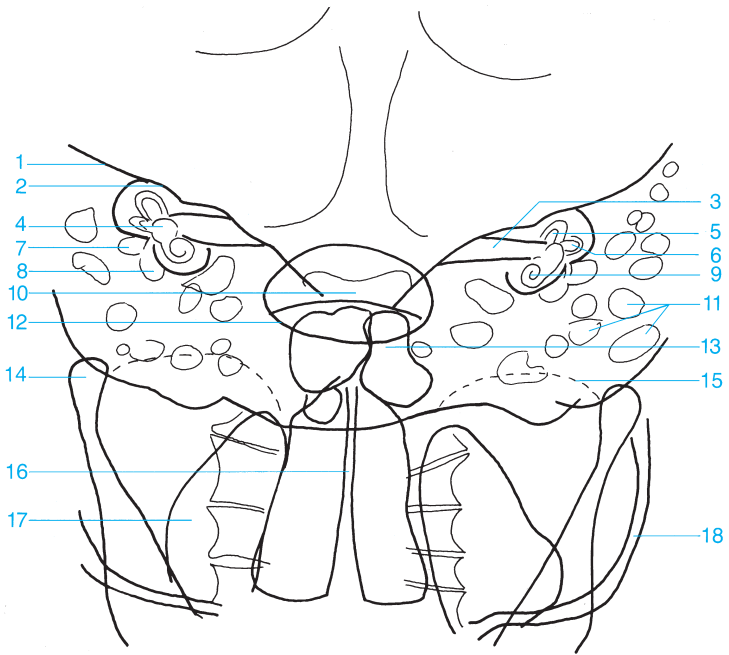
- 5 Temporozygomatic suture
- 6 Coronoid process (visualized end on)
- 7 Zygomatic process of the temporal bone



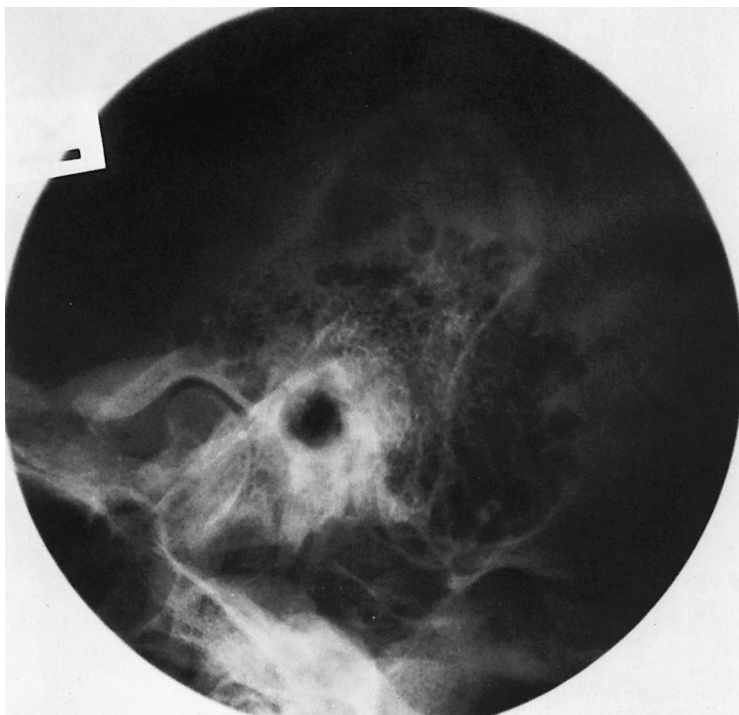

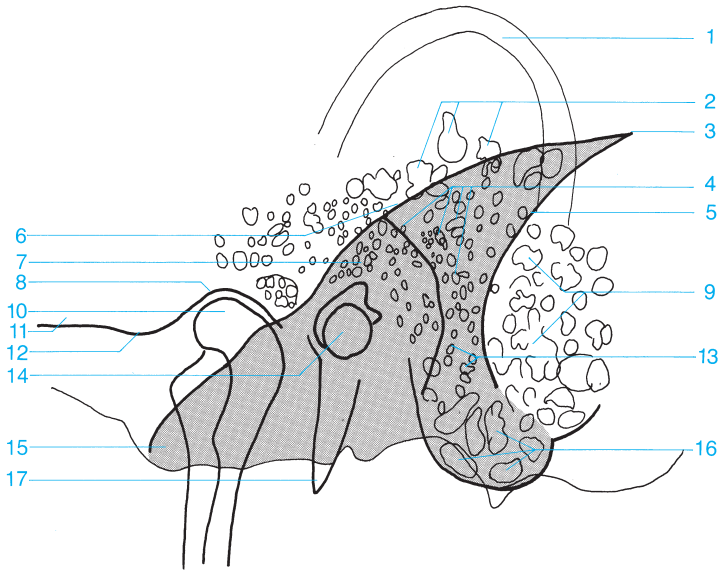
- |    |  |    |                            |
|----|--|----|----------------------------|
| 1  | Nasal septum   | 11 | Foramen spinosum           |
| 2  | Zygomatic bone   | 12 | Clivus                     |
| 3  | Posterior wall of maxillary sinus  | 13 | Foramen lacerum            |
| 4  | Maxillary sinus (with orbit, partially superimposed)                       | 14 | Condyle of the mandible    |
| 5  | Middle cranial fossa, greater wing (anterior wall of middle cranial fossa) | 15 | Cochlea                    |
| 6  | Pterygopalatine fossa  | 16 | Internal auditory canal    |
| 7  | Coronoid process   | 17 | Semicircular canals        |
| 8  | Pterygoid fossa  | 18 | Anterior arch of the atlas |
| 9  | Sphenoid sinus   | 19 | Jugular foramen            |
| 10 | Foramen ovale  | 20 | Mastoid air cells          |
|    |  | 21 | Dens of the axis           |
|    |  | 22 | Foramen magnum             |
|    |  | 23 | Cervical spine             |





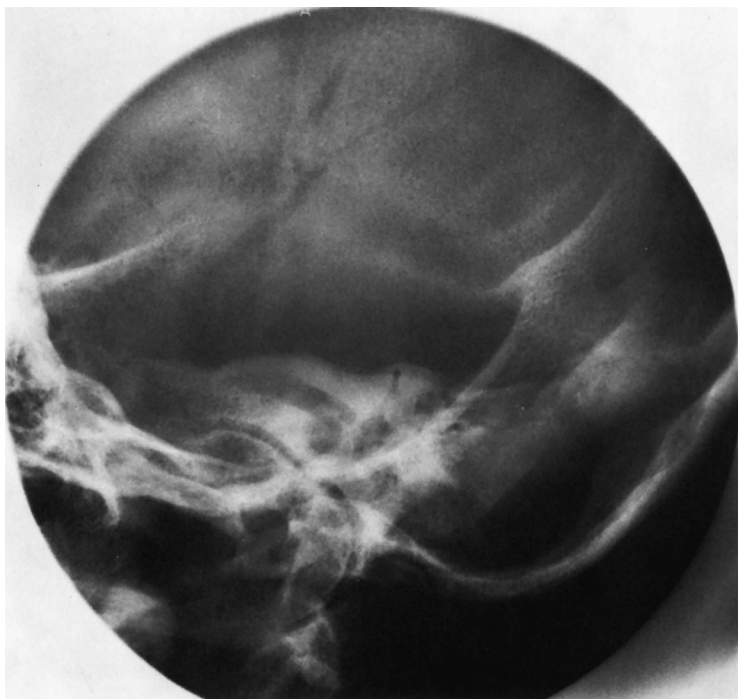- |                                      |   |
|--------------------------------------|---|
| <b>1</b> Petrous ridge               | <b>10</b> Dorsum sellae                   |
| <b>2</b> Arcuate eminence            | <b>11</b> Mastoid air cells               |
| <b>3</b> Internal auditory canal     | <b>12</b> Foramen magnum                  |
| <b>4</b> Vestibule                   | <b>13</b> Frontal sinus                   |
| <b>5</b> Anterior semicircular canal | <b>14</b> Condyle of the mandible         |
| <b>6</b> Lateral semicircular canal  | <b>15</b> Roof of the orbit               |
| <b>7</b> Antrum of the mastoid       | <b>16</b> Nasal septum and nasal cavities |
| <b>8</b> Tympanic cavity             | <b>17</b> Maxillary sinus                 |
| <b>9</b> Cochlea                     | <b>18</b> Zygomatic arch                  |

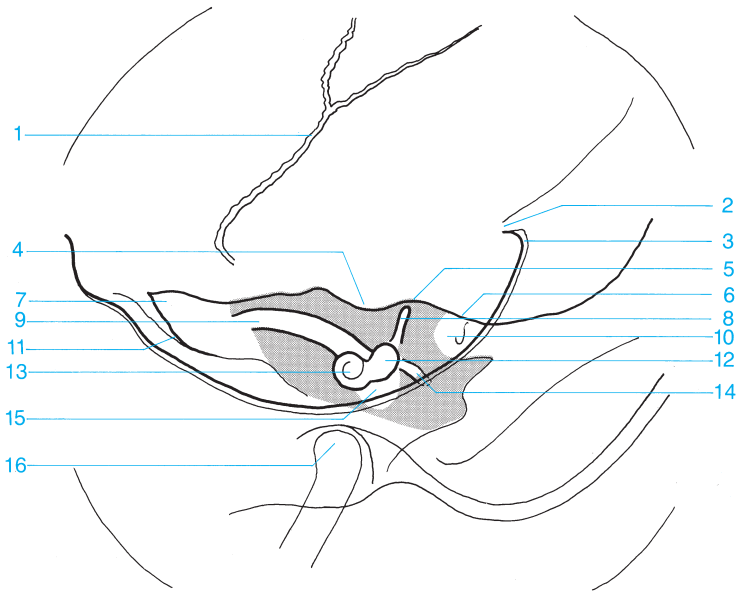




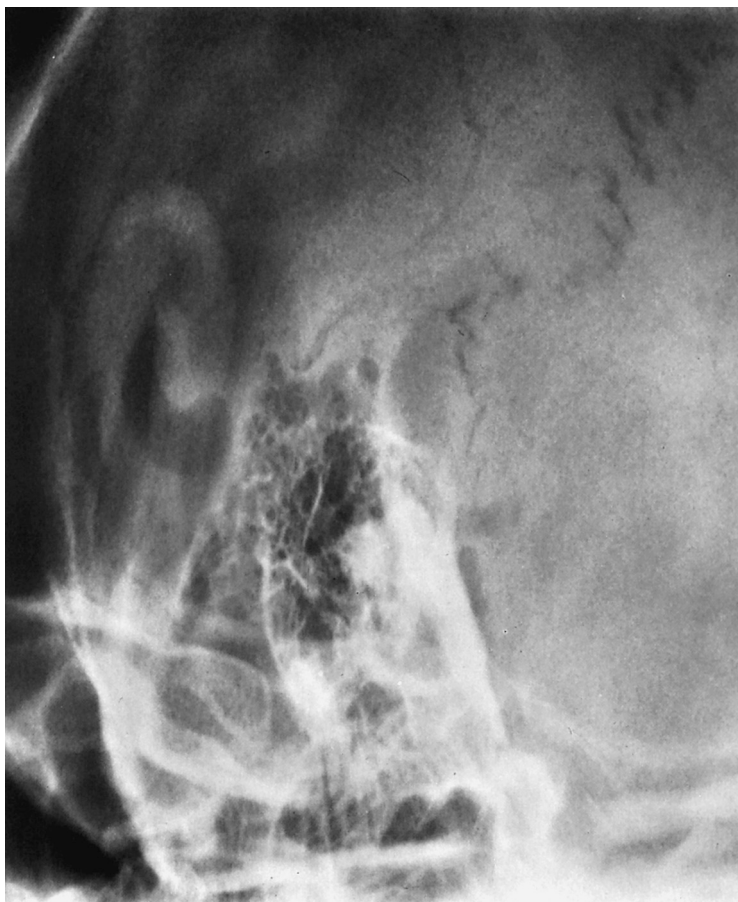- |  |   |
|--|---|
| <b>1</b> Outer ear                           | <b>11</b> Zygomatic process of the temporal bone      |
| <b>2</b> Squamous air cells                  | <b>12</b> Articular tubercle                          |
| <b>3</b> Angle of Citelli                    | <b>13</b> Retrofacial air cells                       |
| <b>4</b> Periantral air cells                | <b>14</b> Internal and external auditory canal        |
| <b>5</b> Sulcus of the sigmoid sinus         | <b>15</b> Apex of the petrous bone                    |
| <b>6</b> Anterior margin of the petrous bone | <b>16</b> Air cells in the tip of the mastoid process |
| <b>7</b> Antrum of the mastoid               | <b>17</b> Styloid process                             |
| <b>8</b> Temporomandibular joint fossa       |   |
| <b>9</b> Marginal air cells                  |   |
| <b>10</b> Condyle of the mandible            |   |

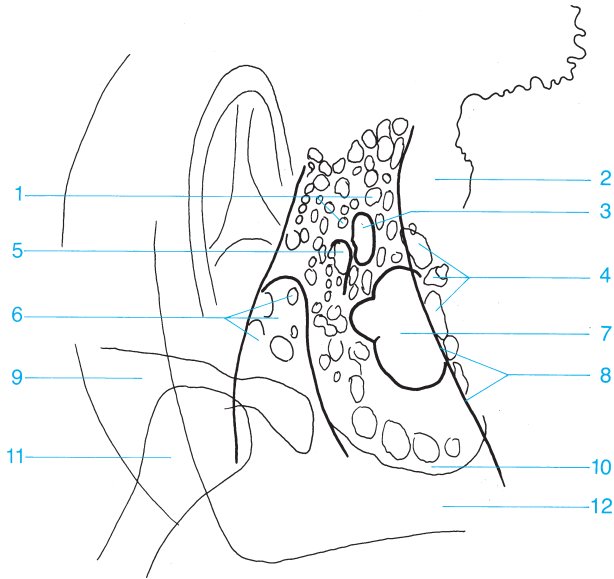




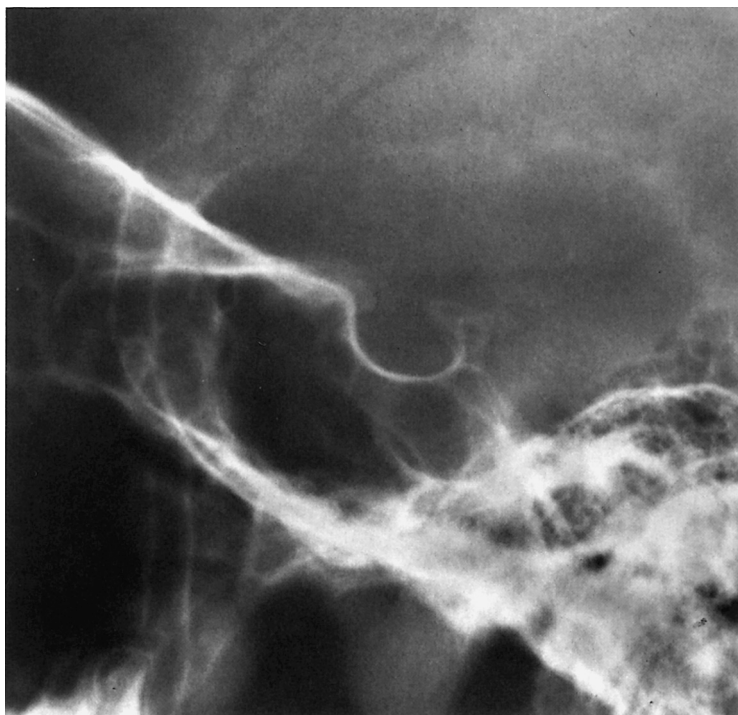


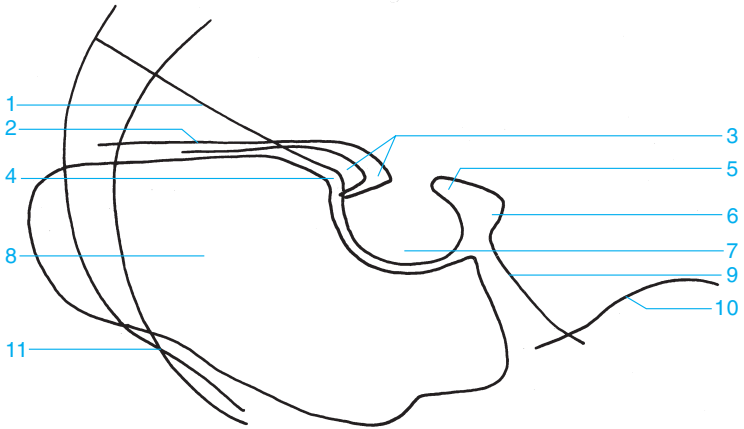
- |                                   |                               |
|-----------------------------------|-------------------------------|
| 1 Sphenosquamous suture           | 9 Internal auditory canal     |
| 2 Internal occipital protuberance | 10 Antrum                     |
| 3 Internal occipital crest        | 11 Sphenopetrosal fissure     |
| 4 Subarcuate fossa                | 12 Vestibule                  |
| 5 Arcuate eminence                | 13 Cochlea                    |
| 6 Roof of the tympanic cavity     | 14 Lateral semicircular canal |
| 7 Apex of the petrous pyramid     | 15 Tympanic cavity            |
| 8 Anterior semicircular canal     | 16 Condyle of the mandible    |



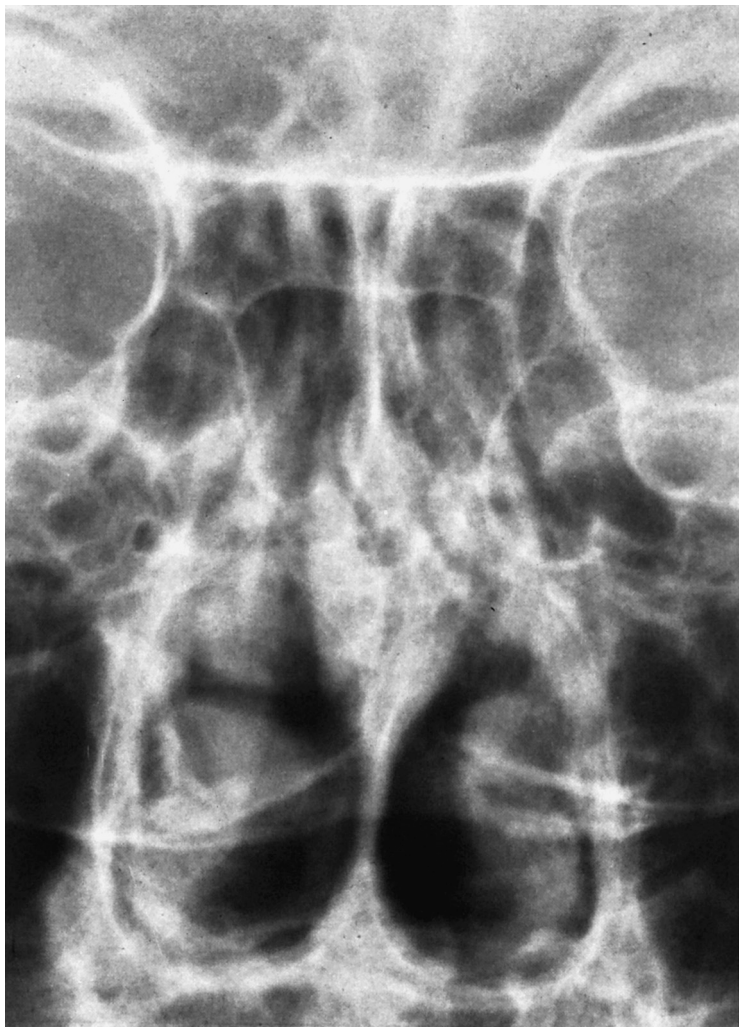

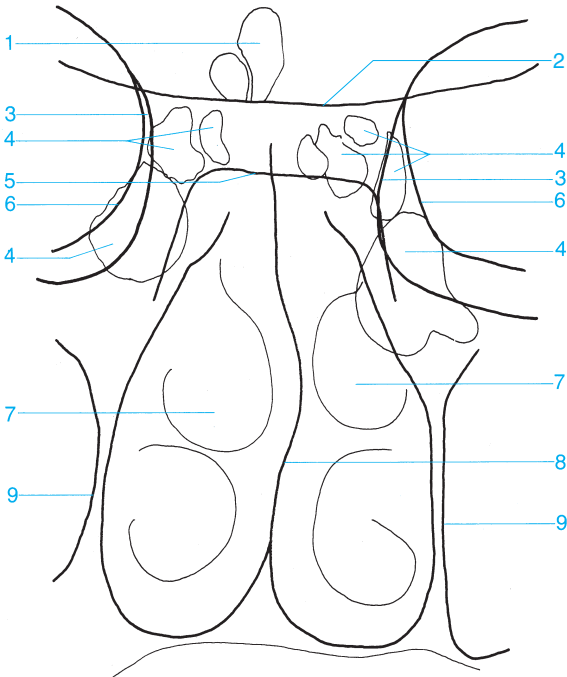
- |  |  |
|--|--|
| <b>1</b> Periantral air cells                        | <b>7</b> Osseous labyrinth   |
| <b>2</b> Sigmoid sinus                               | <b>8</b> Osseous sinus wall (posterior margin of the petrous bone) |
| <b>3</b> Antrum                                      | <b>9</b> Zygomatic bone  |
| <b>4</b> Retrosinus air cells                        | <b>10</b> Apex of the mastoid                                      |
| <b>5</b> Aperture of mastoid antrum                  | <b>11</b> Condyle of the mandible                                  |
| <b>6</b> External auditory canal and tympanic cavity | <b>12</b> Apex of the petrous bone                                 |





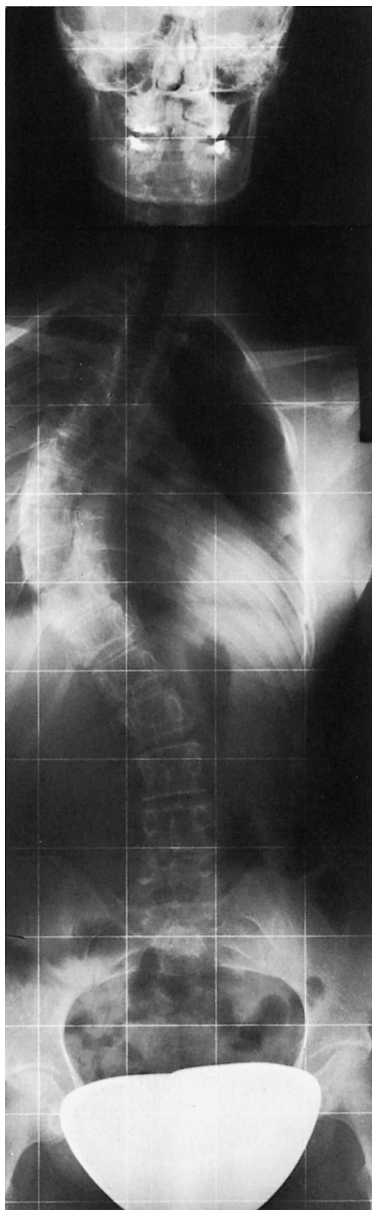
- |   |  |
|---|--|
| <b>1</b> Floor of anterior cranial fossa and roof of orbits | <b>6</b> Dorsum sellae                 |
| <b>2</b> Sphenoid   | <b>7</b> Pituitary fossa               |
| <b>3</b> Anterior clinoid process                           | <b>8</b> Sphenoid sinus                |
| <b>4</b> Tuberculum sellae                                  | <b>9</b> Clivus                        |
| <b>5</b> Posterior clinoid process                          | <b>10</b> Petrous ridge                |
|   | <b>11</b> Greater wing of the sphenoid |

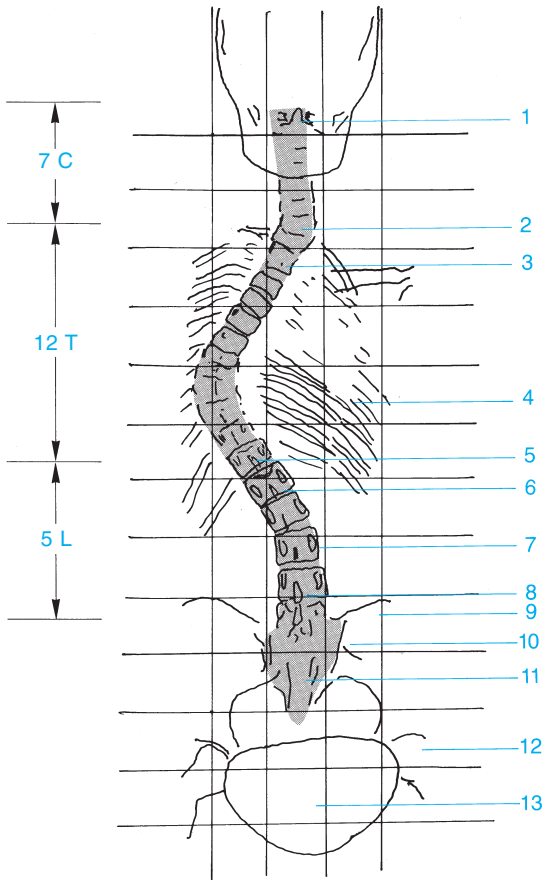




- |  |                                      |
|--|--------------------------------------|
| 1 Frontal sinuses                              | 6 Orbital plate                      |
| 2 Sphenoid                                     | 7 Nasal turbinates                   |
| 3 Medial wall of orbit                         | 8 Nasal septum                       |
| 4 Ethmoid sinus                                | 9 Medial wall of the maxillary sinus |
| 5 Pituitary fossa (floor of the sella turcica) |                                      |

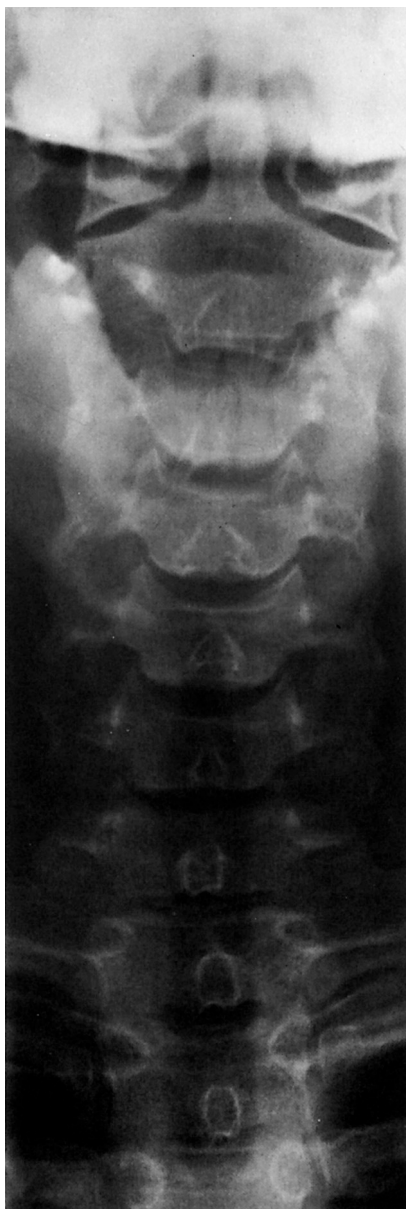

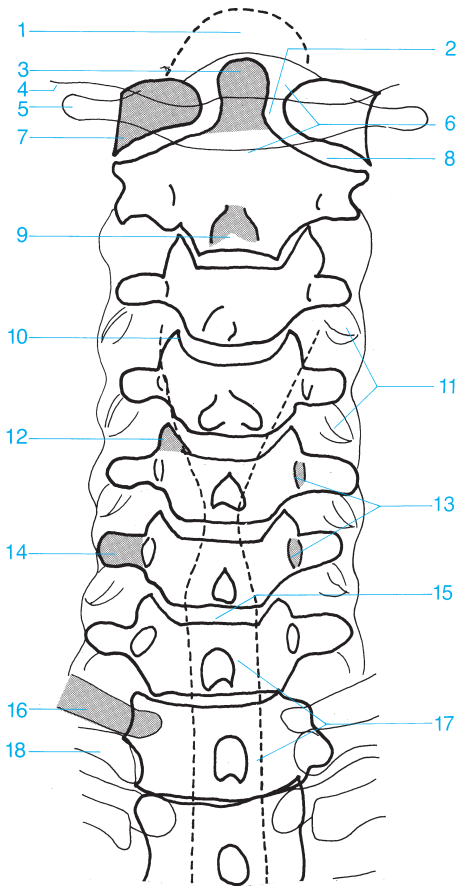




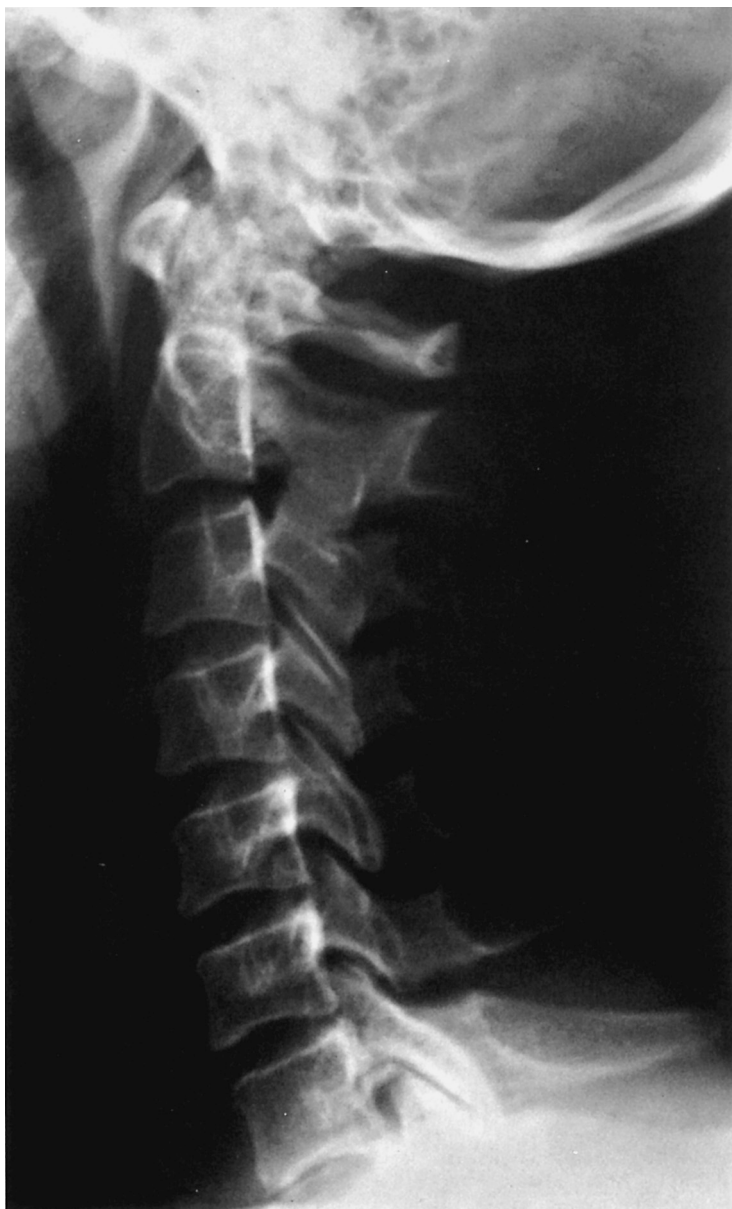- 1 Dens of the axis
- 2 C7
- 3 T2
- 4 Rib cage
- 5 T12
- 6 L1
- 7 Pedicle, L3

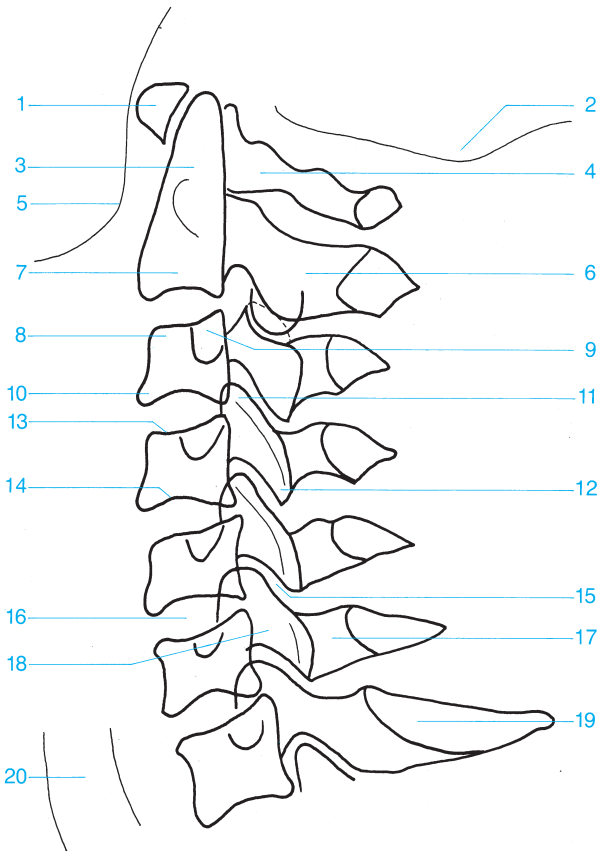
- 8 Spinous process, L6
- 9 Ilium
- 10 Sacroiliac joint
- 11 Sacrum
- 12 Hip
- 13 Gonad shield



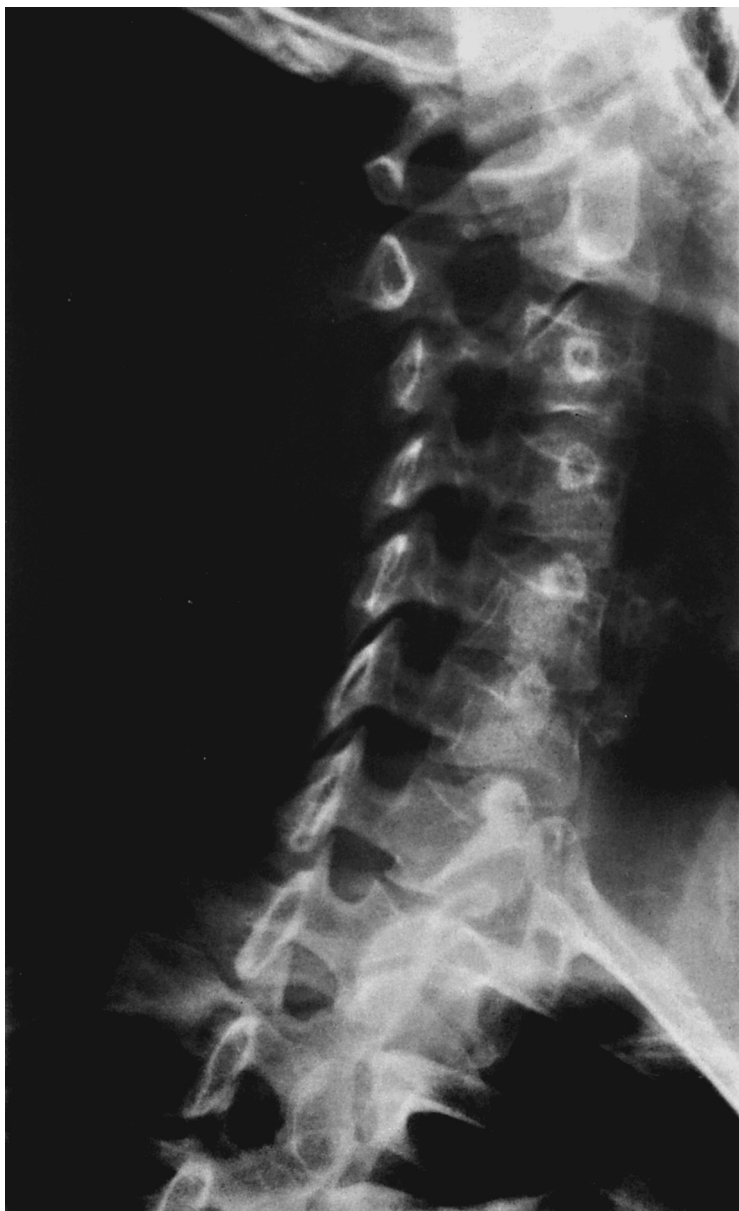

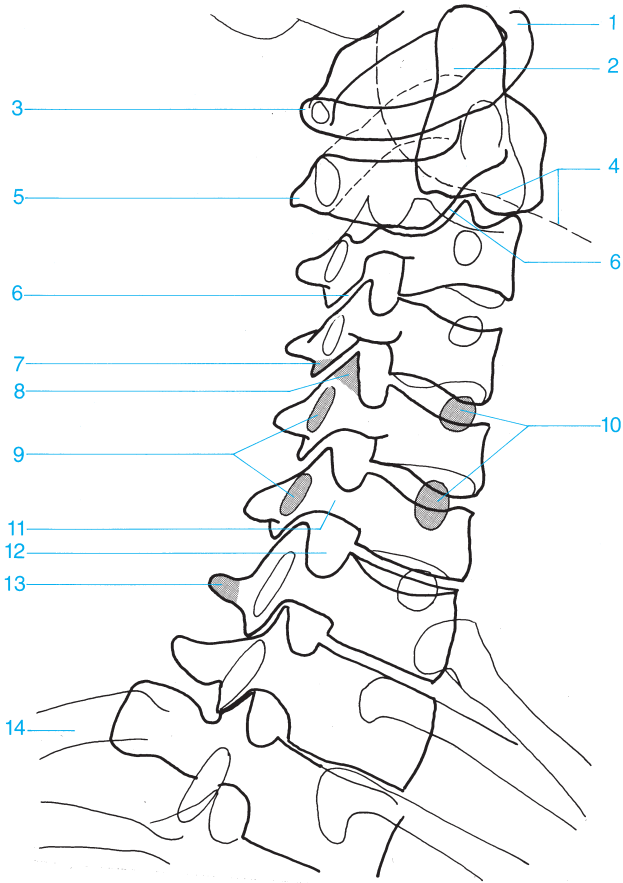
- |                           |                                    |
|---------------------------|------------------------------------|
| 1 Foramen magnum          | 10 Uncovertebral joint             |
| 2 Atlantoaxial joint      | 11 Overlapping articular processes |
| 3 Dens of the axis        | 12 Uncinate process                |
| 4 Occipital bone          | 13 Pedicle                         |
| 5 Transverse process      | 14 Transverse process              |
| 6 Vertebral arch          | 15 Intervertebral disk space       |
| 7 Lateral mass of C1      | 16 Transverse process of T1        |
| 8 Atlantoaxial joint      | 17 Radiolucent band of the trachea |
| 9 Spinous process (bifid) | 18 First rib                       |





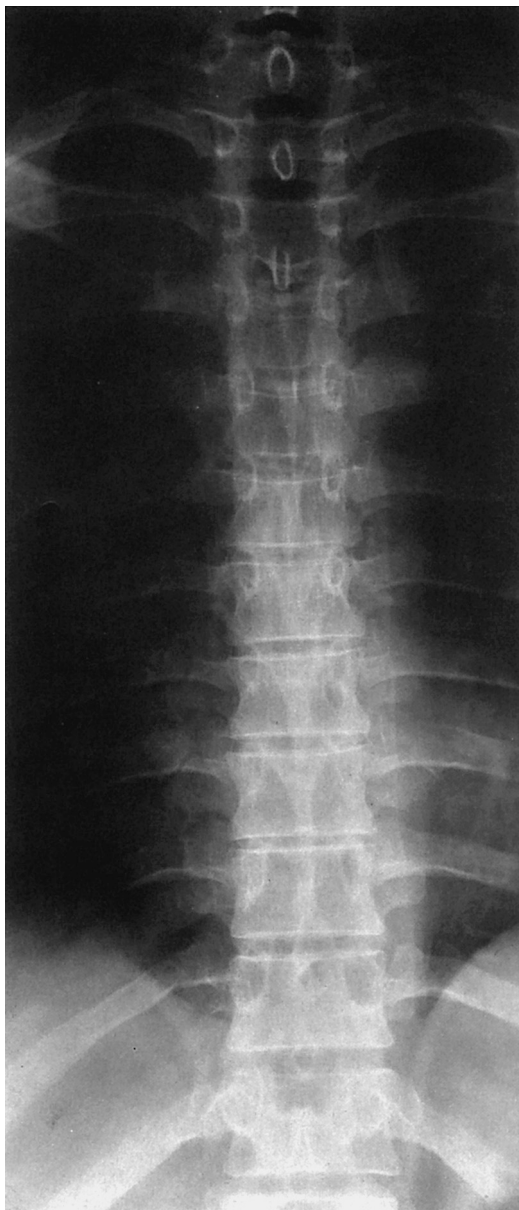- |   |                                 |
|---|---------------------------------|
| 1 Anterior arch of the atlas                | 11 Superior articular facet     |
| 2 Base of the skull                         | 12 Inferior articular facet     |
| 3 Odontoid process                          | 13 Superior vertebral end plate |
| 4 Posterior arch of the atlas               | 14 Inferior vertebral end plate |
| 5 Mandible                                  | 15 Intervertebral facet joint   |
| 6 Spinous process                           | 16 Intervertebral disk space    |
| 7 Body of the axis                          | 17 Lamina                       |
| 8 Anterior superior margin of the vertebra  | 18 Articular pillar             |
| 9 Transverse process                        | 19 Spinous process              |
| 10 Anterior inferior margin of the vertebra | 20 Trachea                      |

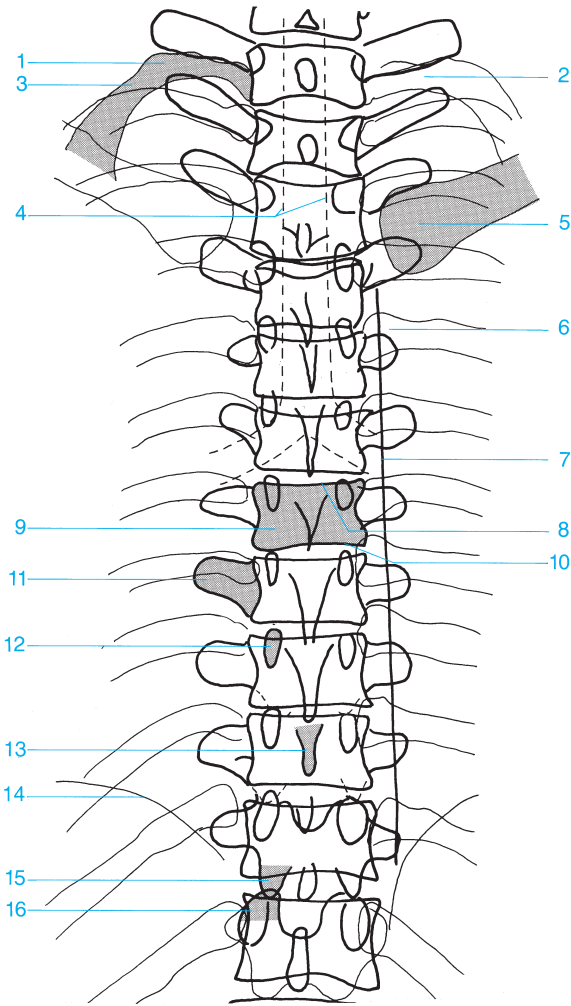




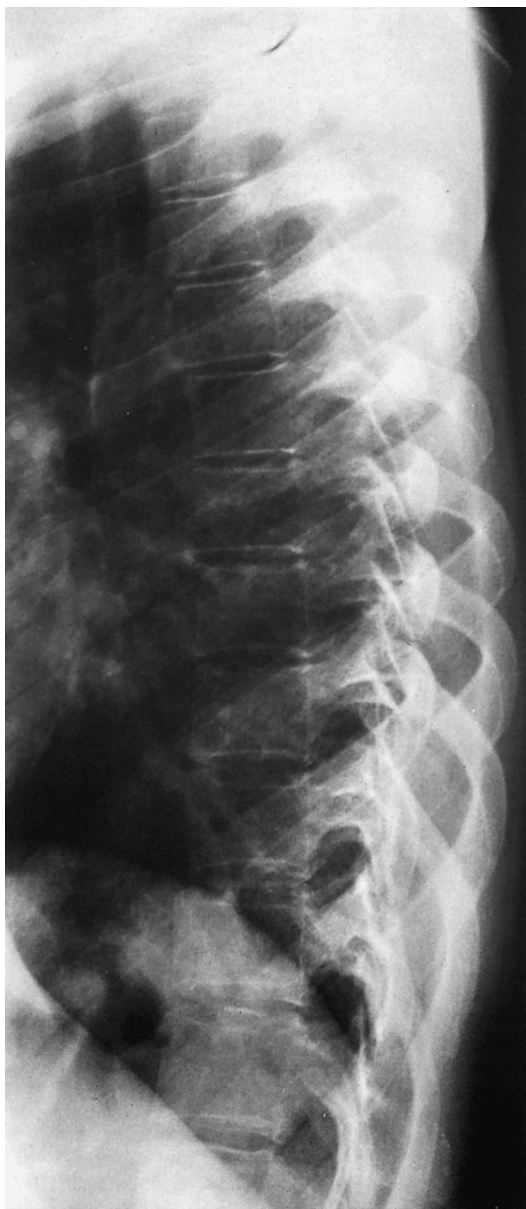- |                              |                              |
|------------------------------|------------------------------|
| 1 Anterior arch              | 8 Superior articular process |
| 2 Odontoid process           | 9 Transverse process         |
| 3 Atlas                      | 10 Contralateral pedicle     |
| 4 Mandible                   | 11 Pedicle                   |
| 5 Body of C2                 | 12 Intervertebral foramen    |
| 6 Facet joint                | 13 Spinous process           |
| 7 Inferior articular process | 14 Ribs                      |

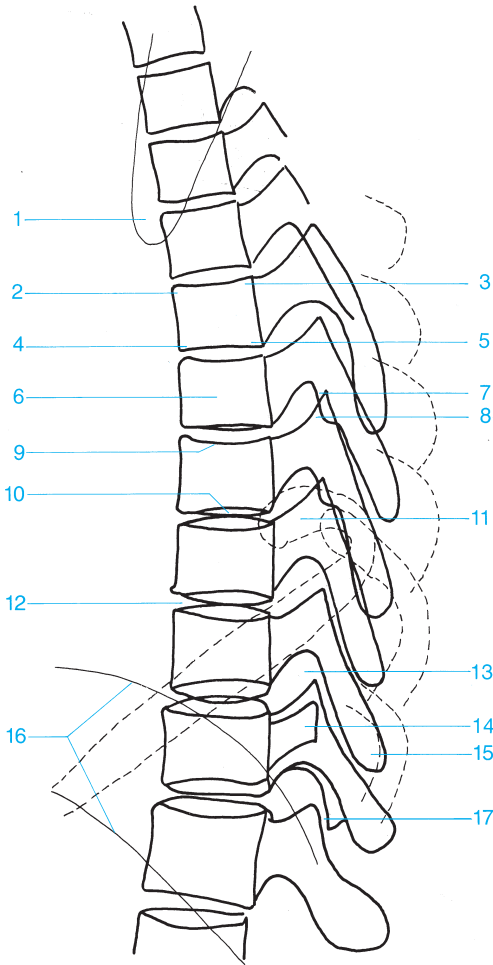




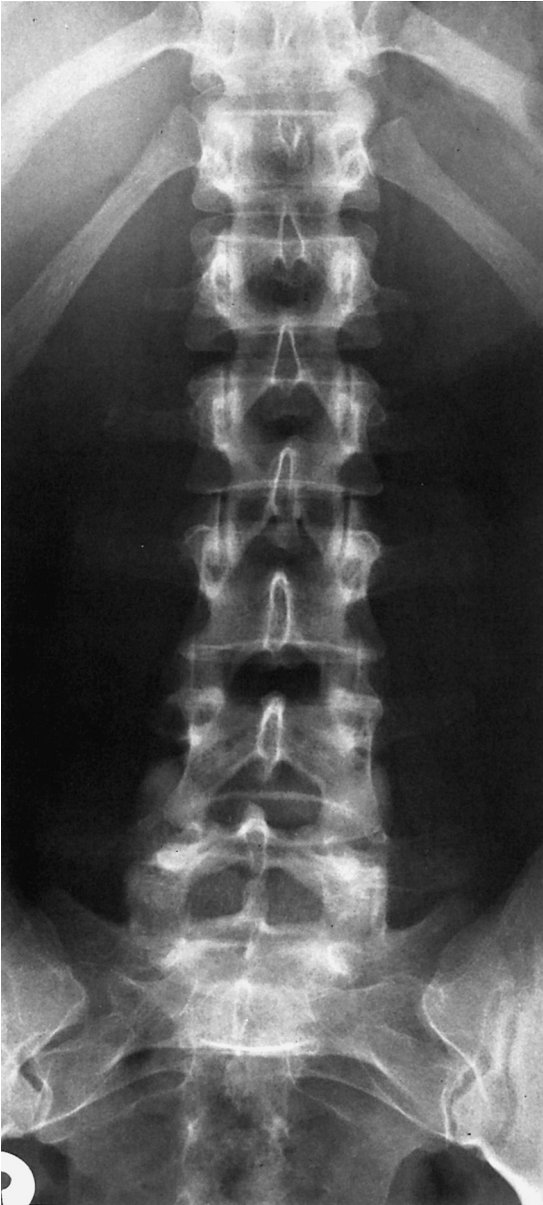


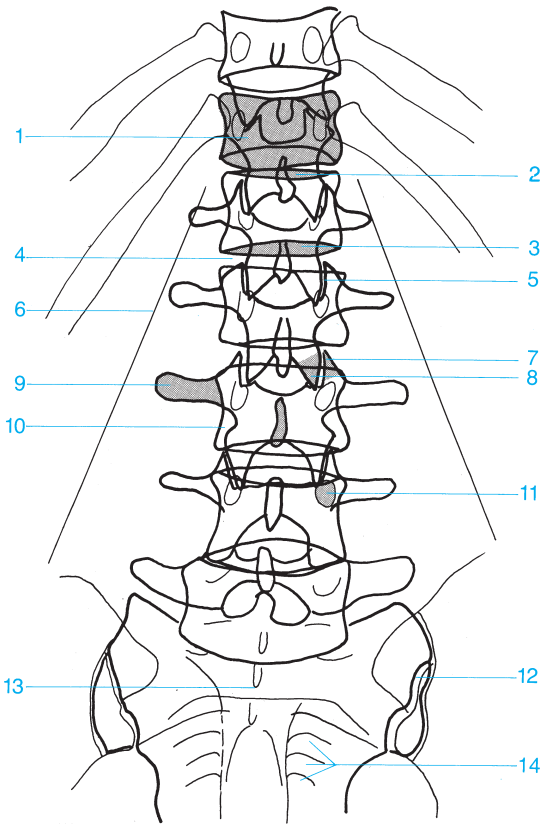
- |                                |                                 |
|--------------------------------|---------------------------------|
| 1 Tubercle of first rib        | 9 Body of vertebra              |
| 2 Neck of the rib              | 10 Inferior vertebral end plate |
| 3 First rib                    | 11 Transverse process           |
| 4 Trachea                      | 12 Pedicle                      |
| 5 Clavicle                     | 13 Spinous process              |
| 6 Head of the rib              | 14 Diaphragm                    |
| 7 Paravertebral line           | 15 Inferior articular process   |
| 8 Superior vertebral end plate | 16 Superior articular process   |





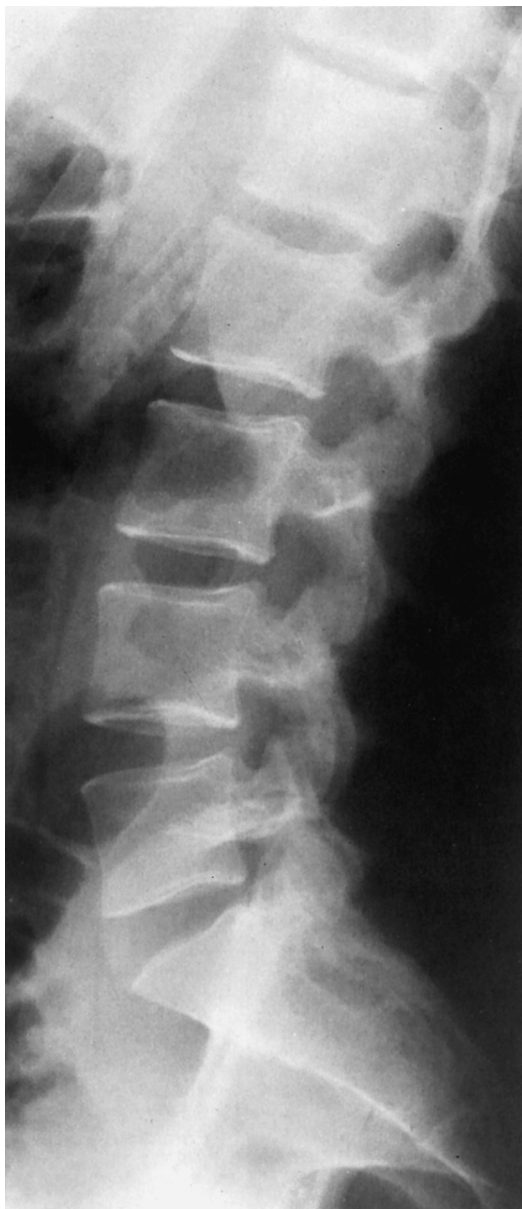- |                                |                                 |
|--------------------------------|---------------------------------|
| 1 Scapula                      | 10 Inferior vertebral end plate |
| 2 Anterior superior margin     | 11 Head of the rib              |
| 3 Posterior superior margin    | 12 Intervertebral disk space    |
| 4 Anterior inferior margin     | 13 Intervertebral foramen       |
| 5 Posterior inferior margin    | 14 Transverse process           |
| 6 Body of vertebra             | 15 Spinous process              |
| 7 Superior articular process   | 16 Diaphragm                    |
| 8 Inferior articular process   | 17 Facet joint                  |
| 9 Superior vertebral end plate |                                 |

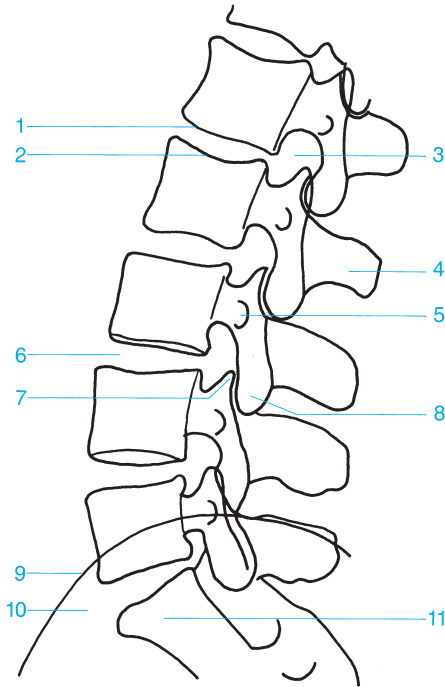




- 1 Body of vertebra
- 2 Superior vertebral end plate
- 3 Inferior vertebral end plate
- 4 Intervertebral disk space
- 5 Facet joint
- 6 Psoas
- 7 Superior articular process

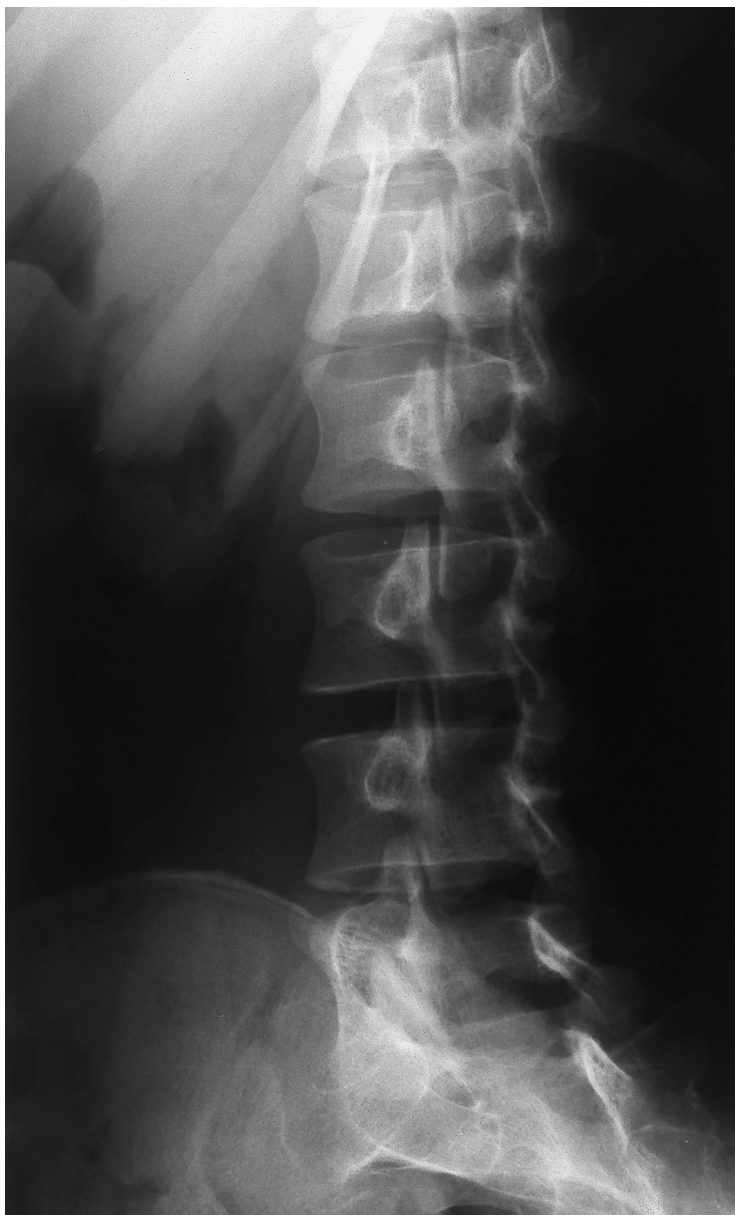- 8 Inferior articular process
- 9 Transverse process
- 10 Spinous process
- 11 Pedicle
- 12 Sacroiliac joint
- 13 Sacrum
- 14 Sacral foramina

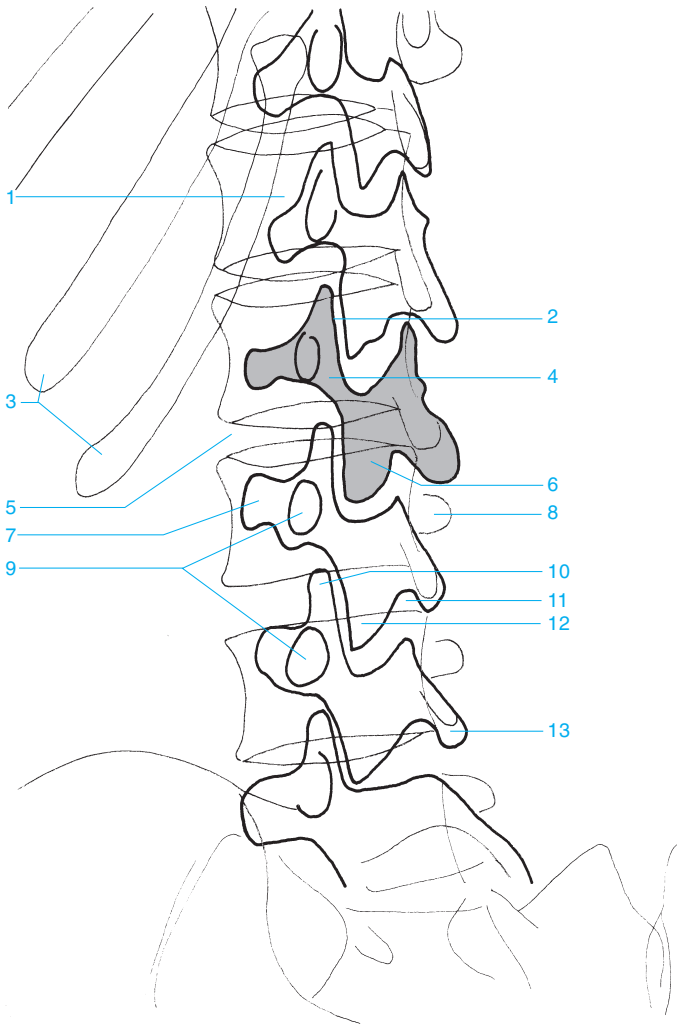




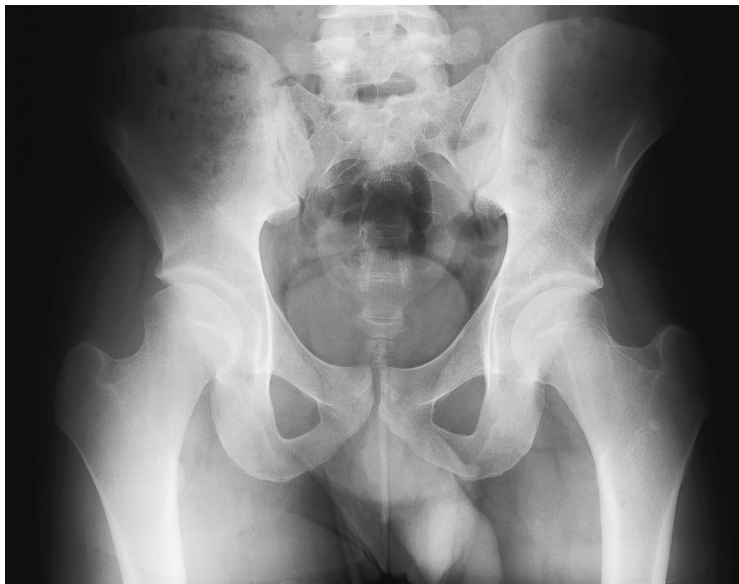
- |                                |                              |
|--------------------------------|------------------------------|
| 1 Superior vertebral end plate | 7 Superior articular process |
| 2 Inferior vertebral end plate | 8 Inferior articular process |
| 3 Intervertebral foramen       | 9 Iliac crest                |
| 4 Spinous process              | 10 Promontory                |
| 5 Transverse process           | 11 Sacrum                    |
| 6 Intervertebral disk space    |                              |

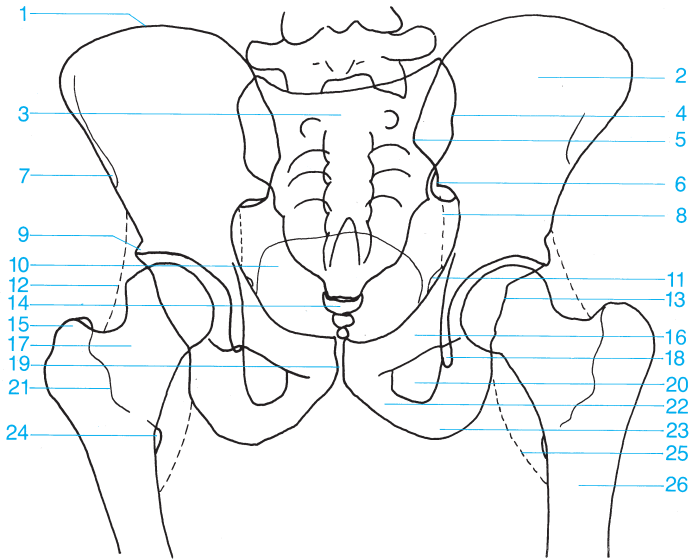




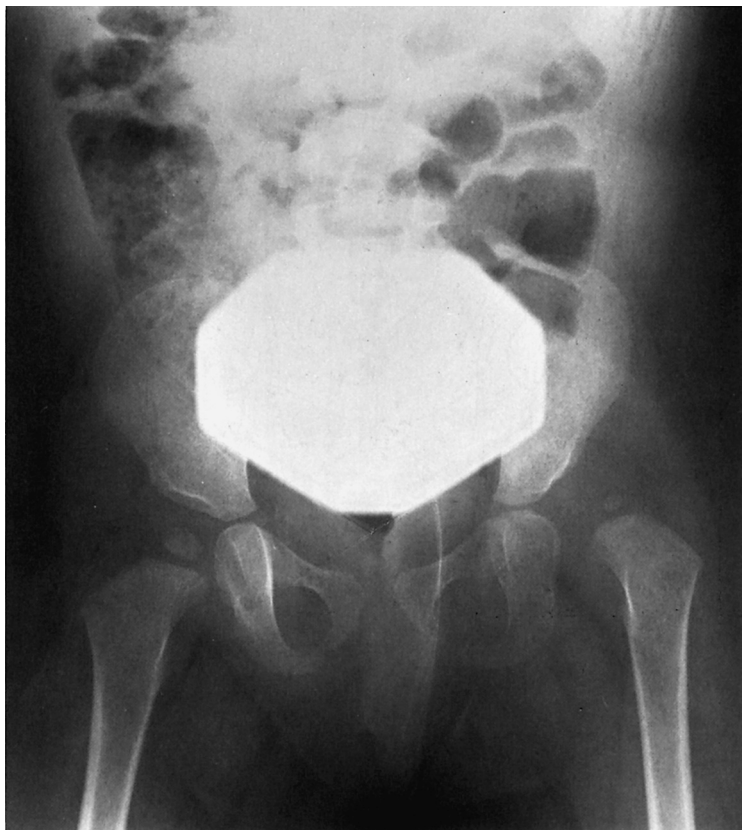


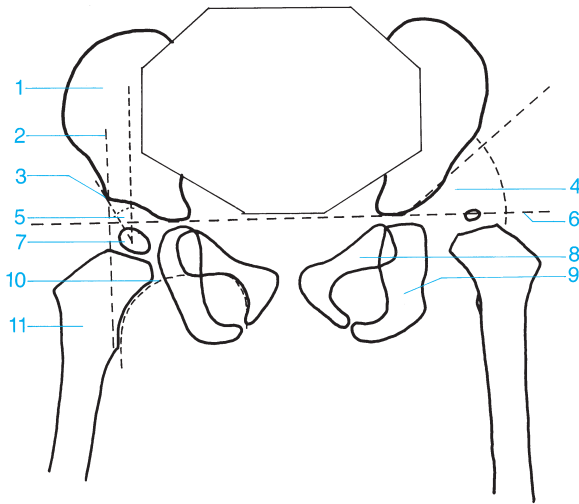
- |                                  |                                    |
|----------------------------------|------------------------------------|
| 1 Body of vertebra               | 8 Contralateral transverse process |
| 2 Intervertebral disk space      | 9 Pedicle                          |
| 3 Ribs                           | 10 Superior articular process      |
| 4 Interarticular part            | 11 Intervertebral foramen          |
| 5 Intervertebral disk space      | 12 Inferior articular process      |
| 6 Lamina                         | 13 Spinous process                 |
| 7 Ipsilateral transverse process |                                    |



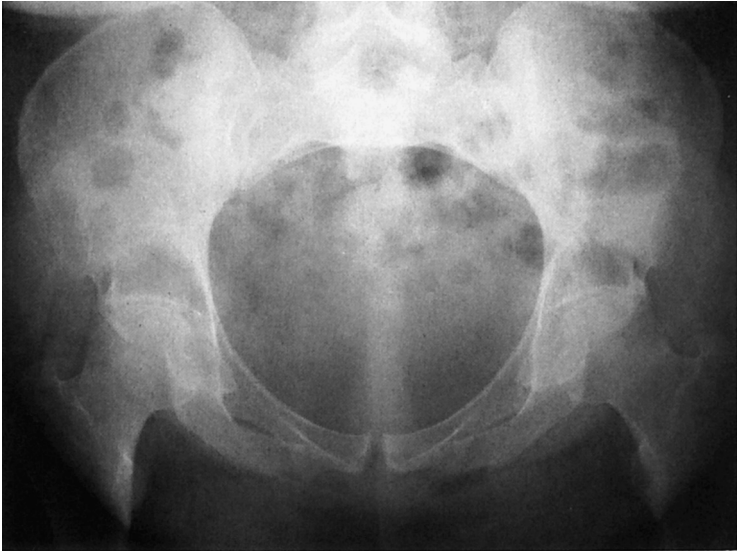

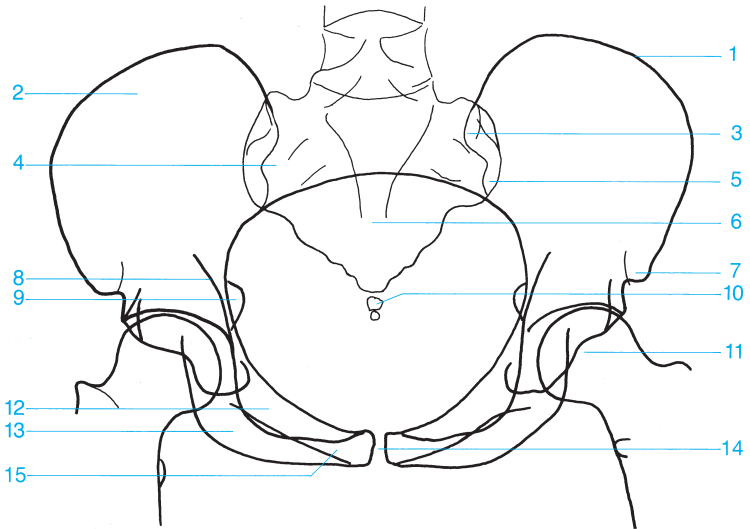
- |   |                                       |
|---|---------------------------------------|
| 1 Iliac crest                               | 14 Coccyx                             |
| 2 Iliac wing                                | 15 Greater trochanter                 |
| 3 Sacrum                                    | 16 Superior pubic ramus               |
| 4 Sacroiliac joint                          | 17 Femoral neck                       |
| 5 Posterior superior iliac spine            | 18 Acetabular teardrop                |
| 6 Posterior inferior iliac spine            | 19 Pubic symphysis                    |
| 7 Anterior superior iliac spine             | 20 Obturator foramen                  |
| 8 Obturator internus                        | 21 Intertrochanteric crest            |
| 9 Acetabular convexity (promontory)         | 22 Inferior pubic ramus               |
| 10 Urinary bladder                          | 23 Ischial tuberosity                 |
| 11 Spine of the ischium                     | 24 Lesser trochanter                  |
| 12 Fat stripe medial to the gluteus minimus | 25 Fat stripe medial to the iliopsoas |
| 13 Posterior acetabular rim                 | 26 Femur                              |





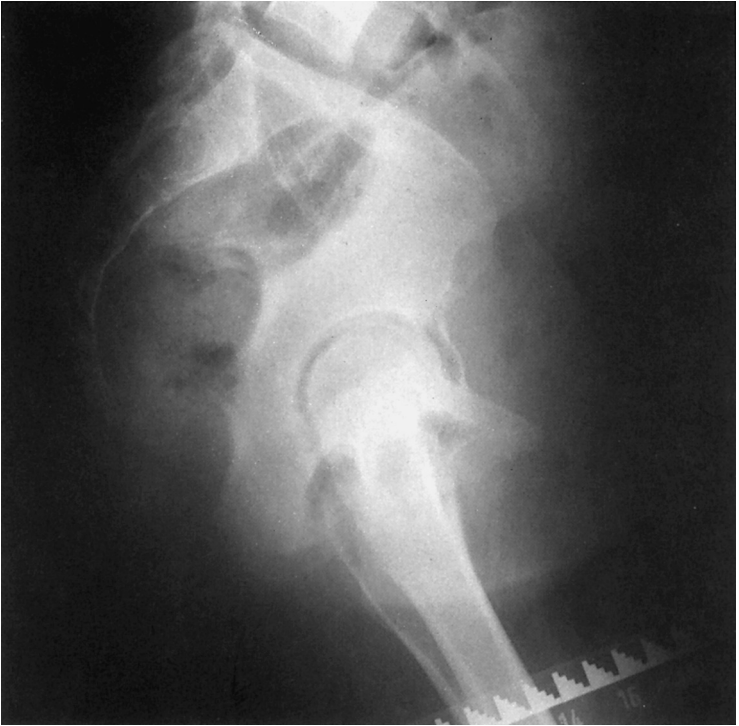- |   |   |
|---|---|
| <b>1</b> Ilium  | <b>6</b> Hilgenreiner's line (triradiate cartilage line)  |
| <b>2</b> Perkin's line (vertical line from the roof of the acetabulum intersecting Hilgenreiner's line)   | <b>7</b> Femoral epiphysis  |
| <b>3</b> Acetabular convexity (promontory)  | <b>8</b> Pubic bone   |
| <b>4</b> Angle of acetabular inclination  | <b>9</b> Ischium  |
| <b>5</b> Wiberg's center-to-corner angle (the angle between a vertical line drawn from the center of the epiphysis and a line drawn from the roof of the acetabulum to the center of the epiphysis) | <b>10</b> Shenton's line (curved line formed by the superior curve of the obturator foramen and the femoral neck) |
|   | <b>11</b> Femur   |

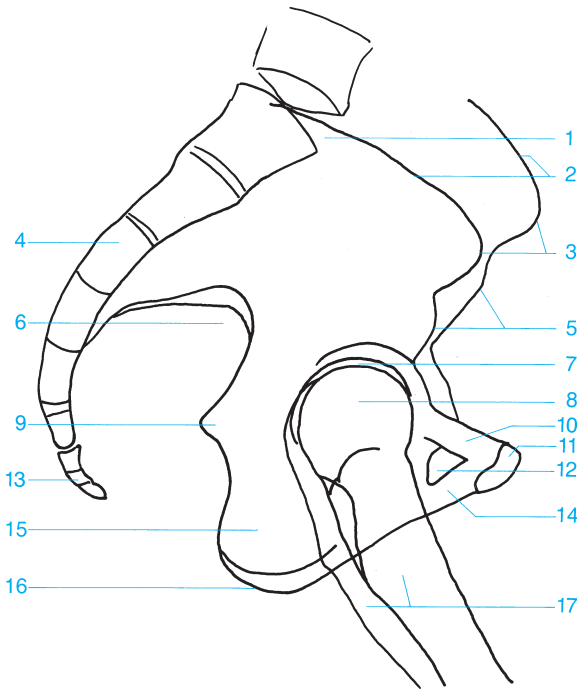




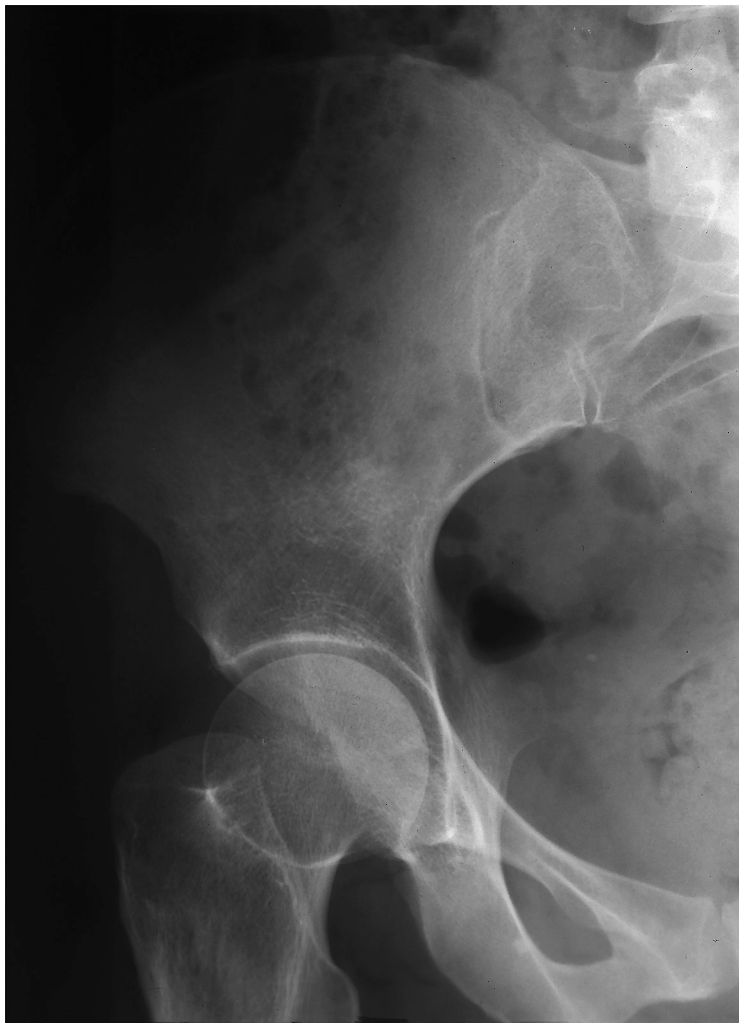- |   |                                |
|---|--------------------------------|
| <b>1</b> Iliac crest                    | <b>9</b> Spine of the ischium  |
| <b>2</b> Iliac wing                     | <b>10</b> Coccyx               |
| <b>3</b> Posterior superior iliac spine | <b>11</b> Femoral head         |
| <b>4</b> Sacral ala                     | <b>12</b> Superior pubic ramus |
| <b>5</b> Posterior inferior iliac spine | <b>13</b> Ischial tuberosity   |
| <b>6</b> Sacrum                         | <b>14</b> Pubic symphysis      |
| <b>7</b> Anterior superior iliac spine  | <b>15</b> Inferior pubic ramus |
| <b>8</b> Iliopubic line                 |                                |

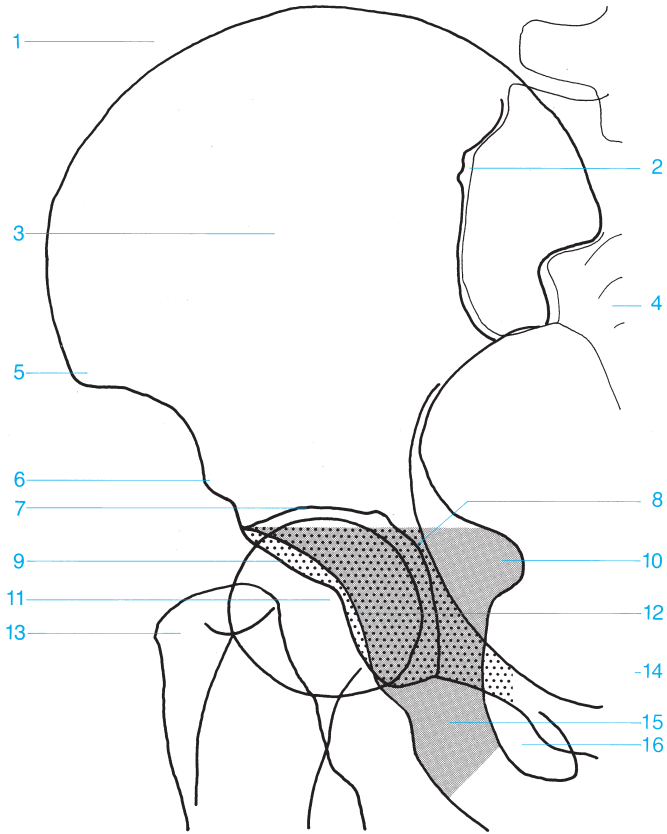




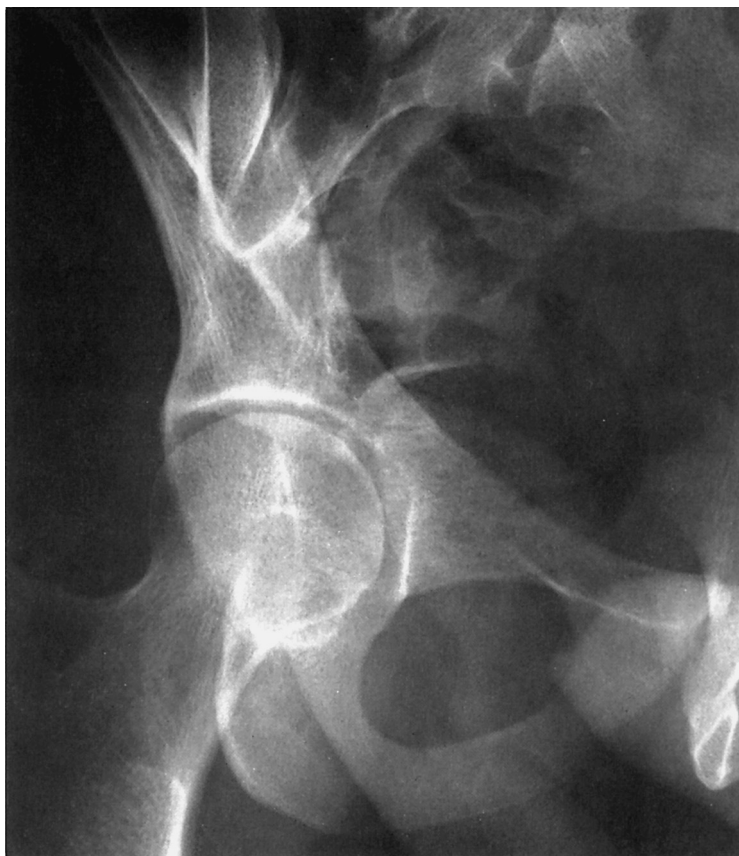

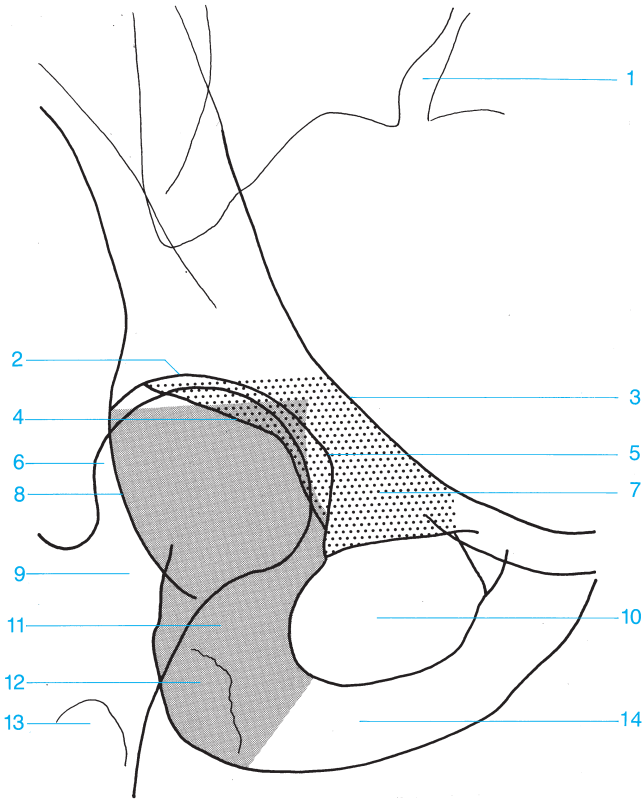
- |  |                                |
|--|--------------------------------|
| <b>1</b> Promontory                    | <b>10</b> Superior pubic ramus |
| <b>2</b> Iliac crest                   | <b>11</b> Pubic symphysis      |
| <b>3</b> Anterior superior iliac spine | <b>12</b> Obturator foramen    |
| <b>4</b> Sacrum                        | <b>13</b> Coccyx               |
| <b>5</b> Anterior inferior iliac spine | <b>14</b> Inferior pubic ramus |
| <b>6</b> Greater sciatic notch         | <b>15</b> Body of the ischium  |
| <b>7</b> Joint space of the hip        | <b>16</b> Ischial tuberosity   |
| <b>8</b> Femoral head                  | <b>17</b> Femur                |
| <b>9</b> Spine of the ischium          |                                |



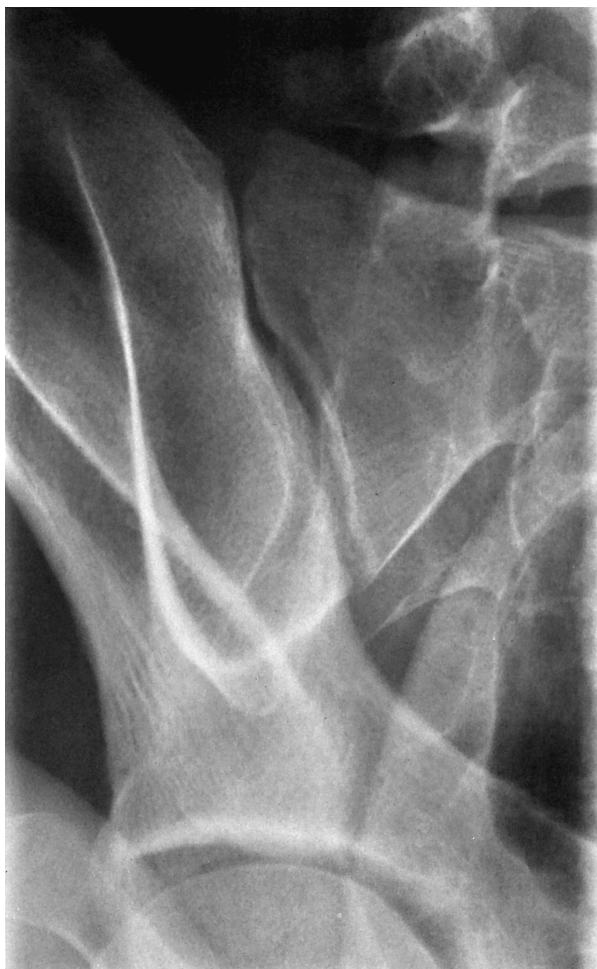

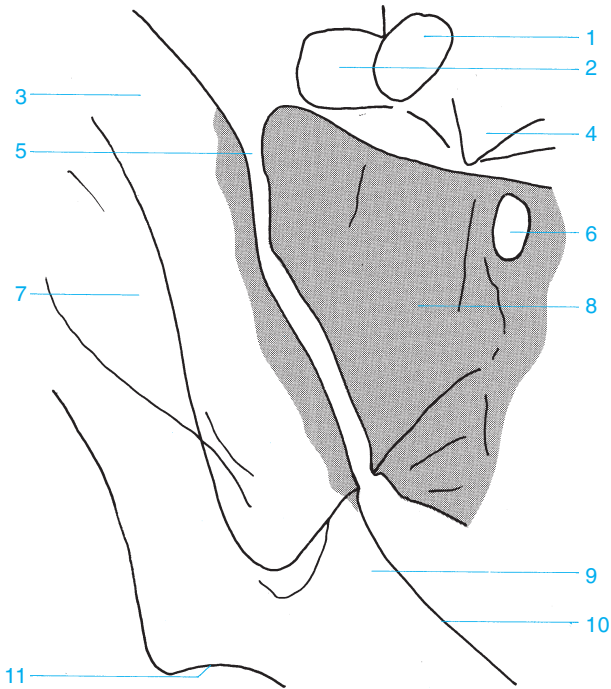
- |  |  |
|--|--|
| <b>1</b> Iliac crest                   | <b>9</b> Anterior acetabular rim       |
| <b>2</b> Sacroiliac joint              | <b>10</b> Spine of the ischium         |
| <b>3</b> Iliac wing                    | <b>11</b> Femoral head                 |
| <b>4</b> Sacrum                        | <b>12</b> Posterior acetabular rim     |
| <b>5</b> Anterior superior iliac spine | <b>13</b> Greater trochanter           |
| <b>6</b> Anterior inferior iliac spine | <b>14</b> Pubic bone (anterior column) |
| <b>7</b> Roof of the acetabulum        | <b>15</b> Ischium (posterior column)   |
| <b>8</b> Floor of the acetabulum       | <b>16</b> Obturator foramen            |





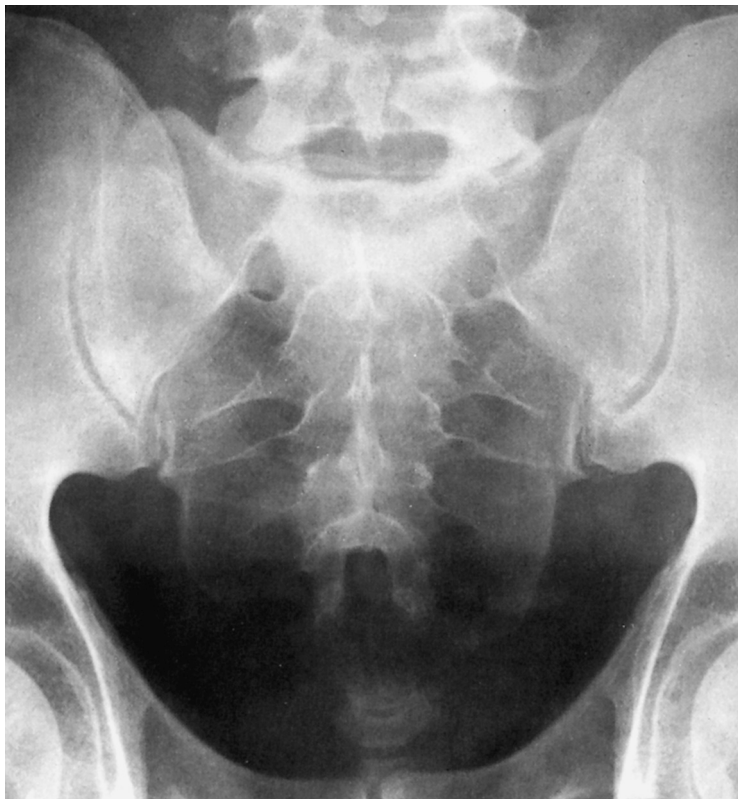- |                                       |                                      |
|---------------------------------------|--------------------------------------|
| <b>1</b> Sacroiliac joint             | <b>8</b> Posterior acetabular rim    |
| <b>2</b> Roof of the acetabulum       | <b>9</b> Femoral neck                |
| <b>3</b> Iliopectineal line           | <b>10</b> Obturator foramen          |
| <b>4</b> Anterior acetabular rim      | <b>11</b> Ischium (posterior column) |
| <b>5</b> Anterior acetabular floor    | <b>12</b> Ischial tuberosity         |
| <b>6</b> Femoral head                 | <b>13</b> Lesser trochanter          |
| <b>7</b> Pubic bone (anterior column) | <b>14</b> Inferior pubic ramus       |

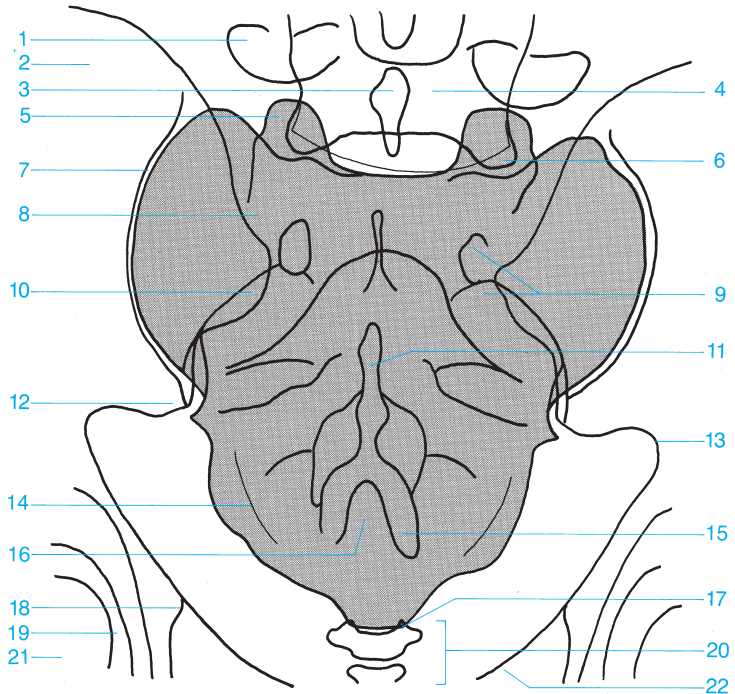




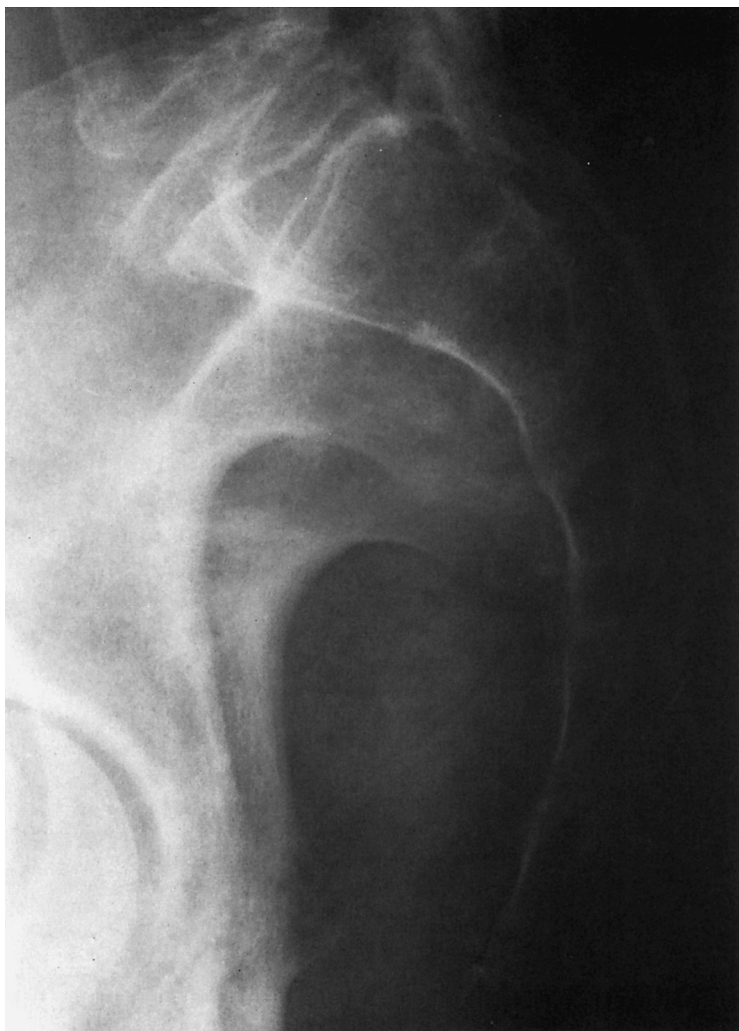
- |                                   |                                     |
|-----------------------------------|-------------------------------------|
| <b>1</b> Pedicle of L5            | <b>7</b> Iliac wing                 |
| <b>2</b> Transverse process of L5 | <b>8</b> Lateral part of the sacrum |
| <b>3</b> Iliac wing               | <b>9</b> Ilium                      |
| <b>4</b> Body of vertebra L5      | <b>10</b> Arcuate line              |
| <b>5</b> Sacroiliac joint         | <b>11</b> Roof of the acetabulum    |
| <b>6</b> Sacral foramen           |                                     |

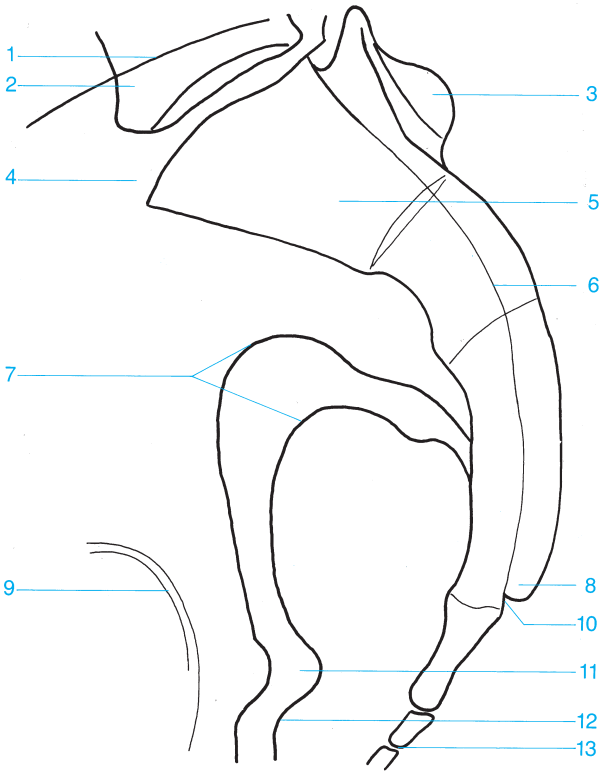






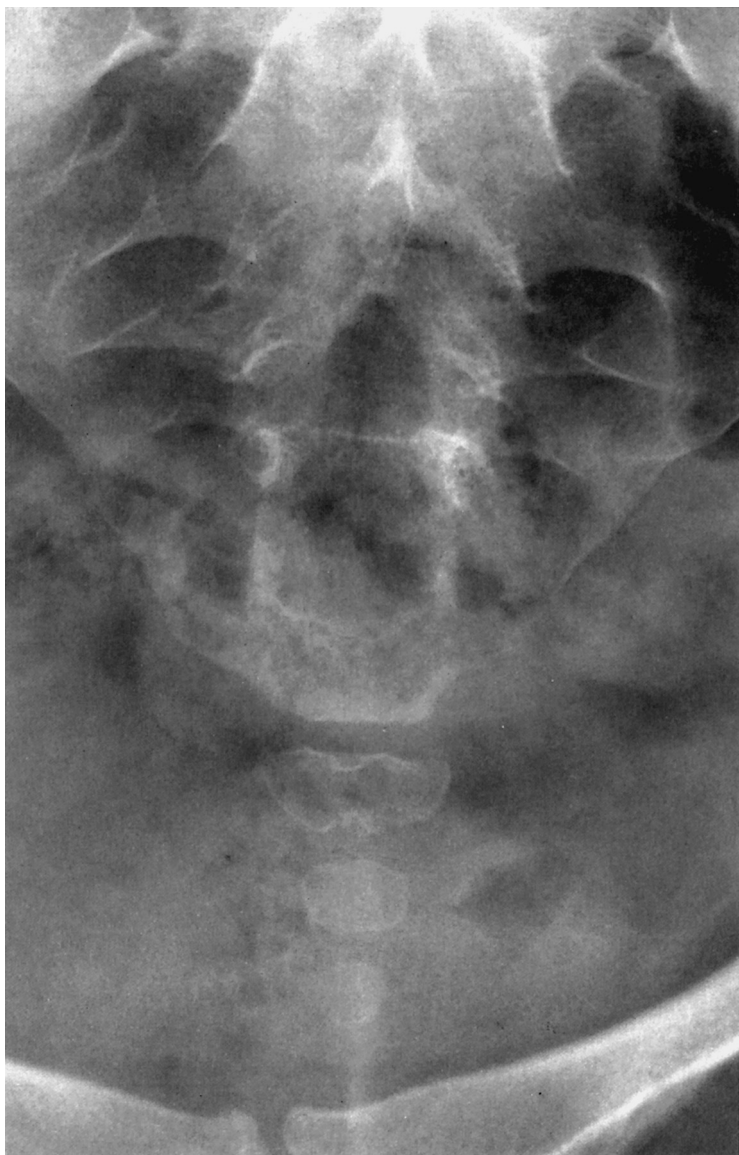
- |                                    |                                   |
|------------------------------------|-----------------------------------|
| 1 Transverse process               | 12 Posterior inferior iliac spine |
| 2 Iliac wing                       | 13 Greater sciatic notch          |
| 3 Spinous process                  | 14 Lateral sacral crest           |
| 4 L5                               | 15 Cornu of the sacrum            |
| 5 Superior articular process       | 16 Sacral hiatus                  |
| 6 Inferior articular process of L5 | 17 Cornu of the coccyx            |
| 7 Sacroiliac joint                 | 18 Spine of the ischium           |
| 8 Sacral ala                       | 19 Hip                            |
| 9 Sacral foramina                  | 20 Coccyx                         |
| 10 Posterior superior iliac spine  | 21 Femoral head                   |
| 11 Median sacral crest             | 22 Superior pubic ramus           |

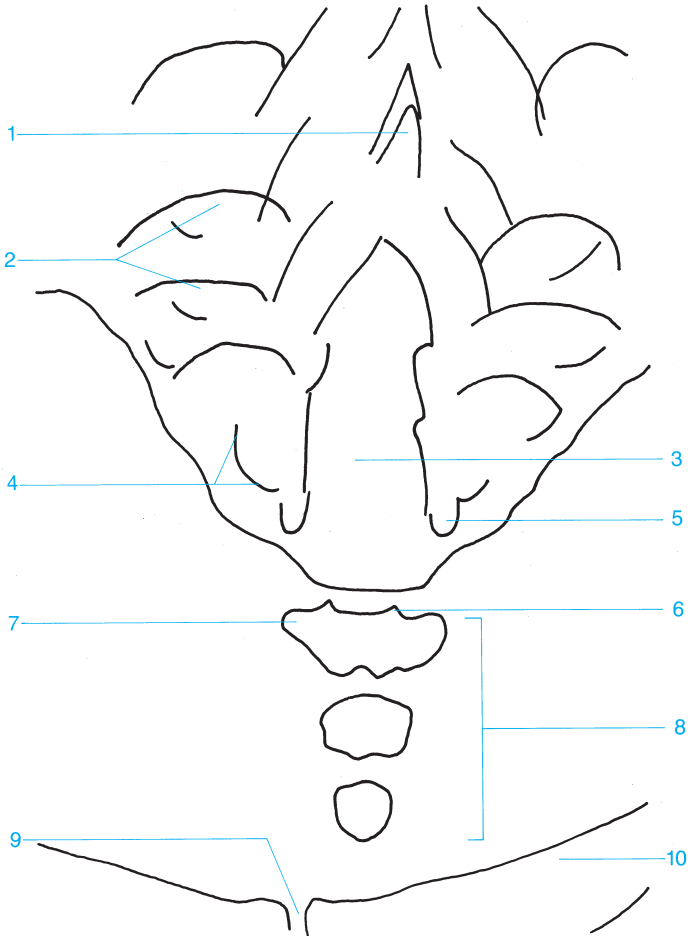




- 1 Iliac crest
- 2 L5
- 3 Median sacral crest
- 4 Promontory
- 5 Sacrum
- 6 Sacral canal
- 7 Greater sciatic notch

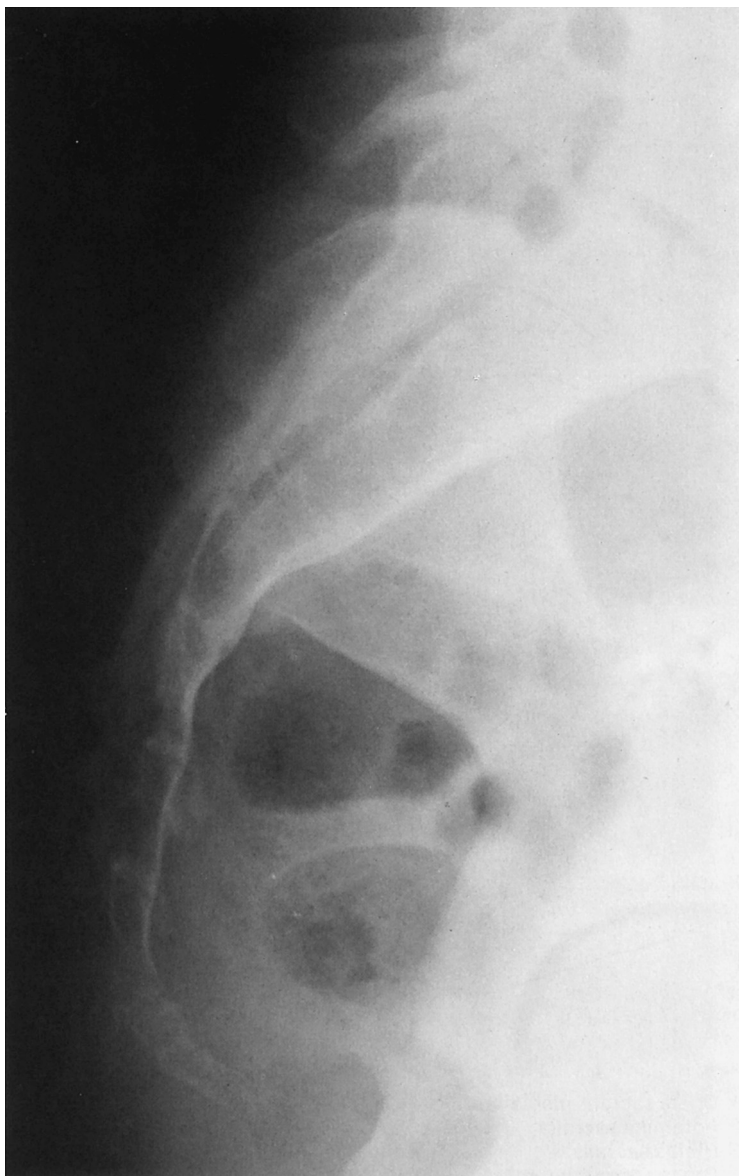
- 8 Cornu of the sacrum
- 9 Hip
- 10 Sacral canal
- 11 Spine of the ischium
- 12 Lesser sciatic notch
- 13 Coccyx

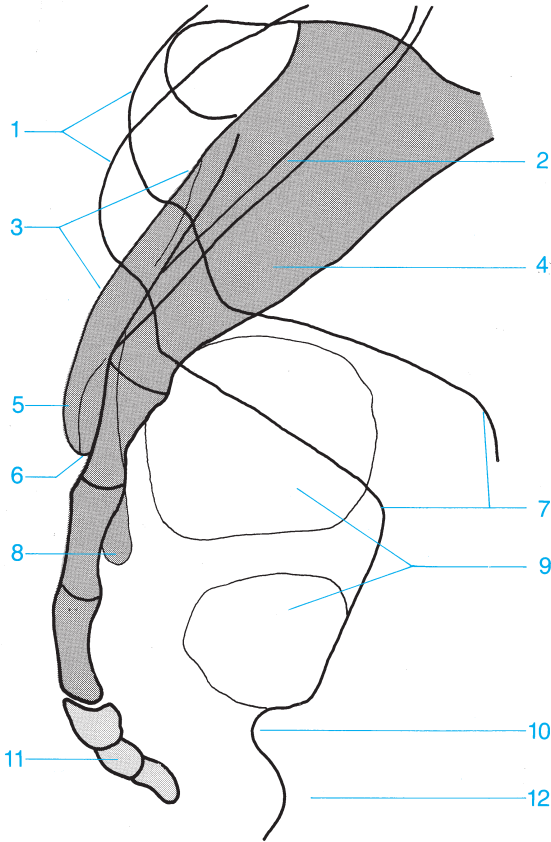




- 1 Median sacral crest
- 2 Sacral foramina
- 3 Sacral hiatus
- 4 Lateral sacral crest
- 5 Cornu of the sacrum

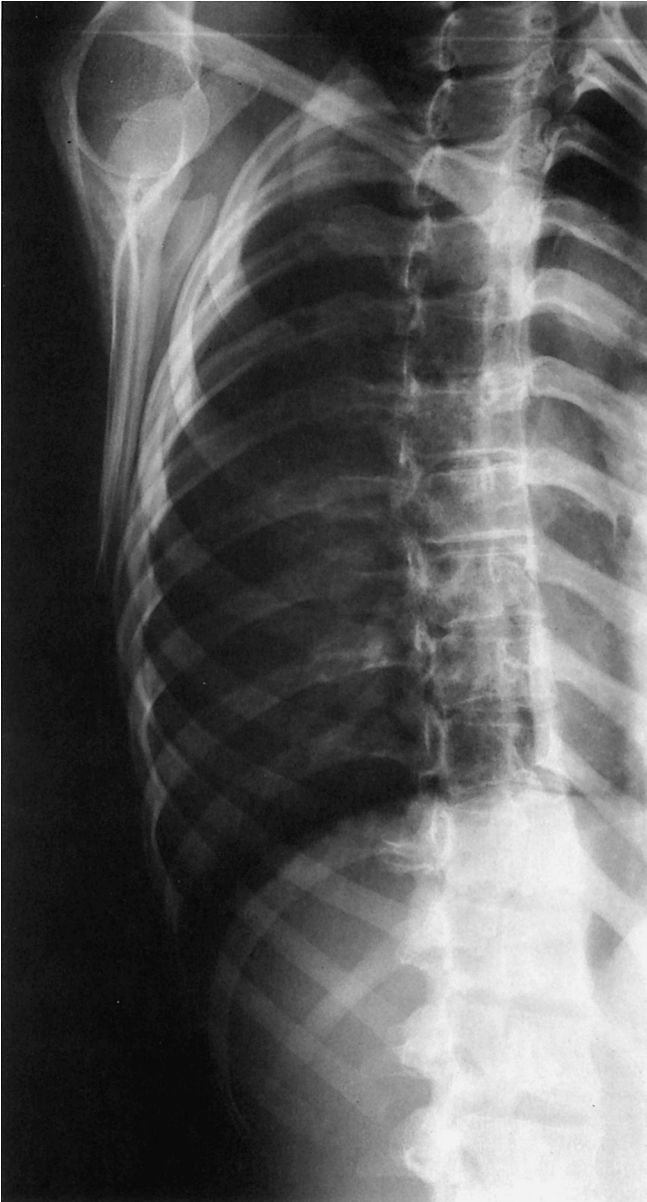
- 6 Cornu of the coccyx
- 7 Transverse process
- 8 Coccyx
- 9 Pubic symphysis
- 10 Superior pubic ramus

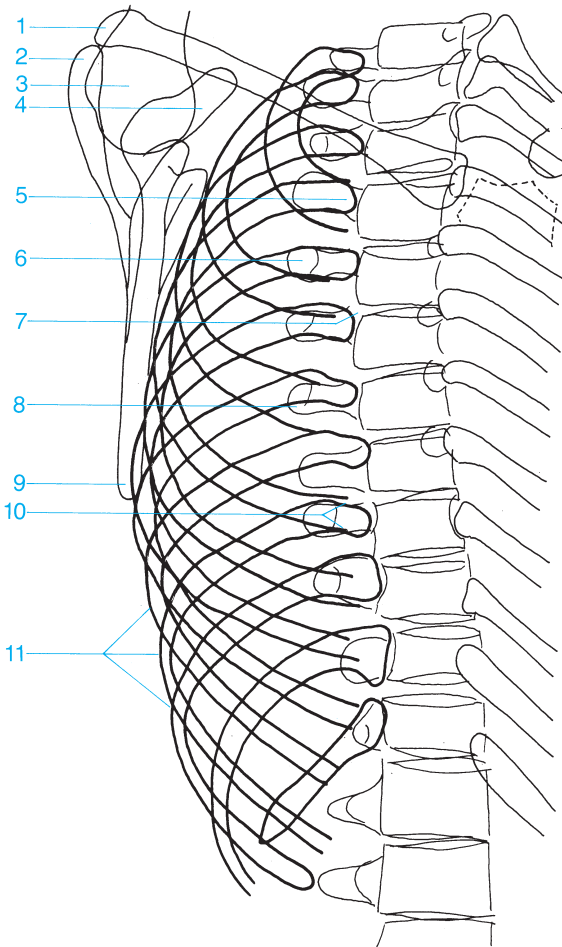




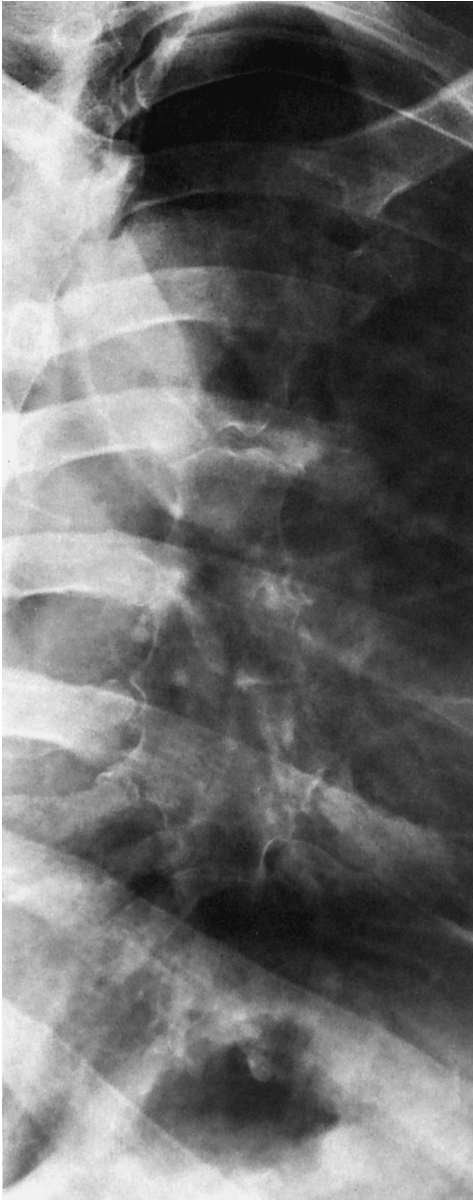- |                       |                         |
|-----------------------|-------------------------|
| 1 Iliac crest         | 7 Greater sciatic notch |
| 2 Sacral canal        | 8 Lateral sacral crest  |
| 3 Median sacral crest | 9 Rectal gas            |
| 4 Sacrum              | 10 Spine of the ischium |
| 5 Cornu of the sacrum | 11 Coccyx               |
| 6 Sacral canal        | 12 Ischium              |

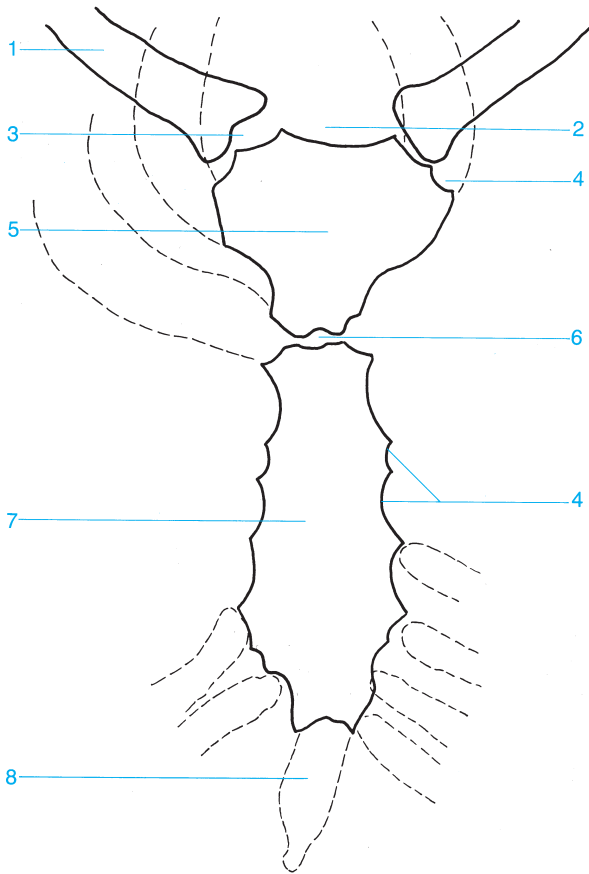




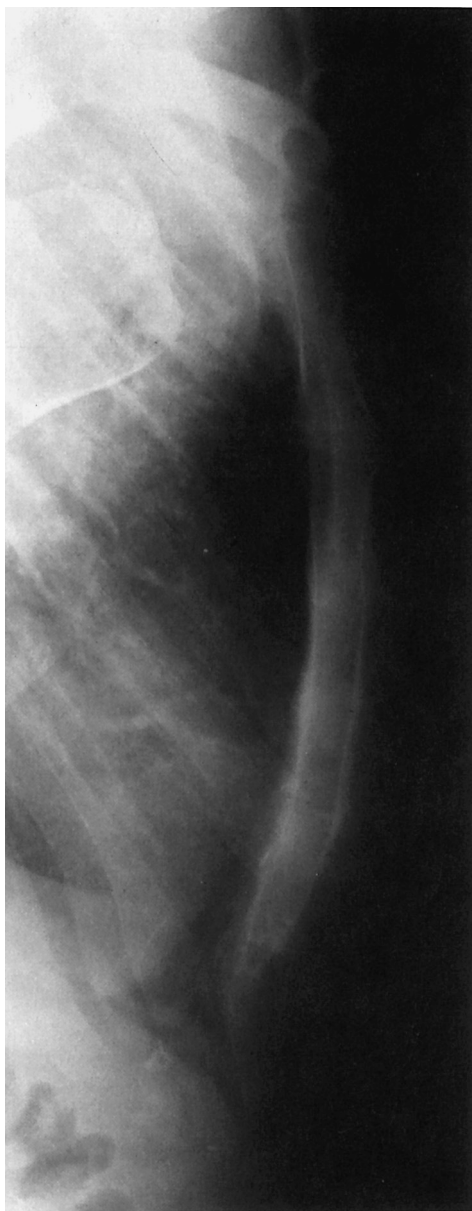


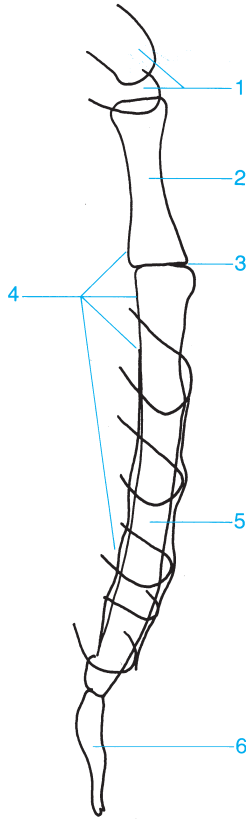
- |                         |                                 |
|-------------------------|---------------------------------|
| 1 Clavicle (distal end) | 7 Costovertebral articulation   |
| 2 Acromion              | 8 Transverse process            |
| 3 Humeral head          | 9 Inferior angle of the scapula |
| 4 Coracoid process      | 10 Neck of the rib              |
| 5 Head of the rib       | 11 Costal arch                  |
| 6 Costotransverse joint |                                 |



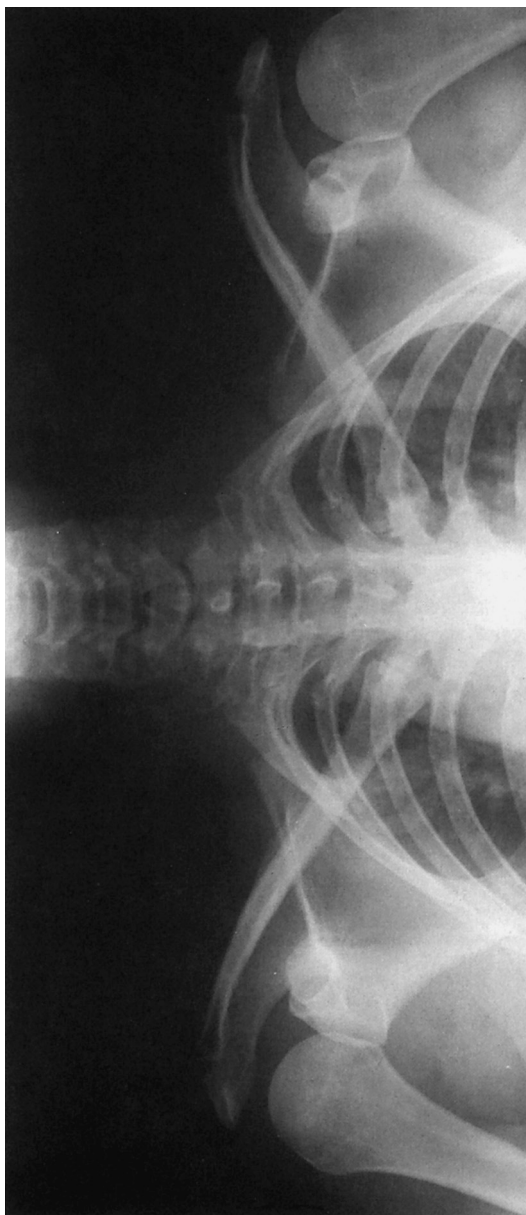


- |                          |                            |
|--------------------------|----------------------------|
| 1 Clavicle               | 5 Manubrium of the sternum |
| 2 Sternal notch          | 6 Sternal angle            |
| 3 Sternoclavicular joint | 7 Body of the sternum      |
| 4 Costal notch           | 8 Xiphoid process          |





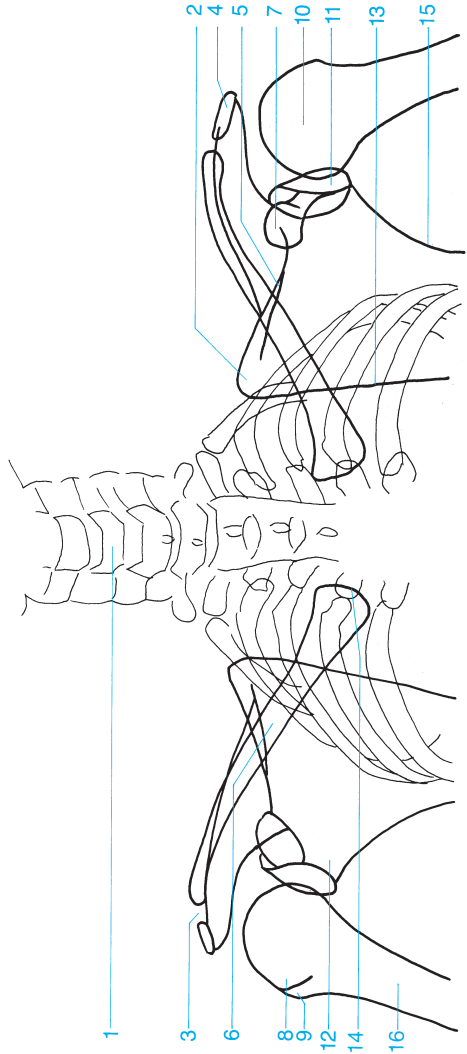
- |                            |                       |
|----------------------------|-----------------------|
| 1 Clavicles                | 4 Retrosternal space  |
| 2 Manubrium of the sternum | 5 Body of the sternum |
| 3 Sternal angle            | 6 Xiphoid process     |



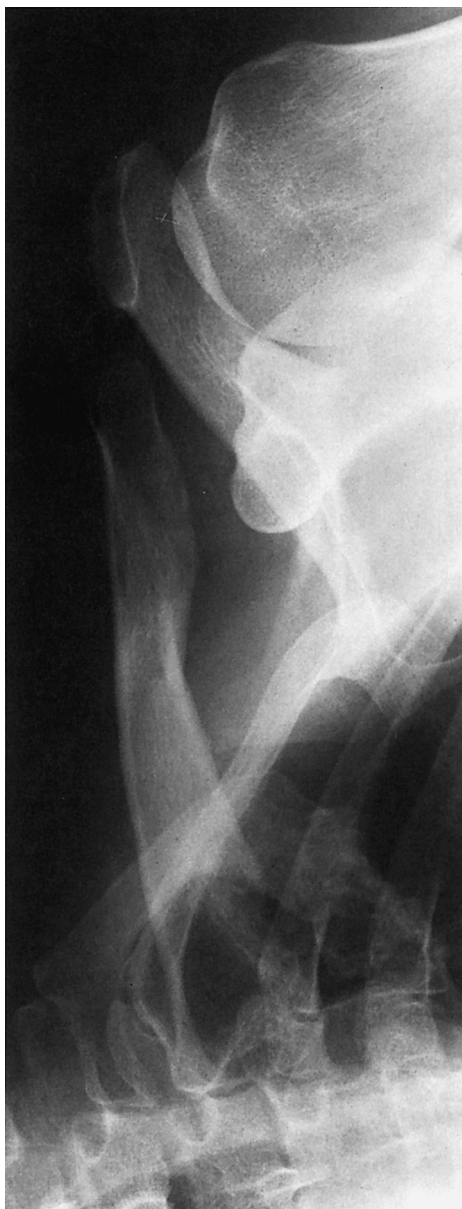- 1 Cervical spine
- 2 Superior angle of the scapula
- 3 Acromioclavicular joint
- 4 Acromion
- 5 Spine of the scapula
- 6 Clavicle

- 7 Coracoid
- 8 Lesser tubercle of the humerus
- 9 Greater tubercle of the humerus
- 10 Humeral head
- 11 Glenoid fossa (articular surface)

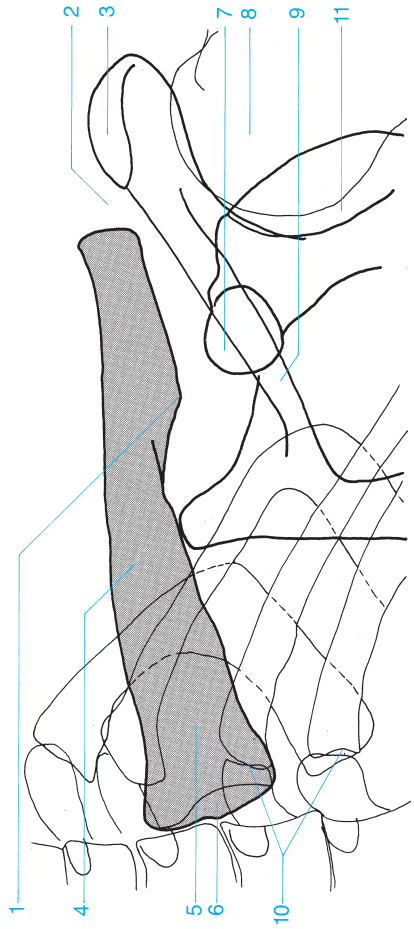
- 12 Glenoid process of the scapula
- 13 Medial margin of the scapula
- 14 Proximal clavicle
- 15 Lateral margin of the scapula
- 16 Humerus

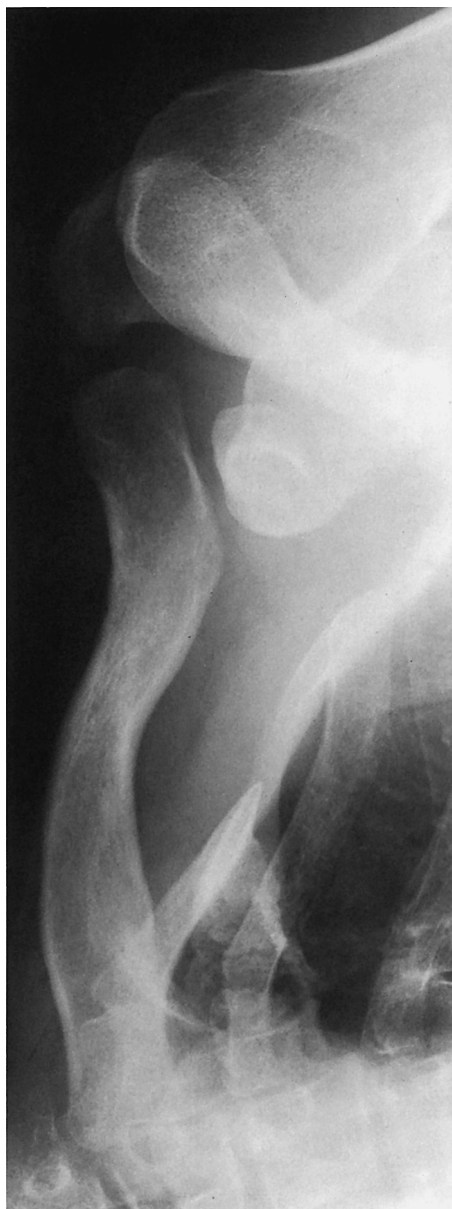



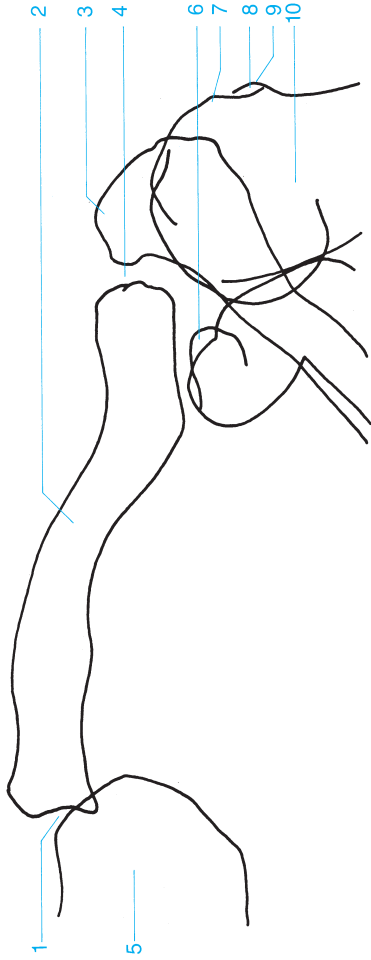


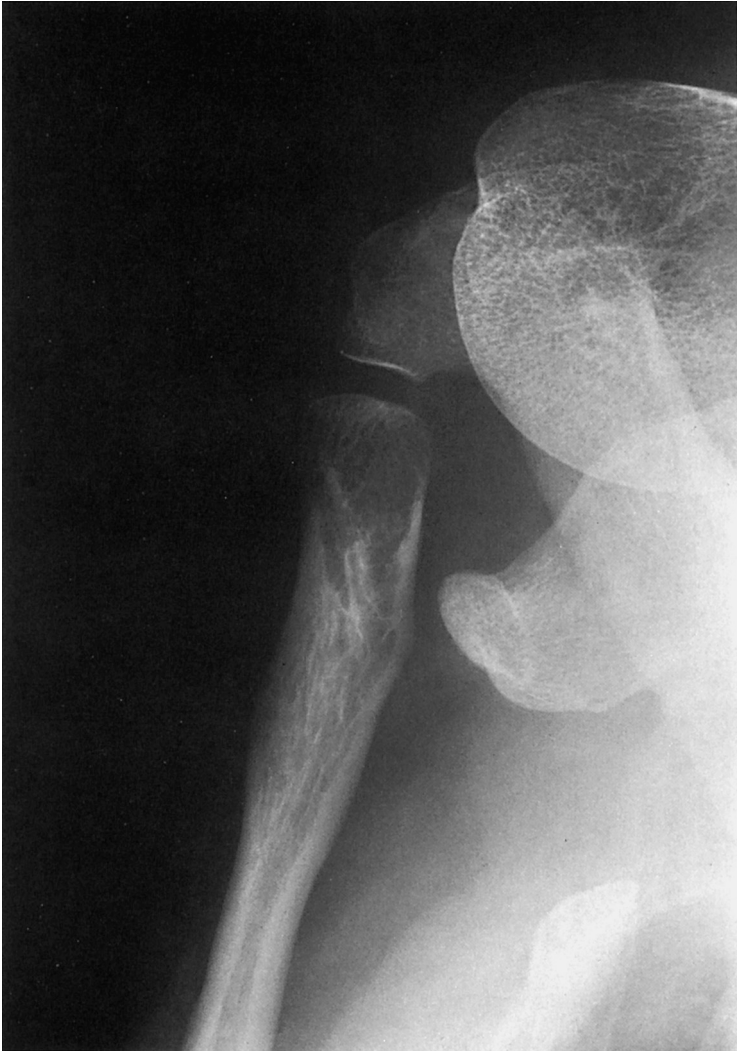- 1 Conoid tubercle of the clavicle
- 2 Acromioclavicular joint
- 3 Acromion
- 4 Clavicle
- 5 Superior angle of the scapula
- 6 Proximal clavicle
- 7 Coracoid process
- 8 Humeral head
- 9 Spine of the scapula
- 10 Costoclavicular joint
- 11 Glenoid fossa



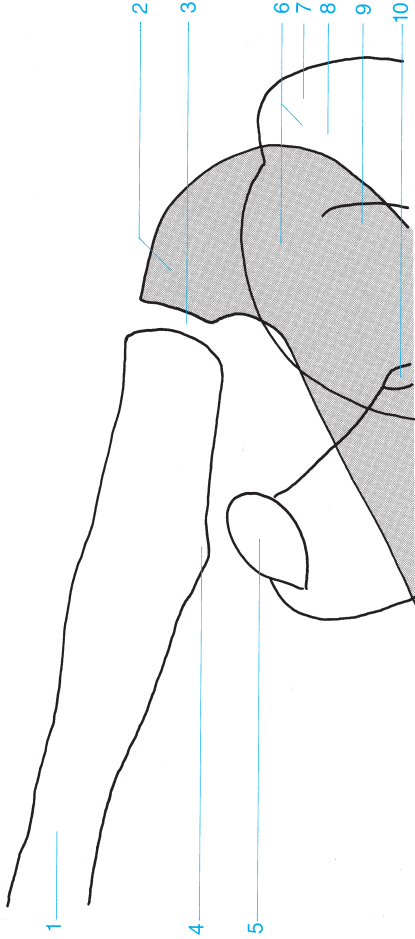


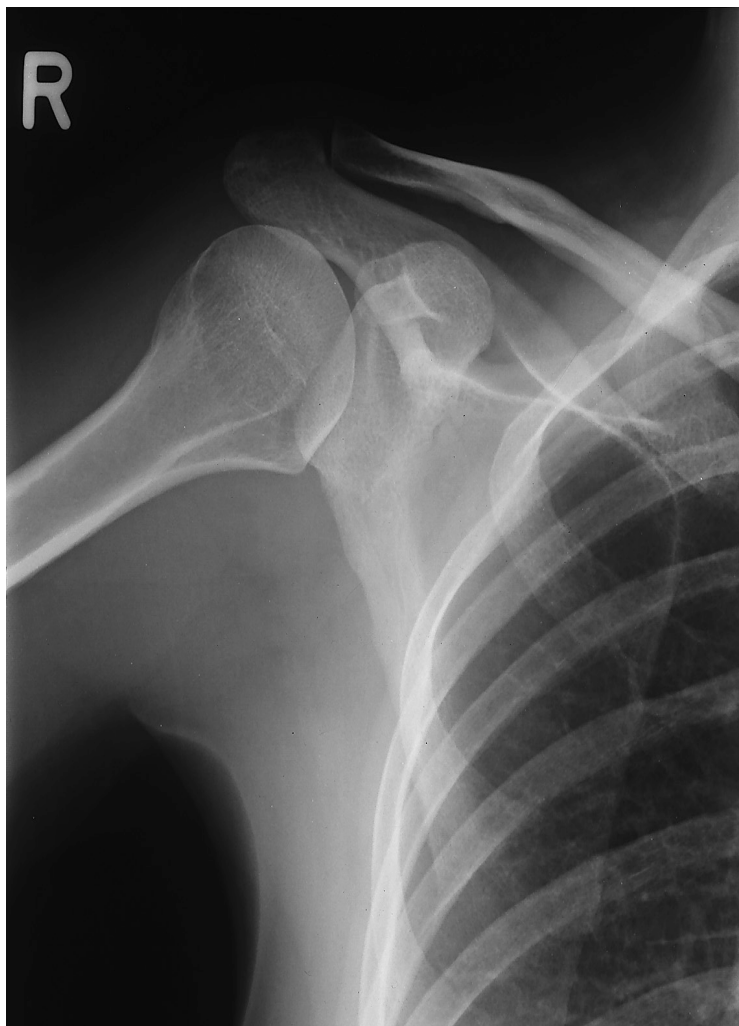- 1 Sternoclavicular joint
- 2 Clavicle
- 3 Acromion
- 4 Acromioclavicular joint
- 5 Sternum (manubrium)
- 6 Coracoid process
- 7 Greater tubercle of the humerus
- 8 Bicipital groove
- 9 Lesser tubercle of the humerus
- 10 Humeral head

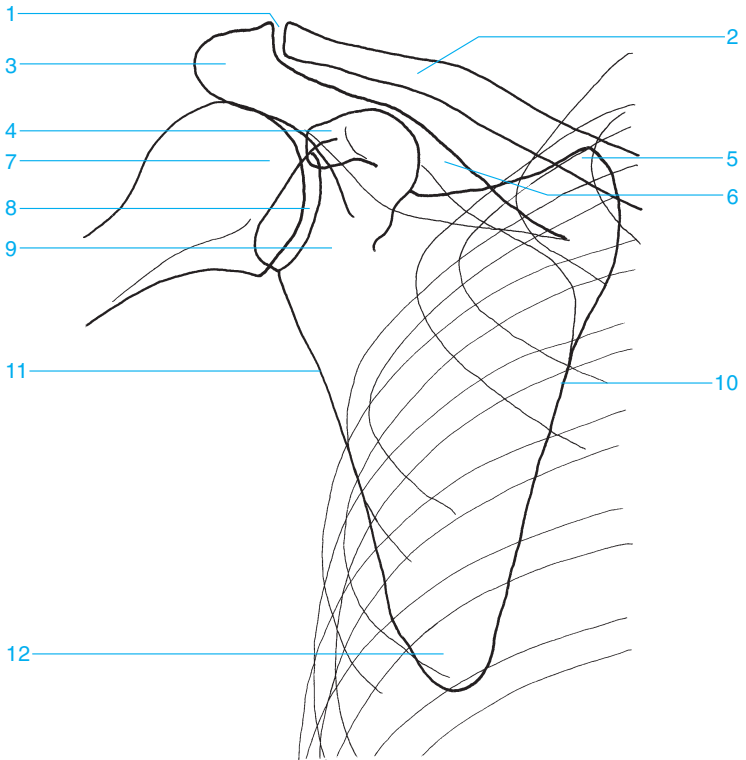




- 1 Clavicle
- 2 Acromion
- 3 Acromioclavicular joint
- 4 Conoid tubercle of the clavicle
- 5 Coracoid process
- 6 Humeral head
- 7 Greater tubercle of the humerus
- 8 Bicipital groove
- 9 Lesser tubercle of the humerus
- 10 Glenoid fossa

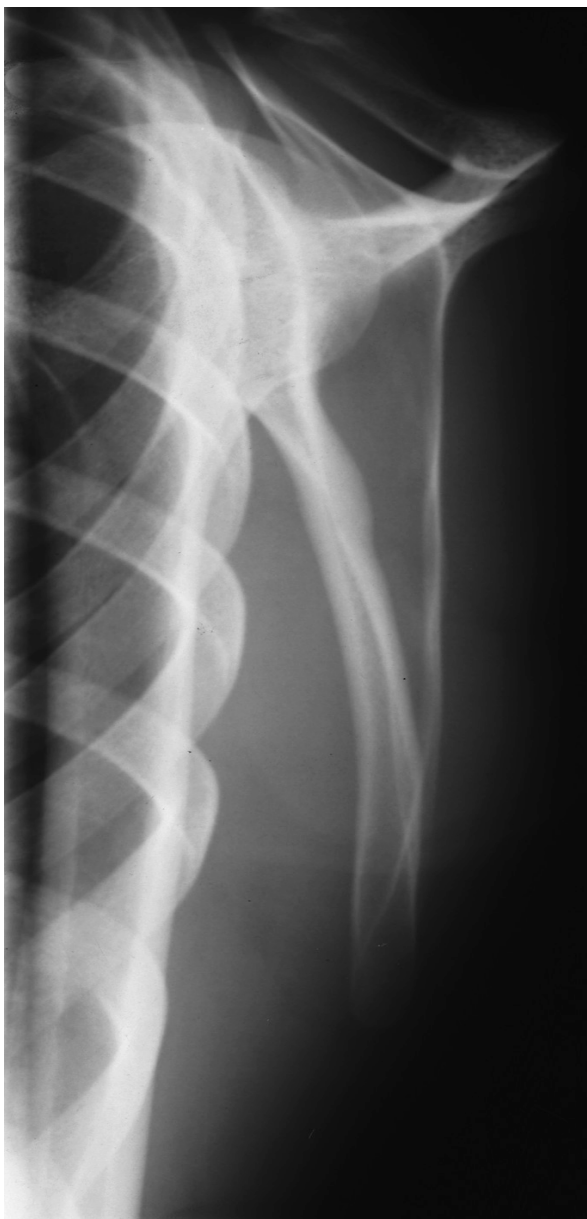


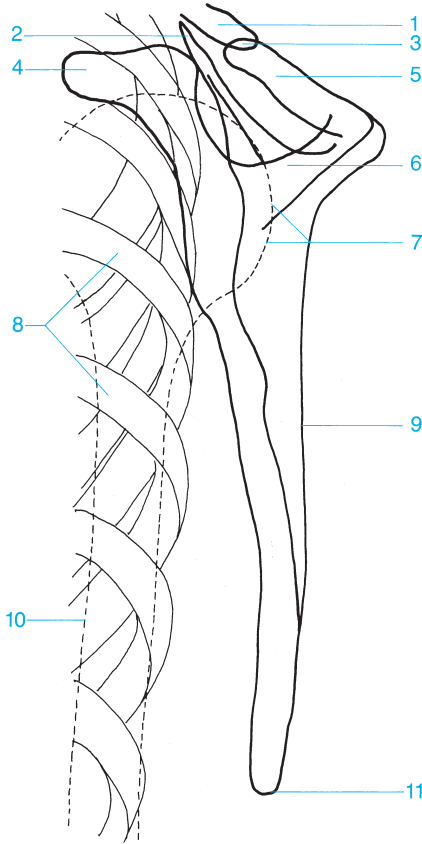




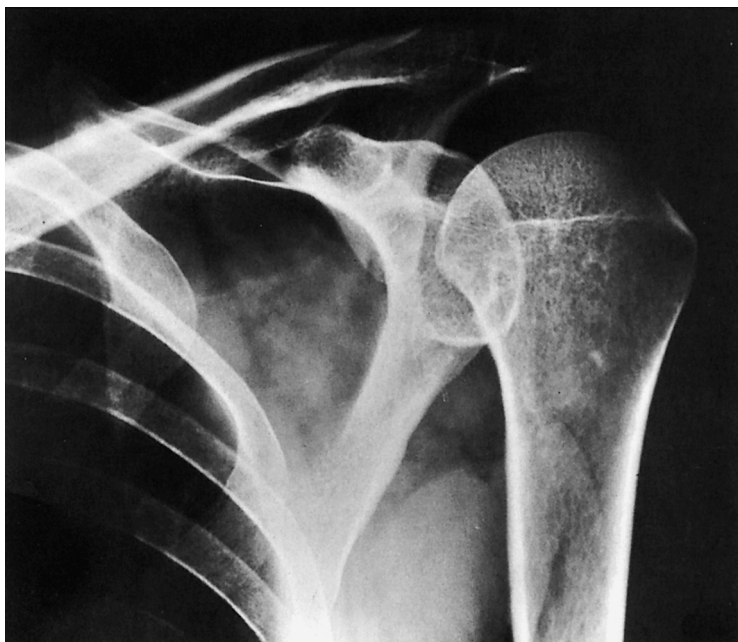- |                                  |  |
|----------------------------------|--|
| <b>1</b> Acromioclavicular joint | <b>8</b> Articular surface                     |
| <b>2</b> Clavicle                | <b>9</b> Lateral process (neck) of the scapula |
| <b>3</b> Acromion                | <b>10</b> Medial margin                        |
| <b>4</b> Coracoid process        | <b>11</b> Lateral margin                       |
| <b>5</b> Superior angle          | <b>12</b> Inferior angle                       |
| <b>6</b> Spine of the scapula    |  |
| <b>7</b> Humeral head            |  |

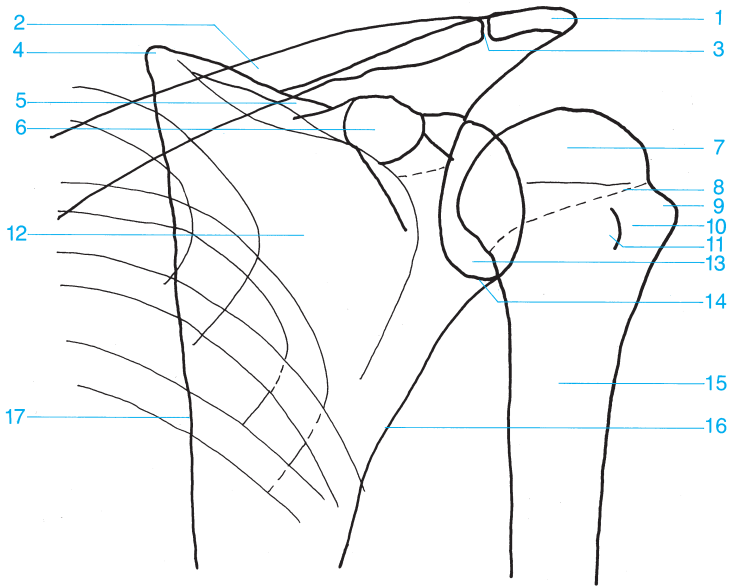




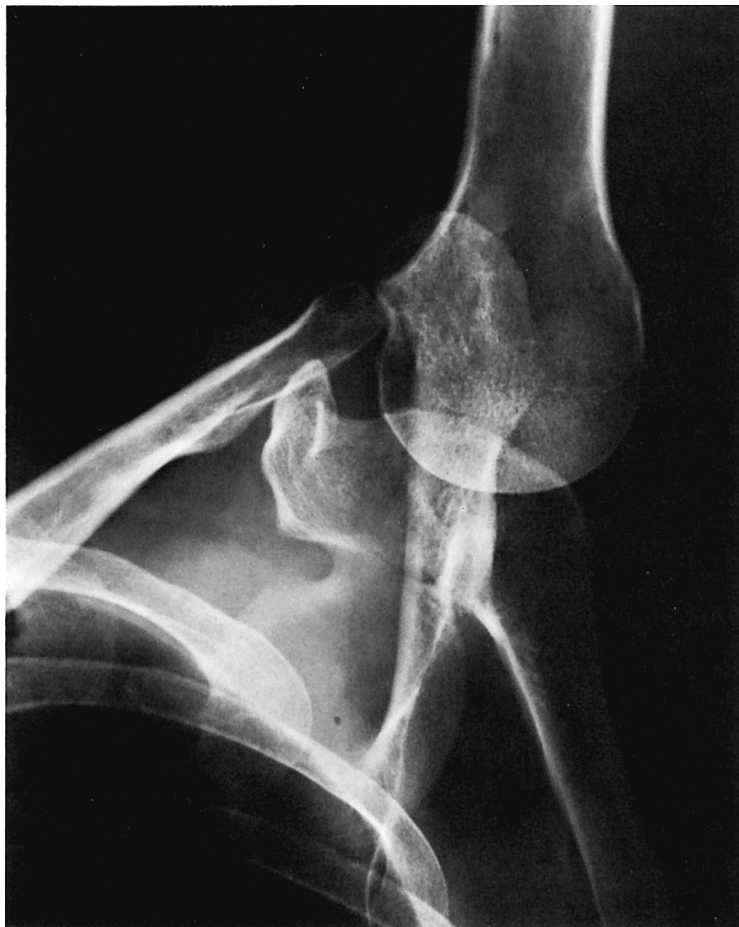

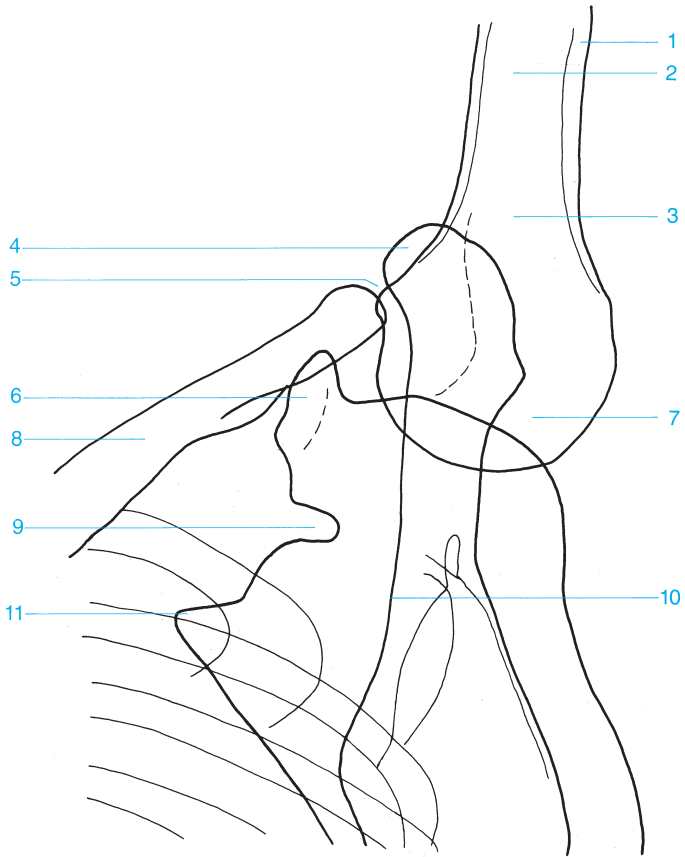
- |                                 |                                  |
|---------------------------------|----------------------------------|
| 1 Distal clavicle               | 7 Humeral head                   |
| 2 Superior angle of the scapula | 8 Ribs                           |
| 3 Acromioclavicular joint       | 9 Lateral margin of the scapula  |
| 4 Coracoid process              | 10 Humeral shaft                 |
| 5 Acromion                      | 11 Inferior angle of the scapula |
| 6 Spine of the scapula          |                                  |



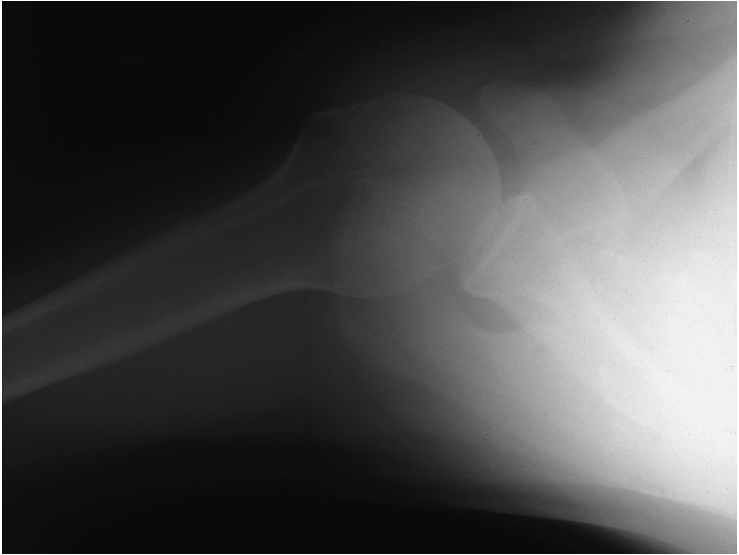


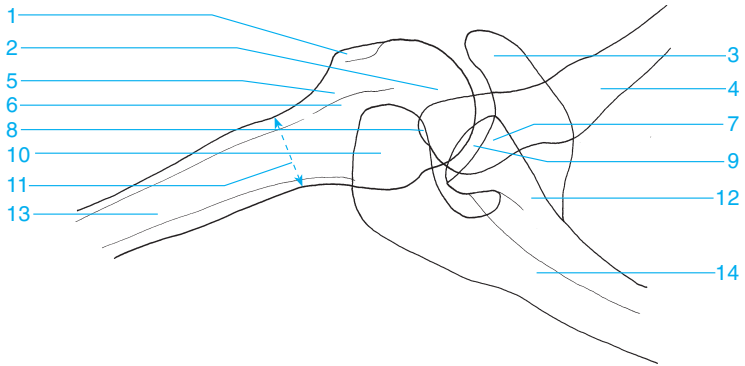
- |                                   |                                   |
|-----------------------------------|-----------------------------------|
| 1 Acromion                        | 10 Bicipital groove               |
| 2 Clavicle                        | 11 Lesser tubercle of the humerus |
| 3 Acromioclavicular joint         | 12 Scapula                        |
| 4 Superior angle of the scapula   | 13 Glenoid fossa                  |
| 5 Spine of the scapula            | 14 Glenoid labrum                 |
| 6 Coracoid process                | 15 Surgical neck                  |
| 7 Humeral head                    | 16 Lateral margin of the scapula  |
| 8 Anatomical neck                 | 17 Medial margin of the scapula   |
| 9 Greater tubercle of the humerus |                                   |





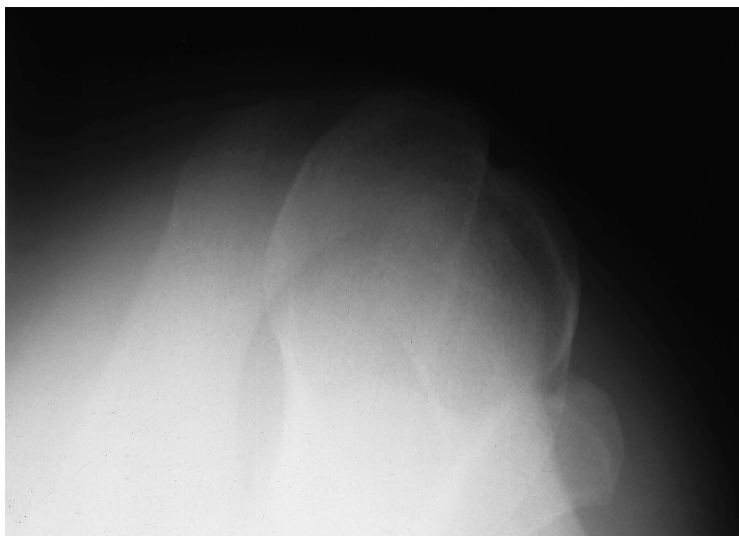
- |                                  |   |
|----------------------------------|---|
| <b>1</b> Cortex                  | <b>7</b> Humeral head                   |
| <b>2</b> Metaphysis              | <b>8</b> Clavicle                       |
| <b>3</b> Surgical neck           | <b>9</b> Suprascapular notch            |
| <b>4</b> Acromion                | <b>10</b> Spine of the scapula          |
| <b>5</b> Acromioclavicular joint | <b>11</b> Superior angle of the scapula |
| <b>6</b> Coracoid process        |   |

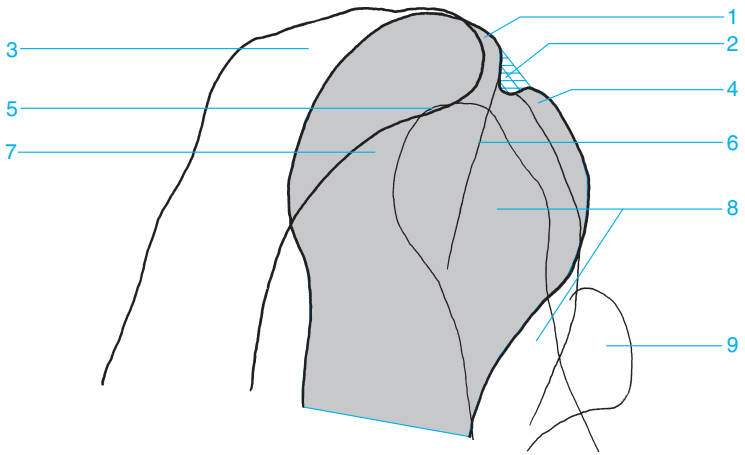




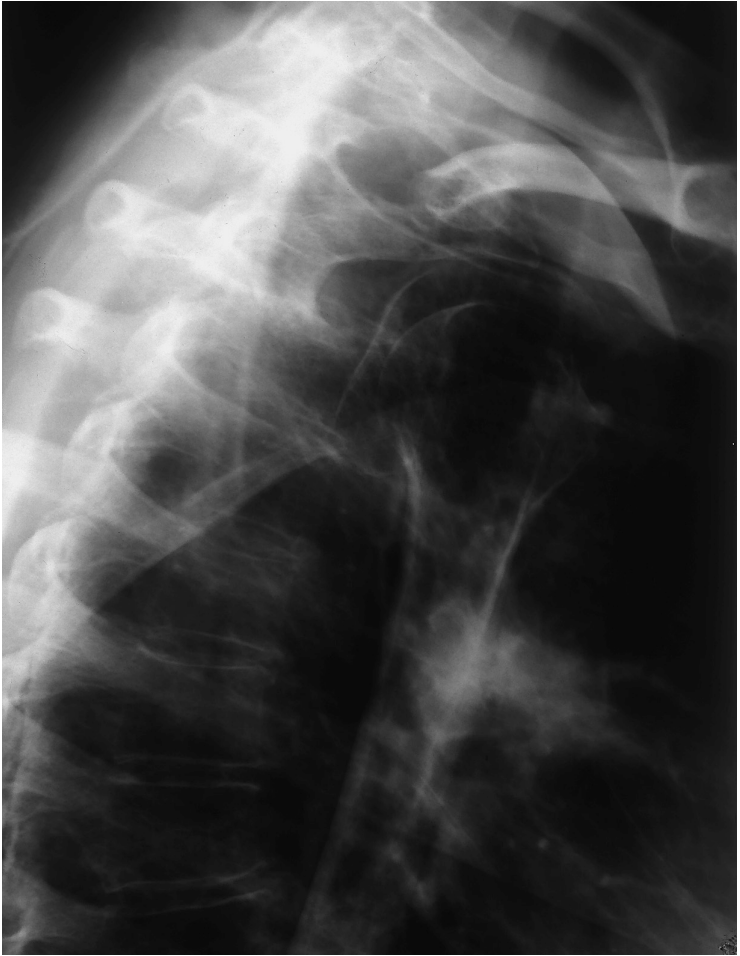- |  |   |
|--|---|
| <b>1</b> Lesser tubercle of the humerus  | <b>8</b> Acromioclavicular joint        |
| <b>2</b> Humeral head                    | <b>9</b> Glenohumeral joint             |
| <b>3</b> Coracoid process                | <b>10</b> Acromion                      |
| <b>4</b> Clavicle                        | <b>11</b> Superior angle of the scapula |
| <b>5</b> Bicipital groove                | <b>12</b> Neck of the scapula           |
| <b>6</b> Greater tubercle of the humerus | <b>13</b> Humerus                       |
| <b>7</b> Glenoid fossa                   | <b>14</b> Scapula                       |

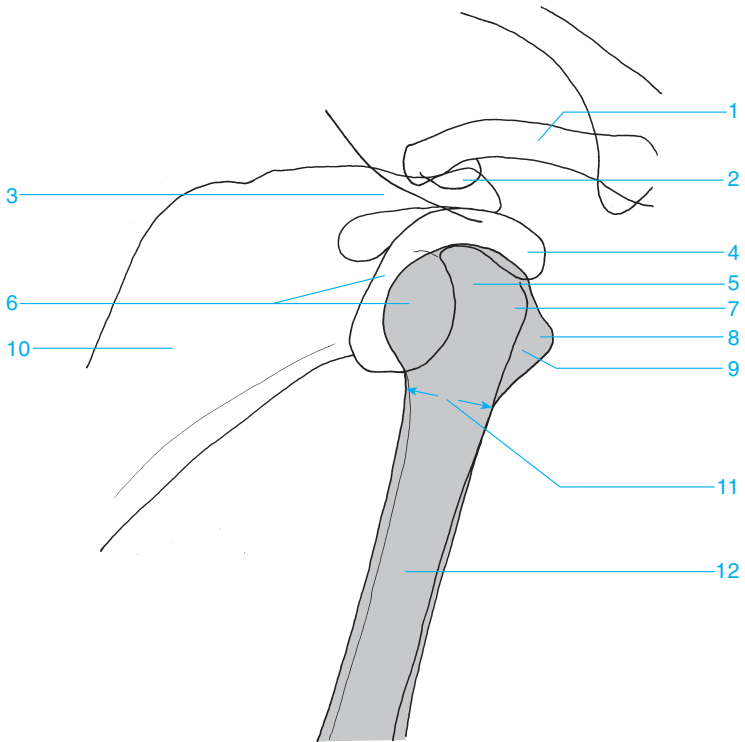




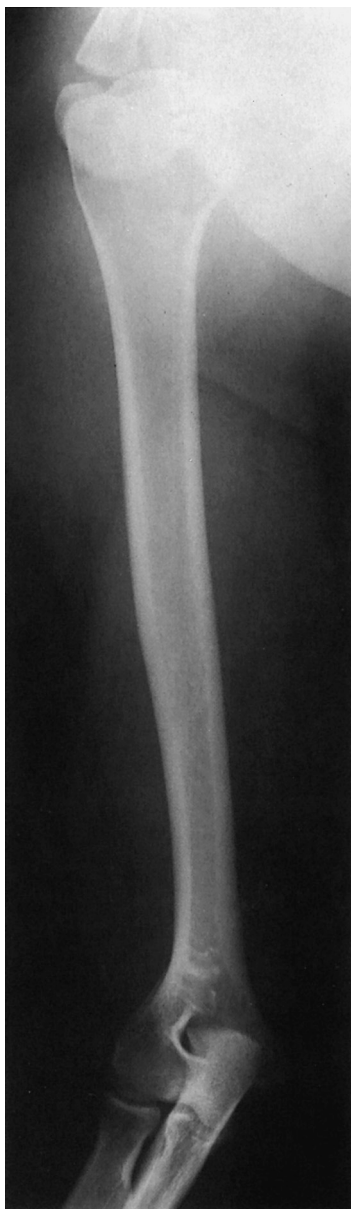

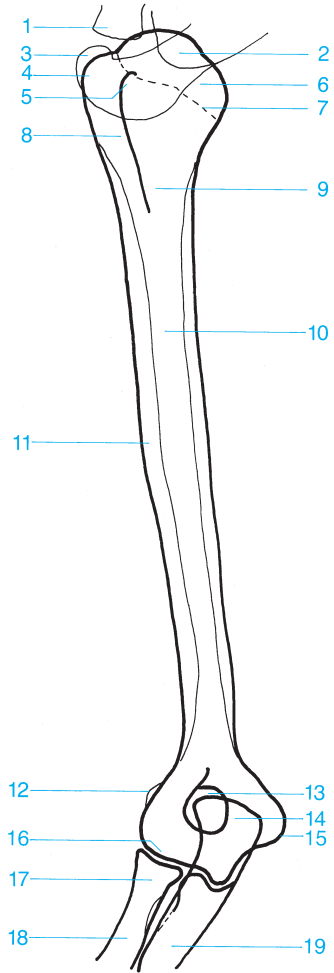
- |                                   |                                 |
|-----------------------------------|---------------------------------|
| 1 Greater tubercle of the humerus | 6 Crest of the greater tubercle |
| 2 Bicipital groove                | 7 Humeral head                  |
| 3 Acromion                        | 8 Clavicle                      |
| 4 Lesser tubercle of the humerus  | 9 Coracoid process              |
| 5 Acromioclavicular joint         |                                 |



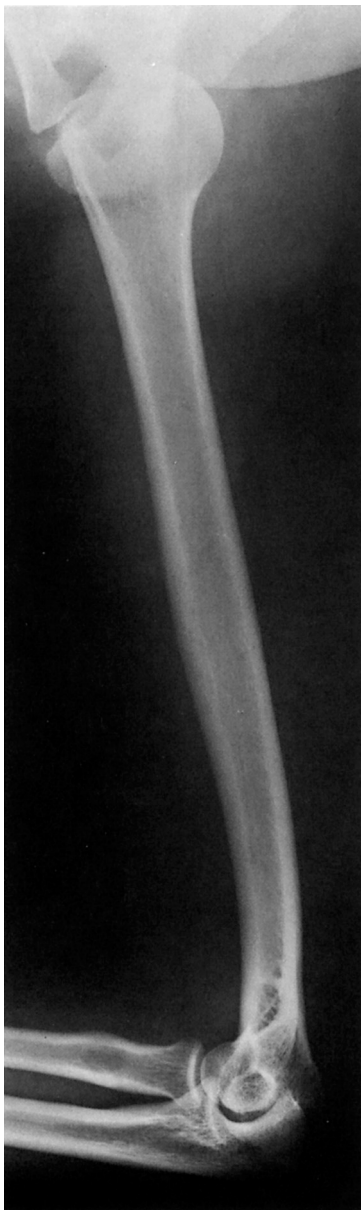

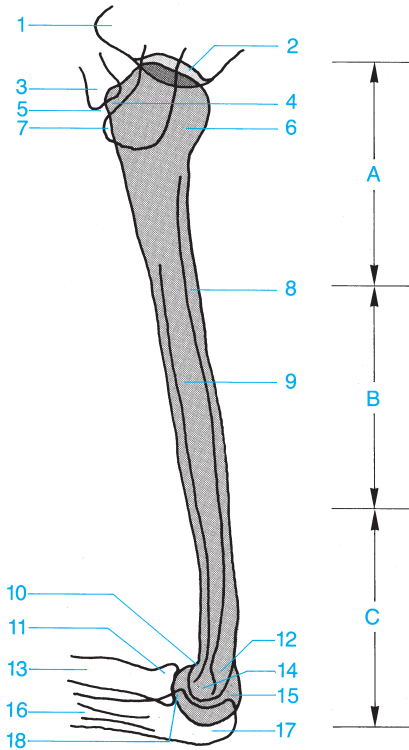
- |                                  |  |
|----------------------------------|--|
| <b>1</b> Clavicle                | <b>7</b> Greater tubercle of the humerus |
| <b>2</b> Acromioclavicular joint | <b>8</b> Lesser tubercle of the humerus  |
| <b>3</b> Acromion                | <b>9</b> Bicipital groove                |
| <b>4</b> Coracoid process        | <b>10</b> Scapula                        |
| <b>5</b> Humeral head            | <b>11</b> Surgical neck                  |
| <b>6</b> Glenoid fossa           | <b>12</b> Humerus                        |





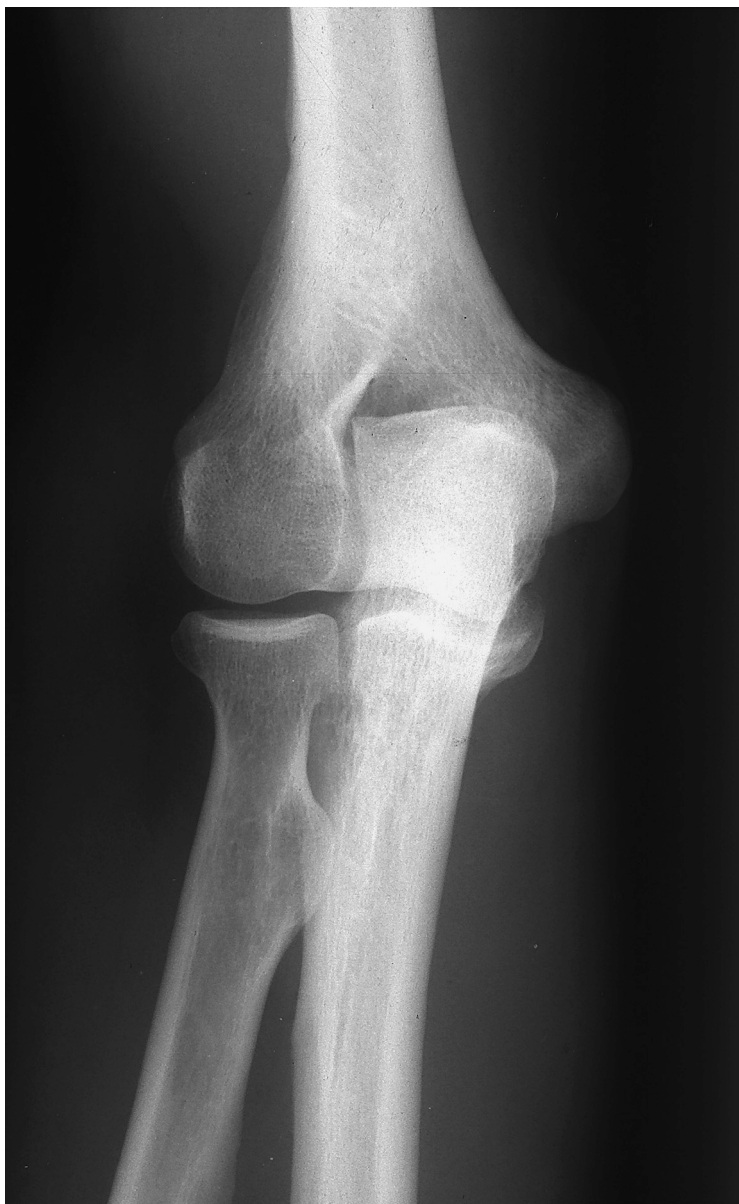- 1 Clavicle
- 2 Lateral process (neck) of the scapula
- 3 Acromion
- 4 Greater tubercle of the humerus
- 5 Lesser tubercle of the humerus
- 6 Humeral head
- 7 Anatomical neck
- 8 Bicipital groove
- 9 Surgical neck
- 10 Humerus
- 11 Deltoid tuberosity
- 12 Lateral epicondyle
- 13 Olecranon fossa
- 14 Olecranon
- 15 Medial epicondyle
- 16 Trochlea
- 17 Radial head
- 18 Radius
- 19 Ulna

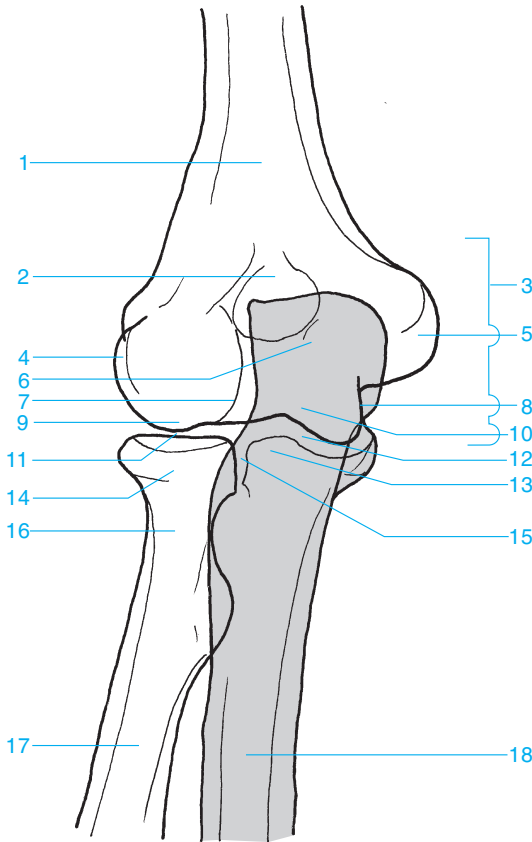




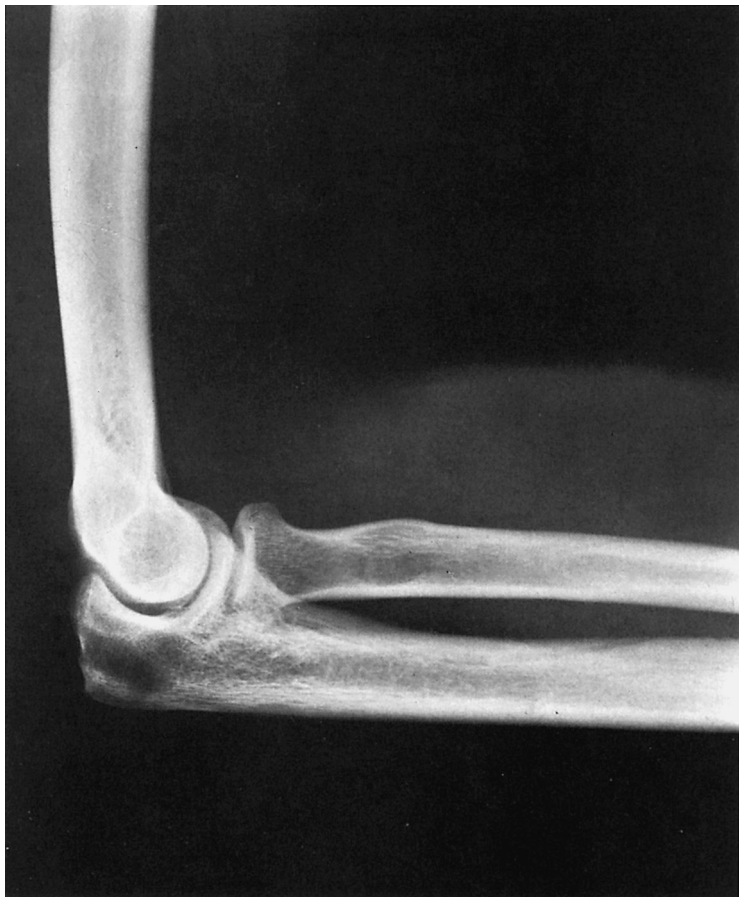- |   |                            |
|---|----------------------------|
| <b>A</b> Proximal third of the humerus  | <b>9</b> Humeral shaft     |
| <b>B</b> Medial third of the humerus    | <b>10</b> Coronoid fossa   |
| <b>C</b> Distal third of the humerus    | <b>11</b> Radial head      |
| <b>1</b> Coracoid process               | <b>12</b> Olecranon fossa  |
| <b>2</b> Glenoid fossa                  | <b>13</b> Radius           |
| <b>3</b> Clavicle                       | <b>14</b> Trochlea         |
| <b>4</b> Lesser tubercle of the humerus | <b>15</b> Capitellum       |
| <b>5</b> Acromioclavicular joint        | <b>16</b> Ulna             |
| <b>6</b> Humeral head                   | <b>17</b> Olecranon        |
| <b>7</b> Acromion                       | <b>18</b> Coronoid process |
| <b>8</b> Cortex                         |                            |

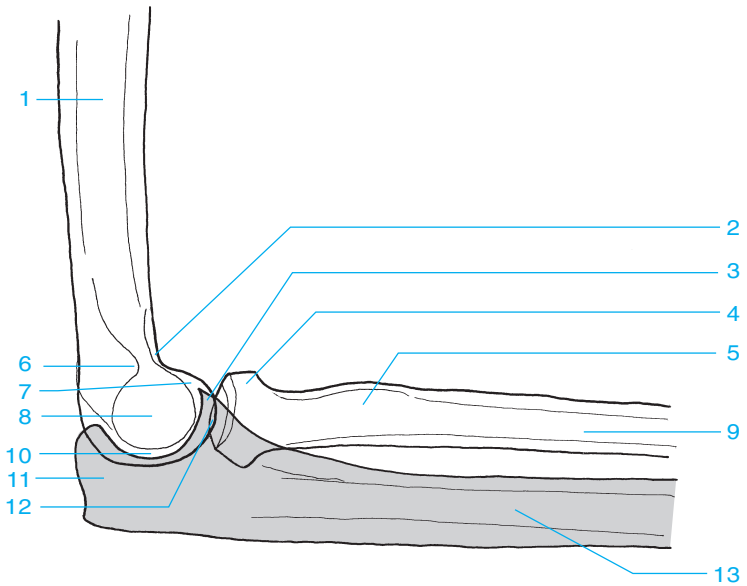




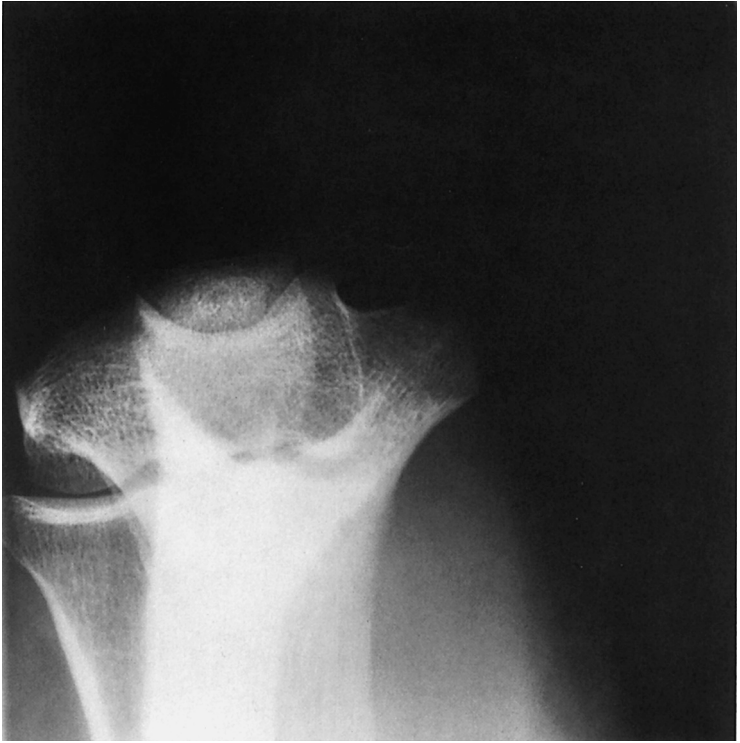

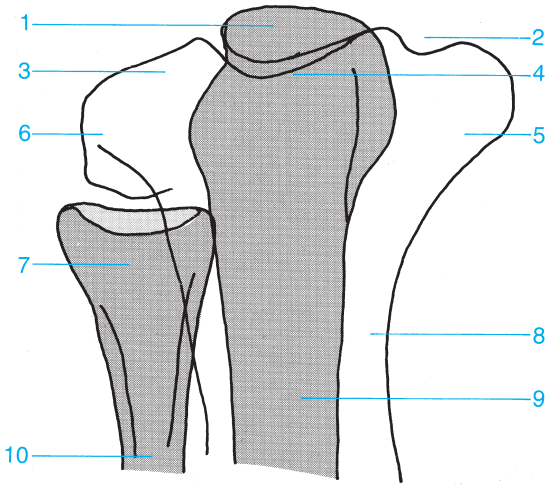
- |  |                              |
|--|------------------------------|
| 1 Humerus                                      | 10 Trochlea                  |
| 2 Olecranon fossa                              | 11 Humeroradial joint        |
| 3 Medial epicondyle of the humerus             | 12 Humeroulnar joint         |
| 4 Lateral epicondyle of the humerus            | 13 Coronoid process          |
| 5 Apex of the medial epicondyle of the humerus | 14 Radial head               |
| 6 Olecranon                                    | 15 Proximal radioulnar joint |
| 7 Lateral margin of the trochlea               | 16 Radial neck               |
| 8 Medial margin of the trochlea                | 17 Radius                    |
| 9 Capitellum                                   | 18 Ulna                      |





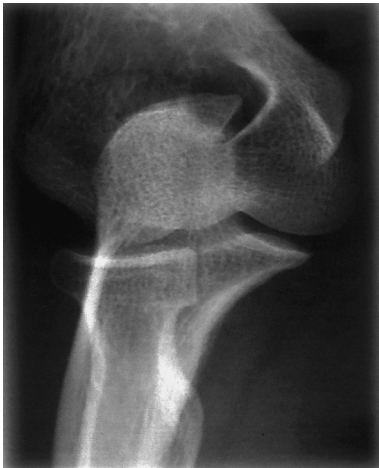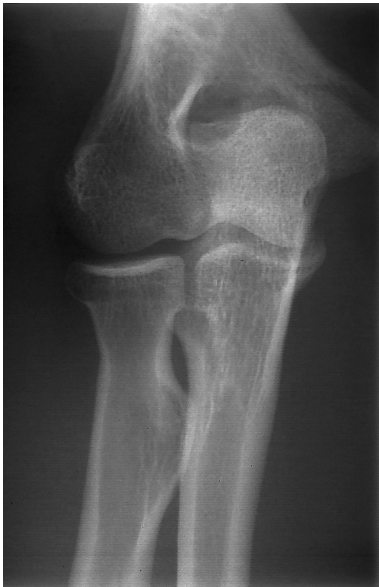- |                            |                              |
|----------------------------|------------------------------|
| <b>1</b> Humerus           | <b>8</b> Lateral epicondyle  |
| <b>2</b> Coronoid fossa    | <b>9</b> Radius              |
| <b>3</b> Coronoid process  | <b>10</b> Humeroulnar joint  |
| <b>4</b> Radial head       | <b>11</b> Olecranon          |
| <b>5</b> Radial tuberosity | <b>12</b> Humeroradial joint |
| <b>6</b> Olecranon fossa   | <b>13</b> Ulna               |
| <b>7</b> Medial epicondyle |                              |

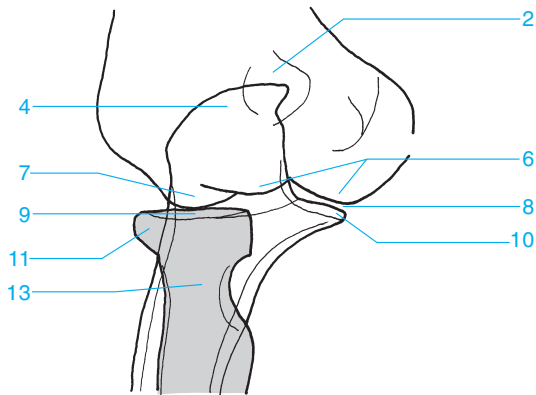
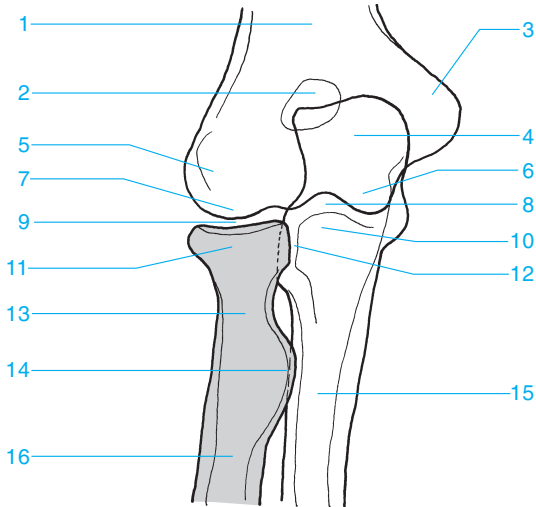




- 1 Olecranon
- 2 Cubital tunnel
- 3 Capitellum
- 4 Trochlea
- 5 Medial epicondyle

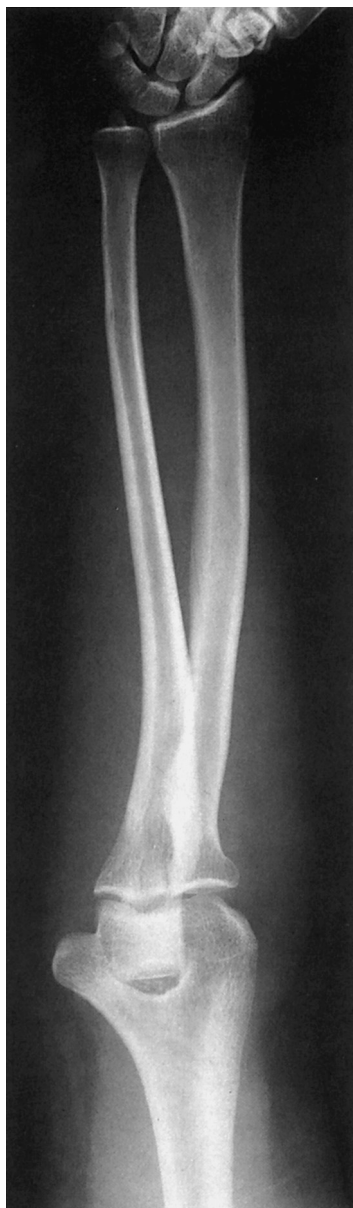- 6 Lateral epicondyle
- 7 Radial head
- 8 Humerus
- 9 Ulna
- 10 Radius



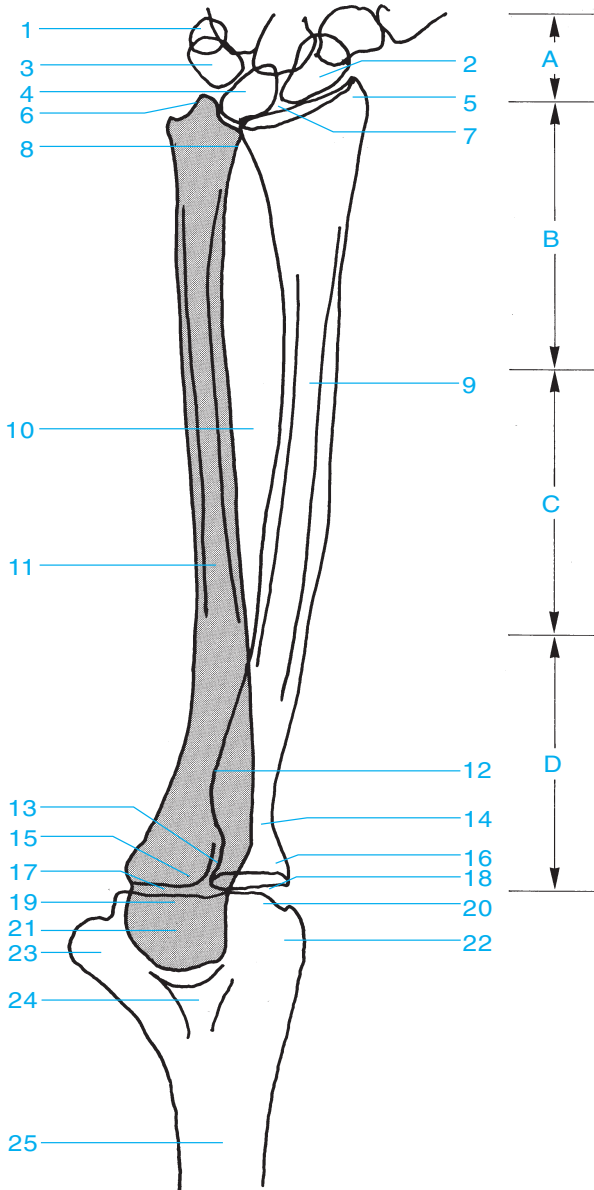


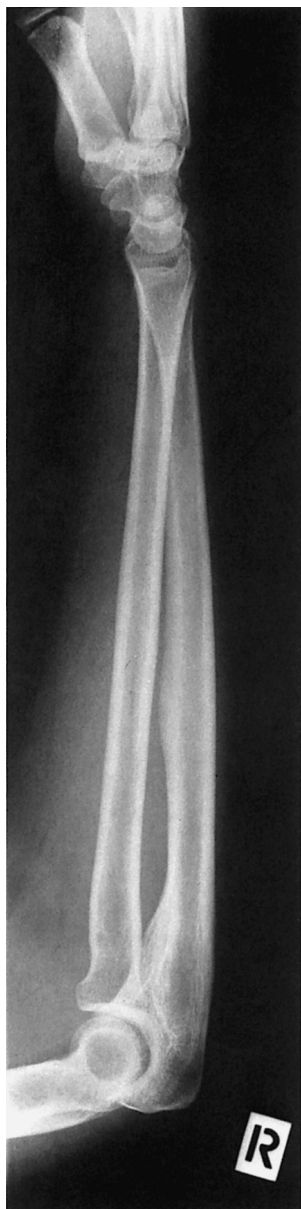- |                      |                              |
|----------------------|------------------------------|
| 1 Humerus            | 9 Humeroradial joint         |
| 2 Olecranon fossa    | 10 Coronoid process          |
| 3 Medial epicondyle  | 11 Radial head               |
| 4 Olecranon          | 12 Proximal radioulnar joint |
| 5 Lateral epicondyle | 13 Radial neck               |
| 6 Trochlea           | 14 Radial tuberosity         |
| 7 Capitellum         | 15 Ulna                      |
| 8 Humeroulnar joint  | 16 Radius                    |



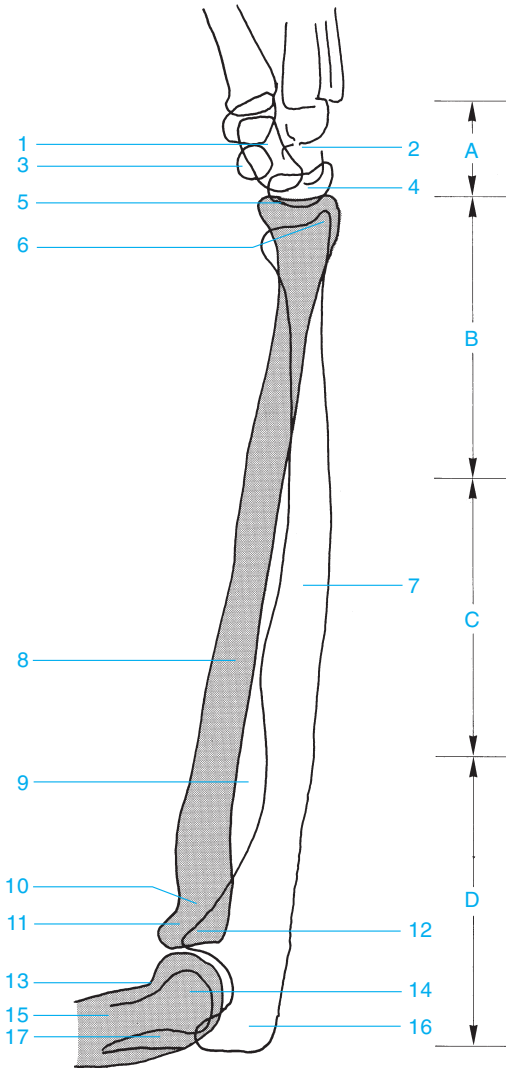


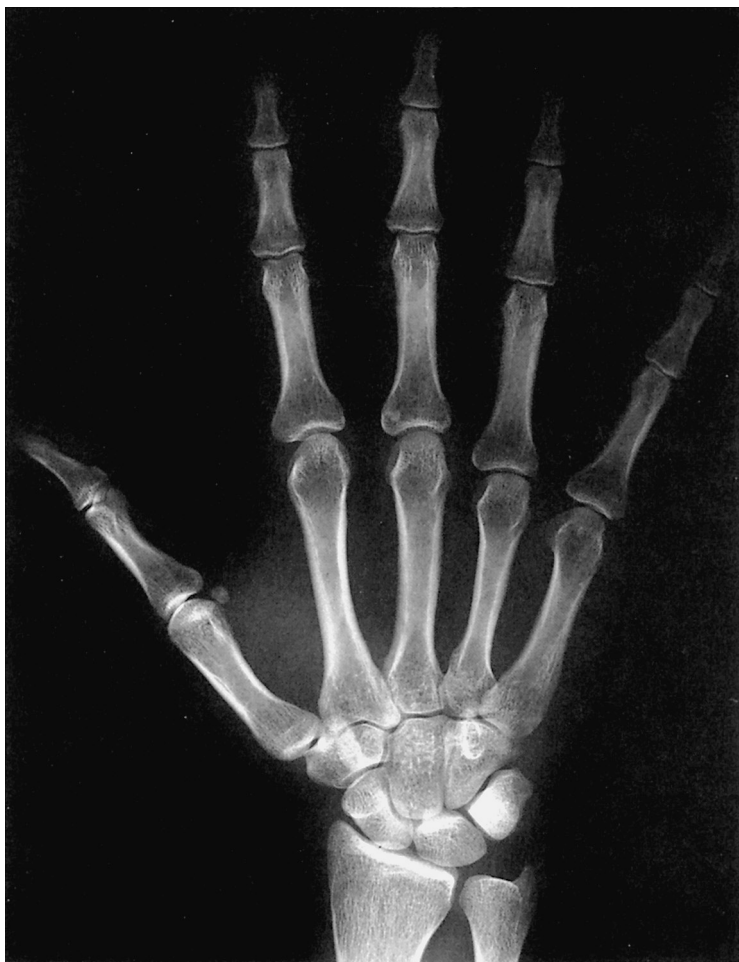- A** Carpal bones
- B** Distal third of the forearm
- C** Middle third of the forearm
- D** Proximal third of the forearm
- 1** Pisiform bone
- 2** Scaphoid
- 3** Triquetrum
- 4** Lunate bone
- 1-4** Proximal carpal row
- 5** Radial styloid
- 6** Ulnar styloid
- 7** Radiocarpal joint
- 8** Distal radioulnar joint
- 9** Radius
- 10** Interosseous membrane
- 11** Ulna
- 12** Radial tuberosity
- 13** Proximal radioulnar joint
- 14** Radial neck
- 15** Coronoid process
- 16** Radial head
- 17** Humeroulnar joint
- 18** Humeroradial joint
- 19** Trochlea
- 20** Capitellum
- 21** Olecranon
- 22** Lateral epicondyle of the humerus
- 23** Medial epicondyle of the humerus
- 24** Olecranon fossa
- 25** Humerus

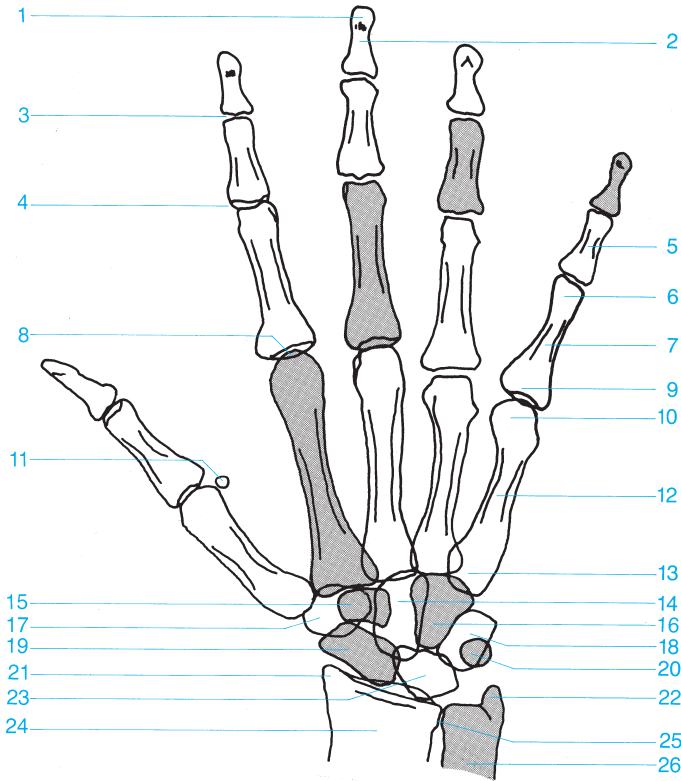




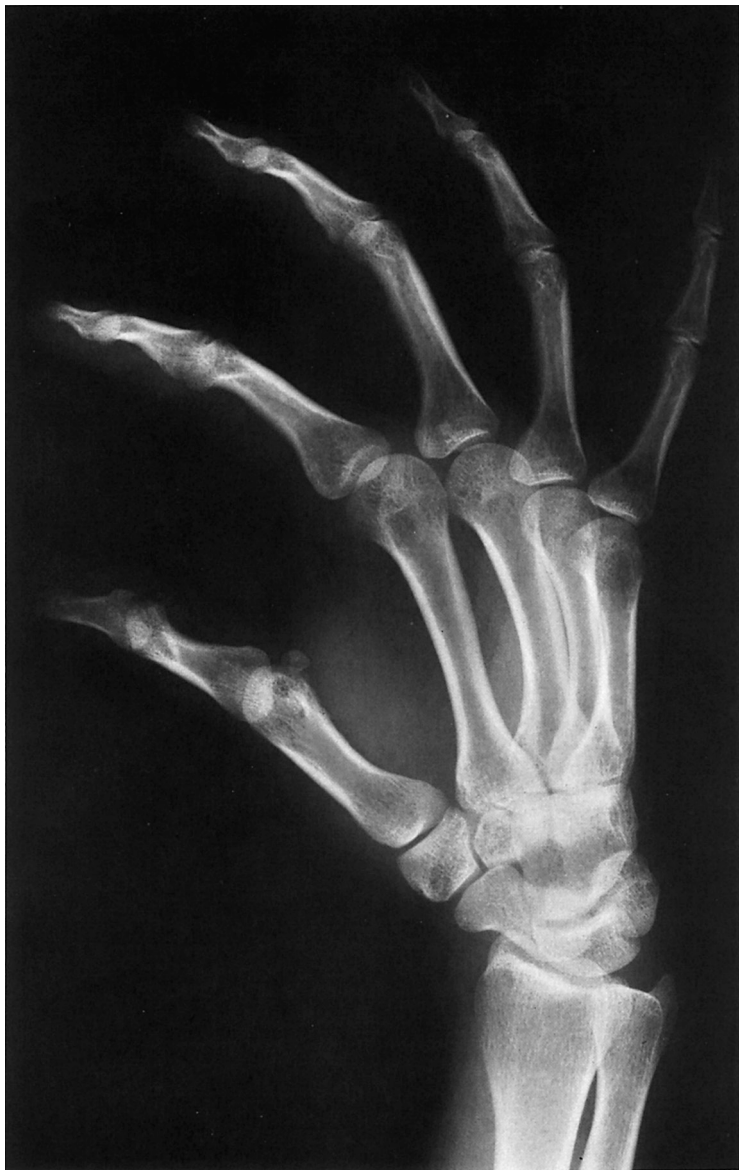- A** Carpal bones
- B** Distal third of the forearm
- C** Middle third of the forearm
- D** Proximal third of the forearm
- 1** Triquetrum
- 2** Scapoid
- 3** Pisiform bone
- 4** Lunate bone
- 1–4** Proximal carpal row
- 5** Radiocarpal joint
- 6** Ulnar styloid
- 7** Ulna
- 8** Radius
- 9** Interosseous membrane
- 10** Radial neck
- 11** Radial head
- 12** Coronoid process
- 13** Coronoid fossa
- 14** Trochlea of the humerus
- 15** Humerus
- 16** Olecranon
- 17** Olecranon fossa

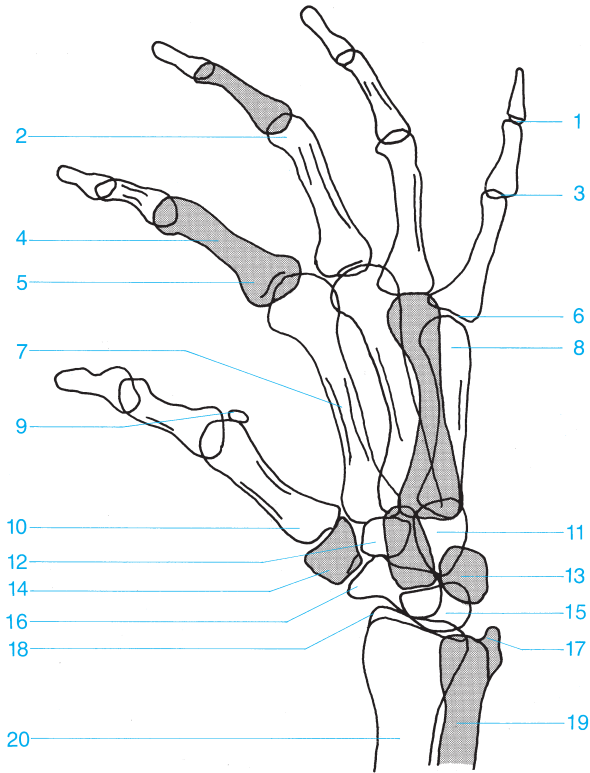






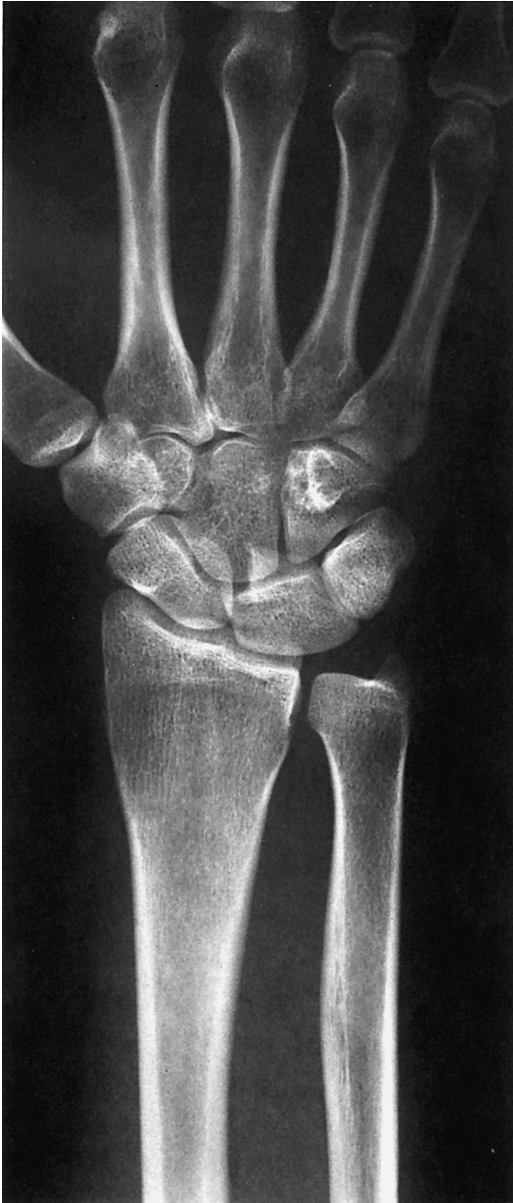- |                                  |                            |
|----------------------------------|----------------------------|
| 1 Distal phalanx (tuft)          | 14 Capitate                |
| 2 Distal phalanx                 | 15 Trapezoid               |
| 3 Distal interphalangeal joint   | 16 Hamate                  |
| 4 Proximal interphalangeal joint | 17 Trapezium               |
| 5 Middle phalanx                 | 18 Triquetrum              |
| 6 Head of the proximal phalanx   | 19 Scaphoid                |
| 7 Proximal phalanx               | 20 Pisiform                |
| 8 Metacarpophalangeal joint      | 21 Radial styloid          |
| 9 Base of the proximal phalanx   | 22 Ulnar styloid           |
| 10 Metacarpal head               | 23 Lunate                  |
| 11 Sesamoid                      | 24 Distal radius           |
| 12 Metacarpal                    | 25 Distal radioulnar joint |
| 13 Metacarpal base               | 26 Distal ulna             |

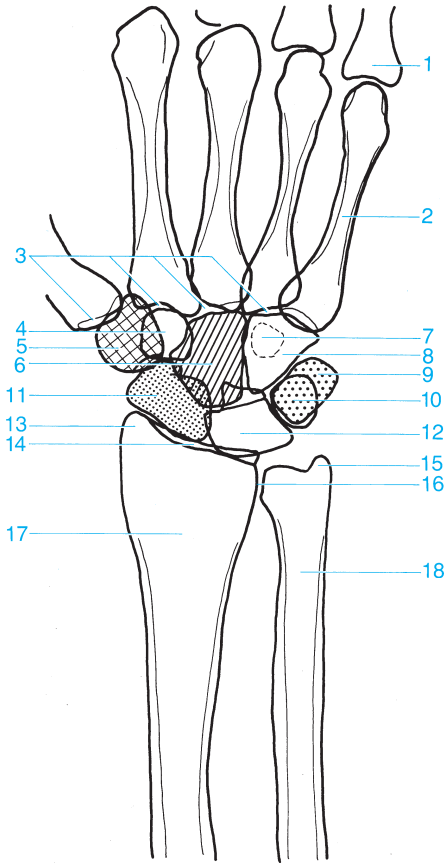




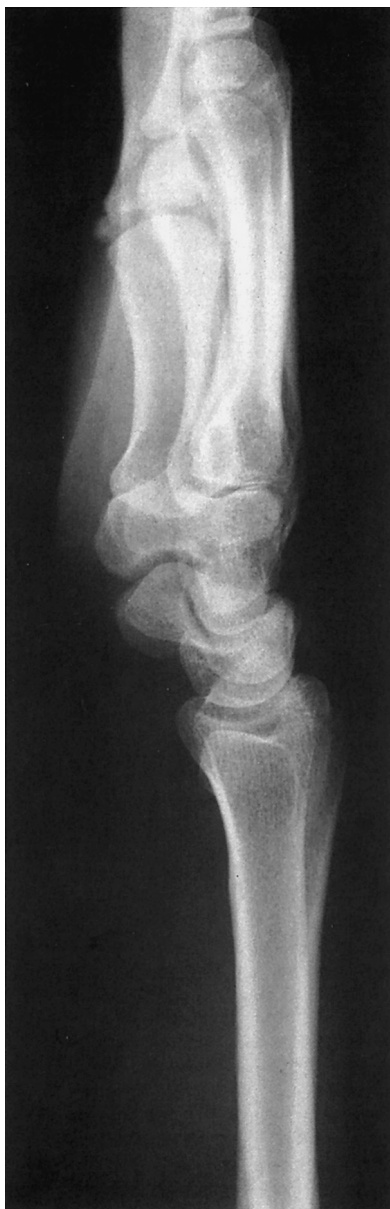- |   |                               |
|---|-------------------------------|
| <b>1</b> Distal interphalangeal joint   | <b>11</b> Capitate and hamate |
| <b>2</b> Head of the proximal phalanx   | <b>12</b> Trapezoid           |
| <b>3</b> Proximal interphalangeal joint | <b>13</b> Triquetrum          |
| <b>4</b> Proximal phalanx               | <b>14</b> Trapezium           |
| <b>5</b> Base of the proximal phalanx   | <b>15</b> Lunate              |
| <b>6</b> Metacarpophalangeal joint      | <b>16</b> Scaphoid            |
| <b>7</b> Metacarpal                     | <b>17</b> Ulnar styloid       |
| <b>8</b> Metacarpal head                | <b>18</b> Radial styloid      |
| <b>9</b> Sesamoid                       | <b>19</b> Distal ulna         |
| <b>10</b> Metacarpal base               | <b>20</b> Distal radius       |

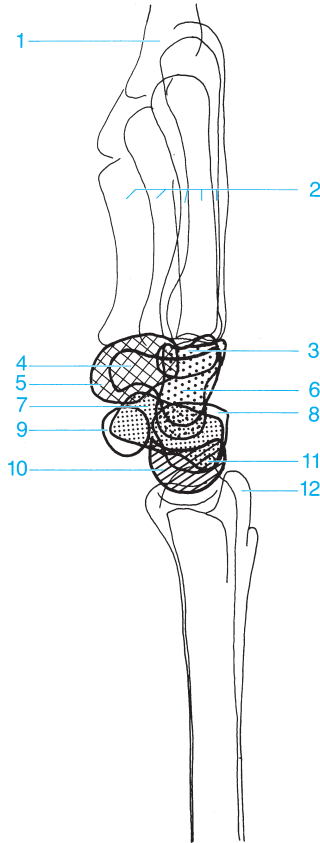










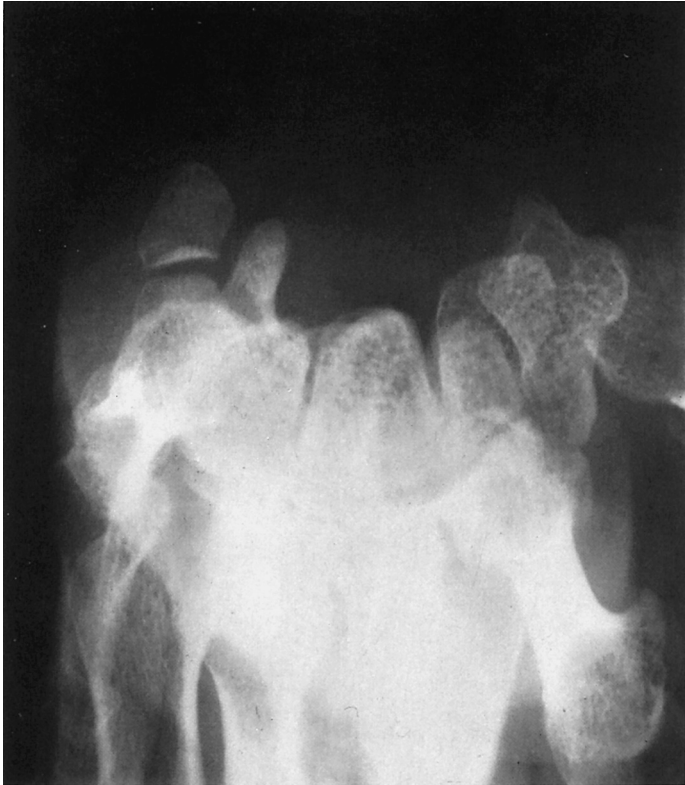- |                                |                             |
|--------------------------------|-----------------------------|
| <b>1</b> Proximal phalanx      | <b>10</b> Pisiform          |
| <b>2</b> Fifth metacarpal      | <b>11</b> Scaphoid          |
| <b>3</b> Carpometacarpal joint | <b>12</b> Lunate            |
| <b>4</b> Trapezoid             | <b>13</b> Radial styloid    |
| <b>5</b> Trapezium             | <b>14</b> Radiocarpal joint |
| <b>6</b> Capitate              | <b>15</b> Ulnar styloid     |
| <b>7</b> Hook of the Hamate    | <b>16</b> Radioulnar joint  |
| <b>8</b> Hamate                | <b>17</b> Radius            |
| <b>9</b> Triquetrum            | <b>18</b> Ulna              |

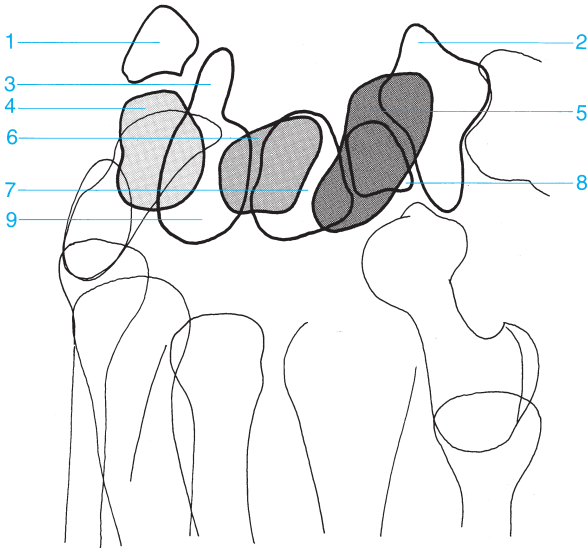




- 1 Proximal phalanx
- 2 Metacarpals
- 3 Trapezoid
- 4 Hook of the Hamate
- 5 Trapezium 
- 6 Capitate 

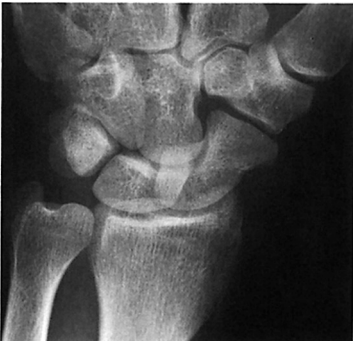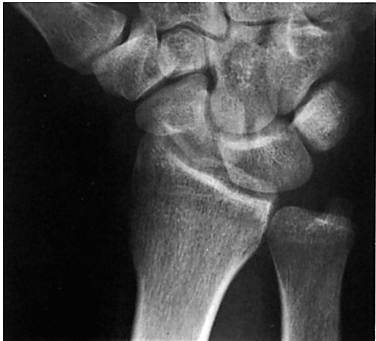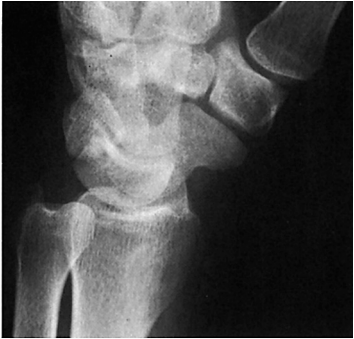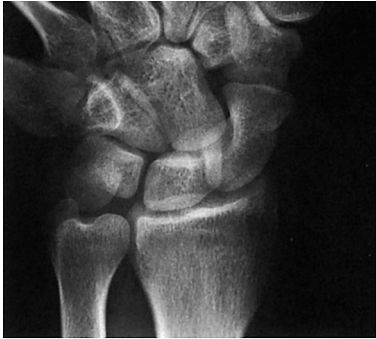- 7 Scaphoid 
- 8 Triquetrum
- 9 Pisiform
- 10 Lunate 
- 11 Radial styloid
- 12 Ulnar styloid

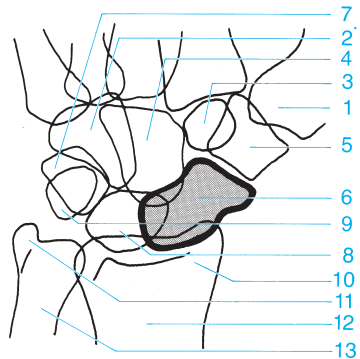
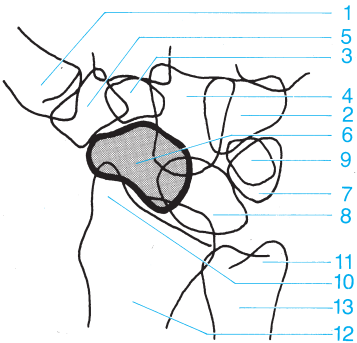
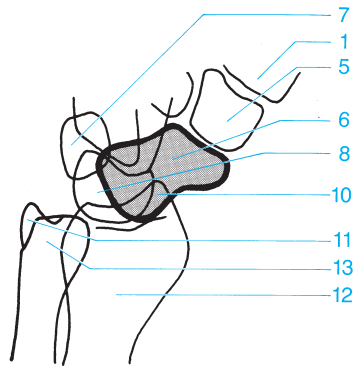
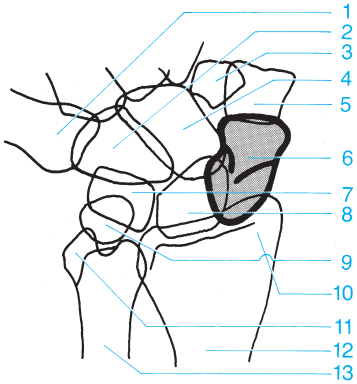




- 1 Pisiform
- 2 Trapezium
- 3 Hook of the hamate
- 4 Triquetrum
- 5 Scaphoid

- 6 Lunate
- 7 Capitate
- 8 Trapezoid
- 9 Hamate

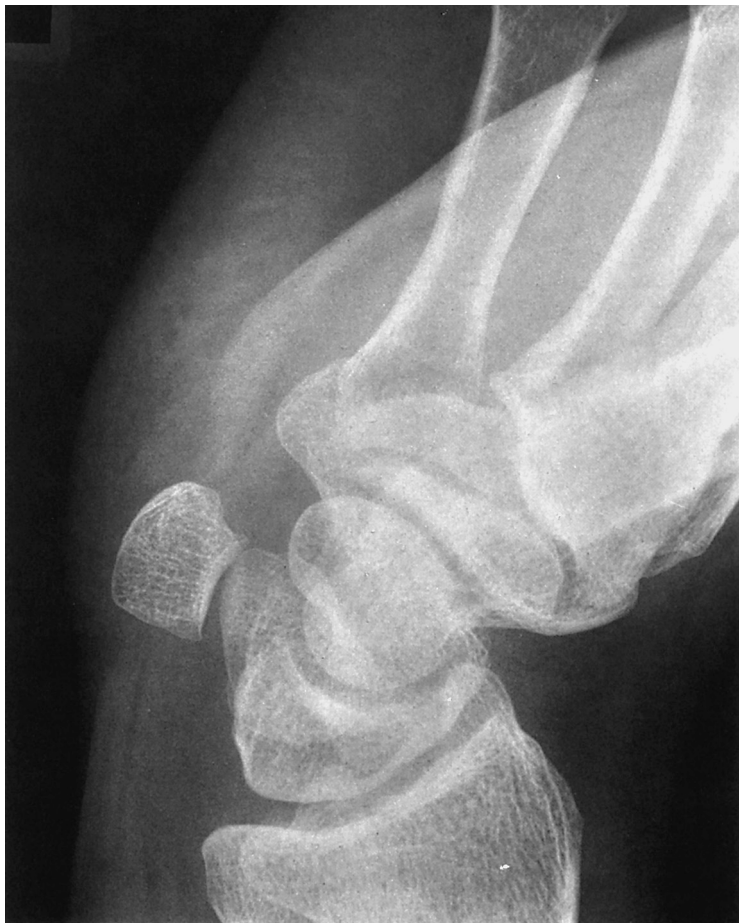

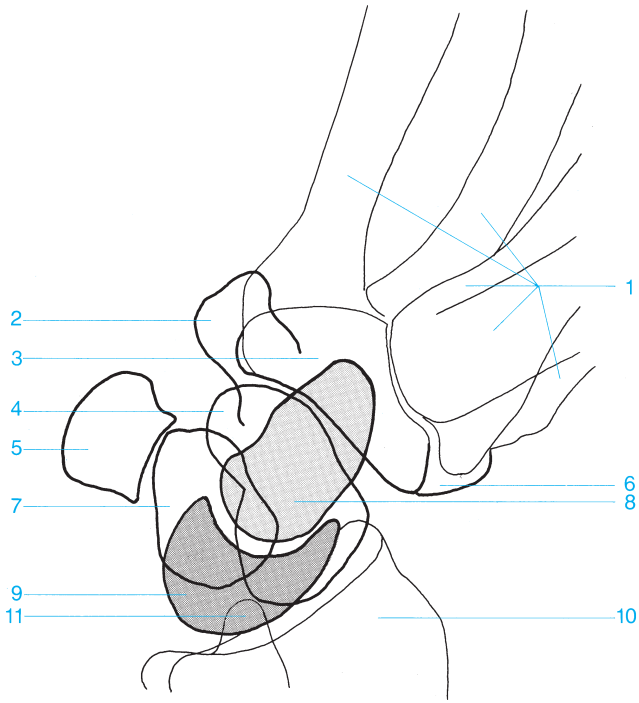


- 1 Metacarpal
- 2 Hamate
- 3 Trapezoid
- 4 Capitate
- 5 Trapezium
- 6 Scaphoid
- 7 Triquetrum

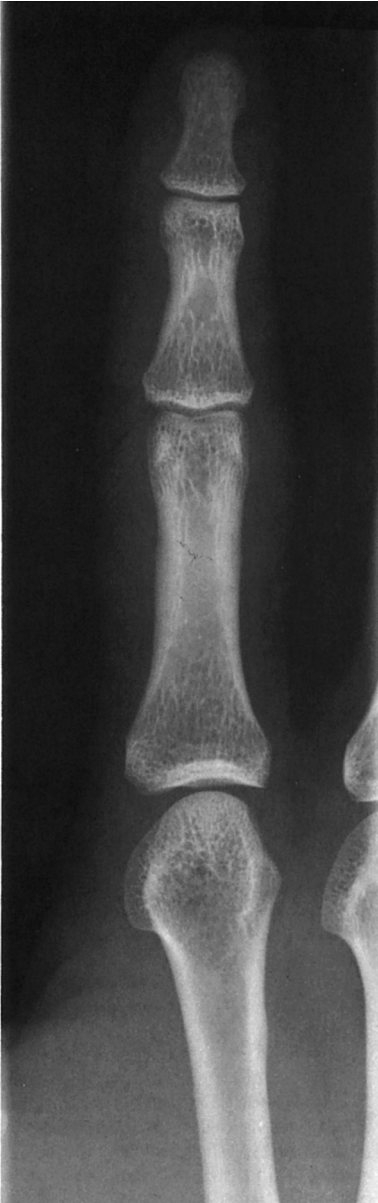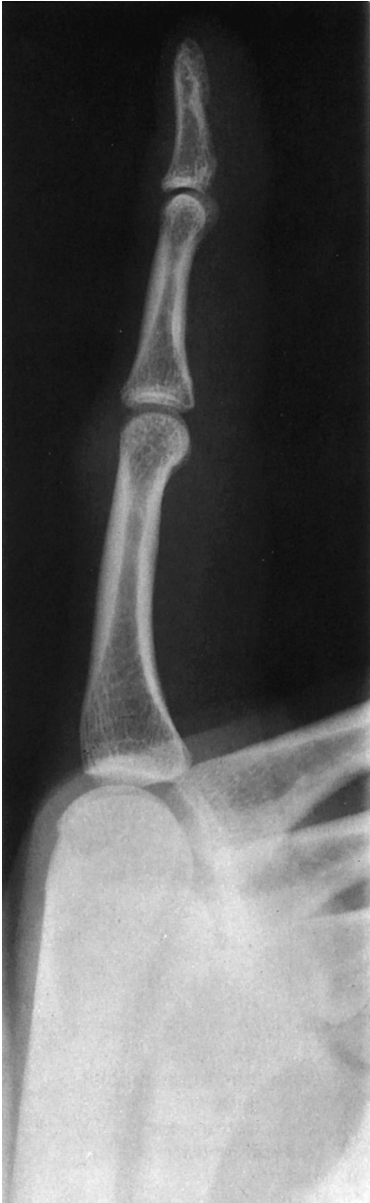- 8 Lunate
- 9 Pisiform
- 10 Radial styloid
- 11 Ulnar styloid
- 12 Radius
- 13 Ulna

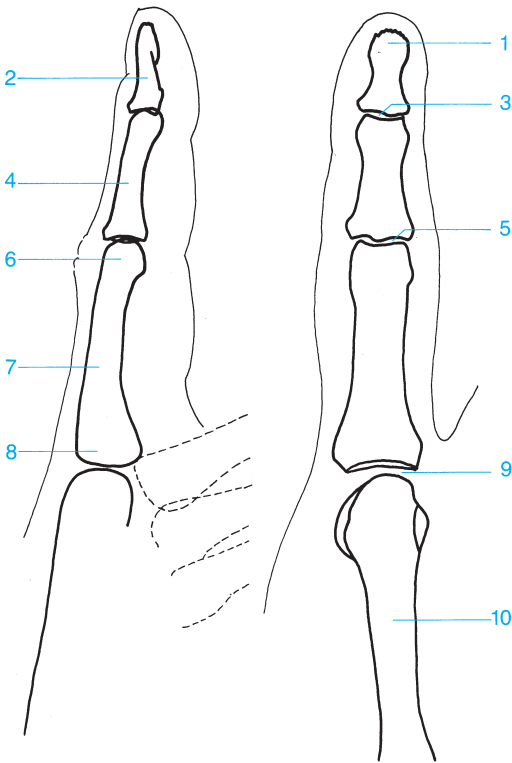




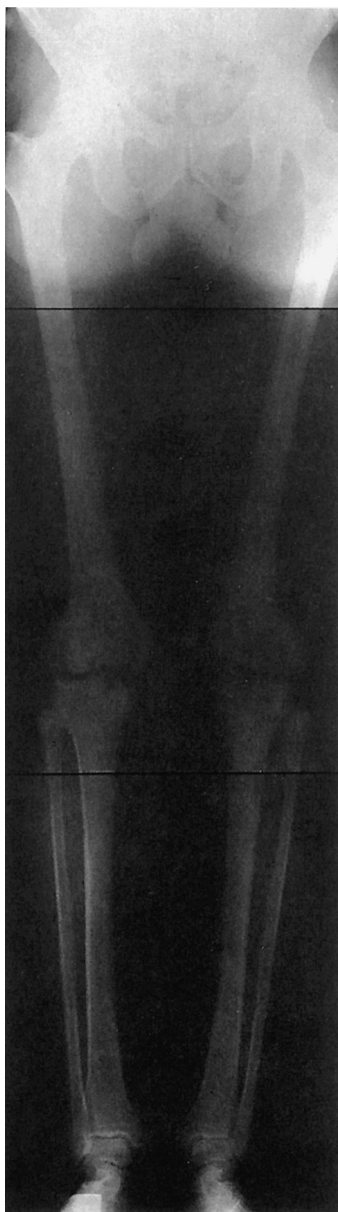

- |                      |                         |
|----------------------|-------------------------|
| <b>1</b> Metacarpals | <b>7</b> Triquetrum     |
| <b>2</b> Hamate      | <b>8</b> Capitate       |
| <b>3</b> Trapezoid   | <b>9</b> Lunate         |
| <b>4</b> Scaphoid    | <b>10</b> Radius        |
| <b>5</b> Pisiform    | <b>11</b> Ulnar styloid |
| <b>6</b> Trapezium   |                         |

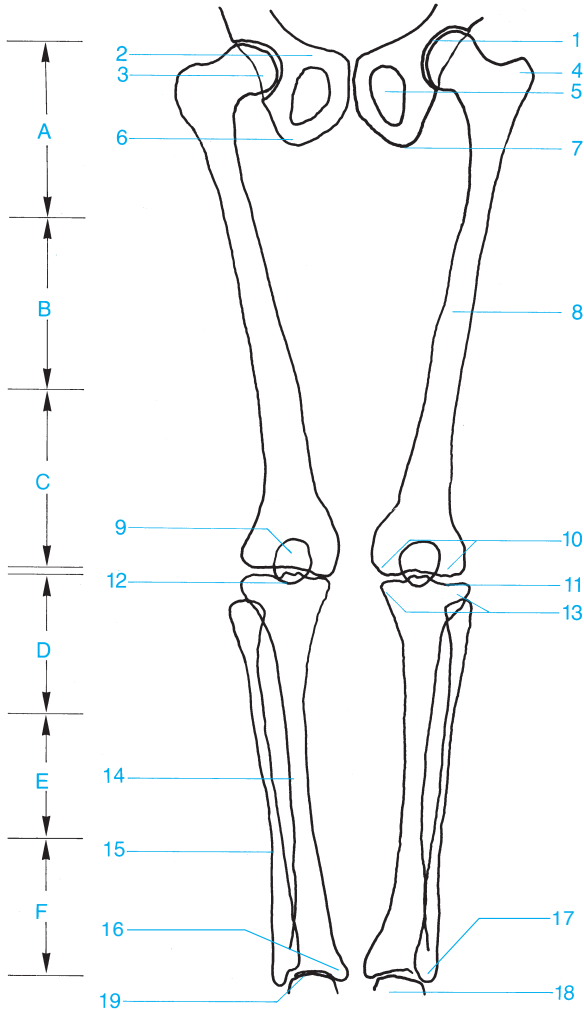


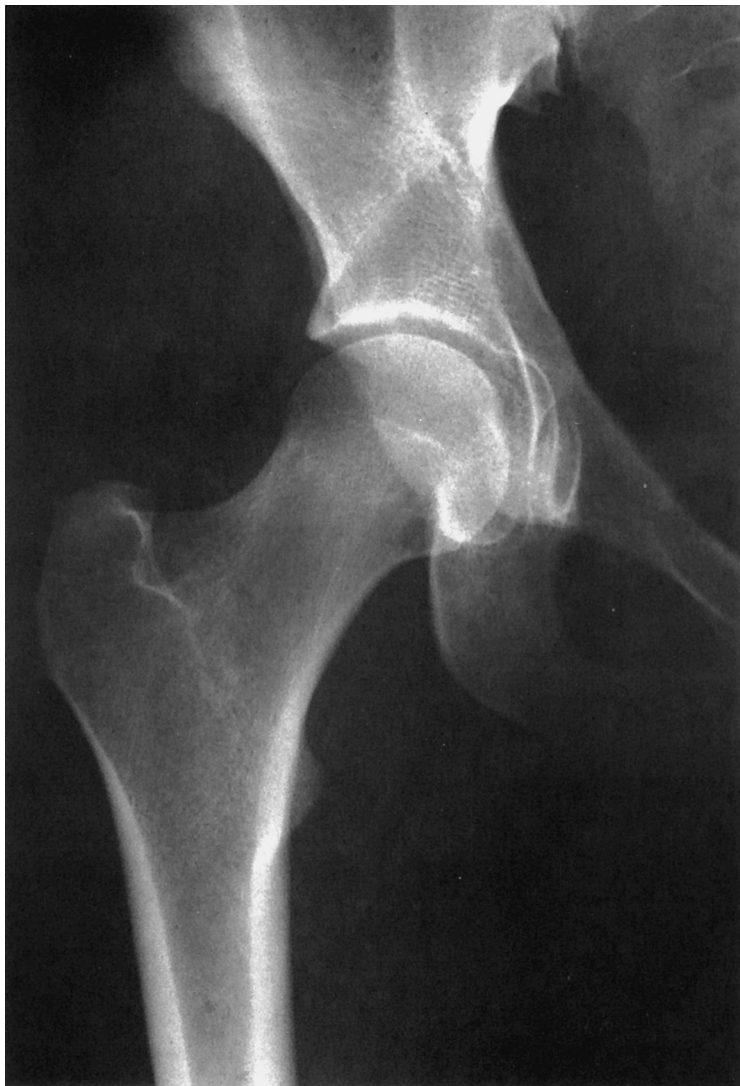

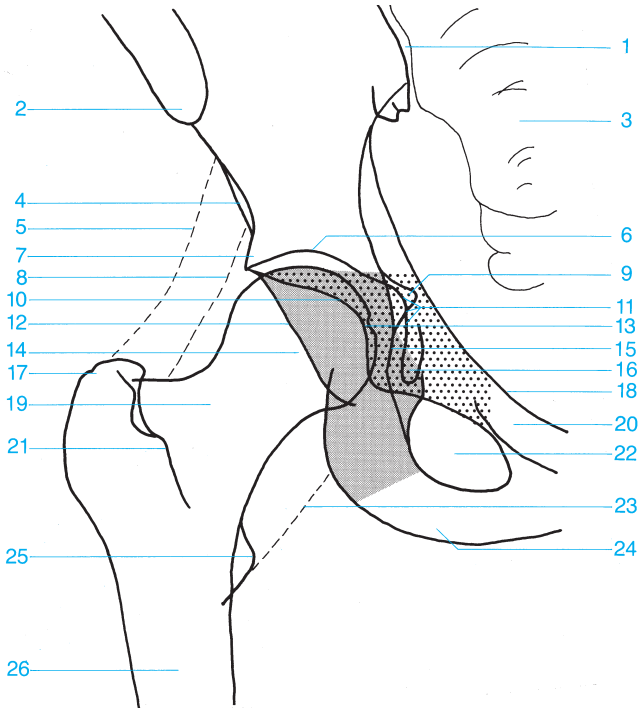
- |   |                                       |
|---|---------------------------------------|
| <b>1</b> Distal phalanx (tuft)          | <b>6</b> Head of the proximal phalanx |
| <b>2</b> Distal phalanx                 | <b>7</b> Proximal phalanx             |
| <b>3</b> Distal interphalangeal joint   | <b>8</b> Base of the proximal phalanx |
| <b>4</b> Middle phalanx                 | <b>9</b> Metacarpophalangeal joint    |
| <b>5</b> Proximal interphalangeal joint | <b>10</b> Metacarpal                  |



- A** Proximal third of the femur
- B** Middle third of the femur
- C** Distal third of the femur
- D** Proximal third of the lower leg
- E** Medial third of the lower leg
- F** Distal third of the lower leg
- 1** Joint space of the hip
- 2** Pubic bone
- 3** Femoral head
- 4** Greater trochanter
- 5** Obturator foramen
- 6** Ischium
- 7** Ischial tuberosity
- 8** Femur
- 9** Patella
- 10** Medial and lateral femoral condyles
- 11** Joint space of the knee
- 12** Intercondylar eminence
- 13** Medial and lateral tibial condyles
- 14** Tibia
- 15** Fibula
- 16** Medial malleolus
- 17** Lateral malleolus
- 18** Trochlea of the talus
- 19** Ankle

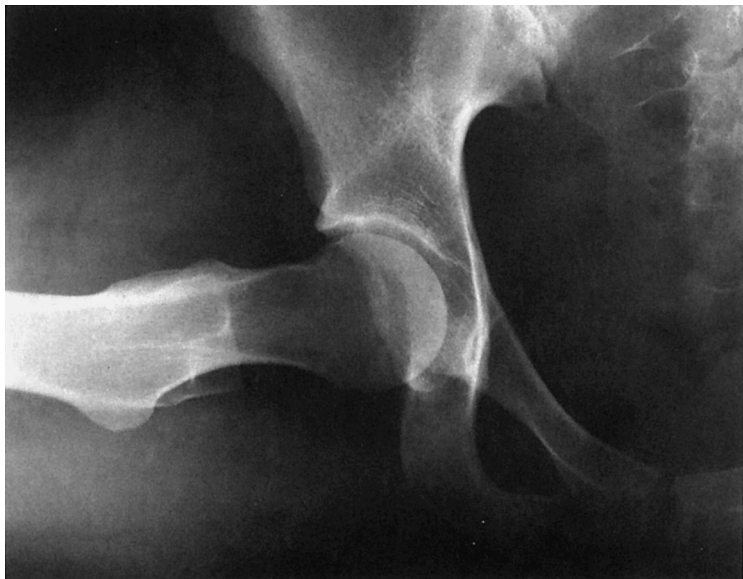


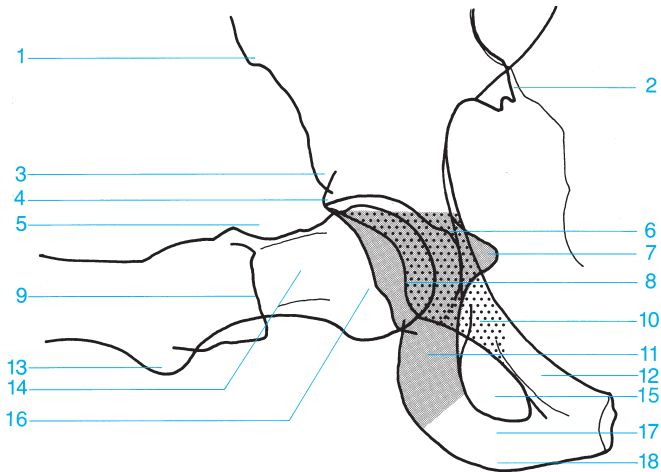






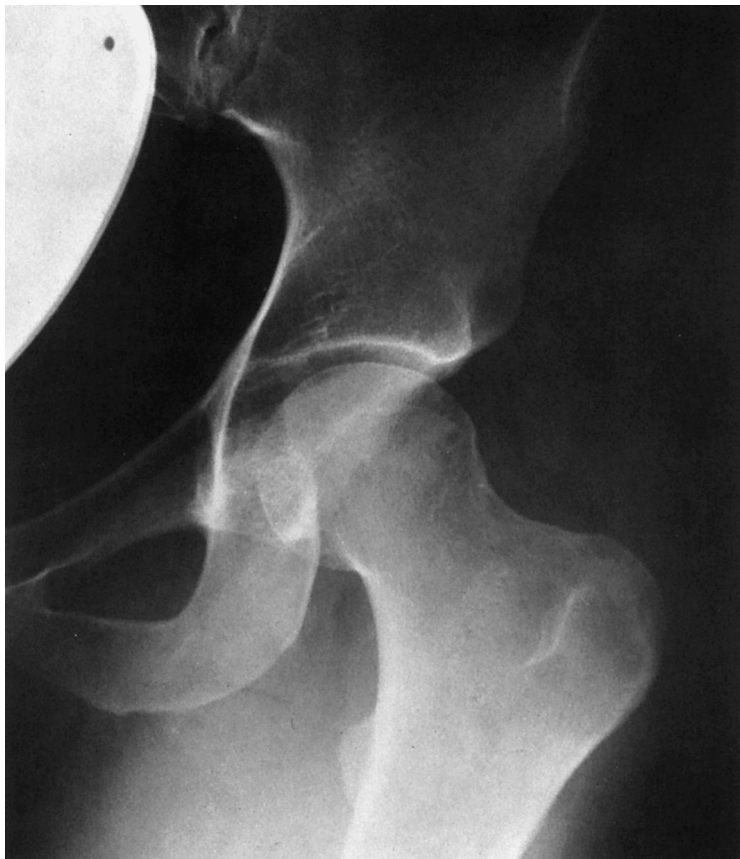- |  |   |
|--|---|
| 1 Sacroiliac joint                         | 15 Ilioischial line                             |
| 2 Anterior superior iliac spine            | 16 Köhler's teardrop figure                     |
| 3 Sacrum                                   | 17 Greater trochanter                           |
| 4 Anterior inferior iliac spine            | 18 Terminal line                                |
| 5 Intergluteal fat stripe                  | 19 Femoral neck                                 |
| 6 Roof of the acetabulum                   | 20 Superior pubic ramus                         |
| 7 Acetabular convexity (promontory)        | 21 Intertrochanteric crest                      |
| 8 Fat stripe medial to the gluteus minimus | 22 Obturator foramen                            |
| 9 Spine of the ischium                     | 23 Fat stripe medial to the iliopsoas           |
| 10 Anterior acetabular rim                 | 24 Ischial tuberosity                           |
| 11 Floor of the acetabulum                 | 25 Lesser trochanter                            |
| 12 Posterior acetabular rim                | 26 Femur  |
| 13 Fovea of the femoral head               | ■ Ischium (posterior column)                    |
| 14 Femoral head                            | ▨ Pubic bone, anterior column (anterior column) |

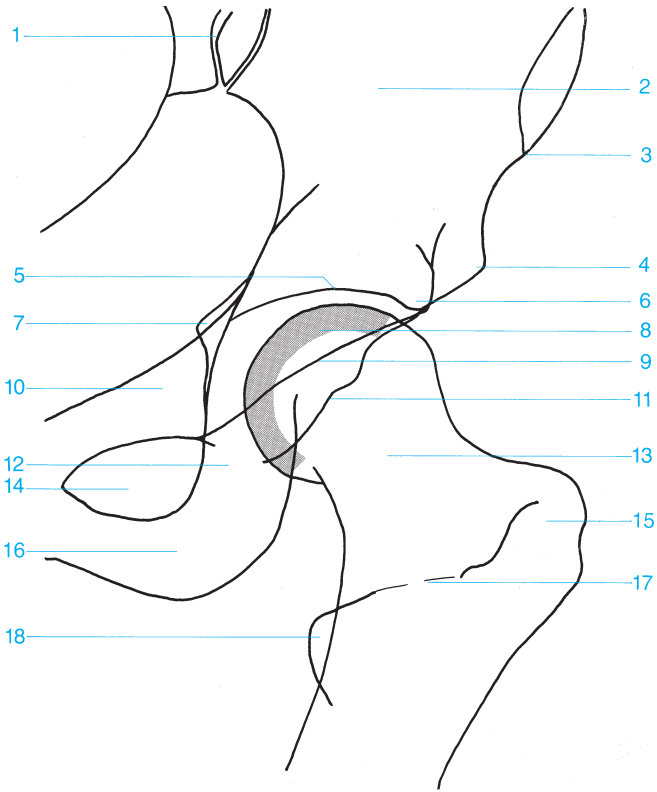




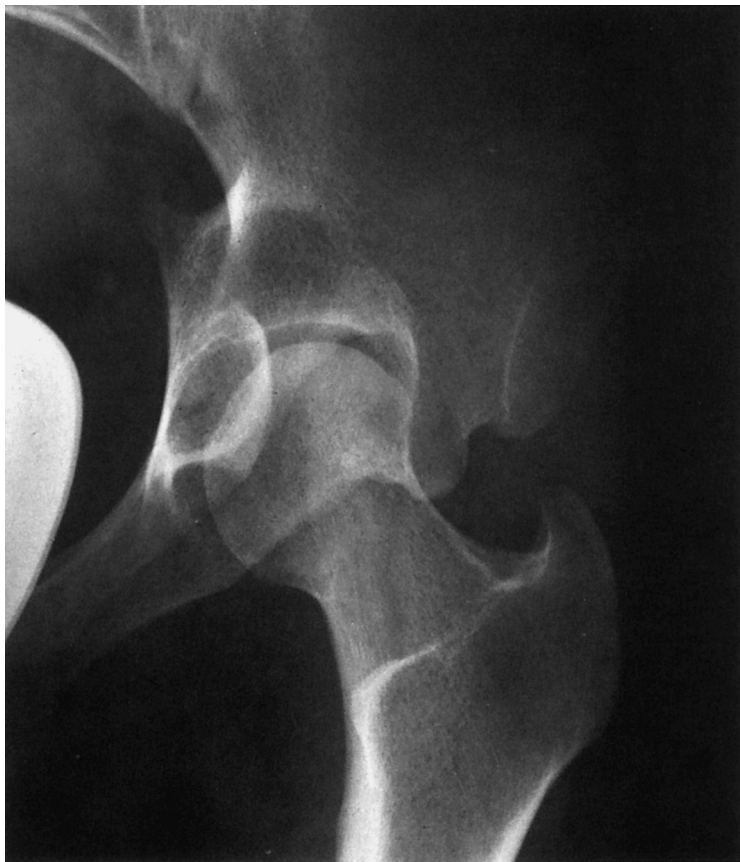

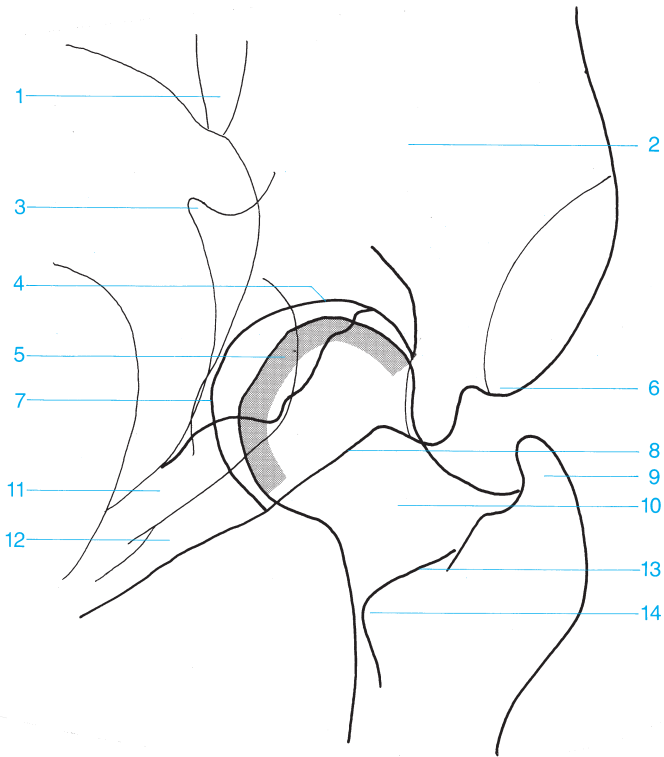
- |  |  |
|--|--|
| <b>1</b> Anterior superior iliac spine | <b>12</b> Superior pubic ramus   |
| <b>2</b> Sacroiliac joint              | <b>13</b> Lesser trochanter  |
| <b>3</b> Anterior inferior iliac spine | <b>14</b> Femoral neck   |
| <b>4</b> Superior acetabular rim       | <b>15</b> Obturator foramen  |
| <b>5</b> Posterior acetabular rim      | <b>16</b> Femoral head   |
| <b>6</b> Floor of the acetabulum       | <b>17</b> Inferior pubic ramus   |
| <b>7</b> Spine of the ischium          | <b>18</b> Ischial tuberosity   |
| <b>8</b> Anterior acetabular rim       |  Pubic bone |
| <b>9</b> Greater trochanter            |  Ischium    |
| <b>10</b> Pubic bone (anterior column) |  |
| <b>11</b> Ischium (posterior column)   |  |



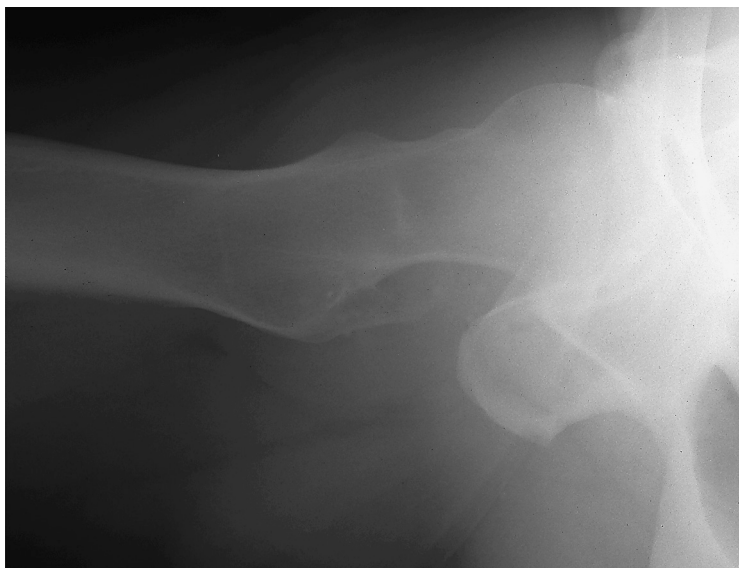

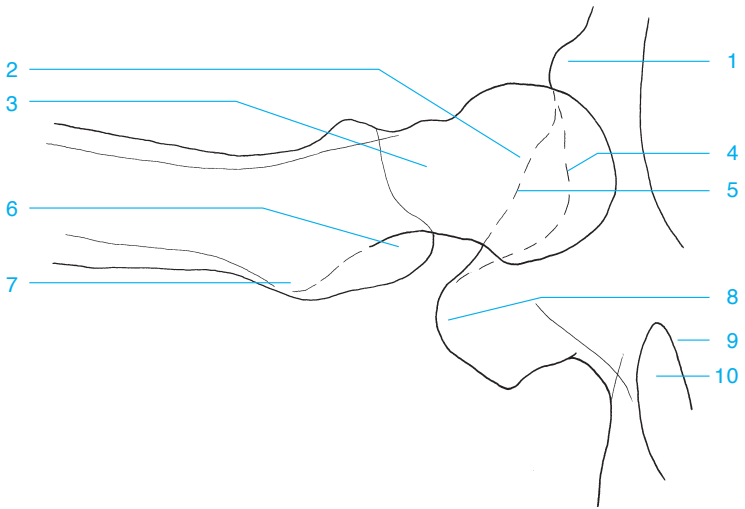
- |   |  |
|---|--|
| <b>1</b> Sacroiliac joint                               | <b>10</b> Pubic bone (anterior column) |
| <b>2</b> Ilium  | <b>11</b> Posterior acetabular rim     |
| <b>3</b> Anterior superior iliac spine                  | <b>12</b> Ischium                      |
| <b>4</b> Anterior inferior iliac spine                  | <b>13</b> Femoral neck                 |
| <b>5</b> Roof of the acetabulum                         | <b>14</b> Obturator foramen            |
| <b>6</b> Superior acetabular rim                        | <b>15</b> Greater trochanter           |
| <b>7</b> Spine of the ischium                           | <b>16</b> Ischial tuberosity           |
| <b>8</b> Anterior articular surface of the femoral head | <b>17</b> Intertrochanteric crest      |
| <b>9</b> Anterior acetabular rim                        | <b>18</b> Lesser trochanter            |





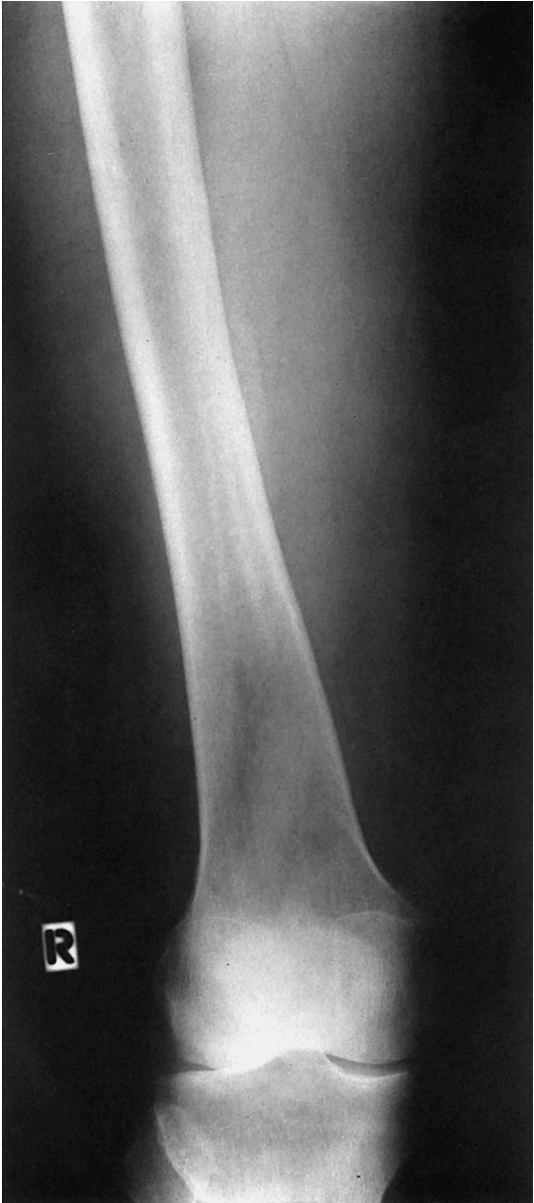- |  |                                   |
|--|-----------------------------------|
| <b>1</b> Sacroiliac joint                                | <b>8</b> Anterior acetabular rim  |
| <b>2</b> Iliac bone                                      | <b>9</b> Greater trochanter       |
| <b>3</b> Spine of the ischium                            | <b>10</b> Femoral neck            |
| <b>4</b> Roof of the acetabulum                          | <b>11</b> Ischium                 |
| <b>5</b> Posterior articular surface of the femoral head | <b>12</b> Pubic bone              |
| <b>6</b> Anterior superior iliac spine                   | <b>13</b> Intertrochanteric crest |
| <b>7</b> Floor of the acetabulum                         | <b>14</b> Lesser trochanter       |

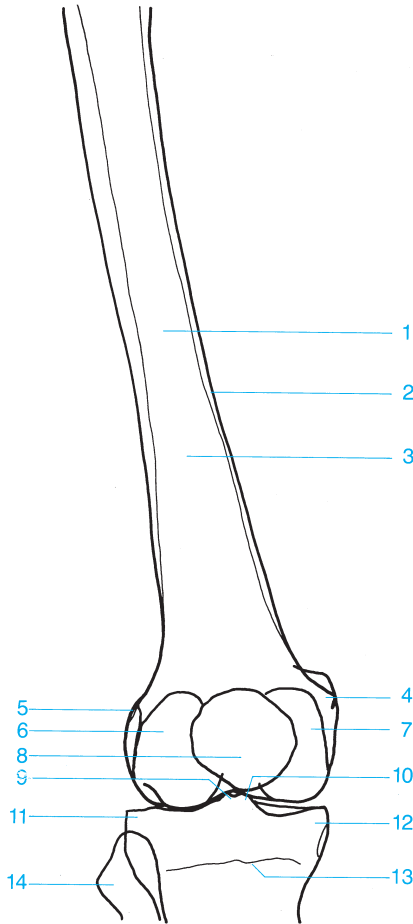




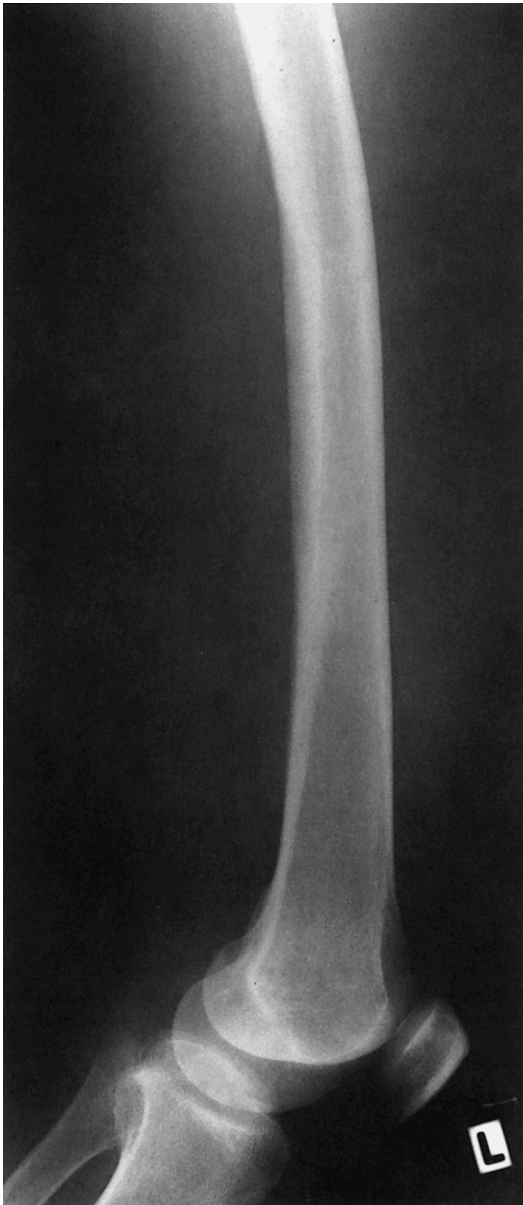- |                                 |                      |
|---------------------------------|----------------------|
| 1 Anterior inferior iliac spine | 6 Greater trochanter |
| 2 Femoral head                  | 7 Lesser trochanter  |
| 3 Femoral neck                  | 8 Ischial tuberosity |
| 4 Anterior acetabular rim       | 9 Pubic bone         |
| 5 Posterior acetabular rim      | 10 Obturator foramen |

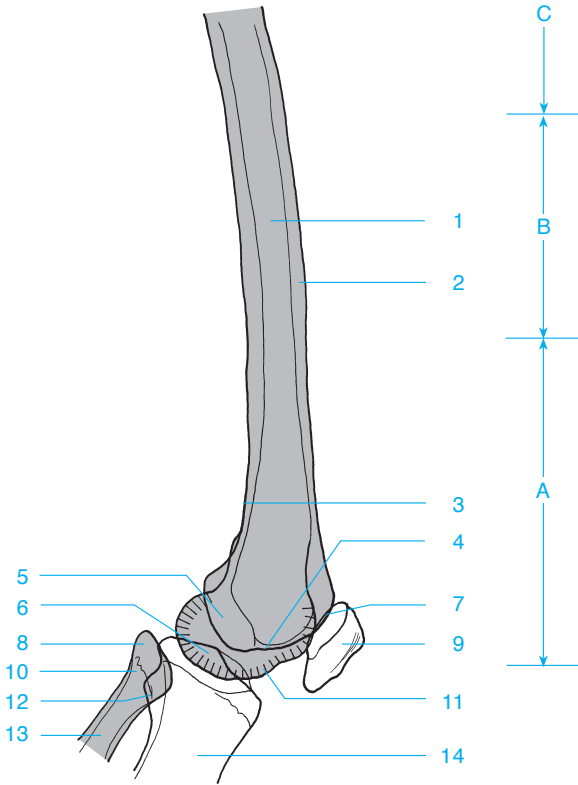




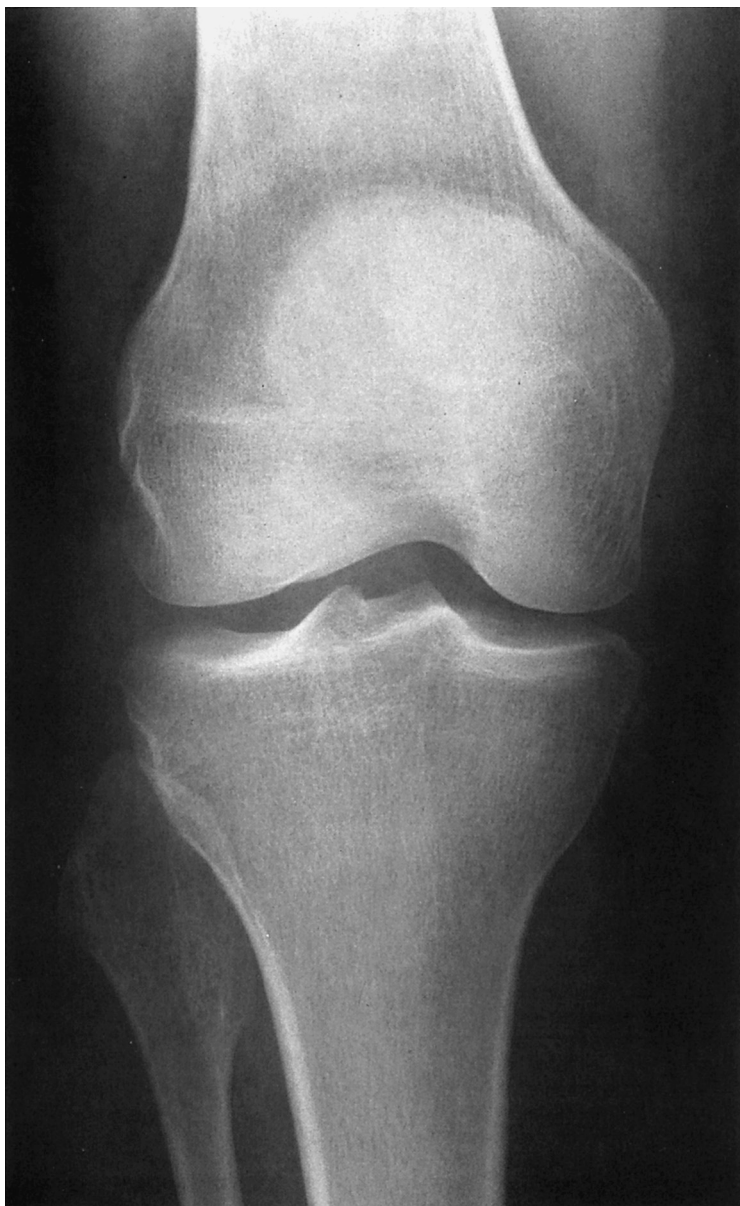


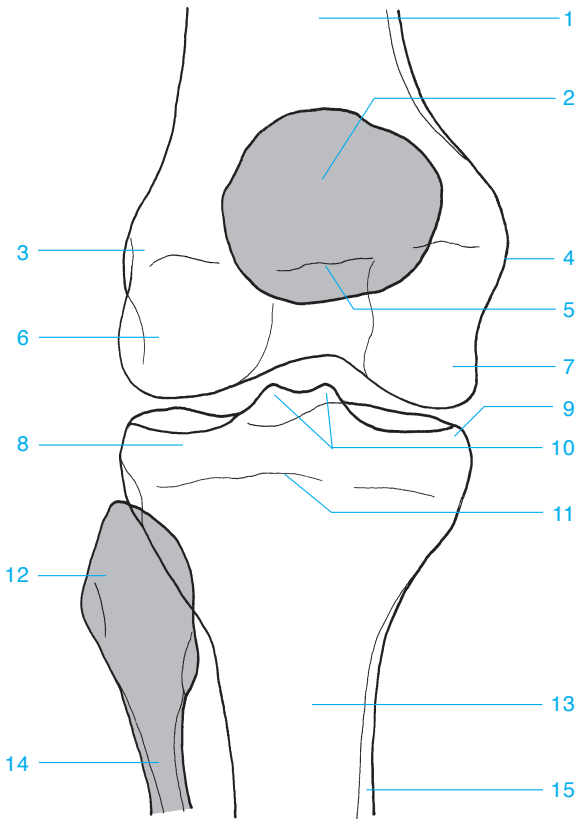
- |                                     |   |
|-------------------------------------|---|
| <b>1</b> Femoral shaft              | <b>9</b> Lateral tubercle of the intercondylar eminence |
| <b>2</b> Cortex                     | <b>10</b> Medial tubercle of the intercondylar eminence |
| <b>3</b> Medullary canal            | <b>11</b> Lateral tibial condyle                        |
| <b>4</b> Medial femoral epicondyle  | <b>12</b> Medial tibial condyle                         |
| <b>5</b> Lateral femoral epicondyle | <b>13</b> Growth plate                                  |
| <b>6</b> Lateral femoral condyle    | <b>14</b> Fibular head                                  |
| <b>7</b> Medial femoral condyle     |   |
| <b>8</b> Patella                    |   |



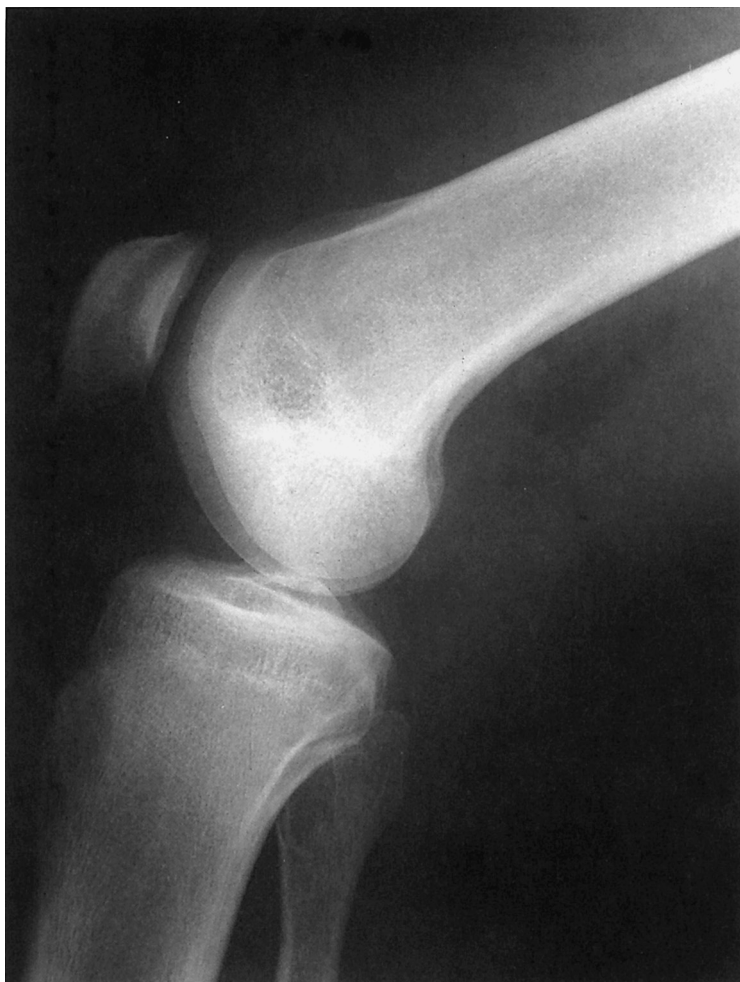

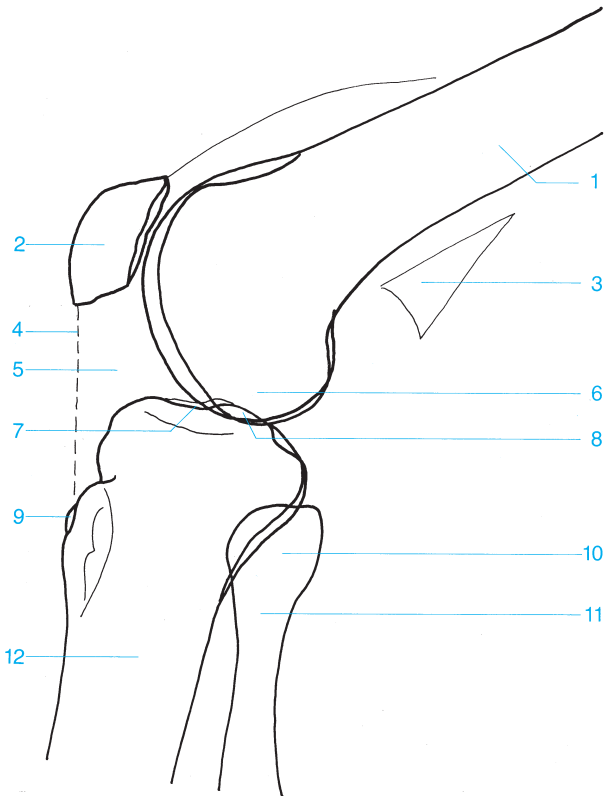
- A** Distal third of the femur
- B** Middle third of the femur
- C** Proximal third of the femur
- 1** Femur
- 2** Cortex
- 3** Popliteal fossa
- 4** Lateral femoral condyle
- 5** Intercondylar fossa
- 6** Intercondylar eminence
- 7** Patellofemoral joint
- 8** Apex of the fibular head
- 9** Patella
- 10** Fibular head
- 11** Medial femoral condyle
  - a Opposite the lateral tibial condyle, which articulates with the fibula.
  - b Regardless of the lateral position, the corresponding lateral articular surfaces of the patella and femur are longer proximal to distal than the corresponding medial articular surfaces.
- 12** Tibiofibular joint
- 13** Fibula
- 14** Tibia





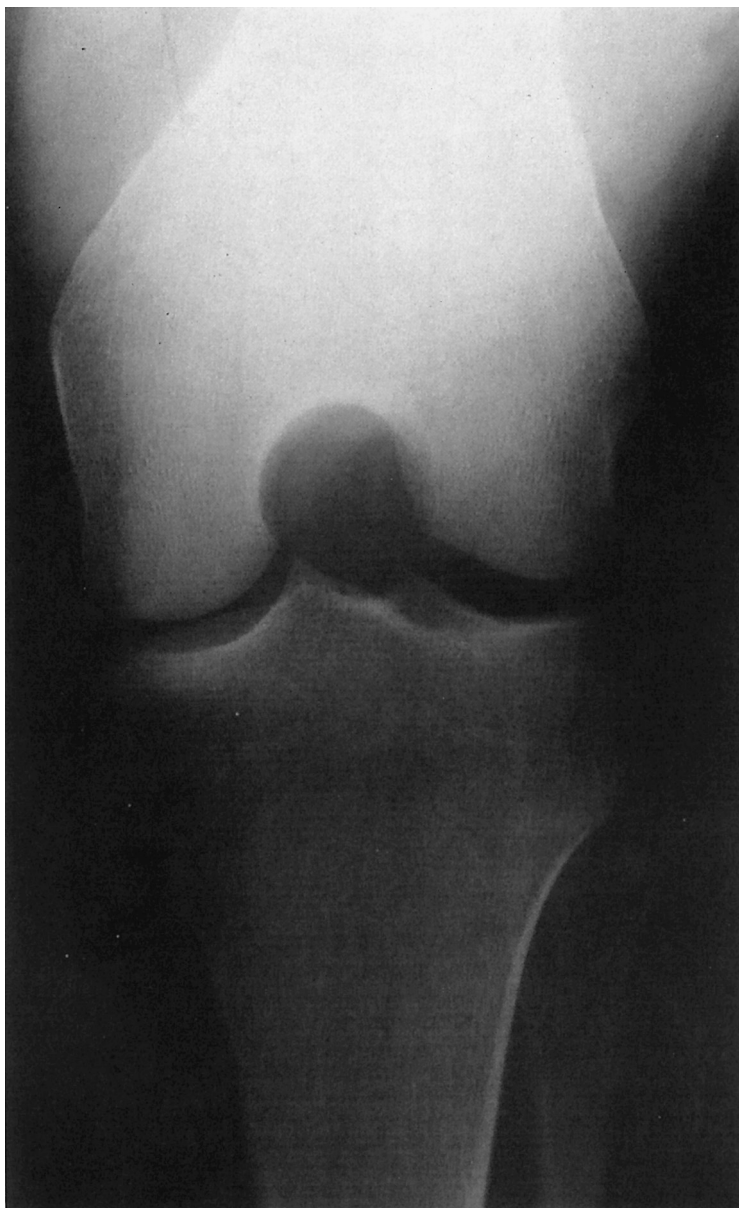
- |                                     |  |
|-------------------------------------|--|
| <b>1</b> Femur                      | <b>9</b> Medial tibial condyle                                       |
| <b>2</b> Patella                    | <b>10</b> Medial and lateral tubercles of the intercondylar eminence |
| <b>3</b> Lateral femoral epicondyle | <b>11</b> Epiphyseal plate   |
| <b>4</b> Medial femoral epicondyle  | <b>12</b> Fibular head   |
| <b>5</b> Growth plate               | <b>13</b> Tibia  |
| <b>6</b> Lateral femoral condyle    | <b>14</b> Fibula   |
| <b>7</b> Medial femoral condyle     | <b>15</b> Cortex   |
| <b>8</b> Lateral tibial condyle     |  |

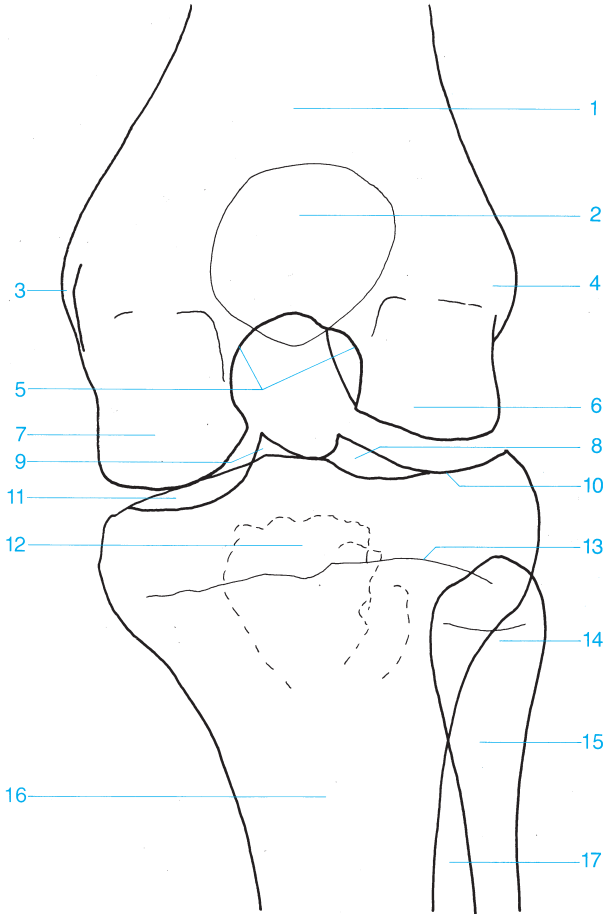




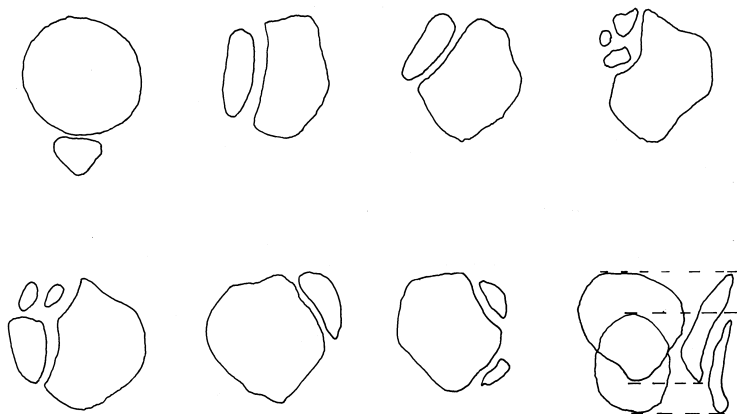
- |                           |                          |
|---------------------------|--------------------------|
| 1 Femur                   | 7 Tibial plateau         |
| 2 Patella                 | 8 Intercondylar eminence |
| 3 Posterior fat           | 9 Tibial tuberosity      |
| 4 Patellar ligament       | 10 Fibular head          |
| 5 Infrapatellar fat pad   | 11 Fibular neck          |
| 6 Lateral femoral condyle | 12 Tibia                 |



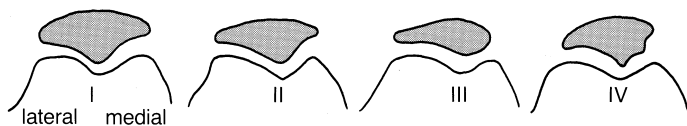




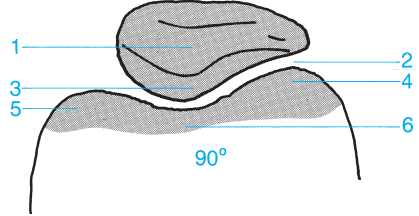
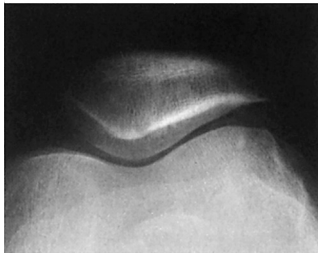
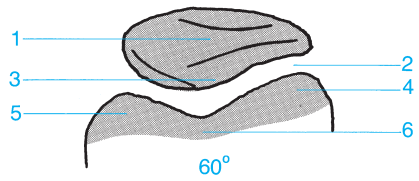
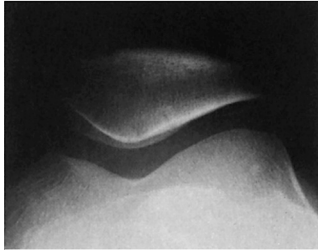
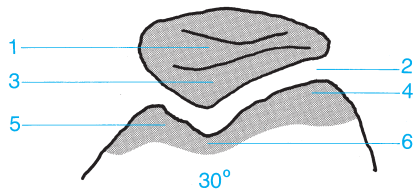
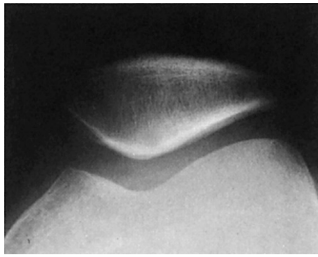
- |   |  |
|---|--|
| <b>1</b> Femur  | <b>9</b> Medial tubercle of the intercondylar eminence |
| <b>2</b> Patella  | <b>10</b> Lateral tibial plateau                       |
| <b>3</b> Medial femoral epicondyle                      | <b>11</b> Medial tibial plateau                        |
| <b>4</b> Lateral femoral epicondyle                     | <b>12</b> Tibial tuberosity                            |
| <b>5</b> Intercondylar fossa                            | <b>13</b> Growth plate                                 |
| <b>6</b> Lateral femoral condyle                        | <b>14</b> Fibular head                                 |
| <b>7</b> Medial femoral condyle                         | <b>15</b> Fibular neck                                 |
| <b>8</b> Lateral tubercle of the intercondylar eminence | <b>16</b> Tibia  |
|   | <b>17</b> Interosseous membrane                        |



Most common forms of multipartite patella (as described by Schaer).

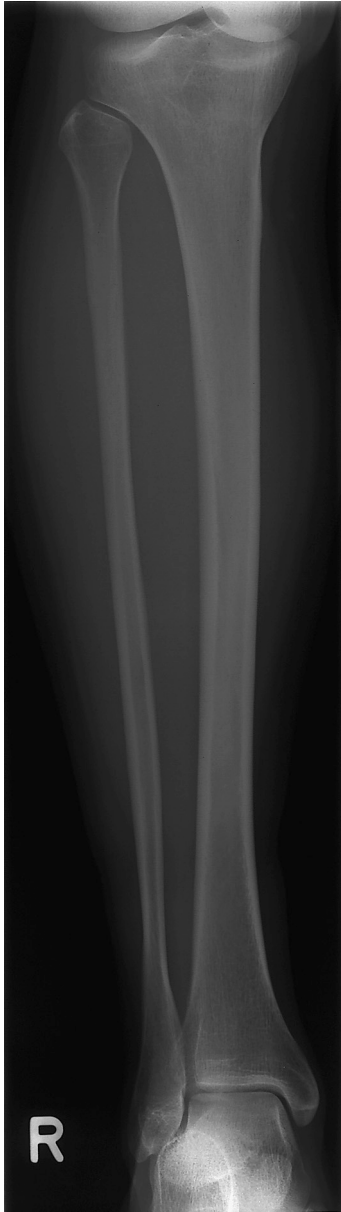

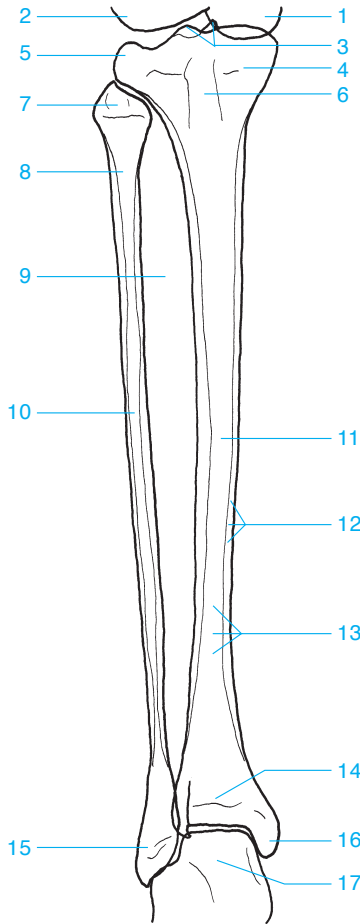
Wiberg's classification of patellar shapes (right knee)



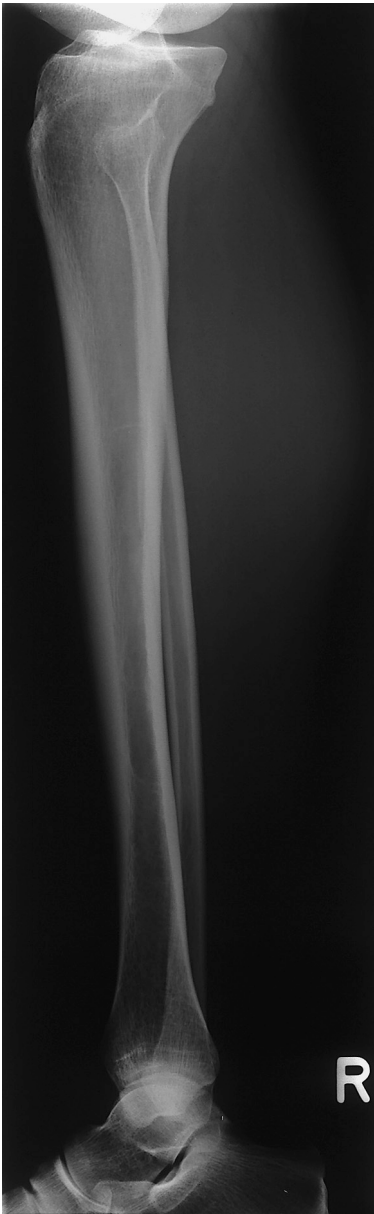- 1 Patella
- 2 Patellofemoral joint
- 3 Articular surface

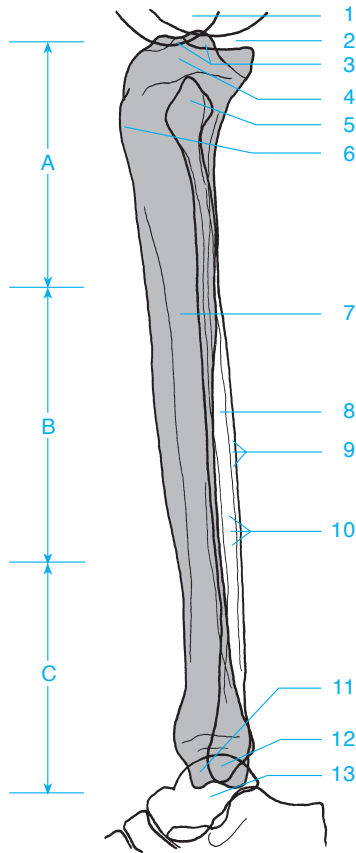
- 4 Lateral femoral condyle (generally larger)
- 5 Medial femoral condyle
- 6 Intercondylar fossa





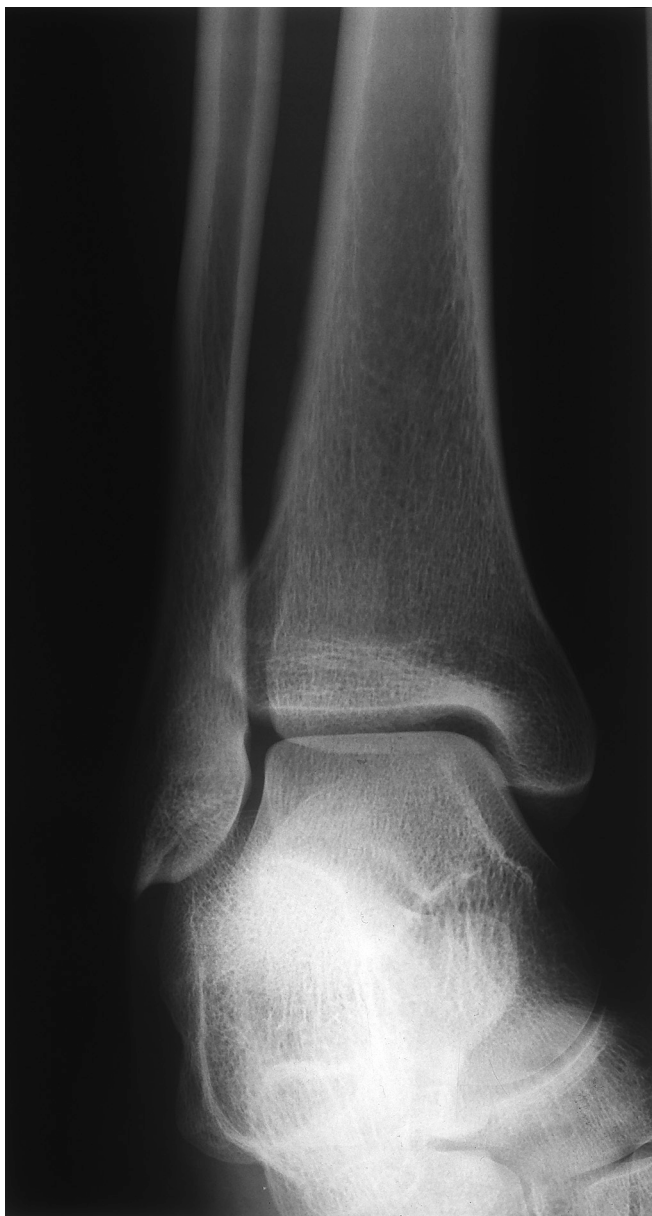- |  |                         |
|--|-------------------------|
| 1 Medial femoral condyle                                     | 9 Interosseous membrane |
| 2 Lateral femoral condyle                                    | 10 Fibula               |
| 3 Medial and lateral tubercles of the intercondylar eminence | 11 Tibia                |
| 4 Medial tibial condyle                                      | 12 Cortex               |
| 5 Lateral tibial condyle                                     | 13 Medullary canal      |
| 6 Tibial tuberosity  | 14 Growth plate         |
| 7 Fibular head   | 15 Lateral malleolus    |
| 8 Fibular neck   | 16 Medial malleolus     |
|  | 17 Talus                |

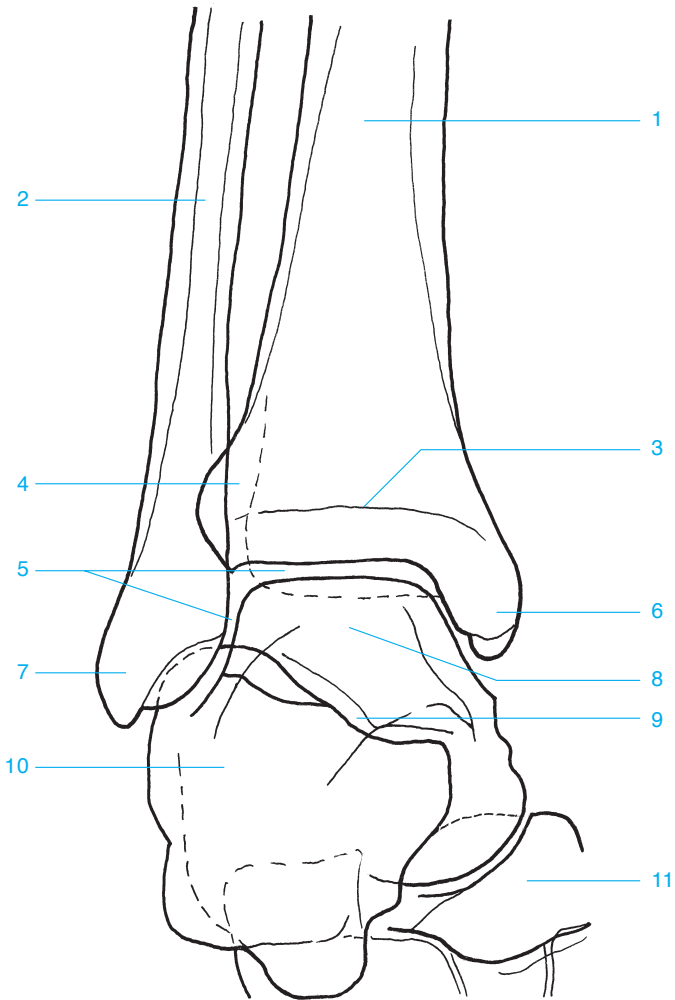




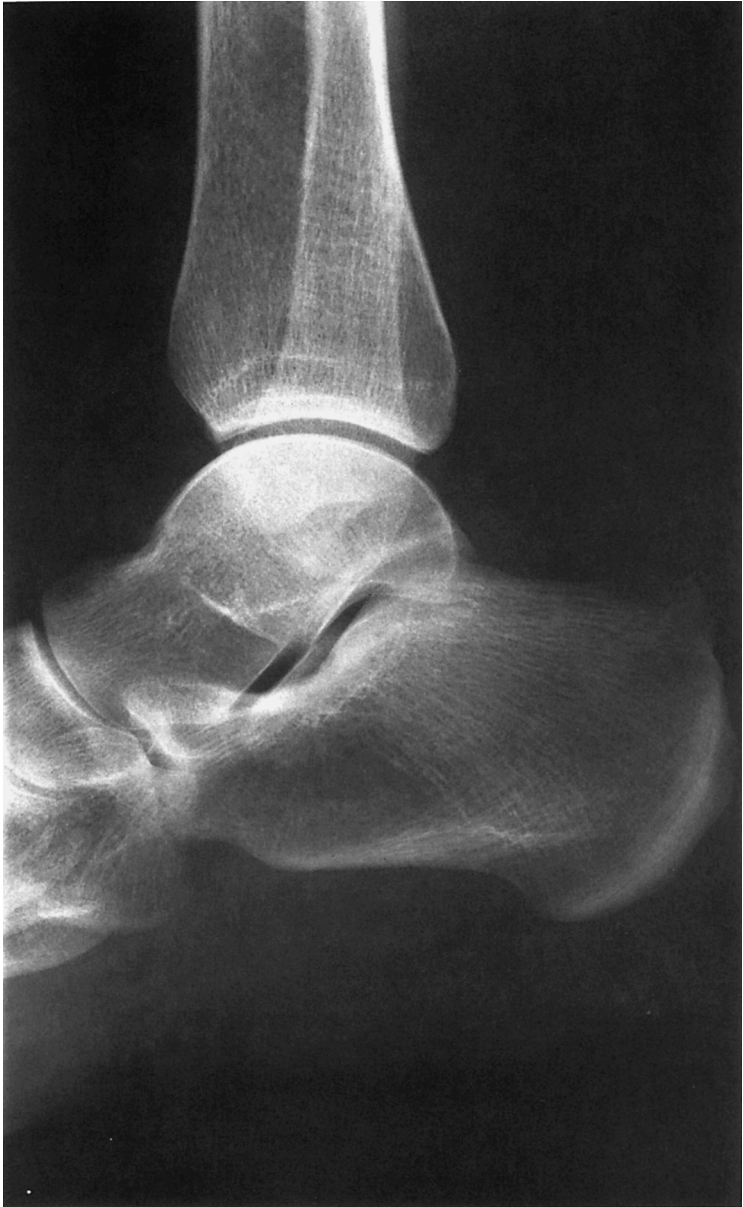- |  |  |
|--|--|
| <b>A</b> Proximal third of the lower leg     | <b>6</b> Proximal tibial apophysis (in children) |
| <b>B</b> Middle third of the lower leg       | <b>7</b> Tibia                                   |
| <b>C</b> Distal third of the lower leg       | <b>8</b> Fibula                                  |
| <b>1</b> Medial and lateral femoral condyles | <b>9</b> Cortex                                  |
| <b>2</b> Knee                                | <b>10</b> Medullary canal                        |
| <b>3</b> Intercondylar eminence              | <b>11</b> Medial malleus                         |
| <b>4</b> Medial and lateral tibial condyles  | <b>12</b> Lateral malleus                        |
| <b>5</b> Fibular head                        | <b>13</b> Talus                                  |

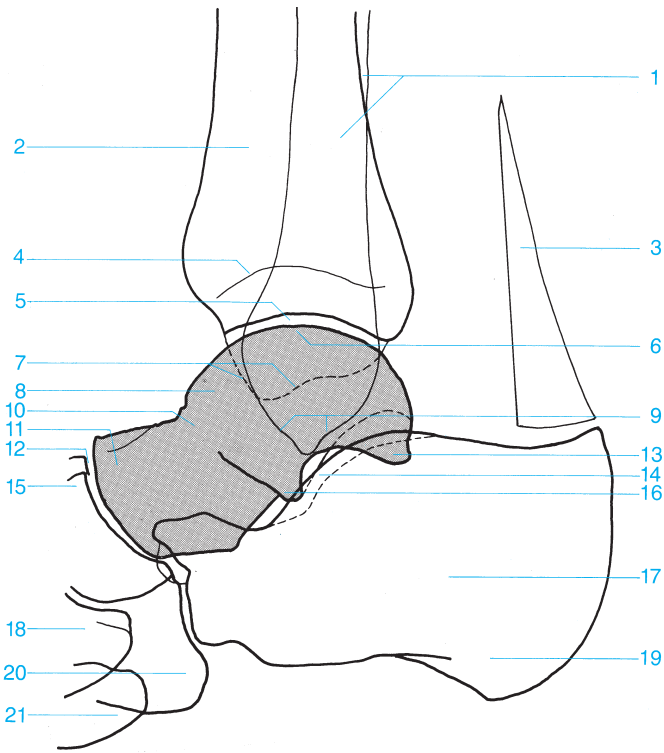




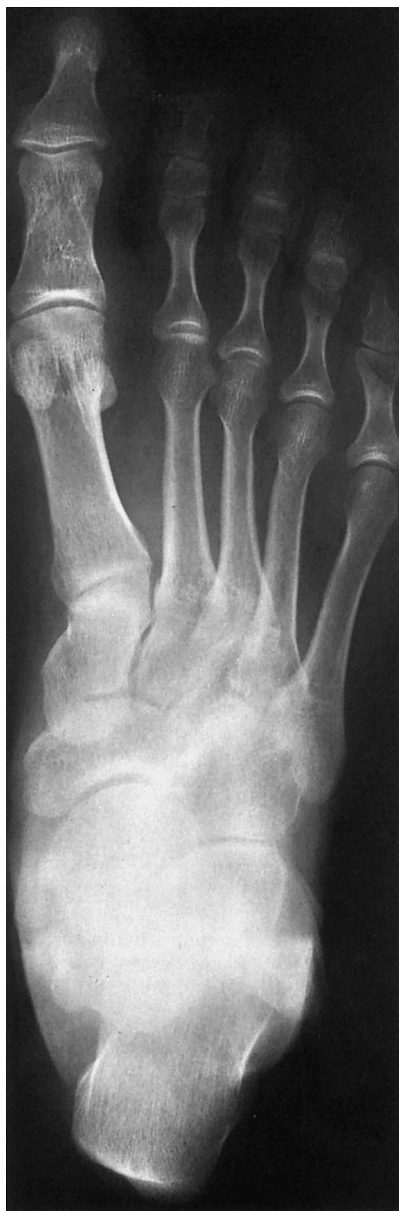

- |                    |                         |
|--------------------|-------------------------|
| 1 Tibia            | 7 Lateral malleolus     |
| 2 Fibula           | 8 Trochlea of the talus |
| 3 Growth plate     | 9 Subtalar joint        |
| 4 Fibular notch    | 10 Calcaneus            |
| 5 Ankle            | 11 Navicular            |
| 6 Medial malleolus |                         |

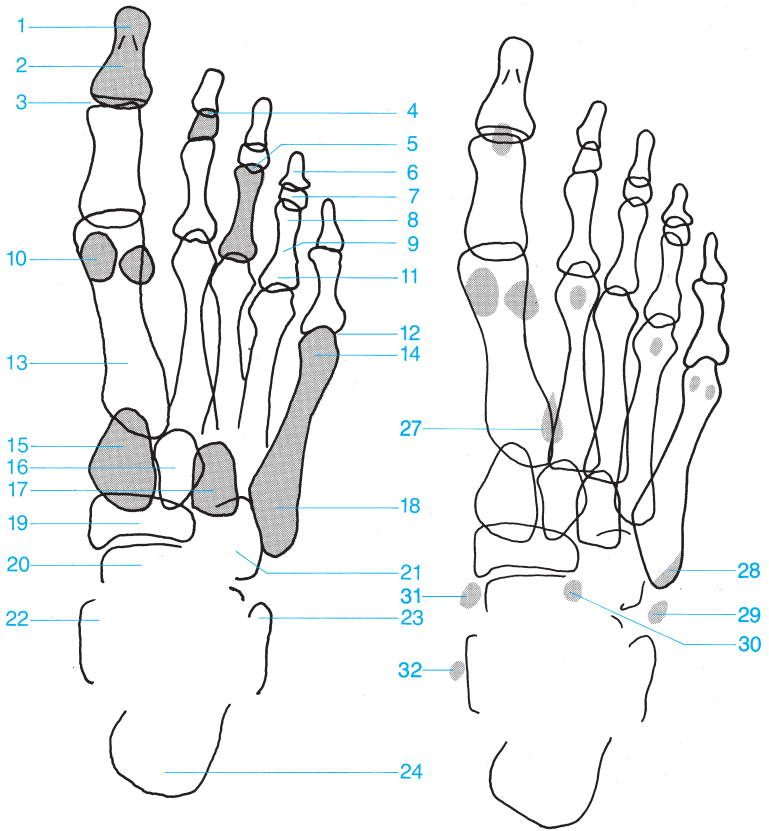




- |                                |   |
|--------------------------------|---|
| <b>1</b> Fibula                | <b>12</b> Talonavicular joint                   |
| <b>2</b> Tibia                 | <b>13</b> Posterior process of the talus        |
| <b>3</b> Achilles tendon       | <b>14</b> Sinus tarsi                           |
| <b>4</b> Growth plate          | <b>15</b> Navicular                             |
| <b>5</b> Ankle                 | <b>16</b> Lateral process of the talus          |
| <b>6</b> Trochlea of the talus | <b>17</b> Calcaneus                             |
| <b>7</b> Medial malleolus      | <b>18</b> Medial cuneiform                      |
| <b>8</b> Talus                 | <b>19</b> Posterior tuberosity of the calcaneus |
| <b>9</b> Lateral malleolus     | <b>20</b> Cuboid                                |
| <b>10</b> Neck of the talus    | <b>21</b> Base of the fifth metatarsal          |
| <b>11</b> Head of the talus    |   |

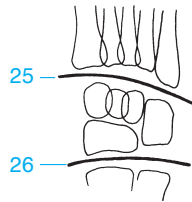


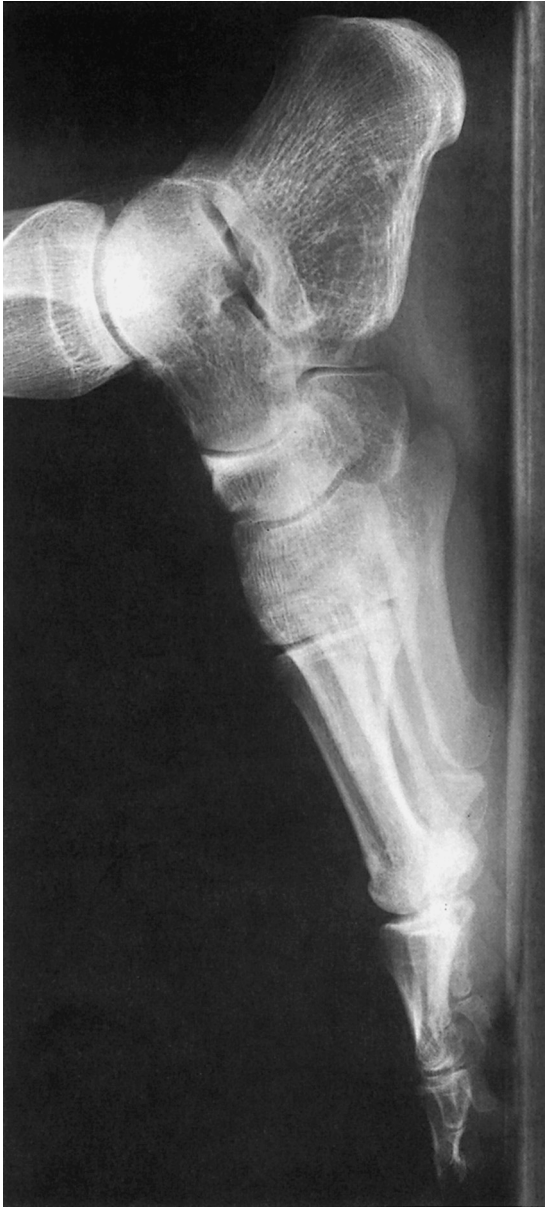- 1 Distal phalanx (tuft)
- 2 Distal phalanx of the great toe
- 3 Distal interphalangeal joint of the great toe
- 4 Distal interphalangeal joint
- 5 Proximal interphalangeal joint
- 6 Distal phalanx
- 7 Middle phalanx
- 8 Head of the proximal phalanx
- 9 Proximal phalanx
- 10 Sesamoid
- 11 Base of the phalanx
- 12 Metatarsophalangeal joint
- 13 Metatarsal
- 14 Metatarsal head
- 15 Medial cuneiform
- 16 Middle cuneiform
- 17 Lateral cuneiform
- 18 Base of the fifth metatarsal
- 19 Navicular
- 20 Head of the talus
- 21 Cuboid
- 22 Medial malleolus
- 23 Lateral malleolus
- 24 Calcaneus
- 25 Tarsometatarsal joints (Lisfranc's joints)
- 26 Transverse tarsal joint (Chopart's joint)

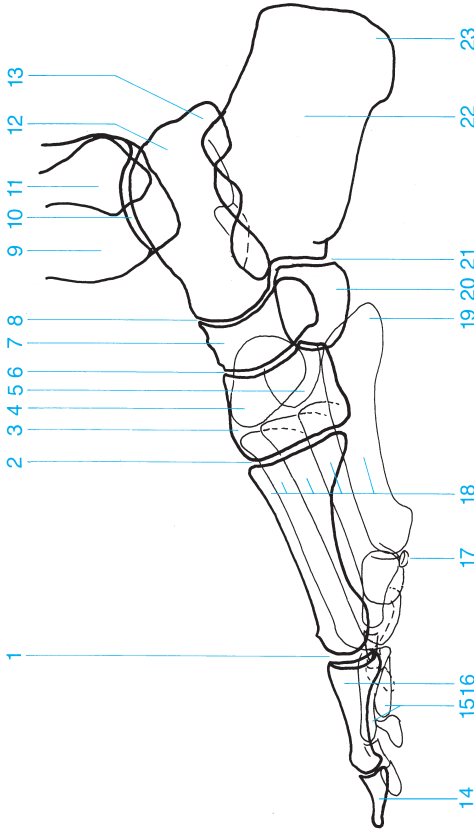


Common sesamoids and accessory bones in the foot.

- 27 Os intermetatarsium
- 28 Os vesalianum
- 29 Os peroneum
- 30 Secondary cuboid
- 31 Os tibiale externum
- 32 Os supratalare

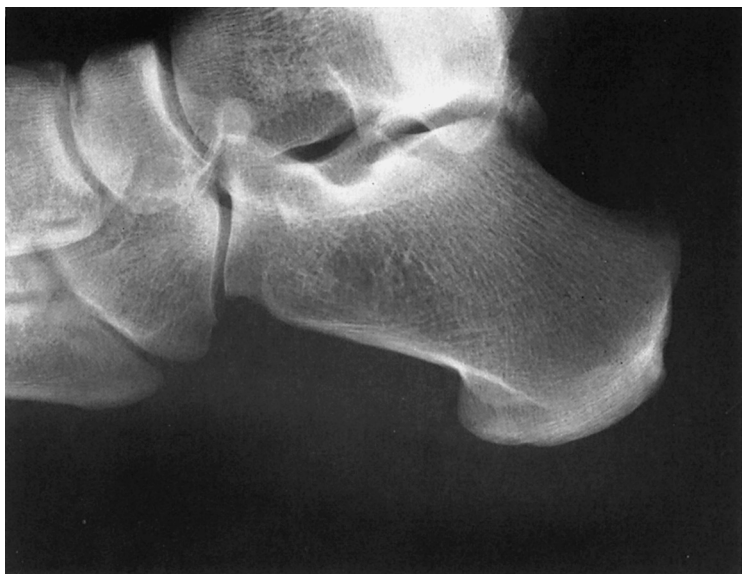


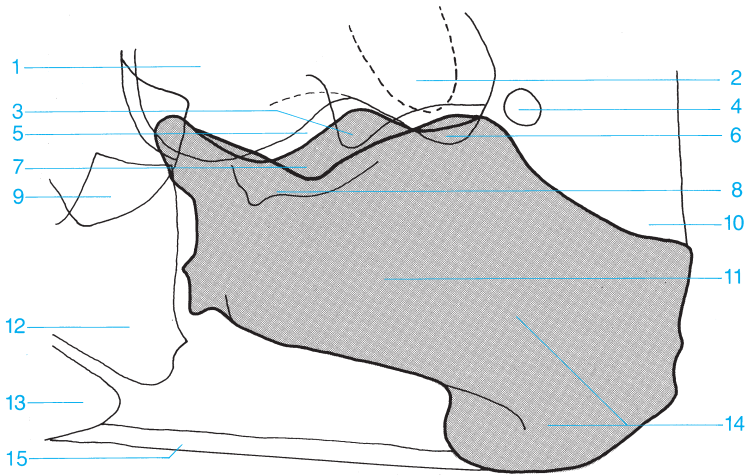




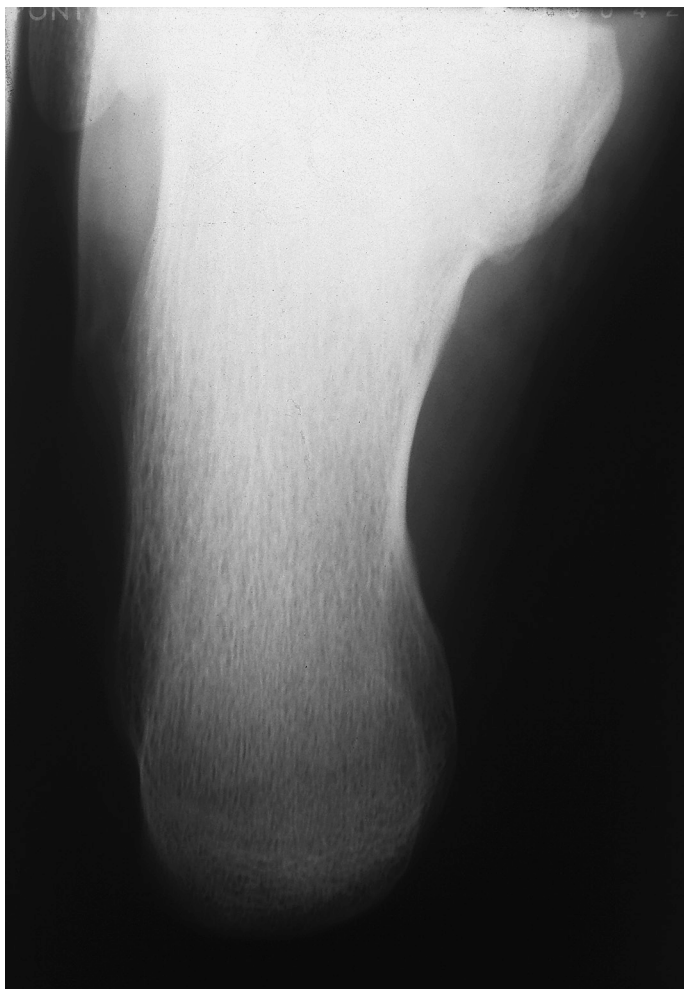- 1 Metatarsophalangeal joint
- 2 Tarsometatarsal joint
- 3 Medial cuneiform
- 4 Middle cuneiform
- 5 Lateral cuneiform
- 6 Cuneonavicular joint
- 7 Navicular
- 8 Talocalcaneonavicular joint
- 9 Tibia
- 10 Ankle
- 11 Fibula
- 12 Talus
- 13 Posterior process of the talus
- 14 Distal phalanx
- 15 Middle phalanx
- 16 Proximal phalanx
- 17 Sesamoid
- 18 Metatarsal
- 19 Base of fifth metatarsal
- 20 Cuboid
- 21 Calcaneocuboid joint
- 22 Calcaneus
- 23 Posterior tuberosity of the calcaneus

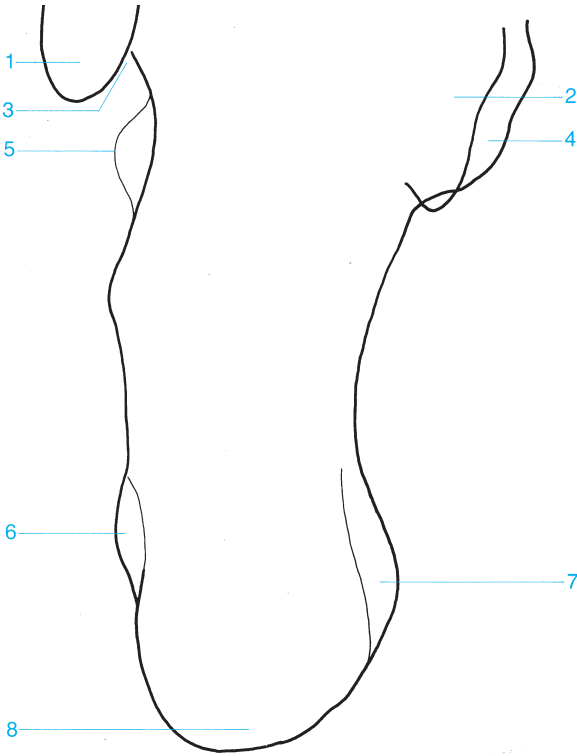






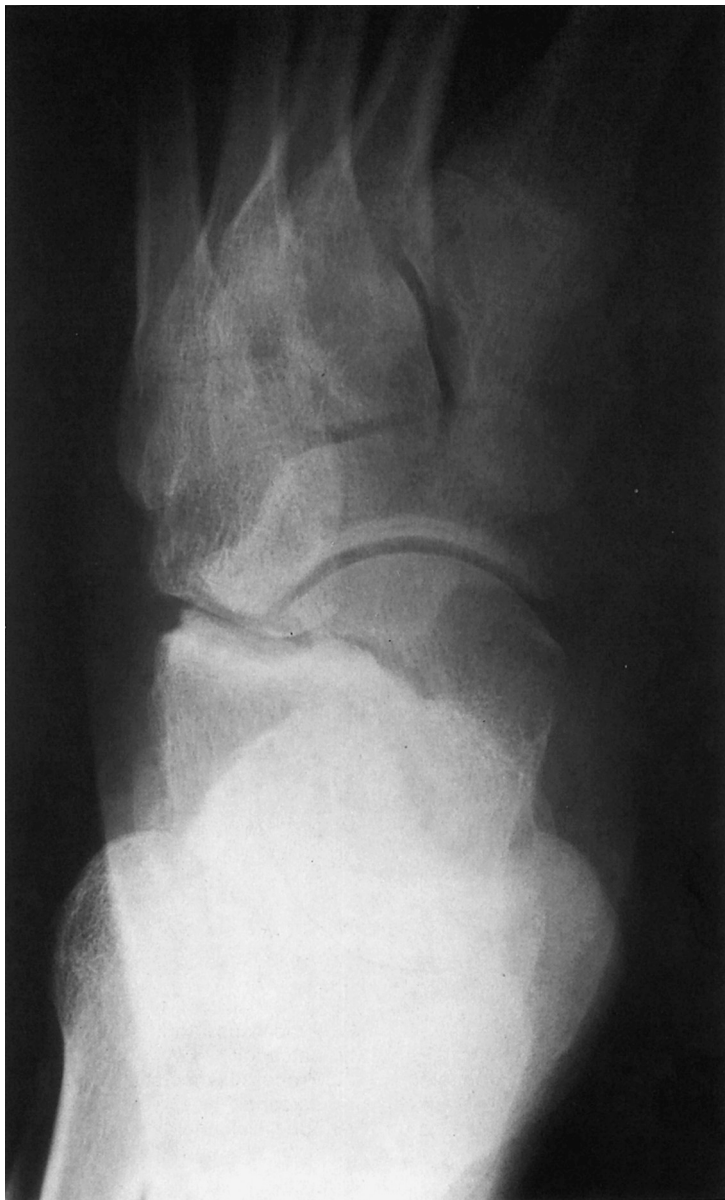- |   |   |
|---|---|
| <b>1</b> Talus                          | <b>9</b> Navicular                              |
| <b>2</b> Lateral malleolus              | <b>10</b> Achilles tendon                       |
| <b>3</b> Lateral process of the talus   | <b>11</b> Calcaneus                             |
| <b>4</b> Os trigonum                    | <b>12</b> Cuboid                                |
| <b>5</b> Subtalar joint                 | <b>13</b> Base of fifth metatarsal              |
| <b>6</b> Posterior process of the talus | <b>14</b> Posterior tuberosity of the calcaneus |
| <b>7</b> Sinus tarsi                    | <b>15</b> Plantar aponeurosis                   |
| <b>8</b> Sustentaculum tali             |   |

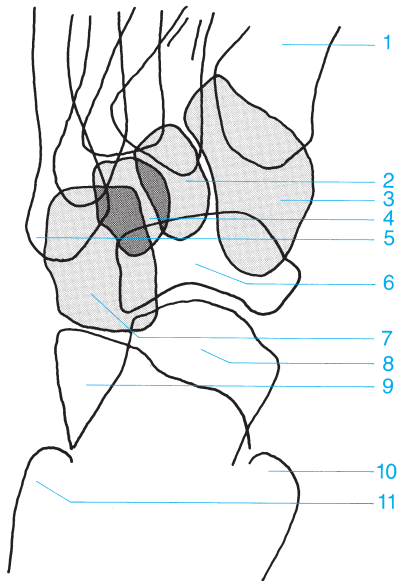




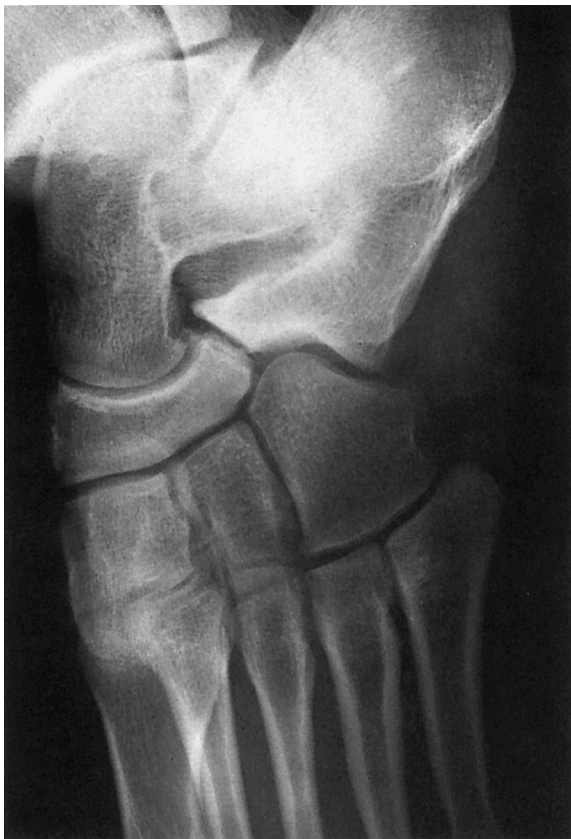- 1** Lateral malleolus
- 2** Talus
- 3** Groove for the peroneus longus tendon
- 4** Sustentaculum tali
- 5** Peroneal trochlea

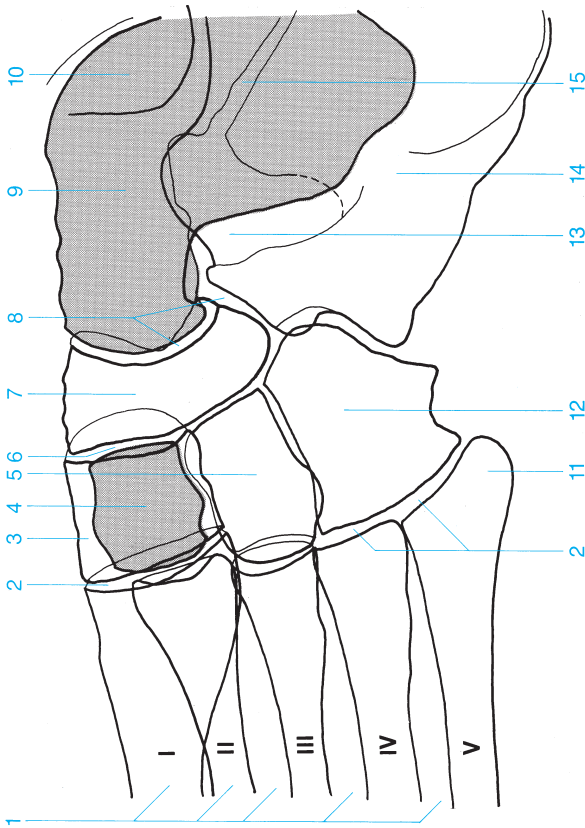
- 6** Lateral process of the posterior tuberosity of the calcaneus
- 7** Medial process of the posterior tuberosity of the calcaneus
- 8** Posterior tuberosity of the calcaneus





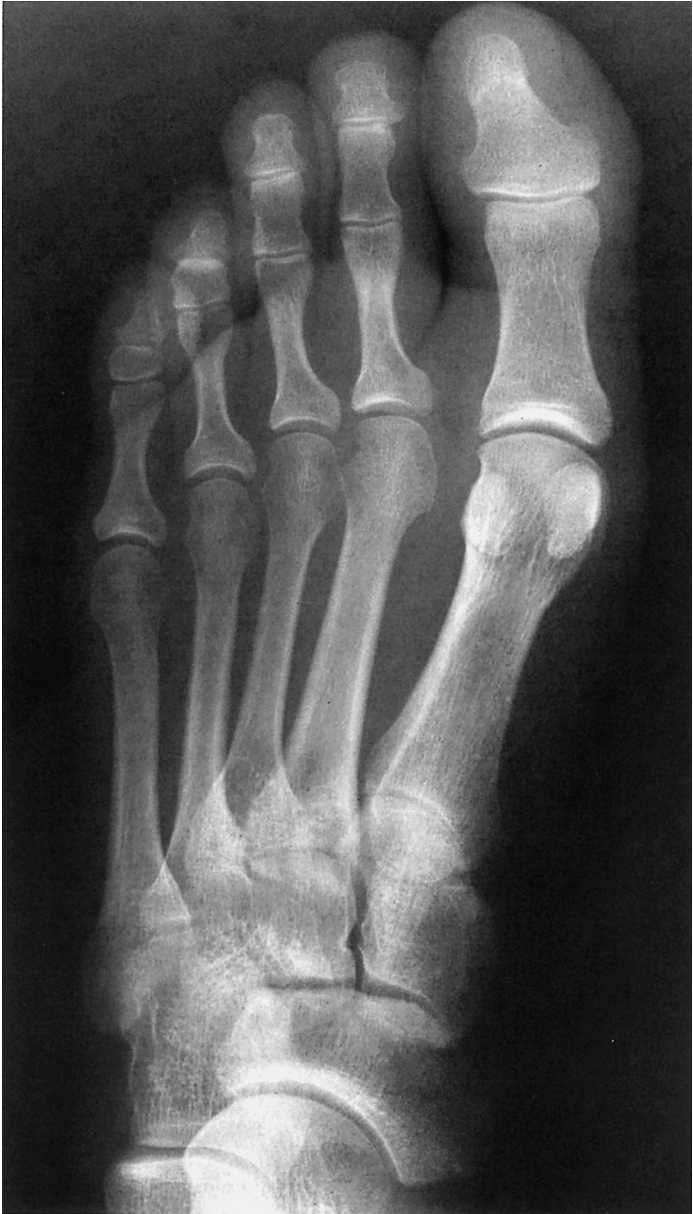- |                                |                      |
|--------------------------------|----------------------|
| 1 Metatarsal                   | 7 Cuboid             |
| 2 Middle cuneiform             | 8 Head of the talus  |
| 3 Medial cuneiform             | 9 Calcaneus          |
| 4 Lateral cuneiform            | 10 Medial malleolus  |
| 5 Base of the fifth metatarsal | 11 Lateral malleolus |
| 6 Navicular                    |                      |

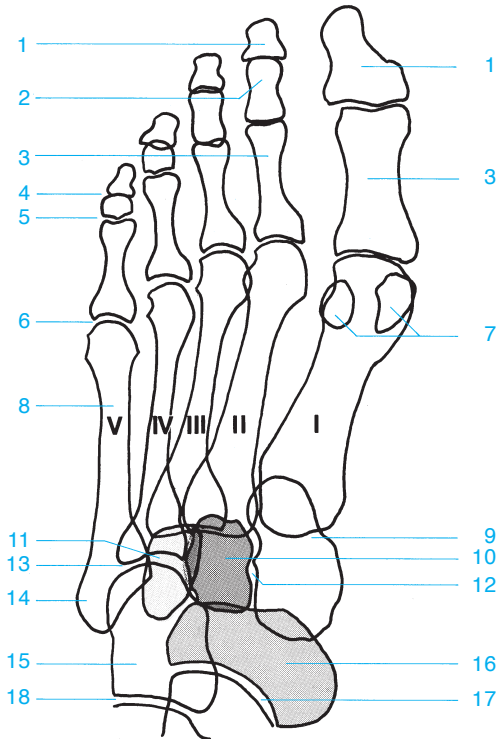




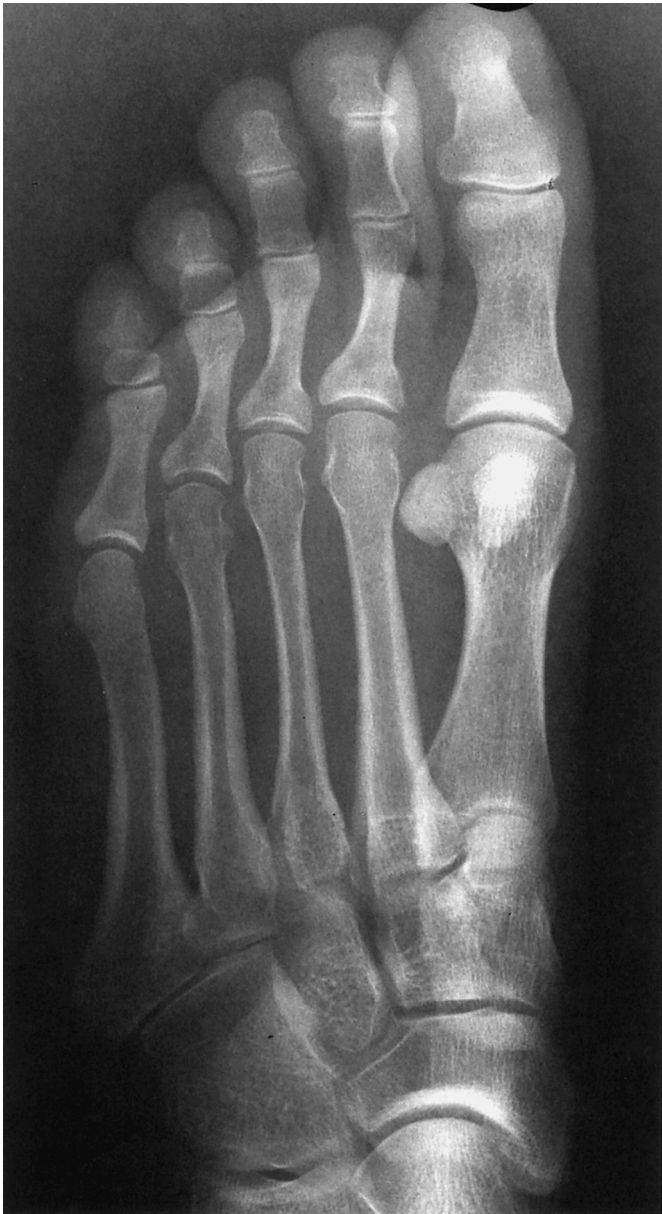- 1 Metatarsals
- 2 Tarsometatarsal joint
- 3 Medial cuneiform
- 4 Middle cuneiform
- 5 Lateral cuneiform
- 6 Cuneonavicular joint
- 7 Navicular
- 8 Talocalcaneonavicular joint
- 9 Talus
- 10 Malleolus
- 11 Base of the fifth metatarsal
- 12 Cuboid
- 13 Sinus tarsi
- 14 Calcaneus
- 15 Subtalar joint (and talocalcaneonavicular joint)

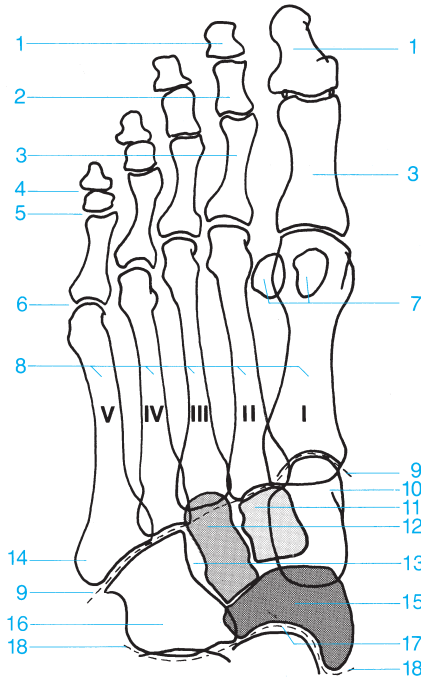






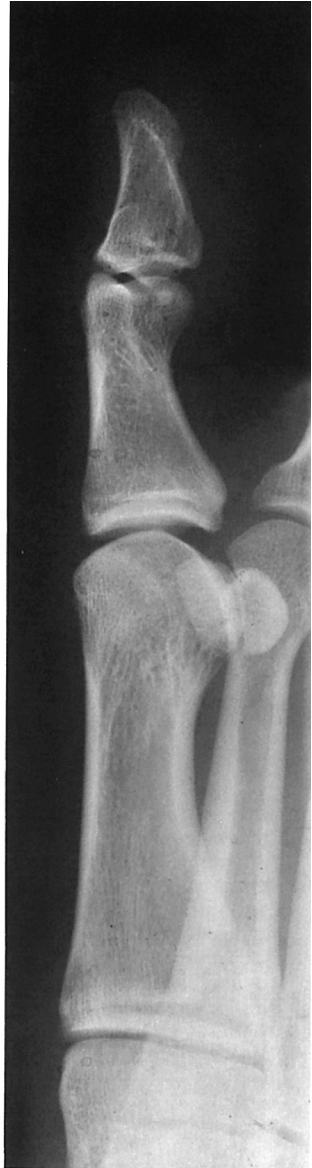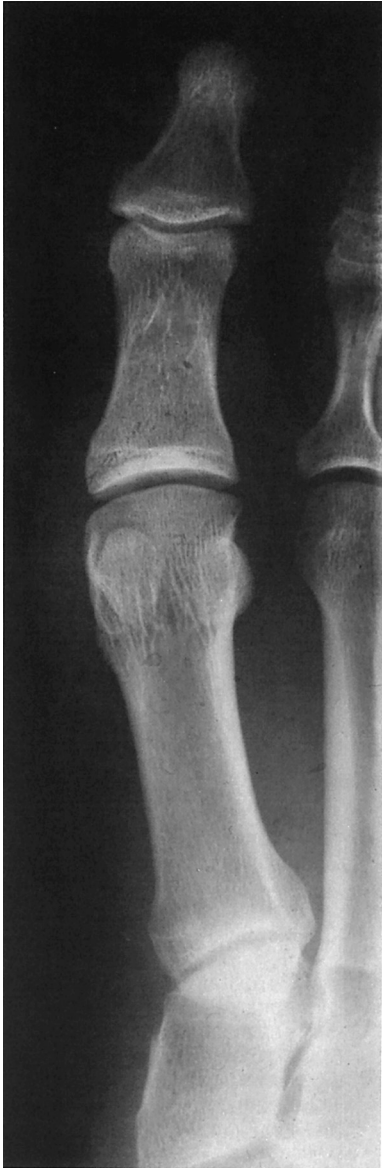- |                                  |                                 |
|----------------------------------|---------------------------------|
| 1 Distal phalanx                 | 10 Middle cuneiform             |
| 2 Middle phalanx                 | 11 Lateral cuneiform            |
| 3 Proximal phalanx               | 12 Intertarsal joint            |
| 4 Distal interphalangeal joint   | 13 Metatarsophalangeal joint    |
| 5 Proximal interphalangeal joint | 14 Base of the fifth metatarsal |
| 6 Metatarsophalangeal joint      | 15 Cuboid                       |
| 7 Sesamoids                      | 16 Navicular                    |
| 8 Metatarsals                    | 17 Talocalcaneonavicular joint  |
| 9 Medial cuneiform               | 18 Calcaneocuboid joint         |

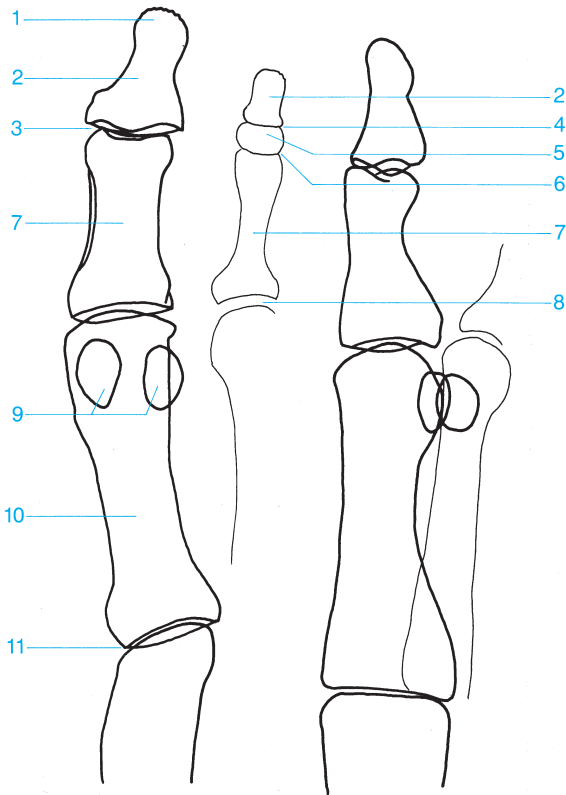




- 1 Distal phalanx
- 2 Middle phalanx
- 3 Proximal phalanx
- 4 Distal interphalangeal joint
- 5 Proximal interphalangeal joint
- 6 Metatarsophalangeal joint
- 7 Sesamoids
- 8 Metatarsals
- 9 Tarsometatarsal joint (Lisfranc's joint)
- 10 Medial cuneiform

- 11 Middle cuneiform
- 12 Lateral cuneiform
- 13 Intertarsal joint
- 14 Base of the fifth metatarsal
- 15 Navicular
- 16 Cuboid
- 17 Talocalcaneonavicular joint
- 18 Transverse tarsal joint (Chopart's joint between the talus, calcaneus, navicular, and cuboid)





- |   |                                    |
|---|------------------------------------|
| <b>1</b> Distal phalanx (tuft)                  | <b>7</b> Proximal phalanx          |
| <b>2</b> Distal phalanx                         | <b>8</b> Metatarsophalangeal joint |
| <b>3</b> Interphalangeal joint of the great toe | <b>9</b> Sesamoids                 |
| <b>4</b> Distal interphalangeal joint           | <b>10</b> First metatarsal         |
| <b>5</b> Middle phalanx                         | <b>11</b> Tarsometatarsal joint    |
| <b>6</b> Proximal interphalangeal joint         |                                    |

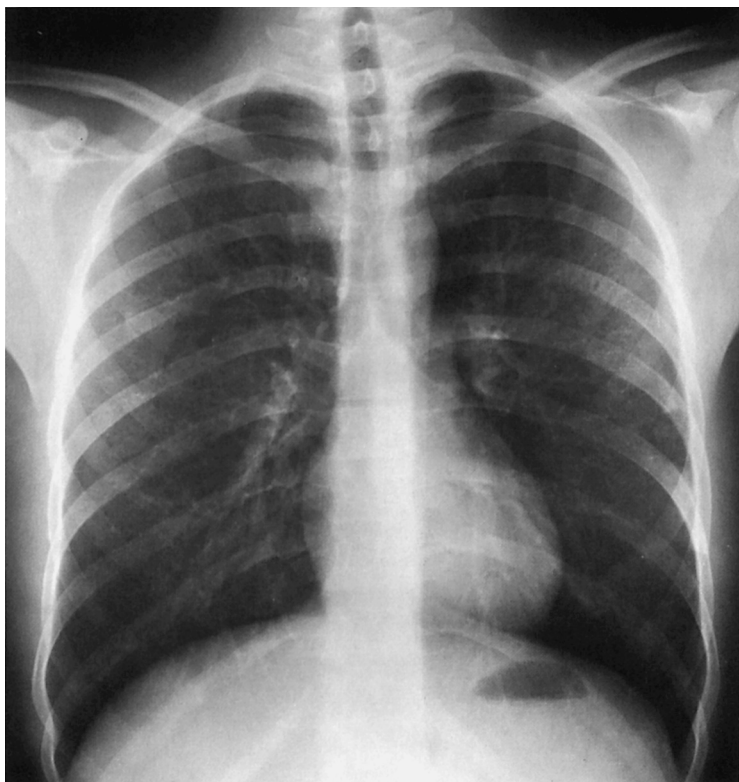


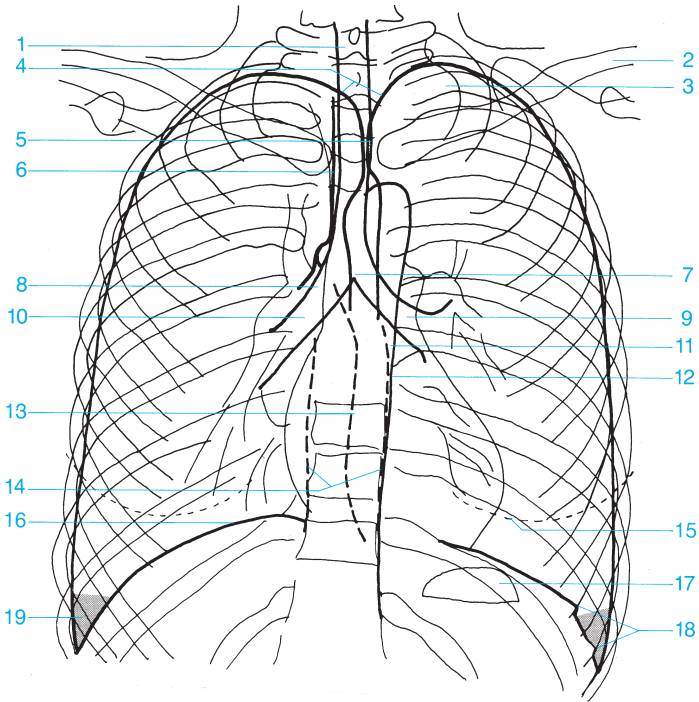
---

## Anatomy of Miscellaneous Plain Films

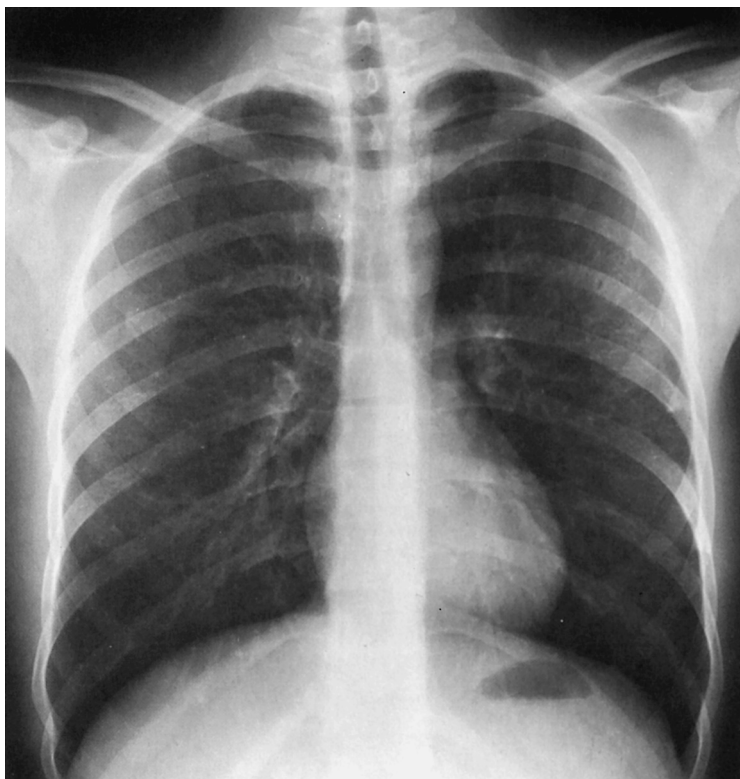
---

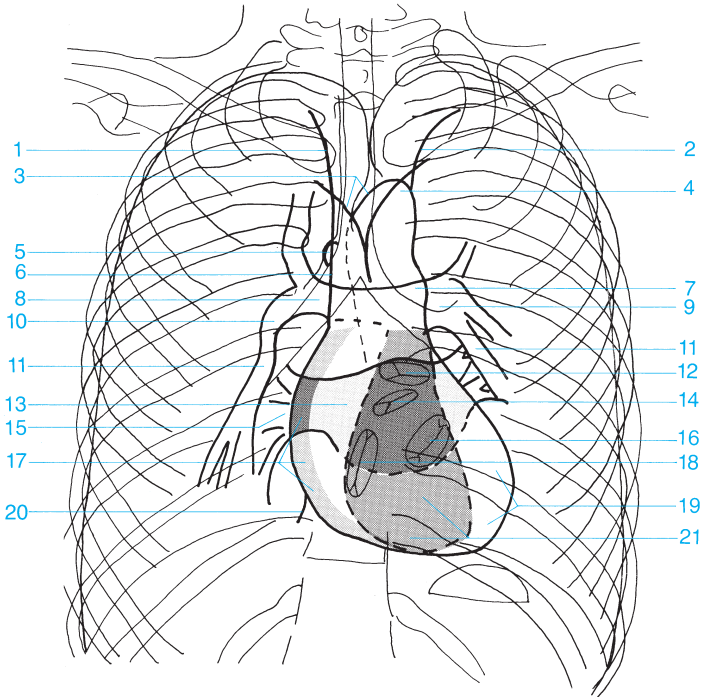




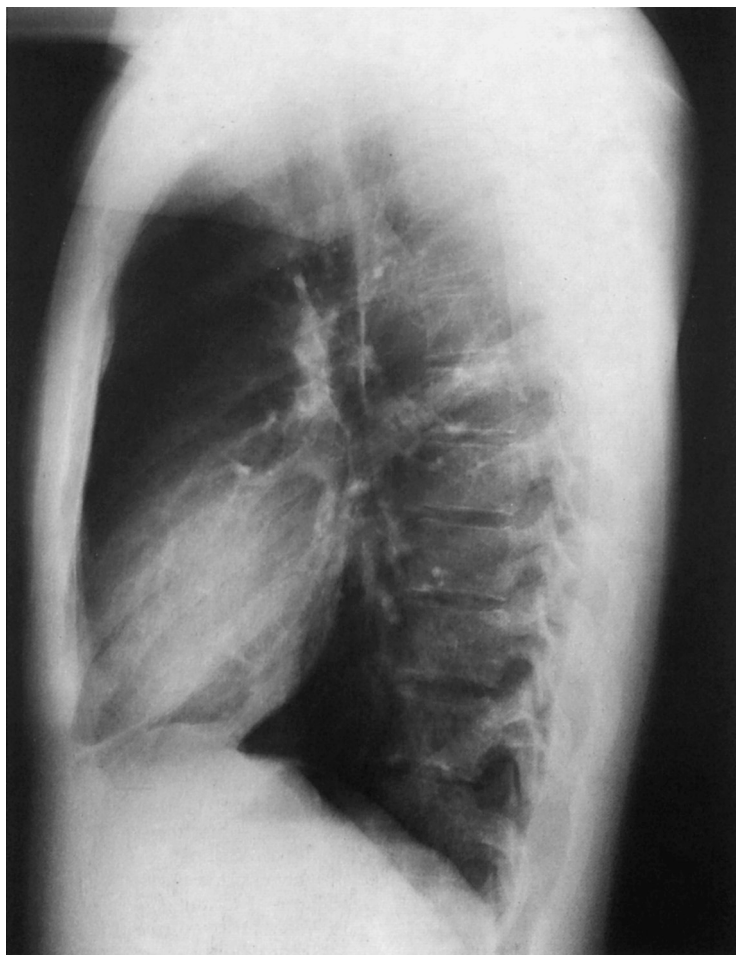

- |    |   |    |  |
|----|---|----|--|
| 1  | Trachea   | 11 | Paraaortic stripe                              |
| 2  | Clavicle  | 12 | Descending aorta                               |
| 3  | Apex of the lung                                  | 13 | Azygoesophageal stripe                         |
| 4  | Curve of the apex of the lung                     | 14 | Paraspinal stripe                              |
| 5  | Posterior border between the right and left lungs | 15 | Shadow of the breast                           |
| 6  | Right paratracheal stripe                         | 16 | Diaphragm                                      |
| 7  | Carina of the trachea                             | 17 | Gastric bubble                                 |
| 8  | Right main bronchus                               | 18 | Insertions of the diaphragm                    |
| 9  | Left main bronchus                                | 19 | Costodiaphragmatic recess (costophrenic angle) |
| 10 | Intermediate bronchus                             |    |  |

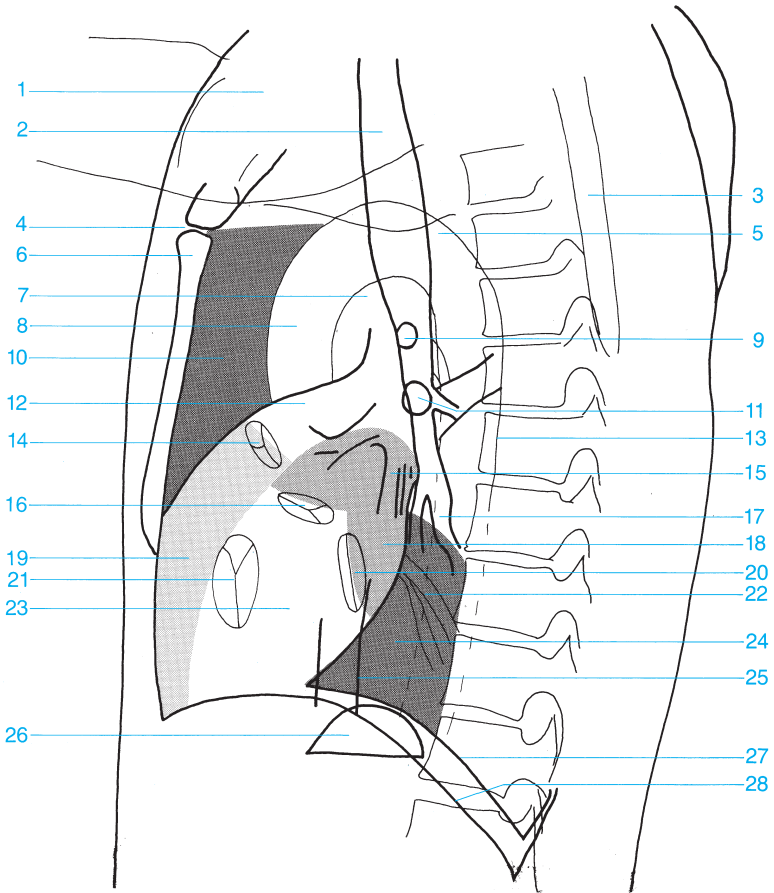




- |   |   |
|---|---|
| <b>1</b> Contour of the right brachiocephalic vein        | <b>11</b> Inferior lobar branch of the pulmonary artery |
| <b>2</b> Contour of the subclavian artery                 | <b>12</b> Pulmonary valve                               |
| <b>3</b> Subclavian and aortic arches                     | <b>13</b> Left atrium                                   |
| <b>4</b> Aortic arch                                      | <b>14</b> Aortic valve                                  |
| <b>5</b> Azygos vein                                      | <b>15</b> Venous confluence                             |
| <b>6</b> Superior vena cava                               | <b>16</b> Mitral valve                                  |
| <b>7</b> Main pulmonary artery                            | <b>17</b> Right atrium                                  |
| <b>8</b> Right pulmonary artery                           | <b>18</b> Tricuspid valve                               |
| <b>9</b> Left pulmonary artery                            | <b>19</b> Left ventricle                                |
| <b>10</b> Intermediate part of the right pulmonary artery | <b>20</b> Inferior vena cava                            |
|   | <b>21</b> Right ventricle                               |

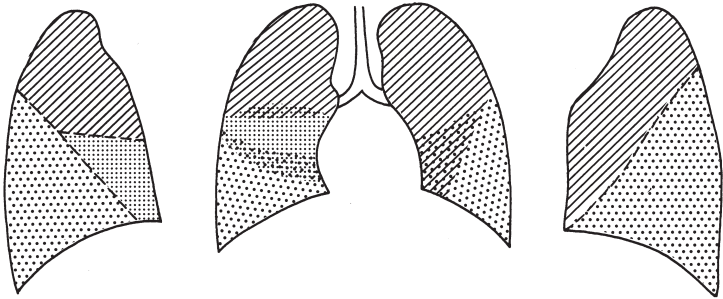
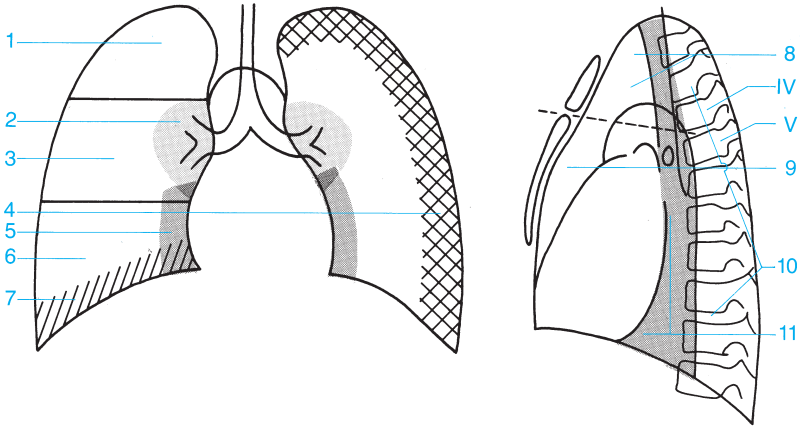


- |                                |                             |
|--------------------------------|-----------------------------|
| 1 Soft tissues of the shoulder | 10 Retrosternal space       |
| 2 Trachea                      | 11 Left upper lobe bronchus |
| 3 Scapula                      | 12 Main pulmonary artery    |
| 4 Sternal angle                | 13 Descending aorta         |
| 5 Aortic arch                  | 14 Pulmonary valve          |
| 6 Body of the sternum          | 15 Pulmonary veins          |
| 7 Aortopulmonary window        | 16 Aortic valve             |
| 8 Ascending aorta              | 17 Lower lobe bronchus      |
| 9 Right upper lobe bronchus    | 18 Left atrium              |



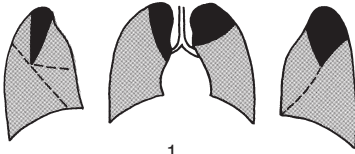
**19** Right ventricle  
**20** Mitral valve  
**21** Tricuspid valve  
**22** Pulmonary veins  
**23** Left ventricle  
**24** Retrocardiac space

**25** Inferior vena cava  
**26** Gastric bubble  
**27** Left hemidiaphragm (tangent to the gastric bubble and ending in the shadow of the heart)  
**28** Right hemidiaphragm

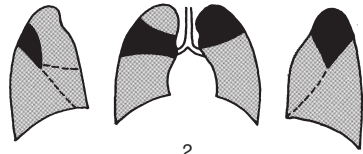


 Upper Lobe     
  Middle Lobe     
  Lower Lobe

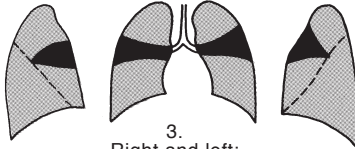
- 1 Upper region of the lung
- 2 Perihilar region
- 3 Middle region of the lung
- 4 Chest wall
- 5 Pericardial region
- 6 Lower region of the lung
- 7 Supradiaphragmatic region
- 8 Superior anterior mediastinum
- 9 Inferior anterior mediastinum
- 10 Posterior mediastinum
- 11 Middle mediastinum (fourth and fifth thoracic vertebrae)



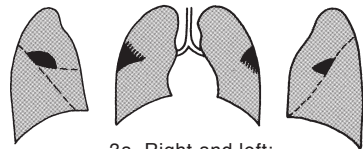
1.  
Right: apical segment of the upper lobe  
Left: apical posterior segment of the upper lobe



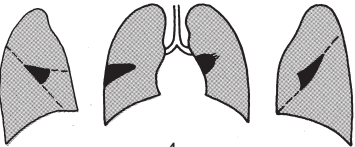2.  
Right: posterior segment of the upper lobe  
Left: apical posterior segment of the upper lobe



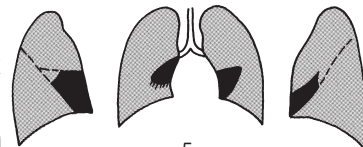
3.  
Right and left:  
anterior segment of the upper lobe



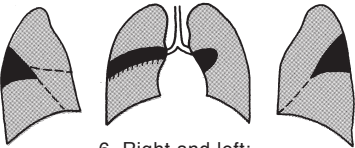
3a. Right and left:  
axillary subsegment



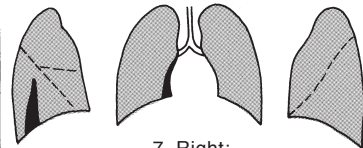
4.  
Right: lateral segment of the middle lobe  
Left: superior lingular segment



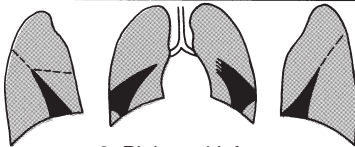
5.  
Right medial segment of the middle lobe  
Left: inferior lingular segment



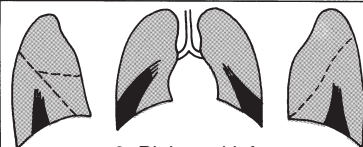
6. Right and left:  
superior segment of the lower lobe



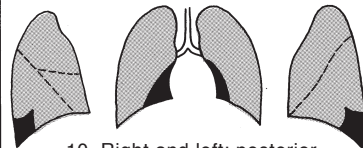7. Right:  
medial segment of the lower lobe



8. Right and left:  
anterior basal segment of the lower lobe



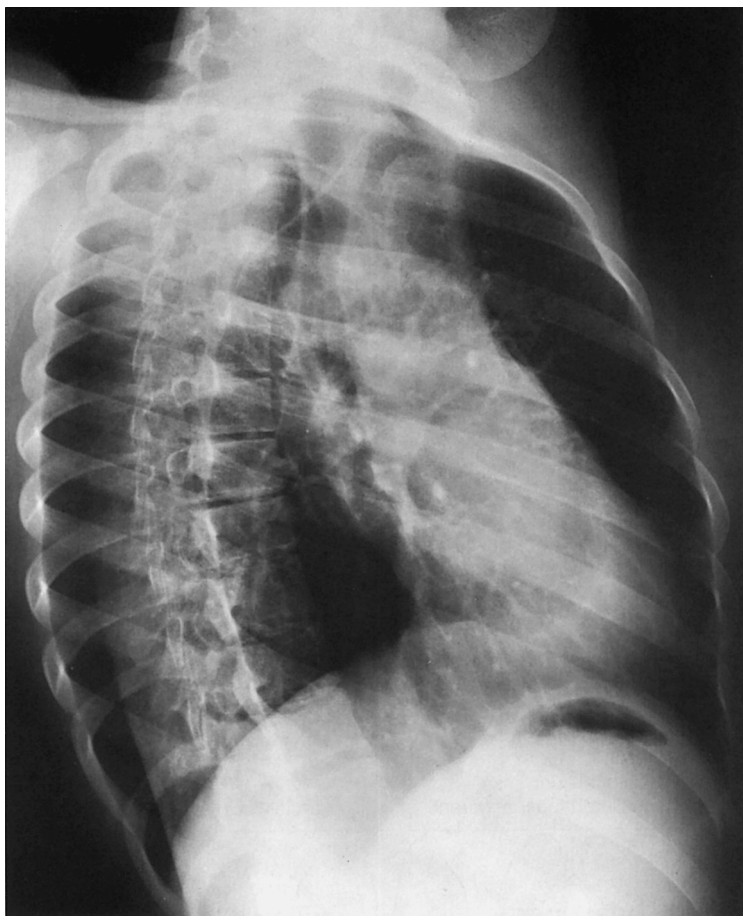9. Right and left:  
lateral basal segment of the lower lobe

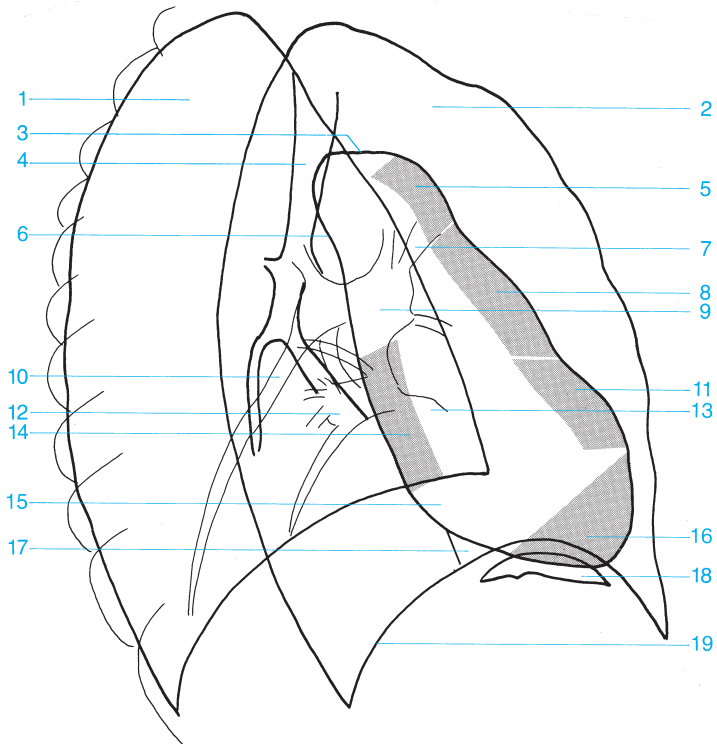


10. Right and left:  
posterior basal segment of the lower lobe

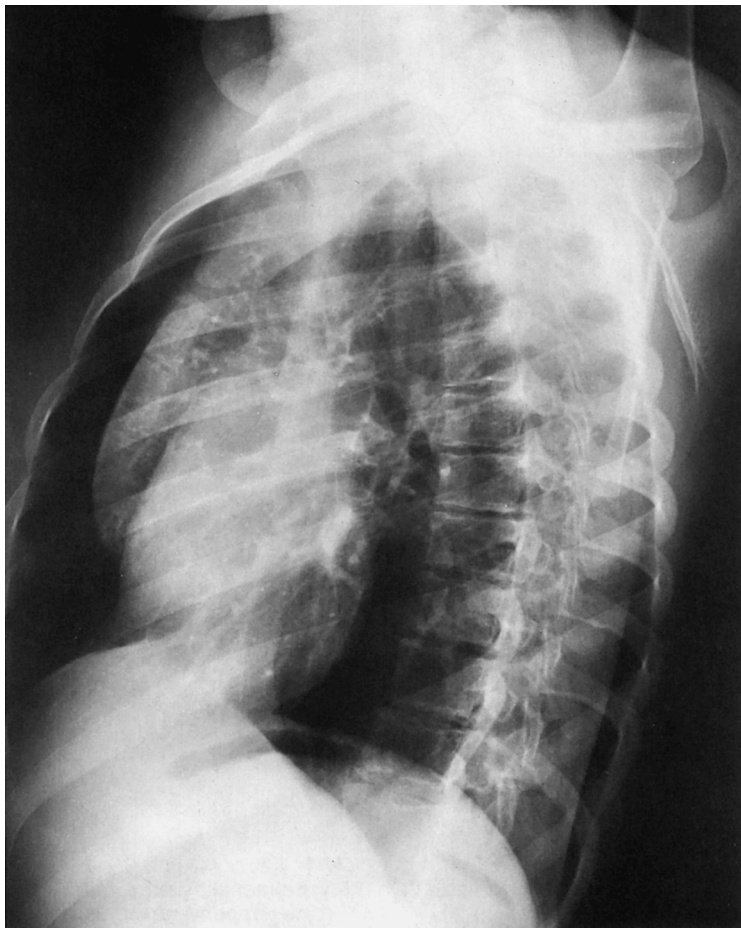Segments of the lung

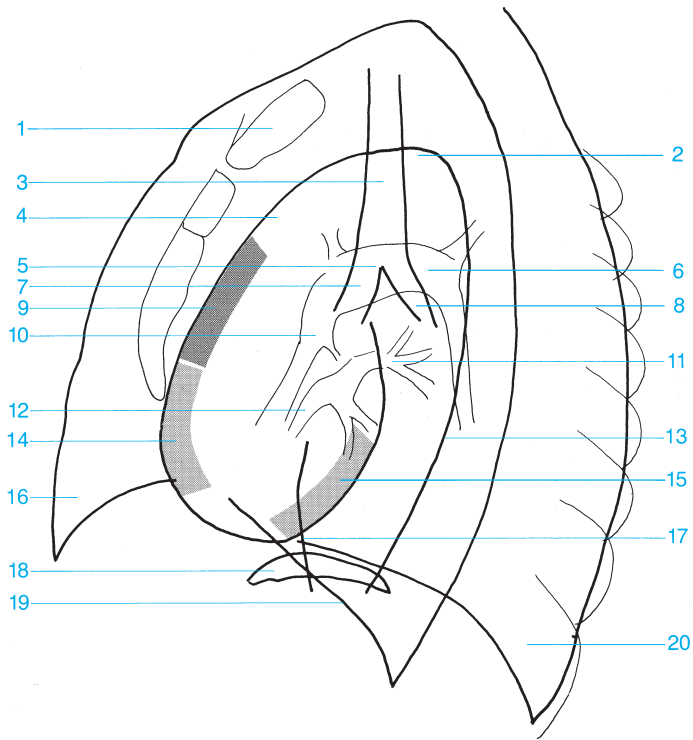




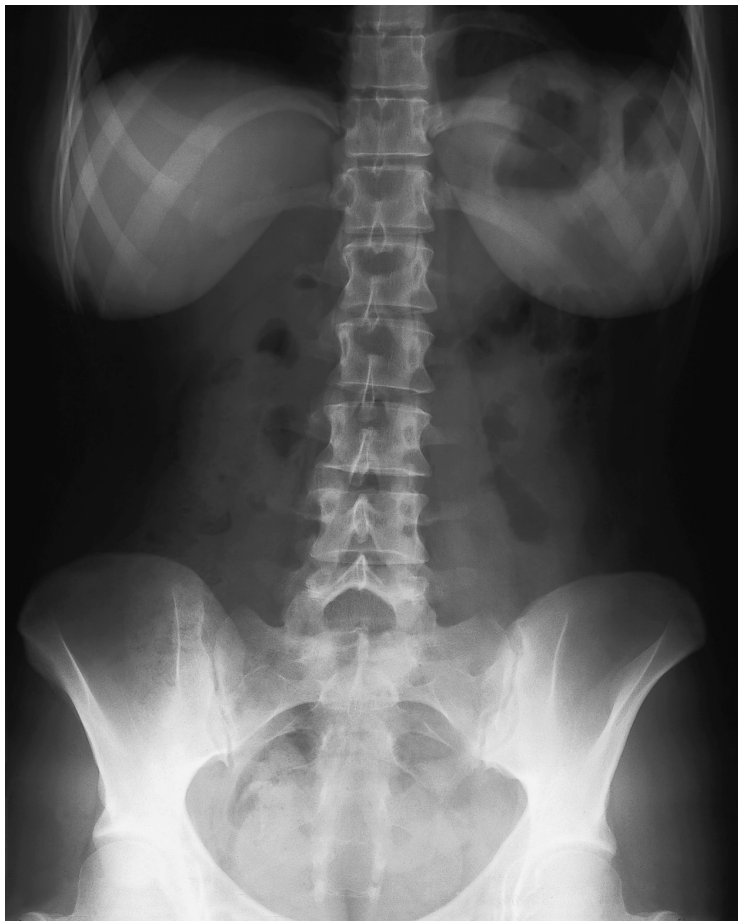


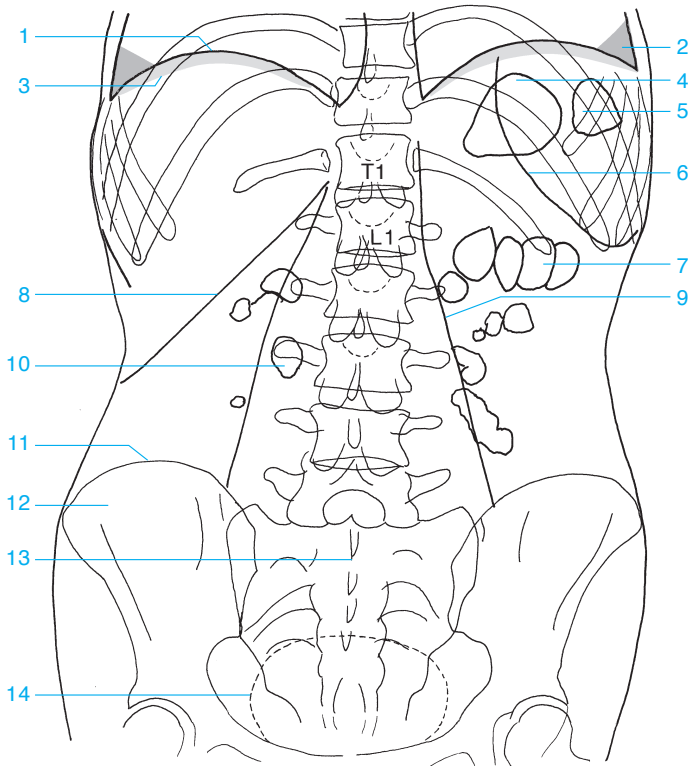
- |    |  |    |                               |
|----|--|----|-------------------------------|
| 1  | Right lung   | 11 | Infundibulum                  |
| 2  | Left lung  | 12 | Inferior right pulmonary vein |
| 3  | Aortic arch  | 13 | Inferior left pulmonary vein  |
| 4  | Trachea  | 14 | Left atrium                   |
| 5  | Ascending aorta                                      | 15 | Right atrium                  |
| 6  | Descending aorta                                     | 16 | Left ventricle                |
| 7  | Left upper lobe pulmonary vein, artery, and bronchus | 17 | Inferior vena cava            |
| 8  | Main pulmonary artery                                | 18 | Gastric bubble                |
| 9  | Left pulmonary artery                                | 19 | Diaphragm                     |
| 10 | Right inferior lobar branch of the pulmonary artery  |    |                               |



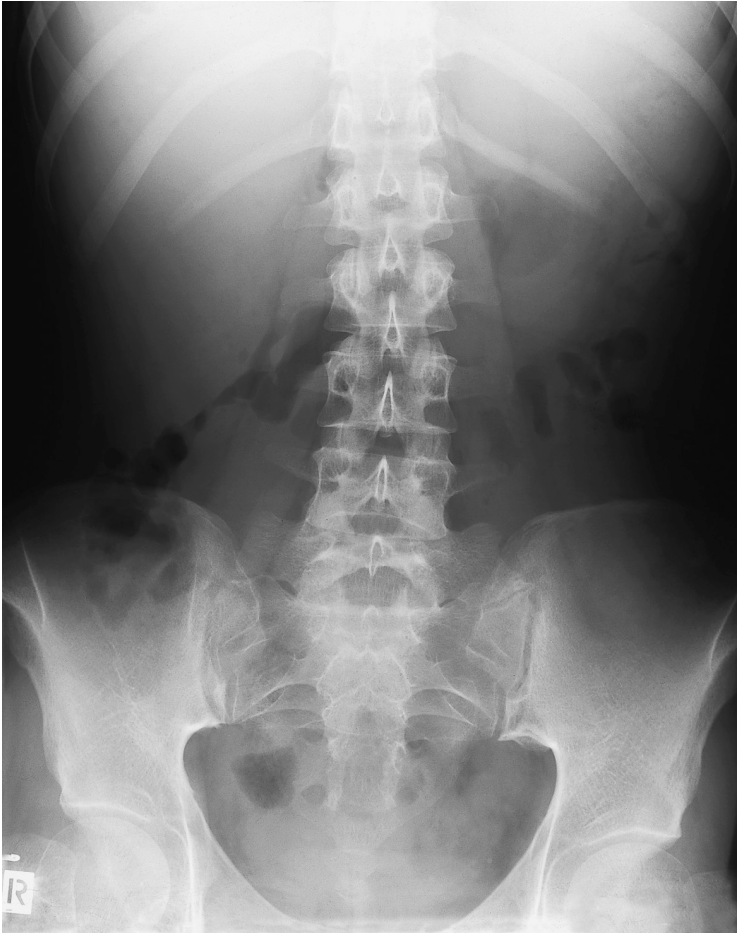


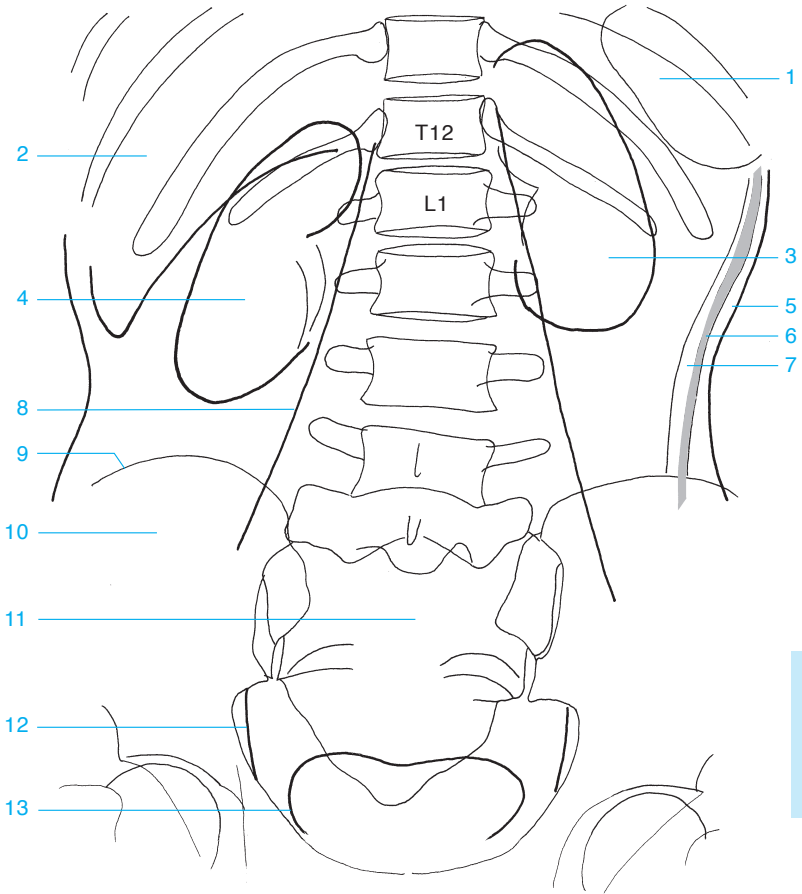
- |                                  |   |
|----------------------------------|---|
| <b>1</b> Sternum                 | <b>12</b> Right pulmonary vein                |
| <b>2</b> Aortic arch             | <b>13</b> Descending aorta                    |
| <b>3</b> Trachea                 | <b>14</b> Right ventricle                     |
| <b>4</b> Ascending aorta         | <b>15</b> Left ventricle                      |
| <b>5</b> Carina of the trachea   | <b>16</b> Right lung                          |
| <b>6</b> Left pulmonary artery   | <b>17</b> Inferior vena cava                  |
| <b>7</b> Right main bronchus     | <b>18</b> Gastric bubble (left hemidiaphragm) |
| <b>8</b> Left main bronchus      | <b>19</b> Right hemidiaphragm                 |
| <b>9</b> Right atrium            | <b>20</b> Left lung                           |
| <b>10</b> Right pulmonary artery |   |
| <b>11</b> Left pulmonary vein    |   |





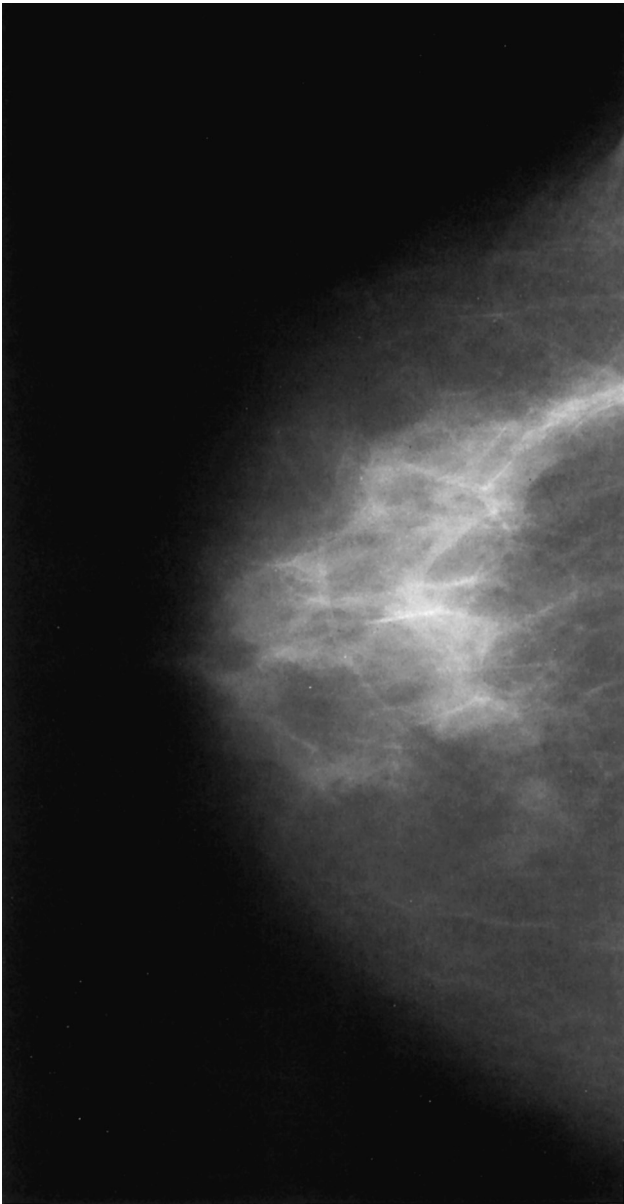
- |  |                                |
|--|--------------------------------|
| 1 Diaphragm                                      | 7 Gas in the transverse colon  |
| 2 Costodiaphragmatic recess (costophrenic angle) | 8 Inferior margin of the liver |
| 3 Subphrenic space                               | 9 Margin of the psoas          |
| 4 Gastric bubble                                 | 10 Gas in the small bowel      |
| 5 Gas in the splenic flexure of the colon        | 11 Iliac crest                 |
| 6 Lower margin of the spleen                     | 12 Ilium                       |
|  | 13 Sacrum                      |
|  | 14 Urinary bladder             |

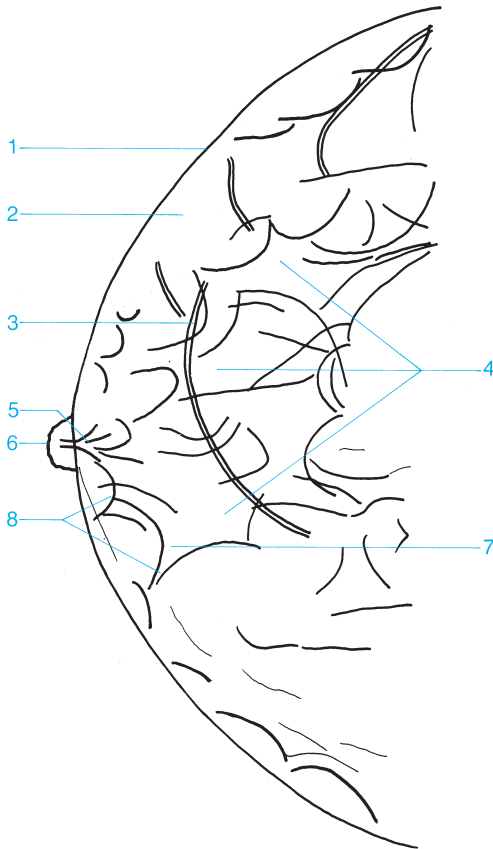




- |                     |                       |
|---------------------|-----------------------|
| 1 Spleen            | 8 Psoas               |
| 2 Liver             | 9 Iliac crest         |
| 3 Left kidney       | 10 Ilium              |
| 4 Right kidney      | 11 Sacrum             |
| 5 Subcutaneous fat  | 12 Obturator internus |
| 6 Abdominal muscles | 13 Urinary bladder    |
| 7 Preperitoneal fat |                       |

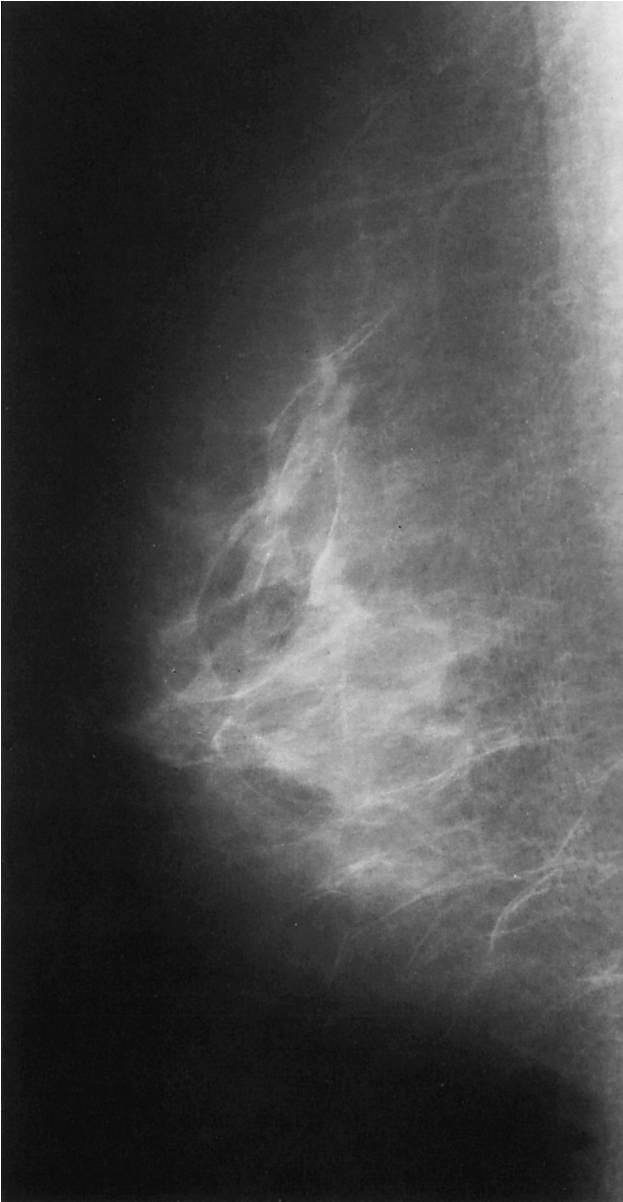

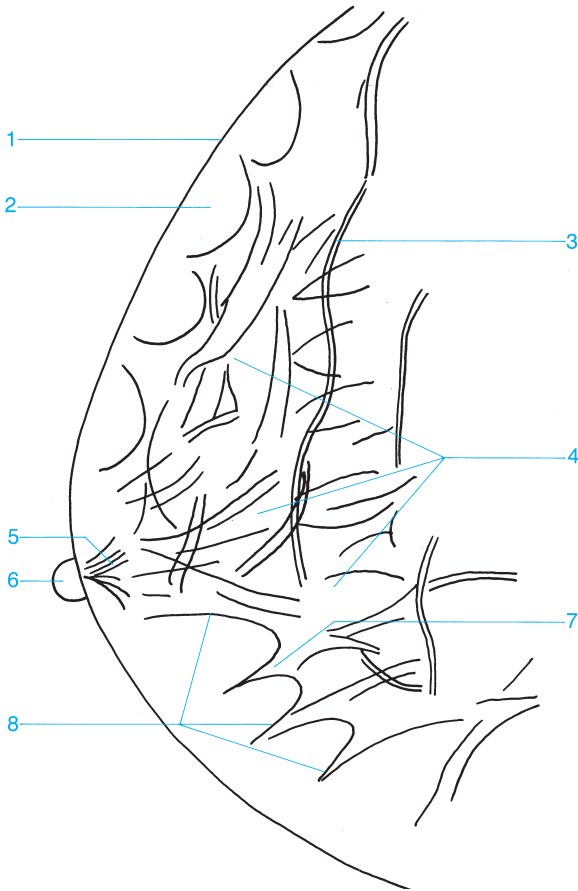




- 1 Skin
- 2 Subcutaneous fat
- 3 Veins
- 4 Glandular tissue

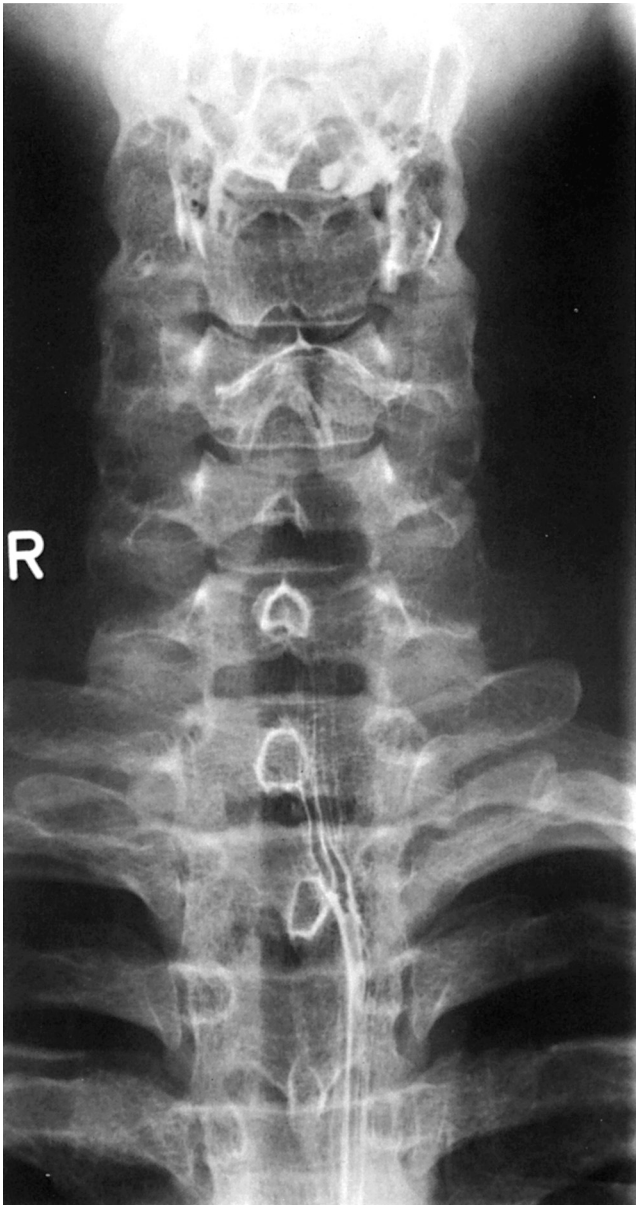
- 5 Lactiferous duct posterior to the nipple
- 6 Nipple
- 7 Contour of a lobule
- 8 Cooper's ligaments

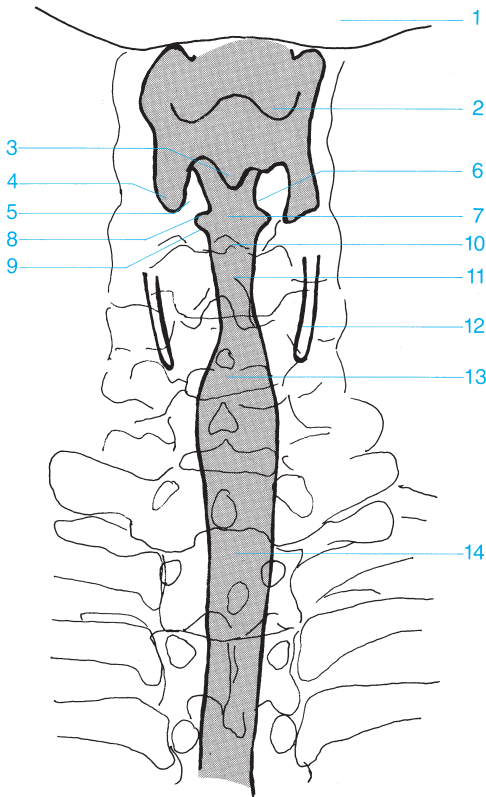




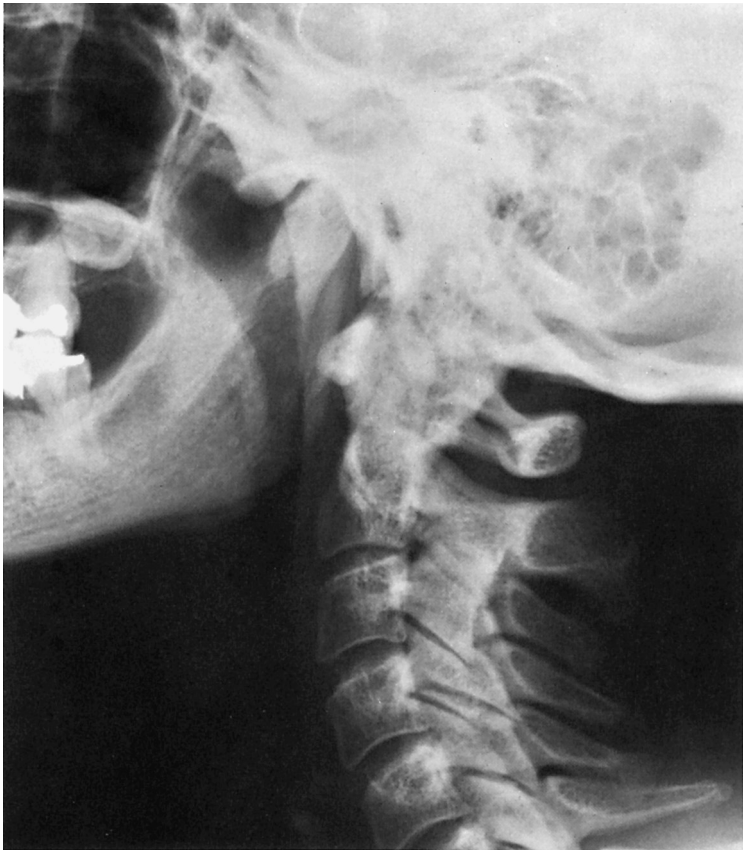- 1 Skin
- 2 Subcutaneous fat
- 3 Veins
- 4 Glandular tissue

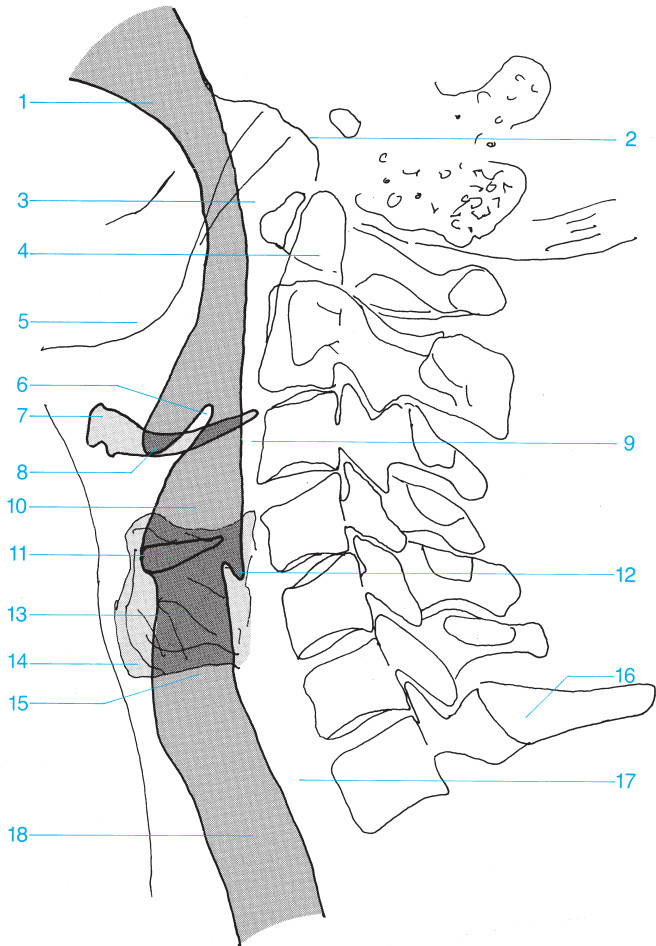
- 5 Lactiferous duct posterior to the nipple
- 6 Nipple
- 7 Contour of a lobule
- 8 Cooper's ligaments





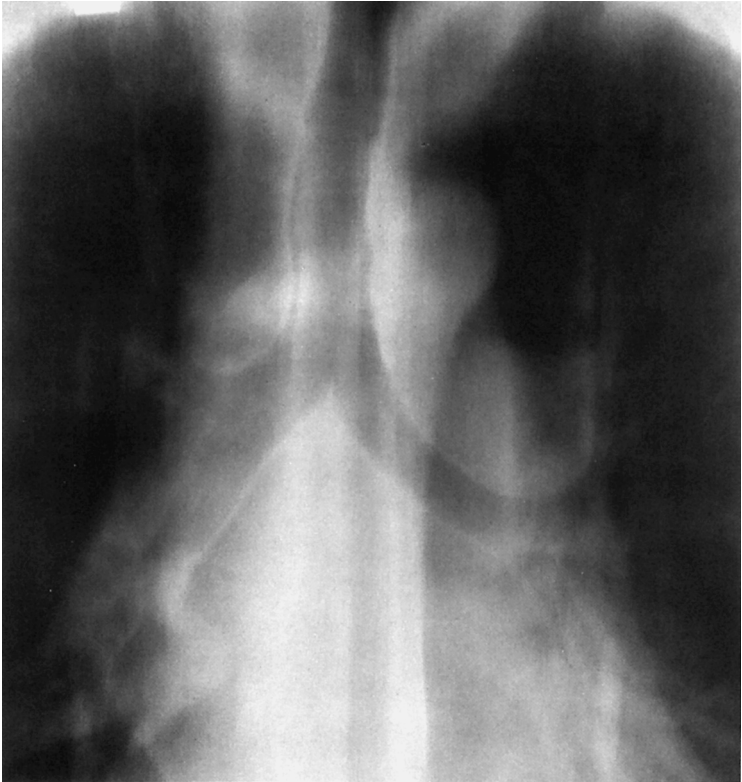
- |                                      |                                |
|--------------------------------------|--------------------------------|
| 1 Mandible                           | 8 Ventricle of the larynx      |
| 2 Floor of the vallecula             | 9 Vocal fold (true vocal cord) |
| 3 Interarytenoid notch               | 10 Rima glottidis              |
| 4 Piriform recess                    | 11 Subglottic space            |
| 5 Arytenoid cartilages               | 12 Thyroid cartilage           |
| 6 Vestibular fold (false vocal cord) | 13 Proximal trachea            |
| 7 Vestibule of the larynx            | 14 Distal trachea              |

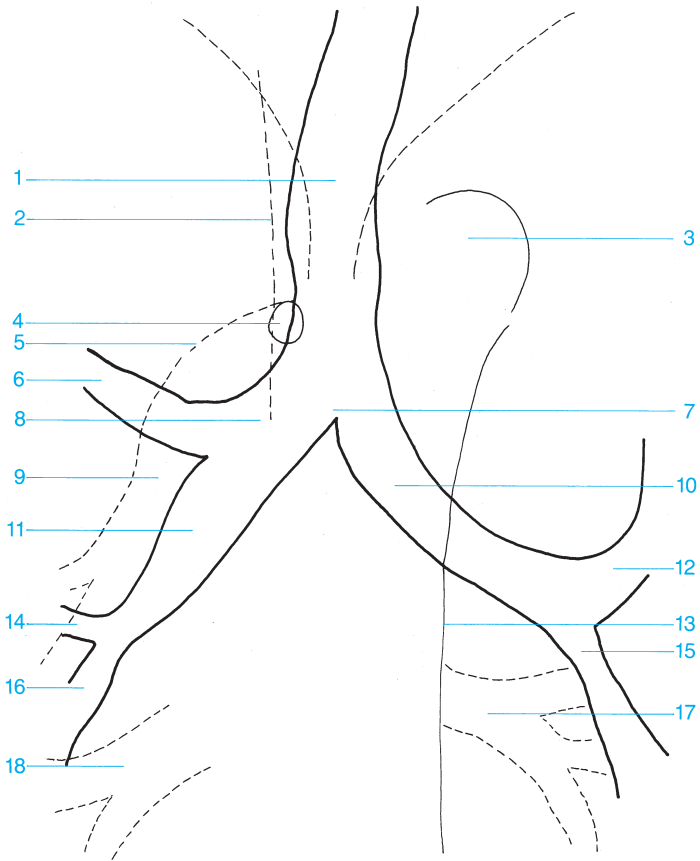




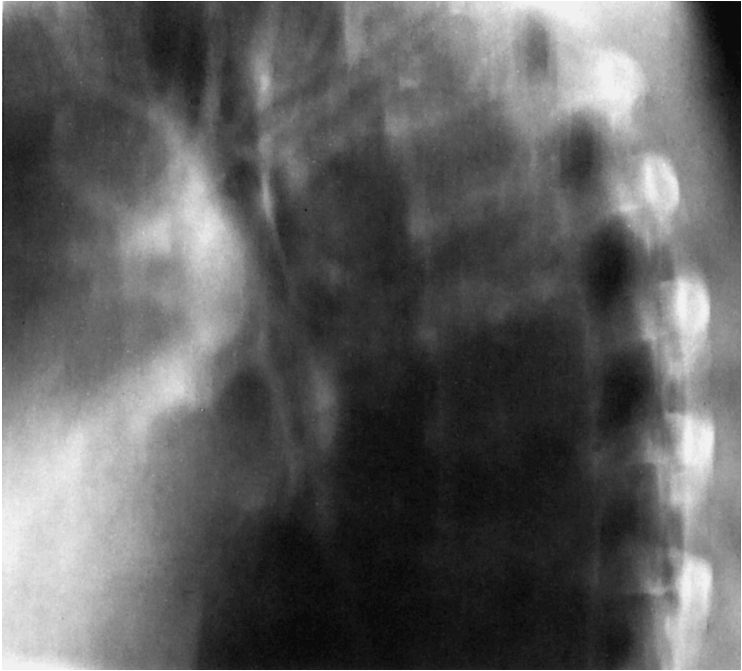- |                            |   |
|----------------------------|---|
| 1 Oral cavity              | 11 Ventricle of the larynx                          |
| 2 Base of the skull        | 12 Inferior posterior margin of the piriform recess |
| 3 Posterior nasopharynx    | 13 Subglottic space                                 |
| 4 Dens of the axis         | 14 Thyroid cartilage                                |
| 5 Mandible                 | 15 Proximal trachea                                 |
| 6 Epiglottis               | 16 Vertebra C7                                      |
| 7 Hyoid bone               | 17 Esophagus  |
| 8 Floor of the vallecula   | 18 Distal trachea                                   |
| 9 Retropharyngeal space    |   |
| 10 Vestibule of the larynx |   |

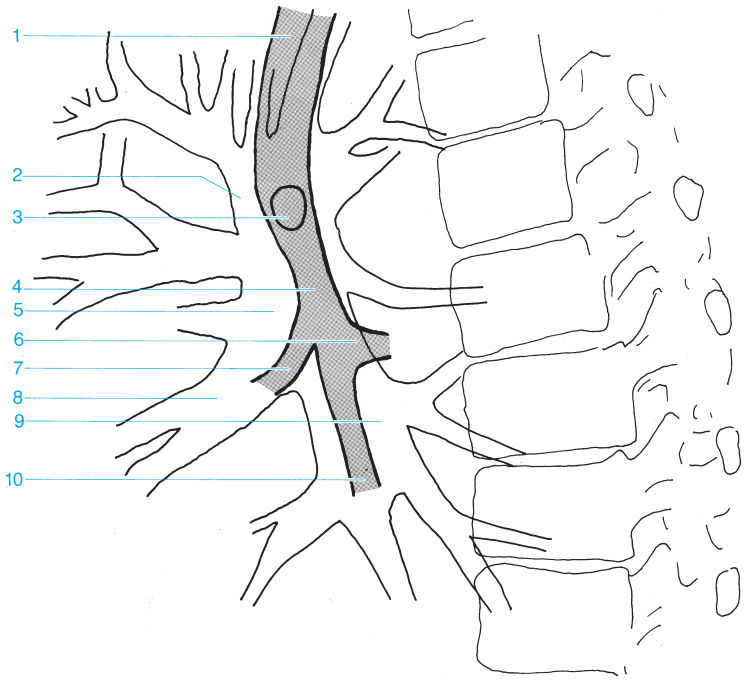




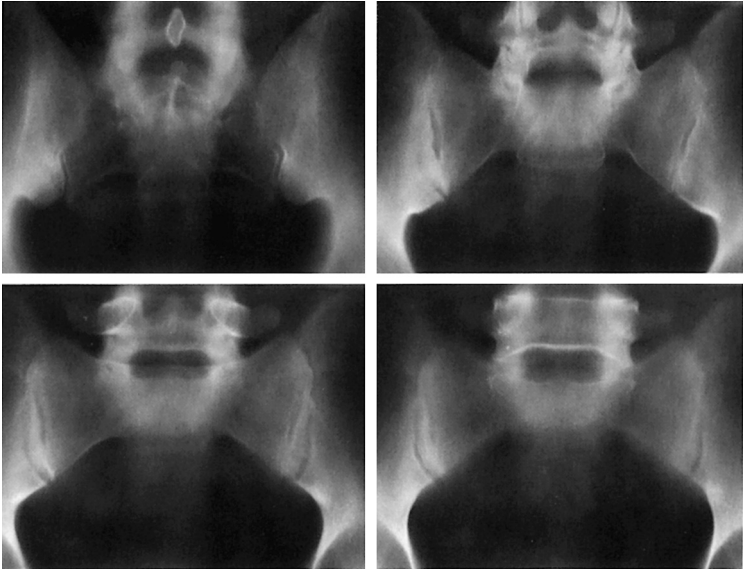


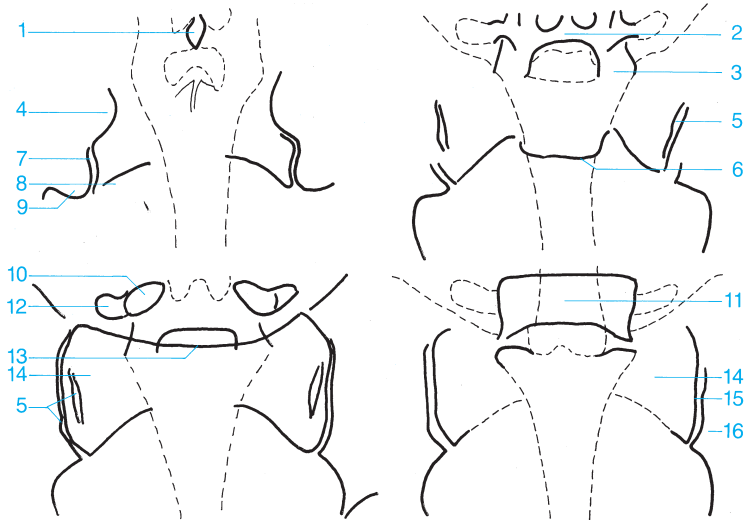
- |  |                                     |
|--|-------------------------------------|
| <b>1</b> Trachea                                       | <b>10</b> Left main bronchus        |
| <b>2</b> Superior vena cava                            | <b>11</b> Intermediate bronchus     |
| <b>3</b> Aortic arch                                   | <b>12</b> Left upper lobe bronchus  |
| <b>4</b> Azygos vein                                   | <b>13</b> Descending aorta          |
| <b>5</b> Right pulmonary artery                        | <b>14</b> Middle lobe bronchus      |
| <b>6</b> Right upper lobe bronchus                     | <b>15</b> Left lower lobe bronchus  |
| <b>7</b> Bifurcation of the trachea                    | <b>16</b> Right lower lobe bronchus |
| <b>8</b> Right main bronchus                           | <b>17</b> Pulmonary veins           |
| <b>9</b> Inferior lobar branch of the pulmonary artery | <b>18</b> Venous confluence         |





- |  |  |
|--|--|
| <b>1</b> Trachea                                       | <b>7</b> Middle lobe bronchus                          |
| <b>2</b> Superior lobar branch of the pulmonary artery | <b>8</b> Middle lobar branch of the pulmonary artery   |
| <b>3</b> Origin of the upper lobe bronchus             | <b>9</b> Inferior lobar branch of the pulmonary artery |
| <b>4</b> Intermediate bronchus                         | <b>10</b> Lower lobe bronchus                          |
| <b>5</b> Right pulmonary artery                        |  |
| <b>6</b> Segmental bronchus of the lower lobe          |  |





- |   |  |
|---|--|
| 1 Spinous process                                   | 9 Posterior inferior iliac spine           |
| 2 Lamina  | 10 Pedicle                                 |
| 3 Inferior articular process                        | 11 L5                                      |
| 4 Posterior superior iliac spine                    | 12 Transverse process                      |
| 5 Middle portion of the sacroiliac joint            | 13 Promontory                              |
| 6 Anterior aspect of the sacrum                     | 14 Sacral ala                              |
| 7 Posterior inferior aspect of the sacroiliac joint | 15 Anterior aspect of the sacroiliac joint |
| 8 Sacral foramina                                   | 16 Ilium (iliac wing)                      |

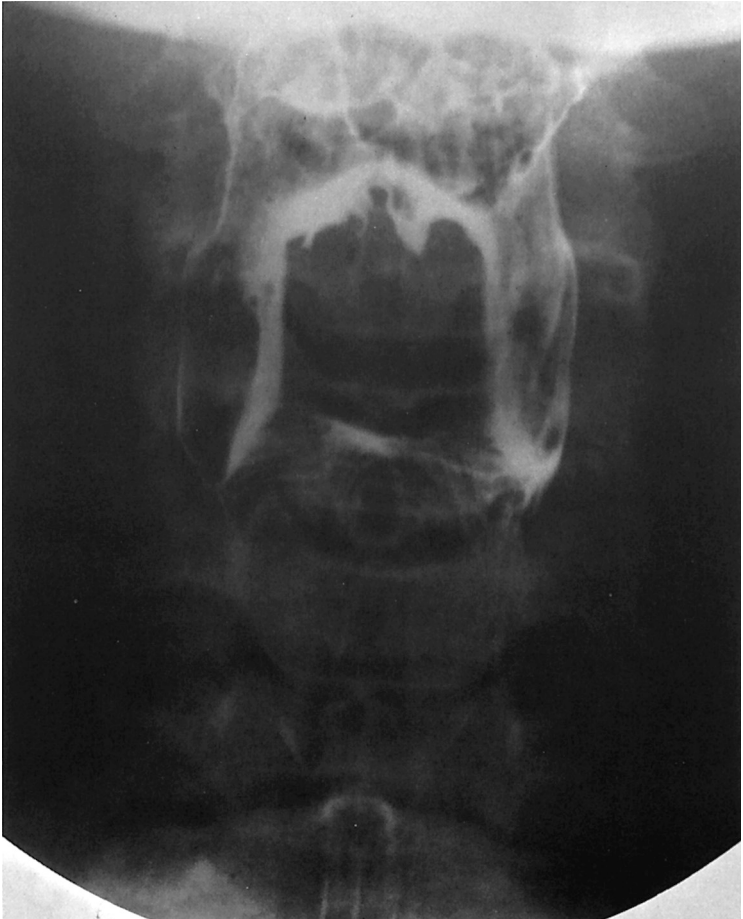

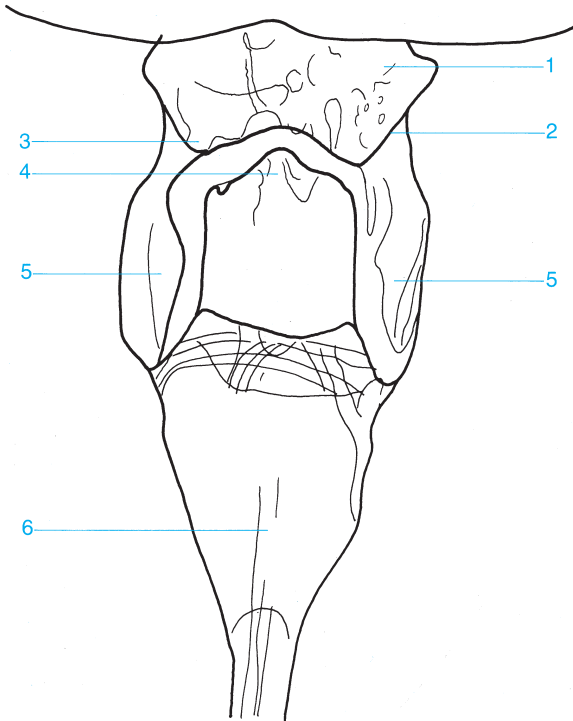
---

## Contrast Studies

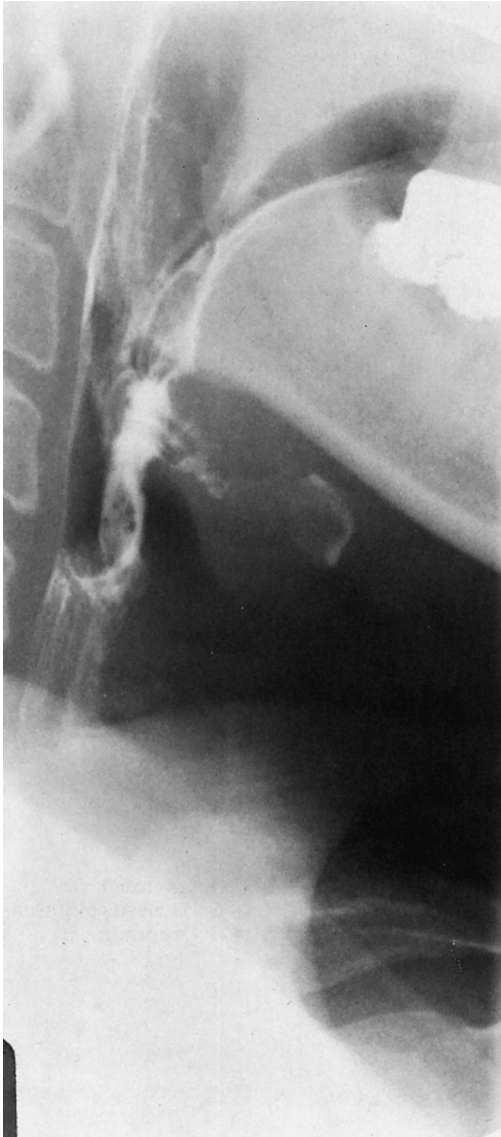---

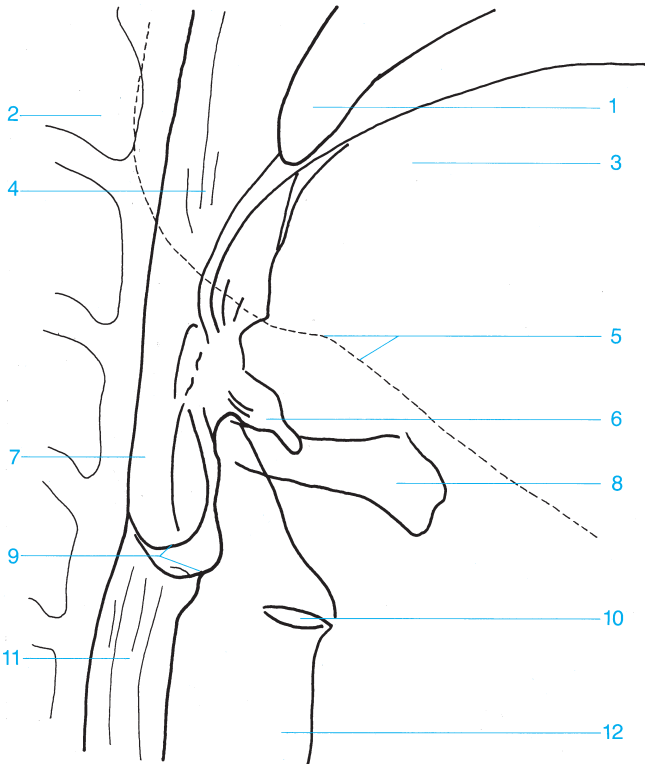






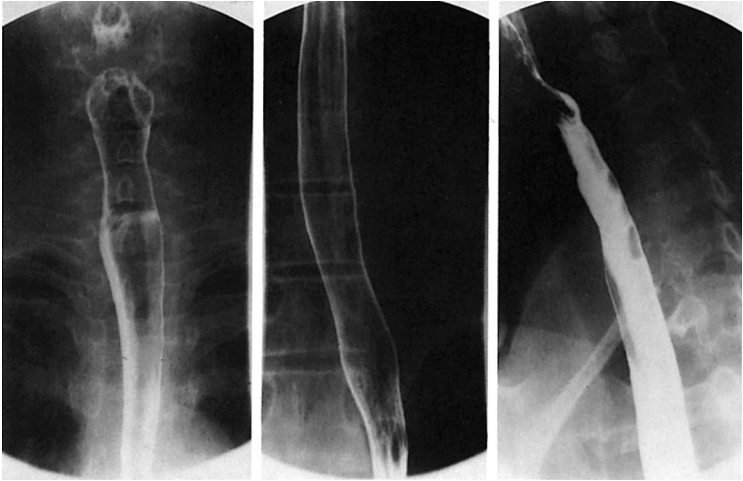- |                                 |                   |
|---------------------------------|-------------------|
| 1 Pharynx                       | 4 Epiglottis      |
| 2 Lateral glossoepiglottic fold | 5 Piriform recess |
| 3 Vallecula                     | 6 Esophagus       |

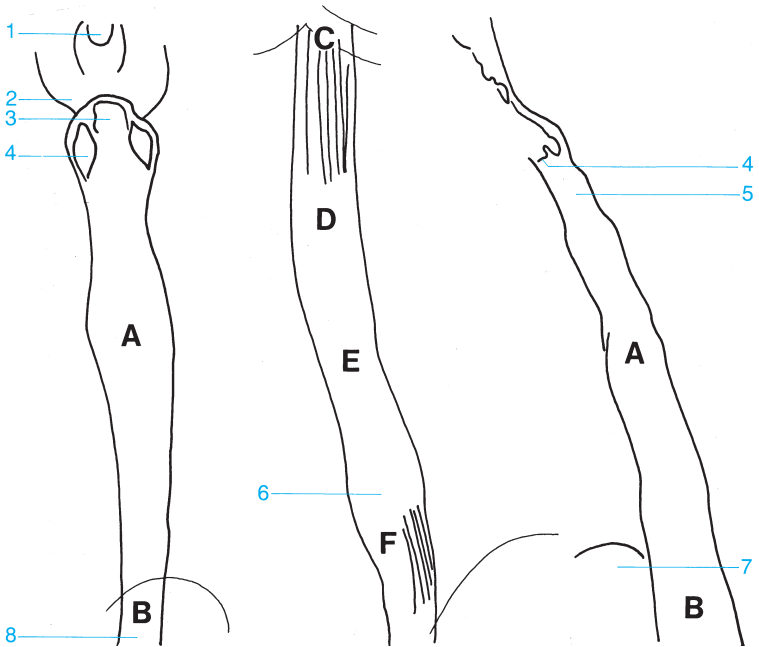




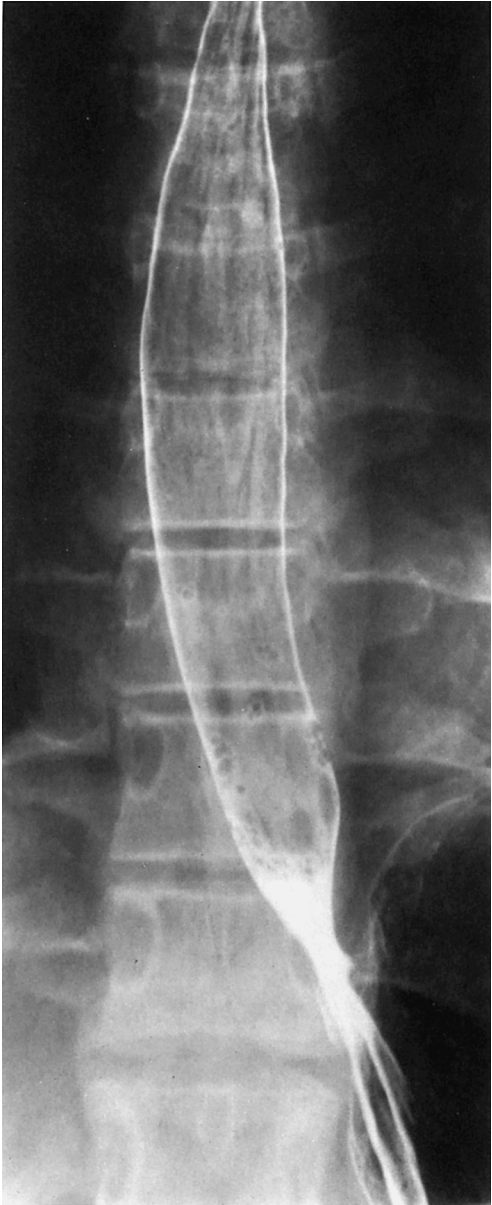- 1 Uvula
- 2 Cervical spine (axis)
- 3 Tongue
- 4 Oropharynx
- 5 Mandible
- 6 Vallecula

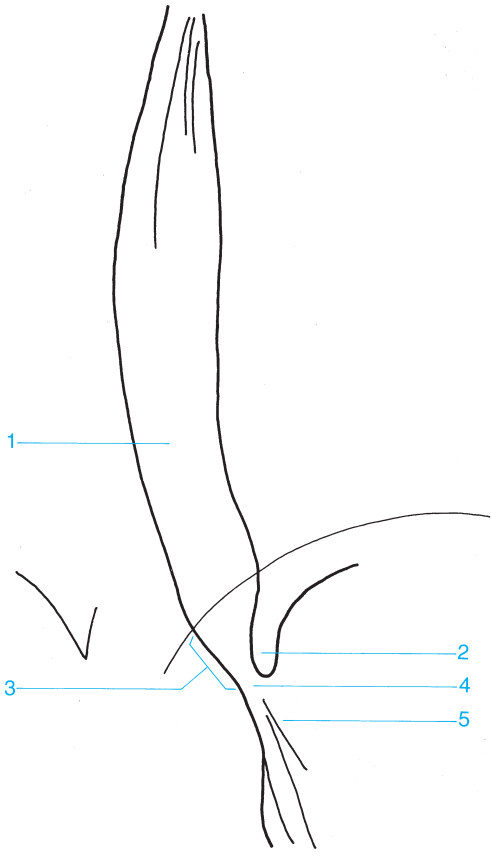
- 7 Larynx
- 8 Hyoid bone
- 9 Piriform recess
- 10 Ventricle of the larynx
- 11 Esophagus
- 12 Trachea





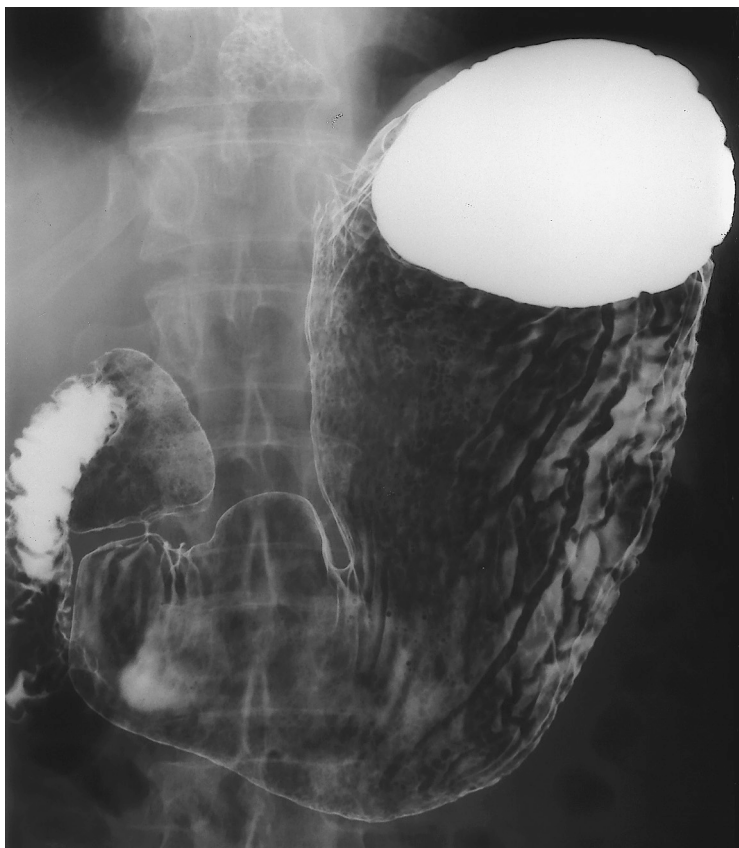- |                                 |                          |
|---------------------------------|--------------------------|
| 1 Uvula                         | A Paratracheal segment   |
| 2 Lateral glossoepiglottic fold | B Aortic segment         |
| 3 Epiglottis                    | C Bronchial segment      |
| 4 Piriform recess               | D Interbronchial segment |
| 5 Upper esophageal sphincter    | E Retrocardiac segment   |
| 6 Body of the esophagus         | F Epiphrenic segment     |
| 7 Aortic arch                   |                          |
| 8 Bronchial and aortic segment  |                          |

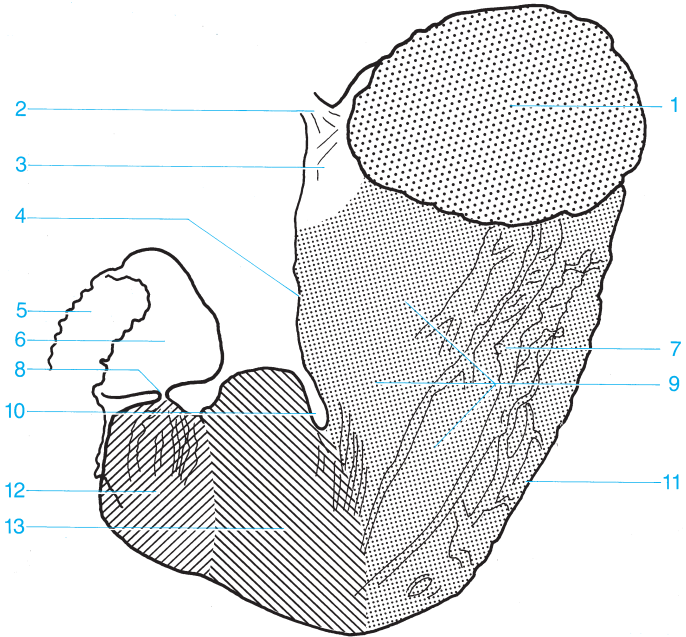




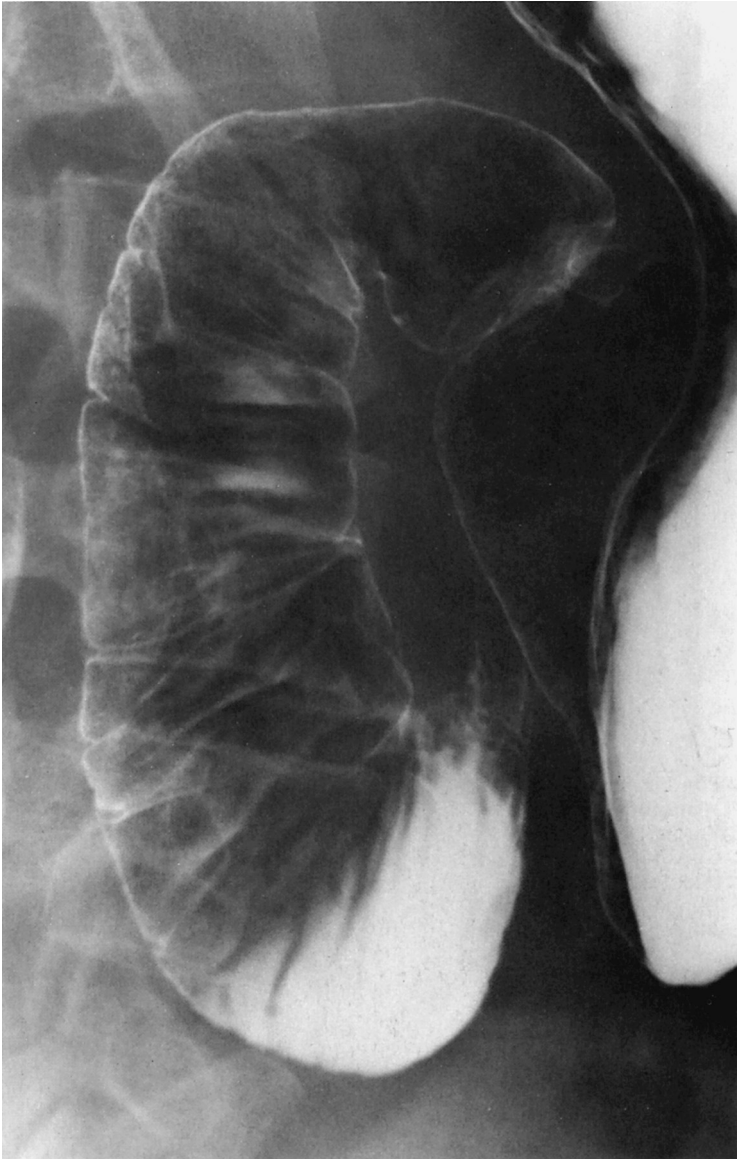
- 1 Distal esophagus
- 2 Gastroesophageal angle
- 3 Abdominal esophagus
- 4 Esophageal hiatus
- 5 Cardia

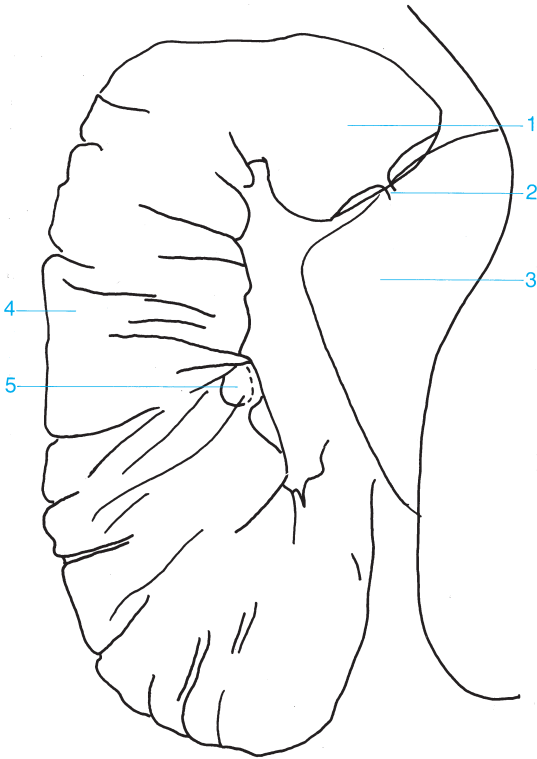






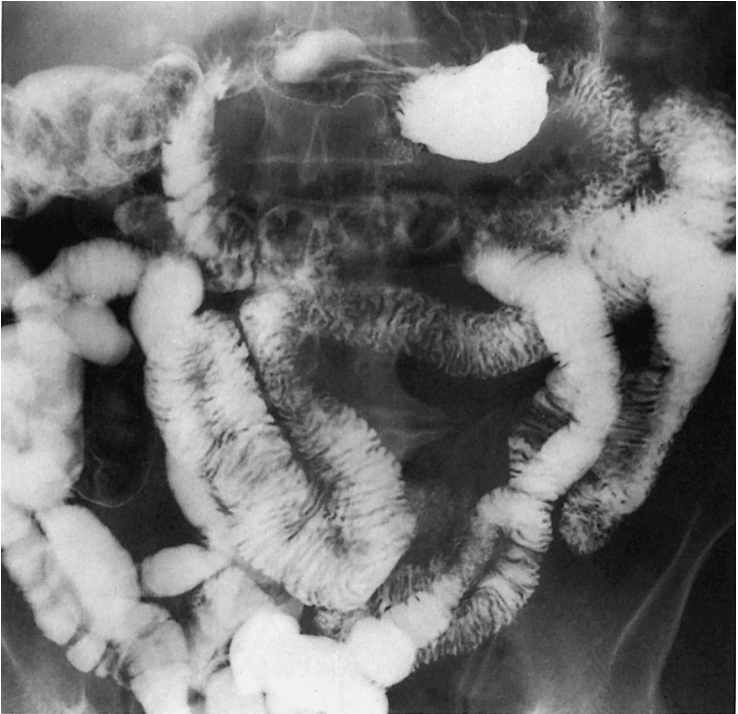- |                                  |                       |
|----------------------------------|-----------------------|
| 1 Fundus                         | 8 Pylorus             |
| 2 Abdominal esophagus            | 9 Body of the stomach |
| 3 Cardia                         | 10 Angular notch      |
| 4 Lesser curvature               | 11 Greater curvature  |
| 5 Duodenum                       | 12 Pyloric antrum     |
| 6 Ampulla of Vater               | 12 + 13 Antrum        |
| 7 Gastric folds (posterior wall) |                       |

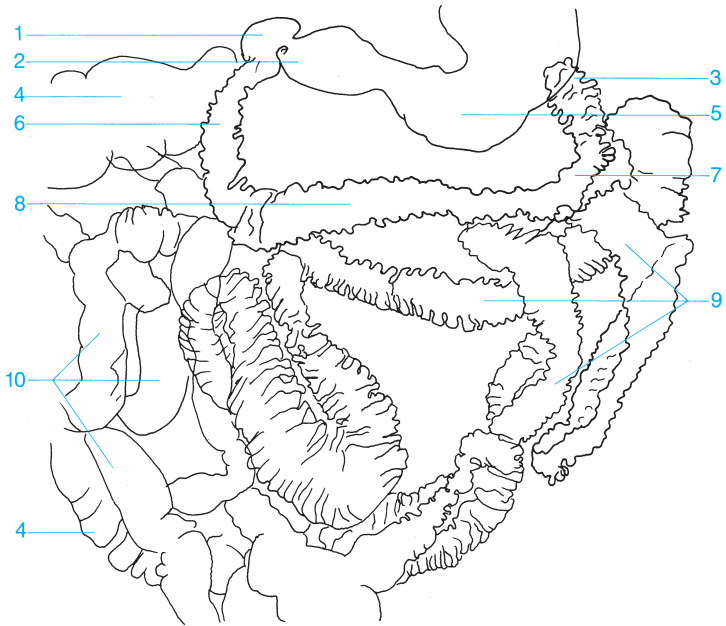




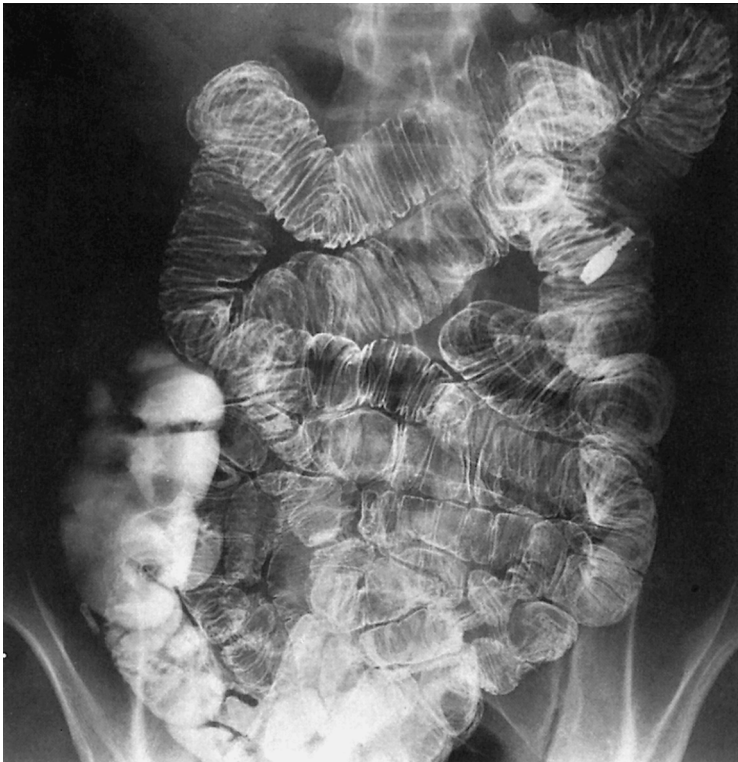- 1** Ampulla of Vater
- 2** Pylorus
- 3** Pyloric antrum

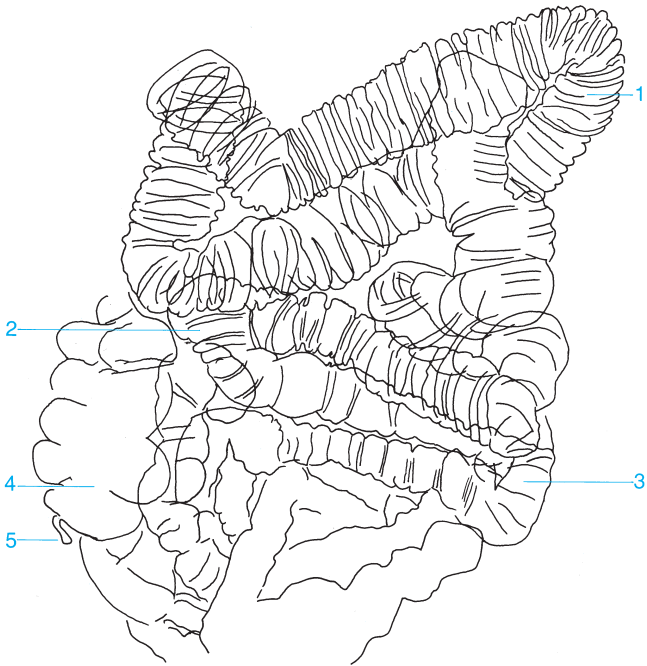
- 4** Descending duodenum
- 5** Papilla of Vater





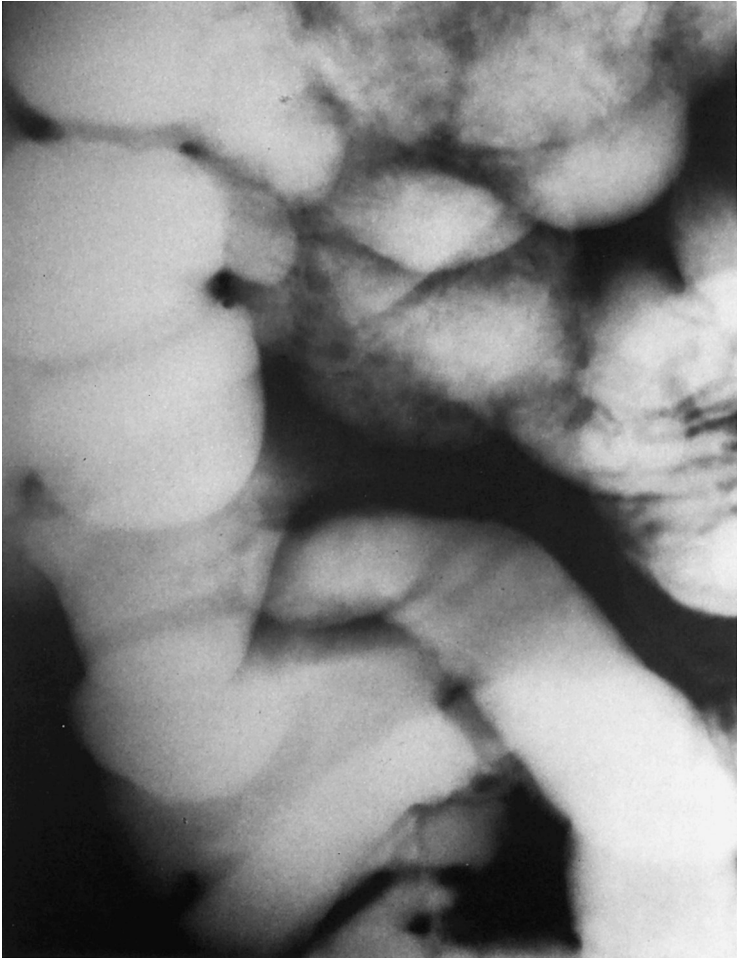- |                                 |                                      |
|---------------------------------|--------------------------------------|
| <b>1</b> Ampulla of Vater       | <b>6</b> Descending duodenum         |
| <b>2</b> Pyloric antrum         | <b>7</b> Ascending duodenum          |
| <b>3</b> Duodenojejunal flexure | <b>8</b> Horizontal part of duodenum |
| <b>4</b> Colon                  | <b>9</b> Jejunum                     |
| <b>5</b> Body of the stomach    | <b>10</b> Ileum                      |

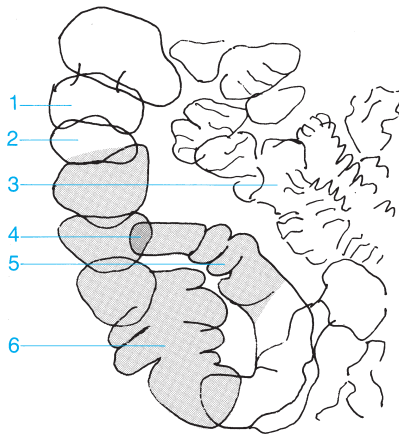




- |  |                   |
|--|-------------------|
| <b>1</b> Jejunum                           | <b>4</b> Cecum    |
| <b>2</b> Junction of the ileum and jejunum | <b>5</b> Appendix |
| <b>3</b> Ileum                             |                   |

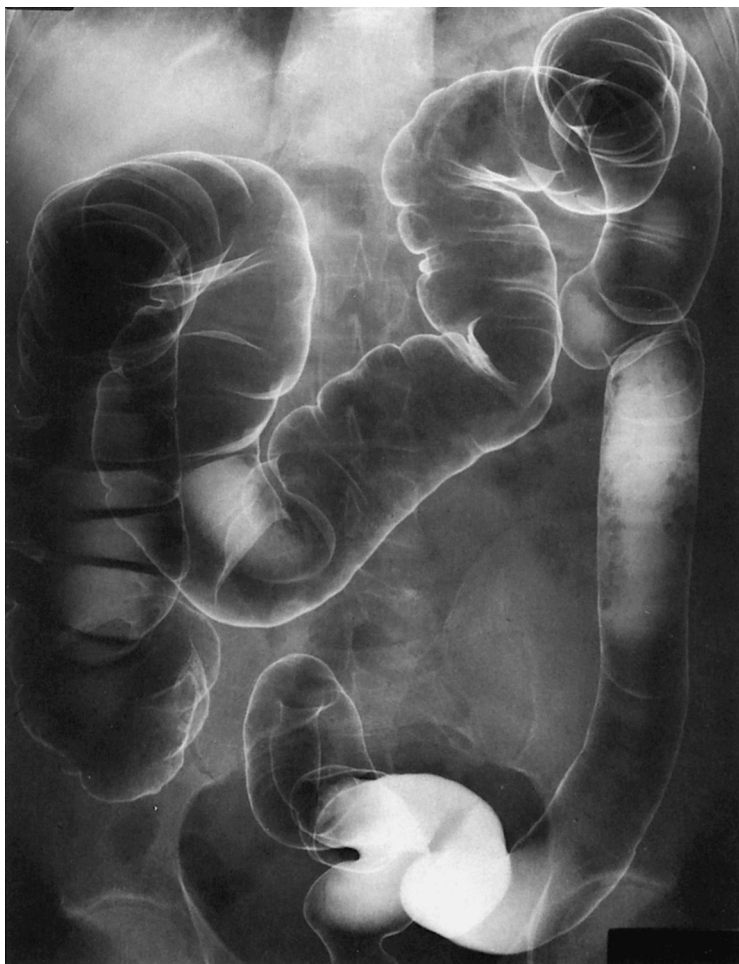

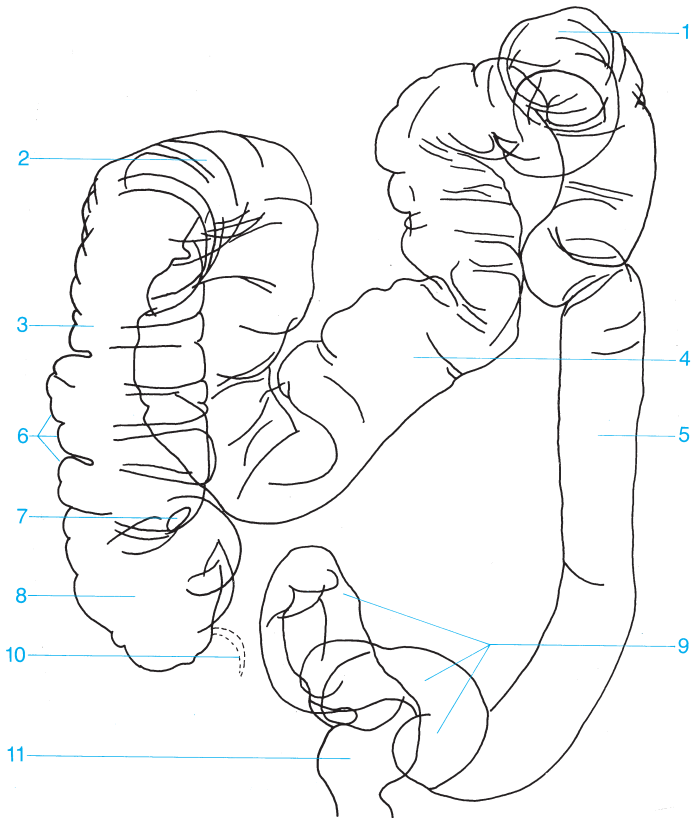




- 1 Haustra of the colon
- 2 Ascending colon
- 3 Ileum

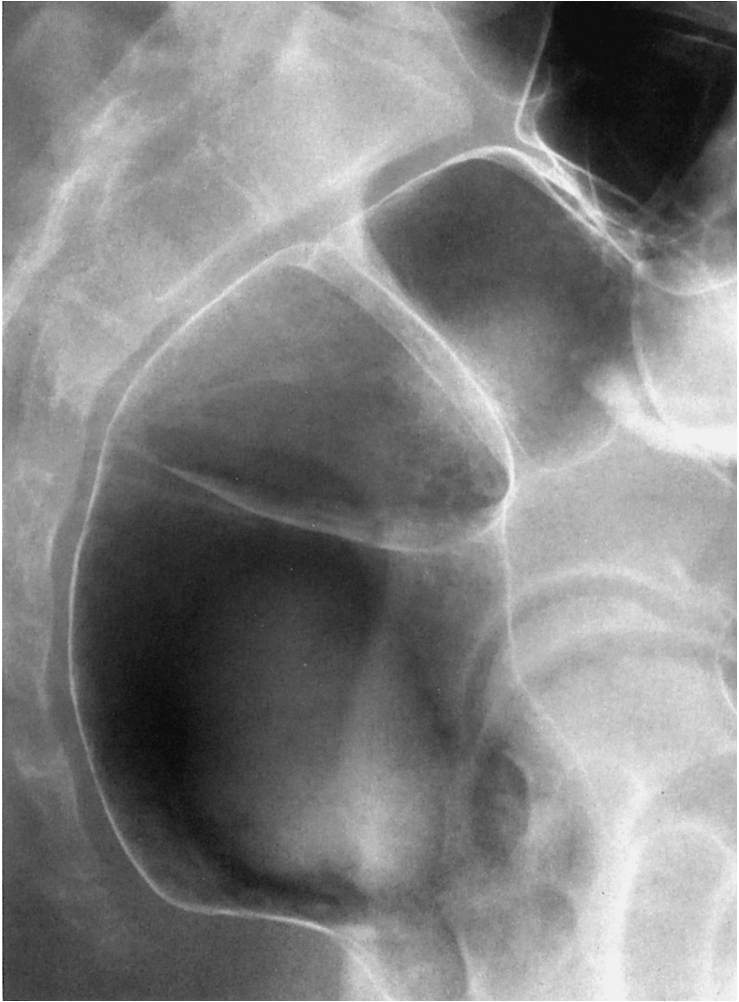- 4 Ileocecal valve
- 5 Terminal ileum
- 6 Cecum

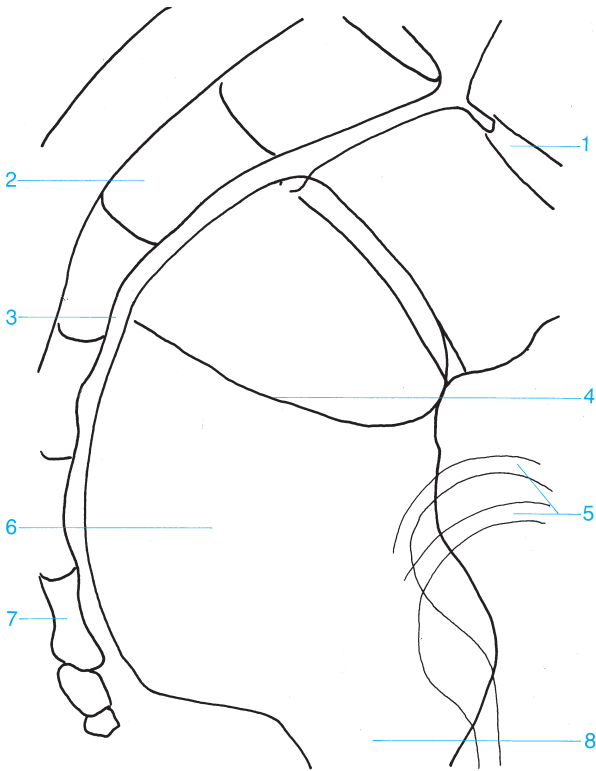




- 1 Splenic flexure of the colon
- 2 Hepatic flexure of the colon
- 3 Ascending colon
- 4 Transverse colon
- 5 Descending colon
- 6 Haustra

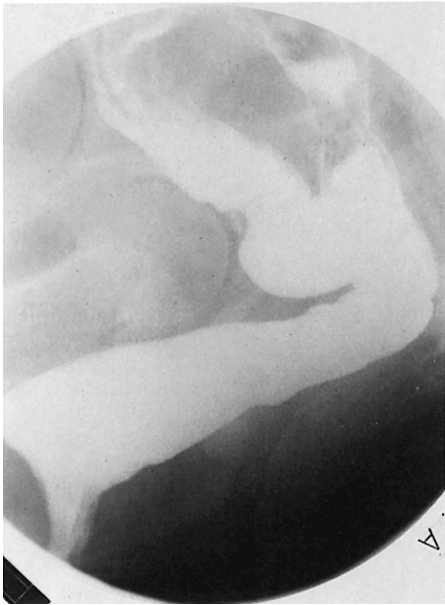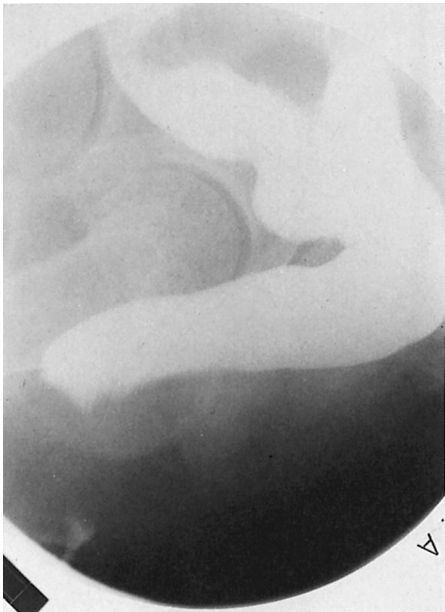- 7 Ileocecal valve
- 8 Cecum
- 9 Sigmoid colon
- 10 Appendix
- 11 Rectum

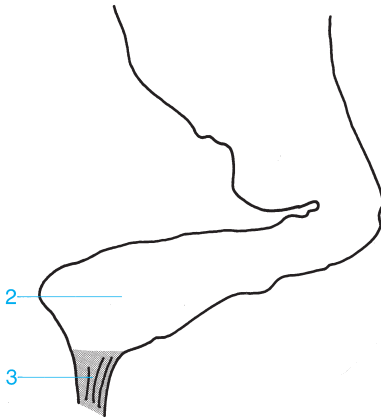
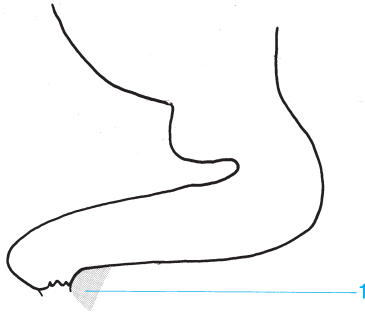




- 1 Rectosigmoid junction
- 2 Sacrum
- 3 Retrorectal space
- 4 Transverse rectal fold

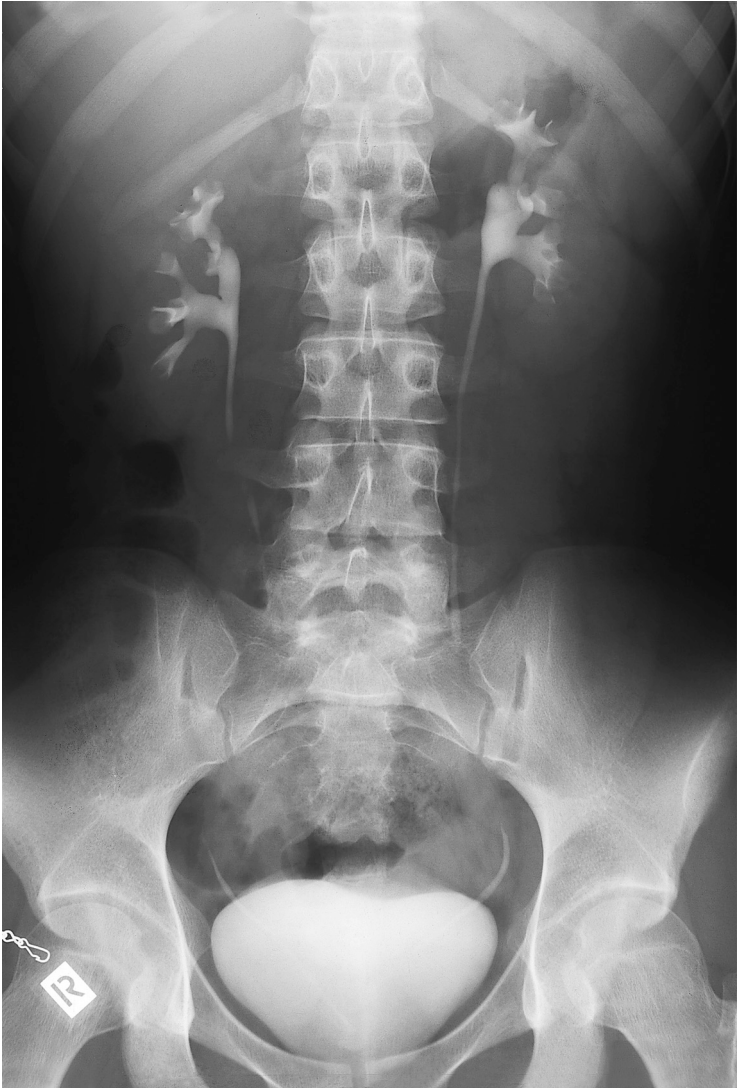- 5 Femoral head
- 6 Rectal ampulla
- 7 Coccyx
- 8 Anorectal junction

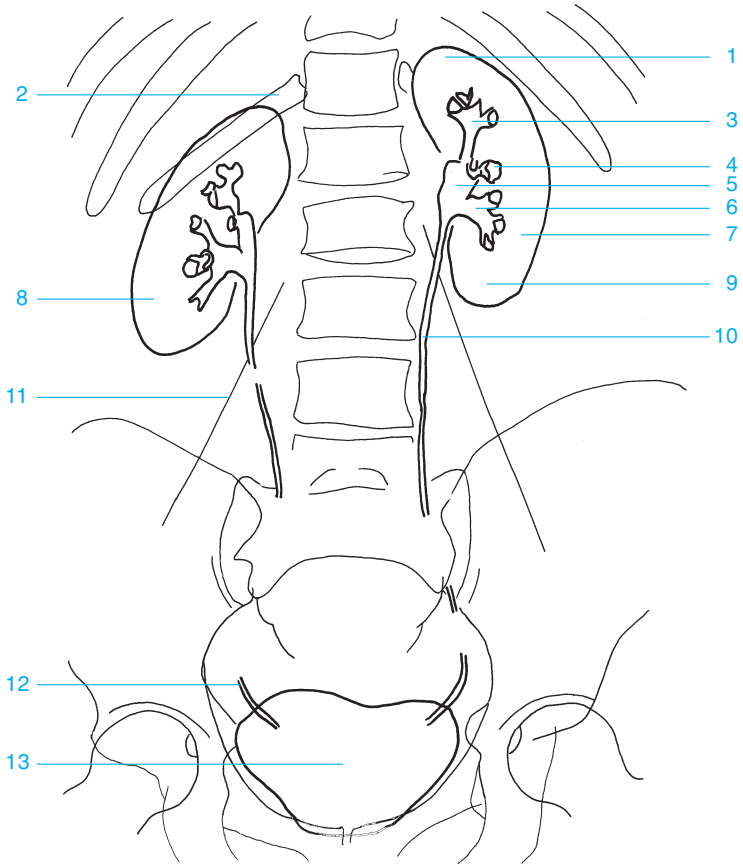




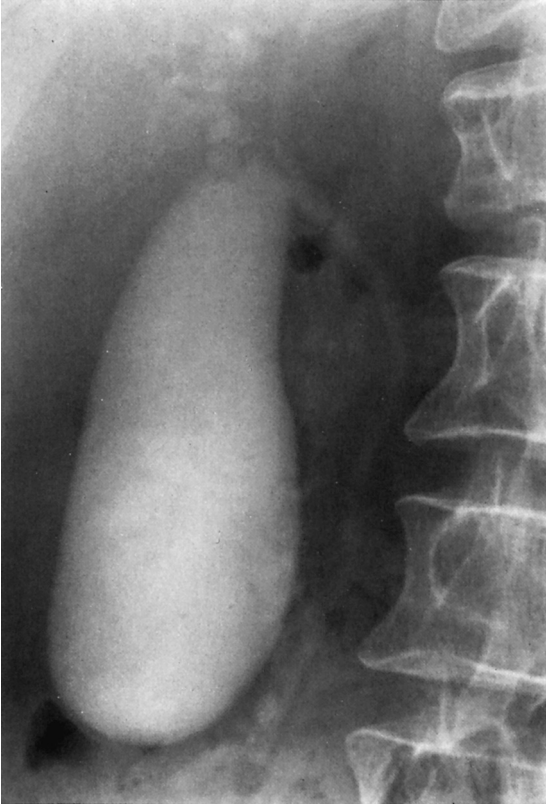- 1 Puborectalis
- 2 Rectal ampulla
- 3 Anal canal

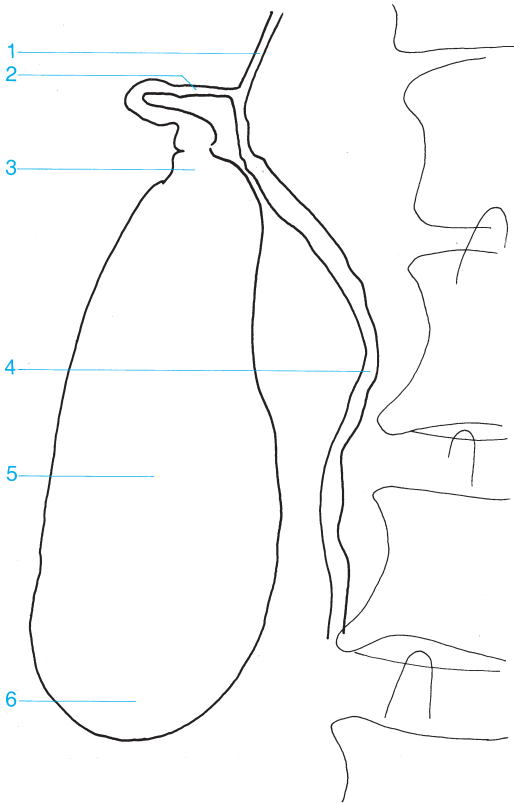




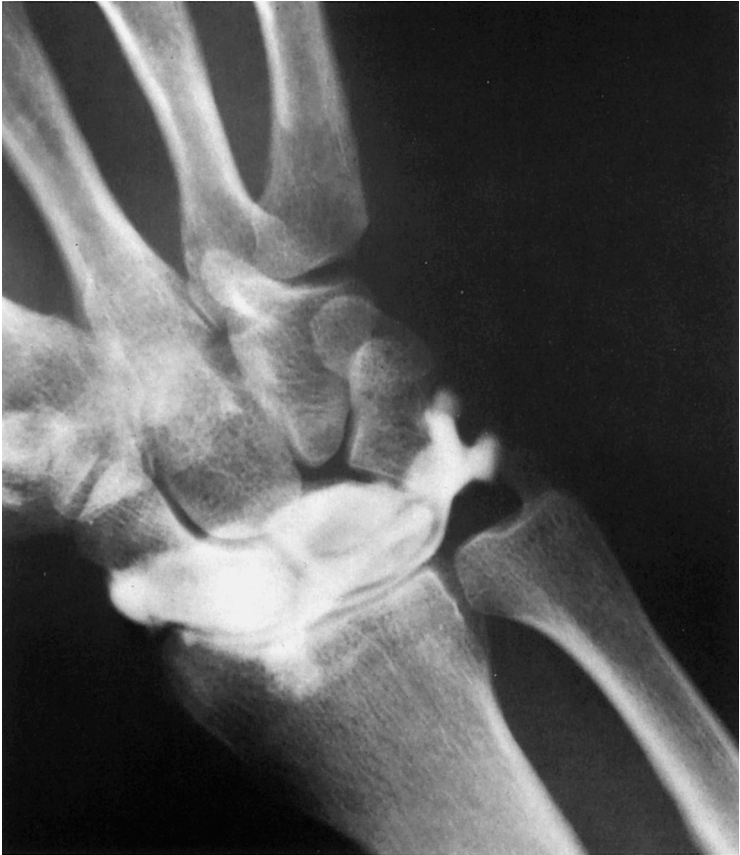

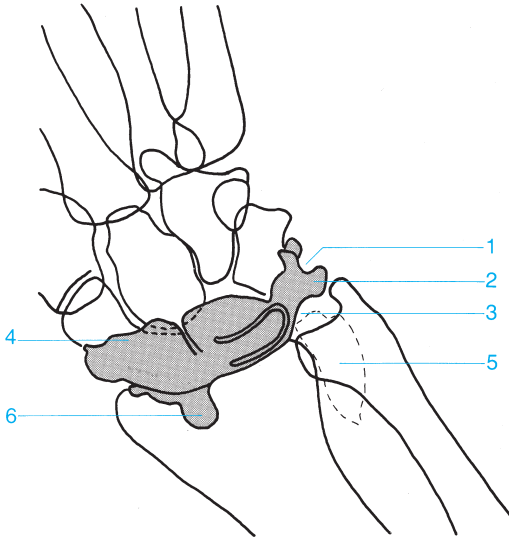
- |                               |                               |
|-------------------------------|-------------------------------|
| 1 Superior pole of the kidney | 8 Right kidney                |
| 2 Twelfth rib                 | 9 Inferior pole of the kidney |
| 3 Superior calyces            | 10 Ureter                     |
| 4 Middle calyces              | 11 Margin of the psoas        |
| 5 Renal pelvis                | 12 Distal ureter              |
| 6 Inferior calyces            | 13 Urinary bladder            |
| 7 Left kidney                 |                               |



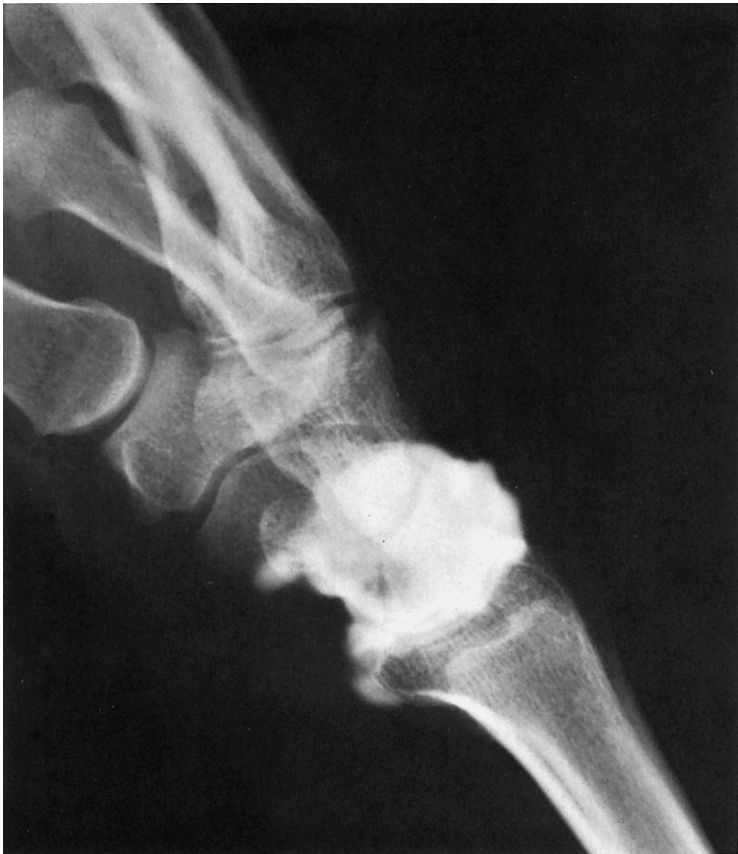

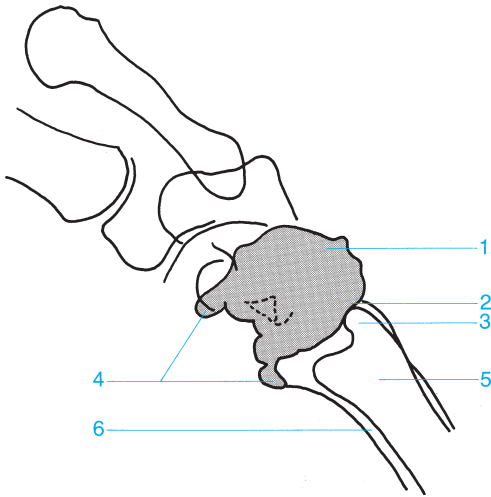
- |                                  |                                    |
|----------------------------------|------------------------------------|
| <b>1</b> Common hepatic duct     | <b>4</b> Common bile duct          |
| <b>2</b> Cystic duct             | <b>5</b> Body of the gallbladder   |
| <b>3</b> Neck of the gallbladder | <b>6</b> Fundus of the gallbladder |





- |                             |                    |
|-----------------------------|--------------------|
| 1 Meniscus                  | 4 Extensor recess  |
| 2 Ulnar recess              | 5 Sacciform recess |
| 3 Triangular fibrocartilage | 6 Flexor recess    |

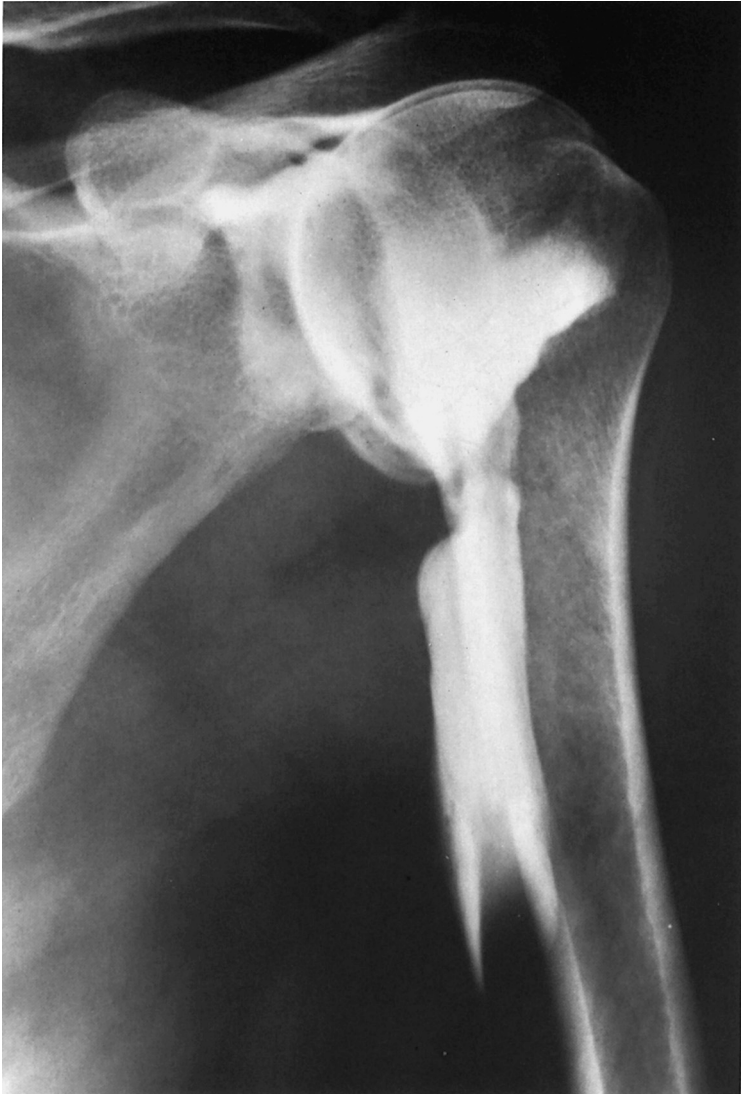

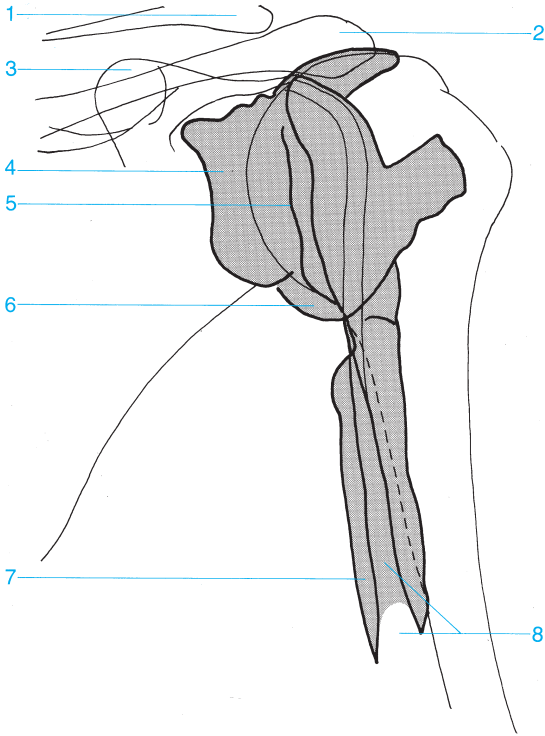


- 1 Extensor recess
- 2 Ulnar recess
- 3 Ulnar styloid

- 4 Flexor recess
- 5 Ulna
- 6 Radius

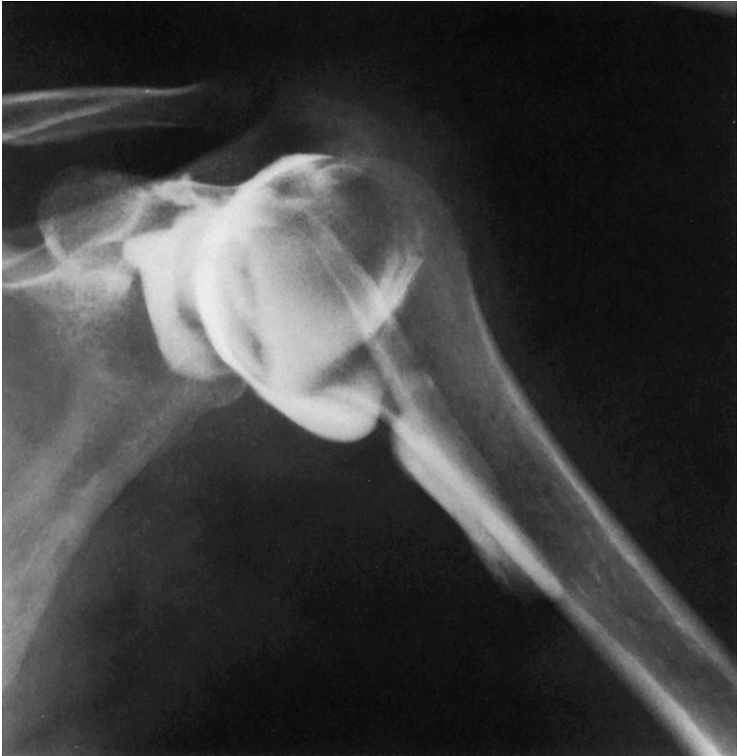

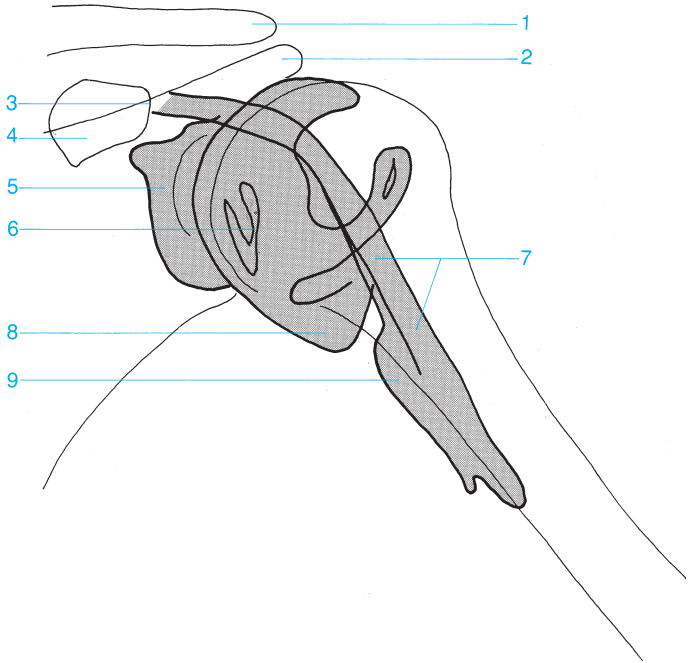




- 1 Clavicle
- 2 Acromion
- 3 Coracoid process
- 4 Subscapular bursa
- 5 Glenoid labrum

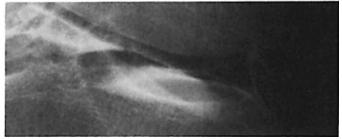
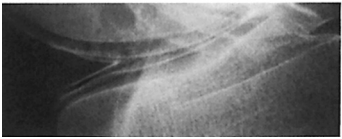
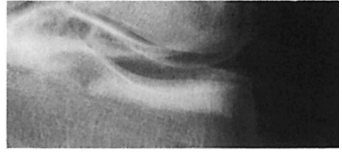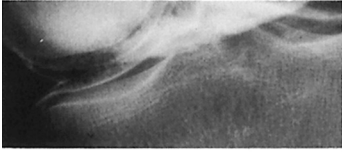
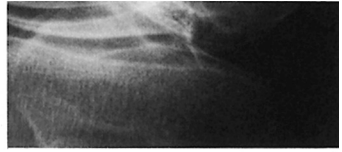
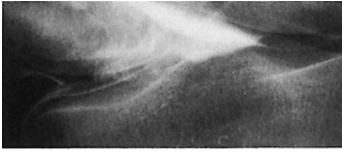
- 6 Axillary recess
- 7 Intertubercular sheath
- 8 Tendon sheath of the long head of the biceps

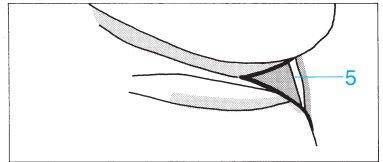
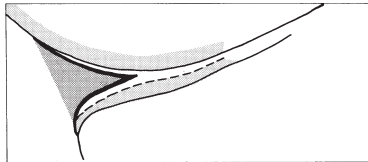

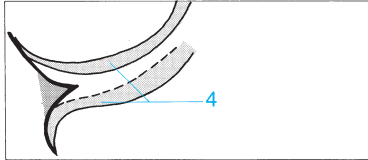

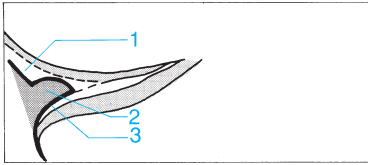




- 1 Clavicle
- 2 Acromion
- 3 Insertion of the biceps tendon
- 4 Coracoid process
- 5 Subscapular bursa

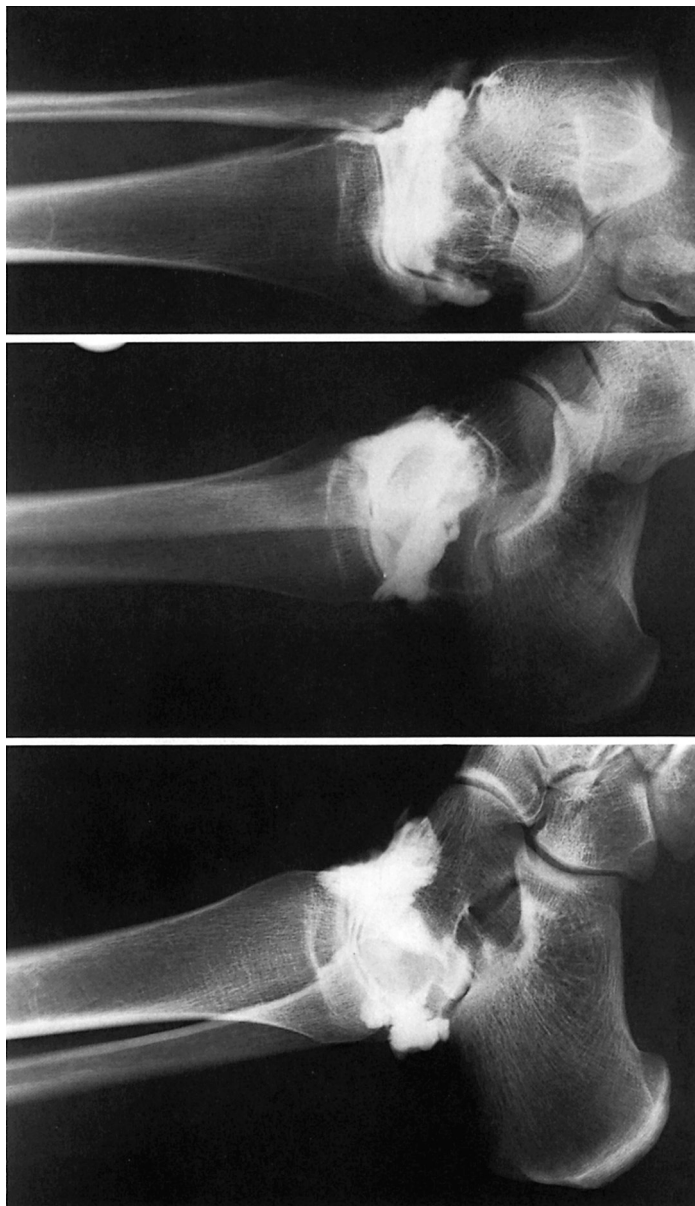- 6 Glenoid labrum
- 7 Tendon sheath of the long head of the biceps
- 8 Axillary recess
- 9 Intertubercular sheath



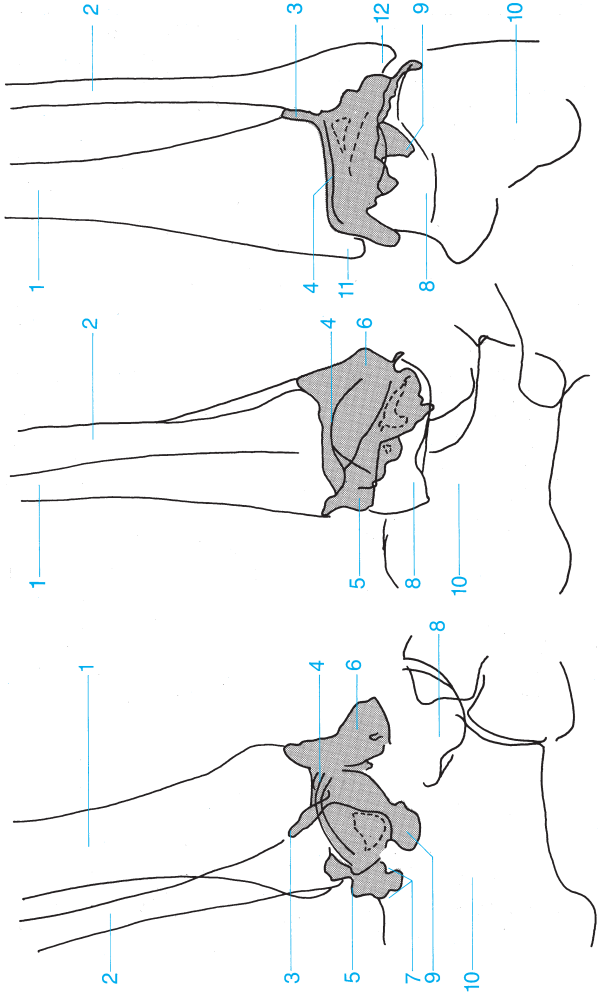


- 1 Superior capsular recess
- 2 Meniscus
- 3 Inferior capsular recess

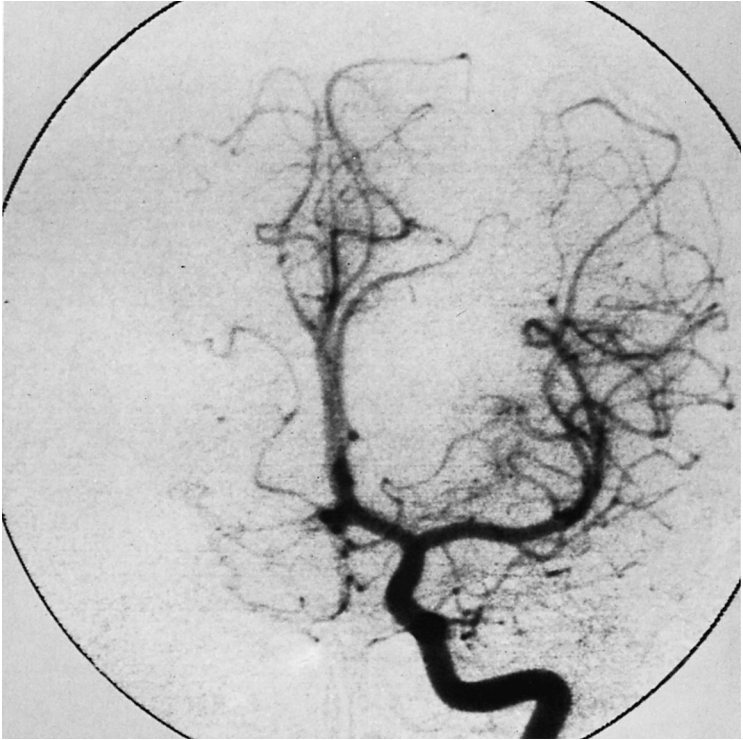- 4 Cartilage
- 5 Popliteal bursa

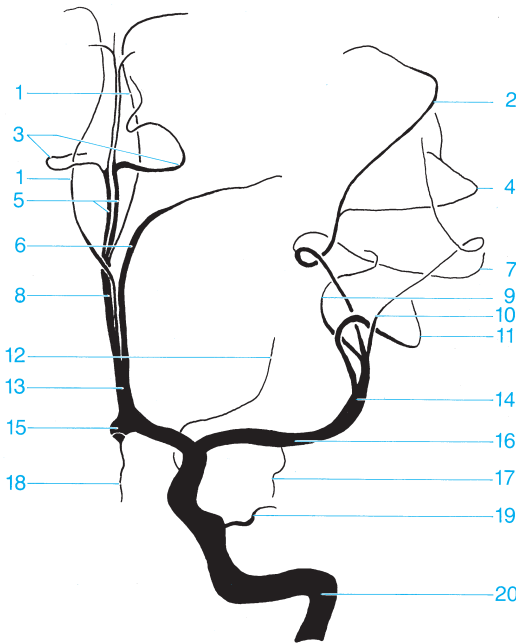


- 1** Tibia
- 2** Fibula
- 3** Tibiofibular joint
- 4** Joint space
- 5** Posterior recess
- 6** Anterior recess
- 7** Ilium recesses (anatomy varies)
- 8** Talus
- 9** Supracalcaneal recess
- 10** Calcaneus
- 11** Medial malleolus
- 12** Lateral malleolus

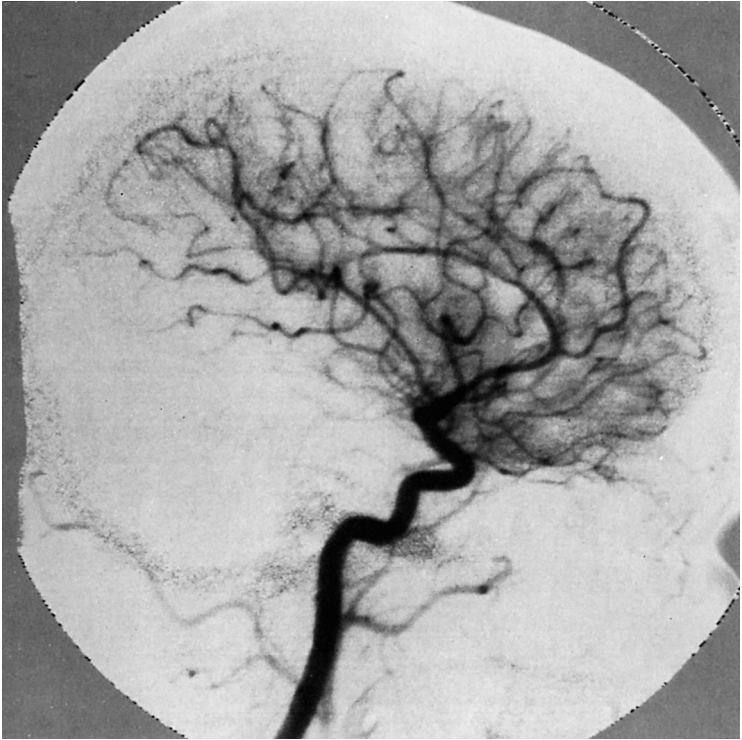

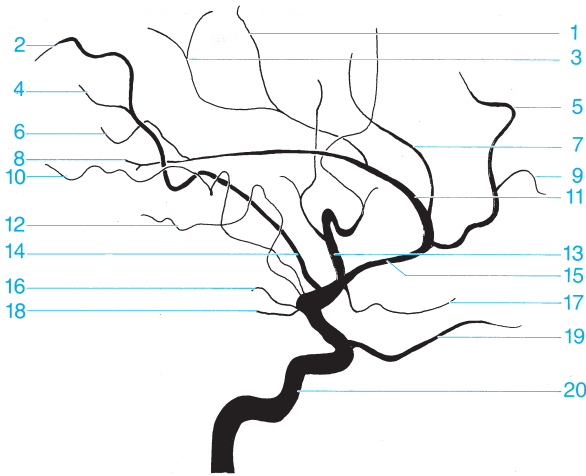




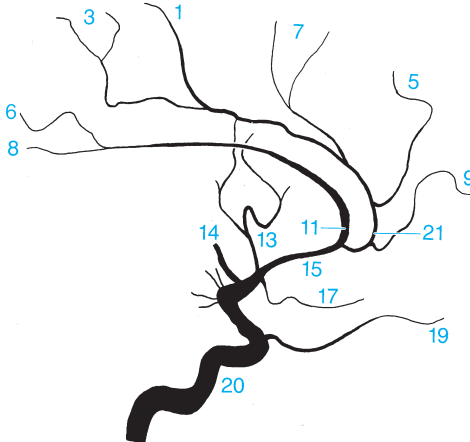


- |  |  |
|--|--|
| <b>1</b> Callosomarginal artery  | <b>13</b> Second segment of the anterior cerebral artery (from here on referred to as the pericallosal artery) |
| <b>2</b> Anterior parietal artery  | <b>14</b> Second segment of the middle cerebral artery   |
| <b>3</b> Pericallosal artery   | <b>15</b> Anterior communicating artery of the cerebrum (obscured by a vascular arch)                          |
| <b>4</b> Posterior parietal artery   | <b>16</b> First segment of the middle cerebral artery (sphenoid part)  |
| <b>5</b> Pericallosal artery (fourth segment of the anterior cerebral artery, superior to the corpus callosum) | <b>17</b> Temporal polar artery  |
| <b>6</b> Frontal polar artery  | <b>18</b> Frontal orbital artery   |
| <b>7</b> Precentral sulcal artery  | <b>19</b> Ophthalmic artery  |
| <b>8</b> Third segment of the anterior cerebral artery or pericallosal artery                                  | <b>20</b> Internal carotid artery  |
| <b>9</b> Artery of the angular gyrus   |  |
| <b>10</b> Posterior temporal artery  |  |
| <b>11</b> Prefrontal arteries  |  |
| <b>12</b> Anterior choroidal artery  |  |

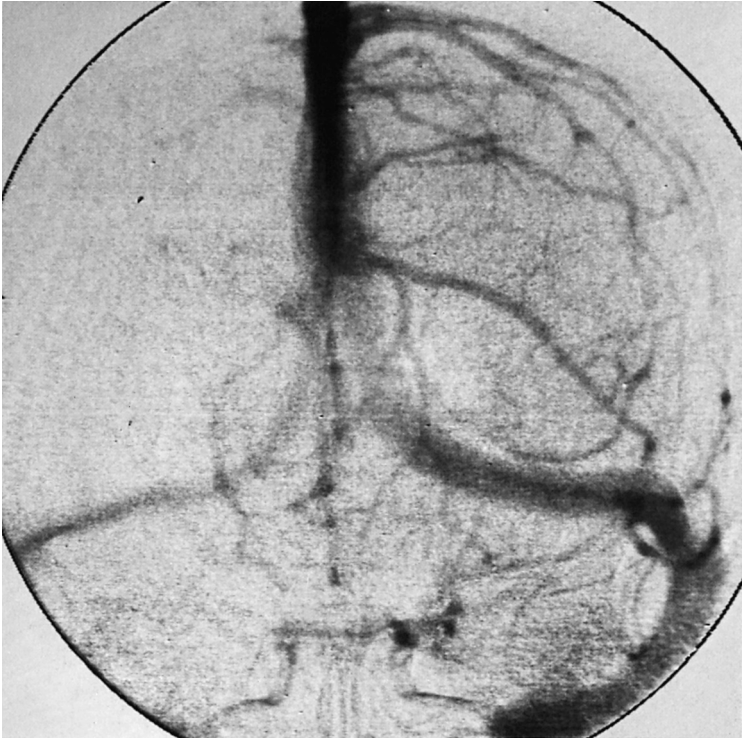


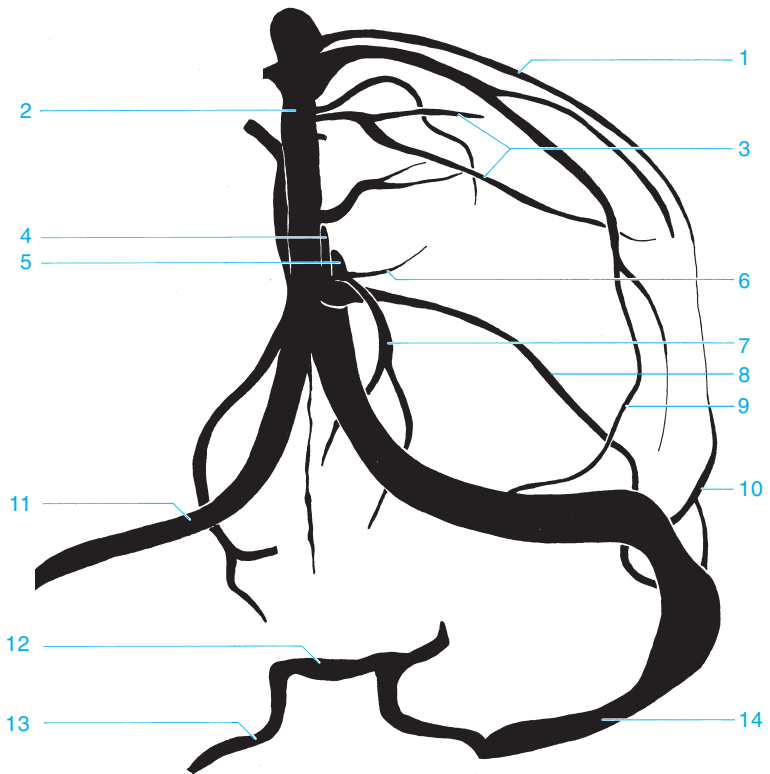


Variant (40%)

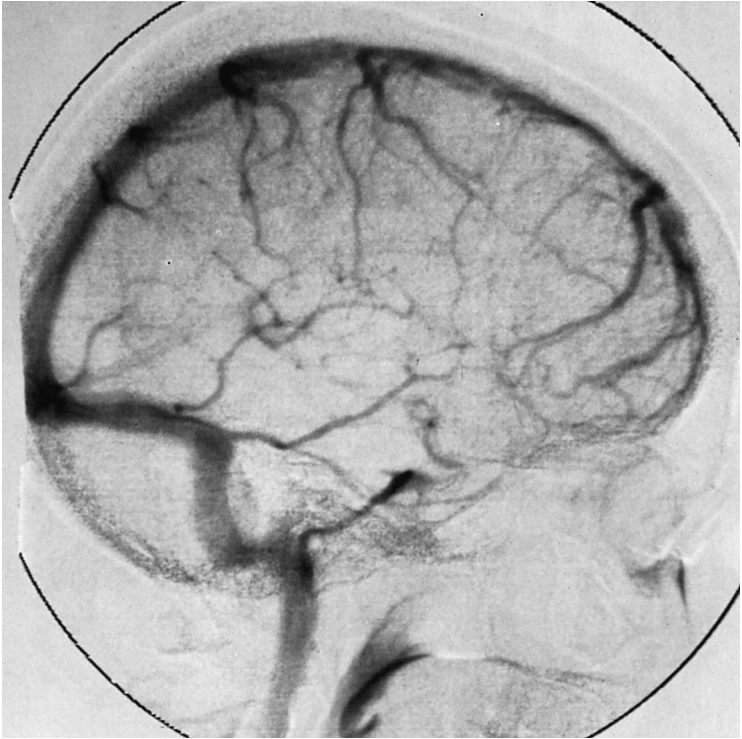


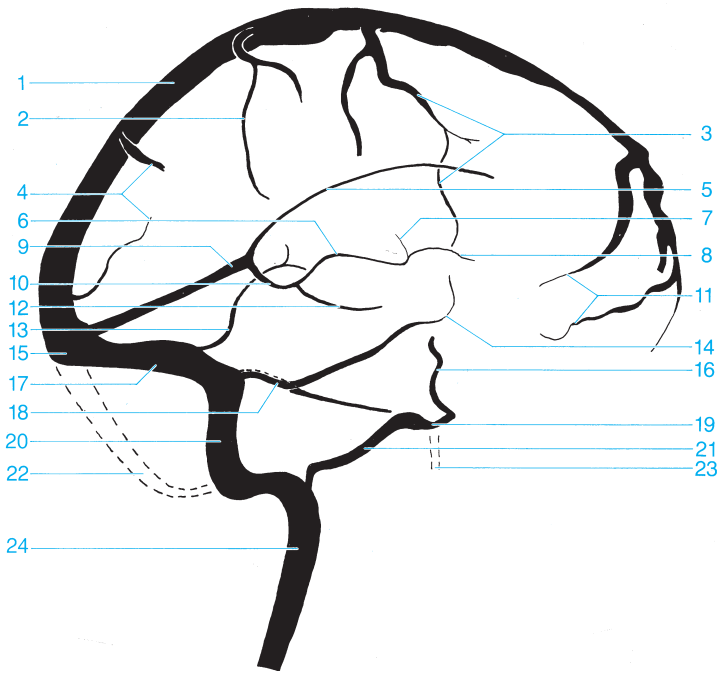
- |                                     |   |
|-------------------------------------|---|
| 1 Posterior internal frontal artery | 13 Prefrontal arteries                            |
| 2 Anterior parietal artery          | 14 Second segment of the middle cerebral artery   |
| 3 Paracentral artery                | 15 Second segment of the anterior cerebral artery |
| 4 Posterior parietal artery         | 16 Anterior choroidal artery                      |
| 5 Anterior internal frontal artery  | 17 Frontal orbital artery                         |
| 6 Superior internal parietal artery | 18 Posterior communicating artery                 |
| 7 Medial internal frontal artery    | 19 Ophthalmic artery                              |
| 8 Inferior internal parietal artery | 20 Internal carotid artery                        |
| 9 Frontal polar artery              | 21 Callosomarginal artery                         |
| 10 Artery of the angular gyrus      |   |
| 11 Pericallosal artery              |   |
| 12 Posterior temporal artery        |   |





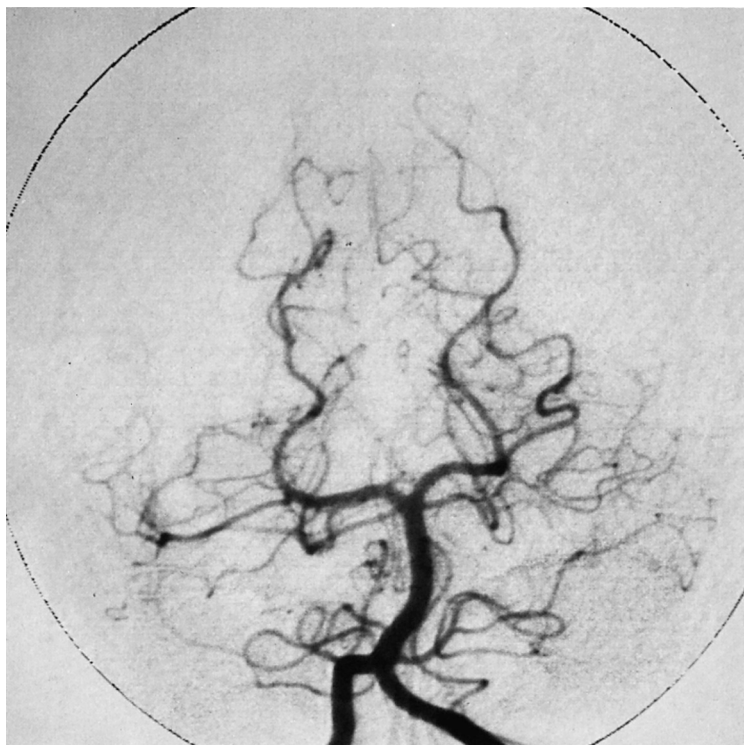
- |   |                                 |
|---|---------------------------------|
| 1 Parietal vein                               | 8 Frontal veins                 |
| 2 Superior sagittal sinus                     | 9 Veins of the fossa of Sylvius |
| 3 Superior anastomotic vein (vein of Trolard) | 10 Sphenoparietal sinus         |
| 4 Great cerebral vein of Galen                | 11 Transverse sinus             |
| 5 Internal cerebral vein                      | 12 Intercavernous sinus         |
| 6 Superior thalamostriate vein                | 13 Inferior petrosal sinus      |
| 7 Basal vein of Rosenthal                     | 14 Sigmoid sinus                |

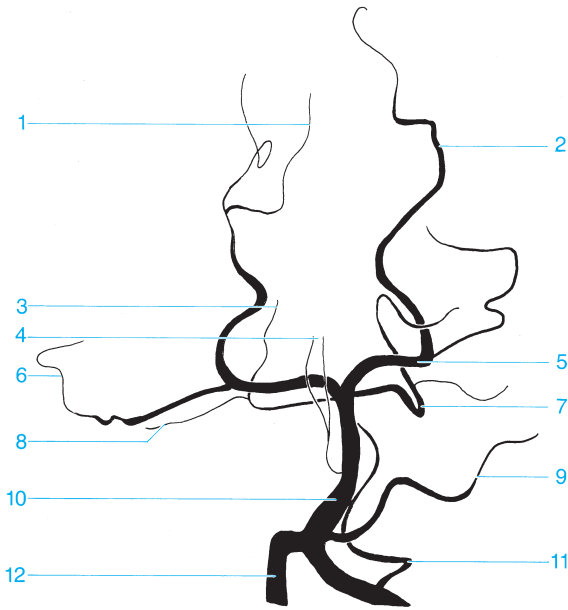




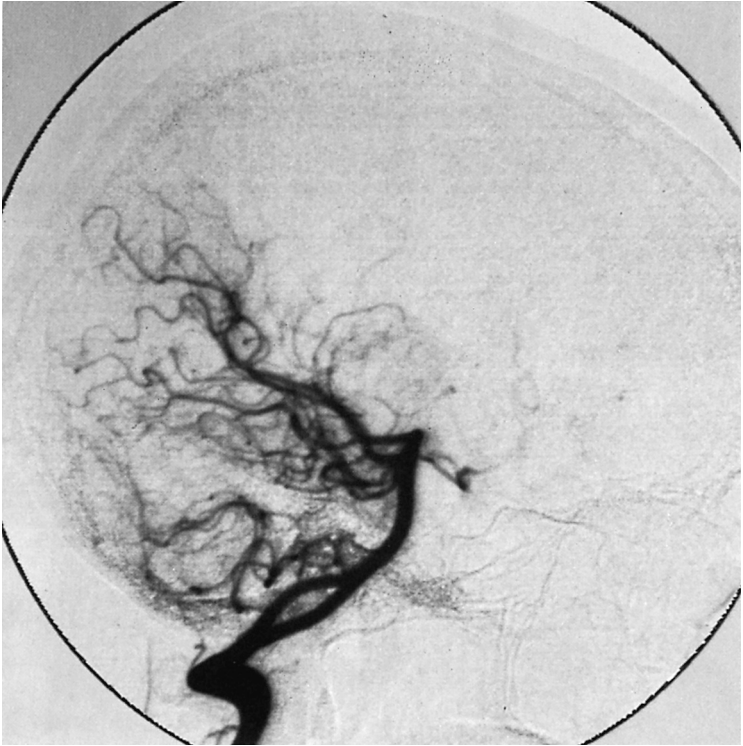- |   |   |
|---|---|
| 1 Superior sagittal sinus                     | 14 Veins of the fossa of Sylvius        |
| 2 Parietal vein                               | 15 Confluence of sinuses                |
| 3 Superior anastomotic vein (vein of Trolard) | 16 Cavernous sinus (anterior drainage)  |
| 4 Occipital veins                             | 17 Transverse sinus                     |
| 5 Inferior sagittal sinus                     | 18 Superior petrosal sinus              |
| 6 Internal cerebral vein                      | 19 Cavernous sinus (posterior drainage) |
| 7 Superior thalamostriate veins               | 20 Sigmoid sinus                        |
| 8 Vein of the septum pellucidum               | 21 Inferior petrosal sinus              |
| 9 Straight sinus                              | 22 Occipital sinus                      |
| 10 Great cerebral vein of Galen               | 23 Pterygoid plexus                     |
| 11 Ascending frontal veins                    | 24 Internal jugular vein                |
| 12 Basal vein of Rosenthal                    |   |
| 13 Inferior anastomotic vein (vein of Labbé)  |   |

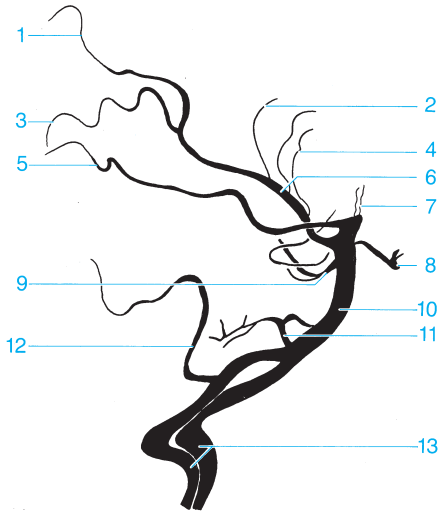




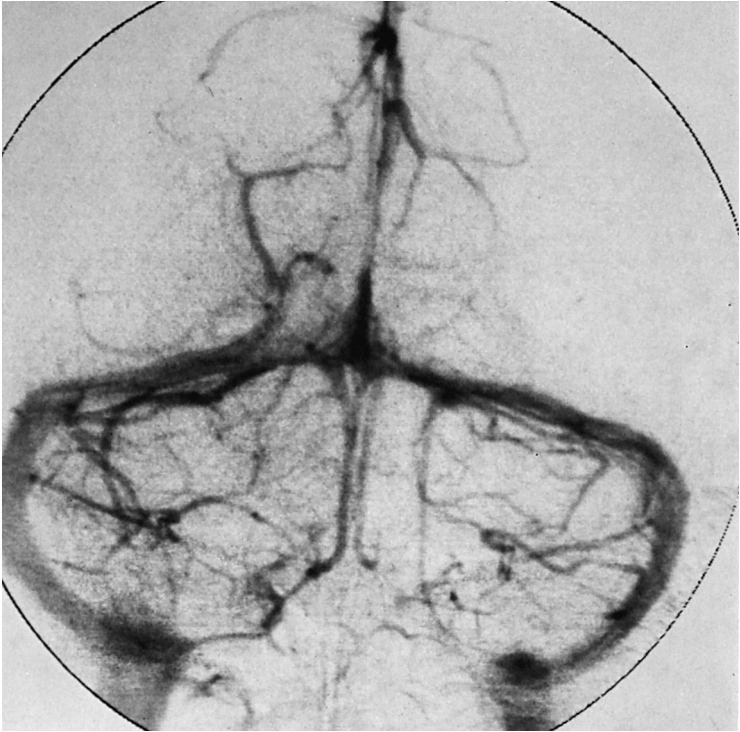


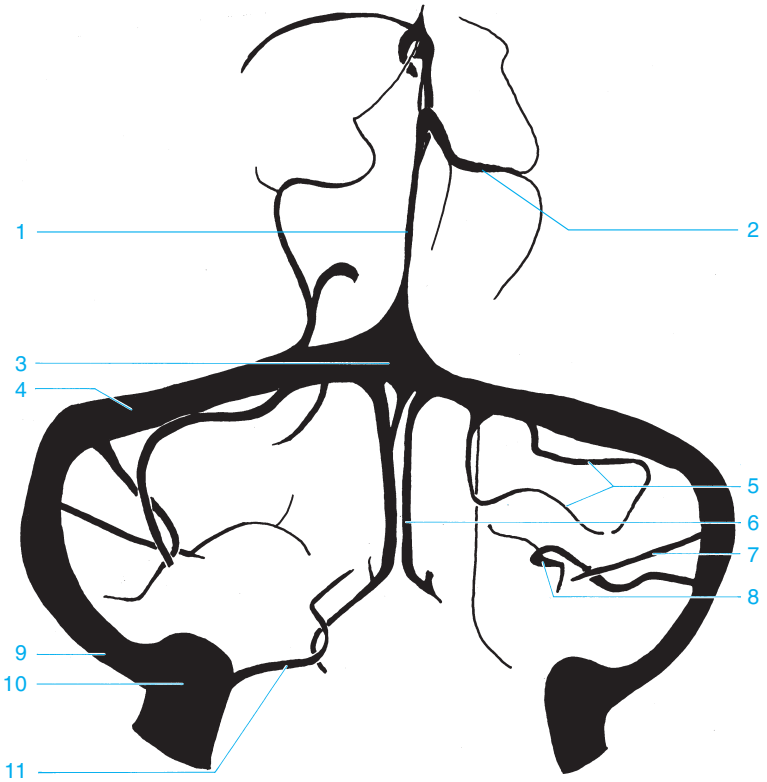
- |  |   |
|--|---|
| <ul style="list-style-type: none"> <li>1 Calcarine branch of the medial occipital artery</li> <li>2 Parieto-occipital artery</li> <li>3 Vermis branch</li> <li>4 Thalamoperforate arteries</li> <li>5 Posterior cerebral artery</li> <li>6 Temporo-occipital artery</li> </ul> | <ul style="list-style-type: none"> <li>7 Superior cerebellar artery</li> <li>8 Marginal artery</li> <li>9 Anterior inferior cerebellar artery</li> <li>10 Basilar artery</li> <li>11 Posterior inferior cerebellar artery</li> <li>12 Vertebral artery</li> </ul> |
|--|---|



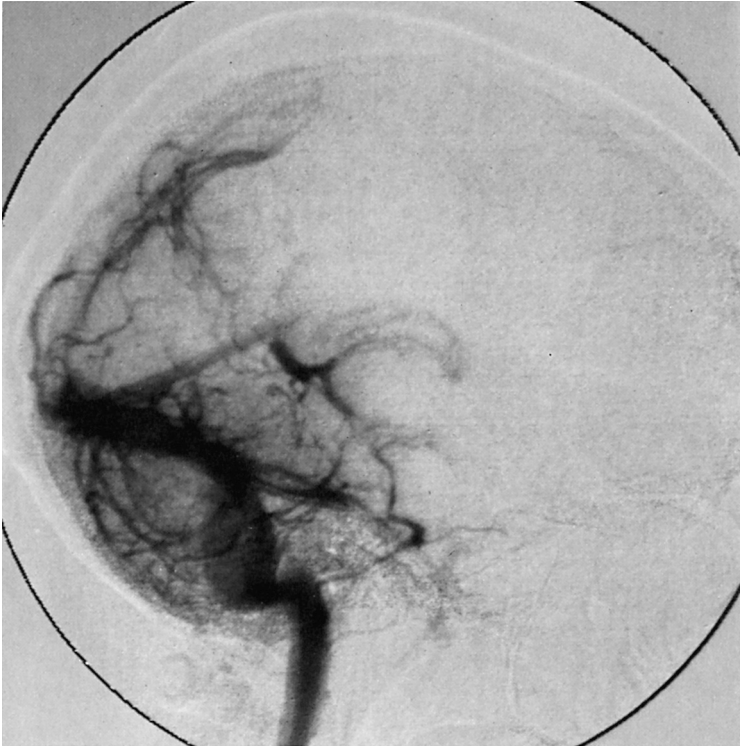

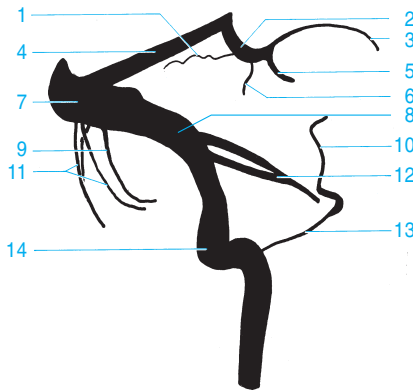
- |   |   |
|---|---|
| 1 Parieto-occipital artery                            | 7 Branches of the posterior cerebral artery to the thalamus |
| 2 Dorsal corpus callosal branch                       | 8 Posterior communicating artery                            |
| 3 Calcarine branch of the medial occipital artery     | 9 Superior cerebellar artery                                |
| 4 Choroidal arteries (posterior, medial, and lateral) | 10 Basilar artery   |
| 5 Temporo-occipital artery                            | 11 Anterior inferior cerebellar artery                      |
| 6 Posterior cerebral artery                           | 12 Posterior inferior cerebellar artery                     |
|   | 13 Vertebral arteries                                       |





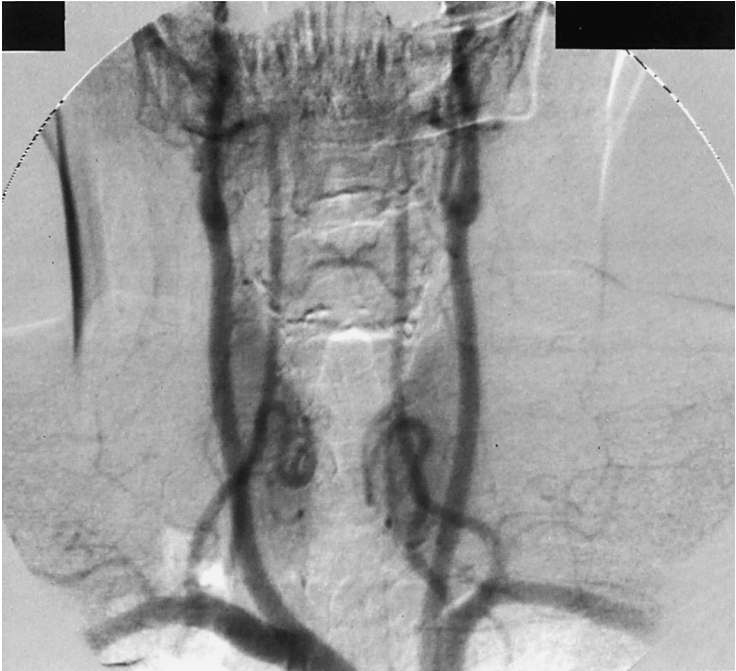- |   |  |
|---|--|
| <ul style="list-style-type: none"> <li>1 Straight sinus</li> <li>2 Superior cerebral veins</li> <li>3 Confluence of sinuses</li> <li>4 Transverse sinus</li> <li>5 Veins of the cerebellar hemisphere</li> <li>6 Inferior vein of the vermis</li> </ul> | <ul style="list-style-type: none"> <li>7 Inferior vein of the cerebellar hemisphere</li> <li>8 Petrosal vein (entering the superior petrosal sinus)</li> <li>9 Sigmoid sinus</li> <li>10 Bulb of the jugular vein</li> <li>11 Inferior petrosal sinus</li> </ul> |
|---|--|

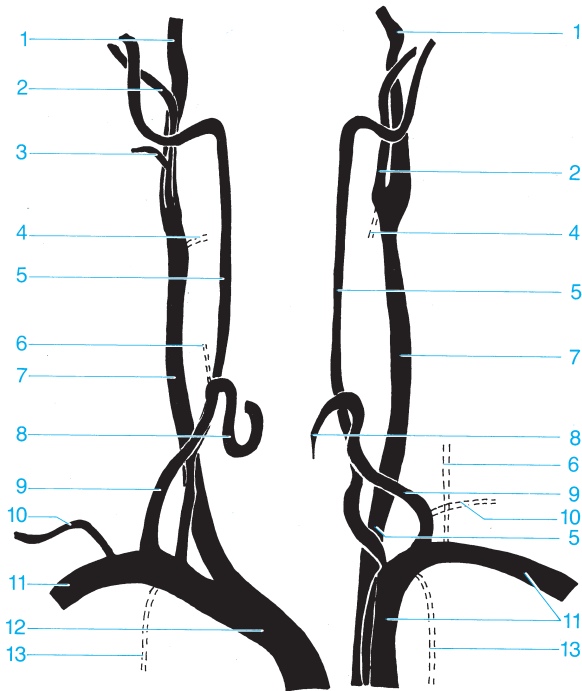




- |   |  |
|---|--|
| 1 Superior veins of the cerebellar hemisphere | 9 Inferior veins of the cerebellar hemisphere  |
| 2 Great cerebral vein of Galen                | 10 Cavernous sinus                             |
| 3 Internal cerebral vein                      | 11 Inferior veins of the cerebellar hemisphere |
| 4 Straight sinus                              | 12 Superior petrosal sinus                     |
| 5 Basal vein of Rosenthal                     | 13 Inferior petrosal sinus                     |
| 6 Precentral cerebellar vein                  | 14 Sigmoid sinus                               |
| 7 Confluence of sinuses                       |  |
| 8 Transverse sinus                            |  |

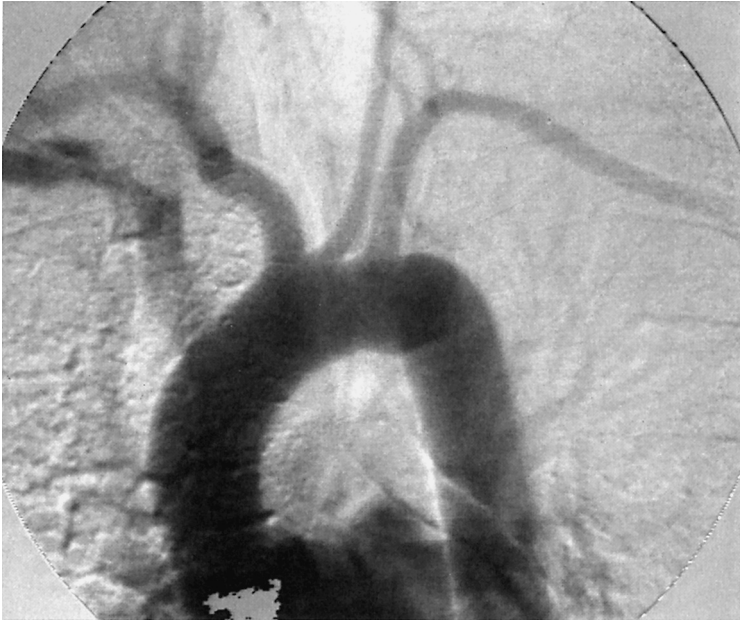

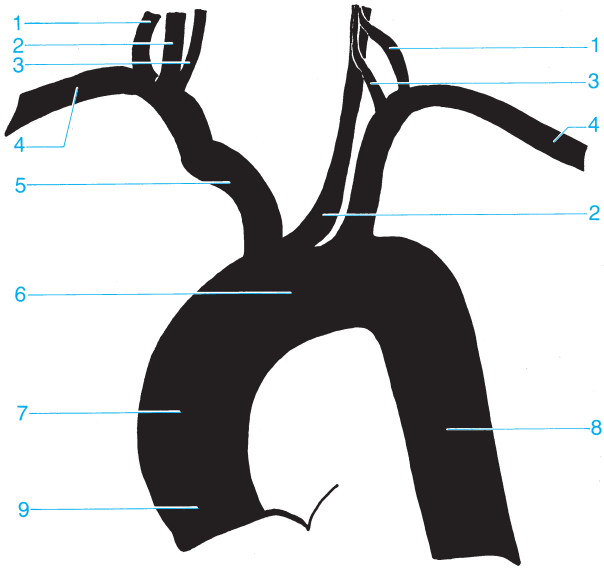




- 1 Internal carotid artery
- 2 External carotid artery
- 3 Facial artery
- 4 Superior thyroid artery
- 5 Vertebral artery
- 6 Ascending cervical artery
- 7 Common carotid artery

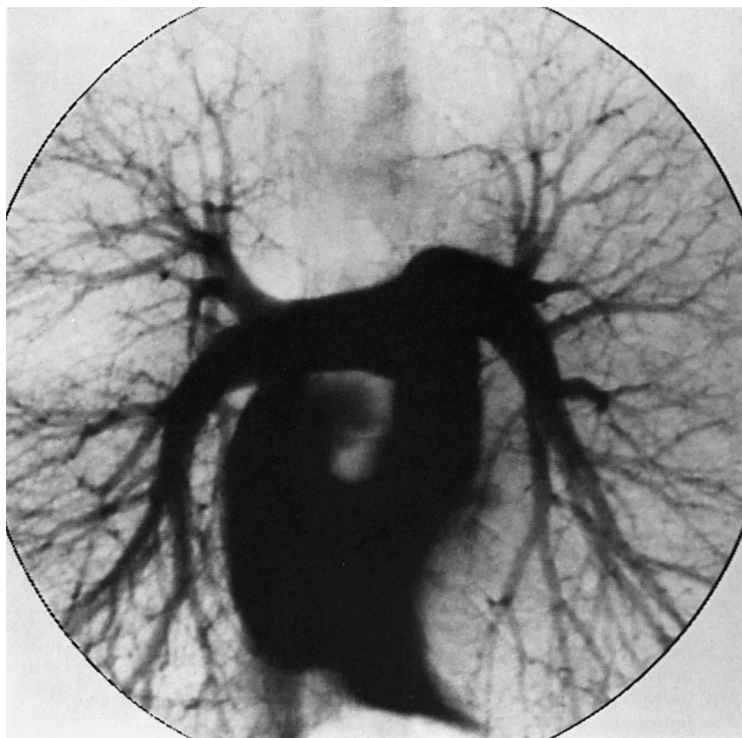
- 8 Inferior thyroid artery
- 9 Thyrocervical trunk
- 10 Suprascapular artery
- 11 Subclavian artery
- 12 Brachiocephalic trunk
- 13 Internal thoracic artery

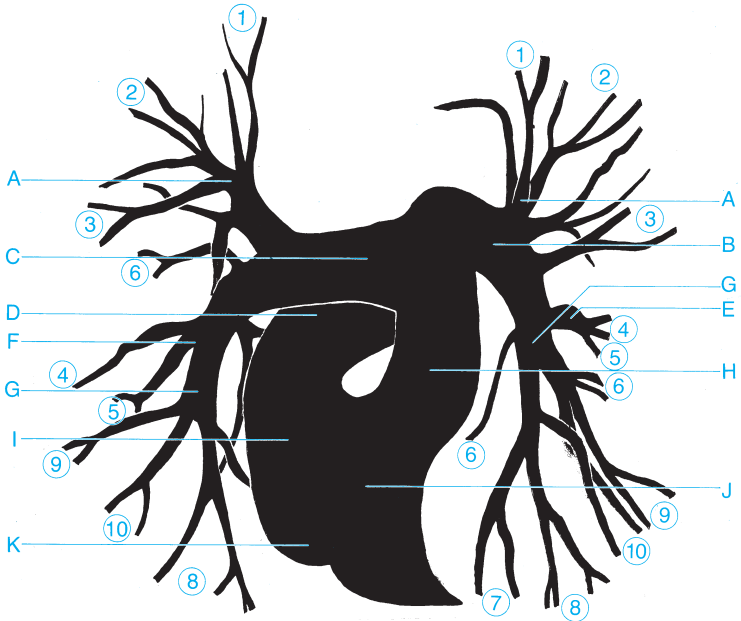




- 1 Thyrocervical trunk
- 2 Common carotid artery
- 3 Vertebral artery
- 4 Subclavian artery
- 5 Brachiocephalic trunk

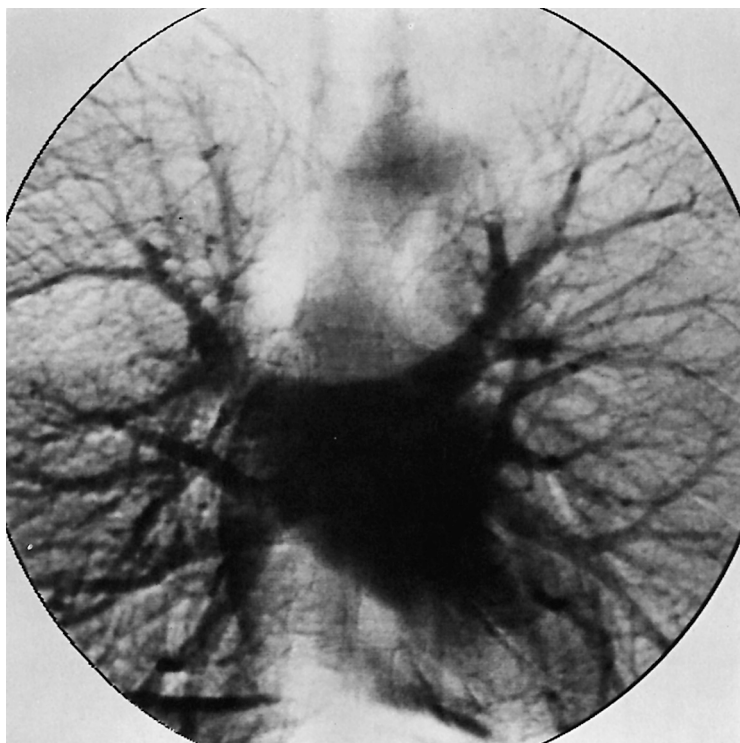
- 6 Aortic arch
- 7 Ascending aorta
- 8 Descending aorta
- 9 Aortic bulb

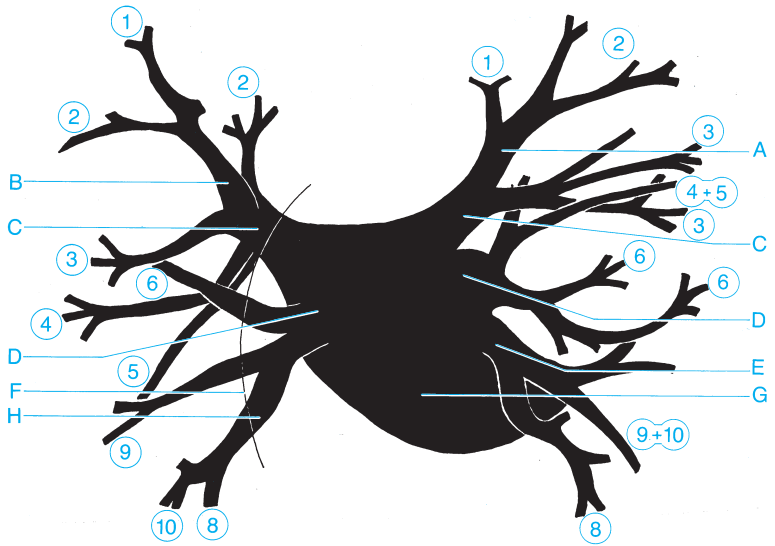




○ = Segmental arteries 1-10

- |  |  |
|--|--|
| <b>A</b> Apical branch                               | <b>G</b> Inferior lobar branch of the pulmonary artery |
| <b>B</b> Left pulmonary artery                       | <b>H</b> Pulmonary trunk                               |
| <b>C</b> Right pulmonary artery                      | <b>I</b> Right atrium                                  |
| <b>D</b> Superior vena cava                          | <b>J</b> Right ventricle                               |
| <b>E</b> Lingular branch                             | <b>K</b> Inferior vena cava                            |
| <b>F</b> Middle lobar branch of the pulmonary artery |  |

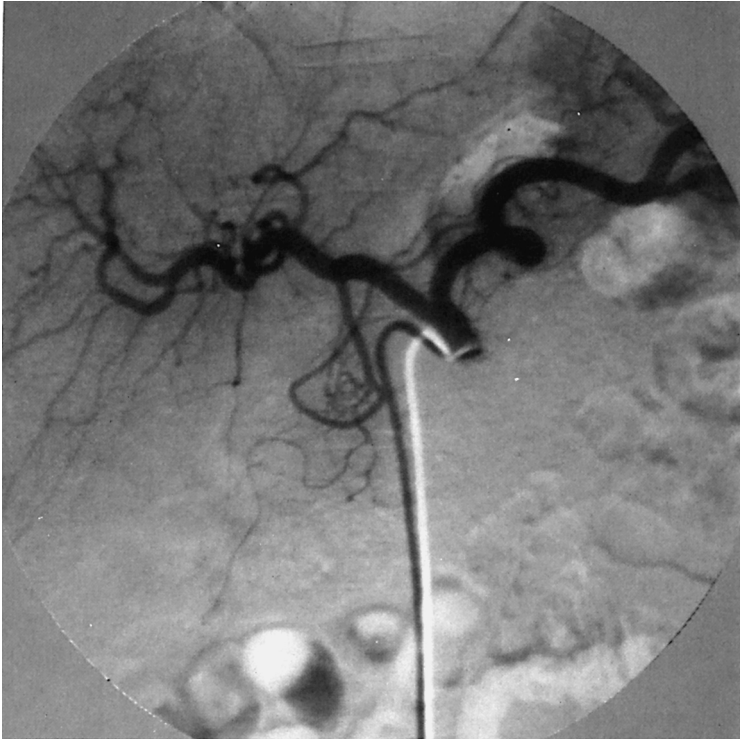


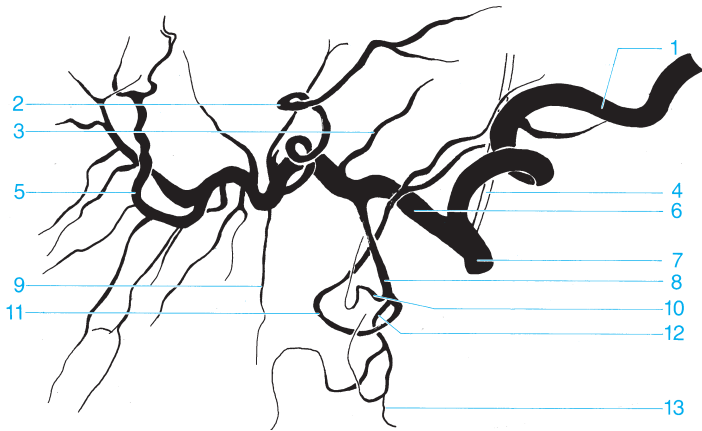


○ = Segmental arteries 1-10

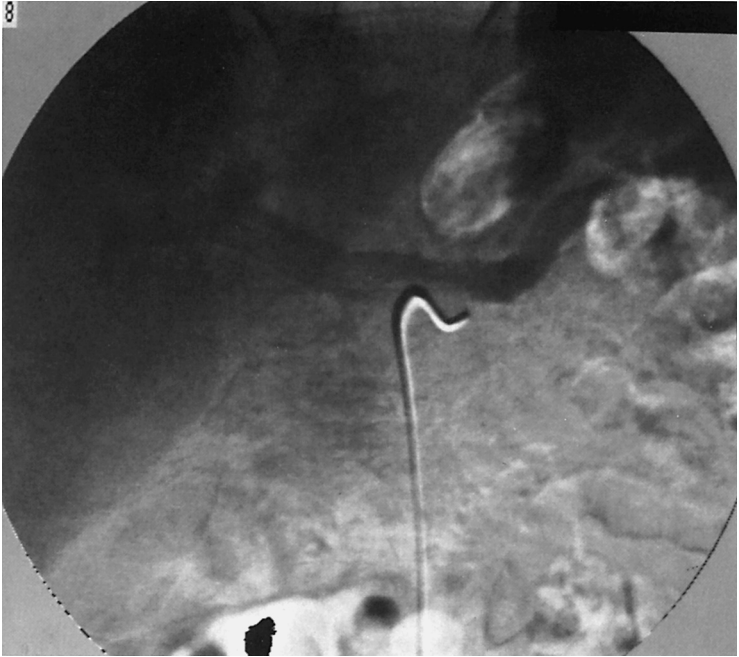- |                                  |                              |
|----------------------------------|------------------------------|
| <b>A</b> Apicoposterior branch   | <b>E</b> Common basal vein   |
| <b>B</b> Apical branch           | <b>F</b> Right atrium        |
| <b>C</b> Inferior pulmonary vein | <b>G</b> Left atrium         |
| <b>D</b> Superior pulmonary vein | <b>H</b> Inferior basal vein |

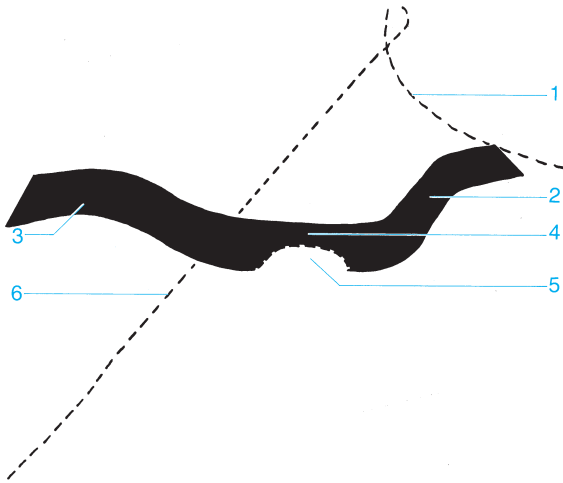




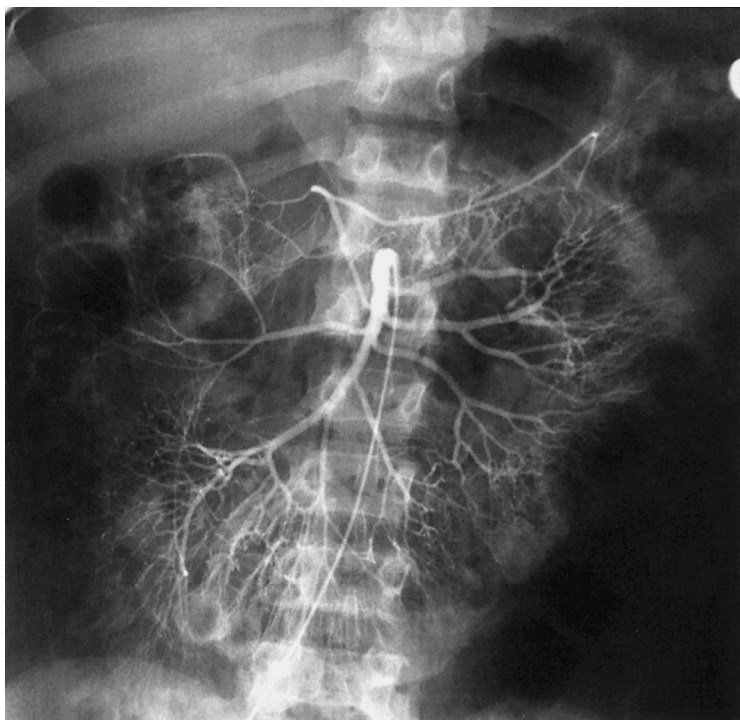


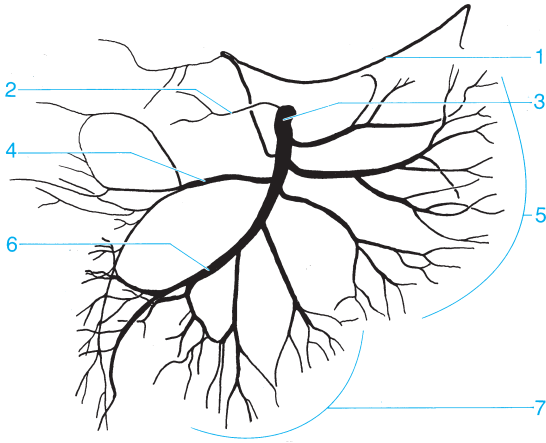
- |  |   |
|--|---|
| <b>1</b> Splenic artery                            | <b>8</b> Gastroduodenal artery  |
| <b>2</b> Left branch of the proper hepatic artery  | <b>9</b> Cystic artery  |
| <b>3</b> Right gastric artery                      | <b>10</b> superior supraduodenal artery   |
| <b>4</b> Left gastric artery                       | <b>11</b> Right gastroepiploic artery   |
| <b>5</b> Right branch of the proper hepatic artery | <b>12</b> Superior pancreaticoduodenal artery   |
| <b>6</b> Common hepatic artery                     | <b>13</b> Inferior pancreaticoduodenal artery (anastomosis with the superior mesenteric artery) |
| <b>7</b> Celiac trunk                              |   |



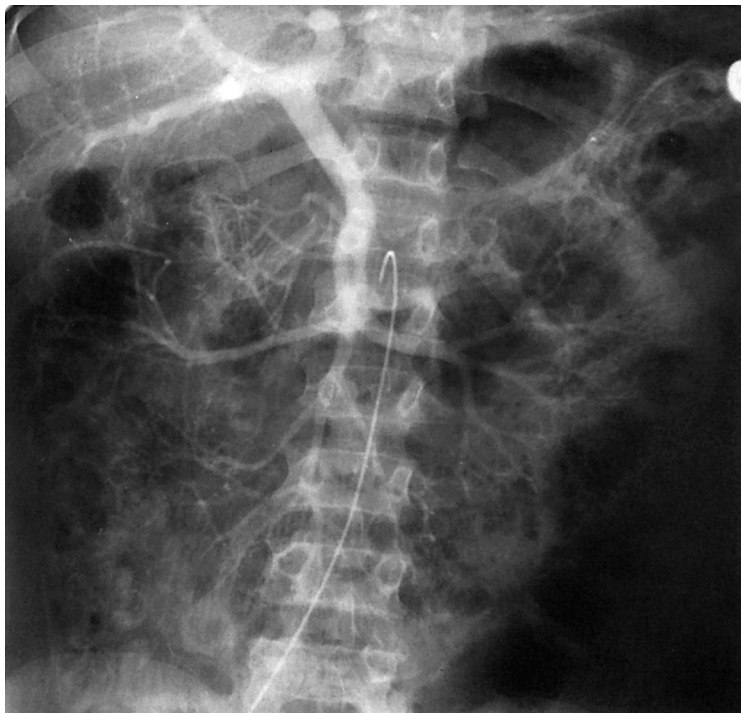


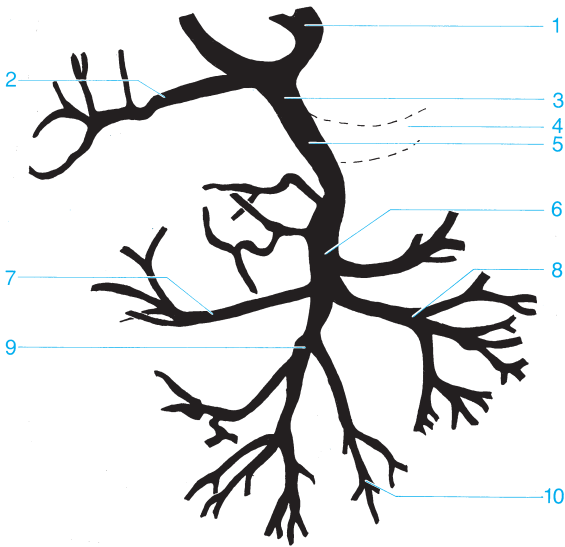
- |                       |  |
|-----------------------|--|
| <b>1</b> Spleen       | <b>4</b> Confluence                      |
| <b>2</b> Splenic vein | <b>5</b> Junction of the mesenteric vein |
| <b>3</b> Portal vein  | <b>6</b> Liver                           |





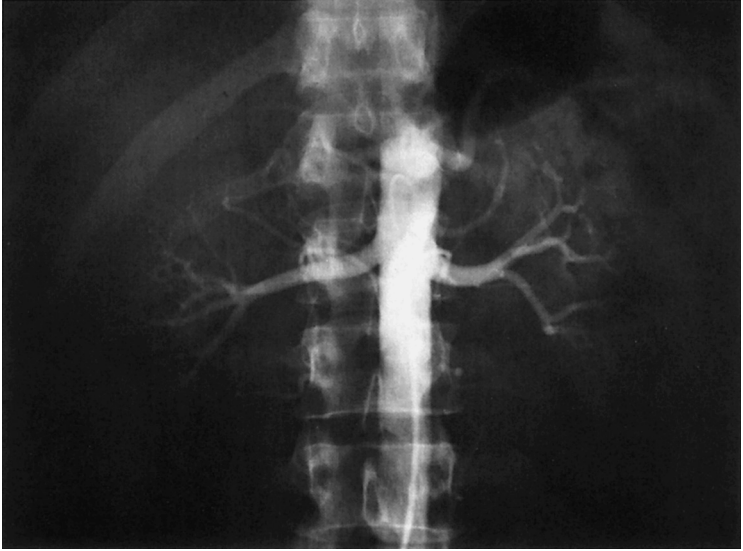
- |                                       |                    |
|---------------------------------------|--------------------|
| 1 Middle colic artery                 | 5 Jejunal arteries |
| 2 Inferior pancreaticoduodenal artery | 6 Ileocolic artery |
| 3 Superior mesenteric artery          | 7 Ileal arteries   |
| 4 Right colic artery                  |                    |

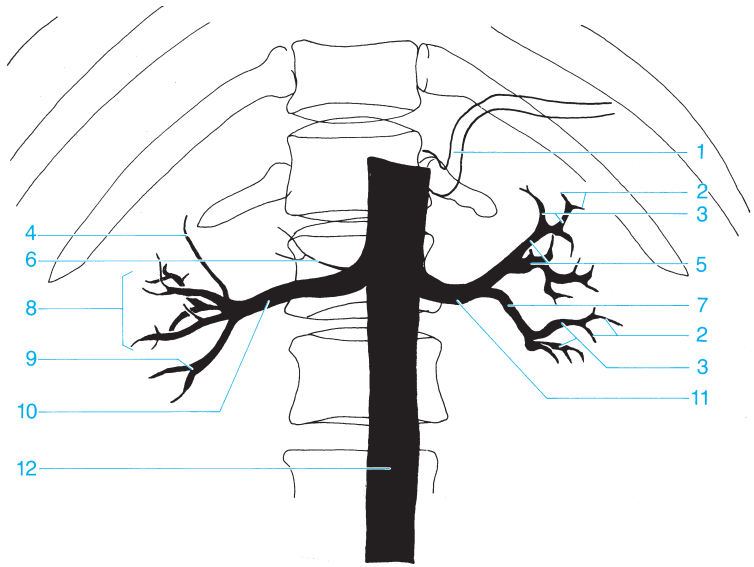




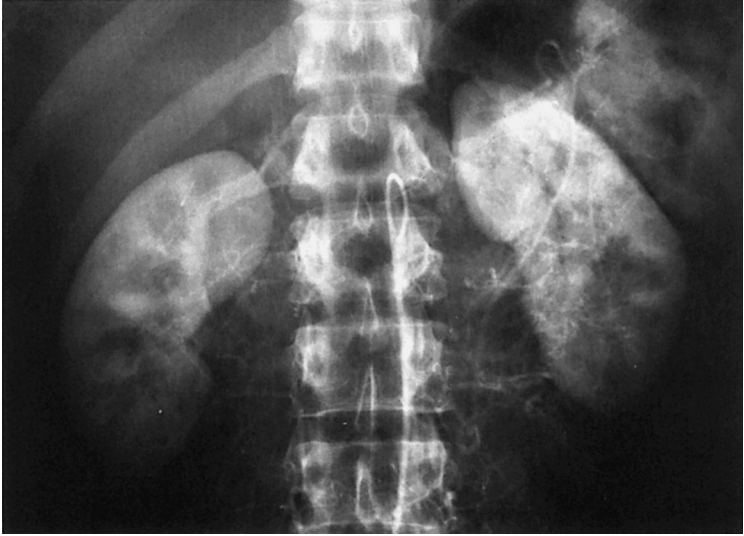- |   |                                 |    |                          |
|---|---------------------------------|----|--------------------------|
| 1 | Left branch of the portal vein  | 6  | Superior mesenteric vein |
| 2 | Right branch of the portal vein | 7  | Right colic vein         |
| 3 | Portal vein                     | 8  | Jejunum veins            |
| 4 | Splenic vein                    | 9  | Ileocolic vein           |
| 5 | Confluence                      | 10 | Ileum veins              |

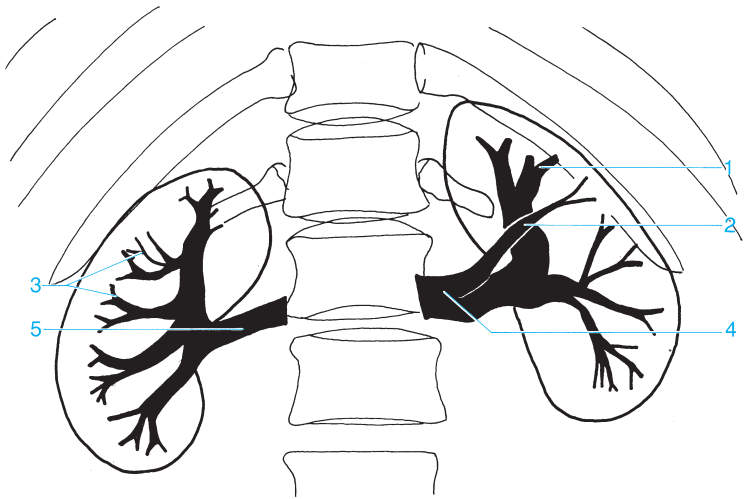




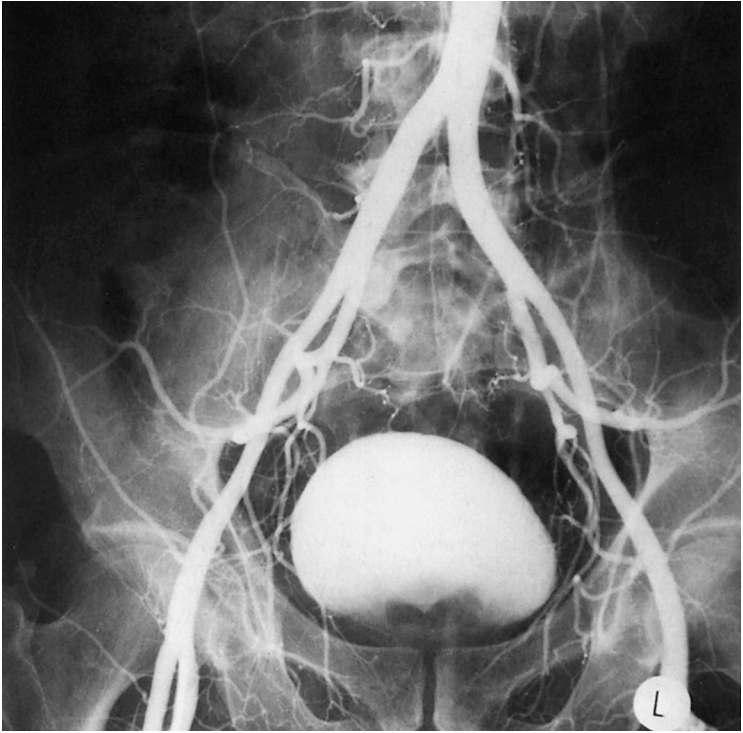


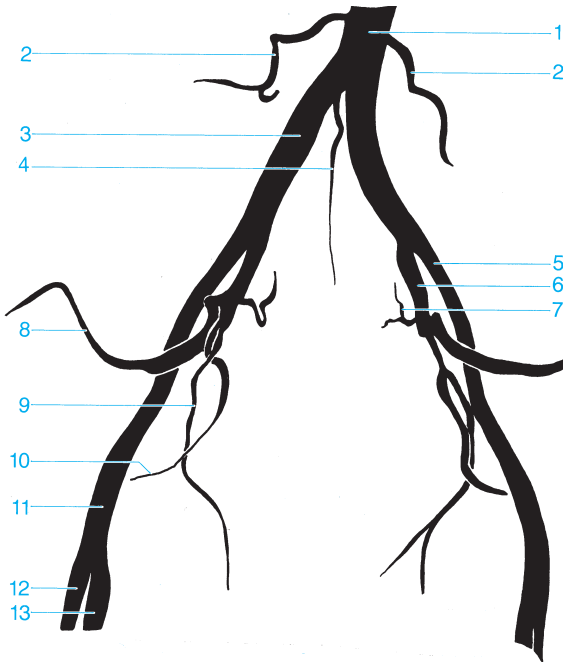
- |  |   |
|--|---|
| 1 Splenic artery                       | 7 Segmental arteries (posterior branch) |
| 2 Arcuate arteries                     | 8 Middle segmental artery               |
| 3 Interlobular arteries                | 9 Inferior segmental artery             |
| 4 Superior segmental artery            | 10 Right renal artery                   |
| 5 Segmental arteries (anterior branch) | 11 Left renal artery                    |
| 6 Inferior adrenal artery              | 12 Abdominal aorta                      |





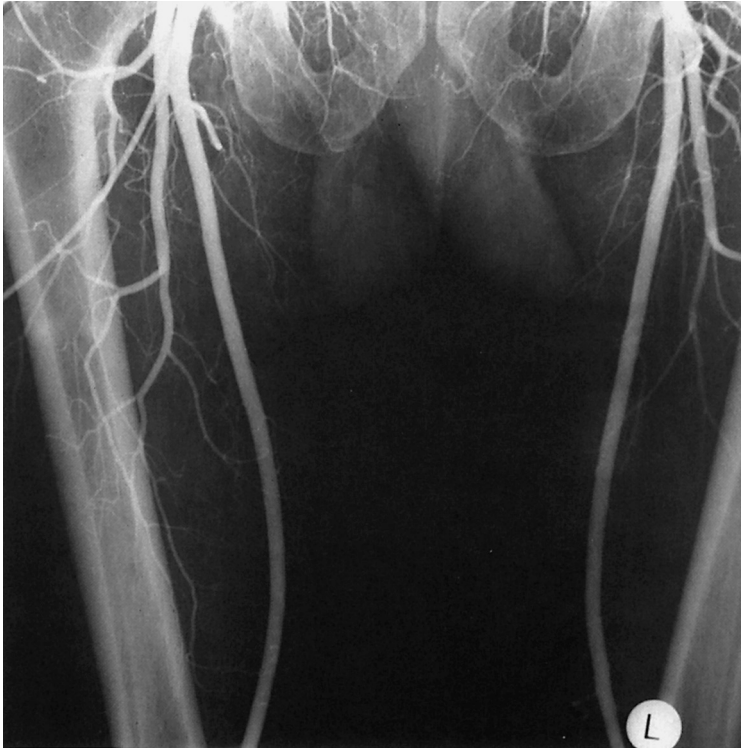
- |                                     |                    |
|-------------------------------------|--------------------|
| 1 Interlobular vein                 | 4 Left renal vein  |
| 2 Superior branch of the renal vein | 5 Right renal vein |
| 3 Arcuate vein                      |                    |


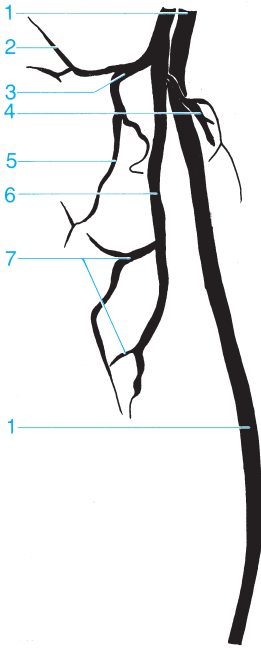




- 1 Abdominal aorta
- 2 Lumbar artery
- 3 Common iliac artery
- 4 Median sacral artery
- 5 External iliac artery
- 6 Internal iliac artery
- 7 Lateral sacral artery

- 8 Superior gluteal artery
- 9 Obturator artery
- 10 Inferior gluteal artery
- 11 Common femoral artery
- 12 Deep femoral artery
- 13 Superficial femoral artery

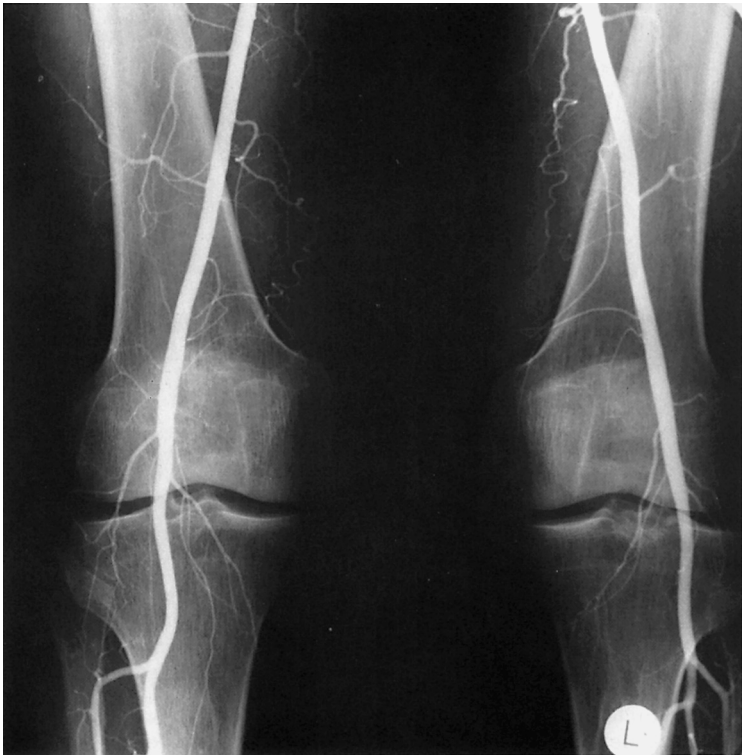

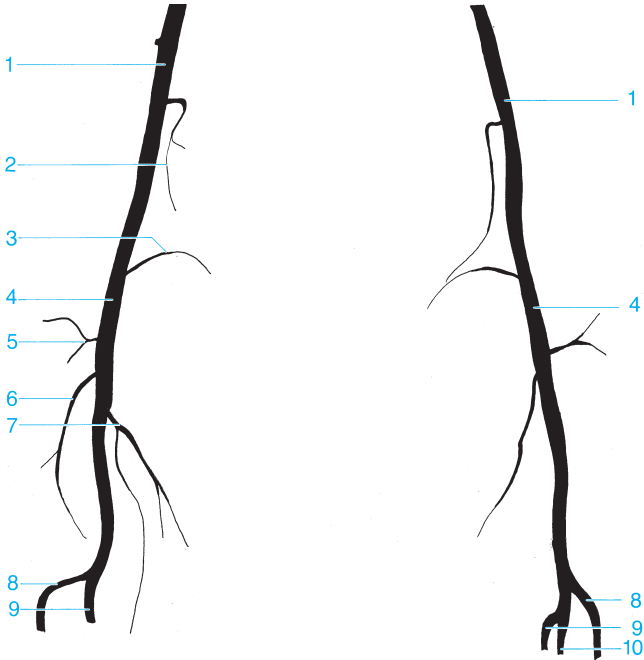


- 1 Superficial femoral artery
- 2 Ascending branch of the lateral femoral circumflex artery
- 3 Lateral femoral circumflex artery
- 4 Medial femoral circumflex artery

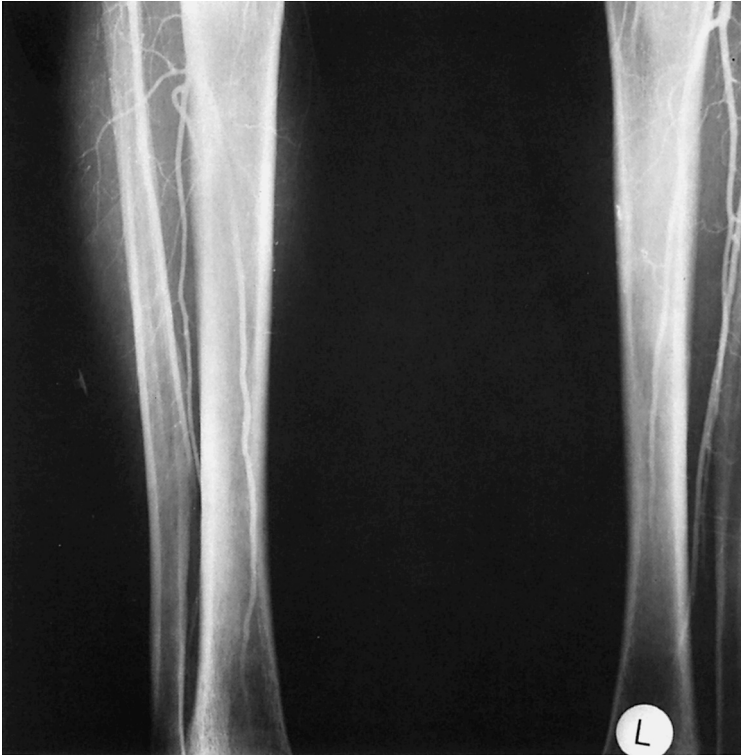- 5 Descending branch of the lateral femoral circumflex artery
- 6 Deep femoral artery
- 7 Perforating artery

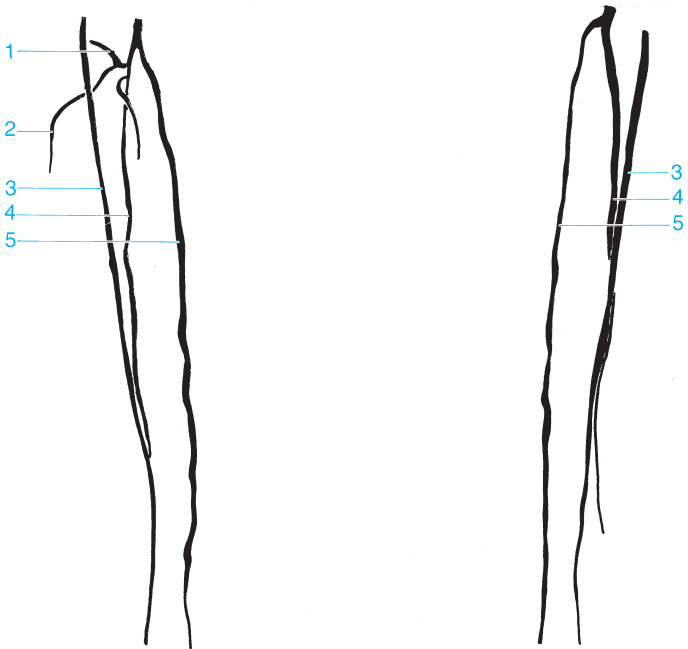






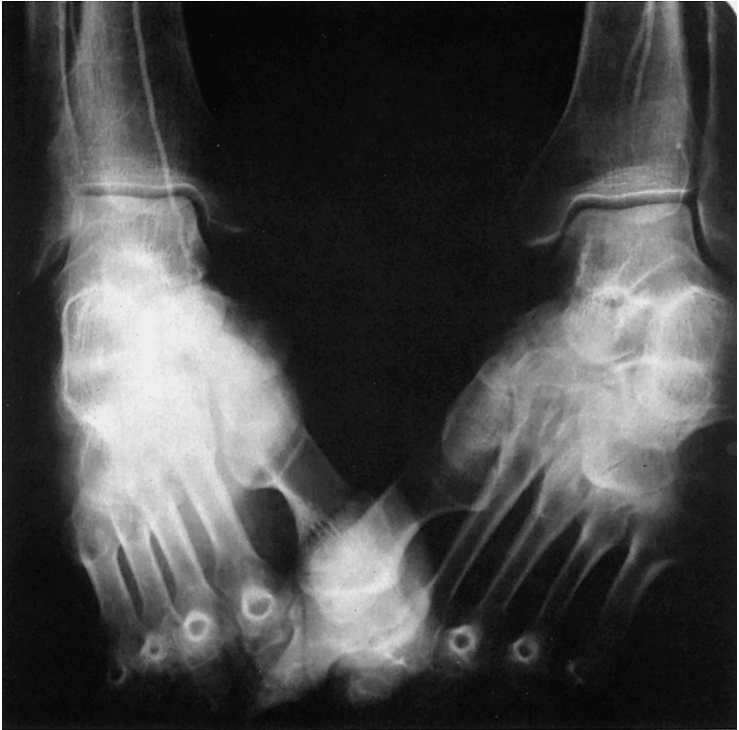- |                                     |                                    |
|-------------------------------------|------------------------------------|
| 1 Superficial femoral artery        | 6 Middle genicular artery          |
| 2 Descending genicular artery       | 7 Inferior medial genicular artery |
| 3 Superior medial genicular artery  | 8 Anterior tibial artery           |
| 4 Popliteal artery                  | 9 Posterior tibial artery          |
| 5 Superior lateral genicular artery | 10 Peroneal artery                 |

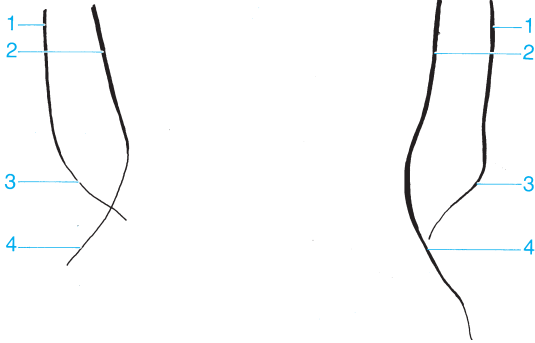




- 1 Circumflex fibular artery
- 2 Muscular branch
- 3 Anterior tibial artery

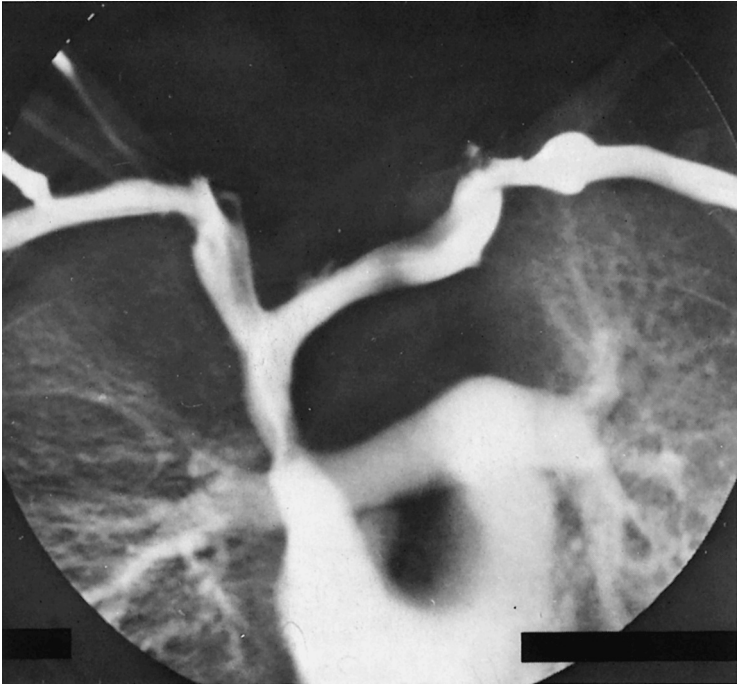
- 4 Peroneal artery
- 5 Posterior tibial artery

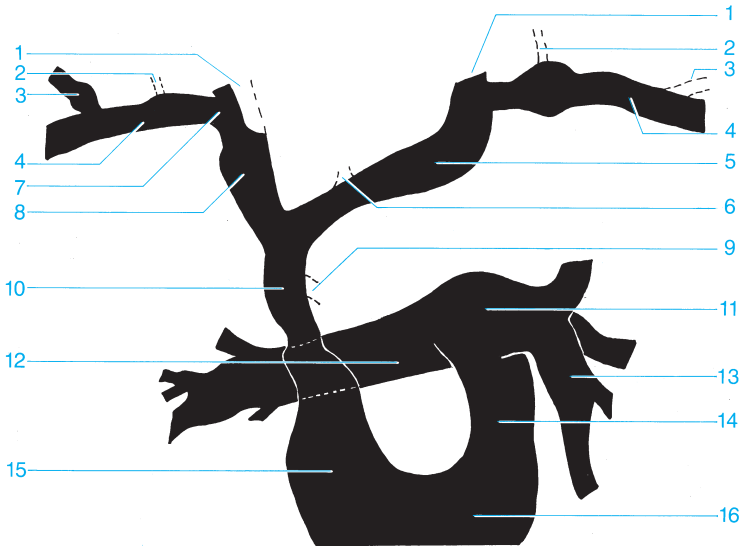




- 1 Anterior tibial artery
- 2 Posterior tibial artery

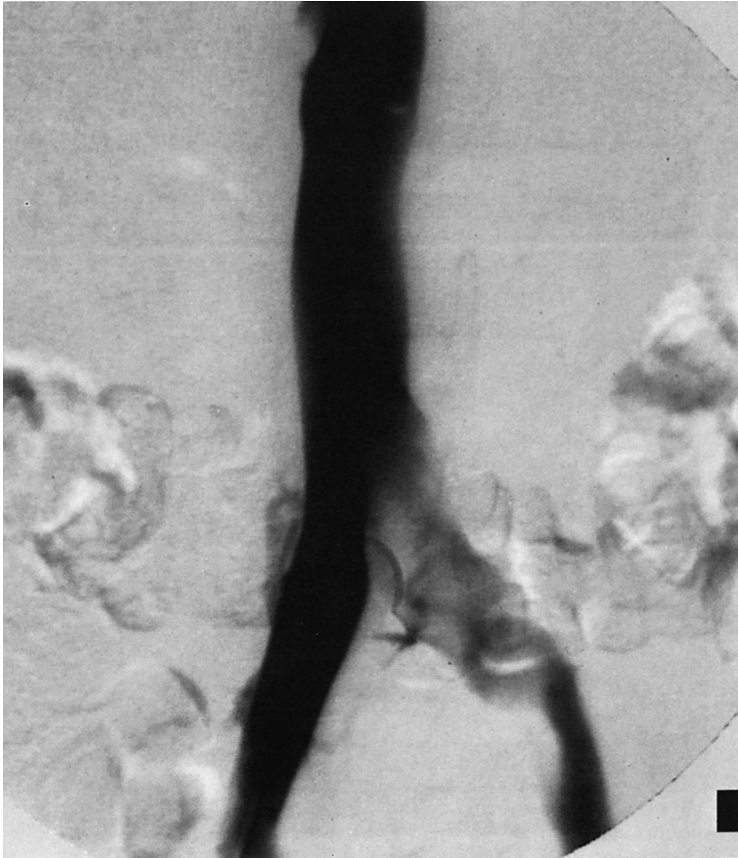- 3 Dorsalis pedis artery
- 4 Plantar artery

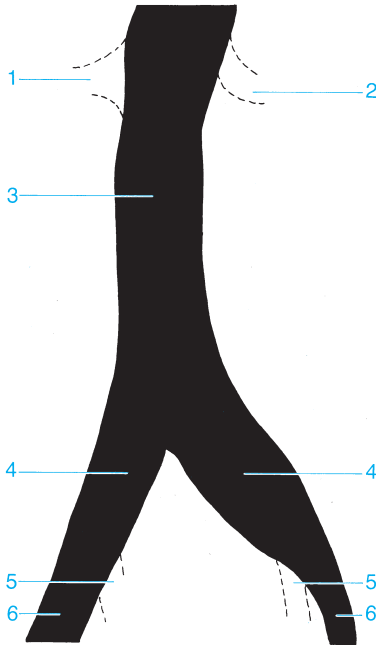




- |                              |                           |
|------------------------------|---------------------------|
| 1 Internal jugular vein      | 9 Azygos vein             |
| 2 External jugular vein      | 10 Superior vena cava     |
| 3 Cephalic vein              | 11 Pulmonary trunk        |
| 4 Subclavian vein            | 12 Right pulmonary artery |
| 5 Left brachiocephalic vein  | 13 Left pulmonary artery  |
| 6 Inferior thyroid vein      | 14 Infundibulum           |
| 7 Venous angle               | 15 Right atrium           |
| 8 Right brachiocephalic vein | 16 Right ventricle        |

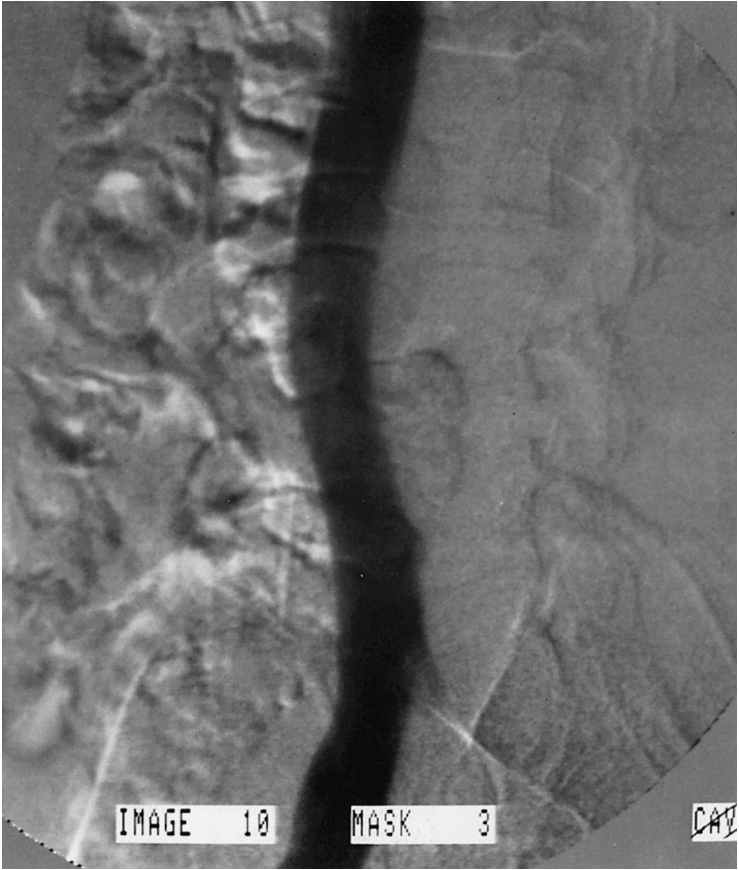

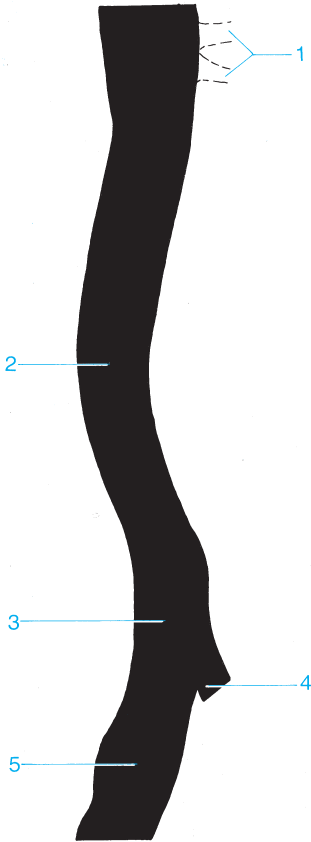




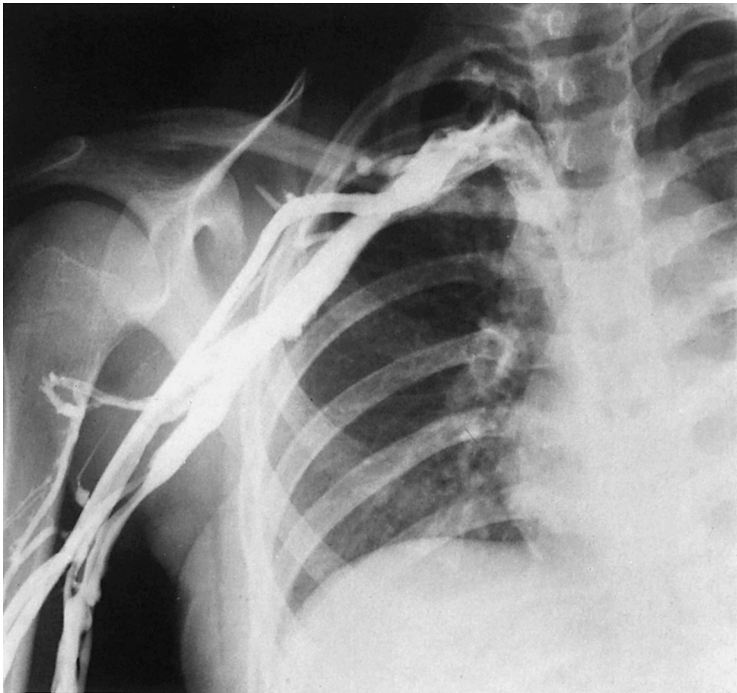
- 1 Right renal vein
- 2 Left renal vein
- 3 Inferior vena cava

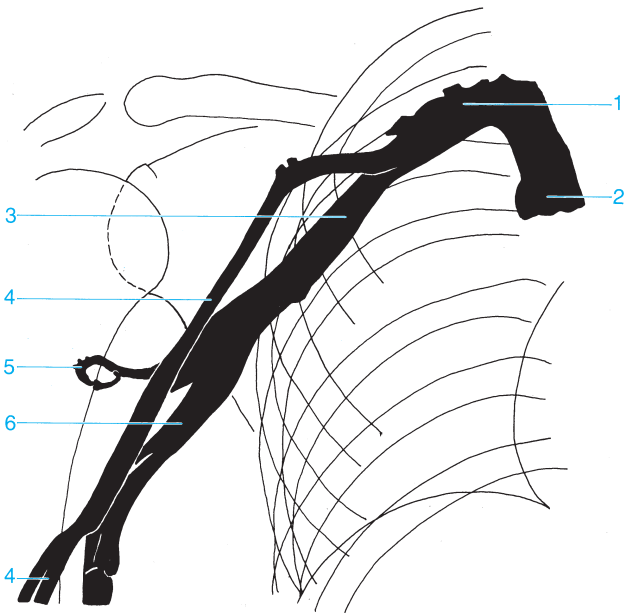
- 4 Common iliac vein
- 5 Internal iliac vein
- 6 External iliac vein





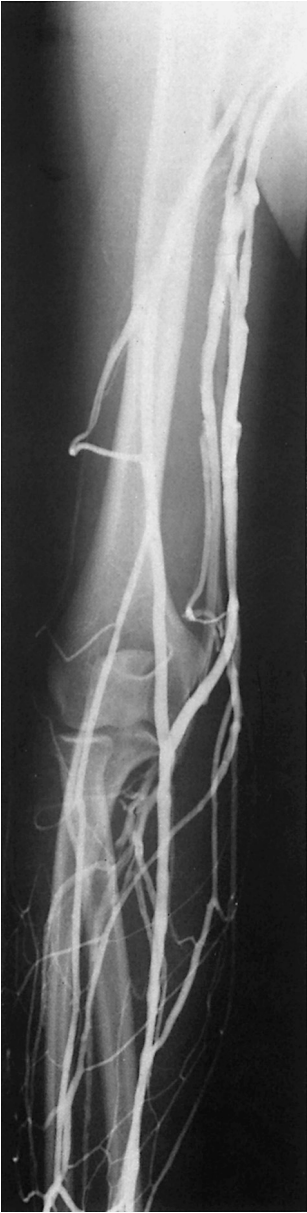- 1 Renal veins
- 2 Inferior vena cava
- 3 Common iliac vein
- 4 Internal iliac vein
- 5 External iliac vein

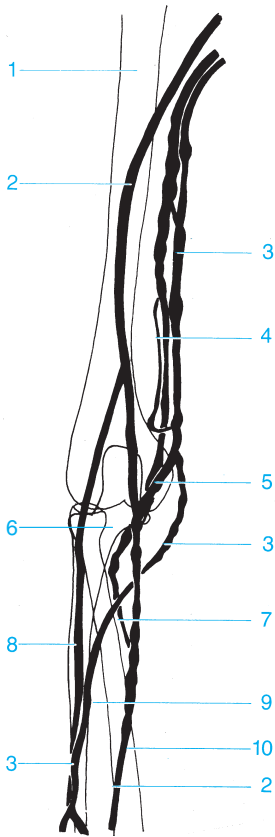




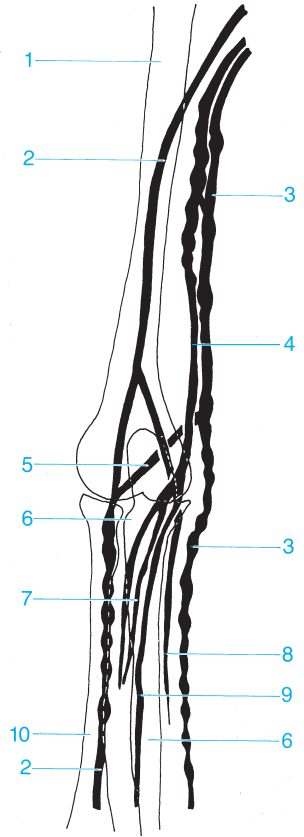
- 1 Subclavian vein
- 2 Superior vena cava
- 3 Axillary vein

- 4 Cephalic vein
- 5 Deep veins of the arm
- 6 Brachial veins





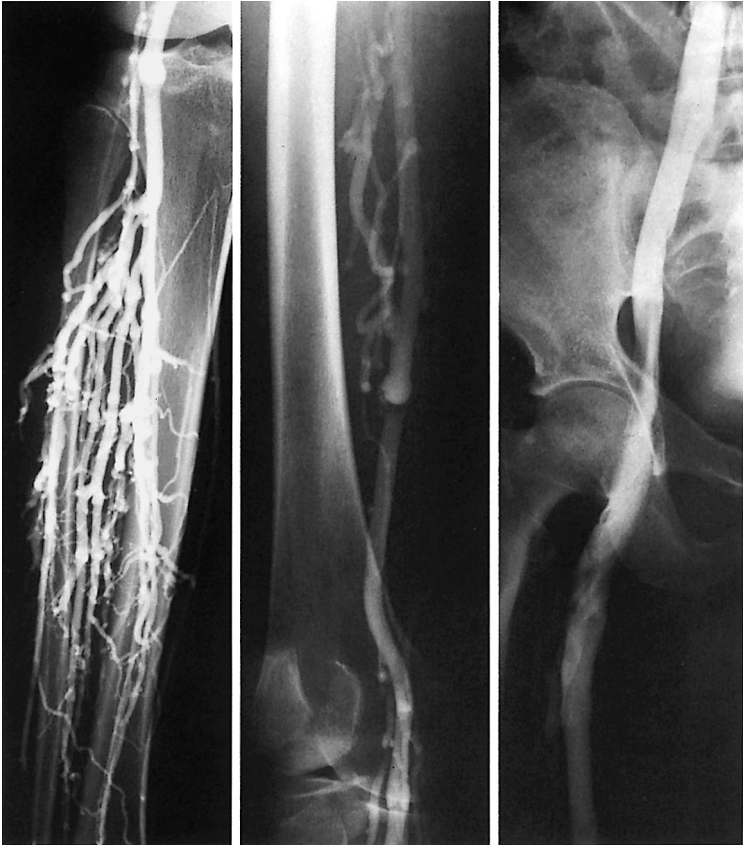Pronation

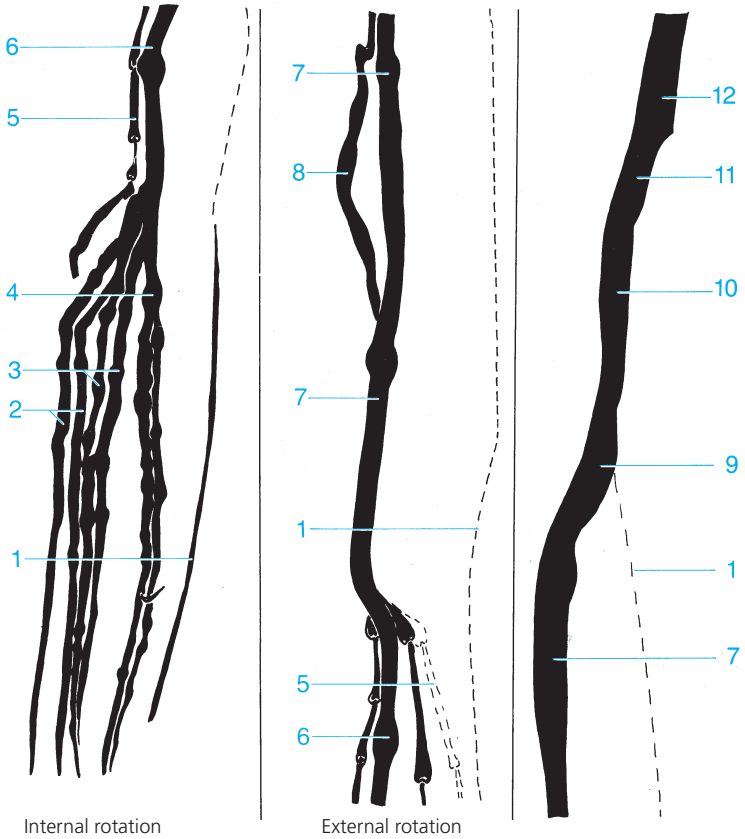


Supination

- |                       |                            |
|-----------------------|----------------------------|
| 1 Humerus             | 6 Ulna                     |
| 2 Cephalic vein       | 7 Radial veins             |
| 3 Basilic vein        | 8 Ulnar veins              |
| 4 Brachial vein       | 9 Median antebrachial vein |
| 5 Median cubital vein | 10 Radius                  |







- 1 Great saphenous vein
- 2 Anterior tibial veins
- 3 Peroneal veins
- 4 Posterior tibial veins
- 5 Small saphenous vein
- 6 Popliteal vein

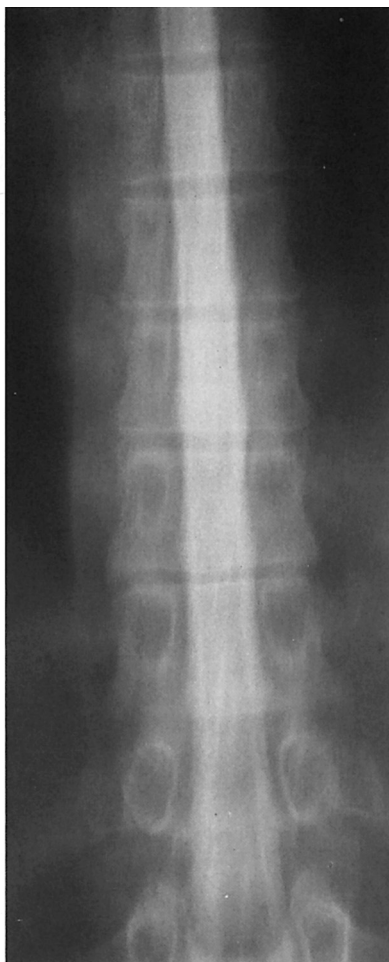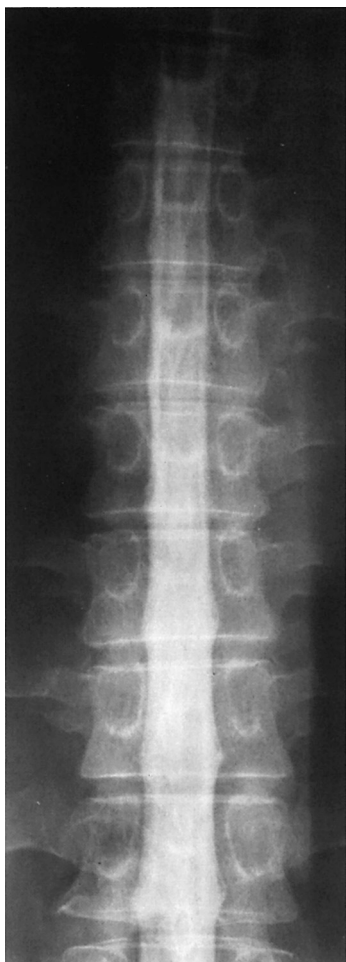- 7 Superficial femoral vein
- 8 Deep femoral vein
- 9 Femoral vein
- 10 External iliac vein
- 11 Common iliac vein
- 12 Inferior vena cava

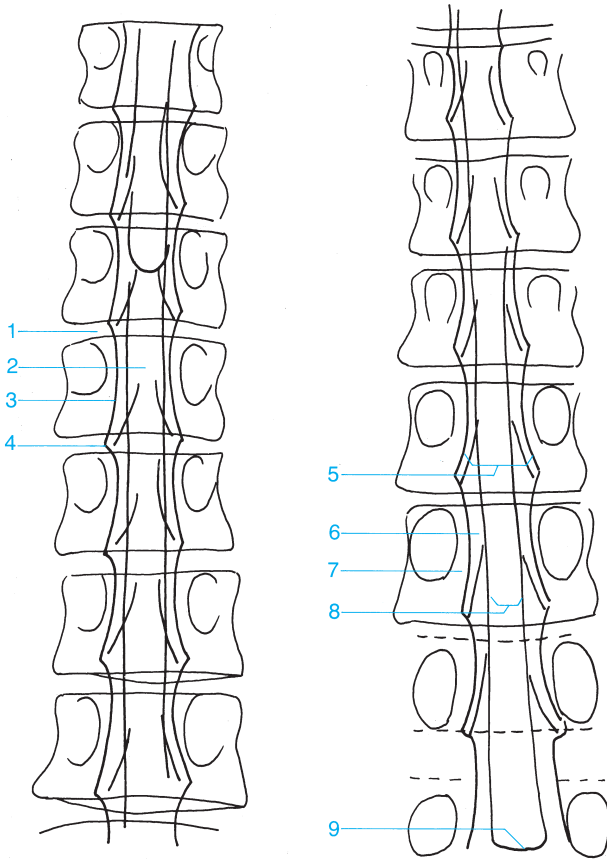


---

## Special Studies

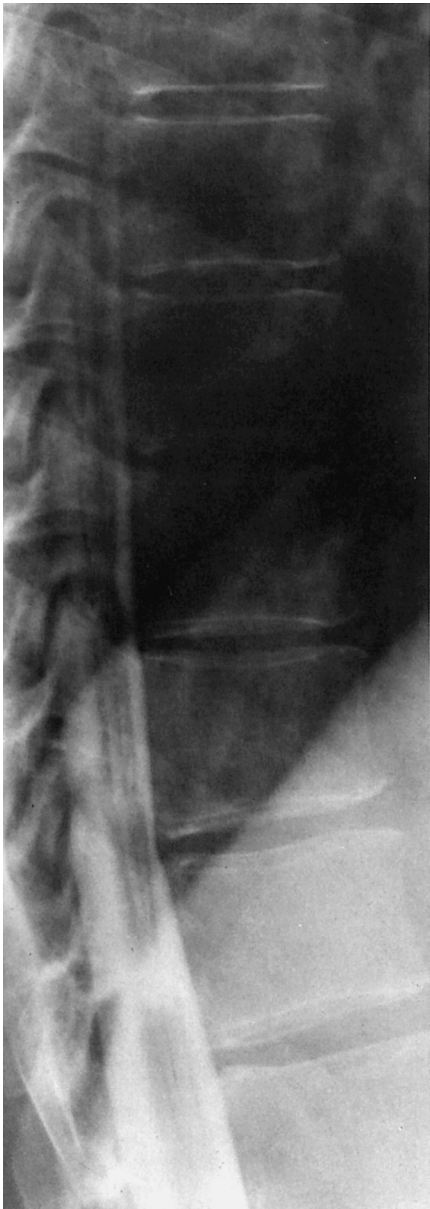
---

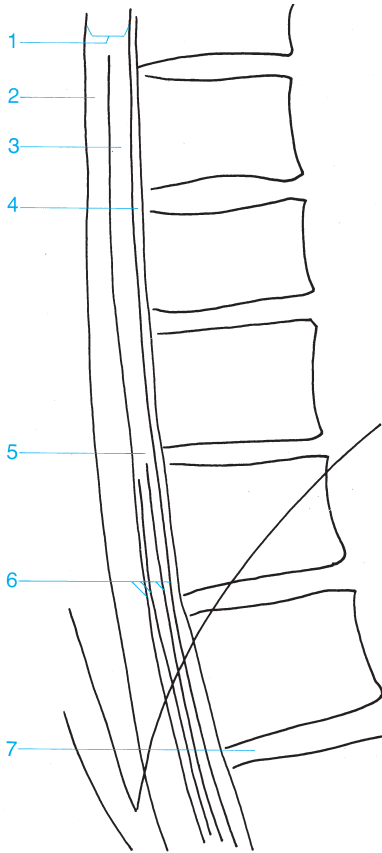




- 1 Intervertebral disk
- 2 Spinal cord
- 3 Lateral margin of the dural sac
- 4 Nerve root sheath
- 5 Intradural space

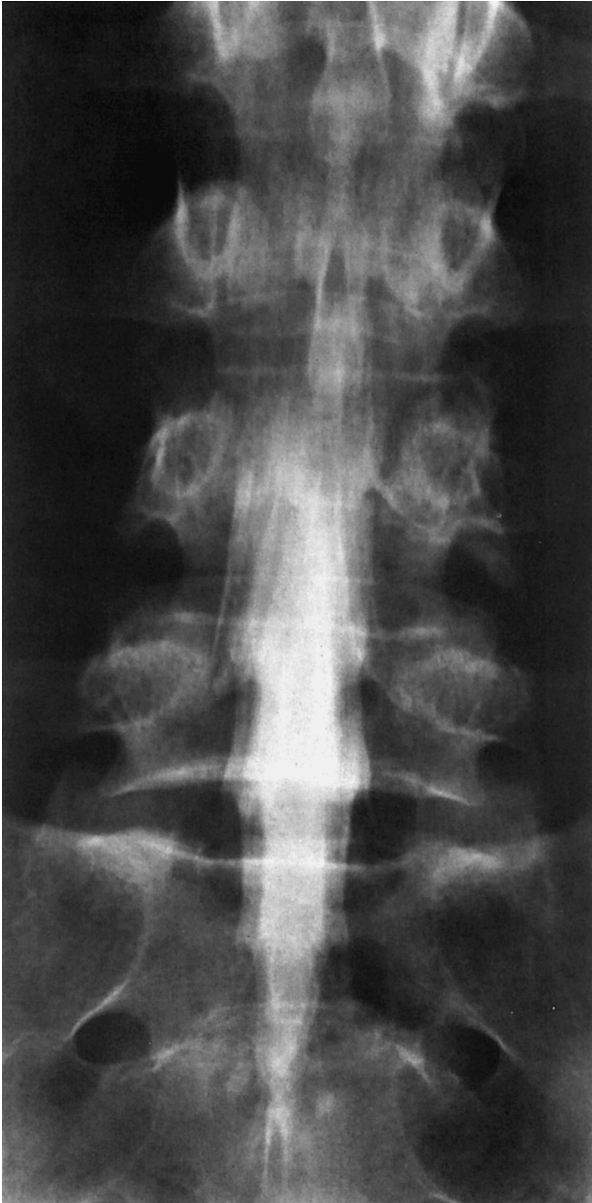- 6 Lateral subarachnoid space
- 7 Extradural space
- 8 Intramedullary region
- 9 Medullary cone

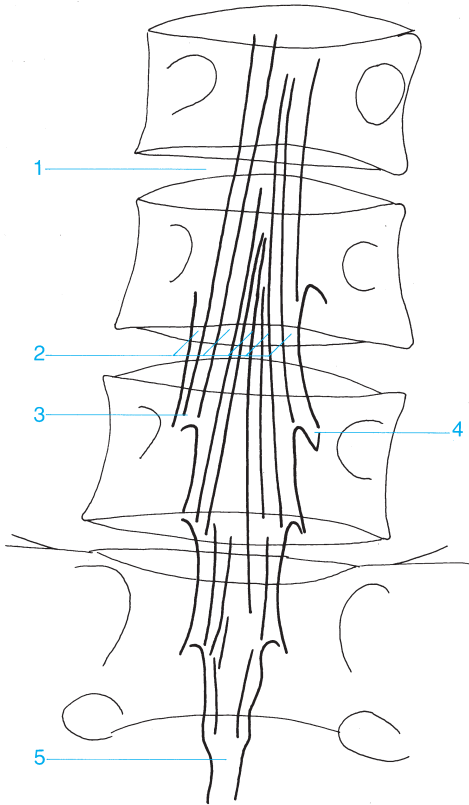




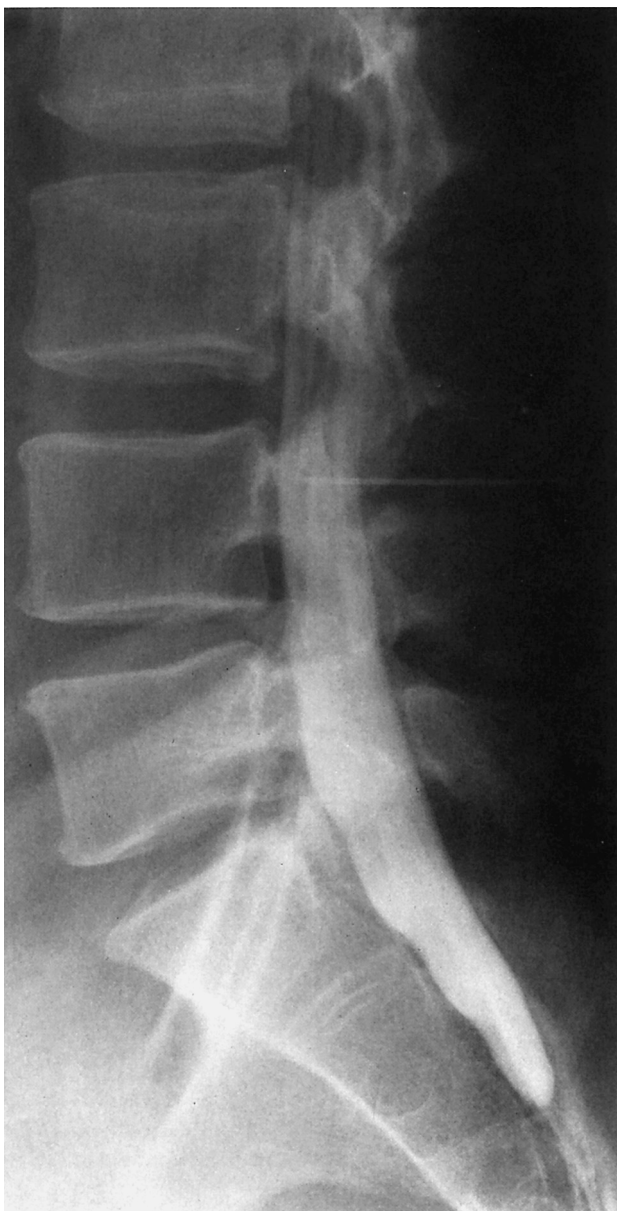
- |                                |                       |
|--------------------------------|-----------------------|
| 1 Dural sac                    | 5 Medullary cone      |
| 2 Posterior subarachnoid space | 6 Cauda equina        |
| 3 Spinal cord                  | 7 Intervertebral disk |
| 4 Anterior subarachnoid space  |                       |

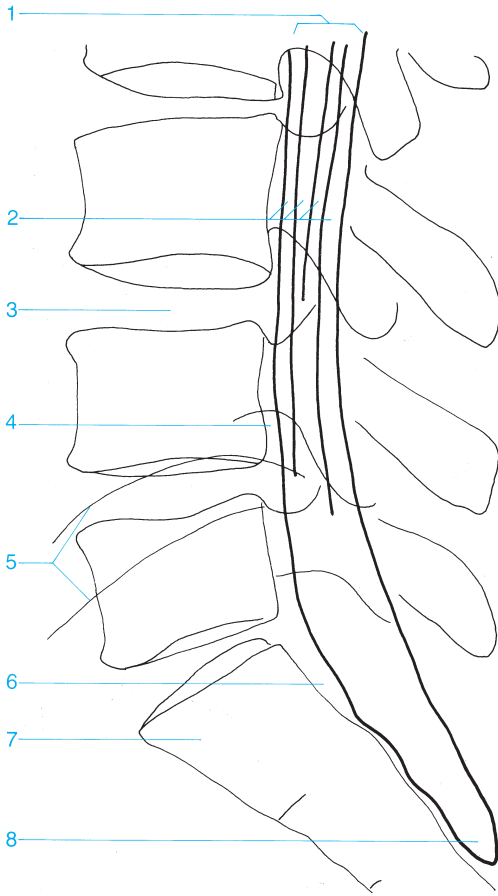




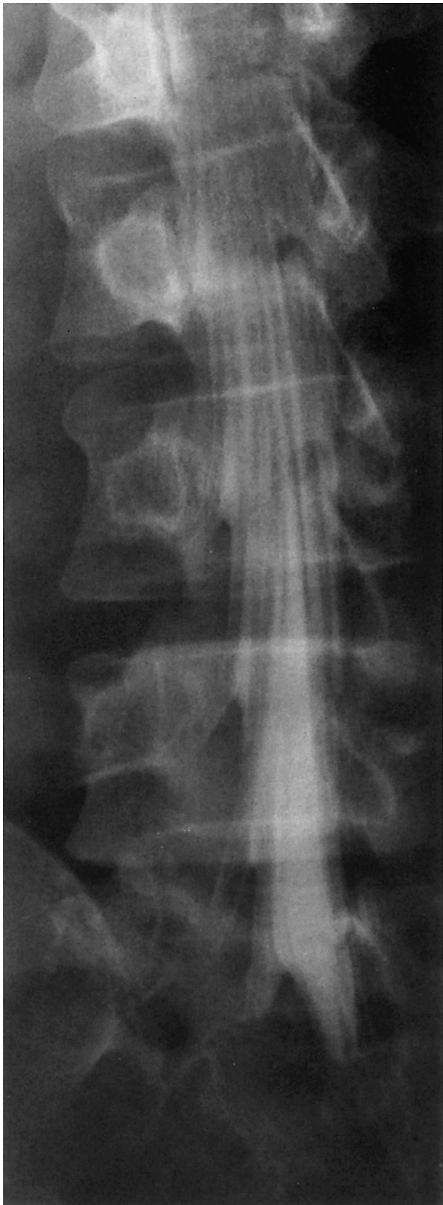

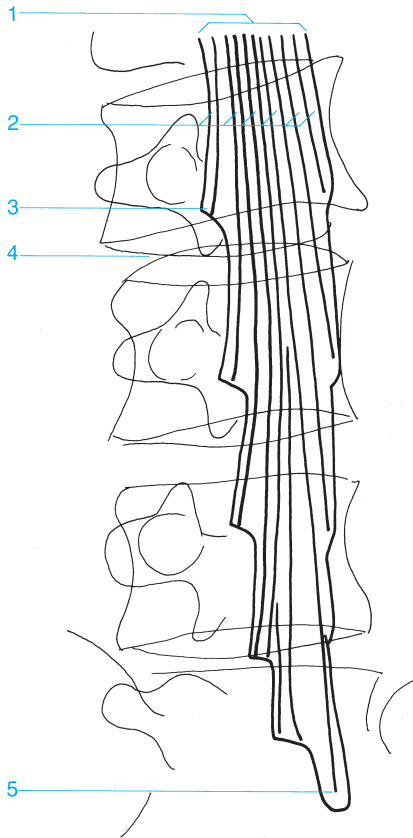
- |   |                               |
|---|-------------------------------|
| 1 Intervertebral disk                         | 4 Nerve root sheath           |
| 2 Cauda equina                                | 5 Distal end of the dural sac |
| 3 Spinal nerve root in the subarachnoid space |                               |





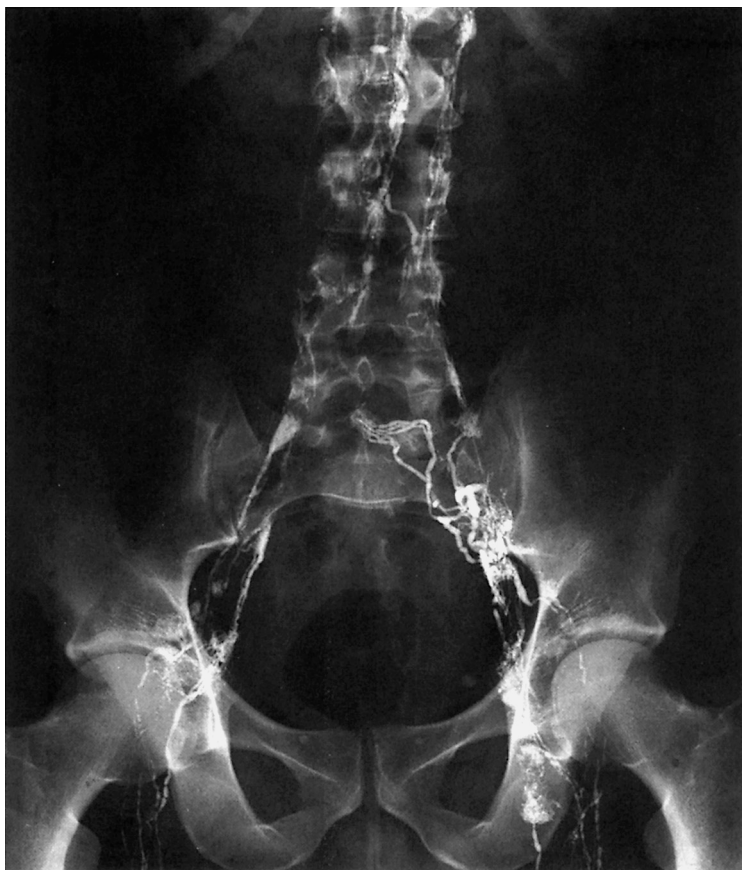- |                          |                               |
|--------------------------|-------------------------------|
| 1 Dural sac              | 5 Iliac crest                 |
| 2 Cauda equina           | 6 Epidural fat                |
| 3 Intervertebral disk    | 7 Sacrum                      |
| 4 Intervertebral foramen | 8 Distal end of the dural sac |

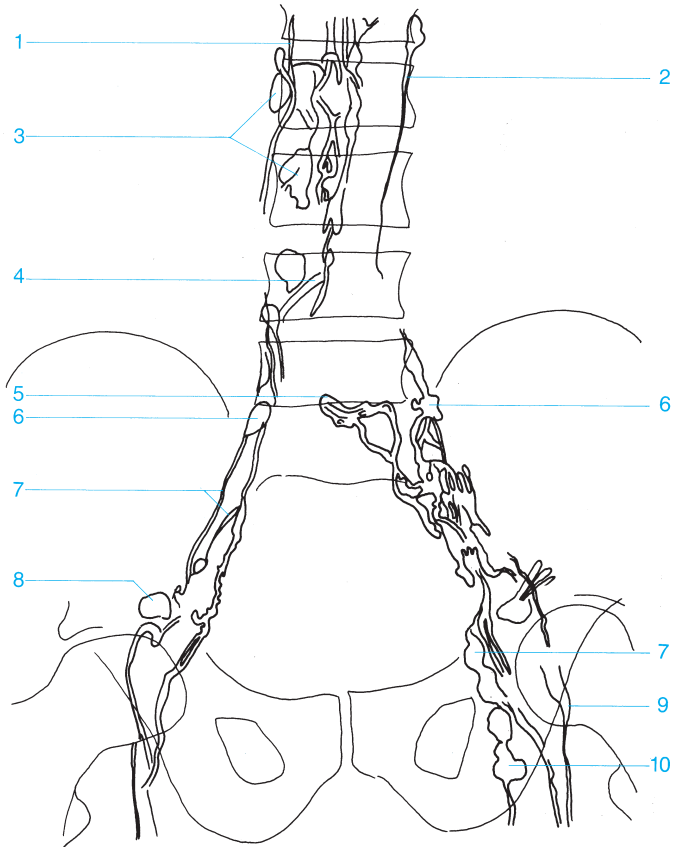




- 1 Dural sac
- 2 Cauda equina
- 3 Nerve root sheath, L3

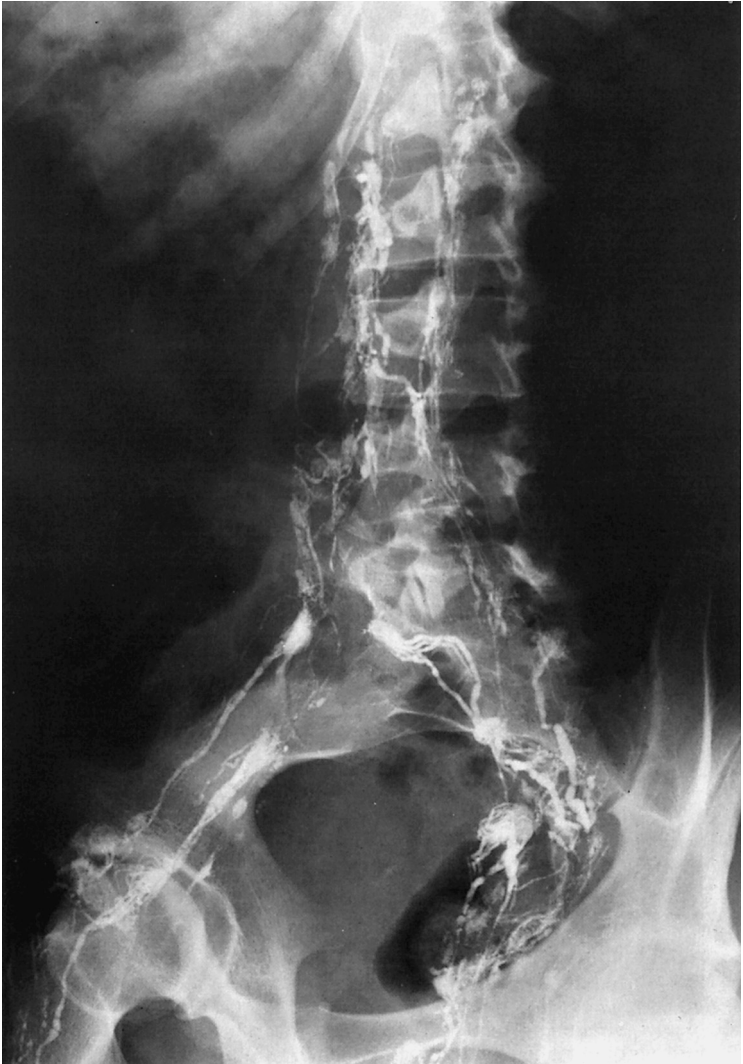- 4 Intervertebral disk L3-4
- 5 Distal end of the dural sac (usually at the level of S1 or S2)

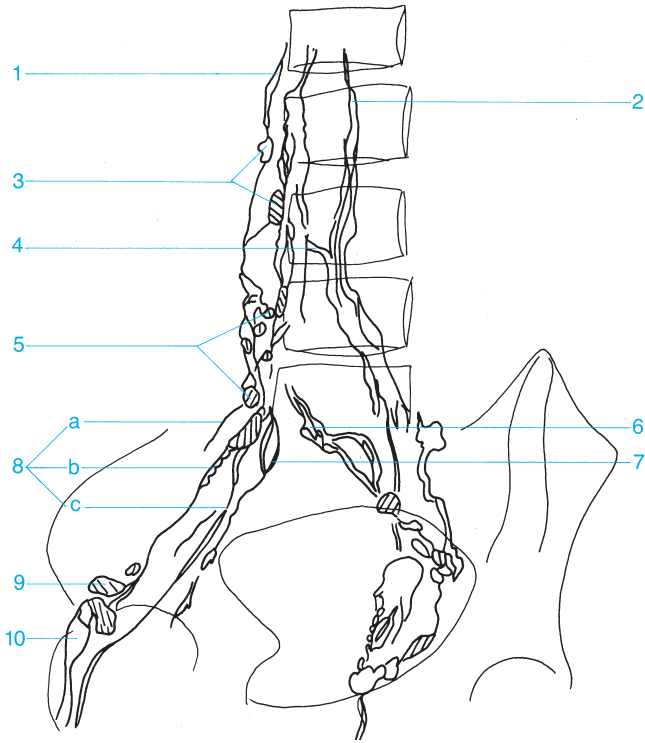




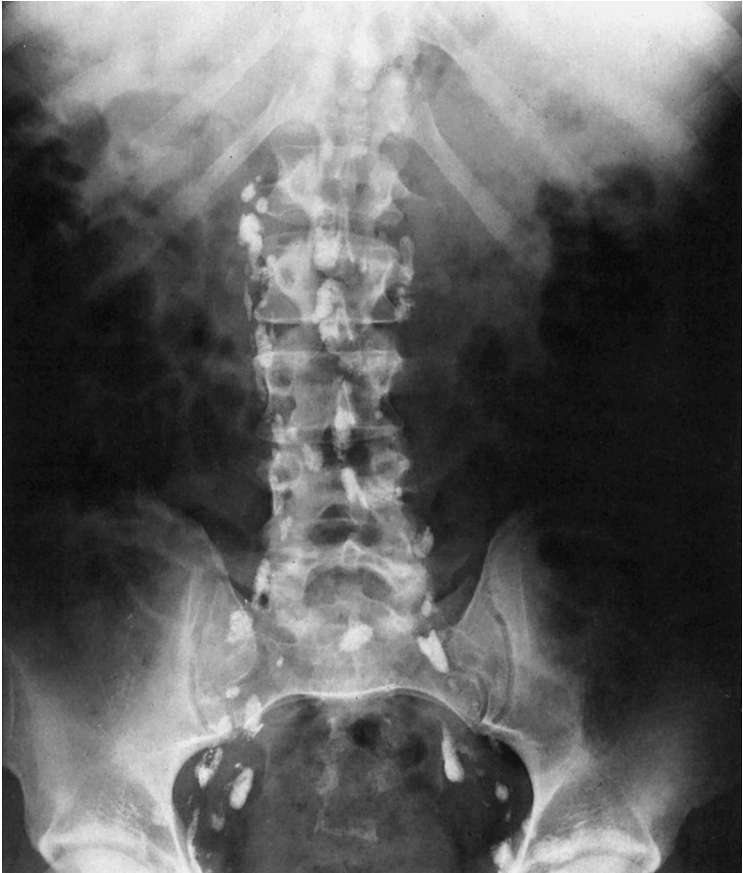- |                            |  |
|----------------------------|--|
| 1 Right lumbar trunk       | 7 Lymph channels of the external iliac lymph nodes |
| 2 Left lumbar trunk        | 8 Lateral lacunar lymph nodes                      |
| 3 Lumbar lymph nodes       | 9 Superficial inguinal lymph nodes                 |
| 4 Crossover                | 10 Deep inguinal lymph nodes                       |
| 5 Promontory lymph nodes   |  |
| 6 Common iliac lymph nodes |  |

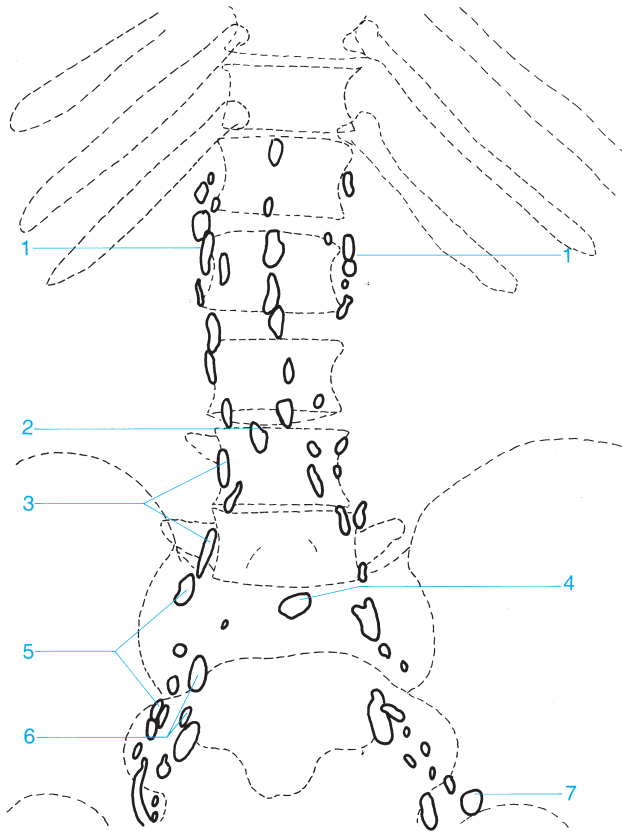




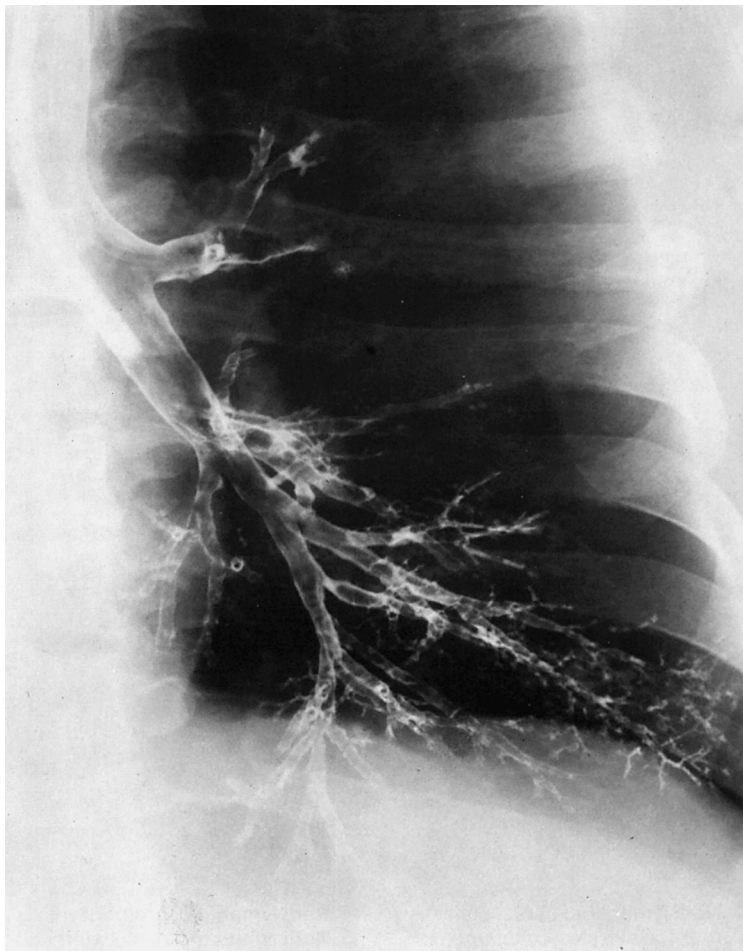


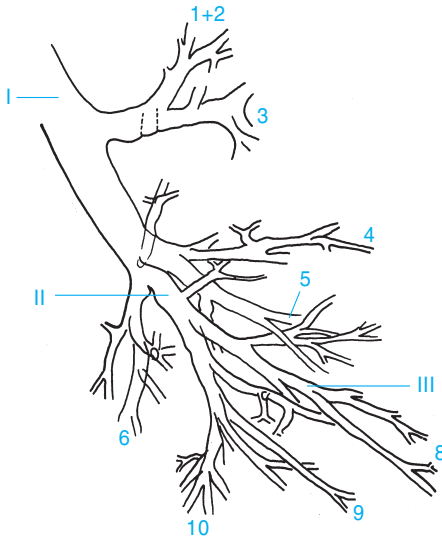
- |  |   |
|--|---|
| <ul style="list-style-type: none"> <li><b>1</b> Right lumbar trunk</li> <li><b>2</b> Left lumbar trunk</li> <li><b>3</b> Lumbar lymph nodes</li> <li><b>4</b> Crossover</li> <li><b>5</b> Common iliac lymph nodes</li> <li><b>6</b> Promontory lymph nodes</li> <li><b>7</b> Lymph channels connecting the internal iliac lymph nodes with the external and common iliac lymph nodes</li> </ul> | <ul style="list-style-type: none"> <li><b>8</b> External and common iliac lymph nodes                             <ul style="list-style-type: none"> <li>a External chain</li> <li>b Middle chain</li> <li>c Internal chain</li> </ul> </li> <li><b>9</b> Lacunar lymph node</li> <li><b>10</b> Superficial inguinal lymph nodes</li> </ul> |
|--|---|



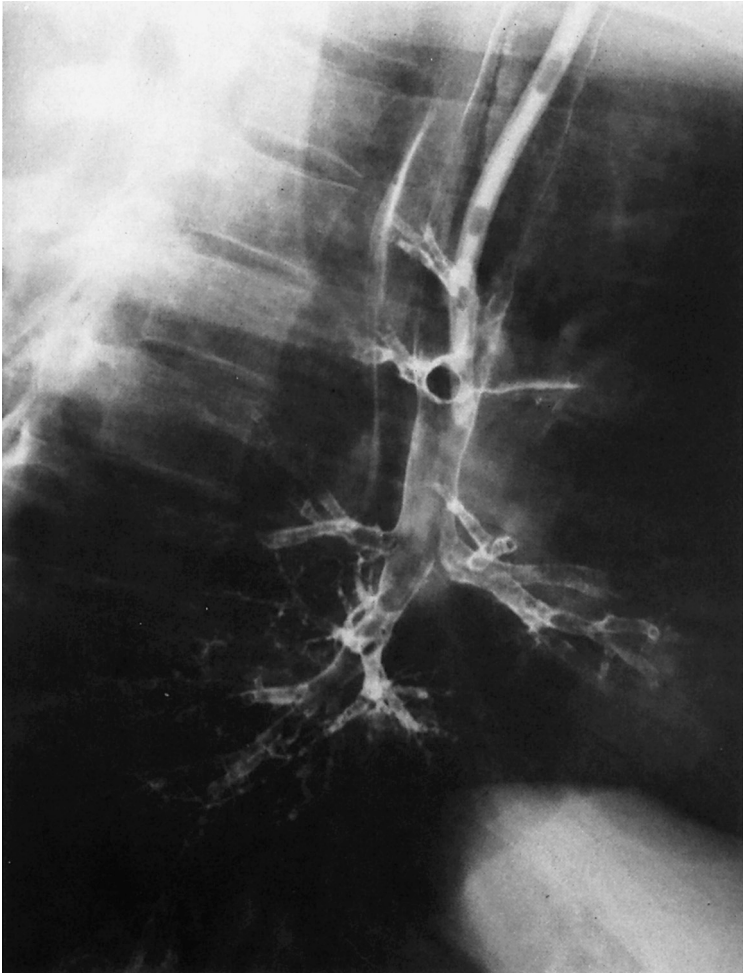

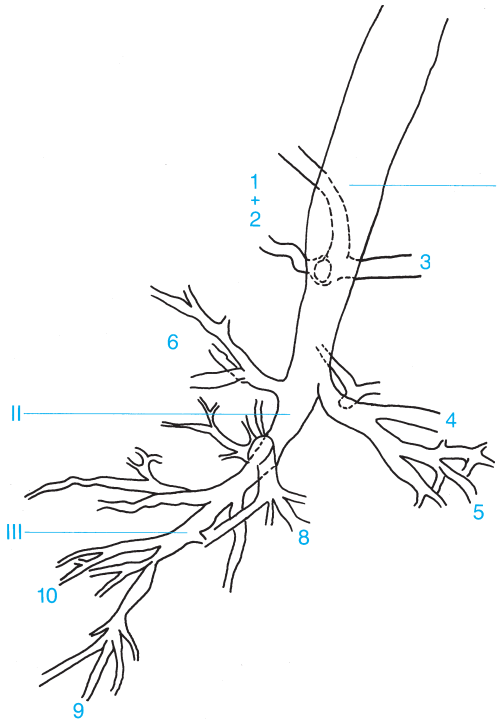
- |  |                              |
|--|------------------------------|
| 1 Para-aortic lymph nodes (lateral aortic, preaortic, and retroaortic) | 4 Promontory lymph nodes     |
| 2 Crossover  | 5 External iliac lymph nodes |
| 3 Common iliac lymph nodes   | 6 Internal iliac lymph nodes |
|  | 7 Lacunar lymph node         |





- |   |   |
|---|---|
| <p><b>1 + 2</b> Apical-posterior segment of the upper lobe</p> <p><b>3</b> Anterior segment of the upper lobe</p> <p><b>4</b> Lingula of the superior segment of the upper lobe</p> <p><b>5</b> Lingula of the inferior segment of the upper lobe</p> <p><b>6</b> Superior segment of the lower lobe</p> <p><b>7</b> Not present on left side</p> | <p><b>8</b> Anterior-medial basal segment of the lower lobe</p> <p><b>9</b> Lateral basal segment of the lower lobe</p> <p><b>10</b> Posterior basal segment of the lower lobe</p> <p><b>I</b> Main bronchus</p> <p><b>II</b> Lobar bronchus</p> <p><b>III</b> Segmental bronchus</p> |
|---|---|

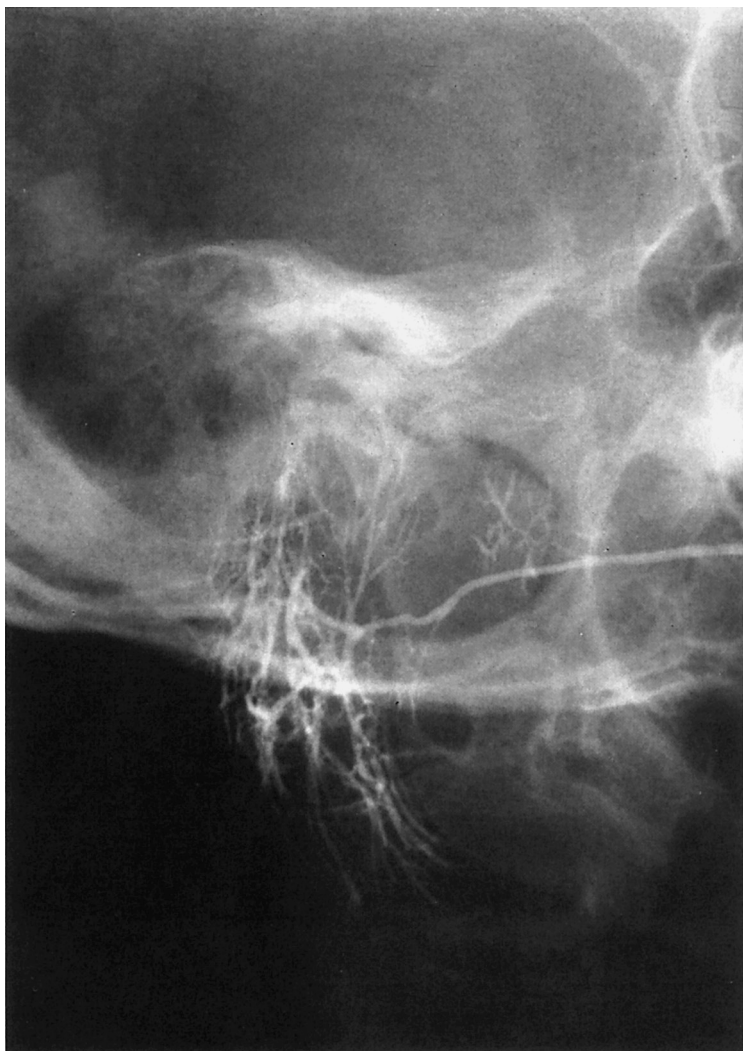


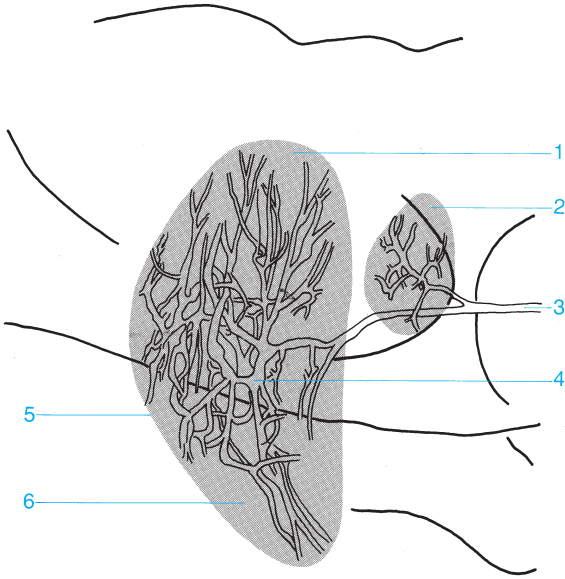


- 1 + 2** Apical-posterior segment of the upper lobe
- 3** Anterior segment of the upper lobe
- 4** Lingula of the superior segment of the upper lobe
- 5** Lingula of the inferior segment of the upper lobe
- 6** Superior segment of the lower lobe
- 7** Not present on left side

- 8** Anterior-medial basal segment of the lower lobe
- 9** Lateral basal segment of the lower lobe
- 10** Posterior basal segment of the lower lobe
- I** Main bronchus
- II** Lobar bronchus
- III** Segmental bronchus

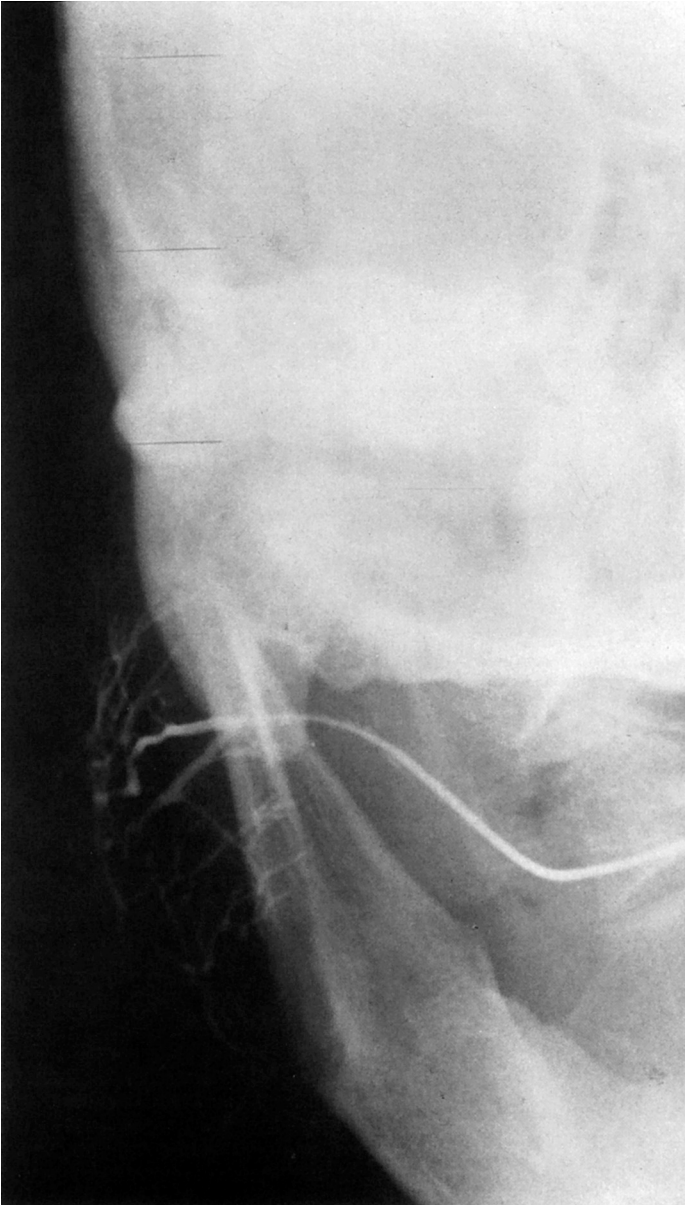


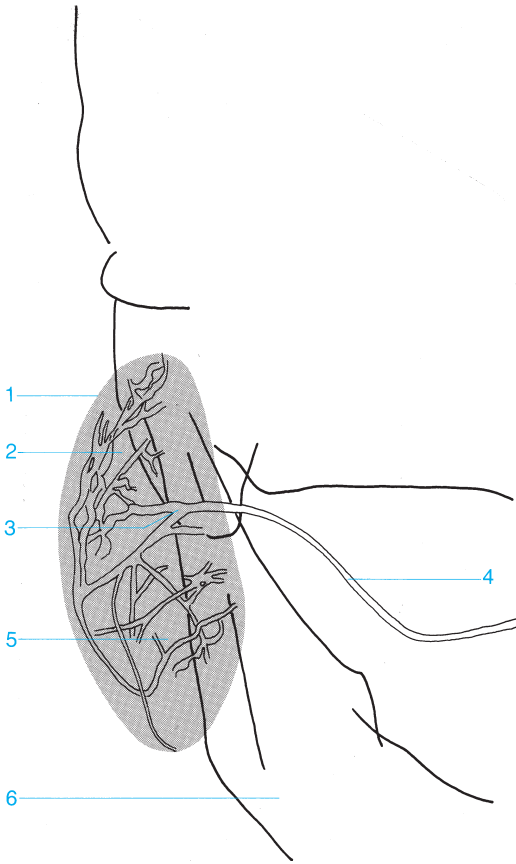




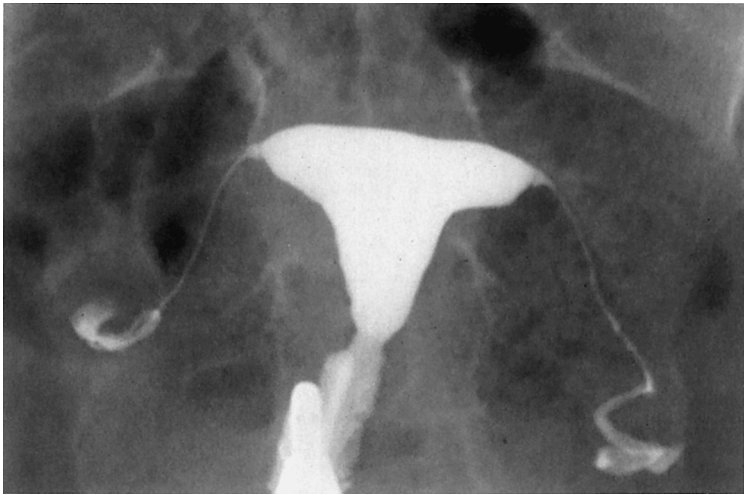
- 1 Superficial lobe of the parotid gland
- 2 Accessory parotid gland
- 3 Parotid duct (Stenson's duct)

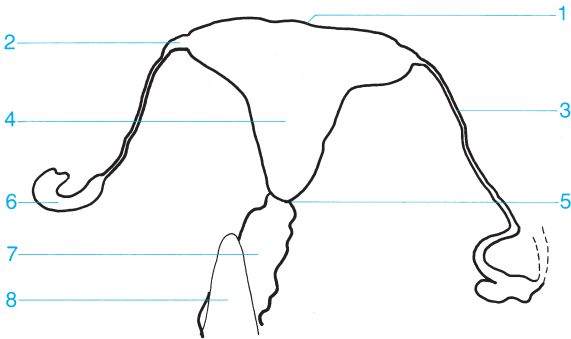- 4 Intralobular ductal system
- 5 Parotid gland
- 6 Deep lobe of the parotid gland (beneath the facial nerve)



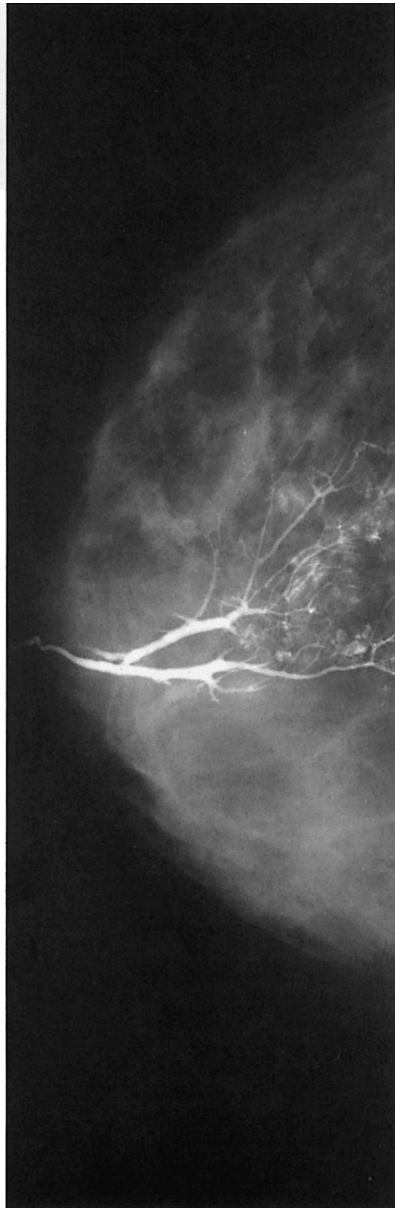
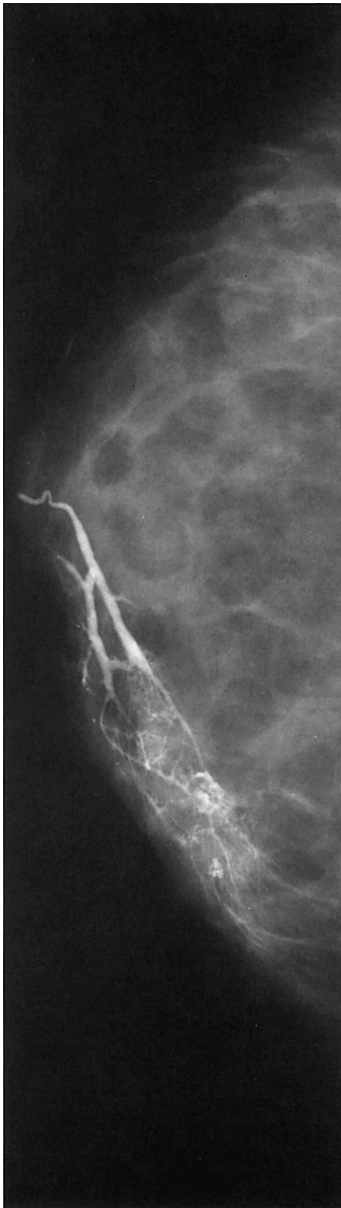

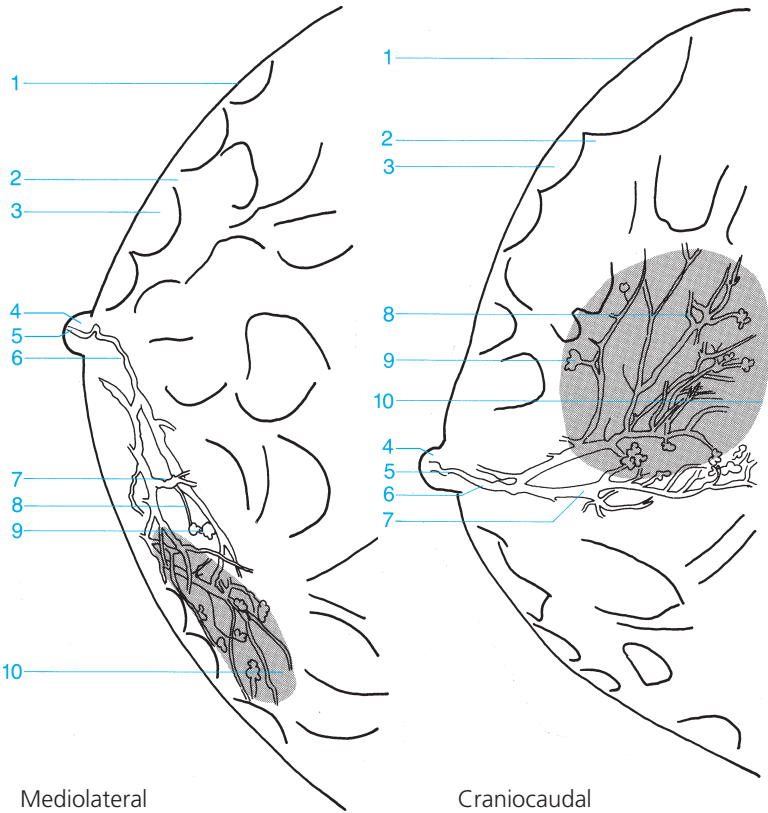
- |  |  |
|--|--|
| <b>1</b> Parotid gland   | <b>4</b> Parotid duct (Stensen's duct)                             |
| <b>2</b> Superficial lobe of the parotid gland (on the facial nerve) | <b>5</b> Deep lobe of the parotid gland (beneath the facial nerve) |
| <b>3</b> Intralobular parotid ductal system                          | <b>6</b> Mandible  |





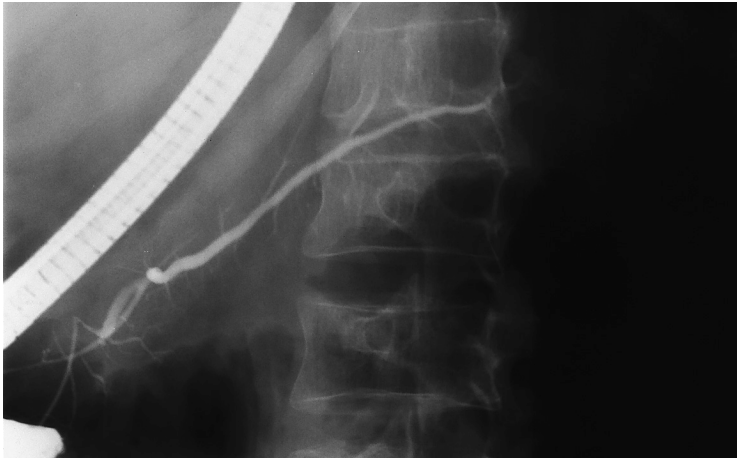
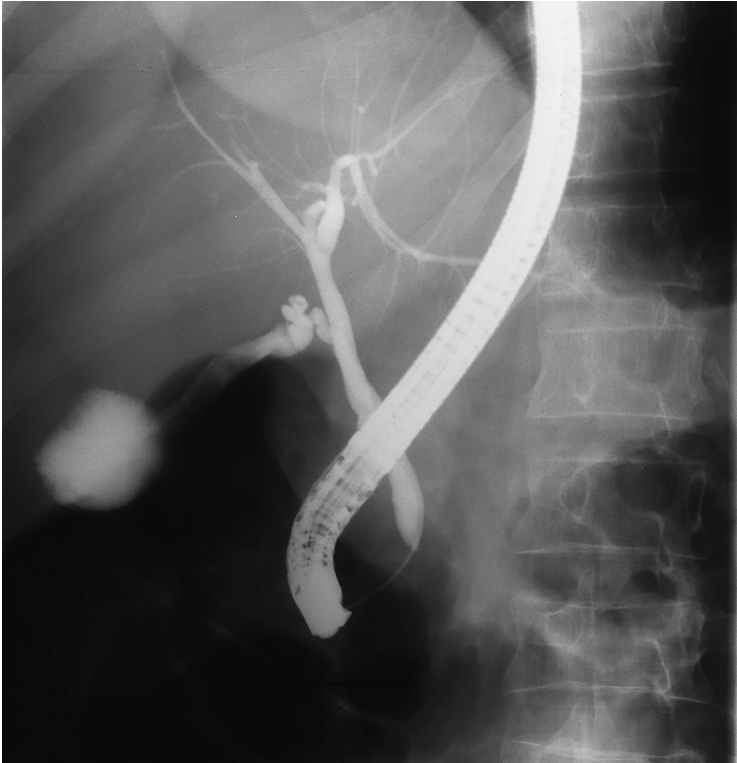- |   |   |
|---|---|
| <b>1</b> Fundus of the uterus                 | <b>5</b> Cervical canal                 |
| <b>2</b> Uterine ostium of the fallopian tube | <b>6</b> Fimbriae of the fallopian tube |
| <b>3</b> Fallopian tube                       | <b>7</b> Vagina                         |
| <b>4</b> Uterine cavity                       | <b>8</b> Instrument                     |

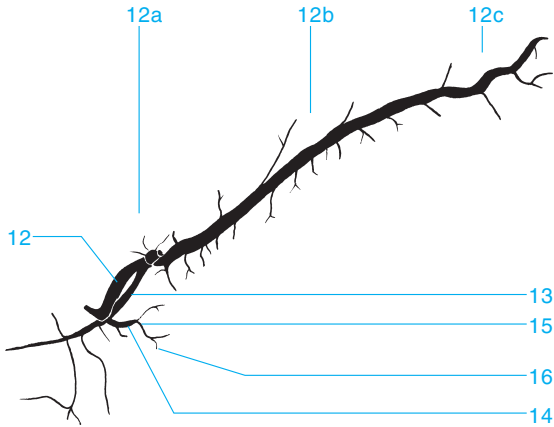
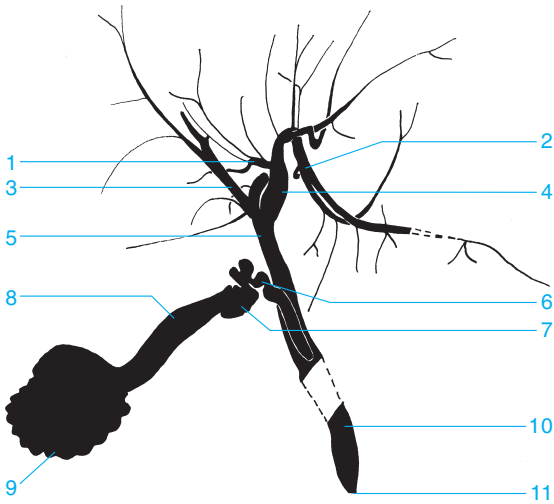




- 1 Skin and subcutaneous tissue
- 2 Cooper's ligament
- 3 Subcutaneous fatty tissue
- 4 Nipple
- 5 Main lactiferous duct posterior to the nipple
- 6 Lactiferous sinus
- 7 Lactiferous duct
- 8 Ductules
- 9 Lobules
- 10 Lobe







- |  |                              |
|--|------------------------------|
| 1 Medial branch of the left hepatic duct | 10 Common bile duct          |
| 2 Lateral branch                         | 11 Papilla of Vater          |
| 3 Right hepatic duct                     | 12 Pancreatic duct           |
| 4 Left hepatic duct                      | a Head region                |
| 5 Common hepatic duct                    | b Body region                |
| 6 Cystic duct                            | c Tail region                |
| 7 Neck of the gallbladder                | 13 Accessory pancreatic duct |
| 8 Body of the gallbladder                | 14 Primary lateral duct      |
| 9 Fundus of the gallbladder              | 15 Secondary lateral duct    |
|  | 16 Tertiary lateral duct     |

## A

- Abdomen
  - muscle, 207
  - subcutaneous fat, 207
  - supine, 207
  - upright, 205
- Abdominal aorta, 297, 301
- Accessory parotid gland, 345
- Acetabulum
  - angle of inclination, 61
  - convexity, 59, 61, 143
  - floor, 67, 69, 143, 145, 149
  - rim
    - anterior, 67, 69, 143, 145, 147, 149, 151
    - posterior, 59, 67, 69, 143, 145, 147, 151
    - superior, 145, 147
  - roof, 61, 67, 69, 71, 143, 147, 149
  - teardrop, 59
- Achilles tendon, 171, 177
- Acromioclavicular joint, 87, 89, 91, 93, 95, 97, 99, 101, 103, 105, 107, 111
- Acromion, 81, 87, 89, 91, 93, 95, 97, 99, 101, 103, 105, 107, 109, 111, 257, 259
- Aditus ad antrum, 35
- Adrenal artery, inferior, 297
- Air cells
  - marginal, 31
  - mastoid, 7, 27, 29, 31
  - periantral, 31, 35
  - retrofacial, 31
  - retrosinus, 35
  - squamous, 31
- Ampulla
  - rectal, 245, 247
  - of Vater, 233, 235, 237
- Anal canal, 247
- Anastomic vein
  - inferior, 271
  - superior, 269, 271
- Angiography
  - ankle, 309
  - aorta
    - arch, 283
    - pelvic, 301
  - celiac trunk
    - arterial phase, 289
    - venous phase, 291
  - foot, 309
  - knee, 305
  - lower leg, 307
  - thigh, 303
- Angle
  - acetabulum, 61
  - of Citelli, 31
  - costophrenic, 193, 205
  - gastroesophageal, 231
  - mandible, 3, 17, 19, 21, 22
  - scapula
    - inferior, 81, 95, 97
    - superior, 87, 89, 95, 97, 99, 101, 103
  - sternum, 83, 85, 196
  - venous, 311
  - Wiberg's center-to-corner, 61
- Angular gyrus, artery, 265, 267
- Ankle, 140, 169, 171, 175
  - angiogram, 309
  - anterior-posterior view, 169
  - arthrogram, 263
  - joint space, 263
  - lateral view, 171
  - recess
    - anterior, 263
    - posterior, 263
  - supracalcaneal, 263
  - tendon, 263
  - see also* Foot; Leg
- Anorectal junction, 245
- Antebrachial vein, median, 319
- Antrum, 33, 35, 233
  - mastoid, 29, 31
  - pyloric, 233, 235, 237
- Aorta
  - abdominal, 297, 301
  - arch, 195, 196, 201, 203, 217, 229, 283
    - anterior-posterior angiogram, 283
  - ascending, 196, 201, 203, 283
  - bulb, 283
  - descending, 193, 196, 201, 203, 217, 283
  - pelvic, angiogram, 301
  - valve, 195, 196
- Aortopulmonary window, 196
- Appendix, 239, 243
- Arcuate artery, 297
- Arcuate eminence, 7, 29, 33
- Arcuate line, 71
- Arcuate vein, 299
- Arm
  - deep vein of, 317
  - upper
    - anterior-posterior view, 109
    - lateral view, 111
    - see also* Elbow; Forearm; Shoulder; Wrist
- Arteriography, 264–309
  - carotid artery, 264–71
    - anterior-posterior
      - arterial phase, 265
      - venous phase, 269
    - lateral
      - arterial phase, 267
      - venous phase, 271
  - pulmonary artery
    - arterial phase, 285

- venous phase, 287
- vertebral artery, 272–9
  - anterior-posterior
    - arterial phase, 273
    - venous phase, 277
  - lateral
    - arterial phase, 275
    - venous phase, 279
- Artery
  - adrenal, inferior, 297
  - of angular gyrus, 265, 267
  - arcuate, 297
  - basilar, 273, 275
  - brachiocephalic trunk, 281, 283
  - callosomarginal, 265, 267
  - carotid
    - anterior-posterior arteriogram
      - arterial phase, 265
      - venous phase, 269
    - common, 281, 283
    - external, 281
    - internal, 265, 267, 281
    - lateral arteriogram
      - arterial phase, 267
      - venous phase, 271
  - celiac trunk, 289
    - arterial phase, 289
    - venous phase, 291
  - cerebellar
    - anterior inferior, 273, 275
    - posterior inferior, 273, 275
    - superior, 273, 275
  - cerebral
    - anterior, 265, 267
      - fourth segment, 265
      - second segment, 265, 267
      - third segment, 265
    - middle, 265, 267
      - first segment, 265
      - second segment, 265, 267
    - posterior, 273, 275
  - cervical, ascending, 281
  - choroidal
    - anterior, 265, 267
    - lateral, 275
    - medial, 275
    - posterior, 275
  - colic
    - middle, 293
    - right, 293
  - communicating
    - anterior, 265
    - posterior, 267, 275
  - cystic, 289
  - dorsalis pedis, 309
  - facial, 281
  - femoral
    - common, 301
    - deep, 301, 303
      - lateral circumflex, 303
        - ascending branch, 303
      - medial circumflex, 303
      - superficial, 301, 303, 305
    - fibular, circumflex, 307
  - frontal
    - anterior internal, 267
    - medial internal, 267
    - posterior internal, 267
  - gastric
    - left, 289
    - right, 289
  - gastroduodenal, 289
  - gastroepiploic, right, 289
  - genicular
    - descending, 305
    - inferior medial, 305
    - middle, 305
    - superior lateral, 305
    - superior medial, 305
  - gluteal
    - inferior, 301
    - superior, 301
  - hepatic
    - common, 289
    - left branch, 289
    - right branch, 289
  - ileal, 293
  - ileocolic, 293
  - iliac
    - common, 301
    - external, 301
    - internal, 301
  - interlobular, 297
  - jejunal, 293
  - lumbar, 301
  - marginal, 273
  - meningeal, middle, 5
  - mesenteric, superior, 289, 293
    - arterial phase, 293
    - venous phase, 295
  - obturator, 301
  - occipital, medial, 273, 275
    - calcarine branch, 275
  - ophthalmic, 265, 267
  - orbital, frontal, 265, 267
  - pancreaticoduodenal
    - inferior, 289, 293
    - superior, 289
  - paracentral, 267
  - parietal
    - anterior, 265, 267
    - internal
      - inferior, 267
      - superior, 267

- posterior, 265, 267
- parieto-occipital, 273, 275
- perforating, 303
- pericallosal, 265, 267
- peroneal, 305, 307
- plantar, 309
- polar
  - frontal, 265, 267
  - temporal, 265
- popliteal, 305
- prefrontal, 265, 267
- pulmonary
  - apical branch, 285
  - arteriography
    - arterial phase, 285
    - venous phase, 287
  - left, 195, 201, 203, 285, 311
  - left upper lobe, 201
  - lingular branch, 285
  - lobar branch
    - inferior, 195, 201, 217, 219, 285
    - middle, 219, 285
    - superior, 219
  - main, 195, 196, 201
  - right, 195, 203, 217, 219, 285, 311
  - trunk, 285, 311
- renal
  - left, 297
  - right, 297
- sacral
  - lateral, 301
  - median, 301
- segmental, 285, 287
  - anterior branch, 297
  - inferior, 297
  - middle, 297
  - posterior branch, 297
  - superior, 297
- splenic, 289, 297
- subclavian, 195, 281, 283
  - arch, 195
- sulcal, precentral, 265
- supraduodenal, superior, 289
- suprascapular, 281
- temporal, posterior, 265, 267
- temporo-occipital, 273, 275
- thalamoperforate, 273
- thoracic, internal, 281
- thyroid
  - inferior, 281
  - superior, 281
- tibial
  - anterior, 305, 307, 309
  - muscular branch, 307
  - posterior, 305, 307, 309
- vertebral, 273, 275, 281, 283
  - anterior-posterior arteriogram
    - arterial phase, 273
    - venous phase, 277
  - lateral arteriogram
    - arterial phase, 275
    - venous phase, 279
  - see also* Aorta
- Arthrography
  - ankle, 263
  - knee, 261
  - shoulder
    - anterior-posterior, 257
    - oblique, 259
  - wrist
    - lateral, 255
    - posterior-anterior, 253
- Articular processes, 43
  - inferior, 47, 49, 51, 53, 55, 57, 73, 221
  - superior, 47, 49, 51, 53, 55, 57, 73
- Articular tubercle, 31
- Articulation, *see* Joint
- Arytenoid cartilage, 213
- Ascending colon, 241, 243
- Atlantoaxial joint, 11, 43
- Atlas, 47
  - anterior arch, 27, 45, 47
  - posterior arch, 7, 45
- Atrium
  - left, 195, 196, 201, 287
  - right, 195, 201, 203, 285, 287, 311
- Auditory canal
  - external, 31, 35
    - opening, 5
  - internal, 3, 7, 11, 27, 29, 31, 33
- Axilla, venogram, 317
- Axillary recess, 257, 259
- Axillary vein, 317
- Axis, 45, 227
  - dens, 3, 27, 41, 43, 215
- Azygoesophageal stripe, 193

## B

- Basal vein
  - common, 287
  - inferior, 287
  - of Rosenthal, 269, 271, 279
- Basilar artery, 273, 275
- Basilic vein, 319
- Biceps
  - head, tendon sheath, 257, 259
  - tendon insertion, 259
- Bicipital groove, 91, 93, 99, 103, 105, 107, 109
- Big toe, *see* Toe
- Bile duct, common, 251, 353
- Bladder, *see* Urinary bladder
- Brachial vein, 317, 319

- Brachiocephalic trunk, 281, 283
  - Brachiocephalic vein
    - left, 311
    - right, 311
      - contour, 195
  - Breast
    - ductules, 351
    - galactogram, 351
    - glandular tissue, 209, 211
    - lactiferous duct, 209, 211, 351
    - lactiferous sinus, 351
    - lobules, 351
      - contour, 209, 211
    - mammogram
      - craniocaudal, 209, 211
      - mediolateral, 211
    - nipple, 209, 211, 351
    - shadow, 193
    - skin, 209, 211, 351
    - subcutaneous fat, 209, 211, 351
    - subcutaneous tissue, 351
    - veins, 209, 211
  - Bronchogram, left, 340–3
    - anterior-posterior, 341
    - lateral, 343
  - Bronchus
    - intermediate, 193, 217, 219
    - lobar, 341, 343
    - lower lobe, 196, 219
      - left, 217
      - right, 217
    - segmental, 219, 341, 343
    - main, 341, 343
      - left, 193, 203, 217
      - right, 193, 203, 217
    - middle lobe, 217, 219
    - upper lobe
      - left, 196, 201, 217
      - origin, 219
      - right, 196, 217

*see also* Lung
- C
- Calcaneocuboid joint, 175, 185
  - Calcaneus, 169, 171, 172, 175, 177, 181, 183, 187, 263
    - lateral view, 177
    - posterior tuberosity, 171, 175, 177, 179
      - lateral process, 179
      - medial process, 179
    - tangential view, 179
  - Callosomarginal artery, 265, 267
  - Canine teeth, 21, 22
  - Capitate bone, 125, 127, 129, 131, 133, 135, 137
  - Capitellum, 111, 113, 117, 119, 120
  - Capsular recess
    - inferior, 261
    - superior, 261
  - Carotid artery
    - arteriography
      - anterior-posterior
        - arterial phase, 265
        - venous phase, 269
      - lateral
        - arterial phase, 267
        - venous phase, 271
    - common, 281, 283
    - external, 281
    - internal, 265, 267, 281
  - Carpal bones, 120, 122
    - proximal row, 120, 122
  - Carpal tunnel, 133
  - Carpometacarpal joint, 129
  - Cartilage
    - arytenoid, 213
    - knee, 261
    - nasal, 24
    - thyroid, 213, 215
    - triradiate cartilage line, 61
    - wrist, triangular fibrocartilage, 253
  - Cauda equina, 327, 329, 331, 333
  - Cavernous sinus, 279
    - anterior drainage, 271
    - posterior drainage, 271
  - Cecum, 239, 241, 243
  - Celiac trunk, 289
    - angiography
      - arterial phase, 289
      - venous phase, 291
  - Cephalic vein, 311, 317, 319
  - Cerebellar artery
    - anterior inferior, 273, 275
    - posterior inferior, 273, 275
    - superior, 273, 275
  - Cerebellar vein
    - hemispheric, 277
    - inferior, 277, 279
    - precentral, 279
    - superior, 279
  - Cerebral artery
    - anterior, 265, 267
      - fourth segment, 265
      - second segment, 265, 267
      - third segment, 265
    - middle, 265, 267
      - first segment, 265
      - second segment, 265, 267
    - posterior, 273, 275
  - Cerebral vein
    - great, 269, 271, 279
    - internal, 269, 271, 279
    - superior, 277

- Cervical artery, ascending, 281  
 Cervical canal, 349  
 Cervical spine, 27, 87  
   anterior-posterior view, 43  
   lateral view, 45  
   oblique view, 47  
 Cervical vessels, anterior-posterior  
   angiogram, 281  
 Chest, 192–203  
   anterior oblique view  
     left, 203  
     right, 201  
   lateral radiograph, 196–7  
   myelogram  
     anterior-posterior, 325  
     lateral, 327  
   posterior-anterior radiograph, 193, 195  
   wall, 198  
   *see also* Lung  
 Cholangiopancreatography, endoscopic retrograde (ERCP), 353  
 Cholecystocholangiogram, 251  
 Chopart's (intertarsal) joint, 172, 187  
 Choroidal artery  
   anterior, 265, 267  
   lateral, 275  
   medial, 275  
   posterior, 275  
 Citelli, angle of, 31  
 Clavicle, 49, 81, 83, 85, 87, 89, 91, 93, 95, 99, 101, 103, 105, 107, 109, 111, 193, 257, 259  
   anterior-posterior view, 89  
   conoid tubercle, 89, 93  
   distal, 97  
   oblique view, 91  
   proximal, 87, 89  
 Clinoid process  
   anterior, 5, 37  
   posterior, 5, 37  
 Clivus, 5, 27, 37  
 Coccyx, 59, 63, 65, 73, 75, 77, 79, 245  
   anterior-posterior view, 77  
   cornu, 73, 77  
   lateral view, 79  
 Cochlea, 27, 29, 33  
 Colic artery  
   middle, 293  
   right, 293  
 Colic vein, right, 295  
 Colon, 237, 243  
   ascending, 241, 243  
   descending, 243  
   haustra, 241, 243  
   hepatic flexure, 243  
   sigmoid, 243  
   splenic flexure, 243  
     gas, 205  
     transverse, 243  
     gas, 205  
 Common bile duct, 251, 353  
 Common hepatic duct, 251, 353  
 Communicating artery  
   anterior, 265  
   posterior, 267, 275  
 Contrast studies  
   colon, 243  
   defecography, 247  
   duodenum, 235  
   esophagus, 229, 231  
   hypopharynx  
     anterior-posterior view, 225  
     lateral view, 227  
   ileocecal region, 241  
   intravenous cholecystocholangiogram, 251  
     urogram, 249  
   rectum, 245  
   small bowel, 237, 239  
   stomach, 231, 233, 235, 237  
   *see also* Arteriography; Arthrography  
 Cooper's ligament, 209, 211, 351  
 Coracoid, 87  
 Coracoid process, 81, 89, 91, 93, 95, 97, 99, 103, 105, 107, 111, 257, 259  
 Coronal suture, 5  
 Coronoid fossa, 111, 115, 122  
 Coronoid process, 17, 19, 21, 22, 27, 111, 113, 115, 119, 120, 122  
   end on view, 25  
 Corpus callosum, 265  
   dorsal branch, 275  
 Costal arch, 81  
 Costal notch, 83  
 Costodiaphragmatic recess, 193, 205  
 Costophrenic angle, 193, 205  
 Costotransverse joint, 81, 89  
 Costovertebral articulation, 81  
 Cranial fossa  
   anterior, 37  
   greater wing, 27  
   middle, 27  
 Cranium, *see* Skull  
 Cribriform plate, 5  
 Crista galli, 11  
 Crossover, lymph nodes, 335, 337, 339  
 Cubital tunnel, 117  
 Cubital vein, median, 319  
 Cuboid bone, 171, 172, 175, 177, 181, 183, 185, 187  
   secondary, 173  
 Cuneiform bone  
   lateral, 172, 175, 181, 183, 185, 187  
   medial, 171, 172, 175, 181, 183, 185, 187

middle, 172, 175, 181, 183, 185, 187  
 Cuneonavicular joint, 175, 183  
 Cystic artery, 289  
 Cystic duct, 251, 353

## D

Deep vein of arm, 317  
 Defecography, 247  
 Deltoid tuberosity, 109  
 Dens, 7, 11  
 axis, 3, 27, 41, 43, 215  
 Dental enamel, 22  
 Dental root canal, 19, 22  
 Dentin, 22  
 Descending colon, 243  
 Diaphragm, 49, 51, 193, 201, 205  
 insertions, 193  
*see also* Hemidiaphragm  
 Diploe, 5  
 Dorsalis pedis, 309  
 Dorsum sellae, 29, 37  
 Duct  
 common bile, 251, 353  
 cystic, 251, 353  
 hepatic  
 common, 251, 353  
 left, 353  
 right, 353  
 lactiferous, 209, 211, 351  
 pancreatic, 353  
 accessory, 353  
 body region, 353  
 head region, 353  
 lateral  
 primary, 353  
 secondary, 353  
 tertiary, 353  
 tail region, 353  
 parotid, 345, 347  
 Stenson's, 345, 347  
 Duodenojejunal flexure, 237  
 Duodenum, 233, 235  
 ascending, 237  
 descending, 235, 237  
 horizontal, 237  
 papilla of Vater, 235, 353  
 Dural sac, 327, 331, 333  
 distal end, 329, 331, 333  
 lateral margin, 325

## E

Ear  
 auditory canal  
 external, 31, 35  
 opening, 5

internal, 3, 7, 11, 27, 29, 31, 33  
 cochlea, 27, 29, 33  
 outer, 31  
 semicircular canal, 7, 27  
 anterior, 29, 33  
 lateral, 29, 33  
 tympanic cavity, 29, 33, 35  
 roof, 33  
 Elbow  
 anterior-posterior view, 113  
 axial view, 117  
 lateral view, 115  
*see also* Arm; Forearm  
 Enamel, 22  
 End plate  
 inferior, 45, 49, 51, 53, 55  
 superior, 45, 49, 51, 53, 55  
 Endoscopic retrograde  
 cholangiopancreatography (ERCP),  
 353  
 Epidural fat, 331  
 Epiglottis, 215, 225, 229  
 Epiphyseal plate, 157  
 Epiphysis, 61  
 ERCP (endoscopic retrograde  
 cholangiopancreatography), 353  
 Esophageal hiatus, 231  
 Esophagus, 215, 225, 227, 229, 231  
 abdominal, 231, 233  
 aortic segment, 229  
 body, 229  
 bronchial segment, 229  
 distal, 231  
 epiphrenic segment, 229  
 interbronchial segment, 229  
 paratracheal segment, 229  
 retrocardiac segment, 229  
 sphincter, upper, 229  
 Ethmoid sinus, 3, 5, 9, 11, 13, 15, 39  
 Ethmoidal groove, 24  
 Extensor recess, 253, 255  
 External auditory canal, 31, 35  
 opening, 5  
 Extradural space, 325  
 Extremity, *see* Arm; Leg

## F

Facet joint, 45, 47, 51, 53  
 inferior, 45  
 superior, 45  
 Facial artery, 281  
 Facial bones, pantomogram, 23  
 Facial nerve, 345, 347  
 Fallopian tube, 349  
 fimbriae, 349  
 uterine ostium, 349



- Fat
  - epidural, 331
  - gluteus minimus fat stripe, 59, 143
  - iliopectoral fat stripe, 59, 143
  - intergluteal fat stripe, 143
  - knee
    - infrapatellar, 159
    - posterior, 159
  - preperitoneal, 207
  - subcutaneous
    - abdomen, 207
    - breast, 209, 211, 351
- Femoral artery
  - common, 301
  - deep, 301, 303
  - lateral circumflex, 303
    - ascending branch, 303
  - medial circumflex, 303
  - superficial, 301, 303, 305
- Femoral vein, 321
  - deep, 321
  - superficial, 321
- Femur, 59, 61, 65, 140, 143, 155, 157, 161
  - articular surface, 155
  - condyle
    - lateral, 140, 153, 155, 157, 159, 161, 163, 165, 167
    - medial, 140, 153, 155, 157, 161, 163, 165, 167
  - cortex, 153, 155, 157
  - distal third, 140, 155
  - epicondyle
    - lateral, 153, 157, 161
    - medial, 153, 157, 161
  - epiphyseal plate, 157
  - epiphysis, 61
  - head, 63, 65, 67, 69, 73, 140, 143, 145, 151, 245
    - anterior articular surface, 147
    - fovea, 143
    - posterior articular surface, 149
    - tangential view (Schneider I), 147
    - tangential view (Schneider II), 149
  - medullary canal, 153
  - middle third, 140, 155
  - neck, 59, 61, 69, 143, 145, 147, 149, 151
  - proximal third, 140, 155
  - shaft, 153
- Fibula, 140, 155, 157, 165, 167, 169, 171, 175, 263
  - cortex, 167
  - head, 153, 155, 157, 159, 161, 165, 167
    - apex, 155
  - medullary canal, 167
  - neck, 159, 161, 165
  - notch, 169
- Fibular circumflex artery, 307
- Fimbriae, 349
- Finger
  - interphalangeal joint
    - distal, 125, 127, 139
    - proximal, 125, 127, 139
  - phalanx
    - distal, 125, 139
    - middle, 125, 139
    - proximal, 125, 127, 129, 139
  - in two planes, 139
- Fissure
  - orbital, superior, 13, 15
  - sphenopetrosal, 33
- Flexor recess, 253, 255
- Foot
  - angiogram, 309
  - anterior-posterior view, 173
  - forefoot
    - anterior-posterior view, 185
    - oblique view, 187
  - lateral view, 175
  - see also* Ankle; Toe
- Foramen
  - infraorbital, 9
  - intervertebral, 47, 51, 55, 57, 331
  - jugular, 7, 27
  - mandibular, 19
  - mental, 19, 21, 22
  - obturator, 59, 65, 67, 69, 140, 143, 145, 147, 151
  - sacral, 53, 71, 73, 77, 221
  - tooth, apical, 19, 22
- Foramen lacerum, 27
- Foramen magnum, 5, 7, 27, 29, 43
- Foramen ovale, 9, 27
- Foramen rotundum, 9, 13
- Foramen spinosum, 27
- Forearm
  - anterior-posterior view, 121
  - distal third, 120, 122
  - lateral view, 123
  - middle third, 120, 122
  - proximal third, 120, 122
  - venogram, 319
  - see also* Elbow; Wrist
- Forefoot
  - anterior-posterior view, 185
  - oblique view, 187
  - see also* Toe
- Fossa
  - coronoid, 111, 115, 122
  - cranial
    - anterior, 37
    - greater wing, 27
    - middle, 27
  - glenoid, 87, 89, 93, 99, 103, 107, 111
  - intercondylar, 155, 161, 163

olecranon, 109, 111, 113, 115, 119, 120, 122  
 pituitary, 5, 37, 39  
 popliteal, 155  
 pterygoid, 27  
 pterygopalatine, 22, 27  
 subarcuate, 33  
 of Sylvius, vein, 269, 271  
 temporal, 25  
 temporomandibular joint, 31  
 Frontal artery, internal  
 anterior, 267  
 medial, 267  
 posterior, 267  
 Frontal sinus, 3, 5, 9, 11, 13, 15, 29, 39  
 Frontal vein, 269  
 ascending, 271  
 Frontonasal suture, 24  
 Frontozygomatic suture, 3

## G

Galactography, 351  
 Gallbladder, 251, 353  
 fundus, 251, 353  
 neck, 251, 353  
 Gas  
 colon  
 splenic flexure, 205  
 transverse, 205  
 rectum, 79  
 small bowel, 205  
 Gastric artery  
 left, 289  
 right, 289  
 Gastric bubble, 193, 197, 201, 203, 205  
 Gastric folds, 233  
 Gastroduodenal artery, 289  
 Gastroepiploic artery, right, 289  
 Gastroesophageal angle, 231  
 Gastrointestinal system, 224–47  
 Genicular artery  
 descending, 305  
 inferior medial, 305  
 middle, 305  
 superior lateral, 305  
 superior medial, 305  
 Glandular tissue, breast, 209  
 Glenohumeral joint, 103  
 Glenoid fossa, 87, 89, 93, 99, 103, 107, 111  
 Glenoid labrum, 99, 257, 259  
 Glossoepiglottic fold, lateral, 225, 229  
 Gluteal artery  
 inferior, 301  
 superior, 301  
 Gluteus minimus muscle, fat stripe, 59, 143  
 Gonad shield, 41

Great toe, *see* Toe  
 Growth plate, 153, 157, 161, 165, 169, 171

## H

Hamate bone, 125, 127, 129, 133, 135, 137  
 hook, 129, 131, 133  
 Hand  
 anterior-posterior view, 125  
 oblique view, 127  
*see also* Finger; Wrist  
 Haustra of colon, 241, 243  
 Heart, 195  
 atrium  
 left, 195, 196, 201, 287  
 right, 195, 201, 203, 285, 287, 311  
 mitral valve, 195, 197  
 posterior-anterior radiograph, 195  
 shadow, 197  
 tricuspid valve, 195, 197  
 ventricle  
 left, 195, 197, 201, 203  
 right, 195, 197, 203, 285, 311  
 Hemidiaphragm  
 left, 197, 203  
 right, 197, 203  
 Hemithorax, osseous, 81  
 Hepatic artery  
 common, 289  
 left branch, 289  
 right branch, 289  
 Hepatic duct  
 common, 251, 353  
 left, 353  
 right, 353  
 Hepatic flexure, 243  
 Hiatus  
 esophageal, 231  
 sacral, 73, 77  
 Hilgenreiner's line, 61  
 Hip, 41, 73, 75  
 anterior-posterior view, 143  
 axial view, 151  
 joint space, 65, 140  
 Lauenstein view, 145  
*see also* Leg  
 Humeroradial joint, 113, 115, 119, 120  
 Humeroulnar joint, 113, 115, 119, 120  
 Humerus, 87, 103, 107, 109, 113, 115, 117, 119, 120, 122, 319  
 cortex, 101, 111  
 distal third, 111  
 epicondyle  
 lateral, 109, 113, 115, 117, 119, 120  
 medial, 109, 113, 115, 117, 119, 120  
 head, 81, 87, 89, 91, 93, 95, 97, 99, 101, 103, 105, 107, 109, 111

- medial third, 111
  - metaphysis, 101
  - neck
    - anatomical, 99, 109
    - surgical, 99, 101, 107, 109
  - proximal third, 111
  - shaft, 97, 111
  - tubercle
    - greater, 87, 91, 93, 99, 103, 105, 107, 109
    - crest of, 105
    - lesser, 87, 91, 93, 99, 103, 105, 107, 109, 111
  - see also* Trochlea
  - Hyoid bone, 22, 215, 227
  - Hypopharynx
    - anterior-posterior view, 225
    - lateral view, 227
  - Hysterosalpingogram, 349
- I**
- Ileal artery, 293
  - Ileal vein, 295
  - Ileocecal region, spot film, 241
  - Ileocecal valve, 241, 243
  - Ileocolic artery, 293
  - Ileocolic vein, 295
  - Ileum, 237, 239, 241
    - terminal, 241
  - Iliac artery
    - common, 301
    - external, 301
    - internal, 301
  - Iliac bone, 149
  - Iliac crest, 55, 59, 63, 65, 67, 75, 79, 205, 207, 331
  - Iliac lymph nodes, 335, 337
    - common, 335, 337, 339
    - external, 337, 339
    - internal, 337, 339
  - Iliac spine
    - anterior
      - inferior, 65, 67, 143, 145, 147, 151
      - superior, 59, 63, 65, 67, 143, 145, 147, 149
    - posterior
      - inferior, 59, 63, 73, 221
      - superior, 59, 63, 73, 221
  - Iliac vein
    - common, 313, 315, 321
    - external, 313, 315, 321
    - internal, 313, 315
  - Iliac wing, 59, 63, 67, 71, 73, 221
  - Ilioischial line, 143
  - Iliopectineal line, 69
  - Iliopsoas muscle, fat stripe, 59, 143
  - Iliopubic line, 63
  - Ilium, 41, 61, 71, 147, 205, 207, 221
  - Incisor teeth, 21, 22
  - Infraorbital foramen, 9
  - Infundibulum, 201, 311
  - Inguinal lymph nodes
    - deep, 335
    - superficial, 335, 337
  - Innominate line, 3, 11, 13
  - Interarytenoid notch, 213
  - Intercavernous sinus, 269
  - Intercondylar eminence, 140, 155, 159, 167
    - lateral tubercle, 153, 157, 161, 165
    - medial tubercle, 153, 157, 161, 165
  - Intercondylar fossa, 155, 161, 163
  - Intergluteal fat stripe, 143
  - Interlobular artery, 297
  - Interlobular vein, 299
  - Internal auditory canal, 3, 7, 11, 27, 29, 31, 33
  - Interosseous membrane
    - forearm, 120, 122
    - leg, 161, 165
  - Interphalangeal joint
    - finger
      - distal, 125, 127, 139
      - proximal, 125, 127, 139
    - toe
      - distal, 172, 185, 187, 189
      - proximal, 172, 185, 187, 189
  - Intertarsal (Chopart's) joint, 185, 187
  - Intertrochanteric crest, 59, 143, 147, 149
  - Intertubercular sheath, 257, 259
  - Intervertebral disk, 325, 327, 329, 331, 333
  - Intervertebral disk space, 43, 45, 51, 53, 55, 57
  - Intervertebral facet joint, 45, 47, 51, 53
  - Intervertebral foramen, 47, 51, 55, 57, 331
  - Intradural space, 325
  - Intramedullary region, 325
  - Intravenous contrast studies, 249–51
    - cholecystocholangiogram, 251
    - urogram, 249
  - Ischium, 61, 65, 67, 69, 79, 140, 145, 147, 149
    - posterior column, 143, 145
    - spine, 59, 63, 65, 67, 73, 75, 79, 143, 145, 147, 149
    - tuberosity, 59, 63, 65, 69, 140, 143, 145, 147, 151
- J**
- Jaw
    - lower, *see* Mandible
    - pantomogram, 23
    - upper, *see* Maxilla

- Jejunal artery, 293  
 Jejunal vein, 295  
 Jejunum, 237, 239  
 Joint  
   acromioclavicular, 87, 89, 91, 93, 95, 97, 99, 101, 103, 105, 107, 111  
   atlantoaxial, 11, 43  
   calcaneocuboid, 175, 185  
   carpometacarpal, 129  
   Chopart's (intertarsal), 172, 187  
   costotransverse, 81, 89  
   costovertebral, 81  
   cuneonavicular, 175, 183  
   facet, 45, 47, 51, 53  
     inferior, 45  
     superior, 45  
   glenohumeral, 103  
   humeroradial, 113, 115, 119, 120  
   humeroulnar, 113, 115, 119, 120  
   interphalangeal  
     finger  
       distal, 125, 127, 139  
       proximal, 125, 127, 139  
     toe  
       distal, 172, 185, 187, 189  
       proximal, 172, 185, 187, 189  
   intertarsal, 185, 187  
   Lisfranc's (tarsometatarsal), 172, 187  
   metacarpophalangeal, 125, 127, 139  
   metatarsophalangeal, 172, 175, 185, 187, 189  
   patellofemoral, 155, 164  
   radiocarpal, 120, 122, 129  
   radioulnar, 129  
     distal, 120, 125  
     proximal, 113, 119, 120  
   sacroiliac, 41, 53, 59, 67, 69, 71, 73, 143, 145, 147, 149  
     anterior aspect, 221  
     middle portion, 221  
     posterior inferior aspect, 221  
     thirty-degree anterior oblique view, 71  
     tomogram, 221  
   sternoclavicular, 83, 91  
   subtalar, 177, 183  
   talocalcaneonavicular, 175, 183, 185, 187  
   talonavicular, 171  
   tarsometatarsal, 172, 175, 183, 185, 187, 189  
   temporomandibular, 7, 19, 21  
     fossa, 31  
   tibiofibular, 155, 263  
   transverse tarsal, 172, 187  
   uncovertebral, 43  
   *see also* Ankle; Elbow; Hip; Knee; Shoulder; Wrist  
 Jugular foramen, 7, 27  
 Jugular vein  
   bulb of, 277  
   external, 311  
   internal, 271, 311  
 Junction  
   anorectal, 245  
   of mesenteric vein, 291  
   rectosigmoid, 245
- K**
- Kidney  
   calyces  
     inferior, 249  
     middle, 249  
     superior, 249  
   inferior pole, 249  
   left, 207, 249  
   renal pelvis, 249  
   right, 207, 249  
   superior pole, 249  
 Knee, 167  
   angiogram, 305  
   anterior-posterior view, 157  
   arthrogram, 261  
   capsular recess  
     inferior, 261  
     superior, 261  
   cartilage, 261  
   Frik tunnel view, 161  
   joint space, 140  
   lateral view, 159  
   meniscus, 261  
   posterior fat, 159  
   *see also* Leg; Patella  
 Köhler's teardrop figure, 143
- L**
- Lactiferous duct, 209, 211, 351  
 Lacunar lymph nodes, 337, 339  
   lateral, 335  
 Lamboid suture, 3, 5, 7  
 Lamina papyracea, 13  
 Larynx, 227  
   ventricle, 213, 215, 227  
   vestibule, 213, 215  
 Leg  
   full-length anterior-posterior view, 141  
   lower  
     angiogram, 307  
     anterior-posterior view, 165  
     distal third, 140, 167  
     lateral view, 167  
     middle third, 140, 167  
     proximal third, 140, 167  
   venogram, 321

- see also* Ankle; Foot; Hip; Knee;  
Thigh
- Ligament  
Cooper's, 209, 211, 351  
patellar, 159
- Line  
arcuate, pelvis, 71  
Hilgenreiner's, 61  
ilioischial, 143  
iliopectineal, 69  
iliopubic, 63  
innominate, 3, 11, 13  
paravertebral, 49  
Perkin's, 61  
Shenton's, 61  
terminal, 143  
triradiate cartilage, 61
- Lingula, 341, 343
- Lisfranc's (tarsometatarsal) joint, 172, 187
- Liver, 207, 291  
inferior margin, 205
- Lower extremity, *see* Ankle; Foot; Hip;  
Knee; Leg; Thigh
- Lower jaw, *see* Mandible
- Lower leg, *see* Leg
- Lumbar artery, 301
- Lumbar lymph nodes, 335, 337  
lumbar trunk  
left, 335, 337  
right, 335, 337
- Lumbar myelograms  
anterior-posterior, 329  
lateral, 331  
oblique, 333
- Lumbar spine  
anterior-posterior view, 53  
lateral view, 55  
oblique view, 57
- Lunate bone, 120, 122, 125, 127, 129, 131,  
133, 135, 137
- Lung  
apex, 193  
left, 199, 200, 203  
lower lobe, 198, 199  
anterior-medial basal segment, 199,  
341, 343  
lateral basal segment, 199, 341, 343  
medial segment, 199  
posterior basal segment, 199, 341, 343  
superior segment, 199, 341, 343  
middle lobe, 198, 199  
lateral segment, 199  
lingular segment  
inferior, 199  
superior, 199  
medial segment, 199  
pericardial region, 198  
perihilar region, 198  
posterior border, 193  
right, 199, 200, 203  
right hilum, lateral tomogram, 219  
segments, 198–9  
supradiaphragmatic region, 198  
upper lobe, 198, 199  
anterior segment, 199, 341, 343  
apical segment, 199  
apical-posterior segment, 199, 341,  
343  
axillary subsegment, 199  
inferior segment, lingula, 341, 343  
posterior segment, 199  
superior segment, lingula, 341, 343  
*see also* Bronchus
- Lymph nodes  
crossover, 335, 337, 339  
iliac  
common, 335, 337, 339  
external, 337, 339  
internal, 337, 339  
inguinal  
deep, 335  
superficial, 335, 337  
lacunar, 337, 339  
lateral, 335  
lumbar, 335, 337  
para-aortic, 339  
lateral aortic, 339  
preaortic, 339  
retroaortic, 339  
promontory, 335, 337, 339
- Lymph tracts  
iliac channels, 335, 337  
lumbar trunk  
left, 335, 337  
right, 335, 337
- Lymphangiogram, bipedal, 334–9  
anterior-posterior, channel phase, 335  
anterior-posterior, nodal phase, 339  
oblique, channel phase, 337

## M

- Malleolus, 183  
lateral, 140, 165, 169, 171, 172, 177, 179,  
181, 263  
medial, 140, 165, 169, 171, 172, 181, 263
- Malleus  
lateral, 167  
medial, 167
- Mammogram  
craniocaudal, 209  
mediolateral, 211
- Mandible, 3, 5, 9, 45, 47, 213, 215, 227,  
347

- angle, 3, 17, 19, 21, 22
  - Clementschitsch view, 21
  - condylar process, 3, 22
  - condyle, 7, 9, 19, 21, 22, 27, 29, 31, 33, 35
  - coronoid process, 5
  - ramus, 17, 19, 21
    - cortex, 19
  - see also* Temporomandibular joint
  - Mandibular canal, 3, 19, 21, 22
  - Mandibular foramen, 19
  - Manubrium, sternum, 83, 85, 91
  - Marginal air cells, 31
  - Marginal artery, 273
  - Mastoid
    - air cells, 7, 27, 29
    - antrum, 29, 31
    - apex, 35
  - Mastoid process, 3
    - air cells, 31
  - Maxilla, 3, 17, 21, 24
    - alveolar process, 9
    - alveolar recess, 9, 22
    - lateral wall, 17
  - Maxillary sinus, 3, 5, 9, 11, 13, 15, 17, 21, 22, 25, 27, 29
    - medial wall, 39
    - posterior wall, 27
    - zygomatic recess, 25
  - Mediastinum
    - inferior anterior, 198
    - middle, 198
    - posterior, 198
    - superior anterior, 198
  - Medullary cone, 325, 327
  - Meningeal artery, middle, 5
  - Meniscus
    - knee, 261
    - wrist, 253
  - Mental foramen, 19, 21, 22
  - Mental protuberance, 3, 19, 21
  - Mesenteric artery, superior, 289, 293
    - arteriography
      - arterial phase, 293
      - venous phase, 295
  - Mesenteric vein
    - junction of, 291
    - superior, 295
  - Metacarpal bones, 125, 127, 131, 135, 137, 139
    - base, 125, 127
    - fifth, 129
    - head, 125, 127
  - Metacarpophalangeal joint, 125, 127, 139
  - Metaphysis, 101
  - Metatarsal bones, 172, 175, 181, 183, 185, 187
    - anterior-posterior view, 181
    - fifth, base, 171, 172, 175, 177, 181, 183, 185, 187
    - first, 189
    - head, 172
    - oblique view, 183
  - Metatarsophalangeal joint, 173, 175, 185, 187, 189
  - Mitral valve, 195, 197
  - Molar teeth, 21, 22
  - Muscle
    - abdominal, 207
      - gluteus minimus, fat stripe, 59, 143
      - iliopsoas, fat stripe, 59, 143
      - obturator internus, 59, 207
      - peroneus longus, groove for tendon, 179
      - psoas, 53, 207
        - margin, 205
      - puborectalis, 247
    - Myelograms, 324–33
      - lumbar
        - anterior-posterior, 329
        - lateral, 331
        - oblique, 333
      - thoracic
        - anterior-posterior, 325
        - lateral, 327
- N**
- Nasal bone, 5, 9, 24
    - inferior, 3
  - Nasal cartilage, 24
  - Nasal cavity, 11, 21, 22, 29
  - Nasal septum, 3, 9, 11, 13, 17, 27, 29, 39
  - Nasal sinuses
    - occipitofrontal view, 11
    - Waters view, 9
  - Nasal spine, anterior, 17, 24
  - Nasal turbinate, 39
    - inferior, 13
  - Nasomaxillary suture, 24
  - Nasopharynx, 5
    - posterior, 215
  - Navicular bone, 169, 171, 172, 175, 177, 181, 183, 185, 187
  - Nerve, facial, 345, 347
  - Nerve root sheath, 325, 329
    - L3, 333
  - Nipple, 209, 211, 351
  - Nose
    - lateral view, 24
    - vestibule, 24
  - see also* Nasal bone; Nasal cavity; Nasal septum

## O

- Obturator artery, 301
- Obturator foramen, 59, 61, 65, 67, 69, 140, 143, 145, 147, 151
- Obturator internus muscle, 59, 207
- Occipital artery, medial, 273, 275
  - calcarine branch, 275
- Occipital bone, 7, 43
- Occipital crest, 7
  - internal, 33
- Occipital protuberance
  - external, 7
  - internal, 7, 33
- Occipital sinus, 271
- Occipital vein, 271
- Occiput, 3
- Odontoid process, 45, 47
- Olecranon, 109, 111, 113, 115, 117, 119, 120, 122
  - fossa, 109, 111, 113, 115, 119, 120, 122
- Ophthalmic artery, 265, 275
- Optic canal, 15
- Oral cavity, 215
- Orbit, 9, 13, 27
  - floor, 13, 17, 22
  - lateral wall, 5, 11, 13, 15
  - medial wall, 39
  - posterior-anterior view, 13
  - Rhese view, 15
  - roof, 3, 11, 13, 15, 29, 37
- Orbital artery, frontal, 265, 267
- Orbital fissure, superior, 13, 15
- Orbital plate, 39
- Oropharynx, 227
- Os frontale, 4
- Os intermetatarsium, 173
- Os occipitale, 4
- Os parietale, 4
- Os peroneum, 173
- Os sphenoidale, 4
- Os supratallare, 173
- Os temporale, 4
- Os tibiale externum, 173
- Os trigonum, 177
- Os vesalianum, 173
- Os zygomaticum, 4
- Osseous hemithorax, 81
- Osseous labyrinth, 35
- Osseous sinus, wall, 35
- Pancreatic duct, 353
  - accessory, 353
  - body region, 353
  - head region, 353
  - lateral
    - primary, 353
    - secondary, 353
    - tertiary, 353
  - tail region, 353
- Pancreaticoduodenal artery
  - inferior, 289, 293
  - superior, 289
- Pantomogram, facial bones, 23
- Papilla of Vater, 235, 353
- Para-aortic lymph nodes, 339
  - lateral aortic, 339
  - preaortic, 339
  - retroaortic, 339
- Para-aortic stripe, 193
- Paracentral artery, 267
- Paraspinal stripe, 193
- Paratracheal stripe, right, 193
- Paravertebral line, 49
- Parietal artery
  - anterior, 265, 267
  - internal
    - inferior, 267
    - superior, 267
  - posterior, 265, 267
- Parietal bone, 5
- Parietal vein, 269, 271
- Parieto-occipital artery, 273, 275
- Parotid duct, 345, 347
- Parotid gland, 345, 347
  - accessory gland, 345
  - deep lobe, 345, 347
  - intraalobular ductal system, 345, 347
  - sialogram
    - anterior-posterior, 347
    - lateral, 345
  - superficial lobe, 345, 347
- Pars interarticularis, 57
- Patella, 140, 153, 155, 157, 159, 161, 163
  - articular surface, 155, 163
  - infrapatellar fat pad, 159
  - multipartite, 162
  - ninety-degree view, 163
  - shapes, Wiberg's classification, 162
  - sixty-degree view, 163
  - thirty-degree view, 163
  - see also* Knee
- Patellar ligament, 159
- Patellofemoral joint, 155, 163
- Pedicle, 43, 47, 49, 53, 57, 71, 221
- Pelvis
  - anterior-posterior view, 59
  - child, 61

## P

- Pacchionian granulations, 3
- Palate
  - hard, 5, 13, 22
  - soft, 5, 22

- aortic angiogram, 301
- arcuate line, 71
- Guthmann's view, 65
- iliac wing view, 67
- inlet view, 63
- obturator view, 69
- renal, 249
- Perforating artery, 303
- Periantral air cells, 31, 35
- Pericallosal artery, 265, 267
- Pericardial region, 198
- Perihilar region, 198
- Perkin's line, 61
- Peroneal artery, 305, 307
- Peroneal trochlea, 179
- Peroneal vein, 321
- Peroneus longus muscle, groove for tendon, 179
- Petrosal sinus
  - inferior, 269, 271, 277, 279
  - superior, 271, 277, 279
- Petrosal vein, 277
- Petrous bone, 7, 31
  - apex, 31, 35
  - margin
    - anterior, 31
    - posterior, 35
  - Mayer view, 35
  - Schüller view, 31
  - Stenvers view, 33
- Petrous pyramid, apex, 33
- Petrous ridge, 3, 9, 11, 13, 29, 37
  - Altschul view, 29
- Phalanx
  - finger
    - distal, 125, 139
    - tuft, 139
    - middle, 125, 139
    - proximal, 125, 127, 129, 131, 139
    - base, 125, 127, 139
    - head, 125, 127, 139
  - toe
    - distal, 172, 175, 185, 187, 189
    - tuft, 172, 189
    - middle, 172, 175, 185, 187, 189
    - proximal, 175, 185, 187, 189
    - head, 172
- Pharynx, 225
- Piriform recess, 213, 225, 227, 229
  - inferior posterior margin, 215
- Pisiform bone, 120, 122, 125, 129, 131, 133, 135, 137
  - special view, 137
- Pituitary fossa, 5, 37, 39
- Plantar aponeurosis, 177
- Plantar artery, 309
- Plexus, pterygoid, 271
- Polar artery
  - frontal, 265, 267
  - temporal, 265
- Popliteal artery, 305
- Popliteal bursa, 261
- Popliteal fossa, 155
- Popliteal vein, 321
- Portal vein, 291, 295
  - left branch, 295
  - right branch, 295
- Prefrontal artery, 265, 267
- Premolar teeth, 21, 22
- Preperitoneal fat, 207
- Promontory, 55, 59, 65, 75, 221
- Promontory lymph node, 335, 337, 339
- Psoas muscle, 53, 207
  - margin, 205, 249
- Pterygoid fossa, 27
- Pterygoid plexus, 271
- Pterygoid process, 22
- Pterygopalatine fossa, 22, 27
- Pubic bone, 61, 67, 69, 140, 145, 147, 149, 151
  - anterior column, 143, 145, 147
- Pubic symphysis, 59, 63, 65, 77
- Pubis
  - inferior ramus, 59, 63, 65, 69, 145
  - superior ramus, 59, 63, 65, 73, 77, 143, 145
- Puborectalis muscle, 247
- Pulmonary artery
  - apical branch, 285
  - arteriography
    - arterial phase, 285
    - venous phase, 287
  - left, 195, 201, 203, 285, 311
  - upper lobe, 201
  - lingular branch, 285
  - lobar branch
    - inferior, 195, 201, 217, 219, 285
    - middle, 219, 285
    - superior, 219
  - main, 195, 196, 201
  - right, 195, 203, 217, 219, 285, 311
  - trunk, 285, 311
- Pulmonary hilum, anterior-posterior tomogram, 217
- Pulmonary valve, 195, 196
- Pulmonary vein, 196, 197, 217
  - apical branch, 287
  - apicoposterior branch, 287
  - inferior, 287
    - left, 201
    - right, 201
  - left, 203
    - upper lobe, 201
  - right, 203



superior, 287  
 Pulp cavity, 19, 22  
 Pylorus, 233, 235  
 antrum, 233, 235, 237

## R

Radial vein, 319  
 Radiocarpal joint, 120, 122, 129  
 Radiographs  
 abdomen  
 standing, 205  
 supine, 207  
 chest  
 lateral, 196–7  
 left, anterior oblique view, 203  
 posterior-anterior, 193  
 heart and major vessels, 195  
 right, anterior oblique view, 201  
 lung segments, 198–9  
 Radioulnar joint, 129  
 distal, 120, 125  
 proximal, 113, 119, 120  
 Radius, 109, 111, 113, 115, 117, 119, 120,  
 122, 129, 135, 137, 255, 319  
 distal, 125, 127  
 head, 109, 111, 113, 115, 117, 119, 120,  
 122  
 neck, 113, 119, 120, 122  
 oblique view, 119  
 styloid, 120, 125, 127, 129, 131, 135  
 tuberosity, 115, 119, 120  
 Rectosigmoid junction, 245  
 Rectum, 243, 245  
 ampulla, 245, 247  
 gas, 79  
 transverse fold, 245  
 Renal arteriogram  
 arterial phase, 297  
 venous phase, 299  
 Renal artery  
 left, 297  
 right, 297  
 Renal pelvis, 249  
 Renal vein, 315  
 left, 299, 313  
 right, 299, 313  
 superior branch, 299  
 Retrocardiac space, 197  
 Retrofacial air cells, 31  
 Retropharyngeal space, 215  
 Retrorectal space, 245  
 Retrosinus air cells, 35  
 Retrosternal space, 85, 196  
 Rib, 47, 57, 97  
 first, 43, 49  
 tubercle, 49

head, 49, 51, 81  
 neck, 49, 81  
 twelfth, 249  
 Rib cage, 41  
 Rima glottidis, 213  
 Root canal, 19, 22

## S

Sacciform recess, 253  
 Sacral artery  
 lateral, 301  
 median, 301  
 Sacral canal, 75, 79  
 Sacral crest  
 lateral, 73, 77, 79  
 median, 73, 75, 77, 79  
 Sacral foramen, 53, 71, 73, 77, 221  
 Sacral hiatus, 73, 77  
 Sacroiliac joint, 41, 53, 59, 67, 69, 71, 73,  
 143, 145, 147, 149  
 anterior aspect, 221  
 middle portion, 221  
 posterior inferior aspect, 221  
 thirty-degree anterior oblique view, 71  
 tomogram, 221  
 Sacrum, 41, 53, 55, 59, 63, 65, 67, 71, 75,  
 79, 143, 205, 207, 245, 331  
 ala, 63, 73, 221  
 anterior aspect, 221  
 anterior-posterior view, 73  
 cornu, 73, 75, 77, 79  
 lateral view, 75  
 Sagittal sinus  
 inferior, 271  
 superior, 269, 271  
 Sagittal suture, 3  
 Salivary gland, *see* Parotid gland  
 Saphenous vein  
 great, 321  
 small, 321  
 Scaphoid, 120, 122, 125, 127, 129, 131,  
 133, 135, 137  
 Scapula, 51, 99, 103, 107, 196  
 angle  
 inferior, 81, 95, 97  
 superior, 87, 89, 95, 97, 99, 101, 103  
 anterior-posterior view, 95  
 articular surface, 95  
 lateral view, 97  
 margin  
 lateral, 87, 95, 97, 99  
 medial, 87, 95, 99  
 process  
 glenoid, 87  
 lateral (neck), 95, 103, 109  
 spine, 87, 89, 95, 97, 99, 101

- Sciatic notch
  - greater, 65, 73, 75, 79
  - lesser, 75
- Segmental artery, 285, 287
  - anterior branch, 297
  - inferior, 297
  - middle, 297
  - posterior branch, 297
  - superior, 297
- Sella turcica
  - anterior-posterior view, 39
  - floor, 39
  - lateral view, 37
- Semicircular canal, 7, 27
  - anterior, 29, 33
  - lateral, 29, 33
- Septum pellucidum, vein of, 271
- Sesamoid
  - foot, 172, 173, 175, 185, 187, 189
  - hand, 125, 127
- Sheath
  - biceps head, tendon, 257, 259
  - intertubercular, 257, 259
  - nerve root, 325, 329
    - L3, 333
- Shenton's line, 61
- Shoulder
  - anterior-posterior abduction view, 101
  - anterior-posterior arthrogram, 257
  - anterior-posterior view, 99
  - axial view, 103
  - oblique arthrogram, 259
  - soft tissues, 196
  - stress view, 87
  - tangential view, 105
  - trans thoracic view, 107
    - see also* Arm
- Sialograms, 344–7
  - anterior-posterior parotid, 347
  - lateral parotid, 345
- Sigmoid colon, 243
- Sigmoid sinus, 35, 269, 271, 277, 279
  - sulcus, 31
- Sinus
  - cavernous, 279
    - anterior drainage, 271
    - posterior drainage, 271
  - confluence of, 271, 277, 279
  - ethmoid, 3, 5, 9, 11, 13, 15, 39
  - frontal, 3, 5, 9, 11, 13, 15, 29, 39
  - intercavernous, 269
  - lactiferous, 351
  - maxillary, 3, 5, 9, 11, 13, 15, 17, 21, 22, 25, 27, 29
    - medial wall, 39
    - posterior wall, 27
    - zygomatic recess, 25
  - nasal
    - occipitofrontal view, 11
      - Waters view, 9
  - occipital, 271
  - osseous, wall, 35
  - petrosal
    - inferior, 269, 271, 277, 279
    - superior, 271, 277, 279
  - sagittal
    - inferior, 271
      - superior, 269, 271
  - sigmoid, 35, 269, 271, 277, 279
    - sulcus, 31
  - sphenoid, 5, 15, 27, 37
  - sphenoparietal, 269
  - straight, 271, 277, 279
  - tarsal, 171, 177, 183
  - transverse, 269, 271, 277, 279
    - sulcus, 7
- Skeleton, 2–189
- Skin, breast, 209, 211, 351
- Skull, 2–39
  - base, 17, 27, 45, 215
  - jaw and facial bones, pantogram, 23
  - lateral view, 5
  - mandible
    - Clementschietsch view, 21
    - ramus, 19
  - maxilla, 17
  - nasal sinuses
    - occipitofrontal view, 11
      - Waters view, 9
  - nose, lateral view, 24
  - orbit
    - posterior-anterior view, 13
    - Rhese view, 15
  - petrous bone
    - Mayer view, 35
    - Schüller view, 31
    - Stenvers view, 33
  - petrous ridge, Altschul view, 29
  - posterior, Towne view, 7
  - posterior-anterior view, 3
  - sella turcica
    - anterior-posterior view, 39
    - lateral view, 37
  - zygomatic arch, 25
- Small bowel, 237, 239
  - gas, 205
  - ileocecal region, spot film, 241
    - see also* Duodenum; Ileum; Jejunum
- Space
  - ankle joint, 263
  - extradural, 325
  - hip joint, 65, 140
  - intervertebral disk, 43, 45, 51, 53, 55, 57
  - intradural, 325

- knee joint, 140
- retrocardiac, 197
- retropharyngeal, 215
- retrorectal, 245
- retrosternal, 85, 196
- subarachnoid
  - anterior, 327
  - lateral, 325
  - posterior, 327
  - spinal nerve root, 329
- subglottic, 213, 215
- subphrenic, 205
- Special studies, 324–53
  - bipedal lymphangiogram
    - anterior-posterior
      - channel phase, 335
      - nodal phase, 339
    - oblique, channel phase, 337
  - bronchogram, left
    - anterior-posterior, 341
    - lateral, 343
  - endoscopic retrograde cholangio-pancreatography (ERCP), 353
  - galactogram, 351
  - hysterosalpingogram, 349
  - myelogram
    - lumbar
      - anterior-posterior, 329
      - lateral, 331
      - oblique, 333
    - thoracic
      - anterior-posterior, 325
      - lateral, 327
  - parotid sialogram
    - anterior-posterior, 347
    - lateral, 345
- Sphenoid, 3, 11, 13, 15, 37, 39
  - greater wing, 5, 9, 13, 37
  - lesser wing, 13, 15
- Sphenoid sinus, 5, 15, 27, 37
- Sphenoparietal sinus, 269
- Sphenopetrosal fissure, 33
- Sphenosquamous suture, 33
- Spinal cord, 325, 327
- Spinal nerve root, subarachnoid space, 329
- Spine, 40–79
  - anterior-posterior full-length view, 41
  - cervical, 27, 87, 227
    - anterior-posterior view, 43
    - lateral view, 45
    - oblique view, 47
  - lumbar
    - anterior-posterior view, 53
    - lateral view, 55
    - oblique view, 57
  - thoracic
    - anterior-posterior view, 49
    - lateral view, 51
  - see also* Coccyx; Pelvis; Sacroiliac joint; Sacrum; Vertebrae
- Spinous process, 43, 45, 47, 49, 51, 53, 55, 57, 73, 221
- Spleen, 207, 291
  - lower margin, 205
- Splenic artery, 289, 297
- Splenic flexure, 243
  - gas, 205
- Splenic vein, 291, 295
- Spot images
  - mammogram
    - craniocaudal, 209
    - mediolateral, 211
  - trachea
    - anterior-posterior view, 213
    - lateral view, 215
- Squamous air cells, 31
- Stenson's duct, 345, 347
- Sternal notch, 83
- Sternoclavicular joint, 83, 91
- Sternum, 83, 85, 196, 203
  - angle, 83, 85, 196
  - anterior-posterior view, 83
  - lateral view, 85
  - manubrium, 83, 85, 91
- Stomach, 231, 233, 235, 237
  - angular notch, 233
  - antrum, 233
  - cardia, 231, 233
  - fundus, 233
  - gastric bubble, 193, 197, 201, 203, 205
  - gastric folds, 233
  - greater curvature, 233
  - lesser curvature, 233
- Straight sinus, 271, 277, 279
- Stripe
  - azygoesophageal, 193
  - paraortic, 193
  - paraspinal, 193
  - paratracheal, 193
- Styloid process, 22, 31
  - radius, 120, 125, 127, 129, 131, 135
  - ulna, 120, 122, 125, 127, 129, 131, 135, 255
- Subarachnoid space
  - anterior, 327
  - lateral, 325
  - posterior, 327
  - spinal nerve root, 329
- Subarcuate fossa, 33
- Subclavian artery, 195, 281, 283
  - arch, 195
- Subclavian vein, 311, 317
- Subcutaneous fat
  - abdomen, 207

breast, 209, 211, 351  
 Subglottic space, 213, 215  
 Subphrenic space, 205  
 Subscapular bursa, 257, 259  
 Subtalar joint, 177, 183  
 Sulcal artery, precentral, 265  
 Sulcus  
   sigmoid sinus, 31  
   transverse sinus, 7  
 Supracalcaneal recess, 263  
 Supraduodenal artery, superior, 289  
 Suprascapular artery, 281  
 Suprascapular notch, 101  
 Sustentaculum tali, 177, 179  
 Suture  
   coronal, 5  
   frontonasal, 24  
   frontozygomatic, 3  
   lambdoid, 3, 5, 7  
   nasomaxillary, 24  
   sagittal, 3  
   sphenosquamous, 33  
   temporozygomatic, 25  
 Symphysis pubis, 59, 63, 65, 77

## T

Talocalcaneonavicular joint, 175, 183, 185, 187  
 Talonavicular joint, 171  
 Talus, 165, 167, 171, 175, 177, 179, 183, 187, 263  
   head, 171, 172, 181  
   lateral process, 171, 177  
   neck, 171  
   posterior process, 171, 175, 177  
   trochlea, 140, 169, 171  
 Tarsal joint, transverse, 172, 187  
 Tarsometatarsal joint, 172, 175, 183, 185, 187, 189  
 Temporal artery, posterior, 265, 267  
 Temporal bone, 5, 21  
   petrous portion, 5, 15  
   zygomatic process, 25, 31  
   *see also* Temporomandibular joint  
 Temporal fossa, 25  
 Temporo-occipital artery, 273, 275  
 Temporomandibular joint, 7, 19, 21  
   fossa, 31  
   *see also* Mandible; Temporal bone  
 Temporozygomatic suture, 25  
 Tendon  
   Achilles, 171, 177  
   ankle, recess, 263  
   biceps muscle  
     insertion, 259  
     sheath, 257, 259  
   peroneus longus muscle, groove for, 179  
 Terminal line, 143  
 Thalamoperforate artery, 273  
 Thalamostriate vein, superior, 269, 271  
 Thalamus, 275  
 Thigh  
   angiogram, 303  
   anterior-posterior view, 153  
   lateral view, 155  
 Thoracic artery, internal, 281  
 Thoracic myelograms  
   anterior-posterior, 325  
   lateral, 327  
 Thoracic spine  
   anterior-posterior view, 49  
   lateral view, 51  
 Thorax, *see* Chest  
 Thyrocervical trunk, 281, 283  
 Thyroid artery  
   inferior, 281  
   superior, 281  
 Thyroid cartilage, 213, 215  
 Thyroid vein, inferior, 269, 271  
 Tibia, 140, 155, 157, 159, 161, 165, 167, 169, 171, 175, 263  
   apophysis, proximal, 167  
   condyle  
     lateral, 140, 153, 155, 157, 165, 167  
     medial, 140, 153, 157, 165, 167  
   cortex, 165  
   medullary canal, 165  
   plateau, 159  
     lateral, 161  
     medial, 161  
   tuberosity, 159, 161, 165  
 Tibial artery  
   anterior, 305, 307, 309  
   muscular branch, 307  
   posterior, 305, 307, 309  
 Tibial vein  
   anterior, 321  
   posterior, 321  
 Tibiofibular joint, 155, 263  
 Toe  
   anterior-posterior view, 189  
   interphalangeal joint, 189  
     distal, 172, 185, 187, 189  
     proximal, 172, 185, 187, 189  
   lateral view, 189  
   phalanx, 172  
     distal, 172, 175, 185, 187, 189  
     middle, 172, 175, 185, 187, 189  
     proximal, 172, 175, 185, 187, 189  
 Tomograms, 216–21  
   facial bones, pantomogram, 23  
   lung, right hilum, 219  
   pulmonary hilum, 217

- sacroiliac joint, 221
  - Tongue, 9, 227
  - shadow, 22
  - Tooth
    - apical foramen, 19, 22
    - canine, 21, 22
    - dentin, 22
    - enamel, 22
    - incisor, 21, 22
    - molar, 21, 22
    - premolar, 21, 22
    - root, 22
    - root canal, 19, 22
  - Trachea, 21, 43, 45, 49, 193, 196, 201, 203, 217, 219, 227
    - anterior-posterior spot view, 213
    - bifurcation, 217
    - carina, 193, 203
    - distal, 213, 215
    - lateral spot view, 215
    - proximal, 213, 215
  - Transverse colon, 243
    - gas, 205
  - Transverse process, 43, 45, 47, 49, 51, 53, 55, 57, 73, 77, 81, 221
    - L5, 71
    - T1, 43
  - Transverse sinus, 269, 271, 277, 279
    - sulcus, 7
  - Transverse tarsal joint, 172, 187
  - Trapezium, 125, 127, 129, 131, 133, 135, 137
  - Trapezoid, 125, 127, 129, 131, 133, 135, 137
  - Tricuspid valve, 195, 197
  - Triquetrum, 120, 122, 125, 127, 129, 131, 133, 135, 137
  - Triradiate cartilage line, 61
  - Trochanter
    - greater, 59, 67, 140, 143, 145, 147, 149, 151
    - lesser, 59, 69, 143, 145, 147, 149, 151
  - Trochlea, 109, 111, 113, 117, 119, 120, 122
    - lateral margin, 113
    - medial margin, 113
    - peroneal, 179
    - talus, 140, 169, 171
  - Tuberculum sellae, 37
  - Tympanic cavity, 29, 33, 35
    - roof, 33
  - styloid, 120, 122, 125, 127, 129, 131, 135, 137, 255
  - Ulnar vein, 319
  - Uncinate process, 43
  - Uncovertebral joint, 43
  - Upper extremity, *see* Arm; Elbow; Forearm; Hand; Shoulder; Wrist
  - Upper jaw, *see* Maxilla
  - Ureter, 249
    - distal, 249
  - Urinary bladder, 59, 205, 207, 249
  - Urogram, 249
  - Uterine cavity, 349
  - Uterine ostium, 349
  - Uterus, fundus, 349
  - Uvula, 227, 229
- 
- V**
- Vagina, 349
  - Vallecula, 225, 227
    - floor, 213, 215
  - Valve
    - aortic, 195, 196
    - ileocecal, 241, 243
    - mitral, 195, 197
    - pulmonary, 195, 196
    - tricuspid, 195, 197
  - Vater
    - ampulla of, 233, 235, 237
    - papilla of, 235, 353
  - Vein
    - anastomotic
      - inferior, 271
      - superior, 269, 271
    - antebrachial
      - median, 319
    - arcuate, 299
    - of arm, deep, 317
    - axillary, 317
    - azygos, 195, 217, 311
    - basal
      - common, 287
      - inferior, 287
      - of Rosenthal, 269, 271, 279
    - basilic, 319
    - brachial, 317, 319
    - brachiocephalic
      - left, 311
      - right, 311
      - contour, 195
    - breast, 209, 211
    - cephalic, 311, 317, 319
    - cerebellar
      - hemispheric, 277
      - inferior, 277, 279
      - precentral, 279
- 
- U**
- Ulna, 109, 111, 113, 115, 117, 119, 120, 122, 129, 135, 255, 319
    - distal, 125, 127
    - recess, 253, 255

- superior, 279
- cerebral
  - great, 269, 271, 279
  - internal, 269, 271, 279
  - superior, 277
- colic, right, 295
- cubital, median, 319
- femoral, 321
  - deep, 321
  - superficial, 321
- of fossa of Sylvius, 269, 271
- frontal, 269
  - ascending, 271
- of Galen, 269, 271, 279
- ileal, 295
- ileocolic, 295
- iliac
  - common, 313, 315, 321
  - external, 313, 315, 321
  - internal, 313, 315
- interlobular, 299
- jejunal, 295
- jugular
  - bulb of, 277
  - external, 311
  - internal, 271, 311
- of Labbé, 271
- mesenteric
  - junction of, 291
  - superior, 295
- occipital, 271
- parietal, 269, 271
- peroneal, 321
- petrosal, 277
- popliteal, 321
- portal, 291, 295
  - left branch, 295
  - right branch, 295
- pulmonary, 196, 197, 217
  - apical branch, 287
  - apicoposterior branch, 287
  - inferior, 287
    - left, 201
    - right, 201
  - left, 203
    - upper lobe, 201
  - right, 203
    - superior, 287
- radial, 319
- renal, 315
  - left, 299, 313
  - right, 299, 313
  - superior branch, 299
- saphenous
  - great, 321
  - small, 321
- of septum pellucidum, 271
- splenic, 291, 295
- subclavian, 311, 317
- thalamostriate, superior, 269, 271
- thyroid, inferior, 311
- tibial
  - anterior, 321
  - posterior, 321
- of Trolard, 269, 271
- ulnar, 319
- of vermis
  - branch, 273
  - inferior, 277
- see also* Vena cava
- Vena cava
  - inferior, 195, 197, 201, 203, 285, 313, 315, 321
    - anterior-posterior venogram, 313
    - lateral venogram, 315
  - superior, 195, 217, 285, 311, 317
    - anterior-posterior venogram, 311
- Venography
  - axilla, 317
  - forearm, 319
  - leg, 321
  - vena cava
    - inferior
      - anterior-posterior, 313
      - lateral, 315
      - superior, 311
- Venous angle, 311
- Venous confluence, 195, 217, 291, 295
- Ventricle
  - left, 195, 197, 201, 203
  - right, 195, 197, 203, 285, 311
- Vertebrae, 49, 51, 53, 57
  - articular facet
    - inferior, 45
    - superior, 45
  - articular pillar, 45
  - articular process
    - inferior, 47, 49, 51, 53, 55, 57, 73, 221
    - superior, 47, 49, 51, 53, 55, 57, 73
  - C1, lateral mass, 43
  - C2, 47
  - C7, 41, 215
  - end plate
    - inferior, 45, 49, 51, 53, 55
    - superior, 45, 49, 51, 53, 55
  - L1, 41
  - L3
    - nerve root sheath, 333
    - pedicle, 41
  - L5, 71, 73, 75, 221
    - inferior articular process, 73
    - pedicle, 71
    - transverse process, 71

L6, spinous process, 41  
 lamina, 45, 57, 221  
 margin  
   anterior  
     inferior, 45, 51  
     superior, 45, 51  
   posterior  
     inferior, 51  
     superior, 51  
 pars interarticularis, 57  
 pedicle, 43, 47, 49, 53, 57, 71, 221  
 spinous process, 43, 45, 47, 49, 51,  
   53, 55, 57, 73, 221  
 T1, transverse process, 43  
 T2, 41  
 T4, 198  
 T5, 198  
 T12, 41  
 transverse process, 43, 45, 49, 51,  
   53, 55, 57, 73, 77, 81, 221  
 Vertebral arch, 43  
 Vertebral artery, 273, 275, 281, 283  
 arteriography  
   anterior-posterior  
     arterial phase, 273  
     venous phase, 277  
   lateral  
     arterial phase, 275  
     venous phase, 279  
 Vestibular fold, 213  
 Vestibule, 29, 33  
   larynx, 213, 215  
   nose, 24

Vocal cord  
   false, 213  
   true, 213  
 Vocal fold, 213

## W

Wiberg's center-to-corner angle, 61  
 Wrist  
   anterior-posterior view, 129  
   arthrogram  
     lateral, 255  
     posterior-anterior, 253  
   extensor recess, 253, 255  
   flexor recess, 253, 255  
   lateral view, 131  
   meniscus, 253  
   saciform recess, 253  
   triangular fibrocartilage, 253  
   ulnar recess, 253, 255  
   *see also* Forearm; Hand

## X

Xiphoid process, 83, 85

## Z

Zygomatic arch, 3, 13, 15, 22, 25, 29  
 Zygomatic bone, 5, 9, 11, 27, 35  
   frontal process, 13  
 Zygomatic process, 5  
   temporal bone, 25, 31  
 Zygomatic recess, 25