

QM

31

L58

1879


UC-NRLF



SD 18 978

VEST-POCKET
ANATOMY
LEONARD.

MEDICAL SCHOOL
LIBRARY



EX LIBRIS

IN MEMORIAM
A. K. CRAWFORD, M. D.

A. N. Crawford

THE
VEST-POCKET
ANATOMIST.

(FOUNDED UPON "GRAY.")

BY C. HENRI LEONARD, A. M., M. D.

—•—
MULTUM IN PARVO.

—•—
SECOND ENLARGED EDITION.

VIIITH THOUSAND.

QM 31

L58

1879

—•••—
DETROIT:

CORNER GRATIOT AND WOODWARD AVENUES.

Univ Calif - Digitized by Microsoft®
1879.

COPYRIGHTED 1875—1878.

LEONARD'S PHYSICIAN'S POCKET DAY-BOOK.

Post-paid, \$1.00 ; with your name on side in gold leaf, \$1.25 ;
name, town and State, \$1.50.

This edition contains no printed matter (many physicians requesting such, preferring the Dose Book bound by itself). It is three and three-fourths by seven and one-fourth inches in size, and is bound in full Russia leather, with flap, pocket, pencil-loop, red edges and gilt side stamp. The regular price of such a styled book is from \$1.50 to \$2.00. I desire it shall be the most complete, best gotten up, cheapest and lightest day-book for physicians' use ever issued. It is large enough to carry ordinary bills without folding, and also a full supply of prescription blanks, etc. It is so arranged that it will accommodate DAILY CHARGES for forty families per week, with a separate column for weekly credits for the entire year; or DAILY CHARGES for twenty families per week, with DAILY CREDITS for the entire year. Besides the Dr. and Cr. columns to each name, there is also one for ledger page (if the ordinary ledger instead of my ledger [page 111] is used), and one each for Discount, Total Dr., Total Cr., and Balance Due. You can "post" every ten days, or every month. There is a complete record for ninety-six obstetrical cases, and a monthly memoranda for a Dr. and Cr. cash account. It is good for one year from the first of any month. It is so arranged that the family name needs to be written but once during the entire month, if your practice is small, or at most but three times; the rest of the account-keeping being in figures, the amount of your daily charges. Accounts can be kept in one-fifth the usual time required by other methods.

LEONARD'S PHYSICIAN'S BOUND STATEMENTS.

400. Bound, with Stub. Post-paid, \$2.25.

Each account-statement will have your town, name, street address, office hours, etc., printed upon it, with six lines for Debit and Credit entries, with their appropriately printed headings, etc., etc. The size of each is three and a half by six and a half inches, exclusive of stub.

Sample pages of Day-Book or Statements on receipt of stamp.

C. HENRI LEONARD, M. D., Publisher,
Corner Gratiot and Woodward avenues, DETROIT, MICH.

(No goods sent except on receipt of full remittance.)

MANUAL OF BANDAGING.

By C. Henri Leonard, A. M., M. D.

Over 100 original illustrations; cloth, 8vo., postpaid, \$1.50

CONTENTS—CHAPTER I.—Charpie and Cotton-wool. Chapter II.—Compresses; (Illustrated.) Chapter III.—Bandages in general. Chapter IV.—Classification of Bandages. Chapter V.—Bandages of the head, 30 are given; (Illustrated.) Chapter VI.—Bandages of the neck, 10 are given; (Illustrated.) Chapter VII.—Bandages of the Upper Extremity, 32 given; (Illustrated.) Chapter VIII.—Bandages of the Body, 24 given; (Illustrated.) Chapter IX.—Bandages of the Lower Extremity, 56 are given; (Illustrated.) Chapter X.—Immovable Dressings; (Illustrated.) Chapter XI.—Strappings; (Illustrated.) Chapter XII.—Knots; (Illustrated.) Chapter XIII.—Poultices.

*INCLUDED IN THE LIST OF TEXT BOOKS USED
AT THE MEDICAL DEPARTMENT OF
MICHIGAN UNIVERSITY.*

“It describes and gives cuts of almost all conceivable bandages. To those who have never enjoyed the opportunities which a large hospital can alone afford, this book will prove a very valuable aid.”—*Peninsular Jour. Med.* “Every student should possess it; and as it is the most explicit and best illustrated English work of its kind, there will be few physicians who will not prize its worth.”—*St. Louis Med Jour.* “The wood-cuts are very instructive. It is charming to look, at last, upon a new set of these. We heartily commend the book.”—*Louisville Med. News.*

Sent post-paid on receipt of price by addressing the Publisher.

C. HENRI LEONARD, M. D.,
DETROIT, MICH

Univ Calif - Digitized by

27969

REFERENCE AND DOSE BOOK.

By C. HENRI LEONARD, A. M., M. D.

Third Edition (18 Thousand), revised and enlarged. Cloth, post-paid, 75c.

Contains the Doses of more Remedies than any other Dose-Book or *Materia Medica* published, and is used in every Medical College in the United States, and by Physicians and Druggists in every State and Territory, the Canadas, Manitoba, New Brunswick, Nova Scotia, Prince Edward's Island, Newfoundland, British Columbia, England, Hawaiian Islands, Africa, India, China and Australia.

CONTENTS.—Medium and maximum **DOSES** of all officinal and non-officinal remedies, and their preparations, arranged in alphabetical order, with pronunciation, (common names in small type below drug name) the Orthography that of the last U.S.P. **RULES** for Genitive case-endings in prescription writing. A complete list of **INCOMPATIBLES**. Ditto of **POISONS** and their **ANTIDOTES**, and Tests for same. Rules for resuscitation of the drowned, treatment of poisoned wounds, etc. A complete table of tests for **URINARY DEPOSITS**. **OBSTETRIC TABLES**, and rules for management in difficult cases and accidents. **PRONUNCIATION** of Medico-Biographical Names. Table of **FEEES** for city and country practice. Visceral Measurements for guides in auscultation and percussion. Table of the Exanthemata, and differential diagnosis. Tables of **WEIGHTS, MEASURES**, etc., both French and American. List of **ABBREVIATIONS**, besides several pages of miscellaneous matter, useful in emergencies.

"It is emphatically a *multum in parvo*, and contains a fund of valuable information of every day requirement. Besides being the most complete Dose Book we know of, it is indispensable to the practitioner on account of its other contents.—*Peninsular Jour. Med.*

"Every one must acknowledge that this author has compressed an immense amount of ready, practical information into the minimum of space."—*Chicago Med. Jour. and Examiner.*

"A very complete little volume, containing a rare selection of valuable information, arranged for ready reference."—*St. Louis Med. Jour.*

"One of the best books of its size issued."—*Am. Med. Bi-weekly.*

ANIMAL VACCINE.

(WARRANTED 15 DAYS.)

10 large X Points,	\$1.00
10 " XX "	2.00
5 " XX "	1.00
Crusts, per grain,.....	1.00

Address ALL Orders (none filled without remittance), for Books, etc., to the publisher,

C. HENRI LEONARD, M. D.,

Corner Gratiot and Woodward Aves., DETROIT, MICH.

HEAD AND NECK.

MUSCLES.

(Nervous supply is indicated by [] brackets.)
The — dash divides the origin from the insertion.

(1) EPICRANIAL REGION 1.

Occip'ite-fronta'lis : outer $\frac{2}{3}$ superior curved line of occiput, and mastoid process—frontal quadrilateral expansion to the facial muscles. [Supra-orbital, facial, occipital, posterior auricular.]

(2) AURICULAR REGION 3.

Atto'lens au'rem : occipital fascia—upper part of pinna. [Small occipital.]

A'trahens au'rum : lateral edge aponeuro'sis of occipito-frontalis—front of helix. [Facial, inferior maxillary.]

Ret'rahens au'rem : mastoid process—lower cranial surface of the concha. [Facial.]

(3) INTRA-AURICULAR REGION 4.

Ten'sor tym'pani : inferior surface petrous bone, Eustachian tube—backwards to handle malleus. [Otic ganglion.]

Laxa'tor tym'pani ma'jor : spinous process sphenoid, Eustachian tube—back through Glaserian fissure to neck of the malleus, [Facial.]

Laxa'tor tym'pani mi'nor : superior and posterior part external meatus—forward and inwards to handle of the malleus. [Facial.]

Stape'dius : interior of pyramid—forward to neck of stapes. [Facial.]

(4) PALPEBRAL REGION (4) 3.

Orbicula'ris palpebra'rum : internal angular process frontal bone, nasal process superior maxilla, sphincter of eye. [Facial and supra-orbital.]

Corru'ga'tor supercil'ii : inner extremity superciliary ridge—under surface orbicularis, opposite the middle of the orbital arch. [Facial, supra-orbital.]

Ten'sor tar'si : crest of os lachrymalis—tarsal cartilage near puncta; covers in lachrymal canals. [Facial.]

(5) ORBITAL REGION 7.

Lava'tor palpe'brae superio'ris : inferior surface lesser wing of sphenoid, anteriorly to foramen opticum—upper border superior tarsal cartilage. [III d.]

Rec'tus supe'rior : margin optic foramen—sclerotica. [III d.]

Rec'tus infe'rior : optic foramen—sclerotica. [III d.]

Rec'tus inter'nus : optic foramen—sclerotica. [III d.]

Rec'tus exte'r'nus: 2 heads between which pass III^{d.}, nasal branch of Vth, and VIth nerves and ophthalmic vein; *upper* from outer margin optic foramen, *lower* from ligament of Zinn and process of bone at sphenoidal fissure—sclerotica. [VIth.]

Obliq'uus supe'rior: near optic foramen—"pulley" thence at right angle to sclerotica. [IVth.]

Obliq'uus infe'rior: depression in orbital plate in superior maxilla—sclerotica, outer surface. [III^d.]

(6) NASAL REGION 7.

Pyramida'lis na'si: occipito-frontalis—compressor naris. [Facial.]

Leva'tor la'bii superio'ris ala'que na'si: nasal process superior maxilla—cartilage of the ala and lip. [Facial.]

Dila'tor na'ris ante'rior: Cartilage ala—inner border integument ala. [Facial.]

Dila'tor na'ris poste'rior: nasal notch superior maxilla—skin at inner margin nostril. [Facial.]

Compres'sor na'ris: above incisive fossa superior maxilla—pyramidalis nasi, nasal fibro-cartilage; its fellow opposite side. [Facial.]

Compres'sor na'rimum mi'nor: alar cartilage—skin at the end of the nose. [Facial.]

Depres'sor a'læ na'si: incisive fossa superior maxilla—septum and ala nasi. [Facial.]

(7) SUPERIOR MAXILLARY REGION 4.

Leva'tor la'bii superio'ris: lower margin orbit—lip. [Facial.]

Leva'tor an'guli o'ris: canine fossa superior maxilla—angle mouth. [Facial.]

Zygomat'icus ma'jor: in front zygoma—angle oris. [Facial.]

Zygomat'icus mi'nor: malar bone near maxillary suture—angle oris. [Facial.]

(8) INFERIOR MAXILLARY REGION 3.

Leva'tor la'bii Infe'rio'ris, or **Leva'tor men'ti**: incisive fossa inferior maxilla—skin of chin. [Facial.]

Depres'sor la'bii infe'rio'ris: external oblique line inferior maxilla—integument of lower lip. [Facial.]

Depres'sor an'guli o'ris, or **Quadra'tus men'ti**: external oblique line inferior maxilla—angle oris. [Facial.]

(9) INTER-MAXILLARY REGION 3.

Orbicula'ris o'ris: sphincter oris. [Facial.]

Buccina'tor: alveolar processes superior and inferior maxillæ—converges, to the angle of the mouth, and orbicularis. [Facial, inferior maxillary.]

Riso'rius: fascia above masseter—angle oris. [Facial.]

(10) TEMPORO-MAXILLARY REGION 2.

Masse'ter: malar process superior maxilla, lower border zygoma—angle and lower half ramus inferior maxilla, outer surface. [Inferior maxillary.]

Tempora'lis: temporal fossa, curved line of frontal and parietal bones, pterygoid ridge of sphenoid—Coronoid process inferior maxilla. [Inferior maxillary.]

(11) PTERYGO-MAXILLARY REGION 2.

Pterygoide'us inter'nus: pterygoid fossa, tuberosity palate bone—lower and inner side ramus inferior maxilla. [Inferior maxillary.]

Pterygoide'us exter'nus: *upper* head from pterygoid ridge great wing of sphenoid; *lower* from external pterygoid plate, tuberosity of palate, and superior maxillary bones—pterygoid depression in front condyle inferior maxilla. [Inferior maxillary.]

(1) SUPERFICIAL CERVICAL REGION 2.

Platys'ma myoide'us: clavicle, acromian process, fascia of deltoid and pectoralis major—inferior maxilla below external oblique line. [Facial, superior cervical.]

Ster'no-clei'do-mastoide'us: sternum and clavicle—mastoid process, superior occipital curved line. [Spinal accessory, cervical plexus.]

(2) INFRA-HYOID REGION 4.

Ster'no-hyoide'us: sternum and sternal end of clavicle—hyoid bone. [Communicating branch of descendens and communicans noni.]

Ster'no-thyroide'us: upper posterior edge sternum—oblique line of ala of cartilage (thyroid.) [Communicating branch of descendens and communicans noni.]

Thy'ro-hyoide'us: Oblique line of thyroid cartilage—body and greater cornu hyoid bone. [Hypoglossal.]

O'mo-hyoide'us: upper border scapula (bound down to clavicle by cervical fascia)—hyoid bone. [Communicating branch of descendens and communicans noni.]

(3) SUPRA-HYOID REGION 4.

Digas'tricus: mastoid process of temporal (ligament binding to hyoid bone)—symphysis inferior maxilla. [Facial, inferior dental.]

Sty'lo-hyoide'us: outer surface, middle styloid process—body hyoid bone, perforated by digastricus. [Facial.]

Mylo-hyoide'us: (forms floor of mouth) mylo-hyoid ridge of inferior maxilla—body of os hyoides. [Inferior dental.]

Ge'nio-hyoid'e'us: inferior genial tubercle inferior maxilla—body os hyoides. [Hypoglossal.]

(4) LINGUAL REGION (5) 4.

Ge'nio-hy:-glos'sus: superior genial tubercle of inferior maxilla—os hyoides and whole length inferior surface tongue. [Hypoglossal.]

Hy:-glos'sus: side of body and greater and lesser cornua hyoid—back and side of tongue. [Hypoglossal.]

Lingua'lis: under surface glossa from base to tip, between hyo-glossus and Genio-hyo-glossus. [Chorda tympani.]

Sty'lo-glo'sus: outer and anterior center styloid process—side of tongue. [Hypoglossal.]

(5) PHARYNGEAL REGION (5) 4.

Constric'tor infe'rior: sides of cricoid and thyroid cartilages—fibrous raphe of posterior median line of pharynx. [Pharyngeal plexus, glosso-pharyngeal, external laryngeal.]

Constric'tor me'dius: greater and lesser cornua hyoid—posterior median pharyngeal raphe. [Glosso-pharyngeal, pharyngeal plexus.]

Constric'tor supe'rior: lower 3d of the margin of internal pterygoid plate, palate and contiguous palatal muscles—posterior median pharyngeal raphe and occipital pharyngeal spine. [Glosso-pharyngeal, pharyngeal plexus.]

Sty'lo-pharynge'us: inner side base of styloid process—constrictor muscles and upper border thyroid cartilage. [Glosso-pharyngeal and pharyngeal plexus.]

(6) PALATAL REGION 5.

Leva'tor pala'ti: under surface petrous portion of temporal, Eustachian tube—posterior surface soft palate. [Facial.]

Ten'sor pala'ti: scaphoid fossa of the sphenoid, Eustachian tube (bound to hamular process)—anterior surface hard and soft palate. [Otic ganglion.]

Azygos uvulae: posterior nasal spine palate bone—uvula. [Facial.] (Is not a *single* muscle as its name implies.)

Pala'to-glos'sus: (anterior pillar) anterior lateral surface soft palate—side and dorsum of tongue. [Meckel's ganglion.]

Pala'to-pharynge'us: (posterior pillar) soft palate—joins stylo-pharyngeus to be inserted into posterior border thyroid cartilage. [Meckel's ganglion.]

(7) INTRA-LARYNGEAL REGION 5.

Cri'co-thyroid'e'us: front and side of cricoid—up- and outwards to lower border thyroid cartilage. [Laryngeal to the muscles this group.]

Thy'ro-arytaenoid'e'us: posterior surface thyroid cartilages and

crico-thyroid membrane—backwards to anterior surface arytenoid cartilage; (false vocal cord.)

Cri'co-arytænoide'us latera'lis: superior border cricoid cartilage—obliquely up- and backwards to external angle base arytenoid cartilage.

Cri'co-arytænoide'us poste'rior: posterior surface cricoid cartilage—up- and outwards to external angle base arytenoid.

Arytænoide'us: fills up posterior concave surface of arytenoid cartilage.

(8) EPIGLOTTIDIAN REGION 3.

Thy'ro-epig'otide'us: internal surface thyroid cartilage—upwards to margin of epiglottis. [Laryngeal to the muscles of this group.]

Arytæ'no-epiglottide'us supe'rior: apex arytenoid cartilage—to fold mucous membrane between arytenoid cartilage and side of epiglottis.

Arytæ'no-epig'ottide'us infe'rior: arytenoid cartilage just above superior vocal cord—forwards and upwards to the margin of the epiglottis.

(9) ANTERIOR VERTEBRAL REGION 4.

Rec'tus cap'itis anti'cus ma'jor: (continuation scalenus anticus) 4 slips from anterior tubercles transverse processes 3d, 4th, 5th and 6th cervical vertebræ—basilar process occipital bone. [Suboccipital and cervical plexus.]

Rec'tus cap'itis ant.'cus mi'nor: anterior surface lateral mass of atlas and its transverse process—basilar process occipital. [Suboccipital, cervical plexus.]

Rec'tus latera'lis: upper surface transverse process atlas—jugular process occipital. [Suboccipital.]

Lon'gus col'li: *1st portion* from anterior tubercles transverse processes of 3d, 4th and 5th cervical vertebræ—tubercle of anterior arch of atlas; *2d portion* from 1st, 2d (and 3d) dorsal—transverse processes 5th and 6th cervical vertebræ; *3d portion* from 1st, 2d, 3d dorsal and 7th, 6th, 5th cervical—bodies 2d, 3d and 4th cervical vertebræ. [Lower cervical branches.]

(10) LATERAL VERTEBRAL REGION. 3.

Scale'nus anti'cus: inner border and superior surface 1st rib—anterior tubercles transverse processes 3d, 4th, 5th and 6th cervical vertebræ. [Branches lower cervical.]

Scale'nus me'dius: behind groove for subclavian artery on 1st rib—posterior tubercles transverse processes lower 6 cervical vertebræ. [Branches lower cervical.]

Scale'nus posti'cus: 2d rib, outer surface—transverse processes lower 3 cervical vertebræ. [Branches lower cervical.]

(II) POSTERIOR VERTEBRAL REGION 4.

Rec'tus cap'itis post'icus ma'jor: spinous process axis—inferior occipital curved line. [Occipital.]

Rec'tus cap'itis post'icus mi'nor: tubercle posterior arch atlas—beneath insertion of above. [Occipital.]

Obliq'uus infe'rior: spinous process axis—horizontally to transverse process atlas. [Occipital.]

Obliq'uus supe'rior: transverse process atlas—occipital bone, between curved lines. [Occipital.]

ARTERIES.

CAROTIS COMMUNIS: arises on right side, from innominate, behind sterno-clavicular articulation; on left side, from arch of aorta, highest part, and is more deeply placed than the right and passes obliquely outwards to root of neck behind sterno-hyoid and sterno-thyroid muscles, innominate vein and thymus gland. Starting now from each side of neck, each pass up- and outwards to superior border of thyroid cartilage, there dividing into external and internal carotid. Course indicated by line from sternal end clavicle to point midway between mastoid process and angle of inferior maxilla. Vein lies to outside, pneumogastric nerve on posterior plane between them, the three being enveloped by same sheath of cervical fascia. No branches but terminal.

CAROTIS EXTER'NA: (8 brs., see above) up between neck of inferior maxilla and external meatus, there dividing into temporal and internal maxillary. Crossed by hypoglossal nerve, lingual and facial veins, digastric and stylo-hyoid muscles. Is quite superficial. **Thyroide'a supe'rior**: greater cornu hyoid, curving down to thyroid gland *anas.* with its fellow of opposite side and inferior thyroid. **Hyoid'e'a**, runs along inferior border of bone, *anas.* with opposite fellow. **Descen'dens superficialis**, down- and outwards across sheath common carotid supplying sterno-mastoid and adjacent muscles and integument. **Larynge'a supe'rior** pierces thyro-hyoid membrane supplying muscles, mucous membrane glands, etc., of larynx and epiglottis; *anas.* with opposite fellow. **Cri'co-thyroide'a**, transversely across crico-thyroid membrane, *anas.* with opposite fellow. **Lingua'lis**: up- and inwards to under surface of tongue (ranine); runs parallel with hypoglossal nerve. **Hyoid'e'a**, along superior border bone, supplying muscles, *anas.* with opposite fellow. **Dorsa'lis lin'guæ**, ascends to dorsum tongue *anas.* with opposite fellow, supplying mucous membrane, tonsil, epiglottis, soft palate, etc. **Sublingua'lis** runs for- and

outwards to sublingual gland, supplies it, adjacent muscles, membranes, etc. *Ranina*, on lingualis to tip of tongue, accompanied by gustatory nerve; *anas.* with opposite fellow, supplying adjacent parts. **Facialis**: near angle inferior maxillary obliquely for- and upwards to maxillary gland, then up over jaw, up- and forwards to angle of mouth, along side of nose to inner canthus of eye (angular.) **CERVICAL BRS.**: *Palatina ascenden's*, between stylo-glossus and stylo-pharyngeus, to outer side pharynx, supplying muscles, tonsil, Eustachian tube, etc.; divides, one branch going up tensor palati to supply soft palate, glands, etc., the other branch goes to tonsil *anas.* with tonsillar. *Anas.* posterior palatine of internal maxillary. *Tonsillaris*, up to supply this gland and root of tongue. *Submaxillares* (3 or 4), supplying this gland and adjacent parts. *Submentalis*, off just as facial quits submaxillary gland, running forwards upon mylo-hyoid, supplying it and digastric (*anas.* with sublingual) to symphysis; the superficial branch turns round the chin, passing up to *anas.* with inferior labial, supplying muscles and integument; the deep branch runs up on bone to supply deep muscles and lip, *anas.* with inferior labial and mental. **FACIAL BRS.**: *Musculares*, to internal pterygoid, masseter, buccinator. *Labialis inferior*, beneath depressor anguli oris to lower lip, *anas.* inferior coronary, mental branch of dental, etc. *Coronaria inferior* beneath depressor anguli oris along edge lower lip, supplying adjacent parts and *anas.* with opposite fellow, inferior labial, and mental branch of inferior dental. *Coronaria superior* along edge of upper lip, *anas.* with opposite fellow, supplying adjacent parts, septum and ala of nose. *Lateralis nasi*, supplying side and dorsum of nose, septum, *anas.* opposite fellow, infra-orbital and nasal branch ophthalmic. *Angularis*, terminal branch, ascends up to inner canthus, *anas.* with nasal branch ophthalmic. **Occipitalis**: from posterior part near inferior margin of digastricus, up between atlas and mastoid process, horizontally across occiput, then up to vertex, then dividing into numerous branches. *Musculares*, to digastricus, stylo-hyoid, stylo-mastoid, splenius capitis, trachelo-mastoid. *Auricularis*, to posterior surface concha. *Meningea inferior* along side internal jugular vein through foramen lacerum to dura in posterior fossa. *Arteria princeps cervicis*, descends back part neck, superficial branch supplying splenius and trapezius, *anas.* with superficial cervical; the deep branch *anas.* with vertebral and cervical branch superior intercostal; supplies adjacent parts. *Craniales*, to mus-

cles and integument of posterior surface cranium. *Auricula'ris post'e'rior*: from above stylo-hyoid, ascends beneath parotid gland, to groove between mastoid process and ear cartilage, dividing into anterior and posterior branches, the former passes forwards to *anas.* with temporal; the latter, back to *anas.* with occipital. *Sty'lo-mastoid'e'a*, enters do foramen supplying cells, tympanum, and semi-circular canals. *Auricu-la'ris*, to back part of cartilage of ear, and, penetrating, to its anterior surface. *Pharynge'a ascen'dens*: (smallest branch) deep seated, arising near commencement of external carotid, up, between internal carotid and pharynx, to base of skull. *Ex-ternal branches*, to recti antici muscles, glands of neck, sym-pathetic, pneumogastric and hypoglossal nerves; *anas.* with ascending cervical. *Pharynge'a* (3 or 4) to parts of pharynx and adjacent muscles, etc. *Meninge'a* backwards through foramen lacerum posterius, another branch through foramen lacerum basis cranii, another through anterior condyloid fo-ramen to dura mater. *Tempora'lis*: from parotid gland up to root zygoma, dividing into anterior and posterior. *Transver'sa facie'i*, in parotid gland, runs across face, supplying glands, integument and muscles, *anas.* with facial and infra-orbital. *Tempora'lis me'dia*, above zygoma to temporal muscle and orbicularis, *anas.* with lachrymal and palpebral branches of ophthalmic and deep temporal branches of internal maxil-lary. *Auricula'ris anterio'res* to anterior ear, *anas.* with posterior auricular. *Tempora'lis ante'rior* forwards over forehead, supplying integument, muscles, etc., *anas.* with frontal and supra-orbital. *Tempora'lis poste'rior*, up- and back-wards over side of head, *anas.* with opposite fellow, posterior auricular and occipital. *Maxilla'ris inter'na*: (see external caro-tid) inwards to inner side of condyle inferior maxilla into spheno-maxillary fossa, to supply deep structures of the face. MAXILLARY PORTION: *Ca'vi tym'pani* (tympanic) up through fissura Glaseri, supplying membrana tympani, laxator tympa-ni, *anas.* with stylo-mastoid and Vidian. *Meninge'a me'dia*, from internal lateral ligament of jaw up through foramen spi-nosum, dividing into anterior and posterior branches, supply-ing anterior and posterior surface of dura and bones, facial nerves, and branches to other parts; *anas.* with opposite fel-low, anterior and posterior meningeal. *Meninge'a par'va*, through foramen ovale to Casserian ganglion and dura; also to nasal fossa and soft palate. *Alveola'ris infe'rior*, (inf. den-tal) with dental nerve to foramen on ramus, then along dental canal supplying teeth, etc., till opposite bicuspid tooth, then

divides into incisor and mental branches, the former to incisor teeth, *anas.* with opposite fellow; the latter passes out mental foramen, *anas.* with inferior labial, inferior coronary, submental and supplies adjacent parts. Mylo-hyoid branch given off just as artery enters inferior dental foramen; it runs in its groove to its muscle. **PETERYGOID PORTION:** *Tempora'les profun'dæ* (2) anterior and posterior branches up to temporal muscle. *Peterygoide'æ*, to do muscles. *Masseter'ica*, to do muscle. *Bucca'lis*, to do muscles. **SPHENO-MAXILLARY PORTION:** *Alveola'ris*, common branch with following, supplying (superior dental) teeth, antrum and gums. *Infra-orbita'lis*, continuation of main artery, along infra-orbital canal, and out infra-orbital foramen, supplying inferior rectus and inferior oblique, antrum, front teeth, lachrymal sac, etc.; *anas.* with facial, buccal, nasal branch ophthalmic, etc. *Palati'na descen'dens*, down posterior palatine canal to gums, mucous membrane, palate, etc. *Vidia'na*, through its canal, with nerve, to pharynx, Eustachian tube and tympanum. *Pterygo-palati'na*, to upper part pharynx and Eustachian tube. *Spheno-palati'na* (nasal), to mucous membrane of nose, septum, antrum, ethmoid and sphenoid cells.

CAROTIS INTER'NA: (8 brs.) Superior border thyroid cartilage up through carotid foramen in temporal bone; in the skull it runs forwards in a course represented by ↘ [italic f laid horizontally.] No branches from cervical part. Tonsil is internal to it. *Tympan'ica*: to tympanum. *Receptac'u'æ*: small branches to cavernous sinus, pituitary body, Casserian ganglion, etc. *Ophthal'mica*: at inside anterior clinoid process, forwards through optic foramen to inner canthus, dividing into frontal and nasal. *Lachryma'lis*, to lachrymal gland, conjunctiva; malar and meningeal branches; *anas.* freely with temporal, palpebral, etc. *Supra-orbita'lis*, out supra-orbital foramen to muscles and skin of forehead and pericranium; *anas.* with temporal, facial, etc. *Ethmoida'les*, (2) anterior and posterior to ethmoidal cells and meninges. *Palpebra'les*, (2) superior and inferior, encircle eyelids, down nasal duct, *anas.* with temporal, inferior orbital, etc. *Fronta'lis*, out inner angle orbit to forehead, supplying adjacent parts, *anas.* with supra-orbital. *Nasa'lis*, to lachrymal sac, then down the nose, supplying its whole surface; *anas.* with facial, etc. *Cilia'res bre'ves*, (12—15) supply choroid and ciliary processes. *Cilia'res lon'gæ*, (2) to ciliary ligament and iris. *Cilia'res anterio'res*, from muscular branches, to iritic arterial circle. *Centra'lis retinae*, pierces optic nerve and runs in it to retina.

Muscula' res, (2) superior and inferior to muscles of eye. *Cere' bri arte' ria ante' rior*: at fissure of Sylvius forward in the great longitudinal fissure, *anas.* with its fellow by *ante' rior commu' nicans*; curves round anterior border corpus callosum, running back to its posterior part to *anas.* with posterior cerebral supplying olfactory and optic nerves, inferior surface anterior lobes, 3d ventricle, anterior perforated space, corpus callosum and inner surface of hemispheres. *Cere' bri arte' ria me' dia*: (largest branch,) obliquely outwards along fissure of Sylvius, dividing into *ante' rior* branch to pia of anterior lobe, *me' dian* branch to small lobe at extremity of Sylvian fissure; *poste' rior* branch which supplies middle lobe; *small* branches to corpus striatum through substantia perforata. *Commu' nicans poste' rior*: from back part of artery backwards, *anas.* with posterior cerebral of basilar. *Choroide'a ante' rior*: from back part of artery back- and outwards, entering descending horn of lateral ventricle; is distributed to hippocampus major, corpus fimbriatum and choroid plexus.

VERTEBRA' LIS: (6 brs.) 1st and largest branch of subclavian. Enters foramen in transverse process of 6th cervical vertebra and ascends in these cervical foramina to the axis, then outwards, piercing occipito-atloid ligament and dura, passing through foramen magnum along in front of medulla, unites with opposite fellow to form basilar. *Spina' les latera' les*, enter spinal canal through the intervertebral foramina and supply (anterior branches) the cord and membranes and (posterior branches) posterior surface of vertebral bodies. *Muscula' res*: deep muscles of neck, *anas.* with occipital and deep cervical. *Poste' riores meninge' a*, (2) to falx cerebelli. *Spina' lis ante' rior*, given off near termination, unites with opposite fellow, and descends on cord, *anas.* with spinal branches through the intervertebral foramina down to sacrum. Supplies pia of cord (being placed beneath it) and cord. *Spina' lis poste' rior*, arises at side of medulla and passes down posterior surface of cord, being reinforced similarly to the anterior spinal, to sacrum. *Infe' rior cerebella' ris*, winds back over medulla, to under surface of cerebellum, there dividing, the inferior branches going backwards to notch between the two hemispheres, the external branch supplying the inferior surface-*anas.* with superior cerebellar; branches, also to choroid plexus, 4th ventricle.

BASILLA' RIS: (see above) from posterior to anterior borders of pons, there dividing into posterior cerebral. *Transversa*, to pons, internal auditory meatus, under surface cerebellum

(ant. cerebellar). *Superior cerebella'ris*, near end basilar, up over cerebellum, supplying it, pineal gland, velum interpositum. *Posterior cerebra'lis*, winds round crus cerebri to inferior surface of posterior cerebral lobes, supplying them, and choroid plexus, *anas.* with anterior and middle cerebral.

Circle of Willis: (10); from behind forwards: basilar, 2 posterior cerebral, 2 posterior communicating, 2 internal carotids, 2 anterior cerebral, anterior communicating.

Inferior Thyroide'a: (see arteries of upper extremity) branch of thyroid axis, up behind sheath of common carotid and sympathetic nerve to under surface of thyroid gland, *anas.* with opposite fellow, and superior thyroid. *Laryngea'lis*, to back part larynx. *Trachea'les*, to trachea, *anas.* with bronchial. *Œsophagea'les*. *Cervica'lis ascen'dens*, up neck, supplying muscles, vertebræ, cord and membranes.

Cervi'cis profun'da: (see arteries of upper extremity) branch of superior intercostal, ascends back part of neck, below complexus, to axis, supplying adjacent parts, and *anas.* with branches of vertebral and princeps cervicis of occipital.

VEINS.

Ve'næ Dip'loes: walls only of epithelium, with many *culs-de-sacs*. *Fronta'lis*, opens into supra-orbital through supra-orbital notch. *Tempora'lis ante'rior* opens into deep temporal. *Tempora'lis poste'rior* confined to parietal region, opens into lateral sinus. *Occipita'lis*, opens into occipital vein or sinus.

Cerebra'les: noted for their thin coats, muscular tissue and absence of valves. *Superiores*, (7 or 8 on each side) for- and inwards to superior longitudinal sinus, there receiving inferior cerebral which drain the same hemisphere. *Inferiores anteri'o-res*, under surface of anterior lobes; terminate in cavernous sinus. *Inferiores latera'les*, (3 to 5) terminate in lateral sinus. *Inferiores Me'diæ*, from posterior lobe, etc., to straight sinus behind venæ Galeni. **Ve'næ Cale'ni** (2, one from right, one from left ventricle) formed by *ve'na corpo'ris stria'ti* and *ve'na choroide'a*; pass back and out of transverse fissure to straight sinus. *Cerebella'res*, superior, inferior and lateral sets; the 1st open into straight, the 2d into lateral, the 3d into superior petrosal sinus.

Si'nus: (16 in No.) *Superior longitudina'lis*, begins at crista Galli, runs back over cerebrum to torcular Herophili; receives superior cerebral and parietal veins. *Infe'rior longitudina'lis*, along posterior part free margin of falx cerebri to straight sinus. *Tentorii* (straight), junction of tentorium and falx

cerebri to torcular Herophili; receives inferior longitudinal sinus, venæ Galeni, inferior median cerebral, and superior cerebellar veins. *Laterales*, (2) from torcular to foramen lacerum posterius into internal jugular vein, receives straight and occipital sinus, etc. *Occipitales*, (2) smallest; posterior margin of foramen magnum to torcular. *Caverni*, (2) sides of sella Turcica from sphenoid fissure to apex petrous part of temporal. Receives ophthalmic vein connecting the frontal with these sinus; also inferior anterior cerebral veins. *Circularis*, surrounds pituitary body, communicates with each cavernous. *Inferiores petrosales*, (2) termination of cavernous to internal jugular vein. *Transversus*, connects the inferior petrosales across basilar process of occipital. *Superiores petrosales*, (2) on superior border petrous part of temporal, connecting lateral and cavernous; receives inferior lateral cerebral, anterior lateral cerebellar veins.

Ve'na Facia'lis: obliquely across side face from inner canthus, to unite, under inferior maxilla, to form a trunk for internal jugular. Receives *supra-orbita'lis*, *supra-palpebra'lis*, *nasalis*, *inferior palpebra'lis*, *fronta'lis*, *supra-orbitalis*, *supra-labia'lis*, *inferior labia'lis*, *bucca'lis*, *masseter'ica*, *submentalis*, *inferior palati'na* (which arises from plexus about tonsil, etc.), *submaxilla'ris*, *ranina*; also communicates with ophthalmic (see cavernous sinus).

Tempora'lis: from side and vertex of head, uniting with internal maxillary forms temporo-maxillary. Receives *parotideæ*, *anteriores auricula'res*, *transversa faciei*.

Maxilla'ris Inter'na: *media meningeæ*, *temporalis profunda*, *pterygoideæ*, *masseter'ica*, *bucca'lis*, *palati'na*, *inferior dentalis*, forms, with above, temporo-maxillary.

Temporo-Maxilla'ris: union of temporal and internal maxillary, descends in parotid gland and divides, one branch going to join facial, the other to external jugular. Receives posterior auricular.

Posterior auricula'ris: plexus side of head, receives *stylo-mastoideæ* and branches from external ear; empties into temporo-maxillary.

Occipita'lis: (from plexus), back part vertex of skull deeply between muscles of neck lying in course of artery, to internal jugular. Receives *mastoideæ*, which communicates with lateral sinus.

Jugula'ris Exter'na: from temporo-maxillary near angle lower jaw, down into subclavian accompanied by auricularis magnus nerve. Has 2 pair of valves. Receives *occipita'lis*, *posterior*

jugula'ris externa (draining superficial muscles of back of neck), *supra-scapula'ris*, *transver'sa cervic'is*.

Ante'rior jugula'ris: drains integument and superficial muscles of anterior and middle portion of neck, emptying into subclavian. No valves.

Jugul'ris inter'n: from jugular foramen at junction of lateral and inferior petrosal sinus, vertically down the side of neck (outer side of main arteries), uniting with subclavian to form vena innominata; 1 pr. valves, $\frac{3}{4}$ inch above termination. Receives *facial'is*, *lingua'lis*, *pharynge'æ*, *super'ior thyroide'a*, *me'dia thyroide'a*.

Vertebra'lis: drains occipital region and deep muscles of back of neck; enters foramen in transverse process of atlas down through similar foramina of the cervical vertebræ to 6th (or 7th) where it passes out to enter v. innominata. Receives *post'e'rior condylo'i'da*, *muscula'res*, *dorso-spina'les*, *menin'gio-achidia'næ*, *ascen'dens* and *profun'da cervica'les*. 1 pr. valves guard its mouth.

NERVES.

CRANIAL. 1st or *Ner'vus olfac'us*.—From corpus striatum, middle and anterior lobes of cerebrum. *Supplies* the Schneiderian membrane. Special function, smelling.

2d or *Op'ticus*.—From optic thalami and the corpora geniculata et quadrigemina, out through optic foramen to retina. Special function, sight.

3d or *Moto'rius Ce'uli*.—From crus cerebri and pons (?) out through foramen lacerum anterius to all the muscles of the orbit, save the superior oblique and external rectus; a few filaments pass to the iris. Is a motor nerve.

4h or *Pathet'icus*.—From valve of Vieussens, through foramen lacerum anterius to superior oblique. Is a motor.

5h or *Trigem'inus*.—The *sensory*, or posterior root, from the lateral tract of the medulla, the pons, and cerebellum (middle peduncle). The *motor* root from the pyramidal body. The *sensory* supplies are to the eye-ball (iris, ciliary body, etc), lachrymal gland, conjunctiva, Schneiderian membrane, all the muscles and integument about the eye-ball, orbit, os frontalis, nose, mouth, cheek, lips, temple, superior portion of pharynx, tongue, gums, and teeth. *Motor* filaments are given to the external and internal pterygoid, temporal, buccinator, and masseter muscles. *Special* sensation (taste) to mucous membrane of mouth, gums, tongue (anterior and middle portion), sub-lingual gland, conical and fungiform papillæ.

BRS.—I. OPHTHALMICUS: *sensory*; forward through sphenoidal fissure from Casserian ganglion, joined by cavernus plexus of sympathetic. *Lachrymalis*. *Frontalis*; (a) supra-trochlearis, (b) supraorbital. *Nasal*; ganglionic, long ciliary (2 or 3), infra-trochlear branches. II. SUPERIOR MAXILLARIS; sensory: forwards through foramen rotundum from Casserian ganglion appearing on face through infra-orbital foramen. *Orbital*; (a) temporal, (b) malar branches. *Spheno-palatini* (2). *Posteriores dentales* (2); (a) anterior branches, (b) posterior branches. *Anterior dentales*. *Palpebrales*. *Nasales*. *Labiales*. All inosculate with branches from facial. III. INFERIOR MAXILLARIS: sensor root from Casserian ganglion, motor unites with it after passing through foramen ovale. ANTERIOR DIVISION: (a) masseteric, (b) deep temporal, (c) buccal, (d) pterygoid branches. POSTERIOR DIVISION: *Auriculo-temporalis*; (a) anterior temporal, (b) posterior temporal (out under cover of parotid), (c) communicating with facial, (d) inferior and superior auricular, (e) 2 branches to meatus, (f) branches to temporo-maxillary articulation, (g) branches to parotid gland. *Gustatorius*, side of tongue to lip; (a) communicating branches, (b) branches of distribution to tongue, gums, etc. *Inferior dentales*, in dental canal inferior maxilla to teeth, etc.; (a) mylo-hyoid to do muscle, etc., (b) dental branches.

6th or Abducens.—From pons, corpus pyramidale and medulla through foramen lacerum anterius to supply motor influence to the rectus externus oculi.

7th or Facial's.—From lateral tract medulla and 4th ventricle, out through stylo-mastoid foramen to *all* the muscles of the face, ear and their integument, the platysma, buccinator, digastric, stylo-hyoid, lingualis, stapedius, laxator and tensor tympani, levator palati, and azygos uvulæ. Is essentially a motor nerve. *Tympanicus*. *Chorda tympani*. *Posterior auricularis*; (a) auricular branch, (b) occipital branch. *Stylohyoidæus*. *Digastric branch*. *Temporo-facialis*; (a) temporal branches, (b) infra-orbital, (superficial and deep branches), (c) malar branches. *Cervico-facialis*; (a) buccal, (b) supra-maxillary branches, (c) infra-maxillary branches.

8th or I. Glosso-pharyngeus, II. Pneumogastricus, III. Spinalis Accessorius.—I. and II. from floor of 4th ventricle; III. from lateral tract of cord as low as 6th cervico-spinalis, and also from medulla just below origin of I. and II. Part I. passes out through foramen lacerum posterius to supply *sensation* to mucous membrane of pharynx, fauces, Eustachian tube,


tympanum, and tonsil; *motor* influence to the pharyngeal muscles; *gustation* to posterior third of tongue and its lateral papillæ. Branches of *communication* (sympathetic, facial, tympanic); *Carotid* branches. *Pharyngeal* branches. *Muscular* branches. *Tonsillar* branches. *Lingual* branches. Part II, through foramen lacerum posterius to supply *motor* and *sensor* filaments to the muscles and parts about the pharynx, larynx and trachea concerned in speech and respiration; *motor* filaments to the pharynx, heart, œsophagus, stomach, and filaments to the splenic and hepatic plexi. *Auricula'ris*. *Pharyngeal branch*. *Superior laryngeal'lis*. *Recur'rens* (or inferior *laryngeal'lis* (the motor of larynx). *Cervico-cardiac* (2 or 3 in number). *Thoracico-cardiac*. *Anteriores pulmona'res* (2 or 3 in number.) *Posterior pulmona'ris*. *Œsophagea'les*. *Gastric* branches. Part III, supplies motor filaments to sterno-mastoideus and trapezius. The accessory part arising from lateral tract of cord, the spinal portion as low down as 6th cervical nerve, passing up in spinal foramen into skull, then out, with the accessory portion, through jugular foramen.

9th or Hyp:glos'sus.—From floor of medulla. Is the *motor* of the tongue. Out through anterior condyloid foramen to supply the genio-hyoid, genio-hyo-glossus, hyo-glossus, stylo-glossus, thyro-hyoid, sterno-hyoid, omo-hyoid, and sterno-thyroid muscles. Is deep-seated (beneath internal carotid), but finally curves over externally to the carotid to muscles for distribution. Has *branches of communication* with pneumogastric, sympathetic, 1st and 2d cervical and gustatory. *Descen'dens noni* (on carotid sheath), joining with 2d and 3d cervical. *Thyro-hyoid* branch. *Muscular* branches.

CERVICA'LES: each increase in size from 1st to 5th; 8 pairs in all. Have anterior and posterior branches, the latter having ganglionic enlargements. The 1st, or *sub-occipital*, (anterior branch) has exit between atlas and occiput, the remaining 7 between their respective vertebræ. The 4 upper (anterior branches) unite to form the cervical plexus; the 4 lower (anterior) with the 1st dorsal form the brachial plexus.

Cervi'cis p'exus: SUPERF. BR. *Superficial'lis colli*, from 2d and 3d; obliquely forwards to anterior and lateral parts of neck. *Auricula'ris mag'nus*, from 2d and 3d; ascends to parotid gland, having facial, posterior auricular and mastoid branches. *Occipita'lis mi'nor*, from 2d; ascends to side of head; has auricular branch. *Supra-clavicular'es*, from 3d and 4th; downwards, having sternal, clavicular, and acromial

branches. DEEP BRs.: *Communicantes*, loop between 1st and 2d, to sympathetic, hypoglossal, pneumogastric, and spinal accessory nerves. *Musculares*, from 1st. *Communicans noni*, from 2d and 3d, uniting with descendens noni. *Threnicus*, from 3d, 4th and 5th; crosses subclavian artery down to middle mediastinum, thence to pericardium, diaphragm and pleura. The left is the longer. POSTERIOR BRANCHES: each have external and internal divisions supplying the muscles of the back of the neck, etc. *Sub-occipitalis*, from 1st, up to sub-occipital region. *Occipitalis major*, the internal branch from the 2d cervical. *Occipital branch*, from the 3d cervical, internal branch. All the others have only the external and internal branches, supplying the muscles contiguous to them.



UPPER EXTREMITY. MUSCLES.

(1) ANTERIOR THORACIC REGION 3.

Pectoralis major: sternal half clavicle, $\frac{1}{2}$ front of sternum down to 7th rib, cartilage of true ribs, aponeurosis—external oblique—anterior bicipital ridge of humerus. [Anterior thoracic.]

Pectoralis minor: 3d, 4th and 5th ribs—anterior border coracoid process of scapula. [Anterior thoracic.]

Subclavius: 1st rib-cartilage—under surface middle 3d of clavicle. [Branch from 5th and 6th cervical.]

(2) LATERAL THORACIC REGION 1.

Serratus magnus: 9 digitations from the 8 superior ribs—whole length inner margin scapula, posterior surface. [Posterior thoracic.]

(3) ACROMIAL REGION 1.

Deltoides: outer 3d anterior border, upper surface, of clavicle; outer margin, upper surface acromian process; whole length lower border spine of scapula—prominence outer surface (middle) humerus. [Circumflex.]

(4) ANTERIOR SCAPULAR REGION 1.

Subscapularis: inner $\frac{2}{3}$ subscapular fossa—lesser tuberosity humerus. [Subscapular.]

(5) POSTERIOR SCAPULAR REGION 4.

Supra-spinaeus: internal $\frac{2}{3}$ of supra-spinous fossa of scapula—upper facet greater tuberosity humerus. [Supra-scapular.]

Infra-spinaeus: internal $\frac{2}{3}$ of infra-spinous fossa—middle facet greater tuberosity humerus. [Supra-scapular.]

Te'res mi'nor: dorso-axillary border scapula—lowest facet greater tuberosity of humerus. [Circumflex.]

Te'res ma'ior: dorsum inferior angle scapula—posterior bicipital ridge humerus. [Subscapular.]

(6) ANTERIOR HUMERAL REGION 3.

Coraco-brachia'lis: apex coracoid process scapula—rough ridge inner (middle) side of humerus. [Musculo-cutaneous.]

Bi'ceps: long head above glenoid cavity; short head, coracoid process—bicipital tuberosity radius. [Musculo-cutaneous.]

Brachia'lis anti'cus: lower half outer and inner surfaces shaft humerus, septa—under surface coronoid process ulna. [Musculo-cutaneous, musculo-spiral.]

(7) POSTERIOR HUMERAL REGION 2.

Tri'ceps: long head, depression below glenoid cavity; external head, posterior superior part of humerus; internal head, posterior surface of humerus *below* musculo-spiral groove—olecranon process ulna. [Musculo-spiral]

Subancone'us: just above olecranon fossa humerus—posterior ligament elbow-joint. [Musculo-spiral.]

(8) ANTERIOR BRACHIAL REGION, SUPERFICIAL LAYER, 5.

Prona'tor ra'dii te'res: above internal condyle humerus, common flexor tendon, fascia, inner side coronoid process ulna—rough ridge radius, outer (middle) surface. [Median.]

Flex'or car'pi radia'lis: common flexor tendon, internal condyle humerus, fascia—base of index metacarpal. [Median.]

Palma'ris lon'gus: common internal condyloid (humerus) flexor tendon, fascia—annular ligament and palmar fascia. [Median.]

Flex'or car'pi ulna'ris: 1st head, common flexor tendon internal condyle humerus; 2d head, internal margin olecranon—pisiform bone. [Ulnar.]

Flex'or subli'mis d'gito'rum: 1st, internal condyle humerus (common flexor tendon); 2d head, inner side coronoid process ulna; 3d head, oblique line radius—lateral margins 2d phalanges, tendon split for passage of flexor profundus digitorum. [Median.]

(9) ANTERIOR BRACHIAL REGION, DEEP LAYER, 3.

Flex'or profun'dus d'g'ito'rum: upper $\frac{2}{3}$ anterior and inner surface ulna, inner side coronoid process, interosseous membrane—bases last phalanges. [Ulnar, anterior interosseous.]

Flex'or lon'gus pol'licis: upper $\frac{2}{3}$ anterior surface radius, interosseous membrane—base last phalanx thumb. [Anterior interosseous.]

Prona'tor quadra'tus: oblique line and lower 4th ulna—lower

4th anterior surface and external border radius. [Anterior interosseous.]

(10) RADIAL REGION 3.

Supinator longus: upper $\frac{2}{3}$ external condyloid ridge humerus, septum—styloid process radius. [Musculo-spiral.]

Extensor carpi radialis longior: lower third external condyloid ridge humerus, septum—base metacarpus indicis. [Musculo-spiral.]

Extensor carpi radialis brevior: common tendon external condyle humerus, external lateral ligament, septa—base metacarpus middle finger. [Posterior interosseous.]

(11) POSTERIOR BRACHIAL REGION, SUPERFICIAL LAYER, 4.

Extensor communis digitorum: common tendon external condyle humerus, septa—2d and 3d phalanges. [Posterior interosseous.]

Extensor minimi digiti: external condyle humerus, septa—unites with tendon extensor communis digitorum to be inserted into 2d and 3d phalanges of little finger. [Posterior interosseous.]

Extensor carpi ulnaris: common tendon external condyle humerus, middle 3d posterior border ulna, fascia—base 5th metacarpus. [Posterior interosseous.]

Anconeus: back part outer condyle humerus—side, olecranon and upper posterior 3d ulna. [Musculo-spiral.]

(12) POSTERIOR BRACHIAL REGION, DEEP LAYER, 5.

Supinator brevis: external condyle humerus, external lateral and orbicular ligaments, oblique line ulna—(surrounds radius at its upper part) back part inner surface; outer edge bicipital tuberosity; oblique line of radius. [Posterior interosseous.]

Extensor ossis metacarpi pollicis: posterior surface shaft ulna and radius (middle 3d), interosseous membrane—base 1st metacarpus. [Posterior interosseous.]

Extensor primi interossei pollicis: posterior surface radius, interosseous membrane—base 1st phalanx of thumb. [Posterior interosseous.]

Extensor secundi interossei pollicis: posterior surface ulna, interosseous membrane—base 2d phalanx thumb. [Posterior interosseous.]

Extensor indicis: posterior surface ulna, interosseous membrane—joins tendon extensor communis digitorum to 2d and 3d phalanges indicis. [Posterior interosseous.]

(13) THUMB, RADIAL REGION, 4.

Abductor pollicis: ridge trapezium and annular ligament—radial side base 1st phalanx thumb. [Median.]

Oppo'nens po'licis: palmar surface trapezium, annular ligament—whole length 1st metacarpus, radial side. [Median.]

Flex'or bre'vis po'licis: trapezium, outer $\frac{2}{3}$ annular ligament, trapezoid, os magnum, base 3d metacarpus, tendon flexor carpi radialis—both sides base 1st phalanx thumb. [Median, ulnar.]

Adduc'tor po'licis: whole length 3d metacarpus—ulnar side base 1st phalanx thumb. [Ulnar.]

(14) LITTLE FINGER, ULNAR REGION, 4.

Palma'ris bre'vis: annular ligament palmar fascia—skin inner border palm. [Ulnar.]

Abduc'tor min'im'i dig'iti: pisiform bone, tendon flexor carpi ulnaris—ulnar side base 1st phalanx little finger. [Ulnar.]

Flex'or bre'vis min'im'i dig'iti: tip unciform, process annular ligament—base 1st phalanx little finger. [Ulnar.]

Oppo'nens min'im'i dig'iti: unciform process annular ligament—ulnar side 5th metacarpus. [Ulnar.]

(15) MIDDLE PALMAR REGION 3.

Lumb'ica'ies: (4); accessories to flexor profundus digitorum—tendon extensor communis digitorum. [Median and Ulnar.]

I'teros'nei dor's'a'es: (4); metacarpi—base 1st phalanges 1st, 2d, 3d fingers. [Ulnar.]

Interos'nei pa'ma'res: (3); 2d, 4th and 5th metacarpi—1st phalanges of same fingers. [Ulnar.]

ARTERIES.

SUB'CLAVIA: (4 brs.) *Right*, I. from innominate at sternoclavicular articulation to inner margin scalenus anticus. (*Left*, I. from transverse portion aortic arch opposite 2d dorsal vertebra to scalenus anticus); II internal border scalenus anticus to outer of scalenus medius III. from external border scalenus medius to lower border 1st rib, midway along clavicle. **Vertebra'lis**, upper and back portion of part I.—enters foramen 6th cervical vertebra to be continued upwards (see page 10). **Thyroid'e'us ax'is**, anterior part of first portion, inner side scalenus anticus. *Infe'rior thyroide'a* (see page 11). *Transversa'lis colli*, (a) superficial cervical beneath anterior margin trapezius—to trapezius and glands in that region. (b) *Poste'rior scapula'ris* to superior angle of scapula to anastomose at the inferior angle with subscapular. *Supra-scapula'ris*—outwards and backwards parallel with clavicle to supra-spinous fossa; distributed to muscles in that region. **Sterna'lis inter'na** (mammary), origin just below thyroid axis, behind clavicle along

inside chest to 6th intercostal space, there dividing into musculo-phrenic and superior epigastric. *Colmes nervi phrenici*, to diaphragm; anastomoses with other phrenic branches. *Mediastinales*, to areolar of anterior mediastinum, also remains of thymus. *Pericardiales*, to upper pericardium, triangularis sterni, *anas.* musculo-phrenic. *Anteriores intercostales*, to 5 or 6 upper intercostal spaces, to intercostal and pectoral muscles and mammary gland; *anas.* aortic intercostal. *Perforantes*, to 5 or 6 upper intercostal spaces, to pectoral muscles and mammary gland. *Musculo-phrenica*, perforates diaphragm at 8th or 9th rib, supplying intercostal spaces, diaphragm and abdominal muscles. *Epigastrica superior*—down behind rectus to supply that muscle and others near it; *anas.* with inferior epigastric. *Superior intercostales*, upper and back portion 11d part to 1st and 2d intercostal spaces, supplying spinal muscles and cord; *anas.* aortic intercostals. *Profunda cervicis*—back to 7th cervical vertebra and between complexus and semi-spinalis colli runs to axis, supplying contiguous muscles, *anas.* anterior princeps cervicis.

AXILLARIA: (7 brs.) lower border 1st rib to tendons latissimus dorsi and teres major; 1st part, 1st rib to pect. minor; 11d, from superior border pectoralis minor to inferior border same; 111d, from inferior border pectoralis minor to tendon latissimus dorsi. *Superior Thoracica*, 1st part—forwards and inwards along superior border pectoralis minor, supplying pectoral muscles; *anas.* internal mammary and intercostal. *Acromialis Thoracica*, 1st part to upper border pectoralis minor; *Acromiales*, towards acromian process to deltoid; *anas.* suprascapular and posterior circumflex. *Thoracica*, 2 or 3 in number, supplying serratus magnus and pectoral muscles; *anas.* intercostals of internal mammary. *Descending* branches supply pectoralis major and deltoid, as accompanying cephalic vein. *Thoracica loca*, 11. part, down- and inwards along inferior border pectoralis minor to pectoral muscles, axillary and mammary glands, serratus magnus and subscapularis; *anas.* internal mammary and intercostal. *Thoracica alaris*, 11. part, to glands and areolar tissue of the axilla. *Subscapularis*, 111. part, opposite inferior border do muscle, down and back inferior margin do muscle to inferior angle scapula; *anas.* posterior scapular. *Dorsalis scapulae*—dividing into 3 branches, “subscapular,” “infra-spinous,” and “median.” Altogether they supply the scapular, latissimus dorsi and serratus magnus muscles. *Make a general anastomosis.* *Posterior circumflexa*, opposite inferior border subscapularis, winds round neck

humerus to supply deltoid; *anas.* anterior circumflex, supra-scapular, acromio-thoracic. *Anterior circumflexa*, just below above, passes anterior to humerus supplying deltoid; *anas.* posterior circumflex, acromio-thoracic.

BRACHIALIS: (5 brs.) inferior border teres major to $\frac{1}{2}$ inch below bend of elbow. Runs along inner border biceps and coraco-brachialis; is superficial. *Superior profunda*, opposite inferior border trochanter major, winds backwards in spiral groove down to elbow; *anas.* recurrent radial; supplies deltoid, coraco-brachialis, triceps. *Posterior articularis*, perpendicular down to back of elbow-joint; *anas.* interosseous recurrent, posterior ulnar recurrent, anastomotica magna. *Nutricia*, middle of arm to bone near insertion coraco-brachialis. *Inferior profunda*, just below middle arm to *anas.* posterior ulnar recurrent and anastomotica magna at elbow; accompanied by ulnar nerve. *Anastomotica magna*, 2 inches above elbow-joint—winds round and down humerus to elbow-joint; *anas.* posterior ulnar recurrent, inferior profunda, anterior ulnar recurrent. *Musculares*, 3 or 4, to coraco-brachialis, brachialis anticus.

RADIALIS: (12 brs.) end of the brachialis down radial side forearm, along inner border supinator longus to wrist; then winds around carpus beneath thumb-extensors to enter palm of hand between thumb and index finger to form "deep palmar arch": *anas.* deep branch of ulnar. *Radialis recurrens*, below elbow—up arm supplying brachialis anticus, supinator longus, supinator brevis, *anas.* superior profunda. *Musculares*, to radial side forearm. *Superficialis volæ*, just as artery about to wind around the carpus—to muscles in ball of thumb; *anas.* with ulnar forming "superficial palmar arch." *Anterior carpalis*, to wrist; *anas.* anterior carpalis of ulnar. *Posterior carpalis*, to wrist; *anas.* posterior carpalis of ulnar, anterior interosseous, and posterior perforating of deep palmar arch as 2 *dorsal interosseous* branches. *Metacarpalis*, (1st dorsal interosseous) supplies adjoining sides index and middle fingers. *Dorsales pollicis*, (2) along dorsum of thumb. *Dorsalis indicis*, radial side back of index. *Princeps pollicis*, beginning palmar arch to sides of palmar aspect of thumb. *Radialis indicis*, palmar arch to radial side index. *Perforantes*, (3), to inosculate with 3 dorsal interosseous. *Palmares interossea*, (3 or 4), from arch to *anas.* at finger-clefts with digital branches of superficial arch.

ULNARIS: (8 brs.) little below bend of elbow—along radial side flexor carpi ulnaris to palm of hand, forming "superficial

palmar arch" with superficialis volæ. Anterior ulna'ris recurrens, just below elbow-joint—up and inwards between brachialis anticus and pronator radii teres, supplying these; *anas.* anastomotica magna, and inferior profunda. Posterior ulna'ris recurrens, just below preceding—back and inwards beneath flexor sublimis up to internal condyle humerus, supplying joint and neighboring muscles; *anas.* inferior profunda, anastomotica magna, interosseous recurrent. Interos'sea, short trunk below tuberosity radius—backwards to interosseous membrane, dividing into: INTEROS'SEA ANTE'RIOR, passing down forearm on interosseous membrane, piercing membrane at superior border pronator quadratus to descend to back of wrist, supplying *nutrient* (to radial and ulnar arteries) and *muscular* branches; gives off *median* branch, accompanied by *do* nerve. *Anas.* posterior carpal of radial and ulnar. INTEROS'SEA POSTE'RIOR, down back forearm, between deep and superficial muscular layers, to wrist, supplying these muscles; *anas.* as preceding. *Posterior interos'sea recurrens*, near its origin to interval between olecranon and external condyle, beneath supinator brevis; *anas.* superior profunda, posterior ulnar recurrent. *Muscula'res*, to muscles of ulnar side of forearm. *Carpa'lis ante'rior*, beneath flexor profundus, *anas.* anterior carpal of radial. *Posterior carpa'lis*, above pisiform bone, beneath flexor carpi ulnaris, giving small branch to *inesculate* with posterior carpal of radial, forming "*posterior carpal arch*"; continued along 5th metacarpus, forming its dorsal branch. *Commu'nicans*, from commencement palmar arch, deeply inwards, *anas.* with radial forming "*deep palmar arch.*" *Digita'les*, (4) from convexity of superficial palmar arch, supplying ulnar side 4th and adjoining sides 3d, 2d and 1st fingers.

VEINS.

Ulna'ris ante'rior, from anterior carpus and ulnar side hand, up along ulnar side forearm to elbow-joint, to form basilica. Communicates with median and posterior ulnar.

Ulna'ris poste'rior, posterior ulnar border hand and vein of little finger (*v. salvatella*)—unites with preceding just below elbow-joint.

Bas'ilica, coalescence of anterior and posterior ulnares; receives median-basilic at elbow, ascends inner side arm to venæ comites of brachial artery, or axillary vein.

Rad'a'lis, dorsum thumb, radial side index and hand—at bend elbow receives median-cephalic to become the cephalic.

Cephal'ica up between deltoid and pectoralis major to axillary veins

Me'dia: palmar surface of hand and middle of forearm (communicates with ulnar and radial), to median-cephalic and median-basilic at elbow.

Cephal'ica me'dia: obliquely outwards from bend elbow, between supinator longus and biceps; empties into cephalic as a formative branch.

Basil'ica me'dia: obliquely inwards behind biceps and pronator radii teres; empties into basilic as formative branch.

The following are the deep veins, and accompany their respective arteries as *venæ comites*, intercommunicating with each other, and the superficial veins, frequently.

Digitales, (2) empty into the superficial palmar.

Palma'res superficia'les, (2) empty into ulnar and radial.

Palma'res profun'dæ, empty into radial *venæ comites*.

Interos'ææ, (2) accompany the anterior and posterior interosseous arteries, commencing at the wrist, terminating in *venæ comites* of the ulnar.

Com'ites radia'lis, form, with the ulnar, the *comites* of brachial.

Com'ites ulna'ris, with the radial, form *comites* of brachial.

Com'ites brachia'lis, receiving veins corresponding to the branches of the brachial artery, empty into the axillary vein.

Axilla'ria, is the continuation of the basilic. Commences at lower border of the axillary space; receives veins corresponding to branches of its artery, and terminates in the subclavian at outer border 1st rib. [Valves at inferior border subscapularis, terminations of *vena subscapularis* and *vena cephalica*.]

Subcla'via, continuation of axillary, emptying into *vena innominata* at right sterno-clavicular articulation. Separated from its artery by scalenus anticus muscle and phrenic nerve. Receives external and anterior jugulars, branch from cephalic, and internal jugular. [Valves just external to entrance of external jugular, or about 1 inch from its termination.]

NERVES.

PLEX'US BRACHIA'LIS: formed by anterior roots 4 lower cervical and 1st dorsal nerves. 5th and 6th cervical unite, then are joined by 7th to form *upper trunk*. 8th cervical and 1st dorsal unite to form *lower trunk*. Both trunks accompany the subclavian artery to the axilla, lying upon its outer side. Opposite clavicle, each of the trunks gives off a fasciculus, which, uniting, form a third trunk; in the centre of the

axilla the original *upper* cord lies to the *outside* of the artery ; the original *lower* cord to the *inside* ; the cord formed from fascicular union, *posteriorly*. The plexus lies between the anterior and middle scaleni, beneath the clavicle upon 1st serration of the serratus magnus and the subscapular muscles. (Has 4 brs. above, 9 below the clavicle.) Receives communicating branches from cervical plexus, phrenic, inferior cervical, sympathetic ganglia. *Communicans*, 5th cervical to phrenic on scalenus anticus. *Muscula'res*, to longus colli, scaleni, rhomboidei and subclavius. *Posterior thorac'icus*, from 5th and 6th cervical to serratus magnus. Passes behind brachial plexus. *Supra-scapula'ris*, from "outer cord" obliquely outwards beneath trapezius, to supra-spinous fossa through supra-scapular notch, here giving 2 branches to supra-spinatus muscle and 1 to joint; in infra-spinous fossa, 2 branches to muscle, 1 to joint; all of these are given off ABOVE the clavicle. Those BELOW the clavicle are: *Exter'nus ante'rior thorac'icus*, "outer cord" inwardly across axillary vessels to pectoralis major. *Inter'nus ante'rior thorac'icus*, "inner cord" passes up between axillary artery and vein (*sometimes perforating the vein*) to pectorales major and minor. *Subscapula'res*, (3) "posterior cord" the *upper* to subscapular muscles; the *longer* to latissimus dorsi; the *lower* to teres major. *Circumflex'us*, "posterior cord", down behind axillary vessels to lower border subscapularis, dividing into *upper* branch winding round neck of humerus, supplying deltoideus and integument; *lower* branch to teres minor, deltoideus and integument over posterior surface deltoid. *Articula'ris*, given off before division, to joint. *Mus'culo-cuta'neus*, continuation of outer cord, *perforates coraco-brachialis*, obliquely outwards between biceps and brachialis anticus to these muscles, integument to elbow, and to the joint. *Anterior* branch, down radial border of forearm from elbow, to wrist, supplying integument to ball of thumb; communicates with radial. *Posterior* branch, given off middle of forearm, supplies integument to wrist, on radial side; communicates with radial and external cutaneous. *Inter'nus cuta'neus*, "inner cord", down in company with brachial artery, becoming cutaneous at middle of arm, then dividing into *anterior* branch, supplying integument of ulnar side of arm to wrist, communicating with branch from ulnar *posterior* branch down, on inner side of basilic vein, over internal condyle, on posterior ulnar side of forearm to wrist communicating at wrist with dorsal branch of ulnar; at elbow with lesser internal cutaneous. *Cuta'neus m'inor inter'nus*, from

“inner cord” to integument inner side of arm. *Medius*, (4 branches) arises by 2 roots, one from “outer” and one from “inner” cord; at first lies to outer side of the artery, crosses it at middle of arm; in forearm runs between the 2 heads of the pronator radii teres, beneath flexor sublimis till near annular ligament, when it lies between flexor sublimis and flexor carpi radialis; it passes beneath annular ligament to hand. (No branches in the arm.) *Muscula'res*, from near elbow, to all forearm muscles save flexor carpi ulnaris. *Anterior interos'seus*, follows course of the artery, to flexor profundus digitorum, flexor longus pollicis, and pronator quadratus. *Cuta'neus palmar'is*, crosses annular ligament, the outer branch supplying the thumb-region; the inner branch, the palmar. *Digitales*, (5) two go to thumb, the 3d to radial side of index; the 4th divides to supply adjacent sides of index and middle; the 5th the adjacent sides of middle and ring fingers, communicating with branches from ulnar. *Ulna'ris*, (7 brs.); continuation of “inner cord”, down ulnar side of arm and forearm (over the back of inner humeral condyle) upon flexor profundus digitorum, having ulnar artery externally, crosses annular ligament at outer side of pisiform bone, dividing into superficial and deep palmar branches. *Articula'res*, to elbow joint. *Muscula'res*, one to flexor carpi ulnaris, the other to flexor profundus digitorum. Both arise near elbow. *Cuta'neus*, arises middle forearm, has a deep and superficial branch. *Dorsa'lis cuta'neus*, arises 2 inches above wrist, passes to back of hand, supplying ulnar side of wrist, inner side of little finger, adjoining sides of little and ring fingers. *Articula'res*, to wrist. *Palmar'is superficialis*, supplies palmaris brevis, and integument inner side of hand, ulnar side of the little and adjoining sides of the little and ring fingers. *Palmar'is profun'dus*, follows course of “deep palmar arch”, supplying muscles of interosseous spaces, lumbricales, adductor and flexor brevis pollicis. *Mus'culo-spira'lis* (4 brs.; *largest br. of plexus*) continuation of “posterior cord”; winds around the humerus in spiral groove, etc., to front of external condyle, then divides into radial and interosseous. *Muscula'res*, to triceps, anconeus, supinator longus, extensor carpi radialis longior, and brachialis anticus. *Cuta'nei*, (3), internal branches supply integument of back of arm down to olecranon: external branches perforate external head of triceps, supplying integument lower anterior half of arm, the lower branch running down radial side of forearm (posteriorly) to wrist, supplying contiguous integument. *Ra-*

dia'lis, down by outer side of radial artery, just concealed by supinator longus till within 3 inches of wrist, where pierces deep fascia of outer side forearm; divides to supply radial side of ball of thumb, (communicating with external cutaneous nerve), and on back of hand forms an arch with ulnar, giving off 4 *digital* nerves; the 1st to ulnar side of thumb; the 2d to radial side of index; the 3d, adjoining sides of index and middle; the 4th, adjoining sides of middle and ring fingers. *Interos'seus poste'rior*, pierces supinator brevis, winding to back of forearm, passing down to wrist, there having ganglionic enlargement. Supplies carpus, and all muscles on back of forearm *except* anconeus, supinator longus and extensor carpi radialis longior.

B O D Y .

MUSCLES.

(1) BACK, FIRST LAYER, 2.

Trape'zius: inner 3d superior curved occipital line, ligamentum nuchæ, spinous processes of 7th cervical and all the dorsal vertebræ—posterior border clavicle, superior margin acromian process and superior border spine of scapula. [Spinal accessory, cervical plexus.]

Latis'simus dor'si: aponeurosis from spinal processes 6 lower dorsal, all lumbar and sacral vertebræ, external lip iliac crest—twisting upon itself so as to be inserted into bicipital groove of humerus. [Subscapular.]

(2) BACK, SECOND LAYER, 3.

Leva'tor an'guli scap'ulæ: transverse processes of 3 or 4 superior cervical vertebræ—posterior border scapula. [5th cervical, cervical plexus.]

Rhomboid'e'us mi'nor: ligamentum nuchæ, spinal processes 7th cervical and 1st dorsal vertebræ—down- and outwards to root scapular spine. [5th cervical.]

Rhomboid'e'us ma'jor: spinal processes superior dorsal vertebræ—tendinous arch along vertebral border scapula. [5th cervical.]

(3) BACK, THIRD LAYER, 4.

Serra'tus posti'cus supe'rior: ligamentum nuchæ, spinal processes 7th cervical and 2 or 3 superior dorsal vertebræ—superior border 2d, 3d, 4th, 5th ribs. [Posterior external brs. cervical.]

Serra'tus posti'cus infe'rior: spinal processes 11th and 12th dorsal, 1st, 2d and 3d lumbar vertebræ—up and out to inferior border 4 inferior ribs. [External branches dorsal.]

Sple'nus : ligamentum nuchæ, spinal processes 7th cervical and 6 superior dorsal vertebræ—*capitis*, into mastoid process and occiput; *colli*, transverse processes 3 or 4 superior cervical vertebræ. [External posterior branches cervical.]

(4) BACK, FOURTH LAYER, SACRAL AND LUMBAR REGION, 1.

Erec'tor spl'æ : sacro-iliac groove, lumbo-sacral tendon, iliac crest, transverse processes sacrum--sacro-lumbalis, longissimus dorsi. [External posterior branches lumbar.]

(5) BACK, FOURTH LAYER, DORSAL AND CERVICAL REGION, 10.

Sa'cro-lumba'lis : (see above)—angles inferior ribs. [Dorsal.]

Accesso'rius : angles 6 lower—angles 6 superior ribs. [Dorsal.]

Cervica'lis ascen'dens : 4 or 5 superior ribs—transverse processes 4th, 5th, 6th cervical vertebræ. [Cervical.]

Longis'simus dor'si : see erector spinæ, of which it is the larger portion; inserted (*lumbar* region) into transverse processes lumbar vertebræ; *dorsal*, tips transverse processes of all vertebræ, and 7 to 11 ribs, between their tubercles and angles. [Lumbar, dorsal.]

Transversa'lis col'li : transverse processes, 3d, 4th, 5th, 6th dorsal—transverse processes 5 inferior cervical vertebræ. [Cervical branches.]

Trache'lo-mastoide'us : transverse processes 3d, 4th, 5th, 6th dorsal, and articular processes 3 or 4 inferior cervical vertebræ—posterior margin mastoid process. [Cervical branches.]

Spina'lis dor'si : spinal processes 1st, 2d lumbar and 11th and 12th dorsal vertebræ—spinal processes of dorsal vertebræ. [Dorsal branches.]

Spina'lis cervi'cis : spinal processes 5th, 6th cervical (1st, 2d dorsal) vertebræ—spinal process axis (sometimes 3d and 4th cervical.) [Cervical branches.]

Complex'us : transverse processes 7th cervical and 3 superior dorsal vertebræ, articular processes 4th, 5th, 6th cervical—between superior and inferior curved occipital lines. [Cervical branches, sub-occipital, great occipital.]

Biven'tor cervi'cis : 2 or 4 tendons from as many superior dorsal vertebræ—superior curved occipital line, inside of complexus [Cervical branches.]

(6) BACK, FIFTH LAYER, 8.

Semispina'lis dor'si : transverse processes of vertebræ between 11th and 5th dorsal—spinal processes of 6th and 7th cervical and 4 superior dorsal vertebræ. [Dorsal branches.]

Semispina'lis col'li : transverse processes 4 superior dorsal and articular processes 4 inferior cervical vertebræ—spinal processes 2d, 3d, 4th, 5th cervical. [Cervical branches.]

Multif'idus spi'næ: fills groove on either side spinal processes back part sacrum, articular processes in lumbar and cervical region, transverse processes in dorsal region—spinal processes and laminæ of the 4 vertebræ above. [Posterior spinal branches]

Rotato'res s_i'næ: (11) upper and back part transverse processes of dorsal vertebræ—inferior border and outer surface of laminæ of vertebræ above. [Dorsal branches.]

Supra-spina'les: on spinal processes of cervical vertebræ. [Cervical branches.]

Inter-spina'les: in pairs between spinal processes of adjacent vertebræ; 6 cervical, 3 dorsal (1st to 4th, and 11th to 12th), 4 lumbar. [Spinal branches.]

Exten'sor Coccy'gis: last bone sacrum—inferior part coccyx, lying on posterior surface.

Inter-transversa'les: 7 cervical, 12 dorsal, 4 lumbar, lying between transverse processes. [Spinal branches.]

(7) ABDOMINAL REGION 6.

Obli'quus abdom'inis exter'nus: 8 digitations from inferior borders 8 lower ribs—*down* to anterior $\frac{1}{2}$ outer iliac crest, pubic spine and symphysis, linea alba. Poupart's ligament formed by its aponeurosis. [Inferior intercostal, ilio-hypogastric, ilio-inguinal nerves supply this and the 5 following muscles.]

Obl'quus inter'nus: outer $\frac{1}{2}$ Poupart's ligament, anterior $\frac{2}{3}$ middle lip iliac crest, lumbar fascia—pectineal line, linea alba, pubic crest, inferior edges cartilages of 4 inferior ribs.

Transversa'lis: outer $\frac{1}{3}$ Poupart's, anterior $\frac{2}{3}$ internal lip ilium, internal surfaces cartilages of 6 inferior ribs, aponeurosis from spinal and transverse processes lumbar vertebræ—pubic crest (forming with above "conjoined tendon"), lineæ ilio-pectinea and alba.

Rec'tus abdom'inis: pubic crest and symphysis—cartilages 5th, 6th, 7th ribs. (In sheath formed by internal oblique and transversalis aponeuroses.)

Pyram'idalis: pubes—linea alba midway to umbili'cus.

Quadra'tus lumbo'rum: posterior 4th iliac crest, ilio-lumbar ligament—transverse processes 3d, 4th, 5th lumbar vertebræ and last rib.

(8) THORACIC REGION 5.

Intercosta'les exter'ni: (11) outer lip of groove in inferior borders of ribs—*down* and *forwards* to superior border rib below. [Intercostal.]

Intercosta'les inter'ni: (11) inner lip of groove—*down* and *backwards* to rib below. [Intercostal.]

Infracosta'les: inferior surface of one rib—internal surface 1st, 2d or 3d rib below. [Intercostal.]

Triangula'ris ster'ni: side of gladi'olus, internal surface ensiform appendix, cartilage of 3 or 4 lower true ribs—cartilages of 2d, 3d, 4th, 5th ribs. [Intercostal.]

Levato'res costa'rum: (12) transverse processes dorsal vertebræ—superior border rib below, near angle. [Intercostal.]

(9) DIAPHRAGMATIC REGION I.

Diaphrag'ma: internal surfaces 6 or 7 lower ribs, ligamenta arcuata, crures from 2d, 3d, 4th lumbar vertebræ, ensiform cartilage—converge forming common central tendon. *Aortic* opening for aorta, vena azygos major, thoracic duct; *œsophageal*, œsophagus and pneumogastric nerves; *vena cava* for inferior vena cava; *right crus* transmits sympathetic and greater and lesser splanchnics; *left crus*, vena azygos minor and splanchnics. [Phrenic.]

(10) PERINÆAL REGION 8.

Sphinc'ter a'ni: tip of coccyx and fascia in front—common central perinæal tendon. [Hemorrhoidal branch 4th sacral.]

Sphinc'ter inter'nus: muscular ring ($\frac{1}{2}$ inch wide), 1 inch from anus, surrounding rectum.

Accelera'tor uri'næ: central perineal tendon and raphe—covers bulb corpus cavernosum, and spongiosum, and dorsal vessels.

Erec'tor pe'nis: internal surface tuber ischii—sides and inferior surface crus.

Transver'sus perinæ'i: internal surface ascending ischic ramus—obliquely for- and inwards to central perinæal tendon.

Leva'tor a'ni: inside of pubic ramus and body, ischic spine, fascia (angle of division into obturator and vesical)—central perinæal tendon, rectum, coccyx; forms floor of pelvic cavity.

Compres'sor ure'thræ: pubic ramus—surrounds membranous portion.

Coccyge'us: ischic spine and lesser sacro-sciatic ligament—side of coccyx and last sacral segment.

(In the female the above perinæal muscles are essentially the same; the *erector clitoridis* takes the place of erector penis, being inserted into the sides of the clitoris; *sphincter vaginæ* represents the accelerator urinæ of the male, surrounding the vagina.)

ARTERIES.

ARCH OF AORTA: (5 branches); from left^o ventricle, opposite middle of sternum, upwards for 2 inches, arching back-

wards over root of left lung (on level 2d dorsal vertebra), the "descending portion," runs down on the left side of 2d and 3d vertebræ, there becoming thoracic aorta. In front, are left pleura, lung, pneumogastric, phrenic, and cardiac nerves; behind, trachea, right pulmonary vessels and nerves, root of right lung, cardiac plexus, œsophagus, thoracic duct, left recurrent nerve. *Corona'ria dex'tra*: above free margin right semilunar valve, between pulmonary artery and right auricular appendix; runs round right border of heart to posterior interventricular groove, there dividing into 2 branches, supplying right heart; *anas.* at apex with left coronary. *Corona'ria sin'istra*: (smaller) above left semilunar valve, passes forwards between left auricular appendix and pulmonary artery to anterior interventricular groove, dividing into two branches, supplying left side of heart. *Innomina'ta*: commencement transverse portion of arch, ascends obliquely up to right sternoclavicular articulation, dividing into common carotid and subclavian. *Caro'tis commu'nis sin'istra* and *Subcla'via sin'istra*: (see pages 6 and 19.)

AOE'TA THORAC'ICA: (see arch) 5 branches. Terminates at aortic opening in diaphragm as "abdominal aorta," there lying upon front of vertebral bodies. *Pericardi'acæ*: to pericardium. *Bronchia'les*: (3 generally) to the left bronchus. *œsophage'æ*: (4 or 5) front of aorta, obliquely down to œsophagus, *anas.* with inferior thyroid, gastric and phrenic. *Mediastina'les posterior'es*: glands and areolar tissue therein. *Intercosta'les*: (10 pairs) right longer than left; pass out to do spaces, there dividing into *anterior* branches ascending to inferior border rib above, the smaller branch of it on the superior border rib below, running towards sternum, *anas.* with internal mammary, thoracic branches of axillary, superior intercostal, epigastric, phrenic, lumbar, etc. *Posterior* branch passes backwards, supplying vertebræ, cord, and muscles of back. (1st space supplied by superior intercostal of subclavian.)

AOE'TA ABDOM'INIS: (9 brs.); from aortic opening of diaphragm, in front last dorsal vertebræ, terminates on body 4th lumbar, in the "common iliacs." *Phren'icæ*: (2) obliquely outwards to supply diaphragm, inferior vena cava, œsophagus and supra-renal capsule; *anas.* freely. *Coeli'aca*: (axis $\frac{1}{2}$ inch long) horizontally forwards, dividing into *CORONA'RIA VENTRIC'ULI* (gastric), which passes round lesser curvature stomach from cardiac end to pylorus, there *inosc.* with hepatic. *HEPAT'ICA*, to the transverse fissure of liver to supply right and left lobes, giving off *pyloric* branch to stomach,

running from right to left; *gas'tro-duodena'lis* that supplies greater curve of stomach (*gas'tro-epiplo'ica dex'tra*, which *inosc.* with *gas'tro-epiplo'ica sin'istra* of splenic), pancreas and duode'num (*pancreat'ico-duodena'lis*, which *inosc.* with duodenal branch of superior mesenteric); *cyst'ica*, small branch to gall bladder, **SPLEN'ICA**, horizontally left to spleen: *pancreat'ica* (*magna* and *par'va*) small branches to pancreas; *va'sa bre'via*, 5 to 7 small branches to cardiac end of stomach; *gas'tro-epiplo'ica sin'istra*, around greater curve stomach from left to right, *anas.* *gas'tro-epiplo'ica dex'tra*. **Supra-rena'les**: obliquely up- and outwards to supra-renal capsules. **Mesenter'ica supe'rior**: $\frac{1}{4}$ inch below cœlic axis, to the intestines. **Infe'rior pancreat'ico-duodena'lis**, up to head pancreas and lower $\frac{2}{3}$ duode'num, *anas.* with *pancreat'ico-duodena'lis* of hepatic. *Va'sa intesti'na tenuis*, 12 to 15 looping branches to jejunum and ileum. *Ilio-col'ica*, down right obliquely, to ileum and cæcum. *Col'ica dex'tra*, horizontally to right to ascending colon. *Col'ica me'dia*, up to transverse colon, *inosc.* *colica dex'tra* and *colica sin'istra*. (Free anastomosis of all these vessels.) **Re'na'les**: sides aorta just below superior mesenteric horizontally outwards to each kidney. **Spermat'ica**: slender vessels supplying testicles, or ovaries. **Mes'enter'ica infe'rior**: left side aorta 2 inches above bifurcation, to sigmoid flexure of colon, and rectum. *Col'ica sin'istra*, horizontally to left to descending colon. *Sigmoide'æ*, branches passing obliquely downwards to sigmoid flexure. *Hæmorrhoida'lis supe'rior*, termination of inferior mesenteric supplying superior part of rectum, *anas.* with middle hæmorrhoidal of internal iliac, and inferior hæmorrhoidal of internal pudic. The branches of both mesenteric arteries are in free anastomosis. **Lumba'les**: 4 pairs arising from back aorta, dividing, near transverse processes into *abdominal* branches (supplying muscles, and *anas.* with epigastric, internal mammary, intercostal, ilio-lumbar and circumflex iliac branches) and *dorsal* branches (supplying back muscles, etc., with a spinal branch to meninges and cord), *anas.* intercostal. **Sa'cra me'dia**: back of aorta at its bifurcation, down median line to coccyx, there *anas.* with lateral sacral, supplying adjacent parts.

ILIACÆ COMMUNES: from bifurcation of aorta, obliquely out- and downwards to intervertebral substance between sacrum and last lumbar, there dividing into internal and external iliac; each are about 2 inches long. Give small branches to peritoneum, ureters, psoæ, etc. The left is the larger.

ILIACA INTER'NA: (see above); $1\frac{1}{2}$ inches long, dividing

at greater sacro-sciatic foramen into anterior and posterior trunks. Branches from the ANTERIOR trunk are: *Vesica'lis supe'rior*: part of foetal-hypogastric that remains pervious, to fundus of bladder, and vas deferens. *Vesica'lis me'dia*: base of bladder and vesiculæ seminales. *Vesica'lis infe'rior*: base bladder, prostate, and vesiculæ seminales. *Hæmorrh. ida'lis me'dia*: rectum, *anas.* with hæmorrhoidal branch of inferior mesenteric and internal pudic. (*Uterine*: to neck, and ascends to fundus, giving branch to ovary and tube, etc. *Vaginal*: corresponds to inferior vesicle, supplying vagina, urethra, etc.) *Obturato'ria*: forwards to superior border obturator foramen, escaping there, dividing into an *internal* (curving round inner border foramen, supplying adjacent muscles, etc., *anas.* with external branch and internal circumflex) and *external* branch (round outer margin foramen supplying adjacent muscles). The branches inside the pelvis are *iliac*, *vesical* and *pubic*; the latter *anas.* with epigastric. Sometimes rises from epigastric, then liable to be wounded in operation for hernia. *Pudi'ca inter'na*: terminal branch; supplies external generative organs; out of pelvis beneath pyriformis (great sacro-sciatic foramen), crosses ischic spine, re-enters pelvis through lesser sacro-sciatic foramen, ascends ischic ramus up to pubes. *Hæmorrhoidales infe'iores*, 2 or 3 to rectum, etc. *Superficialis perinæ'i*, to scrotum and perinæum. *Transver'sa perinæ'i*. *A. corp'ris bulbo'si*, to bulb and Cowper's gland. *A. corp'ris caverno'si*, terminal branch running forwards in this structure. *Dorsa'lis pe'nis*, forwards to glans. *Sciat'ica*: terminal branch (see lower extremity.) Branches from the POSTERIOR trunk are: *Glute'a supe'rior*: (see lower extremity.) *Ilio-lumba'lis*: divides at upper part iliac fossa into *lumbar* (to psoas and quadratus muscles, branches to spinal canal) and *iliac* branch (to iliacus internus, *anas.* with gluteal, epigastric, etc.) *Sacra'les latera'les*: (2) *superior*, enters 1st or 2d sacral foramen, *anas.* with fellows and middle sacral; *inferior*, descends on sacrum, *anas.* over coccyx with middle sacral and opposite fellow.

ILIACA EXTERNA: from bifurcation common iliac to femoral arch. Line drawn from left of umbili'cus to a point on Poupart's ligament midway between pubes and anterior superior spinal process of ilium, indicates its course. *Epigas'trica*: few lines above Poupart's, up- and inwards to umbili'cus, there *anas.* with internal mammary and inferior intercostal. *Spermat'ica externa'lis*, to cremaster. *Pubic* branch. *Musculaires*. *Circumflexa il'i*: origin opposite above from outer side

artery, runs obliquely up- and outwards on iliac crest, supplying adjacent muscles, and *anas.* with gluteal, epigastrie, and lumbar arteries.

 VEINS.

Innomina'tæ: *right* is short ($1\frac{1}{2}$ inches long), running from sterno-clavicular articulation to join left innominate at inferior border cartilage of 1st rib, forming vena cava superior. Is external to artery, and receives right lymphatic duct, right vertebral, right internal mammary, right inferior thyroid and right superior intercostal veins. *Left* is 3 inches long, runs in front of the three large arterial branches of aorta; receives corresponding venous branches as right. Neither have valves.

Mamma'ria inter'na: 2 to each artery, uniting in single trunk, emptying into innominate.

Thyroide'a inf'e'rior: (sometimes 3 or 4) from thyroid venous plexus, emptying into right and left innominate.

Intercosta'les superio'res: from 2 or 3 superior intercostal spaces, emptying into innominatæ. Left bronchial empties into left intercostal.

Ve'na ca'va supe'rior: $2\frac{1}{2}$ to 3 inches long, formed of vena innominatæ, emptying into right auricle; receives vena azygos major, and pericardial veins. No valves.

Az'ygos ma'jor: opposite 1st or 2d lumbar vertebra, from right lumbar veins, up through aortic diaphragmatic opening to right side 3d dorsal vertebra, arching over root right lung, emptying into vena cava. Receives the 10 lower right intercostal veins, vena azygos minor, several œsophageal, mediastinal, vertebral, and right bronchial veins. Imperfect valves, though its branches have complete ones.

Az'ygos mi'nor inf'e'rior: lumbar region of left side from lumbar veins, or branches of renal, through left crus of diaphragm to 6th or 7th dorsal vertebra, there crossing to terminate in azygos major. Receives 4 or 5 lower intercostal, and some œsophageal and mediastinal veins.

Az'ygos mi'nor supe'rior: from branches intercostal and azygos minor inferior veins; empties into one of the other azygos veins.

Bronchia'les: from lungs; the right terminating in azygos major; the left in the left superior intercostal.

Spina'les: *dorsi-spina'lis*, whole length of back of spine, forming network, terminating in the vertebral (of neck), the intercostal (of thorax), lumbar and sacral veins. *Longitudi'na'les spina'les anterio'res*, whole length vertebral foramen;

anterior surface terminating as dorsi-spinal, etc. *Longitudinales spinales posteriores*, whole length vertebral foramen, posterior surface, terminating in dorsi-spinal. *V. basis vertebrarum*, from bodies of vertebræ, terminating in anterior longitudinal. *Medullis-spinales*, cover cord, between pia and arachnoid, from sacrum to occiput; *anas.* freely with those contiguous. No valves in any of the spinal veins.

Iliaca externa, interna and *communis*, see lower extremity. ✓

Ve'na ca'va infe'rior: junction of the 2 common iliacs, up on right side of aorta, terminating in lower and back part of right auricle. It receives: the *lumbar* branches (3 or 4 in No.) from muscles and integument of loins; the *right spermatic* (the left emptying into left renal), both having valves; *ovarian*, have same termination; the *renal*, the left being the longer; the right *supra-renal* (the left terminating in the left renal, or phrenic); the right *phrenics* (the left superior emptying into superior intercostal or internal mammary, and the inferior into the left renal); the *hepatic*, 3 branches (no valves), these commencing as the *intra-lobular* veins (in the centre of the lobule), forming the *sub-lobular*, and these last finally the larger hepatic trunks.

Ve'na por'ta: 4 inches long; no valves in it or its branches; formed by *mesenterica inferior*, (draining rectum, sigmoid flexure, and descending colon; its branches *inosc.* with internal iliac); *mesenterica superior* (draining small intestines, cæcum, ascending and transverse colon); *splenica* (5 or 6 branches from spleen; receiving branches of *va'sa bre'via*, left *gas'tro-epiplo'ica*, *pancreat'ica* and *pancreat'ico-duodena'lis* veins); *gas'trica*, from lesser stomachic curvature.

Cardiacæ: *ve'na cor'dis mag'na*, from apex, up anterior interventricular groove to base ventricles, curving to left side to back part of heart, emptying into coronary sinus, guarded by 2 valves; receives posterior cardiac and left cardiac veins. *Ve'na cor'dis me'dia*, (posterior cardiac) from apex up posterior interventricular groove, terminating in coronary sinus, guarded by valve. *Ve'na par'va*, (anterior veins), 3 or 4 small branches from anterior surface of right ventricle, emptying into lower part right auricle. *Ve'næ thebe'sii* drains muscular substance, opening into right auricle.


Pulmonales: 4 in No.; commence in capillary network upon bronchial cells, uniting to form a trunk for each lobe, the one of the middle lobe of the right lung unites with the one from the superior lobe, hence 2 veins from each side. No valves; carry *arterial* blood;

NERVES.

SPINAL NERVES: 31 pairs, viz.: 8 cervical, 12 dorsal, 5 lumbar, 5 sacral, 1 coccygeal. Each have an anterior and posterior root, hence have moto-sensor functions.

Cervica'les; (see pages 15 and 16). **Dorsa'les:** 1st from between 1st and 2d dorsal vertebræ, the last from between 12th dorsal and 1st lumbar. The **POSTERIOR** branches have *external* and *internal* branches. The *cutaneous* branches are the 6 upper from the internal branches, the 6 lower from the external branches. These nerves supply the structures of the back. **ANTERIOR** branches supply walls of the chest and abdomen, each having branches from the sympathetic. *Superiores Intercostales*, pass forwards with the arteries, giving off numerous branches, the chief being the lateral cutaneous, which have anterior and posterior branches. The 1st intercostal has no lateral branches; the 2d has a large one (the *intercosto-humeralis*), which supplies the integument of upper inner half of arm. *Intercostales inferiores*, have nearly the same course as the superior, supplying the anterior cutaneous nerves to abdomen, and having lateral branches.

Lumba'les: have largest roots of all; have *anterior* and *posterior* branches; the latter having external and internal branches; the *anterior* branches uniting to form the lumbar plexus. Supply muscles and integument in their region. The *anterior* branches communicate with sympathetic. **Sacra'les** and **Coccygea'les:** (see nerves of lower extremity.)



LOWER EXTREMITY.

MUSCLES.

(1) ILIAC REGION 3.

Psoas magnus; last dorsal and all lumbar vertebræ (transverse processes)—lesser trochanter, in union with iliacus. [Anterior branches lumbar.]

Psoas parvus; sides of bodies last dorsal and 1st lumbar vertebræ—ilio-pectineal eminence. [Anterior branches lumbar.]

Iliacus; iliac fossa, crest and anterior spinous processes of ilium, base sacrum—outer side tendon psoas magnus. [Anterior crural.]

(2) ANTERIOR FEMORAL REGION 7.

Tensor vaginæ femoris; outer crest ilium, anterior superior spinous process—fascia lata, $\frac{1}{4}$ way (laterally) down the thigh. [Superior gluteal.]

Sarto'rius; (longest muscle of body) anterior superior spinal process ilium, part of notch below—upper, inner side of tibial shaft, having crossed the anterior surface of the thigh obliquely. [Anterior crural.]

Quad'riceps exten'sor: (*vas'ti inter'nus* and *exter'nus*, *rec'tus* and *crure'us*); the *rec'tus* from anterior inferior spinal process ilium and groove above acetabulum,—the *vas'tus exter'nus* from anterior border great trochanter, *linea aspera*,—the *vas'tus inter'nus* and *crure'us* from inner lip of *linea aspera* and nearly all internal, anterior and external surface of femur—shaft—into patella. [Anterior crural.]

Subcrure'us: lower anterior surface of femur—synovial pouch behind patella. [Anterior crural.]

(3) INTERNAL FEMORAL REGION 5.

Grac'il's: inner margin rami of pubes and ischium—inner side upper part tibia above insertion semitendinosus and beneath sartorius. [Obturator.]

Pectine'us: Gimbernat's ligament, *linea ilio-pectinea*—rough line between trochanter minor and *linea aspera*. [Obturator and anterior crural.]

Adduc'tor lon'gus: front of pubes—middle 3d of *linea aspera*. [Obturator.]

Adduc'tor bre'vis: descending ramus of pubes between gracilis and obturator—upper part *linea aspera*, behind pectineus. [Obturator.]

Adduc'tor mag'nus: ramus of pubes and ischium, and tuber ischii—from great trochanter to inner condyle. [Obturator and great sciatic.]

(4) GLUTEAL REGION 9.

Glute'us max'imus: superior curved line of ilium down to coccyx and sacro-sciatic ligaments—rough line between great trochanter and *linea aspera*. [Inferior gluteal branch sacral plexus.]

Glute'us me'dius: between superior and middle iliac curved lines, crest, fascia—great trochanter. [Superior gluteal.]

Glute'us min'imus: between middle and inferior curved lines, margin great sacro-sciatic notch—impression anterior border trochanter major. [Superior gluteal.]

Pyrifor'mis: front of sacrum, anterior margin great sacro-sciatic foramen and anterior surface great sacro-sciatic ligament, etc.—through great sacro-sciatic foramen to superior border great trochanter. [Sacral plexus.]

Obtura'tor inter'nus: inner margin obturator foramen, pubic and ischic rami, and obturator membrane—through lesser

sacro-sciatic foramen to superior border great trochanter in front of pyriformis. [Sacral plexus.]

Gemellus superior: outer surface of spine of ischium—horizontally outwards to superior border great trochanter, in company with obturator internus. [Sacral plexus.]

Gemellus inferior: superior outer border tuber ischii—superior border great trochanter with obturator internus. [Sacral plexus.]

Obturator externus: inner side obturator foramen, pubic and ischic rami, internal $\frac{2}{3}$ of external surface obturator membrane—out- and backwards to digital fossa of femur. [Obturator]

Quadratus femoris: outer border tuber ischii—horizontally outwards to linea quadrati of posterior surface of great trochanter. [Sacral plexus.]

(5) POSTERIOR FEMORAL REGION 3.

Biceps: long head from tuber ischii, short head from linea aspera—outer side head fibula, covering external lateral ligament. Forms outer “ham-string.” [Great sciatic.]

Semi-tendinosus: tuber ischii in company with biceps, and the aponeurosis—tendon (inner side popliteal space) curves round internal tibial tuberosity to inner surface of shaft (external and beneath sartorius.) [Great sciatic.]

Semi-membranosus: tuber ischii, above and external to biceps and semi-tendinosus—back of tibial tuberosity in 3 digitations, beneath internal lateral ligament. The two preceding, with this, and gracilis and sartorius, form inner “hamstring.” [Great sciatic.]

(6) ANTERIOR TIBIO-FIBULAR REGION 4.

Tibialis anticus: outer tibial tuberosity and superior $\frac{3}{4}$ shaft, external surface—inner under surface internal cuneiform and base 1st metatarsus. [Anterior tibial.]

Extensor proprius pollicis: middle anterior surface fibula and interosseous membrane—base last phalanx great toe. [Anterior tibial.]

Extensor longus digitorum: external tuberosity tibia, upper $\frac{3}{4}$ anterior surface shaft of fibula, interosseous membrane—3 tendons distributed to 4 lesser toes. (Anterior tibial.)

Pronus tertius: part of above, lower outer fourth fibula—base 5th metatarsus. [Anterior tibial.]

(7) POSTERIOR TIBIO-FIBULAR REGION, SUPERFICIAL LAYER, 3.

Gastrocnemius: 2 heads, one from each femur condyle—unites with soleus to form tendo Achillis, inserted into posterior surface os calcis. [Internal popliteal.]

Sole'us: oblique line tibia, back of head and superior portion fibular shaft—os calcis. [Internal popliteal.]

Planta'ris: outer surface external femur condyle and posterior ligament knee-joint—os calcis, posterior surface. Noted for long, slim tendon. [Internal popliteal.]

(8) POSTERIOR TIBIO-FIBULAR REGION, DEEP LAYER, 4.

Poplite'us: (forms floor popliteal space) depression below tuberosity of external femur condyle—inner $\frac{2}{3}$ triangular space above oblique line on posterior surface tibia. [Internal popliteal.]

Flex'or lon'gus polli'cis: lower internal $\frac{2}{3}$ fibular shaft, interosseous membrane, muscular septum and fascia—through groove in tibia, astragalus, calcis to base last phalanx big toe. [Posterior tibial.]

Flex'or lon'gus digito'rum: posterior surface tibia below oblique line, intermuscular septum—behind inner malleolus, calcis arch, joined by tendon flexor accessorius, divides into 4 tendons which pass through slits in the tendons of flexor brevis digitorum to be inserted into bases of last phalanges of the 4 outer toes. [Posterior tibial.]

Tibia'lis Posti'cus: interosseous membrane, superior $\frac{1}{3}$ posterior surface tibial shaft, superior $\frac{2}{3}$ fibula, inner surface—behind inner malleolus, beneath calcaneo-scapoid articulation to tuberosity scaphoid and internal cuneiform. [Posterior tibial.]

(9) FIBULAR REGION 2.

Perone'us lon'gus: head, and upper, outer $\frac{2}{3}$ fibular shaft, muscular fascia and septa—behind external malleolus, through cuboid groove to outer side base 1st metatarsus. [Musculo-cutaneous.]

Perone'us bre'vis: middle $\frac{1}{3}$ outer surface fibular shaft, muscular septa—behind external malleolus to dorsal surface base 5th metatarsus. [Musculo-cutaneous.]

(10) FOOT, DORSAL REGION, 1.

Exten'sor bre'vis digito'rum: outer side os calcis, astragalocalcanean ligament, anterior annular ligament—4 tendons, the 1st into 1st phalanx of great toe, the rest into outer sides of tendons of long extensor to 2d, 3d and 4th toes. [Anterior tibial.]

(11) FOOT, PLANTAR REGION, 1ST LAYER, 3.

Abduc'tor polli'cis: inner tuberosity os calcis, internal annular ligament, plantar fascia—inner side base 1st phalanx great toe. [Internal plantar.]

Flex'or bre'vis digito'rum: internal tuberosity os calcis, plantar

fascia, muscular septa—4 tendons, sides 2d phalanges of outer toes. [Internal plantar.]

Abduc'tor min'im'i dig'iti: outer tuberosity os calcis, plantar fascia, muscular septum—outer side base 1st phalanx little toe, joins tendon of short flexor. [External plantar.]

(12) FOOT, PLANTAR REGION, 2D LAYER, 2.

Flex'or acceso'rius: *inner* head from inner surface os calcis and calcaneo-scaphoid ligament; *outer* head, inferior surface os calcis and plantar ligament—tendon flexor longus digitorum. [External plantar.]

Lumbrica les: (4); tendon of long flexor—inner sides bases of 2d phalanges of 4 outer toes. [Internal plantar to 1st and 2d; external plantar to 3d and 4th.]

(13) FOOT, PLANTAR REGION, 3D LAYER, 4.

Flex'or bre'vis pol'licis: internal border of the cuboid and contiguous surface of external cuneiform, tendon of tibialis posticus—outer and inner sides base 1st phalanx big toe [Internal plantar.]

Adduc'tor pol'licis: tarsal extremity of 2d, 3d and 4th metatarsi and sheath of peroneus longus—outer side base 1st phalanx big toe. [External plantar.]

Flex'or bre'vis min'im'i dig'iti: base of 5th metatarsus and sheath peroneus longus—outer side base 1st phalanx little toe. [External plantar.]

Trans'er'sus pe'dis: under surface head 5th metatarsus, transverse ligament of metatarsus—outer side 1st phalanx of big toe. [External plantar.]

(14) FOOT, PLANTAR AND DORSAL INTEROSSEOUS REGION, 7.

Interos'sei d'orsa'les: (4); bipenniform, from adjacent sides of metatarsi—bases of 1st phalanges, outer (except the 1st) side of the 4 outer toes. **Planta'res:** (3); arise from the shafts of the 3d, 4th and 5th metatarsi, inner side—inner sides of the bases of the 1st phalanges of the same toes, and common extensor tendon. [External plantar.]

ARTERIES.

SCIAT'ICA: (5 branches): larger terminus of anterior trunk of internal iliac; out through lower part of the great sacro-sciatic foramen, resting on pyriformis, descending between tuber ischii and great trochanter, to supply muscles of the thigh. **Coccygea'lis:** inwards, *piercing* great sacro-sciatic ligament, supplying glutæus maximus and integument. **Glutæ'o inferio'res:** 3 or 4 supplying glutæus maximus. **Co'mes ner'vi ischiad'ici:** accompanying great sciatic nerve, and finally

pierces it and is lost in its substance. *Muscula'ros*: to back part of hip, *anas.* with gluteal, superficial perforating, external and internal circumflex. *Articula'ros*: to hip-joint capsule.

GLEUTÆ'A SUP'E'RIOR: largest branch of internal iliac; out above pyriformis, dividing into deep and superficial branches; supplies iliacus, obturator internus, pyriform. *Superficial* branch, beneath glutæus maximus, supplying it; *anas.* with posterior branch sacral. *Deep* branch, between glutæus medius and glutæus minimus, the superior division *anas.* at anterior superior spinous process of ilium with circumflex iliac and external circumflex; the inferior division goes to great trochanter, *anas.* with external circumflex. Branches supply all muscles in this region, also joint.

FEMORA'LIS: (7 branches); from Poupart's ligament to opening in adductor magnus. A line drawn from the middle of said ligament to internal femuric condyle lies over its course. Vein lies on inside; anterior crural nerve on the outside of artery. *Superficia'lis epigas'trica*: $\frac{1}{2}$ inch below Poupart's ligament through saphenous opening upwards to umbili'cus in the fascia covering the external oblique abdominis; *anas.* deep epigastric and internal mammary. *Superficia'lis circumflex'a ili'aca*: arises close to above, outwards to iliac crest, supplying glands fascia and integument, *anas.* circumflex iliac, gluteal, external circumflex. *Superficia'lis externa pud'ca*: inner side, $\frac{1}{2}$ inch below Poupart's ligament, pierces fascia lata, crosses spermatic cord, supplies integument of lower part of abdomen, penis, scrotum, (or labia); *anas.* internal pudic branches. *Profun'da externa pud'ca*: passes inwards on pectineus, piercing fascia at pubes, supplies integument of perinæum, scrotum, (or labia); *anas.* superficial perinæal. *Profun'da fem'oris*: outer and back part, 1 to 2 inches below Poupart's ligament, passes back of artery and the femoral vein to inner side femur, terminating in adductor magnus, lower 3d, *anas.* with popliteal and inferior perforating. *Circumflex'a exter'na*, having ascending, descending and transverse branches, supplying muscles in that region, and *anas.* with gluteal, circumflex iliac, superior articular of popliteal, near great trochanter with sciatic, superior perforating and internal circumflex. *Circumflex'a inter'na*, inwards to joint, supplying contiguous mnsclcs, and head of femur; *anas.* with obturator, sciatic, external circumflex and superior perforating. *Perforan'tes*, the "superior," supplying adductors magnus and brevis, biceps, glutæus maximus and *anas.* with sciatic, internal circumflex and middle perforating; "middle" one supplies flexors of thigh and

nutrient artery, *anas.* with its fellows; the "inferior" supplies the thigh flexors, *anas.* with its fellows and terminal branch of profunda. *Muscula/res*: 2 to 7 in No., supplying sartorius and vastus internus. *Anastomotica magna*: arises just before the femoral pierces the adductor magnus, dividing into *superficial* branch, accompanying long saphenous nerve, to supply integument; *deep* branch descends to inner side of knee, where it *anas.* with superior internal articular and recurrent of anterior tibial, and supplies knee-joint and contiguous parts.

POPLITEA: (7 branches); from termination of femoral down to lower border of popliteus muscle, dividing into anterior and posterior tibial. Nerve and vein superficial to artery. *Muscula/res*: *superior* (2 or 3), supply vastus externus and thigh flexors; *anas.* inferior perforating, terminal branches profunda. *Inferior* (2), supply gastrocnemius heads and plantaris. Arise opposite knee-joint. *Cuta/nei*: supply integument of calf of leg. *Articula/res superio/res*: *internal*, running inwards over femur condyles, *anas.* with *anastomotica magna*, inferior internal articular and superior external articular, supplying vastus internus and knee-joint. *External*, running circularly outwards above femur condyles, supplying vastus externus, knee-joint, etc.; *anas.* with external circumflex, and with *anastomotica magna* forming an arch. *Azygos articula'ris*: opposite bend of joint, piercing posterior ligament, supplies ligaments, synovial membranes and joint. *Articula/res inferio/res*: wind round tibial head; the *internal*, beneath internal lateral ligament, etc., to front and inner side of joint, supplying tibial head and joint. The *external*, beneath external lateral ligament, etc., to front of joint, *anas.* with the one of opposite side, superior articular and anterior tibial recurrent.

TIBIALIS ANTERIOR: (3 branches); forward through interosseous membrane and 2 heads of tibialis posticus, lying upon anterior surface of interosseous membrane down to front of ankle, there becoming dorsalis pedis. A line drawn from inner fibular head to midway between the 2 malleoli indicates its course. Has *venæ comites*; the anterior tibial nerve lies a little superficial and to its outer side. *Recur'rons*: arises just as artery passes through interosseous membrane, running up in tibialis anticus muscle to front of joint, *anas.* with the articulares. *Muscula/res*: numerous, supplying integument and muscles throughout the course; *anas.* with branches from posterior tibial and peroneal. *Malleola/res*: *internal* arises a

inches above articulation, inwards, beneath tendons ramifying upon inner malleolus, *anas.* with branches from posterior tibia and internal plantar. *External*, outwards beneath tendons, supplying outer malleolus, *anas.* with anterior peroneal, and tarsea branch of dorsalis pedis.

DORSA'LIS PE'DIS: (4 branches); from bend of ankle to 1st interosseous space, there dividing into communicating and dorsalis hallucis. Venæ comites; anterior tibial nerve lies on outer side. *Tar'sea:* arises over scaphoid, passing outwards beneath extensor brevis digitorum, supplying that muscle and tarsal articulations; *anas.* metatarsal, external malleolar, peroneal, and external plantar. *Metatar'sea:* outwards over metatarsal heads, giving off 3 *interos'seæ* branches which pass forwards to clefts of the 3 outer toes, there dividing to supply adjacent sides of the toes, and outer side of little toe. *Anas.* with tarsea and external plantar; the 3 interosseous, each, receive a posterior perforating branch from plantar arch near their origin, and each a branch from anterior perforating of digital near the toe-clefts. *Dorsa'lis hallu'cis:* forwards along outer border 1st metatarsus to 1st toe-cleft, there dividing to supply inner side of big toe, and the adjacent sides of big and 2d toes. *Communicans:* dips down into sole, *anas.* with external plantar to form plantar arch, there dividing to supply toes same as dorsalis hallucis.

TIBIA'LIS POSTE'RIOR: (5 brs.); from lower border popliteus, parallel inner border tendo Achillis, to fossa between inner ankle and heel, there dividing into the plantar arteries. Has venæ comites; nerve to the outside for the lower $\frac{3}{4}$ of its course. *Peronæ'a:* from 1 inch below popliteus, obliquely outwards to fibula, descending along inner border of it to outer ankle, supplying contiguous structures, *anas.* with external malleolar, tarsal, and external plantar. *Ante'rior peronæ'a,* given off 2 inches above ankle, piercing interosseous membrane, passes down to front of outer ankle and tarsus, supplying adjacent structures, *anas.* with tarsal and external malleolar. *Nutri'tia,* to fibula. *Muscula'res,* to fibular muscles. *Nutri'ta:* near origin of posterior tibia, being largest of its kind in the body; enters tibia just below oblique line. *Muscula'res:* to soleus and deep muscles. *Communicans:* transversely across tibia 2 inches above its inferior extremity to *anas.* with peroneal. *Calca'næe interna'les:* several branches arising just before division of posterior tibial, supplying fat and integument about heel, and muscles of inner side of foot; *anas.* with peroneal, internal malleolar.

PLANTA'RIS INTER'NA: forwards along inner side of foot to big toe, *anas.* with digital branches, supplies abductor pollicis, flexor brevis digitorum, etc.

PLANTA'RIS EXTER'NA: (2 brs.); out- and forwards to base 5th metatarsus, then turning obliquely inwards to 1st interosseous space, *inosc.* with communicating branch from dorsalis pedis, forming *plantar arch*. **Perforan'tes posterio'res:** (3); ascend through back part of the 3 outer interosseous spaces; *anas.* with interosseous branches of metatarsal. **Digita'es:** (4); arise from arch and supply both sides of the 3 outer toes and outer side of the 2d toe, bifurcating at the respective toe-clefts to do this. At each bifurcation a branch (the *anterior perforating*) is sent upwards through the interosseous space; *anas.* with interosseous branches of the metatarsal.

VEINS.

Saphe'na inter'na, or *long saphenous:* from plexus at dorsum and inner side of foot, ascends, in front of inner ankle, behind inner margin of tibia, bends behind inner femuric condyle, empties into femoral through saphenous opening, $1\frac{1}{2}$ inches below Poupart's ligament, where it receives *superficialis circumflexa iliaca*, *superficialis epigas'trica*, and *superficialis exter'na pudica*. Communicates with internal plantar, tibial, etc. 2—6 valves.

Saphe'na exter'na: plexus at dorsum and outer side of foot, up behind outer ankle to median line of leg, accompanied by external saphenous nerve; empties into popliteal vein, between heads of gastrocnemius. 2 valves, one near termination. *Communicates* with deep veins of foot.

Tibia'les posterio'res: formed from *external* and *internal plantar* joining with the *peroneal*. Course same as artery.

Tibia'les anterio'res: continuation of *ve'næ dorsales pe'dis*, pierce interosseous membrane at upper part of leg, and form, by junction with the *posterior tibial* veins, the popliteal.

Poplita'a: (see tibial anterior) up to tendinous aperture of adductor magnus, there becoming the femoral; receives *sural*, *articular*, and *external saphenous* veins. 4 valves. Crosses artery from within outwards.

Femora'lis: (see above); up to Poupart's ligament, there becoming external iliac. Lies (below) to outside, but crosses beneath the artery to its inside. Receives *muscular* branches, and *profunda femoris*, and *internal saphenous* at $1\frac{1}{2}$ inches below Poupart's ligament. 4 or 5 valves.

Ili'aca exter'na: (see above); to sacro-iliac symphysis, there

uniting with internal iliac to form common iliac. On right side, lies to inside of artery at first, but gradually passes behind it. On left side, altogether on inside of artery. Receives *epigastric* and *circumflex iliac*. No valves.

Iliacocolic: formed by venæ comites of *all* the branches of the iliac artery, but the umbilical; lies first to inside, but finally gets behind the artery. No valves, though the plexûs that help form it are abundantly supplied. 1. *Hæmorrhoidal* plexus; 2. *vesico-prostatic* plex.; 3. *vaginal* plex.; 4. *uterine* plex.; 5. *dorsalis penis* plex.; these all intercommunicate very freely.

Iliaca communis: (see *iliaca externa*); terminates at intervertebral substance between 4th and 5th lumbar vertebræ, there, with its fellow of opposite side, forms vena cava inferior. On the right it is the shorter, and nearly vertical. Receives *ilio-lumbar*. and sometimes *lateral sacral* veins. *Middle sacral* empties into left common iliac. No valves.

NERVES.

LUMBAR PLEXUS: formed by anterior roots of the 4 upper lumbar nerves communicating with each other. It furnishes different nervous branches to supply the inferior extremities. **Ilo-hypogastrica:** 1st lumbar, outwards to iliac crest, piercing there the transversalis, the *iliac* branch being distributed to gluteal integument; the *hypogastric* supplies the integument in umbilical region. **Ilo-inguinalis:** 1st lumbar; escapes at external ring, supplying inner thigh, scrotum (labia in female) and inguinal region. **Genito-cruialis:** 2d lumbar and branch from 1st, pierces psoas, and near Poupart's ligament divides; the *genital* branch to genitals, the *cruial* to integument on anterior upper aspect of thigh; *communicates* with middle cutaneous. **Cuta'neu: exter'nu:** 2d lumbar; perforates psoas, and at Poupart's ligament divides; the *anterior* branch supplying the anterior and external part of thigh to knee: the *posterior*, supplying posterior surface of thigh to its middle. **Obtura'tor:** 3d and 4th lumbar, and at upper part of obturator foramen enters thigh, dividing into: *anterior* branch supplying adductor longus and brevis, pectineus and femoral artery, giving articular branch to hip-joint; *posterior* branch pierces obturator externus, passes to front of adductor magnus, dividing into muscular branches; *articular* branch is given off for knee-joint. **Obtura'tor accesso'rius:** either from obturator, or filaments from 3d and 4th lumbar; supplies pectineus, hip-joint, and a cutaneous branch to leg. Sometimes wanting.

ANTE'RIOR CRURA'LIS: 3d and 4th lumbar, through psoas beneath Poupart's ligament to thigh, external to artery in pelvis, supplies iliacus, and femoral artery; without, all the muscles on front of the thigh but the tensor vaginae femoris. **Cuta'neus me'di'us:** through fascia lata below Poupart's ligament, dividing into 2 branches, supplying sartorius and integument in front as low as knee. **Cut.'neus int.'nus,** obliquely across upper part femoral sheath, the *anterior* branch perforating fascia at lower 3d of thigh, supplies integument of inside of thigh to knee-joint; the *inner* branch descends along posterior border sartorius to knee, piercing fascia, giving off numerous branches, descending still farther, supplying integument of inner side of leg. **Sap'he'nus inter'us,** downwards beneath sartorius to knee, inner side, then along inner side of leg in company with internal saphenous vein, dividing into 2 branches, one terminating at inner ankle, the other distributed to integument of dorsum of foot. Supplies muscles and integument in its course, giving off branches *communicating* with internal cutaneous and obturator nerves; another to patellar integument and forms a "plexus patellæ" with other branches. **Mu'cula'res,** all muscles of front of leg but tensor vaginae femoris. **Articula'res,** 2 to knee-joint ligaments.

SACRA'LES: 5; the 4 upper through anterior sacral canals, the 5th through the sacro-coccygeal foramen; the posterior are smaller and through posterior sacral canals, except the 5th, which is through posterior sacro-coccygeal foramen. Have *long roots*. *Posterior internal* branches supply multifidus spinæ. *Posterior external* branches supply integument over sacrum, coccyx and posterior gluteal region, forming many anastomosing loops. *Anterior,* the 4 upper supplying rectum, bladder, (vagina) and pelvic viscera (*communicating* with sympathetic), with their muscular branches supplying levator ani, coccygeus, sphincter ani, and integument between anus and coccyx. The 5th pierces coccygeus muscle, supplies integument over coccyx, *communicating* with coccygeal.

COCYGEA'LIS: posterior branch receives branch of *com.* from posterior sacral and is lost in fibrous cover of coccyx. Anterior branch pierces sacro-sciatic linament, supplying integument about coccyx. *Anas.* 5th sacral.

SACRAL PLEX'US: is formed by lumbo-sacral, the anterior branches of 3 upper (and part of the 4th) sacral nerves. Is triangular in form, the base corresponding to the exits of nerves, and rests on pyriformis, anterior surface, covered by

fascia. *Muscula' res*: supply pyriformis, obturator internus, gemelli, and quadratus femoris. *Glutæus supe'rior*: back part lumbo-sacral, passes through great sacro-sciatic foramen, the *superior* branch supplying glutæus minimus and medius, the *inferior* branch supplying glutæus minimus and medius, and lower portion tensor vaginæ femoris. *Pudi'cus*: plexus, lower part; out great sciatic foramen, in through the lesser sacro-sciatic foramen, terminating in perineal and dorsal nerves of penis. *Infe'rior hæmorrhoida'lis*, near origin pudic, supplies external sphincter and adjacent integument, *communicates* with inferior pudental and superficial perineal. *Perinæ'us*, terminal branch, accompanies perineal artery; the *anterior cutaneous* branches supply scrotum and under part of penis, (labia), and levator ani; the *posterior* branches supply sphincter ani and integument in front of anus, and back part scrotum. The *muscular* branches supply transversus perinæi, accelerator urinæ, erector penis, compressor urethræ, and bulb. *Dorsa'lis pe'nis*, along ramus ischii, with pudic artery, follows it and its branches to the glans penis, which it supplies. *Anas.* with sympathetic, supplies integument of prepuce and of penis, and corpus cavernosum. (In female, to the analogous parts.)

SCIATICUS PARVUS: supplies integument of perinæum, back part of thigh and leg, and glutæus maximus. Two branches from sacral plexus unite to form it; follows course of sciatic artery in distribution, piercing fascia in popliteal region, accompanies external saphenous vein to middle of leg. *Inferio' res glutæ'i*, to glutæus maximus, several large branches. *Inter'nal cuta'nei*, to skin of upper and inner side of thigh, posterior aspect; scrotum by inferior pudental that curves around tuber ischii. *Ascenden'tes cuta'nei*, run upwards and supply integument of gluteal region, and muscles. Branches to integument of thigh, popliteal region and upper part of leg.

SCIATICUS MAGNUS: $\frac{3}{4}$ inch wide, and continuation of lower part sacral plexus, passing out of great sacro-sciatic foramen below pyriformis, down between great trochanter and tuber ischii to lower 3d of thigh, there dividing into internal and external poplitæus. *Articula' res*, to hip-joint and capsule. *Muscula' res*, to flexors of the leg, adductor magnus, integument of the back part of thigh also supplied by this nerve.

POPLITE'US INTERNUS: (see above); largest terminal branch; down through middle of popliteal space, beneath

soleac arch becoming posterior tibial. *Articula' res*, (3); knee-joint, accompanying superior internal articular, inferior internal articular, and azygos arteries. *Muscula' res*, (4 or 5) to gastrocnemius, plantaris, soleus and popliteus. *Saphe' nus exter' nus*, down between gastrocnemius heads, to middle of leg, there piercing fascia and *anas*. with communicans peronæi, then down along outer margin of tendo Achillis in company with vein, supplying integument of outer side of foot and little toe, *communicates* with musculo-cutaneous.

TIBIA' LIS POSTE' RIOR: from lower border poplitæus passes down leg with posterior tibial artery, between heel and internal ankle, there dividing into external and internal plantar; above lies to inside of artery, below to outer side. *Muscula' res*, to tibialis posticus, flexor longus digitorum, and pollicis. *Cuta' neus planta' ris*, perforates internal annular ligament, supplying integument of heel and inner side of sole of foot. *Planta' ris inter' nus*: (see above) largest terminal branch accompanying internal plantar artery along inner side of foot. *Cuta' nei*, to sole of foot. *Muscula' res*, to flexor brevis digitorum, and abductor pollicis. *Articula' res*, to tarsus and metatarsus. *Digitales*, (4); supplying the first 3 toes (both sides) and inner margin of the 4th toe, integument, articulations, nails, etc., and 1st and 2d lumbricales. *Planta' ris exter' nus*: (see tibial posterior) follows course of its artery to outer side of foot, supplying little toe and outer half of 4th toe, and structures adjacent, flexor accessorius, and abductor minimi digiti. *Superficia' lis* branch goes to outer side of 5th and adjacent sides of 4th and 5th toes, flexor brevis minimi digiti, and the 2 interossei of 4th metatarsal space. *Deep* branch supplies remaining interossei, 2 outer lumbricales, adductor pollicis, transversus pedis.

POPLITE' US EXTE' RNUS (or peronæ' us): $\frac{1}{2}$ size of internus poplitæus (see great sciatic); descends along outer margin of popliteal space to fibula, and about 1 inch below its head divides into anterior tibial and musculo-cutaneous. *Articula' res*: (2) accompanies external articular arteries to outer side of knee. Sometimes a 3d is given off as a recurrent, which supplies front of knee. *Cuta' nei*, (2 or 3); supply integument of back and outer side of leg as far as its lower 3d. *Communica' ns peronæ' i*, arises near fibular head, joining external saphenous at middle of leg. *Tibia' lis ante' rior*: (see above) passes obliquely forwards to front of interosseous membrane, reaching outer side of anterior tibial artery at middle of leg, descending thence to front of ankle it divides into external and internal

branches. *Muscula' res*, to tibialis anticus, extensor longus digitorum, extensor proprius pollicis. *Exter'nal* or *tar'seus*, outwards across tarsus, supplies external brevis digitorum, and articulations of tarsus and metatarsus; becomes gangli-
onic. *Internal* branch accompanies dorsalis pedis artery, supplying 1st interosseous space and adjacent sides 1st and 2d toes, *communicates* with internal division of musculo-cutaneous. *Mus'culo-cuta'neus*: supplies muscles of fibular side of leg and dorsal integument of foot (see poplitæ'us exte'r'nus). At lower 3d of leg (its front and outer side) divides into internal and external branches. *Muscula' res*, fibular muscles and integuments. *Internal* branch, down in front of ankle to supply inside of great toe and adjacent sides of 2d and 3d toes, integument of inner ankle and inside of foot; *communi-
cates* with internal saphenous and anterior tibial. *External* branch, down outer side dorsum of foot to supply adjacent sides of 3d, 4th and 5th toes, integument of outer ankle and outer side of foot; *communicates* with external saphenous.

OSTEOLOGY.

NOTE.—Muscles in *italics*, are muscles of insertion. Figures in [] show the primary number of ossific centres, and date of appearance of ossification.

COMPOSITION: Gelatine and blood-vessels, 33.30; calcic phosphate, 51.04; calcic carbonate, 11.30; calcic fluoride, 2.00; magnesian phosphate, 1.16; sodic chloride and oxide, 1.20; total, 100.00.

NUMBER: vertebral column (including sacrum and coccyx) 26; cranium, 8; ossiculi auditus, 6; face, 14; hyoid, sternum and ribs, 25; upper extremity, 64; lower extremity, 60; total, 204. To this may be added the patellæ and teeth, making a grand total of 238.

SPINE has 33 vertebræ, viz.: 7 cervical, 12 dorsal, 5 lumbar, 5 sacral, 4 coccygeal. They each have a body, 7 processes, 2 pedicles, 2 laminæ, 4 notches, and a foramen. The cervical are noted for the smallness and broadness of body, bifid spinous processes, bifid and perforated transverse processes, etc. The peculiar are the 1st, or *atlas*, which is like a "ring;" the 2d, or *axis*, having a large (odontoid) process; the 7th, or *prominens*, having a long spinous process. The dorsal have body largest antero-posteriorly, spinous processes directed downwards, facets for ribs. Peculiar are the 1st, having one whole facet, the rest demi-facets for the ribs; 10th, 11th and 12th, each having a distinct facet for a rib. *Muscles:*

to the atlas are attached 10; to the axis, 11; to the remaining (anteriorly) 10, (posteriorly) 22. [The vertebræ are developed from 3 centres by ossification, the first appearing at 6th week; at sixteen 4 secondary centers appear, and at twenty-one a circular plate for superior and inferior surfaces of body. A few exceptions, as atlas (2 primitive centers), axis (6), 7th cervical and the lumbar (5).]

Sacrum: triangular, anterior and posterior foramina, lateral masses, laminæ, tubercular transverse processes, promontory, sacral canal and groove, auricular surface. *Articulations* (4); 2 innominate, 5th lumbar, coccyx. *Muscles*, (5); pyriform, *coccygeus*, *glutæus maximus*, *erector spinæ*, *latissimus dorsi*. [35, 8th week.]

Coccyx: cornua. *Articulation*, (1); sacrum. *Muscles*, (4); *coccygeus*, *glutæus maximus*, sphincter and levator ani. [4 birth to puberty.]

Occipitale: superior and inferior curved lines, crest, protuberance, foramen magnum, condyles, basilar and jugular processes, pharyngeal spine, anterior and posterior condyloid foramina; fossæ cerebri et cerebelli, torcula protuberance, grooves for occipital, lateral, inferior petrosal, superior longitudinal sinûs and medulla, jugular fossa. *Artic.* (6); 2 parietal, 2 temporal, sphenoid, atlas. *Musc.* (12); *occipito-frontalis*, *trapezius*, *sterno-cleido-mastoid*, *complexus*, *splenius capitis*, *obliquus superior*, *rectus posticus major* and *minor*, *rectus lateralis*, *rectus anticus major* and *minor*, *superior pharyngeus*, *constrictor*. [4, 10th week.]

Parietale: eminence, foramen, temporal ridge; Pacchionian depressions, middle meningeal groove, superior longitudinal and lateral sinûs. *Artic.* (5); fellow, occipital, frontal, temporal, sphenoid. *Musc.* (1); temporal. [1.]

Frontale: eminence, superciliary ridges, external and internal angular processes, supra-orbital notches and arches, temporal ridges and fossæ, nasal eminence and spine; orbital plates, lachrymal fossa, pulley depression, ethmoid notch, anterior ethmoid foramina, foramen cæcum, meningeal grooves, Pacchionian depressions, frontal and superior longitudinal sinûs (frontal suture). *Artic.* (12); 2 parietal, sphenoid, ethmoid, 2 nasal, 2 superior maxillæ, 2 lachrymal, 2 malar. *Musc.* (3 pr.); *corrugator supercilii*, *orbicularis palpebrarum*, temporal. [2.]

Temporale: zygoma, articular eminence, glenoid fossa, Glasserian fissure, vaginal, styloid, mastoid and auditory processes, mastoid foramen, superior and inferior petrosal

and lateral sinûs, aquæductus vestibuli, meatus auditorius internus, hiatus Fallopii, opening for smaller petrosal nerve, depression Casserian ganglion, carotid canal, openings for Jacobson's and Arnold's nerves, aquæductus cochleæ, jugular fossa, stylo-mastoid foramen, auricular fissure, canal for Eustachian tube, and tensor tympani. *Artic.* (5); occipital, parietal, sphenoid, inferior maxilla, malar. *Musc.* (14); temporal, masseter, occipito-frontalis, *sterno-mastoid*, *splenius capitis*, *trachelo-mastoid*, digastric, retrahens aurem, stylo-pharyngeus, stylo-hyoid, stylo-glossus, levator palati, tensor tympani, stapedius. [4, 8th week.]

Sphenoi'des: ethmoid spine, optic groove, olivary process, sella turcica, anterior middle and posterior clinoid processes, cavernous groove; foramina opticum, lacerum anterius, rotundum, Vesalii, ovale, spinosum; spinous, hamular, vaginal and external and internal pterygoid processes; rostrum, pterygoid notch and ridge, scaphoid, pterygoid, temporal and zygomatic fossæ, Vidian and pterygo-palatine canals. *Artic.* (12); all of cranium and 2 malar, 2 palate and vomer. *Musc.* (12 pr.); temporal, external and internal pterygoid, superior constrictor, tensor palati, laxator tympani, levator palpebræ, obliquus superior, internal and external recti, superior and inferior recti. [10, 8th w.]

Ethmoi'des: crista galli, infundibulum, os planum, unci-form process, olfactory foramina, superior meatus, anterior and posterior cells. *Artic.* (15); sphenoid, frontal, 2 sphenoidal turbinated, 2 nasal, 2 superior maxillary, 2 lachrymal, 2 palate, 2 inferior turbinated, vomer. *Musc.* none. [3, 4th m.]

Nasa'le: groove for nasal nerve. *Artic.* (4); frontal, ethmoid, fellow, superior maxilla. *Musc.* none. [1, 8th w.]

Maxilla're supe'rior: nasal process lachrymal tubercle, orbicular surface, infra-orbital groove and foramen, canine and incisive fossa, canine eminence, alveolar process, posterior dental canals, maxillary tuberosity, middle and inferior meatus, palate process, anterior and posterior palatine canals; antrum. *Artic.* (9); frontal, ethmoid, nasal, malar, lachrymal, inferior turbinated, palate, vomer, fellow. *Musc.* (9); orbicularis palpebrarum, inferior obliquus oculi, levator labii superioris alæque nasi, levator labii superioris proprius, levator anguli oris, compressor naris, depressor alæ nasi, masseter, buccinator. [4, early.]

Lachryma'le: lachrymal groove. *Artic.* (4); frontal, ethmoid, superior maxilla, inferior turbinated. *Musc.* (1); tensor tarsi. [1, 8th week.]

Mala'ra: frontal, zygomatic, orbital and maxillary processes, temporo-malar canal, *Artic.* (4); frontal, sphenoid, temporal, superior maxilla. *Musc.* (5); levator labii superioris proprius, zygomaticus major and minor, masseter, temporal. [1, 8th week.]

Os pala'ti: orbital, maxillary, and sphenoid processes, spheno-palatine foramen, superior meatus and superior turbinated crest, middle meatus and inferior turbinated crest, inferior meatus; posterior palatine canal, tuberosity, posterior nasal spine. *Artic.* (7); sphenoid, ethmoid, superior maxilla, inferior and superior turbinated, vomer, fellow. *Musc.* (4); tensor palati, azygos uvulæ, internal and external pterygoid. [1, —.]

Turbina'tum infe'rior: lachrymal, ethmoid and maxillary processes. *Artic.* (4); ethmoid, superior maxilla, lachrymal, palate. *Musc.* none [1, 4th month.]

Vo'me: naso-palatine groove. *Artic.* (6); sphenoid, ethmoid, 2 superior maxilla, 2 palate. *Musc.* none. [2, 8th week.]

Maxilla'ra infe'rior: coronoid process, condyle, ramus, sigmoid notch, mental foramen and process, symphysis, groove for facial artery, inferior dental foramen, mylo-hyoid groove and ridge, sublingual and submaxillary fossæ, genial tubercles. *Artic.* (2); 2 temporal. *Musc.* (14 pr.); levator menti, depressor labii inferioris, depressor anguli oris, *platysma*, buccinator, *masseter*; genio-hyo-glossus, genio-hyoid, mylo-hyoid, *digastric*, superior constrictor, *temporal*, *internal* and *external pterygoid*. [2, early.]

Hyo'idæ: greater and lesser cornua, body. *Artic.* none. *Musc.* (11); *sterno-*, *thyro-*, *omo-*, *stylo-*, *mylo-* and *genio-hyoid*, genio-hyo-glossus, hyo-glossus, middle constrictor, lingualis, *pulley* of digastric. [5, 8th month.]

Ster'num: *manubrium*, *gladidus*, *ensiform appendix*; facets for 7 superior ribs. *Artic.* (16); 7 pairs ribs, 2 clavicles. *Musc.* (10); pectoralis major, sterno-mastoid, sterno-hyoid and sterno-thyroid, triangularis sterni, obliquus externus and *internus*, transversalis, *rectus*, *diaphragm*. [6, 5th month.]

Co's'tæ (ribs): head, neck, tuberosity, articular and non-articular protuberances, angle, facets for superior and inferior vertebræ. *Artic.* (24); vertebræ and costal cartilages. *Musc.* (19); [3 each, save the last two, these but 2; early.] *Peculiar ribs:* 1st, shortest, most curved, horizontally placed, having grooves for subclavian artery and vein; 2d, some larger than 1st, is not twisted, etc.; 10th, single articular facet; 11th and 12th, single articular facet, no neck or tuberosity.

Costal Cartilages: *artic.* with sternum and ribs. *Musc.* (10); subclavius, sterno-thyroid, pectoralis major, *internus obliquus*, transversalis, *rectus*, *diaphragm*, internal and external intercostal, triangularis sterni. (The last 3 are muscles of origin and insertion.)

Clavic'ula: shape of letter *f*; sternal and acromial extremity; oblique line, tuberosity, rhomboid impression. *Artic.* (3); sternum, scapula, 1st costo-cartilage. *Musc.* (6); sterno-mastoid and sterno-hyoid, *trapezius*, pectoralis major, deltoid, *subclavius*. [2, first of all.]

Scap'ula: acromian and coracoid processes, glenoid cavity, neck, subscapular fossa, ridges; supra-scapular notch, supra- and infra-spinous fossæ, spine, groove for dorsalis scapulæ vessels. *Artic.* (2); clavicle, humerus. *Musc.* (17); subscapularis, supra- and infra-spinatus, *trapezius*, deltoid, omo-hyoid, *serratus magnus*, *levator anguli scapulæ*, *rhomboideus major* and *minor*, triceps, teres major and minor, biceps, coraco-brachialis, *pectoralis minor*, latissimus dorsi. [7, 8th w.]

Hu'merus: head, anatomical and surgical necks, greater and lesser tuberosities, bicipital ridge and groove, posterior bicipital ridge, rough deltoid surface, internal and external condyles, coronoid and radial depressions, radial head, trochlear surface; musculo-spiral groove, olecranon depression. *Artic.* (3); scapula, ulna, radius. *Musc.* (24); *supra- and infra-spinatus*, *teres major* and *minor*, *subscapularis*, *pectoralis major*, *latissimus dorsi*, *deltoid*, *coraco-brachialis*, *brachialis anticus*, triceps; pronator radii teres, flexor carpi radialis, palmaris longus, flexor sublimis digitorum, flexor carpi ulnaris; supinator longus, extensor carpi radialis longior and brevior, extensor communis digitorum, extensor minimi digiti, extensor carpi ulnaris, anconeus, supinator brevis. [7, early.]

Ulna: olecranon, greater and lesser sigmoid cavities, coronoid process, nutrient foramen, styloid process; oblique line, groove for extensor carpi ulnaris. *Artic.* (2); humerus, radius. *Musc.* (13); *triceps*, *anconeus*, flexor and extensor carpi ulnaris, *brachialis anticus*, pronator radii teres, flexor sublimis and profundus digitorum, pronator quadratus, supinator brevis, extensor ossis metacarpi and extensor secundi internodii pollicis, extensor indicis. [3, 5th w.]

Ra'dius: head, neck, bicipital tuberosity, oblique line, nutrient foramen, styloid process, 2 grooves; 4 grooves for extensor muscles. *Artic.* (4); humerus, ulna, scaphoid, semilunar. *Musc.* (9); *biceps*, *supinator longus* and *brevis*, flexor

sublimis digitorum, flexor longus pollicis, *pronator quadratus*, extensor ossis metacarpi pollicis, extensor primi internodii pollicis, *pronator radii teres*. [3.]

CAR'PUS: (8); [1 after birth]: *Scaphol'des:* *artic.* (5); radius, trapezium, trapezoid, magnum, semi-lunar. *Semi-luna're:* *artic.* (5); radius, magnum, unciform, scaphoid, cuneiform. *Cuneifor'me:* *artic.* (3); semilunar, pisiform, unciform. *Pisifor'me:* *artic.* (1); cuneiform. *Musc.* (2); *flexor carpi ulnaris*, abductor minimi digiti. (LOWER ROW.) *Trapezium:* *artic.* (4); scaphoid, trapezoid, 1st and 2d metacarpal. *Musc.* (3); abductor, flexor ossis metacarpi and flexor brevis pollicis. *Trapezol'des:* *artic.* (4); scaphoid, 2d metacarpal, trapezium, magnum. *Musc.* (1); flexor brevis pollicis. *Os mag'num:* *artic.* (7); scaphoid, semilunar, 2d, 3d, 4th metacarpal, trapezoid, unciform. *Musc.* (1); flexor brevis pollicis. *Uncifor'me:* *artic.* (5); semilunar, 4th, 5th metacarpal, cuneiform, os magnum. *Musc.* (2); flexor brevis and flexor ossis metacarpi minimi digiti, anterior annular ligament.

METACAR'PUS: (5); bones are prismoid, curved longitudinally, convex behind, concave in front. [2, 6th week.] **1s:** *artic.* (2); trapezium, 1st phalanx. *Musc.* (3); *flexor* and *extensor ossis metacarpi pollicis*, 1st dorsal interosseous. **2d:** *artic.* (5); trapezium, trapezoides, magnum, 3d metacarpus, 2d phalanx. *Musc.* (5); *flexor carpi radialis*, *extensor carpi radialis longior*, 1st and 2d dorsal interosseous, 1st palmar interosseous. **3d:** *artic.* (4); magnum, 2d and 4th metacarpal, 3d phalanx. *Musc.* (5); *extensor carpi radialis brevior*, flexor brevis pollicis, adductor pollicis, 2d and 3d dorsal interosseous. **4th:** *artic.* (5); magnum, unciform, 3d and 5th metacarpal, 4th phalanx. *Musc.* (3); 3d and 4th dorsal and 2d palmar interosseous. **5th:** *artic.* (3); unciform, 4th metacarpal, 5th phalanx. *Musc.* (5); *flexor* and *extensor carpi ulnaris*, *flexor ossis metacarpi minimi digiti*, 4th dorsal and 3d palmar interosseous. (An error in "Gray" here.)

PHALAN'GES: (14); [2, 6th w.] **First row:** *artic.* metacarpal and 2d row. *Musc.* 1st or thumb, (4); *extensor primi internodii*, *flexor brevis*, *abductor* and *adductor pollicis*. **Index,** (2); 1st dorsal and palmar interosseous. **Middle finger,** (2); 2d and 3d dorsal interosseous. **Ring finger,** (2); 4th dorsal and 2d palmar interosseous. **Little finger,** (3); 3d palmar interosseous, *flexor brevis* and *abductor minimi digiti*. **Second row:** thumb, (2); *flexor longus* and *extensor secundi internodii pollicis*. To the others, (4); *flexor sublimis* and *extensor communis digitorum*, with *extensor indicis* to index and

extensor minimi digiti to little finger. Third row: *flexor profundus*, and *extensor communis digitorum*.

Innomina'tum: crest, superior, middle and inferior curved lines, anterior and posterior superior and inferior spinal processes, greater and lesser sacro-sciatic notches, ilio-pectineal eminence line and groove, acetabulum, cotyloid notch; body, crest, spine, angle of pubes, ischic spine and tuberosity, obturator foramen, ischic and pubic rami; internal iliac fossa, groove for obturator and pubic vessels, symphysis pubis, auricular and sacro-iliac rough surfaces. *Artic.* (3); fellow, sacrum, femur. *Musc.* (33); tensor vaginæ femoris, *obliquus externus* and *internus*, *latissimus dorsi*, *transversalis*, *quadratus lumborum*, *erector spinæ*; 3 *glutæi*, *rectus*, *pyriformis*, *iliacus*, *sartorius*; (ischium) *obturator externus* and *internus*, *levator ani*, 2 *gemelli*, *coccygeus*, *biceps*, *semi-tendinosus*, *semi-membranosus*, *quadratus femoris*, *adductor magnus*, *transversus perinæi*, *erector penis*; (pubes) *psaos parvus*, *pectineus*, *adductor longus* and *brevis*, *gracilis*, *compressor urethræ*, (*accelerator urinæ*). [8, 3 primary, 5 secondary.]

Femur: head, depression for ligamentum teres, neck, greater and lesser trochanters, spiral line, shaft, internal and external tuberosities and condyles; digital fossa, trochanteric line, inter-condyloid notch, *linea aspera*. *Artic.* (3); innominatum, tibia, patella. *Musc.* (23); *glutæus medius* and *minimus*, *pyriformis*, *obturator internus* and *externus*, 2 *gemelli*, *quadratus femoris*; *psaos magnus*, *iliacus*; 2 *vasti*, *glutæus maximus*, *biceps*, 3 *adductors*, *pectineus*, *crureus* and *subcrureus*, *gastrocnemius*, *plantaris*, *popliteus*. [5, 5th w.]

Patella: subcutaneous surface; outer and inner facets. *Artic.* condyles of femur, (ligamentum patellæ attaches it to tibia.) *Musc.* (4); *rectus*, *crureus*, *vastus externus* and *internus*. [Sesamoid, 3d year.]

Tibia: head, spine, internal and external tuberosity, tubercle, fibular facet, crest, internal malleolus; popliteal notch, oblique line, nutrient foramen, common groove for *flexor longus digitorum* and *tibialis posticus*, another for *flexor longus pollicis*. *Artic.* (3); femur, fibula, astragalus. *Musc.* (10); *semi-membranosus*; *tibialis anticus*, *extensor longus digitorum*; *sartorius*, *gracilis*, *semi-tendinosus*; *popliteus*, *soleus*, *flexor longus digitorum*, *tibialis posticus*, *ligamentum patellæ*. [3, 5th w.]

Fibula: head, styloid process, shaft, external malleolus; groove for *peroneus longus* and *brevis*, nutrient foramen. *Artic.* (2); tibia, astragalus. *Musc.* (9); *biceps*, *soleus*, 3 *peronei*.

nei; extensor longus digitorum and pollicis, tibialis posticus, flexor longus pollicis. [3, 6th w.]

TAR'SUS, (7): *Calcis*: greater and lesser processes, tubercle, superior and inferior grooves. *Artic.* (2); astragalus, cuboid. *Musc.* (8); *tibialis posticus*, *tendo Achillis*, *plantaris*, abductor pollicis and minimi digiti, flexor and extensor brevis digitorum, flexor accessorius. [1, 6th m.] *Cuboi'des*: *artic.* (4); calcis, external cuneiform, 4th and 5th metatarsi (occasionally scaphoid). *Musc.* (1); flexor brevis pollicis. [1, 9th m.] *Astrag'alus*: *artic.* (4); tibia, fibula, calcis, scaphoid. *Musc.* none. [1, 7th m.] *Scaphoi'des*: *artic.* (4); astragalus, 3 cuneiform (sometimes cuboid.) *Musc.* (1); *tibialis posticus*. [1, 4th y.] *Cuneifor'me inter'nus*: largest of the three; *artic.* (4); scaphoid, middle cuneiform, 1st and 2d metatarsal. *Musc.* (2); *tibialis anticus* and *posticus*. [1, 3d y.] *Cuneifor'me me'dius*: smallest; *artic.* (4); scaphoid, internal and external cuneiform, 2d metatars. *Musc.* none. [1, 4th y.] *Cuneifor'me exter'nus*: *artic.* (6); scaphoid, middle cuneiform, cuboid, 2d, 3d, 4th metatarsi. *Musc.* (2); *tibialis posticus*, flexor brevis pollicis. [1, 1st y.]

METATAR'SUS, (5): shaft straight, posterior extremity wedge-shaped, anterior rounded. [2, 8th w.] *1st*: greater size, shortest. *Artic.* (3); internal cuneiform, phalanx, 2d metatarsus. *Musc.* (3); *tibialis anticus*, *peroneus longus*, 1st dorsal interosseous. *2d*: longest. *Artic.* (6); 3 cuneiform, 1st and 3d metatarsi, 2d phalanx. *Musc.* (3); adductor pollicis, 1st and 2d dorsal interosseous. *3d*: *artic.* (4); external cuneiform, 2d and 3d metatarsus, 3d phalanx. *Musc.* (4); 2d and 3d dorsal and 1st plantar interosseous, adductor pollicis. *4th*: *artic.* (5); external cuneiform, cuboid, 3d and 5th metatarsi, 4th phalanx. *Musc.* (4); adductor pollicis, 3d and 4th dorsal and 2d plantar interosseous. *5th*: tubercular eminence. *Artic.* (3); cuboid, 4th metatarsus, 5th phalanx. *Musc.* (5); *peroneus brevis* and *tertius*, flexor brevis minimi digiti, 4th dorsal and 3d plantar interosseous.

PHALAN'GES, (14): shaft convex above, concave below; posterior extremity concave, anterior is convex. [2, after metatarsus.] *1st row*: *artic.* metatarsal and 2d row. *Musc.*: big toe, (5); *extensor brevis digitorum*, *transversus pedis*, *abductor*, *adductor* and *flexor brevis pollicis*. Second, (2); 1st and 2d dorsal interosseous. Third, (2); 3d dorsal and 1st plantar interosseous. Fourth, (2); 4th dorsal and 2d plantar interosseous. Fifth, (3); *flexor brevis* and *adductor minimi digiti*, 3d plantar interosseous. *2d row*: *artic.* 1st and 3d phalanges.

Musc. big toe, (2); *extensor* and *flexor longus pollicis*. Remaining toes, (4 each); *flexor brevis digitorum*, and *ext. longus* and *brevis digitorum*, *lumbricales*. 3d row: *artic.* 2d phalanges. *Musc.* (3 each); *extensor longus* and *brevis*, and *flexor longus digitorum*.

OSSEICULA AUDITUS (3): *Malleus*: head, neck, manubrium (handle), *processus brevis* and *gracilis*. *Artic.* (1); *incus*. *Musc.* (3); *laxator major* and *minor tympani*, *tensor tympani*. *Incus*: body, short and long processes, *os orbiculare*. *Artic.* (2); *malleus*, *stapes*. *Musc.* none. *Stapes*: head, neck, base, *crura*. *Artic.* (1); *incus*. *Musc.* (1); *stapedius*.

ACTION OF MUSCLES.

Head is moved *forwards* by *platysma myoideus*, *sternomastoid*, *rectus capitis anticus major*, *rectus capitis anticus minor*, (assisted by, when jaw is fixed) *mylo-hyoid*, *genio-hyoid*, *genio-hyoglossus*, *digastricus*. *Backwards* by *trapezius*, *splenius capitis*, *complexus*, *trachelo-mastoid*, *rect. capt. post. maj.*, *rect. cap. post. min.*, *obliquus cap. superior*. *Sideways* by *platysma myoideus*, *sterno-cleido-mastoid*, *trapezius*, *splenius capitis*, *splen. colli*, *trachelo-mastoid*, *complexus*.

Neck: *forwards* by *platysma myoideus*, *sterno-cleido-mastoid*, *digastricus*, *mylo-hyoid*, *genio-hyoid*, *genio-hyoglossus*, *omo-hyoid*, *sterno-hyoid*, *thyro-hyoid*, *rect. cap. ant. major* and *minor*, *longus colli*. *Backwards* by *trapezius*, *rhomboideus minor*, *serratus posticus superior*, *splenius capitis*, *splenius colli*, *complexus*, *trachelo-mastoid*, *transversalis colli*, *inter-spinales colli*, *rect. cap. post. maj.* and *minor*, *obliquus capitis superior* and *inferior*, *scalenus posticus*, *levator anguli scapulæ*. *Sideways* by the above in conjoined action, and the *scaleni*, *inter-transversales*, *recti-laterales*.

Trunk: *forwards* by *rectus abdominis*, *pyramidalis*, *obliquus externus* and *internus abdominis*, *psoas magnus* and *parvus*; assisted by (when arms are carried forwards) *pectoralis major* and *minor*, *serratus magnus*. *Backwards*, *trapezius*, *rhomboideus major*, *latissimus dorsi*, *serratus posticus superior* and *inferior*, *sacro-lumbalis*, *longissimus dorsi*, *spinales dorsi*, *semi-spinalis dorsi*, *multifidus spinæ*, *intertransversalis dorsi et lumborum*. *Laterally*, *obliquus externus* and *internus*, *quadratus lumborum*, *longissimus dorsi*, *sacro-lumbalis*, *serratus posticus*, *latissimus dorsi*.

Scapula: *forwards* by *pectoralis minor*, *serratus magnus*, *Backwards*, *trapezius*, *rhomboidei*, *latissimus dorsi*. *Up-*

wards, trapezius, levator scapulæ, rhomboidei. *Downwards*, trapezius, latissimus dorsi, pectoralis minor.

Humerus: *forwards*, deltoid, pectoralis major; assisted, sometimes, by biceps, coraco-brachialis. *Backwards*, deltoid, teres major and minor, triceps (long head), latissimus dorsi. *Inwards*, pectoralis major, latissimus dorsi. *Rotated inwards*, subscapularis, assisted by pectoralis major, lat. dorsi, teres major. *R. outwards*, supra-spinatus, infra-spinatus, teres minor.

Forearm: *forwards*, biceps, brachialis anticus, pronator radii teres; assisted by flex. carpi rad., flex. sublimis digitorum, flex. carpi ulnaris, supinator longus. *Backwards*, triceps, anconeus. *Rotated inwards*, pronator radii teres, flex. carpi radialis, palmaris longus, flexor sublimis dig., pronator quadratus. *R. outwards*, biceps, supinator brevis, extensor secundi internodii pollicis.

Carpus: *forwards*, flex. carpi radialis, palmaris longus, flex. sublimis and profundus dig., flex. carpi ulnaris, flex. longus pollicis. *Backwards*, ext. carpi rad. long. and brev. ext. secundi internodii pollicis, ext. indicis, ext. com. dig., ext. prop. pollicis. *Outwards*, flex. carpi rad., ext. carp. rad. long. and brevior, ext. ossis metacarpi pol., ext. primi internodii pol. *Inwards*, flex. sublim. and profund. digitorum, flex. and ext. carpi ulnaris, ext. com. dig., ext. min. digiti.

Thumb: *inwards* and *forwards*, opponens, flex. brevis and flex. long. pollicis. *Outwards* and *backwards*, ext. ossis metacarpi, ext. primi and secundi internodii pollicis. *Upwards* and *away from fingers*, abductor, flex. brev. pollicis. *Backwards* and *towards fingers*, adductor, ext. primi and secundi internodii pollicis.

Fingers: *flexed*, flex. sublimis and profundus dig., lumbricales, flex. and abductor minimi digiti. *Backwards*, ext. communis, ext. minimi digiti and indicis. *Outwards*, interossei, abductor indicis and minimi digiti. *Inwards*, interossei, abductor minimi digiti.

Thigh: *forwards*, psoas mag., iliacus, tensor vaginæ fem. pectineus, adductor longus and brevis. *Backwards*, glut. max. and med., pyriformis, obturator intern., add. mag., biceps, semitend., semi-membranosus. *Inwards*, psoas mag., iliacus, pectineus, gracilis, the 3 adductores, obturator extern., quad. femoris. *Outwards*, tens. vag. fem., the 3 glutæi, pyriformis. *Rotated inwards*, tens. vag. fem., glut. med., and, if leg extended, sartorius, semi-tendinosus. *R. outwards*, glut. max. and med., pyriformis, gemelli, obtura-

tores, quad. fem., psoas mag., iliacus, the 3 adductores, biceps femoris.

Leg: *flexed*, semi-tendinosus, biceps, semi-membranosus, gracilis, sartorius, popliteus. *Extended*, rectus fem., crureus 2 vasti.

Foot: *inwards*, ext. prop. pollicis, flex. long. dig., flex. long. pol., tibialis posticus. *Outwards*, the 3 peronei, ext. long. dig. *Flexed*, tibialis anticus, ext. prop. pol., ext. long. dig., peroneus tertius. *Extended*, gastrocnemius, plantaris, soleus, flex. long. dig., flex. long. pol., tib. posticus, peroneus longus and brevis.

Toes: *flexed*, adductor, abductor, flex. longus and brevis pollicis, abductor and flex. brev. minimi digiti, flex. brev. and longus digitorum, flex. accessorius, lumbricales, interossei. *Extended*, ext. long. and brevis digitorum, ext. prop. pollicis. *Inwards*, abductor pollicis, interossei. *Outwards*, add. pollicis and min. digiti, interossei.

—o—

CIRCULATION.

Cardiac and pulmonic: The venæ cavæ receive the systemic venous blood, and convey it into the right auricle; then it passes into the right ventricle (through the tricuspid, or auriculo-ventricular valves, to be thrown into the pulmonic artery (going through the semilunar, or pulmonary valves); is then conveyed to the lungs and oxygenized in the capillary plexus about the intercellular structure and the air-cells, and returned, by the pulmonary veins (4 in number) to the *left* side of the heart, into the left auricle; it then passes into the left ventricle (through the mitral valve) to be forced into the aorta (through the semilunar valves), and from thence to supply the system at large.

Fœtal: from the placenta through the umbilical vein to the liver; from thence, by the hepatic veins and *ductus venosus Arantii*, to the inferior vena cava, to the right auricle; the most of the current, guided by the Eustachian valve, passes through the foramen ovale into the *left* auricle, and from thence into the left ventricle, and from thence into the aorta and system at large. A part of the current, however, enters the *right ventricle*, is then forced into the pulmonary artery, and from the imperviousness of the fœtal lungs is most all conveyed to the aorta by the *ductus arteriosus Botalli*. The blood is at last conducted by the umbilical arteries (branches of the internal iliac) to the placenta for reoxygenation.

RESUME OF OSTEOLOGY.

Name of Bone.	Number of Articulations,	Number of Muscles attached.	Primary Developmental Centres.
Occipital.....	6.....	12.....	4
Parietal.....	5.....	1.....	1
Frontal.....	12.....	3.....	2
Temporal.....	5.....	14.....	4
Sphenoid.....	12.....	12.....	10
Ethmoid	15.....	none.....	3
Nasal.....	4.....	none.....	1
Maxillary Sup.....	9.....	9.....	4
Lachrymal.....	4.....	1.....	1
Malar	4.....	5.....	1
Palate.....	7.....	4.....	1
Turbinated Inf.....	4.....	none.....	1
Vomer.....	6.....	none.....	2
Maxillary Inf.....	2.....	14.....	2
Hyoid.....	none.....	11.....	5
Sternum.....	16.....	10.....	6
Ribs (12).....	24.....	19.....	34
Clavicle.....	3.....	6.....	2
Scapula.....	2.....	17.....	7
Humerus.....	3.....	24.....	7
Ulna.....	2.....	13.....	3
Radius	4.....	9.....	3
Scaphoid	5.....	none.....	1
Semilunar.....	5.....	none.....	1
Cuneiform.....	3.....	none.....	1
Pisiform.....	1.....	2.....	1
Trapezium	4.....	3.....	1
Trapezoid	4.....	1.....	1
Os Magnum.....	7.....	1.....	1
Unciform.....	5.....	2.....	1
Metacarpal (5).....	19.....	18.....	10
Phalanges (14).....	23.....	20.....	28
Vertebræ (24).....	72.....	39.....	85
Sacrum.....	4.....	5.....	11
Coccyx.....	1.....	4.....	4
Innominatum.....	3.....	33.....	3 and 5
Femur.....	3.....	23.....	5
Patella.....	1.....	4.....	sesamoid
Tibia.....	3.....	10.....	3

Fibula.....	2.....	9.....	3
Calcis	2.....	8.....	1
Cuboid.....	4.....	1.....	1
Astragalus.....	4.....	none.....	1
Scaphoid.....	4.....	1.....	1
Int. Cuneiform.....	4.....	2.....	1
Mid. Cuneiform.....	4.....	none.....	1
Ext. Cuneiform.....	6.....	2.....	1
Metatarsal (5).....	21.....	13.....	10
Phalanges (14).....	23.....	23.....	28
Malleus.....	1.....	3.....	?
Incus.....	2.....	none.....	?
Stapes	1.....	1.....	?



INDEX.

	PAGE.
Arteries: Body.....	29
Extremity (lower).....	39
“ (upper).....	19
Head and Neck.....	6
Body.....	26
Circulation.....	58
Extremity (lower)	35
“ (upper).....	16
Head and Neck	1
Muscles: Action of.....	56
Body	26
Extremity (lower).....	35
“ (upper)	16
Head and Neck.....	1
Nerves: Body.....	35
Extremity (lower).....	44
“ (upper).....	23
Head and Neck	13
Osteology	48
Resume Table of.....	59
Veins: Body.....	33
Extremity (lower).....	43
“ (upper).....	22
Head and Neck.....	11

The Vest-Pocket Anatomist,

BY C. HENRI LEONARD, A. M., M. D.,

Third Edition (8th Thousand)—Paper, 50c, Cloth, 75c. Used in every Medical College in the United States. 1,500 copies ordered by Balliere, Tyn-dall & Cox, London, England.

CONTENTS :

Each BONE: its name; pronunciation; the points of interest; the number and names of muscles attached (those of insertion being indicated by different type); number of articulations, and names of bones articulating; number of developmental centers, and time of first appearance.

Each MUSCLE: its name; origin; insertion; nervous supply; pronunciation; etc.

Each ARTERY: its name; number of branches from main vessel; pronunciation of each; origin; course; structures supplied; anastomosis. (Given in successive order of origin; the main vessels indicated by larger type.)

Each VEIN: its name; pronunciation; course; where emptying; vessels received; number of valves, etc.

Each NERVE: its name; pronunciation; origin; course; branches; distribution; anastomosis, etc. (Main branches indicated by larger type.)

Complete resume **TABLE** of the bones.

CLASSIFIED TABLE of the action of the muscles.

THE CODES OF MEDICAL ETHICS.

Paper, 25 cents.

CONTENTS: The Code of Ethics of the American Medical Association; that of the American Institute of Homœopathy; that of the National Eclectic Medical Society.

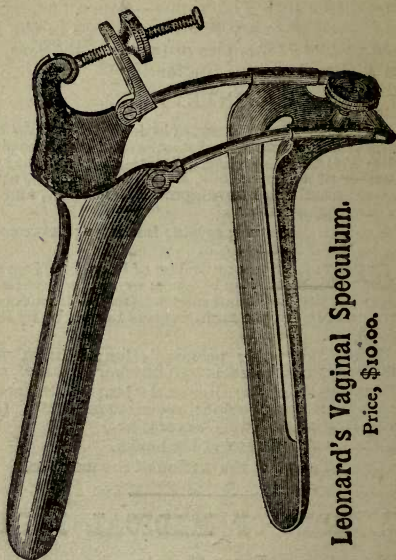
✍ Either book sent post-paid upon receipt of price by the publisher,

C. Henri Leonard, M. D.,

DETROIT, MICH.

A New Vaginal Speculum.

By C. HENRI LEONARD, M. D.



Leonard's Vaginal Speculum.

Price, \$10.00.

The cut gives a view of the speculum when fully expanded. As now seen, the tips of the blades are $4\frac{1}{4}$ inches apart; the inside measurement of the base of the blades being $2\frac{3}{4}$ inches. By the thumb screw attached to the lower blade, it (the lower blade) may be fixed at any point upon the perineal rods. When the base-extension, by the means of the perineal rods, is not made use of, the opening is then the same size as in the ordinary bivalve

specula. When thus closed, and the superior blade is not elevated, the speculum is in form ready for introduction. The upper blade is $\frac{1}{2}$ inch shorter than the lower one, thus allowing an expansion of the blades without the rubbing of the upper one over an inflamed cervix uteri. The blades measure, from the attachments of the perineal rods, respectively $4\frac{1}{8}$ and 5 inches in length. The upper blade has a fenestra which admits the urethra, thus relieving all pressure upon this sensitive organ when the perinæum is fully depressed. The lower blade also has a fenestra extending from its base to within an inch of its tip; this allows an *easy* probing of an anteflexed uterus, bent to an acute angle, the probe being allowed to press down the posterior vaginal wall, through this opening, until it can easily enter and traverse the distorted cervical canal. E.

The blades are well rounded up, and so relieve an excessive stretching of the vagina at their sides, thus making the instrument of easy introduction and painless to the patient. *Indeed, every patient that I have used one upon (and I have used them in many cases, and in vaginæ of all sizes, parties married and unmarried) has, upon questioning her in regard to the matter, declared that it gave her the least discomfort of any she had had introduced).*

You can make any operation upon the uterus or the sides of the vagina with this instrument; and by its use you may dispense with an assistant. When the perineal rods are used it is essentially a *Sim's Speculum*, only a self-retaining one. It may be used with the patient on the back, or in the "Sim's position", at the option of the operator.

Each instrument is made in the highest style of the art possible, and is finished, in full, in heavy nickel-plate, and will be warranted perfect in its action.

Sent post or express-paid on receipt of the price by

C. HENRI LEONARD, M. D.,

DETROIT, MICH.

LEONARD'S DOSE AND DAY BOOK

Leather, with Pencil Loop—\$1.25.

Printed matter is the same as in REFERENCE and DOSE BOOK. To this has been added an uniquely designed Daily Record for charges and patients to be visited, so arranged as to be posted to *any* Ledger at the end of each month. It has a capacity for 6,000 entrances of Debits, and like number of Credits (or for 15 patients a week): a complete Obstetric Record for 64 cases; 16 pages for Miscellaneous Accounts and 16 pages for Memoranda.

It is by far the cheapest, most condensed and comprehensive Day-Book or Record yet devised. Accounts can be kept in one-fifth the usual time, and with no writing but the name and address of the patient, and the figures indicating the charges. Is good for *one year* from the first of *any* month. Short accounts need no Ledger posting.

LEONARD'S MULTUM IN PARVO LEDGER.

Post-paid—\$2.50.

This is designed *especially* for the Dose and Day-Book, and greatly facilitates "posting." It does away with all the paging and much of the figuring required in the regular Ledger system. On a single line of a page the entire debit and credit account of a patient, in monthly statements, is seen for *the entire year*. It is divided into *five portions*, and will accommodate 400 patients yearly for five years.

By the use of these Books nine-tenths of the labor of book-keeping is done away with. Though the Ledger can be used *only* with the Dose and Day Book, yet the latter can be used with *any* Ledger.

Either post-paid on receipt of price.

C. HENRI LEONARD, M. D.

DETROIT, MICH.

THE HAIR;

Its Growth, Care, DISEASES AND TREATMENT.

By C. HENRI LEONARD, A. M., M. D.

Cloth, Post-paid, \$1.25.

*ILLUSTRATED BY NUMEROUS ENGRAVINGS OF
THE MICROSCOPICAL APPEARANCE IN
HEALTH AND DISEASE.*

CONTENTS:

- Chapters upon the Physiology of the Shaft and Bulb.
- The Chemistry of the Hair.
- The Microscopy of the Hair and Bulb.
- Hirsuties, or excess of Hair.
- Alopecia, or Baldness.
- Canities, or Blanching of Hair.
- Asteatodes.
- Pityriasis, or Dandruff.
- Seborrhœa.
- Eczema.
- Tinea Favosa.
- Tinea Tonsurans and Kerion.
- Tinea Alopecia.
- Tinea Sycosis (mentagra).
- Acne and Impetigo.
- Vegetable Parasitic Diseases in General.
- Animal Parasites.
- Phthiriasis, or Louse Disease.
- Acarus Folliculorum,
- Diseases of the Color of the Hair.
- Chignon Fungus.
- Coloring the Hair.
- Dressing the Hair.
- Removing Superfluous Hairs.
- Description of Hair Shafts of Ancient Egyptians, Peruvian Incas, the Babylonians, and Uses made of the Hair, and Miscellaneous Anecdotes. IN PRESS.

C. HENRI LEONARD, M. D., PUBLISHER,
Detroit, Mich.

LEONARD'S Prescription Blanks and Tablet.

THE CHEAPEST BLANKS PUBLISHED.

Each Tablet is made up of neatly printed Blanks, and is stoutly bound, and has a good, stiff pasteboard back; on the back of the Tablet (not the Blanks), is given the Antidotes to Poisons, and Rules for Genitive Case-endings in Prescription-Writing.

Each Blank has printed on its face the Name, Address and Office Hours of the Physician; the Name, Address, etc., of the Druggist; also the sign of Recipe in its appropriate position. The size of each blank is $3\frac{1}{2}$ by $4\frac{3}{4}$ inches, or $3\frac{1}{4}$ by $5\frac{1}{2}$ inches, (according to style preferred), and all are cut from the best 60-pound book paper.

PRICES.

For 6,000 Blanks done up into 150 Tablets, with 12 changes in Physicians' addresses.....	\$15.00
For 6,000 Blanks, done up into 60 Tablets, 12 changes in the Physicians' addresses.....	\$12.00
For 6,000 Blanks, done up into 60 Tablets, with 6 changes in the Physicians' addresses.....	\$10.00
For 4,000 Blanks, done up into 40 Tablets, with 8 changes in the Physicians' addresses.....	\$ 8.00
For 3,000 Blanks, done up into 30 Tablets, with 6 changes in the Physicians' addresses.....	\$ 6.50
For 2,000 Blanks, done up into 20 Tablets, with 4 changes in the Physicians' addresses.....	\$ 4.50
For 1,000 Blanks, done up into 10 Tablets, with 2 changes in the Physicians' addresses.....	\$ 2.50

Be sure and write THE ADDRESSES plainly or send cards when possible.

METRIC BLANKS.

These are same size and prices as the ordinary Blanks described above, but are furnished, in addition to Physicians' and Druggists' name and addresses, with Metric lines for the Gramme and Centigramme. The back of the Tablets bear, instead of Antidotes to Poisons, etc., Ready Rules to and from Metric Weights, Exceptions and Sp. Gr. of Exceptions, and table of Exact Values of ordinary weights or measures in Metric system. Sample Blanks on receipt of stamps. No goods sent except on receipt of the full amount *in advance*. We will stand all errors made in "following copy."

When ordered sent by mail 25 cts for each 1,000 must be added to the above prices for postage.

Address all orders to

C. HENRI LEONARD, M. D., DETROIT, MICH.

THE HIPPOCRATIC OATH, LAW AND APHORISMS.

EDITED BY C. HENRI LEONARD, A. M., M. D.

Octavo, paper covers, post-paid \$1.00.

In this edition the several translations and annotations will be diligently compared, and as *free* a rendering as possible of the Greek idioms will be given. A smooth version, rather than a strictly *literal* one, will be the object of the editor. There has been no recent edition of the work of this author, the Father of Medicine, issued, and none in a popular edition from the American press. No physician should remain ignorant of the *sound medical teachings* found in these Aphorisms. IN PREPARATION.

THE DISEASES

OF THE

Nose and Pharynx.

By Dr. CARL MICHEL, of Cologne.

Translated from the German by Professors C. YOUNG
and C. C. YEMANS, M. D.

OCTAVO, 112 PAGES, PAPER COVERS, POST-PAID, \$1.00.

Any one having anything to do with nasal and pharyngeal diseases, the scourge of our north-temperate climates, can illy afford to be without this great specialist's monograph. Its low price places it in easy reach of all.

C. HENRI LEONARD, M. D., PUBLISHER,
S. E. Cor. Gratiot and Woodward Aves., DETROIT, MICH.

The Medical Advance.

PREMIUMS AND CLUBBING RATES.

For FIVE DOLLARS, I will send five dollars' worth of the *Pharmaceutical Preparations* advertised in this journal by F. Stearns—(Fluid extracts, new products, sugar-coated pills, elixirs, resinoides, lozenges, suppositories, syrups, tinctures, etc., etc.) at his best prices, and include a copy of the MEDICAL ADVANCE *free* for one year.

For FOUR DOLLARS, I will send four dollars' worth surgical instruments or apparatus of any sort, or from any list, at best prices and include a copy of the MEDICAL ADVANCE for one year.

For THREE DOLLARS, I will send three dollars' worth of any medical books, and a copy of the MEDICAL ADVANCE *free* for one year.

For TWO DOLLARS, I will send two dollars' worth of any of *my* publications, postpaid, and a copy of the MEDICAL ADVANCE *free* for one year.

For ONE DOLLAR AND A HALF, I will send 1 copy of Leonard's Day-book, with *your name, town and State on the side in gold-leaf*, and a copy of the MEDICAL ADVANCE for one year *free*.

For the regular SUBSCRIPTION PRICE of *any regular* two-dollar (or one) medical journal published in the United States, I will send a copy of such journal, and include a copy of the MEDICAL ADVANCE for one year *free*.

For TWO DOLLARS AND FIFTY CENTS, I will send a good Hypodermic Syringe (retail price two dollars and fifty cents), by mail, *postpaid*, and include a copy of the MEDICAL ADVANCE for one year *free*.

For TWO DOLLARS AND FIFTY CENTS, I will send by mail, *postpaid*, a good 4-inch clinical, or fever thermometer—self-registering scale—in hard rubber case, and include a copy of the MEDICAL ADVANCE one year *free*.

For TWO DOLLARS, I will send any pattern pocket medicine case, the regular price of which is two dollars, and include the MEDICAL ADVANCE for one year.

C. HENRI LEONARD, A. M., M. D.,

Editor and Publisher.

524777



3 1378 00524 7773

~~3061~~

