

THE ULTIMATE POCKET-SIZED GUIDE TO NEUROLOGY

OXFORD HANDBOOK OF NEUROLOGY

Includes common presentations and disorders

Sections on neuroanatomy, neurosurgery, neuroradiology, and neurophysiology

Extensively illustrated with diagrams including brachial and lumbosacral plexi, dermatomes, peripheral nerves, and brainstem cross-sections

Hadi Manji

WITH

Seán Connolly

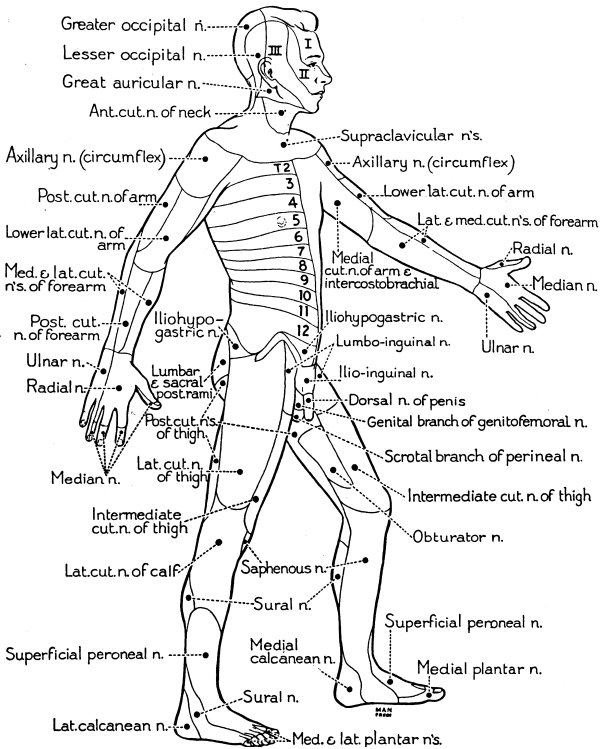
Neil Dorward

Neil Kitchen

Amrish Mehta

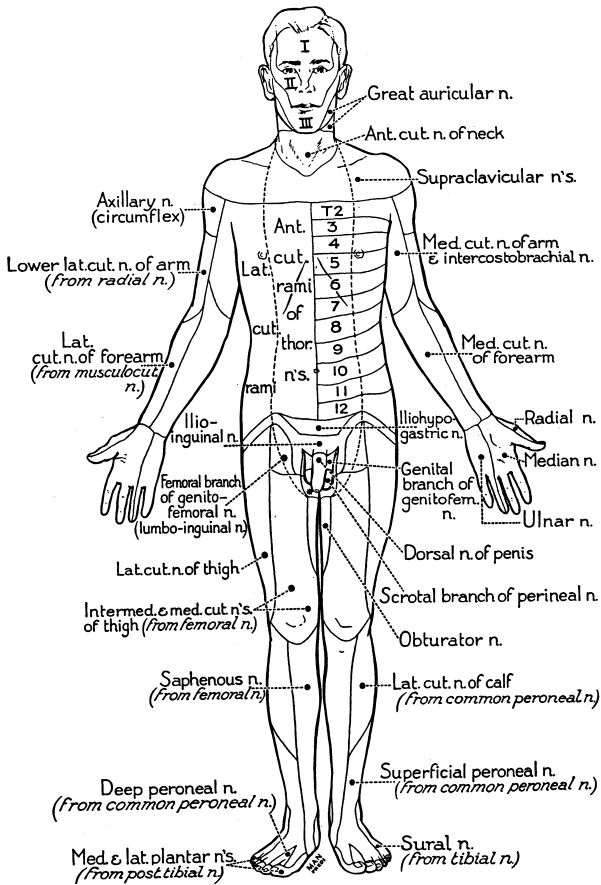
Adrian Wills

Cutaneous distribution of the nerves of the body



First of four views. The anterior cutaneous nerve of the neck has been renamed the transverse cutaneous nerve of the neck. The lower lateral cutaneous nerve of the arm is now recognized as part of the posterior cutaneous nerve of the forearm. Lumboinguinal nerve refers to the femoral branch of the genitofemoral nerve.

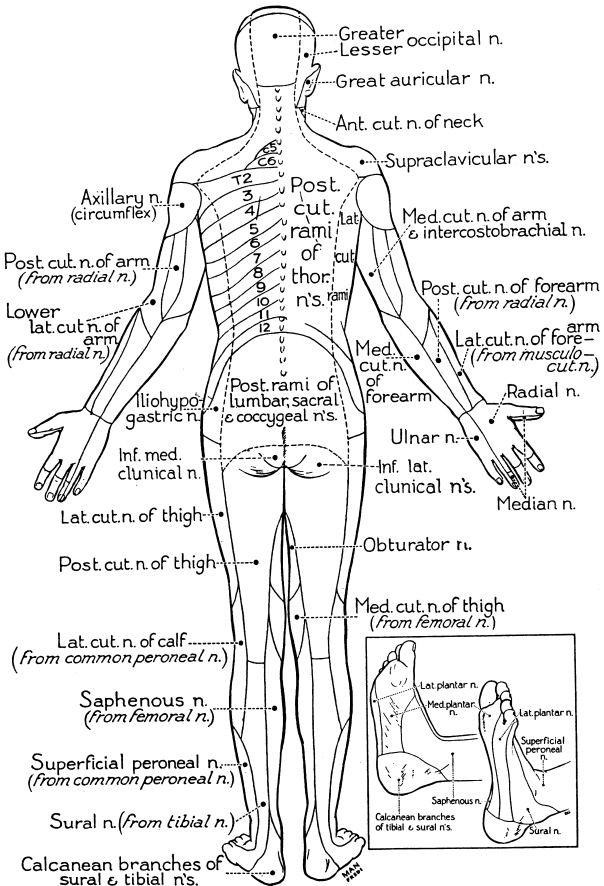
Reproduced with permission from Haymaker, W. and Woodhall, B. (1998). *Peripheral Nerve Injuries: Principles of Diagnosis*, 2nd edn. American Association of Neurological Surgeons.



Second of four views. See comment opposite regarding the lower lateral cutaneous nerve of the arm.

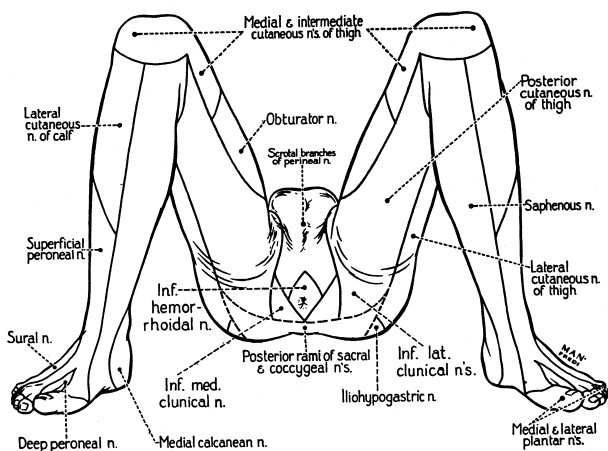
Reproduced with permission from Haymaker, W. and Woodhall, B. (1998). *Peripheral Nerve Injuries: Principles of Diagnosis*, 2nd edn. American Association of Neurological Surgeons.

Cutaneous distribution of the nerves of the body



Third of four views. The inferior lateral and inferior medial clunical nerves have been renamed *perineal branches of the posterior cutaneous of the thigh*. See comment in Fig. A4 legend regarding the lower lateral cutaneous nerve of the arm.

Reproduced with permission from Haymaker, W. and Woodhall, B. (1998). *Peripheral Nerve Injuries: Principles of Diagnosis*, 2nd edn. American Association of Neurological Surgeons.



Fourth of four views. The names of some nerves have been changed as follows: The clunical nerves (inferior lateral and inferior medial) are now termed the *perineal branches of the posterior cutaneous nerve of the thigh*; the inferior hemorrhoidal nerve is now called the *inferior rectal nerve*.

Reproduced with permission from Haymaker, W. and Woodhall, B. (1998). *Peripheral Nerve Injuries: Principles of Diagnosis*, 2nd edn. American Association of Neurological Surgeons.

OXFORD MEDICAL PUBLICATIONS

**Oxford Handbook of
Neurology**

Published and forthcoming Oxford Handbooks

Oxford Handbook of Clinical Medicine 6/e (also available for PDAs and in a Mini Edition)
Oxford Handbook of Clinical Specialties 7/e
Oxford Handbook of Acute Medicine 2/e
Oxford Handbook of Anaesthesia 2/e
Oxford Handbook of Applied Dental Sciences
Oxford Handbook of Cardiology
Oxford Handbook of Clinical Dentistry 4/e
Oxford Handbook of Clinical and Laboratory Investigation 2/e
Oxford Handbook of Clinical Diagnosis
Oxford Handbook of Clinical Haematology 2/e
Oxford Handbook of Clinical Immunology and Allergy 2/e
Oxford Handbook of Clinical Surgery 2/e
Oxford Handbook of Critical Care 2/e
Oxford Handbook of Dental Patient Care 2/e
Oxford Handbook of Dialysis 2/e
Oxford Handbook of Emergency Medicine
Oxford Handbook of Endocrinology and Diabetes
Oxford Handbook of ENT and Head and Neck Surgery
Oxford Handbook for the Foundation Programme
Oxford Handbook of Gastroenterology and Hepatology
Oxford Handbook of General Practice 2/e
Oxford Handbook of Genitourinary Medicine, HIV and AIDS
Oxford Handbook of Geriatric Medicine
Oxford Handbook of Medical Sciences
Oxford Handbook of Obstetrics and Gynaecology
Oxford Handbook of Oncology 2/e
Oxford Handbook of Ophthalmology
Oxford Handbook of Palliative Care
Oxford Handbook of Practical Drug Therapy
Oxford Handbook of Psychiatry
Oxford Handbook of Public Health Practice 2/e
Oxford Handbook of Rehabilitation Medicine
Oxford Handbook of Respiratory Medicine
Oxford Handbook of Rheumatology 2/e
Oxford Handbook of Tropical Medicine 2/e
Oxford Handbook of Urology

Oxford Handbook of Neurology

Hadi Manji

Consultant Neurologist and Honorary Senior Lecturer
National Hospital for Neurology and Neurosurgery
Queen Square, London; and Consultant Neurologist
Ipswich Hospital NHS Trust, UK

Seán Connolly

Consultant in Clinical Neurophysiology
St Vincent's University Hospital Dublin, Ireland

Neil Dorward

Consultant Neurosurgeon and Honorary Senior Lecturer
Royal Free Hospital London, UK

Neil Kitchen

Consultant Neurosurgeon, National Hospital for
Neurology and Neurosurgery, Queen Square, London, UK

Amrish Mehta

Consultant Neuroradiologist, Hammersmith Hospitals
NHS Trust, London, UK

Adrian Wills

Consultant Neurologist, Queen's Medical Centre,
Nottingham, UK

OXFORD
UNIVERSITY PRESS

OXFORD

UNIVERSITY PRESS

Great Clarendon Street, Oxford OX2 6DP

Oxford University Press is a department of the University of Oxford.
It furthers the University's objective of excellence in research, scholarship,
and education by publishing worldwide in

Oxford New York

Auckland Cape Town Dar es Salaam Hong Kong Karachi
Kuala Lumpur Madrid Melbourne Mexico City Nairobi
New Delhi Shanghai Taipei Toronto

With offices in

Argentina Austria Brazil Chile Czech Republic France Greece
Guatemala Hungary Italy Japan Poland Portugal Singapore
South Korea Switzerland Thailand Turkey Ukraine Vietnam

Oxford is a registered trade mark of Oxford University Press
in the UK and in certain other countries

Published in the United States
by Oxford University Press, Inc., New York

© Oxford University Press 2007

The moral rights of the authors have been asserted
Database right Oxford University Press (maker)

First published 2007

All rights reserved. No part of this publication may be reproduced,
stored in a retrieval system, or transmitted, in any form or by any means,
without the prior permission in writing of Oxford University Press,
or as expressly permitted by law, or under terms agreed with the appropriate
reprographics rights organization. Enquiries concerning reproduction
outside the scope of the above should be sent to the Rights Department,
Oxford University Press, at the address above

You must not circulate this book in any other binding or cover
and you must impose the same condition on any acquirer

British Library Cataloguing in Publication Data
Data available

Library of Congress Cataloging in Publication Data
Data available

Typeset by Newgen Imaging Systems (P) Ltd., Chennai, India
Printed in Italy
on acid-free paper by
LegoPrint S.p.A.

ISBN 0-19-850973-1 (flexicover: alk. paper) 978-0-19-850973-8 (flexicover: alk. paper)

10 9 8 7 6 5 4 3 2 1

Foreword

Pass any young doctor in the corridor of a busy general hospital and the chances are that person will be carrying an Oxford Handbook relevant to their current clinical attachment. Surprise any consultant reviewing notes from a recent clinic in the office and the same book may also be (more discreetly) close at hand. Previously, those dealing with the intricacies of clinical neurology were disadvantaged. Now, Hadi Manji, Seán Connolly, Neil Dorward, Neil Kitchen, Amrish Mehta, and Adrian Wills have put right this defect. The team offers expertise in clinical neurology, neurosurgery, neurophysiology, and neuroradiology. And, as consultants working in busy clinical neuroscience centres, each brings to his contribution the discipline of a classical approach to the neurological encounter together with pragmatism, much common sense, and a good deal of clinical experience.

This is not a book to read expecting the rich and discursive prose narratives of the eloquent clinical expositor; nor, equally, one in which to be ensnared by the weeds of descriptive reflexology or shackled by the competitive impedimenta of eponymous hagiography—although a useful appendix lists some names that have echoed through the corridors of neurological establishments down the ages. Rather, it is a book for both the specialist and generalist to consult when faced with the typical, but nonetheless complex, presentations of neurological and neurosurgical disorders; one from which to be reminded of how best to investigate and manage the many conditions—common and otherwise—that affect the central and peripheral nervous systems and muscle; and one that wisely sets out what to expect from laboratory investigations, and how these inform clinical formulations that remain the substance of clinical neurology. Bullet points, lists, and algorithms for diagnosis and management may not make for bedtime reading but they do provide an economic and invaluable synthesis for others of what needs to be known in order to manage diseases of the nervous system effectively. Having done this successfully for themselves on many occasions in the clinic and on the wards, the team of experts now passes on its experience and understanding of neurological and neurosurgical disease to a wider readership.

Do not look for copies of the *Oxford Handbook of Neurology* sitting undisturbed on dusty office shelves. This book will only be found alongside the many dog-eared and well-thumbed copies of its 35 companion volumes in the pockets and on the desktops of busy students of neurological disease.

Professor Alastair Compston
University of Cambridge
October 2006

Oxford University Press makes no representation, express or implied, that the drug dosages in this book are correct. Readers must therefore always check the product information and clinical procedures with the most up-to-date published product information and data sheets provided by the manufacturers and the most recent codes of conduct and safety regulations. The authors and the publishers do not accept responsibility or legal liability for any errors in the text or for the misuse or misapplication of material in this work.

Preface

General physicians have always found neurology difficult and perhaps intimidating. This is a reflection of inadequate training and perhaps perpetuated by the neurologists of a bygone era. Neurology still remains the most clinical of the medical subspecialties—investigative tools such as MRI and DNA analysis will never replace the basic neurological history-taking and examination, which when performed skilfully, is wonderful to watch. This is not some voodoo technique revealed to the chosen few but can be learnt from good role models and practise.

Even today, neurological training remains a clinical apprenticeship with hints and ‘clinical handles’ that are passed down from teacher to pupil and are not in the standard textbooks. In this book we have tried to pepper these in when appropriate. In keeping with the style of the Oxford Handbook series the format is necessarily didactic and hopefully clear for the reader when faced with a patient with neurological symptoms and signs.

Neurology and neurologists have had a reputation for ‘being elephantine in their diagnostic skills but murine in their therapeutic strategies’. This has changed with numerous treatment options now being available. Although neither dramatic in their benefit nor curative, options now exist for patients with multiple sclerosis, Alzheimer’s disease, motor neuron disease, Parkinson’s disease, and ischaemic stroke.

Our hope is that this book will go some way to smooth the neurological pathways for juniors in training and perhaps even some senior colleagues!

‘...few patients oblige with the symptoms it is their duty to have and not many refrain from complaining of those they ought not to have. When I tried to teach the art of medical diagnosis to students, I often used to ask them this riddle: “what runs about farm yards, flaps its wings, lays eggs and barks like a dog?” ...the answer is a hen! Usually one of the more earnest and innocent of the students would say: “but sir! I don’t understand the bit about barking like a dog”. Ah yes, I must explain.
That was just put in to make it difficult.’

[Richard Asher quoted in British Medical Association (1984).
A sense of Asher; a new miscellany. BMA, London.]

Hadi Manji
September 2006

This page intentionally left blank

Acknowledgements

Dr Mike Lunn and Dr Andrew Graham for reading the manuscript and making helpful suggestions; Dr Chris Hawkes for his help with 'Clinical Pearls'; Catherine Barnes and Elizabeth Reeve for their steadfast support and encouragement.

This page intentionally left blank

Contents

Symbols and abbreviations *xiii*

Detailed contents *xxv*

1	Neurological history and examination	1
2	Neuroanatomy	33
3	Common clinical presentations	55
4	Neurological disorders	103
5	Neurosurgery	315
6	Clinical neurophysiology	425
7	Neuroradiology	479
	Appendix 1: Neurological disability scales	507
	Appendix 2: Clinical pearls	511
	Appendix 3: Neurological eponyms	515
	Appendix 4: Useful websites	523

Index *525*

This page intentionally left blank

Symbols and abbreviations

≥	greater than or equal to
≤	less than or equal to
↓	decreased
↑	increased
AC	air conduction
ACE	angiotensin converting enzyme
ACh	acetylcholine
AChI	acetylcholinesterase inhibitor
AChR	acetylcholine receptor
ACom	anterior communicating artery
ACST	Asymptomatic Carotid Surgery Trial
AD	autosomal dominant
ADC	apparent diffusion coefficient (map)
ADCA	autosomal dominant cerebellar ataxia
ADEM	acute disseminated encephalomyelitis
ADL	activities of daily living
ADM	abductor digiti minimi (muscle)
A & E	accident and emergency (department)
AED	anti-epileptic drug
AF	atrial fibrillation
AHB	abductor hallucis brevis
AIC	anterior iliac crest
AIDP	acute inflammatory demyelinating polyneuropathy
AIDS	acquired immune deficiency syndrome
AION	anterior ischaemic optic neuropathy
ALL	anterior longitudinal ligament
ALS	amyotrophic lateral sclerosis
AMAN	acute motor axonal neuropathy
AMSAN	acute motor and sensory axonal neuropathy
ANA	antinuclear antibody
ANCA	anti-neutrophil cytoplasmic antibody

AP	anteroposterior
APB	abductor pollicis brevis (muscle)
ApoE	apolipoprotein E
APP	amyloid precursor protein
AR	autosomal recessive
ASA	anterior spinal artery
ASDH	acute subdural haematoma
ASO	ankle-stabilizing orthosis
ATLS	advanced trauma life support (protocol)
AV	arteriovenous
AVF	arteriovenous fistula
AVM	arteriovenous malformation
BAER	brainstem auditory evoked response
BBB	blood-brain barrier
BC	bone conduction
bd	twice a day
BE	bacterial endocarditis
BETS	benign epileptiform transients of sleep
BHCG	beta human chorionic gonadotrophin
BIH	benign intracranial hypertension
BMD	Becker muscular dystrophy
BMI	body mass index
BP	blood pressure
BPPV	benign paroxysmal positional vertigo
BSE	bovine spongiform encephalopathy
CADASIL	cerebral autosomal dominant arteriopathy with subcortical infarcts and leucoencephalopathy
CAN	chronic axonal neuropathy
c-ANCA	cytoplasmic anti-neutrophil cytoplasmic antibody
CB	conduction block
CBD	corticobasal degeneration
CCA	common carotid artery
CCF	carotid cavernous fistula
CE	contrast-enhanced (MRI)
CEA	carcinoembryonic antigen
CEO	chronic external ophthalmoplegia
CH	cluster headache
CIDP	chronic inflammatory demyelinating polyneuropathy

CJD	Creutzfeldt–Jakob disease
CK	creatine kinase
CMAP	compound muscle action potential
CMT	Charcot–Marie–Tooth disease
CMV	cytomegalovirus
CNE	concentric needle electrode
CNS	central nervous system
COC	combined oral contraceptive
COMT	catechol-O-methyltransferase
COX	cyclo-oxygenase
CPA	cerebellopontine angle
CPAP	continuous positive airway pressure
CPEO	chronic progressive external ophthalmoplegia
CPK	creatine phosphokinase
CPP	cerebral perfusion pressure
CR	controlled-release
CSF	cerebrospinal fluid
CT	computerized tomography
CTA	computerized tomography angiography
CV	conduction velocity
CVS	cardiovascular system
Cx	cervical (spine)
CXR	chest X-ray
DA	dopamine
DAI	diffuse axonal injury
DaT	dopamine transporter
dAVF	dural arteriovenous fistula
DCLB	dementia with cortical Lewy bodies
ddC	2', 3'-dideoxycytidine
ddl	2', 3'-dideoxyinosine
DHE	dihydroergotamine
DIC	disseminated intravascular coagulation
DILS	diffuse inflammatory lymphocytosis syndrome
DIO	dorsal interosseous (muscle)
DIP	distal interphalangeal
DLB	dementia with Lewy bodies
DM	diabetes mellitus or dermatomyositis

DMD	Duchenne muscular dystrophy
DML	distal motor latency
DMT	disease-modifying treatment
DNET	dysembryoplastic neuroepithelial tumour
DRD	dopa-responsive dystonia
DRPLA	dentatorubral pallidoluysian atrophy
DSA	digital subtraction angiography
d4T	2', 3'-dideohydro-3'-deoxythymidine
DVA	developmental venous anomaly
DVLA	Driver and Vehicle Licensing Agency
DVT	deep vein thrombosis
DWI	diffusion-weighted image
DXT	deep X-ray therapy
EA	episodic ataxia (EA1, EA2)
EAM	external auditory meatus
EBV	Epstein–Barr virus
ECG	electrocardiogram
ECT	electroconvulsive therapy
EDB	extensor digitorum brevis (muscle)
EDH	extradural haematoma
EEG	electroencephalogram
EHL	extensor hallucis longus (muscle)
EMG	electromyography
ENA	extractable nuclear antigen
EOM	eye movement channel (in EEG)
EP	evoked potential
EPC	epilepsia partialis continua
EPP	end plate potential
ERG	electroretinography
ESR	erythrocyte sedimentation rate
ET	essential tremor
EVD	extraventricular drain
FBC	full blood count
FEV1	forced expiratory volume in 1 second
FDG	fluorine-18 labelled deoxyglucose
FDP	flexor digitorum profundus
FDS	flexor digitorum superficialis

FH	family history
FLAIR	fluid attenuated inversion recovery (MRI)
FLARE	fast low-angle recalled echoes (MRI)
FM	foramen magnum
fMRI	functional magnetic resonance imaging
FP-CIT	fluoropropyl-2 β -carbomethoxy-3 β -(4-[125I]-iodophenyl)tropane
FSH	facioscapulohumeral (dystrophy)
FTD	frontotemporal dementia
FVC	forced vital capacity
GAD	glutamic acid decarboxylase
GBS	Guillain–Barré syndrome
GCS	Glasgow Coma Scale
Gd	gadolinium
GE	gradient echo
GEN	gaze-evoked nystagmus
GI	gastrointestinal
GP	general practitioner
GPI	globus pallidus internus
GSS	Gerstmann–Straussler–Scheinker (syndrome)
GT	glutamyl transferase
GTN	glyceryl trinitrate
GTP	guanosine triphosphate
GTT	glucose tolerance test
HAART	highly active retroviral therapy
HAD	HIV-associated dementia
Hb	haemoglobin
HD	Huntington's disease
HDL	high density lipoprotein
HDU	high-dependency unit
HHV6	human herpesvirus 6
HI	head injury
HIV	human immunodeficiency virus
HLA	human leucocyte antigen (system)
HNPP	hereditary neuropathy with liability to pressure palsies
HMSN	hereditary motor and sensory neuropathy
HOCM	hypertrophic obstructive cardiomyopathy
HRT	hormone replacement therapy

HSAN	hereditary sensory and autonomic neuropathy
HSE	herpes simplex encephalitis
HSN	hereditary sensory neuropathy
HSV	herpes simplex virus
5-HT	5-hydroxytryptamine
HTLV-I	human T-cell lymphocytotropic virus type I
hyperKPP	hyperkalaemic periodic paralysis
hypoKPP	hypokalaemic periodic paralysis
IAC	internal auditory canal
IBM	inclusion body myositis
ICA	internal carotid artery
ICH	intracerebral haemorrhage
ICP	intracranial pressure
ICU	intensive care unit
Ig	immunoglobulin (IgA, IgM, etc.)
IHD	ischaemic heart disease
IHS	International Headache Society
IIH	idiopathic intracranial hypertension
IM	intramuscular
INO	internuclear ophthalmoplegia
INR	international normalized ratio
IO	inferior oblique (muscle)
IP	interphalangeal (joint)
IPD	idiopathic Parkinson's disease
IPNV	isolated peripheral nerve vasculitis
IQ	intelligence quotient
IR	inferior rectus (muscle)
ISH	idiopathic stabbing headache
ITU	intensive therapy unit
IV	intravenous
IVDU	intravenous drug user
JME	juvenile myoclonic epilepsy
KSS	Kearns–Sayre syndrome
LA	local anaesthetic
LDL	low density lipoprotein
LEMS	Lambert–Eaton myasthenic syndrome
LFT	liver function test

LGMD	limb–girdle muscular dystrophy (LGMD1A, LGMD1B, etc.)
LHON	Leber’s hereditary optic neuropathy
LMN	lower motor neuron
LOC	loss of consciousness
LP	lumbar puncture
LR	lateral rectus (muscle)
LVF	left ventricular failure
MAG	myelin-associated glycoprotein
MAOI	monoamine oxidase inhibitors
MCA	middle cerebral artery
MCV	mean corpuscular volume or motor conduction velocity
MD	myotonic dystrophy
MELAS	mitochondrial encephalopathy with lactic acidosis and stroke-like episodes
MERRF	mitochondrial epilepsy with ragged red fibres
MG	myasthenia gravis
MGUS	monoclonal gammopathy of unknown significance
MI	myocardial infarction or myoinositol
min	minute/s
MIP	maximum intensity projection (MRI)
MMN	multifocal motor neuropathy
MMNCB	multifocal motor neuropathy with conduction block
MMSE	mini-mental state examination
MND	motor neuron disease
MNGIE	mitochondrial myopathy–neuropathy–GI dysmotility–encephalopathy
MP	metacarpophalangeal (joint)
MPR	multiplanar reformation (CT)
MPTP	1-methyl-4-phenyl-1,2,3,6-tetrahydropyridine
MR	medial rectus (muscle) or magnetic resonance
MRA	magnetic resonance angiography
MRI	magnetic resonance imaging
MRS	magnetic resonance spectroscopy
MRSA	methicillin-resistant <i>Staphylococcus aureus</i>
MRV	magnetic resonance venography
MS	multiple sclerosis
MSA	multiple system atrophy
MSA-C	multiple system atrophy, olivo-ponto-cerebellar variant

MSA-P	multiple system atrophy, parkinsonian variant
MSLT	multiple sleep latency test
MSU	midstream urine
MUAC	motor-unit action potential
MUP	motor unit potential
MuSK	muscle-specific kinase
NAA	N-acetyl aspartate
NAP	nerve action potential
NARP	neuropathy–ataxia–retinitis pigmentosa
NBCA	N-butyl-cyanoacrylate (glue)
NCS	nerve conduction studies
NCT	non-contrast computerized tomography
NEAD	non-epileptic attack disorder
neuro obs	neurological observations
NF	neurofibromatosis (NF1, NF2)
NG	nasogastric (tube)
NINDS	National Institute of Neurological Disorders and Stroke (USA)
NIV	non-invasive ventilation
NMDA	N-methyl-D-aspartate
NMJ	neuromuscular junction
NMO	neuromyelitis optica
NPH	normal pressure hydrocephalus
NSAID	nonsteroidal anti-inflammatory drug
NTD	neural tube defect
O ₂ sat.	oxygen saturation
OCB	oligoclonal band
od	once a day
ON	optic neuritis
OP	opening pressure
OPCA	olivopontocerebellar atrophy
OSAHS	obstructive sleep apnoea/hypopnoea syndrome
OT	occupational therapist
PaCO ₂	arterial carbon dioxide tension
p-ANCA	perinuclear anti-neutrophil cytoplasmic antibody
PANK	pantothenate kinase
PaO ₂	arterial oxygen tension
PC	phase contrast

PCNSL	primary CNS lymphoma
PCO ₂	carbon dioxide tension
Pcom	posterior communicating (artery)
PCR	polymerase chain reaction
PD	Parkinson's disease or proton density
PE	pulmonary embolism or plasma exchange
PEG	percutaneous endoscopic gastrostomy
PET	positron emission tomography
PICA	posterior inferior cerebellar artery
PIPJ	proximal interphalangeal joint
PK	protein kinase
PLD	peripheral labyrinthine disorder
PLEDS	periodic lateralizing epileptiform discharges
PLL	posterior longitudinal ligament
PM	polymyositis
PMA	progressive muscular atrophy
PMH	past medical history
PML	progressive multifocal leucoencephalopathy
PNET	primitive neuroectodermal tumours
PNS	peripheral nervous system
PO	orally, by mouth
PO ₂	oxygen tension
POEMS	polyneuropathy–organomegaly–endocrinopathy– monoclonal gammopathy–skin changes
POP	progestogen only pill
PPMS	primary progressive multiple sclerosis
PPRF	paramedian pontine reticular formation
PR	per rectum (via the rectum)
PROGRESS	Perindopril Protection Against Recurrent Stroke Study
PROMM	proximal myotonic myopathy
PrP	prion protein
PSA	prostate-specific antigen
PSP	progressive supranuclear palsy
PV	per vagina (via the vagina)
PWI	perfusion-weighted imaging (MRI)
qds	four times a day
RAPD	relative afferent pupillary defect
RAS	reticular activating system

RBC	red blood cell
RBD	REM sleep behaviour disorder
RCT	randomized controlled trial
REM	rapid eye movement (sleep)
RIG	radiologically inserted gastrostomy
RNS	repetitive nerve stimulation
RR	relative risk or respiratory rate
RRMS	relapsing/remitting multiple sclerosis
RTA	road traffic accident
rt-PA	recombinant tissue plasminogen activator
RX	treatment
SA	sinoatrial (node)
SAD	seasonal affective disorder
SAH	subarachnoid haemorrhage
SALT	speech and language therapist
SaO ₂	arterial oxygen saturation
SC	subcutaneous
SCA	spinocerebellar ataxia
SCLC	small cell lung cancer
SCM	sternocleidomastoid (muscle)
SCV	sensory conduction velocity
SDH	subdural haematoma
SE	spin echo
SERMS	selective (o)estrogen receptor modulator
SFEMG	single fibre electromyography
SIADH	syndrome of inappropriate antidiuretic hormone
SjvO ₂	jugular venous oxygen saturation
SLE	systemic lupus erythematosus
SMA	spinal muscular atrophy
SN	substantia nigra
SNAP	sensory nerve action potential
SO	superior oblique (muscle)
SOD1	superoxide dismutase 1
SOMI	sterno-occipito-mandibular immobilizer (brace)
SPECT	single photon emission computerized tomography
SPMS	secondary progressive multiple sclerosis
SR	superior rectus (muscle) or slow-release

SSEP	somatosensory evoked potential
SSPE	subacute sclerosing panencephalitis
SSRI	selective serotonin reuptake inhibitor
SSPE	subacute sclerosing panencephalitis
STICH	Surgical Trial in Intracerebral Haemorrhage
STN	subthalamic nucleus
SUDEP	sudden unexpected death in epilepsy
SUNCT	short-lasting unilateral neuralgiform headache with conjunctival injection and tearing
SWJ	square wave jerk
SXR	skull X-ray
T4	thyroxine
TB	tuberculosis
T/C	tonic–clonic (seizure)
TCA	tricyclic antidepressant
tds	three times a day
TG	trigeminal
TIA	transient ischaemic attack
tid	three times a day
TLE	temporal lobe epilepsy
TM	tympanic membrane
TMJ	temporomandibular joint
TOE	transoesophageal echocardiogram
TOF	time of flight (in MRI)
TPHA	<i>Treponema pallidum</i> haemagglutination assay (syphilis)
TPMT	thiopurine methyltransferase
TVO	transient visual obscuration
T1W	T1-weighted (MRI)
T2W	T2-weighted (MRI)
U & E	urea and electrolytes
UMN	upper motor neuron
UPDRS	unified Parkinson's disease rating scale
UPSIT	University of Pennsylvania smell identification test
URTI	upper respiratory tract infection
USS	ultrasound scan
UTI	urinary tract infection
UV	ultraviolet
VA	visual acuity or ventriculo-atrial

VC	vital capacity
vCJD	variant CJD
VDRL	Venereal Disease Research Laboratory (test for syphilis)
VEP	visual evoked potential
VER	visual evoked response
VHL	Von Hippel–Lindau disease
VIM	ventral intermediate (thalamic nucleus)
VLCFA	very-long-chain fatty acid
VLDL	very low density lipoprotein
VMA	vanillylmandelic acid
VP	ventricular peritoneal
VZV	varicella zoster virus
WBC	white blood cell
WCC	white cell count
WFNS	World Federation of Neurological Surgeons
XL	extended release (drug)

Detailed contents

Symbols and abbreviations *xiii*

1 Neurological history and examination	1
Principles of neurological history taking	2
The general examination	4
Cranial nerve 1 (olfactory nerve)	6
Cranial nerve 2 (optic nerve and visual pathway)	8
Cranial nerves 3 (oculomotor), 4 (trochlear), and 6 (abducens)	12
Cranial nerves 5 and 7–12	16
Examination of the upper and lower limbs	18
Bedside cognitive testing, including language	24
The mini-mental state examination (MMSE)	30
<hr/>	
2 Neuroanatomy	33
The cranial cavity	34
Dermatomes of the upper and lower limbs	36
Innervation of the upper limbs	38
Innervation of the lower limbs	46
Cross-sections of the brain and spinal cord	52
<hr/>	
3 Common clinical presentations	55
Loss of consciousness	56
Acute vertigo	58
Acute headache (thunderclap headache)	62
Acute neuromuscular weakness	64

Acute focal neurological syndromes	68
Spastic paraparesis	70
Ataxia	72
Acute visual failure	76
Coma	80
Coma prognosis	84
Excessive daytime sleepiness	86
Tremor	90
Tics	94
Chorea and athetosis	96
Myoclonus	98
Dystonia	100

4 Neurological disorders **103**

Cerebrovascular disease: stroke	104
Management of stroke	108
Prevention of ischaemic stroke	110
Cerebral venous thrombosis	112
Images in cerebrovascular disease	114
Dementia: introduction	124
Alzheimer's disease	126
Frontotemporal dementia	128
Other dementias	130
Creutzfeldt–Jakob disease (CJD)	132
Epilepsy: introduction	136
Management of epilepsy	138
Women and epilepsy	142
Seizures versus dissociative non-epileptic attack disorder (NEAD) or pseudoseizures	144
Management of status epilepticus	146

- Headache: migraine—introduction and clinical features 148
- Migraine: differential diagnosis, investigations, and IHS criteria 150
- Management of acute migraine: the stepped care regimen 152
- Management of migraine prophylaxis 154
- Migraine and women 156
- Primary short-lasting headaches 160
- Cluster headache 162
- Trigeminal neuralgia 164
- Idiopathic intracranial hypertension (IIH) 166
- Parkinsonism and Parkinson's disease (PD):
introduction 170
- Clinical features of parkinsonism and PD 172
- Differential diagnosis of PD and investigation 174
- Drug-induced parkinsonism 178
- Medical management of PD 180
- Surgical treatment of PD 184
- Management of other problems in PD 186
- Multiple system atrophy (MSA) 188
- Progressive supranuclear palsy (PSP) 190
- Corticobasal degeneration (CBD) 192
- Peripheral nerve disorders: introduction and clinical approach 194
- Diagnosis of peripheral nerve disorders 196
- Investigations in peripheral nerve disorders 198
- Diabetic neuropathies 200
- Guillain-Barré syndrome (GBS) 202
- Chronic inflammatory demyelinating polyneuropathy (CIDP) 206
- Multifocal motor neuropathy with conduction block (MMN-CB) 210

- Vasculitic neuropathy 212
- Muscle disorders: classification and features 214
- Muscle disorders: investigations 216
- Dermatomyositis, polymyositis, and inclusion body myositis 220
- Motor neuron disease: introductions and clinical features 224
- Motor neuron disease: investigations and management 226
- Multiple sclerosis: introduction and clinical features 228
- Multiple sclerosis: investigations and diagnosis 230
- Multiple sclerosis: management 236
- Myasthenia gravis: introduction, clinical features, and investigations 238
- Myasthenia gravis: management 240
- Paraneoplastic disorders: introduction 244
- Paraneoplastic syndromes: central nervous system 246
- Paraneoplastic syndromes: peripheral nervous system 250
- Paraneoplastic syndromes: investigations and management 252
- Vertigo, dizziness, and unsteadiness: introduction 254
- Dizziness, unsteadiness, or 'off balance': neurological causes 256
- Benign paroxysmal positional vertigo (BPPV) 258
- Dizziness, unsteadiness, or 'off balance': non-neurological causes 262
- Neurogenetic disorders: introduction 264
- Hereditary ataxias 266
- Genetic neuropathies 268
- Inherited myopathies 272
- Myotonic dystrophy (MD) 276

Inherited movement disorders	278
Inherited mitochondrial disorders	280
Inherited dementias	282
Inherited neurocutaneous syndromes	284
Hereditary metabolic diseases	286
Infectious disease: bacterial meningitis	288
Viral encephalitis	292
Neurology of HIV/AIDS: introduction	296
Neurological disorders due to HIV	298
Opportunistic infections associated with HIV	300
MRI images in infectious diseases	304
Lumbar puncture	308
Intravenous immunoglobulin (IV Ig)	312
Diagnosis of brainstem death	314

5 Neurosurgery

315

Subarachnoid haemorrhage (SAH)	316
Imaging of SAH: examples	320
Spontaneous intracranial haemorrhage (ICH)	328
Imaging of ICH: examples	330
Cerebral aneurysms	334
Cerebral arteriovenous malformations (AVM)	338
Cavernous haemangioma (cavernoma) and developmental venous anomaly (DVA)	340
Dural arteriovenous fistulae (dAVF)	342
Hydrocephalus	344
Complications of shunts	348
Intracranial tumours	350
Intracranial tumours: management of specific tumours	354
Imaging of intracranial tumours: examples	360

Imaging of spinal tumours: examples	372
Head injuries (HI)	376
Management of specific head injuries	380
Imaging of head injuries: examples	386
Spinal injuries	392
Imaging spinal injuries: examples	396
Degenerative spinal conditions: cervical spine	402
Degenerative spinal conditions: thoracic and lumbar spine	406
Imaging of degenerative spinal conditions: examples	410
Developmental abnormalities	414
Imaging of developmental abnormalities: examples	418
Syringomyelia	422

6 Clinical neurophysiology	425
Introduction	426
Electroencephalography (EEG): introduction	428
EEG: use and abuse	430
EEG: abnormal rhythms	432
EEG and epilepsy	436
EEG and diffuse cerebral dysfunction	440
EEG in the intensive care unit	444
Technical summary of nerve conduction studies (NCS)	446
Peripheral nerve disorders: NCS abnormalities	450
Technical summary of needle electromyography (EMG)	452
Needle EMG: patterns of abnormality	454
NCS and needle EMG findings in myopathies and motor axonal loss	460

NCS and needle EMG findings in Guillain–Barré syndrome	462
NCS and needle EMG findings in neuromuscular transmission disorders	464
Visual evoked responses (VERs)	468
Somatosensory evoked potentials (SSEPs)	470
Brainstem auditory evoked responses (BAERs)	474
Normal values in clinical neurophysiology	476

7 Neuroradiology **479**

Techniques in diagnostic radiology	480
Cerebrovascular disease	486
Subarachnoid haemorrhage	490
Intracerebral haemorrhage	492
Guidelines for head injury	494
Imaging strategies for cervical spine trauma	496
Guidelines for the neuroradiology of tumours	498
CNS infections	500

Appendices **505**

1 Neurological disability scales	507
2 Clinical pearls	511
3 Neurological eponyms	515
4 Useful websites	523

Index	525
-------	-----

This page intentionally left blank

Neurological history and examination

- Principles of neurological history taking 2
- The general examination 4
- Cranial nerve 1 (olfactory nerve) 6
- Cranial nerve 2 (optic nerve and visual pathway) 8
- Cranial nerves 3 (oculomotor), 4 (trochlear),
and 6 (abducens) 12
- Cranial nerves 5 and 7–12 16
- Examination of the upper and lower limbs 18
- Bedside cognitive testing, including language 24
- The mini-mental state examination (MMSE) 30

Principles of neurological history taking

‘The primary role of the examination becomes the testing of the hypotheses derived from the history’

(William Landau)

The usual approach to a clinical problem is to ask the following:

- Where is the lesion, e.g. brain, spinal cord, anterior horn cell, peripheral nerve, neuromuscular junction, muscle?
- What is the aetiology, e.g. vascular, degenerative, toxic, infective, genetic, inflammatory, neoplastic, functional?
- What is the differential diagnosis?
- Is treatment possible?
- What is the prognosis?

A detailed history usually will yield more information than the neurological examination and ancillary tests.

- Family members and eyewitness accounts are essential, e.g. in patients with dementia and blackouts. Obtain a history by telephone if necessary.
- A review of the case notes if available is very useful.
- Analysis of symptoms will follow a similar plan:
 - date/week/month/year of onset;
 - character and severity;
 - location and radiation;
 - time course;
 - associated symptoms;
 - aggravating and alleviating factors;
 - previous treatments;
 - remissions and relapses.

Past medical history

Do not always accept the patient's diagnostic terms—enquire into specific symptoms, e.g. ‘migraine’, ‘seizure’, ‘stroke’.

Family history

Draw a family tree. Document specific illnesses and cause of death if known. In certain communities enquire about consanguinity.

Social history

This should include:

- alcohol;
- smoking;
- recreational drug use;
- risk factors for HIV;
- detailed travel history;
- dietary habits.

This page intentionally left blank

The general examination

This starts on first meeting the patient—it is useful practice to collect patients from the waiting room.

- Assess gait—broad-based, unsteady, reduced arm swing on one side?
- Look for tremor—may only be evident when walking.
- Look for loss of facial expression.
- Assess speech—dysarthria

General examination is essential: ideally all patients should be stripped to the underclothes.

- Cardiovascular system. Pulse, heart sounds, blood pressure (lying down and standing after 3 minutes if any suggestion of autonomic involvement).
- Respiratory system. Diaphragmatic movement. May need to measure forced vital capacity (FVC) not FEV₁ in, e.g. GBS, MG.
- Gastrointestinal system. Palpate for hepatosplenomegaly or abdominal masses.
- Genitalia. In men testicular examination should be considered. PR examination if malignancy suspected or assessment of anal tone and sensation if cord or cauda equina compression in differential diagnosis.
- Breasts. Essential if neoplastic or paraneoplastic conditions are considered.
- Examine the spine—hairy patch may indicate underlying spinal disorder or a dermal sinus. Auscultation over spine may reveal the bruit of a dural AVM.
- Skin—melanoma. Vitiligo indicating underlying autoimmune disorder, e.g. MG.
- Head. Remember to palpate the temporal arteries in elderly headache patients; auscultation may reveal a bruit. Palpate the trapezii for evidence of tenderness in muscle tension and cervicogenic headache.

This page intentionally left blank

Cranial nerve 1 (olfactory nerve)

- Patients may not recognize a problem unless it is essential for work or hobbies, e.g. chef. Therefore question specifically.
- History may indicate local nasal or sinus disease, preceding URTI or head injury.
- Nose is supplied by the olfactory and trigeminal nerves. Irritants like NH_3 stimulate the trigeminal nerve and may be misleading.
- Use the University of Pennsylvania Smell Identification Test (UPSIT) if available. Otherwise use bedside products, e.g. orange peel, coffee, chocolate. Ask if there is a smell (perception, peripheral process) and then identify it (cognitive, central process).
- Anosmia commonly occurs after viral infections and head injury.
- In idiopathic Parkinson's disease (80%) and Alzheimer's disease, loss of sense of smell may be an additional early feature.
- Other causes of anosmia:
 - Refsum's disease;
 - olfactory groove meningioma;
 - superficial siderosis;
 - Kallman's syndrome (anosmia + hypogonadism, X-linked recessive);
 - paraneoplastic disorders.

This page intentionally left blank

Cranial nerve 2 (optic nerve and visual pathway)

Visual acuity (VA)

- Distance VA of each eye is tested with the Snellen chart. This compares what a normal person can see at 6 m. Below the age of 40 years most should see better than 6/6. In older patients VA < 6/9 needs explanation.
- Correction for refractive errors with glasses or using a pinhole.
- Near VA assessed with Jaeger reading charts.
- In papilloedema VA preserved unless chronic. In optic neuritis or infiltration VA impaired.
- Colour vision tested with Ishihara colour plates.

Visual field

- Visual field is assessed by confrontation with each eye in turn using a red pin (5 mm red target). Finger waving is too crude.
- Goldmann perimeter is a bowl-shaped device and uses small light targets (kinetic).
- Humphrey is an automated technique (static).
- Visual inattention indicates parietal lobe dysfunction.
- Uncooperative or aphasic patients—observe reaction to menace.

Visual field defects

- Monocular field defect: ocular, retinal, or optic nerve disorders.
- Constricted fields—glaucoma, chronic papilloedema.
- Tunnel vision—retinitis pigmentosa.
- Tubular vision—non-organic.
- Central scotoma—optic nerve or macular disease.
- Altitudinal defects are due to retinal vascular lesions as no vessels cross the horizontal raphe.

Defects affecting both eyes may indicate a lesion of or behind the optic chiasm (vertical meridian). The common patterns of field loss are shown in Table 1.1. Fig. 1.1 shows a diagram of visual field defects.

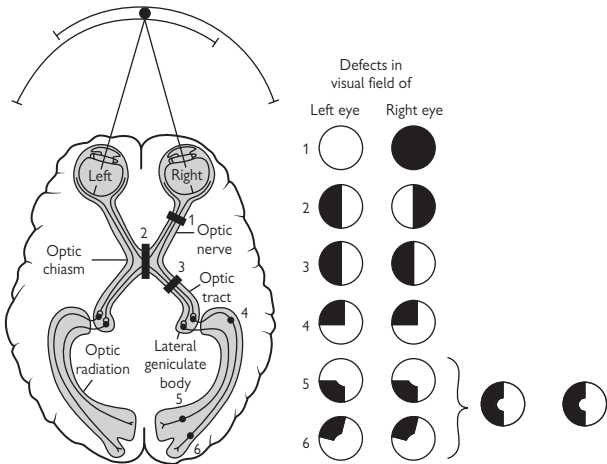


Fig. 1.1 Diagram of visual field defects. 1. Unilateral blindness, 2. Bitemporal hemianopia, 3. Homonymous hemianopia, 4. Superior quadrantanopia; 5, 6. Inferior and superior quadrantanopias with macular sparing. Permission requested from Brown University, Rhode Island, USA.

Table 1.1 Common patterns of visual field loss.

Field defect	Site of lesion(s)	Aetiology
Homonymous hemianopia	Optic tract, optic radiation, occipital lobe	Stroke, tumour
Superior quadrantanopia	Temporal lobe	Stroke, tumour
Inferior quadrantanopia	Parietal lobe	Stroke, tumour
Bitemporal hemianopia	Optic chiasm	Pituitary adenoma, craniopharyngioma
Binasal hemianopia	Perichiasm	Bilateral internal carotid artery aneurysms
Junctional scotoma	Junction of optic nerve and chiasm	Tumour
Bilateral scotomas	Occipital pole	Head injury

Clinical points

- Complete homonymous hemianopia indicates only that the lesion is behind the optic chiasm. The more posterior the lesion, the more congruous the defect.
- Macular sparing occurs because the middle cerebral artery supplies the occipital pole and the posterior cerebral artery the rest of the lobe.
- Junctional lesions between the optic nerve and chiasm affect ipsilateral optic nerve fibres and fibres from the inferior nasal retina of the opposite optic nerve as they loop after decussation.

Pupillary reactions

- Test reaction to light: direct and consensual with a bright pen torch; ophthalmoscope light not strong enough.
- Accommodation reflex is observed by watching the pupil as gaze is shifted from a distant object to a near object.
- Marcus–Gunn pupil (afferent pupillary defect) results from optic nerve dysfunction or, if extensive, retinal disease. Detected by the ‘swinging torch test’—a bright light is quickly moved back and forth between the eyes. The affected eye dilates rather than constricts when the light is swung to it because less light is perceived by the damaged pathway.

Fundoscopy with the direct ophthalmoscope

- confirm the red reflex and assess the clarity of the media;
- assess disc colour for pallor.

Fundoscopy findings

- Pigmented temporal crescent seen in myopes.
- 80% of normal discs will have venous pulsation. May be elicited by gentle eyeball pressure.
- Papilloedema
 - hyperaemia of disc margin;
 - blurring of margins;
 - raised optic disc;
 - engorged veins;
 - haemorrhages;
 - cotton wool spots and exudates;
 - retinal folds.
- Retinal abnormalities;
 - hard and soft exudates;
 - microaneurysms and new vessel formation;
 - pigmentary changes (bone spicules in retinitis pigmentosa);
- macular changes (star, cherry red spot).
- Drusen or hyaline bodies are shiny bodies on the surface, near or buried in the disc elevating it and resembling papilloedema.
- Medullated nerve fibre layer (pearly white) is myelin from the optic nerve that continues into the nerve fibre layer. May be confused with papilloedema.

Table 1.2 Pupillary abnormalities

Abnormality	Pupils	Other features	Tests
3rd nerve palsy	Dilated; no response to light or accommodation	Weakness: MR, IO, IR, SR. Ptosis (complete/partial)	—
Horner's syndrome (meiosis, ptosis, enophthalmos, anhidrosis)	Constricted pupil; reacts to light and accommodation	Partial ptosis, also upside-down ptosis (lower lid elevation), anhidrosis, enophthalmos	10% cocaine dilates normal pupil but not sympathetic denervated one. 1% hydroxyamphetamine dilates pupil in first or second order neuron damage.
Argyll Robertson pupil	Small, horizontally elongated pupil. Response to accommodation but not to light	Syphilis, diabetes	—
Tonic pupil (Adie). Usually unilateral	Dilated pupil constricts slowly to accommodation. Unreactive to light but will constrict on prolonged and intense illumination. Vermiform movements visible on slit lamp	Generalized areflexia = Holmes-Adie syndrome	0.125% pilocarpine constricts pupil

Cranial nerves 3 (oculomotor), 4 (trochlear), and 6 (abducens)

Figure 1.2 shows the muscles innervated by cranial nerves 3, 4, and 6.

Extra-ocular eye movements

- Monocular diplopia due to refractive error, cataract, media opacity, macular disease, visual cortex disorder (bilateral) or functional.
- Horizontal diplopia is due to weakness of medial or lateral rectus.
- Oblique separation with one image slightly tilted is due to superior or inferior oblique weakness.
- Images are maximally separated when direction of gaze is towards the site of maximal action of the paretic muscle.
- The outer image comes from the paretic eye.

Eye movements: pursuit and saccadic

- Fixation—observe the fixed eye for 30 seconds: horizontal square wave jerks (SWJ) seen in cerebellar disease, PSP, and MSA.
- Saccades (rapid conjugate eye movements) tested by asking the patient to fixate between two targets (fist right hand and fingers left hand).
 - Observe for speed of initiation (latency).
 - Saccadic velocity.
 - Accuracy. (Undershoot = hypometria found in cerebellar disorders, PD and HD. Overshoot = hypermetria caused by cerebellar dysfunction.)
 - Helps detect subtle internuclear ophthalmoplegia (INO)—lesion of medial longitudinal fasciculus. In a partial lesion, slowing of adduction ipsilateral to the lesion and nystagmus in contralateral abducting eye. In complete lesion adduction absent. Causes: demyelination or vascular.

See Fig. 1.3.

- Smooth pursuit. Test horizontal and vertical movements by tracking a target keeping the head still. Broken pursuit non-specific sign due to cerebellar disease, drugs, e.g. anticonvulsants and sedatives. If only in one direction indicates posterior cortical lesion ipsilateral to the direction of broken pursuit.

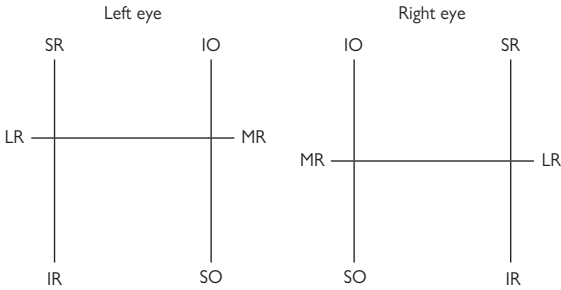


Fig. 1.2 Diagram showing muscles innervated by cranial nerves 3, 4, and 6. Cranial nerve 3: medial rectus (MR); inferior oblique (IO); superior rectus (SR); inferior rectus (IR). Cranial nerve 4: superior oblique (SO). Cranial nerve 6: lateral rectus (LR).

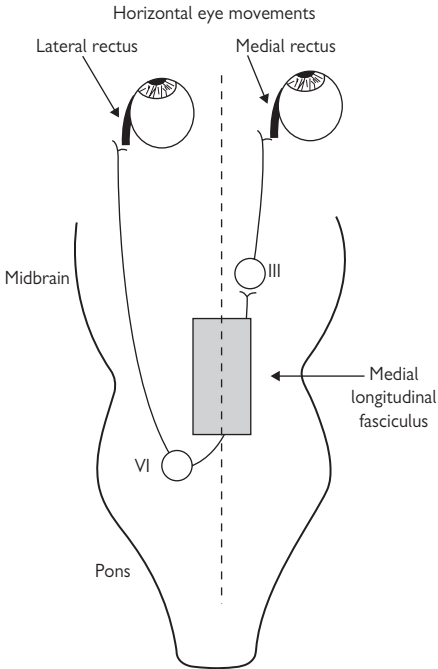


Fig. 1.3 Horizontal eye movements

Nystagmus

- Involuntary oscillation is initiated by a slow drift of the eye. If followed by a corrective fast phase = jerk nystagmus; if both phases have equal velocity = pendular nystagmus. Direction of nystagmus described by fast phase.
- Jerk nystagmus due to vestibular damage—peripheral (labyrinth, vestibular nerve) or central (brainstem). See Table 1.3.

Other types of jerk nystagmus (central vestibular)

- Downbeat nystagmus:
 - present in the primary position;
 - accentuated on lateral gaze;
 - due to disturbance of vestibulocerebellum caused by Arnold–Chiari malformation, cerebellar degeneration, drug toxicity, e.g. lithium.
- Upbeat nystagmus:
 - present in primary position;
 - due to lesion in the tegmental grey matter of brainstem;
 - causes: MS, vascular, cerebellar degeneration.
- Gaze-evoked nystagmus (GEN):
 - only present on eccentric gaze not primary position;
 - may be horizontal, upbeating on upgaze and or down beating on downgaze;
 - bilateral horizontal GEN due to cerebellar and brainstem disorders, drugs, alcohol, diffuse metabolic disorders.

Table 1.3 Features of peripheral and central vestibular nystagmus

Peripheral	Central
Unidirectional fast phase beating away from affected labyrinth	Uni- or multidirectional
Associated with severe vertigo, vomiting, nausea	Mild symptoms. Other neurological signs, e.g. disconjugate eye movements, pyramidal signs
Amplitude increases with gaze towards the direction of the fast phase	May be gaze-evoked
Various components—horizontal, torsional, vertical	
Suppressed by fixation (Fresnel goggles removes fixation)	No change with fixation

Cranial nerves 5 and 7–12

Cranial nerve 5 (trigeminal)

Sensory via three divisions (ophthalmic V¹, maxillary V², mandibular V³).

- Ophthalmic (V¹). Extends posteriorly to the vertex.
- Sensation but not taste to anterior 2/3 of the tongue also supplied by TG nerve.
- Motor fibres to muscles of mastication (temporalis, masseter, and pterygoids via mandibular division).
- Jaw deviates to side of weak pterygoid muscle.
- Corneal reflex has a consensual component. Useful in the presence of an ipsilateral facial palsy.
- Jaw jerk—if brisk indicates pathology above midbrain level.
- Roger's sign = numb chin syndrome due to metastatic deposit around inferior alveolar branch. Breast cancer, lymphoma.

Cranial nerve 7 (facial)

- Supplies the muscles of facial expression and taste to anterior two thirds of the tongue (via corda tympani branch).
- Lower motor neuron facial palsies result in complete ipsilateral facial weakness.
- The upper face is bilaterally innervated—frontalis and to a lesser extent orbicularis oculi are spared in upper motor neuron palsies.

Cranial nerve 8 (acoustic nerve)

- Two divisions:
 - cochlear (hearing);
 - vestibular (balance).
- Hearing is crudely tested by whispering numbers in one ear whilst blocking the other.
- Rinne's test—256 Hz tuning fork first held in front of the external auditory meatus and then placed firmly on the mastoid.
 - Normal (positive test), air conduction louder > bone conduction.
 - Conductive deafness, BC > AC.
 - Sensorineural deafness, Rinne's positive.
- Weber's lateralization test—tuning fork placed in middle of forehead.
 - Unilateral conductive deafness—louder to the ipsilateral side.
 - Sensorineural deafness—louder to contralateral side.
- Vestibular function tested using:
 - Hallpike's test (see Fig. 4.20 in 'Benign paroxysmal positional vertigo', Chapter 4).
 - Unterberger's test—with eyes closed and arms extended, patient marches on the spot for one minute. Positive test if veers to one side. (Does not differentiate central from peripheral.)

Cranial nerve 9 (glossopharyngeal nerve)

- Taste fibres from posterior third of the tongue.
- General sensation tympanic membrane, mucous membranes from posterior pharynx, tonsils, and soft palate.
- Afferent part of the gag reflex.

Cranial nerve 10 (vagus nerve)

- Motor fibres innervate the striated muscles of palate, pharynx, larynx.
- Soft palate observed as patient says 'aahh'.
 - Deviation away from side of lesion.
- Lesions of recurrent laryngeal branch cause ipsilateral vocal cord paralysis with dysphonia and a weak cough.
- Parasympathetic autonomic fibres travel in the vagus nerve to the respiratory, GI, and cardiovascular systems.

Cranial nerve 11 (accessory nerve)

- Innervation to sternocleidomastoid (SCM) and trapezius.
- SCM (supplied by ipsilateral hemisphere) assessed by asking patient to twist the head against resistance and palpate contralateral SCM.
- Trapezius assessed by shoulder shrug and palpating muscle.

Cranial 12 (hypoglossal nerve)

- Observe for fasciculations—may be difficult. Observe with tongue inside the mouth.
- Tongue strength assessed by asking patient to push inside the mouth against cheek.
- Tongue movement dexterity assessed by asking patient to move tongue side to side. Slowness without wasting suggests spasticity.
- In LMN lesions tongue deviated to the side of the lesion.

Examination of the upper and lower limbs

Ideally, patient should be stripped to underclothes.

General points

- Document hand dominance.
- Look for wasting—first dorsal interosseus muscle easiest (ulnar).
- Examine scapular muscles (winging of the scapula due to lesions of long thoracic nerve).
- Palpate extensor digitorum brevis (EDB) on the foot.
- Observe for fasciculation—may need to spend a few minutes in good light.
- Screening test—ask patient to hold arms outstretched palms up with eyes closed.
 - Pronator drift indicates mild pyramidal weakness.
 - Pseudoathetosis (involuntary movements of fingers) indicates loss of position sense.
 - Postural tremor may be caused by essential tremor, demyelinating neuropathy, or drugs (sodium valproate, steroids).

Tone

↑ Spastic (pyramidal) assessed by the following:

- Upper limbs:
 - rapid flexion/extension movement at the elbow (clasp knife);
 - supinator catch (rapid supination movement at wrist);
 - Hoffman's sign (rapid flexion at DIPJ of middle finger results in brisk flexion movements at other fingers)—positive in upper motor lesions.
- Lower limbs:
 - a brisk flick at the knee when legs extended results in a catch if tone increased;
 - test for clonus at ankles.

↑ Extrapyramidal increase in tone assessed:

- by slow flexion/extension movements at the wrist;
- may be enhanced by synkinesia (ask patient to move contralateral limb).

Muscle strength

All that is required is maximal strength for one second—useful in patients with 'giveaway weakness'. Table 1.4 gives the muscles to be tested and Table 1.5 gives a grading system to evaluate the results.

Table 1.4 Important myotomes

Muscle*	Roots	Nerve	Action
Trapezius	C3, 4	Spinal accessory	Shrug shoulder
Rhomboids	C4, 5	Dorsal scapular	Brace shoulders back
Supraspinatus	C5, 6	Suprascapular	Abduct shoulder 15°
Deltoid	C5, 6	Axillary	Abduct shoulder 15–90°
Infraspinatus	C5, 6	Suprascapular	External rotation of arm
Biceps	C5, 6	Musculocutaneous	Flex forearm
Triceps	C6, 7	Radial	Extend forearm
Extensor carpi	C5, 6	Radial	Extend wrist
Finger extensors	C7, 8	Posterior interosseous	Extend fingers
FDP I and II	C8, T1	Median	Flex DIPJ
FDP III and IV	C8, T1	Ulnar	Flex DIPJ
FDS	C8, T1	Median	Flex PIPJ
APB	C8, T1	Median	Abduct thumb
OP	C8, T1	Median	Thumb to 5th finger
ADM	C8, T1	Ulnar	Abduct 5th finger
1ST DIO	C8, T1	Ulnar	Abduct index finger
Iliopsoas	L1, 2	Femoral	Flex hip
Hip adductors	L2, 3	Obturator	Adduct hip
Hip extensors	L5, S1	Inferior gluteal	Extend hip
Quadriceps	L2, 3	Femoral	Extend knee
Hamstrings	L5, S1	Sciatic	Flex knee
Tibialis anterior	L5, S1	Deep peroneal	Dorsiflex foot
Gastrocnemius	S1, 2	Tibial	Plantarflex foot
Tibialis posterior	L4, 5	Tibial	Invert foot
EHL	L5, S1	Deep peroneal	Dorsiflex hallux
Peroneus longus	L5, S1	Superficial peroneal	Evert foot

* Muscles in bold font are essential in a basic neurological examination.

Table 1.5 MRC grading system for muscle strength

MRC grade	Observed muscle power
0	No movement
1	Flicker of movement
2	Movement with gravity eliminated
3	Movement against gravity
4, 4+, or 4–	Weak
5	Normal power

Coordination**Upper limbs**

- 'Finger nose' testing: intention tremor with increased amplitude near target.
- Dysdiadokinesia (rapid pronation/supination movements of one hand on the palm of contralateral hand).
- Tapping to elicit rhythm.

Lower limbs

- Heel/shin testing.
- With eyes open and closed to assess for sensory ataxia (worse).

Sensory testing

- Do not spend too much time on this.
- Map out abnormality for pain (pin prick), light touch (cotton wool), vibration (128 Hz tuning fork), joint position (at DIPJ) in fingers and toes and working proximally.

Figure 1.4 shows the dermatomes of the upper and lower limbs.

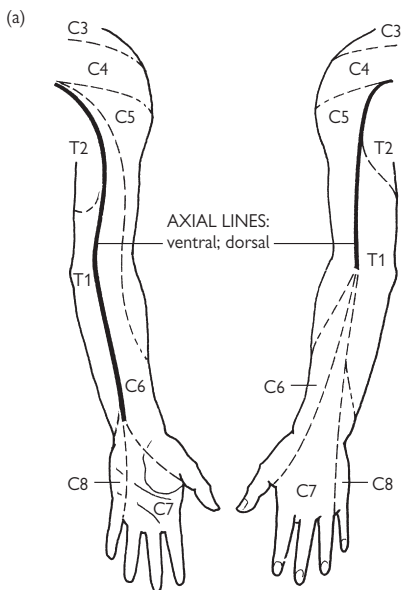


Fig. 1.4 (a) Dermatomes of upper limb.

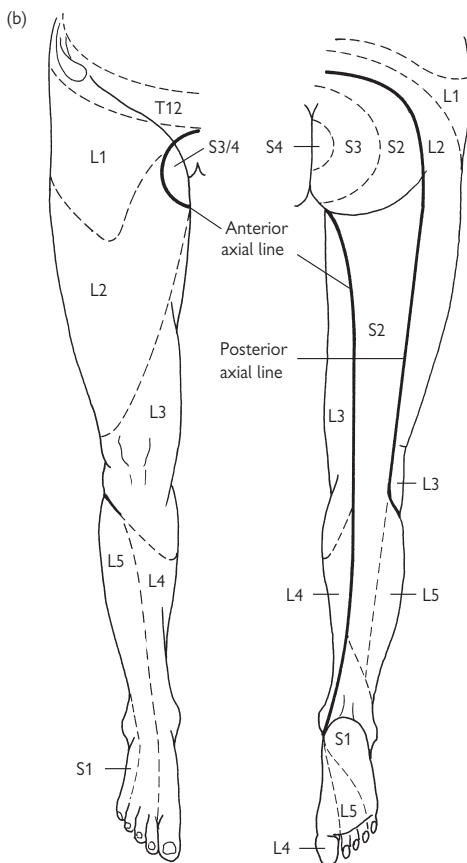


Fig. 1.4 (b) Dermatomes of lower limb. In both diagrams note the axial lines.

Reproduced with permission from MacKinnon, P. and Morris, J. (2005). *Oxford Textbook of Functional Anatomy*, Vol. 1, 2nd edn. Oxford University Press, Oxford.

Deep and superficial tendon reflexes (see Table 1.6)**Deep tendon reflexes**

- The deep tendon reflexes are graded from 0 (absent), ± (present with reinforcement), + (depressed), ++ (normal), +++ (increased).
- Reinforcement can be obtained by jaw clenching or Jendrassik's manoeuvre (patient links hands and pulls).
- Deep tendon reflexes may also be inverted—the tested reflex is absent but there is spread to a lower level. This indicates a lower motor neuron lesion at the level of the reflex but an upper motor neuron lesion below (most common at C5/C6).

Main superficial reflexes

- Abdominal (upper T8/9; lower T10/11)—absent in some UMN lesions.
- Cremasteric (L1/2)—elicited by stroking inner thigh with reflex ipsilateral testicular elevation.
- Anal (S4/5)—scratch anal margin with reflex contraction visible.

Gait examination

- Romberg's sign. Patient standing with eyes open. On closure of eyes, swaying or fall suggesting disturbance of proprioception. Useful in non-organic disorders.

The various gait disturbances encountered in clinical practice are shown in Table 1.7.

Table 1.6 Deep tendon reflexes

Reflex	Nerve	Root
Biceps	Musculocutaneous	C5/6
Supinator	Radial	C5/6
Triceps	Radial	C7
Finger flexors	Median/ulnar	C8
Knee	Femoral	L3/4
Ankle	Tibial	S1/2

Table 1.7 Gait disturbances encountered in clinical practice

Gait disturbance	Description	Common causes
Gait apraxia	Small shuffling steps—'marche à petits pas'; difficulty in starting to walk; cycling on bed significantly better	Small vessel disease, hydrocephalus
Parkinsonian	Shuffling; loss of arm swing	Parkinsonism
Spastic paraparesis	Stiff 'walking through mud'	Cord lesion, parasagittal lesion
Myopathic	Waddling	Myopathic, dystrophic disorders
Foot drop	Foot slapping	Neuropathy, radiculopathy rarely UMN
Cerebellar ataxia	Wide-based; 'drunken'	Any cerebellar pathology
Sensory ataxia	Wide-based; foot slapping; deteriorates with eye closure	Neuropathy, subacute combined degeneration of cord, posterior column disorders, e.g. MS

Bedside cognitive testing, including language

There is no point in attempting a cognitive assessment in a patient who is drowsy or uncooperative.

1 Alertness Record the level of wakefulness and reactivity.

2 Orientation

- Time (time of day; day of the week, month, and year). Disorientation in time common in delirium, moderate dementia, and amnesic syndromes.
- Place (building, town, county, country).
- Person (name, age, date of birth). Dysphasic patients may appear confused due to an inability to understand or express themselves.

3 Attention and concentration

- Count backwards from 20.
- Months of the year backwards.
- Digit span. Ask patient to repeat string of increasing digits—two trials at each level. Record highest level at which either trial correct, e.g.

3 4 8

4 7 9

2 3 6 7

1 4 5 9

2 7 9 5 6

1 8 7 2 3

Normal 6 ± 1

4 Memory

Anterograde memory

- Name and address, e.g. John Green, 157, Church Lane, Cambridge.
- Assess immediate recall and after 5 minutes.

Retrograde memory

- Dates for Second World War.
- Recent world events—sports, royal family news, prime minister.
- Autobiographical memory—parents, childhood events.

5 Frontal executive function (frontal lobe)

Initiation—verbal fluency test

- Ask patient to generate as many words as possible in 1 minute beginning with the letter F, A, or S, excluding names of people or places. Normal: 15 depending on age and intellect.
- Name as many animals or fruit in 1 minute. > 20, normal; < 10 abnormal.

Abstract thought

Interpretation of proverbs (frontal lobe disorders result in concrete interpretations), e.g. 'a stitch in time saves nine'; 'too many cooks spoil the broth'.

Cognitive estimates

Frontal patients give bizarre and illogical answers to questions like the following:

- How many camels are there in Holland?
- What is the height of an average English woman?
- What is the population of London?

Alternating hand movements

- With arms out, fingers of one hand extended; the other with fist clenched. Reverse positions rhythmically. See Figure 1.5.
- Luria 3 step test. See Figure 1.6. Difficulties with complex motor movements associated with left frontal lesions.

6 Dominant (usually left) hemisphere function

Language

Aphasia (Table 1.8) and dysphasia are impairments of language function. Dysarthria is the abnormal motor production of speech.

- Spontaneous speech assessed during conversation and description of a picture.
 - Articulation (abnormal in bulbar, cerebellar, and basal ganglia disorders).
 - Fluency—in-non-fluent speech reduced rate of word production and short phrases.
 - Grammar—lack of pronouns, prepositions, and errors of tense. Correlates with non-fluent language.
 - Paraphasic errors—word substitution, e.g. black for blank (similar sounding = phonemic) or apple for pear (meaning-based = semantic).
 - Prosody—loss of intonation, pitch, and stress occur in right hemisphere lesions but also in non fluent speech and in articulatory disorders.
- Naming. Record 10 items—a mixture of common and uncommon objects, e.g. pen, watch, sleeve, watch winder, buckle.
- Comprehension:
 - single words—point to objects in the room, e.g. door, ceiling
 - complex instructions—‘pick up the piece of paper, fold it in half and give it to me’
 - conceptual—‘what is the colour of a banana?’ ‘What is the name of item in the kitchen that enables you to cut?’
- Repetition, e.g. ‘the band played and the audience clapped’, ‘no ifs, ands, or buts’.
- Reading a passage (see example in box) usually parallels spoken language problems. Occasionally alexia can occur without aphasia.
- Writing—ask patient to write any novel sentence. Dictate a sentence e.g. the cat sat on the mat.

Calculation Simple arithmetic (addition, subtraction).

Praxis skills First to command and, if not possible, then by imitation ‘show me how you would’:

- blow a kiss (buccofacial);
- wave goodbye (limb gestures);
- hammer a nail (object use).

Table 1.8 Types of aphasias and characteristics

Type of aphasia	Fluency	Repetition	Comprehension	Naming
Broca's (inferior frontal lobe)	Non fluent	Affected	Not affected	Affected
Wernicke's (posterior superior temporal lobe)	Fluent	Affected	Affected	Affected

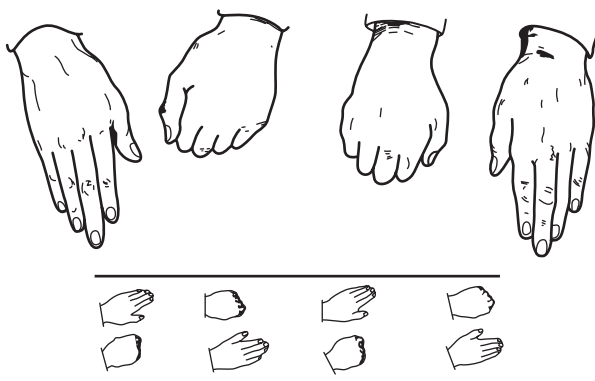


Fig. 1.5 Alternating hand movements test. The hand positions (above) and the sequence of movements to the patient (below) are shown.

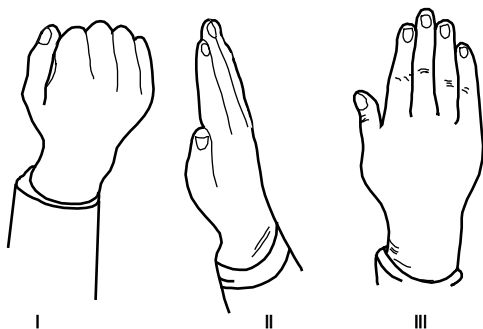


Fig. 1.6 Luria three-step test sequence of hand positions (first—edge—palm) is shown.

Example of passage for reading

On an early autumn Monday morning, Dr David Gordon, driving his Mercedes convertible, reflected upon his weekend that he had spent relaxing at their seaside cottage in Aldeburgh on the Suffolk coast. As a busy general practitioner in Peckham, his morning surgery consisted of the usual mixture of patients with headaches, coughs and colds and intractable social problems. Lunch, as always, was of a cheese baguette accompanied by a yogurt drink. Driving home exhausted but fulfilled, he looked forward to a quiet supper with his wife Rachel followed by watching Coronation Street on the TV.

7 Non-dominant (usually right) hemisphere function**Neglect**

- Sensory neglect: patient ignores visual, tactile, and auditory stimuli from left side.
- Sensory extinction: patient responds to visual or tactile stimulus from each side separately but, when bilateral stimuli presented ignores neglected side.
- Hemispatial neglect: in drawing a clock face, one side of clock is omitted. (see Fig 1.7).
- Dressing apraxia: patient unable to dress, e.g. shirt inside out.
- Constructional ability. Copy shapes, e.g. overlapping pentagons. (see Fig 1.8)
- Prosopagnosia: impaired facial recognition.

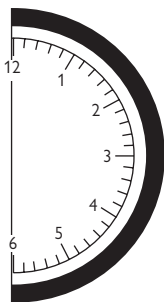


Fig. 1.7 In drawing a clock face patient with hemispatial neglect will omit one side.

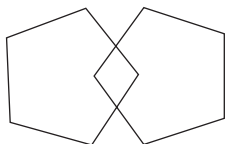


Fig. 1.8 Overlapping pentagons from the Mini-Mental State examination.

The mini-mental state examination (MMSE)

Commonly used bedside test (Table 1.9)¹. Caveats include:

- take into account age, education, culture;
- insensitive to focal deficits especially frontal lobe;
- cut-off score 24/30 but patients with superior background IQ may perform well despite significant cognitive impairment.

¹ Folstein, M.F., Folstein, S., and McHugh, P.R. (1975), 'mini-mental state': a practical method for grading the cognitive state of patients for the clinician. *J. Psychiatric Res.* **12**, 189–98.

Table 1.9 The Mini-Mental state examination (MMSE)*

Test	Score per Item	Maximum score/test
Orientation		
Year, month, day, date, season	1	5
Country, county, town, hospital [†] , ward/room	1	5
Registration		
Examiner names 3 objects (e.g. ball, pen, key); Patient repeats each item	1	3
Attention		
Ask patient to start with 100 and subtract 7. Stop after 5 subtractions, e.g. 100, 93, 86, 79, 72, 65	1	5
<i>or</i>		
Ask patient to spell 5-letter word backwards, e.g. 'world'. Score number of letters in correct order		
Recall		
Ask for the 3 words you asked patient to number in 'Registration' test	1	3
Language		
Naming: point to object and ask patient to name it. e.g. watch, tie	1	2
Repetition		
Ask patient to repeat sentence after you (only 1 trial allowed), e.g. 'no ifs, ands, or buts'	1	1
3-Stage command		
e.g. 'take this paper, fold it in half, and give it to me'. Score 1 point for each stage of command correctly executed	1	3
Reading		
Ask patient to read a command on paper, e.g. 'close your eyes', and to execute it	1	1
Writing		
Ask patient to write a sentence. To score 1 it must be sensible and must contain a noun and a verb	1	1
Copying		
Copy picture of intersecting pentagons (Fig. 1.8). To score 1, all 10 angles must be present and two must intersect	1	1
Maximum possible score		30

* No half-points are given in the MMSE.

[†] Home or hospital depending on location of the test.

This page intentionally left blank

Neuroanatomy

The cranial cavity 34

Dermatomes of the upper and lower limbs 36

Innervation of the upper limbs 38

Innervation of the lower limbs 46

Cross-sections of the brain and spinal cord 52

The cranial cavity

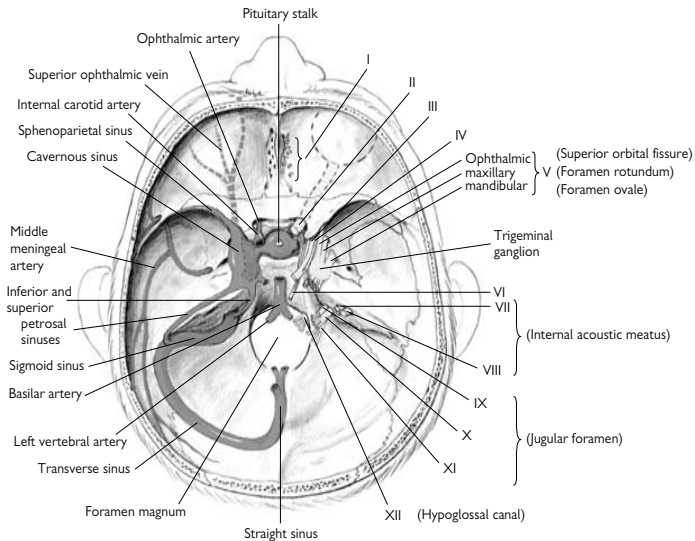


Fig. 2.1 Interior of skull base; vessels and nerves.

Adapted with permission from MacKinnon, P. and Morris, J. (2005). *Oxford Textbook of Functional Anatomy*, Vol. 3, 2nd edn. Oxford University Press, Oxford.

This page intentionally left blank

Dermatomes of the upper and lower limbs

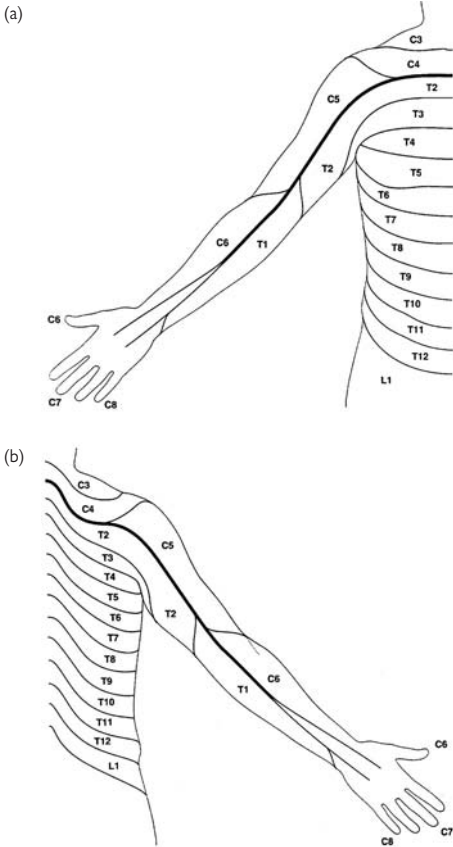


Fig. 2.2 Approximate distribution of dermatomes: (a) on the anterior aspect of the upper limb; (b) on the posterior aspect of the upper limb.

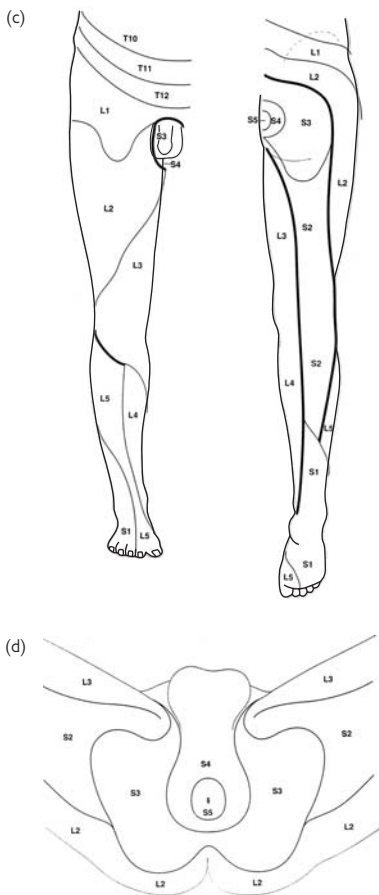


Fig. 2.2 Approximate distribution of dermatomes: (c) on the lower limb; (d) on the perineum. Reprinted from *Aids to the Examination of the Peripheral Nervous System*; 4th edn, (2000) pp. 56–9, with permission from Elsevier.

Innervation of the upper limbs

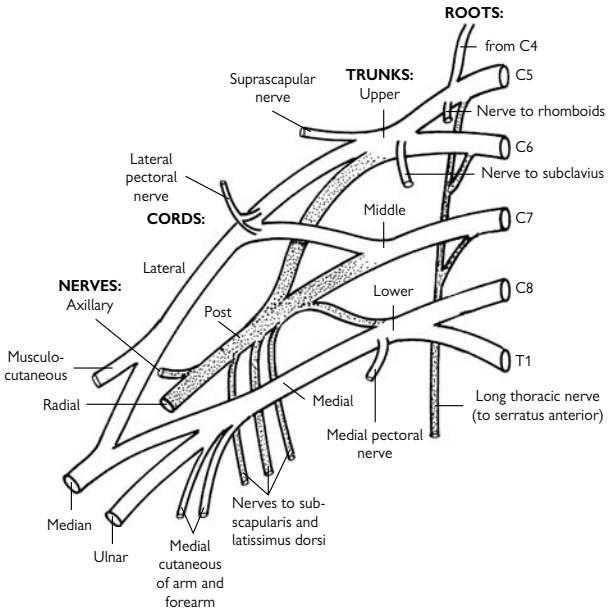


Fig. 2.3 Brachial plexus: schematic diagram of trunks, cords, and branches.

Reproduced with permission from MacKinnon, P. and Morris, J. (2005) *Oxford Textbook of Functional Anatomy*, Vol. 1, 2nd edn. Oxford University Press, Oxford.

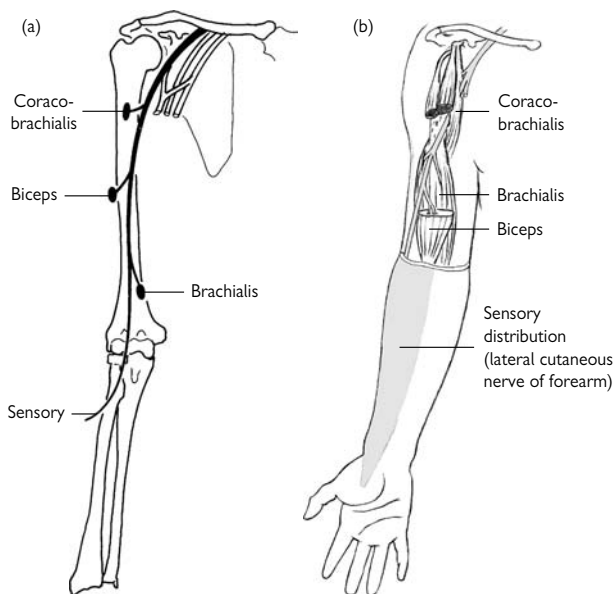


Fig. 2.4 Course of musculocutaneous nerve. (a) Supply to muscles. (b) Supply to skin.

Reproduced with permission from MacKinnon, P. and Morris, J. (2005) *Oxford Textbook of Functional Anatomy*, Vol. 1, 2nd edn. Oxford University Press, Oxford.

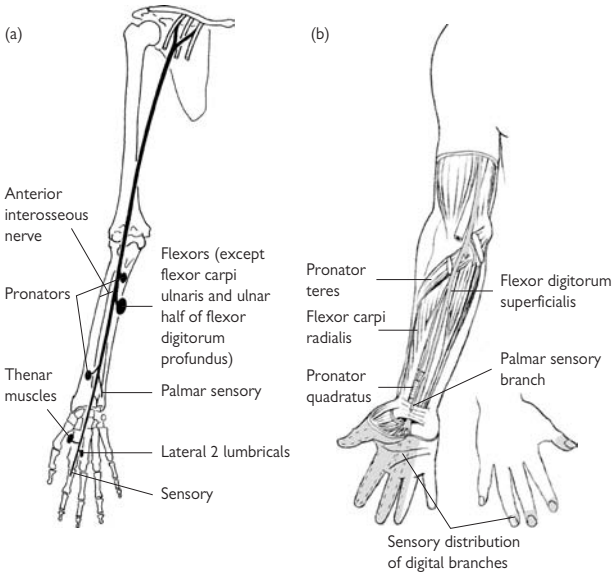


Fig. 2.5 Course of median nerve. (a) Supply to muscles. (b) Supply to skin. Note: anterior interosseous nerve supplies flexor pollicis longus; flexor digitorum profundus to second and third digits, and pronator quadratus. Adapted with permission from MacKinnon, P. and Morris, J. (2005) *Oxford Textbook of Functional Anatomy*, Vol. 1, 2nd edn. Oxford University Press, Oxford.

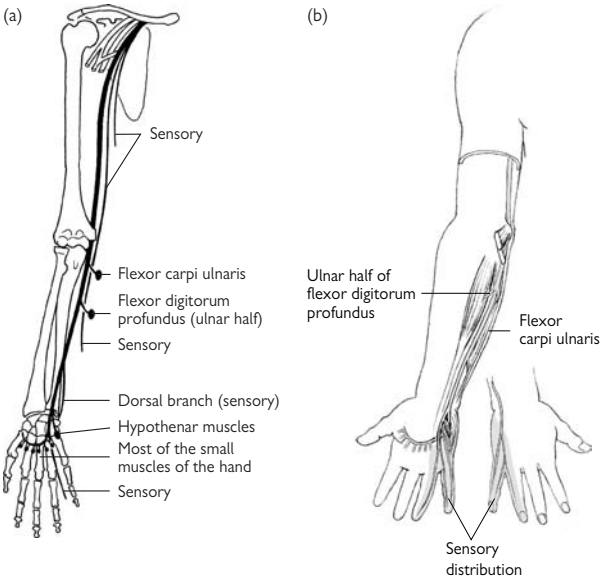


Fig. 2.6 Course of ulnar nerve. (a) Supply to muscles. (b) Supply to skin. Reproduced with permission from MacKinnon, P. and Morris, J. (2005). *Oxford Textbook of Functional Anatomy*, Vol. 1, 2nd edn. Oxford University Press, Oxford.

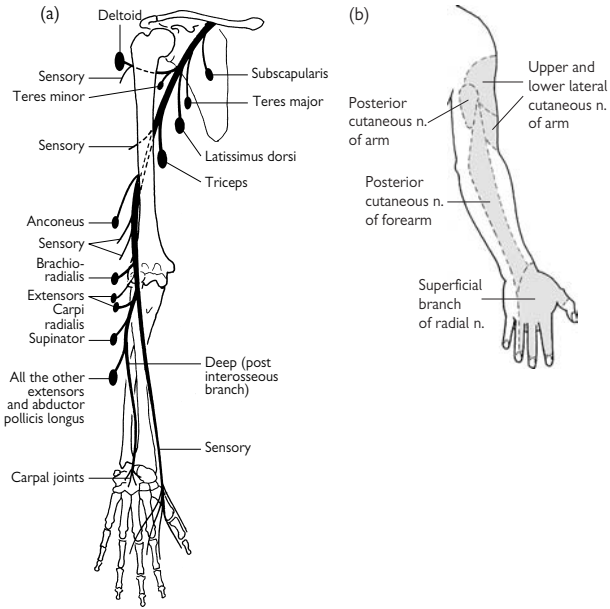


Fig. 2.7 (a) Posterior cord, axillary, and radial nerves: supply to muscles. Note: posterior interosseus branch supplies extensor digitorum communis, extensor pollicis longus, extensor carpi ulnaris. (b) Course of radial nerve: supply to skin. Reproduced with permission from MacKinnon, P. and Morris, J. (2005) *Oxford Textbook of Functional Anatomy*, Vol. 1, 2nd edn. Oxford University Press, Oxford.

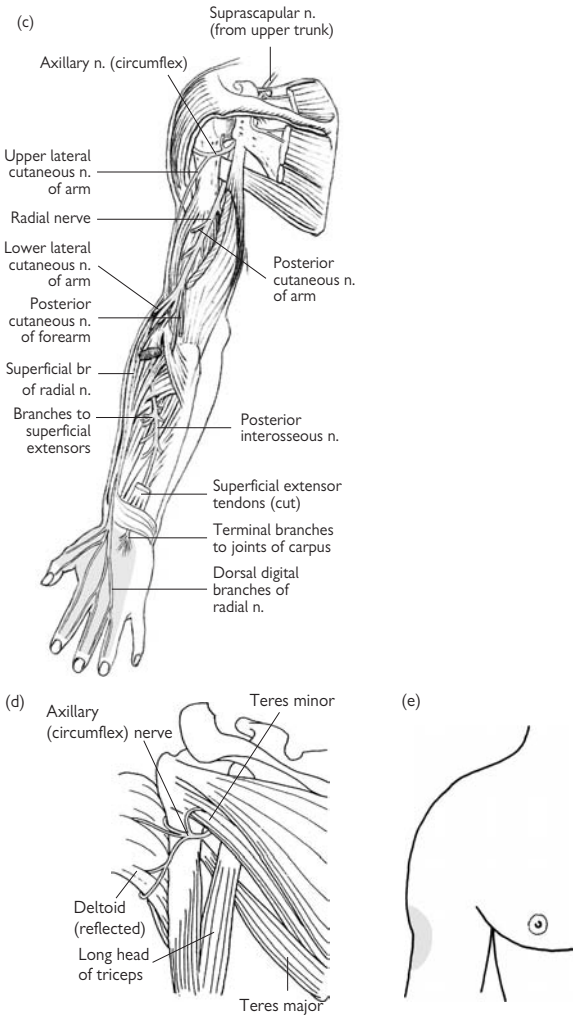


Fig. 2.7 (c) Course of radial nerve: sensory supply (to hand). (d) Course of axillary nerve. (e) Axillary nerve: supply to skin.

Reproduced with permission from MacKinnon, P. and Morris, J. (2005) *Oxford Textbook of Functional Anatomy*, Vol. 1, 2nd edn. Oxford University Press, Oxford.

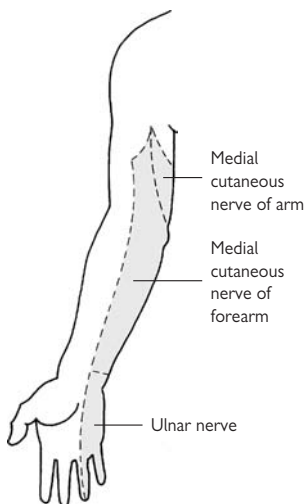


Fig. 2.8 Distribution of medial cutaneous nerves of arm and forearm and of ulnar nerve.

Reproduced with permission from MacKinnon, P. and Morris, J. (2005) *Oxford Textbook of Functional Anatomy*, Vol. 1, 2nd edn. Oxford University Press, Oxford.

This page intentionally left blank

Innervation of the lower limbs

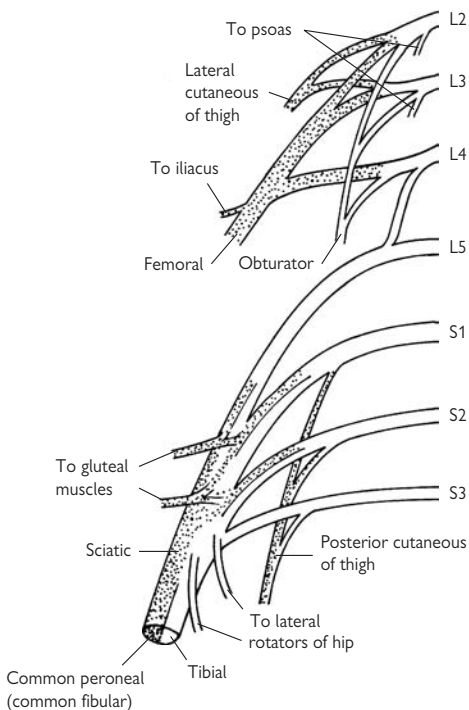


Fig. 2.9 Lumbosacral plexus.

Reproduced with permission from MacKinnon, P. and Morris, J. (2005) *Oxford Textbook of Functional Anatomy*, Vol. 1, 2nd edn. Oxford University Press, Oxford.

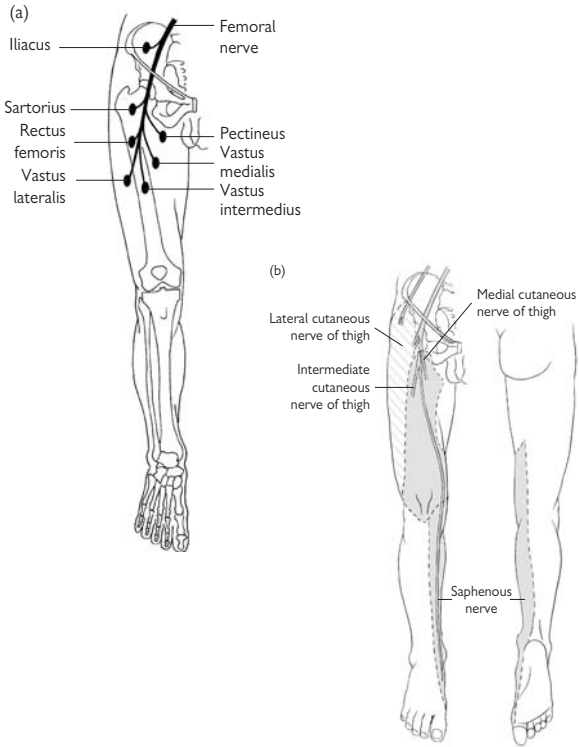


Fig. 2.10 (a) Femoral nerve: supply to muscles. (b) Femoral nerve: supply to skin; also lateral cutaneous nerve of thigh.

Reproduced with permission from MacKinnon, P. and Morris, J. (2005) *Oxford Textbook of Functional Anatomy*, Vol. 1, 2nd edn. Oxford University Press, Oxford.

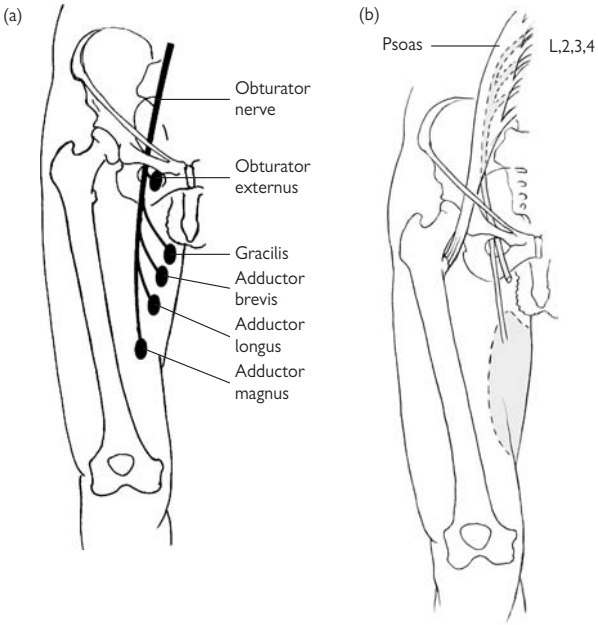


Fig. 2.11 Obturator nerve. (a) Supply to muscles. (b) Supply to skin.

Reproduced with permission from MacKinnon, P. and Morris, J. (2005) *Oxford Textbook of Functional Anatomy*, Vol. 1, 2nd edn. Oxford University Press, Oxford.

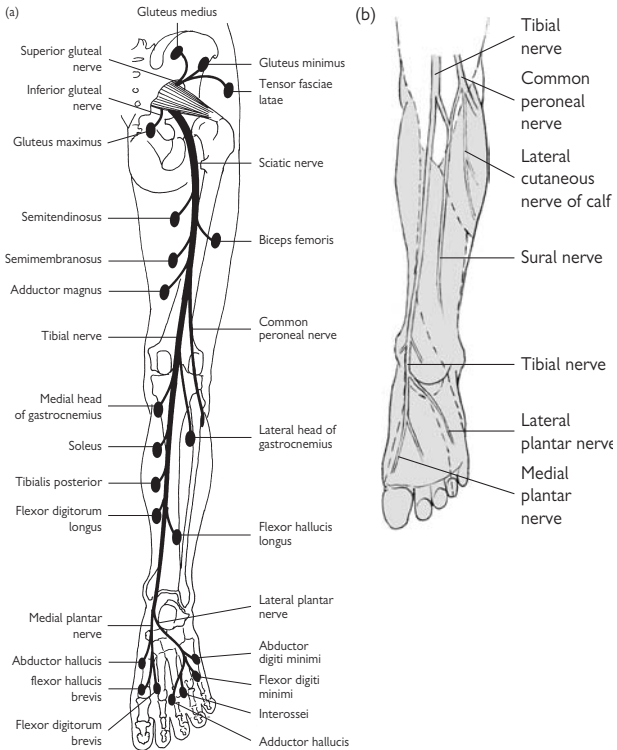


Fig. 2.12 Sciatic and tibial nerves. (a) Supply to muscles. (b) Supply to skin. Reproduced with permission from MacKinnon, P. and Morris, J. (2005) *Oxford Textbook of Functional Anatomy*, Vol. 1, 2nd edn. Oxford University Press, Oxford.

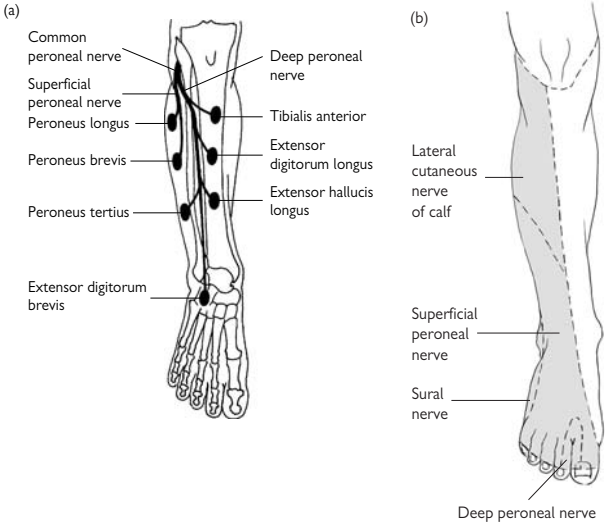


Fig. 2.13 Common peroneal nerve. (a) Supply to muscles. (b) Supply to skin.

Reproduced with permission from MacKinnon, P. and Morris, J. (2005) *Oxford Textbook of Functional Anatomy*, Vol. 1, 2nd edn. Oxford University Press, Oxford.

This page intentionally left blank

Cross-sections of the brain and spinal cord

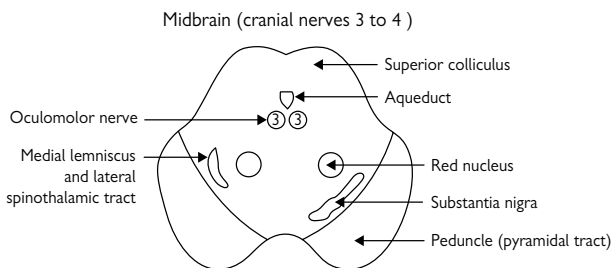


Fig. 2.14 Cross-section, mid-brain. Cranial nerves 3 to 4.

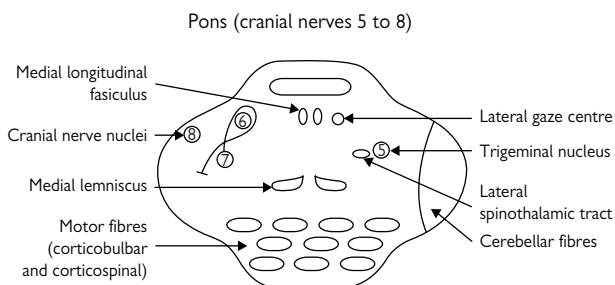


Fig. 2.15 Cross-section, pons. Cranial nerves 5 to 8.

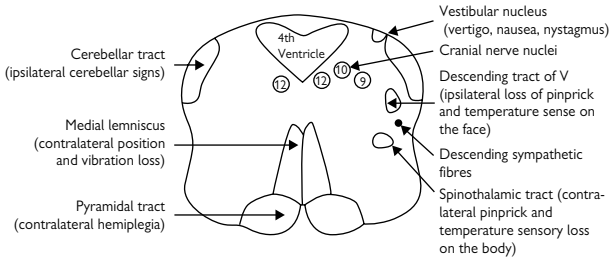


Fig. 2.16 Cross-section, medulla. Cranial nerves 9 to 12.

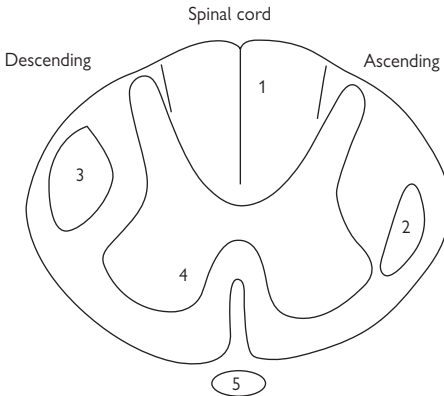


Fig. 2.17 Spinal cord cross-section. 1. Dorsal columns; 2. spinothalamic tracts; 3. corticospinal tracts; 4. anterior horn cells; 5. anterior spinal artery.

This page intentionally left blank

Common clinical presentations

- Loss of consciousness 56
- Acute vertigo 58
- Acute headache (thunderclap headache) 62
- Acute neuromuscular weakness 64
- Acute focal neurological syndromes 68
- Spastic paraparesis 70
- Ataxia 72
- Acute visual failure 76
- Coma 80
- Coma prognosis 84
- Excessive daytime sleepiness 86
- Tremor 90
- Tics 94
- Chorea and athetosis 96
- Myoclonus 98
- Dystonia 100

Loss of consciousness

This is a common problem.

- Eyewitness account (verbal or written) is essential. May need to contact by telephone.
- Better to label an episode 'Cause' than diagnose epilepsy if not sure. Time will make the diagnosis clear. Avoid trials of anticonvulsants.
- Advise the patient about implications for driving. May need to inform the DVLA.

Aetiology

Neurological causes

- Epileptic seizures.¹
- Raised ICP (tumour especially posterior fossa lesions, hydrocephalus due to, e.g. colloid cyst).
- SAH.
- Sleep disorders (narcolepsy, cataplexy).
- Basilar artery migraine (rare).
- Cerebrovascular disease (rare, unless massive stroke or brainstem).

Neurally mediated syncope

- Neurocardiogenic (vasovagal) syncope.¹
- Carotid sinus syncope.
- Situational syncope (cough, micturition).

Cardiac syncope

- Cardiac arrhythmias.¹
- Structural cardiopulmonary disease (aortic stenosis, HOCM, pulmonary embolus).

Orthostatic or postural hypotension

- Drugs¹, e.g. vasodilators, antidepressants, L-dopa preparations.
- Autonomic neuropathy (GBS, diabetes, amyloid).
- Autonomic failure (MSA, PD).
- Addison's disease.

Metabolic disorders

- Hypoglycaemia.
- Hyperventilation induced alkalosis.

Psychiatric disorders

- Psychogenic non epileptic attacks.¹

¹ Commonest causes.

Diagnosis

See Table 3.1. The eyewitness account will help make the diagnosis.

Table 3.1 Features differentiating vasovagal syncope from epileptic seizures

	Seizure	Syncope
Trigger	Rare—flashing lights, hyperventilation	Common (blood, needles, hot environment, standing, pain)
Prodrome	Common—auras	Very common—nausea, lightheadedness, tinnitus, greying vision
Onset	Sudden	Gradual
Duration	1–3 min	1–30 sec
Convulsive jerks	Common—prolonged	Common—brief
Incontinence	Common	Uncommon
Tongue biting	Common	Rare
Post-event confusion	Common	Rare
Colour	Pale, cyanotic (tonic–clonic seizures)	Very pale

Investigations

Consider the following:

- Blood: hb (anaemia), glucose (especially in diabetics or if preprandial), K^+ , Ca^{2+} .
- ECG: 24-h tape (repeated) or, if necessary, a prolonged cardiomemo; echocardiogram for cardiac syncope.
- Tilt table testing. Sensitive for syncopal tendencies.
- EEG by itself does not diagnose epilepsy. 50% false negative rate for interictal EEG in patients with epilepsy. Reduced to 30% by repeating and 20% with sleep-deprived EEG. False positive EEG in up to 2% healthy young adults.
- Ictal video-EEG-telemetry most sensitive and specific test for epilepsy. Note: frontal lobe epileptic seizures may appear normal even on ictal EEG.
- Imaging—preferably with MRI—for focal seizures, focal signs, or signs and symptoms of ↑ICP.

Acute vertigo

Vertigo is the illusion of rotation caused by asymmetry of neural activity between the right and left vestibular nuclei. Bilateral damage does not cause vertigo.

Essential to determine if the vertigo is central or peripheral since cerebellar infarction/haemorrhage can be life-threatening and require neurosurgical intervention.

Aetiology

- Acute vertigo with no other symptoms or signs is very unlikely to be due to vertebrobasilar ischaemia.
- Acute vestibular neuritis, presumed viral, affects lateral semicircular canal function.
- Infarction within the territory of the anterior vestibular artery, a branch of the internal auditory artery, that in turn branches from the anterior inferior cerebellar artery. Clinical presentation is similar to that of a vestibular neuritis but usually occurs in older patients with risk factors for stroke such as diabetes, hypertension, and cardiac disease, e.g. atrial fibrillation.
- Brainstem stroke, accompanied by other signs:
 - Horner's syndrome;
 - dysarthria;
 - incoordination;
 - diplopia;
 - numbness of the face.
- Inferior cerebellar infarction can present with only vertigo, nystagmus, and postural instability.
- Multiple sclerosis can produce an evolving vestibular syndrome with a plaque around the 8th nerve root entry zone but other signs present.

Clinical features

Clinical presentation is with acute onset vertigo, nausea and vomiting.

Spontaneous nystagmus

- Peripheral origin is indicated by the following characteristics:
 - Horizontal with a torsional component.
 - Does not change direction with a change in gaze.
 - Bidirectional nystagmus excludes the diagnosis.
 - Slow phase towards affected ear; fast phase towards unaffected ear.
 - Visual fixation ↓ the nystagmus and removing fixation ↑ it. At bedside, if Fresnel lenses not available, use an ophthalmoscope focused on the optic disc or the retinal blood vessels with the other eye covered. The nystagmus should be evident in the primary position. Note that the direction of the nystagmus is inverted when viewed through the ophthalmoscope
- Central nystagmus is often purely horizontal or vertical and changes in direction with changes in the position of the gaze (i.e. bi- or multidirectional).
- Purely vertical and purely torsional nystagmus is usually also of central origin.

- Horizontal—torsional nystagmus may occur in both peripheral and central disorders.
- Visual fixation has little effect on nystagmus of central origin.

The head impulse test a bedside test of the horizontal vestibulo-ocular reflex (See Fig 3.1).

- Indicates absent lateral semicircular canal function on affected side.
- If a catch up saccade occurs in one direction and not the other this indicates a peripheral vestibular lesion on that side within the labyrinth or the 8th nerve including the root entry zone in the brainstem.

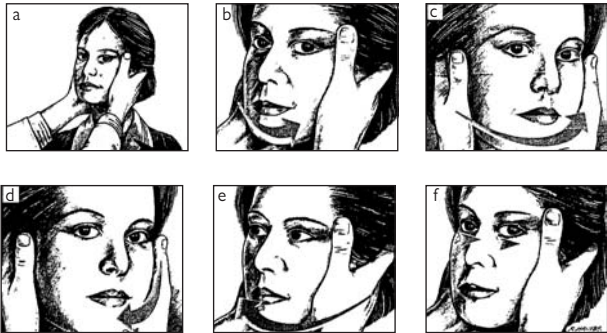


Fig. 3.1 The head impulse test. The examiner turns the patient's head as rapidly as possible about 15° to one side and observes the ability of the patient to keep fixating on a distant target. The patient illustrated has a right peripheral lesion with a severe loss of right lateral semicircular canal function. While the examiner turns the patient's head towards the normal left side (top row), the patient is able to keep fixating on target. By contrast, when the examiner turns the patient's head to the right, the vestibulo-ocular reflex fails and the patient cannot keep fixating on target (e) so that she needs to make a voluntary rapid eye movement, i.e. a saccade, back to target (f) after the head impulse has finished; this can be easily observed by the examiner. It is essential that the head is turned as rapidly as possible; otherwise smooth pursuit eye movements will compensate for the head turn. Reproduced with permission from Halmagyi, G.M. (2005). *Diagnosis and management of vertigo. Clin. Med.* 5(2), 159–65. Royal College of Physicians.

Fukuda or Unterberger's test Marching on the spot with eyes closed and arms out. Positive test—patient veers to side of the lesion. Cerebellar lesion patients unable to stand unaided to do test. Does not discriminate between central and peripheral causes.

Other signs

- Patients with a peripheral lesion can typically stand but veer/tilt to the side of the lesion. Those with a central lesion are often unable to stand without support.
- If signs not typically peripheral assume central and investigate.

Recurrent attacks of acute vertigo May be due to one of the following.

- Ménière's disease.
- Migraine.
- Posterior circulation TIAs (rare); brief crescendo of attacks heralding stroke. Some may be associated with diplopia, dysarthria, or facial numbness.
- Episodic ataxia.

Differential diagnosis See Table 3.2.

Management

- If peripheral, treat with vestibular sedatives, e.g. betahistine 8–16 mg TDS. Symptoms always resolve in a few days due to vestibular compensatory mechanisms.
- If central, consider CT to exclude a cerebellar infarction/haemorrhage. MRI more sensitive at detection of posterior fossa infarcts. Some develop cerebral oedema resulting in hydrocephalus and need urgent shunting and/or decompression.
- Significant number of posterior circulation infarcts due to cardiogenic embolism.
 - ECG, 24-hour ECG, transthoracic and or trans-oesophageal echo.
 - ? Anticoagulation.

Table 3.2 Differential diagnoses of acute vertigo

Cause	History	Examination	Investigation
Acute vestibular neuritis	Develops over hours and resolves in days; viral infection	Spontaneous 'peripheral' nystagmus, positive head impulse test	Unilateral caloric hypoexcitability, audiogram normal. MRI normal
Labyrinthine infarction	Abrupt onset; previous vascular disease	As for vestibular neuritis	As for neuritis; MRI-silent infarcts
Perilymph fistula	Abrupt onset; associated head trauma, barotrauma, coughing or sneezing; May be associated with chronic otitis and cholesteatoma	As for neuritis; possible perforation of tympanic membrane. Positive fistula test (vertigo and nystagmus induced by pressure in the external canal)	As for labyrinthitis; CT temporal bone may show erosion from cholesteatoma
Brainstem and cerebellar infarction	Abrupt onset; history of vascular disease; other neurological symptoms	Spontaneous central nystagmus; head impulse test positive only if root entry zone involved; focal neurological signs	Unilateral caloric hypoexcitability if anterior inferior cerebellar artery involved. MRI shows infarction in medulla, pons, or cerebellum.

Note: Ménière's syndrome can initially present with acute vertigo but it rarely lasts more than 4 or 5 hours (other symptoms: low frequency tinnitus, hearing loss, and a sense of fullness in the ears).

Acute headache (thunderclap headache)

- 2% of visits to A & E department are due to headache.
- In patients with 'worst ever' headache and a normal neurological examination, 12% may have a subarachnoid haemorrhage (SAH). If neurological exam is abnormal this becomes 25%. The diagnosis of SAH is missed initially in up to 32%.

'Thunderclap headache' may be defined as an abrupt onset, often a 'worst ever' headache that is maximal in seconds but may develop in minutes.

Differential diagnoses

Vascular causes

- SAH.
- Carotid and vertebral artery dissection.
- Cerebral venous thrombosis.
- Arterial hypertension.

Non-vascular causes

- Meningoencephalitis.
- Intermittent hydrocephalus (colloid cyst of the 3rd ventricle).
- Spontaneous intracranial hypotension.

Primary headache syndromes

- Coital cephalgia (headache associated with sexual activity).
- Crash migraine.
- Benign cough and exertional headache.
- Icepick or idiopathic stabbing headache.
- Exploding head syndrome.

Clinical features

The 'red flags' in a patient with such a presentation include:

- worst ever headache;
- onset with exertion (20% of SAH occur with exertion, e.g. sexual intercourse);
- impaired alertness or conscious level, neck stiffness, progressive neurological deterioration;
- abnormal neurological examination (third or sixth nerve palsy, papilloedema, subhyaloid haemorrhage, hemiparesis, or diplegia (anterior communicating aneurysm)).

A first episode of headache cannot be classified as tension type headache (IHS criteria for diagnosis requires at least 9 similar episodes) or migraine (4 previous episodes required for diagnosis) without aura.

Investigations

All patients should have a CT scan and, if that is negative, a lumbar puncture.

CT scans become less sensitive at the detection of blood with time:

- day 1, 95%.
- day 3, 74%.
- day 7, 50%.

- day 14, 30%.
- day 21, almost 0%.

Therefore, 5% of scans in patients with SAH normal initially. Technical factor is thin cuts (<10 mm) are more sensitive than thicker cuts; if the haemoglobin is less than 10 g/l, blood appears isodense. Expertise in reading CT scans essential.

If the CT scan is negative, an LP should be performed providing there are no contraindications such as a signs of ↑ICP.

- Always measure OP—elevated in 60% of SAH, and in cerebral venous thrombosis.
- Sample should be centrifuged immediately and the CSF compared to plain water in a glass tube against a white background.
- In SAH, usually > 100 000 RBC + 1–2 WBC per 1000 RBC. If there are a lot more white cells consider meningitis complicated by a traumatic tap.

Alternatively, after a few days following a SAH, a meningitic reaction may occur. In SAH protein is usually elevated.

- Xanthochromia (resulting from breakdown of haemoglobin to oxyhaemoglobin (pink) and bilirubin (yellow) may take at least 12 hours to develop; hence the recommendations to delay LP until 12 hours after ictus unless meningitis is a strong possibility. This may disappear after 14 days.
- Although spectrophotometry is more sensitive than visual inspection in looking for xanthochromia, it is not widely available.
- Other causes of xanthochromia: jaundice, elevated CSF protein (>1.5 g/l), malignant melanoma, and rifampicin. If CT positive or there is persistently bloody CSF or xanthochromia by visual inspection, cerebral angiography and a neurosurgical opinion are necessary.

SAH versus traumatic tap

- OP elevated in SAH.
- Use 3 tube test against a white background for xanthochromia.
- WBC—in SAH, 1 per 1000 RBC. After 3–5 days, polymorphs and lymphocytes.

Acute neuromuscular weakness

Acute flaccid paralysis may be due to disorders of:

- nerve;
- muscle;
- or neuromuscular junction.

In the early stages of an acute myelopathy due to trauma or an intraspinal haemorrhage or myelitis due to inflammatory or infectious causes, clinical signs may resemble those of a peripheral rather than a central disorder.

Clinical features

- The tempo of progression will give a clue to aetiology—sudden onset paraparesis, for example, is most likely to be due to a vascular insult to the spinal cord such as anterior spinal artery (ASA) thrombosis.
- Most of the neuromuscular causes tend to have a subacute course progressing over a few days.
- An exception are the periodic paralyses (both hyperkalaemic and hypokalaemic). Key finding is depressed or absent reflexes which will also be found in weakness due secondary hypokalaemia. In the periodic paralyses attacks may last minutes or hours in hyperKPP and hours/days in hypoKPP.
- Significant sensory deficit is unusual in GBS, whereas a pure motor deficit without sensory loss is unusual in vasculitic neuropathy.
- A sensory level and sphincter dysfunction implies a spinal cord disorder. Spinal cord compression without pain and a sensory level are unusual.
- Back pain may be a feature of GBS.
- Autonomic dysfunction occurs in GBS, but pupillary dilatation and hypersalivation are found in botulism. Persistent hypertension and tachycardia in association with pure motor weakness occurs in porphyria.

Differential diagnosis—See Table 3.3.

Table 3.3 Differential diagnosis of acute neuromuscular weakness

Disorder	Clinical features	Investigations
Peripheral nerve disorders		
Guillain-Barré syndrome	Subacute onset but may be sudden, few sensory signs; no sphincter involvement. Vascular autonomic dysfunction; no sensory level	NCT shows slowing but may be normal; CSF protein ↑, few cells 10–20.
Vasculitic neuropathy	Patchy motor and sensory loss; pain and dysaesthesia. Underlying primary vasculitic or rheumatological syndrome	NCT may reveal clinically asymptomatic lesions. Nerve ± muscle biopsy
Acute intermittent porphyria	Distal motor neuropathy hypertension, and tachycardia	Blood and urine analysis
Diphtheria	Oropharyngeal weakness at onset; Pharyngeal membrane	NCT—axonal neuropathy; serology
Heavy metal poisoning e.g. lead	Motor neuropathy, blue gum line, Mees lines, abdominal pain	serum lead level
Neuromuscular junction disorders		
Myaesthesia gravis	Fluctuating muscle weakness, ocular, bulbar, respiratory involvement. Reflexes intact	Tension test, ACh receptor antibodies. EMG studies show decrement. Single fibre—jitter
Lambert–Eaton syndrome	Variable muscle weakness. Ocular, muscles spared. Underlying carcinoma	Voltage gated calcium channel antibodies. EMG shows potentiation
Botulism	Muscle weakness, ophthalmoplegia with pupillary and autonomic changes	Isolation of organism from wound; serology

Table 3.3 (Contd.)

Disorder	Clinical features	Investigations
Muscle disorders		
Inflammatory myopathy	Muscle pain and weakness, usually proximal. Rhabdomyolysis	CPK ↑, EMG myopathic; muscle biopsy
Hypokalaemic periodic paralysis	Autosomal dominant. Duration: hours to days. Triggers: rest after exercise, carbohydrate meal, stress	Short exercise EMG, mutation in <i>CACNA1S</i> gene
Hyperkalaemic periodic paralysis	Autosomal dominant. Duration: minutes to hours. Triggers: rest after exercise, K ⁺ -containing foods	Short exercise EMG, mutation in <i>SCN4A</i> gene
Anterior horn cell disorder		
Due to poliovirus or other enterovirus	Acute lower motor neuron syndrome	Stool culture; CSF PCR
Myelopathic disorders		
Acute transverse myelitis	Initially, flaccid rather than spastic. Sphincter involvement, sensory level. May be first episode of demyelination or viral e.g. Herpes varicella zoster	MRI spine ± brain; CSF for oligoclonal bands; PCR
Anterior spinal artery syndrome	Acute flaccid paralysis with sensory level. Sparing of posterior columns	MRI thoracic spine cardiac, thrombophilia, vasculitic screen
Functional disorders	Bizzare gait, Hoover's sign, non-organic sensory level, e.g. anterior only	MRI and CSF to exclude organic disorder

This page intentionally left blank

Acute focal neurological syndromes

In patients who present with acute focal neurological deficit, the history and examination should point to the site of pathology and to the possible pathological mechanism(s).

Clinical notes

Onset of symptoms

- Sudden onset of focal neurological dysfunction without warning suggests a vascular aetiology.
- Slow progression ('march') of symptoms over a few seconds suggests an ictal phenomenon.
- Progression over minutes or hours points to a migrainous diathesis.
- Exceptions to these rules occur since occasionally a stroke may progress in a stepwise manner over hours or days.
- Gradual development of focal neurological deficit over days or weeks and months indicates a space-occupying lesion such as tumour.

Duration of symptoms Only factor that distinguishes a TIA from a stroke is the duration of TIA is < 24 hours although most episodes last only a few minutes.

Nature of symptoms

- Cerebrovascular events cause negative symptoms and signs, i.e. loss of sensory, motor, language, or visual function.
- Ictal events generally cause positive phenomena such as tingling in an arm or leg.
- Migraine may cause both positive and negative symptoms and signs—tingling marching up the arm and dysphasia.
- Space-occupying lesions will result in a progressive loss of function or may trigger positive ictal symptoms.

Additional symptoms and signs

- Associated throbbing unilateral headache during or after the development of neurological symptoms point to migraine but headache occurs in 15% of patients with TIAs, 25% of patients with acute ischaemic stroke, and all cases of subarachnoid haemorrhage.
- Carotid and vertebral artery dissection may both cause focal neurological deficits in association with head, face, neck, or ocular pain.
- In an elderly patient with monocular visual loss temporal arteritis needs exclusion.
- Subdural haematoma may present with an acute onset with or without headache.
- Partial seizures may progress rapidly to generalized tonic clonic seizures.

- 2% of patients presenting with an acute stroke may have a seizure, either partial or generalized, at onset.
- Meningoencephalitis may present with symptoms and signs such as headache, neck stiffness, and photophobia as well as focal signs due to an associated vasculitis.

Loss of consciousness

- TIA and ischaemic stroke patients very rarely present with loss of consciousness.
- If it does occur, the most likely causes are SAH, a large brain stem stroke, or a massive hemispheric intracerebral haemorrhage.
- Large hemispheric ischaemic strokes may progress to coma after a few days (secondary haemorrhage).
- Following a seizure, some patients may present with a Todd's paresis.

Causes of acute focal neurological symptoms and signs

- Transient ischaemic attack (TIA)/stroke.
- Migraine aura.
- Partial (focal) seizure.
- Intracranial structural lesions:
 - tumour;
 - subdural haematoma;
 - AVM;
 - giant aneurysm.
- Multiple sclerosis and inflammatory CNS disorders.
- Metabolic disorders:
 - hypoglycaemia;
 - hypo- and hypercalcaemia;
 - Wernicke's encephalopathy.
- Meningoencephalitis:
 - cerebral abscess;
 - associated vasculitis;
 - specific organisms, e.g. herpes simplex and temporal lobes, *Listeria monocytogenes* and brainstem involvement.
- Other disorders:
 - myasthenia gravis;
 - hyperventilation and panic attacks;
 - somatization disorders.

Spastic paraparesis

Bilateral upper motor neuron signs in the legs. A common presentation caused by a variety of disorders.

Clinical features

- Gait is effortful and stiff, 'walking through mud'.
- Check for a sensory level—anterior and posterior.
- In degenerative conditions the abdominal reflexes remain, e.g. MND.
- Patients presenting with a short history, associated back pain, and bladder and bowel symptoms (urgency, incontinence)—emergency assessment necessary (cord compression).
- Lesions at lower end of spinal cord above L1 and involving cauda equina, e.g. dural AVM, will have a mixture of upper and lower motor neuron signs, e.g. extensor plantars and absent ankle jerks.

Aetiology

See Table 3.4. In cases of undiagnosed spastic paraparesis consider a trial of L-dopa for dopa-responsive dystonia.

Table 3.4 Causes of spastic paraparesis

Cause	Comment
Structural causes	
Parasagittal lesion	E.g. meningioma or dominant anterior cerebral artery infarction affecting medial areas of both frontal lobes
Spinal disease	
Degenerative disease	Note: sensory level may be lower than expected Cervical or thoracic disc disease
Syringomyelia	Typically affecting spinothalamic fibres with sparing of posterior column fibres; anterior horn cell damage causes wasting of hand muscles if syrinx in cervical/thoracic region
Tumors	Intradural and extradural e.g. meningioma
Spinal AVM	
Neurological disorders	
Demyelination e.g. MS	Investigations: MRI brain, cord, oligoclonal bands in CSF, VER
Inflammatory disorders	
Sarcoidosis	Investigations: MRI with gadolinium; blood and CSF ACE; CXR, gallium, or PET scan; histology e.g. skin, liver, muscle
Vascular disorders	
Anterior spinal artery syndrome	Level T10, sparing posterior column Investigations: MRI
Hereditary disorders	
Adrenoleucodystrophy	Investigations: VLCFA; MRI; synacthen test
Hereditary spastic paraparesis	Diagnosis: family history; genetic testing
Infections	
HIV vacuolar myelopathy	Investigations: HIV test; CD4; viral load
Syphilis	Investigations: blood and CSF VDRL, TPHA
HTLV-1	Investigations: blood and CSF HTLV-1
Metabolic disorders	
B ₁₂ deficiency	Investigations: B ₁₂ , homocysteine
Cerebral palsy (spastic diplegia)	Birth history; non-progressive
Degenerative disorders	
Motor neuron disease (primary lateral sclerosis)	Investigations: MRI brain, cord; EMG/NCT ± CSF

Ataxia

Ataxia implies incoordination and results from disorders of:

- cerebellum and its associated pathways;
- loss of proprioceptive sensory input in peripheral nerve disorders and in spinal cord lesions affecting the posterior columns (sensory ataxia).

Cerebellar disease

Signs of cerebellar disease

- Gait ataxia—wide based, reeling. May be more apparent when turning or stopping suddenly. When mild, only tandem gait may be impaired.
- Dysmetria—an inability to perform acute finger to nose movements accurately with past pointing or a similar inability on heel/shin testing.
- Dysdiadokinesia—inability to perform rapid alternating movements.
- Tremor—intention or ‘hunting’ tremor (kinetic). Postural (static) tremors may also occur.
- Loss of rhythm—rapid tapping on the back of the hand or tapping the heel on the opposite knee.
- Hypotonia.
- Dysarthria—with slurred speech and a scanning dysarthria as words are broken up into syllables; impaired modulation of volume.
- Eye movements—broken up pursuit movements; overshooting or undershooting targets on saccadic eye movements (saccadic dysmetria). Macrosaccadic square wave jerks in primary position (sudden short duration movements laterally with rapid correction).
- Nystagmus—coarse nystagmus with the fast phase in the direction of the lesion; multidirectional nystagmus.
- Hyporeflexia.

Differential diagnoses of acquired cerebellar ataxia

- Toxic: alcohol.
- Drugs:
 - phenytoin;
 - lithium.
- Vascular:
 - ischaemic stroke;
 - haemorrhage.
- Inflammatory: demyelination (MS, ADEM).
- Neoplastic:
 - metastases (breast, bronchus);
 - primary brain tumours (in children, pilocytic astrocytoma and medulloblastoma);
 - paraneoplastic syndrome, associated with: small cell lung cancer (anti Hu, anti PCA2, ANNA 3); ovarian cancer (anti Yo), breast cancer (anti Yo and Ri), and testicular cancer (anti Ta/Ma2); Hodgkin's lymphoma (anti Tr); neuroblastoma (anti Hu); and thymoma (anti CRMP5/CV2).
- Infectious/post infectious:
 - viral cerebellitis (measles);
 - SSPE;
 - HIV;
 - Miller Fisher syndrome (ataxia, areflexia, ophthalmoplegia + GQ1b antibody).
- Prion: sporadic or variant CJD.
- Structural:
 - Arnold–Chiari malformation;
 - AVM;
 - basilar invagination (Paget's disease).
- Degenerative: cerebellar variant of MSA.
- Nutritional or GI related:
 - vitamin E deficiency;
 - thiamine (B₁ deficiency) in e.g. Wernicke's encephalopathy;
 - coeliac disease (with myoclonus).
- Endocrine: T4↓.

Differential diagnoses of hereditary cerebellar ataxias

- In general the autosomal dominant ataxias (ADCAs) and the other autosomal disorders that may have ataxia as an additional feature such as Huntington's disease, dentatorubral pallidoluysian atrophy (DRPLA), Gerstmann–Straussler–Scheinker (GSS) tend to present > 25 years of age.
- Autosomal recessive ataxias, inborn errors of metabolism, mitochondrial disorders, and episodic ataxias present < 25 years of age.

Autosomal dominant cerebellar ataxias (ADCA)

- At least 25 spinocerebellar ataxia genes. Ataxia in combination with any of the following—pyramidal, peripheral nerve, ophthalmoplegia, dementia. Absence of a family history does not exclude the possibility of diagnosis.
 - SCA 2—slow saccades, upper limb areflexia;
 - SCA 3—dystonia, parkinsonism, facial myokymia, bulging eyes;
 - SCA 6—'pure cerebellar syndrome';
 - SCA 7—pigmentary macular dystrophy.

Recessive ataxias—See Table 3.5.

Inborn errors of metabolism

- Hexoaminidase A or B deficiency.
- Adrenoleucodystrophy.
- Wilson's disease.

Episodic ataxias—See Table 4.20.

Mitochondrial disorders with ataxia

- NARP (neuropathy, ataxia, retinitis pigmentosa).
- MELAS (mitochondrial encephalopathy with lactic acidosis and stroke like episodes).
- MERRF (myoclonic epilepsy with ragged red fibres).

Sensory ataxia**Clinical features**

Any marked loss of proprioception will result in sensory ataxia.

- Signs of a neuropathy with loss of joint position sense.
- Pseudoathetosis of fingers when arms outstretched and eyes closed.
- Upper limb position sense loss is tested by attempting to bring both horizontally outstretched index fingers together in the midline with eyes closed.
- Heel shin testing deteriorates with eye closure.
- Positive Romberg's sign.

Table 3.5 Differential diagnoses of autosomal recessive cerebellar ataxias

Disease	Age of onset (range) yrs	Clinical/laboratory features	Genetics
Friedreich's ataxia	5–15 (0–60)	Kyphoscoliosis, pes cavus, lower limb areflexia, ↑ plantars, axonal neuropathy, cardiomyopathy, impaired GTT	Fratxin gene, chr 9q13
Ataxia telangiectasia	1–6 (0–20)	↓IgG and IgA (↑ infections), skin and conjunctival telangiectasia, oculomotor apraxia chorea, dystonia, hypogonadism, absent lower limb reflexes	ATM, chr 11q22.3
Ataxia with oculomotor apraxia type 1	2–6 (2–18)	Common in Japan, Portugal. Oculomotor apraxia, chorea, cognitive impairment, areflexia, severe axonal neuropathy. ↓ albumin, ↑ cholesterol, ↑ LDL, ↓ HDL	Aprataxin, chr 9p13.3
Abetalipoproteinaemia	2–17	Friedreich's phenotype + steatorrhea, retinitis pigmentosa, distal amyotrophy, acanthocytes, absent VLDL/LDL, ↓ cholesterol, ↓ vitamin A, E, K	Microsomal triglyceride transfer protein (MTP), chr 4q22
Ataxia with vitamin E deficiency	2–20 (2–52)	Friedreich's phenotype + head titubation. No cardiomyopathy or ↓ GTT. Vitamin E ↓	Alpha tocopherol protein, chr 8q13.

Differential diagnoses of sensory ataxia

- CIDP.
- Paraproteinaemic neuropathy (IgM).
- Refsum's disease (due to defect in phytanic acid metabolism. Other features include deafness, retinitis pigmentosa). A rarer defect of pristanate metabolism presents in a similar fashion (Massion Vernier disease).
- Sensory ganglionitis (paraneoplastic, Sjögren's syndrome, idiopathic).
- Friedreich's ataxia has a significant peripheral nerve component.
- Spinal cord disorders (affecting posterior columns):
 - cervical spondylosis;
 - demyelination (MS).

Acute visual failure

Monocular transient visual loss

- Amaurosis fugax due to emboli from carotid vessels or heart.
 - Sudden onset lasting 5–15 minutes. Described as a curtain being pulled downwards in front of the eye. Loss may be quadrantic or total and may be accompanied by contralateral limb signs due to ipsilateral hemispheric ischaemia.
- Closed angle glaucoma—accompanied by halos around lights and may not always be associated with redness and pain.
- Transient visual obscurations (TVO) are a grey-out precipitated by postural change or straining. Causes:
 - chronic papilloedema due to ↑ICP;
 - hypotension and hypoperfusion.
 - TVO that are gaze-evoked suggest orbital tumours.
- Retinal migraine is rare and results from transient vasospasm that responds to calcium channel blockers.

Bilateral, transient visual loss

- Usually due to transient visual cortical dysfunction.
- In patients under the age of 40 years this is most commonly due to migraine.
- Other causes include thromboembolism, hypotension, or hyperviscosity.
- In children may occur post-trauma or as part of the benign occipital epilepsy syndrome in childhood.

Non-progressive unilateral sudden visual loss

- Usually due to ischaemia of the optic nerve or retina.
- Anterior ischaemic optic neuropathy (AION) presents with infarction of the optic disc and is due to atherosclerosis or temporal arteritis.
- Optic nerve infarction due to embolism is rare.
- Retrobulbar optic nerve infarction (or posterior ischaemic optic neuropathy) occurs in the setting of cerebral hypoperfusion perioperatively.
- Central retinal artery or branch occlusion is due to emboli or arteriosclerosis. Field defects may be altitudinal, quadrantic, or total. A cherry red spot at the macula is pathognomonic.
- Central retinal vein occlusion occurs in hypertensives, diabetics or those with a thrombophilia. A haemorrhagic retinopathy results in a dense central scotoma with preserved peripheral vision.

- Idiopathic central serous chorioretinopathy results from leakage of fluid into the subretinal space. Symptoms include a positive scotoma (black or grey spot in the visual field), metamorphosia (distortion of images), or micropsia. Fluorecein angiography is necessary for diagnosis.
- Retinal and vitreous haemorrhage.

Non-progressive bilateral sudden visual loss

- Usually a result of an infarct in the visual radiation causing a homonymous hemianopia.
- Bilateral occipital infarcts can result in tubular or checkerboard visual fields or total cortical blindness.
- Anton's syndrome due to bilateral parieto-occipital infarcts causes cortical blindness accompanied by denial and confabulation.
- Leber's hereditary optic neuropathy.
 - Maternally transmitted mitochondrial disorder.
 - Mutations have been identified at positions 11778, 3460, 15257, and 14484.
 - Presentation is in young men with a rapid permanent loss of central vision.
 - In the acute phase typical findings include circumpapillary telangiectatic microangiopathy, pseudopapilloedema, an absence of fluorescein leakage, and marked arteriolar narrowing.

Visual loss of sudden onset with progression (unilateral)

Usually due to acute optic neuritis. Commonest cause is demyelination.

Typical symptoms

- Periocular pain and pain on eye movement.
- Progressive visual loss over a few days.
- Phosphenes or photopsias (spontaneous flashes of light) on movement.
- Spontaneous improvement in vision.
- Uhthoff's phenomenon—temporary decrease in VA with increased body temperature after a bath or exercise.
- Fading of vision and Pulfrich's phenomenon (misperception of the trajectory of moving objects).

Typical signs

- ↓ VA, colour vision, contrast sensitivity.
- Variety of field defects including centrocaecal scotoma.
- Relative afferent pupillary defect (RAPD).
- Optic disc may be normal or swollen.
- Associated uveitis or retinal perivenous sheathing.

Table 3.6 Differential diagnosis of acute optic neuritis

Diagnosis	Clinical features	Investigations
Corticosteroid responsive optic neuropathy		
Sarcoidosis	Progressive severe visual loss, often bilateral, isolated or part of a multisystem disorder. More common in Africans and Afro-Caribbeans. Relapse on steroid withdrawal.	Gadolinium-enhanced MRI brain and orbits, CSF, ANA, ACE, CXR, Gallium scan, tissue biopsy
SLE		
Autoimmune optic neuropathy		
Behçet's disease		
Neuromyelitis optica		
Other inflammatory causes		
Post infectious	Bilateral, childhood, good prognosis, swollen disc, macular star, spontaneous recovery	<i>Bartonella</i> , <i>Borrelia</i> , syphilis serology
Post vaccinal ADEM		
Neuro-retinitis		
Compressive optic neuropathy		
Tumours e.g. meningioma, glioma, pituitary adenoma	Painless, optic atrophy at presentation	MRI, biopsy
Metastases		
Thyroid ophthalmopathy	Painful	
Aneurysms		
Sinus mucocoeles		
Infectious optic neuropathy		
Syphilis	Progressive visual loss, disc oedema, vitreous cellular reaction	Serology, CSF, CXR, tuberculin test.
TB		
Lyme disease		
Viral optic neuritis		
Toxic and nutritional optic neuropathy		
Vitamin B12 deficiency	Bilateral, symmetrical	B ₁₂ , homocysteine
Tobacco-alcohol amblyopia		
Methanol intoxication	Poor prognosis	
Etambutol		
Cuban & Tanzanian epidemic opticomyelopathy		

Coma

Coma is the state of unrousable unconsciousness. The Glasgow Coma Scale (GCS) (p. 377) defines coma as:

- failure to open eyes in response to verbal command (E2);
- motor response no better than weak flexion (M4);
- incomprehensible sounds in response to pain (V2).

Neuroanatomy and neuropathology

Consciousness, which is the state of awareness of self and environment with the ability to respond appropriately to stimuli, results from:

- arousal (ascending reticular activating system);
- awareness (cerebral cortex).

Coma results from damage to the RAS in the brainstem or extensive bilateral cortical damage.

Aetiology

- Head injury.
- Medical causes of coma:
 - cerebrovascular disease (50%);
 - hypoxic–ischaemic injury (20%);
 - metabolic and infective (30%).

General assessment of coma

History Crucial to contact family, attending ambulance personnel. Obtain PMH, travel, drug details.

General examination

- Temperature (↑ or ↓).
- Pulse and BP (septicaemia, Addison's disease).
- Skin lesions (rash, needle marks, bruises, pigmentation).
- Respiration:
 - slow shallow breaths: drug intoxication;
 - deep rapid respiration: metabolic acidosis;
 - periodic respiration: cardiac failure, brainstem lesion;
 - rapid shallow respiration: brainstem lesion;
- Breath odour (alcohol, ketones, hepatic or renal failure).
- Abdominal examination (hepatosplenomegaly in liver or lympho proliferative disease, polycystic kidneys).
- Otoscopy (blood).

Neurological assessment

- Check for meningism (meningitis, SAH).
- Fundoscopy:
 - papilloedema;
 - subhyaloid haemorrhages (SAH);
 - retinopathy (diabetes, hypertension, infection e.g. choroidal tubercle, HIV).
- Level of consciousness (GCS). Note: if facial injuries or tracheostomy, verbal response unassessable.

Neurological examination: motor and sensory system

Look for asymmetry, evidence of significant cortical (decorticate) or brainstem (decerebrate) damage.

- Observe for seizure activity (focal or general: implies cortical damage)
- Tone
- Posture
- Reflexes, plantar responses
- Response to pain:
 - using a pen, press nail bed of finger and toe;
 - apply supraorbital pressure in case of damage to spinothalamic damage in limbs. Flexor response = cortical or upper brainstem injury; extensor response = brainstem injury.

Neurological examination: brainstem function

- Pupillary responses (with an appropriate bright light (not the ophthalmoscope).
 - Unilateral fixed dilated pupil (3rd nerve palsy due to tentorial herniation or PCom artery aneurysm).
 - Bilateral fixed dilated pupils: severe brainstem damage or atropine-like drugs used in resuscitation.
 - Midpoint, fixed = midbrain lesion.
 - Small pinpoint = pontine lesion (also opiates).
 - Small, reactive pupils = diencephalic (thalamus) lesion.
 - Horner's syndrome = hypothalamus, brainstem, or internal carotid artery lesion.
- Eye deviation.
 - Conjugate lateral deviation caused by ipsilateral frontal lesion or brainstem (PPRF) lesion.
 - Dysconjugate eyes due to III, IV, or VI palsy or brainstem lesion.
 - Skew deviation in brainstem lesions.
- Spontaneous eye movements.
 - Repetitive horizontal deviations (ping pong gaze) = brainstem lesion.
 - Retractory nystagmus (eyes jerk back into orbits) = midbrain lesion.
 - Downward ocular bobbing = pontine lesion.
- Reflex eye movements (see Fig. 3.2).
 - Oculocephalic manoeuvre. Head moved side to side—normally eyes deviate to opposite side. If brainstem affected eyes remain fixed.
 - Oculovestibular test. First check that tympanic membrane intact. Instill 50–200ml ice cold water into EAM: normal tonic response = eyes deviate to side of instillation with nystagmus and quick phase away from side of instillation. Dysconjugate or absent response = brainstem lesion.
- Corneal reflex.

Classification of coma***Coma without focal signs or meningism***

- Hypoxic–ischaemic injury
- Metabolic
- Toxic
- Post-ictal.

Coma with meningism.

- Meningoencephalitis
- SAH.

Coma with focal signs

- Haemorrhage
- Infarction
- Abscess
- Tumour
- Hypoglycaemia can cause focal signs.

Investigations

- Metabolic screen.
- CT scan or MRI if possible especially in coma with meningism or focal signs.
- A normal CT does not exclude ↑ ICP.
- EEG (see 'EEG and diffuse cerebral dysfunction', p. 440)
- If no contraindications consider LP.

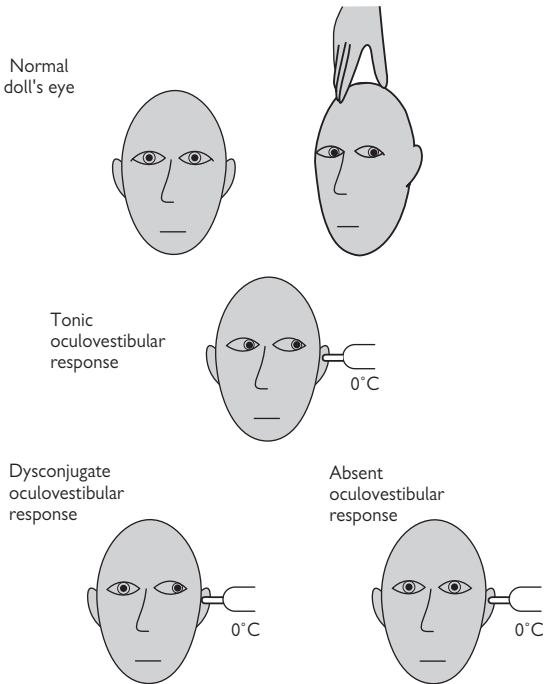


Fig. 3.2 Reflex eye movements. Reprinted with permission from Bates, D (2004). *Medicine*, 32(10), 69–74.

Coma prognosis

Neurologists are often asked to prognosticate on comatose patients in ITU in order that decisions about further active treatment can be made. The prognosis can be affected by aetiology, depth and duration of coma.

Aetiology

- Drug overdose patients have a good prognosis despite significant impairment of brainstem function.
- Likelihood of good recovery:
 - metabolic or infection, 25%;
 - hypoxic–ischaemic injury, 10%;
 - cerebrovascular disease or SAH, 5%.

Depth of coma

Within 6 hours:

- if eye opening, 20% chance of good recovery compared to 10% if no eye opening;
- no motor response, 3% ; if flexion or better, 15%;
- no noise, 8%; groaning, 30%.

Duration of coma

The chance of making a good recovery decreases with time.

- By day 3, 7% will make a moderate or good recovery.
- After day 14, 2%.
- Patients who remain in coma for > 7–15 days, will either die or remain in a vegetative state.

Prognostic signs

The data for prognostic signs in coma are poor. No one clinical sign can act as a predictor.

- At 24 hours, absence of both oculovestibular and corneal reflexes and extension to pain, in the absence of sedative drugs, chance of a good recovery is < 3%.
- Intact pupillary and corneal responses and localization to pain at 24 hours indicates a 40% chance of good recovery.

This page intentionally left blank

Excessive daytime sleepiness

- Epworth sleepiness scale (see box) is a useful tool in the clinic to assess the common complaint of sleepiness.
- Anyone with sleepiness causing problems with work and driving or an Epworth score of > 12 despite having > 7 hours sleep each night should be investigated.

Causes of persistent sleepiness

- Lack of sleep:
 - inadequate time in bed;
 - sleep disruption, e.g. babies;
 - shift work.
- Sleep disruption:
 - obstructive sleep apnoea/hypopnoea syndrome (OSAHS);
 - periodic limb movement disorder.
- Sleepiness with normal sleep:
 - narcolepsy;
 - idiopathic hypersomnolence;
 - neurological causes, e.g. tumours of hypothalamus, pineal, upper brainstem, bilateral paramedian thalamic infarcts, head injury, MS;
 - drugs;
 - psychological, e.g. depression, SAD.

Causes of intermittent sleepiness

- Kleine–Levin syndrome (episodic disorder associated with bulimia, hypersexuality).
- Catamenial hypersomnia.

Epworth Sleepiness Scale¹

Name:

Date:

Your age: (y)

Your sex: Male/Female

How likely are you to doze off or fall asleep in the situations described below, in contrast to feeling just tired?

This refers to your usual way of life in recent times.

Even if you haven't done some of these things recently, try to work out how they would have affected you.

Use the following **scale** to choose the most appropriate number for each situation:

- 0, would never doze
- 1, slight chance of dozing
- 2, moderate chance of dozing
- 3, high chance of dozing

Situation	Chance of dozing
Sitting and reading	—
Watching TV	—
Sitting, inactive in a public place (e.g. a theatre or a meeting)	—
As a passenger in a car for an hour without a break	—
Lying down to rest in the afternoon when circumstances permit	—
Sitting and talking to someone	—
Sitting quietly after a lunch without alcohol	—
In a car, while stopped for a few minutes in the traffic	—
Total	—

Score

- 0–10, normal range
- 10–12, borderline
- > 12/24 = abnormal

¹ Johns, MW (1991). *Sleep*, **14**, 540–5.

Obstructive sleep apnoea/hypopnoea syndrome (OSAHS)

- Commonest cause of sleepiness most often found in middle-aged and elderly men.
- Incidence: 20–50/100,000.
- Risk factors:
 - 50% are obese.
 - retrognathia—results from excessive relaxation of the upper airway muscles during sleep.
- Sleep fragmentation is due to repeated cycles of apnoea and arousal.
- Result is a sixfold increased risk of RTA but also hypertension, cardiac arrhythmias, and heart failure.
- Investigations include an overnight study of breathing pattern and oximetry. A limited study does not exclude the diagnosis and polysomnography may be necessary.
- Management includes:
 - weight loss
 - reduction of alcohol intake
 - most will require continuous positive airway pressure (CPAP).

Narcolepsy

- Classical tetrad:
 - sleepiness;
 - hypnagogic hallucinations;
 - sleep paralysis;
 - cataplexy.
- Onset in teens or 20s. Incidence: 0.2/100,000.
- Cause may be related to a reduction of hypocretin production from the hypothalamus.
- Sleepiness is characterized by irresistible sleep attacks in inappropriate situations such as whilst eating.
- Cataplexy is due to a sudden loss of muscular tone, falling to the ground, or head drop. Facial twitching may occur. Episodes last a few seconds but may be as long as 10 minutes. There is no loss of awareness. Triggers include emotional outbursts such as laughing.
- 85% of Caucasians are HLA DR2 DQw1⁺. (However, this is present in 22–40% in the normal population and lacks diagnostic specificity.)
- Multiple sleep latency test (MSLT) is the most useful investigation.

Treatment

- Sleepiness:
 - modafinil (200–800 mg/day);
 - mazindol (2–8 mg/day);
 - methylphenidate (10–100 mg/day);
 - selegeline (2.5–10 mg/day);
 - dexamphetamine (5–60 mg/day).

- Cataplexy, sleep paralysis, hypnagogic hallucinations respond to fluoxetine 20–40 mg/day, clomipramine 20–200 mg/day.

Periodic limb movement disorder

- Recurrent limb movements every 20–40 seconds during non-REM sleep.
- May be associated with daytime sleepiness.
- Associated with restless legs syndrome, which responds to dopamine agonists and levodopa preparations.

Tremor

- Definition: rhythmical, involuntary oscillatory movement of a body part.
- Normal physiological tremor 5–12 Hz (↑ anxiety, caffeine, T4↑).

Phenomenological classification

- Rest tremor.
- Action tremor—produced by voluntary contraction of muscle.
 - Postural tremor: present while maintaining posture against gravity.
 - Kinetic tremor—occurs during voluntary movement.
 - Intention tremor—occurs with target-directed movement with increase in amplitude at termination of movement (cerebellar).
 - Task-specific tremor, e.g. writing tremor.
 - Isometric tremor, e.g. orthostatic tremor.

Essential tremor

- Sporadic or autosomal dominant:
 - gene ETM1 on chr 3q13 and ETM2 on chr2p22–25;
 - DATscan may differentiate between ET and parkinsonian tremor.

Clinical features

- 50% + FH.
- Bilateral.
- Symmetrical.
- Postural or kinetic tremor of hands (e.g. tea cup).
- Associated with head tremor and/or voice tremor.
- 50% respond to alcohol.
- Slowly progressive.

Differential diagnosis

- Dystonic tremor (asymmetric, irregular).
- Parkinson's disease.
- Hyperthyroidism.
- Neuropathic tremor.

Management

- Propranolol up to 320 mg/day.
- Primidone up to 250 mg tds (side-effects common).
- Topiramate (up to 400 mg/day).
- Gabapentin (mixed results).
- Stereotactic surgery (lesional or deep brain stimulation) to VIM nucleus of thalamus should be considered in severe cases.

Dystonic tremor

Presentation

- Jerky irregular action tremor.
- Task-specific, e.g. writer's cramp with jerky spasms.

Management

- Botulinum toxin under EMG.
- Anticholinergic drugs.
- Propranolol and primidone.

Task-specific tremor

- Localized essential tremor, e.g. primary writing tremor.
- Affects writers, musicians, sports persons (golfers, dart players).

Consider:

- betablockers;
- anticholinergics;
- botulinum toxin.

Holmes' tremor (rubral, midbrain, thalamic tremor)

- Irregular low-frequency tremor at rest, posture, and intention.
- Involves proximal and distal arm muscles.
- Site of lesion thalamus to midbrain.
- Causes:
 - stroke;
 - AVM;
 - tumours;
 - demyelination.
- May respond to L-dopa or DA. Surgery as for ET.

Primary orthostatic tremor

- Presentation with unsteadiness on standing.
- Improves with walking.
- May be associated with cerebellar degeneration.
- Frequency 14–18 Hz.
- Tremor palpated or auscultated over calf muscles (helicopter rotor blades).
- Responds to clonazepam.

Neuropathic tremor

Usually with demyelinating neuropathy:

- AIDP;
- CIDP;
- IgM paraproteinaemic neuropathy;
- HMSN I;
- porphyria (paroxysmal tremor).

Characteristically an action tremor similar to ET. PET studies indicate cerebellar activity.

Drug-induced tremor

- Alcohol.
- Salbutamol.
- Lithium.
- Steroids.
- Cyclosporin.
- Sodium valproate.

Palatal tremor (low frequency 1–2 Hz)

Site of pathology is Guillain–Mollaret’s triangle formed by red nucleus, olives, and dentate nucleus.

- Essential (associated with clicking heard by patient due to contraction of tensor veli palatini in Eustachian tube).
- Symptomatic:
 - tumours;
 - Whipple’s disease;
 - neuroferritinopathy;
 - demyelination.

Psychogenic tremor

- May be sudden onset.
- Unusual combinations of rest and postural/intention tremor.
- Decrease in amplitude and frequency with distraction.
- ‘Entrainment’—change in frequency during voluntary contraction or movements of contralateral hand.
- External loading ↑ amplitude, whereas PD and ET ↓.
- Coactivation—resistance to passive movement with change in tone and tremor.
- Past history or other features of somatization or conversion disorder.

This page intentionally left blank

Tics

- Rapid, stereotypic involuntary movements.
- Can be voluntarily suppressed but suppression leads to build up of internal tension.
- Triggered by stress or boredom.
- Male preponderance (3:1).
- Peak age of onset around 7 years.
- Causes:
 - Gilles de la Tourette syndrome;
 - neuroacanthocytosis;
 - neuroleptics;
 - common in Asperger's patients;
 - head trauma.

Patients present with the following.

- Motor tics:
 - eye winks;
 - eye blinks;
 - grimaces;
 - head tosses;
 - sniffs;
 - throat clearing.
- Vocal tics:
 - foul utterances (coprolalia);
 - repeating sounds or words (echolalia).

Resolution usually occurs at the end of adolescence.

Treatment

- When mild, no treatment.
- If socially disabling:
 - clonazepam;
 - neuroleptics but side-effect of tardive dyskinesia;
 - reserpine;
 - tetrabenazine.

This page intentionally left blank

Chorea and athetosis

- Chorea: continuous flow of irregular, brief, jerky, flowing movements.
- Athetosis—slower, flowing movements.
- May be incorporated into semi-purposeful movements.

Causes

- Hereditary:
 - Huntington's disease;
 - benign hereditary chorea;
 - neuroacanthocytosis;
 - Wilson's disease;
 - SCA;
 - ataxia telangiectasia;
 - mitochondrial disease (Leigh's disease).
- Infection:
 - Sydenham's chorea (post-streptococcal);
 - HIV;
 - SSPE;
 - vCJD.
- Vascular (often hemichorea):
 - infarction;
 - polycythaemia.
- Metabolic:
 - hyper- and hypoglycaemia;
 - hyperthyroidism;
 - hypocalcaemia.
- Immunological:
 - SLE
 - anti-phospholipid syndrome
 - pregnancy—chorea gravidarum
- Drug-induced:
 - anti-Parkinsonian drugs;
 - dopamine antagonists drugs, e.g. phenothiazines;
 - oral contraceptive (previous history of Sydenham's chorea);
 - amphetamines, cocaine.

Treatment

- Neuroleptics, e.g. sulpiride, risperidone, olanzapine.
- Tetrabenazine (side-effect: depression).

This page intentionally left blank

Myoclonus

Sudden shock-like involuntary movement:

- Positive myoclonus: brief muscle contraction.
- Negative myoclonus: pause in muscle activity (asterixis).

Classification

- Distribution:
 - generalized;
 - focal;
 - multifocal;
 - segmental.
- Clinical presentation:
 - spontaneous;
 - action;
 - reflex (auditory, visual, or to touch).
- Site of origin:
 - cortical;
 - brainstem;
 - spinal cord.

Aetiology

Physiological

- Hypnic jerks
- Hiccup.

Epileptic

- Focal epilepsy
 - EPC.
- Myoclonic epilepsies:
 - progressive myoclonic epilepsy (Unverricht–Lundborg disease).

Encephalopathies

- Metabolic (liver, renal failure).
- Infections.
 - prion diseases;
 - HIV;
 - SSPE;
 - post-anoxic;
- Drugs, e.g. tricyclics, L-dopa.

Degenerative conditions

- Alzheimer's disease
- MSA
- Corticobasal degeneration
- Cerebellar degeneration—Ramsay Hunt syndrome (e.g. coeliac disease).

Hereditary

- HD.
- Mitochondrial disorders.
- Myoclonic dystonia (DYT 11).
- Storage disorders:
 - Lafora body disease;
 - sialidosis;
 - ceroid-lipofuscinosis (Batten's, Kuf's disease);
 - lipidosis (Tay–Sachs, Krabbe's disease).

Focal lesions brain or spinal cord.

Cortical myoclonus

- Myoclonic jerks triggered by movement or stimulus-sensitive.
- Distal muscles most affected.
- EEG may be diagnostic:
 - cortical discharges time-locked to myoclonic jerks;
 - giant cortical somatosensory evoked potentials.

Brainstem myoclonus

- Bilateral synchronous jerking with adduction of arms, flexion of elbows, flexion of trunk and head.
- Stimulus-induced: tap nose, lip, head or loud noise.

Aetiology

- Paraneoplastic.
- Brainstem encephalitis.
- MS.
- Encephalomyelitis with rigidity.

Spinal myoclonus

Two types.

- 1 Rhythmic, repetitive, bilateral, jerking one or two adjacent parts. Persist during sleep.
- 2 Propriospinal myoclonus:
 - usually trunk muscles—flexion;
 - prominent when lying down;
 - stimulus-sensitive.

Aetiology

- Inflammatory cord lesion.
- Tumour.
- Trauma.

Treatment of myoclonus

- Clonazepam—250 µg starting dose.
- Sodium valproate.
- Piracetam or levetiracetam.

Dystonia

Syndrome caused by sustained muscle contraction resulting in twisting and repetitive movements or postures that are due to co-contraction of antagonistic muscles.

- Focal dystonia: one body part.
- Segmental: two or more adjacent body parts.

Classification

- Primary dystonias. Dystonia and dystonic tremor only clinical manifestation.
 - DYT1 dystonia (see 'Inherited movement disorders', p. 278);
 - sporadic, usually adult onset.
- Dystonia plus syndromes:
 - dopa-responsive dystonia (DRD) (see 'Inherited movement disorders', p. 278);
 - myoclonic dystonia.
- Heredodegenerative syndromes:
 - Wilson's disease;
 - HD (see 'Inherited movement disorders', p. 278);
 - SCA (see 'Hereditary ataxias', p. 266);
 - Lubag (dystonia–parkinsonism);
 - early onset PD (PARKIN 2); (see 'Inherited movement disorders', p. 278);
 - Hallervorden–Spatz;
 - neuroacanthocytosis (also chorea, orofacial dyskinesias, axonal neuropathy, CPK ↑, tongue biting, seizures, and cognitive decline);
 - Lesch–Nyhan syndrome.
- Degenerative syndromes:
 - MSA;
 - PSP;
 - CBD.
- Secondary dystonias:
 - perinatal trauma/hypoxia;
 - stroke;
 - focal lesions especially putamen or rostral midbrain.

Investigations

- Exclude Wilson's disease:
 - serum copper and caeruloplasmin levels;
 - 24 hour urinary copper;
 - slit lamp examination for Kayser–Fleischer rings.
- Onset < 25 years check DYT1 gene.
- MRI especially in generalized or hemidystonia dystonia, additional neurological signs.
- Consider other genetic tests as above (e.g. HD, SCA).
- **Fresh** blood films for acanthocytes × 3 (neuroacanthocytosis).

Management

- Consider trial of L-dopa in any patient with onset < 40 years, especially childhood or adolescent, for DRD.
- Anticholinergic drugs, e.g. benhexol up to 80 mg/day.
- If unhelpful, especially in generalized dystonia, consider:
 - tetrabenazine;
 - pimozide;
 - sulpiride.
- Thalamic (GPi) deep brain stimulation may be an option.
- Focal dystonia—local botulinum toxin (cervical dystonia, blepharospasm, task-specific dystonias, laryngeal dystonia).

- Cerebrovascular disease: stroke 104
- Management of stroke 108
- Prevention of ischaemic stroke 110
- Cerebral venous thrombosis 112
- Images in cerebrovascular disease 114
- Dementia: introduction 124
- Alzheimer's disease 126
- Frontotemporal dementia 128
- Other dementias 130
- Creutzfeldt–Jakob disease (CJD) 132
- Epilepsy: introduction 136
- Management of epilepsy 138
- Women and epilepsy 142
- Seizures versus dissociative non-epileptic attack disorder (NEAD) or pseudoseizures 144
- Management of status epilepticus 146
- Headache: migraine—introduction and clinical features 148
- Migraine: differential diagnosis, investigations, and IHS criteria 150
- Management of acute migraine: the stepped care regimen 152
- Management of migraine prophylaxis 154
- Migraine and women 156
- Primary short-lasting headaches 160
- Cluster headache 162
- Trigeminal neuralgia 164
- Idiopathic intracranial hypertension (IIH) 166
- Parkinsonism and Parkinson's disease: introduction 170
- Clinical features of parkinsonism and PD 172
- Differential diagnosis of PD and investigation 174
- Drug-induced parkinsonism 178
- Medical management of PD 180
- Surgical treatment of PD 184
- Management of other problems in PD 186
- Multiple system atrophy (MSA) 188
- Progressive supranuclear palsy (PSP) 190
- Corticobasal degeneration (CBD) 192
- Peripheral nerve disorders: introduction and clinical approach 194
- Diagnosis of peripheral nerve disorders 196
- Investigations in peripheral nerve disorders 198
- Diabetic neuropathies 200
- Guillain–Barré syndrome (GBS) 202
- Chronic inflammatory demyelinating polyneuropathy (CIDP) 206

Neurological disorders

- Multifocal motor neuropathy with conduction block (MMN-CB) 210
- Vasculitic neuropathy 212
- Muscle disorders: classification and features 214
- Muscle disorders: investigations 216
- Dermatomyositis, polymyositis, and inclusion body myositis 220
- Motor neuron disease: introductions and clinical features 224
- Motor neuron disease: investigations and management 226
- Multiple sclerosis: introduction and clinical features 228
- Multiple sclerosis: investigations and diagnosis 230
- Multiple sclerosis: management 236
- Myasthenia gravis: introduction, clinical features, and investigations 238
- Myasthenia gravis: management 240
- Paraneoplastic disorders: introduction 244
- Paraneoplastic syndromes: central nervous system 246
- Paraneoplastic syndromes: peripheral nervous system 250
- Paraneoplastic syndromes: investigations and management 252
- Vertigo, dizziness, and unsteadiness: introduction 254
- Dizziness, unsteadiness, or 'off balance': neurological causes 256
- Benign paroxysmal positional vertigo (BPPV) 258
- Dizziness, unsteadiness, or 'off balance': non-neurological causes 262
- Neurogenetic disorders: introduction 264
- Hereditary ataxias 266
- Genetic neuropathies 268
- Inherited myopathies 272
- Myotonic dystrophy (MD) 276
- Inherited movement disorders 278
- Inherited mitochondrial disorders 280
- Inherited dementias 282
- Inherited neurocutaneous syndromes 284
- Hereditary metabolic diseases 286
- Infectious disease: bacterial meningitis 288
- Viral encephalitis 292
- Neurology of HIV/AIDS 296
- Neurological disorders due to HIV 298
- Opportunistic infections associated with HIV 300
- MRI images in infectious diseases 304
- Lumbar puncture 308
- Intravenous immunoglobulin (IV Ig) 312
- Diagnosis of brainstem death 314

Cerebrovascular disease: stroke

- Third most common cause of death worldwide and most common cause of neurological disability.
- Incidence 240/100,000/year.
- Defined by the rapid onset of focal neurological deficit due to infarction or haemorrhage lasting more than 24 hours.
- Transient ischaemic attack (TIA)—symptoms and signs resolve within 24 hours.
- However, these definitions may change as newer treatments, such as thrombolysis given earlier, become routine.
- Early risk of stroke after TIA or minor stroke is high:
 - 7 day risk, 8–12%.
 - 30 day risk, 18%.

Aetiology

Ischaemic stroke (80%)

- Atherothromboembolism:
 - carotid and vertebral stenosis;
 - intracranial stenosis;
 - aortic arch atheroma.
- Cardioembolism.
- Small vessel disease (lacunar stroke).
- Arterial dissection.
- Inflammatory vascular disorders:
 - giant cell arteritis;
 - systemic vasculitides, e.g. SLE;
 - primary angiitis.
- Haematological disorders:
 - antiphospholipid syndrome;
 - thrombophilic states.
- Genetic disorders:
 - CADASIL;
 - mitochondrial disorders, e.g. MELAS;
 - sickle cell disease.
- Infections:
 - meningitis, e.g. TB;
 - HIV.
- Others:
 - migraine;
 - COC, pregnancy.

Cerebral haemorrhage

Intracerebral haemorrhage

- Small vessel disease.
- AVM.
- Amyloid angiopathy.

- Tumours.
- Cerebral venous thrombosis.
- Haematological disorders:
 - anticoagulants, antiplatelet drugs, and thrombolytic therapy;
 - coagulation disorders.
- Drug abuse, e.g. cocaine.
- Moya moya syndrome.

Subarachnoid haemorrhage

- Aneurysm.
- Trauma.

Risk factors see Table 4.1

Clinical features

Anterior circulation (carotid territory)

- Amaurosis fugax/retinal infarction.
- Hemiparesis.
- Hemisensory loss.
- Hemianopia (optic tract and radiation).
- Dysphasia.
- Sensory inattention.
- Visual inattention.

Table 4.1 Relative risk (RR) of stroke

Risk factors	RR
Age (> 75 versus 55–64 years)	5
Hypertension (160/95 versus 120/80)	7
Smoking	2
Diabetes	2
IHD	3
AF	5
Previous TIA	5

Posterior circulation (vertebrobasilar)

- Ataxia.
- Cranial nerve involvement:
 - diplopia;
 - facial sensory loss;
 - LMN facial palsy;
 - vertigo;
 - dysphagia;
 - dysarthria.
- Hemiparesis (may be bilateral).
- Hemisensory loss (may be bilateral).
- Hemianopia (occipital lobe).
- Cortical blindness—basilar artery occlusion.

Lacunar strokes result in:

- pure motor strokes (face, arm, and leg) in the posterior limb of internal capsule;
- pure sensory stroke (thalamus);
- ataxic hemiparesis (weakness and ataxia affecting the same side) due to a pontine lesion;
- clumsy hand/dysarthria due to a lesion in the pons or in its internal capsule.

Investigations

Blood tests (first-line)

- FBC and ESR.
- Ca^{2+} (hypo- or hypercalcaemia may be a cause of focal deficit).
- U & E, creatine, LFT.
- Glucose.
- Thyroid function.
- Cholesterol.
- Clotting screen.

Blood tests (second-line)

- Thrombophilia screen:
 - protein C, S, and antithrombin III defects;
 - factor V Leiden mutation 20210GA;
 - antiphospholipid antibody;
 - lupus anticoagulant.
- Blood cultures (BE).
- Homocysteine.
- Lactate.
- Cardiac enzymes.

Other investigation

- Urine analysis (diabetes, haematuria in BE or vasculitis, toxicology screen).
- ECG (AF, MI).
- Echocardiogram and TOE.

Imaging

- Should be performed within 24 hours to exclude haemorrhagic stroke and other causes, e.g. tumours.
- CT: reveals appropriate lesion in 50%.
- MRI: may not show haemorrhage in first few hours.
- T2-weighted images show lesions in 90% by 24 hours.
- Multiple infarcts suggest cardioembolism or vasculitis.
- Diffusion-weighted images (DWI) show changes within minutes.
Useful to distinguish acute from chronic changes.
- Imaging of extracranial vessels should be performed in all patients with TIA or mild to moderate stroke affecting carotid circulation:
 - carotid ultrasonography;
 - MR or CT angiography (MRA/CTA).

Management of stroke

General management

- Admission to a stroke unit has been shown to reduce mortality by 30% and improve outcome.
- Blood pressure: cerebral autoregulation is disturbed after stroke. Optimal management uncertain but consider treatment if sustained BP > 220/120 in infarction and 185/115 in cerebral haemorrhage. Lower levels in the acute stage should not be treated unless coexistent with hypertensive encephalopathy, aortic dissection, acute MI, or LVF.
- Oxygenation: no data available but O₂ should be given if saturation < 92%.
- Control of blood glucose: hyperglycaemia in acute stroke associated with poor outcome. Maintain normal levels with insulin if necessary.
- Pyrexia is usually due to infection, which should be treated, but may be due to very large infarcts.
- Swallowing and nutrition: if abnormal swallow arrange SALT assessment. Consider NG tube or PEG tube feeding. Advice from dietician for nutritional support.
- Physiotherapy: early mobilization and rehabilitation to minimize physical deterioration, restore function, and develop strategies for coping with impairment.
- DVT prevention: avoid dehydration. Compression stockings. Consider use of thromboprophylaxis if prolonged immobilization with SC heparin after 2–4 weeks. No controlled data on this issue.
- Seizures occur in 2%—focal or generalized. Conventional AED for recurrent events.
- Depression and neuropsychiatric complications such as emotional lability in 50%. Use TCA or SSRIs.

Specific treatment of acute stroke

Acute ischaemic stroke

- Thrombolysis:
 - beneficial in patients with major stroke and a large ischaemic penumbra within 3 hours of onset;
 - ineffective or even harmful in extensive completed stroke with a small penumbra;
 - major complication is haemorrhagic transformation. Risk factors include extensive infarction on early CT and uncontrolled BP;
 - intravenous recombinant tissue plasminogen activator (r-TPA) given within 3 hours improved outcome despite an increased risk of haemorrhage (NINDS trial). Most benefit obtained if given within first 90 minutes but benefit may occur up to 6 hours. Current guidelines suggest treatment should be undertaken in specialized centres only. Service organization a major barrier at present.
- Antiplatelet drugs:
 - aspirin started within 48 hours reduces mortality and recurrent stroke.
 - CT first to exclude haemorrhage. Loading dose 300 mg followed by 75–150 mg daily. If intolerant of aspirin use clopidogrel.

- Anticoagulation:
 - immediate treatment with heparin reduces DVT and PE but associated with increased risk of cerebral haemorrhage;
 - AF or other cardioembolic cause treat with aspirin and start oral anticoagulation after at least 2 weeks;
 - at present no data on heparin in dissection.
- Surgery: hemicraniectomy may be considered in raised intracranial pressure (malignant MCA occlusion). Posterior fossa craniectomy for large cerebellar infarcts. No trial evidence for these procedures.

Acute intracranial haemorrhage

- Stop anticoagulants and antiplatelet drugs. Correct coagulation deficits.
- Cerebellar haemorrhage may cause hydrocephalus due to aqueduct compression. Referral to neurosurgeon for decompression and/or shunting.
- Results from STICH trial comparing supratentorial haemorrhage treated by surgery versus conservative management are awaited.

Prevention of ischaemic stroke

Primary prevention

Atheroembolism

- Avoidance and treatment of risk factors:
 - hypertension;
 - diabetes;
 - smoking;
 - hypercholesterolaemia.
- The risk of stroke in patients with asymptomatic carotid stenosis is much less than in those with symptomatic stenosis—2% per annum versus 15% in the first year.
- The Asymptomatic Carotid Surgery Trial (ACST) found a significant reduction in stroke risk after surgery but 32 patients would have to be operated upon to prevent one stroke or death over 5 years. A high-risk subgroup who would benefit needs to be identified using specialized radiological techniques.
- AF: non-rheumatic AF risk of stroke ↑ five fold. ↑ if other risk factors present:
 - increasing age;
 - hypertension;
 - impaired LV function;
 - valve disease;
 - diabetes.
- High risk: 8–12% annual stroke risk if age >75 years, diabetes, hypertension. Warfarin with target INR 2–3 reduces stroke risk by 60%. If warfarin contraindicated use aspirin.
- Low risk: 1% annual stroke risk. If age < 65 years and no other risk factors use aspirin.

Primary intracerebral haemorrhage Hypertension major risk factor.

Secondary prevention

- Lifestyle changes, e.g. smoking, weight, and alcohol reduction.
- BP: PROGRESS trial showed ↓ in haemorrhagic and ischaemic stroke using perindopril and indapamide even if BP normal. Caution in those with severe bilateral carotid or vertebral disease.
- Cholesterol lowering if > 5–5.5 mmol in Heart Protection Study ↓ risk of stroke and other vascular events in patients with previous ischaemic stroke, coronary, or peripheral vascular disease.
- Antiplatelet drugs:
 - aspirin (75–300 mg) reduces the risk of recurrent stroke and vascular death by 18%.
 - clopidogrel (75 mg) may be slightly more effective and should be used in those intolerant of aspirin.
 - dipyridamole slow-release monotherapy as effective as aspirin.
 - combination of aspirin + dipyridamole (200 mg) may be more effective than aspirin alone.

- Warfarin has no benefit for secondary prevention in patients in sinus rhythm.
- AF patients should be anticoagulated after stroke.
- Surgical/endovascular treatment:
 - carotid endarterectomy highly beneficial in those with > 70% stenosis; moderately beneficial for those with 50–69%.
 - higher risk of stroke and therefore benefit in those with recent symptoms, ulcerated plaque, and hemisphere presentation rather than amaurosis fugax;
 - Early surgery in the first few weeks (3–6) after TIA or minor stroke becoming more common.
 - Operative mortality 1.1%; operative risk of stroke approximately 5%.
 - Carotid angioplasty and stenting currently being evaluated.

Cerebral venous thrombosis

Epidemiology

- Incidence 0.22/100,000.
- Most frequent in neonates. Women > men.
- Risk factors:
 - pregnancy and puerperium;
 - oral contraceptive pill;
 - ENT infections;
 - cancer;
 - prothrombotic states;
 - dural AV fistulae.

Clinical features

- ↑ ICP as idiopathic intracranial hypertension:
 - headache;
 - visual obscurations;
 - papilloedema;
 - VIth nerve palsy.
- Focal neurological deficit:
 - hemiparesis;
 - dysphasia;
 - seizures.
- Diffuse encephalopathy:
 - delirium;
 - coma;
 - seizures;
 - multifocal neurological deficits.
- Cavernous sinus syndrome
 - III, IV, VI, V¹ palsy;
 - proptosis.

Investigations

- Imaging. See 'Cerebrovascular disease' in p. 486–8.
- Lumbar puncture:
 - after exclusion of mass lesion;
 - OP > 20 cm CSF.

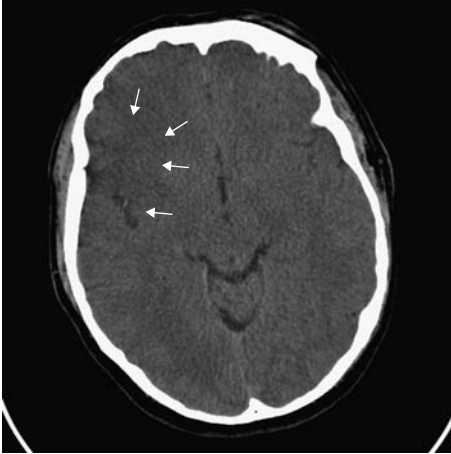Management

- Treat associated infection.
- Anticoagulation with heparin followed by warfarin for 6 months. Lifelong if prothrombotic conditions exist.
- If not responding or deteriorating, consider local thrombolysis therapy.
- ↑ ICP:
 - repeated LP or external lumbar drain or lumbo-peritoneal shunt;
 - mannitol;
 - if not responding or deteriorating consider sedation, ventilation, and decompression craniectomy.
- Seizures: IV phenytoin or valproate.

This page intentionally left blank

Images in cerebrovascular disease

(a)



(b)

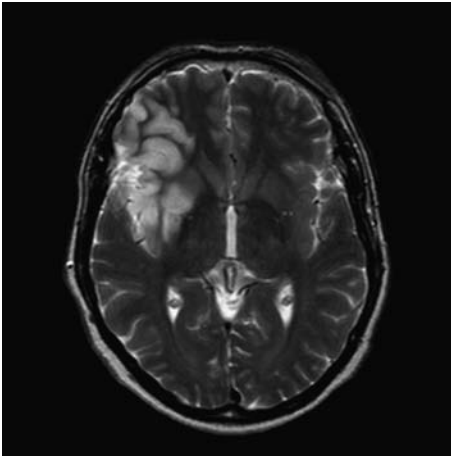


Fig. 4.1 Acute right MCA territory infarct. (a) Non-enhanced CT; (b) T2 axial MRI (c) DWI; and (d) ADC map. (a): Subtle low attenuation in the right inferior frontal gyrus, frontal operculum, insular cortex, and putamen (*white arrows*) consistent with acute ischaemia. (b) T2 sequence shows gyral expansion, with effacement of local CSF spaces and abnormal signal in the corresponding area.

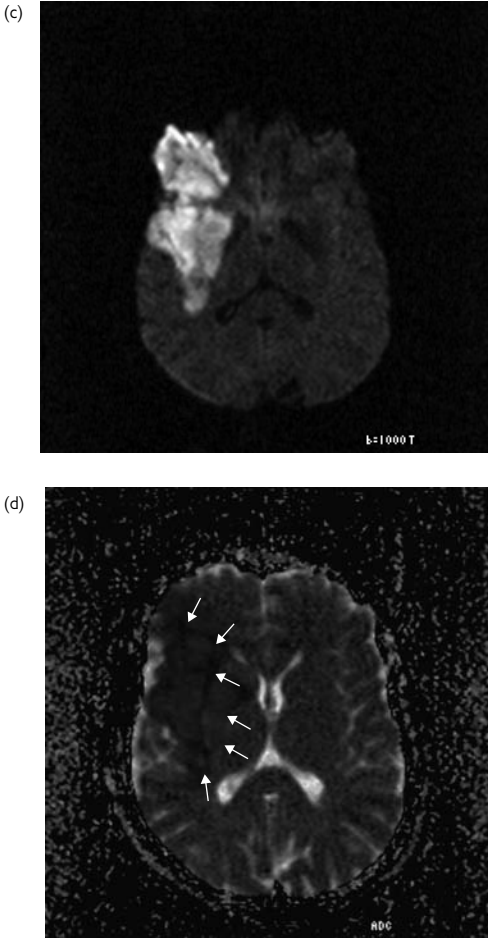
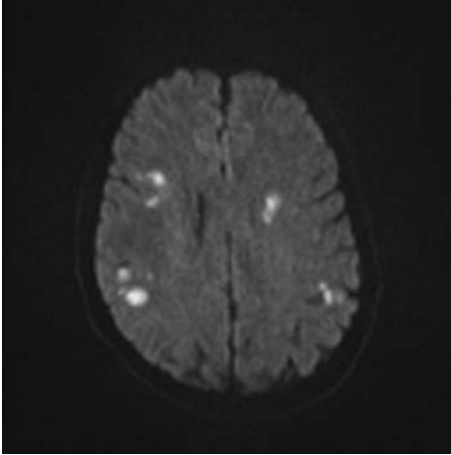


Fig. 4.1 (c) and (d) Restriction of diffusion with hyperintensity on DWI and hypointensity on ADC corresponds with an acute infarct (*white arrows*).

(a)



(b)

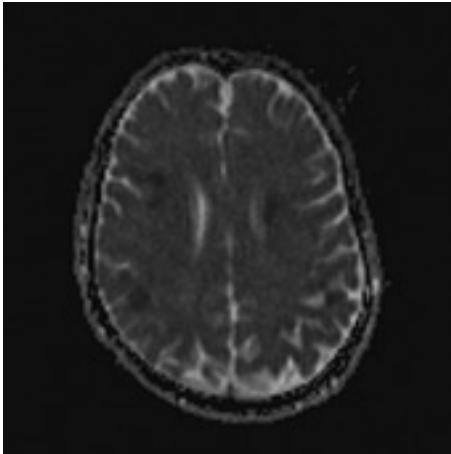


Fig. 4.2 Acute embolic infarcts in patient with atrial fibrillation. (a) DWI axial and (b) ADC map. (a) Multiple small hyperintense areas on DWI consistent with restriction of diffusion. (b) Matching low signal on ADC map. Mainly cortical in distribution. Typical appearances for acute embolic infarcts. Subsequent echocardiogram revealed left atrial thrombus.

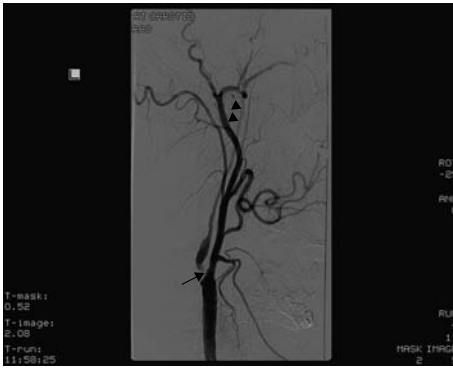


Fig. 4.3 Critical stenosis of internal carotid artery (catheter angiogram). Tight stenosis at the origin of the ICA with a narrow jet of flow through the stenotic segment (arrow). The calibre of the distal ICA is narrowed due to reduced flow a degree of vessel collapse (arrowheads).

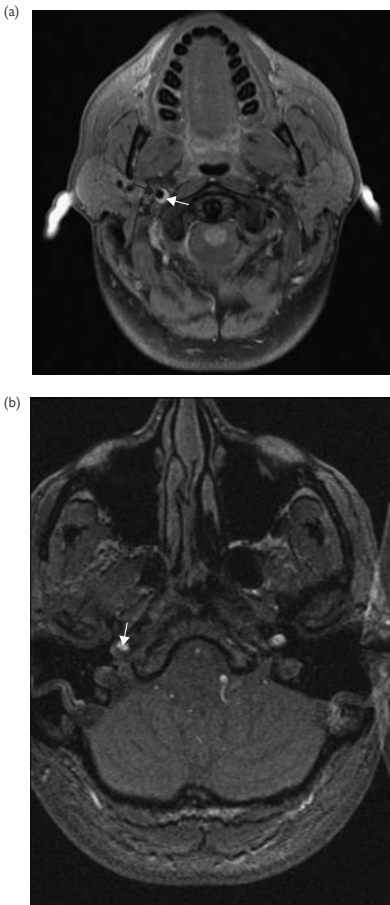


Fig. 4.4 Carotid artery dissection. (a) Fat-saturated T1 axial and (b) axial source image from three-dimensional time of flight MRA. (a) Expanded right ICA at the skull base with an eccentrically placed lumen, denoted by the flow void (*black arrow*), and a crescent of hyperintensity (methaemoglobin) indicating intramural haematoma (*small white arrows*). Typical appearances of a dissection. (b) Note that the MRA (at a higher level) only demonstrates flow in the eccentric true lumen dissection (*white arrow*).

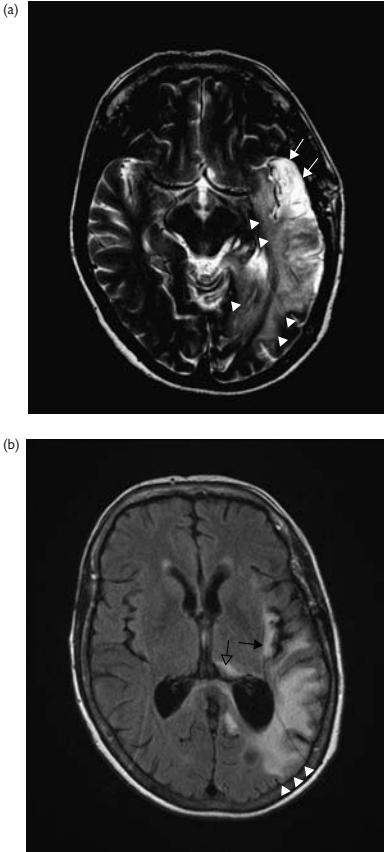


Fig. 4.5 Cerebral vasculitis. (a) Axial T2-weighted and (b) axial FLAIR MRI. Extensive area of signal abnormality involving the left temporal, inferior parietal and occipital lobes with involvement of both grey and white matter. (a) More established area of damage shown in the lateral and anterior aspects of the left temporal lobe (*white arrows*) while (b) more acute involvement is shown in the left inferior parietal lobule/posterior temporal lobe (*white arrowheads*). (a) There is extensive involvement of the white matter (*white arrowheads*) and (b) involvement of the left insular cortex (*black arrow*), posterior nuclei of the left thalamus (*open black arrow*), and left occipital lobe. The distribution does not conform to a vascular territory and the disease process has relatively little associated mass effect.

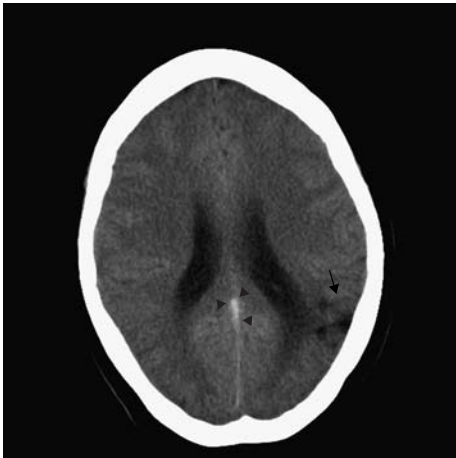


Fig. 4.6 Straight sinus thrombosis (non-enhanced CT). Hyperdense and expanded straight sinus (*black arrowheads*). Note mature venous infarct in left inferior parietal lobe (*black arrow*).

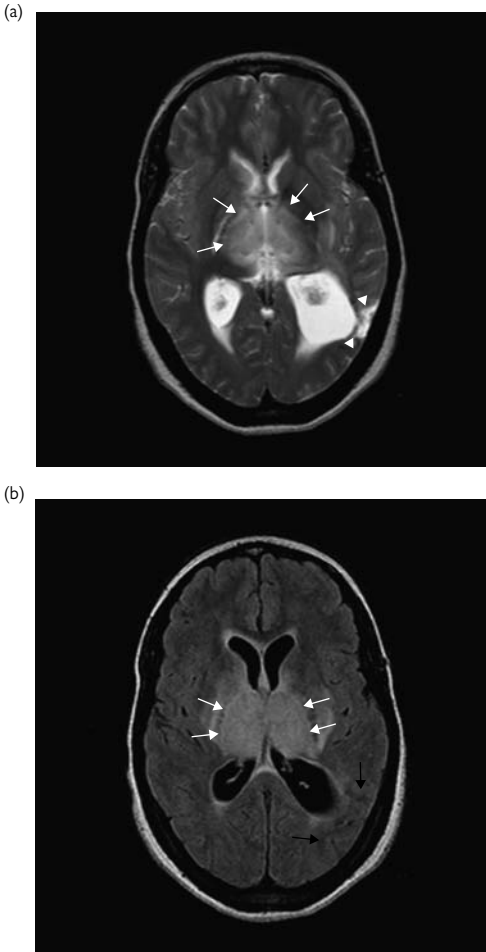


Fig. 4.7 Straight sinus thrombosis: (a) axial T2 and (b) FLAIR. Abnormal hyperintensity within both thalami and posterior aspects of the lentiform nuclei (*white arrows*). Note the mature damage in the left inferior parietal lobe due to a previous venous infarct (*white arrowheads T2; black arrows FLAIR*).

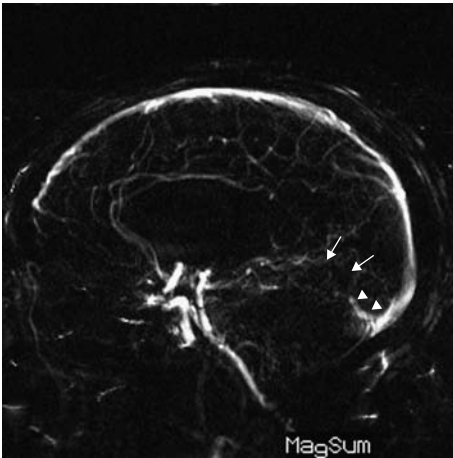


Fig. 4.8 Straight sinus thrombosis (phase contrast MRV). Absent flow-related signal in the straight sinus in keeping with thrombosis and occlusion (*arrows*). Flow within the distal portion of the straight sinus preserved (*arrowheads*).

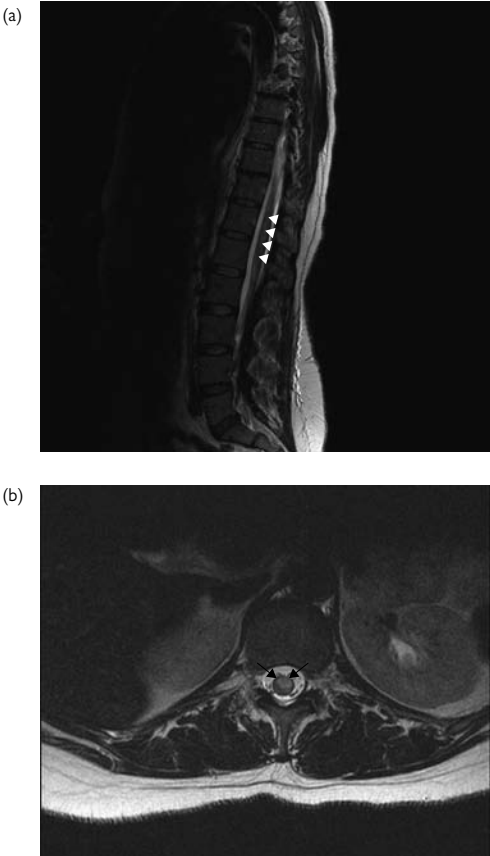


Fig. 4.9 Lower spinal cord infarct. (a) Sagittal T2 weighted and (b) axial T2 weighted MRI. Subtle hyperintensity and expansion is demonstrated in the terminal spinal cord (*closed white arrowheads*). (b) Axial imaging reveals signal abnormality involving the anterior two-thirds of the cross-sectional profile of the spinal cord (*black arrows*), typical for an anterior spinal artery territory infarct.

Dementia: introduction

Dementia is defined as a syndrome of progressive impairment in two or more areas of cognition sufficient to interfere with work, social function, or relationships. The areas of cognition included in the definition are:

- memory;
- language;
- abstract thinking;
- praxis;
- visuospatial or perceptual skills;
- personality;
- social behaviour.

Epidemiology At 60 years of age 1% of the population is affected; 40% of those > 85 years. High levels of education may be protective.

Aetiology

Common

- Alzheimer's disease (70%).
- Cortical Lewy body disease (20%).
- Frontotemporal dementia (10%).
- Cerebrovascular disease.

Rarer causes

- Corticobasal degeneration (see 'Corticobasal degeneration (CBD),' p. 192).
- CJD.
- CADASIL (cerebral autosomal dominant arteriopathy with subcortical infarcts and leucoencephalopathy).

Treatable causes

- Depressive pseudodementia.
- Normal pressure hydrocephalus.
- B₁₂ deficiency.
- Hypothyroidism.
- Syphilis.
- HIV.
- Benign tumours, e.g. subfrontal meningioma.
- Subdural haematoma.

Investigations

First-line

- FBC, ESR.
- Routine chemistry.
- T4.
- B₁₂.
- VDRL, TPHA.
- CXR.
- CT or (preferred) MRI.
- Formal neuropsychological assessment.

Second-line

- CSF examination.
- HIV.
- Genetic testing.
- EEG.
- Volumetric MRI.
- SPECT.
- Brain biopsy.

Alzheimer's disease

Epidemiology

- Incidence: 1.2 per 1000 person years among 65–69-years-olds, ↑ to 53.5 in those >90 years.
- Prevalence 4.4% in those >65 years.
- Affects F>M.
- Most common > 65 years.

Pathology

Generalized cortical atrophy, especially temporal lobes. Deposits of amyloid A4 protein in cortex with neuritic plaques. Neurofibrillary tangles contain tau and ubiquitin proteins. In cases of amyloid angiopathy, amyloid is found in vessels walls.

Genetics

Familial cases tend to present at a younger age. Familial autosomal dominant cases associated with mutations in 3 genes:

- APP gene (amyloid precursor protein) on chr 21;
- presenilin 1 and 2;
- homozygous apolipoprotein E ε 4.

Clinical features

- Memory impairment. Episodic (personal experiences) and semantic (store of conceptual and factual knowledge) are affected. Complaints of forgetting day to day events, learning new information. Recent past > distant past.
- Visuospatial impairment, e.g getting lost when driving.
- Constructional and dressing apraxia.
- Language impairment, e.g. word-finding difficulties. Alexia, agraphia, acalculia.
- Mini-mental state examination (MMSE). Insensitive but practical.
- Physical signs:
 - mild akinetic rigid syndrome;
 - myoclonus.

Investigations

- EEG: mild slowing in moderate disease. Non-specific.
- MRI to exclude treatable causes, e.g. hydrocephalus.
- Hippocampal volume measurements show correlation with histology. Can be used to monitor disease progression:
 - bilateral hippocampal/entorhinal cortex volume loss disproportionate to atrophy;
 - volume loss with posteroanterior gradient.
 - Small vessel white matter hyperintensities on T2W common.
- SPECT: bilateral temporal/parietal perfusion/metabolism defects.

Management

- Multidisciplinary team with nurse, counsellor, psychiatrist.
- Mild cognitive impairment. 10–15% risk of progression to Alzheimer's disease. No data on treatment with acetylcholinesterase inhibitors (AChI).
- AChI and memantine (NMDA receptor antagonist) may improve cognition at least for 6 months. Patients may derive benefit for 2–3 years. If no benefit from one drug, switch. Stop if MMSE < 12.
 - Donepezil, 5–10 mg daily.
 - Rivastigmine, 1.5–6 mg bd.
 - Galantamine, 4–12 mg bd
 - Memantine, 5–10 mg bd.
- Behavioural and psychiatric disorders are common. Consider (initial doses):
 - quetiapine, 25 mg od;
 - olanzapine, 2.5 mg od;
 - risperidone, 0.5 mg daily.

Frontotemporal dementia

Epidemiology

- Usual onset 45–65 years.
- M = F.

Pathology

Atrophy affecting frontal and anterior temporal lobes. In progressive non-fluent aphasia, asymmetrical atrophy of the dominant hemisphere. Bilateral atrophy of the temporal lobes is found in semantic dementia form. Variable histopathology—cortical loss of pyramidal cells, sometimes with inclusion (Pick) bodies and swollen (Pick) neurons.

Genetics

50% autosomal dominant inheritance. Some with parkinsonian features have tau mutations on chr 17. Associated cases with MND link to chr 9.

Clinical features

Frontotemporal dementia

- Change in personality, social and personal behaviour.
- Apathetic, emotionally blunted.
- Overactive, disinhibited.
- Stereotypic movements, e.g. hand rubbing.
- Perseverative.
- Loss of insight.
- Memory intact.

Investigations

- EEG: normal.
- MRI: frontal and anterior temporal lobe atrophy.

Progressive non-fluent aphasia

- Pure language deficit.
- Non-fluent, effortful speech.
- Loss of prosody.
- Repetition impaired.
- Impairment of well rehearsed series, e.g. days of the week.
- Anomia.
- Writing affected.
- Comprehension intact.

Note: Alzheimer's patients may develop a similar language disorder in association with abnormalities in other domains.

Semantic dementia

- Loss of meaning of words.
- Inability to recognize objects and faces.
- Speech is fluent, effortless, but lacks content.
- Semantic paraphasias, e.g. dog for cat.
- Anomia.
- Impaired comprehension.

Note: May be confused with Alzheimer's disease but memory for day to day events and autobiographical details is intact.

Frontotemporal dementia with MND

Development of amyotrophic lateral form of MND after onset of dementia.

Other dementias

Cortical Lewy body disease

Epidemiology Usually sporadic. Most commonly elderly patients.

Pathology Generalized atrophy, depigmentation of substantia nigra. Lewy body inclusions in cortical neurons. 40% have amyloid deposits.

Clinical features

- L-dopa responsive parkinsonism.
- Cortical symptoms—aphasia, apraxia.
- Fluctuating mental state.
- Visual hallucinations and illusions.
- Very sensitive to neuroleptic drugs.

Investigations

MRI: generalized atrophy. Absence of significant temporal atrophy in a demented patient suggests DLB.

Vascular dementia

Epidemiology Usually >40 years. Risk factors include hypertension, smoking, vascular disease.

Pathology Multiple infarcts in cortical and subcortical areas or fibrous and hyaline degeneration of small arteries leading to white matter infarction.

Clinical features

- Recurrent stepwise deterioration.
- Pyramidal signs.
- Pseudobulbar palsy.
- When mainly subcortical disease slowly progressive syndrome with dysarthria, parkinsonism, gait disorder (*marche à petits pas*) = subcortical arteriosclerotic dementia.

Investigations MRI: areas of typical infarction. In subcortical dementia widespread leucoarosis, mainly anterior and periventricular.

CADASIL

Clinical features

- Stroke-like episodes.
- Cognitive impairment in variable cognitive domains.
- Strongly associated with migraine.

Investigations

- MRI: extensive white matter T2W signal change involving the temporal lobes especially anteriorly, and the subinsular region.
- Genetics: Notch 3 mutation on chr 19.

This page intentionally left blank

Creutzfeldt–Jakob disease (CJD)

CJD is a human transmissible spongiform encephalopathy. Prion protein (PrP) gene contains a polymorphic locus at codon 129 encoding methionine or valine. Important in determining susceptibility to sporadic and acquired forms.

- Sporadic CJD, 85–90% cases.
- Familial forms, 10–15% cases:
 - familial CJD;
 - Gerstmann–Straussler–Scheinker;
 - fatal familial insomnia.
- Iatrogenic CJD (human pituitary derivatives, dura mater and corneal grafts), 1%.
- Variant CJD, in UK 160 reported cases.

Sporadic CJD

Incidence and epidemiology 1 per million per year. In UK 60 cases per annum. Mean age of onset 65 years (range 15–94 years). Peak age group, 7th decade. No sex difference; no definite environmental risk factors identified; similar incidence world wide. 75% methionine homozygous (MM) at codon 129, 15% heterozygous (MV), 10% valine homozygous (VV).

Pathology Random misfolding in the prion protein (PrP) or somatic mutation in encoding gene causes the disease. Key pathological features in the brain: spongiform changes, neuronal loss, astrocytosis. PrP deposition demonstrated by immunocytochemistry.

Clinical features

- Rapidly progressive dementia.
- Cerebellar ataxia.
- Myoclonus.
- Pyramidal and extrapyramidal signs.
- Amyotrophy (rare).
- Cortical blindness (rare).

Differential diagnosis

- Alzheimer's disease.
- Cerebral vasculopathy—inflammatory, lymphoma.
- Chronic encephalitis—Hashimoto's encephalitis, SSPE.
- Paraneoplastic encephalitis.
- Demyelinative disorders.

Investigations

- MRI: putamen and caudate hyperintensity on FLAIR and diffusion weighted imaging (DWI) (see Fig. 4.10 (a)).
- EEG: periodic triphasic complexes (60%). May be normal early in disease.
- CSF: ↑ brain-specific protein 14-3-3 (90%). Note: also ↑ if bloodstained CSF, raised WCC, recent seizures, traumatic brain injury, stroke, encephalitis, paraneoplastic syndromes. Normal WCC; protein, moderate elevation.
- PrP gene codon 129 polymorphism status.

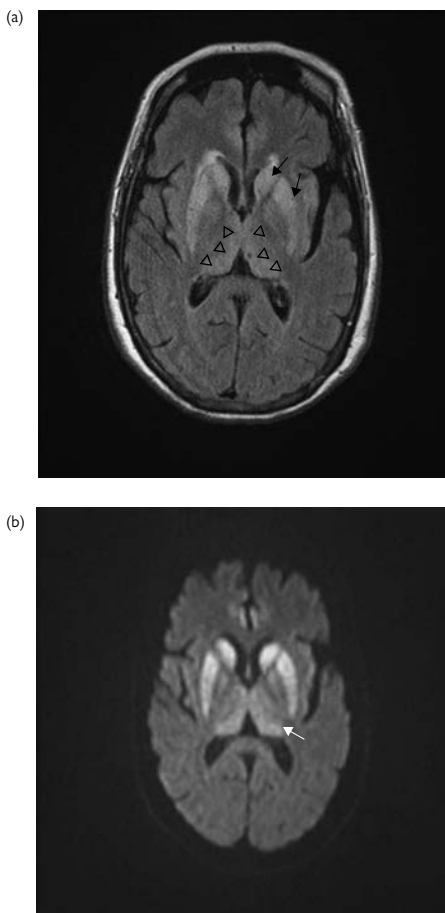


Fig. 4.10 Sporadic Creutzfeldt-Jakob disease (sCJD). (a) FLAIR axial and (b) diffusion-weighted (DWI) MRI. Bilateral symmetric hyperintensity involving the striatal nuclei (*black arrows*). With less prominent involvement of the pulvinar and medial nuclei of the thalami bilaterally (*open black arrowheads*). (b) Note the more conspicuous signal change and increased sensitivity on DWI. In contrast, variant CJD (vCJD) typically demonstrates marked hyperintensity in the pulvinar and medial nuclei of the thalami bilaterally as the most prominent feature (the so-called 'hockey-stick' sign, *white arrow*).

Diagnosing sporadic CJD**Diagnostic criteria**

I Rapidly progressive dementia (if > 2 years diagnosis doubtful)

II Group of symptoms including the following:

- myoclonus
- visual or cerebellar symptoms
- pyramidal or extrapyramidal features
- akinetic mutism

III Typical EEG

Definite diagnosis

Neuropathology/immunochemistry confirmed

Probable diagnosis

Criterion I plus at least 2 from criterion II plus criterion III or 'possible diagnosis' plus positive for protein 14-3-3.

Possible diagnosis

Criterion I plus at least 2 from criterion II and duration <2 years

Management

Supportive. Myoclonus treated with clonazepam, valproate, or piracetam. MRC trial using quinacrine underway.

Variant Creutzfeldt–Jakob disease (vCJD)

vCJD is the human form of bovine spongiform encephalopathy (BSE). Dietary transmission by ingestion of cow products most likely source.

Incidence and epidemiology In UK 160 cases to date. Size of future epidemic unknown. Younger patients affected: typically 14–50 years though older patients reported. All homozygous MM at codon 129.

Pathology Florid amyloid plaques in cerebrum and cerebellum; spongiform change in caudate and putamen; accumulation of abnormal PrP demonstrated by immunocytochemistry. There is widespread accumulation of abnormal PrP in lymphoid tissue (tonsils and spleen).

Clinical features (early)

- Psychiatric symptoms:
 - depression;
 - withdrawal;
 - aggression and irritability;
 - anxiety, fear;
 - hallucinations and delusions.
- Sensory symptoms (thalamic):
 - limb pain;
 - paraesthesiae and dysaesthesiae;
 - numbness;
 - cold or burning sensations.

Later features

- Ataxia.
- Movement disorders—myoclonus, choreiform movements, dystonia.
- Cognitive impairment.

Progression is less rapid than for sCJD—mean duration 14 months.

Differential diagnosis

- Wilson's disease (copper, caeruloplasmin levels, 24 hour urinary copper, and slit lamp exam for Kayser–Fleischer rings).
- Alzheimer's disease.
- Cerebral vasculitis.
- Vitamin B₁₂ deficiency.
- Infective encephalitis.
- Paraneoplastic syndrome.

Investigations

- MRI: bilateral, symmetrical high signal in the posterior thalamus ('pulvinar sign'; see Fig.4.10 (b)).
- EEG: normal or non-specifically abnormal. Triphasic complexes not seen.
- CSF: normal WCC; protein mild–moderate elevation. 14-3-3 ↑ in 50%. Less sensitive than for sCJD.
- PrP gene codon 129 status.
- Tonsil biopsy may be considered but is not routine. A positive tonsillar biopsy does *not* make a diagnosis of 'definite vCJD'.
- Brain biopsy only if there is a possibility of a treatable disorder that cannot be diagnosed by other methods e.g. vasculitis.

Management

- Supportive and palliative.
- vCJD is not transmissible by ordinary contact or body fluids but invasive procedures require specific precautions.

Epilepsy: introduction

Defined as the tendency to have recurrent seizures. Epilepsy is a manifestation of underlying brain disease. Single seizures or those occurring during acute illness should not be classified as epilepsy.

Incidence 50/100,000/year; 1 in 200 have active epilepsy (in UK, 350,000). Higher incidence in developing countries.

Aetiology

Unknown in two-thirds of cases. In UK, community surveys show:

- cerebrovascular disease, 15%;
- cerebral tumour, 6%;
- alcohol-related, 6%;
- post-traumatic, 2%;
- genetic disorders, 1%.

Other causes include hippocampal sclerosis, and cortical and vascular malformations. In the tropics, neurocysticercosis is a common cause.

Classification

Basic classification is between generalized (50%) and focal (50%), subdivided into aetiological categories.

- Idiopathic (genetic predisposition with normal development, examination, and EEG).
- Symptomatic (structural abnormality).
- Cryptogenic (structural abnormality supposed but not proven).

Classification of epilepsy (modified, abbreviated classification of the International League against Epilepsy)

Generalized epilepsies and syndromes

- Idiopathic with age-related onset:
 - childhood absence epilepsy;
 - juvenile myoclonic epilepsy (JME);
 - epilepsy with generalized tonic-clonic (T/C) seizures on waking.
- Symptomatic and cryptogenic:
 - West's syndrome;
 - Lennox-Gastaut syndrome;
 - epilepsy with myoclonic absences.
- Symptomatic
 - myoclonic encephalopathy.

Focal epilepsies and syndromes

- Idiopathic with age-related onset:
 - benign childhood epilepsy with centrotemporal spikes;
 - reading epilepsy.
- Symptomatic:
 - epilepsy with simple partial, complex partial, or secondarily generalized seizures arising from any part of the cortex;
 - epilepsia partialis continua (EPC);
 - syndromes characterized by specific activation.

Undetermined epilepsies and syndromes (focal or generalized)

Epilepsy with continuous spike and wave activity in sleep.

Clinical features

Seizures are paroxysmal, stereotypic events. Diagnosis is clinical; eyewitness accounts are crucial. Usually followed by a period of drowsiness. See 'Loss of consciousness' p. 56.

Triggers include:

- alcohol;
- fatigue;
- sleep deprivation;
- infections;
- hypoglycaemia;
- stress;
- strobe lighting (photosensitive epilepsy);
- reading, hot water (rare).

Childhood absences

- Rare after age 10 years.
- F > M.
- Brief loss of awareness many times a day. Triggered by hyperventilation.
- Remit in adulthood.
- EEG characteristic—3 Hz spike and wave, no photosensitivity.

Juvenile myoclonic epilepsy (JME)

- Onset before age 30 years.
- Myoclonic jerks in the morning.
- Typical absences.
- Generalized tonic-clonic seizures.
- EEG typical with generalized spike and wave \pm photosensitivity.
- Remission rare.

Complex partial seizures

- Associated with underlying structural abnormality, e.g. hippocampal sclerosis, DNET.
- Automatism (lip smacking, chewing, swallowing, stereotypical hand movements).
- Déjà vu and jamais vu.
- Olfactory auras (unpleasant).
- Unusual behaviour or emotionality.

Investigations

- Blood investigations:
 - FBC, ESR;
 - renal, liver function, calcium, glucose;
 - ECG (rare: \uparrow QT interval presenting as morning generalized T/C seizures).
- MRI with specific views of hippocampi if complex partial seizures. Abnormal in 30% of generalized epilepsies and 70% focal epilepsies. See Chapter 7.
- EEG (see 'EEG and epilepsy', p. 446). Useful in classification of epilepsy but not in the diagnosis of patients who present with loss of consciousness.

Management of epilepsy

General advice

- Inform the DVLA.
- Avoid unsafe activities e.g. swimming alone, mountain climbing.
- Take showers rather than baths.

Starting treatment

Single seizures

No treatment unless there is a high risk of recurrence, e.g. abnormal EEG as in JME or an abnormal MRI. If precipitating factors (e.g. alcohol) identified, avoidance may prevent recurrence.

After a single unprovoked seizure, risk of recurrence is 24% with no cause and normal EEG. and 65% if associated with a neurological abnormality + abnormal EEG.

Prophylaxis

No indication for starting treatment in patients with head injuries, craniotomy, brain tumours, unless seizures occur.

Drug treatment

Aim of treatment is to render patient seizure-free with minimal side-effects. Other factors include sudden unexpected death in epilepsy (SUDEP)—1/200/year in refractory epilepsy.

- Factors to be taken into account:
 - age;
 - sex;
 - type of epilepsy;
 - other drugs, e.g. contraceptive pill;
 - other medical conditions, e.g. liver or renal dysfunction.
- Treatment is initiated at low dose gradually titrating to an effective level to avoid side-effects ('start low, go slow').
- If seizures continue, increase dose to maximum tolerated. If seizures continue, withdraw first drug and try another first-line drug.
- If unsuccessful, adjunctive treatment with a second-line drug should be considered.

Drug monitoring

Measuring drug levels is indicated in the following situations:

- suspected poor or erratic compliance;
- symptoms of toxicity, e.g. nausea, ataxia, confusion, diplopia;
- valproate levels are only of use for monitoring compliance. Blood levels do not correlate with therapeutic levels as valproate is highly fat-soluble.

Table 4.2 First- and second-line drugs for different types of epilepsy

Type of epilepsy	First-line drugs	Second-line drugs
Generalized	Valproate or lamotrigine	Levetiracetam or topiramate
Focal	Carbamazepine or lamotrigine or valproate	Levetiracetam or topiramate
Additional myoclonus	Valproate or lamotrigine	Levetiracetam
Absence	Valproate or ethosuximide	

Table 4.3 Antiepileptic drugs: dosages and side-effects

AED	Dose	Side-effects
Carbamazepine (SR form)*	Start 200 mg/day. ↑ at 2-week intervals until control achieved. Usually 400–1200 mg/day	Rash, neutropenia, conduction defects, SIADH, numerous drug interactions. May make myoclonus worse. Liver enzyme inducing. Note COC.
Sodium valproate*	Start 200 mg bd, ↑ 2-weekly intervals. Max 2.5g/day. CR form available for od use	Rash, tremor, weight gain, hair loss, menstrual changes, ↓ platelets. ↑ NH ₃ , encephalopathy
Lamotrigine*	Start 25 mg/day as monotherapy; ↑ 50 mg 2-weekly. If adjunct to valproate, start 25 mg alternate days for 2 weeks, ↑ 25 mg 2-weekly. Maximum dose, 400 mg/day.	Rash, especially with valproate. Multisystem allergic disorder
Topiramate	Start 25 mg/day; ↑ 25 mg 2-weekly. Maximum dose 400 g/day	Weight loss, memory problems, renal calculi
Levetiracetam	Start 250 mg/day, ↑ 2-weekly. Maximum dose 2 g/day	Weakness, irritability, mood swings. Rare: ↑ seizures
Phenytoin	Start 200 mg/day, then monitor levels to ↑ dose 2-weekly. Note: First order kinetics: small dose increase → large changes in levels	Gum hypertrophy, acne, hirsutism, coarse facies, osteoporosis, ataxia.

* Do FBC, U & E, LFT before starting drug.

- Carbamazepine and valproate are accepted as first line recommendations for partial and generalized seizures, respectively.
- Lamotrigine is used for both types of seizures in women of child-bearing age.
- Other add-on therapies available:
 - gabapentin;
 - tiagabine;
 - pregabalin;
 - oxcarbazepine.
- Phenytoin and phenobarbitone are effective but little used due to long-term side-effects. Only indication is in status epilepticus as can be given IV.
- Clobazam useful adjunct in the short term, especially when cluster seizures occur, e.g. perimenstrually. Dose, 10–20 mg bd.

Prognosis with drug treatment

By 12 months 60–70% will be seizure-free. After 2 years, withdrawal of drugs can be considered. Predictive factors for relapse:

- syndromic epilepsy, e.g. JME;
- underlying structural pathology;
- severe prolonged epilepsy before remission;
- ↑ age.

Factors that may affect the decision to stop include driving. Patients are advised to stop driving during drug withdrawal and for 6 months thereafter.

Surgery Should be considered, and patients referred to a specialist centre, in cases with:

- surgically resectable lesion, e.g. DNET;
- temporal lobe seizures in whom there is evidence of mesial temporal sclerosis (see Fig. 4.11).

In such patients seizure-free rates 80%, with 3–4% permanent neurological deficit and 1% mortality rates.

Vagus nerve stimulation is an option with no serious side-effects in those with refractory epilepsy, and unsuitable for surgery.

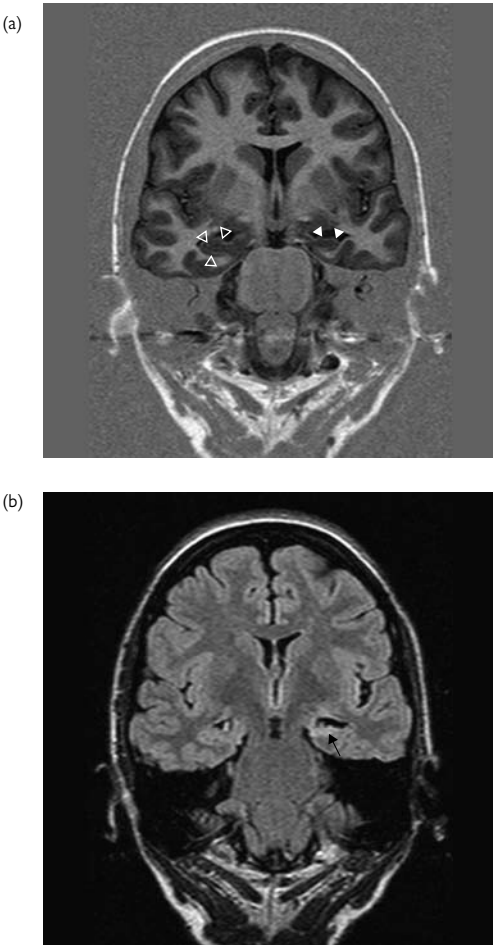


Fig. 4.11 Hippocampal sclerosis. (a) Thin section gradient echo T1-weighted volume and (b) thin section coronal FLAIR MRI. Typical reduction in volume (*white arrowheads*) and hyperintensity (*black arrow*) of the left hippocampus.

Women and epilepsy

Contraception

- Carbamazepine, oxcarbazepine, phenytoin, phenobarbitone, primidone, and topiramate (enzyme-inducing drugs) ↓ blood levels of oestrogen and progesterone.
- Sodium valproate, gabapentin, tiagabine, levetiracetam, and pregabalin do not affect levels. However, recent controversy regarding lamotrigine.
- Recommend COC with at least 50 micrograms oestrogen if on enzyme-inducing drugs. Break-through bleeding implies inadequate dose.
- Progestogen-only pill (POP) similarly affected. Recommend change of contraception or use depot injection (Depot Provera 150 mg/12 weeks).

Fertility

- Women with epilepsy have lower fertility rates due to multiple factors, e.g. sexual dysfunction in those with TLE.
- Valproate associated with polycystic ovarian syndrome.

Pregnancy

- Pre-conception counselling essential.
- 90% chance of a normal child and 95% chance of not having a major malformation.
- Start folic acid supplements 5 mg/day to ↓ risks of neural tube defects, especially with valproate and carbamazepine.
- Risks and benefits of stopping drug at least for first trimester need discussion.
- Lowest possible dose should be used, e.g. risk of spina bifida with valproate significantly reduced if dose < 1000 mg/day. Consider using Chrono preparation to ↓ peak levels.
- Teratogenicity:
 - incidence of fetal abnormality in general population 2–3%. Risk ↑ to 4–6% with single AED. ↑ with multiple drug therapy;
 - patients on valproate and carbamazepine should have a series of high definition USS to detect anencephaly (11weeks), NTD (16–18 weeks), congenital cardiac defects (18–20 weeks);
 - alpha fetoprotein levels at 18 weeks for NTD.

Epilepsy during pregnancy

- 20% ↑ fits, 50% unchanged, 25% ↓ seizures.
- Carbamazepine, valproate, phenytoin levels ↓ but free drug levels ↑. If well controlled, no changes necessary. Measure levels (free levels if possible) at presentation so that if fits occur dose changes can be made. Any dose increases may need reversal after delivery.
- Lamotrigine clearance ↑. Dose ↑ necessary.
- First fit during pregnancy needs investigation:
 - eclampsia;
 - higher incidence of structural lesions, e.g. meningioma, AVM;
 - SAH;
 - arterial and venous thromboses.

During labour Risk of seizure 3%, due to lack of compliance, fatigue, dehydration, lack of sleep. Lorazepam can be used.

Vitamin K Enzyme-inducing drugs (carbamazepine, phenytoin, phenobarbitone) affect clotting synthesis. Require vitamin K, 20 mg /day starting 1 month before delivery. Neonate given 1 mg IM at delivery.

Breast feeding

Only phenobarbitone and primidone found in breast milk at high enough concentrations to cause drowsiness.

Seizures versus dissociative non-epileptic attack disorder (NEAD) or pseudoseizures

A major cause of misdiagnosis of epilepsy. But some patients may have both types of attacks. 50% of status cases may be NEAD.

Clinical features of NEAD

- Usually female (ratio 8:1).
- History of childhood physical and/or sexual abuse.
- Triggered by stress.
- Not responsive to multiple drugs trials.
- Frequent admissions to hospital.
- Other non-diagnosed physical symptoms.

Differential diagnosis See Table 4.4.

Investigations In cases of doubt, videotelemetry helps in diagnosis.

Management

- Establish diagnosis with certainty.
- Explain that attack is unconscious response to some form of stress.
- Relaxation techniques, cognitive behaviour therapy.
- Consider withdrawal of AED.

Table 4.4 Characteristics of NEAD compared with those of epileptic seizures

Characteristic	NEAD	Epileptic seizures
Triggered by anger, panic, suggestion	Common	Rare
Onset	Gradual	Sudden
Duration	Prolonged, hours	minutes
Breathing	Continuous	Apnoeic
Colour	Normal	Cyanosed
Retained consciousness	Yes, elevate arm above face and drop. Patient usually avoids falling on to face. Vibrating tuning fork inserted gently into nostril will wake most patients	Rare
Unusual movements	Pelvic thrusting back arching, erratic movements. Fighting if held down	Unusual
Eyes	Resistance to forced eye opening	No resistance
Occur in company	Common	Unusual
Tongue biting	Rare	Common
Self injury	Rare	Common
Incontinence	Rare	Common
Post ictal confusion	Rare	Common
Prolactin levels before and 20 minutes after	No rise	Elevation but may be normal after prolonged status
Post ictal EEG	Normal	Slowing

Management of status epilepticus

Status epilepticus is defined by:

- continuous seizures;
- two or more seizures with incomplete recovery of consciousness in between;
- lasting more than 30 minutes.

A neurological emergency with mortality 10–20%.

Epidemiology

Annual incidence 10–60/100 000/year. Most common in children with mental handicap or structural brain lesions. In adults, presentation usually without a history of epilepsy:

- cerebral infection, e.g. encephalitis;
- cerebrovascular disease;
- cerebral tumour;
- acute metabolic disturbance;
- alcohol intoxication.

Management of prodromal phase

- Patients with epilepsy may develop increasing seizures or myoclonic jerks. Early treatment may prevent progression.
 - Lorazepam 4 mg IV (rate not critical) or diazepam 10 mg IV (slowly 2–5 mg/min) or rectal diazepam (gel) 10–20 mg.

Management of generalized tonic/clonic status epilepticus

- General measures:
 - O₂;
 - ECG, BP, oximetry, temperature;
 - IV access;
 - measure electrolytes, glucose, calcium, magnesium, FBC, clotting, AED levels, alcohol, toxicology, blood cultures;
 - BM stix. If ↓ glucose, give 50% glucose 50 ml.
 - Poor nutrition or alcohol abuse: give thiamine 250 mg IV slowly.
- Investigate cause of status. Consider:
 - CT scan or MRI;
 - CSF examination.
- Reinstate any withdrawn AED. Continue existing AED.

Specific drug treatment

- 1 Give single dose of 4 mg lorazepam IV if not already given or diazepam 10 mg IV (slowly, rate 2–5 mg/min).
- 2 If seizures continue after 10 minutes and patient not on phenytoin, give:
 - phenytoin 15–18 mg/kg (usual adult dose 1000 mg) diluted to 10 mg/ml normal saline over 20 minutes. Do not mix with other drugs. ECG monitoring. Optimal plasma concentration 10–20 mg/l (40–80 mmol/l). Measure level 2 hours later. Repeat 24 hours later for accurate level.

- **Or** fosphenytoin (pro-drug, acts more rapidly). 22.5 mg/kg (15–18 mg phenytoin sodium equivalents) diluted to 10 mg/ml in normal saline at <100 mg/minute.
 - **Or** (if patient is on phenytoin) phenobarbitone 10 mg/kg (usual adult dose 700 mg) over 10 minutes. Monitor respiration and BP. + send phenytoin levels and make up deficit as follows:
Phenytoin (mg/kg) = $0.7 \times$ required blood level (mg/l) – measured blood level (mg/l).
- 3 If seizures stop, continue with maintenance phenytoin (IV/oral/via NG). If not, proceed to ventilation and general anaesthesia with thiopentone or propofol or midazolam. Continue until EEG seizures cease or until a burst suppression pattern is obtained.

Failure to respond

- Inadequate doses of phenytoin or phenobarbitone.
- Failure to continue maintenance therapy.
- Medical complications, e.g. acidosis, electrolyte disturbance.
- Could this be pseudostatus? More common than true status. EEG will answer this question. Also check hospital records for previous admissions.

Headache: migraine—introduction and clinical features

Epidemiology

- Common. Prevalence in women, 18%; men, 6%.
- Mean age of onset 19 years.
- 46% have a family history. Risk of a child developing migraine 70% if both parents are affected, 45% when one parent affected.
- A rare dominantly inherited condition, familial hemiplegic migraine, due to a mutation on chromosome 19 that codes for a subunit of the voltage-gated calcium channel.
- Cerebral autosomal dominant arteriopathy with subcortical infarcts and leucoencephalopathy (CADASIL) may present with hemiplegic migraine and progress to an ischaemic encephalopathy.

Pathophysiology

Migraine is a neurovascular disorder in a genetically predisposed individual. Predisposition is an instability within the trigeminovascular network originating within the brainstem, in particular the dorsal midbrain and dorsolateral pons. Diffuse projections from the locus ceruleus to the cerebral cortex result in impaired cerebral cortical blood flow causing the spreading depression associated with migrainous auras.

Clinical features

- Migraine is an episodic headache usually associated with nausea (\pm vomiting) and photophobia.
- May be preceded by focal neurological symptoms. The aura may not necessarily be followed by headache (previously known as migraine equivalents).
- 30% may have other coexisting headaches, e.g. tension and analgesic overuse headaches.

Headache features

- Unilateral in 2/3 of patients and bilateral in 1/3.
- Pain felt behind or along the inner angle of the eye or frontotemporal regions.
- Radiates back to the occiput or the neck.
- Site of headache may be either ipsilateral or contralateral to the focal neurological disturbance.
- Occasional patients may complain of limb pain ipsilateral to the side of the headache.
- Character of the headache is dull at onset and later throbbing (increasing with each pulse). Other patients may only describe a constant headache or even a slight muzzy headache.
- Made worse with movement.

Aura features

- Visual auras include: visual hallucinations, scotomas, and fortification spectra (zig-zag lines resembling a fortified wall when viewed from above) or teichopsia. Usually white and shimmer or jitter and move

across the visual field leaving behind an area of impaired vision—scintillating scotomas.

- Other visual phenomena include flashes of light (photopsia). Note: Occipital lobe epilepsy causes hallucinations that are circular or of geometric shapes and multicoloured.
- Sensory auras are usually positive, i.e. paraesthesiae rather than numbness, and spread over minutes or hours (5%).
- Other auras: hemiparesis (marching over minutes or hours), dysphasia, olfactory and gustatory hallucinations, and distortion of body parts such as tongue swelling.

Migraine triggers

- Stress and relaxation after stress.
- Sleep: either lack of or unaccustomed excess (lying in).
- Trauma (especially in children).
- Sensory stimulation: glare, flickering lights, smells (e.g. certain perfumes).
- Food and eating habits: missing a meal (hypoglycaemia). Foods including red wine, cheese, chocolate.
- Food additives: monosodium glutamate.
- Exercise.
- Excess heat and dehydration.
- Drugs: vasodilators such as nitroglycerin.
- Changes in barometric pressure such as those preceding a thunderstorm.

Migraine variants

Vertebrobasilar migraine Brainstem symptoms: diplopia, vertigo, incoordination, ataxia, and dysarthria occur in posterior circulation migraine attacks. May also be fainting or loss of consciousness due to involvement of the midbrain reticular formation. In severe cases a stuporous or comatose state may last for a week (migraine stupor). Most cases are associated with other vertebrobasilar symptoms.

Ophthalmoplegic migraine Extra-ocular paresis—the 3rd nerve is most often affected. Paresis may last for days or weeks. Exclude a compressive lesion such as a posterior communicating artery aneurysm.

Retinal migraine Unusual variant results from constriction of retinal arterioles impairing vision in one eye and is associated with headache behind the same eye. Compressive lesions and a TIA must be excluded.

Benign recurrent vertigo Migraineurs have abnormalities of the vestibular system. Attacks of vertigo accompanied by tinnitus, deafness, and headache may respond to anti-migraine therapy.

Migraine: differential diagnosis, investigations, and IHS criteria

Differential diagnosis

- Headache occurs in 15% of patients with TIA, 25% with acute ischaemic stroke, 50% with acute intracerebral haemorrhage.
- Other causes of headache with focal neurological disturbance:
 - temporal arteritis;
 - dissection of the carotid and vertebral arteries;
 - meningococcal meningitis may resemble an acute migraine attack. Note: a lymphocytic pleocytosis may be found in the CSF during a migraine attack.

Investigations

Imaging studies detect a significant abnormality in <0.5% patients with migraine and a normal neurological examination. Therefore not usually indicated. MRI scans in migraine patients, with and without auras, may reveal small non-specific white matter lesions in 30% of individuals under the age of 40 years.

Abbreviated International Headache Society (IHS) criteria for migraine

Migraine without aura

- a Headache lasting 4 hours to 3 days
- b Nausea/vomiting and/or light and noise sensitivity
- c Two of the following:
 - unilateral pain
 - moderate or severe intensity pain
 - aggravation by simple physical activity
 - pulsating pain

Migraine with aura

At least 3 of the following:

- reversible focal brainstem or cortical dysfunction
- aura develops over > 4 minutes or 2 auras in succession
- each aura < 60 min
- headache < 60 min following aura

Suggested criteria for chronic or transformed migraine

- d Daily or almost daily (> 15 days/month) head pain > 1 month
- e Average headache duration > 4 hours/day (untreated)
- f At least one of the following:
 - a previous history of IHS migraine
 - history of increasing headache frequency with decreasing severity of migrainous features over at least 3 months
 - current superimposed attacks of headache that meets all the IHS criteria except duration

This page intentionally left blank

Management of acute migraine: the stepped care regimen

1 Simple analgesia with antiemetics if nausea and vomiting are not a major symptom as gastric motility is impaired during a migraine attack.

- Aspirin, 900–1200 mg (dissolved) + metoclopramide, 10mg or domperidone, 10–20mg.
- Alternative drugs include paracetamol, 1000 mg and NSAIDS e.g. ibuprofen, naproxen, diclofenac.

2 Triptans

- All drugs of this class (sumatriptan, zolmitriptan, naratriptan, rizatriptan, eletriptan, almotriptan, frovatriptan) have a high efficacy with up to 70% having a response within 2 hours and 40% being pain-free at 2 hours (see Table 4.5).
- Zolmitriptan and rizatriptan available as wafers—do not have faster action of action.
- Sumatriptan available as nasal spray and injection.
- Drugs work best when taken early but not during the prodrome or the aura phase.
- Headache recurrence within 12–24 hours occurs in 30%.
- Usual advice is to take a further dose of triptan, perhaps combining it with an NSAID.
- If no response try another triptan.
- Overuse may result in rebound headaches in 10%.
- Contraindications: coronary artery disease, cerebrovascular disease, uncontrolled hypertension, peripheral vascular disease, significant hepatic impairment, and pregnancy.
- Side-effects: chest discomfort or heaviness; jaw, shoulder, and neck tightness; paraesthesiae; fatigue and dizziness.
- Drug interactions: avoid MAOI. Propranolol ↑ serum concentration of rizatriptan. Therefore use 5 mg dose. Possible serotonin syndrome when used with SSRIs.

Ergotamine preparations

- Still a role for considering ergotamine tartrate in, for example, those patients intolerant to 5-HT agonists. 1–2 mg alone or in combination with caffeine may be given orally at onset or may be used in those patients who have premonitory symptoms such as cravings, yawning, or fatigue.
- May also be administered by inhaler or suppository.
- Overdosage results in nausea, rebound headache, and peripheral vasoconstriction. The recommended maximum dose per week is 10 mg.
- Dihydroergotamine (DHE) used intravenously in patients with intractable migraine at doses of 0.3–1.0 mg 8-hourly upto total dose 10 mg (specialist headache units).

Table 4.5 Triptan characteristics

More rapid onset	Lower recurrence rate, lower side effects
Sumatriptan, 50–100 mg	Naratriptan, 2.5 mg
Rizatriptan, 5–10 mg	Frovatriptan, 2.5 mg
Zolmitriptan, 2.5 mg	
Eletriptan, 40–80 mg	
Almotriptan, 12.5 mg	

Management of migraine prophylaxis

- Headache diary useful to monitor frequency and patterns, e.g. relationship to periods, weekends, analgesic and triptan overuse.
- Prophylaxis ineffective if medication overuse.
- Avoid triggers—dietary in only 10%.
- Consider prophylaxis if ≥ 2 attacks per month or one prolonged attack affecting lifestyle.
- Prophylactic drugs (see Table 4.6):
 - beta-blockers;
 - amitriptyline especially if migraine associated with tension headache;
 - sodium valproate;
 - topiramate.

Table 4.6 Prophylaxis of migraine headache

Drug	Contraindication	Dose (mg)	Side effects	Comments
Beta blockers	Asthma, peripheral vascular disease, pregnancy			
<i>Non-selective</i>				
Propranolol		20–320	Postural hypotension, fatigue, cold limbs, vivid dreams	Long-acting preparation available
Timolol		10–20		
Nadolol		80–160		
<i>Selective</i>				
Metoprolol		200		Slow release
Atenolol		100		
5-HT₂ antagonists				
Pizotifen	Pregnancy	0.5–3	Weight gain	Single nocturnal dose
Cyproheptadine		4–8	Weight gain	Single nocturnal dose
Methysergide	Peripheral vascular & coronary disease, peptic ulcer, pregnancy	1–6	Epigastric pain, cramps, mood changes; rarely, retroperitoneal & pleural fibrosis	Cease treatment for 1 month every 6 months to prevent fibrotic effects. Specialist headache clinic supervision
Amitriptyline	Pregnancy, cardiac conduction defects, coronary disease, peptic ulcer, pregnancy	10–150	Dry mouth, drowsiness	Useful if tension headache as well. Combine with beta-blocker
Antiepileptic drugs				
Sodium valproate	Pregnancy, liver disease	500–1500	Weight gain, alopecia, liver dysfunction, tremor, pancreatitis, polycystic ovaries	Chrono preparation. Not licensed in UK for migraine
Topiramate	Pregnancy	25–100	Weight loss, memory & concentration, acute glaucoma	Recently licensed in UK
Gabapentin	Pregnancy	900–4800	Fatigue, dizziness, diplopia, ataxia	Not licensed in UK for migraine

Migraine and women

Menstrual migraine

- Hormonal trigger is baseline exposure to high levels of oestrogen followed by a fall in levels.
- Release of uterine prostaglandins occurring around menstruation an additional mechanism.
- 60% of women report an increase in migraine frequency around menstruation.
- 14% have exclusively menstruation-related migraine.

Management of menstruation related migraine

Non-hormonal prophylaxis

- NSAIDs:
 - mefenamic acid 500 mg 3–4 times daily or naproxen 500 mg bd 1–2 days before headache and for duration of period (–2 to +3 days of menstruation).
- Ergotamine, 1 mg od or bd (or 1/2 suppository) during vulnerable period.
- Naratriptan, 1 mg bd or frovatriptan 2.5 mg bd for 3–5 days.

Hormonal prophylaxis

- Topical oestrogen:
 - transdermal oestrogen, 100 µg 3 days before period;
 - oestradiol gel 1.5 mg in 2.5 mg gel 3 days before menstruation for 7 days.
- Combined COC in patients with irregular periods. If attacks occur in pill-free period, tricycling (3 consecutive packets followed by pill-free interval).
- Depot progesterone: inhibition of ovulation so that menstruation ceases. Oral POP not helpful because hypothalamic/pituitary axis not suppressed.
- Other hormonal strategies. In conjunction with gynaecologist or endocrinologist: danazol, bromocryptine, tamoxifen.

Migraine, contraception, and stroke

- Migraine can worsen, improve, or remain unchanged when patients are prescribed the combined oral contraceptive pill (COC).
- Migraine may start *de novo* on starting the COC. It is not essential to stop the pill at the first migraine since this may improve over a number of cycles.
- Stop pill in the following situations:
 - new persisting headache;
 - new onset migraine aura;
 - dramatic increase in headache frequency and intensity;
 - development of unusual and especially prolonged auras.

Risk of stroke in young women under the age of 45 years rises from 5–10 per 100,000 to 17–19 per 100,000 in migraineurs.

- Risk is higher in those with aura than those without.
- COC is also associated with a small increased risk of stroke. Crucial to assess the other stroke risk factors—smoking, hypertension,

hypercholesterolaemia, diabetes, obesity. Risks of stroke need to be weighed against the risks of pregnancy and the psychosocial consequences of unwanted pregnancies.

Guidelines for the use of COC in women with migraine

- Identify risk factors for stroke:
 - ischaemic heart disease or cardiac disease with embolic potential;
 - smoking;
 - diabetes mellitus;
 - hypertension;
 - age > 35 years;
 - obesity (BMI > 30);
 - family history of arterial disease;
 - systemic disease associated with stroke, e.g. sickle cell.
- Identify migraine type, i.e. with or without aura
- Assess risk of stroke.
 - COC relatively safe: migraine without aura; no other risk factors.
 - Use COC with caution: migraine without aura with one vascular risk factor.
 - COC relatively or absolutely contraindicated: migraine with aura; migraine without aura + 2 or more risk factors.

Migraine, the menopause, and HRT

- At menopause, migraine improves in 65%, worsens in 10%, and is unchanged in 25%.
- Migraine worsens in most who undergo a surgical menopause.
- No evidence that women over the age of 45 years with migraine are at increased risk of stroke compared to non-migraineurs.
- The indications and contraindications to the use of HRT similar to women without migraine.
- HRT when necessary for menopausal symptoms may improve or worsen migraine.
- Consider the following strategies:
 - ↓ oestrogen dose.
 - Change type of oestrogen (conjugated to synthetic ethinyl oestradiol or pure oestrone).
 - Change to a continuous regimen if migraine during withdrawal phase.
 - Try oestrogen patch—more steady state level.
 - Reduce progesterone dose.
 - Change progesterone type.
 - Try local progesterone application.
 - Withdraw progesterone (with periodic endometrial biopsy and vaginal ultrasound).
 - If osteoporosis main concern, try selective oestrogen receptor modulator (SERMS), e.g. raloxifene instead of oestrogen-containing HRT.

Migraine and pregnancy

- 80% of migraineurs ↓ attacks—especially migraine without aura and those with menstruation-related migraine.
- Migraine without aura patients may experience auras for the first time in pregnancy.
- If first presentation of migraine with aura during pregnancy or if change in usual migraine symptoms exclude other disorders:
 - cerebral venous thrombosis;
 - AVM;
 - imminent eclampsia.

Management of migraine in pregnancy

Non-drug advice

- To avoid pregnancy-related nausea and vomiting resulting in hypoglycaemia and dehydration:
 - eat small, frequent carbohydrate snacks;
 - adequate fluid intake.
- Adequate rest.
- Acupuncture, relaxation techniques.

Drugs

- Minimize drug exposure especially during first trimester.
- If possible, stop prophylactic drugs.
- Acute treatment:
 - paracetamol: safe in all trimesters and during lactation;
 - aspirin: probably safe but caution near term due to ↑ risk of post partum haemorrhage, neonatal bleeding, and premature closure of ductus arteriosus. Avoid during lactation—risk of Reye's syndrome and bleeding in infant;
 - NSAIDs: insufficient data to support use;
 - codeine: not recommended but occasional use probably safe;
 - metoclopramide, prochlorperazine, domperidone, chlorpromazine probably safe. Metoclopramide excreted in breast milk; therefore avoid in lactation;
 - triptans—not recommended;
 - ergotamine preparations—contraindicated in pregnancy and lactation.
- Prophylaxis during pregnancy:
 - betablockers associated with intrauterine growth retardation therefore avoid. If necessary use lowest possible dose.
 - amitriptyline: conflicting data regarding limb deformities and muscle spasms, irritability, and convulsions in neonates. Use if necessary in second trimester only.
 - pizotifen: limited data available.
 - sodium valproate: contraindicated due to high risk of fetal deformities.

This page intentionally left blank

Primary short-lasting headaches

See Table 4.7 for a description of the primary short-lasting headaches.

Paroxysmal hemicrania

- Rare.
- Important differential diagnosis for cluster headache.
- Shorter duration and higher frequency are clues.
- Patients prefer to sit quietly, behaviour that is rare in cluster headache.
- Secondary causes described include:
 - frontal lobe tumours;
 - idiopathic intracranial hypertension;
 - collagen vascular disease.
- Attacks are triggered by head movement.
- Indomethacin is promptly effective.
 - Treatment should start with 25 mg tds. If there is a partial or no response after 10 days, the dose should be increased to 50 mg tds. If necessary, the dose could be increased to 75 mg tds. Side-effects: GI disturbances. Misoprostol and proton pump inhibitors should be used.

SUNCT

- Rare.
 - Differential diagnosis for trigeminal neuralgia. SUNCT affects V1, while TGN usually affects V2 and V3.
 - Duration of pain 5–250 seconds in SUNCT, < 1 second in TGN.
 - Autonomic features are present in SUNCT and rarely in TGN.
 - SUNCT unresponsive to most treatments although lamotrigine is worth trying; TGN usually responds to carbamazepine.
 - Both are triggered by cutaneous stimuli.
- MRI is necessary to exclude secondary causes such as posterior fossa tumours.

Table 4.7 Primary short-lasting headaches including autonomic cephalgias

Feature	Cluster headache	Paroxysmal hemicrania	SUNCT*	ISH*	Trigeminal neuralgia	Hypnic headache
Sex (M:F)	5:1	1:2	2:1	F>M	F>M	5:3
Pain type	Boring	Boring	Stabbing	Stabbing	Stabbing	Throbbing
Severity of pain	Very severe	Very severe	Severe	Severe	Very severe	Moderate
Location of pain	Orbital	Orbital	Orbital	Any	V2/V3>V1	Generalized
Duration of pain	15–180 min	2–45 min	15–120 s	<30 s	<1 s	15–30 min
Frequency	1–8/day	1–40/day	1/day–30/hour	Any	Any	1–3/night
Autonomic features	+	+	+	–	–	–
Triggers	Alcohol, sleep	Mechanical	Cutaneous	None	Cutaneous	Glyceryltrinitrate
Indomethacin-responsive?	No	Yes	No	Yes	No	Yes

*SUNCT, Short-lasting unilateral neuralgiform headache with conjunctival injection and tearing; ISH, idiopathic stabbing headache

Cluster headache

Epidemiology Prevalence, 0.1%. Male: female ratio 5:1. Commonest age of onset 3rd and 4th decades.

Clinical features

- Episodic cluster: periods lasting 7 days to 1 year separated by pain-free remissions lasting 1 month.
- Chronic cluster: attacks lasting for more than 1 year without remission or remission lasting less than 4 weeks.

Headache features

- Excruciatingly severe unilateral orbital, supraorbital, temporal pain lasting 15 minutes–3 hours but usually 45–90 minutes.
- Abrupt onset and cessation.
- Frequency may range from one every other day to 8 per day.
- Associated autonomic features—lacrimation, nasal congestion, rhinorrhoea, facial/forehead sweating, miosis, ptosis, eyelid oedema, conjunctival injection.
- Restlessness or agitation during headache.
- Other features include a striking circannual and circadian periodicity
- Some also have typical migrainous auras.
- Triggers: alcohol, GTN, exercise.

Differential diagnosis

- Secondary causes such as tumours need exclusion by MRI.
- Features helpful in differentiating CH from migraine include:
 - relatively short headache duration;
 - rapid onset and cessation;
 - periodicity (daily and annually);
 - alcohol precipitates attack within 1 hour rather than hours as in migraine.
- Paroxysmal hemicrania is similar but more common in females, with briefer and more frequent attacks. Exquisitely responsive to indomethacin.

Management

Acute attacks

- Subcutaneous sumatriptan 6 mg has a rapid effect and a high response rate. This may be used twice daily. Alternatives include sumatriptan 20 mg intranasally, zolmitriptan 5 mg orally.
- 100% oxygen, 7–12 litres/minute should be used for 20 minutes via a non-rebreathing mask with all apertures sealed up.
- 20–60 mg topical lidocaine 4–6% solution instilled intranasally may be a useful adjunct.

Preventive treatments Short-term regimens are useful for patients with short bouts of CH for a few weeks or help in establishing longer-term preventive measures.

- Prednisolone 60 mg/day for 5 days and tailing off by 10 mg every 3 days.

- Methysergide useful in patients with clusters lasting a few weeks. Start at 1 mg od, increasing the dose by 1 mg every 3 days to a tds regimen until 5 mg in total. Thereafter the dose can be increased every 5 days by 1 mg to a maximum of 4 mg tds. Prolonged treatment is associated with retroperitoneal, cardiac, and pleural fibrosis. Therefore, a drug holiday for 1 month is recommended every 6 months.
- Ergotamine 1–2 mg PO or rectally can be taken 1 hour prior to an attack or at bedtime if they occur predictably. Concomitant use of sumatriptan is contraindicated.

Long-term prevention

Indicated for long bouts of episodic and chronic cluster headaches.

- Verapamil: after a baseline ECG, start at 80 mg bd increasing after 10–14 days to 80 mg tds. Thereafter the dose is increased by 80 mg every 10–14 days with an ECG prior to each increment to a maximum dose of 320 mg tds.
- Lithium: after renal and liver function tests, starting dose is 300 mg bd with regular monitoring to achieve a level in the upper therapeutic range. NSAIDS, diuretics, and carbamazepine use are contraindicated.

Trigeminal neuralgia

Defined as 'sudden, usually unilateral, severe, brief, stabbing pain in the distribution of one or more of the branches of the trigeminal nerve.'

Epidemiology Usual onset after the age of 40. More common in women.

Clinical features

- Neurological examination including facial sensation normal.
- 2nd and 3rd divisions are most often affected.
- Attacks last < 1s. Refractory period after an attack. Frequent attacks in a short duration may leave a lingering pain.
- Triggers include cutaneous sensory stimuli caused by touch, shaving, eating, talking and cold draughts.
- Attacks during sleep are rare.
- Secondary weight loss, dehydration and depression may occur.
- Secondary causes include:
 - schwannoma of the TG nerve;
 - meningioma compressing the Gasserian ganglion;
 - malignant infiltration of the skull base;
 - in young patients, especially if bilateral maybe due to MS.

A significant proportion of idiopathic cases are due to arterial or venous compression of the posterior nerve root.

Differential diagnosis

- TMJ dysfunction.
- Atypical migraine.
- Atypical facial pain.
- Pterygopalatine neuralgia.
- Trigeminal autonomic cephalgias e.g. cluster headache, SUNCT.

Investigations MRI of the brain indicated to exclude the secondary causes. In patients < 50 years, 5% may have an abnormality such as trigeminal Schwannoma, Meckel's cave meningioma, or a demyelinating pontine plaque.

Management

Drug treatment To avoid side-effects, start at low dose and increase gradually. See Table 4.8.

- Occasionally, combinations of drugs may be necessary to avoid using high doses, e.g. baclofen and carbamazepine.
- In crises consider intravenous phenytoin (as fosphenytoin 250 mg).

Surgical treatment In cases refractory to medical therapy or those in whom there are intolerable side-effects, surgical options (Table 4.9) need to be considered.

Table 4.8 Drug treatments for trigeminal neuralgia

Drug	Dose (mg)	Side-effects
Carbamazepine	300–1000	Drowsiness, ataxia, hyponatraemia, drug interactions
Oxcarbazepine	300–1200	Drowsiness, ataxia, hyponatraemia
Baclofen	30–90	Sedation, drowsiness
Phenytoin	200–300	Sedation, ataxia
Gabapentin*	300–3600	Sedation
Lamotrigine*	100–400	Sedation, rash

*Unlicensed

Table 4.9 Surgical options in the treatment of trigeminal neuralgia

Procedure	Comments
Peripheral branch alcohol injection	Safe. Mild sensory loss.
Cryotherapy	High recurrence rate: mean, 10 months
Radiofrequency thermocoagulation	Safe. Risk of anaesthesia dolorosa. Recurrence rate 60% at 5 years
Glycerol injection to Meckel's cave	Safe. Recurrence rate 65% at 5 years
Microvascular decompression via posterior fossa approach	Mortality upto 0.4% Complications: CSF rhinorrhea, cerebellar venous infarction. Recurrence rate 25% at 5 years.
Gamma knife surgery directed at the TG nerve stereotactically	Long-term effects unknown. 6 months for effect. Low recurrence rate.

Idiopathic intracranial hypertension (IIH)

IIH is a syndrome of ↑ intracranial pressure without hydrocephalus or mass lesion. Normal CSF constituents. Previously referred to as benign intracranial hypertension (BIH) or pseudotumour cerebri.

Epidemiology

- The incidence is 1–3/100,000/year.
- Marked female preponderance.
- Age range: 15–44 years.
- Major risk factors:
 - female;
 - obesity;
 - recent weight gain;
 - hypertension;
 - menstrual irregularity.
- In any atypical patient, for example, a man, look for secondary cause.

Pathophysiology

Unknown. Possible mechanisms include:

- obstruction to CSF outflow at the level of the arachnoid villi or in the draining veins;
- excess CSF production;
- increased cerebral oedema.

Clinical presentation

Usual symptoms reflect ↑ICP or papilloedema:

- Daily headache (throbbing) associated with nausea and vomiting.
- Visual symptoms: visual obscurations (loss of vision) lasting a few seconds, visual blurring, and/or visual field loss.
- No localizing neurological signs except uni- or bilateral VI nerve palsies causing diplopia.
- Cases are reported with third and fourth nerve palsies, internuclear ophthalmoplegia, and skew deviation. There are very atypical and other causes such as venous sinus thrombosis need to be excluded.
- Papilloedema may occasionally be unilateral.
- Papilloedema may be absent in patients with optic atrophy.
- Central visual loss occurring early should raise concern about some other cause of optic disc oedema such as optic neuritis or anterior ischaemic optic neuropathy.
- Central visual loss may occur in IIH if severe disc oedema is associated with retinal oedema, haemorrhages, exudates, or choroidal folds in the papillomacular bundle or the macula.

Differential diagnosis of papilloedema

- Myelinated nerve fibres.
- Crowded optic disc (hypermetropes) with bunching of vessels in a small disc looks like papilloedema.

- Tilted optic disc. May be associated with visual field defects.
- Optic nerve head drusen. Associated with visual field loss and occasionally with haemorrhage at the optic disc. With drusen, the optic cup is often absent. Drusen may be buried and therefore not visible. On CT, calcification may be seen and ophthalmic ultrasound may be diagnostic.
- Other causes of disc swelling:
 - optic neuritis;
 - ischaemia;
 - neoplastic infiltration.

Diagnosis of papilloedema may be difficult! Clues that an apparently swollen disc is not due to papilloedema:

- blind spot is not enlarged;
- spontaneous venous pulsation may be present or venous pulsation will appear on minimal orbital pressure;
- the absence of an optic cup in a mild to moderately swollen disc;
- abnormal vessels at the disc.
- If in doubt, an ophthalmological opinion may be useful.
- Fluorescein angiography is the gold standard. Retinal photos useful for future reference.

Conditions that may produce intracranial hypertension and mimic IIH

Medical disorders

- Addison's disease.
- Hypoparathyroidism.
- Chronic obstructive pulmonary disease.
- Right heart failure with pulmonary hypertension.
- Sleep apnoea.
- Renal failure.
- Severe iron deficiency.

Medications

- Tetracyclines.
- Vitamin A and related compounds.
- Anabolic steroids.
- Withdrawal of corticosteroids.
- Growth hormone administration.
- Nalidixic acid.
- Lithium.
- Norplant levonorgestrel implant system.

Obstruction to venous drainage

- Cerebral venous thrombosis.
- Jugular vein thrombosis.

Imaging studies

- MRI and MR venography should be performed to exclude hydrocephalus, mass lesions, meningeal infiltration. Isodense tumours and subdural collections may be missed by CT. MR venography will detect most sinus venous obstructions. If MRI is unavailable or unsuitable because of the patient's size, a CT with contrast should be performed.
- Radiographic signs of raised intracranial pressure in IIH include flattening of the posterior globe (80%) and, an empty sella (70%). Slit-like ventricles are **not** a sign of IIH.

Lumbar puncture

- The LP is done with the patient in the lateral decubitus position and the legs extended.
- May be difficult to perform LPs on this group of patients. LPs can be done under X-ray guidance. Radiologists perform the procedure with the patient prone rather than supine—not satisfactory since there are no data to compare the opening pressures, in these two positions.
- Normal CSF pressure is less than 200 mm of water. The pressure increases with weight.
- To diagnose IIH, pressure > 250 mm water. Levels between 200 and 250 mm CSF are non-diagnostic and need to be repeated. Occasionally, a transducer monitor via a lumbar drain may be needed to clarify the diagnosis.

Management

No evidence of visual loss

Conservative management with:

- Weight loss.
- Diuretics: there are no trials comparing the diuretics.
 - Acetazolamide drug of choice as it reduces the rate of CSF production by the choroid plexus. Starting dose is 125 mg bd increasing to 250 mg tds. If tolerated the dose can be increased to 250 mg qds. Side effects include paraesthesiae, altered taste and depression.
 - Furosemide is an alternative.
- Headache can be treated with amitriptyline and anti migraine medication.
- Close follow up is required with assessment of visual acuity, visual fields (automated or Goldmann), initially at one month, then at three monthly. Subsequent follow up is dependant on the clinical course.

Evidence of visual loss

Surgical intervention needs to be considered. The options are:

- Lumboperitoneal shunting. Side-effects include infection, shunt obstruction, low pressure headache.
- Optic nerve sheath fenestration. Highly specialized procedure. Complications include infection, local haemorrhage.

There are no comparative data on these two procedures.

Repeated LP

- May be unpleasant for the patient.
- Can result in low pressure headache, which complicates the clinical picture.
- Helpful in some patients with severe headache and also in the management of IIH in pregnancy where drugs are relatively contraindicated.

Parkinsonism and Parkinson's disease: introduction

Causes of parkinsonism

- Idiopathic Parkinson's disease (PD).
- Parkinsonian-plus syndromes:
 - PSP;
 - MSA;
 - corticobasal degeneration (CBD).
- Secondary parkinsonism:
 - vascular;
 - drug-induced;
 - post-encephalitic;
 - hydrocephalus.
- Degenerative disorders:
 - Alzheimer's disease;
 - Parkinson—dementia—MND complex.
- Genetic disorders:
 - Wilson's disease (consider in all cases < 50 years);
 - Huntington's disease (akinetic rigid (Westphal) variant);
 - Dopa-responsive dystonia.

Epidemiology of PD

- Incidence: 18/100,000.
- Prevalence : 150/100,000.
- In UK, 100 000 cases at any one time.
- M: F ratio: 1.35:1.

Aetiology of PD

- ↑ risk of PD:
 - pesticides;
 - rural residence, farming;
 - MPTP (1-methyl-4-phenyl-1,2,3,6-tetrahydropyridine).
- ↓ risk has been associated with cigarette smoking and caffeine.

Pathophysiology of PD

- Hallmarks of PD are the presence of Lewy bodies + neuronal cell death in the pars compacta of the substantia nigra.
- PD does not develop until striatal dopamine (DA) levels drop to 20% and substantia nigra (SN) cell loss exceeds 50%.
- Functional anatomy involved in PD includes:
 - primary motor cortex;
 - supplementary motor area;
 - striatum (putamen and caudate);
 - globus pallidus;
 - substantia nigra;
 - subthalamic nucleus (STN);
 - thalamus.
- SN acts like an accelerator on the basal ganglia and damage results in slowing.
- STN is a brake and damage therefore causes excessive movement.

This page intentionally left blank

Clinical features of parkinsonism and PD

Diagnosis of a parkinsonian syndrome

Bradykinesia: slowness of initiation of voluntary movement with progressive reduction in speed and amplitude with repetition e.g. thumb and index finger. Plus at least one of the following:

- Rigid ↑ tone.
- Rest tremor:
 - may be the first symptom in 75% of cases of PD.
 - 20% of patients never develop tremor.
 - Some patients may in addition have a postural element to the tremor—this is delayed in onset ('re-emergent'), comes on a short period after the posture is adopted.
- Postural instability not caused by primary visual, vestibular, cerebellar, or proprioceptive dysfunction.

Features supportive of PD: ≥ 3 for definite PD

- Unilateral onset.
- Rest tremor.
- Progressive.
- Persistent asymmetry affecting the side of onset most.
- Good response to L-dopa.
- Severe L-dopa induced chorea.
- L-dopa response for > 25 years.
- Clinical course > 10 years.

Exclusion criteria for PD

- History of repeated strokes with stepwise progression of parkinsonian features (vascular PD).
- History of repeated head injury.
- History of definite encephalitis.
- Oculogyric crises.
- Neuroleptic treatment at onset of symptoms.
- Sustained remission.
- Strictly unilateral features after 3 years.
- Supranuclear gaze palsy (PSP).
- Cerebellar signs (MSA).
- Early severe autonomic involvement (MSA).
- Early severe dementia (DCLB).
- Babinski's sign (but note striatal toe may mimic).
- Negative response to L-dopa (if malabsorption excluded).
- MPTP exposure.

Other features of PD

- Anosmia. 80% PD patients have ↓ sense of smell. If normal consider PSP, CBD, or MSA.
- Dystonia:
 - unusual in early disease—consider MSA;
 - more common after L-dopa therapy.
- Bladder and bowel symptoms:
 - mild urinary symptoms. Frequency, urgency, but rarely incontinence may occur due to detrusor hyperreflexia;
 - in MSA these occur earlier and are more severe;
 - constipation is common.
- Postural hypotension: mild but may be exacerbated by levodopa and dopamine agonists.
- Speech disorder:
 - hypophonia (monotonous and low volume);
 - tendency to repeat the first syllable (palilalia).
- Sleep disorders:
 - restless legs syndrome;
 - REM sleep behaviour disorder where patients act out their dreams.
- Dementia. In the late stage 20% of patients may have dementia:
 - with memory impairment;
 - fluctuating confusion;
 - visual hallucinations;
 - dopaminergic medication may compound the problem.

Differential diagnosis of PD and investigation

Differential diagnosis

- Essential tremor (ET) versus PD
 - ET 10 times more prevalent than PD.
 - ET is a postural \pm action tremor. A severe postural tremor may be present at rest but is not 'pill rolling'.
 - Patients with ET may also have: vocal tremor; head tremor ('no-no' or 'yes-yes').
 - In PD there may be: jaw tremor; leg rest tremor.

For further differential diagnoses see Table 4.10.

Investigations

- No diagnostic test for PD. Diagnosis is made on clinical grounds.
- ¹²³I-FP-CIT SPECT scan (DaTscan). Ligand binds to the dopamine re-uptake transporter protein in the pre-synaptic terminals. \downarrow indicates loss of striatonigral neurons. Useful in differentiating ET from PD, but not PD from MSA and PSP.
- Exclude Wilson's if onset < 50 years:
 - serum copper, caeruloplasmin;
 - 24 hour urinary copper;
 - slit lamp examination for Kayser–Fleischer rings.
- MSA patients may have degeneration of Onuf's nucleus—detected as polyphasic potentials with \uparrow latency on urethral or sphincter EMG.
 - False positives occur in patients who have had prostatic surgery and in occasional patients with PSP.
 - Sphincter EMG has a sensitivity of 0.74 and a specificity of 0.89.
- Autonomic function tests, if MSA differential. Similarly, a cognitive assessment: dementia is unusual in MSA.
- MRI (see Table 4.11).

Table 4.10 Features of other parkinsonian syndromes

Diagnosis	Clinical features	Response to levodopa
Multiple system atrophy (striatonigral degeneration, sporadic olivopontocerebellar atrophy, and Shy-Drager syndrome)	Early dysautonomia (orthostatic hypotension, impotence, bladder dysfunction) Cerebellar dysfunction Pyramidal signs Stimulus-sensitive myoclonus Extreme forward flexion of neck (antecollis) Mottled cold hands Inspiratory stridor Dysarthria	Good response in 20% and sustained in 13%. Dyskinesias or motor fluctuations may occur. Cranial dystonia prominent. Early wheelchair requirement due to early loss of postural reflexes and ataxia
Progressive supranuclear palsy	Supranuclear vertical gaze palsy Apraxia of eye lid opening Axial rigidity > limb rigidity Early falls Speech and swallowing disturbance Neck extension	Good response rare
Corticobasal degeneration	Apraxia, cortical sensory changes, alien limb behaviour, pronounced asymmetric rigidity, limb dystonia, stimulus-sensitive myoclonus	None
Vascular parkinsonism	'Lower half' parkinsonism with prominent gait problems; minimal upper limb dysfunction; pseudobulbar palsy, pyramidal signs	Minimal
Dementia with Lewy bodies	Early dementia; rigidity > bradykinesia or tremor; hallucinations; fluctuating cognitive status; exquisite sensitivity to neuroleptics	Motor features respond well. Psychiatric side-effects

Table 4.11 MRI findings in parkinsonian syndromes

Syndrome	Finding
IPD	Nigral patchy signal loss
MSA	Putamen: ↓ lateral putamen signal on T2-weighted images due to iron deposition; ↑ signal lateral putamen due to gliosis. Pons: 'hot cross bun' sign due to lateral and longitudinal fibres becoming evident on T2-weighted images. See Fig. 4.12
PSP	Midbrain atrophy and 3rd ventricular dilatation.
CBD	Asymmetrical atrophy

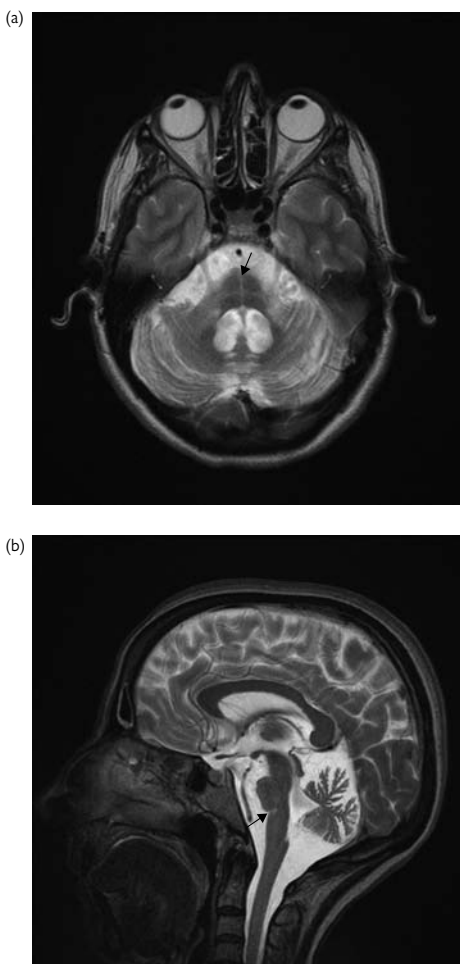


Fig. 4.12 Multisystem atrophy: cerebellar type (MSA-C). (a) Axial and (b) sagittal T2W MRI. Profound volume loss in the cerebellar hemispheres, vermis, middle cerebellar peduncles and brainstem is typical with predilection for the pons and olivary nuclei. (a) Note prominence of intrapontine CSF clefts (*black arrow*) described as the 'hot-cross bun' sign. (b) Sagittal MRI demonstrates pontine volume loss with flattening of the anterior surface and widening of the pontomedullary angle (*black arrow*).

Drug-induced parkinsonism

- Depletion of presynaptic dopamine stores:
 - reserpine;
 - tetrabenazine.
- Dopaminergic blockers:
 - neuroleptic drugs: phenothiazines (chlorpromazine), butyrophenones (haloperidol), thioxanthines (flupenthixol), and substituted benzamides (sulpiride);
 - prochlorperazine prescribed for labyrinthine symptoms and nausea;
 - metoclopramide for GI symptoms;
 - cinnarizine, atypical calcium channel blocker prescribed for vestibular disorders;
 - combinations of antidepressant and neuroleptics, e.g. Motival[®], which contain fluphenazine and nortriptyline; Parstelin[®] (trifluoperazine and tranylcypromine).

Clinical features

- Tremor and asymmetry as in PD.
- patients may have a mixed movement disorder with untreated parkinsonism coexisting with:
 - orofacial dyskinesia;
 - stereotypies;
 - akathisia.
- Parkinsonism may resolve within days of drug being stopped but may take years especially if depot preparations have been used.
- Elderly patients may be left with residual signs.

This page intentionally left blank

Medical management of PD

A multidisciplinary team is essential:

- PD nurse;
- physiotherapist;
- occupational therapist;
- social worker.

Levodopa

Levodopa therapy remains the gold standard of treatment.

- Starting dose is Madopar[®] (co-beneldopa) or Sinemet[®] (co-careldopa) 62.5 with meals tid.
- Side-effects: nausea, vomiting, anorexia. Often resolve spontaneously.
- Consider domperidone, 10–30 mg tds.
- Modified release preparations (Madopar[®] CR and Sinemet[®] CR) have no beneficial effect in the prevention of motor complications.
- Bioavailability of these CR preparations is 70% that of the immediate release preparations.
- CR preparations are especially useful for nocturnal hypokinesia and rigidity.
- Dispersible levodopa preparation useful adjunct in kick-starting immediately on waking or in the case of sudden offs or during episodes of non-responsiveness.
- Motor complications develop in 50% of all PD patients after 6 years of levodopa therapy.
- Monotherapy with DA drugs not associated with these complications; hence the rationale for delaying the use of levodopa therapies in younger patients if possible.

Long-term complications of levodopa therapy

- Involuntary movements or dyskinesias:
 - peak dose choreathetoid dyskinesia;
 - diphasic dyskinesia;
 - dystonia (painful cramp).
- Response fluctuations:
 - end of dose deterioration (wearing off);
 - unpredictable on/off switching.
- Psychiatric:
 - confusion;
 - visual hallucinations;
 - delusions;
 - illusions.

Dopamine agonists (DA)

- DA drugs (Table 4.12) act directly on post-synaptic dopamine receptors without the need for conversion to dopamine.
- DA have a role as an alternative to levodopa as monotherapy, particularly in younger patients, to delay the use of levodopa and its long-term motor complications.
- In patients already on levodopa who have developed motor complications, dopamine agonists may be used with a consequent lowering of levodopa dosage.

Adverse effects

- All DA: nausea, vomiting, postural hypotension, confusion, hallucinations, somnolence.
- Domperidone, 10–20 mg tds is useful for the GI side-effects and postural hypotension (peripheral effects).
- Ergot-derived DA: ankle oedema, erythromelalgia, Raynaud's, retroperitoneal fibrosis, pleural effusions, cardiac valvular disease.

Table 4.12 Dopamine agonists

Drug	Dosage
Ergot-derived	
Pergolide	3–5 mg/day
Cabergoline	2–6 mg/day
Non-ergot derived	
Ropinirole	Up to 24 mg/day in 3 divided doses
Pramipexole	Up to 3.3 mg/day in 3 divided doses

* Long half-life; once daily dose.

Apomorphine

- Apomorphine, a potent D1 and D2 agonist, has poor oral bioavailability. Given by subcutaneous (SC) injection or continuous infusion.

Indications

- SC injection of apomorphine may be used in assessing the dopaminergic response, pattern, and distribution of dyskinesias in patients on long-term levodopa therapy.
- Intermittent injections are used as rescue for severe 'off' periods in patients already on maximal levodopa and DA therapy. Helpful in painful 'off' period dystonias as well 'off' period sphincter and swallowing difficulty.
- Continuous infusion: consider in all patients with refractory motor fluctuations that cannot be managed on oral therapy and require > six apomorphine SC injections. This form of treatment should be considered prior to surgery.
- Temporary apomorphine therapy should be considered in PD patients undergoing abdominal surgery.

Apomorphine challenge test to assess effect

- Start domperidone 30 mg tid 36 hours prior to test.
- No oral anti-parkinsonian drugs for 4–6 hours before challenge.
- Normal breakfast.
- Assess baseline motor function using Unified Parkinson's Disease Rating Scale (UPDRS).
- Time to rise from a chair and walk 12 metres is measured.
- Apomorphine 1.5 mg SC administered and motor response observed for 30 minutes.
- Yawning may precede motor response.
- If no significant response, 3 mg is administered.
- Dose increased every 30 minutes up to 7–10 mg.
- Positive response is if there is an improvement in UPDRS score of 15–20% or 25% increase in walking time.

Other therapies**Anticholinergic agents**

- Limited role and should only be prescribed in young patients with severe tremor and dystonia.
- Trihexyphenidyl (benzhexol) (2–5 mg tid) and orphenadrine (50 mg tid) are the most commonly used.
- Side-effects a major drawback especially in elderly patients—confusion, cognitive impairment, nausea, dry mouth, precipitation of closed angle glaucoma, and urinary retention.

Amantadine

- Previously used in early PD to delay the use of levodopa; with the advent of DA drugs there is little use for this indication.
- New role in the management of drug-related dyskinesias due to glutamate antagonistic properties.
- Dose 100–300 mg /day.
- Side effects: confusion, hallucinations, ankle oedema, livedo reticularis, insomnia (second dose at midday).

Selegiline

- MAOI drug has a mild symptomatic effect.
- Used as adjunct therapy to levodopa.
- Dose of 5 mg bd.
- Side-effects: confusion, hallucinations, insomnia (second dose at midday).
- New melt preparation a given at a lower dose of 1.25–2.5 mg/day.

COMT inhibitors

- ↑ the amount of levodopa reaching CNS.
- Entacapone (200 mg) prescribed with each dose of levodopa (dose range 400–1200 mg/day).
- Side-effects: excess dopaminergic effects, dyskinesias managed by ↓ levodopa, diarrhoea.

This page intentionally left blank

Surgical treatment of PD

New surgical procedures have developed as a result of a better understanding of the pathophysiology of PD (Table 4.13).

Table 4.13 Functional neurosurgery in PD

Outcome	Posteroventral pallidotomy	Thalamotomy (VIM nucleus)	Bilateral stimulation		
			Thalamic (VIM nucleus)	STN	Pallidal
Dyskinesias	++*	0	0	++	++
Tremor	+*	+*	+++	+	+
'off' periods	+++	?	0	+++	+++
ADL	++	?	0	+++	+++
Medication	Increased	Unchanged	Unchanged	Reduced(++)	Reduced(+)
Morbidity (%)	5	5	5	?	?
Mortality (%)	2	?	0	?	?

* Contralateral.

Key: +/++/+++ = increasing benefit. 0 = no benefit.

This page intentionally left blank

Management of other problems in PD

Depression

- Affects the quality of life in 40%.
- Although SSRIs (e.g. citalopram and sertraline) are first choice, concern this class of drugs may cause a deterioration of parkinsonian symptoms.
- Mirtazapine (presynaptic α_2 antagonist).
- Alternative drugs are the tricyclics.
- In severe cases ECT may be an option.

Psychosis

- Occurs in 10–15%.
- Symptoms: mild illusions, visual hallucinations, and paranoid delusions.
- Underlying pathophysiology is combination of development of cortical Lewy body dementia and drugs.

Management

- Treat any infection (UTI, bed sores, etc.).
- Correct any metabolic derangement, e.g. dehydration.
- Reduce and withdraw anticholinergics, selegiline, amantadine, DA and, lastly, levodopa.
- If necessary, balance between 'mad and mobile' and 'stiff but sane'.
- Consider addition of a newer generation of antipsychotic drugs, e.g. quetiapine. Low dose clozapine (6.25–50 mg, mean 25 mg) has been shown to be effective. Agranulocytosis occurs in 1.2% of patients.

Dementia

- Features of Lewy body dementia include visual hallucinations, a fluctuating course with lucid intervals, and an exquisite sensitivity to neuroleptic drugs.
- Benefit with the use of cholinesterase inhibitor drugs used in the treatment of Alzheimer's disease, such as donepezil and rivastigmine.

Sleep disturbance

Common problem due to combination of factors:

- Stiffness and rigidity, making it difficult to turn in bed. Consider CR levodopa preparations or cabergoline.
- Bladder disturbance due to detrusor hyperreflexia resulting in nocturia. Oxybutynin and tolterodine may help.
- Restless legs: CR levodopa or cabergoline at night.
- Rapid eye movement (REM) sleep behaviour disorder (RBD) where purposeful nocturnal motor activity occurs. Clonazepam 0.5–2 mg is effective.

Excess salivation due to an inability to swallow

- Can be treated with anticholinergic drugs but will have significant side-effects.
- Hyoscine patches behind the ear
- Instillation of atropine drops 0.5% on the tongue two or three times a day.
- ? botulinum toxin injection or DXT into the parotid glands if unresponsive and problematical.

'Freezing': especially in doorways: visual, patterned cues across doorway help. Use of 'laser cane' to step over beam.

Falls and postural instability

- Occur late in the course of the disease and are unresponsive to medication.
- Multidisciplinary assessment with a physiotherapist and OT to acquire walking aids and make appropriate adaptations.

Multiple system atrophy (MSA)

Within the spectrum of MSA:

- striatonigral degeneration;
- olivopontocerebellar atrophy;
- autonomic failure.

Overlap occurs with disease progression.

Epidemiology

- Presentation usually 6th decade.
- Life expectancy is around 6 years from onset.
- There are no familial cases reported.

Pathophysiology

- Targeted areas are the striatum, substantia nigra, brainstem nuclei, dentate nuclei of the cerebellum, anteriomedial columns of the spinal cord, and Onuf's spinal nucleus, which innervates urethral and anal sphincters.
- Argyrophilic neuronal and glial cytoplasmic inclusions positive for alpha synuclein.

Clinical features

- Parkinsonian form (MSA-P) presents with an akinetic rigid syndrome. Tremor is less frequent than in PD.
- Olivopontocerebellar variant (MSA-C) presents with ataxia.
- Autonomic involvement with impotence in men, anorgasmia in women, orthostatic hypotension not due to drugs, urinary urgency, and incontinence early in the disease may be a pointer to MSA.
- Bulbar involvement can lead to laryngeal stridor and sleep apnoea.
- Pyramidal involvement not severe: brisk reflexes, extensor plantar responses that in a patient with PD could be due to vascular disease or cervical spondylosis.
- Other clinical signs:
 - dusky blue hands due to autonomic involvement;
 - marked antecollis;
 - painful dystonias;
 - low amplitude myoclonic jerks of the outstretched fingers (polyminimyoclonus);
 - cognitive problems rare.

Investigations

- Autonomic function tests may confirm the clinical findings.
- Sphincter EMG may show denervation of the external anal sphincter.

MRI

- MSA-P:
 - atrophy of stratum/putamen > caudate;
 - putaminal hypointensity (posterolateral margin) + thin rim of hyperintense signal;
 - ↓ width of pars compacta.
- MSA-C (see Fig. 4.12):
 - pontine atrophy;
 - atrophy of middle cerebellar peduncles, cerebellum + inferior olives;
 - T2W hyperintensity ('hot cross bun sign').

Management

- 50% of MSA cases are L-dopa-responsive.
- If no response or significant side-effects, try amantadine (100 mg bd).
- Orthostatic hypotension:
 - reduce dopaminergic drugs;
 - TED stockings;
 - head up tilt at night;
 - high salt intake;
 - fludrocortisone (0.1–0.2 mg at night): side-effect, supine hypertension.
 - midodrine 2.5 mg, ↑ to 10 mg tds.
- Bladder urgency: oxybutynin 2.5 mg bd, maximum 5 mg tds.
- Nocturia: intranasal DDAVP 20–40 micrograms at night. Side-effect hyponatraemia.

Progressive supranuclear palsy (PSP)

Also called Steele–Richardson–Olszewski syndrome.

Incidence Usual onset in the 6th and 7th decades. The median survival is 7 years from onset.

Pathophysiology

- Tau positive neurofibrillary tangles found in the pallidum, substantia nigra, periaqueductal grey matter, and superior colliculi.
- Frontal cortical involvement.

Clinical features

- Presentation with a symmetrical akinetic rigid syndrome with the axial trunk and neck muscles being more affected than the limbs.
- Tremor is uncommon.
- Falls backwards early in the course of disease.
- Supranuclear gaze palsy affecting down more than upgaze is the most distinctive feature with symptoms of difficulty scanning the printed page and walking downstairs.
- Other features:
 - surprised look due to frontalis overactivity;
 - growling dysarthria with palilalia;
 - dysphagia;
 - apraxia of eyelid opening.
- Impairment of frontal lobe executive function with a frontal lobe dementia later in the disease with personality change and emotional lability.
- Bladder symptoms unusual and occur late.

Investigations

MRI:

- Midbrain atrophy ('Mickey mouse ears') due to enlargement of 3rd ventricle + interpeduncular fossa + ↓ AP diameter of midbrain + depression of superior midbrain on sagittal images ('humming bird sign').
- T2W hyperintense signal periaqueductal grey matter + globus pallidus.
- Fronto-temporal atrophy.

Management

- Response to levodopa is usually poor.
- Amantadine should be tried.
- PEG tube feeding necessary in severe dysphagia.
- Pneumonia is the commonest cause of death.

This page intentionally left blank

Corticobasal degeneration (CBD)

Incidence Presents in the 6th and 7th decades.

Pathophysiology

- Degeneration of posterior frontal, inferior parietal, and superior temporal cortices, thalami, substantia nigra, and cerebellar dentate nuclei.
- Tau deposition in swollen achromatic neurons.

Clinical features

- Striking asymmetry at onset and throughout the disease course usually involving one limb.
- Combination of akinetic rigidity and cortical features. The latter are:
 - apraxia;
 - cortical sensory loss (simultagnosia and dysgraphaesthesia);
 - 'alien limb phenomenon': hand may interfere with activities of the other arm or grasp on to doors and handles.
- Other features:
 - stimulus-sensitive myoclonus;
 - painful limb dystonia;
 - bulbar problems with dysphagia and dysarthria.

Investigations MRI shows asymmetric cortical atrophy in clinically affected areas.

Management

- Poor response to levodopa.
- Clonazepam, piracetam, and sodium valproate may be used for troublesome myoclonus.
- PEG tube feeding may be necessary in severe dysphagia.

This page intentionally left blank

Peripheral nerve disorders: introduction and clinical approach

Response to physical or metabolic trauma by peripheral nerves is limited to four pathological mechanisms.

1. **Wallerian degeneration** when a nerve is transected with axonal and myelin degeneration of the distal segments. Distal portion will remain electrically excitable for up to 10 days. Denervation potentials are seen in muscles between 10 and 14 days after injury.
2. **Axonal degeneration or axonopathy**. Distal axonal loss ('dying back') due to toxins and metabolic disorders such as diabetes. Most common pathological reaction. Presents as a symmetrical length-dependent neuropathy. Axonal regeneration proceeds at the rate of 2–3 mm per day.
3. **Neuronopathy** with nuclear degeneration of the motor anterior horn cells in the spinal cord or the sensory neurons within the dorsal root ganglia (ganglionopathy). Occurs as a result of degenerative processes in motor neuron disease or as a paraneoplastic or autoimmune phenomenon in sensory neuronopathies.
4. **Segmental demyelination** results from either direct damage to the myelin sheath, as in the GBS, or the Schwann cell, e.g. GBS or CIDP. Repeated episodes of demyelination and remyelination result in a proliferation of Schwann cells—onion bulbs.

Clinical approach

History

- Motor symptoms: difficulty opening jars; tripping due to weakness of ankle dorsiflexion. Proximal weakness (differential diagnosis: myopathies) and/or onset in upper limbs occurs as radiculopathy, radiculoneuropathy (e.g. CIDP), and vasculitis.
- Sensory symptoms: positive sensory symptoms, e.g. pins and needles, burning, tight band-like sensation. Indicative of an acquired rather than an inherited neuropathy.
 - **Hypoaesthesia**—reduced sensitivity or numbness.
 - **Paraesthesiae**—abnormal sensations, which may be spontaneous or evoked, but not unduly painful or unpleasant.
 - **Dysaesthesiae**—unpleasant paraesthesiae.
 - **Hyperaesthesia**—increased sensitivity to a stimulus.
 - **Allodynia**—painful sensation resulting from a non-painful stimulus such as light stroking.
 - **Hyperalgesia**—greater than normal response to a painful stimulus.
 - **Hyperpathia**—delayed painful after-sensation to a stimulus.
 - **Neuropathic pain**—burning, gnawing, sharp shooting, or jabbing pains intermittently.

Clinical examination

- Foot deformities such as pes cavus, pes planus, clawing of the toes, or scoliosis may indicate a hereditary neuropathy.
- Nerve thickening (ulnar at the elbow, superficial radial at the wrist, or the common peroneal around the fibular head) may indicate leprosy, CIDP, Refsum's disease, amyloidosis, CMT (I and III), or HNPP.
- Clinical signs that are useful pointers to large fibre involvement (joint position and vibration sense):
 - pseudoathetosis (involuntary movement of the fingers when the hands are held outstretched and the eyes are shut);
 - positive Romberg's sign (increased swaying and unsteadiness with the eyes closed compared to when the eyes are open).
- Small fibre neuropathies (damage to the unmyelinated and small myelinated fibres). Pain and temperature sensation are impaired but reflexes may be normal since the afferent fibres of the tendon stretch reflexes lie within the large myelinated fibres.
- In the length-dependent sensory neuropathies, involvement of the anterior intercostal and thoracic nerves will result in a midline area of sensory loss, which could be interpreted as a sensory level falsely implicating spinal cord pathology.
- Autonomic dysfunction:
 - symptoms of orthostatic lightheadedness, impotence, bladder and bowel dysfunction;
 - examination includes pupillary responses to light and accommodation;
 - BP erect and supine (after 3 minutes).
- Clues to a demyelinating neuropathy:
 - postural tremor of the outstretched hands;
 - weakness out of proportion to the degree of wasting;
 - generalized areflexia;
 - thickened nerves.

Diagnosis of peripheral nerve disorders

To reach a diagnosis the following questions need to be answered after the history and examination.

1. What is the temporal evolution of the disorder?
 - acute (days up to 4 weeks), e.g. GBS, vasculitis.
 - subacute (4 to 8 weeks).
 - Chronic (> 8 weeks), e.g. CIDP.
2. Which parts or combinations of the peripheral nervous system are involved?
 - Motor: distal or proximal; focal; or symmetrical/asymmetrical.
 - Sensory: small fibres (pain and temperature) or large fibres (joint position and vibration).
3. Autonomic involvement?
4. Cranial nerve involvement?
5. Clues to genetic neuropathy? Clues include family history, onset in childhood (motor milestones delayed).

Acute neuropathy See acute NM syndromes.

Chronic neuropathy

The following patterns may be recognized in most cases and will help formulate a differential diagnosis. See also Fig. 4.13.

Pattern 1 Symmetrical proximal and distal weakness with sensory loss. Consider: CIDP, vasculitis.

Pattern 2 Symmetrical distal weakness with sensory loss. Consider: metabolic disorders, e.g. diabetes; drugs and toxins; hereditary neuropathies, e.g. CMT I and II, amyloidosis.

Pattern 3 Asymmetric distal weakness with sensory loss.

- Multiple nerve involvement. Consider: vasculitis; hereditary neuropathy with liability to pressure palsies (HNPP); infections, e.g. Lyme disease, leprosy; HIV; infiltration with lymphoma or carcinoma; sarcoidosis.
Note: mononeuritis multiplex may eventually develop into a confluent sensory and motor neuropathy.
- Single nerve or root. Consider: compressive lesions and radiculopathy.

Pattern 4 Asymmetric distal or proximal weakness without sensory loss. Consider: motor neuron disease, multifocal motor neuropathy with conduction block (MMN-CB), neuralgic amyotrophy.

Pattern 5 Asymmetric proximal and distal weakness with sensory loss. Consider: polyradiculopathy or plexopathy due to diabetes, malignant infiltration, neuralgic amyotrophy, HNPP.

Pattern 6 Symmetric sensory neuropathy without weakness (mainly small fibre involvement with pain and temperature dysfunction). Consider: diabetes, HIV, amyloidosis, Fabry's disease, idiopathic.

Pattern 7 Symmetric sensory loss without weakness (large and small fibre dysfunction). Consider: diabetes, drugs, toxins.

Pattern 8 Marked proprioceptive sensory loss. Consider: ganglionopathy due to paraneoplastic disorders, Sjögren's syndrome, B₆ and cis-platinum toxicity, HIV.

Pattern 9 Neuropathy with autonomic involvement. Consider: diabetes, amyloid (familial or acquired), porphyria, GBS.

Pattern 10 Neuropathy with cranial nerve involvement (most often the facial nerve) Consider: Lyme disease, HIV, CIDP, sarcoidosis, malignant infiltration, Gelsolin familial amyloid neuropathy (Finnish), Tangier disease.

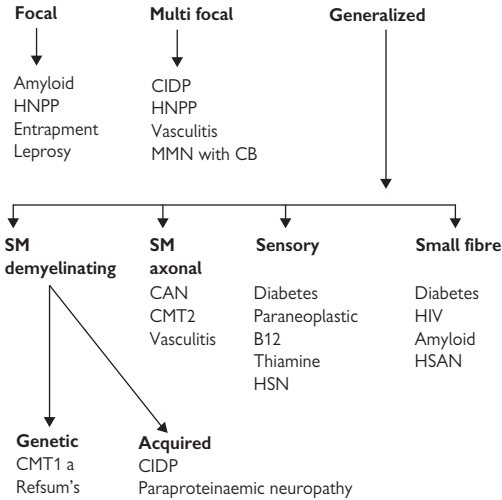


Fig. 4.13 Algorithm for the diagnosis of peripheral neuropathy. CAN, chronic axonal neuropathy; CIDP, chronic inflammatory demyelinating neuropathy; CMT, Charcot–Marie–Tooth disease; HIV, human immunodeficiency virus; HNPP, hereditary neuropathy with liability to pressure palsies; HSAN, hereditary sensory and autonomic neuropathy; HSN, hereditary sensory neuropathy; MMN with CB, multifocal motor neuropathy with conduction block; SM, sensorimotor.

Investigations in peripheral nerve disorders

NCT necessary in most cases (see Chapter 6) to:

- Distinguishing demyelinating neuropathy (20%) from axonal neuropathy (80%).
- Identifying features to distinguish hereditary from acquired neuropathy (e.g. uniform slowing of motor conduction velocities in hereditary neuropathy).
- Detection of clinically asymptomatic abnormalities.
- Distinguishing symmetrical, length-dependent neuropathy from asymmetric, patchy neuropathy that suggests a vasculitic or inflammatory aetiology.

Blood tests

First-line

- Haematology: FBC, ESR, B12, folate.
- Biochemistry: renal and liver function, Ca, fasting glucose, immunoglobulins, and protein electrophoresis.
- Immunology: ANA, dsDNA, ENA (anti-ro and la).

Second-line

- Antineuronal antibodies.
- ACE.
- Lyme.
- HIV.

Third-line

- Vasculitic neuropathy: hepatitis B, C, cryoglobulins, complement C3, C4, c-ANCA, p-ANCA.
- Genetic tests: chr 17 (duplication for CMT 1a, deletion for HNPP), P0, Connexin 32, familial amyloid polyneuropathy (FAP) mutations.
- Specific antibody tests: GQ1b, (Miller Fisher syndrome), GM1 (MMN with CB), anti-MAG (IgM paraproteinaemic neuropathy).

Radiology

- CXR (sarcoidosis malignancy).
- MRI brachial, lumbosacral plexus (CIDP, infiltration).

CSF examination

Should be considered in any progressive undiagnosed neuropathy.

- ↑ CSF protein, pleocytosis, oligoclonal bands indicate demyelination or inflammatory process.
- Cytology examination for malignant cells.

Nerve biopsy

Sural, superficial peroneal, superficial radial, or dorsal ulnar nerve biopsy should be considered in the following situations:

- Vasculitis (nerve and muscle biopsy may ↑ yield).
- CIDP if NCT and CSF not supportive.
- Amyloid neuropathy.
- Possible hereditary neuropathy with no FH and genetic tests negative.
- Complex neurological syndromes with PN involvement.

Diagnostic yield is low in chronic axonal neuropathy.

Nerve selected depends on clinical and NCT involvement. If normal NCT, yield is poor.

Complications

- Infection.
- Persistent pain and numbness.

Diabetic neuropathies

Epidemiology Commonest cause of neuropathy worldwide. 8% have neuropathy at diagnosis; 50% after 25 years.

Diagnosis of diabetes mellitus (DM)

- Type 1. Beta cell destruction (autoimmune).
- Type 2. Relative insulin deficiency.

Criteria for diagnosis of DM

- Symptoms of DM (polyuria, polydipsia, weight loss) + random plasma glucose > 11.1 mmol/l **or**
- Fasting plasma glucose > 7.8 mmol/l **or**
- 2 hour plasma glucose after GTT (75 g glucose load) > 11.1 mmol/l.

Classification of diabetic neuropathies

Diabetic polyneuropathy

Clinical features

- Distal, symmetrical sensory > motor neuropathy starting in the toes progressing to knees when fingers and hands become affected ('glove and stocking'). Complaints of numbness, tingling, and symptoms of a painful small fibre neuropathy (burning, stabbing).
- Weakness restricted to small muscles of feet.
- Absent ankle and or knee jerks.
- Associated autonomic function abnormality correlates with severity of neuropathy:
 - postural hypotension;
 - loss of sinus arrhythmia;
 - impotence;
 - gastroparesis;
 - nocturnal diarrhoea.
- Retinopathy
- Nephropathy with proteinuria.

NCT

Length-dependent changes, mixed axonal and demyelinating changes with small amplitudes and slowing.

Nerve biopsy

Indicated if prominent autonomic dysfunction early for amyloid; marked or rapid progression with motor signs to exclude CIDP and vasculitis.

Management

- Foot care: regular assessment for callus and ulcer formation. Podiatric referral.
- Ophthalmological and renal assessment.
- Strict control of hyperglycaemia.
- Neuropathic pain control (gabapentin, pregabalin, carbamazepine, amitriptyline, lamotrigine).

Diabetic cachectic neuropathy (or acute painful neuropathy of DM)

- Usually in elderly men with poor diabetic control and profound weight loss.
- Symptoms of small fibre neuropathy: burning, allodynia, hyperaesthesia.
- Spontaneous recovery with good diabetic control.

Insulin neuritis

Onset with insulin treatment. Acute painful neuropathy that improves with good diabetic control.

Diabetic lumbosacral radiculo-plexus-neuropathy (Bruns–Garland syndrome)

- Usually seen in males, > 50 years with type 2 DM.

Clinical features

- Abrupt onset severe pain in back, hips, anterior thighs. Followed by progressive proximal weakness and wasting but may involve distal muscles.
- Usually uni- but occasionally bilateral.
- Associated with weight loss.

Differential diagnosis

Vasculitis, malignant infiltration.

Investigations

- NCT: changes of distal sensory diabetic neuropathy.
- EMG: denervation changes in paraspinal, proximal, and distal muscles.
- Consider MRI (with contrast) lumbosacral spine and plexus for infiltration.
- CSF for malignant cells.
- Nerve biopsy (of intermediate cutaneous nerve of thigh) not usually indicated. Shows microvasculitis.

Management

Strict diabetic control; pain management. Role of steroids and IV Ig unclear. Most recover spontaneously.

Diabetic truncal radiculoneuropathy

- Abrupt onset with burning radicular pain over thoracic spine, ribs, chest, or abdomen. Weakness of abdominal or respiratory muscles. Spontaneous recovery.

Cranial neuropathies

3rd and 6th nerves affected. 3rd nerve palsy associated with orbital pain in 50%. Pupil spared. MRA needed to exclude a posterior communicating artery aneurysm. Recovery in 3 months.

Mononeuropathies

Increased susceptibility to compression injuries: carpal tunnel syndrome, ulnar and common peroneal nerves. If associated with wasting, local decompression should be considered. Results not as good as in non-diabetics.

Guillain–Barré syndrome (GBS)

Epidemiology

Commonest cause of acute neuromuscular paralysis. Annual incidence: 1–2/100 000. Occurs sporadically but epidemics occur in Northern China (AMAN).

Pathophysiology

2/3 preceded by a GI or URT infection. Most common are:

- *Campylobacter jejuni*;
- cytomegalovirus (CMV);
- Epstein–Barr virus;
- *Haemophilus influenzae*;
- *Mycoplasma pneumoniae*.

75% cases due to an acute inflammatory demyelinating neuropathy (AIDP) with cellular and antibody mechanisms playing a role. In cases preceded by *C. jejuni* infection, molecular mimicry results in ganglioside antibodies (GM1). Significance of antibodies more apparent in the Miller Fisher variant (GQ1b antibody) and acute motor axonal neuropathy (AMAN) with the GD1a antibody.

Clinical features

- Onset is with progressive usually ascending weakness, with or without paraesthesia. By definition nadir is reached by 4 weeks.
- Severe back pain may occasionally be a feature.
- Cranial nerve involvement involves the facial and bulbar musculature.
- Tendon reflexes gradually lost.
- Up to 25% have respiratory muscle weakness that may require ventilation.
- Autonomic involvement.

Regional variants

- Miller Fisher syndrome (ophthalmoplegia, ataxia, and areflexia) strongly associated with GQ1b antibody).
- Pharyngo-cervico-brachial pattern.
- Acute oropharyngeal palsy (similar to diphtheria).
- Flaccid paraparesis variant.
- Pure sensory variant.
- Acute pandysautonomia.

Investigations

- Blood tests to exclude conditions that mimic GBS (see 'Acute neuromuscular weakness' in chapter 3) include K^+ , porphyria.
- CSF examination: usually protein level \uparrow but may be normal in the first week. WCC is usually normal (cytoalbuminaemic dissociation). If \uparrow consider HIV infection (seroconversion) or Lyme disease.
- Antibody measurements have little role to play in diagnosis but may have a prognostic role (GD1a).
- NCT may be normal in the early stages (see Chapter 6).

- Focal conduction block is a diagnostic hallmark but occurs proximally and may be difficult to demonstrate.
- 'F' waves may be prolonged indicative of a proximal demyelination.
- Acute axonal degeneration occurs in AMAN or AMSAN but in AIDP may be due to secondary axonal damage associated with a poor outcome in terms of residual deficit.

Management

Disease-modifying treatment

- Intravenous immunoglobulin (IV Ig) has become the treatment of choice. Similar efficacy to PE. Dose: 0.4 g/kg/day for 5 days.
- Plasma exchange (PE) effective compared to supportive treatment alone. 4 exchanges sufficient for moderate to severe disease. In mild disease (able to stand but not run), two exchanges maybe adequate.
- Combining PE and IV Ig does not confer additional benefit.
- Although there are no data, in patients who show no response after 2 weeks (especially if there is still evidence of conduction block):
 - consider repeat course IV Ig **or**
 - consider PE.
 - If there is a relapse after a course of IV Ig, a repeat course may be reasonable.
- Corticosteroids have **not** been shown to be useful in GBS.

General supportive management

Warn ITU and anaesthetist of a patient with GBS in hospital.

- Respiratory: failure to recognize this insidious complication is one cause of mortality. Regular monitoring of vital capacity (VC) not peak flow is essential. If this falls below 20 ml/kg (1.5 l for average adult) transfer to the ITU. By the time O₂ saturation or the PO₂ falls it is too late.
- Swallowing: need SALT assessment. If compromised consider NG tube or PEG.
- Cardiac: brady- and tachy-arrhythmias as well as fluctuations in blood pressure occur as a result of autonomic involvement. ECG monitoring essential on severely affected patients at least until they are recovering.
- Thromboembolic: all patients should be on low molecular weight heparin + TED stocking for DVT prevention.
- Neuropathic pain is common: treated with gabapentin, carbamazepine, or analgesics such as tramadol. Amitriptyline should be avoided especially in the early stages because of its potential cardiac side-effects.
- Depression needs to be anticipated and treated if necessary.
- Bowel functioning needs regulation—constipation occurs due to immobility and drug side-effects.
- Physiotherapy: essential in the early stages to prevent contractures and later during rehabilitation.

Outcome

Mortality is 5%. At 1 year 15% unable to walk unaided. Poor outcome associated with:

- older age
- preceding diarrhoeal illness
- severity and rapid rate of deterioration
- electrically inexcitable nerves, and muscle wasting.

This page intentionally left blank

Chronic inflammatory demyelinating polyneuropathy (CIDP)

CIDP, which may be considered a chronic form of GBS, is important to recognize as a cause of chronic neuropathy because it is treatable.

Incidence 0.15/100,000. Prevalence: 1.24–1.9/100,000. Mean age of onset, 47 years.

Clinical presentation

- Most patients will have weakness and some sensory symptoms. Distribution usually symmetrical distal and proximal.
- Clues to diagnosis:
 - upper limb onset;
 - postural tremor;
 - pseudoathetosis;
 - weakness out of proportion to wasting;
 - large fibre sensory loss;
 - generalized areflexia, thickened nerves.
- 10% purely motor; 10% purely sensory (ataxic).
- Cranial nerve involvement rare: III and VIth.
- Autonomic and respiratory complications unusual.

Clinical course Monophasic progression >8 weeks, relapsing–remitting, chronic progressive.

Clinical variants

- Focal or multifocal monomelic (single limb) presentation.
- Sensory ataxic variant. May resemble ganglionopathy due to a paraneoplastic disorder or Sjögren's syndrome.
- Diabetes and CIDP. Diagnosis must be considered in any diabetic patient with predominant motor or ataxic neuropathy. May be difficult to confirm due to axonal changes on NCT due to diabetes. ↑ protein levels in the CSF occur in diabetic patients
- Hereditary neuropathy and CIDP. Cases are reported of HMSN Ia with superimposed inflammatory CIDP responding to treatment. Clues include significant positive sensory symptoms and/or a rapid deterioration in motor signs.
- CNS involvement in CIDP. Combination of CNS involvement on clinical presentation, such as an internuclear ophthalmoplegia, with demyelinating lesions on MRI scans. Relapses may occur as a result of the central or peripheral pathology.

Investigations

NCS (see p. 446)

- MCV slowing (variable not uniform).
- DML prolonged.
- F wave prolonged.
- Conduction block away from usual sites.
- Temporal dispersion.
- Denervation on EMG indicates axonal loss.

CSF

- Cell count <10 cells.
- Protein >1g (80%).
- Oligoclonal bands may be positive.

Indications for biopsy Discrepancy between clinical findings and NCT: 48% demyelination, 21% axonal; 21% mixed; 18% normal.

Differential diagnosis

- Hereditary: CMT 1a, 1b, X-linked; HNPP; Refsum's.
- Toxic: amiodarone, perhexiline.
- Paraproteinaemic: myeloma, POEMS, Waldenström's macroglobulinaemia.

Management

First-line See Table 4.14.

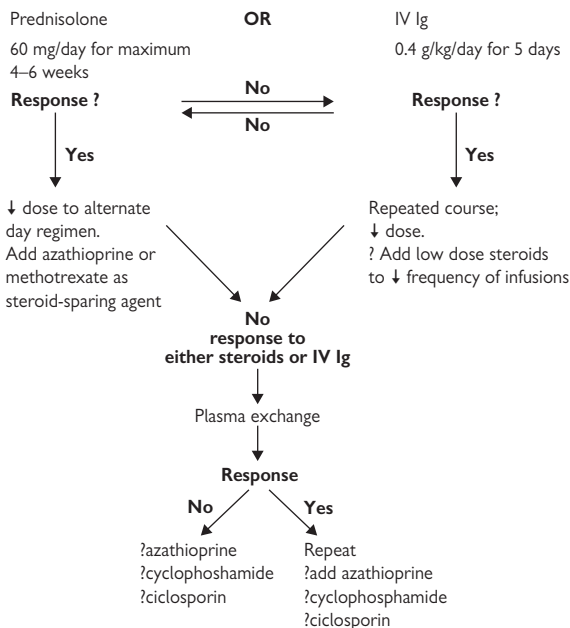


Fig. 4.14 Treatment flow chart for CIDP

Table 4.14 First-line management of CIDP

	corticosteroids	IVIg	Plasma exchange
Response rate (%)	65–95	70	80
Response speed	Slow	Rapid	Rapid
Relapses	No	Yes	Yes
Cost	Cheap	Expensive	Moderate
Complications	Long-term	Blood product	Invasive, sepsis, cardiovascular complications

Second-line (no RCT data)

- Azathioprine, 2.5 mg/kg/day, as immunosuppressant and/or steroid-sparing agent.
- Cyclophosphamide, oral 1–2 mg/kg/day or IV 1–3 mg (pulsed).
- Ciclosporin A: starting 3–7 mg/kg/day, maintenance 2–3 mg/kg/day.

CIDP in association with monoclonal gammopathy

The findings of IgG, IgA, and IgM paraproteins of unknown significance (MGUS) in association with CIDP is not uncommon.

- Patients with IgG and IgA + clinical + neurophysiological findings consistent with CIDP should be treated as such.
- All patients with a monoclonal protein must be evaluated for a myeloproliferative disorder with:
 - urinary protein electrophoresis;
 - skeletal survey;
 - bone marrow examination.
- levels of paraprotein should be regularly monitored as risk of developing a myeloproliferative disorder.

Patients with IgM monoclonal proteins reacting to myelin-associated glycoprotein (MAG) have a distinctive syndrome:

- Usually over the age of 50 years.
- Slowly progressive, distal, symmetrical, sensory > motor features.
- Sensory ataxia
- Postural tremor.
- Disproportionate prolongation of the DML compared to proximal CV.
- Nerve biopsy shows decompaction and widening of myelin lamellae by protein deposition.
- Treatment response to steroids and IV Ig is poor. Rituximab (monoclonal antibody against CD20), shows promise.

This page intentionally left blank

Multifocal motor neuropathy with conduction block (MMN-CB)

MMN-CB is an acquired chronic demyelinating neuropathy that may be considered as part of the spectrum of CIDP. Mimics MND.

Epidemiology 100 times less common than MND. M:F ratio 3:1. Mean age of onset 41 years.

Pathophysiology Immune-mediated supported by association with GM1 antibody and treatment response.

Clinical features

- Progressive, asymmetric distal weakness of upper > lower limbs.
- Cramps and twitching in affected limb.
- No sensory symptoms or signs.
- Weakness > atrophy in early stages.
- In affected limb, fasciculations, myokymia, and reduced reflexes.
- Cranial nerve involvement (bulbar) rare.

Differential diagnosis

- Motor neuron disease (spinal muscular atrophy variant).
- CIDP.
- Lead poisoning.
- Hexosaminidase A deficiency.

Investigations

- High titres of GM1 antibody in 80%.
- CSF normal.
- NCT: sensory studies normal; small CMAPS; conduction block (CB) outside usual entrapment sites. Reduced MCV in segments with CB. Localized denervation.

Treatment

- IV Ig 0.4 g/kg/day effective. Regular infusions necessary.
- In some patients steroids may cause deterioration.
- Oral or IV cyclophosphamide can be tried in resistant cases.

This page intentionally left blank

Vasculitic neuropathy

Epidemiology

Rare. Encountered in patients with systemic vasculitides or connective tissue disorders. Vasculitis may be restricted to peripheral nerves only. 6–12 /million/year.

Aetiology

Systemic necrotizing vasculitis

- Polyarteritis nodosa
- ANCA-associated (Churg–Strauss syndrome, Wegener's granulomatosis, microscopic polyangiitis).

Vasculitis associated with connective tissue disorders

- Rheumatoid arthritis.
- Sjögren's syndrome.
- SLE.

Hypersensitivity vasculitis

- Drug-induced vasculitis.
- Malignancy.

Infections

- Bacterial: Lyme, TB, syphilis.
- Viral: HIV, herpes zoster, CMV.

Isolated peripheral nerve vasculitis (IPNV)

Clinical features

- Mononeuritis multiplex progressing stepwise. In ↓ order of frequency:
 - common peroneal;
 - posterior tibial;
 - ulnar;
 - median;
 - radial;
 - femoral;
 - sciatic;
- 25% have a symmetrical sensory motor neuropathy at presentation.
- Dysaesthetic pain, 75%.
- Asymmetric onset clue to vasculitis.

Investigations

- Laboratory tests for underlying vasculitis or inflammatory disorder:
 - FBC, ESR;
 - renal and liver function;
 - urinalysis;
 - ANA, ds DNA, ENA, ANCA, rheumatoid factor;
 - C3, C4;
 - cryoglobulins;
 - hepatitis B, C;
 - ACE;

- Lyme;
- HIV.
- CXR
- NCT:
 - patchy; asymmetric neuropathy;
 - clinically asymptomatic lesions.
- Nerve ± muscle biopsy. See 'Investigations in peripheral nerve disorders'; p. 198.

Management

1. Discuss management with local vasculitis experts usually rheumatologists or nephrologists.
2. IPNV, commonly a monophasic illness, may not require cyclophosphamide, and steroids only may suffice.
3. Variety of protocols for treatment. Note: pulsed cyclophosphamide (IV or O) as effective as continuous oral but with less side effects and bladder toxicity.

Induction

IV cyclophosphamide 10–15mg/kg (max 1g) + IV methyl prednisolone 1g pulses. Every 2 weeks × 6. Oral steroids 20–30 mg continued if systemically unwell but stop within 3 months if possible

- Measure WBC at 7, 10, 14 days.
- If WBC < 3 (polymorphs < 2.5), ↓ dose for next pulse.
- If WBC at day 14 < day 10, delay treatment for 1 week.
- ↓ dose of cyclophosphamide if renal impairment.
- H₂ antagonist (e.g. ranitidine 150 mg bd).
- Bladder toxicity minimal with pulsed cyclophosphamide—mesna optional. Advise at least 3L per day on day of infusion and 24 hours later.
- Septrin 480 mg bd 3 × week for *Pneumocystis jiroveci* prophylaxis.

Maintenance

- Pulses 3-weekly × 4, then monthly 6–12 months.
- If in remission at 1 year consider azathioprine or methotrexate.

Muscle disorders: classification and features

Classification

Major classification between inherited and acquired disorders.

Inherited disorders

- Muscular dystrophy.
- Myotonic dystrophy.
- Congenital myopathies.
- Metabolic myopathies.
- Mitochondrial myopathies.
- Channelopathies.

Acquired disorders

- Inflammatory myopathies.
- Endocrine myopathies.
- Drug-induced myopathies.
- Metabolic myopathies.
- Toxic myopathies.

Clinical features

History

- Symptoms suggestive of proximal myopathy: difficulty rising from sitting position; reaching high shelves.
- Difficulty using aerosols: long flexors in IBM.
- Myalgia or tenderness.
- Exercise-related muscle cramps and pains (glycogen and lipid metabolic myopathies).
- Symptoms of myoglobinuria (dark urine).
- Dysphagia.
- Developmental history: delayed milestones, difficulty playing sports at school.
- Family history.
- Drugs, e.g. statins.

Examination

- Proximal weakness in upper and lower limbs.
- In IBM finger flexors and quadriceps particularly involved.
- Distal limb muscle involvement is seen in IBM but also in the inherited distal myopathies and the scapuloperoneal syndrome.
- Involvement of extraocular muscles:
 - oculopharyngeal muscular dystrophy (OPMD) in association with bulbar and limb involvement;
 - chronic progressive external ophthalmoplegia (CPEO) in isolation or as part of the Kearns–Sayre mitochondrial syndrome.
- Facial muscles are involved in:
 - myotonic dystrophy;
 - facioscapulohumeral (FSH) dystrophy.

- Severe weakness of the neck extensors leading to a 'dropped head':
 - due to an inflammatory myopathy that may be very localized;
 - also in MG and MND.
- Muscle hypertrophy, confined to the calves, is typically seen in Duchenne (DMD) and Becker (BMD) dystrophies. More general hypertrophy is a feature of myotonia congenita.
- Myotonia (slow relaxation) feature of MD and channelopathies.
- Muscle contractures occur in:
 - Emery–Dreifuss muscular dystrophy;
 - fibrosing myositis found in scleromyxoedema.
- Depressed or absent reflexes may suggest an associated neuropathy, (unless there is profound muscle wasting of the appropriate muscles). Consider:
 - paraneoplastic;
 - mitochondrial disorders.
- Skin rashes. Characteristic skin rash of dermatomyositis (Gottron's rash) over face and the extensor surfaces of the MP and IP joints.

Muscle disorders: investigations

Biochemical studies

- Serum creatine kinase (CK) best indicator of muscle disease. \uparrow up to $3 \times$ normal may occur following:
 - strenuous exercise;
 - IM injections and EMG studies;
 - viral infections.
- Highest levels of CK in inflammatory myopathies, acute rhabdomyolysis, and in early stages of DMD when the patient is still ambulant.
- Serum CK levels are normal in most congenital myopathies, myotonic syndromes as well as corticosteroid and thyrotoxic myopathies.
- In asymptomatic individuals \uparrow CK level may indicate:
 - a predisposition to malignant hyperthermia;
 - McArdle's disease;
 - early inflammatory myopathy;
 - carriers of DMD and BMD gene.
- In chronic denervating disorders such SMA and MND, CK levels \uparrow but never greater than $10 \times$ normal.
- Myoglobinuria will result in a positive urinary benzadine dip test, which also reveals haematuria and haemoglobinuria.
- Venous lactate \uparrow at rest or after exercise in:
 - patients with mitochondrial myopathy;
 - defects of the respiratory chain.
- Lactate production is \downarrow or absent in the metabolic myopathies due to defects in:
 - glycogenolysis (myophosphorylase or phosphorylase b kinase deficiency);
 - the glycolytic pathway (phosphofructose kinase and lactate dehydrogenase deficiency).

The forearm exercise test

- Venous blood samples are taken for estimation of lactate and ammonia at rest and at 1, 2, 4, 6, and 10 minutes after a one minute period of repetitive maximum isometric contractions of the forearm flexor muscles.
- Normally, there is a 2- or 3-fold \uparrow in lactate concentration within the first 2 minutes after exercise. \downarrow or absent in patients with defects in the glycogenolytic and glycolytic pathways.
- In patients with myoadenylate deaminase deficiency NH_3 production is reduced or absent.

Neurophysiology studies (NCT EMG) See Chapter 6.

EMG features of a myopathic disorder are:

- Motor unit action potential (MUAP) duration and amplitudes will be \downarrow .
- \uparrow number of polyphasic motor unit potentials.
- With voluntary contraction there is early recruitment of \uparrow numbers of short duration MUAPs with a full interference pattern.

- Spontaneous fibrillation potentials, positive sharp waves, and complex repetitive discharges prominent in inflammatory myopathies, toxic myopathies, e.g. chloroquine myopathy, metabolic myopathy such as hypothyroid myopathy, and some cases of DMD.
- In myotonic disorders pronounced increase in insertional activity with a diagnostic waxing and waning ('dive bomber') of myotonic discharges due to electrical instability of the muscle cell membrane.

Muscle biopsy

- Ideal muscle to biopsy is one that is only moderately affected (MRC grade 4).
- Select muscle that has not been the site of IM injections or EMG studies (may take at least 1 month for such changes to heal).
- Muscles that are very weak and/or atrophied will show non-specific end-stage changes and will be of little diagnostic use.
- Selection of needle versus open biopsy will depend on experience and availability.
- Open biopsy preferred in cases of inflammatory myopathies and where quantitative or molecular analyses required.
- Some of the muscle tissue obtained should be frozen for histological, histochemical, and immunohistochemical investigations. Latter technique will diagnose, using monoclonal antibodies, enzyme deficiencies, storage disorders, and the various dystrophinopathies and sarcoglycanopathies.
- Tissue should also be fixed in glutaraldehyde for electron microscopy, essential in the diagnosis of mitochondrial and IBM.

Molecular diagnosis

Molecular diagnosis is an increasingly important method of diagnosis but muscle biopsy remains the gold standard especially in *de novo* cases.

Muscular dystrophies

- X-linked recessive:
 - DMD, mutations in dystrophin gene (found in 70% cases);
 - BMD, mutations in dystrophin gene;
 - Emery–Dreifuss, mutations in EMD gene (encoding emerin).
- Autosomal dominant:
 - Myotonic dystrophy, DM protein kinase gene mutation;
 - FSH, deletions in 4q;
 - OPMD, PABP2 gene;
 - Emery–Dreifuss, mutations in LMNA gene (encoding lamin A and C);
 - Limb girdle dystrophies, mutations in genes coding for myotilin, lamin A/C, caveolin.
- Autosomal recessive:
 - Limb girdle dystrophies, various mutations including calpain 3, sarcoglycans.

Other investigations

- Imaging with CT and or MRI useful in detecting atrophy and hypertrophy or defining the extent of a polymyositis.
- Nuclear magnetic resonance spectroscopy may be useful in the evaluation of patients with glycolytic and mitochondrial dysfunction.
- ECG and echo essential for patients with DMD and BMD, MD, and ED.

This page intentionally left blank

Dermatomyositis, polymyositis, and inclusion body myositis

Clinical features of dermatomyositis (DM) and polymyositis (PM)

- DM, presentation subacutely over weeks but may be acute.
- PM, slower presentation over weeks or months.
- In DM the characteristic skin rash may precede muscle disorder.
 - Heliotrope (blue–purple) rash with oedema on upper eyelids.
 - Erythematous rash over cheeks, upper chest, upper posterior chest ('shawl sign'), and knuckles.
 - Erythematous scaly eruption over knuckles (Gottron's sign).
 - Dilated capillary loops at base of fingernails.
 - Lateral and palmar areas of hands become rough and cracked with 'dirty' horizontal lines ('mechanic's hands').
- Extramuscular complications:
 - in both DM and PM, interstitial lung disease 10% associated with anti-Jo 1 antibodies;
 - myocarditis and conduction abnormalities may occur;
 - in severe disease dysphagia may occur.

Clinical features of inclusion body myositis (IBM)

- Presentation is chronic over months and years.
- Most common acquired inflammatory disorder in those >50 years.
- Distribution of muscle weakness is clue to diagnosis.
 - Distal and proximal weakness especially finger flexors and ankle dorsiflexors.
 - Weakness and atrophy may be asymmetric.
 - Marked quadriceps weakness presents as falls.
 - Mild facial weakness may occur.
 - Dysphagia may be present early or late.

Investigations See Table 4.15.

Management of DM and PM

Corticosteroids

- Early aggressive management associated with better outcome—unless very indolent.
 - IV methylprednisolone 500 mg for 5 days, followed by oral prednisolone 1 mg/kg daily.
 - When CK normal and clinical improvement reduce by 5 mg alternate days over 2 months. Thereafter, dose gradually reduced monitoring CK and clinical state.
 - Note. Osteoporosis prophylaxis with baseline bone scan, bisphosphonate with Ca and vitamin D supplements

Table 4.15 Inflammatory myopathies

Characteristics	Polymyositis	Dermatomyositis	Inclusion body myositis
Age at onset	> 18 years	Any age, 2 peaks: 5–15 & 45–60 years	> 50 years
Female: male ratio	2:1	2:1	1:3
Familial association	No	No	Rarely
Association with: connective tissue diseases	Yes	Scleroderma, MCTD	Yes
Systemic autoimmune diseases	Yes	No	No
Malignancy	No	RR 1.3–2.1	4.4
Viruses	No	HIV, HTLV-1	No
Muscle involvement	Proximal symmetrical	Proximal symmetrical	Distal, proximal, asymmetrical, finger flexors, quadriceps
Atrophy	+	+	++
Serum CK (I)	Up to 50 ×	Up to 50 ×	Normal to 10 ×
EMG	Myopathic	Myopathic	Myopathic + mixed large units; 30% have signs of an axonal neuropathy
Muscle biopsy	Peri- & endomysial infiltrate, inflammatory infiltrate	Perifascicular atrophy Perivascular & perifascicular, inflammatory infiltrate	Endomysial infil- trate rimmed vacuoles
Cells	CD8 + T cells, macrophages	B cells, CD4 + T cells, macrophages	CD 8 + T cells, eosinophilic inclusions
EM		Tubulovesicular inclusions in capillary endothelium	Helical filaments, fibrils

RR = relative risk

- Consider starting immunosuppressant drugs at the same time to reduce steroid dose.
 - Azathioprine 2.5 mg/kg/day (check TPMT levels)
 - Methotrexate (up to 30 mg/day).
 - Other options: ciclosporin up to 5 mg/kg/day; oral cyclophosphamide 2 mg/kg/day; mycophenolate 2 g daily.

IV immunoglobulin

Effective but expensive; used in resistant cases.

Physiotherapy

- Maintain residual strength.
- Prevention of contractures.
- Supply of orthotics.

OT assessment

Home visit for advice re: home access, stairs, grab rails in bathroom etc.

Monitoring

- Primarily muscle strength and function rather than CK.
- Rising CK may herald relapse but may occur without a CK rise.
- Steroid-induced myopathy a possible concern.

Management of IBM

- Corticosteroids, immunosuppressant drugs, and IV Ig have not been shown to be of significant functional benefit.
- Trial of steroids may be considered if marked inflammatory cells on biopsy or very high CK.

This page intentionally left blank

Motor neuron disease: introduction and clinical features

Incidence: 2/100,000/year; prevalence 5/100,000. In UK, 1200 new cases/year. Age of onset: median 60 years, but up to 10% present < 40 years.

Aetiology

- 5–10% autosomal dominant inheritance.
- 20% of these have a mutation in gene for Cu, Zn superoxide dismutase (SOD1).
- Clustering in some areas, e.g. Guam (genetic and dietary factors).

Clinical features

Typical MND (amyotrophic lateral sclerosis)

- 70% of cases.
- Asymmetric onset of weakness in upper or lower limb (e.g. foot drop or hand weakness) or dysarthria or dysphagia.
- Variable mixture of upper and lower motor signs, e.g. weak, wasted triceps with brisk reflex.
- Widespread fasciculation may only be evident if patient examined carefully. Observe muscles for a few minutes.
- Fasciculating tongue (difficult sign in early stages).
- Neck flexion weakness.
- Corticobulbar signs, e.g. brisk jaw jerk.
- ↑↑ plantar responses.
- Abdominal reflexes retained.
- Sensory symptoms occasionally but no signs.
- Median survival 3–4 years.

Progressive bulbar palsy

- 20% cases.
- More common in elderly women.
- Onset with dysarthria and/or dysphagia.
- Limb involvement later, maybe years.
- Median survival 2–3 years.

Progressive muscular atrophy (PMA)

- 10% of cases.
- LMN weakness of arms or legs (e.g. 'flail arm variant' or Bernhard-Vulpian syndrome).
- Most develop bulbar symptoms.
- Median survival 5 years. Some 10 years.

Primary lateral sclerosis

- Slowly progressive, symmetrical upper motor neuron syndrome.
- Survival 15–20 years.

MND-dementia syndrome

- 5% of cases.
- Presentation with frontotemporal dementia.
- Later develop signs of MND.
- 3% of cases (30% of MND patients have frontal cognitive changes).

Other presentations to the neurologist that reveal the diagnosis on detailed history and examination:

- respiratory failure;
- wasted hand;
- weight loss;
- dropped head.

Other causes of motor neuron disorders

Genetic

- Spinal muscular atrophy (proximal and distal onset; autosomal recessive).
- Brown-Vialetto-Von Laere syndrome (early onset bulbar and spinal MND with sensorineural deafness).
- Fazio-Londe syndrome (infantile onset, bulbar, autosomal recessive).
- Hexosaminidase deficiency.
- X-linked bulbospinal muscular atrophy (Kennedy's syndrome)—mutation in androgen receptor gene:
 - facial and tongue fasciculations;
 - proximal symmetrical weakness;
 - gynaecomastia;
 - diabetes;
 - sensory neuropathy (on NCS).
- Hereditary spastic paraparesis.

Acquired

- Infections (poliomyelitis, HTLV-1, HIV).
- Prion disease (amyotrophic form of CJD).
- Toxins (lead, mercury).
- Endocrinopathies (↑ T4, hyperparathyroidism, insulinoma).

Mimics of MND

- Spondylotic myeloradiculopathy (cervical and lumbar).
- Multifocal motor neuropathy with conduction block.
- Foramen magnum lesions.
- Syringomyelia.
- Spinal dural fistulae.
- Inclusion body myositis.
- Myasthenia gravis.
- Benign cramp fasciculation syndrome.

Motor neuron disease: investigations and management

Investigations

First-line

- FBC, ESR.
- Biochemistry including Ca^{2+} , glucose, T4, CPK, immunoglobulins, and protein electrophoresis, VDRL + TPHA.
- Autoantibody screen.
- CXR.
- MRI, e.g. crano-cervical junction, lumbar spine.
- EMG and NCT (see Chapter 6)

Second-line

- CSF examination: protein may be slightly ↑; > 5 cells, markedly elevated protein, oligoclonal bands may suggest another diagnosis e.g. motor variant of CIDP, meningeal infiltration, HIV, or syphilis.
- ACh receptor antibodies.
- Anti-GM1 antibodies (MMN with CB).
- Anti-neuronal antibodies.
- Lead and mercury levels.
- Hexosaminidase levels (white cell enzymes).
- Muscle biopsy (inclusion body myositis).
- Nerve biopsy (if sensory abnormalities on NCT) for vasculitis.

Management

Involvement of a multidisciplinary team

- Physiotherapist.
- OT.
- Orthotics (neck brace, ASO).
- Speech and language therapy (communication aids, swallowing assessments).
- Dietician.
- In the later stages, palliative care.

Drug treatment

- Riluzole, 50 mg bd ↑ life expectancy by 3 months. Important psychologically for patient and family. LFTs need monitoring.

Symptomatic treatment**Table 4.16** Symptomatic treatment in MND

Symptom	Treatment
Cramps	Quinine sulphate, 200 mg bd; Carbamazepine, phenytoin, baclofen
Sialorrhea	Home suction device; atropine eye drops 0.5%, one drop instilled sublingual bd; hyoscine transdermal patches; amitriptyline 10 mg; glycopyrolate liquid
Thick secretions, weak cough	Carbocisteine 250–750 mg tds; assisted cough
Emotional lability	SSRI (citalopram)
Depression	Psychological support; antidepressants

Nutrition

- Consider percutaneous endoscopic gastrostomy (PEG) or radiologically inserted gastrostomy (RIG). Indications:
 - risk of aspiration;
 - > 10% loss of body weight despite nutritional supplements;
 - dehydration.
- PEG relatively safe if VC > 1l; if < 1l, RIG safer.

Respiratory support

Respiratory insufficiency may occur insidiously and requires regular assessment.

- Symptoms: orthopnoea, dyspnoea on mild exertion or talking, poor sleep, excessive daytime sleepiness (Epworth sleep score > 9), fatigue, impaired concentration, morning headache.
- Signs: ↑RR, paradoxical diaphragmatic movement, weak cough, tachycardia, confusion.
- Measure FVC sitting or standing and supine. If supine < 25% sitting, significant diaphragmatic weakness is present. FVC ≤ 80% predicted indicative of respiratory insufficiency.
 - May be difficult in patients with facial weakness or bulbar involvement.
 - Sniff nasal pressure may be more accurate. ≤ 40 mmHg = respiratory insufficiency.
- Blood gases (earlobe) $p\text{CO}_2 \geq 6.5 \text{ kPa}$ = respiratory failure.
- Nocturnal desaturation on overnight oximetry.
- Non-invasive ventilation (NIV) utilizes nasal or face masks and non-invasive inspiratory positive pressure devices (NIPPY).

Multiple sclerosis: introduction and clinical features

Multiple sclerosis (MS) is an inflammatory demyelinating disorder of the CNS defined by episodes disseminated in time and neuroanatomical location.

Epidemiology

- In the UK, 90,000 individuals affected.
- Incidence 7/100,000/year, prevalence 100–150/100,000.
- Female:male ratio 2:1.
- Rare before puberty and after the age of 60 years.
- Peak incidence in 30s and 40s.
- Incidence higher with increasing latitude.

Pathogenesis

- Two phases—initial inflammatory process (relapsing–remitting phase) followed by a degenerative phase (primary or secondary phase).
- An association with HLA DR15 and DQ6 suggests genetic susceptibility triggered by an environmental factor, e.g. infection with EBV or HHV6.

Clinical features

Subacute evolution of symptoms over days; symptoms reach a plateau and resolve over days or weeks.

- Transverse myelitis:
 - weakness, sensory symptoms;
 - urinary urgency and retention;
 - flexor spasms;
 - spastic quadra or paraparesis;
 - sensory level.
- brainstem:
 - ataxia;
 - diplopa;
 - dysarthria;
 - facial numbness;
 - internuclear ophthalmoplegia;
 - gaze palsy;
 - rubral tremor.
- Cerebellum:
 - ataxia, dysarthria, nystagmus.
- Optic neuritis: visual loss, painful eye movements, RAPD (relative afferent pupillary defect), impaired colour vision (Ishihara colour plates), ↓ acuity, optic atrophy.
- Cerebral hemispheres:(subcortical white matter)
 - poor memory;
 - disinhibition (late);
 - dementia (late).

- Cortical:
 - epilepsy (10%).
- Characteristic symptoms/signs:
 - Lhermitte's symptom. Neck flexion causes paraesthesiae or tingling down the spine due to a cervical cord plaque. Other causes: B₁₂ deficiency, cervical spondylosis, or tumour;
 - Uhthoff's phenomenon: worsening of symptoms, e.g. vision, when body temperature is raised due to, e.g. exercise;
 - Internuclear ophthalmoplegia. Other causes: vascular, Wernicke's encephalopathy, pseudo-INO in MG.

Course of disease

- 85% present with relapsing/remitting disease (RRMS).
- After 10–15 years, 50–60% enter the secondary progressive phase some with relapses (SPMS).
- 10% have primary progressive disease (PPMS) with gradual accumulation of disability.
 - Average age of onset is 40 years.
 - Males affected > females.

Multiple sclerosis: investigations and diagnosis

Investigations

MRI See Figs. 4.15 and 4.16.

- T2W high signal changes seen in the corpus callosum, periventricular white matter, brainstem.
- In patients >50 years white matter lesions are less specific as they are found in normal individuals and those with cerebrovascular disease and migraine.

Evoked responses

- Visual evoked responses (VER): delay is the most sensitive method of demonstrating previous optic neuritis even after clinical recovery.
- Somatosensory evoked potentials (SSEP) and brainstem evoked potential (BSEP) less useful.

CSF oligoclonal bands (OCB)

- Presence of OCB in the CSF not in the serum are indicative of inflammation confined to the CNS.
- Positive in 95% of clinically definite MS.
- May be present in other disorders such as paraneoplastic syndromes, vasculitis, autoimmune disorders, infections.

Diagnosis of MS

See box for the McDonald criteria for diagnosis of MS.

- MS is a clinical diagnosis with a prerequisite of evidence of lesions disseminated in time and place and to the exclusion of mimics.
- It is not possible to diagnose MS after a single monophasic episode even if there are multiple lesions on MRI as there is no dissemination in time.
- After an isolated episode of demyelination an abnormal brain MRI suggests that the likelihood of suffering a further attack and therefore of making a diagnosis of MS is 90% compared to 15% if the brain MRI is normal.

McDonald criteria for diagnosis of MS¹

- 2 or more episodes; objective clinical evidence of 2 or more lesions
- No additional tests required.

2 or more episodes; objective clinical evidence of one lesion

- dissemination in space shown by MRI (nine or more T2 lesions or one Gd enhancing lesion) or equivocal MRI (two or more lesions) + OCB in CSF or await further clinical episode at a different site.

One episode; objective clinical evidence of two or more lesions

- Dissemination in time shown by MRI or second clinical episode.

One episode; objective clinical evidence of one lesion

- Dissemination in space shown by MRI or equivocal MRI + OCB in CSF **and**
- Dissemination in time shown by MRI or second clinical episode

Insidious neurological progression suggestive of MS

- Positive OCB in CSF **and**
- Dissemination in space shown by MRI or abnormal VEP associated with equivocal MRI **and**
- Dissemination in time shown by MRI or continued progression for 1 year.

Note: MRI criterion for dissemination in time is that MRI of brain and or cord after at least 3 months should show new disease activity with at least one Gadolinium enhancing lesion.

¹ Mc Donald, W.I., et al. (2001) Recommended diagnostic criteria for multiple sclerosis: guidelines from the International panel on the diagnosis of multiple sclerosis. *Ann. Neurol.* 50 121–7.

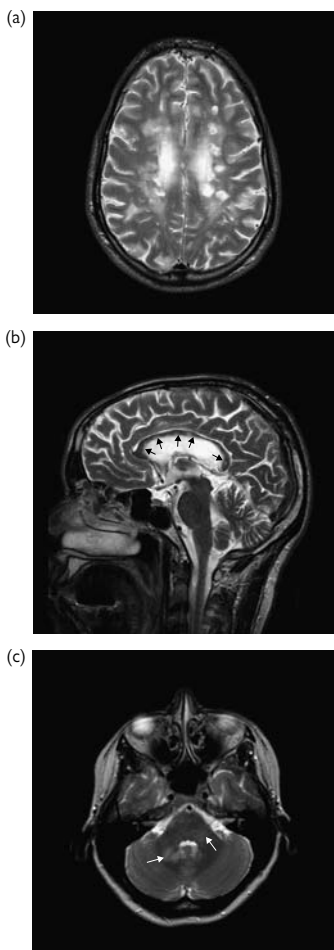


Fig. 4.15 Multiple sclerosis. (a), (c) T2-weighted axial; (b) sagittal T2-weighted MRI. Multiple rounded or ovoid deep cerebral white matter lesions with surrounding areas of ill defined less pronounced hyperintensity are typical. There is marked involvement of the corpus callosum demonstrated axially and sagittally (*black arrows*). involvement of the posterior fossa is common, in this case, lesions in the middle cerebellar peduncles are particularly suggestive of MS ((*c*) *white arrows*.) (a), (b) Note that there is loss of white matter volume and thinning of the corpus callosum in keeping with the latter stages of disease progression.

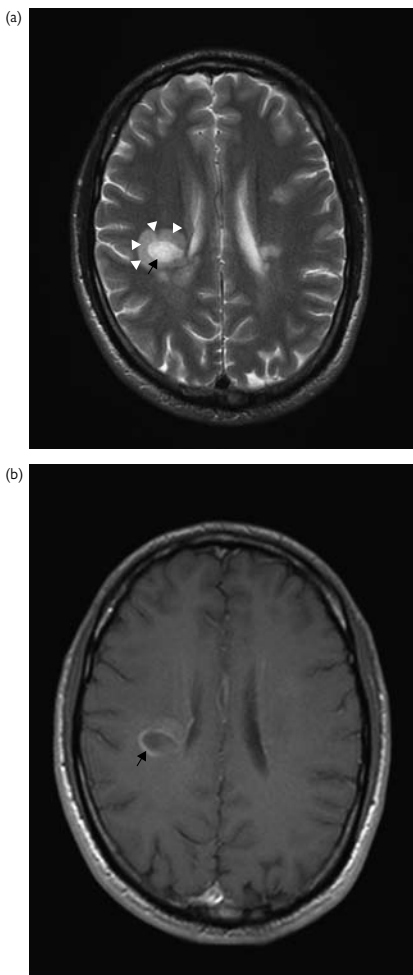


Fig. 4.16 Acute presentation of MS. (a) Axial T2-weighted and (b) axial post-contrast enhanced MRI. Several rounded hyperintense lesions in the deep cerebral white matter. The largest in the right corona radiata ((a) *black arrow*) is surrounded by a halo of slightly less hyperintensity ((a) *white arrowheads*) and demonstrates an incomplete ring of enhancement ((b) *black arrow*).

Differential diagnosis**ADEM**

- Usually antecedent infection or immunization.
- Monophasic.
- Fever, headache, meningism.
- Seizures.
- Coma.
- Multifocal neurological deficits.
- Bilateral ON.
- CSF pleocytosis, elevated protein,
- OCB positive in 30% and may disappear.
 - MRI shows larger lesions; involve grey matter; mass effect; uniform enhancement.

Neurosarcoidosis See Fig. 4.17

- Systemic features (lungs, skin, uveitis).
- Meningeal enhancement on MRI with Gd.
- Other investigations: ACE, CXR, gallium scan, lacrimal gland biopsy.

Neuromyelitis optica

- Optic neuritis and myelitis occur simultaneously or in rapid succession.
- MRI brain normal.
- OCB negative.
- NMO IgG antibody positive.

Other mimics

- SLE.
- Behçet's.
- Lyme disease.
- Primary CNS vasculitis.
- Leucodystrophies.

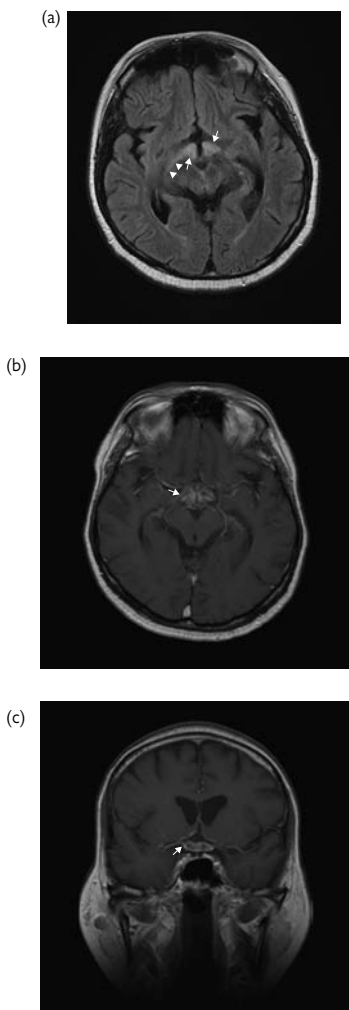


Fig. 4.17 Neurosarcoidosis (a) FLAIR axial; (b) and (c) axial and coronal post contrast enhanced MRI. There is hyperintensity, expansion and peripheral enhancement of the optic chiasm and hypothalamus (*small white arrows*) with extension of abnormal signal posteriorly along the right optic tract ((a) *white arrowheads*).

Multiple sclerosis: management

Acute relapses

- Corticosteroids hasten recovery.
 - IV methylprednisolone 1g daily for 3 days or 500 mg daily for 5 days.
 - Oral methylprednisolone 500 mg–2 g daily for 3 to 5 days.
- Side-effects (intravenous): flushing, psychiatric disturbance, insomnia, hyperglycaemia, hypertension. Exclude infection prior to treatment (MSU). Rarely, aseptic bone necrosis reported.

Disease-modifying treatments (DMT)

- Interferon beta is a natural cytokine with effects on the immune system. Three preparations are available:
 - IFN beta-1b (Betaferon[®]);
 - IFN beta-1a (Avonex[®]);
 - IFN beta-1a (Rebif[®]);
- Glatiramer acetate (Copaxone) is a combination of amino acids.
- All drugs ↓ frequency of relapse by 1/3: i.e. 3 to 2 relapses over 3 years.
- IFN beta reduces progression of disability compared to placebo. It is not clear if this is sustained.
- The effect of IFN beta in secondary progressive disease is unclear. May be effective in those with superimposed relapsing disease.
- IFN beta shows no effect in primary progressive disease.

In patients with aggressive disease unresponsive to IFN:

- Mitoxantrone.
- Monoclonal antibodies natalizumab and alemtuzumab (Campath-1H) should be considered.

Symptomatic treatment

Spasticity

- Treat any infections, constipation, pain.
- Physiotherapy essential.
- Baclofen starting 5 mg/day ↑ to 40 mg tds. Limited by side effects of sedation, muscle weakness.
- Tizanidine starting 2mg/day ↑ to 8 mg tds. LFT needs monitoring.
- Dantrolene starting 25 mg/day ↑ to 100 mg tds. Monitor LFTs.
- Gabapentin starting at 100 mg ↑ 800 mg tds helps tonic spasms or phasic spasticity.
- Focal spasticity, e.g. adductor spasm use botulinum toxin.
- In severe lower limb spasticity resistant to therapy, intrathecal baclofen via a pump.

Bladder dysfunction

There are three aspects of neurogenic bladder dysfunction:

- Detrusor hyperreflexia characterized by reduced capacity, urgency, frequency and incontinence.
- Detrusor/sphincter dyssynergia associated with urgency, delayed emptying, retention.

- Bladder hyporeflexia characterized by incomplete emptying and increased residual urine. All 3 may be present simultaneously.

Symptomatic treatment includes the following:

- Even distribution of fluid intake (2l)/day.
- Pelvic floor exercises help urgency and incontinence.
- Measure residual urine volume by catheter or bladder USS. If > 100 ml consider intermittent self catheterization. May be limited by disability.
- Detrusor hyperreflexia treated with:
 - oxybutynin 2.5 mg bd–5 mg bd;
 - oxybutynin XL 5 mg od;
 - tolterodine 2–4 mg/day;
 - tolterodine XL 4 mg od
- Nocturia managed by intranasal desmopressin 10–20 µg. Side effect hyponatraemia.

Fatigue

Fatigue is common and worsened by heat.

- Exclude other causes, e.g. ↓ Hb, ↑ T4.
- Fatigue management classes with aerobic training.
- Screen for depression and treat.
- Amantadine, 100–200 mg daily.
- Modafinil, 100–200 mg daily.

Myasthenia gravis: introduction, clinical features, and investigations

Epidemiology

- Prevalence 50–125/1,000,000.
- Peak incidence:
 - females in their 2nd and 3rd decades;
 - another peak affecting mainly males in their 6th and 7th decades.

Pathophysiology

- ↓ in the number of nicotinic AChRs at NMJ.
- Also conformational change, simplification, and ↑ gap at the neuromuscular junction.
- As a result of the decrease in receptors, the end-plate potentials (EPPs) ↓ amplitude and fail to trigger a muscle action potential. Neuromuscular fatigue occurs as increasing numbers of fibres fail to fire with repeated contractions.
- AChR antibodies are pathogenic: present in 85% of generalized and 50% of ocular MG patients. No correlation between the titres of antibody and disease severity.
- Subgroup of patients with seronegative MG have antibodies to the muscle-specific kinase (MuSK) protein.
- Thymus is abnormal in 75% of patients: hyperplasia (85%) and thymoma (15%).
- Other autoimmune conditions associated with MG: thyroiditis, Graves's disease, rheumatoid arthritis, SLE, pernicious anaemia, Addison's disease, vitiligo.

Clinical features

- Painless muscle weakness ↑ with exercise is the clinical hallmark.
- In early stages, weakness may be transient and variable often misdiagnosed as a functional disorder.
- In 15–20%, only the ocular muscles are involved: ptosis and/or diplopia.
- In 85% the weakness is generalized.
- Presenting features are ocular (70%), limb weakness (10%), generalized muscle weakness (9%), dysphagia (6%), dysarthria and dysphonia (5%), jaw weakness (4%), and neck weakness (1%).
- Rarely, respiratory failure and isolated foot drop may be the presentation.
- Certain muscles are preferentially affected: neck and finger extensors.
- Vital capacity measurement lying and standing essential. Peak flow measurement is unhelpful.
- Reflexes and sensory testing are normal.
- Patients with longstanding disease may be left with fixed muscle weakness.
- MG may be exacerbated by:
 - hyperthyroidism (found in 3%);
 - occult infection;
 - drugs (aminoglycosides, quinine, anti-arrhythmic drugs).

Investigations

Serum AChR antibody test: highly specific for MG.

Repetitive nerve stimulation: sensitive in 50–60% of cases (see chapter 6).

Single fibre EMG studies: detect delay or failed neurotransmission in pairs of muscle fibres supplied by a single nerve fibre. Specialized technique positive in 90% but is not specific to MG and may be found in other NMJ disorders.

Tensilon (edrophonium) test: uses a rapid onset (30 seconds) short-acting (5 minutes) cholinesterase inhibitor drug given IV. If there is unequivocal improvement in a muscle that can be tested objectively the test is positive.

- Difficult to interpret in borderline cases.
- Potential cardiac-side effect of the test (bradycardia)—therefore performed with full resuscitation measures being available.
- Two observers should be present.
- Sequence of test is as follows:
 - IV atropine 600 micrograms before edrophonium (optional);
 - test dose 3 mg edrophonium;
 - if no response, 7 mg given.

Post-contrast CT or MRI: of the mediastinum looking for thymoma.

Other tests: striated muscle antibody occurs in 90% of patients with thymoma compared with 30% in all MG patients. Thyroid function, thyroid antibodies, vitamin B₁₂, and intrinsic and gastric parietal cell antibodies.

Differential diagnoses

Generalized MG

- Lambert–Eaton syndrome.
- Botulism.
- Drug-induced myasthenia (penicillamine).
- Congenital myasthenic syndromes.
- Inflammatory myopathies.
- Motor neuron disease (bulbar onset).

Ocular MG

- Thyroid ophthalmopathy.
- Mitochondrial disease (progressive external ophthalmoplegia).
- Intracranial mass lesion (cavernous sinus).
- Wernicke's encephalopathy.
- Oculopharyngeal muscular dystrophy (OPMD).

Myasthenia gravis: management

Cholinesterase inhibitors

Pyridostigmine bromide (Mestinon) acts within 1 hour with duration of action of 4 hours. The 2–4–6 starting regimen may be used:

- 30 mg twice daily: 2 days;
- 30 mg five times daily: 4 days;
- 60 mg/30 mg/60 mg/30 mg/60 mg: 6 days;
- 60 mg five times daily: thereafter.
- The maximum dose is rarely more >300 mg a day.
- Higher doses cause muscle twitching and increased weakness. Overdosage causes a cholinergic crisis with bulbar and respiratory muscle weakness. Patients need to be warned.
- Side-effects: caused by effects on muscarinic smooth muscle NMJ—abdominal pain and diarrhoea that responds to propantheline 15–30mg PRN.

Prednisolone

- Steroids indicated in patients not adequately controlled with cholinesterase inhibitors and who are unsuitable for thymectomy.
- Prednisolone usually started as an inpatient because of the risk of deterioration which occurs in 50% of MG patients at 7–21 days (steroid dip).
- Initial starting dose of 10 mg on alternate days is ↑ every 2 or 3 days to a dose of 1–1.5 mg/kg on alternate days.
- Improvement begins after 2–4 weeks with maximal benefit at 6–12 months.
- After 3 months or when remission is evident the dose is slowly tapered to the minimum dose required. A small dose may be required on the off day to prevent fluctuation of strength.
- Few patients may be able to do without steroids.
- All patients should be started on osteoporosis prevention with a bisphosphonate. HRT should be considered in post-menopausal women.
- Patients should be advised to carry a steroid card.

Azathioprine

- Azathioprine, with its actions predominantly on T cells, is used:
 - for those in whom corticosteroids are contraindicated;
 - for those with an insufficient response to corticosteroids;
 - as a steroid-sparing agent.
- Combination of steroids and azathioprine acts synergistically.
- TPMT levels need to be measured to predict the risk of haematological side-effects.
- Starting dose is 50 mg/day for 1 week increasing by 50 mg/week to a dose of 2.5 mg/kg/day.
- Desirable haematological endpoints are:
 - WBC < 3500/mm³;
 - lymphocyte count < 1000/mm³;
 - MCV > 100 fL.

- Blood tests (FBC and LFT) necessary every week for 2 months and then 3 monthly for the duration of treatment.
- Therapeutic benefit may not be apparent for up to 12 months.
- Side-effects:
 - 5% have a hypersensitivity reaction with nausea, abdominal pain, fever, rash or arthralgia in which case the drug must be stopped;
 - bone marrow suppression;
 - hepatotoxicity.

Other immunosuppressants

- In patients intolerant of azathioprine, ciclosporin 2–5 mg/kg/day in two divided doses (total dose 125–250 mg twice daily) may be considered. Side-effects include nephrotoxicity and hypertension. Trough drug levels need monitoring.
- Methotrexate is also used as a steroid sparing agent (7.5–20 mg once weekly + folate).
- Mycophenolate mofetil 1g bd.

Plasma exchange and IV immunoglobulin

- Both may be used for patients in myasthenic crisis with severe bulbar and respiratory compromise.
- Patients may also be pre-treated prior to thymectomy.
- Patients with seronegative MG may also respond. The effects last 4–6 weeks.
- Plasma exchange: 5 exchanges, 3 to 4 litres per exchange over 2 weeks.
- IV immunoglobulin: 0.4 g/kg/day for 5 days.

Thymectomy

- Procedure should be carried out in units with adequate surgical and post-operative experience of management of MG patients.
- Mortality rate in such institutions is the same as for general anaesthesia.
- Post-operative anticholinesterase medication is given IV at a dose of 75% of the pre-operative oral dose.

Indications

- Prevention of local spread of a thymoma. If complete removal cannot be achieved, post-operative radiotherapy is necessary. Some patients with thymoma may become weaker after thymectomy and require further immunosuppressive treatment.
- Therapeutic benefit in MG (generalized and less often in ocular myasthenia): results in complete remission in some patients or a reduction in immunosuppressive medication in others.
- No randomized controlled trials in patients under the age of 45 years with AChR antibodies: general consensus on its benefit.
- Surgery should be considered before starting corticosteroids if clinically feasible.
- In patients over the age of 45 years and those who are AChR antibody negative, there is controversy.

- In children surgery should be deferred until after puberty since the thymus has a role in the development of the immune system.
- Benefits of thymectomy may not be evident for months or years after surgery.

Summary of MG management See Fig. 4.18.

Ocular MG

- In patients with pure ocular MG who do not completely respond to pyridostigmine, corticosteroids are necessary. Often low doses may be adequate.
- Thymectomy is an option in younger, AChR antibody positive patients.
- If the extraocular muscle weakness is consistent, prisms may help the diplopia.
- Ptosis props help to hold up the eyelids.
- Where deficits are chronic and static corrective surgery may be an option.

Women and MG

- 14% of babies born to mothers with MG develop neonatal MG due to the placental transfer of maternal antibodies.
- Weakness may be apparent days after birth and last for days or months. Treatment is not necessary.
- Some patients have antibodies to fetal as well as adult AChRs. This may result in recurrent miscarriage or give rise to fetal deformities such as arthrogryposis multiplex congenita or facial deformities.
- Corticosteroids and azathioprine are both teratogenic. Adequate advice on contraception and pre-pregnancy counselling are necessary.

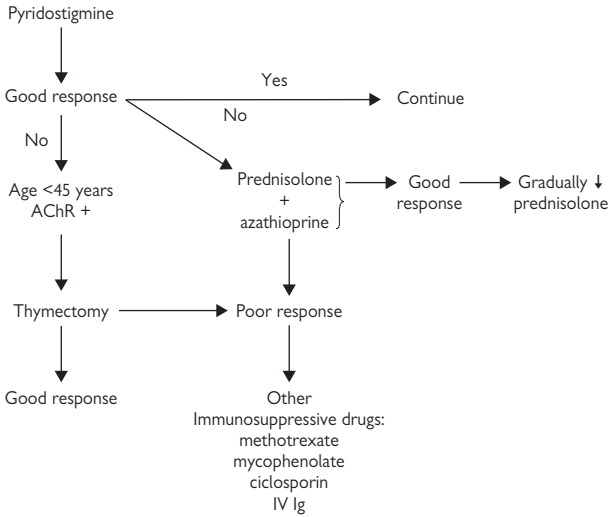


Fig. 4.18 Flow chart for the management of MG.

Paraneoplastic disorders: introduction

- Term applies to all non-metastatic neurological conditions in which no specific aetiology such as vascular, metabolic, or treatment-related causes can be identified.
- Important to note that a particular antibody can be found in a number of different syndromes and that one syndrome can be associated with different antibodies.
- Usually a neurological presentation in a patient not known to have cancer.
- Clinical picture is usually with a subacute progressive syndrome but may rarely be one with slow progression, relapses, and remissions or a benign course.
- Since there is evidence of a biologically effective immune response against the tumour, tumours may initially remain small or only locally invasive.

Table 4.17 Paraneoplastic disorders, associated antibodies, and cancer types

Syndrome	Paraneoplastic antibody	Associated cancer
Lambert–Eaton myasthenic syndrome (LEMS)	VGCC	SCLC
Subacute cerebellar degeneration	anti-Hu	SCLC
	anti-PCA-2	SCLC
	Anti-Yo	Ovary, breast
	Anti-Ta/Ma2	Testis
	Anti-Ri	Breast
	Anti-Tr	Hodgkin's lymphoma
Opsoclonus/myoclonus (children)	Anti-Hu	Neuroblastoma
Opsoclonus/myoclonus (adult)	Anti-Ri	Breast
	Anti-Hu	SCLC
	Anti-Ma	Various
	Anti-ta/Ma2	Testis
Subacute sensory neuropathy/neuronopathy	Anti-Hu	SCLC
	Anti-amphiphysin	SCLC
	ANNA-3	SCLC
	Anti CRMP5/CV2	SCLC, thymoma
Limbic encephalitis	Anti-Hu	SCLC
	Anti-Ta/ma2	Testis
	ANNA 3	SCLC
	Anti-CRMP5/CV2	SCLC, thymoma
Retinopathy	Anti-Hu	SCLC
	Anti-recoverin	SCLC
Stiff person (anti-GAD) syndrome	Anti-amphiphysin	Breast

Key: VGCC, voltage gated calcium channel; SCLC, small cell lung cancer; anti-PCA-2; anti-purkinje cell antibody; anti-GAD, anti-glutamic acid decarboxylase antibody

Paraneoplastic syndromes: central nervous system

Limbic encephalitis

- Presents with short-term anterograde with variable retrograde memory disturbance.
- May be associated with denial and confabulation.
- Epileptic seizures (as a partial non-convulsive status).
- Acute confusional state, psychiatric symptoms (such as personality change, hallucinations, depression) may coexist.
- MRI (Fig. 4.19): hyperintensity signal change in mesial temporal lobes.
- CSF: mild pleocytosis and oligoclonal bands.
- Pathologically, there is neuronal loss in the amygdala and hippocampi.
- Differential diagnosis includes:
 - tumours;
 - infective meningoencephalitis (HSV);
 - thiamine deficiency;
 - venous thrombosis;
 - vasculitis;
 - amnesic syndrome with K^+ channel antibodies.

Encephalomyelitis with or without rigidity (spinal interneuronitis)

- Generalized disorder may occur.
- Cognitive change.
- Seizures.
- Brainstem, cerebellar, and myelopathic symptoms and signs.
- Patients present initially with sensory symptoms such as dysaesthesiae followed by the development of stiffness and rigidity.
- Painful stimulus-sensitive spasms.
- Myoclonus.
- Profuse sweating.
- Natural history is progression to death in 3 years.
- Differential diagnosis includes stiff person syndrome with anti-GAD antibody.

Cerebellar degeneration

- Rapidly evolving syndrome over days and weeks.
- Affects gait, speech, trunk, and limbs.
- Vertigo, nausea, vomiting, and downbeat nystagmus.
- Differential diagnosis:
 - tumours;
 - infections;
 - drugs.
- MRI: cerebellar atrophy.
- CSF: mild pleocytosis with oligoclonal bands.

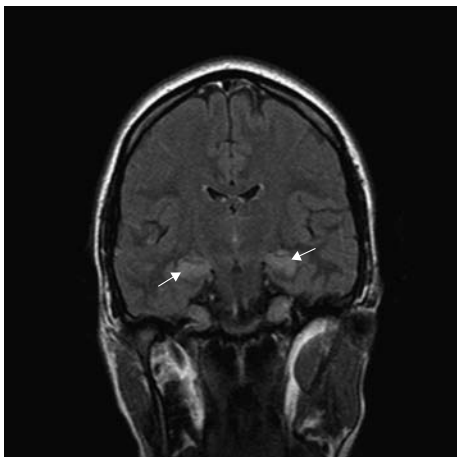


Fig. 4.19 Limbic encephalitis (coronal FLAIR MRI). Symmetric hyperintensity and swelling of the hippocampus bilaterally (*white arrows*). While paraneoplasia is the most common aetiology, potassium channelopathies, status epilepticus, and hypoxic injury are other causes.

Opsoclonus, myoclonus, and ataxia

- 'Dancing eyes, dancing feet syndrome' occurs as a result of damage to the fastigial nucleus of the cerebellum or may arise from dysfunction of omnipause neurons in the pons.
- Opsoclonus is defined as involuntary, chaotic, and repetitive rapid eye movements. In children this is due to either a neuroblastoma or a viral infection.

Rhombencephalitis

- Generalized brainstem syndrome may occur with gaze palsies; respiratory involvement with central sleep apnoea.
- Differential diagnosis:
 - Infections such as listeria;
 - Inflammatory conditions such as Behçet's.

Retinopathy

- Rare.
- Associated with melanoma.
- Symptoms include painless loss of visual acuity, photosensitivity, abnormalities of colour vision (cone symptoms), and night blindness (rod symptoms).
- Electroretinogram is flat even though vision may be relatively preserved.
- Differential diagnosis: vascular and vasculitic disorders such as giant cell arteritis; optic neuritis; drugs and toxins; Leber's optic atrophy.



This page intentionally left blank

Paraneoplastic syndromes: peripheral nervous system

Sensory neuropathy/neuronopathy

- Typically patients present with an asymmetrical painful sensory neuropathy that gradually evolves to loss of proprioception with pseudoathetosis and a severe sensory ataxia.
- Onset may be in the upper limbs, which is unusual in peripheral neuropathies.
- Rate of progression variable.
- There may be motor involvement.
- Nerve conduction tests may show both axonal and demyelinative changes.
- In sensory neuropathy/neuronopathy sensory action potentials are absent with no or minor motor abnormalities.
- Differential diagnoses:
 - CIDP;
 - vasculitis;
 - neuropathy due to nutritional deficiencies;
 - Sjögren's syndrome.

Motor neuron syndromes

- Three groups identified in cancer patients with motor neuron syndromes:
 - some are anti-Hu positive and will go on to develop involvement of other areas of the nervous system;
 - patients, usually women, who present with an upper motor syndrome that resembles primary lateral sclerosis and also have breast cancer;
 - patients who have both amyotrophic lateral sclerosis and cancer coincidentally.
- There may be an association between lymphoma and cancer.
- Differential diagnosis includes multifocal motor neuropathy with conduction block, which is associated with anti-GMI antibodies.

Autonomic neuropathy

- Autonomic failure may be a paraneoplastic manifestation with postural dizziness, abdominal pain, diarrhoea, gastroparesis, pseudo-obstruction, and oesophageal achalasia.
- Differential diagnoses include:
 - Guillain-Barré syndrome;
 - amyloid neuropathy;
 - Fabry's disease;
 - autonomic variant of multiple system atrophy.

Lambert–Eaton syndrome (LEMS)

- 60% of cases, this is a paraneoplastic disorder usually associated with a small cell lung cancer.
- 40% autoimmune (usually female and younger patients).
- Voltage-gated calcium channel antibody does not discriminate between the two.
- Clinical presentation:
 - proximal weakness around the pelvic girdle with or without weakness around the shoulder girdle;
 - weakness improves with sustained or repeated exercise;
 - reflexes reappear after exercise (post-tetanic accentuation);
 - cranial nerve involvement occurs in 30% (dysphagia, dysarthria, ptosis, and diplopia);
 - autonomic involvement is manifested with symptoms of a dry mouth.
- EMG studies show:
 - a reduced amplitude of the CMAP after a single supramaximal stimulus;
 - an increase after exercise (post-exercise facilitation);
 - a decremental response to repetitive stimulation at 3 Hz with an incremental response $> 200\%$ at > 30 Hz.
- Single fibre studies reveal increased jitter.
- Tensilon test may be positive in LEMS but never to the extent seen in myasthenia gravis.
- Other causes of myopathy also need to be considered.

Paraneoplastic syndromes: investigations and management

Tumour identification

- Careful clinical examination should include looking for:
 - clubbing;
 - careful skin examination for melanoma;
 - lymphadenopathy at all palpable sites;
 - breast palpation;
 - testicular palpation;
 - PR examination;
 - PV examination (by gynaecologist if necessary).
- Tumour markers:
 - PSA (prostate specific antigen);
 - CEA (carcinoembryonic antigen) for GI malignancy;
 - CA125 (for ovarian cancer).
- Imaging:
 - CXR;
 - CT or MRI of chest, abdomen, and pelvis;
 - mammography;
 - increasing role for the use of positron emission tomography (PET) in detection of cancers if the above investigations are negative.

Management

Treatment of the tumour if possible should be the first line of management. Paraneoplastic peripheral syndromes and those due to Hodgkin's disease seem to have the best response.

Immunological therapy

- No controlled data.
- As a first line of treatment consider IV methylprednisolone 1 g/day for 3 days.
- IV immunoglobulin 0.4 g/kg/day—anecdotal reports of benefit especially in stiff person syndrome.

Symptomatic treatment

- Opsoclonus: clonazepam, propranolol.
- Myoclonus: clonazepam, valproate, piracetam.
- LEMS: 3, 4 diaminopyridine, pyridostigmine.
- Stiff person syndrome: diazepam, clonazepam, baclofen.

This page intentionally left blank

Vertigo, dizziness, and unsteadiness: introduction

- Common problem.
- Differentiate between labyrinthine symptoms (vertigo and dizziness) and unsteadiness (staggering, off balance), which may be due to a variety of neurological and general medical disorders, e.g. posterior fossa tumours.
- In the elderly, the clinical picture may result from multiple pathologies.

Vertigo

- Vertigo is an illusion of movement, which is typically rotational but can also be tilting or swaying.
- Underlying mechanism is an asymmetry of neural activity between the right and left vestibular nuclei.
- Vertigo is always temporary even after vestibular nerve section because of neurochemical compensatory changes in the brainstem.
- Other clinical features of vertigo:
 - nausea and vomiting;
 - worse with head movement and patients prefer lying still.

Acute first episode of vertigo See 'Acute vertigo', pp. 58–61.

Recurrent episodes of spontaneous vertigo

Classified by duration of the vertigo.

Vertigo lasting a few seconds:

- Benign paroxysmal positional vertigo (BPPV). (See 'Benign paroxysmal positional vertigo', pp. 258–61.)

Vertigo lasting minutes or hours

- Ménière's disease.
 - Due to intermittent endolymphatic hypertension
 - Produces attacks of severe vertigo, nausea, and vomiting with low-frequency hearing loss, tinnitus, and a sense of fullness in the affected ear.
 - Audiogram essential: low-frequency hearing loss.
 - In the early stages the caloric and audiogram tests may be normal but with repeated episodes progressive hearing loss will be apparent and may fluctuate.
 - Treatment ↓ sodium intake aiming for a urinary sodium of less than 50 mmol/day. Thiazide diuretics: bendroflumethiazide 2.5 mg. Surgical options as a last resort include endolymphatic sac surgery and intracranial vestibular nerve section. Transtympanic gentamicin labyrinthectomy will stop the disabling vertigo but will not prevent hearing loss.

- Migraine.
 - Vertigo may form part of the aura in vertebrobasilar migraine and is followed by the typical throbbing headache.
 - Some migraineurs, however, only suffer with vertigo and nausea without a significant headache component.
 - Standard migrainous therapies are helpful.
- Rarely, partial seizures may present with vertigo. Usually history of epileptic seizures.
- A post-operative, post-traumatic, or cholesteatoma-associated perilymph fistula may produce vertigo especially on straining. This is associated with hearing loss
- Episodic ataxia (see p. 266–7).

Dizziness, unsteadiness, or 'off balance': neurological causes

Important to assess and examine carefully for the following possible causes.

Peripheral labyrinthine disorder (PLD)

- Patients with an uncompensated PLD complain of constant 'dizziness'.
- History of a previous acute vestibular neuritis or significant head injury.

The neurological examination:

- Assess the gait looking for unsteadiness especially on turning; tandem gait with eye closure is impaired in vestibular disorders and also in patients with large fibre neuropathy and posterior spinal cord pathology.
- Patients with bilateral vestibular failure, providing they have no signs of a neuropathy will not be able to stand on foam with eyes closed.
- Unterberger's test (see p. 60) may indicate vestibular abnormality but will not differentiate between central and peripheral causes.
- The head impulse test (Fig. 3.1, p. 59), if positive, implies absent lateral semicircular canal function on the affected side.
- Eye movements assessed for nystagmus, pursuit, and saccades
- Corneal reflexes should be tested in case of an acoustic neuroma, although other signs will be found.
- Hearing tested at the bedside using Rinne's and Weber's tests.
- The external auditory meati and tympanic membranes must be viewed with an auroscope.
- Hallpike's test See Fig. 4.20 p. 258, must always be performed.
- Caloric testing helpful in confirming lateral canal paresis.
- Bilateral vestibular failure patients (usually due to gentamicin toxicity) complain of vertigo, oscillopsia, and unsteadiness. There is a degradation of visual acuity with rapid head movements due to an inability to fixate.

Cerebellar disorder

- Broad-based gait or poor tandem gait.
- Eye movements usually reveal broken up pursuit and hypometric saccades.
- Finger–nose and heel–shin ataxia.
- Aetiology (see pp. 72–5):
 - tumours;
 - paraneoplastic;
 - hereditodegenerative (SCA).

Basal ganglia disorders

- Progressive supranuclear palsy may present with unsteadiness and a tendency to fall backwards.
- Autonomic dysfunction in MSA and PD will result in postural dizziness due to hypotension.

Hemispheric lesions

- Parietal lobe lesions may present with unsteadiness of gait and no other signs.
- Frontal lobe lesions cause gait disorders which are described as unsteadiness.
 - Aetiology: tumours or small vessel disease.

Hydrocephalus

Spinal cord disorders

- MS.
- B₁₂ deficiency.

Peripheral neuropathy

- Large fibre neuropathy affecting proprioceptive fibres will cause unsteadiness and a positive Romberg's sign.
- Associated autonomic neuropathy will cause postural hypotension: diabetes, amyloid, HIV.

Primary orthostatic tremor Unsteadiness on standing only. Auscultate calf muscles.

Benign paroxysmal positional vertigo (BPPV)

BPPV is characterized by brief attacks of rotatory vertigo provoked by rapid changes in head position relative to gravity.

Incidence Most common cause of dizziness, about 20%.

Pathophysiology

- BPPV is a mechanical disorder due to the movement of debris (canalolithiasis) within the endolymph to the most dependant part of the canal during head position changes.
- Posterior semicircular canal is the most commonly affected followed by the horizontal and, least often, the anterior semicircular canal.

Clinical features

- Antecedent events include head trauma and viral infections with or without acute labyrinthitis. In some, may occur during the course of a progressive inner ear disease such as Ménière's disease.
- Typical symptoms:
 - vertigo on turning over in bed, lying down, or sitting up from the supine position;
 - vertigo on looking up or bending forward.
- Diagnosis is made by the observation of the typical features of peripheral positional nystagmus (Table 4.18) using Hallpike's manoeuvre (Fig. 4.20).
- Typical features of posterior canal BPPV with a normal CNS examination. No further investigation unless:
 - no response to repositioning manoeuvres;
 - nystagmus is atypical such as down-beating nystagmus;
 - In these circumstances MRI indicated.

Treatment

In cases with a positive Hallpike's test:

- Epley liberatory manoeuvre (Fig. 4.21).
- Semont (Fig. 4.22); Brandt–Daroff positional exercises.
- These manoeuvres are effective in 80–90%

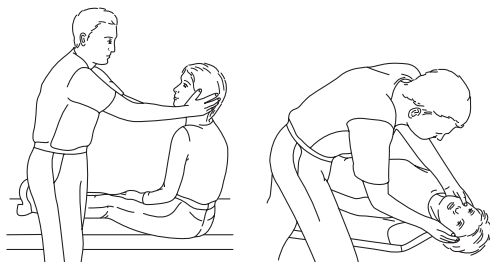


Fig. 4.20 Dix–Hallpike manoeuvre.

The natural history for BPPV is for spontaneous resolution with exacerbations, but the condition persists in 30% if untreated.

In patients with a typical history but with negative Hallpike's, manoeuvres for the horizontal and anterior canals should be performed, i.e. variations of the Hallpike test.

Table 4.18 Characteristics of peripheral vs central positional nystagmus

Symptom/sign	Positional nystagmus	
	Peripheral	Central
Latency (time to onset of nystagmus or vertigo)	0–40 s (mean 7.8s)	No latency
Duration	< 60 s	Symptoms, signs persist
Fatigability (lessening signs/symptoms with repetition)	Yes	No
Nystagmus	Fixed direction, torsional upwards towards the lower most ear.	Variable
Intensity of symptoms and signs	Severe vertigo with nausea.	Mild. Nausea rare. Marked nystagmus
Reproducibility	Inconsistent	Consistent

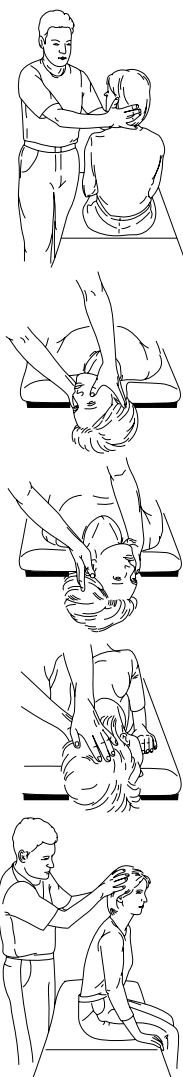

Fig. 4.21 Epley's manoeuvre. Treatment of left posterior canal BPPV.

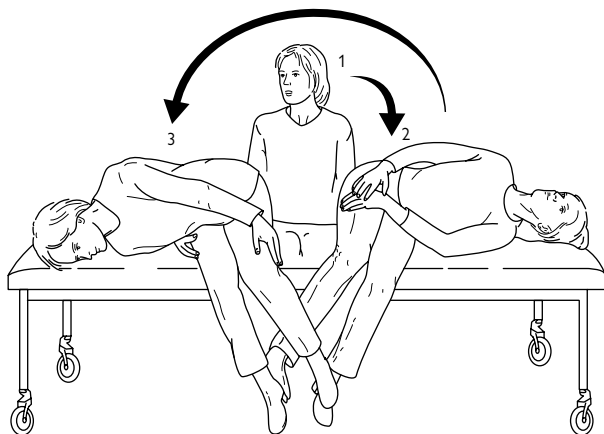


Fig. 4.22 Semont's manoeuvre. Treatment of left posterior canal BPPV.

Instructions

- 1 Sit on edge of the bed.
- 2 Lie down sideways to position which brings on vertigo.
- 3 Change sides.
- 4 Remain until symptoms subside.
- 5 Sit up for 30 seconds.
- 6 Lie down on appropriate side for 30 seconds.

Continue this sequence of positioning until symptoms resolve. Repeat exercises 3–4 times a day until 2 consecutive vertigo-free days.

Dizziness, unsteadiness, or ‘off balance’: non-neurological causes

Cardiological

If symptoms suggest presyncope consider:

- vasovagal attacks;
- carotid hypersensitivity;
- postural hypotension;
- cardiac arrhythmias such as paroxysmal atrial fibrillation and Stokes–Adams attacks.
- Severe aortic stenosis causes presyncope especially during exertion.

Ophthalmological

- Cataracts and macular degeneration.
- Visual field defects may cause subtle unsteadiness.
- Eye movement disorders such as an internuclear ophthalmoplegia.

Differential diagnoses:

- MS;
- AVM;
- cerebrovascular disease;
- Wernicke’s encephalopathy.

Hyperventilation

- May be due to anxiety as a result of any of the above diagnoses and will compound the symptoms of dizziness and unsteadiness.
- Hyperventilation may be a sign of asthma or other lung disorder such as a PE or interstitial lung disease.
 - CXR and lung function tests necessary.
 - Constant sighing may be a clue to chronic hyperventilation.
 - ↓ pCO₂ symptoms include paraesthesiae, cold extremities, light-headedness and dizziness, chest discomfort, and a sense of weakness especially on the left.
 - Reproduce symptoms by asking patient to force hyperventilate for 3 minutes.
 - Hyperventilation is not a diagnosis. Identify underlying cause, which may be anxiety due to, for example, worry about underlying serious disease, psychological distress, or pain.

Other general medical causes

Check FBC, renal, liver, thyroid function, Ca, PO₄.

This page intentionally left blank

Neurogenetic disorders: introduction

- 10% of neurological patients have single gene mutation disorders.
- Family history essential. May require contacting other hospitals, consultant colleagues, and GPs.
- Examination of other family members helpful.
- Absence of a FH may be due to:
 - autosomal recessive or X-linked inheritance;
 - new mutation;
 - non-paternity;
 - reduced penetrance;
 - variable phenotypes;
 - phenomenon of anticipation—milder disease in preceding generations.
- Distinction between diagnostic and predictive (or presymptomatic) testing.
 - Diagnostic test: symptomatic patient. Purpose of test is to determine cause.
 - Predictive test. At risk but asymptomatic individual tested to determine if the mutant gene is present. Risk of developing the disease depends on penetrance.
- Pretest counselling mandatory.
- Signed consent mandatory.
- Request form requires detailed FH and clinical phenotype.
- Prenatal testing available for some disorders by chorionic villous biopsy. Counselling essential and discussions regarding any interventions, i.e. termination if test is positive.

This page intentionally left blank

Hereditary ataxias

Early onset ataxias (< 20 years)

Autosomal recessive disorders: Friedreich's ataxia

Gene

Trinucleotide (GAA) mutation in Frataxin gene. 96% have an expansion in both alleles. Others have a point mutation in one allele and expansion in other. Diagnosis excluded if two normal sized alleles.

Clinical features

- Gait ataxia.
- Pyramidal weakness and signs, extensor plantars.
- Axonal peripheral neuropathy (absent ankle jerks).
- Optic atrophy.
- Abnormal eye movements: nystagmus, broken pursuit, hypometric saccades, macrosaccadic square wave jerks.
- Deafness.
- Skeletal abnormalities:
 - pes cavus;
 - scoliosis.
- ECG abnormalities: widespread T wave inversion.
- Diabetes or glucose intolerance.

Differential diagnoses

- Vitamin E deficiency.
- Abetalipoproteinaemia.
- Ataxia telangiectasia (conjunctival telangiectasia, IgA deficiency, frequent infections, risk of malignancy; ATM gene).
- Mitochondrial disorders.
- Cholestanosis (cerebrotendinous xanthomatosis). Tendon xanthomas, ataxia, spasticity, neuropathy, cataracts.

Late onset ataxias (>20 years)

These are usually autosomal dominant (ADCA). All have features of cerebellar ataxia (Table 4.19).

Table 4.19 Characteristics of autosomal dominant cerebellar ataxias (ADCA)

Clinical features	Gene
ADCA type I (complex) ± Pyramidal signs ± supranuclear ophthalmoplegia ± extrapyramidal signs ± peripheral neuropathy ± dementia	SCA1, SCA2, SCA3, SCA12, SCA17
ADCA type II Pigmentary retinopathy ± any other signs for type I (above)	SCA7
ADCA type III Pure cerebellar ± mild pyramidal signs. Late onset	SCA6

Episodic ataxias

Table 4.20 Characteristics of episodic ataxias EA1 and EA2

Features	EA1	EA2
Age at onset (years)	3–20	3–30
Duration of attack	Minutes	Hours–days
Interictal myokymia	+	–
Response to acetazolamide	+/-	++
Progressive ataxia	No	Sometimes. Interictal nystagmus
Seizures	Sometimes	No
Gene	K ⁺ channel, KCNA1	Na ⁺ channel, CACNA1A

Genetic neuropathies

Figure 4.23 shows a flowchart for demyelinating hereditary neuropathies.

Charcot–Marie–Tooth disease

- Common condition: prevalence 1:2500.
- NCT helps to classify into:
 - demyelinating: upper limb MCV < 38 m/s. Other clues: homogeneous rather than patchy slowing which may indicate CMT1 X or acquired demyelinating neuropathy;
 - axonal: upper limb MCV > 38 m/s;
 - intermediate: upper limb MCV 25–45 m/s may indicate CMT1 X.

Demyelinating neuropathy (CMT1)

- CMT1a most common form. AD. 70% caused by duplication in peripheral myelin protein 22 gene (PMP22) on chromosome 17p11.2.
- CMT1b. AD. Caused by mutations in human myelin protein zero (P0) on chromosome 1q22–q23.
- CMT1d caused by mutations in early growth response 2 gene (EGR) on chromosome 10 (rare).
- Dejerine–Sottas disease (and congenital hypomyelinating neuropathies) which present in the first decade and are more severe characterized by point mutations in PMP22, P0, and EGR2.

Axonal neuropathy (CMT2)

Fewer genes identified.

In sporadic and AD axonal neuropathy:

- mitofusin 2 (mitochondrial GTPase);
- if no male to male transmission or sporadic or index case female: Connexin 32. If negative: P0, neurofilament light chain (NFL), and KIF1B beta.

Intermediate cases

- Check chr 17 first. If negative and no male to male transmission CMT X caused by mutations in Connexin 32 gene.
 - Males more severely affected than females.
 - Females may be axonal, males demyelinating.
 - Neurophysiology: patchy demyelination.
 - Rarely, CNS involved (plantars ↑).
- If negative: P0, PMP22, and EGR2 point mutations.

Hereditary neuropathy with liability to pressure palsies (HNPP)

Autosomal dominant. Gene: PMP22 deletion.

Clinical features

- Recurrent pressure palsies.
- Recurrent brachial plexopathy.
- Transient sensory symptoms.
- NCT shows patchy, demyelinating neuropathy.

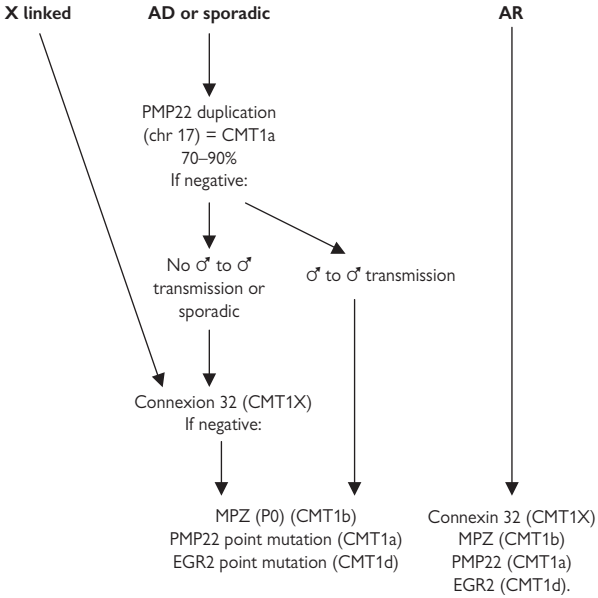


Fig. 4.23 Hereditary demyelinating neuropathies

Hereditary sensory and autonomic neuropathies (HSAN) or hereditary sensory neuropathies (HSN)**HSAN I**

- Autosomal dominant.
- Clinical features:
 - prominent sensory loss;
 - lancinating pains;
 - complications of ulceration and amputation;
 - motor involvement: may resemble CMT with prominent sensory involvement;
 - SPTLC1 gene or RAB 7 gene mutations.

HSAN II

- Autosomal recessive.
- No gene identified.
- Clinical features:
 - early onset;
 - sensory symptoms in limbs and trunk.

HSAN III (Riley–Day syndrome)

- Autosomal recessive.
- Mutations in IKAP gene.
- Clinical features.
 - autonomic symptoms predominate;
 - sensory and motor involvement.

HSAN IV

- Autosomal recessive.
- Mutations in TRKA gene.
- Clinical features:
 - congenital insensitivity to pain;
 - anhidrosis;
 - recurrent episodes of fever;
 - self-mutilating behaviour;
 - mental retardation;
 - loss of unmyelinated fibres on biopsy.

HSAN V

- Autosomal recessive.
- Mutations in TRKA gene.
- Clinically similar to HSAN IV.
- Loss of small myelinated fibres on biopsy.

This page intentionally left blank

Inherited myopathies

Inherited myopathies with limb–girdle weakness

Duchenne's (DMD) and Becker's (BMD) muscular dystrophies (X-linked dystrophy)

- DMD: incidence 3/1000 per live born ♂; prevalence 3/100,000.
- BMD: Incidence 0.3/1000; Prevalence 0.3/100,000.

Clinical features

- BMD is the milder form with better prognosis.
- Presentation in early childhood with walking difficulty and toe walking.
- Other features:
 - Gower's manoeuvre;
 - calf hypertrophy; contractures.
- Wheelchair dependant around age of 10–12 years in DMD.
- Scoliosis compromises respiratory function.
- Cardiomyopathy occurs in both DMD and BMD.

Diagnosis

- CK ↑ > 10,000.
- DNA detection of mutation in dystrophin gene found in 70%.
- If negative muscle biopsy with dystrophin, immunological studies necessary.

Management

- In DMD use of steroids controversial.
- Ventilatory support increases quality and life expectancy.

Limb–girdle muscular dystrophy syndromes

Clinical features

- Range of phenotypes from non-specific limb–girdle weakness to those resembling the X-linked muscular dystrophies.
- Facial weakness not a feature.
- Variable cardiac and respiratory complications.

Genetics

Table 4.21 Genetics of limb–girdle muscular dystrophy (LGMD) syndromes

Syndrome	Chromosome	Protein
Autosomal dominant		
LGMD1A	5q	Myotilin
LGMD1B	1q	Lamin A/C
LGMD2C	3p	Caveolin
Autosomal recessive		
LGMD2A	15q	Calpain
LGMD2B	2p13	Dysferlin
LGMD2C	13q	γ -Sarcoglycan

Diagnosis Muscle biopsy mandatory to identify abnormal protein by immunohistochemistry in order to focus DNA studies.

Proximal myotonic myopathy (PROMM)

- AD disorder similar to myotonic dystrophy but with limb–girdle rather than distal weakness.
- Muscle pain and stiffness prominent features.
- Gamma GT levels \uparrow .
- Genetic defect in zinc finger gene on chromosome 3.

Inherited myopathy with distal weakness**Miyoshi's myopathy**

- AR.
- Onset in teens with weakness and wasting of gastrocnemius muscle progressing to involve more proximal muscles.
- CK markedly \uparrow .
- Muscle biopsy shows dystrophic changes.

Welander's myopathy

- AD.
- Onset between 4th and 6th decades.
- Weakness in the upper limbs (wrist and finger extensors) and wasting of hand muscles followed by foot drop and leg weakness.
- CK normal or slightly \uparrow .
- Muscle biopsy shows myopathic changes with rimmed vacuoles.

Nonaka myopathy (hereditary inclusion body myopathy type 2)

- AR.
- Onset with tibialis anterior weakness and wasting.

Other inherited myopathies**Facioscapulohumeral (FSH) muscular dystrophy**

- AD.
- Prevalence: 1–2/100,000.

Clinical features

- Onset in teens with facial weakness. Weakness of scapular fixators results in upward displacement ('chicken wings').
- Deltoid is spared but there is weakness of humeral muscles (biceps and triceps).
- Leg weakness is common affecting hip flexors, quadriceps, and tibialis anterior.
- Asymmetric weakness, usually worse on the right, is the rule.
- Risk of being wheelchair bound is 20%.
- No cardiac complications.

Diagnosis

- CK ↑ several-fold
- EMG myopathic.
- DNA diagnosis by demonstration of a truncated region at chromosome 4q35.
- Muscle biopsy may show inflammatory changes confusing the diagnosis.

Emery–Dreifuss muscular dystrophy (see p. 217)

- X-linked and AD inheritance.

Clinical features

- Progressive scapulo-humeral peroneal weakness.
- Thin muscles.
- Contractures of cervical extensors, biceps, and long finger extensors characteristic.
- Cardiac conduction defects with atrial paralysis with absent or small p waves causing sinus bradycardia requiring pacing.

Diagnosis Muscle biopsy required for immunocytochemistry to demonstrate absence of lamin A/C and emerin.

This page intentionally left blank

Myotonic dystrophy (MD)

MD is a multisystem disorder characterized by myopathy and myotonia. The incidence is 1/8000 live births.

Genetics

- Autosomal dominant disorder with full penetrance but variable expression.
- Gene abnormality is an expansion in the CTG trinucleotide repeats in the dystrophica myotonica protein kinase gene.
- Anticipation, the increased clinical severity in succeeding generations, well recognized.

Clinical features

Phenotype varies from a lethal severe congenital myopathy to late-onset cataracts.

- Neuromuscular:
 - myotonia;
 - distal muscle weakness (hand and foot drop) with progression to proximal muscles;
 - facial weakness;
 - temporalis, masseter, and sternomastoid wasting and weakness.
- CNS:
 - somnolence;
 - cognitive impairment.
- Cardiac:
 - conduction defects with heart block and tachyarrhythmias due to fibrosis in the conduction system and SA node;
 - cardiomyopathy;
 - risk of sudden death and anaesthetic complications.
- Eyes: cataracts.
- Endocrine:
 - diabetes mellitus and impaired GTT;
 - testicular atrophy;
 - repeated miscarriages and menstrual irregularities;
 - frontal hair loss.
- Smooth muscle involvement:
 - oesophageal problems;
 - respiratory infections;
 - recurrent cholecystitis.

Investigations

- Serum CK may be ↑.
- EMG: myopathic and myotonic features.
- DNA testing for triplet expansion > 5–30 in the DM-PK gene.

Management

- Genetic counselling especially as the severe congenital form occurs in the offspring of affected females with > 100 repeats.
- Prenatal diagnosis available.
- Myotonia if symptomatic—mexilitine if ECG QT interval normal.

This page intentionally left blank

Inherited movement disorders

Parkinson's disease (PD)

PARK 2 (Parkin)

- AR.
- Young onset PD but onset 70 years also described.
- 50% cases onset < 50 years.
- Excellent response to L-dopa.
- Marked sleep benefit.
- Hyperreflexia.
- Early dystonia.
- Very slowly progressive.

PARK 1 (alpha synuclein)

- AR.
- Rare.

Huntington's disease

- AD with full penetrance.
 - Expansion of CAG trinucleotide repeat > 36 repeats.
 - Expansion size inversely related to age of onset.
 - ↑ expansion with each generation—'anticipation'.
 - Prenatal diagnosis available.

Clinical features

- Onset 4th and 5th decades.
- Movement disorders:
 - chorea, initially fidgetiness;
 - parkinsonism—juvenile onset Westphal variant;
 - dystonia.
- Psychiatric features:
 - change in personality.
- Dementia.
- Other features:
 - slowed saccades;
 - head thrust or blinking to generate saccades;
 - progressive weight loss.

Differential diagnosis

- Dentatorubropallidoluysian atrophy (DRPLA).
- ADCA I.
- Hallervorden–Spatz disease (AR, caused by mutation in the pantothenate kinase gene (PANK 2)).
- Neuroferritinopathy (AD, adult onset neurodegenerative disorder associated with iron accumulation in the basal ganglia).

Dystonia

Primary (Oppenheim's) dystonia

- Prevalence 1:3000. Common in Ashkenazi Jews.
- AD:
 - DYT 1 gene on chr 9 (coding for torsin A protein);
 - low penetrance (30%);
 - variable expression.

Clinical features

- Childhood onset
- Initially focal (foot); variable spread to segmental or generalized.
- Craniocervical muscles spared.

Dopa-responsive dystonia (DRD)—Segawa's disease

- AD:
 - mutation in gene for GTP cyclohydrolase 1;
 - AR form due to mutation in tyrosine hydroxylase gene.

Clinical features

- Childhood lower limb onset progressing to generalized dystonia.
- Diurnal variation in symptoms.
- Mild parkinsonism.
- Paraparesis presentation.
- Also cases described similar to cerebral palsy.
- Exquisite response to L-dopa

Management

- Therapeutic trial of L-dopa in all cases of dystonia < 30 years: Sinemet 275 tds for 3 months.
- In equivocal cases phenylalanine loading test.

Inherited mitochondrial disorders

Table 4.22 summarizes the major inherited mitochondrial disorders.

- Mitochondrial DNA maternally inherited.
 - deletions, e.g. KSS and CEO, usually sporadic and not transmitted.
 - point mutations, e.g. MELAS, MERRF, LHON, maternally transmitted.
- Nuclear DNA encodes some respiratory chain proteins. Therefore AD (e.g. Leigh's syndrome).
- Consider mitochondrial disorders in any patient with multi neuraxis involvement especially if sensory neural deafness.

Investigations

- CK.
- MRI brain (see Fig. 4.24).
- Serum and CSF lactate.
- NCT and EMG studies.
- Blood mt-DNA studies: ↓ mtDNA with age.
- Muscle biopsy:
 - ragged red fibres;
 - COX-negative fibres;
 - mitochondrial enzyme analysis.

Table 4.22 Inherited mitochondrial disorders

Syndrome	Phenotype	Inheritance	Mutation
CPEO	Chronic progressive external ophthalmoplegia ± myopathy	AR, AD, maternal	Deletions, point mutations
Kearns-Sayre (KSS)	Ophthalmoplegia, pigmentary retinopathy, cardiac arrhythmia, ataxia, ↑ CSF protein	Not transmitted	Deletions not found in blood; need muscle biopsy
MELAS	Mitochondrial myopathy, encephalopathy, lactic acidosis, stroke-like episodes	Maternal	Point mutation A3243G
MERRF	Myoclonus, epilepsy, ragged red fibres + ataxia, neuropathy, deafness, lipomas	Maternal	Point mutation A8344G
Leber's hereditary optic neuropathy (LHON)	Optic neuropathy. In female carriers: MS like syndrome	Maternal	Point mutations
NARP	Neuropathy, ataxia, retinitis pigmentosa	Maternal	Point mutations
MIINGIE	Mitochondrial myopathy, neuropathy, GI involvement encephalopathy	AR	Point mutations

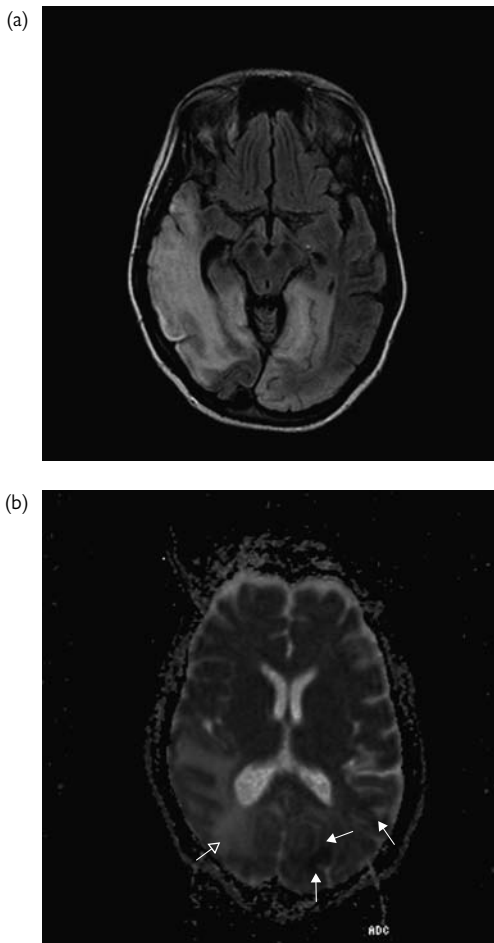


Fig. 4.24 Mitochondrial encephalopathy, lactic acidosis, and stroke-like episodes (MELAS). (a) Axial FLAIR and (b) ADC map MRI. Bilateral asymmetric confluent lobar signal abnormality involving both grey and white matter with a typically posterior predilection and failure to conform to vascular territories is the most common presentation. (b) Note the involved parenchyma demonstrates both areas of restricted (hypointense on ADC map; *white arrows*) and free diffusion (hyperintense on ADC; *open white arrow*).

Inherited dementias

Alzheimer's disease

- Sporadic AD:
 - no single gene;
 - apolipoprotein E (ApoE) 4 allele \times 3 (heterozygote) or \times 8 (homozygote) risk of developing AD.
- $<$ 5% AD inherited. 3 genes:
 - beta-amyloid precursor protein (APP) ($<$ 5% early onset AD);
 - presenilin 1 (50% early onset familial AD);
 - presenilin 2 ($<$ 1%).
- No specific features to distinguish sporadic from familial apart from early onset.

Frontotemporal dementia (FTD)

- FTD with parkinsonism
- Gene on chr 17q21 (tau protein)
- Clinical features:
 - behaviour change;
 - parkinsonism;
 - psychotic symptoms;
 - amyotrophy.

HD See 'Inherited movement disorders', p. 278.

Prion diseases

Normal PrP coded by gene on chr 20.

Familial CJD

- Most common point mutation at codon 200.
- Earlier onset than sporadic CJD.
- Otherwise indistinguishable from sporadic CJD.

Gerstmann–Straussler–Scheinker syndrome

- Point mutation codon 102.
- Onset 3rd or 4th decades.
- Cerebellar features.
- Dementia.
- Progressive over years.

Fatal familial insomnia

- Onset 20–70 years.
- Progressive insomnia.
- Autonomic features.
- Memory impairment.

This page intentionally left blank

Inherited neurocutaneous syndromes

Tuberous sclerosis

- AD.
- Mutation on tumour suppression genes 1 on chr 9q34 or 2 on chr 16p13.3.

Clinical features

- Childhood epilepsy.
- Cognitive impairment.
- Adenoma sebaceum.
- Subungual fibromas.
- Shagreen patches.
- Ashleaf patches (under UV light).
- Risk of malignancy—astrocytomas, cardiac rhabdomyomas, renal angioliipomas.

CT

Shows paraventricular calcification, hamartomas.

Neurofibromatosis 1 (NF1)

- AD.
- Mutation of NF1 gene, chr 17q (neurofibromin).
- Clinical phenotype:
 - café au lait patches, axillary freckling;
 - plexiform neuromas (risk of sarcomatous change);
 - optic nerve and brain gliomas;
 - pheochromocytoma.

Neurofibromatosis 2 (NF2)

- AD.
- Mutation in NF2 gene, chr22 (Schwanomin).
- Clinical features:
 - bilateral acoustic neuromas;
 - meningiomas.

Von Hippel–Lindau disease

- AD.
- Mutation in VHL tumour suppressor gene.

Clinical features

- Cerebellar haemangioblastomas.
- Retinal angiomas.
- Renal tumours.
- Polycythaemia.
- Pheochromocytoma.

Screening programme for VHL patient (annual)

- Physical examination.
- Urine testing + 24 hour VMA collection.
- Renal USS.
- Direct and indirect ophthalmoscopy with fluorescein angiography.
- Brain MRI every 3 years.

Sturge–Weber syndrome

- Port wine stain (V1).
- Buphthalmos.
- Epilepsy.
- Cognitive impairment.
- Intracranial calcification.

Hereditary metabolic diseases

May present in adulthood. see Table 4.23 for a summary.

Table 4.23 Characteristics of hereditary metabolic diseases

Disorder	Clinical features	Investigations
Niemann-Pick type C	Supranuclear gaze palsy, dementia, organomegaly	Bone marrow: foamy storage cells, sea blue histiocytes: NPC1 gene
Abetalipoproteinaemia (X-linked)	Ataxia, head tremor	Acanthocytes, lipoprotein electrophoresis: ↓ cholesterol
Adrenoleucodystrophy	Spasticity, neuropathy, dementia	MRI: leucodystrophy. Very long chain fatty acids. Synacthen test
Fabry's disease	Painful neuropathy young stroke, skin lesions	Alpha galactosidase deficiency
GM1 gangliosidosis	Extrapyramidal features	Beta galactosidase deficiency
GM2 gangliosidosis	Spasticity, dementia, motor neuropathy/ neuronopathy	Hexosaminidase deficiency
Metachromatic leucodystrophy	Neuropathy, dementia, spasticity	Arylsulphatase A deficiency. MRI: leucodystrophy
Tangier's disease	Neuropathy, orange tonsils	High density lipoprotein deficiency
Arginase deficiency	Spasticity, dementia	Hyperammonaemia

This page intentionally left blank

Infectious disease: bacterial meningitis

Incidence and microbiology Annual incidence around 2–3/100,000 with peaks in infants and adolescence. Vaccination against *Haemophilus influenzae* type b and group C meningococcus has had significant impact.

Risk factors

- Splenic dysfunction or splenectomy e.g. sickle cell disease (*Streptococcus pneumoniae*).
- T lymphocyte defects due to chemotherapy, malignancy, HIV (*Listeria monocytogenes*).
- Skull fracture, middle and inner ear fistulas (*S. pneumoniae*).
- Penetrating skull trauma, CSF shunts (staphylococcus).
- Mucosal epithelial damage, e.g. smoking, recent viral illness.
- Consider tuberculous meningitis in those from endemic areas.
- In the immunosuppressed, e.g. HIV—cryptococcal meningitis and TB.

Clinical features

Presenting features typically with headache, fever, photophobia, neck stiffness. In addition:

- cranial nerve palsies (IIIrd, IVth, VIth, VIIth);
- focal neurological deficits;
- seizures (20–30%). Usually in *S. pneumoniae* and *H. influenzae* meningitis
- ↑ ICP (altered conscious level, hypertension, bradycardia, abnormal respiratory pattern, papilloedema (late));
- purpura or petechial haemorrhages (non-blanching with glass test): *Neisseria meningitides*;
- septic shock: *N. meningitides*.
- Tuberculous meningitis may be more insidious with gradual development of fever, weight loss, headache with progression to focal deficit, altered consciousness.
- Look for evidence of immunosuppression as may be the first presentation of HIV or lymphoproliferative disorder, e.g. oral candidiasis, lymphadenopathy.

Investigations

- 1 Blood culture as latex agglutination bacterial antigen tests or PCR can be performed and may remain positive even after antibiotics.
- 2 CXR for evidence of TB.
- 3 CT scan does **not** exclude raised ICP. See p. 500—indications.
- 4 Lumbar puncture is contraindicated if:
 - signs of ↑ICP;
 - ↓ GCS;
 - coagulopathy;
 - focal symptoms, signs or seizures (unless CT scan normal);
 - cardiovascular compromise;
 - infection of skin at LP site.
- 5 See Table 4.24 for lumbar puncture and blood findings in different forms of meningitis.

Table 4.24 LP findings in meningitis

Condition	CSF pressure (mmH ₂ O)	WBC (u/l)	Protein (g/l)	Glucose (mmol/l)
Normal	50–200	<5 lymphocytes	0.2–0.45	75% blood glucose
Bacterial meningitis	↑	100–60 000, mainly neutrophils	0.5–5	< 40% blood glucose
Tuberculous meningitis	↑	10–500, neutrophils in early disease, lymphocytes later	0.5–5	↓ < 40% of blood glucose
Fungal meningitis	↑	25–500, mainly lymphocytes	0.5–5	↓
Viral meningitis	Normal or ↑	↑ lymphocytes	0.5–2	Normal

Management**Choice of antibiotic**

Choice of antibiotic depends on age of patient and any other associated features, e.g. immunocompromised. CT or LP should not delay first dose of antibiotic.

In adults likely organisms are:

- *Streptococcus pneumoniae*;
- *Neisseria meningitidis*;
- if > 50 years, *Listeria monocytogenes*.

Drug recommendation before identification of organism

- Meningitis with **typical** meningococcal rash:
 - 2.4 g benzyl penicillin 4-hourly or ampicillin 4-hourly.
- Meningitis without typical rash:
 - cefotaxime 2 g 6-hourly or ceftriaxone 12-hourly *plus* +
 - vancomycin (in suspected *S. pneumoniae* until sensitivities are known in case of resistance) 500 mg 6-hourly *plus* +
 - ampicillin 2 g 4 hourly if > 50 years (to cover listeria).

If clear history of betalactam anaphylaxis:

- chloramphenicol 25 mg/kg 6-hourly +
- vancomycin 500 mg 6-hourly;
- if > 50, years add cotrimoxazole to cover listeria.

Therapy after identification from CSF or blood

- *N. meningitidis*:
 - 2.4 g benzylpenicillin IV 4-hourly or ampicillin 2 g 4-hourly.
 - If history of allergy to betalactams chloramphenicol 25 mg/kg IV 6-hourly.
- *S. pneumoniae*:
 - ceftriaxone or cefotaxime;
 - add vancomycin or rifampicin 600 mg 12-hourly if patient from penicillin-resistant area.
- *H. influenzae*: cefotaxime or ceftriaxone.
- *L. monocytogenes*: ampicillin 2g 4-hourly + gentamicin 5 mg/kg divided into 8-hourly doses.
- Tuberculosis meningitis: isoniazid 5–10 mg/kg 24 hourly + rifampicin 8–15 mg/kg 24 hourly + pyrazinamide 20–30 mg/kg 24 hourly + pyridoxine 25 mg;

↑ ICP

A medical emergency. Patient should be managed on ITU. Give mannitol, 0.25 g/kg IV over 10 minutes. May require sedation, intubation, and ventilation to reduce pCO₂ and controlled hypothermia.

Seizures

Should be treated initially with lorazepam 4 mg IV, followed by phenytoin 18 mg/kg as a loading dose under ECG monitoring followed by maintenance dose IV. If seizures continue treat as for status epilepticus.

Corticosteroids

Shown to reduce morbidity in adults specifically in *S. pneumoniae* and tuberculous meningitis. Data does not include meningococcal meningitis but it is reasonable to consider at least until organism isolated—10 mg dexamethasone 6-hourly IV for 4 days with first dose given with first antibiotic dose.

Viral encephalitis

Infection of the brain parenchyma is usually accompanied by a meningitis producing a meningoencephalitis. The organism is identified in only 30–50% of cases.

Incidence

- Herpes simplex encephalitis (HSV-1), most frequent cause of sporadic fatal encephalitis: 1 case per million per year probably an underestimate.
- In the far east Japanese B encephalitis causes 15 000 deaths/year.

Aetiology See Table 4.25.

Clinical features

- Essential to take a full travel history (e.g. Japanese B encephalitis).
- History of animal bites (e.g. rabies).
- No association between HSV-1 and cold sores.
- Presentation, especially for HSV encephalitis, acute with:
 - headache;
 - fever;
 - focal neurology (e.g. dysphasia);
 - seizures;
 - encephalopathic presentation with confusion, delirium, behavioural changes, and coma.
- Untreated mortality 70%.
- With aciclovir still high at 20–30%.

Differential diagnosis

Diffuse encephalopathy

- Liver and renal failure.
- Diabetic coma.
- Anoxic/ischaemic brain injury.
- Systemic infection.
- Toxic drug effects.
- Mitochondrial cytopathies.

Non-viral causes of infectious encephalitis

- *Mycobacterium tuberculosis*.
- *Mycoplasma pneumoniae*.
- *Listeria monocytogenes*.
- *Borrelia burgdorferi*.
- Brucellosis.
- Leptospirosis.
- Legionella.
- All causes of pyogenic meningitis.
- Fungal: cryptococcus, aspergillosis, candidiasis.
- Parasitic: human African trypanosomiasis, toxoplasmosis, schistosomiasis.

Acute disseminated encephalitis (ADEM) May have a similar presentation but clues include recent vaccination, spinal cord and optic nerve involvement, and widespread white matter involvement on MRI.

Table 4.25 Aetiology of viral encephalitis

Worldwide distribution	Geographically specific
HSV -1 and 2	Western equine virus
EBV	Eastern equine virus
CMV	California encephalitis
VZV	St Louis encephalitis
HHV6	Japanese B encephalitis
Non-polio enteroviruses	Tick-borne encephalitis
Mumps	West Nile virus
Rabies	
HIV (at seroconversion)	

Investigations

- Routine blood investigations may reveal a metabolic aetiology.
- CXR to exclude TB, legionella, mycoplasma, and neoplasia.
- Baseline virology serology may later provide evidence of recent infection.
- CT/MRI: gyral swelling and signal abnormality/low attenuation which is typically bilateral but asymmetric \pm haemorrhage.

EEG

- Emergency EEG may be necessary to make diagnosis. Look for diffuse non-specific abnormalities or periodic lateralizing epileptiform discharges 'PLEDS'.
- In H. simplex encephalitis PLEDS may be bilateral and evolve with differing periodicity over each lobe.
- If PLEDS occur away from the temporal lobe, interpret with caution.
 - May improve spontaneously and rapidly.

LP

- Lymphocytic pleocytosis 10–200/mm³.
- Protein, 0.6–6 g/l.
- Rarely, the CSF may be normal.
- CSF PCR to detect HSV-1 is 95% specific. Sensitivity if taken 2–10 days after onset is 95%. False negative results most likely in the first 48 hours and after 10 days.

Management

- Aciclovir (10 mg/kg tds) immediately diagnosis is suspected. Continue for 14 days. It should only be discontinued if an alternative definite diagnosis is made. In immunosuppressed patients treat for 21 days. Note. Renal toxicity may occur and needs to be monitored. 5% of patients may relapse.
- Best predictors of outcome are treatment within 4 days of onset, GCS > 6 at presentation.
- Steroids if there is evidence of raised ICP.
- AED for seizures.
- May need HDU /ITU monitoring.

This page intentionally left blank

Neurology of HIV/AIDS: introduction

- HIV infection can affect the whole neuraxis and at all stages of the illness.
- Different pathological processes can be present simultaneously.

Basic principles

- 10% of patients may have a neurological disorder at seroconversion:
 - meningoencephalitis;
 - myelitis;
 - GBS;
 - Polymyositis.
- Persistent CSF abnormalities, even during the asymptomatic phase, include:
 - mild pleocytosis;
 - ↑ protein;
 - oligoclonal bands.
- To diagnose conditions such as cryptococcal meningitis, specific tests such as the cryptococcal antigen test are required.
- ↓ inflammatory response: 1/3 of patients with cryptococcal meningitis have meningism.
- Low threshold for brain imaging and lumbar puncture required.
- ↓ antibody response: in toxoplasmosis, there is no rise in IgM levels.
- CD4 count is a useful guide to the underlying pathological process:
 - toxoplasmosis, cryptococcal meningitis, progressive multifocal leucoencephalopathy occur at CD4 counts < 200.
 - CMV disease occurs at CD4 counts < 50.

This page intentionally left blank

Neurological disorders due to HIV

HIV-associated dementia (HAD)

- Usually occurs late in the disease.
- Symptoms include impaired attention, memory loss, apathy.
- Signs in the early stages include jerky eye movements, brisk reflexes, cerebellar abnormalities.
- Differential diagnoses include metabolic derangement, e.g. hypoxia, recreational drug use, depression.

Investigations to exclude other pathology

- MRI shows atrophy and diffuse white matter changes.
- CSF examination (non-specific cytochemical abnormalities).
- CSF HIV RNA load cannot be used to diagnose HAD.
- Neuropsychological assessment useful—subcortical dementia with abnormalities in the domains of information processing, psychomotor speed, and recall memory.

Vacuolar myelopathy (VM)

- Occurs in conjunction with HIV dementia.
- Signs of a spastic paraparesis without a sensory level.
- Resembles subacute combined degeneration due to vitamin B₁₂ deficiency.
- MRI usually normal.
- Check B₁₂ level and, if low normal, homocysteine levels.
- Consider checking indicated HTLV-1 serology as co-infection may occur.

Peripheral nerve syndromes

Distal sensory peripheral neuropathy (DSPN)

- 25% of AIDS patients.
- Occurs late in AIDS.
- Symptoms of paraesthesiae, burning pain, dysaesthesiae.
- Signs: little or no weakness, reduced or absent ankle reflexes. Impaired sensation to pain and temperature (mainly a small fibre neuropathy).
- Neuropathy due to antiretroviral drugs is very similar: ddC, ddI, and d4T.
- Other drugs that may also cause neuropathy include isoniazid, vincristine, thalidomide, metronidazole.

Investigations

- B₁₂, glucose levels, alcohol intake.
- Nerve conduction studies normal or may show an axonal neuropathy.
- Thermal thresholds abnormal.
- Nerve biopsy unnecessary unless abnormal features such as significant weakness are present to exclude vasculitis, demyelination, or lymphoma.

Other peripheral nerve syndromes

- Mononeuritis multiplex due to HIV vasculitis and CMV.
- Acute and chronic demyelinating polyneuropathy.
- Diffuse inflammatory lymphocytosis syndrome (DILS) resembles Sjögren's syndrome. Occurs during immunocompetent phases and associated with a high CD8 count.

Polyradiculopathy

- CMV.
- Lymphoma.
- Herpes viruses
- Syphilis.

Myopathy

- Polymyositis occurs in the early stages of HIV infection.
- Zidovudine causes a mitochondrial myopathy.

Opportunistic infections associated with HIV

Toxoplasmosis

- Usually a reactivation in individuals who have been previously exposed and have +ve toxoplasma serology.
- Acute or subacute presentation with focal neurological signs or movement disorders such as athetosis and symptoms and signs of ↑ ICP.
- Imaging: multiple focal enhancing lesions with surrounding oedema.
- Differential diagnoses: primary CNS lymphoma, tuberculoma, or tuberculous abscesses.
- Treatment: see Table 4.26.
- If significant mass effect add dexamethasone 4 mg qds and gradually taper (See Fig. 4.25).

Cryptococcal meningitis

- Acute or subacute presentation with headache, altered mental state, and meningism.
- Imaging: hydrocephalus, cryptococcomas, or dilated Virchow-Robin spaces filled with organisms.
- CSF:
 - opening pressure frequently ↑;
 - pleocytosis, ↑ protein, and ↓ sugar but may be normal;
 - India ink staining positive in 75%;
 - cryptococcal antigen positive in 95%;
 - Serum cryptococcal antigen measurement may be a useful screening method in those with mild non-specific symptoms.
- Poor prognostic markers:
 - altered mental state;
 - CSF OP > 20 csm CSF;
 - CSF WCC < 10;
 - hyponatraemia;
 - relapse episode.

Treatment See Table 4.26.

- In mild cases where none of the poor prognostic markers are present, fluconazole is an alternative drug to amphotericin.
- May require repeated LPs for raised ICP. Consider insertion of a lumbar peritoneal shunt if frequent LPs required.
- Acetazolamide may have an adjunctive role.
- Acute phase Rx 4–6 weeks or CSF culture negative.

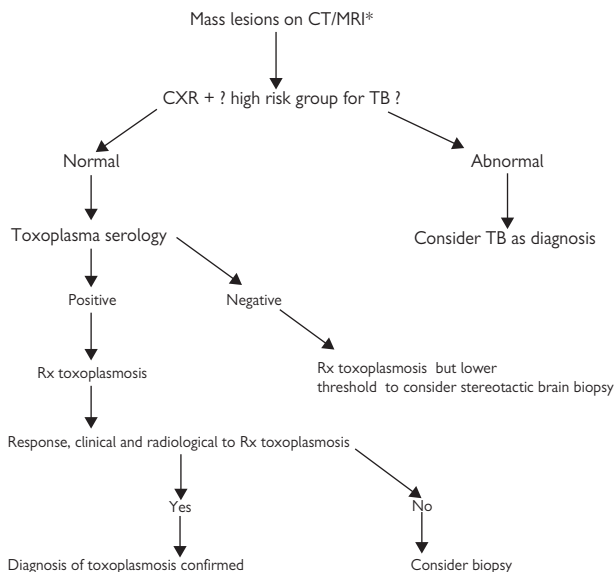


Fig. 4.25 Algorithm for the management of mass lesions (CD4 count less than $200/\text{mm}^3$) as detected on CT/MRI (MRI is preferred as more sensitive). If \uparrow ICP, treat with dexamethasone 4 mg qds. Once improved, gradually taper. Benefit may be due to \downarrow oedema or response if lymphoma. At least 2 weeks may be necessary to assess for a response to anti-toxoplasmosis therapy. In some cases, providing there is no urgency, one may need to wait 1 month.

Table 4.26 Treatment of opportunistic infections in HIV/AIDS

Disorder	Acute treatment	Maintenance	Comments
Toxoplasmosis	Pyrimethamine loading dose 100 mg/day PO, followed by 75 mg/day + folinic acid 15 mg/day + sulphadiazine 6–8 g/day IV/O	Pyrimethamine 25–50 mg/day + sulphadiazine 2–4 g/day + folinic acid 10 mg/day	If allergic to sulpha drugs use clindamycin 2.4–4.8 g/day. Maintenance 600 mg/day
Cryptococcal meningitis	Amphotericin B, 0.4–1.0 mg/kg/day IV \pm flucytosine, 150 mg/kg/day PO	Fluconazole, 200 mg/day/PO	In mild cases fluconazole, 400 mg IV PO may be used

Progressive multifocal leucoencephalopathy (PML)

- Caused by reactivation of JC virus, a polyoma virus.
- Subacute presentation with focal signs with no evidence of ↑ ICP.
- Imaging:
 - MRI shows non-enhancing focal white matter lesions with little or no mass effect on T2-weighted images.
 - T1-weighted images show discrete low signal changes.
- CSF: JC virus detected by PCR in 75%. Specificity 99%.
- Blood serology unhelpful since 80% of the general population seropositive due to a childhood upper respiratory tract infection.

Treatment

- HAART (highly active antiretroviral therapy) by improving immune function.
- Cidofovir has anti-JC viral activity. Mixed reports when combined with HAART. Toxic side-effects: nephrotoxicity, ocular hypotension.
- Alpha interferon shown to have some benefit in one pre-HAART, open-labelled study.

CMV infection

- May cause a meningoencephalitis.
- Lumbar polyradiculopathy.
- Retinitis.
- Diagnosis: neutrophil pleocytosis in the CSF; CMV isolation in the CSF by PCR.
- Treatment with ganciclovir or foscarnet.

This page intentionally left blank

MRI images in infectious diseases

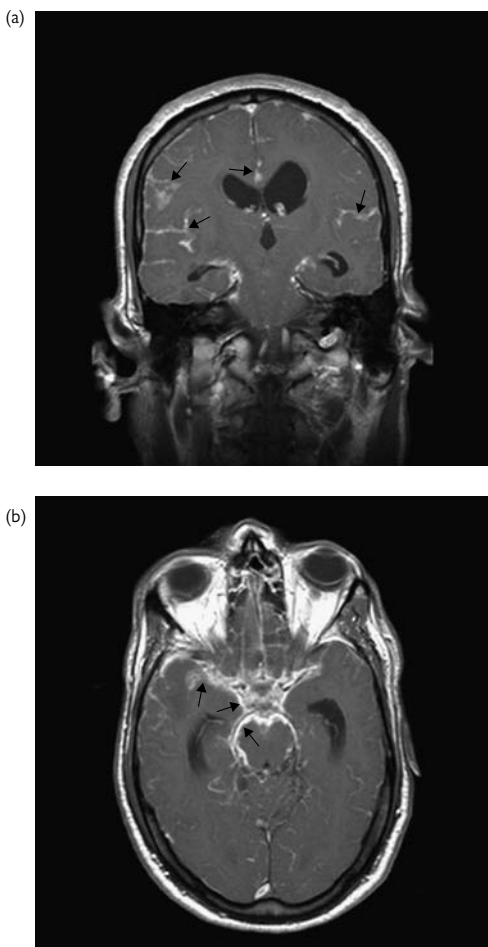

Fig. 4.26 Meningitis. (a) Post-contrast coronal MRI. Pneumococcal meningitis: thickening and enhancement of leptomeningeal surfaces over cerebral hemispheres and Sylvian fissure (*black arrows*). (b) Post-contrast axial MRI. Tuberculous meningitis: thickening and enhancement of basal meninges in suprachiasmatic and pre-pontine cisterns (*black arrows*). Note in both cases there is dilation of the ventricles due to communicating hydrocephalus.

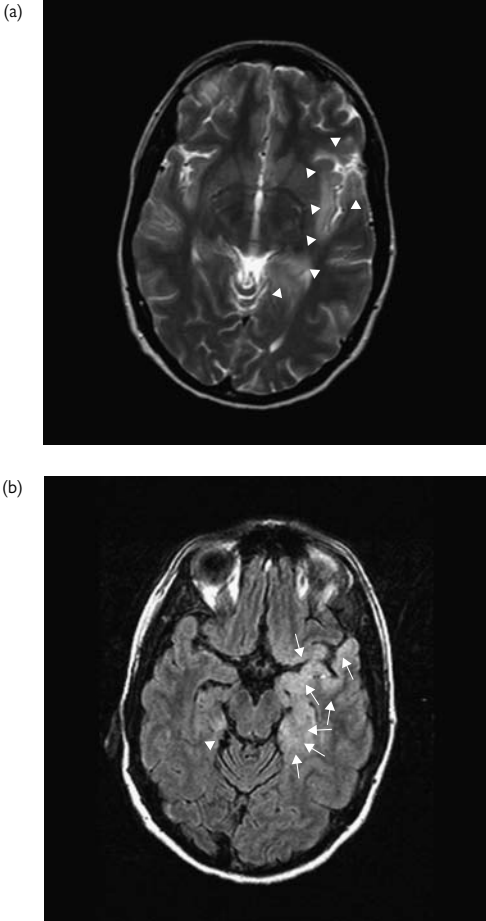


Fig. 4.27 HSV encephalitis. (a) Axial T2W and (b) axial FLAIR MRI. Ill-defined hyperintensity with gyral expansion involving the anterior and medial aspects of the left temporal lobe, including the amygdala and hippocampus, and inferior portion of the left frontal lobe and insular cortex ((a) white arrowheads and (b) white arrows). Asymmetric bilateral temporal lobe involvement is typical. Note the subtle involvement of the right medial temporal lobe ((b) white arrowheads). Gyriiform enhancement and haemorrhagic change are common.

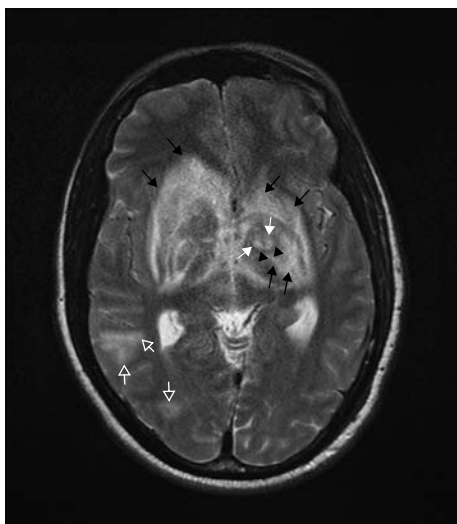


Fig. 4.28 Cerebral toxoplasmosis (axial FLAIR MRI). Bilateral mass lesions with heterogeneous signal intensity in the deep grey nuclei. Target appearance is shown in the left anterior thalamus with a ring of hypointensity (*black arrowheads*) surrounding an area of hyperintensity (*white arrows*) and central hypointensity. Note also further lesions peripherally at the grey–white matter junction in the right temporo-occipital region (*open white arrows*).

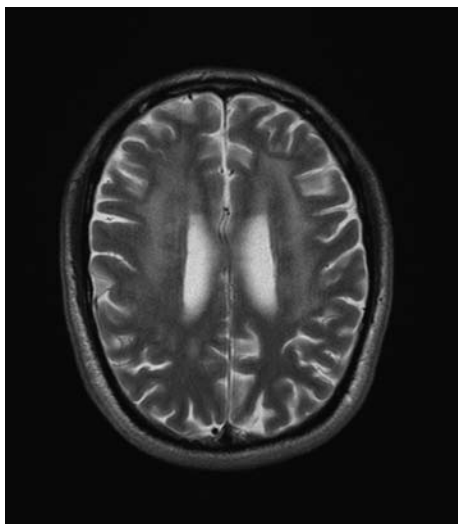


Fig. 4.29 HIV encephalopathy (T2W axial MRI). Bilateral hyperintensity involving the cerebral white matter in association with volume loss denoted by prominence of the cerebral sulci.

Lumbar puncture

Indications

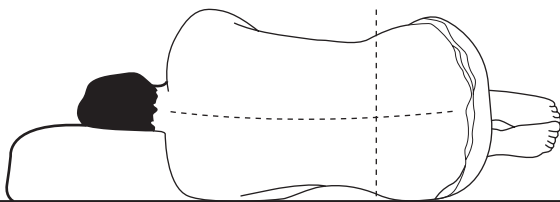
- Diagnosis of neurological disorders:
 - infectious meningitis and encephalitis (cytochemical parameters + microbiology + PCR);
 - demyelinating disorders, e.g. MS (oligoclonal bands);
 - inflammatory disorders of the CNS, e.g. sarcoidosis;
 - inflammatory disorders of the PNS, e.g. GBS and CIDP (cytoalbuminaemic dissociation);
 - malignant infiltration (cytology);
 - mitochondrial disorders (CSF lactate);
 - subarachnoid haemorrhage (SAH).
- Measurement of opening pressure, e.g. IIH.
- Treatment of ↑ ICP, e.g. IIH, meningitis due to *Cryptococcus neoformans*.
- Administration of antibiotics and chemotherapy.
- Injection of radio-opaque (myelography) or radioisotope materials, e.g. leak localization in intracranial hypotension.

Contraindications

- ↑ ICP due to mass lesion or obstructive hydrocephalus.
- Note: in infection a normal CT does not exclude ↑ICP.
- Local infection at LP site.
- Bleeding diathesis including anticoagulants.

Procedure

- Careful explanation and reassurance.
- Warn about complications of post-LP headache.
- Sedation with 5 mg diazepam may be useful.
- Firm mattress or table essential.
- Maximum one thin pillow.
- Patient lies horizontally in left or right lateral position.
- Neck flexed and knees drawn up in fetal position (See Fig. 4.34).
- Place a pillow between knees.
- Shoulder and pelvis vertical.
- Alternative is to sit patient upright, leaning over bed tray with one pillow.
- Identify L3–L4 interspace—line connecting anterior iliac crests (AIC). See Fig. 4.34.
- palpate and mark interspinous space with nail mark or indelible pen.
- Full sterile technique:
 - gloves;
 - clean area extending from each AIC, above and below L3 and L4 interspace with antiseptic solution starting in middle and cleaning in a circular fashion outwards.
- Infiltrate skin and subcutaneous tissue with small amount of 1–2% lignocaine. Excessive amounts make it difficult to palpate interspace.
- Wait 2–3 minutes.



The line connecting the highest points of the crests traverses the L₃-L₄ interspace

Fig. 4.30 Lateral positioning for LP. Reprinted with Permission from Sharief M, et al. (2004). *Medicine*, **32**(9), 44-7.

- Insert spinal needle with stylet in position between interspace while holding skin taut with index and middle finger of the other hand.
- Aim slightly towards umbilicus.
- Needle passes through interspinous ligaments and resistance as the ligamentum flavum is penetrated.
- Remove stylet to see if CSF drains.
- Measure OP by attaching manometer.
- Ask patient to relax knees a little to obtain accurate OP.
- Watch for respiration-related movement of CSF column.
- Drain manometer fluid into collection tube.
- Remove manometer avoiding moving needle.
- Collect 3 or 4 further tubes at least 3–5 ml each for:
 - protein;
 - microbiology;
 - oligoclonal bands;
 - cytology.
- One further sample for CSF glucose.
- Always take an extra sample if there is a possibility of further tests being necessary. Keep in the fridge or lab.
- Reinsert stylet, remove needle, apply pressure for 1–2 minutes.
- Apply sterile dressing.
- Allow patient to roll over and back.
- Take blood for glucose and oligobands if necessary.
- Label samples and write out forms yourself.
- Advise flat bed rest for 2–3 hours.

Complications

- Traumatic tap due to vertebral vein puncture. Allow CSF to drain until clear (in SAH, CSF samples uniformly stained) then collect samples.
- Post-LP headache common. Incidence ↓ with smaller gauge needle. Features:
 - postural headache, i.e. ↑ sitting or standing, ↓ lying flat;
 - associated with neck pain;
 - tinnitus;
 - nausea and vomiting.
- Treatment of post-LP headache
 - Reassurance;
 - bedrest and ↑ intake of fluids;
 - caffeine drinks, e.g. coffee, coke, or Red Bull®;
 - very rarely, if symptoms do not settle, consider IV caffeine infusion or autologous blood patch by an experienced anaesthetist.
- Dry tap (failure to obtain CSF). Causes:
 - subarachnoid space not penetrated—try interspace above or below;
 - low CSF pressure due to spinal blockage or intracranial hypotension;
 - adhesive arachnoiditis or malignant infiltration.
- Meningitis or epidural abscess: rare.

- Bleeding (all rare):
 - local extradural;
 - local intradural (subarachnoid);
 - intracranial subdural haematoma (cerebral atrophy risk factor).

Interpreting LP findings

- Characteristics of normal CSF:
 - appearance: Clear, colourless;
 - opening pressure: 8–16 mm, CSF > 20 definitely abnormal;
 - cells/ μ l: < 5 lymphocytes;
 - protein: 0.1–0.45 g/l;
 - glucose > 50% blood glucose.
- Causes of \uparrow OP:
 - mass lesion
 - brain swelling e.g. meningitis, encephalitis, trauma
 - idiopathic intracranial hypertension
 - cerebral venous thrombosis
 - hydrocephalus (communicating or non communicating)
- If traumatic tap, subtract one white cell per 500 RBC.
- Causes of xanthochromia:
 - $\uparrow\uparrow$ CSF protein;
 - SAH after 12 hours;
 - jaundice;
 - rifampicin.
- Oligoclonal bands present in CSF but not in serum indicative of intrathecal synthesis found in:
 - MS;
 - CNS infections;
 - ADEM.
- See 'Infectious diseases: bacterial meningitis' and 'Viral encephalitis', this chapter.
- Characteristics of CSF malignant meningitis:
 - Appearance: Clear or cloudy;
 - opening pressure: normal or \uparrow ;
 - cells/ μ l: <200; mixed inflammatory and malignant;
 - protein: upto 1 g/l;
 - glucose may be < 50% blood level.

Intravenous immunoglobulin (IV Ig)

- Prepared from pooled plasma from 8000+ donors. Therefore, batch inconsistencies.
- Blood product—theoretical risk of transmission of (unknown) viruses and prions.
- Contains IgG + traces of IgM, IgA + soluble factors such as cytokines.
- Mechanism of action. Several possible:
 - anti-idiotypic antibodies;
 - ↑ saturation and blockade of Fc receptors on macrophages;
 - modulation of pro-inflammatory cytokines.
- Expensive: approximately £3400 for 5-day course.

Indications

Guillain–Barré syndrome

- Licensed in UK.
- Trials indicate ≡ plasma exchange.
- Dose: 0.4 g/kg/day for 5 days.
- No trial data on initiating treatment after 2 weeks or mild GBS.
- Some patients improve initially then relapse—reasonable to consider another course.
- If no response, ? further course or PE.

Multifocal motor neuropathy with conduction block

- Treatment of choice.
- Patients may deteriorate with steroids or PE.
- May require regular infusions.

CIDP

- IV Ig ≡ steroids ≡ PE.
- May require regular infusions.

Myasthenia gravis

- Used in myasthenic crises.
- Preop prior to thymectomy.

Myositis

- Dermatomyositis—trials support use if steroids fail or inadequate response
- Inclusion body myositis—no good evidence for benefit.
- Polymyositis—anecdotal evidence for benefit only if steroids fail.

Multiple sclerosis

- ↓ relapse rate in RCTs similar to that with beta interferons.
- No data in secondary progressive or on disability.

Other disorders (anecdotal evidence only)

- Stiff person syndrome.
- Paraneoplastic syndromes.
- Rasmussen's encephalitis.
- Lower motor neuron syndromes.

Complications

Usually mild and transient but caution in patients with renal impairment, cardiac dysfunction, or ↑ viscosity due to ↑ gammaglobulins or ↑ cholesterol. IgA deficiency patients risk an anaphylactic reaction—preparations with low Ig A levels available.

- Systemic effects (common): fever, myalgia, headache.
- Cardiovascular: hypertension, cardiac failure, MI, venous thrombosis.
- Renal: acute renal failure.
- Neurological: migraine, aseptic meningitis, stroke, reversible encephalopathy.
- Hypersensitivity reactions: anaphylaxis, haemolytic anaemia, neutropenia, lymphopenia.
- Skin: urticaria, eczema.
- Changes in laboratory results: hyponatraemia (artefactual), ↑ ESR (rouleaux formation), ↓ Hb (dilutional), ↑ LFTs.

Procedure

- Check FBC, renal, liver function, immunoglobulin levels prior to infusion unless extreme urgency.
- Send antibody tests and serological tests.
- Discuss issues regarding blood product and possible complications.
- Obtain consent especially for unlicensed use.
- Start infusions at slow rate initially.
- Regular monitoring of pulse, BP, and temperature by nursing staff especially during first infusions.
- Usual dose: 0.4 g/kg/day for 5 days. Subsequent doses dependent on response and relapse rate. In CIDP and MMN usually every 4–12 weeks.
- Monitor renal function.

Diagnosis of brainstem death

Death is defined as 'the irreversible loss of the capacity for consciousness, combined with the irreversible loss of the capacity to breathe spontaneously'.

Requisites before assessment of brainstem function

- Known aetiology for the irreversible brain damage
- Effects of depressant drugs, hypothermia, and metabolic and endocrine causes of coma should have been excluded
- Patient is on a ventilator as spontaneous respiration inadequate or absent

Individual examinations should be carried out by two senior doctors after an interval of 24 hours. Staff making the diagnosis should not be involved in potential organ donation.

Criteria for a diagnosis of brainstem death

- 1 Pupils are fixed and do not respond to light.
- 2 Corneal reflex absent.
- 3 Vestibulo-ocular reflex absent (instill 50 ml of iced water into each ear: check TM intact).
- 4 Gag reflex absent and no response to bronchial stimulation by passage of a suction catheter down trachea.
- 5 Motor response: no response within cranial nerve territory to painful stimuli applied to limbs or supraorbital area.
- 6 Respiration: no respiratory movements when disconnected from ventilator. Give 6 litres O₂ and ensure pCO₂ rises > 6.5 kPa.

No further tests such as EEG are necessary if all conditions fulfilled.

Neurosurgery

- Subarachnoid haemorrhage (SAH) 316
- Imaging of SAH: examples 320
- Spontaneous intracranial haemorrhage (ICH) 328
- Imaging of ICH: examples 330
- Cerebral aneurysms 334
- Cerebral arteriovenous malformations (AVM) 338
- Cavernous haemangioma (cavernoma) and developmental venous anomaly (DVA) 340
- Dural arteriovenous fistulae (dAVF) 342
- Hydrocephalus 344
- Complications of shunts 348
- Intracranial tumours 350
- Intracranial tumours: management of specific tumours 354
- Imaging of intracranial tumours: examples 360
- Imaging of spinal tumours: examples 372
- Head injuries (HI) 376
- Management of specific head injuries 380
- Imaging of head injuries: examples 386
- Spinal injuries 392
- Imaging spinal injuries: examples 396
- Degenerative spinal conditions: cervical spine 402
- Degenerative spinal conditions: thoracic and lumbar spine 406
- Imaging of degenerative spinal conditions: examples 410
- Developmental abnormalities 414
- Imaging of developmental abnormalities: examples 418
- Syringomyelia 422

Subarachnoid haemorrhage (SAH)

Subarachnoid haemorrhage (SAH) occurs in 1/10,000 of the population per year in the UK.

Clinical presentation

Clinical severity varies widely.

- Headache—worst ever headache; 'hit on the back of the head'. May occur during strenuous activity such as sexual intercourse. Associated with vomiting.
 - Coma.
 - Sudden death.
- Examination may reveal:
- typical signs of meningism (neck stiffness, photophobia, positive Kernig's sign);
 - presence of subhyaloid haemorrhages on fundoscopy;
 - signs of ↑ ICP (bradycardia, hypertension);
 - (late) papilloedema.
- See Tables 5.1 and 5.2 for grading systems for SAH.

Causes

- Berry aneurysm.
- Traumatic and infectious aneurysms.
- Clotting disorder, e.g. warfarin.
- Dural AVM.

Diagnosis

- 1 CT scan positive in 95% in first 24 hours. If negative proceed to:
- 2 LP: measuring opening pressure and looking for evidence of blood and or xanthochromia.
- 3 Check clotting screen.
- 4 If CT scan positive or LP positive → CT angiogram or digital subtraction angiography (formal catheter angiogram).
See Chapter 7.

Management

Cerebral vasospasm

- Focal cerebral ischaemia as a result of cerebral artery vasospasm is the biggest cause of neurological morbidity.
- Vasospasm is maximal from 5–10 days post-SAH.

Standard prevention and treatment

- Calcium antagonist nimodipine 60 mg 4-hourly has been shown to decrease the rate of development of vasospasm-induced ischaemic deficits from over 25% to < 20%.
- Hydration with normal saline.

Table 5.1 World Federation of Neurological Surgeons (WFNS) grading system for SAH

Grade	Glasgow Coma Scale (GCS) score	Motor deficit
1	15	Absent
2	14–13	Absent
3	14–13	Present
4	12–7	Present or absent
5	6–3	Present or absent

Table 5.2 Fisher classification of SAH on the basis of the blood load on the brain CT scan

Grade	Blood on CT
1	No blood detected (SAH diagnosed on LP)
2	Diffuse/vertical layers < 1mm thick
3	Localised clot or layers > 1mm thick
4	Intra cerebral or intraventricular clot with diffuse or no SAH

- 'Triple H' therapy = hypertension (with inotropic drugs), haemodilution, and hypervolaemia and is used in established vasospasm.
- Use of colloid solutions such as albumin, dextran, or hexastarch (to improve flow and rheology viscosity).
- Chemical (papaverine) or balloon angioplasties to physically open up the cerebral arteries are also used but with mixed results. Appears most useful around the time of endovascular (coil) or neurosurgical (clip) interventions but the effects are probably not sustained.

Investigations

- Many units utilize transcranial Doppler to monitor cerebral arterial flow as a surrogate marker of vasospasm.
- Xenon-CT and diffusion/perfusion MRI are also used when available to study deficits in regional cerebral perfusion.

Securing the aneurysm to prevent rebleeding

Timing of the definitive treatment of cerebral aneurysms (coiling or clipping) will depend on:

- patient's general and neurological condition;
- extent of angiographically defined vasospasm;
- the ethos of the neurosurgical unit as to what degree the patients are treated 'early' or 'late'.
- However only in those with large ICHs secondary to middle cerebral artery aneurysms is emergency treatment advocated.

Hydrocephalus See Hydrocephalus, p.344.

Outcome and prognosis

- Angiogram-negative SAH. Following SAH, cerebral angiography is negative in 15–20% of cases, typically associated with prepontine (perimesencephalic) blood on CT. Has a typically benign course. Patient may have headaches for several weeks but with no further haemorrhages. Small risk for development of hydrocephalus.
- Patients with SAH due to an aneurysm:
 - 30% die, usually out of hospital;
 - 30% recover completely;
 - 30% recover with some disability.

This page intentionally left blank

Imaging of SAH: examples

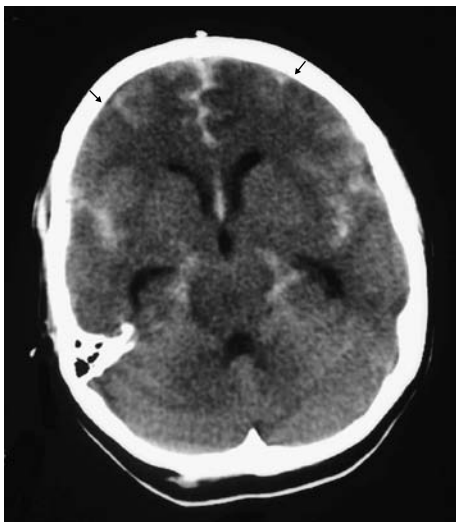

Fig. 5.1 Subarachnoid haemorrhage (SAH) (non-enhanced CT). Acute subarachnoid haemorrhage with acute hyperdense blood within the basal cisterns, Sylvian fissures, and anterior interhemispheric fissure. Small amount of sulcal blood is also shown (*small black arrow*). Note the mild degree of communicating hydrocephalus.

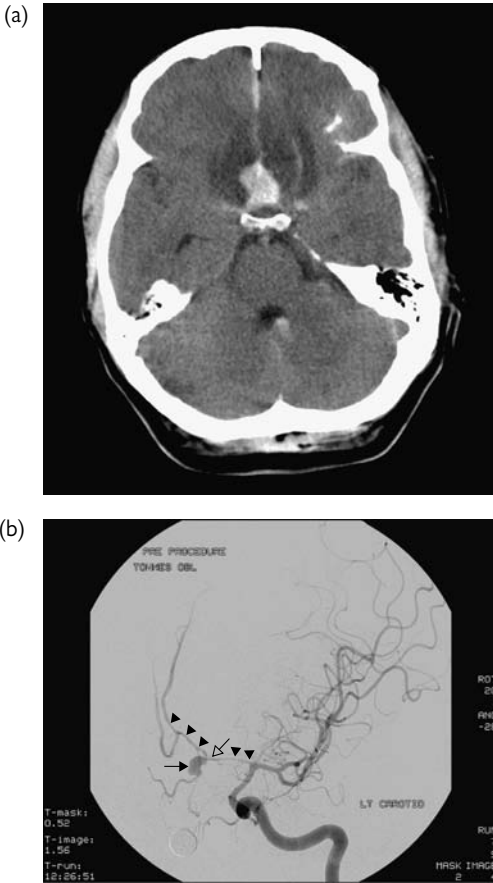


Fig. 5.2 Subarachnoid haemorrhage (SAH); anterior communicating artery aneurysm. (a) Non-enhanced CT; (b) digital subtraction angiography. Acute subarachnoid haemorrhage in the suprachiasmatic cistern and fourth ventricle with a focal haematoma in the inferior aspect of the anterior interhemispheric fissure at the site of the anterior communicating artery (ACoM). Note the surrounding bilateral inferior frontal parenchymal low attenuation representing early ischaemia. Catheter angiography confirmed the presence of an irregular small aneurysm (black arrow) arising from the junction of the A1 and A2 segments of the left anterior cerebral artery (open black arrow). There is marked vasospasm and slower flow in the proximal left anterior cerebral artery (black arrowheads) with reduced opacification of the distal vessels in the ACA territory.

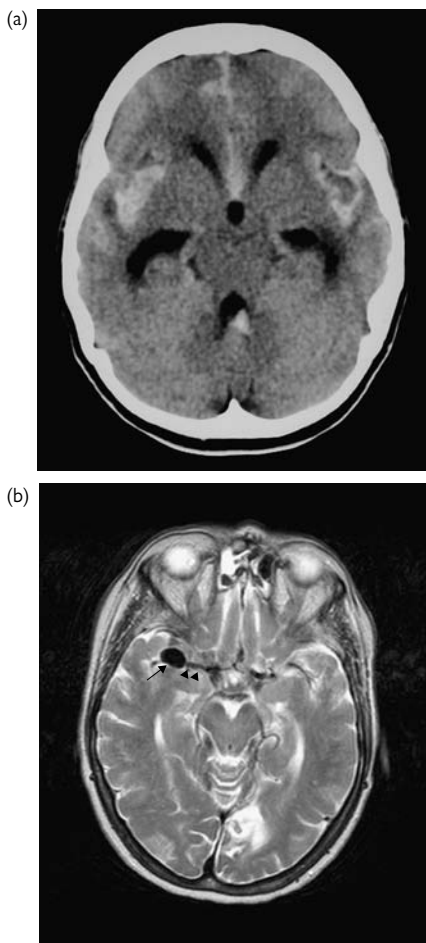


Fig. 5.3 Right middle cerebral artery (MCA) aneurysm and acute SAH. (a) Non-enhanced CT; (b) axial T2-weighted; (c) 3-dimensional TOF MRA of the circle of Willis; and (d) MRA maximum intensity projection (MIP) MRI. Extensive acute subarachnoid haemorrhage is shown within the anterior interhemispheric fissure, fourth ventricle, and Sylvian fissures, prominently on the right (*white arrow*). Communicating hydrocephalus. The distribution is suggestive of a right MCA aneurysm which is shown on subsequent MRI as a rounded signal flow void (*black arrow*).

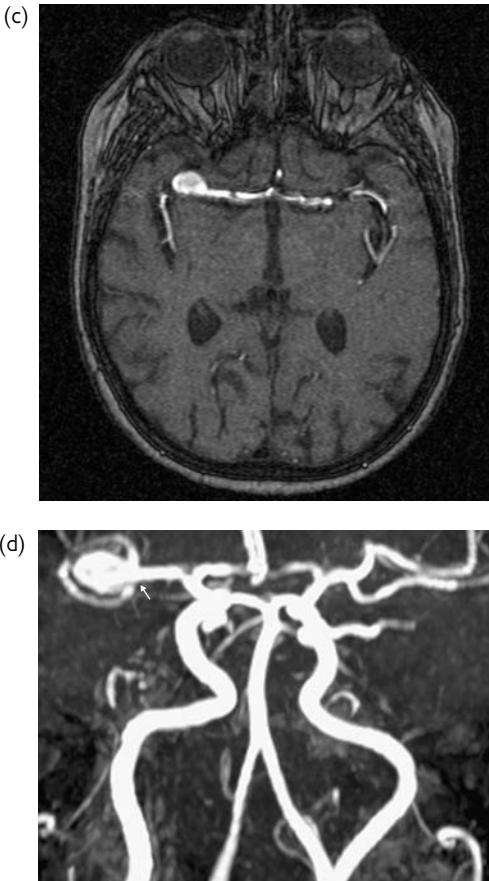
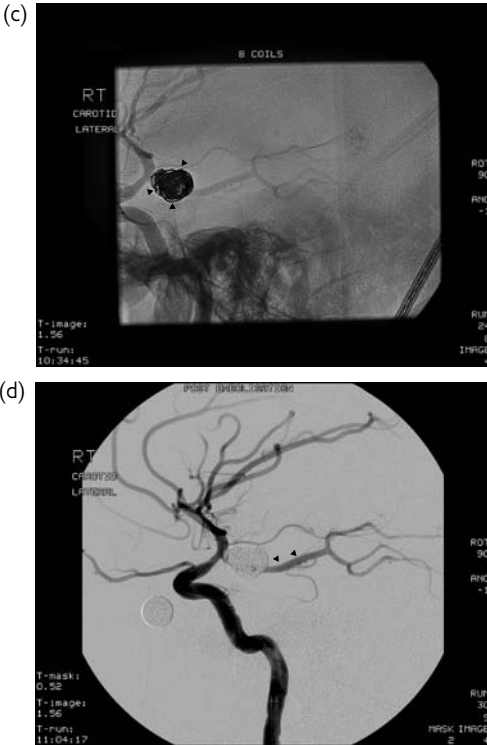


Fig. 5.3 Right middle cerebral artery (MCA) aneurysm and acute SAH. (c) MRA and (d) rotated MIP image demonstrate the aneurysm arising at the bifurcation of the right MCA. The linear flow void in (b *black arrowheads*) represents the M1 segment of the right MCA.

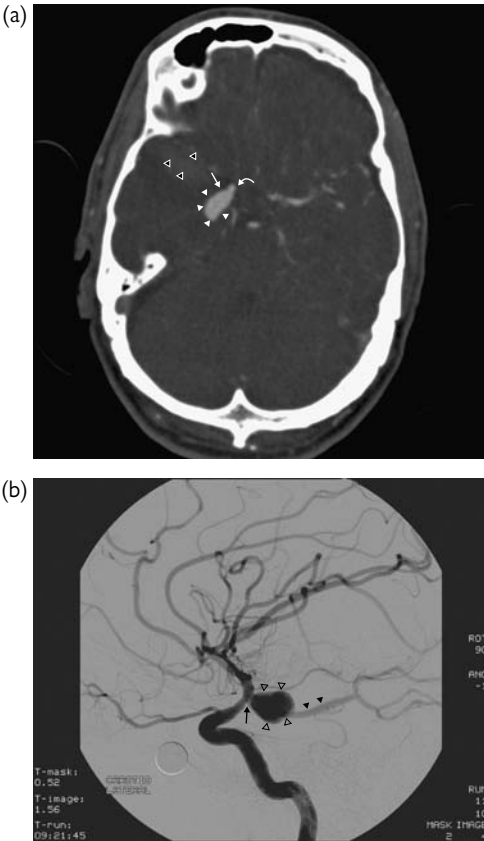

Fig. 5.4 Right posterior communicating artery aneurysm (PCoM) and SAH. (a) Axial multiplanar reformation (MPR) from CT angiogram; (b), (c), and (d) digital subtraction angiogram and coil embolization. Ill defined hyperdensity is shown within the right Sylvian fissure proximally (*open white arrowheads*) in keeping with acute subarachnoid haemorrhage. The fundus of the large PCom artery aneurysm (*white arrowheads*) is directed posterolaterally and the neck arises from the communicating segment of the right internal carotid artery (*white arrows*). This is confirmed on digital subtraction angiogram following selective catheterization of the right internal carotid artery. In (b) the aneurysm (*open black arrowheads*) arises via a relatively narrow neck (*black arrow*) from the communicating segment of the right ICA. Note contrast within the right posterior cerebral artery (*closed black arrowheads*) indicating the presence of a prominent persistent posterior communicating artery.



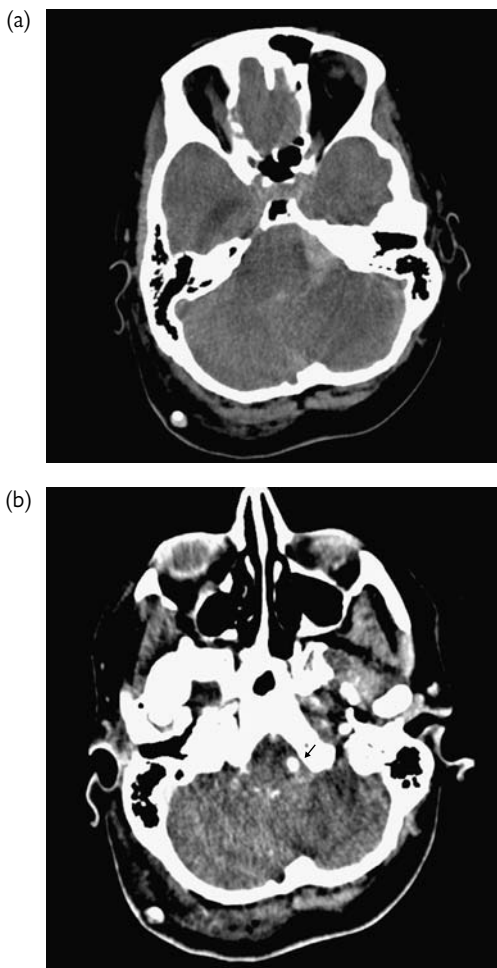


Fig. 5.5 SAH; Left posterior inferior cerebellar artery (PICA) aneurysm. (a) Non-enhanced CT; (b) axial image from CT angiogram. Hyperdense subarachnoid blood within the left cerebellar pontine angle extending into the fourth ventricle. CT angiogram demonstrates a small rounded aneurysm arising at the origin of the left PICA (*black arrow*).

This page intentionally left blank

Spontaneous intracranial haemorrhage (ICH)

- Spontaneous ICH common cause of morbidity.
- 20% of strokes caused by cerebral haemorrhage (75% ICH and 25% SAH).
- Risk factors for ICH are similar to those with ischaemic stroke:
 - age;
 - male gender;
 - hypertension;
 - smoking;
 - diabetes;
 - excess alcohol.

Aetiology

- Haemorrhage is due to rupture of small vessels and microaneurysms in perforating vessels.
- Underlying vascular conditions should be considered:
 - AVM;
 - aneurysm;
 - cavernoma;
 - amyloid angiopathy;
 - cerebral venous thrombosis.
- Haemostatic factors:
 - anticoagulant drugs;
 - anti-platelet drugs;
 - coagulation disorders;
 - thrombolytic therapy.
- Other aetiologies:
 - drug abuse (cocaine);
 - moya moya syndrome;
 - haemorrhage into a tumour (metastatic malignant melanoma, renal, thyroid, and lung carcinoma, choriocarcinoma, oligodendroglioma, and ependymoma).
- Clues to the aetiology may come from site:
 - basal ganglia in hypertensive bleeds;
 - Sylvian fissure in MCA aneurysms;
 - lobar bleeds in amyloid angiopathy.

Clinical features

- Sudden ictus as a stroke.
- ± signs and symptoms of ↑ICP—severe headache and vomiting.
- Seizures and meningism.

Imaging features

See Chapter 7 and 'Imaging of ICH: some examples', p.330.

- CT scan is sensitive diagnostically.
- MRI may help to differentiate hypertensive haemorrhage from other causes.

Management

- Standard medical support.
- Surgical evacuation of the haematoma depends on location, age, and premonitory performance status of the patient. Recent STICH trial suggests no benefit.
- Infratentorial haematomas are special cases—may warrant surgical intervention for evacuation or shunt insertion for hydrocephalus.

Imaging of ICH: examples

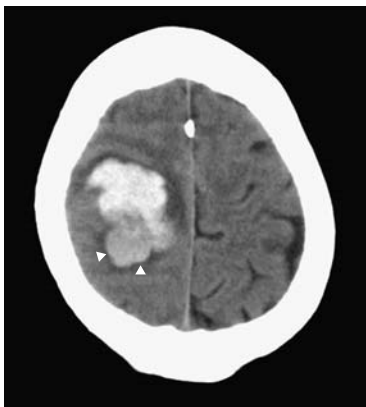


Fig. 5.6 Acute primary intracerebral haematoma (non-enhanced CT). Acute right fronto-parietal intraparenchymal haematoma with high density elements anteriorly and slightly lower attenuation components posteriorly (*white arrowheads*) indicating less acute blood. Note the small rim of surrounding low attenuation and associated mass effect with ipsilateral sulcal effacement.

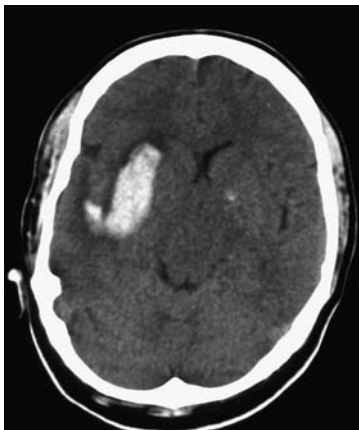


Fig. 5.7 Primary hypertensive haemorrhage (non-enhanced CT). Typical ganglionic haematoma with acute haemorrhage involving the right lentiform nucleus and minor extension into the insular cortex. There is slight effacement of the ipsilateral frontal horn and Sylvian fissure.

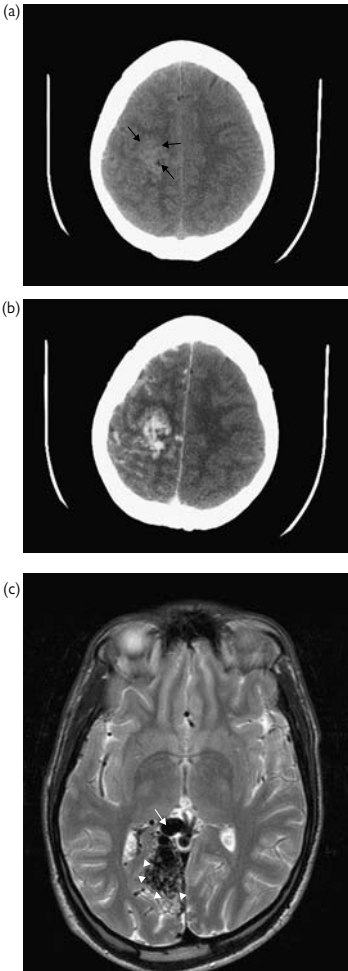


Fig. 5.8 Arteriovenous malformation. (a) Non-enhanced CT; (b) contrast-enhanced CT; and (c) T2-weighted MRI. (a) Large area of ill-defined hyperdensity with little associated mass effect (*black arrows*). (b) Following contrast, multiple serpiginous enhancing structures are demonstrated in the centre of the hyperdense area and surrounding parenchyma in keeping with the nidus of an AVM. (c) Right occipital AVM with multiple focal and serpiginous flow voids (*white arrowheads*). There is little associated mass effect. Note the large draining vein entering the vein of Galen (*white arrows*).

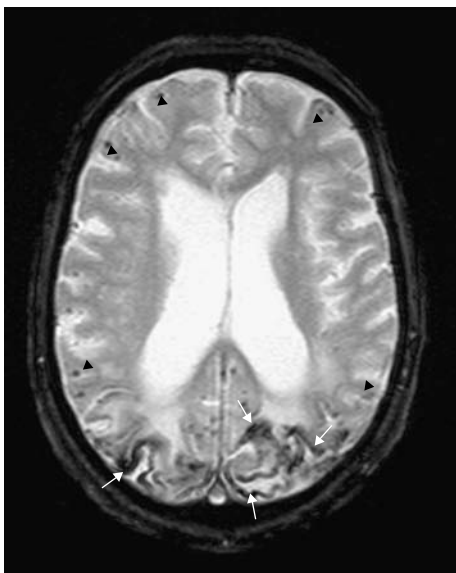


Fig. 5.9 Amyloid angiopathy (axial gradient echo T2* MRI). Elderly patient. Bilateral posteriorly distributed peripheral haemosiderin staining indicates previous lobar haemorrhage (*white arrows*), with multiple widely distributed foci of haemosiderin in both cerebral hemispheres (*black arrowheads*).

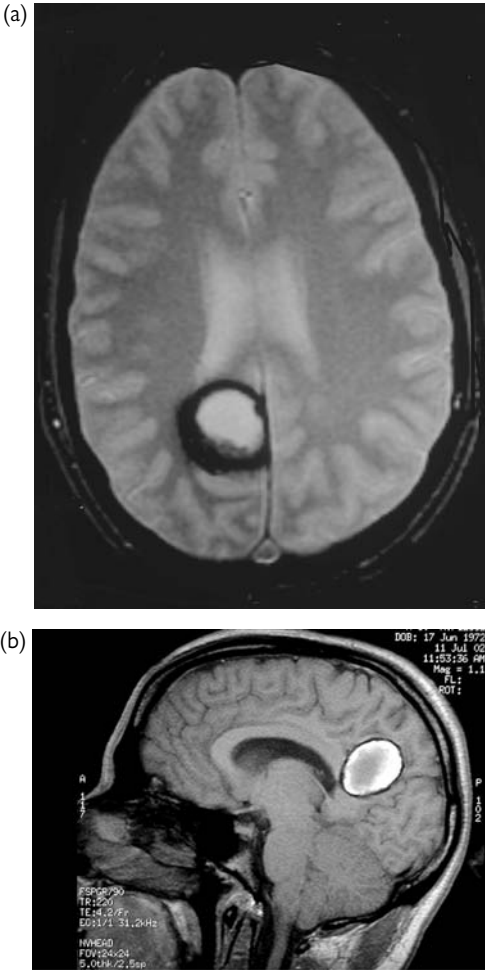


Fig. 5.10 Cavernous angioma. (a) Axial gradient echo T2* and (b) sagittal T1W MRI. Large right inferomedial parietal cavernoma with hypointense ring of haemosiderin surrounding more recent haemorrhage (predominantly extracellular methaemoglobin). Note the absence of surrounding white matter signal change suggesting no recent extralesional haemorrhage.

Cerebral aneurysms

Berry aneurysms

Cerebral (berry) aneurysms are highly prevalent 'blow outs' that occur commonly on the branching points of the cerebral arteries around the circle of Willis in the subarachnoid space.

Incidence and epidemiology

- Prevalence at least 1% in adults in the UK/USA. Increasingly common with age and in females (2 to 1).
- Aneurysms rarely but classically occur in inherited disorders such as polycystic kidney disease, Marfan's syndrome, pseudoxanthoma elasticum. In countries of high prevalence e.g. Japan and especially Finland, familial aneurysms are much commoner.

Neuroanatomy

Typical aneurysm sites are:

- posterior communicating;
- anterior communicating;
- middle cerebral branch points which account for 80% of all aneurysms.
- Cerebral aneurysms are sized as small (< 1 cm maximum diameter), large (1–2.5 cm), and giant (> 2.5 cm). 70% of cerebral aneurysms are small. 20% of cases are multiple.

Natural history Incidental aneurysms have a haemorrhage rate of less than 1% per annum if less than 1 cm in diameter. Larger aneurysms and those associated with multiple aneurysms have a higher bleed rate. Risk of bleeding higher in cigarette-smokers and hypertensives.

Presentation

Cerebral aneurysms present in a variety of ways.

- SAH.
- Incidentally on screening or for unrelated symptoms (e.g. headache).
- 3rd nerve palsy (usually painful, following rapid expansion of a posterior communicating artery aneurysm).
- Visual failure (with large ophthalmic segment aneurysms).

Treatment

Neurosurgical clipping and neuroradiological coiling are current treatment modalities.

- **Surgical clipping** involves a craniotomy, the microdissection of the blood vessels of the brain, and the passing of a titanium clip across the aneurysm neck. If successful this is a permanent cure with no need for subsequent follow-up.
- **Coiling** has the advantage of obviating the need for a craniotomy. A radiologist passes a catheter endovascularly similarly to an angiogram and then delivers a number of platinum coils into the aneurysm itself. This technique in experienced hands probably has less procedural morbidity than neurosurgical clipping. However, there is a higher incidence of regrowth of the aneurysm and late re-SAH. Therefore long-term clinical radiological follow-up is advised.

Note. Both techniques need to avoid occluding a cerebral artery or bursting the aneurysm itself. Procedural risk is thus higher in the early period following SAH. Late treatment reduces this risk but increases the risk of re-haemorrhage before treatment, which is highest in the first few days following the initial SAH.

Infectious cerebral aneurysms

Unusual lesions occur most often in the setting of infective endocarditis with septic embolism. Generally occur in the anterior cerebral circulation and are often multiple.

- Pathology: due to acute pyogenic necrosis of arterial wall secondary to vasculitis. Clinically recognized ipsilateral septic thromboembolism precedes haemorrhage in 40% of cases.
- Bacteriology: most frequent causative organisms found in blood culture are *Staphylococcus* and *Streptococcus* species.
- Predisposing medical conditions: congenital or acquired cardiac valvular disease, IVU, and immunocompromised patients.

Investigations

- High degree of suspicion is required in those high risk patients who develop neurological symptoms—CT or MRI imaging.
- Definitive investigation is four-vessel angiography, where these lesions will be found most commonly in peripheral branches of the middle cerebral artery; angiography must cover this vascular territory.
- Not uncommon for sequential angiograms to be required to follow the response to antimicrobial treatment if a non-surgical treatment regimen is instituted.

Management

- Some recommend antimicrobial therapy alone to treat infectious aneurysms, as in up to 50% of cases such lesions resolve or decrease in size following such treatment.
- Timing of any cardiac surgery is crucial to eliminate the infective focus as a further cause for bacteraemia and emboli.
- Surgery of infectious intracranial aneurysms is technically difficult, but is necessary in selective cases if ↑ size or frank abscess. Excision of the lesion with the involved vessel is required. Neurological deficits may result.

Fungal aneurysms

- Tend to occur more proximally on the intracranial vessels and more frequently involve the large arteries at the base of the brain.
- Occur almost exclusively in immunocompromised patients.
- *Candida albicans* and *aspergillus fumigatus* commonest.
- Tend to be more indolent in nature but their management strategies tend to be similar, i.e. persist with antifungal chemotherapy rather than high risk surgical/radiological interventions unless absolutely necessary.

Traumatic intracranial aneurysms

Unusual condition accounts for < 1% of all intracranial aneurysms. Also known as false or pseudo-aneurysms, which define a tear in the arterial wall, associated with extravessel thrombus, which constitutes the aneurysm wall.

Aetiologies

- Penetrating injuries such as stab wounds, gun shot wounds.
- Following closed head injury: typically and classically at the distal anterior cerebral artery territory, where an artery is torn against the under edge of the falx cerebri. It may also occur at the skull base where it can cause carotico-cavernous fistulae or occlusion.

Clinical presentation is usually as a delayed cerebral haemorrhage following an otherwise unremarkable recovery from brain injury. A high index of suspicion is required.

Treatment is with neurosurgical excision. Vessel reconstruction is almost never possible and vessel sacrifice or bypass is necessary.

This page intentionally left blank

Cerebral arteriovenous Malformations (AVM)

Incidence

- 10 x less common than cerebral aneurysms.
- Rarely multiple except in hereditary haemorrhagic telangiectasia.
- Congenital in origin.

Pathology Consist of tangles of pial blood vessels with characteristic early shunting of blood from arteries to veins.

Clinical presentation

- Frequently asymptomatic through life.
- May present with ICH, seizures.
- Unusual manifestations due to development of a vascular steal or venous hypertension phenomenon.

Natural history studies

Inadequate but risk of haemorrhage is between 2 and 4 % per annum. Features associated with ↑ risk are:

- intranidal aneurysms;
- venous stenosis;
- ectasia;
- old age.

AVM size is **not** related to haemorrhagic risk.

Diagnosis

- **CT.** Non-enhanced scan may be normal or show an area of hyperdensity with no mass effect. 25% show calcification. With contrast avid enhancement and a large draining vein may be visualized.
- **MRI.** Mesh of flow voids, large draining veins. Slow flow lesions may enhance.
- **DSA.** Defines nidus size and architecture accurately. Identifies feeding arteries, the presence of deep or superficial cortical draining veins, flow rate (important for endovascular planning), intranidal aneurysms (in >50%), venous stenosis.

Management

- Decisions critically dependent on angiographic findings of size, shape, position, presence of intra- or extranidal aneurysms, patient age, symptoms.
- AVMs are relatively benign in the medium term and bleeding risk is probably not altered by partial treatment.
- Symptomatic treatment, e.g. anticonvulsants, and regular follow up is an initial option.
- Aim of intervention is complete obliteration.
3 treatment options may be used alone or in combination:

Neurosurgery

- Offers the chance of a cure at one operation but is difficult with a significant morbidity.
- Larger lesions cause normal pressure perfusion breakthrough.
- Surgical risk can be graded with the Spetzler–Martin grading system between 1 and 5:
 - 1, 2, or 3 points depending on size (< 3 cm, 3–6 cm, > 6 cm);
 - 1 point if deep venous drainage;
 - 1 point if eloquent cortex.
- Pre-operative embolization reduces vascularity.
- Significant incidence of residual AVM following surgery.
- Small peripheral AVMs with recent haemorrhage ideal surgical targets.

Neuroradiological embolization

- Aim is to occlude nidus vessels with NBCA glue.
- Only 10–25% can be obliterated completely.
- Useful adjunct to surgery or radiosurgery.
- Complications due to catheter sticking to fragile vessels, extravasation of glue, infarction, or haemorrhage.

Radiosurgery

- High dose radiotherapy focused on the lesion using a stereotactic frame and delivered in one treatment session.
- Gamma knife or Linac-based systems are used to deliver the radiation.
- Advantages: low morbidity, day case procedure.
- However, obliteration occurs gradually over 2 years by progressive endarteritis obliterans. During this period the risk of haemorrhage is not reduced.
- Most suited for lesions < 3 cm.

Cavernous haemangioma (cavernoma) and developmental venous anomaly (DVA)

Cavernomas

- Vascular lesions consisting of large vascular channels with slow blood flow within.
- Capillary lesions macroscopically resemble blackberries.
- May be located within the brain or spinal cord or cauda equina.
- Familial cases reported.
- May result from trauma or radiation.
- 75% solitary; 25% multiple.
- May enlarge.

Clinical presentation

- Haemorrhage < 1% per annum.
- Epilepsy due to epileptogenic haemosiderin leaching out.
- Progressive neurological deficit especially in the posterior fossa and in the spinal cord.

Imaging features (Fig. 5.11)

- CT: normal in 50%. Well defined hyperdense lesion with no oedema ± enhancement unless acute haemorrhage. Occasional calcification.
- MRI: rounded or oval lesion with rim of hypointensity (T1W and T2W) results from haemosiderin due to chronic bleeding. Internal heterogeneous signal on T1W and T2W represents blood products of various ages. T2* hypointense (black) lesion.
- DSA usually negative.

Management

- Accessible lesions can be excised.
- Radiosurgery as a treatment option is still controversial.

Developmental venous anomaly (DVA)

- Represent anomalous venous drainage pathways.
- Enlarged white matter, often periventricular; veins radiate around a central vein.
- May be associated with cavernomas and cortical dysplasia.
- Usually asymptomatic lesions found incidentally on CT/MRI.

Clinical presentation Rarely haemorrhage except when associated with other vascular lesions.

Imaging features

- CT and MRI: small linear or stellate enhancing lesions with no mass effect.
- DSA venous phase reveals a 'Medusa head'.

Management

- Previously excised with poor outcomes.
- Now considered benign normal variant and left alone.

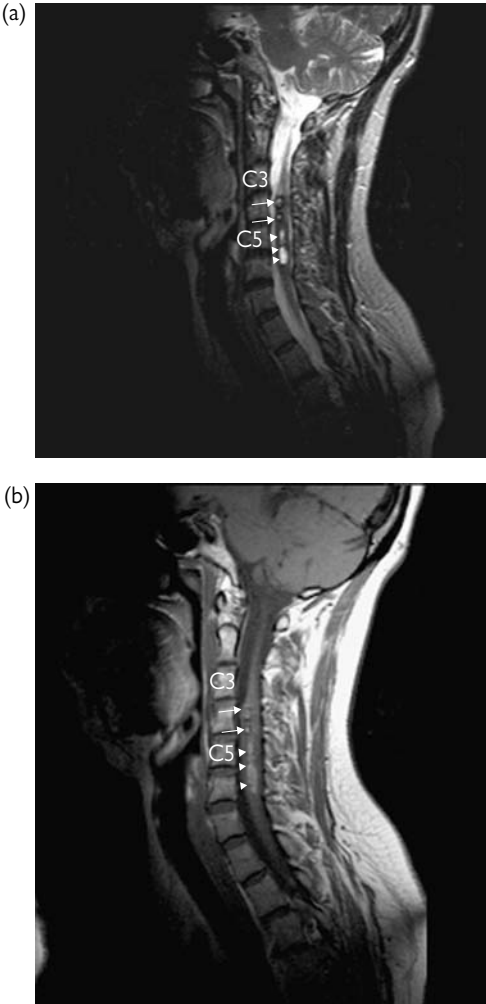


Fig. 5.11 Intramedullary cavernoma. (a) Sagittal T2W and (b) sagittal T1W MRI. Two small focal intramedullary lesions at the level of C4 comprising peripheral haemosiderin rings with haemorrhagic cores (*white arrows*). The spinal cord is mildly expanded and a loculated cavity lies caudally containing haemorrhagic degradation products in keeping with haematomyelia (*white arrowheads*).

Dural arteriovenous fistulae (dAVF)

Cranial dAVF

These occur throughout the neuroaxis. Common sites include anterior fossa floor, adjacent to the major venous sinuses, and the tentorial hiatus.

Clinical features

Presentation is with:

- haemorrhagic stroke;
- progressive neurological deficit due to venous congestion;
- headaches;
- pulsatile tinnitus especially if a bruit is audible;
- seizures.

Imaging

- CT/MRI are usually normal unless there is venous occlusion.
- DSA after haematoma resolution, if acute presentation, defines the location, feeding arteries, and venous drainage.

Grading system according to Djinnian and Merland

- Group 1. Blood drains directly into meningeal vein or sinus. Normal direction of flow.
- Group 2. Venous reflux into cortical veins.
- Groups 3 and 4. Venous reflux is associated with retrograde flow along the venous sinuses.

Group 1 lesions are benign and rarely require treatment to prevent haemorrhage. Other groups are at risk of haemorrhage and warrant intervention.

Treatment

- Require multidisciplinary assessment with neurosurgeon and neuroradiologist.
- Options include occlusion of abnormal fistulous communication between artery and vein by surgery or endovascular techniques using glue occlusion.

Carotid cavernous fistula (CCF)

Subtype of dAVF. Defined as low flow or high flow, traumatic or spontaneous, direct or indirect, aneurysmal or non-aneurysmal.

Clinical features

- Sudden onset painful, pulsatile exophthalmos and ophthalmoplegia.
- Cavernous sinus acts as a barrier and intracranial haemorrhage does not occur.
- High flow fistulae occur in young males following trauma or a ruptured aneurysm. Result in a direct communication between internal carotid artery and the cavernous sinus.
- Low flow or indirect fistulae occur in older patients with vascular risk factors. Result from dural fistulae within the walls of the cavernous sinus from branches of the internal or external carotid arteries.

Management

- High flow fistulae rarely close spontaneously. Closure is with endovascularly released detachable balloons or coils.
- Low flow fistulae tend to obliterate spontaneously. Conservative management by intermittent massage to occlude the internal carotid artery in the neck. Occasionally, partial embolization of external carotid branches but not internal carotid due to risk of stroke.

Spinal dAVF

- Most common spinal vascular malformation (80%).
- May be acquired secondary to thrombosis of the extradural venous plexus.
- Venous hypertension and engorgement result in a subacute necrotizing myelopathy.

Clinical features

- Presents in middle to late age group with a progressive myelopathy (Foix–Alajouanine syndrome).
- Commonly between T5 and L3.
- Spinal bruit may be heard.
- Diagnosis should be considered in any patient with a cauda equina lesion with a mixture of upper and lower neuron signs + sphincter involvement.

Imaging features

- MRI may be normal or show non specific abnormalities with intramedullary hyperintensity on T2W and hypointensity on T1W.
- Typically involves the conus and lumbar enlargement.
- Specific features are the dilated pial veins along the dorsal surface of the cord best seen on T2W images as serpiginous foci of flow void against hyperintense CSF. However, may be difficult to differentiate from CSF pulsatile flow.
- Gadolinium may reveal serpiginous areas of enhancement.
- MRA with contrast may demonstrate enlarged intradural veins.
- Spinal angiography is gold standard for diagnosis, localization, and treatment.

Management

- Endovascular obliteration using liquid embolic agents such as N-butylcyanoacrylate (NBCA) in > 50% of cases.
- Can be performed at the time of spinal angiography.
- Open surgical intervention to divide the fistulous point under a surgical microscope.

Hydrocephalus

- Defined as an excessive accumulation of CSF caused by a disturbance of formation, flow, or absorption.
- Normal CSF production is 500 ml/24 hours.
- Total CSF volume in an adult is 120–150 ml.
- CSF is recycled 3× daily.

Types of hydrocephalus

- Communicating hydrocephalus. Enlarged ventricles with preserved CSF flow between ventricles and the subarachnoid space. Impaired CSF reabsorption results in increased CSF pressure and ventricular enlargement.
- Non-communicating hydrocephalus or obstructive hydrocephalus occurs when CSF outflow tracts are obstructed, e.g. exit foraminae of the 4th ventricle (Magendie and Luschka).
- Hydrocephalus *ex vacuo* refers to compensatory ventricular enlargement secondary to brain atrophy.
- Arrested hydrocephalus occurs usually in communicating hydrocephalus due to incomplete obstruction when CSF production is balanced by absorption. The CSF pressure may be normal. However, patients may undergo decompensation spontaneously or after a minor head injury.
- Normal pressure hydrocephalus is a condition with low grade hydrocephalus with intermittently raised ICP.

Acute hydrocephalus

Aetiology

- Posterior fossa tumours.
- Cerebellar haemorrhage or infarction.
- Colloid cyst of the 3rd ventricle.
- Ependymoma of the 4th ventricle.
- SAH.
- Trauma.
- Acute meningitis.

Clinical features

- Signs and symptoms of ↑ ICP.
- Headache.
- Vomiting.
- Diplopia due to 6th nerve palsies.
- Reduced upgaze.
- Impaired conscious level.
- Occasionally, especially with colloid cyst of the 3rd ventricle, LOC and sudden death.

Chronic hydrocephalus

Aetiology

- SAH.
- Chronic meningitis.
- Slow-growing posterior fossa tumours.
- 1/3 cases no obvious cause.

Clinical features

- Gait disturbance (apraxia).
- Memory disturbance or dementia.
- Urinary incontinence.
- Symptoms and signs of ↑ ICP.

Imaging features in hydrocephalus

CT/MRI features include:

- ventricular enlargement with ballooning of frontal horns;
- enlargement of temporal horns;
- ballooning of the 3rd ventricle;
- disproportionate enlargement of ventricles compared to sulci (neuroradiological expertise necessary);
- periventricular interstitial oedema;
- thinned or upward bowing of corpus callosum on sagittal MRI.
- a large 4th ventricle implies communicating hydrocephalus or obstruction at the level of the 4th ventricular outflow; a small 4th ventricle suggests aqueduct stenosis.

Congenital causes (may present with acute or chronic hydrocephalus):

- aqueduct obstruction;
- Arnold–Chiari malformation;
- Dandy–Walker syndrome;
- benign intracranial cysts.

Management

- Insertion of ventricular peritoneal (VP) shunt inserted via a frontal or parietal burr hole. Attached to a combined valve and reservoir connecting to a distal catheter tunnelled under the skin and implanted into the peritoneum.
- Alternative sites: ventriculopleural shunt; ventriculo-(right) atrial (VA) shunt. Both have a higher complication rate than VP shunt, e.g. pulmonary emboli in VA shunts.
- Programmable shunt valve with variable settings that may be changed by application of magnetic device to skin. Tend to be unreliable, blockage is common, and are expensive.
- Endoscopic 3rd ventriculostomy. Creation of a hole in the floor of the 3rd ventricle allowing CSF to escape from the ventricular system to the basal cisterns. Endoscope introduced into the anterior horn of the lateral ventricle via a frontal burr hole, passed through the foramen of Munro into the 3rd ventricle and a hole punched anterior to tuber cinereum.
- In communicating hydrocephalus, e.g. due to acute meningitis, serial LP or an external lumbar drain may suffice in the acute period. A CSF protein level > 4 g/l will clog most shunts.

Normal pressure hydrocephalus (NPH)

- NPH describes a syndrome of chronic communicating hydrocephalus with normal CSF pressure at lumbar puncture.
- Long-term pressure monitoring reveals intermittently elevated pressures, often at night.
- NPH may follow trauma, infection, or SAH.
- Majority are idiopathic.

Clinical features

Presentation with some or all features of the classical Adam's triad.

- Gait disturbance. Typically the gait is an apraxia, i.e. normal power and sensation, but with an inability to lift the legs to walk. However, performance of the bicycling manoeuvre on the bed is remarkably intact.
- Cognitive impairment. Gradual slowing of verbal and motor responses and patients may seem apathetic or depressed.
- Urinary incontinence

Additional symptoms may include drop attacks and brief episodes of LOC.

Imaging features

- CT. Enlarged ventricles including temporal horns but with normal sulci.
- MRI:
 - no hippocampal volume loss to account for large temporal horns;
 - corpus callosum bowing and accentuation of aqueduct flow void are predictors of a good response to shunting in some studies;
 - presence of periventricular deep white matter lesions indicative of small vessel disease associated with a poor response.
- Isotope cisternography. A tracer injected into the CSF normally fails to enter the ventricles. In patients with NPH reflux of tracer into the ventricles within 24 hours with retention for 24–48 hours. Usefulness of this technique controversial.

Management

- There is no gold standard for diagnosis.
- Decision for shunting is based on clinical impression with supportive evidence from radiology and some of the following:
 - timed walking test before and after removing 30 ml of CSF at LP;
 - cranial bolt monitoring over 24 hours showing 15B-waves;
 - measuring the rate of absorption of CSF by infusion of saline into the thecal sac which represents compliance of the CSF compartments. Normal value 5–10 mmHg/ml/min. > 18 mmHg/ml/min implies active hydrocephalus.

This page intentionally left blank

Complications of shunts

Shunt infection

Usually caused by coagulase-negative *Staphylococcus aureus*. 90% present within 3 months of insertion.

Clinical features

- General malaise.
- Pyrexia.
- Headache, vomiting, meningism.
- Abdominal tenderness or distension.
- Pain and erythema around the shunt.

Laboratory features

- CRP ↑.
- WCC ↑.

Management

- Shunt removal.
- Placement of an external ventricular drain.
- Intrathecal vancomycin for 5–7 days via external ventricular drain (EVD): 5 mg if slit ventricles, 10 mg for normal ventricles, and 15 mg if dilated ventricles daily when CSF draining freely or every 3 days when drain clamped.

Other complications

- Misplacement.
- Haemorrhage.
- Subdural haematomas can occur in the first 6 months especially in the elderly. 10–15% may require surgery.
- Epilepsy. See DVLA regulations. May not drive for 6 months.
- Shunt malfunction:
 - blockage at ventricular, distal, or valve level. Palpation of the shunt reservoir is unreliable;
 - underdrainage: symptoms of hydrocephalus persist. Requires placement of a valve with lower pressure variety;
 - Overdrainage: symptoms of low pressure, i.e. postural headache, dizziness, tinnitus. Imaging reveals slit-like ventricles, subdural fluid collections, dural thickening, and enhancement. Replace with a higher pressure valve.

Follow-up of patients with shunts

- Baseline CT 6 months after insertion.
- Patient and carers given instructions about symptoms of infection and blockage.
- Documentation about type of valve should be given to the patient.
- Programmable valves should be checked after MRI.

This page intentionally left blank

Intracranial tumours

Epidemiology Intracranial tumours are 6th most common neoplasm in adults and the most common solid tumour in children. Incidence of all primary brain tumours is 14–21/100,000/year.

Classification

Tumours of neuroepithelial origin (gliomas)

- Astrocytic tumours:
 - pilocytic astrocytoma, grade I;
 - diffuse astrocytoma, grade II;
 - anaplastic astrocytoma, grade III;
 - glioblastoma, grade IV.
- Oligodendroglioma.
- Ependymoma.
- Choroid plexus papilloma or carcinoma.
- Neuronal and mixed neuronal–glial tumours.
- Pineal parenchymal tumours.
- Embryonal tumours.

Other intracranial tumours

- Tumours of meninges: meningioma.
- Vascular tumours (haemangioblastoma).
- Primary CNS lymphoma (PCNSL).
- Germ cell tumours (germinoma, teratoma).
- Tumours of sellar region (pituitary).
- Tumours of peripheral nerves (neurilemmoma, Schwannoma, neurofibroma).
- Developmental tumours (DNET, craniopharyngioma, colloid cyst, epidermoid and dermoid cysts).
- Metastatic tumours (breast and bronchus most common).

Aetiology

- Majority sporadic.
- Cranial irradiation ↑ risk of meningioma and astrocytoma.
- Immunosuppression (e.g. AIDS) ↑ risk of PCNSL.
- Neurofibromatosis 1 ↑ risk of optic nerve glioma and meningioma.
- Von Hippel–Lindau syndrome associated with haemangioblastomas.
- Tuberous sclerosis associated with giant cell astrocytomas.

Clinical features

- No pathognomonic features of presentation.
- Low grade lesions present with seizures; high grade lesions with raised ICP and a progressive neurological deficit.
- Headache most common presentation but < 1% of patients with headache only have a brain tumour.
 - Frontal headache (supratentorial) or occipital (posterior fossa).
 - Waking in the night or early morning headache.
 - Associated with vomiting.
 - Visual obscurations and papilloedema (late).

- Progressive neurological deficit:
 - hemispheric tumours present with progressive weakness, dysphasia, dyspraxia, visual field deficits;
 - posterior fossa lesions present with ataxia, cranial nerve palsies, and ↑ ICP due to obstructive hydrocephalus;
 - cerebello-pontine angle (CPA) lesions (e.g. vestibular Schwannomas) cause progressive deafness, facial weakness, and ataxia.
- Cognitive and behavioural changes. Usually frontal or subfrontal lesions.
- Seizures are the presenting symptom in 25% of tumours. Usually temporal or frontal lesions. Focal seizures that generalize to tonic/clonic seizures.

Imaging features

- CT ± contrast will identify most gliomas, metastases, meningiomas, and haemangioblastomas. Useful for showing calcification found in oligodendrogliomas.
- MRI ± Gd is more sensitive.
- Contrast enhancement implies BBB breakdown for example in high grade gliomas, meningiomas, and pituitary adenomas.
- Cerebral angiography can differentiate between giant aneurysm and mimicking lesions and also shows tumours with increased vascularity.

Other investigations

If metastases in differential diagnosis:

- full history and examination including PR;
- CXR;
- mammogram;
- CT chest, abdomen, and pelvis;
- bone scan;
- germinomas may secrete β HCG, alphafetoprotein;
- CSF cytology (if no ↑ ICP) for lymphoma, meningeal metastases, and ependymoma.

Differential diagnosis

- Infection (pyogenic abscess, tuberculoma, parasitic cysts, e.g. cysticercosis).
- Vascular lesion (haematoma, infarct with oedema and peripheral luxury perfusion, AVM, giant aneurysm).
- Traumatic haematoma.
- Inflammatory lesions, e.g. tumefactive lesion of MS.

Management

Depends upon:

- patient factors: age, functional status, individual wishes;
- tumour: location, histology, grade.

Biopsy is recommended in almost all cases.

Pre-operative management

- Corticosteroids reduce vasogenic oedema and improve neurological status temporarily.
 - Complications: GI haemorrhage, perforation, immunosuppression, diabetes, osteoporosis.
 - Dosage: loading dose 12 mg IV, followed by 4 mg qds (oral or IV), weaning from post-op day 2 over 1 week.
- When lymphoma is a differential diagnosis, steroids withheld until biopsy is performed.
- Anticonvulsants rarely used prophylactically as no impact on epilepsy incidence. Treatment instituted following a seizure (except within 4 hours of surgery).
- Antibiotics administered for prophylaxis of all intracranial surgery on induction (single dose 3rd generation cephalosporin, e.g. cefradine 1 g IV).
- Angiographic embolization useful to reduce blood flow in vascular tumours, e.g. glomus jugulare.

Surgical management*Neurosurgical terms*

- **Burr holes** are disc-shaped holes cut in the skull through which a biopsy needle, drain, or electrode is passed.
- **Craniotomy** describes the construction of a bone window that is replaced at completion (usually now with titanium plates and screws). Previously 16 mm burr holes joined by saw, now 1–2 miniburr holes (3 × 5 mm) giving access for a high speed craniotome drill to cut window.
- **Craniectomy** refers to removal of bone to access the cranium. Usually for posterior fossa as dural sinuses limit use of bone flaps.
- **Stereotaxy** is the technique by which a biopsy needle is precisely directed by a frame (attached to the skull) to a predetermined scan target.
- **Neuronavigation** is the method of interactive computerized guidance of a surgical instrument displayed on scan during surgery.
- **Debulking** is the subtotal removal of a tumour for diagnosis and relief of mass effect. Usually for high grade gliomas.
- **Excision**: complete removal of tumour and site of origin, e.g. meningioma. May be curative for benign lesions.
- **Subcapsular removal** is internal debulking with preservation of capsule, e.g. vestibular Schwannoma. May be curative preserving VII nerve function.

Neurosurgical procedures

- Freehand burr hole biopsy now superseded by guided procedures but used as an urgent procedure when abscess is diagnostic possibility.
- Stereotactic burr hole biopsy provides an accurate and safe method for diagnosis at almost any location. Diagnostic yield 97%; serious complications 3%; mortality 1%.
- Open biopsy is used for tumours adjacent to eloquent areas or near major blood vessels (may be image-guided).

- Craniotomy and debulking is the usual procedure for gliomas. Radical removal carries a survival advantage but not offered if there is a risk of increased neurological deficit. Internal bulking is performed to relieve pressure symptoms and ↓ tumour load prior to radiotherapy.

Complications ↑ deficit and oedema, epilepsy, haemorrhage, infection.

Intracranial tumours: management of specific tumours

Gliomas

Graded histologically from grade I to IV.

- Grade I (pilocytic astrocytoma usually in children). High cure rate with surgical excision.
- Grade II astrocytoma: median survival 4 years with a subgroup of long-term survivors (30%, 10-year survival).
- Grade III gliomas: median survival is 1.6 years. Grade IV, 0.7 years with treatment. Survival is increased by radical resection in all grades.

Radiotherapy is used as adjunct for all grade II–IV tumours providing Karnofsky score > 70.

- Early complications: somnolence, ↑ cerebral oedema, ↑ neurological deficit.
- Late complications: leucoencephalopathy, cognitive decline, parkinsonism, radiation necrosis, ↑ incidence of meningioma and glioma 10 years + after treatment.

Chemotherapy only recommended for anaplastic oligodendroglioma correlating with 1p and 19q chromosomal losses.

Meningiomas

- Majority are benign—clinically and histologically. Cured by resection.
- 15% have atypical features and adjunct DXT is required for residual tumour.
- <1% malignant and recur despite resection and DXT.
- Convexity lesions usually completely removed with no residual deficit.
- Parasagittal and parafalcine lesions often involve the superior sagittal sinus. In anterior 1/3 sinus may be sacrificed with complete excision. Elsewhere sinus must be reconstructed with vein graft or tumour left *in situ*.
- Suprasellar, tentorial, clivus, CPA and inner sphenoid wing lesions difficult to excise completely. Remnants need regular MRI or DXT.
- Complications: reactionary haemorrhage and coagulopathy due to DIC-like syndrome; epilepsy; profound oedema; venous infarction.

Primary CNS lymphoma

Extranodal high grade B cell lymphoma distinct from systemic lymphomas.

Epidemiology

- Sporadic (median age 55 years).
- Immunosuppressed transplant recipients, congenital immunodeficiency, SLE, Sjögren's, sarcoid, MS patients.
- AIDS.

Clinical features

- Brain (50%): present with signs and symptoms of ↑ ICP and focal neurological deficit.
- Leptomeninges: cranial neuropathies and rarely hydrocephalus.

- Eye. Uveitis, retinal detachment, vitreous haemorrhage, optic neuropathy, and retinal artery occlusion.
- Spinal cord. Focal spinal deficit.

Investigations

- CT ± contrast. Deep-seated, periventricular mass. Typically hyperdense but also isodense with marked enhancement and oedema.
- MRI. Low signal lesion on T1W and high signal on T2W with homogeneous enhancement with Gd. Multiple lesions seen in immunocompromised and may ring enhance resembling an abscess.
- LP (if no mass lesion). ↑ protein, ↓ glucose, abnormal monoclonal B cells.
- Stereotactic brain biopsy. Infiltration with B cells with a dense periventricular pattern. Immunohistochemistry confirms diagnosis and kappa and lambda stains confirm monoclonality.
 - Note. Steroids must not be given prior to biopsy as enhancement disappears making targeting difficult and tumour necrosis precludes histological diagnosis.

Treatment

- Radiotherapy. Median survival, 12–17 months. In AIDS patients 1.5–4.2 months.
- Chemotherapy. Methotrexate induction and maintenance increases survival to 40 months ± DXT.
- In HIV, HAART improves survival.

Cerebral metastases

- Commonest intracranial tumour (30%).
- Incidence ↑ due to ↑ survival with carcinoma, better imaging, and failure of chemotherapeutic agents to cross BBB.

Aetiology

- Haematogenous spread of carcinoma (lung > breast > kidney > GI > melanoma).
- Spread of primary CNS tumour (high grade glioma, primitive neuroectodermal tumours (PNET), ependymoma, pineal tumours).
- Direct invasion from skull or skull base.

Clinical features

- Symptoms and signs of ↑ ICP.
- Focal deficits.
- Seizures.
- Confusion.
- Sudden deterioration due to haemorrhage or vessel occlusion.

Imaging features

- Majority show either ring or solid enhancement.
- Solitary lesion on CT requires MRI (20% multiple).
- Solitary mass with history of carcinoma: > 90% chance of metastasis.
- No history of carcinoma and negative screening < 10% chance of metastasis.
- Solitary lesions in the posterior fossa in the elderly—even in the absence of a known primary, it is likely to be a metastasis.

Management

- Corticosteroids improve symptoms of mass effect.
- Mass lesion primary requires histological diagnosis \pm excision.
- If lesion is inaccessible or multiple, stereotactic biopsy is indicated.
- When lesion is resectable or there are symptoms of mass effect, lesions should be excised at craniotomy (maximum 3 metastases for clearance).
- Surgery followed by whole brain DXT \pm stereotactic DXT boost to residual metastases.
- Chemotherapy may be indicated depending on primary. But usually poor BBB penetration.

Prognosis

- Untreated median survival < 1 month.
- Steroids + DXT: survival 3–4 months (most die from cerebral disease).
- Surgical excision, whole brain DXT, and steroids: survival 9 months (most die from extracranial disease).

Haemangioblastoma

- Benign CNS tumours of vascular origin—usually sporadic, single, cystic lesions in the cerebellum.
- Multiple in von Hippel–Lindau disease. (See Inherited neurocutaneous syndromes, p.284).

Clinical features

- Female:male ratio 2:1.
- Peak incidence 30–60 years.
- The site of lesion: cerebellar > vermis > floor of the 4th ventricle > upper cervical cord.

Presentation

- Headache due to obstructive hydrocephalus.
- Cerebellar signs.
- Cervical tumours cause neck pain and posterior column sensory loss.
- Polycythaemia in 20% (\uparrow erythropoietin secretion).

Imaging features

- CT. Hypodense cyst with an isodense mural cyst that enhances. Typically the cyst does not enhance. Occasionally solid mass lesion.
- MRI. Cyst hypointense on T1W; hyperintense on T2W. Nodule isointense on T1W; hyperintense on T2W. Strong nodular enhancement. More sensitive for detecting small tumours.
- DSA. Hypervascular nodule with a tumour blush. Occasional AV shunting. It is possible to embolize the lesion pre-op.

Differential diagnosis Adults: metastasis. Children: pilocytic astrocytoma.

Management

- Excision for lesions causing symptoms.
- Solid hamangioblastomas are difficult because of uncontrollable haemorrhage and brain swelling.
- Cervicomedullary tumours removed for progressive neurological deficit or haemorrhage but high risk of post-op neurological deficit.

Ventricular tumours

- Colloid cysts, usually of the 3rd ventricle, are benign cystic tumours filled with jelly.
- Rare: < 1% of intracranial tumours.
- Early recognition is important due to the risk of sudden death from hydrocephalus.

Clinical features

- Headaches. May be positional, severe, and recurrent.
- Sudden drop attacks with or without headache.
- Sudden leg weakness.
- Progressive cognitive decline.

Imaging features

- Well-demarcated smooth round cystic mass ± hydrocephalus.
- CT. 65% hyperdense; rarely isodense. Usually no enhancement.
- MRI. Variable intensity depending on contents. T1W: isointense or hyperintense. Variable intensity on T2W.

Differential diagnosis

Neurocysticercosis (multiple lesions isointense to CSF with enhancing nodule (scolex)); large basilar tip aneurysm.

Management

- Small incidental lesions; MRI at regular intervals to monitor size.
- Symptomatic lesions especially with hydrocephalus need excision.

Surgical options

- Transfrontal microsurgical excision. Curative procedure with good access. 5% epilepsy rate.
- Transcallosal microsurgical excision. Curative but with risk of forniceal memory deficit.
- Endoscopic excision. Transcortical minimally invasive approach and low morbidity. However, high technical failure rate and recurrence.
- Stereotactic aspiration. Minimally invasive but inevitable recurrence. Reserved for the elderly and medically unfit patients.

Acoustic neuroma (vestibular Schwannoma)

- Benign tumour arising from the Schwann cells of the vestibular nerve.
- Unilateral tumours are sporadic.
- Bilateral lesions occur in neurofibromatosis II.
- Malignant transformation is rare.

Clinical features

- Unilateral hearing loss followed by tinnitus, vertigo, unsteady gait, facial numbness, and weakness.
- Late development of hydrocephalus and ↑ ICP.

Investigations

- Audiogram. High frequency hearing loss with speech discrimination worse than expected for this level. BSAEP abnormal.
- CT. Usually isointense or rarely hyperintense lesion; enhances with contrast; expansion of the IAC.
- MRI. Isointense on T1W; hyperintense on T2W. May be confined to the internal auditory canal or emerge like an 'icecream cone'.

Imaging guidelines for screening

- High resolution MRI of CPA (axial/coronal planes).
- Screen with T2W images.
- Gd if suspicious lesion.

Differential diagnosis

- Meningioma.
- Epidermoid cyst.
- Aneurysm or vascular ectasia.
- Rarely, arachnoid cyst.
- Metastases.
- Exophytic glomus tumour.

Management

Conservative and interval MRI, especially in the elderly or infirm.

Surgery

- Excision is curative but carries a significant morbidity.
- Possible to preserve hearing with a suboccipital approach.
- Preservation of facial nerve depends on size of the tumour.
- Large tumours with brainstem distortion carry the highest morbidity.
- Translabyrinthine approach (petrous bone hollowed out) for patients already deaf avoids cerebellar retraction.
- Middle fossa approach for intracanalicular lesions.
- Complications: CSF leak; VII and VIII nerve damage; vertigo; hydrocephalus.

Radiotherapy

- Stereotactic DXT has low morbidity in comparison to surgery and a high rate of tumour control.
- Most tumours do not shrink significantly.

This page intentionally left blank

Imaging of intracranial tumours: examples

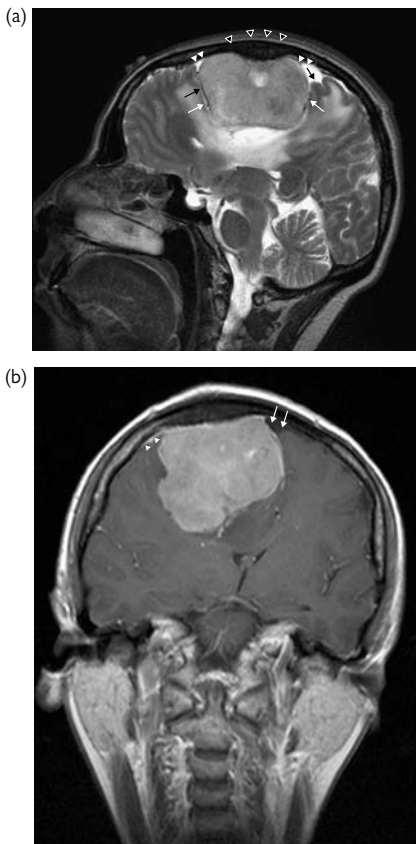


Fig. 5.12 Parafalcine meningioma. (a) T2-weighted sagittal; (b) post-gadolinium contrast enhanced coronal MRI. (a) Large grey matter isointense extra-axial mass denoted by CSF clefts (*white arrowheads*), displaced cortex (*small black arrow*), and pial vessels (*small white arrows*). Abnormal signal in keeping with vasogenic oedema is demonstrated in the underlying white matter. Note also the focal hyperostosis of the skull vault at the base of the tumour (*open white arrowheads*). (b) the mass enhances homogeneously. Note the CSF cleft (*white arrows*) and small 'dural tail' at the site of attachment (*white arrowheads*). There is significant mass effect with displacement of the midline and effacement of the lateral ventricles.

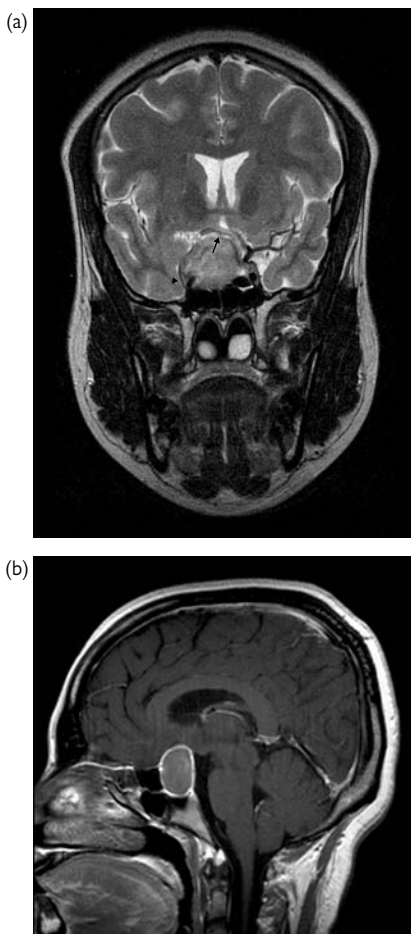


Fig. 5.13 Pituitary macroadenoma. (a) Coronal T2W and (b) sagittal post-contrast enhanced MRI. (a) Large slightly heterogeneous mass expanding the pituitary sella causing depression of the floor of the sella, mainly on the right with extension into the right cavernous sinus where the right cavernous segment of the ICA is encased (*black arrowhead*). The tumour extends into the suprasellar space and distorts the optic chiasm mainly on the left (*black arrow*). (b) The mass enhances most avidly in its periphery. The superior aspect of the clivus—the dorsum sellae—is eroded.

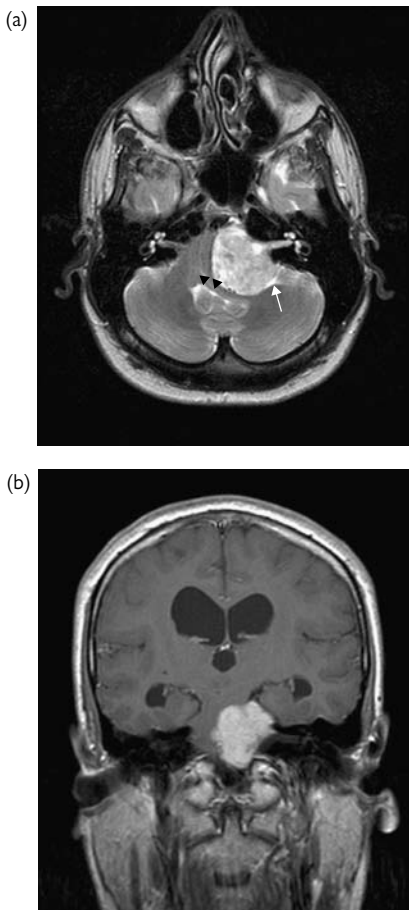


Fig. 5.14 Large vestibular Schwannoma. (a) Axial T2W and (b) post-contrast enhanced coronal MRI. Large lobulated homogeneously enhancing extra-axial mass, (denoted by the CSF cleft (*white arrow*)), in the left CPA cistern extending for a short distance into the internal auditory canal. There is marked distortion of the pons with effacement of the fourth ventricle, mainly on the left (*black arrowheads*). The hyperintensity on T2W imaging and lack of dural attachment are in keeping with a vestibular Schwannoma rather than a CPA cistern meningioma. Note that effacement of the fourth ventricle has resulted in hydrocephalus with dilatation of the third and lateral ventricles.

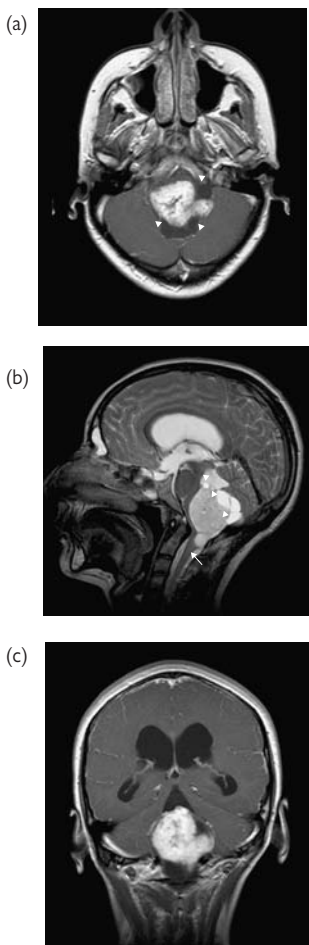


Fig. 5.15 Pilocytic astrocytoma. (a) Post-gadolinium enhanced axial and (c) coronal; (b) sagittal T2W MRI. Large mainly solid T2 hyperintense mass arising from the inferior cerebellar vermis. There are multiple associated cystic components (*arrowheads*). The tumour extends through the craniocervical junction and a small amount of oedema is shown in the cervical medullary junction (*b: white arrow*). The brainstem is clearly displaced anteriorly and outflow from the fourth ventricle is obstructed with resulting dilatation of the third and lateral ventricles.

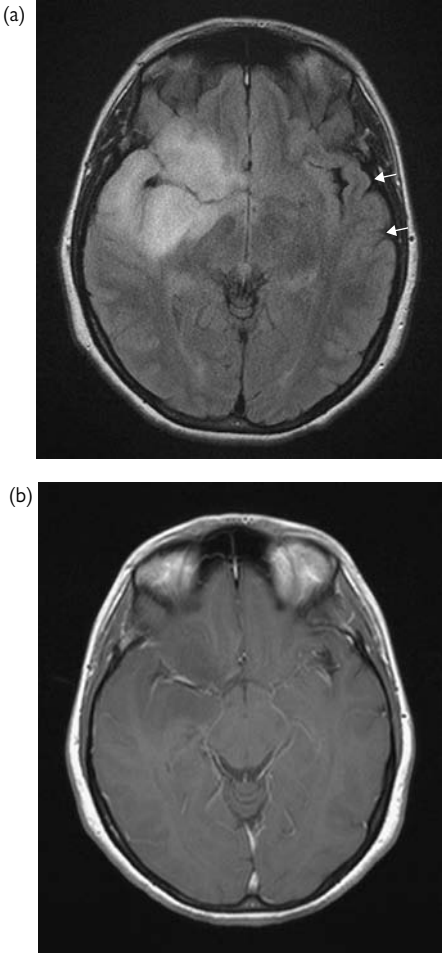


Fig. 5.16 Grade 2 diffuse astrocytoma. (a) Axial FLAIR and (b) post-contrast enhanced axial MRI. Moderately ill defined infiltrative mass of homogeneous hyperintensity causing gyral expansion involving the temporal lobe, and extending into the adjacent inferior frontal lobe on the right. No enhancement is demonstrated. Note the mild degree of mass effect with effacement of sulci on the lateral surface of the temporal lobe compared to the contralateral (*small white arrows*).

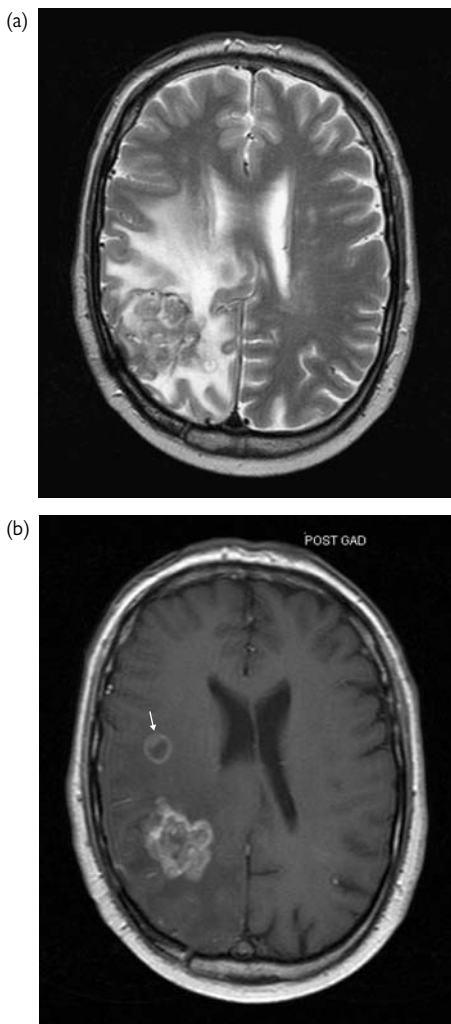


Fig. 5.17 Glioblastoma multiforme. (a) Axial T2W and (b) post contrast enhanced axial MRI. Irregular enhancing heterogenous right parietal mass with surrounding abnormal white matter within which is a second area of enhancing tumour more anteriorly (*white arrow*).

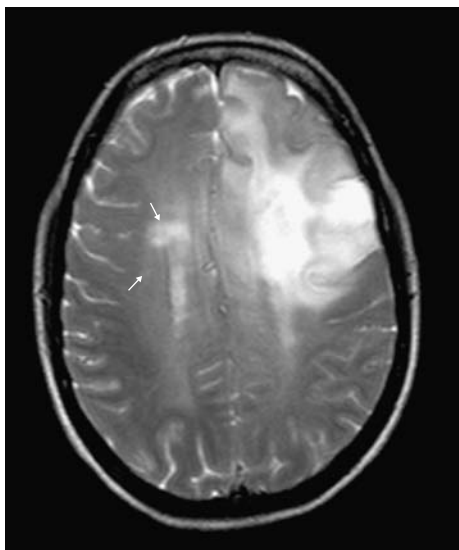


Fig. 5.18 Gliomatosis cerebri (Axial T2W MRI): Diffuse and very ill defined hyperintensity mainly in the left frontal and anterior portion of the left parietal lobe with loss of grey–white matter differentiation and focal areas of gyral expansion resulting in sulcal effacement. There is extension to the contralateral hemisphere with involvement of the corpus callosum (*white arrows*). There is, as is typical for this diagnosis, the impression of preservation of the underlying cerebral architecture. Post-contrast enhanced images did not demonstrate enhancement.

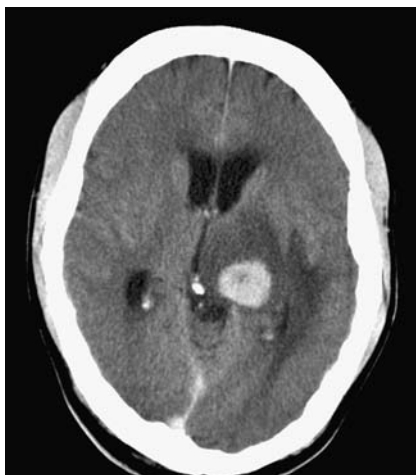

Fig. 5.19 Primary CNS lymphoma (post-contrast enhanced CT). Homogeneously enhancing solid mass involving the deep grey structures and with a periventricular location. Surrounding low attenuation denoting vasogenic oedema. Note the mild distortion of the midline. Non-enhanced images revealed a uniformly hyperdense mass.

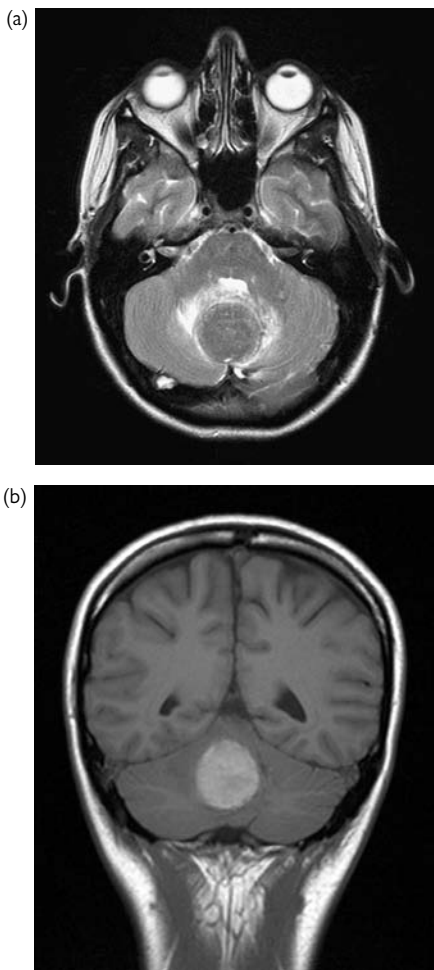


Fig. 5.20 Melanoma metastasis. (a) T2W axial and (b) coronal T1W MRI. The relative T2 hypointensity and T1 hyperintensity of this large cerebellar vermian mass is typical for a melanocytic melanoma deposit. The associated hyperintensity in the surrounding parenchyma denotes vasogenic oedema and there is mass effect upon the fourth ventricle.

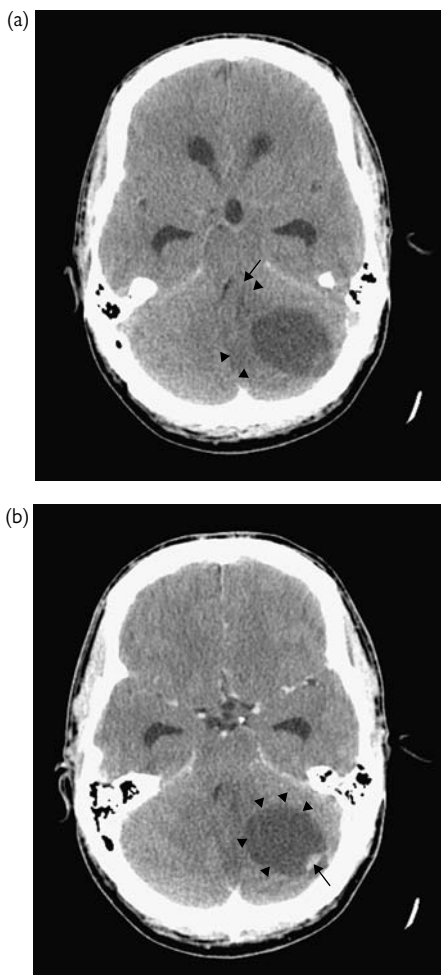


Fig. 5.21 Cerebellar hemangioblastoma. (a) Non enhanced CT and (b) contrast enhanced CT. Large well circumscribed cystic mass with non-enhancing imperceptible wall ((b) *black arrowheads*) and enhancing mural nodule ((b) *black arrow*). Note the small amount of surrounding low attenuation denoting vasogenic oedema ((a) *black arrowheads*) and effacement of the left side of the fourth ventricle ((a) *black arrow*). There is resulting obstructive hydrocephalus with dilatation of the temporal horns.

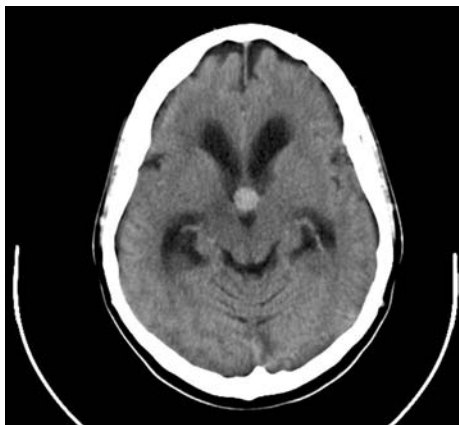


Fig. 5.22 Third ventricular colloid cyst (non-enhanced CT). Rounded hyperdense lesion in the anterior aspect of the third ventricle at the site of the foramen of Munro causing subsequent obstructive hydrocephalus with dilatation of the lateral ventricles.

This page intentionally left blank

Imaging of spinal tumours examples

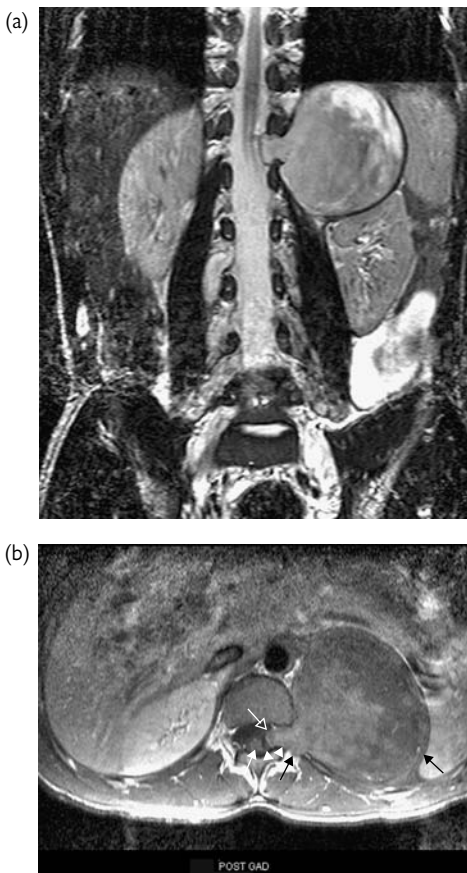


Fig. 5.23 Large spinal neurofibroma. (a) Coronal T2W and (b) post-contrast enhanced axial MRI. Large well encapsulated left-sided extraspinal mass (*black arrows*) extending into the left lumbar intervertebral foramen (*white arrowheads*) causing distortion and displacement of the conus medullaris (*closed white arrow*). There is a small intradural component (*open white arrow*).

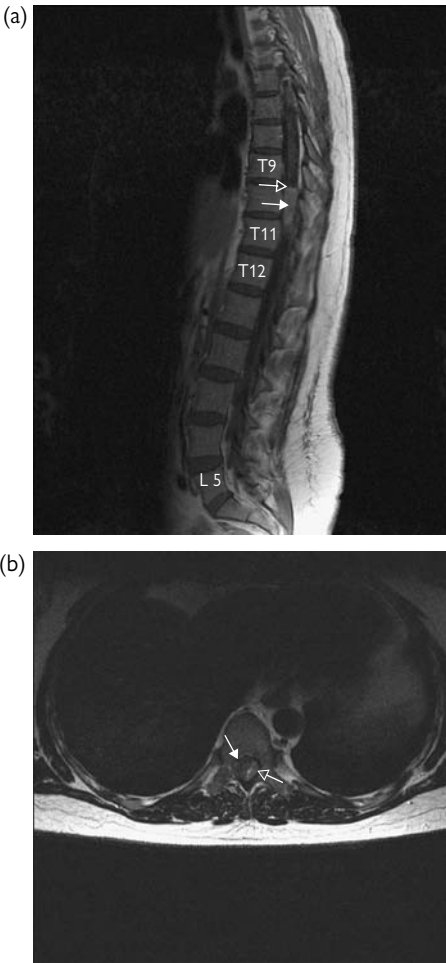

Fig. 5.24 Thoracic spinal meningioma. (a) Post-contrast enhanced sagittal and (b) axial T2W MRI. Homogeneously enhancing intradural extramedullary mass at T10 (closed white arrow) with a relatively broad dural attachment ((a) *open white arrow*). The spinal cord is compressed and displaced to the posterolateral aspect of the vertebral canal ((b) *open white arrow*).

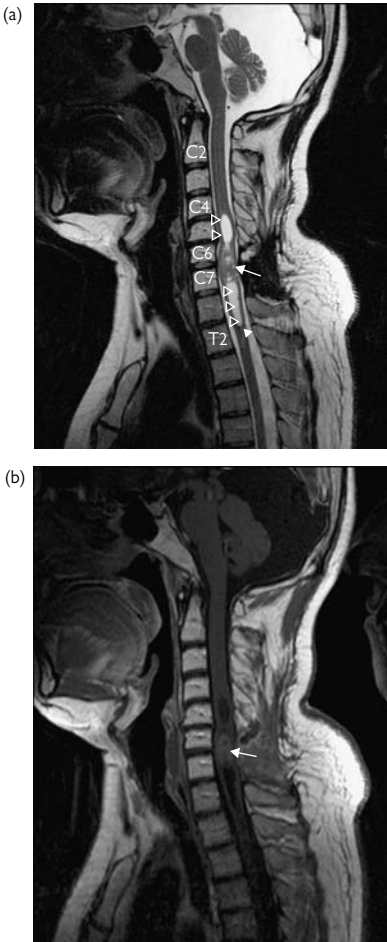


Fig. 5.25 Spinal cord ependymoma. (a) sagittal T2W and (b) post-contrast enhanced sagittal MRI. Intramedullary heterogeneous signal intensity mass at the C6 and 7 vertebral levels (*white arrow*). Cranially and caudally extending cavities are demonstrated (*open white arrowheads*) and a small area of haemosiderin staining, in keeping with previous haemorrhage, is shown in the dependent portion of the caudal cavity (*closed white arrowhead*). Patchy enhancement following gadolinium administration ((b) *white arrow*) and expansion of the spinal cord from C4 to T2 are typical of an intramedullary tumour.

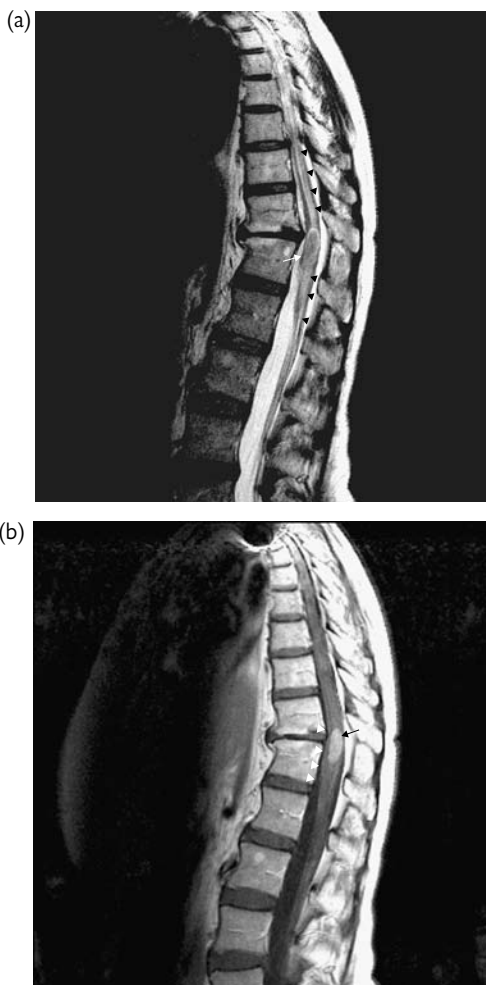


Fig. 5.26 Intramedullary metastasis. (a) Sagittal T2W and (b) post-contrast enhanced sagittal MRI. A well demarcated intramedullary mass ((a) *white arrow*) is associated with surrounding spinal cord oedema ((a) *black arrowheads*) and expansion ((b) *white arrowheads*). The lesion enhances smoothly after contrast administration ((b) *black arrow*). The patient had multiple systemic and intracranial breast metastases.

Head injuries (HI)

- Trauma is a leading cause of death in adults < 45 years.
- Head injury accounts for > 50% of these deaths.
- Alcohol is a significant factor in > 50% of these deaths.
- Mortality for patients undergoing neurosurgery for post-trauma complications is 40%.
- In UK, 1500 per 100,000 attend A & E with a HI; 300 per 100,000 are admitted; 15 per 100,000 are transferred to a neurosurgical unit; 9 per 100,000 die every year.

Pathophysiology

- Diffuse or primary brain injury applies to structural and functional damage sustained at the time of injury.
- Mass lesions include haematomas (extradural, subdural, intracerebral) or intracerebral contusions that affect the frontal and temporal lobes at the site of injury (coup) or opposite the injury (contrecoup).
- Secondary insults relate to subsequent events to which the injured brain is acutely susceptible—hypoxia, hypoperfusion, hyperthermia, ↑ ICP, and metabolic derangements.

Assessment

- 1 Initial assessment according to ATLS protocols. Avoid hypoxia (O_2 sat. < 90%) and hypotension (systolic BP < 90 mmHg)
- 2 Assessment of conscious level using the Glasgow coma scale (see Table 5.3).
- 3 If GCS not depressed, detailed assessment of limb power, sensory assessment, cranial nerve function including pupillary responses, corneal reflexes, gag and cough reflexes.
- 4 Observe respiratory pattern and rate.
- 5 Check pulse and BP.
- 6 Check for scalp lacerations, rhinorrhoea, otorrhoea, haemotympanum, and extracranial injuries. Bruising associated with base of skull injuries includes Battle's sign and racoon eyes.
- 7 If possible determine retrograde and anterograde amnesia.

Head injuries strongly associated with cervical injury.

Table 5.3 Glasgow coma scale (GCS)*

Score	Eye opening	Motor response	Verbal response
1	None	None	None
2	To pain	Extension	Sounds
3	To speech	Abnormal flexion	Words
4	Spontaneously	Flexion	Confused speech
5		Localizes	Orientated
6		Obeys commands	

* Note that the minimum GCS score is 3.

Classification

Severity

- Mild, GCS 13–15 after resuscitation.
- Moderate, GCS 9–12.
- Severe, GCS 3–8.

Post-traumatic amnesia

- Very mild, < 5 min.
- Mild, 5–60 min.
- Moderate, 1–24 hours.
- Severe, 1–7 days.
- Very severe, 1–4 weeks.
- Extremely severe, > 4 weeks.

Management also see Chapter 7.

Indications for urgent CT

- Depression of conscious level after resuscitation.
- Focal neurological signs.
- Epileptic seizure.
- CSF rhinorrhoea or otorrhoea.
- Basal skull fracture.
- Potential penetrating injury.
- Difficulty in assessment due to alcohol and drugs.
- Uncertain diagnosis.

Primary phase management

1. Regular neuro obs to detect any deterioration.
2. Sedation, intubation, and ventilation indicated for:
 - patients in coma with GCS < 9 or deteriorating GCS;
 - poor airway protection;
 - abnormal respiratory pattern;
 - $\text{PaO}_2 < 9 \text{ kPa}$ on air or $< 13 \text{ kPa}$ on O_2 ; $\text{PaCO}_2 > 6 \text{ kPa}$ or $< 3 \text{ kPa}$ on O_2 ;
 - confused and/or agitated patients before CT;
 - significant maxillofacial injuries or oropharyngeal haemorrhage.
3. Mannitol 20% 1 g/kg: 200 ml for average adult may help lower ICP.
4. Corticosteroids have no place in the management of head injuries.
5. Referral to a neurosurgical centre and image transfer if possible of:
all moderate to severe HI; abnormal CT scan; depressed GCS with normal CT scan; all penetrating injuries; uncertain CT findings due to lack of expertise.

Physiological parameters for transfer

- Assume ICP to be 30 mmHg and maintain cerebral perfusion pressure (CPP) (mean arterial pressure – ICP) at > 70 mmHg (with inotropes if necessary).
- Maintain PaO₂ > 15 kPa and PaCO₂ at 4–4.5 kPa.

Secondary phase management

Respiratory management Aim for target arterial CO₂ of 4–4.5 kPa. If prolonged ventilation consider tracheostomy.

ICP

Aim for an ICP < 25 mmHg and CPP > 70 mmHg. ICP is monitored via an intraventricular or intracerebral bolt placed close to the most affected region.

- Stage 1:
 - nurse head up tilt 10–15°;
 - SaO₂ > 97%;
 - PaO₂ > 11 kPa;
 - PaCO₂ at 4.5 kPa;
 - S_{ijv}O₂ > 55%;
 - < 37°C.
- Stage 2:
 - mannitol, inotropes as necessary;
 - ↓ pCO₂ to 4.0 kPa;
 - maintain S_{ijv}O₂ > 55%;
 - maintain temp < 35–36°C. Note: role of hypothermia is controversial;
 - consider external ventricular drain.
- Stage 3:
 - temperature 33°C;
 - consider decompressive craniectomy.
- Stage 4:
 - thiopentone.

Management of specific head injuries

Space-occupying lesions

- Expanding mass lesions due to extradural and subdural haematomas need to be detected early.
- Initially, cerebral hemisphere compression causes contralateral focal signs, followed by deteriorating conscious level (GCS), and finally herniation of the ipsilateral uncus through the tentorial hiatus—causes an ipsilateral 3rd nerve palsy.
- Continued expansion leads to bilateral herniation and brainstem compression.
- Present with decerebrate posturing and Cushing's response (bradycardia and hypertension) followed by hypotension and diabetes insipidus.
- Rarely, a mass lesion causes ipsilateral hemiparesis through brainstem shift impacting the contralateral free edge of the tentorium (Kernohan's notch).

Extradural haematoma (EDH)

- Classically after a HI, e.g. cricket ball, instant LOC, followed by a lucid interval and later by a progressive decline in GCS.
- Haemorrhage is arterial (usually posterior branch of middle meningeal artery is torn at site of skull fracture).
- Bleeding is extradural and strips the dura mater from inner aspect of the skull compressing the brain.

Imaging

CT

- Biconvex high density extra-axial mass.
- Some have low attenuation components, 'swirl sign' indicative of hyperacute bleeding.
- Does not cross suture lines.
- 20% can develop or enlarge after a delay of 36 hours.
- 50% associated with other lesions, e.g. contre-coup contusions, SDH, and SAH.

Management

- True neurosurgical emergency: if necessary resuscitate during transfer.
- Surgical procedure: burr hole over pterion (to ensure further haemorrhage escapes instead of expanding the clot further) followed by craniotomy and evacuation of haematoma.

Outcome

- Depends on pre-operative status.
- Patients with bilateral fixed, dilated pupils may still recover if surgery immediate.
- If pre-op GCS ≥ 8 , 90–100% recovery. If GCS < 8 , mortality rate 30%, good outcome 50–60%.

Acute subdural haematoma (ASDH)

- Occurs after high impact injury, e.g. fall from a height or RTA.
- Highest mortality rate among post-traumatic mass lesions.
- Immediate LOC with progressive decline in GCS.
- Haemorrhage is arterial and venous from contused cerebral cortex, cerebral arteries, and veins.
- Haemorrhage occurs between dura and brain with additional brain damage.

Imaging

- CT: crescentic hyperdense mass. May cross sutures and extend into the interhemispheric fissure and over tentorium. Hyperacute or active bleeding can be low density.
- Anaemia and coagulopathy can cause isodense acute haemorrhages.

Management

- Emergency trauma craniotomy with a large flap to expose entire haematoma and affected cortex for evacuation and haemostasis.
- Cerebral swelling is common and may require frontal or temporal lobectomy for decompression and bone flap removal.
- Patients usually require post-operative ventilation and ICP monitoring.

Outcome

Dependent upon:

- conscious level;
- extent of underlying brain injury;
- degree of secondary swelling.

Mortality, 50–70%. Good outcome in 20–40%.

Chronic subdural haematomata

- Late sequela of minor/moderate HI usually in the elderly.
- A history of a low velocity HI 4–8 weeks previously is often forgotten or ignored.
- There is a gradual evolution of:
 - headaches;
 - cognitive decline;
 - ataxia;
 - hemiparesis;
 - impaired conscious level.

Imaging

CT: low density or isodense mass that may be loculated.

Management

- Dexamethasone 4 mg qds.
- Cortical compression, midline shift, and contralateral hydrocephalus (due to obstruction of 3rd ventricle) indicate need for surgery.
- Burr hole drainage ± subdural drain.
- Re-operation required in 10–15% and further surgery in 5%.
- Complications, usually in the elderly: subdural empyema, < 1%.

Intracerebral haematoma

- Develops from major contusions or vascular injury.
- Management depends upon clinical condition and extent of mass effect.
- Surgical evacuation via craniotomy is indicated when focal signs are evident or GCS ↓.

Other complications

- Cortical contusions due to impact of the brain against corrugated bone or dura. Most common sites are the anterior-inferior temporal and frontal lobes.
- Parasagittal and dorsal brainstem lesions less common.
- May be multiple and bilateral.
- Frequently associated with ASDH and EDH.
- These may develop into mass lesions as the contusions mature.
- 25% develop diffuse brain swelling.
- Craniotomy with evacuation and/or lobectomy may be necessary to manage mass effect.

Traumatic SAH

- Most common cause of SAH and indicative of a severe brain injury.
- Blood is usually in the sulci adjacent to the contusions and SDH rather than in the basal cisterns.
- Vasospasm risk is low but nimodipine 60 mg 4-hourly PO/via NG for 10 days recommended.
- Hydrocephalus is rare.

Penetrating head injuries

- History of injury may be unclear or the patient may be unaware of a penetration.
- Mortality from gun shot wounds, 50–70%.
- Should be suspected if:
 - intracranial air is seen on CT;
 - evidence of indriven bone.

There is a particular risk of:

- infection (meningitis, cerebritis, and abscess);
- cortical injury;
- ICH;
- neurovascular injury (carotid artery, sagittal sinus);
- injury to the optic nerve;

Angiography is mandatory for deep penetrating injuries.

Management

- Close any CSF fistulae.
- ↑ risk of infection: use prophylactic antibiotics.
- ↓ epilepsy rate by removing bone spicules.
- Depressed fractures are locked in place and a circumferential craniectomy performed.

- Haematoma, contused brain tissue, and implanted bone are removed.
- Elevation and debridement indicated for depression of > 1 cm with dural breach within 24 hours of injury.
- However, contraindicated when delayed, eloquent areas of the brain affected, or venous sinus involvement.

Diffuse axonal injury

- Results from shearing of axons within brain matter in a closed brain injury.
- Usually with immediate LOC and is a common cause of post-traumatic persistent coma.
- There is a risk of diffuse brain swelling.

Imaging

- CT:
 - normal initially in 50–80%;
 - later development of petechial haemorrhages.
- MRI more sensitive:
 - multiple hyperintense lesions on T2W imaging and FLAIR especially in corpus callosum and at the grey white matter interface;
 - hypointense on T2* if haemorrhagic.
- Maintain a low threshold for re-imaging as appearances evolve.

Management

- Sedation, intubation, and ventilation.
- ICP monitoring and control.

Basal skull fractures

- Most are undisplaced and do not require surgery.
- Displaced fractures may compress cranial nerves, e.g. optic nerve, and require decompression.
- Maxillofacial fractures that are unstable require elective fixation.
- CSF leaks usually cease spontaneously within 7–10 days.
- Continued leakage requires surgical closure.
- Antibiotic prophylaxis not required for CSF leaks or base of skull fractures.
- Avoid NG tube in base of skull fractures: use orogastric tubes.

Seizures

- Occur commonly in the context of HI, especially if there is a depressed skull fracture.
- Treat with phenytoin, which can be given IV/orally/via NG tube.

Infection

- Antibiotics are only prescribed in the presence of infection—not as prophylaxis.
- Aspiration pneumonia and MRSA are common complications.

Delayed complications

- Vascular:
 - chronic subdural haematoma;
 - carotid dissection;
 - traumatic aneurysms;
 - carotid—cavernous fistula.
- Infection:
 - cerebral abscess;
 - meningitis;
 - subdural empyema;
- Epilepsy
- Cranial nerve deficits
 - olfactory;
 - trigeminal;
 - facial;
 - vestibulo-cochlear (e.g. BPPV).
- Psychological: behavioural disturbance, depression.

This page intentionally left blank

Imaging of head injuries: examples

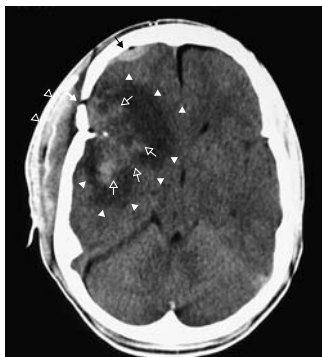


Fig. 5.27 Direct impact (non-enhanced CT). Blunt trauma to the right frontal region with extracranial soft tissue swelling (*open white arrowheads*) and right frontal fracture (*closed white arrow*). There is an extensive underlying parenchymal contusion comprising low attenuation components (*closed white arrowheads*) and central haemorrhagic change (*open white arrows*). There is associated mass effect with ipsilateral sulcal and ventricular effacement and minor distortion of the midline. Note also the small right frontal extradural haematoma (*black arrow*).

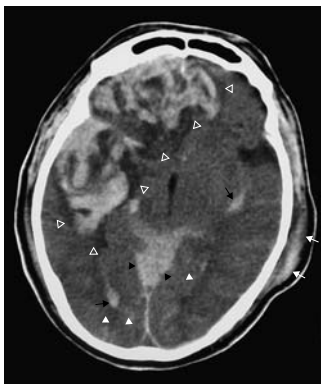

Fig. 5.28 Indirect impact (non-enhanced CT). Blunt trauma to the left temporoparietal region (*white arrows*) with sudden cranial deceleration and angular rotation resulting in shear-strain forces causing large haemorrhagic 'contre-coup' contusions in the inferior aspects of both frontal and right temporal lobes (*open white arrowheads*). Note also smaller foci of parenchymal haemorrhage in the occipital lobe bilaterally (*closed white arrowheads*), intraventricular and subarachnoid blood (*black arrows*), and an extensive tentorial subdural haematoma (*black arrowheads*).

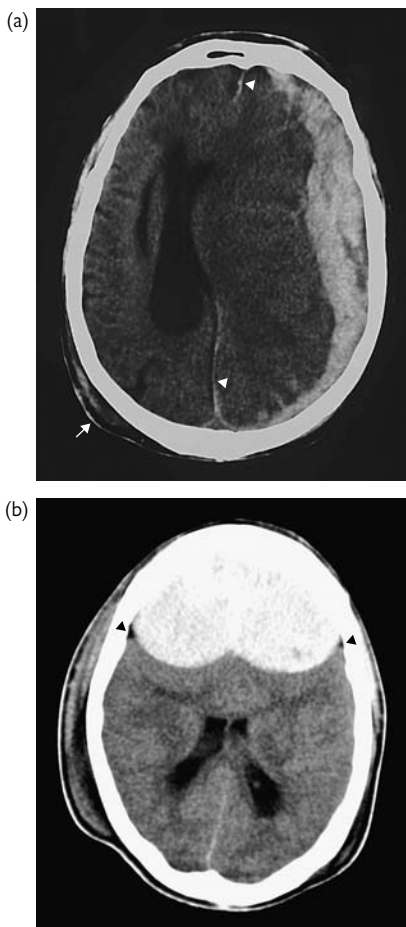


Fig. 5.29 Acute extraaxial haematoma. (a) and (b): non-enhanced CT. A large acute subdural haematoma with crescentic configuration overlying the left cerebral convexity with minor extension into the interhemispheric fissure (*white arrowheads*). There is marked associated mass effect with ipsilateral sulcal and ventricular effacement and severe midline shift. Note the indirect site of impact over the right parietal bone (*white arrow*). By contrast note the CSF clefts (*black arrowheads*) associated with a bifrontal extradural haematoma in (b) which has a biconvex configuration. The frontal horns of the lateral ventricles are grossly effaced.

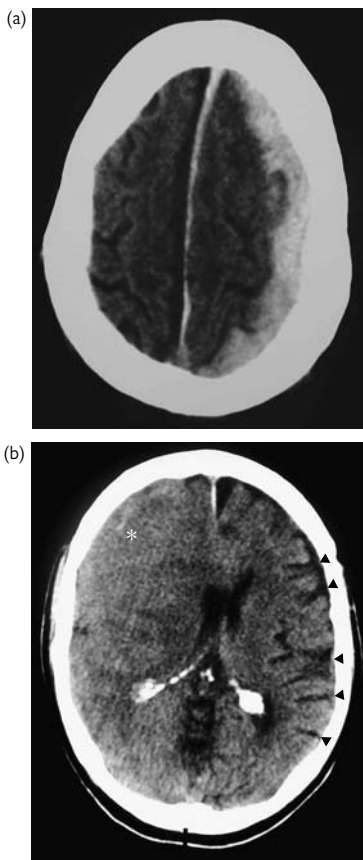


Fig. 5.30 Subdural haematoma. (a)–(d): non-enhanced CT. A large subdural haematoma over the left cerebral convexity and extending into the interhemispheric fissure in (a) is hyperdense in keeping with an acute haematoma. A subacute right-sided subdural haematoma is shown in (b) with iso- to mildly hyperdense material overlying the right cerebral convexity (white asterisk) resulting in effacement and obscuration of ipsilateral cerebral sulci compared to the contralateral side (black arrowheads) and midline distortion.

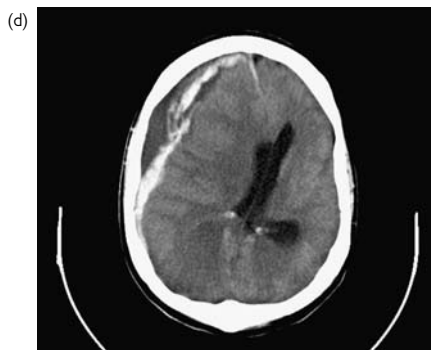
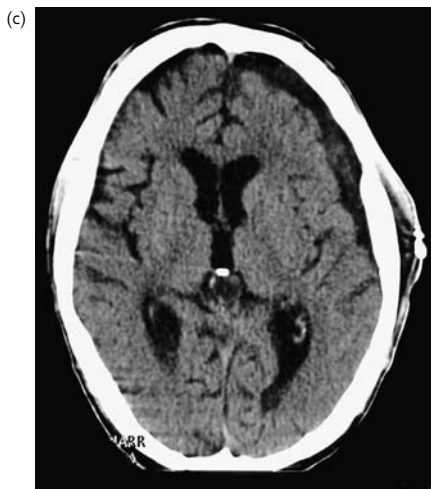
Fig. 5.30 Subdural haematoma. (a)–(d): non-enhanced CT. The left frontal chronic subdural haematoma in (c) is predominantly hypodense but also demonstrates some mass effect with effacement of sulci in the underlying left frontal lobe. There is also a minor alteration in the configuration of the left frontal horn due to mass effect. (d) a hyperacute right frontal subdural haematoma with mass effect. The hyperdense components represent acute haemorrhage, the low attenuation material reflects active bleeding and unclotted oxygenated blood.

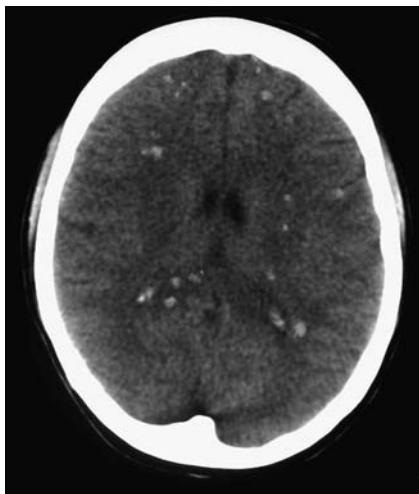


Fig. 5.31 Diffuse axonal injury (DAI; non-enhanced CT). Severe shear-strain injury resulting in multiple foci of acute petechial haemorrhage involving the splenium and posterior aspects of the corpus callosum and frontal parenchyma predominantly at the grey-white matter interface.

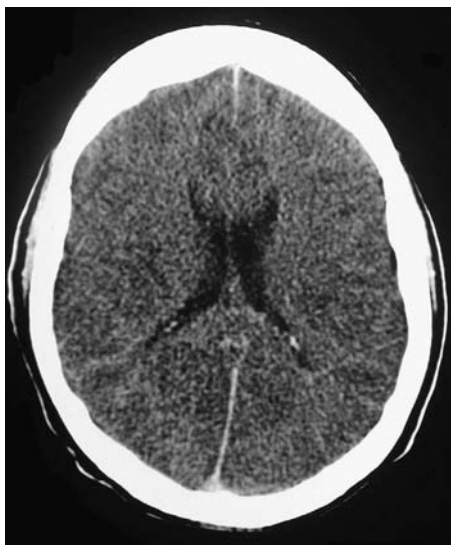


Fig. 5.32 Severe secondary brain injury (non-enhanced CT). There is reversal of the normal grey–white matter pattern with low density change involving the cortex with generalized cerebral swelling indicative of hypoxic/anoxic brain injury.

Spinal injuries

- These are often associated with multiple injuries and head trauma.
- Early detection and immobilization are vital to avoid secondary insults.
- Spinal level defined by the affected vertebral level and the most cephalad cord segment involved.
- Completeness: the prognosis and management are dictated by whether the lesion is complete or not. Incomplete lesions (including sacral sparing, i.e. sensation and control of anal sphincter) may recover to a variable extent and may benefit from decompression.
- Spinal shock refers both to the haemodynamic effects of cord injury and to the flaccid phase (first 1–2 weeks) after cord injury.

Spinal stability

- Instability is defined as the loss of ability of the spine to maintain normal anatomical alignment under normal physiological loads. Instability refers to the increased likelihood of further spinal damage.
- Spinal stability is classified according to the Denis three column model of the spine:
 - anterior column = the anterior one-half of the vertebral body and annulus fibrosus and anterior longitudinal ligament (ALL);
 - middle column = the posterior one-half of the vertebral body and annulus fibrosus and posterior longitudinal ligament (PLL);
 - posterior column = pedicles, laminae, spinous processes, and ligaments.

The spine is unstable if ≥ 2 columns are disrupted.

Acute cord injury

Management

1. Resuscitation and airway protection.
2. Immobilization of the neck and log rolling during assessment and resuscitation.
3. Treatment of life-threatening injuries and bleeding.
4. Urinary catheter.
5. Full neurological examination to determine level and completeness of lesion.
6. Palpate spine for any 'step'.
7. Note any autonomic dysfunction, e.g. ileus, priapism.
8. IV methylprednisolone may improve outcome when administered within 8 hours of injury (30 mg/kg over 15 minutes bolus and maintenance 5.4 mg/kg per hour for 23 hours).

C1 and C2 fracture

C1 and C2 are rings. Fracture in 2 places is typical.

Atlanto-occipital dislocation The distance between the anterior margin of the foramen magnum (basion) and dens > 12.5 cm. Usually fatal.

C1 fracture (Jefferson)

Caused by disruption of the C1 ring due to compression or a burst fracture.

Clinical features Rarely have a neurological deficit as the spinal canal is wide and fragments burst outwards.

Imaging

- Open mouth view X-ray: lateral displacement of C1 lateral masses relative to C2 lateral masses (overhang on C2 ≥ 7 mm).
- Lateral X-ray: fractures of anterior and posterior arch of C1.

Management

- This is an unstable fracture.
- Requires Halo immobilization for 3 months (rigid orthosis using a ring (halo) attached to outer table of skull by four screws attached by vertical side bars joining a rigid jacket strapped to the chest).

C2 fractures

Odontoid peg fractures

Frequently associated with multiple injuries with high force impact.

Classification

- Type 1, upper dens fracture (10%).
- Type 2, base of neck of peg (60%).
- Type 3, transverse fracture through C2 vertebral body (30%).

Clinical features

Neurological deficit in 20% of type 2 fractures. Unusual in type 3 fractures.

Imaging High resolution CT from occiput—C3; MRI cervical cord.

Management

- All unstable fractures.
- Majority treated by halo immobilization. Surgical treatment with fixation is indicated in the following:
 - displacement of fracture > 4 mm;
 - persistent movement in halo;
 - non-union including fibrous union after 3 months;
 - comminuted type 2 fracture.

Hangman's fracture

Usually caused by high impact axial loading injury. Due to bilateral fractures of pars interarticularis of C2.

Clinical features

- Majority are neurologically intact.
- Complain of neck pain and a sensation of instability.
- May walk into A & E holding head!

Imaging

- Usually apparent on lateral cervical spine X-ray.
- MRI is indicated if neurological signs are present.

Management

- Minimally displaced fractures are treated in a SOMI (sterno-occipito-mandibular immobilizer) brace if compliant or halo jacket.
- If fractures displaced > 4 mm, halo is mandatory.

Indications for surgical treatment

- Displacement not reduced with judicious neck extension.
- Persistent movement in halo.
- Associated C2/3 disc disruption.
- Non-union after 3 months' halo treatment.

Subaxial (C3–C7) fractures

- Commonly associated with head injuries and severe neurological deficit.
- Flexion injuries are more severe.
- Fractures through vertebral body, wedge fractures, teardrop fractures (anterior portion of vertebral body), and avulsion fragments.

Clinical features

- Neck pain.
- Radiculopathy.
- Myelopathy.
- Tetraplegia.

Imaging

- Anteroposterior (AP) and lateral cervical X-ray reveal majority of fractures.
- Flexion/extension lateral cervical spine views only to exclude occult instability and only in patients who are fully conscious.
- Increased anterior soft tissue shadow: (C1–4 normal = half vertebral body; C5–7 normal = whole vertebral body) if > requires further investigation with CT or MRI.
- MRI necessary in all patients with abnormal neurological signs.

Management

- Complete neurological deficit: further management aimed at avoiding secondary damage and maximizing rehabilitation.
- Unstable fractures treated with halo or internal fixation to allow early mobilization and avoid respiratory complications.
- Incomplete neurological injury with cord compression requires decompression and fixation (internal or external halo).
- Unstable injury without a deficit or stable deficit managed with a halo if minor displacement; otherwise internal fixation and fusion.

Cervical facet dislocation

- Hyperflexion injury resulting in superior facet 'jumping' inferior facet becoming trapped in dislocation by rim of facet.
- Flexion alone results in bilateral facet dislocation accompanied by disc and ligament disruption.
- Flexion with rotation leads to unilateral facet dislocation.

Clinical features

- Usually severe cord injury.
- Unilateral facet dislocation: 25% are intact neurologically; 25% incomplete cord injury; 40% root injury; 10% complete cord injury.

Imaging Lateral cervical spine X-ray shows anterior transposition of upper vertebra by 25% vertebral body width in uniface dislocation and 50% vertebral body width in bilateral facet dislocations.

Management

- Skull traction with muscle relaxant, e.g. diazepam, commencing at 3 times upper vertebral levels in pounds, increasing by 4–10 pounds every 15 minutes until relocated using image intensifier. Cease at 10 pounds per vertebral level or if there is any evidence of overdistraction (any disc height > 10 mm).
- Open reduction if traction fails.
- Majority require internal fixation with interspinous wiring, lateral mass plates and bone graft to maintain position.

Thoracolumbar fractures

- Caused by high force and associated with multiple trauma.
- Comprise wedge fractures (anterior \pm posterior column), burst fractures (anterior and middle column), or fracture dislocations (all columns).
- Unstable if wedge > 75% vertebral height or 3 adjacent vertebrae wedged.

Clinical features High proportion have a significant neurological deficit.

Imaging Plain films followed by high resolution CT or MRI.

Management

- Complete neurological deficit. Avoid secondary complications and maximize rehabilitation. If unstable, fractures are treated with prolonged bed rest or internal fixation to allow early rehabilitation.
- Incomplete neurological injury with cord compression requires early decompression and internal fixation.
- Unstable injury with no deficit or stable deficit managed with bed rest, corset, or internal fixation. All others require internal fixation and fusion.

Rehabilitation of spinal cord injury

Survivors of spinal cord injury require expert management to avoid the complications of:

- DVT;
- bed sores;
- infections, e.g. UTI;
- respiratory failure;
- contractures;
- osteoporosis;
- psychological problems.

Imaging spinal injuries: examples

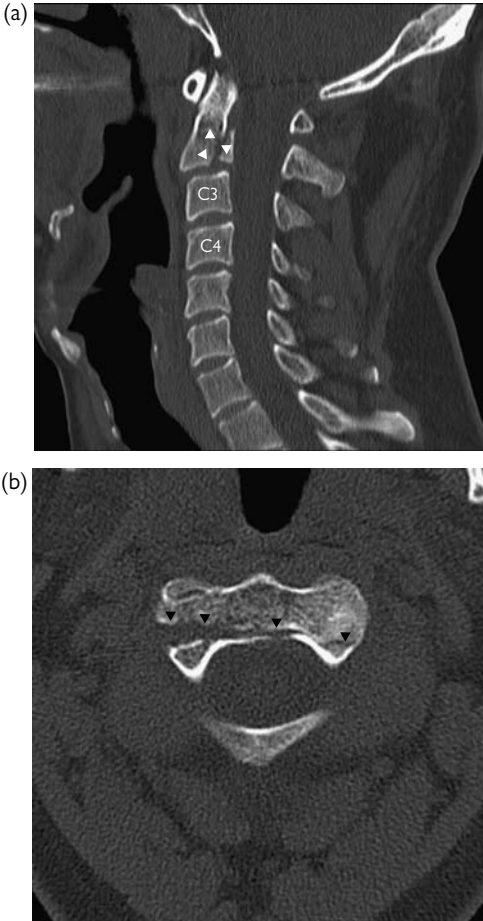


Fig. 5.33 Coronal fracture of body of C2 Hangman's fracture. (a) CT sagittal MPR; (b): axial CT. Slightly displaced fracture through the body of C2 in the coronal plane ((a) white arrowheads; (b) black arrowheads). There is slight anterior subluxation of C2 upon C3.

This page intentionally left blank

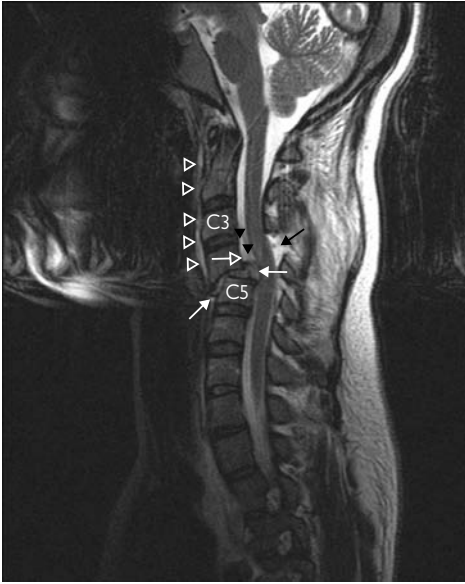


Fig. 5.34 Bilateral cervical facet subluxation. Sagittal T2W MRI. Severe spinal injury with grade 2 spondylolisthesis (anterior subluxation) of C4 upon C5, C4/5 intervertebral discal injury with hyperintensity and posterior bulge into vertebral canal (*closed white arrows*) and posterior ligamentous injury (*black arrow*). There is a shallow epidural haematoma posterior to the C4 vertebral body (*open white arrow*), which has elevated and posteriorly displaced the dura (*black arrowheads*). The spinal cord is distorted and displaced, although no cord contusion is evident at this stage. Note the shallow haematoma in the prevertebral soft tissue compartment (*open white arrowheads*).

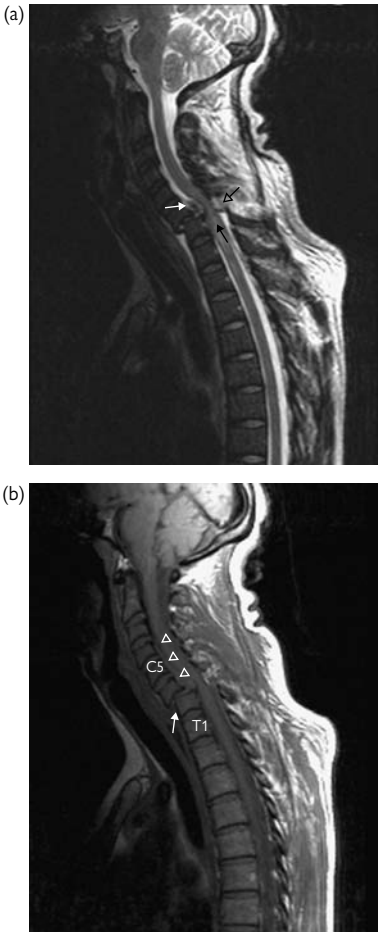


Fig. 5.35 Bilateral facet dislocation. (a) Sagittal T2W and (b) sagittal T1W MRI. Grade 2 spondylolisthesis of C6 upon C7 with large disc protrusion ((a) white arrow), epidural haematoma ((b) open white arrowheads), and rupture of the posterior ligamentous structures ((a) open black arrow). Discontinuity of the anterior longitudinal ligament indicates probable injury ((b) closed white arrow). The spinal cord is compressed and intramedullary signal change, in keeping with oedema, extends from C6 to T1 ((a) closed black arrow). Note the absence of intramedullary hyperintensity on T1W or hypointensity on T2W imaging, which would indicate spinal cord haemorrhage.

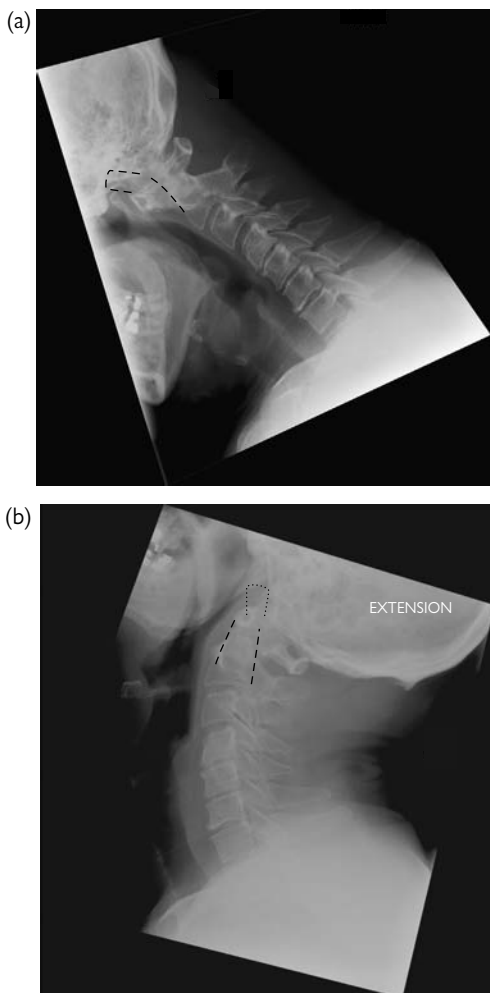


Fig 5.36 Type 2 odontoid peg fracture. (a) and (b) Flexion and extension plain X-ray. Dynamic plain X-rays demonstrate marked instability at the atlanto-axial joint as a result of a fracture through the odontoid peg. On flexion, there is marked anterior subluxation of the C1 ring and fracture fragment of C2 (*dotted line*), in relation to the inferior portion of C2 (*dashed line*) with consequent reduction in the calibre of the vertebral canal at this level.

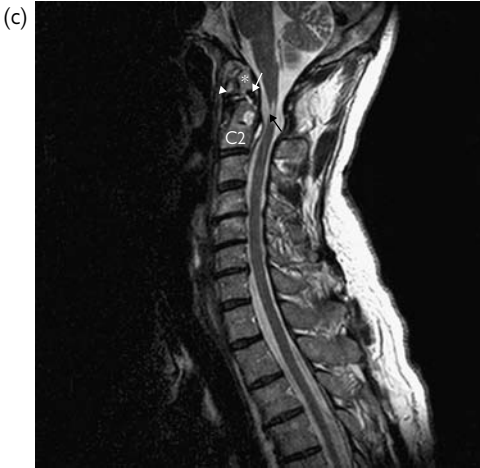

Fig. 5.36 (c) sagittal T2W MRI. Further evaluation with MRI confirms a fracture through C2 with possible interposition of soft tissue between the fractured fragments ((c) *white arrow*). Intramedullary signal change and spinal cord volume loss ((c) *black arrow*) is in keeping with myelomalacia and longstanding instability and intermittent spinal cord compression. Note the anterior arch of C1 ((c) *white arrowhead*) and the fracture fragment of C2 ((c) *white asterisk*).

Degenerative spinal conditions: cervical spine

Cervical degenerative disease is common but care needs to be taken to distinguish pathological conditions from changes due to ageing.

- > 95% individuals > 65 years will have MRI scan abnormalities.

Cervical spondylosis

Non-specific degenerative process resulting in stenosis of the spinal canal and/or root canals. Factors include:

- degenerate disc;
- osteophytes;
- hypertrophy of lamina, articular facets, ligamentum flavum, and posterior longitudinal ligament;
- congenitally narrow canal.

Most common levels affected are C5/C6 and C6/C7.

Mechanical/musculoskeletal neck pain

No root symptoms or signs. Management involves:

- lifestyle and posture changes (occupational therapy);
- anti-inflammatory drugs;
- physiotherapy;
- judicious use of a collar;
- facet joint or epidural injection of LA/steroids;
- surgery rarely indicated.

Radiculopathy

Clinical features

- Referred pain in the arm due to root irritation (brachalgia).
- Initial symptom may be sensory (tingling, burning) in a dermatomal distribution followed by radicular pain (which is in a myotomal pattern).
- Weakness.
- Reflex abnormalities.
- See Table 5.4.

Table 5.4 Clinical presentation of cervical radiculopathies

Nerve root (disc level)	Pain	Motor weakness	↓ Reflexes	Sensory disturbance
C5 (C4/C5)	Neck to shoulder and upper arm	Deltoid, supra + infraspinatus	Supinator	Shoulder, lateral arm
C6(C5/C6)	Lateral forearm, thumb, & index finger	Biceps and brachioradialis	Biceps	Lateral forearm, thumb, & index finger
C7(C6/C7)	Posterior arm, dorsum, forearm, middle finger	Triceps, wrist & finger extensors	Triceps	Posterior forearm, middle finger
C8(C7/T1)	Shoulder medial forearm, ring & little fingers	Thumb flexor, intrinsic hand muscles		Medial hand, ring & little fingers

Red flags

- Fever, chills.
- Weight loss.
- Relentless nocturnal pain.
- History of cancer.
- Immunosuppression.

Consider infection or tumour.

Imaging studies

- Plain X-rays have limited usefulness.
- Flexion and extension views may be useful to detect spinal instability.
- MRI is the primary imaging modality.
- CT ± intrathecal myelography is used in those in whom MRI is contraindicated or where there is extensive metalwork. It may also assess the extent of bony spurs and foraminal encroachment.

Non-surgical management

Most patients with acute radiculopathy due to disc herniation improve with conservative measures.

- NSAIDS
- Hard or soft collar continuously or only at night for 2 weeks
- Translaminar or transforaminal epidural injections of steroids may be considered. Rare complications include spinal cord infarction. Adequate placebo controlled trial data is not available.

Surgical management

Surgery indicated for decompression of cervical root :

- profound weakness;
- uncontrollable pain;
- failure of conservative measures for pain after 6–12 weeks.

An anterior approach is indicated when pathology extends in front of the root and cord as with a central disc. Procedures include:

- simple discectomy;
- Cloward's procedure, which involves bone grafting into the disc space;
- decompression with plating or synthetic joint insertion.

A posterior approach is used when there is lateral canal narrowing. Procedures include foraminotomy, laminectomy, ± laminoplasty.

- Complications uncommon but include: spinal cord injury (< 1%); nerve root injury (2–3%); oesophageal perforation (< 1%); recurrent laryngeal nerve palsy (after anterior approach), 2%.

Cervical spondylotic myelopathy

This is the most common cause of myelopathy in those > 55 years and is due to disc degeneration and osteophytes.

Clinical features

Due to a combination of myelopathy and radiculopathy to varying degrees:

- numb clumsy hands;
- paraesthesiae hands and feet;
- spasticity of the legs;
- bladder symptoms occur late;
- acute cord syndrome with tetraparesis after a fall in a patient with an already compromised cord, e.g. congenitally narrowed canal.

Differential diagnosis

- MND.
- MS.
- Subacute combined degeneration of the cord due to B₁₂ deficiency.

Natural history

Not well defined—disability established early in the disease. > 60 years at presentation associated with poor prognosis. Long periods of non-progression may occur.

Imaging

- MRI is modality of choice.
 - Low signal change on T1 may represent poor prognosis.
 - Significance of T2 signal change uncertain.
 - In general, cord changes may be an indication for early surgery.
- Plain X-rays show degenerative change with loss of disc height and osteophytes. However, these are common findings.

Management

Surgical decompression indicated if:

- progressive myelopathy;
- stable myelopathy but as prophylaxis against further deterioration.

Surgery involves enlarging the canal anteriorly with discectomy and/or vertebrectomy at single or multiple levels.

- Posterior decompression involves laminectomy or laminoplasty.
- In general, the outcome is unpredictable. Improvement may occur and is dependent upon the severity and duration of symptoms pre-operatively.
- If post-operative deterioration occurs, repeat MRI is indicated to assess degree of adequate decompression.

Degenerative spinal conditions: thoracic and lumbar spine

Thoracic disc prolapse

Symptomatic disc prolapses are rare, < 1% of all protruded discs. Most common level T11/T12.

Clinical features

- Pain localized to the spine or radicular. Nocturnal recumbent pain typical.
- Sensory symptoms and signs with a sensory level.
- Spastic paraparesis or rarely a monoparesis.
- Sphincter disturbance.
- Rarely, a Brown–Sequard syndrome.

Imaging

MRI for location, severity of cord compression, and associated myelomalacia.

Management

- Radicular pain managed with analgesics and or local nerve root block. Surgery if intractable.
- Progressive or significant myelopathy or sphincter dysfunction an indication for surgery. If disc is heavily calcified or located midline anterior, transthoracic approach is used. Posterior approach used for lateral and soft anterolateral discs—usually a fusion procedure carried out to ensure spinal stability.

Lumbar intervertebral disc prolapse

- Acute back pain is common but accompanied by sciatica in only 2%.
- L5/S1 disc and L4/5 disc prolapses account for > 95%.

Clinical features

- Acute or gradual onset pain in the back radiating through buttock, thigh, leg to foot. L2 radiculopathy (unusual) causes anterior thigh pain. Triggered by lifting, flexion, or rotation. Dull ache with shooting exacerbations. ↑ with coughing, sneezing, bending, or prolonged sitting.
- Weakness of ankle dorsiflexion and EHL (L5); plantar flexion (S1); knee extension (L3, L4).
- Depressed or absent knee jerk (L3, L4); ankle jerk (S1).
- Straight leg raising (Lasegue's sign) causes dermatomal pain.
- Positive femoral stretch test (hip extension with maximal knee flexion) indicates L2, L3, or L4 root pathology. Other causes: psoas abscess or haematoma.
- Cauda equina syndrome (neurosurgical emergency):
 - bilateral leg pain or sensory disturbance;
 - perianal, perineal, and saddle anaesthesia;
 - urinary and/or faecal incontinence;
 - low back pain;
 - sexual dysfunction;
 - bilateral motor and reflex deficits.

Imaging

- MRI is investigation of choice.
- CT or CT myelogram useful alternatives.
- Most commonly a posterolateral prolapse will compress root just proximal to exit foramen, e.g. L4/L5 disc compresses L5 root. However, the L4 root will be affected by upwardly migrated L4/L5 disc fragment or a far lateral disc protrusion.

Management

Acute back pain and 85% of sciatica resolve in 6–8 weeks with conservative treatment. Note: exclude infection and tumour first.

- Initial bed rest, early mobilization.
- Avoid bending, lifting, prolonged sitting.
- Adequate analgesia.
- Muscle relaxants, e.g. diazepam 2–5 mg.
- Consider epidural or nerve root block.

Indications for surgery

- Cauda equina syndrome.
 - Significant or progressive motor deficit.
 - Severe pain not responding to conservative measures.
- Surgery involves microdiscectomy. Recurrent disc herniation rate is 2%. Recurrence of symptoms may also be due to scarring around nerve root. MRI with Gd shows root enhancement.

Lumbar canal stenosis

Narrowing of the spinal canal in the central, lateral recesses or intervertebral foraminae causing root compression. Most common: L4/5 and L3/L4.

Clinical features

- ‘Neurogenic claudication’: buttock and leg pain or motor deficit on walking, standing, or lying supine. Alleviated by bending forwards or crouching. Exercise tolerance improved by cycling or pushing a trolley.
- Usually bilateral but may affect only one leg.
- Leg numbness or paraesthesiae.
- Occasionally sphincter dysfunction or impotence.
- Neurological examination may be normal.

Imaging

- MRI investigation of choice: bilateral facet hypertrophy. Lateral recess stenosis results in a trefoil deformity on axial scans.
- CT or CT myelography useful if MRI contraindicated or not available.
- Lateral flexion/extension views indicated to exclude spinal instability as fusion may be necessary at decompression.

Management

Mild symptoms: conservative management.

- Rest.
- Adequate analgesia.
- Lumbar corset.
- Physiotherapy for posture and trunk strengthening.
- Epidural steroid/LA injections reported to result in long-term benefit.

Surgery indicated if:

- failure of conservative measures;
- pain;
- significant motor deficit;
- sphincter disturbance.

Decompressive surgery consists of variations on lumbar laminectomies.

- If spondylolisthesis (AP slip of one vertebra on another) or instability, fusion procedures performed.
- Complications: dural tear and CSF leakage.

This page intentionally left blank

Imaging of degenerative spinal conditions: examples

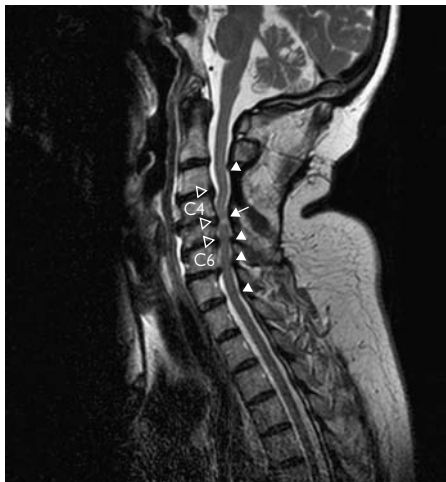

Fig. 5.37 Cervical spondylosis (sagittal T2W MRI). Multilevel degenerative changes extending from C3/4 to C6/7 with disc osteophyte bars (*open white arrowheads*), which indent the anterior surface of the theca and, together with focal thickening/buckling of the posterior ligamentous structures (*closed white arrowheads*), result in substantial narrowing of the cervical vertebral canal maximally at C4/5. Resultant compression of the spinal cord at this level and intramedullary signal abnormality (*white arrow*). In this case, vertebral alignment is preserved.

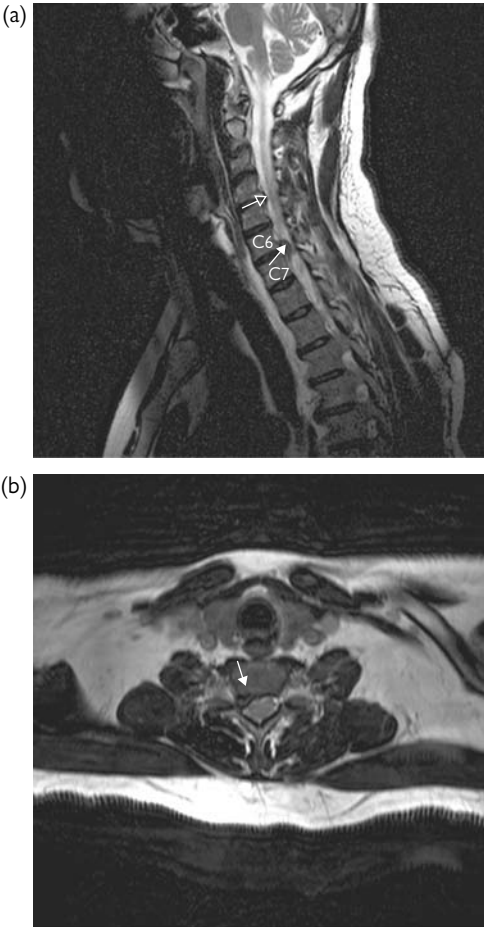


Fig. 5.38 Cervical spondylosis and acute cervical disc prolapse. (a) Sagittal T2W and (b) axial gradient echo T2W MRI. While disc osteophyte bars are present, in particular at C4/5 (*open white arrow*), there is a predominantly soft (acute) right-sided disc protrusion ((a) and (b) *closed white arrow*) resulting in marked narrowing of the right C6/7 intervertebral foramen and likely compromise of the right C7 nerve. There is only mild distortion of the spinal cord at this level.

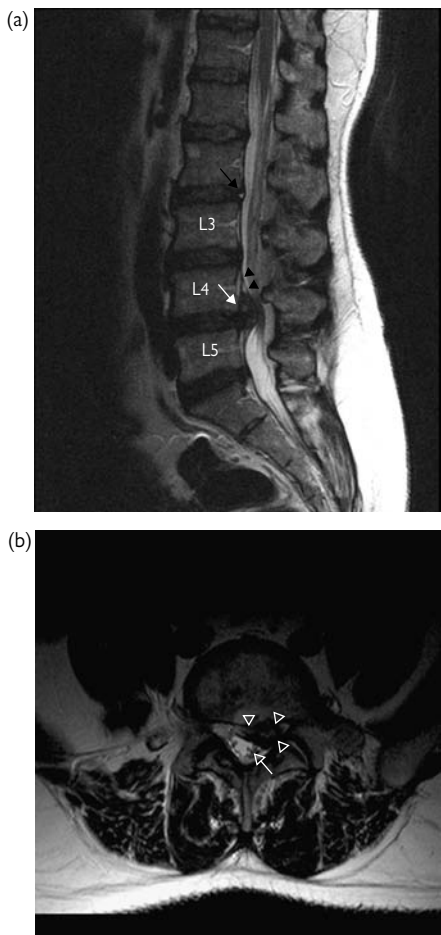


Fig. 5.39 Lumbar disc protrusion. (a) Sagittal T2W and (b) axial T2W MRI. A large cranially migrating left paracentral disc protrusion ((a) closed white arrow; (b) open white arrowheads) is shown at the L4/5 level. Although the left lateral aspect of the theca is effaced and the forming left L5 nerve is compromised as it exits the theca, the intrathecal nerves in the cauda equina (white arrow) are not compressed. The migrating discal component is extradural, elevating and posteriorly displacing the dura ((a) black arrowheads). Note the small annular fissure in the L2/3 intervertebral disc ((a) black arrow).

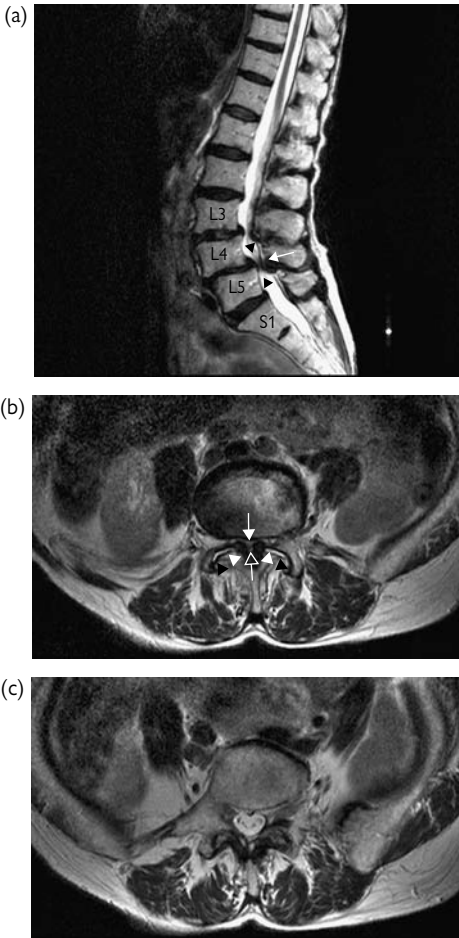


Fig. 5.40 Focal lumbar vertebral canal stenosis. (a) Sagittal T2W; (b) and (c) axial T2W MRI. There is mild anterior subluxation of L4 upon L5 (Grade 1 spondylolisthesis). In conjunction with marked facet joint degeneration and thickening of the posterior ligamentous structures ((a) white arrow; (b) white arrowheads), there is marked narrowing of the vertebral canal at this level ((a) black arrowheads) with effacement of CSF and compression of the cauda equina ((b) closed white arrow) compared to the normal appearance of the theca (c). The small area of hyperintensity posterior to the theca ((b) open white arrow) represents epidural fat rather than residual CSF.

Developmental abnormalities

Arachnoid cysts

Congenital CSF-containing cysts developing between arachnoid layers. 50% in the middle cranial fossa, 10% suprasellar, 10% cerebellopontine angle. Less common sites include quadrigeminal cistern, hemispheric convexity, and the posterior fossa.

Clinical features

- Majority present in childhood:
 - middle cranial fossa: seizures, headache, hemiparesis;
 - suprasellar cysts: hydrocephalus, enlarged skull, developmental delay, visual failure, and precocious puberty.
- In adults, incidental finding.

Imaging features

Sharply demarcated cysts, which may have mass effect. May communicate with the subarachnoid space. Walls are indefinable.

- CT: CSF density with no enhancement. Typically, remodelling and scalloping of adjacent walls is evident. Haemorrhage (rare).
- MRI: CSF signal intensity on all images. Null signal on FLAIR. DWI images show free diffusion in contrast to epidermoid cysts, which show restricted diffusion with ↑ signal. Other differential diagnoses: cystic extra-axial tumour (usually has a wall, a solid component with enhancement); cysticercosis; mega cisterna magna in the posterior fossa.

Management

- If asymptomatic, no treatment.
- Symptomatic cysts drained either via a marsupialization into CSF spaces (via a craniotomy or endoscopy) or via a shunt to the peritoneum.

Chiari malformation

Syndromes of hindbrain descent. four subtypes are probably unrelated. Types 1 and 2 predominate.

Chiari 1 malformation (cerebellar ectopia)

Anatomy

Simple descent of cerebellar tonsils beyond the foramen magnum. Elongated peg-shaped tonsils plug the foramen. Occasionally acquired after LP. Cerebellar descent and arachnoid adhesions interfere with normal transmission of CSF pressure waves across the FM to the spinal reservoir raising ICP and forcing fluid into the central canal of the spinal cord.

Clinical features

Usually presents in young adults.

- Suboccipital headache. ↑ stooping, straining, coughing.
- Brainstem compression with ataxia, lower cranial palsies, pyramidal weakness.
- Central cord syndrome due to the associated syringomyelia with dissociated sensory loss in a cape distribution. ↓ beating nystagmus.

Management

Foramen magnum decompression by removal of 3 × 4 cm crescent of bone from the posterior rim of FM. Restores CSF pathway and decompresses syrinx. Complications: aseptic meningitis, CSF leak, hydrocephalus.

Chiari 2 malformation

Anatomy

Congenital hindbrain abnormality associated with spinal dysraphism (myelomeningocele, spina bifida). Descent of cerebellar tonsils, vermis, medulla, IVth ventricle through FM. Associated with hydrocephalus and elongated upper cervical nerves.

Clinical features

Present in infancy with:

- hydrocephalus;
- respiratory distress;
- dysphagia and aspiration pneumonia;
- downbeat nystagmus;
- quadraparesis.

High mortality from respiratory arrest.

Imaging features

MRI: S-bend medulla, tonsillar descent, large interthalamic connexus, dysgenesis of corpus callosum, hydrocephalus, medullary compression, syringomyelia.

Management

- Insertion of ventriculo-peritoneal (VP) shunt for hydrocephalus.
- Posterior fossa decompression.

Dandy-Walker malformation

- Agenesis of the vermis of the cerebellum, resulting in a large posterior cerebellar cyst opening into the IVth ventricle.
- Hydrocephalus is common.
- Associated with agenesis of the corpus callosum, occipital encephalocele, spina bifida, syringomyelia.
- Facial, ocular, and cardiovascular abnormalities.

Management Insertion of a cyst-peritoneal shunt and/or ventriculo-peritoneal shunt.

Aqueduct stenosis

Congenital aqueduct stenosis presents in childhood with hydrocephalus in the first 3 months of life. Adult forms usually acquired due to inflammation, infection, brainstem tumour, arachnoid cysts.

Clinical features

- Symptoms and signs of ↑ ICP.
- Cognitive impairment.
- Visual field deficit.
- Ataxia.
- Incontinence.

Management

- Insertion of a VP shunt.
- Endoscopic 3rd ventriculostomy (by creation of a hole in the floor of the 3rd ventricle allowing CSF to reach the basal cisterns bypassing the aqueduct and 4th ventricles).

Spinal dysraphism (spina bifida)

Developmental defects of neural tube closure with a variety of abnormalities:

- Spina bifida occulta. Often clinically insignificant finding of hypoplastic posterior sacral elements with normal dural sac and skin cover. May have skin stigmata: hairy patch, naevus. Associated with intradural lipomas, thickened filum terminale, diastematomyelia (split cord), and dermoid cysts. Cause of tethered cord syndrome:
 - neurogenic bladder;
 - paraparesis;
 - foot deformity.
- Meningocele. Developmental absence of sacral and low lumbar posterior elements with bulging meninges exposed at skin surface. Neurological deficit in 30%.
- Myelomeningocele. Congenital absence of posterior vertebral elements, dura and maldevelopment of the terminal spinal cord. All have a neurological deficit with, hydrocephalus in 80%. Associated with Chiari 2 malformation.

Management

Myelomeningocele requires early closure to ↓ infection rate and protect neural tissue from damage. Hydrocephalus may be apparent after closure and treated with a VP shunt. With surgery 85% survive infancy, most with normal IQ.

This page intentionally left blank

Imaging of developmental abnormalities: examples

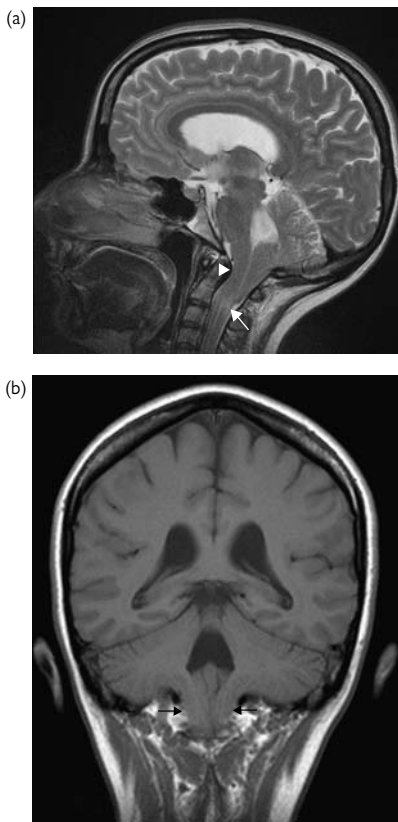


Fig. 5.41 Chiari 1 hindbrain deformation. (a) Sagittal T2W and (b) coronal T1W MRI. There is marked descent of the cerebellar tonsils below the foramen magnum ((b) *black arrows*) to the inferior aspect of C2. The pointed configuration of the tonsillar tips is typical. Note the crowding at the foramen magnum with anterior displacement and kinking of the cervicomedullary junction (*white arrowhead*). Some compression and impingement of the upper cervical spinal cord is also demonstrated with intramedullary signal change at the lower border of C2 (*white arrow*). No definite syrinx or hydrocephalus is shown. The occipito-atlanto-axial osseous configuration is normal in this case.

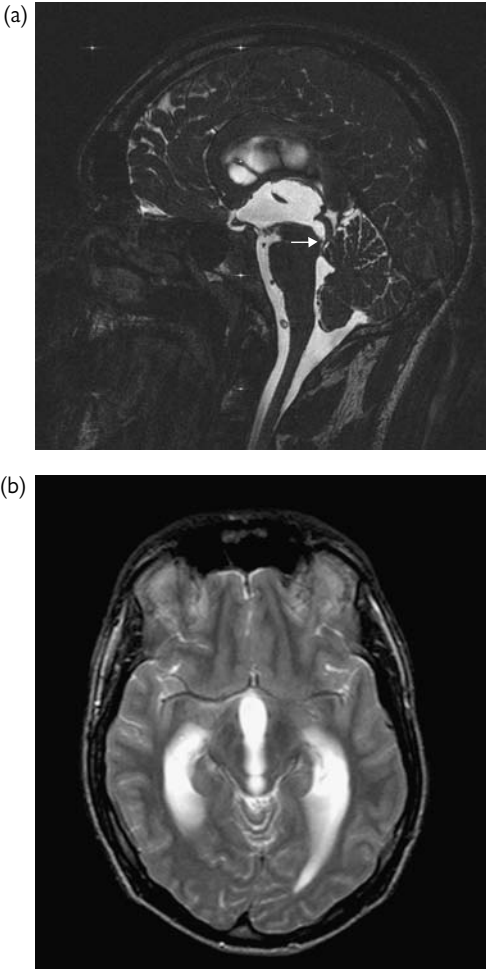


Fig. 5.42 Aqueduct stenosis. (a) Thin section T2W sagittal and (b) axial T2W MRI. Typical beaking/tapering of the inferior aspect of the lumen of the aqueduct of Sylvius ((a) white arrow) resulting in obstruction to CSF flow and proximal hydrocephalus reflected by dilatation of the superior portion of the aqueduct and of the third and lateral ventricles (b).

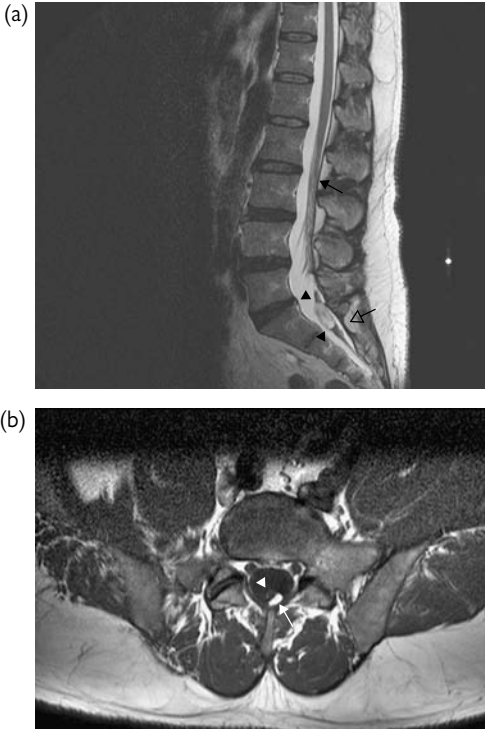


Fig. 5.43 Spinal dysraphism. (a) Sagittal T2W and (b) axial T1W MRI. The termination of the spinal cord is low lying at the upper border of L3 (black arrow) and an intradural ovoid mass at S1 ((a) black arrowheads; (b) white arrowhead) contains fatty elements ((b) white arrow) representing an intradural dermoid inclusion body. Note deficiency of the posterior elements of the second sacral segment ((a) open black arrow).

This page intentionally left blank

Syringomyelia

Caused by cavitations within the spinal cord with clinical deficits. May coexist with a similar condition, syringobulbia. Due to abnormal CSF circulation resulting from anatomical abnormalities.

Causes

- Cerebellar ectopia (Chiari malformations).
- Intramedullary tumours.
- Trauma.

Clinical presentation

Usually early to mid adult life with:

- cough and positional headache due to pathology at FM;
- lower motor neuron weakness in the hands and arms, e.g. wasted hand + paraparesis of the legs;
- dissociated sensory loss (cape distribution) affecting spinothalamic sensation but sparing posterior columns.

Imaging features

Cranial and spinal MRI + Gd. Assessment of the craniocervical junction; presence of any cord tumours. See Fig 5.44.

Management

The natural history is unclear. Medical treatment based on physiotherapy, occupational therapy, and pain management.

Surgery

- Decompression of the FM. May arrest and sometimes reverse progression of syringomyelia.
- Syrinx cavity operations consist of a drainage procedure usually in cases of progressive neurological deficits:
 - syringo-arachnoid shunt;
 - syringo-pleural shunt.

Revision procedures often required.

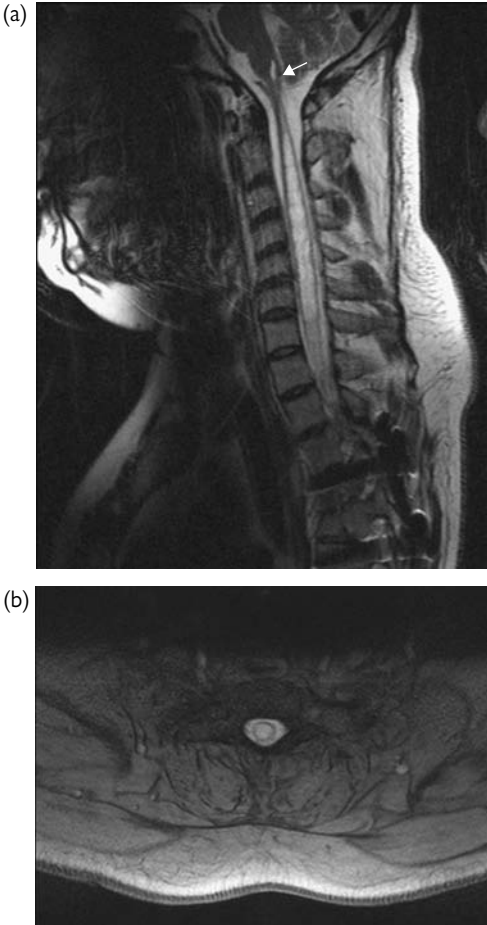


Fig. 5.44 Syringomyelia. (a) Sagittal T2W and (b) axial T2W MRI. A multiseptated centrally located intramedullary long segment lesion of CSF signal intensity on both T2W and T1W imaging expands the spinal cord and extends into the inferior brainstem as syringobulbia ((a) white arrow).

This page intentionally left blank

Clinical neurophysiology

- Introduction 426
- Electroencephalography (EEG): introduction 428
- EEG: use and abuse 430
- EEG: abnormal rhythms 432
- EEG and epilepsy 436
- EEG and diffuse cerebral dysfunction 440
- EEG in the intensive care unit 444
- Technical summary of nerve conduction studies (NCS) 446
- Peripheral nerve disorders: NCS abnormalities 450
- Technical summary of needle electromyography (EMG) 452
- Needle EMG: patterns of abnormality 454
- NCS and needle EMG findings in myopathies and motor axonal loss 460
- NCS and needle EMG findings in Guillain–Barré syndrome 462
- NCS and needle EMG findings in neuromuscular transmission disorders 464
- Visual evoked responses (VERs) 468
- Somatosensory evoked potentials (SSEPs) 470
- Brainstem auditory evoked responses (BAERs) 474
- Normal values in clinical neurophysiology 476

Introduction

Neurophysiological investigations include the following.

- Electroencephalography (EEG).
 - Used in diagnosis and management of epilepsy.
 - Combined with video recordings to establish diagnosis of epilepsy.
 - Assessment of epilepsy before epilepsy surgery.
 - Diagnosis of infective and metabolic brain disorders, e.g. CJD, herpes simplex encephalitis, hepatic encephalopathy.
- Nerve conduction studies (NCS) and needle electromyography (EMG):
 - Study of sensory and motor peripheral nerve disorders, e.g. neuropathies, radiculopathies, dorsal root ganglionopathies, and anterior horn cell disorders.
 - Neuromuscular junction disorders.
 - Skeletal muscle disorders.
 - Cranial nerve disorders, e.g. facial nerve, trigeminal nerve.
- Evoked potentials (EPs).
 - Study sensory and motor pathways in the peripheral and central nervous systems.
 - Useful in investigation of multiple sclerosis, other spinal cord and brainstem disorders, and cranial neuropathies.
 - Monitoring of spinal cord function during surgery for scoliosis and of the facial nerve during acoustic neuroma surgery.

The neurophysiological evaluation helps the neurologist by:

- confirming the clinical diagnosis;
- defining type of dysfunction, e.g. axonal versus demyelinating neuropathy;
- excluding certain disorders in differential diagnosis;
- detecting subclinical disease, e.g. optic nerve demyelination or vasculitic peripheral neuropathy;
- defining severity of disease and indicating prognosis, e.g. extent of axonal degeneration in Guillain–Barré syndrome;
- monitoring change in disease over time;
- identifying muscles most suitable for injection with botulinum toxin in treating focal dystonias.

This page intentionally left blank

Electroencephalography (EEG): introduction

Conventional EEGs are non-invasive recordings of spontaneous brain electrical activity, obtained using scalp electrodes that record fast changing events. EEG waveforms represent spatiotemporal averages of synchronous excitatory and inhibitory potentials generated by interconnecting cortical neurons.

EEG electrode placement Most widely used is the standardized 'International 10/20 system', which uses four anatomical landmarks: nasion, inion, and pre-auricular points. Disc electrodes are placed on the scalp and held by an adhesive.

EEG display Recordings are displayed in various combinations of channels called 'montages'.

EEG activity The frequency of EEG activity is denoted by delta (0–3/second), theta (4–8/second), alpha (8–12/second) and beta (>12/second) frequencies. The normal waking EEG (Fig. 6.1) usually has prominent posterior bilateral alpha activity that is enhanced on eye closure.

EEG recording

The routine EEG is made as follows:

- 21 scalp electrodes are placed, usually according to the International 10/20 system of electrode placement.
- Simultaneous ECG recording.
- An eye movement channel monitors state of alertness.

EEG recordings are susceptible to artefacts such as movement or electrical sources, e.g. sudden change in impedance. They are technically difficult in children, uncooperative patients, and in ICU.

Routine EEGs are usually initially recorded in the waking state. The recording room is quiet and dimly lit to allow the patient to become drowsy. Activation procedures may enhance abnormalities:

- Hyperventilation: vigorous overbreathing for 3 minutes, followed by recording for 1 minute. Especially useful in childhood absence epilepsy as lack of epileptiform abnormality virtually excludes the diagnosis.
- Photoc stimulation: delivered by a strobe light 30 cm from the patient's central vision. Flash frequencies between 1 and 60/second, including during eye closure. Photosensitivity manifested by generalized self-sustaining epileptiform abnormalities.
- Sleep deprivation: usually requires sleep deprivation for 24 hours, which increases liability to epileptiform abnormalities.
- Sedated sleep: induced by medication.

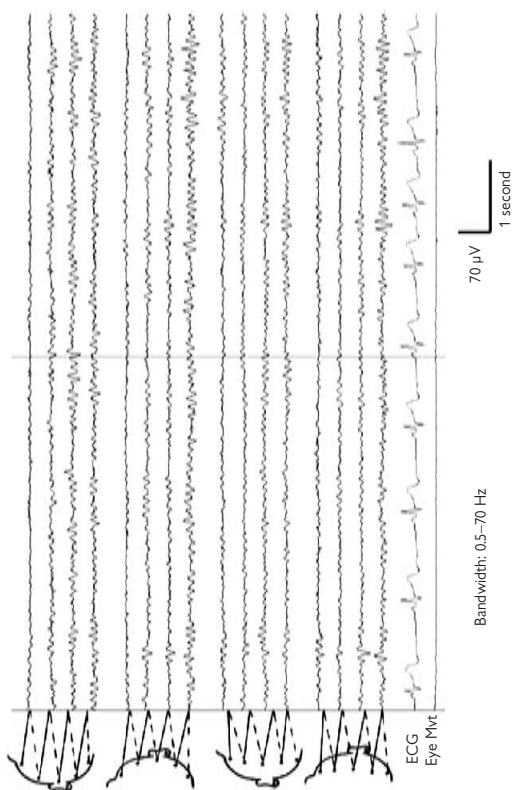


Fig. 6.1 Normal waking adult EEG, longitudinal bipolar montage. ECG = electrocardiogram; Eye Mvt = eye movement channel

Long-term EEG monitoring

Simultaneous video-EEG monitoring records behaviour during attacks.

- Helps to distinguish epileptic seizures from non-epileptic attacks.
 - Useful in pre-operative evaluation to help identify epileptic focus.
- May involve:
- additional anterior temporal, sphenoidal, or foramen ovale electrodes;
 - more invasive EEG recordings using subdural strip or intracerebral depth electrodes;
 - stimulation of subdural electrodes in waking state used to map eloquent areas prior to resection;
 - ambulatory 8- or 16 channel recordings allowing the patient to perform daily activities to help in quantifying seizure burden.

EEG: use and abuse

EEG abnormalities that indicate definite pathology are:

- seizure discharges;
- generalized or focal slowing;
- absence of normal background rhythms;
- periodic phenomena.

EEG is useful in the investigation of:

- epilepsy: epileptiform abnormality on EEG is specific, but not sensitive, for the diagnosis of epilepsy as a cause of any paroxysmal event or transient loss of consciousness. In epileptic patients sensitivity is 25–55% and specificity is 80–98%;
- impaired consciousness/coma;
- toxic confusional states;
- diffuse degenerative disorders, e.g. CJD, Alzheimer's disease;
- metabolic encephalopathies, e.g. hepatic failure, uraemia;
- cerebral trauma;
- parasomnias.

EEG has no role in the investigation of:

- multiple sclerosis;
- headache;
- mental retardation;
- psychoses.

This page intentionally left blank

EEG: abnormal rhythms

Cortical rhythms are generated locally in the cerebral cortex but are modulated at both thalamic and reticular activating system (brainstem) levels.

Periodic phenomena

Periodicity refers to repetitive discharges reflecting diffuse dysfunction of grey and white matter

- Periodic lateralized epileptiform discharges (PLEDS; see Fig. 6.2 (a)):
 - confirm local pathology but are not specific. May be seen in haematomas, metastases, infarcts, or infections.
 - may be associated with subtle and transient focal clinical events.
 - resolve after 1 or 2 weeks, even when underlying lesion is progressive.
 - See 'Viral encephalitis' p.292.
- Generalized periodic discharges occur in:
 - subacute sclerosing panencephalitis (SSPE): simultaneous bilateral complexes of slow and fast components, repeating at 10–20 second intervals;
 - Creutzfeldt–Jakob disease (CJD; Fig. 6.2(b)): discharges at 1–2 second intervals; may be confused with ECG pickup on scalp, and simultaneous ECG channel is important.
 - In both conditions: progressive loss of cortical rhythms until repetitive complexes occur on a silent background.

Pathological slow waves

- Slowing of underlying posterior dominant activity: occurs in hypoxia, hypoglycaemia, cerebrovascular disease, dementia, and metabolic encephalopathies.
- Focal theta/delta slowing aids localization of cerebral dysfunction; focal delta waves are hallmark of electrically silent mass lesions such as tumours, infarctions, and abscesses (Fig 6.2(c)).
- Seizure activity: see 'EEG and epilepsy', this chapter.

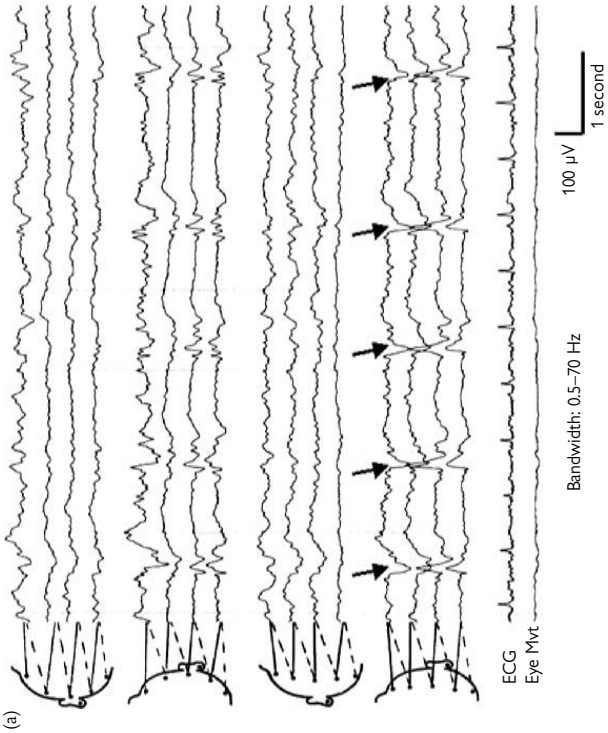


Fig. 6.2 (a) Right-sided periodic lateralized epileptiform discharges (PLEDs), indicated by arrows, in an elderly drowsy patient 2 days following right-sided cerebral infarction. ECG = electrocardiogram; Eye Mvt = eye movement channel.

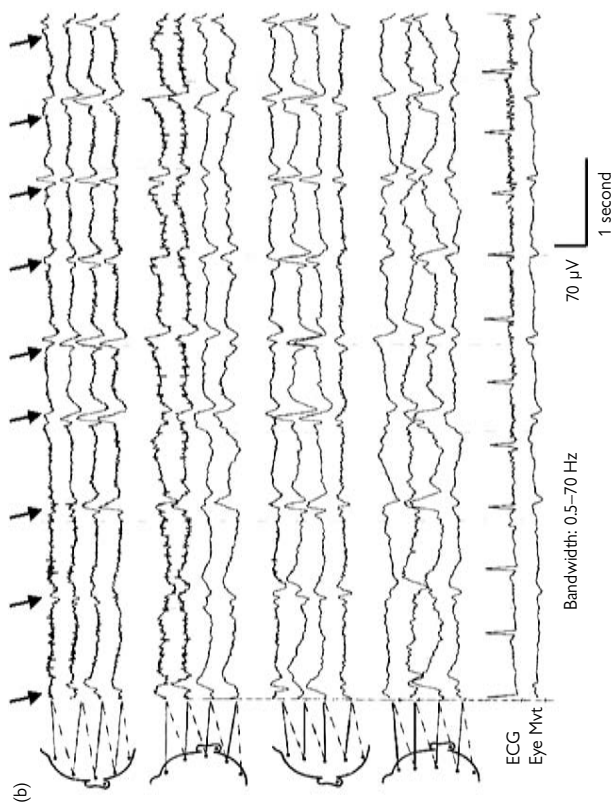


Fig. 6.2 (b) Generalized periodic sharp wave complexes, indicated by arrows, in an adult patient with Creutzfeldt–Jakob Disease (CJD). ECG = electrocardiogram; Eye Mvt = eye movement channel.

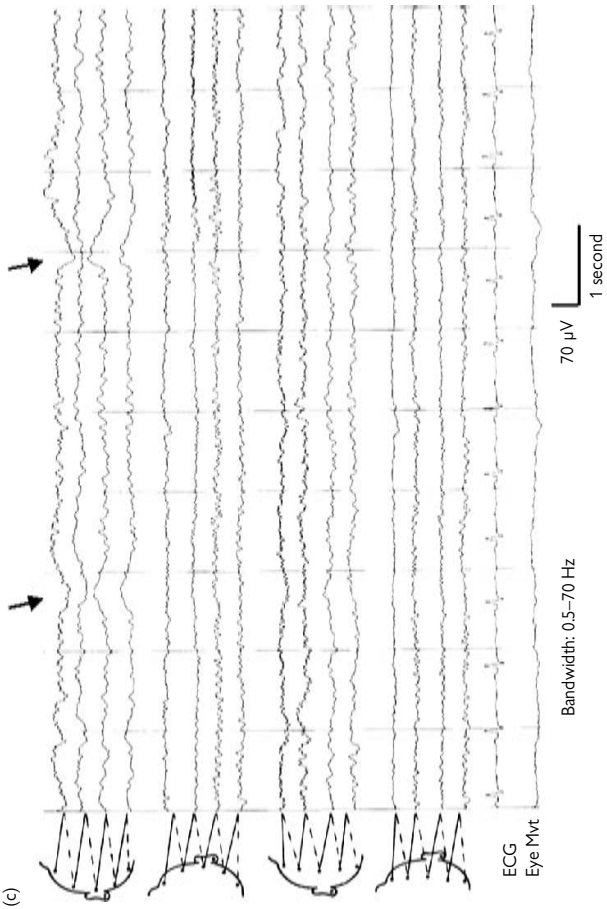


Fig. 6.2 (c) Left temporal focal delta rhythms, indicated by arrows, in a waking adult patient who had had a left-sided subarachnoid haemorrhage 2 years previously. ECG = electrocardiogram; Eye Mvt = eye movement channel.

EEG and epilepsy

Epileptiform activity

The hallmarks are:

- spikes with 20–70 ms duration;
- sharp waves, with 70–200 ms duration;
- spike and wave activity;
- electrographic seizures.

However, similar patterns can occur in the normal EEG but are recognized by the characteristic waveforms, topography, and circumstances of occurrence. For example:

- rhythmic bursts of 6 and 14 per second positive spikes occur in adolescents and young adults during drowsiness and light sleep;
- benign epileptiform transients of sleep (BETS);
- rhythmic midtemporal discharges (psychomotor variant);
- bifrontal slow wave activity elicited in children by hyperventilation;
- rare 6 per second bilateral spike-and-slow wave discharges in anterior regions of waking males or in the occipital region of drowsy females.

Diagnostic strategy in epilepsy

- Misinterpretation of non-epileptiform features is an important cause of false positive EEG reports. Prevalence of rigorously defined epileptiform discharges is 0.5–2% in normal adults.
- A normal EEG does not exclude a diagnosis of epilepsy.
- 33% of epileptic patients exhibit interictal epileptiform discharges in waking EEGs (Fig. 6.3(a)); 16% never do. Probability of interictal epileptiform abnormality in a patient with epilepsy in a 30-minute waking recording is 1 in 3.
- Repeated waking EEGs can increase detection rate of interictal epileptiform abnormality in patients with epilepsy.
- Sleep EEG, particularly following sleep deprivation (Fig. 6.3(b)), increases yield to 80%; drowsiness and sleep increase probability of focal interictal epileptiform abnormalities.
- If interictal EEG is persistently normal consider long-term video-EEG monitoring.
- Note. No relationship between presence or absence of interictal epileptiform abnormality on EEG and seizure frequency or response to medication.

EEG and seizure classification

- EEG findings support distinction between focal and generalized seizures. This will guide therapy. Identification of focal elements at onset of seizures is important, as focal events can rapidly propagate to secondarily generalized discharges.
- Focal asymmetry, slowing, or generalized abnormalities may assist in differentiation.
- Photosensitivity occurs in 5% of epileptic patients, especially in juvenile myoclonic epilepsy. See Fig. 6.3(c).

EEG and discontinuation of treatment In children EEG can be a useful guide as persistent epileptiform abnormality indicates high risk of relapse if treatment discontinued.

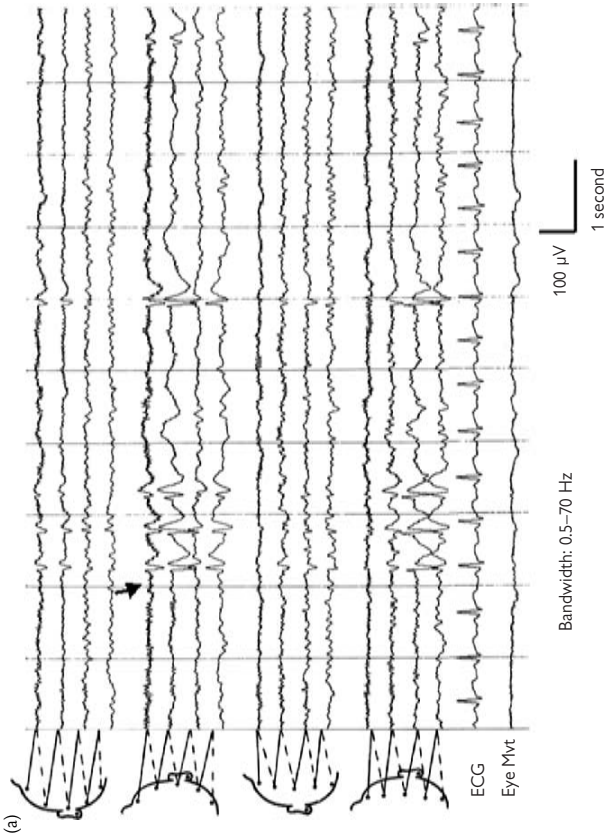


Fig. 6.3 (a) A burst of focal subclinical epileptic activity, indicated by arrow, in the right centrotemporal region of a waking adult patient. ECG = electrocardiogram; Eye Mvt = eye movement channel.

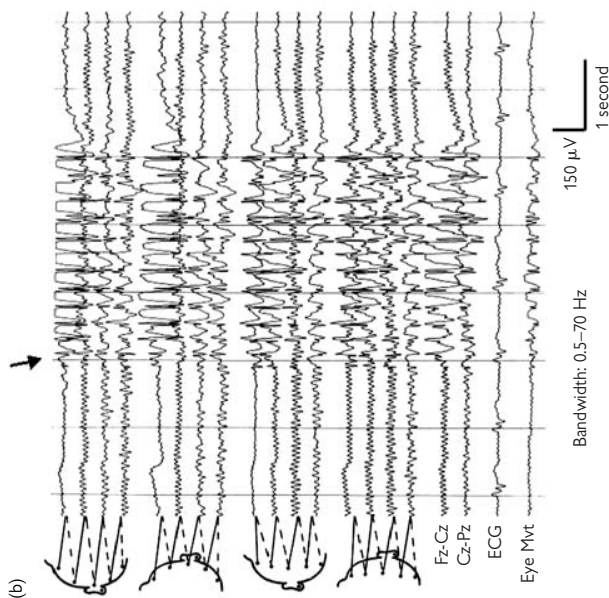


Fig. 6.3 (b) A burst of generalized subclinical spike/polyspike and slow wave activity, indicated by arrow, in a waking adult patient following sleep deprivation. A previous waking EEG had been normal. The patient had one generalized seizure. ECG = electrocardiogram; Eye Mvt = eye movement channel.

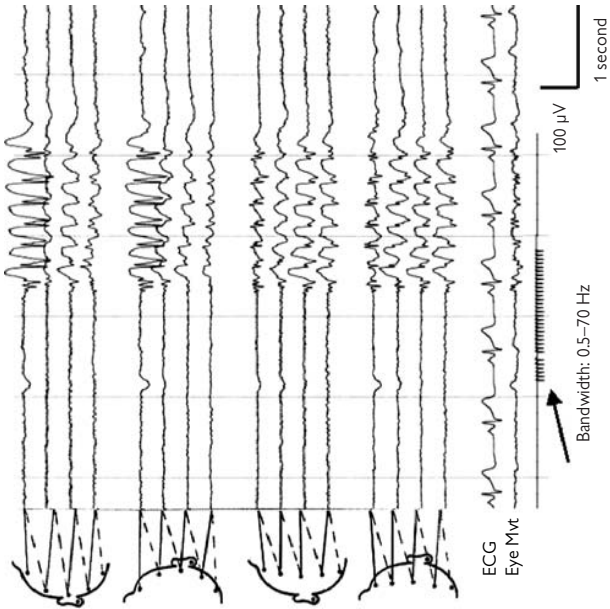


Fig. 6.3 (c) A burst of generalized subclinical spike/polyspike and slow wave activity in a waking adult patient elicited by photic stimulation. The arrow indicates the photic stimulation markers. ECG = electrocardiogram; Eye Mvt = eye movement channel.

EEG and diffuse cerebral dysfunction

EEGs can be helpful in patients with altered mental status, ranging from mild memory difficulties to coma. It is however non-specific as to aetiology. Useful in the following clinical situations:

- Detection of seizure activity in a comatose patient.
- Suggesting aetiology in undiagnosed coma:
 - may reveal focal abnormalities in setting of intracerebral space-occupying lesions;
 - periodic lateralized epileptiform discharges (PLEDS) over the temporal region can suggest herpes simplex encephalitis.
- Diagnosing diffuse degenerative conditions, e.g. CJD, SSPE.
- Help in identification of psychogenic coma or the locked-in syndrome.
- Prognostic guide after anoxic brain injury.
- Evaluation of brain death.

EEG patterns in diffuse cerebral dysfunction

Generalized slowing (Fig. 6.4)

- Can suggest toxic or metabolic encephalopathy.
- Sensory activation using visual, auditory, tactile, or painful stimuli important, as reactive EEG activity implies a better prognosis.

Periodic spiking occurs in post-anoxic encephalopathy and is associated with a poor prognosis.

Alpha coma Non-reactive 8–12/second activity associated with a poor prognosis.




Fig. 6.4 Diffuse symmetrical theta and delta slowing in a waking adult with Lewy body dementia. ECG = electrocardiogram; Eye Mvt = eye movement channel.

Burst suppression

- Bursts of high-amplitude slow and sharp activity alternating with periods of attenuation of background EEG activity.
- May occur after severe anoxic brain injury, general anaesthesia, hypothermia, and barbiturate overdose.
- Used as a marker of adequate barbiturate dosage in status epilepticus treatment.

Triphasic waves. Can occur in:

- metabolic conditions: hepatic, uraemic, and anoxic encephalopathy;
- CJD;
- post-ictal state.

Periodic complexes

- Periodic lateralized epileptiform discharges (PLEDS) occur in destructive lesions: ischaemic stroke, intracerebral haemorrhage, encephalitis.
- Generalized or asymmetrical periodic sharp waves often found in sporadic CJD at some stage of the illness; do not occur in vCJD or familial CJD.
- Generalized periodic stereotypic complexes occur in SSPE and correlate with myoclonic jerking.

Epileptiform patterns

- Non-convulsive status epilepticus.
- Post-ictal.

Normal EEG

- Locked-in syndrome with lesion in pontine tegmentum.
- Psychogenic unresponsiveness.

Electrical inactivity

- Absence of brain waves $>2 \mu\text{V}$ amplitude.
- In brain death, severe poisoning, general anaesthesia, hypothermia.

This page intentionally left blank

EEG in the intensive care unit

Clinical neurological assessment is limited in the unconscious or paralysed and ventilated patient. EEG can help by demonstrating a response to stimulation of the limbs or the cranial nerve territories. EEG abnormalities need to be distinguished from the effect of sedatives and anaesthetic agents.

Coma

See Fig. 6.5.

- Focal repetitive periodic discharges in HSE.
- Diffuse slow waves: metabolic, anoxic brain injury, drug overdose.
- Non-convulsive status epilepticus.

Prognosis after cardiac arrest

- Recovery of continuous activity within first 4 hours correlates with good recovery. In contrast, the predictive value for recovery of EEG is poor at 48 hours.
- Isoelectric and burst suppression patterns not caused by drugs or hypothermia indicate a poor prognosis.

Continuous EEG monitoring is used:

- to detect seizures in patients with status epilepticus who are paralysed and ventilated;
- to assist management of sedation in ventilated patients following head injury;
- in detection of arousals;
- in assessment of prognosis of sepsis-associated encephalopathy by monitoring severity scores based on EEG features.

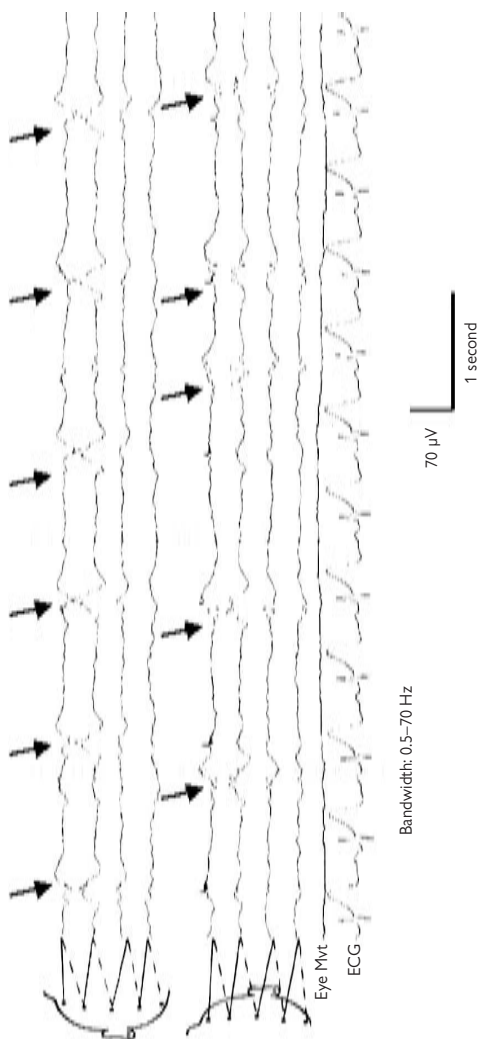


Fig. 6.5 Loss of normal background rhythms and bilateral independent periodic lateralized epileptiform discharges (PLEDS), indicated by arrows, in an adult comatose patient following hypoglycaemia. ECG = electrocardiogram; Eye Mvt = eye movement channel.

Technical summary of nerve conduction studies (NCS)

Standard NCS assess function of the large myelinated motor and sensory fibres (see Table 6.1).

- NCS are dependent on many technical factors:
 - subject's age, gender, and height;
 - skin temperature must be controlled or a correction applied; conduction velocity varies by 2.4 m/s/1 degree from 29°C to 38°C;
 - recording equipment;
 - operator experience.
- NCS are either:
 - **orthodromic** where direction of propagated potentials is the same as normal physiological conduction in the nerve, e.g. sensory nerve distal-to-proximal;
 - **antidromic** where studies are in the opposite direction to normal physiological conduction, e.g. sensory nerve proximal-to-distal.
- Conduction velocity (CV) reflects the velocity of the fastest conducting nerve fibres.
- Durations of the nerve action potential (NAP) or compound muscle action potential (cMAP) waveforms reveal the spectrum of CV in large nerves (Fig 6.6).
- Motor conduction velocity (MCV) in metres/second is calculated by: distance (millimetres) between two separate points of stimulation, one close to muscle being recorded, the other more proximal \div difference between onset latencies of the proximally-elicited and distally-elicited CMAP waveforms elicited by separate supramaximal stimulation (milliseconds).
- Compound muscle action potentials (CMAPs) are recorded from the skin overlying a muscle in response to stimulation of the motor nerve to that muscle. Onset latency, amplitude, area, and duration are measured.
- Sensory nerve action potentials (SNAPs) are recorded from a nerve in response to supramaximal stimulation of the nerve at another site. Onset latency, amplitude, area, and duration are measured.
- Sensory conduction velocity (SCV) is calculated: distance (millimetres) between stimulation and recording electrodes \div onset latency of the SNAP waveform (milliseconds).
- F wave. Supramaximal distal stimulation of a motor nerve also elicits an impulse that travels antidromically to the axon hillock region of the spinal cord where it elicits further motor fibres that propagate back to the muscle. Only explores 1–3% of motor axons in a nerve.
 - Gives information on conduction over the whole length of motor nerve, including proximal sections.
 - frequency of occurrence out of 20 stimuli, minimum latency and range of latencies are recorded.

Table 6.1 Commonest nerves studied by nerve conduction studies

	Motor	Sensory
Head & neck	Facial	Trigeminal
Upper Limb	Median	Median
	Ulnar	Ulnar
		Radial
Lower Limb	Tibial	Sural
	Peroneal—deep	
	Peroneal—superficial	Peroneal—superficial

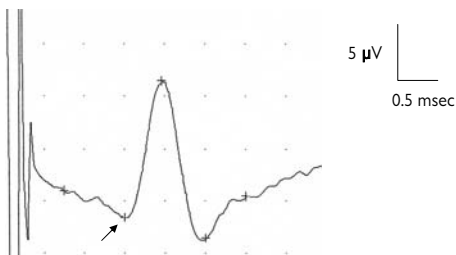


Fig. 6.6 Sensory nerve action potential. The ulnar sensory fibres were stimulated at digit V using surface electrodes and the recording electrodes were placed over the ulnar nerve at the wrist. Arrow indicates 1st positive peak, used in this example to calculate sensory conduction velocity (in this case, 57 metres/second). The amplitude (14 μvolts) was measured between the negative (upward) peak and the 2nd positive (downward) peak. Ten waveforms were averaged. Supramaximal stimulation rate = 1/second.

- H reflex:
 - measures conduction through afferent and efferent fibres in a monosynaptic reflex arc;
 - usually recorded from calf muscles in response to submaximal stimulation of Ia afferents in the tibial nerve at the knee;
 - usually equivalent to eliciting ankle deep tendon reflex;
 - absent if F wave and other NCS are abnormal.

Evaluation of proximal nerve conduction

Indirect studies

- F wave.
- H reflex.

Direct studies:

- Needle EMG of paraspinal muscles
- Nerve root stimulation by:
 - high voltage surface electrical stimulation;
 - monopolar needle electrode stimulation;
 - magnetic stimulation.

This page intentionally left blank

Peripheral nerve disorders: NCS abnormalities

NCS will help classify a peripheral nerve disorder into the following categories:

- sensorimotor;
- pure sensory or pure motor;
- axonal, demyelinating, or mixed;
- generalized, multifocal, or length-dependent.

Demyelinating neuropathies

Characterized by ↓ conduction velocities with preserved sensory nerve action potential (SNAP) and compound muscle action potential (CMAP) amplitudes.

- Abnormalities supportive of demyelinating neuropathy include:
 - ↓ CV below < 70–80% of lower limit;
 - ↑ F wave latencies > 130% lower limit of normal;
 - ↑ distal sensory and motor latencies > 130% lower limit of normal;
 - ↓ CMAP amplitude from proximal stimulation compared to distal stimulation (motor conduction block).
- In many hereditary demyelinating neuropathies, abnormalities tend to be diffuse and to a similar degree in all nerves.
- In acquired demyelinating neuropathies:
 - focal slowing;
 - temporal dispersion (↑ duration of action potentials);
 - regions of conduction block.
- Needle EMG studies can show abnormalities indicating denervation and reinnervation, depending on severity and chronicity

Axonal neuropathies

Characterized by:

- ↓ or unrecordable sensory nerve action potentials (SNAPs) and compound muscle action potentials (CMAPs).
- With severe axonal loss, conduction velocity may be reduced as result of loss of fast-conducting fibres.
- Needle EMG confirms axonal degeneration with features of denervation and reinnervation.

Focal neuropathies

See Fig. 6.7.

- Lesions may cause focal regions of demyelination. Stimulation of the nerve distal to lesion elicits a normal response. Proximal stimulation produces a response with delayed latency corresponding to localized conduction slowing, e.g. ulnar neuropathy at the elbow.
- Focal lesion may result in conduction block at the site of the lesion. For example, with neurapraxia of the common peroneal nerve at the fibular head resulting in foot-drop, distal response may be normal but proximal stimulation may not elicit a response due to conduction block.
- Focal lesion may also cause axonal degeneration distal to site of lesion. This can result in reduced amplitude of SNAPs and CMAPs.

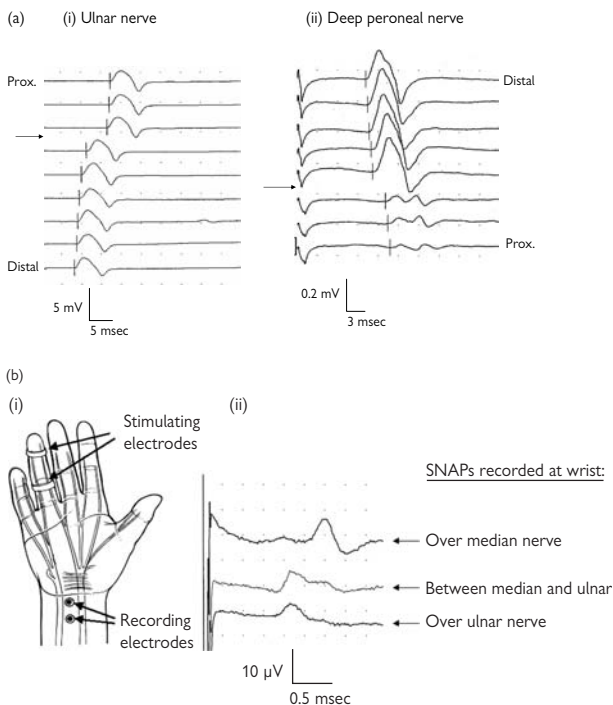


Fig. 6.7 (a) Localization of focal neuropathies. (i) Inching studies, recording from abductor digiti minimi muscle, demonstrating ulnar motor slowing (arrow) localized to the region of the medial epicondyle. Supramaximal stimuli over the nerve at 2 cm intervals, proximal-to-distal. (ii) Inching studies, recording from extensor digitorum brevis muscle, demonstrating deep peroneal motor slowing and partial motor conduction block (arrow) localized to the region of the head of fibula. Supramaximal stimuli over the nerve at 2 cm intervals, distal-to-proximal. (b) Carpal tunnel syndrome. (i) The position of the stimulating surface electrodes on digit IV and the active recording electrodes at the wrist (ii) The median sensory nerve action potential (SNAP) occurring significantly later than the ulnar SNAP, demonstrating slowed sensory conduction velocity of median fibres from digit IV compared to ulnar fibres from digit IV. (Active stimulating-to-recording electrode distances equal for the 3 active recording electrode positions.)

Technical summary of needle electromyography (EMG)

Needle EMG involves extracellular recording of muscle action potentials using either monopolar or concentric needle electrodes. A qualitative assessment, and therefore operator-dependent.

- The motor unit refers to the motor neuron cell body, motor axon, and all innervated muscle fibres. Motor unit potential (MUP) is the sum of activity from muscle fibres of one motor unit.
- Transection of a motor nerve is followed by regrowth at 1 mm/day.

Technical aspects

- Concentric needle electrode (CNE) is inserted into the belly of the muscle at rest.
- Insertional activity is assessed. Normally no other activity.
- Subject asked to activate muscle voluntarily. MUPs are studied and reflect synchronous discharge of all muscle fibres in a motor unit.
- With minimal effort, a few motor units fire initially at 5–7/second. With more effort, more motor units, of higher amplitude and faster firing frequencies, are recruited.
- Recruitment and interference pattern of MUPs assessed at increasing levels of contraction and at maximal voluntary effort.

Notes

- Needle EMG may be contraindicated in patients with coagulopathies, e.g. oral anticoagulant medication, haemophilia, thrombocytopenia. Discuss with clinical neurophysiologist.
- Transient bacteraemia may occur causing endocarditis in those with prosthetic or diseased valves. Discuss with clinical neurophysiologist.
- Muscle biopsy findings in a muscle examined by needle EMG can yield misleading information due to muscle trauma and localized inflammation.
- Serum creatine kinase (CK) levels may rise by 150% of normal after needle EMG. Returns to normal after 48 hours.

This page intentionally left blank

Needle EMG: patterns of abnormality

Spontaneous activity at rest

Fibrillations and positive sharp waves (Fig. 6.8(a)).

- Generated by individual muscle fibres.
- Reflect ↑ excitability of muscle cells due to alteration in resting membrane potentials.
- Occur in:
 - recent denervation;
 - myopathic processes.

Fasciculation potentials

- Result from spontaneous discharges of a group of muscle fibres from all or part of a motor unit.
- May result from pathology in the anterior horn cell, motor, root, or more distal motor nerve.

Myotonia

 (Fig. 6.8(b)).

- Characterized by rhythmic discharges triggered by insertion of EMG needle into muscle. Waveforms resemble positive sharp waves or fibrillations. Discharges wax and wane in amplitude, producing a noise resembling a decelerating motorcycle.
- Occurs in:
 - myotonia congenita;
 - myotonic dystrophy;
 - paramyotonia congenita;
 - hyperkalaemic periodic paralysis.
- Electromyographic, as opposed to clinical myotonia, is also seen in:
 - polymyositis;
 - hypothyroidism;
 - acid maltase deficiency, typically in the paraspinal muscles.

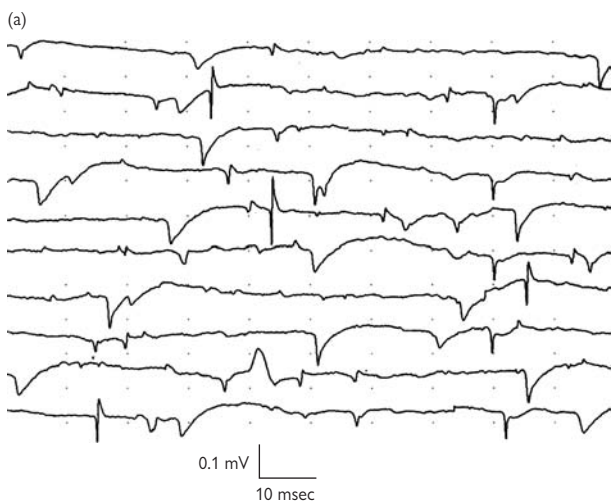


Fig. 6.8 (a) Concentric needle EMG recording of fibrillations and positive sharp waves (downgoing) at rest indicating recent denervation of the muscle.

Complex repetitive discharges

- Have a uniform shape, frequency, and amplitude. Have an abrupt onset, mimicking the sound of a machine gun, with a frequency of 5–100/second.
- Represent a group of muscle fibres firing in near synchrony.
- Occur in:
 - myopathies, e.g. polymyositis, Duchenne muscular dystrophy;
 - chronic denervation, e.g. radiculopathy, spinal muscular atrophy, hereditary neuropathies.

Neuromyotonia

- Characterized by spontaneous and continuous rhythmical discharges at high frequencies
- Represents single fibre or motor unit discharges and originate from a distal motor axon.
- Occurs in conditions associated with continuous muscle fibre activity, e.g. stiff person syndrome, encephalomyelitis with rigidity, Isaac's syndrome.

Myokymia

- Consists of repetitive discharges of one or more motor units, usually in complex bursts.
- Occurs in chronic neuropathies and represents a non-specific response to injury.
- Occurs in radiation plexopathies.
- Can be recorded in facial muscles in patients with multiple sclerosis or pontine glioma.
- May be exacerbated by hyperventilation-induced hypocalcaemia.

Neurogenic processes (affecting motor axons)

- Denervation results in fewer motor units that can be activated voluntarily.
- Acute denervation changes recorded from a muscle at rest initially include spontaneous fibrillations and positive sharp waves.
- Reinnervation results in denser motor units that contain increased number of fibres manifesting as long-duration motor unit potentials (MUPs) and increased fibre density. With ongoing reinnervation, MUPs are unstable (Fig. 6.8 (c)).

Myopathic processes

- Excessively full interference pattern so that baseline is obliterated at earlier effort than in normal muscle.
- Low amplitude and short duration MUPs.
- Complex or polyphasic MUPs due to variation in diameter of pathological muscle fibres.
- Fibrillations and positive sharp waves at rest.
- Unstable MUPs, indicating a recent or active process.
- Stable late potentials in longstanding myopathic disorders.

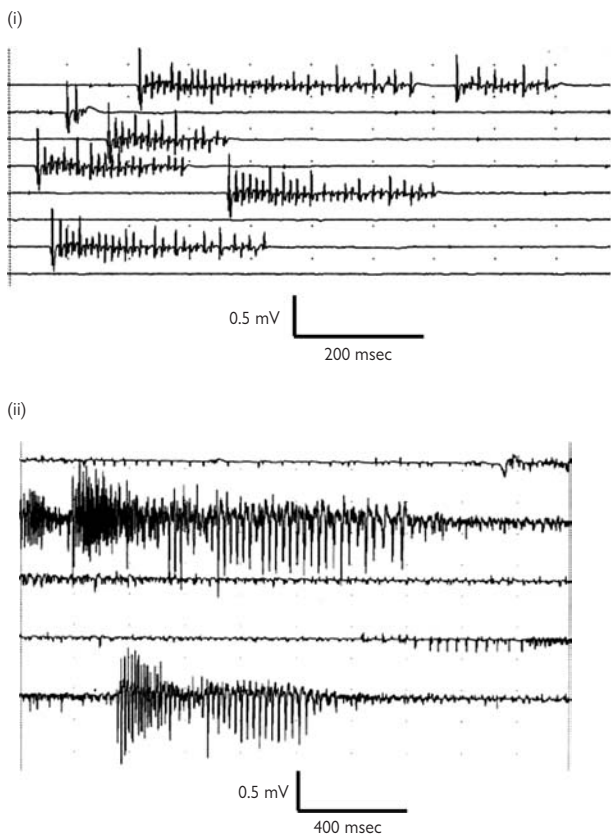


Fig. 6.8 (b) Concentric needle EMG recordings of myotonia from 2 adult patients with myotonic disorders: (i) paramyotonia congenita and (ii) myotonia congenita.

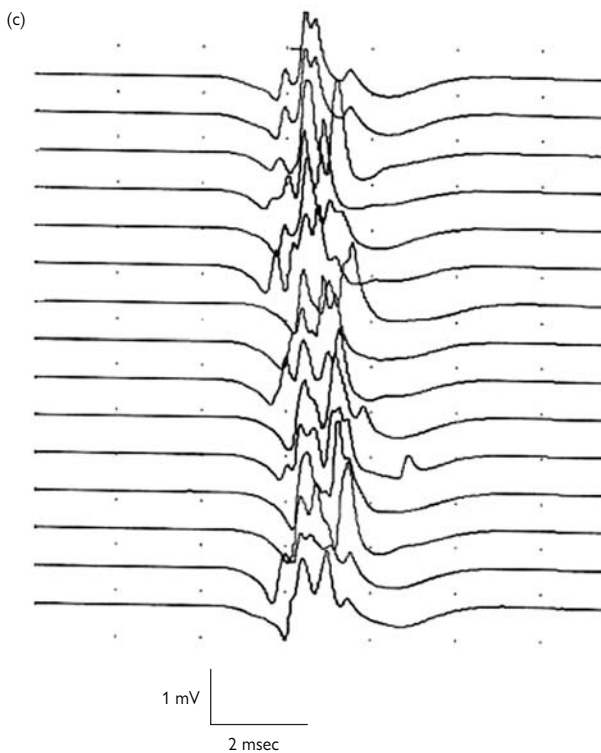


Fig. 6.8 (c) Concentric needle EMG recording, in raster display, of a triggered unstable and irregular motor unit potential, indicating recent reinnervation.

This page intentionally left blank

NCS and needle EMG findings in myopathies and motor axonal loss

NCS and EMG in myopathies

NCS

- Normal nerve conduction velocities.
- Normal sensory nerve action potential amplitudes.
- Compound muscle action potential (CMAP) amplitudes of motor nerves may be reduced in severe myopathy involving distal muscles.

Needle EMG

- Changes may be patchy.
- Needle EMG cannot differentiate between different types of myopathy.
- Spontaneous activity at rest, which may be confined to paraspinal muscles:
 - fibrillations;
 - positive sharp waves;
 - complex repetitive discharges.
- Myopathic motor unit potentials (MUPs) reflecting loss of muscle fibres and increased fibre type variation (Fig. 6.9):
 - polyphasic;
 - low amplitude;
 - short duration.

NCS and EMG in radiculopathies

NCS

- Normal sensory nerve action potentials (SNAPs), as pathology is proximal to the dorsal root ganglion.
- H-reflex from flexor carpi radialis or soleus muscles may be delayed or absent in C7 or S1 radiculopathies respectively.

Needle EMG

- Denervation of paraspinal muscles helps to differentiate root lesions from more peripheral nerve lesions.
- Evidence of denervation is required in ≥ 2 muscles innervated by each motor root.
- Needle EMG of adjacent myotomes determines extent of involvement.

NCS and EMG in motor neuron disease (MND)

MND can be difficult to diagnose in the early stages especially in bulbar onset cases or if confined to one limb.

- Normal sensory NCS.
- Normal motor conduction velocities.
- Amplitudes of compound muscle action potentials (CMAPs) may be reduced.
- Important to rule out motor conduction block.
- Needle EMG: active denervation with partial reinnervation involving different roots and nerves corresponding to different spinal and bulbar segments.
- Progression can be monitored by repeated measurement of CMAPs.

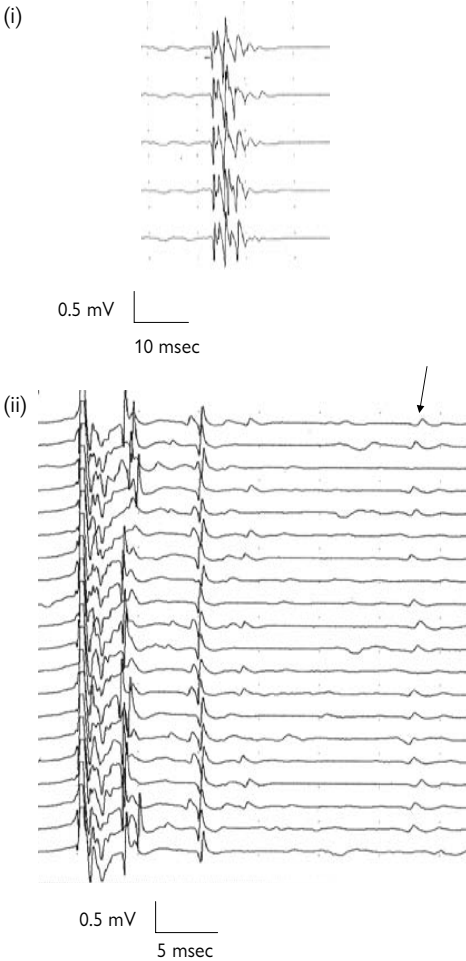


Fig. 6.9 Concentric needle EMG recording, myopathic patterns. (i) Raster display of a triggered low amplitude polyphasic stable motor unit potential. (ii) Raster display of a triggered polyphasic motor unit potential, associated with late (satellite) potentials (see arrow).

NCS and needle EMG findings in Guillain–Barré syndrome

- Motor nerves usually more involved than sensory nerves.
- Large number of nerves should be studied as involvement may be patchy.

Early

- Studies may be normal.
- Delayed distal motor latencies.
- Reduced frequency and delayed F waves.
- Early reduction of F waves may indicate proximal conduction block.

Late

- Widespread slowing in sensory and motor nerves.
- Temporal dispersion of NAP or CMAP.
- Conduction block detected by ↓ CMAP amplitude with more proximal stimulation.

Needle EMG

- Evidence of denervation 2–3 weeks after onset indicates motor axonal loss in addition to demyelination.
- Degree of ↓ CMAP amplitude and denervation on needle EMG indicates severity and guides prognosis.

GBS subgroups

NCS and EMG findings can classify GBS subgroups.

- Acute inflammatory demyelinating polyradiculoneuropathy (AIDP).
- Acute motor axonal neuropathy (AMAN).
- Acute motor and sensory axonal neuropathy (AMSAM).

This page intentionally left blank

NCS and needle EMG findings in neuromuscular transmission disorders

Classified into:

- post-synaptic e.g. myasthenia gravis
- presynaptic e.g. Lambert–Eaton myasthenic syndrome, botulism

Note: it is important to study clinically-affected muscles.

Myasthenia gravis

- Normal sensory nerve conduction studies.
- Amplitude of compound muscle action potential (CMAP) from affected muscle may be ↓ due to motor endplate destruction with normal motor conduction velocities.
- Needle EMG: no evidence of denervation or reinnervation.
- Repetitive nerve stimulation (RNS, see Fig. 6.10(a)):
 - slow rate of repetitive supramaximal stimulation (1–3/second) results in ‘decrement’: ie > 8% ↓ amplitude of 5th CMAP compared to 1st CMAP
 - maximal voluntary contraction of the muscle for 20 seconds or a train of high rate stimulation (10–50/second) may result in some in CMAP amplitude, but < 200%: ie post-activation potentiation due to transient ↑ in acetylcholine release.
 - degree of decrement correlates with clinical severity.
- Single fibre EMG (SFEMG, see Fig. 6.10(b))
 - studies transmission in individual motor endplates.
 - performed if RNS is negative.
 - reveals subclinical neuromuscular transmission defects.
 - ↑ jitter found in extensor digitorum communis muscle in all cases of moderate or severe generalized MG and 96% of mild cases. In ocular MG, ↑ jitter of frontalis muscle found in 89%.

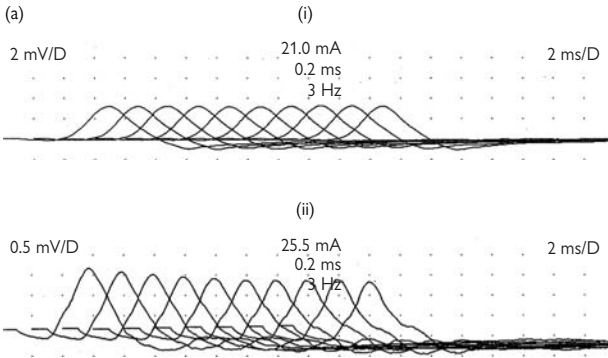


Fig. 6.10 (a) Repetitive nerve stimulation at 3 Hz, recorded from nasalis muscle. (i) Normal (2 mV/D); (ii) 15% decrement in a myasthenic patient (0.5mV/D).

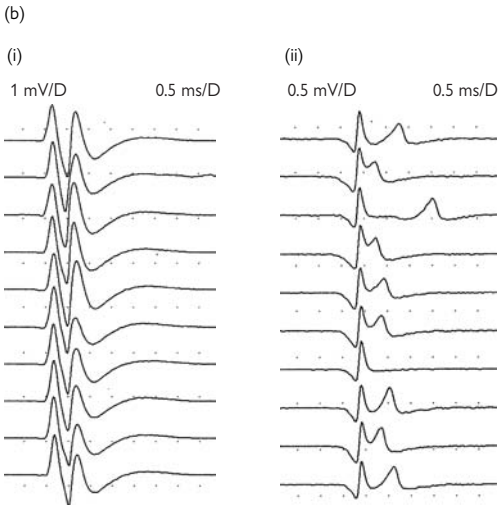


Fig. 6.10 (b) Single fibre EMG. (i) Normal jitter; (ii) increased jitter and blocking in a myasthenic patient.

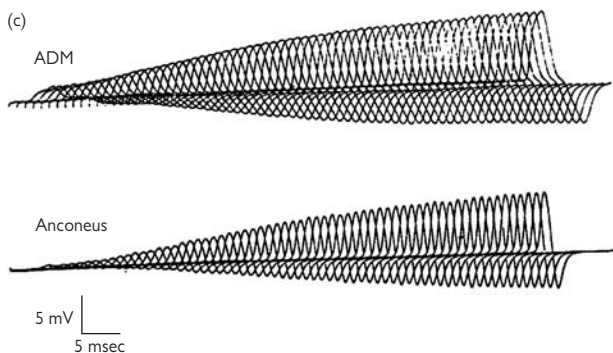


Fig. 6.10 (c) Increment in a patient with Lambert–Eaton myasthenic syndrome (LEMS). Repetitive nerve stimulation at 20 Hz, recorded from abductor digiti minimi (ADM) and anconeus muscles.

Lambert–Eaton myasthenic syndrome (LEMS)

- Sensory nerve conduction studies usually normal unless associated with a paraneoplastic neuropathy.
- CMAP amplitudes are absent or ↓, especially from foot muscles. Normal motor conduction velocities.
- No evidence of denervation or reinnervation on needle EMG.
- RNS see Fig. 6.10(c):
 - slow rate of repetitive supramaximal stimulation (1–3/second) elicits a decrement >8%, similar to MG above
 - maximal voluntary contraction for 20 seconds or high rate of RNS (10–50/second) results in >200% of CMAP post-activation potentiation due to transient ↑ release of acetylcholine.
- SFEMG: ↑ jitter in clinically-affected muscles.

This page intentionally left blank

Visual evoked responses (VERs)

VERs are recorded from the scalp and are averaged from the EEG background of the occipital cortex. Reflect integrity of the central visual field from retina, optic nerve, and cortex.

- The full field VER is elicited by stimulating each eye while the subject fixates on the stimulus. Sensitive to lesions of the optic nerve and anterior chiasm.
- Pattern-reversal stimulation usually used.
- Hemifield stimulation helpful in assessment of retrochiasmatic lesions. May be difficult to interpret.
- Pattern reversal electroretinography (ERG) can be recorded simultaneously with VERs; enables retinal abnormalities to be excluded as a cause of abnormal VERs.

The P100, the most consistent waveform, is a large positive deflection at approximately 100 milliseconds latency, maximal in the occipital midline.

- Latency most consistent parameter.
- Amplitude varies amongst normal individuals.
- Elicited by:
 - luminance change, i.e. flash VER;
 - contrast change with repeated reversal of a black and white checkerboard pattern (pattern reversal VER; Fig.6.11(a)).

Applications

Most commonly used for detection of asymptomatic lesions in MS (Fig. 6.11(b)).

- 90% of patients with a history of optic neuritis have abnormal pattern-reversal VERs.
- Unilateral delay suggests impaired conduction in visual pathway anterior to optic chiasm.
- Site of abnormality cannot be localized when delay is bilateral and equivalent from each eye.
- Normal pattern-reversal VERs do not exclude retrochiasmatic lesions. Possible to have recordable VERs with cortical blindness.

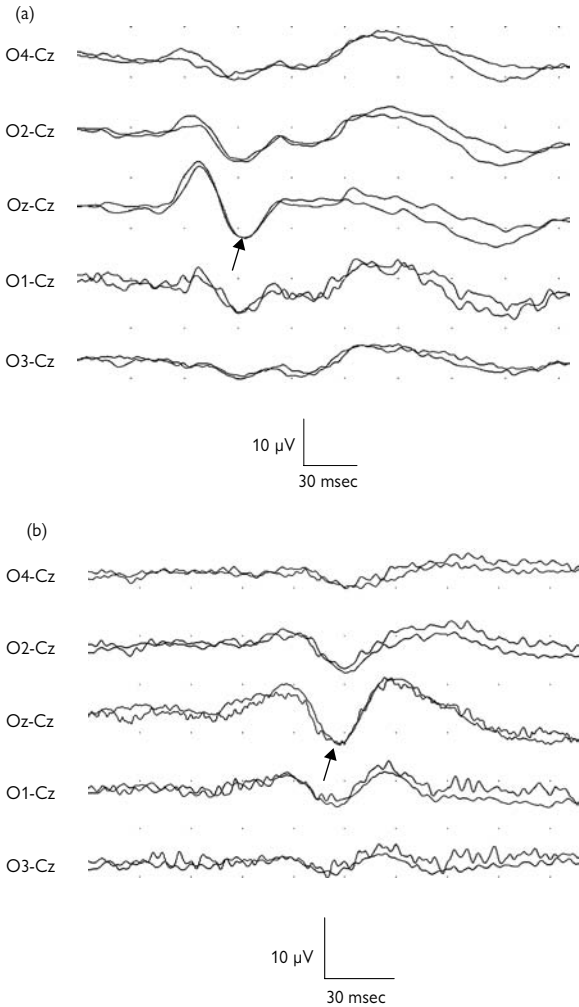


Fig. 6.11 (a) Normal pattern-reversal visual evoked responses (VERs) recorded from a 25-year-old-man. The midline P100 latency (indicated by arrow) was 100 ms. (b) Delayed pattern-reversal VERs recorded from a 48-year-old man with multiple sclerosis. The P100 latency indicated by arrow was 143 ms. (Visual acuity was 6/9.)

Somatosensory evoked potentials (SSEPs)

SSEPs are time-locked responses following stimulation of afferent peripheral nerve fibres from upper and lower limbs. They enable study of the integrity of the large fibre sensory pathways in peripheral nerves, spinal cord, and brain.

Upper limb SSEPs

- Stimulation of median nerve at wrist (Fig. 6.12(a)).
- Recordings from:
 - Erb's point (N9, generated by brachial plexus);
 - upper cervical cord (P/N13, generated by post-synaptic activity in central cord grey matter at cervico-medullary junction/upper cervical cord);
 - scalp over hand area of contralateral somatosensory cortex (N19, thalamus; and P22, parietal sensory cortex).

Lower limb SSEPs

- Stimulation of tibial nerve at ankle (Fig. 6.12(b)).
- Recordings from:
 - T12/L1 (N20, cauda equina potential);
 - scalp over foot/leg area of contralateral somatosensory cortex in midline (N/P37, parietal sensory cortex).

Notes

- Lesions alter SSEPs by delaying or abolishing component waveforms. Waveform amplitude less reliable than latency.
- Lower limb SSEP latencies are proportional to standing height.

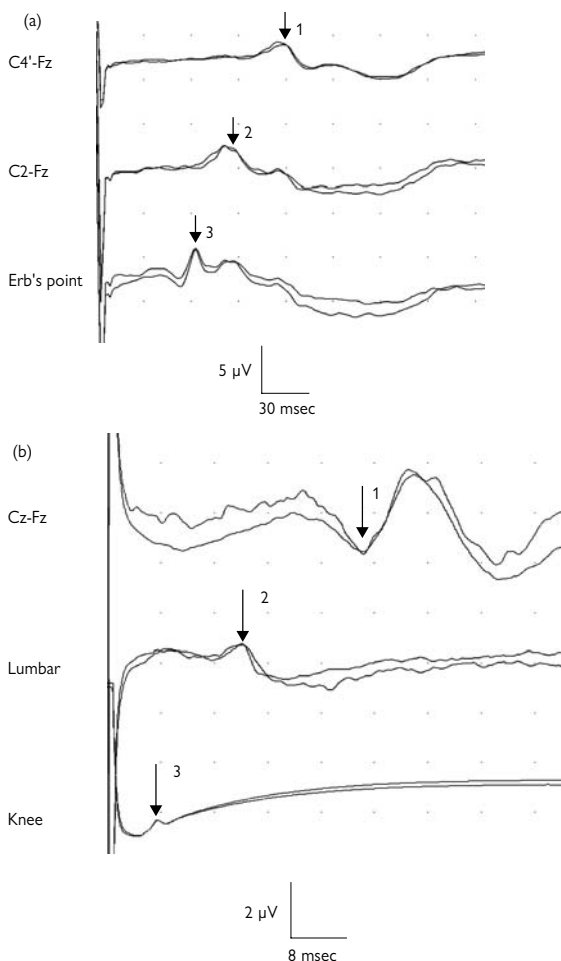


Fig. 6.12 (a) Normal upper limb somatosensory evoked potentials (ULSSEPs), elicited by stimulation of the left median nerve of a 34-year-old woman at the wrist: standing height, 173 cm. Arrow 1 = cortical (N19) waveform; Arrow 2 = cervicomedullary (N13) waveform; Arrow 3 = brachial plexus potential. (b) Normal lower limb somatosensory evoked potentials (LLSSEPs), elicited by stimulation of the left tibial nerve of a 36-year-old woman at the ankle: standing height, 180 cm. Arrow 1 = cortical (P37) waveform; Arrow 2 = lumbar (N20) waveform; Arrow 3 = peripheral nerve waveform recorded at the popliteal fossa.

Indications

- Differentiate between central and peripheral causes of large fibre sensory dysfunction.
- Study proximal peripheral nerves when standard sensory NCS are normal.
- Confirmation of non-organic peripheral sensory loss.

SSEPs in specific conditions

Multiple sclerosis

- Usually ↑ central sensory latencies.
- May indicate second asymptomatic lesion.
- Where peripheral sensory conduction is normal it is possible to localize a lesion:
 - above cervico-medullary junction;
 - at region of cervico-medullary junction/upper cervical cord;
 - below upper cervical region but above cauda equina.
- SSEP abnormalities present in up to 90% of patients with definite MS and 50% of MS patients without sensory symptoms or signs.

Coma

- Bilateral absence of the thalamo-cortical (N19–P22) waveforms indicates poor prognosis.
- Prognostic classification based on SSEPs has been developed for post-hypoxic coma.

Brain death

- Role of neurophysiological investigations in brainstem death remains controversial.
- Absent N19–P22 waveforms.
- P/N13 waveform complex is preserved in 70% of brain dead patients.

Cortical myoclonus Using back-averaging techniques, abnormally large cortical waveforms are observed in progressive myoclonic epilepsy, CJD, post-hypoxic myoclonus.

This page intentionally left blank

Brainstem auditory evoked responses (BAERs)

BAERs (Fig. 6.13) are elicited by clicks presented to the ear by a headphone. Recorded between disc electrodes placed on the scalp at vertex and mastoid of the ear being studied. Normally 6 or 7 waveforms are recorded. Latencies for waveforms I, III, and V are the most consistent and clinically useful.

- Wave I. Generated in auditory nerve near cochlea.
- Wave III. Generated in superior olivary nucleus.
- Wave V. Generated in the lateral lemniscus/inferior colliculus, i.e. upper pons/lower midbrain.
- Most sensitive measure is the wave I–wave III interwave latency difference.

Indications

- Identifying hearing impairment in infancy or in patients who have difficulty cooperating with conventional audiography.
- Determining nature of hearing loss.
- Helping diagnose acoustic neuroma: 98% with acoustic neuroma have abnormal BAERs; 33% have unrecordable BAERs.
- Aiding diagnoses of multiple sclerosis: abnormal in 20–50% of patients who have no brainstem symptoms or signs.
- Aiding localization of brainstem pathology: delayed or absent wave V with normal wave III indicates abnormal conduction in the auditory pathways in the region of the pons.

Note: BAERs are normal in cortical deafness.

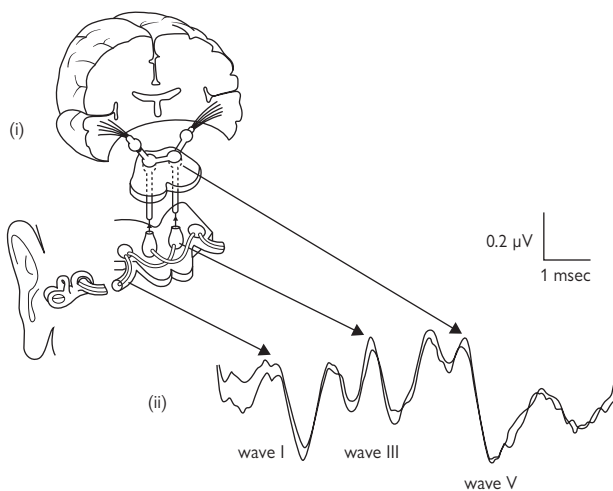


Fig. 6.13 Brainstem auditory evoked responses (BAERs). (i) Schematic diagram of the auditory pathways and the origin of the BAER waveforms. (ii) Example of normal BAER waveforms elicited by click stimulation to one ear of a 36-year-old woman.

Normal values in clinical neurophysiology

- Nerve conduction and evoked potential data are influenced by many subject variables including age, height, skin temperature, and sex.
- They can also be affected by technical factors such as electrode specifications, stimulating and recording parameters, recording equipment, and the person carrying out the study.
- Specific factors exist for particular studies, such as the importance of visual acuity, check size, and luminance for pattern-reversal VERs and hearing threshold for BAERs.

It is an important principle that, where possible, individual departments should collect normal data using the same methods that are employed in the routine clinical work of that laboratory.

The normal limits in Table 6.2–6.4 are approximate for adults and should be used only as a general guideline.

Table 6.2 Motor nerve conduction studies (surface electrodes)

	Median nerve	Tibial nerve
Muscle recorded from	Abductor pollicis brevis	Abductor hallucis brevis
Distal motor onset latency (ms)	≤ 4.0	≤ 6.2
Amplitude (mV)	≥ 5.0	≥ 5.5
Conduction velocity (m/s)	≥ 50 (elbow–wrist)	≥ 40 (knee–ankle)
F-wave latency (ms)*		
Minimum of 20	≤ 30	≤ 58
Interside difference	≤ 2.5	≤ 3.5
H reflex minimum latency (cms)		≤ 33

* It is particularly important to take subject's height into account.

Table 6.3 Sensory nerve conduction studies (surface electrodes)

	Median nerve	Sural nerve
Conduction velocity (m/s)	≥ 50 (digit II–wrist)	≥ 40 (calf–ankle)
Amplitude (μV)	≥ 10	≥ 6

Table 6.4 Evoked potential latencies

Median SSEPs	ERB's point	N13	N19	N13–N19	
Normal range (ms)	≤ 11	≤ 16	≤ 21	≤ 7	
Tibial SSEPs	N20	P37	N20–P37		
Normal range (ms) *	≤ 22	≤ 40	≤ 20.5		
Pattern-reversal VER	P100	Intereye difference			
Normal range (ms)	≤ 120	≤ 11			
BAER	Wave I	Wave III	Wave V	Wave I–III	Wave III–V
Normal range (ms)	≤ 2.2	≤ 4.5	≤ 6.5	≤ 2.5	≤ 2.4

* It is particularly important to take subject's height into account.

This page intentionally left blank

Neuroradiology

- Techniques in diagnostic radiology 480
- Cerebrovascular disease 486
- Subarachnoid haemorrhage 490
- Intracerebral haemorrhage 492
- Guidelines for head injury 494
- Imaging strategies for cervical spine trauma 496
- Guidelines for the neuroradiology of tumours 498
- CNS infections 500

Techniques in diagnostic radiology

Plain radiography

- Limited contrast resolution and risk of ionizing radiation.
- Pregnancy is a contraindication as is lack of menstruation within last 10 days.
- Skull X-ray (SXR) used occasionally for penetrating head injury, characterization of skull vault bone lesions, and assessment of shunt tubing.
- Spinal X-ray indicated in trauma, characterization of bone lesions in haematological disorders (skeletal surveys), flexion/extension views for assessment of stability of cervical spine (e.g. rheumatoid arthritis) and lumbar spine (e.g. pars defects).

Computerized tomography (CT)

- CT employs a highly collimated X-ray beam that is differentially absorbed by various tissues depending on their density. Thinner slices (<2 mm) increase spatial resolution.
- Usually used for the evaluation of bones, e.g. spine and base of skull.
- Contrast enhancement with non-ionic iodinated IV contrast, which appears as higher density, is used to opacify blood vessels and reveal blood–brain barrier (BBB) breakdown: tumours, infection, inflammation.
- Rapid administration of IV contrast (using a pump injector) can be combined with early arterial phase thin-slice CT to generate angiographic images (CTA) of neck vessels and circle of Willis (in, for example, SAH).
- CT has evolved to spiral CT and now multi-slice technology to provide < 1 mm slices within seconds.

Dose issues

- Essential to limit number of studies.
- Thinner slices increase dose.
- CT head/cervical spine not contraindicated in pregnant women—extremely low risk over background radiation. A lead apron over the abdomen can be psychologically beneficial.
- CT of thoracic and lumbar spine contraindicated in pregnancy unless life-threatening condition.

Ultrasonography (USS)

Operator-dependent—requires skill and experience.

Carotid artery Doppler

Indications

- History of TIA/stroke in anterior circulation.
- Asymptomatic carotid bruit.
- Pre-op evaluation before major cardiovascular surgery.
- Post-endarterectomy follow-up.
- Arterial dissection.

Imaging signs

- Visual characterization of atheromatous plaque at bifurcation of common carotid artery (CCA) and in proximal ICA: calcification/ plaque size/degree of stenosis/plaque ulceration.
- May be difficult to distinguish occluded from near occluded vessel.
- Sensitivity 95%; specificity 85–99%.
- In dissection: intimal flap/double lumen/ intramural thrombus/ vessel tapering.
- Assessment of vertebral arteries limited to gross patency and direction of flow.

Transcranial Doppler

Performed using a high-frequency probe over the thin portion of the temporal bone using it as an acoustic window.

Indications

- Intracranial stenoses.
- Occlusions (e.g. MCA).
- Cross-flow through anterior and posterior communicating arteries.
- Midline shift.
- Vasospasm in SAH.
- Detection of supratentorial haematomas, aneurysms, AVM.

Magnetic resonance imaging (MRI)

- Success of technique is based upon its sensitivity to protons in water, which constitutes 70–90% of body tissues.
- Content and properties of water are altered in disease processes providing MRI with diagnostic opportunity.
- MRI has superior contrast resolution, especially of soft tissues, and is safe with no ionizing radiation.

Contraindications

- Pacemaker.
- Ferromagnetic implants (aneurysm clips, cochlear implants).
- 1st trimester pregnancy.
- Large metallic spinal fixation devices make interpretation difficult.
- Claustrophobia (10%)—consider sedation or, in essential cases, anaesthesia. Open MRI in some cases may be an alternative.

Different imaging sequences increase resolution.

- T1-weighted spin echo (SE) (T1W). White matter gives higher signal than grey matter; fat, gadolinium, melanin, proteinaceous fluid are hyperintense.
- T2W SE. Grey matter is higher signal than white matter; fluids including CSF, oedema, and to a lesser extent fat are hyperintense.
- Gradient echo (GE) also known as T2* may be T1- or T2-weighted. Low signal with air, blood products (deoxy- and methaemoglobin), Ca^{2+} , Fe^{2+} , and bone.
- Fluid-attenuated inversion recovery (FLAIR): suppression of fluid signal.

- Contrast-enhanced MRI. Gadolinium is a strongly paramagnetic metallic element injected IV. Rapidly distributed, excreted renally with a half-life of 1.5 hours. Results in enhancement on T1W images where there is BBB breakdown or in vascular tumours.
 - Contraindications: if severe renal impairment (relative contraindication); lactating mothers (no breastfeeding for 24 hours); known allergy.

Magnetic resonance angiography (MRA)

In conventional MRI, flowing blood alters signal intensity by the 'time of flight' and 'phase shift effect'. Time of flight (TOF) angiography uses GE sequences: fast-flowing blood is hyperintense. Two-dimensional TOF is MRA of choice for neck arteries and three-dimensional TOF for the circle of Willis.

Problems

- Blood products are also high signal.
- Insensitive to slow flow: overestimates degree of vessel stenosis; cannot distinguish between occlusion/near occlusion.

Phase contrast (PC) MRA useful for assessing dural venous sinuses.

Contrast-enhanced MRA uses gadolinium and is independent of flow dynamics and TOF effects.

Diffusion-weighted MRI (DWI) Infarction amongst several other applications is high signal. Perfusion-weighted MRI (PWI) measures volume of blood flow to that tissue over time. The combination is under research to identify patients with stroke who may have salvageable tissue.

Magnetic resonance spectroscopy (MRS) Provides information on the relative concentrations and distribution of compounds and ions (H-1, P32, and Na-23). *N*-acetyl aspartate (NAA) is a marker of neuronal integrity and ↓ concentration indicates neuronal loss in, e.g. neurodegenerative disorders, stroke, and MS. Lactate levels are ↑ in anaerobic metabolism, e.g. stroke. Myoinositol (MI) is a breakdown product in Alzheimer's dementia and tumours.

Functional MRI (fMRI)

Used in the evaluation of physiological alterations that occur in brain tissue during normal and abnormal activity, e.g. epilepsy and migraine.

Clinical applications

- Epilepsy surgery planning.
- Determination of language and memory lateralization (alternative to Wada test).
- Defining the proximity of eloquent areas in surgery planning, e.g. tumours and AVM.

Catheter angiography

Indications

- Characterization of vascular lesions, e.g. tumours, aneurysms, and AVM, prior to surgery or endovascular therapy.
- Investigation of SAH.
- Neck vessels, cerebral and spinal circulation.

- Follow-up on endovascular or operative interventions.

Pre-procedure

- Informed consent is mandatory.
- Check clotting. Contraindicated if INR > 1.3 or platelet count < 100.
- Check renal function.
- IV access necessary.

Contraindications

- Uncooperative patient with no anaesthetic cover.
- Contraindication to contrast:
 - history of contrast reaction;
 - severe renal impairment (but not on dialysis);
 - asthma without steroid prophylaxis unless life-threatening indication. Hayfever is not a contraindication.

Note. Patients with DM on metformin must stop the drug for 2 days after contrast study and have renal function checked prior to re-starting it.

Procedure

- Catheter angiography is usually performed by the transfemoral approach.
- Employing a Seldinger technique, a catheter is introduced into the aorta and iodinated contrast is injected into the arterial circulation during image acquisition.
- Background structures are digitally subtracted (DSA) to leave only vessels.
- Patient cooperation and lack of movement (including breath-holding for cerebral DSA) are essential.
- Sedation or anaesthesia may be required.

Complications

Related to puncture:

- Groin haematoma, iliac artery dissection, pseudoaneurysm, and a ruptured vessel may require urgent repair.
- Failure to gain access.
- Multiple puncture attempts may lead to AV fistula or distal embolic shower ('trashed foot').
- Vasovagal episodes especially if puncture is difficult.

Related to angiography:

- 1% risk of stroke, usually temporary. The risk of thromboembolic events is related to duration of procedure and technique. These are determined by level of experience.
- Spinal cord ischaemia due to radicular artery occlusion or embolus in spinal angiography (risk 1–2%).
- Arterial dissection may be a source of emboli.

Related to contrast:

- Mild reaction (vomiting and urticaria).
- Moderate and severe bronchospasm, facial and laryngeal oedema, hypotension, bradycardia, pulmonary oedema, and seizures.

Myelography

Indications

- Patients not suitable for MRI.
- Confirmation of equivocal MRI findings, e.g. nerve root compression.
- Dural fistula.
- Traumatic nerve root avulsion.

Pre-procedure

- Informed consent.
- Check clotting and renal function.

Contraindications

- Raised ICP.
- Pregnancy.
- Previous contrast reaction.
- Clotting abnormality or thrombocytopenia.

Procedure

A maximum of 3 g of iodinated non-ionic contrast is administered intrathecally under fluoroscopic guidance via a standard LP at L3/4. A cervical puncture at C1/2 can be performed if lumbar approach is unsuccessful.

Complications

- Post-LP headache.
- SAH or epidural haemorrhage.
- Pain.
- Instillation of contrast into subepidural or epidural space.
- Infection.
- Contrast reaction including seizures (rare with non-ionic contrast).

Nuclear isotope studies

PET (positron emission tomography) Uses elements emitting positrons with fluorine-18-labelled deoxyglucose (FDG) most commonly used. This identifies areas of increased glucose metabolism.

Indications

- Distinguishing between radionecrosis and glioma.
- Epilepsy surgery planning.
- Localization of neoplasms in paraneoplastic syndromes.

SPECT (single photon emission computed tomography) Uses technetium-99m or iodinated tracer I-123 mainly to study blood flow. Thallium SPECT is used to differentiate between abscesses and tumours such as primary CNS lymphoma (PCNSL) and toxoplasmosis in HIV/AIDS patients.

Interventional neuroradiology

Increasingly used in the management of vascular lesions previously only treated by surgery.

- Aneurysm occlusion with endovascular coiling.
- Parent vessel occlusion for giant aneurysm.
- AVM or AVF embolization, both intracranial and intraspinal.
- Hypervascular tumour embolization, e.g. meningioma and glomus tumour.
- Internal carotid and vertebral artery stenting.
- Super-selective intra-arterial or venous sinus thrombolysis.
- Caroticocavernous fistula occlusion.
- Petrosal sinus venous sampling.

Cerebrovascular disease

Ischaemic stroke

CT scan

- CT should be performed as soon as possible especially if thrombolysis is being considered.
- May detect other unexpected lesions, e.g. tumours.
- If thrombolysis is being considered, haemorrhage and large infarct are contraindications.
- Contrast not indicated and can be misleading.
- CT in acute stroke will differentiate infarct from haemorrhage for up to 5 days.
- A normal scan excludes haemorrhage but not infarct.
- Small haemorrhages lose their high density (white), become iso- then hypodense and therefore may be indistinguishable from infarct: in small haemorrhages by 7–10 days, larger haemorrhages 2–3 weeks.
- Small infarcts less likely to be visible than large ones. 90% of large infarcts are visible at 48 hours compared to 40% of lacunar or small cortical infarcts.
- Large infarcts may show subtle changes by 6 hours—depends on expertise of interpretation. Between 10 days and 3 weeks infarcts become isodense and difficult to define ('fogging').
- After 2–3 months they are more visible as same density as CSF.

MRI

- Shows ischaemic lesion more often than CT and therefore useful in those with CT scan negative infarcts.
- However, due to infarct evolution, with routine MR imaging (T2, proton density, and T1) 'fogging' also occurs and may not show lesions.
- FLAIR (fluid-attenuated inversion recovery) sequences increase sensitivity but will reveal additional incidental lesions making interpretation more difficult.
- Diffusion-weighted imaging (DWI) more sensitive but not specific for infarction. Encephalitis, demyelinating plaques, tumours all show increased signal.
- DWI most useful in identifying minor cortical or lacunar strokes or, in patients with a previous stroke and deteriorating signs, it may show the development of a new lesion.
- Salvageable territory requiring intervention, such as thrombolysis denoted by mismatch of PWI relative to DWI, may be more available in the future.
- Routine MR sequences will show features for haemorrhage (low signal due to haemosiderin) in 90% indefinitely.
- Gradient echo (GE) or T2* sequences are the most sensitive for detection of haemorrhage.

Imaging of atheromatous extracranial vessels

Doppler USS is the simplest, safest, and quickest method of assessing carotid and vertebral arteries to detect stenosis or dissection. Very operator-dependent.

DSA (conventional catheter angiography) is the gold standard and will identify stenosis severity including complete occlusions and almost occluded vessels. However, risk of stroke is 1%. Note: methods of calculation of % stenosis varies.

MRA

- Good correlation between normal MRA and absence of disease.
- However, MRA tends to overestimate degree of stenosis since narrowing may be due to stenosis or ↓ flow or turbulence.
- Contrast-enhanced MRA gives better morphological assessment but, as with MRA, does not differentiate between occlusion and very slow flow ('flow gap').

CT angiography

Arterial dissection

- Contrast-enhanced CT scan rarely diagnostic.
- MRI with fat-suppressed T1W axials recommended as first choice.
 - 'Fried egg appearance'—eccentrically located narrowed lumen within an expanded artery.
 - Lumen may be patent (flow void), reduced flow (isointense), or occluded/very slow flow (hyperintense).
 - Surrounding crescent of intramural haematoma (hyperintense on T1W axials with fat suppression).
 - Absence of high signal in lumen on GE (T2*) indicates occlusion.
- Doppler ultrasound may demonstrate intimal flap, a double lumen, and intramural thrombosis.

If MRI not diagnostic, CTA or MRA may show lesions. DSA remains the gold standard.

Venous thrombosis

Difficult diagnosis to make clinically and radiologically.

- CT scan reveals:
 - local or diffuse swelling;
 - hyperintense venous sinuses and cortical veins;
 - parenchymal lesions—often multiple, low attenuation lesions with oedema and haemorrhage (high density). Thalami and basal ganglia involved if internal cerebral veins thrombosed. SAH may be present.
- Contrast-enhanced CT: enhancement of dural sinuses around non-enhancing expanded thrombus ('delta sign').
- CT venogram demonstrates filling defects and expansion of thrombosed sinuses.
- MRI shows:
 - acute: absent flow void in dural sinus (isointense on T1W but hypointense on T2W (mistaken for flow void). Subacute: sinus hyperintense on T1W and T2W.
 - parenchymal lesions are hyperintense on T2W/FLAIR with oedema ± haemorrhage ± enhancement ± swelling local or diffuse.
- MRV shows loss of flow, or irregularity or severe narrowing indicating thrombus.
- Some cases may require DSA for further evaluation.

- Multiple modalities may be required to make a diagnosis.
 - Prominence of oedema prior to and around haemorrhages suggests venous hypertension.
 - Degree of normal variation in the size of the lateral sinuses and cortical veins makes interpretation difficult.

Cerebral vasculitis

- Typically, the appearances are non-specific with periventricular, subcortical white matter hyperintensities with or without evidence of cortical infarcts and haemorrhagic foci.
- Intracranial MRA is only useful for visualization of the large circle of Willis vessels.
- Catheter angiography is the most sensitive modality with multiple luminal irregularities, narrowings, occlusions, and sometimes aneurysms.

This page intentionally left blank

Subarachnoid haemorrhage

Diagnosis of SAH

Non-enhanced CT positive in 95% within the first 24 hours. Sensitivity decreases with time so that at 1 week < 50% positive. Imaging features include the following:

- Blood (high density) in subarachnoid space \pm intraparenchymal \pm subdural space.
- Distribution of blood indicates site of aneurysm:
 - predominant Sylvian fissure \pm temporal lobe = MCA;
 - symmetric distribution or marked involvement of anteroinferior interhemispheric fissure or medial frontal lobe = ACom artery;
 - lateralization in suprasellar, prepontine, ambient cisterns \pm tentorial subdural component = PCom artery;
 - prepontine and 4th ventricle = PIC artery;
 - interhemispheric subdural = pericallosal artery;
 - perimesencephalic haemorrhage, i.e. blood in prepontine, interpeduncular, and ambient cisterns, = venous aetiology.
- Early communicating hydrocephalus is typical.
- Low attenuation areas may indicate ischaemia from vasospasm.

MRI T1W and T2W are relatively insensitive; FLAIR is the best sequence with hyperintensity in the subarachnoid space. Hypointense on T2*.

Differential diagnosis

- Leptomeningeal infection.
- Inflammation.
- Infiltration.
- Propofol anaesthetic.

Investigation of cause of SAH

- MRA and CTA detect aneurysms > 3 mm.
- Negative in 15–20% of cases of aneurysmal SAH.
- Aneurysms are multiple in 20% and these modalities should provide information on which is responsible as well as vasospasm.
- Phase contrast MRA removes effect of T1 shortening of blood.

DSA remains the gold standard.

- Greater sensitivity for aneurysms < 3 mm.
- Largest aneurysm with irregular contour ('nipple') will typically be responsible for the SAH.
- DSA identifies vasospasm accurately.
- However, negative in 7–10%.

Guidelines for imaging for SAH

- If non-enhanced CT positive \rightarrow CTA or DSA.
- If CTA positive \rightarrow surgery or DSA + endovascular coiling.
- If CTA negative \rightarrow DSA.
- If DSA positive \rightarrow surgery or endovascular coiling.
- If DSA negative \rightarrow may be due to vasospasm or large haematoma \rightarrow consider repeat DSA after an interval.

- If no vasospasm, probable perimesencephalic bleed requiring no further investigation.

Saccular aneurysms

- These are well defined extra-axial lobulated lesions that may present as a result of an SAH or size (> 2.5 cm).
- On CT, if patent, show up as hyperdense to brain tissue and enhancing with or without intramural calcification. If thrombosed, hyperdense lesion with calcification commonly.
- MRI shows variable signal due to slow or turbulent flow. 50% have flow void. Thrombosed lesions often hyperintense on T1W and hypotense on T2W images.
- Further investigation is with MRA or CTA or DSA.

Differential diagnosis

- Meningioma, especially in suprasellar region.
- Macroadenoma/suprasellar mass (especially hyperintense on T1W).
- CP angle AICA or PICA aneurysm.
- 3rd ventricular mass (basilar tip aneurysm).

Note. Differentiating an unruptured aneurysm from a mass, particularly if thrombosed, can be difficult. Aneurysm should always be considered in the differential of a mass in the classic sites.

Intracerebral haemorrhage

Guidelines

Non-enhanced CT and then:

- 1 If haematoma location and history typical of hypertension i.e. striato-capsular (65%), thalamus (20%), pons and cerebellum (10%), no further radiology necessary.
- 2 If atypical, contrast-enhanced MRI; T2* may give evidence of previous haemorrhagic lesions. Also consider MRV or CT venography.
- 3 If there is suspicion of an underlying vascular abnormality or an aneurysm, perform a DSA.
- 4 If initial investigations are unhelpful, repeat delayed MRI or DSA as the acute haematoma can obscure features.

Serial imaging features

Hyperacute (< 6 hours)

- Presence of oxyhaemoglobin, mass effect, and oedema.
- CT: hyperdense with low density elements ('swirl').
- MRI: T1W isointense, T2W hyperintense, T2* heterogeneous or hypointense.

Acute (6 hours to 3 days)

- Presence of deoxyhaemoglobin, mass effect, and oedema.
- CT: hyperdense.
- MRI: T1W isointense, T2W hypointense, T2* hypointense.

Early subacute (3 days to 1 week)

- Presence of cellular methaemoglobin, mass effect, and oedema.
- CT: hyperdense.
- MRI: T1W hyperintense, T2W hypointense, T2* hypointense.

Late subacute (1 week to 1 month)

- Free methaemoglobin, minimal mass effect, and oedema.
- CT: isodense with hypodense rim.
- MRI: T1W hyperintense, T2W hyperintense, T2* hypointense.

Chronic (months)

- Presence of hemosiderin. No mass effect or oedema.
- CT: hypodense.
- MRI: T1W, T2W, and T2* hypodense.

Note

Coagulopathy and severe anaemia result in isodense acute haematoma on CT. Rapidly accumulating haematomas may have fluid levels.

This page intentionally left blank

Guidelines for head injury

- No indication for SXR unless there is a penetrating injury or a depressed skull fracture.
- Non-enhanced CT \pm bone windows indicated if:
 - GCS $<$ 15;
 - history of LOC;
 - retrograde amnesia;
 - focal neurological deficit;
 - persistent headache and/or vomiting;
 - patients under the influence of alcohol or drugs.
- However, 5% of patients with GCS = 15 and no other abnormality will have an abnormal scan. There is pressure to perform CT in all cases of head injury.
- Brain imaging should be carried out early especially to manage mass lesions.
- Have a low threshold for re-imaging as intra- and extra-axial mass lesions may expand rapidly or insidiously.
- MRI is more sensitive for intrinsic and shallow extra-axial collections as well as diffuse brain injury.
- Consider cervical spine injury and appropriate imaging in all head injury patients.

This page intentionally left blank

Imaging strategies for cervical spine trauma

- MRI has revolutionized the diagnostic evaluation of spinal injuries.
- Plain radiography and CT remain the most practical and cost-effective methods of investigation in the acute situation.
- Early surgical intervention is aimed at stabilization of the vertebral column and decompression of the spinal canal.
- Appropriate imaging is critical.
- MR examination in the acute period is indicated in any patient who has a persistent neurological deficit after spinal trauma.
- Some centres perform cervical spine MRI in any unconscious patient with normal X-ray and CT to exclude ligamentous and disc injury.

Fig. 7.1 gives an algorithm for the use of imaging in cervical spine trauma.

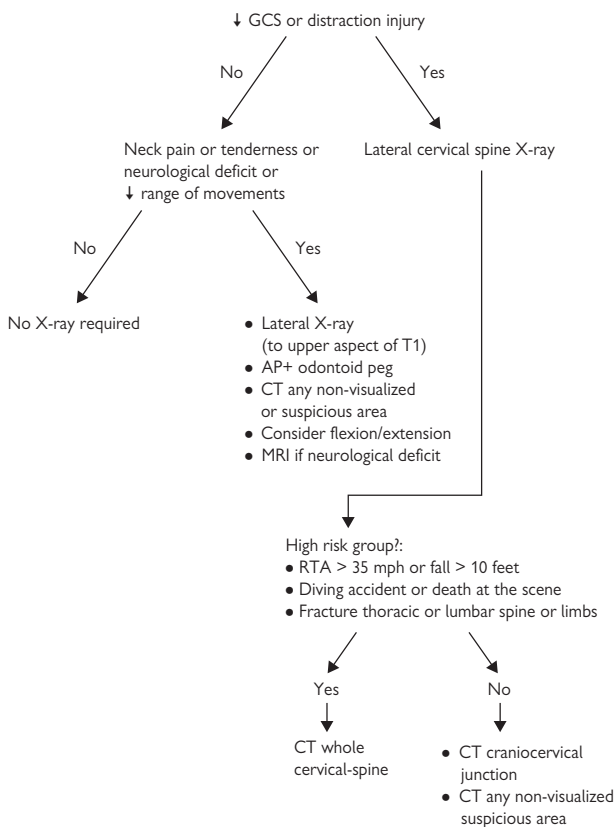


Fig. 7.1 Algorithm for the diagnosis of cervical spine trauma.

Guidelines for the neuroradiology of tumours

- 1 Is the lesion extra-axial or intrinsic? Extra-axial compartment involves extradural, sub- or intradural, and subarachnoid spaces (which also includes the basal cisterns and intraventricular spaces).
 - Extra-axial lesions:
 - pineal;
 - intraventricular;
 - cerebellopontine angle (CPA);
 - parasellar region;
 - foramen magnum;
 - skull base;
 - cavernous sinus;
 - meninges.
 - Intrinsic lesions:
 - corpus callosum;
 - mainly cortex;
 - deep grey structures;
- 2 Establish multiplicity. Metastases commonest cause of multiple lesions, but 50% of cases of metastatic disease present with a solitary lesion.
- 3 Evidence of mass effect. May be subtle with effacement of sulci or interhemispheric hemisphere, gyral or parenchymal distortion. Lesions other than tumours can cause mass effect:
 - acute ischaemic infarcts;
 - acute haematomas;
 - inflammatory masses;
 - demyelinating lesions ('tumefactive').
- 4 Other imaging characteristics:
 - surrounding oedema;
 - degree of definition;
 - presence of calcification (CT may be necessary);
 - degree and pattern of enhancement;
 - heterogeneity;
 - necrosis.
- 5 Consider alternative diagnoses—clinical input essential.
 - Multiple areas of abnormality can be due to: encephalitis; multifocal glioma; or acute embolic infarcts.
 - Differential diagnoses for ring-enhancing lesion: tumour; abscess; haematoma; aneurysm; or inflammatory lesion.
 - Remember lymphoma as a differential diagnosis.

This page intentionally left blank

CNS infections

Meningitis (acute viral, bacterial, or granulomatous, e.g. TB)

Suspected cases do not require imaging routinely unless:

- reduced level of consciousness;
- symptoms and signs of raised ICP;
- focal neurological signs;
- seizures.

Imaging features

CT and MRI may be normal.

- CT may reveal ventricular enlargement, effacement of the basal cisterns, high density subarachnoid space exudate. With contrast exudates may be more prominent and may show pial enhancement.
- MRI may show leptomeningeal enhancement. Other complications of meningitis include hydrocephalus, ventriculitis (ependymitis), abscess, or empyema formation. Vasculitis and venous thrombosis may sometimes be evident.

Differential diagnosis of meningeal thickening

- Metastatic disease including lymphoma.
- Sarcoidosis.
- Post-LP or shunting.

Encephalitis (herpes simplex)

Usually involves the limbic system: temporal lobe/insula/subfrontal region and cingulate gyrus.

Imaging features

CT and, less so, MRI may be normal at least initially.

- CT: grey matter + white matter, low attenuation with mass effect ± patchy enhancement.
- MRI more sensitive with bilateral changes detected earlier. Cytotoxic oedema ↓ T1W and ↑ T2W. Haemorrhage and necrosis later.

Differential diagnosis

- Infarction.
- Tumour.
- Limbic encephalitis (paraneoplastic).

HIV infection

HIV encephalopathy

Characterized by atrophy and ill defined white matter hyperintensity on T2W images. Usually bilateral, commonly frontal with no enhancement or mass effect. Differential diagnosis is PML or CMV encephalitis.

Opportunistic infections and tumours

Toxoplasmosis is the most common cause of mass lesions in HIV-infected patients. Ring-enhancing mass lesions with mass effect usually involving the basal ganglia and at the grey/white matter interface. Rarely, haemorrhagic. Differential diagnosis:

- primary CNS lymphoma (PCNSL);

- tuberculous abscesses or tuberculomata;
- fungal mass lesions.

Cryptococcal infection

- *Cryptococcus neoformans* is the commonest cause of meningitis in HIV patients.
- Imaging studies may be normal or show nodular leptomeningeal enhancement, basal ganglia hyperintensities (gelatinous pseudocysts), cryptococcomas (small parenchymal mass lesions), and hydrocephalus.

CMV

- Typically results in an ependymitis with nodular enhancement and periventricular oedema.
- CMV also causes a lumbosacral polyradiculopathy with nodular enhancement of the nerve roots. Differential diagnoses:
- lymphoma;
- neurosyphilis.

Progressive multifocal leucoencephalopathy (PML)

- Typically involves the parieto-occipital lobes with discrete lesions
↓ T1W and ↑ T2W images.
- There is little or no enhancement and no mass effect. CT reveals low attenuation lesions looking like ischaemic areas.

Parasitic infections – cysticercosis

- Imaging appearances vary with the stage of cyst formation with some individuals showing lesions of differing ages.
- Although usually multiple, solitary in 40%.
- Brain parenchymal lesions more common than intraventricular.
- Subarachnoid lesions in 10%. Grape-like clusters of cysts ('racemose') may mimic a tumour.

Cysts can be classified as follows.

- Vesicular: thin-walled cyst of CSF density on CT and MRI. Mural nodule represents the scolex. No enhancement or oedema.
- Colloidal vesicular: hyperdense cyst with enhancement and oedema on CT. On MRI, cyst is iso/hyperintense on T1W and hyperintense on T2W images.
- Granular nodular: involuting cyst is isodense on CT with calcifying scolex hyperdense. Reducing oedema and enhancement. On MRI isointense on T1W and hypodense on T2W.
- Nodular calcified: small calcified nodules on CT with no oedema or enhancement.

Other complications include obstructive hydrocephalus and meningitis.

Tuberculosis

TB meningitis

- CT scan: iso- or hyperdense exudates in the subarachnoid spaces with avid enhancement with contrast. Hydrocephalus common.
- MRI: basal cistern exudates are isointense on T1W, hyperintense on T2W. Thick nodular enhancement with gadolinium. Additional pathology such as arteritis causing ischaemic changes may also be seen.

Tuberculoma

- CT scan: solitary or multiple lesions of variable density develop from areas of low density cerebritis. Calcification uncommon (< 20%) implies old lesions. With contrast the 'target sign' = central enhancement with enhancing rim and a non-enhancing intervening portion and surrounding oedema.
- MRI: T2W hyperintense centre with hypointense rim, nodular enhancement, and oedema.

Differential diagnoses Abscesses, metastases, granulomatous lesions, e.g. sarcoidosis.

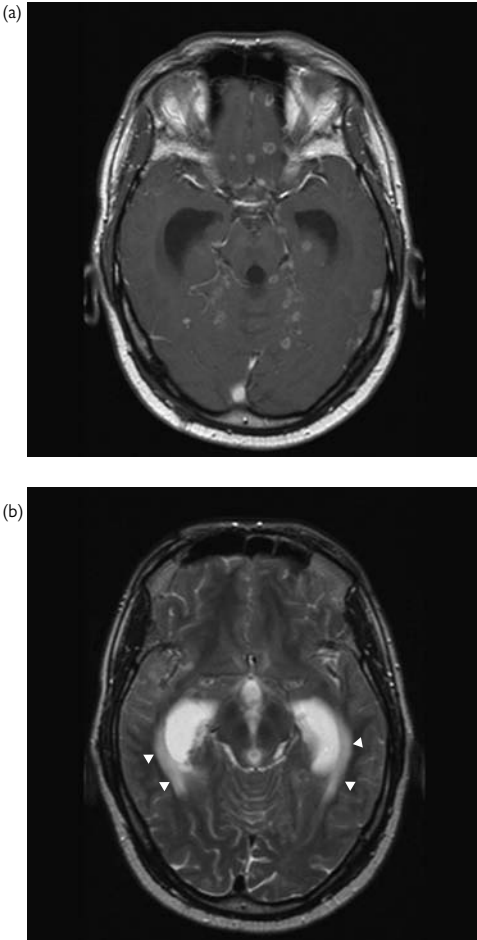


Fig. 7.2 Parenchymal TB. Axial (a) post-contrast-enhanced and (b) T2-weighted MRI. Multiple ring enhancing nodules in infra- and supratentorial compartments with surrounding white matter vasogenic oedema. Note meningeal involvement with obstructive hydrocephalus and periventricular transependymal interstitial oedema lateral to the grossly dilated temporal horns ((b) *white arrowheads*).

This page intentionally left blank

Appendices

1	Neurological disability scales	507
2	Clinical pearls	511
3	Neurological eponyms	515
4	Useful websites	523

This page intentionally left blank

Neurological disability scales

Box A1.1 Kurtzke expanded disability status scale (quantifies disability in multiple sclerosis)

- 1.0 No disability; minimal signs in one FS (functional system)
- 1.5 No disability; minimal signs in more than one FS
- 2.0 Minimal disability in one FS
- 2.5 Mild disability in one FS or minimal disability in two FS
- 3.0 Moderate disability in one FS, or mild disability in three or four FS. Fully ambulatory
- 3.5 Fully ambulatory but with moderate disability in one FS and more than minimal disability in several others
- 4.0 Fully ambulatory without aid; self-sufficient; up and about some 12 hours a day despite relatively severe disability; able to walk without aid or rest some 500 metres
- 4.5 Fully ambulatory without aid; up and about much of the day; able to work a full day; may otherwise have some limitation of full activity or require minimal assistance; characterized by relatively severe disability; able to walk without aid or rest some 300 metres
- 5.0 Ambulatory without aid or rest for about 200 metres; disability severe enough to impair full daily activities (e.g. work a full day without special provisions)
- 5.5 Ambulatory without aid or rest for about 100 metres; disability severe enough to preclude full daily activities
- 6.0 Intermittent or unilateral constant assistance (cane, crutch, brace) required to walk about 100 metres with or without resting
- 6.5 Constant bilateral assistance (canes, crutches, braces) required to walk about 20 metres without resting
- 7.0 Unable to walk beyond approximately 5 metres even with aid; essentially restricted to wheelchair; wheels self in standard wheelchair and transfers alone; up and about in wheelchair some 12 hours a day
- 7.5 Unable to take more than a few steps; restricted to wheelchair; may need aid in transfer; wheels self but cannot carry on in standard wheelchair a full day; may require motorized wheelchair
- 8.0 Essentially restricted to bed or chair or perambulated in wheelchair, but may be out of bed itself much of the day; retains many self-care functions; generally has effective use of arms
- 8.5 Essentially restricted to bed much of day; has some effective use of arms; retains some self-care functions
- 9.0 Confined to bed; can still communicate and eat
- 9.5 Totally helpless bedbound patient; unable to communicate effectively or eat/swallow
- 10.0 Death due to MS

Table A1.1 Barthel Index for chronic neurodisability*

Parameter	Finding	Points
Controlling bowels	Independent. Patient is able to control bowels and have no accidents	10
	Patient may occasionally have an accident or may require a suppository or enema	5
	Cannot meet defined criteria	0
Controlling bladder	Independent. Patient is able to control bladder day & night	10
	Patient may occasionally have an accident or cannot wait for a bedpan or is unable to get to the toilet in time	5
	Cannot meet defined criteria	0
Getting on & off toilet	Independent. Patient can get on and off toilet, adjust clothing, use toilet paper, and keep clothes from becoming soiled. The patient can use an object for support if needed	10
	With help	5
	Cannot meet defined criteria	0
Feeding	Independent. Patient can feed self if food is placed within reach. The patient may use an assistive device if needed. Eating needs to be accomplished within a reasonable time	10
	Some help is needed such as cutting up food	5
	Cannot meet defined criteria	0
Moving from wheelchair to bed and return	Independent in all phases of the activity	15
	With some minimal help or some supervision	10
	Requires assistance	5
	Cannot meet defined criteria	0
Walking on level surface	Independent. Patient can walk at least 50 yards without help or supervision	15
	With help	10
	Unable to walk but can propel a wheelchair independently	5
	Unable to walk and unable to propel a wheelchair	0
Dressing	Independent	10
	With help	5
	Cannot meet defined criteria	0

Table A1.1 (Contd.)

Parameter	Finding	Points
Ascend & descend stairs	Independent. Patient is able to go up and down a flight of stairs safely without supervision or help	10
	With help	5
	Cannot meet defined criteria	0
Grooming	Patient can wash, comb hair, and brush teeth. Men can shave themselves and women can apply makeup	5
	Cannot meet defined criteria	0
Bathing self	Patient may use a bath tub, shower, or take a complete sponge bath unassisted	5
	Cannot meet defined criteria	0

* Barthel Index = sum of points for all 10 items (minimum score 0, maximum 100).

Table A1.2 Modified Hoehn and Yahr scale

Stage of disease	Description of severity of disease
1	Unilateral involvement only
1.5	Unilateral and axial involvement
2	Bilateral involvement without impairment of balance
2.5	Mild bilateral involvement with recovery on pull test
3.0	Mild to moderate involvement; some postural instability but physically independent
4.0	Severe disability; able to walk and stand unassisted
5.0	Wheelchairbound or bedridden unless aided

Table A1.3 Rankin stroke disability scale

Scale	Description of severity of disease
1	Able to carry out all activities of daily living. Almost no disability
2	Slight disability. Self-caring. May not be able to carry out all activities of daily living
3	Moderate disability. Able to walk without an assistant or with a stick. Requires some help in daily tasks
4	Moderately severe disability. Needs an assistant to walk. Needs help with toileting and other activities
5	Severe disability. Bedbound and incontinent, requiring continuous nursing care

Clinical pearls

These are useful clinical vignettes that have been collected on ward rounds and at clinical meetings, but never seem to enter the textbooks. The following are personal favourites (HM and AW).

- **Absent ankle jerks, extensor plantars**

Causes:

- B₁₂ deficiency;
- Friedreich's ataxia;
- HIV (neuropathy + myelopathy);
- spinal AVM;
- cervical and lumbar spondylosis;
- syphilis (taboparesis).

- **Beevor's sign:** movement of the umbilicus on attempting to sit up indicates weakness of the abdominal muscles away from direction of movement. Causes:

- muscular dystrophy;
- thoracic radicular muscle weakness.

- **Cluster headache**

- Patients are restless and walk around, whereas migraine sufferers prefer to lay still.
- May experience unilateral photophobia ipsilateral to headache.

- **Downbeat nystagmus:** usually evident on lateral gaze.

Causes:

- foramen magnum lesion;
- Arnold–Chiari malformation;
- tumour;
- syringobulbia/myelia;
- cerebellar degeneration.

- **Dropped finger** when hands held outstretched and pronated.

Causes:

- anterior horn cell disease (MND, syringomyelia);
- multifocal motor neuropathy with block;
- transiently in brachial neuritis;
- ruptured tendon as in rheumatoid arthritis.

- **Foot drop**

Causes:

- common peroneal nerve lesion (inversion preserved);
- L5 root lesion (inversion affected);
- cortical lesion (extensor plantar);
- cord lesion;
- sciatic nerve lesion (common peroneal nerve fibres selectively affected);
- rarely, myopathic cause, e.g. IBM, or MG;
- consider dystonia if no weakness.

- **Functional coma or status epilepticus**
 - Elevate one arm over the face and drop. In patients with retained consciousness the arm will fall to one side missing the face. In true coma the arm will fall on to the face.
 - Insert a vibrating tuning fork gently into one nostril. Very unpleasant and unexpected stimulus and will wake most non-organic patients.
- **Headache.** Red flags suggesting serious underlying disorder:
 - systemic symptoms: fever, weight loss;
 - risk factors: HIV, cancer;
 - focal neurological signs;
 - sudden onset (thunderclap);
 - age > 50 years (giant cell arteritis);
 - previous headache with change in character, severity, or resistant to therapy.
- **Head thrust test (Halmaygi).** If positive indicates lateral semicircular canal dysfunction.
- **Hoover's sign.** When assessing hip flexion on one side, test for counterextension on the contralateral side. If absent, indicates inadequate effort.
- **Internuclear ophthalmoplegia**
Causes:
 - MS;
 - pontine stroke;
 - MG (pseudo-INO);
 - Wernicke's encephalopathy.
- **Jaw supporting sign.** Indicative of neck flexion weakness especially in MG.
- **Lhermitte's sign.** Neck flexion results in paraesthesiae down the spine or arms. Causes:
 - MS;
 - cervical spondylosis (occasionally, reversed with neck extension);
 - B₁₂ deficiency;
 - cervical cord tumour;
 - cisplatin;
- **Lumbar canal stenosis.** Patients can cycle for miles but develop pain and weakness after walking a few yards. In the flexed trunk position the AP diameter is increased.
- **Lumbar puncture.** Technically this is much easier to perform with the patient sitting and leaning forward over a bed tray/trolley with pillows. However, this position is not suitable if it is necessary to measure the opening pressure.
- **Neck flexion extension weakness**
Causes:
 - myopathy;
 - MG;
 - MND;
 - myotonic dystrophy;
 - Guillain-Barré syndrome.

- **Parkinson's disease.** Reconsider diagnosis if:
 - early falls, especially backwards (PSP);
 - early dysarthria and dysphagia (PSP);
 - early autonomic dysfunction (MSA);
 - marked antecollis (MSA);
 - rapid decline: 'wheelchair sign';
 - early cognitive dysfunction (DCLB);
 - apraxia, myoclonus (CBD).
- **Sensory levels** in spinal cord lesions may be inaccurate, e.g. cervical myelopathy may be result in thoracic sensory level.
- **Shoulder shrug.** In hemiplegic or hemirigid (as in Parkinsonism) patients, a weak or delayed shrug implies intracerebral lesion rather than spinal cord lesion. Innervation of upper trapezius fibres located C1–C5 and are rarely all involved in cervical cord lesions.

This page intentionally left blank

Neurological eponyms

Adie pupil: large pupil reacting slowly to light and accommodation. W.J. Adie, English neurologist .

Alzheimer's disease: commonest cause of dementia. A. Alzheimer, German neurologist who collaborated with Nissl, Erb, and Kraepelin.

Anton's syndrome: visual anosognosia. G. Anton, Austrian neurologist.

Argyll-Robertson pupil: syphilitic pupil that 'accommodates but doesn't react'. D. Argyll-Robertson, Scottish physician and golfer.

Arnold-Chiari syndrome: congenital inferior displacement of cerebellar tonsils. J. Arnold/H. Chiari, German/Austrian pathologists.

Babinski sign: stroking lateral aspect of sole resulting in plantar extension of big toe. J. Babinski-Polish neurologist, pupil of Charcot.

Bassen-Kornzweig disease: ataxia, retinitis pigmentosa, abetalipoproteinemia. F. Bassen/H. Kornzweig, US physician/ophthalmologist.

Battle's sign: bruising over mastoid suggesting fractured base of skull. W. Battle, English surgeon.

Becker muscular dystrophy/myotonia congenita. P. Becker, German geneticist.

Beevor's sign: excessive displacement of umbilicus on attempted sit-up due to weakness of abdominal musculature. C. Beevor, English neurologist.

Bell's palsy: idiopathic lower motor neuron paralysis of facial nerve. C. Bell, Scottish surgeon, accomplished artist, founder of the Middlesex Hospital.

Benedikt's syndrome: ipsilateral oculomotor palsy with contralateral ataxia. M. Benedikt, Austrian physician and soldier.

Berry aneurysm. J. Berry, English surgeon.

Binswanger's dementia: widespread cerebral small vessel disease. O. Binswanger, German psychiatrist.

Bourneville's disease: tuberous sclerosis. D. Bourneville, French neurologist.

Broca's aphasia: expressive aphasia. P. Broca, French surgeon and Darwinist.

Brodman areas: cytoarchitectural map of the brain. K. Brodmann, German neurologist.

Brown-Sequard syndrome: hemi-transection of the cord leading to ipsilateral paralysis and impairment of light touch, joint position and vibration sense with contralateral impairment of temperature and pinprick sensation. C. Brown-Sequard, Mauritian neurologist, peripatetic, with eccentric ideas about testicular extracts.

Canavan's disease: infantile dysmyelination with macrocephaly. M. Canavan, US pathologist.

Charcot-Marie-Tooth disease: peroneal muscular atrophy/HMSN. J. Charcot, French neurologist. Described multiple sclerosis, MND, and ankle clonus. Taught P. Marie, Babinski, and Freud. P. Marie, French neurologist. H. Tooth, English physician, keen musician, and carpenter.

Cheyne-Stokes breathing: alternating hyperpnoea and apnoea. J. Cheyne, Scottish physician.

Chvostek's sign: tapping skin over facial nerve induces muscle twitching; seen in tetany and anxiety. F. Chvostek, Austrian surgeon.

Claude syndrome: ipsilateral oculomotor palsy with contralateral ataxia and chorea due to lesion in red nucleus. H. Claude, French neurologist and colleague of Lhermitte.

Cockayne syndrome: dwarfism, microcephaly, dermatitis, deafness, pyramidal and cerebellar signs. E. Cockayne, English paediatrician and entomologist.

Collet-Sicard syndrome: jugular foramen syndrome involving ninth to twelfth cranial nerves). F. Collet, French otolaryngologist.

Creutzfeldt-Jakob disease: rapid onset dementia due to abnormal prion protein). A. Jakob, German neuropathologist. H. Creutzfeldt, German pathologist.

Dandy-Walker syndrome: maldevelopment of foramina of Luschka and Magendie leading to hydrocephalus. W. Dandy, US neurosurgeon and temporary assistant to Cushing. A. Walker, US neurosurgeon.

Dejerine-Klumpke syndrome: lower brachial plexus palsy (waiter's tip sign). A. Dejerine-Klumpke, French neurologist.

Dejerine anterior bulbar palsy: anterior spinal artery occlusion; Dejerine-Landouzy dystrophy (FSH); Dejerine-Sottas neuropathy (HMSN III); and Dejerine-Thomas atrophy (OPCA). J. Dejerine, French neurologist and amateur boxer.

Dercum's disease: lipomas and neuropathy. F. Dercum, US neurologist.

Devic's disease: optic neuritis and myelopathy. E. Devic, French physician.

Duane's syndrome: developmental anomaly leading to contraction of the globe and narrowing of the palpebral fissure on attempted abduction of the affected eye. A. Duane, US ophthalmologist.

Duchenne muscular dystrophy: X-linked muscular dystrophy. G. Duchenne eccentric, peripatetic French neurologist who invented the punch muscle biopsy.

Eaton–Lambert myasthenic syndrome: weakness, post-tetanic facilitation, associated with voltage-gated calcium channel antibodies. L. Eaton, US neurologist. E. Lambert, US neurophysiologist.

Edinger–Westphal nucleus: autonomic nucleus of oculomotor nerve. L. Edinger, German neurologist and hypnotist. C. Westphal, German neurologist who described Wilson's disease, the deep tendon reflex, and periodic paralysis. Mentored Pick and Wernicke.

Ekbom's syndrome: restless legs or delusional parasitosis. K. Ekbom, Swedish neurologist.

Erb–Duchenne paralysis: upper brachial plexus palsy. W. Erb, German neurologist and keen advocate of the tendon hammer.

Fabry's disease: angiokeratoma, painful neuropathy, stroke, acroparaesthesiae, and renal failure. J. Fabry, German dermatologist.

Fazio–Londe syndrome: ponto-bulbar atrophy. E. Fazio, Italian physician. P. Londe, French neurologist.

Foix–Alajouanine syndrome: subacute necrotizing myelopathy. C. Foix, French neurologist and lyricist. Pupil of Marie. T. Alajouanine, French neurologist.

Foster Kennedy syndrome: optic atrophy and contralateral papilloedema associated with frontal tumours. F. Kennedy, Irish neurologist.

Fothergill disease: trigeminal neuralgia. J. Fothergill, English physician and abolitionist who coined the phrase 'I climbed on the backs of the poor to the pockets of the rich'.

Foville syndrome: gaze palsy, facial palsy and contralateral hemiplegia due to lesion in the pons. A. Foville, French neurologist and Director of Asylums.

Friedreich's ataxia: autosomal recessive spinocerebellar degeneration. N. Friedreich, German neurologist, pupil of Virchow.

Froin's syndrome: high CSF protein secondary to spinal 'block'. G. Froin, French physician.

Froment's sign: flexion of thumb on attempting to hold a sheet of paper between index finger and thumb due to weakness of adductor pollicis. J. Froment, French physician.

Gelineau disease: narcolepsy. J. Gelineau, French physician.

Gerstmann's syndrome: right–left confusion, acalculia, finger agnosia due to dominant parietal lesion. J. Gerstmann, US neuropsychiatrist.

Gilles de la Tourette syndrome: tics. G. Gilles de la Tourette, French neurologist and pupil of Charcot.

Gordon reflex: compression of calf resulting in extension of the big toe in pyramidal lesions. A. Gordon, French neurologist.

Gowers' manoeuvre: inability to stand from sitting without using arms. W. Gowers, English neurologist and stenographer.

Gradenigo's syndrome: pain, deafness, and lateral rectus palsy. C. Gradenigo, Italian otolaryngologist.

Greenfield disease: metachromatic leucodystrophy caused by deficiency of aryl sulphatase A. J. Greenfield, English neuropathologist.

Guillain–Barré syndrome: acute demyelinating neuropathy. C. Guillain, French neurologist. J. Barré, French neurologist and colleague of Babinski.

Hallervorden–Spatz disease: autosomal recessive disorder with rigidity, dementia, and optic atrophy. J. Hallervorden, German neurologist and Nazi. H. Spatz, German neurologist.

Heidenhain variant: CJD with blindness. A. Heidenhain, German neurologist.

Hoffman syndrome: muscle hypertrophy and weakness seen in hypothyroidism. J. Hoffman, German neurologist.

Holmes' tremor: midbrain tremor. G. Holmes, Irish neurologist, keen gardener and golfer.

Hoover's sign: manoeuvre that may distinguish organic from hysterical hemiplegias. C. Hoover, US physician.

Horner's syndrome: ptosis and meiosis due to sympathetic lesion. J. Horner, Swiss ophthalmologist who also established that red–green colour blindness was X-linked.

Huntington's disease: autosomal dominant neurodegenerative disease characterized by dementia and chorea. G. Huntington, US general practitioner.

Ishihara plates: test for colour blindness. S. Ishihara, Japanese ophthalmologist.

Jacksonian seizure: simple partial motor seizure. J. Hughlings Jackson, English neurologist and popularizer of the ophthalmoscope.

Jacod syndrome: optic atrophy, ophthalmoplegia, and trigeminal neuralgia due to lesion in petrosphenoid space. M. Jacod, French neurologist.

Jendrassik manoeuvre: reinforcement of deep tendon reflexes. E. Jendrassik, Hungarian physician.

Kayser–Fleischer ring: brown pigment in iris indicative of copper deposition in Wilson's disease. B. Kayser, German ophthalmologist. R. Fleischer, German physician.

Kernig's sign: flexion of the thigh and extension of the lower limb causing pain in the hamstrings in meningeal irritation. V. Kernig, Russian physician.

Kernohan syndrome: herniation of the temporal lobe causing traction on the contralateral cerebral peduncle and false localization as the weakness is in the ipsilateral limbs. J. Kernohan, Irish pathologist.

Korsakoff's psychosis: loss of short-term memory usually due to alcoholism. S. Korsakoff, Russian neuropsychiatrist and humanist.

Kozhevnikov epilepsy: *epilepsia partialis continua*. A. Kozhevnikov, Russian neurologist and teacher of Korsakoff.

Krabbe's disease: globoid leucodystrophy. K. Krabbe, Danish neurologist.

Kufs' disease: ceroid neuronal lipofuscinosis. H. Kufs, German neurologist.

Kugelberg–Welander syndrome: spinal muscular atrophy (SMA), autosomal recessive, proximal anterior horn cell disorder. E. Kugelberg, M. Welander, Swedish neurologists.

Lafora body disease: progressive myoclonic epilepsy. G. Lafora, Spanish physician.

Lasegue's sign: pain and spasm induced by straight leg raising in patients with lumbar pathology. E. Lasegue, French physician and flatmate of Claude Bernard.

Laurence–Moon–Biedl syndrome: retinitis pigmentosa, hypogonadism, and polydactyly. J. Laurence, English ophthalmologist. R. Moon, US ophthalmologist. A. Biedl, Czech physician.

Leber's optic atrophy: mitochondrial disease causing optic atrophy. T. von Leber, German ophthalmologist.

Leigh's syndrome: subacute necrotizing white matter disease of childhood. D. Leigh, English neuropathologist.

Lennox–Gastaut syndrome: myoclonic and atonic seizures of childhood. W. Lennox, US neurologist. H. Gastaut, French neurobiologist.

Lhermitte's sign: flexion of the neck causing electric shock-like sensation in cervical myelopathy. J. Lhermitte, French neurologist and theologian.

Luschka foramen: foramen of fourth ventricle. H. von Luschka, German anatomist.

Luysian bodies: subthalamic and thalamic nuclei. J. Luys, French neurologist and hypnotist.

Magendie foramen: fourth ventricular foramen. F. Magendie, French physiologist and vivisectionist.

Marchiafava–Bignami syndrome: degeneration of corpus callosum usually due to alcoholism. E. Marchiafava, Italian neurologist. A. Bignami, Italian physician.

Marcus Gunn pupil: afferent pupillary defect. R. Marcus Gunn, Scottish ophthalmologist and fossil collector.

Melkersson–Rosenthal syndrome: facial palsy and fissured tongue. E. Melkersson, Swedish physician. C. Rosenthal, German neurologist.

Millard–Gubler syndrome: pontine lesion leading to facial and abducens palsies with contralateral hemiplegia. A. Millard, French physician. A. Gubler, French physician and botanist.

Miller Fisher syndrome: variant of Guillain–Barré syndrome characterized by ophthalmoplegia, ataxia, and areflexia. M. Fisher, Canadian neurologist.

Mollaret meningitis: recurrent aseptic meningitis. P. Mollaret, French physician.

Monakow syndrome: hemiplegia, hemianaesthesia, and hemianopia due to thrombosis of the anterior choroidal artery. C. von Monakow, Russian neurologist.

Moniz sign: forced plantar flexion of the ankle leading to extension of the toes in pyramidal tract disease. A. Moniz, Portuguese neurologist and co-signatory to the Treaty of Versailles.

Foramen of Monro: (foramen between lateral and third ventricles). A. Monro, Scottish anatomist.

Mott's law of anticipation: hereditary diseases appearing earlier in successive generations. F. Mott, English neuropathologist.

McArdle's syndrome: glycogen storage disease type V. B. McArdle, English neurologist.

MacCormac reflex: crossed adduction of contralateral thigh induced by eliciting the knee jerk in pyramidal tract disease. W. MacCormac, Irish surgeon.

Naffziger test: pressure on the jugular vein causes increased CSF pressure. H. Naffziger, US neurosurgeon.

Niemann–Pick disease: organomegaly and progressive dementia. A. Niemann, German paediatrician. L. Pick, German pathologist.

Nothnagel syndrome: ipsilateral oculomotor palsy and ataxia. H. Nothnagel, Austrian physician.

Ondine's curse: centrally mediated apnoea. Ondine, a legendary water nymph.

Oppenheim reflex: stroking medial side of tibia leading to extension of the great toe in pyramidal tract lesions H. Oppenheim, German neurologist.

Pancoast syndrome: T1 root lesion usually caused by tumour at lung apex. H. Pancoast, US radiologist.

Parinaud's syndrome: dorsal midbrain lesion leading to failure of upgaze and light–near dissociation. H. Parinaud, French ophthalmologist.

Parkinson's disease: paralysis agitans J. Parkinson, English physician and pamphleteer. His house in Hoxton Square is now a nightclub.

Pick's disease: fronto-temporal dementia. A. Pick, Czech physician and music lover.

Pringle disease: tuberous sclerosis. J. Pringle, English dermatologist.

Purkinje cells: cells of the cerebellar cortex. J. Purkinje, Bohemian physiologist and nationalist.

Queckenstedt test: compression of the internal jugular vein during a lumbar puncture to test patency of the subarachnoid space. H. Queckenstedt, German neurologist.

Radovici's sign: palmo-mental reflex. J. Radovici, Romanian neurologist.

Ramsay-Hunt syndrome: myoclonic ataxia or facial nerve palsy induced by herpes zoster. J. Ramsay-Hunt, US neurologist.

Raymond syndrome: abducens palsy and contralateral hemiplegia. F. Raymond, French neurologist and successor to Charcot.

Recklinghausen's disease: neurofibromatosis type I. F. von Recklinghausen, German pathologist.

Refsum's disease: retinitis pigmentosa, anosmia, neuropathy, and syndactyly caused by accumulation of phytanic acid. S. Refsum, Norwegian physician.

Riley-Day syndrome: familial dysautonomia. C. Riley, R. Day, US paediatricians.

Rolando fissure: central cerebral sulcus. L. Rolando, Italian anatomist and physician to Maria Theresa.

Romberg's sign: seen in vestibular disease and sensory ataxia where a patient cannot remain standing on eye closure. M. Romberg, German neurologist.

Sauvigney ophthalmoplegia: internuclear ophthalmoplegia. C. Sauvigney, French ophthalmologist and assistant to Parinaud.

Schwannoma: neurilemmoma. F. Schwann, German anatomist and Jesuit.

Sherrington's law: each posterior spinal nerve supplies its own dermatome. C. Sherrington, English neurophysiologist and Nobel prize winner.

Shy-Drager syndrome: multiple system atrophy. G. Shy, G. Drager, US neurologists.

Sjögren-Larsson syndrome (ichthyosis, ataxia, and mental retardation). T. Sjögren, T. Larsson, Swedish neurologists.

Snellen chart: visual acuity chart. H. Snellen, Dutch ophthalmologist.

Steele-Richardson-Olszewski syndrome: progressive supranuclear palsy. J. Steele, J. Richardson, J. Olszewski, US neurologists.

Steinert disease: myotonic dystrophy. H. Steinert, German physician.

Stellwag sign: infrequent blinking in Parkinson's disease. C. Stellwag, Austrian ophthalmologist.

Strachan's syndrome: painful neuropathy and deafness. W. Strachan, Scottish physician.

Sturge-Weber syndrome: neurocutaneous syndrome. W. Sturge, English physician and liberal. F. Weber, English physician and collector.

Sydenham's chorea: post-infectious chorea. T. Sydenham, English physician and roundhead.

Sylvian aqueduct: cerebral aqueduct. F. Sylvius, Dutch physician.

Tapia syndrome: paralysis of vagus and hypoglossal nerves. A. Tapia, Spanish physician.

Tay–Sachs disease: progressive dementia and retinal cherry red spot caused by hexosaminidase A deficiency. W. Tay, English ophthalmologist and keen cyclist. B. Sachs, German physician.

Thomsen's disease: autosomal dominant myotonia congenita. A. Thomsen, Danish physician and sufferer of the disease.

Tinel's sign: tapping over carpal tunnel resulting in tingling in median nerve distribution. J. Tinel, French neurologist and member of the Resistance.

Todd's paresis: transient weakness following a focal epileptic seizure. R. Todd, Irish physician.

Tolosa–Hunt syndrome: orbital pseudotumour. E. Tolosa, Spanish neurosurgeon. W. Hunt, US neurosurgeon.

Turcot syndrome: familial intestinal polyps and gliomas. J. Turcot, Canadian surgeon.

Unverricht–Lundborg disease: Baltic myoclonus. H. Unverricht, German physician. H. Lundborg, Swedish physician.

Vernet's syndrome: paresis of glossopharyngeal, vagal, and accessory nerves. M. Vernet, French neurologist.

Villaret's syndrome: paresis of glossopharyngeal, vagal, accessory, and hypoglossal nerves with additional sympathetic involvement. M. Villaret, French neurologist.

Vogt–Koyanagi–Harada syndrome: poliosis, deafness, uveitis and meningitis. A. Vogt, Swiss ophthalmologist. Y. Koyanagi, E. Harada, Japanese ophthalmologists.

Von Hippel–Lindau disease: cerebellar haemangioblastomas with retinal and renal angiomas. E. von Hippel, German ophthalmologist. A. Lindau, Swedish pathologist.

Wallenberg's syndrome: posterior inferior cerebellar artery thrombosis. A. Wallenberg, German neurologist.

Wallerian degeneration: degeneration of nerve fibre following axonotmesis. A. Waller, English physiologist.

Weber's syndrome: ipsilateral oculomotor palsy with contralateral hemiplegia due to midbrain lesion. H. Weber, German physician and founder of climatotherapy.

Werdnig–Hoffman disease: spinal muscular atrophy. G. Werdnig, Austrian neurologist. J. Hoffman, German neurologist.

Wernicke's encephalopathy: ophthalmoplegia, delirium, and ataxia due to thiamine deficiency. K. Wernicke, German physician.

West syndrome: infantile spasms. W. West, English physician.

Wilks syndrome: myasthenia gravis. S. Wilks, English physician.

Circle of Willis: arterial anastomosis at base of brain. T. Willis, English physician and Royalist.

Wilson's disease: hepatolenticular degeneration. S. Kinnier Wilson, US neurologist who advised 'never believe what the patient says the doctor said'.

Useful websites

Association of British Neurologists	www.theabn.org
Alzheimer's Society	www.alzheimers.org.uk
Ataxia	www.ataxia.org.uk
Brain and Spine Foundation	www.brainandspine.org.uk
British Association for the Study of Headache	www.bash.org.uk
British Epilepsy Association	www.epilepsy.org.uk
CMT International	www.cmt.org.uk
Driving and Licensing Authority	www.dvla.gov.uk
Directory of Genetic Disorders	www.geneclinics.org/
Dystonia Society	www.dystonia.org.uk
Encephalitis Support Group	www.esg.org.uk
Gene testing laboratories in UK	www.cmgs.org
Genetic Diseases	www.equip.nhs.uk
Guillain–Barré Syndrome Support	www.gbs.org.uk
ME Association	www.meassociation.org.uk
Migraine Trust	www.migrainetrust.org
Motor Neurone Disease Association	www.mndassociation.org
Multiple sclerosis society	www.mssociety.org.uk
Multiple System Atrophy	www.msaweb.co.uk
Muscular Dystrophy Campaign	www.muscular-dystrophy.org
Myasthenia Gravis Association	www.crabby.demon.co.uk/mga

Myotonic Dystrophy	www.mdsguk.org
Narcolepsy Association	www.narcolepsy.org.uk
National Society for Epilepsy	www.epilepsynse.org.uk
National Tremor Foundation	www.tremor.org.uk
Neurofibromatosis Association	www.nfa-uk.org.uk
Neuropathy Trust	www.neuropathy-trust.org
OUCH (cluster headache)	info@ouch-uk.org
Parkinson's Disease Society UK	www.parkinsons.org.uk
PSP association	www.PSPeur.org.uk
Scope (cerebral palsy)	www.scope.org.uk
Stroke Association uk	www.stroke.org
Tourette Association	www.tsa.org.uk
Trigeminal Neuralgia	www.tna-support.org and www.tna-uk.org.uk
Wilson's support group	secretary@wilsons-disease.org.uk
Tuberous Sclerosis	www.tuberous-sclerosis.org.uk

Index

A

- abducens nerve 12–15
- abetalipoproteinaemia 75, 286
- abscess, intracranial 305
- accessory nerve 17
- accommodation reflex 10
- acoustic nerve 16
- acoustic neuroma 357–8
- acquired immune deficiency syndrome (AIDS) 296
 - see also HIV
- action tremor 90
- acute cord injury 392
- acute disseminated encephalomyelitis (ADEM) 234, 293
- acute extraaxial haematoma 390
- acute subdural haematoma (ASDH) 381
- adrenoleucodystrophy 286
- AIDS 296
 - see also HIV
- alternating hand movements 25–6, 27
- Alzheimer's disease 126–7, 128–9, 282
- amantadine, Parkinson's disease 182
- amaurosis fugax 76
- aneurysms, cerebral 334–6
- anterior horn cell disorder 65
- anterior ischaemic optic neuropathy (AION) 76–7
- anterior spinal artery syndrome 65
- anterograde memory, testing 24
- anticholinergic agents, Parkinson's disease 182
- antidromic nerve conduction studies 446–8
- Anton's syndrome 77
- aphasia 26
- apomorphine therapy, Parkinson's disease 181
- aqueduct stenosis 415–16, 423
- arachnoid cysts 414
- arginase deficiency 286
- Argyll Robertson pupil 11
- arrested hydrocephalus 344
- arterial dissection, neuro-radiology 487
- arteriovenous malformations (AVMs), cerebral 338–9
- astrocytoma 364, 367
- ataxia 72–5, 248
 - hereditary 266
 - with oculomotorapraxia type 1 75
 - with vitamin E deficiency 75
- ataxia telangiectasia 75
- atheroembolism 110
- atheromatous extracranial vessels, imaging of 486–7
- athetosis 96
- atlanto-occipital dislocation 392
- atrial fibrillation 119
- attention, testing 24
- autonomic neuropathy 250
- autosomal dominant cerebellar ataxias (ADCAs) 72–5, 266, 267
- axillary nerve 42
- axonal neuropathies, NCS abnormalities 450
- azathioprine, myasthenia gravis 240–3

B

- bacterial meningitis 288–91
- Barthel Index for chronic neurodisability 508
- basal ganglia disorders 256
- basal skull fractures 383
- Becker's muscular dystrophy (BMD) 272–3
- Beevor's sign 519–21
- benign intracranial hypertension 166–7
- benign paroxysmal positional vertigo (BPPV) 254–5, 258–61
- berry aneurysms 334–5

- bilateral facet dislocation 410
- bilateral scotomas 9
- bilateral, transient visual loss 76
- binasal hemianopia 9
- biochemical studies, muscle disorders 216
- bitemporal hemianopia 9
- bladder dysfunction, multiple sclerosis 236–7
- blindness 9
- botulism 65
- brachial plexus 38
- brain cross-sections 52, 53
- brain death
 - diagnosis 314
 - somatosensory evoked potentials 472
- brainstem auditory evoked responses (BAERs) 474–5
- brainstem myoclonus 99
- breast feeding and epilepsy 143
- Broca's aphasia 26
- Brown-Vialetto-Von Laere syndrome 225
- Bruns–Garland syndrome 200–1
- burr holes 351–3

C

- C1 fracture 392, 393
- C2 fracture 392, 393–4, 399
- C3–C7 fractures 394
- CADASIL 130, 148
- cardiac arrest 444
- carotid artery
 - dissection 121
 - internal 120
- carotid artery Doppler 480–1
- carotid cavernous fistula (CCF) 342–3
- carotidynia 148–9
- catheter angiography 482–3
 - cerebrovascular disease 486–7, 488
- cavernoma, intramedullary 386

- cavernous haemangiomas (cavernomas) 340
- central nervous system infections, neuro-radiology 498
- cerebellar ataxias 72–5
- cerebellar degeneration 246
- cerebellar disease 72–5
- cerebellar disorder 256
- cerebellar ectopia 414–15
- cerebellar haemangioblastoma 368
- cerebral aneurysms 334–6
- cerebral arteriovenous malformations (AVMs) 338–9
- cerebral haemorrhage 104–5
- cerebral metastases 355–6, 369, 370
- cerebral toxoplasmosis 306
- cerebral vasculitis 122, 488
- cerebral venous thrombosis 112
- cerebrovascular disease see stroke
- cervical disc prolapse 413
- cervical facet dislocation 394–5, 400–1
- cervical radiculopathies, clinical presentation of 403
- cervical spine
degenerative conditions 402–5
trauma 496–7
- cervical spondylosis 402–5, 412, 413
- cervical spondylotic myelopathy 402–5
- Charcot–Marie–Tooth disease 268
- Chiari malformation 414–15, 420
- cholinesterase inhibitors, myasthenia gravis 240
- chorea 96
- chronic inflammatory demyelinating polyneuropathy (CIDP) 206–9
intravenous immunoglobulin 312
- chronic progressive external ophthalmoplegia (CPEO) 280
- chronic subdural haematoma 381
- closed angle glaucoma 76
- cluster headache 161, 162–3, 519–21
- cognitive testing 24–9
Mini-Mental State Examination 30–1
- colour vision, testing 8
- coma 80–2, 84
aetiology 80, 84
classification 82
depth 84
duration 84
EEG 444, 445
functional 519–21
general assessment of 80–1
investigations 82
neuroanatomy and neuropathology 80
prognosis 84
somatosensory evoked potentials 472
- common peroneal nerve 50
- communicating hydrocephalus 344
- compound muscle action potential (cMAP) 446–8
- computerized tomography (CT) 480
- cerebrovascular disease 486, 487–8
- cervical spine trauma 496, 496–7
- CNS infections 500–2
head injury 494
intracerebral haemorrhage 492
subarachnoid haemorrhage 490, 491
- computerized tomography angiography (CTA)
- cerebrovascular disease 487
subarachnoid haemorrhage 491
- COMT inhibitors, Parkinson's disease 182
- concentration, testing 24
- concentric needle electrode (CNE) 452
- conduction velocity (CV) 446–8
- consciousness, loss of 56–7
- constructional ability 28, 29
- contraception and epilepsy 142
and migraine 482
and stroke 156–7
- contrast-enhanced MRA 482
- coordination, testing 20
- cortical Lewy body disease 130
- cortical myoclonus 99
somatosensory evoked potentials 472
- corticobasal degeneration (CBD) 192
features 175
MRI findings 176
- cranial cavity 34
- cranial dural arteriovenous fistulae (dAVF) 342
- cranial nerve 1 6
cranial nerve 2 8–10
cranial nerve 3 11–15
cranial nerve 4 12–15
cranial nerve 5 16
cranial nerve 6 12–15
cranial nerve 7 16
cranial nerve 8 16
cranial nerve 9 17
cranial nerve 10 17
cranial nerve 11 17
cranial nerve 12 17
cranial neuropathies 200–1
craniectomy 351–3
craniotomy 351–3
- Creutzfeldt–Jakob disease (CJD) 132–5
EEG 433–5
familial 282
- cryptococcal infection, neuroradiology 500, 500–1
- cryptococcal meningitis associated with HIV 300, 301
- cysticercosis, neuro-radiology 501
- cysts, neuroradiology 501
- cytomegalovirus (CMV) infection 302
neuroradiology 500, 500–1

D

- Dandy–Walker malformation 415
- daytime sleepiness, excessive 86–9
- death, brainstem 314
- debulking of intracranial tumours 351–3
- deep tendon reflexes 22, 23
- degenerative spinal conditions
cervical spine 402–5
imaging 410–13
lumbar spine 406–8

- thoracic spine 406–7
 Dejerine–Sottas disease 268
 dementia 124–5
 aetiology 124
 Alzheimer's disease 126–7, 128–9, 282
 CADASIL 130, 148
 cortical Lewy body disease 130
 frontotemporal 128–9, 282
 HIV-associated 298
 inherited 282
 investigations 124–5
 Lewy body see Lewy body dementia
 multi-infarct 130
 Parkinson's disease 186
 semantic 128–9
 vascular 130
 demyelinating neuropathies, NCS abnormalities 450
 depression, Parkinson's disease 186
 dermatomes of upper and lower limbs 21, 36–7
 dermatomyositis (DM) 220–2
 intravenous immunoglobulin 312
 developmental abnormalities 414–16
 imaging 418–20
 developmental venous anomaly (DVA) 340
 diabetes mellitus (DM) 200 and CIDP 206
 diabetic cachectic neuropathy 200–1
 diabetic lumbosacral radiculo-plexus-neuropathy 200–1
 diabetic neuropathies 200, 200–1
 diabetic polyneuropathy 200–1
 diabetic truncal radiculo-neuropathy 200–1
 diffuse axonal injury (DAI) 383, 396
 diffuse cerebral dysfunction, and EEG 440–2
 diffuse encephalopathy 292–3
 diffusion-weighted MRI (DWI) 482
 digital subtraction angiography (DSA) cerebrovascular disease 486–8
 intracerebral haemorrhage 492
 subarachnoid haemorrhage 490, 491
 diphtheria 65
 disability scales 507
 dissociative non-epileptic attack disorder 144, 144–5
 distal sensory peripheral neuropathy 298–9
 Dix–Hallpike manoeuvre 258
 dizziness 254–5
 neurological causes 256–7
 non-neurological causes 262
 dominant hemisphere function, testing 26
 dopamine agonists, Parkinson's disease 181–2
 dopa-responsive dystonia (DRD) 279
 Doppler ultrasonography 480–1
 cerebrovascular disease 486–7
 downbeat nystagmus 14, 519–21
 dressing apraxia 28
 drug-induced parkinsonism 178
 drug-induced tremor 91
 Duchenne's muscular dystrophy (DMD) 272–3
 dural arteriovenous fistulae (dAVF) 342–3
 dysarthria 26
 dysphasia 26
 dystonia 100–1, 279
 dystonic tremor 90–1
- E**
- early onset ataxias 266
 edrophonium test, myasthenia gravis 239
 electroencephalography (EEG) 426, 428–9
 abnormal rhythms 432–5
 activity 428, 429
 diffuse cerebral dysfunction 440–2
 display 428
 electrode placement 428
 epilepsy 436–9
 intensive care unit 444–5
 long-term monitoring 429
 pathological slow waves 432
 periodic phenomena 432, 433–5
 recording 428
 use and abuse 430
 electromyography (EMG), needle 426
 abnormalities 454–5
 Guillain–Barré syndrome 462
 Lambert–Eaton myasthenic syndrome 465–6
 motor neuron disease 460
 myasthenia gravis 465–6
 myopathies 460, 461
 radiculopathies 460
 technical summary 452
 embolic infarcts, acute 119
 Emery–Dreyfuss muscular dystrophy 273–4
 empyema, subdural 306
 encephalitis neuroradiology 500
 viral 292–4
 encephalomyelitis with or without rigidity 246
 ependymoma, spinal 375
 epilepsy 136–7
 aetiology 136
 classification 136
 clinical features 137
 drug treatment 138–40, 139
 EEG 436–9
 hippocampal sclerosis 141
 incidence 136
 investigations 137
 management 138–41, 146–7
 seizures versus dissociative NEAD 144–5
 status epilepticus 146–7, 519–21
 women 142–3
 episodic ataxias 267
 Epley's manoeuvre 258–61, 260
 eponyms 515–21
 Epworth sleepiness scale 86–9, 87
 ergotamine preparations, migraine management 152
 essential tremor 90, 174
 evoked potentials (EPs) 426
 normal values 476–8

excessive daytime sleepiness 86–9
 excision of intracranial tumours 351–3
 extradural haematoma (EDH) 380
 extra-ocular eye movements 12
 eye movements 12, 13

F

Fabry's disease 286
 facial nerve 16
 facioscapulohumeral (FSH) muscular dystrophy 273–4
 false aneurysms 336
 familial Creutzfeldt–Jakob disease 282
 family history 2
 fasciculation potentials, needle EMG 454–5, 455–8
 fatal familial insomnia 282
 fatigue, multiple sclerosis 236–7
 Fazio-Londe syndrome 225
 femoral nerve 47
 fertility and epilepsy 142
 fibrillations, needle EMG 454, 455–8
 focal neurological syndromes, acute 68–9
 focal neuropathies, NCS abnormalities 450, 451
 foot drop 519–21
 forearm exercise test 216
 'freezing', Parkinson's disease 187
 Friedreich's ataxia 75, 266
 frontal executive function (frontal lobe), testing 25–6, 27
 frontotemporal dementia (FTD) 128–9, 282
 with MND 128, 128–9
 Fukuda test 58–60
 functional coma 519–21
 functional MRI (fMRI) 482
 fundoscopy with the direct ophthalmoscope 10
 fungal aneurysms 335
 fungal meningitis 289
 F wave 446–8

G

gait disturbances 22, 23
 gaze-evoked nystagmus (GEN) 14

generalized myasthenia gravis 239
 genetic neuropathies 268–70
 Gerstmann–Straussler–Scheinker syndrome 282
 Glasgow Coma Scale (GCS) 80–2, 377
 glioblastoma multiforme 365
 gliomas 350, 351–3, 354
 gliomatosis cerebri 366
 glossopharyngeal nerve 17
 GM1 gangliosidosis 286
 GM2 gangliosidosis 286
 Guillain-Barré syndrome (GBS) 65, 202–5
 intravenous immunoglobulin 312
 NCS and needle EMG findings 462

H

haemangioblastoma 356, 368
 Hallpike's manoeuvre 256, 258–61
 Halmaygi test 519–21
 hand movements, alternating 25–6, 27
 hangman's fracture 393–4, 399
 headache
 acute (thunderclap) 62–3
 clinical pearls 519–21
 cluster 161, 162–3, 519–21
 hypnic 161
 idiopathic intracranial hypertension 166–7
 migraine see migraine
 paroxysmal hemicrania 160
 primary short-lasting 145
 SUNCT 160
 trigeminal neuralgia 164–5
 head impulse test 58–60
 head injuries 376–9
 assessment 376
 classification 378–9
 Glasgow Coma Scale 80–2, 377
 imaging 386–91
 management 378–9, 380–4
 neuroradiology 494
 pathophysiology 376
 head thrust test 519–21
 heavy metal poisoning 65
 hemispatial neglect 28, 29
 hemispheric lesions 257
 hereditary ataxias 266, 266–7
 hereditary metabolic diseases 286
 hereditary neuropathy with liability to pressure palsies (HNPP) 268
 hereditary sensory and autonomic neuropathies (HSAN) 270
 hereditary sensory neuropathies (HSN) 270
 herpes simplex infection, neuroradiology 500
 hippocampal sclerosis in epilepsy 141
 history taking 2
 HIV 296
 neurological disorders due to 298–9
 neuroradiology 500–1
 opportunistic infections associated with 300–2
 HIV-associated dementia (HAD) 298
 HIV encephalopathy 307
 neuroradiology 500–1
 Hoehn and Yahr scale 510
 Holmes's tremor 91
 homonymous hemianopia 8–10
 Hoover's sign 519–21
 hormone replacement therapy (HRT) and migraine 157
 Horner's syndrome 11, 80–1
 H reflex 446–8
 HSV encephalitis 304
 human immunodeficiency virus see HIV
 Huntington's disease 278
 hydrocephalus 257, 344–6
 hydrocephalus ex vacuo 344
 hyperkalaemic periodic paralysis 65
 hypersensitivity vasculitis 212
 hyperventilation 262
 hypnic headache 161
 hypoglossal nerve 17
 hypokalaemic periodic paralysis 65
 hypopnoea 88

- I**
- idiopathic intracranial hypertension (IIH) 166–7
 - idiopathic Parkinson's disease (IDH) 176
 - idiopathic stabbing headache (ISH) 161
 - immunoglobulin, intravenous 312–13
 - immunosuppressants, myasthenia gravis 241
 - inclusion body myositis (IBM) 220, 221, 222
 - intravenous immunoglobulin 312
 - infectious cerebral aneurysms 335
 - inferior quadrantanopia 9
 - inflammatory myopathy 65
 - inherited dementias 282
 - inherited mitochondrial disorders 280–1
 - inherited movement disorders 278–9
 - inherited myopathies 272–4
 - inherited neurocutaneous syndromes 284–5
 - insomnia, fatal familial 282
 - insulin neuritis 200–1
 - intensive care unit, EEG in the 444–5
 - internal carotid artery, critical stenosis of 120
 - internuclear ophthalmoplegia (INO) 12, 519–21
 - interventional neuroradiology 485
 - intracerebral haematoma 382
 - intracerebral haemorrhage 104–5
 - neuroradiology 492
 - prevention 110
 - intracranial abscess 305
 - intracranial haemorrhage (ICH)
 - imaging 330–3
 - spontaneous 328–9
 - treatment 108–9
 - intracranial tumours 350–3
 - imaging 360–70
 - management 354–8
 - intravenous immunoglobulin 312–13
 - ischaemic stroke 104–5
 - prevention 110–11
 - treatment 108–9
 - Ishihara colour plates 8
 - isolated peripheral nerve vasculitis (IPNV) 212, 213
- J**
- Jaeger reading charts 8
 - jaw supporting sign 519–21
 - Jefferson (C1) fracture 392, 393
 - jerk nystagmus 14, 15
 - junctional scotoma 9
 - juvenile myoclonic epilepsy (JME) 137
- K**
- Kearns–Sayre syndrome (KSS) 280
 - Kennedy's syndrome 225
 - Kleine–Levin syndrome 519–21
 - Kurtzke expanded disability status scale 507
- L**
- labour and epilepsy 142–3
 - Lambert–Eaton myasthenic syndrome (LEMS) 65, 245, 251, 252
 - NCS and needle EMG findings 465–6
 - language function, testing 26, 27
 - aphasias 26
 - late onset ataxias 266
 - lateral cutaneous nerve of thigh 47
 - lateral sclerosis, primary 224–5
 - lead poisoning 65
 - Leber's hereditary optic neuropathy (LHON) 280
 - levodopa therapy, Parkinson's disease 180
 - Lewy body dementia 130
 - EEG 441
 - features 175
 - management 186
 - motor neuron disease–dementia syndrome 224–5
 - Lhermitte's sign 519–21
 - limb–girdle muscular dystrophy syndromes (LGMD) 272–3
 - limbic encephalitis 245, 246, 247
 - limb movement disorder, periodic 89
 - lower limb
 - dermatomes 9, 37
 - examination 18–23
 - innervation 46–54
 - somatosensory evoked potentials 470, 471
 - lower spinal cord infarct 123
 - lumbar canal stenosis 407–8, 419, 519–21
 - lumbar intervertebral disc prolapse 406–7, 418
 - lumbar puncture (LP) 308–11, 519–21
 - lumbosacral plexus 46
 - Luria 3 step test 25–6, 27
- M**
- macroadenoma 361
 - magnetic resonance angiography (MRA) 482
 - cerebrovascular disease 486–7, 488
 - subarachnoid haemorrhage 490, 491
 - magnetic resonance imaging (MRI) 481–2
 - cerebrovascular disease 486, 487–8
 - cervical spine trauma 496–7
 - CNS infections 500, 501–2
 - head injury 494
 - infectious diseases 304–11
 - intracerebral haemorrhage 492
 - subarachnoid haemorrhage 490, 491
 - magnetic resonance spectroscopy (MRS) 482
 - magnetic resonance venography (MRV) 487–8
 - Marcus–Gunn pupil 10
 - MCA temporary infarct, acute 118
 - medial cutaneous nerve 44
 - median nerve 40
 - medical history 2
 - melanoma metastasis 369
 - MELAS 280, 281
 - memory, testing 24

- Ménière's disease 254–5, 258
- meningiomas 354, 341
spinal 374
- meningitis 307
bacterial 288–91
cryptococcal 300, 301
fungal 289
neuroradiology 500
tuberculous 288, 289, 501–2
viral 289
- meningocele 416
- menopause and migraine 157
- menstrual migraine 156
- MERRF 280
- metabolic diseases, hereditary 286
- metachromatic leucodystrophy 286
- metastasis, intramedullary 375
- midbrain tremor 91
- migraine 148–9, 150
clinical features 148–9
differential diagnosis 150
epidemiology 148
IHS criteria 150
investigations 150
management 152–3, 154–5
menstrual 156
pathophysiology 148
prophylaxis 154–5
retinal migraine 76–7, 148–9
stepped care regimen 152–3
triggers 148–9
variants 148–9
vertigo 254–5
women 156–8
- Mini-Mental State Examination (MMSE) 29, 30–1
- mitochondrial disorders with ataxia 72–5
inherited 280–1
- mitochondrial encephalopathy with lactic acidosis and stroke-like episodes (MELAS) 280, 281
- mitochondrial epilepsy with ragged red fibres (MERRF) 280
- Miyoshi's myopathy 273
- modified Hoehn and Yahr scale 510
- molecular diagnosis, muscle disorders 217
- monoclonal gammopathy, CIDP in association with 207–8
- monocular transient visual loss 76
- mononeuropathies 200–1
- motor conduction velocity (MCV) 446–8
- motor neuron disease 224–5, 226–7
aetiology 224
causes 225
clinical features 224–5
intravenous immunoglobulin 312
investigations 226
management 226–7
mimics 225
NCS and EMG 460
- motor-neuron disease–dementia syndrome 224, 224–5
- motor neuron syndromes 250
- movement disorders, inherited 278–9
- multifocal motor neuropathy with conduction block (MMN-CB) 210–11, 312
- multi-infarct dementia 130
- multiple sclerosis (MS) 228–9, 230–5, 236–7
clinical features 228–9
course 229
diagnosis 230, 231
differential diagnosis 234
epidemiology 228
intravenous immunoglobulin 312
investigations 230, 232, 233
Kurtzke expanded disability status scale 507
management 236–7
pathogenesis 228
somatosensory evoked potentials 472
- multiple sleep latency test (MSLT) 88–9
- multiple system atrophy (MSA) 188–9
features 175
MRI findings 176
muscle biopsy 217
- muscle disorders
classification 214
clinical features 214–15
- investigations 216–18
- muscle strength
grading system 19
testing 18, 19
- musculocutaneous nerve 39
- myasthenia gravis (MG) 65, 238–9, 240–3
clinical features 238
differential diagnosis 239
epidemiology 238
intravenous immunoglobulin 241, 312
investigations 239
management 240–3
NCS and needle EMG findings 464, 465–6
pathophysiology 238
- myelography 484
- myelomeningocele 416
- myoclonus 98–9, 245, 248, 252
- myokymia, needle EMG 454–5
- myopathic processes, needle EMG 456, 461
- myopathies
HIV-associated 299
inherited 272–4
NCS and EMG in 460
myositis 312
- myotomes 19
- myotonic dystrophy (MD) 276

N

- narcolepsy 88–9
- neck flexion weakness 519–21
- needle electromyography
see electromyography (EMG), needle
- nerve action potential (NAP) 446–8
- nerve conduction studies (NCS) 426
Guillain-Barré syndrome 462
Lambert-Eaton myasthenic syndrome 465–6
- motor neuron disease 460
- myasthenia gravis 464, 465–6
- myopathies 460
normal values 476–8

- peripheral nerve disorders 450–1
 radiculopathies 460
 technical summary 446–8
 neuritis, acute 79
 neuroanatomy
 cranial cavity 34
 cross-sections of brain and spinal cord 52
 dermatomes of upper and lower limbs 36–7
 innervation of lower limbs 46–54
 innervation of upper limbs 38–44
 neurocutaneous syndromes, inherited 284–5
 neurofibroma, spinal 373
 neurofibromatosis 1 (NF1) 284
 neurofibromatosis 2 (NF2) 284
 neurogenetic disorders 264
 neurogenic processes, needle EMG 455–8
 neurological examination 4
 bedside cognitive testing 24–9
 cranial nerve 1 6
 cranial nerve 2 8–10
 cranial nerves 3, 4 and 6 12–15
 cranial nerves 5 and 7–12 16–17
 Mini-Mental State Examination 30–1
 upper and lower limbs 18–23
 neurological history taking 2
 neuromuscular transmission disorders, NCS and EMG findings in 464–6
 neuromuscular weakness, acute 64–5
 neuromyelitis optica, differential diagnosis 234
 neuromyotonia, needle EMG 454–5
 neuronavigation 351–3
 neuropathic tremor 91
 neuropathy–ataxia–retinitis pigmentosa (NARP) 280
 neurophysiology studies, muscle disorders 216–17
 neuroradiology
 cerebrovascular disease 486–8
 cervical spine trauma 496–7
 CNS infections 500–2
 head injury 494
 interventional 485
 intracerebral haemorrhage 492
 subarachnoid haemorrhage 490–1
 techniques 480–5
 tumours 498
 neurosarcooidosis, differential diagnosis 234, 235
 Niemann–Pick type C 286
 Nonaka myopathy 273
 non-communicating hydrocephalus 344
 non-dominant hemisphere function, testing 28, 29
 non-epileptic attack disorder (NEAD) 144–5
 non-progressive bilateral sudden visual loss 77
 non-progressive unilateral sudden visual loss 76, 76–7
 normal pressure hydrocephalus (NPH) 344, 346
 nuclear isotope studies 484
 nystagmus 14, 15
 downbeat 14, 519–21
 vertigo 58–60, 258, 259
- O**
- obstructive hydrocephalus 344
 obstructive sleep apnoea/hypopnoea syndrome (OSAHS) 88
 obturator nerve 48
 ocular myasthenia gravis 239, 242
 oculocephalic manoeuvre 80–1
 oculomotor nerve 11, 12–15
 oculovestibular test 80–1
 odontoid peg fractures 393–4, 411
 ‘off balance’ neurological causes 256–7
 non-neurological causes 262
 olfactory nerve 6
 ophthalmoplegic migraine 148–9
 Oppenheim’s dystonia 279
 opsochonus 245, 248, 252
 optic nerve 8–10
 optic neuritis, acute 79
 orientation, testing 24
 orthodromic nerve conduction studies 446–8
- P**
- palatal tremor 92
 papilloedema 166–7
 parafalcine meningioma 341
 paraneoplastic disorders 244–5
 central nervous system 246
 intravenous immunoglobulin 312
 investigations and management 252
 peripheral nervous system 250–1
 parasitic infections, neuro-radiology 501
 parenchymal tuberculosis 309
 parkinsonism
 causes 170
 clinical features 172–3
 diagnosis 172, 175
 drug-induced 178
 vascular 175
 Parkinson’s disease (PD) 278
 aetiology 170
 clinical features 172–3
 clinical pearls 519–21
 dementia 186
 depression 186
 diagnosis 172, 174, 175
 differential diagnosis 172
 epidemiology 170
 excess salivation 187
 exclusion criteria 172
 ‘freezing’ 187
 Hoehn and Yahr scale 510
 investigations 174, 176
 medical management 180–2, 184, 186–7
 pathophysiology 170
 psychosis 186
 sleep disturbance 186

surgical treatment 184
 paroxysmal hemicrania 160, 161, 162
 penetrating head injuries 382–3
 periodic limb movement disorder 89
 peripheral labyrinthine disorder (PLD) 256
 peripheral nerve disorders 194–5
 clinical approach 194–5
 diagnosis 196–7
 HIV-associated 298–9
 investigations 198–9
 NCS abnormalities 450–1
 peripheral neuropathy 257
 peroneal nerve, common 50
 PET 484
 phase contrast (PC) MRA 482
 pilocytic astrocytoma 367
 pituitary macroadenoma 361
 plain radiography 480
 cervical spine trauma 496–7
 plasma exchange, myasthenia gravis 241
 poisoning, heavy metal 65
 polymyositis (PM) 220–2
 intravenous immunoglobulin 312
 polyradiculoneuropathy associated with HIV 299
 porphyria, acute intermittent 65
 positron emission tomography (PET) 484
 posterior cord 42
 prednisolone, myasthenia gravis 240
 pregnancy
 and epilepsy 142–3
 and migraine 158
 primary CNS lymphoma 354–5, 372
 primary dystonia 279
 primary lateral sclerosis 224–5
 primary orthostatic tremor 91, 257
 primary short-lasting headaches 160–1
 prion diseases 282
 progressive bulbar palsy 224–5

progressive multifocal leucoencephalopathy (PML) 302
 neuroradiology 500–1
 progressive muscular atrophy (PMA) 224–5
 progressive supranuclear palsy (PSP) 190–1
 features 175
 MRI findings 176
 prosopagnosia 28
 proximal myotonic myopathy (PROMM) 272–3
 proximal nerve conduction, evaluation of 448
 pseudo-aneurysms 336
 pseudoseizures 144–5
 pseudotumour cerebri 166–7
 psychogenic tremor 92
 psychosis, Parkinson's disease 186
 Pulfrich's phenomenon 77–8
 pupillary reactions 10
 defects 11
 pursuit 12

R

radial nerve 42
 radiculopathies, NCS and EMG in 460
 Rankin stroke disability scale 510
 Rasmussen's syndrome 312
 retinal migraine 76–7, 148–9
 retinopathy 245, 248
 retrograde memory, testing 24
 rhombencephalitis 248
 Riley–Day syndrome 270
 Rinne's test 16
 Roger's sign 16
 Romberg's sign 22
 rubral tremor 91

S

saccades, examination 12
 saccular aneurysms 491
 salivation, excess (Parkinson's disease) 187
 sciatic nerve 49
 Segawa's disease 279
 seizures 383
 selegiline, Parkinson's disease 182

semantic dementia 128–9
 Semont's manoeuvre 258–61
 sensory ataxia 72–5
 sensory conduction velocity (SCV) 446–8
 sensory extinction 28
 sensory neglect 28
 sensory nerve action potentials (SNAPs) 446–8
 sensory neuropathy/neuronopathy 250
 sensory testing, upper and lower limbs 20, 21
 short-lasting unilateral neuralgiform headache with conjunctival injection and tearing (SUNCT) 160, 161
 shoulder shrug 519–21
 shunt infection 348
 shunts, complications of 348
 single photon emission computed tomography (SPECT) 484
 sleep apnoea 88
 sleep disturbance, Parkinson's disease 186
 sleepiness, excessive daytime 86–9
 smooth pursuit 12
 Snellen chart 8
 social history 2
 somatosensory evoked potentials (SSEPs) 470–2
 space-occupying lesions 380
 spasticity, multiple sclerosis 236, 236–7
 spastic paraparesis 70, 70–1
 SPECT 484
 spina bifida 416
 spina bifida occulta 416
 spinal cord cross-section 53
 spinal cord disorders 257
 spinal cord infarct 123
 spinal dural arteriovenous fistulae (dAVF) 343
 spinal dysraphism 416, 420
 spinal injuries 392–5
 imaging 396–401
 spinal interneuronitis 246
 spinal myoclonus 99
 spinal stability 392
 spinal tumours, imaging of 372–5

- spontaneous intracranial haemorrhage 328–9
- spontaneous vertigo 254–5
- sporadic Creutzfeldt–Jakob disease (sCJD) 132, 133, 134
- status epilepticus, management of 146–7, 519–21
- Steele–Richardson–Olszewski syndrome see progressive supranuclear palsy
- stereotaxy 351–3
- stiff person syndrome 245, 252
- intravenous immunoglobulin 312
- straight sinus thrombosis 114–15, 116, 117
- stroke (cerebrovascular disease) 104–7
 - aetiology 104–5
 - clinical features 105–6
 - and contraception 156–7
 - imaging 107
 - investigations 106
 - management 108–9
 - and migraine 156–7
 - neuroradiology 236–7, 486–8
 - prevention 110–11
 - Rankin stroke disability scale 510
 - risk factors 105
- Sturge–Weber syndrome 285
- subacute cerebellar degeneration 245
- subacute sensory neuropathy 245
- subarachnoid haemorrhage (SAH) 104–5, 316–18
 - EEG 433–5
 - imaging 320–6
 - neuroradiology 490–1
 - thunderclap headache 62–3, 351–3
 - traumatic 382
- subaxial (C3–C7) fractures 394
- subdural empyema 306
- subdural haematoma 381, 391
- subscapular removal of intracranial tumours 351–3
- SUNCT 160, 161
- superficial tendon reflexes 22, 23
- superior quadrantanopia 9
- swinging torch test 10
- syringomyelia 422–3
- systemic necrotizing vasculitis 212
- T**
- Tangier's disease 286
- task-specific tremor 91
- tendon reflexes 22, 23
- tensilon test, myasthenia gravis 239
- thalamic tremor 91
- thoracic disc prolapse 406
- thoracolumbar fractures 395
- thunderclap headache 62–3
- thymectomy, myasthenia gravis 241–2
- tibial nerve 49
- tics 94
- tonic pupil 11
- toxoplasmosis 306
 - HIV-associated 300, 301
 - neuroradiology 500–1
- transcranial Doppler 480–1
- transient visual obscurations 76
- transverse myelitis, acute 65
- traumatic intracranial aneurysms 336
- traumatic SAH 382
- tremor 90–2
 - essential 90, 174
 - primary orthostatic 257
- trigeminal nerve 16
- trigeminal neuralgia 164–5, 161
- triptans, migraine management 152, 153
- trochlear nerve 12–15
- tuberculoma, neuroradiology 501–2
- tuberculosis
 - neuroradiology 501–2
 - parenchymal 309
- tuberculous meningitis 288, 289
- neuroradiology 501–2
- tuberous sclerosis 284
- tumours
 - intracranial 350–3, 354–8, 360–70
 - neuroradiology 498
 - spinal 372–5
- U**
- Uhthoff's phenomenon 77–8
- ulnar nerve 41, 44
- ultrasonography (USS) 480–1
 - cerebrovascular disease 486–7
- University of Pennsylvania smell identification test (UPSIT) 6
- unsteadiness 254–5
 - neurological causes 256–7
 - non-neurological causes 262
- Unterberger's test 16, 58–60
- upbeat nystagmus 14
- upper limbs
 - dermatomes 21, 36–7
 - examination of 18–23
 - innervation 38–44
 - somatosensory evoked potentials 470, 471
- V**
- vacuolar myelopathy 298
- vagus nerve 17
 - stimulation 140
- variant Creutzfeldt–Jakob disease (vCJD) 134–5
- vascular dementia 130
- vascular parkinsonism 175
- vasculitic neuropathy 65, 212–13
- vasculitis associated with connective tissue disorders 212
- venous thrombosis, neuroradiology 487, 487–8
- ventricular tumours 357, 360
- verbal fluency test 25–6
- vertebrobasilar migraine 148–9

- vertigo 254–5
 - acute 58–61
 - BPPV 254–5, 258–61
 - vestibular Schwannoma 357–8, 362, 363
 - viral encephalitis 292–4
 - viral meningitis 289
 - vision loss of sudden onset with progression 77–8
 - visual acuity (VA) 8
 - visual evoked responses (VERs) 468–9
 - visual failure, acute 76–9
 - visual field 8
 - defects 8–10
 - visual pathway 8–10
 - Von Hippel–Lindau disease 284
- W**
- Weber's lateralization test 16
 - Welander's myopathy 273
 - Wernicke's aphasia 26
 - Wilson's disease 100
 - women
 - epilepsy 142–3
 - migraine 156–8
 - myasthenia gravis 242
- X**
- xanthochromia 62–3
 - X-linked dystrophy 272–3